

CPC Emergency Medicine

Volume V, Number 2, May 2021

Open Access at www.cpcem.org

ISSN: 2474-252X

Clinical Practice and Cases in Emergency Medicine

In Collaboration with the *Western Journal of Emergency Medicine*

Clinicopathological Cases from the University of Maryland

- 134** **55-year-old Male with Fatigue**
Nichols J, Guyther J, Bontempo LJ, ZDW Dezman

Medial Legal Case Reports

- 139** **Physician and Pharmacist Liability: Medicolegal Cases That are Tough Pills to Swallow**
Spaderna M, Bennett M, Arnold R, Weintraub E

Case Series

- 144** **A Pain in the Butt: A Case Series of Gluteal Compartment Syndrome**
Jackson JR, Schreyer K

Case Reports

- 148** **Nebulized Tranexamic Acid for Pediatric Post-tonsillectomy Hemorrhage: A Report of Two Cases**
Minotti B, Rabon L, Mayer-Hirshfeld I, McGreevy J
- 152** **The “Spiked Helmet” Sign Associated with ST-Elevation Myocardial Infarction: A Case Report**
Logan M, Scheler J, Sieber R, Scheler E
- 155** **Legionella Pneumonia on Point-of-care Ultrasound in the Emergency Department: A Case Report**
Lopez RW, Hysell MK, Long JP, Longobardi J
- 159** **Angioedema Secondary to tPA Use in Acute Ischemic Stroke Patient with Hypertension: A Case Report**
Kim C, Hladik A
- 163** **Transient Quadriplegia: A Case-Based Approach to Cervical Trauma**
Jabola R, Boswell B, Lutz RH, Casey J, Ceraulo A
- 167** **Spontaneous Ureteric Rupture and Its Implications in the Emergency Department: A Case Report**
Chua TWL, Wong E

Contents continued on page iii



UC Irvine Health





**ACOEP stands with all emergency
physicians and providers on the
front line. We thank you for your
tireless work and effort.**



www.acoep.org

Clinical Practice and Cases in Emergency Medicine

Indexed in PubMed and full text in PubMed Central

Rick A. McPheeters, DO, Editor-in-Chief
Kern Medical/UCLA- Bakersfield, California

Mark I. Langdorf, MD, MHPE, Senior Associate Editor
University of California, Irvine School of Medicine- Irvine, California

Shahram Lotfipour, MD, MPH, Senior Associate Editor
University of California, Irvine School of Medicine- Irvine, California

Shadi Lahham, MD, MS, Associate Editor
University of California, Irvine School of Medicine- Irvine, California

Manish Amin, DO, Associate Editor
Kern Medical/UCLA- Bakersfield, California

John Ashurst, DO, Decision Editor/ ACOEP Guest Editor
Kingman Regional Health Network, Arizona

Anna McFarlin, MD, Decision Editor
Louisiana State University Health Science Center- New Orleans, Louisiana

Austin Smith, MD, Decision Editor
Vanderbilt University Medical Center-Nashville, Tennessee

Christopher Sampson, MD, Decision Editor
University of Missouri- Columbia, Missouri

Joel Moll, MD, Decision Editor
Virginia Commonwealth University School of Medicine- Richmond, Virginia

Scott Goldstein, DO, Decision Editor
Sidney Kimmel College of Medicine- Philadelphia, Pennsylvania

Steven Walsh, MD, Decision Editor
Einstein Medical Center Philadelphia-Philadelphia, Pennsylvania

Melanie Heniff, MD, Decision Editor
University of Indiana School of Medicine- Indianapolis, Indiana

Gentry Wilkerson, MD, Decision Editor
University of Maryland School of Medicine

Rachel A. Lindor, MD, JD, Decision Editor
Mayo Clinic College of Medicine and Science

Jacqueline K. Le, MD, Decision Editor
Desert Regional Medical Center

Christopher San Miguel, MD, Decision Editor
Ohio State University Wexner Medical Center

Editorial Board

Amin A. Kazzi, MD, MAAEM
The American University of Beirut, Beirut,
Lebanon

Anwar Al-Awadhi, MD
Mubarak Al-Kabeer Hospital, Jabriya,
Kuwait

Arif A. Cevik, MD
United Arab Emirates University
College of Medicine and Health Sciences, Al
Ain, United Arab Emirates

Abhinandan A. Desai, MD
University of Bombay Grant Medical
College, Bombay, India

Bandr Mzahir, MD
King Fahad Medical City, Riyadh, Saudi
Arabia

Barry E. Brenner, MD, MPH
Case Western Reserve University

Brent King, MD, MMM
University of Texas, Houston

Daniel J. Dire, MD
University of Texas Health Sciences Center
San Antonio

David F.M. Brown, MD
Massachusetts General Hospital/Harvard
Medical School

Edward Michelson, MD
Texas Tech University

Edward Panacek, MD, MPH
University of South Alabama

Erik D. Barton, MD, MBA
Icahn School of Medicine, Mount Sinai,
New York

Francesco Dellacorte, MD
Azienda Ospedaliera Universitaria "Maggiore
della Carità," Novara, Italy

Francis Counselman, MD
Eastern Virginia Medical School

Gayle Galleta, MD
Sørlandet Sykehus HF, Akershus
Universitetssykehus, Lorenskog, Norway

Hjalti Björnsson, MD
Icelandic Society of Emergency Medicine

Jacob (Kobi) Peleg, PhD, MPH
Tel-Aviv University, Tel-Aviv, Israel

Jonathan Olshaker, MD
Boston University

Katsuhiko Kanemaru, MD
University of Miyazaki Hospital, Miyazaki, Japan

Khrongwong Musikatavorn, MD
King Chulalongkorn Memorial Hospital,
Chulalongkorn University, Bangkok, Thailand

Leslie Zun, MD, MBA
Chicago Medical School

Linda S. Murphy, MLIS
University of California, Irvine School of
Medicine Librarian

Nadeem Qureshi, MD
St. Louis University, USA
Emirates Society of Emergency Medicine,
United Arab Emirates

Niels K. Rathlev, MD
Tufts University School of Medicine

Pablo Aguilera Fuenzalida, MD
Pontificia Universidad Católica de Chile,
Región Metropolitana, Chile

Peter A. Bell, DO, MBA
Liberty University
College of Osteopathic Medicine

Peter Sokolove, MD
University of California, San Francisco

Robert M. Rodriguez, MD
University of California, San Francisco

Robert Suter, DO, MHA
UT Southwestern Medical Center

Robert W. Derlet, MD
University of California, Davis

Rosidah Ibrahim, MD
Hospital Serdang, Selangor, Malaysia

Samuel J. Stratton, MD, MPH
Orange County, CA, EMS Agency

Scott Rudkin, MD, MBA
University of California, Irvine

Scott Zeller, MD
University of California, Riverside

Steven Gabaeff, MD
Clinical Forensic Medicine

Steven H. Lim, MD
Changi General Hospital, Simei, Singapore

Terry Mulligan, DO, MPH, FIFEM
ACEP Ambassador to the Netherlands Society of
Emergency Physicians

Vijay Gautam, MBBS
University of London, London, England

Wirachin Hoonpongmanont, MD, MSBATS
Siriraj Hospital, Mahidol University, Bangkok,
Thailand

Advisory Board

Amal Khalil, MBA
UC Irvine Health School of Medicine

Elena Lopez-Gusman, JD
California ACEP
American College of Emergency Physicians

Adam Levy, BS
American College of Osteopathic Emergency
Physicians

John B. Christensen, MD
California Chapter Division of AAEM

Lori Winston, MD
California ACEP
American College of Emergency Physicians
Kaweah Delta Healthcare District

Mark I. Langdorf, MD, MHPE
UC Irvine Health School of Medicine

Jorge Fernandez, MD
California ACEP
American College of Emergency Physicians
University of California, San Diego

Peter A. Bell, DO, MBA
American College of Osteopathic Emergency
Physicians
Liberty University, College of Osteopathic Medicine

Robert Suter, DO, MHA
American College of Osteopathic Emergency
Physicians
UT Southwestern Medical Center

Shahram Lotfipour, MD, MPH
UC Irvine Health School of Medicine

Brian Potts, MD, MBA
California Chapter Division of AAEM
Alta Bates Summit-Berkeley Campus

Editorial Staff

Leila Danishgar, BS
Editorial Director

Nicholas Gossett, BS
CPC-EM Associate Editorial Director
Associate Marketing Director

Maria Nguyen, BS
WestJEM Associate Editorial Director

June Casey, BA
Copy Editor

Alissa Fiorentino, BA
WestJEM Staff Liaison

Cassandra Saucedo, BS
CPC-EM Publishing Director

Ishan Shah, BS
CPC-EM Associate Publishing Director
Associate Marketing Director

Christine Louis, BS
WestJEM Publishing Director

Isabelle Nepomuceno, BS
WestJEM Associate Publishing Director
Associate Marketing Director

Official Journal of the California Chapter of the American College of Emergency Physicians, the American College of Osteopathic Emergency Physicians, and the California Chapter of the American Academy of Emergency Medicine



Available in MEDLINE, PubMed, PubMed Central, Google Scholar, eScholarship, DOAJ, and OASPA.

Editorial and Publishing Office: WestJEM/Department of Emergency Medicine, UC Irvine Health, 333 City Blvd, West, Rt 128-01, Orange, CA 92866, USA

Office: 1-714-456-6389; Email: Editor@westjem.org

Clinical Practice and Cases in Emergency Medicine

Indexed in PubMed and full text in PubMed Central

This open access publication would not be possible without the generous and continual financial support of our society sponsors, department and chapter subscribers.

Professional Society Sponsors

AMERICAN COLLEGE OF OSTEOPATHIC EMERGENCY PHYSICIANS
CALIFORNIA ACEP

CALIFORNIA CHAPTER DIVISION OF
AMERICAN ACADEMY OF EMERGENCY MEDICINE

Academic Department of Emergency Medicine Subscribers

Albany Medical College Albany, NY	INTEGRIS Health Oklahoma City, OK	Robert Wood Johnson University Hospital New Brunswick, NJ	University of Florida, Jacksonville Jacksonville, FL
American University of Beirut Beirut, Lebanon	Kaweah Delta Health Care District Visalia, CA	Rush University Medical Center Chicago, IL	University of Illinois at Chicago Chicago, IL
Arrowhead Regional Medical Center Colton, CA	Kennedy University Hospitals Turnersville, NJ	Southern Illinois University Carbondale, IL	University of Illinois College of Medicine Peoria, IL
Augusta University Augusta GA	Kern Medical Bakersfield, CA	St. Luke's University Health Network Bethlehem, PA	University of Iowa Iowa City, IA
Baystate Medical Center Springfield, MA	Lakeland HealthCare St. Joseph, MI	Stanford/Kaiser Emergency Medicine Residency Program Stanford, CA	University of Louisville Louisville, KY
Beaumont Hospital Royal Oak, MI	Lehigh Valley Hospital and Health Network Allentown, PA	Staten Island University Hospital Staten Island, NY	University of Maryland Baltimore, MD
Beth Israel Deaconess Medical Center Boston, MA	Loma Linda University Medical Center Loma Linda, CA	SUNY Upstate Medical University Syracuse, NY	University of Michigan Ann Arbor, MI
Boston Medical Center Boston, MA	Louisiana State University Health Sciences Center New Orleans, LA	Temple University Philadelphia, PA	University of Missouri, Columbia Columbia, MO
Brigham and Women's Hospital Boston, MA	Madigan Army Medical Center Tacoma, WA	Texas Tech University Health Sciences Center El Paso, TX	University of Nebraska Medical Center Omaha, NE
Brown University Providence, RI	Maimonides Medical Center Brooklyn, NY	University of Alabama, Birmingham Birmingham, AL	University of South Alabama Mobile, AL
Carl R. Damall Army Medical Center Fort Hood, TX	Maricopa Medical Center Phoenix, AZ	University of Arkansas for Medical Sciences Little Rock, AR	University of Southern California/Keck School of Medicine Los Angeles, CA
Conemaugh Memorial Medical Center Johnstown, PA	Massachusetts General Hospital Boston, MA	University of California, Davis Medical Center Sacramento, CA	University of Tennessee, Memphis Memphis, TN
Desert Regional Medical Center Palm Springs, CA	Mayo Clinic College of Medicine Rochester, MN	University of California Irvine Orange, CA	University of Texas, Houston Houston, TX
Doctors Hospital/Ohio Health Columbus, OH	Mt. Sinai Medical Center Miami Beach, FL	University of California, Los Angeles Los Angeles, CA	University of Texas Health San Antonio, TX
Eastern Virginia Medical School Norfolk, VA	North Shore University Hospital Manhasset, NY	University of California, San Diego La Jolla, CA	University of Warwick Library Coventry, United Kingdom
Einstein Healthcare Network Philadelphia, PA	Northwestern Medical Group Chicago, IL	University of California, San Francisco San Francisco, CA	University of Washington Seattle, WA
Emory University Atlanta, GA	Ohio State University Medical Center Columbus, OH	UCSF Fresno Center Fresno, CA	University of Wisconsin Hospitals and Clinics Madison, WI
Genesys Regional Medical Center Grand Blanc, Michigan	Ohio Valley Medical Center Wheeling, WV	University of Chicago, Chicago, IL	Wake Forest University Winston-Salem, NC
Hartford Hospital Hartford, CT	Oregon Health and Science University Portland, OR	University of Colorado, Denver Denver, CO	Wright State University Dayton, OH
Hennepin County Medical Center Minneapolis, MN	Penn State Milton S. Hershey Medical Center Hershey, PA	University of Florida Gainesville, FL	
Henry Ford Hospital Detroit, MI	Presence Resurrection Medical Center Chicago, IL		

State Chapter Subscribers

ARIZONA CHAPTER DIVISION OF THE
AMERICAN ACADEMY OF EMERGENCY MEDICINE
CALIFORNIA CHAPTER DIVISION OF THE
AMERICAN ACADEMY OF EMERGENCY MEDICINE
FLORIDA CHAPTER DIVISION OF THE
AMERICAN ACADEMY OF EMERGENCY MEDICINE

GREAT LAKES CHAPTER DIVISION OF THE
AMERICAN ACADEMY OF EMERGENCY MEDICINE
TENNESSEE CHAPTER DIVISION OF THE
AMERICAN ACADEMY OF EMERGENCY MEDICINE

UNIFORMED SERVICES CHAPTER DIVISION OF THE
AMERICAN ACADEMY OF EMERGENCY MEDICINE
VIRGINIA CHAPTER DIVISION OF THE
AMERICAN ACADEMY OF EMERGENCY MEDICINE

International Society Partners

EMERGENCY MEDICINE ASSOCIATION OF TURKEY
LEBANESE ACADEMY OF EMERGENCY MEDICINE
MEDITERRANEAN ACADEMY OF EMERGENCY MEDICINE

NORWEGIAN SOCIETY FOR EMERGENCY MEDICINE
SOCIEDAD ARGENTINA DE EMERGENCIAS

SOCIEDAD CHILENO MEDICINA URGENCIA
THAI ASSOCIATION FOR EMERGENCY MEDICINE

To become a *WestJEM* departmental sponsor, waive article processing fee, receive print and copies for all faculty and electronic for faculty/residents, and free CME and faculty/fellow position advertisement space, please go to <http://westjem.com/subscribe> or contact:

Alissa Fiorentino
WestJEM Staff Liaison
Phone: 1-800-884-2236
Email: sales@westjem.org

JOURNAL FOCUS

Clinical Practice and Cases in Emergency Medicine (CPC-EM) is a MEDLINE-indexed internationally recognized journal affiliated with the *Western Journal of Emergency Medicine* (WestJEM). It offers the latest in patient care case reports, images in the field of emergency medicine and state of the art clinicopathological and medicolegal cases. CPC-EM is fully open-access, peer reviewed, well indexed and available anywhere with an internet connection. CPC-EM encourages submissions from junior authors, established faculty, and residents of established and developing emergency medicine programs throughout the world.

Table of Contents *continued*

- 171 **Acute Demyelinating Encephalomyelitis Following Measles Infection Due to Vaccine Failure: A Case Report**
RJ McMickle, L Fryling, RJ Fleischman
- 174 **Arterial-embolic Strokes and Painless Vision Loss Due to Phase II Aortitis and Giant Cell Arteritis: A Case Report**
K Endres, O Anjum, N Costain
- 178 **Pneumopericardium after Laparoscopic Hernia Repair Presents with ST-segment Changes: A Case Report**
D Galindo, E Martin, D Franzen
- 182 **A Report of Two Cases: Unlearning Lactic Acidosis**
S Mohan, DS Goldfarb, RS Hoffman
- 186 **Point-of-care Ultrasound in Early Diagnosis of Cardiomyopathy in a Child with Viral Myocarditis: A Case Report**
A Gupta, T Eckenswiler
- 190 **Atezolizumab-induced Autoimmune Diabetes in a Patient with Metastatic Breast Cancer: A Case Report**
R Clontz, DM Dang, MA Hieger, BA Becker
- 194 **Rhabdomyolysis: A Case Report of an Extrapulmonary Presentation of *Mycoplasma pneumoniae***
M Gulenay, VA Sasson, K Taylor
- 198 **Point-of-care Ultrasound to Distinguish Subgaleal and Cephalohematoma: Case Report**
J Acuña, S Adhikari
- 202 **Can't Dissolve Me Now: A COVID-19 Provoked Venous Thromboembolism Breaks Through Apixaban: Case Report**
AW Arena, A Hussein, EJ Kurkowski, ML Kulkarni
- 206 **Reversible Total Vision Loss Caused by Severe Metformin-associated Lactic Acidosis: A Case Report**
A Koons, AM Amaducci, KD Katz
- 210 **A Traumatic Tick Bite: A Case Report**
D Finnin, C Hanowitz
- 214 **A Case Report of Cardiogenic Syncope Due to Loperamide Abuse: Acute Presentation and Novel Use of Buprenorphine**
DJ Betting, JA Chenoweth, AF Jarman

Policies for peer review, author instructions, conflicts of interest and human and animal subjects protections can be found online at www.cpcem.org.

Table of Contents *continued*

- 218 **Neonatal Parotitis: A Case Report**
A Gupta, T Kingdon, A McKernan
- 222 **When the Red Tide Rolls In: A Red Tide Associated Angioedema Case Report**
S Rabinowitz, JJ Solano
- 226 **Pediatric Innominate Artery Pseudoaneurysm Rupture in Vascular Ehlers-Danlos Syndrome: A Case Report**
A Vos, KM Burns
- 230 **Profound Weakness and Blurry Vision in a Pandemic: A Case Report**
JM O'Keefe, KJH Grall
- 234 **Chloroquine Ingestion to Prevent SARS-CoV-2 Infection: A Report of Two Cases**
J Graff, MG Thompson, Z Berriochoa, B Kuhn, AM Ruha, C Lipinski
- 239 **Metronidazole, an Uncommon Cause of Dizziness and Ataxia in the Emergency Department: A Case Report**
ME Starrs, OM Yenigun
- 242 **Salmonella Aortitis in an Elderly Male, a Rare but Deadly Cause of Abdominal Pain: A Case Report**
KM Yanusheski, S Kaur, M Eberhardt
- 246 **Accidental Arthrotomy Causing Aseptic Monoarthritis Due to Agave Sap: A Case Report**
ST Ontiveros, AB Minns

Images in Emergency Medicine

- 249 **Bilateral Luxatio Erecta Humeri**
MA Martinez-Romo, S Lotfipour, CE McCoy
- 251 **Adolescent Male with Severe Groin Pain Due to Traumatic Injury**
H Ohno, S Takeda, S Mitsuya, K Yamauchi
- 253 **A Young Boy with Neck Pain**
H Ohno, S Takeda, S Mitsuya, H Yoshihara, K Yamauchi
- 255 **Rare but Foreseeable: Rapidly Expanding Retropharyngeal Hematoma After Fall from Height**
A Bracey, CS Ahn, RN Barnicle, MP Frost, MN Leonard, BJ Wright
- 258 **Case of Displaced Glenoid Fracture After Fall: Subtle Findings with Significant Implications for Trauma Patients**
S Sebt, M Barden, E Leroux
- 261 **Hemithorax Westermark Sign Secondary to Complete Pulmonary Artery Occlusion from Pulmonary Embolus**
M Louthan, D Ng
- 263 **Ultrasonographic Findings in Fat Embolism Syndrome**
S Yonezaki, K Nagasaki, H Kobayashi
- 265 **Young Woman with Leg Lesions**
D Finnin

Clinical Practice and Cases in Emergency Medicine (CPC-EM) is a open-access Medline-indexed internationally recognized journal affiliated with the *Western Journal of Emergency Medicine* (WestJEM). CPC-EM is distributed electronically to 19,000 emergency medicine scholars. This includes our sponsors California ACEP, the American College of Osteopathic Emergency Physicians, California Chapter of AAEM, and over 83 academic department of emergency medicine subscribers and 8 AAEM State Chapters.

Table of Contents *continued*

- 267 **An Unusual ECG Artifact Caused by Faulty Cardiac Monitor Leads**
B Imhoff, W Casey
- 270 **“One Note Higher”: A Unique Pediatric Hand Fracture**
S Szymanski, M Zylstra, A Hull
- 273 **A Rare Case of Cranial Nerve VII Neuropraxia Associated with Alveolar Nerve Blocks**
S Allegra, R Church, V Sudireddy

Erratum

- 275 **This Article Corrects: “Subacute Presentation of Central Cord Syndrome Resulting from Vertebral Osteomyelitis and Discitis: A Case Report”**
T Dang, F Dong, G Fenati, M Rabiei, M Cerda, MM Neeki, S Wattenbarger

Clinical Practice and Cases in Emergency Medicine (CPC-EM) is a open-access Medline-indexed internationally recognized journal affiliated with the *Western Journal of Emergency Medicine* (WestJEM). CPC-EM is distributed electronically to 19,000 emergency medicine scholars. This includes our sponsors California ACEP, the American College of Osteopathic Emergency Physicians, California Chapter of AAEM, and over 83 academic department of emergency medicine subscribers and 8 AAEM State Chapters.

CPC**EM** Clinical Practice & Cases

CALL FOR SUBMISSIONS

-Patient Care Case Reports

-Images in Emergency Medicine

Fully open-access, peer reviewed, well indexed: CPC-EM is available anywhere with an internet connection at **CPCEM.org**

Clinical Practice and Cases in Emergency Medicine is an internationally recognized journal affiliated with the MEDLINE-indexed **Western Journal of Emergency Medicine**

CPC-EM encourages submissions from junior authors and countries with developing emergency medicine programs

IS NO DISABILITY INSURANCE A RISK YOU'RE WILLING TO TAKE?

COVID-19 HAS INCREASED THE RISKS OF PRACTICING EMERGENCY MEDICINE

LET US PROTECT YOUR LIFESTYLE

- EMERGENCY MEDICINE SPECIFIC POLICIES
- MAJOR DISABILITY & LIFE INSURANCE COMPANIES
- DISCOUNTS AVAILABLE INCLUDING MILITARY & FEDERAL
- NO MEDICAL EXAM REQUIRED
- CURRENT POLICY CHECKUP

 **DI 4 MDS**
DISABILITY INSURANCE SPECIALISTS
30+ YEARS OF EXPERIENCE

CONTACT NOW



Journal of Education & Teaching *in* Emergency Medicine

A publication of **CORD**

Education

We believe that all learners should benefit from active learning.

We are an online, open access, peer-reviewed journal-repository for EM educators in all major topic areas.

Scholarship

We believe educators should advance through the scholarship of their educational work. JETem gives you the opportunity to publish & distribute your outstanding, scholarly academic work.

Submit your content or contact us to become a reviewer!



visualem



small groups



tbl



simulation



lecture



oral boards



podcasts



curriculum



innovations

www.jetem.org



published by

eScholarship University of California

55-year-old Male with Fatigue

Jennifer Nichols, MD*

Jennifer Guyther, MD[†]

Laura J. Bontempo, MD, MEd[†]

Zachary D.W. Dezman, MD, MS, MS^{†‡}

*University of Maryland Medical Center, Department of Emergency Medicine, Baltimore, Maryland

[†]University of Maryland School of Medicine, Department of Emergency Medicine, Baltimore, Maryland

[‡]University of Maryland, Baltimore, Department of Epidemiology and Public Health, Baltimore, Maryland

Section Editor: Joel Moll, MD

Submission history: Submitted November 2, 2020; Revision received November 27, 2020; Accepted November 25, 2020

Electronically published April 16, 2021

Full text available through open access at http://escholarship.org/uc/uciem_cpccm

DOI: 10.5811/cpccm.2020.11.50651

This clinicopathological case presentation from the University of Maryland details the initial assessment and management of a 55-year-old, dialysis-dependent man with fatigue. We present how one of our emergency medicine faculty develops her differential when faced with this complaint. She describes how she arrives at the suspected diagnosis and the test she believes is needed to prove her hypothesis. The final surprising diagnosis is then revealed. [Clin Pract Cases Emerg Med. 2021;5(2):134–138.]

Keywords: *CPC; dialysis; shock.*

CASE PRESENTATION (DR. NICHOLS)

A 55-year-old male presented to the emergency department (ED) from his dialysis center with two days of fatigue and generalized weakness. He reported that he had been outside in the heat frequently and admitted to poor fluid intake. He received 250 milliliters (mL) of intravenous (IV) fluid prior to the initiation of dialysis. However, the session was terminated prematurely because the patient began feeling unwell. Emergency medical services (EMS) was called and the patient was transported to the ED. On arrival to the ED, EMS reported that they believed the patient was in supraventricular tachycardia based on their rhythm strip.

The patient's past medical history was significant for end stage renal disease (ESRD) due to focal segmental glomerulosclerosis, hypertension, secondary hyperparathyroidism, obstructive sleep apnea, chronic pancreatitis, and gastroesophageal reflux disease. He had an arteriovenous fistula placed in his left upper extremity and had a prior left inguinal hernia repair. He was prescribed the following: lidocaine patches, ranitidine, lisinopril, metoprolol succinate, pravastatin, B complex-C-folic acid vitamins, sevelamer carbonate, sildenafil, aspirin, and sodium bicarbonate. He was allergic to chlorhexidine, which resulted in a rash, as well as rosuvastatin, ezetimibe, and atorvastatin, all of which resulted in muscle cramps and an elevation in his serum creatine kinase. He smoked cigarettes

(12.5 pack years) and denied using smokeless tobacco, alcohol, or drugs.

On initial examination the patient was awake, alert, well-appearing, and appeared in no acute distress. He was afebrile (36.7° Celcius) with a heart rate of 142 beats per minute (bpm) and a blood pressure of 103/69 millimeters of mercury (mm Hg). He was breathing at a rate of 16 breaths per minute and was saturating at 96% on room air. He weighed 129 kilograms (kg) and was five feet 10 inches tall (1.8 meters) with a body mass index of 41.1 kg/meters². His head was normocephalic and atraumatic. His oropharynx was dry and without erythema or exudate. Extraocular movements were intact. Pupils were equally round and reactive to light. There was no eye discharge. His neck exhibited no jugular venous distension (JVD). His heart sounds were tachycardic but regular and no murmur was auscultated. He had intact distal pulses. He had normal respiratory effort and normal breath sounds, was not in respiratory distress, and had no wheezes. His abdomen was soft and non-tender. He had a left upper extremity fistula with a palpable thrill and audible bruit. There was no extremity edema, tenderness or deformity. He was alert and oriented to person, place, and time. His skin was warm and intact without diaphoresis. He had a normal mood and affect, and his behavior was normal.

His initial labs (Table), chest radiograph (CXR) (Image 1) and initial electrocardiogram (ECG) (Image 2) are shown. The

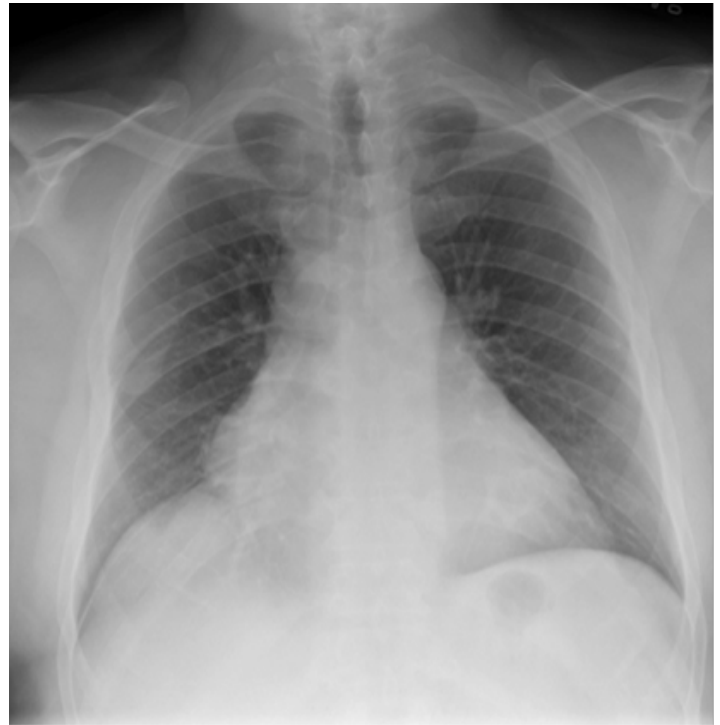
Table. Laboratory test results of a 55-year-old male on hemodialysis who presented to the emergency department with fatigue.

Laboratory test	Result	Normal range
Complete blood count		
White blood count	14.3 K/mcL	4.5-11 K/mcL
Hemoglobin	9.8 g/dL	12.6-17.4 g/dL
Hematocrit	30.3%	37-50%
Platelets	142 K/mcL	153-367 K/mcL
Chemistry		
Sodium	137 mmol/L	136-145 mmol/L
Potassium	4.6 mmol/L	3.5-5.1 mmol/L
Chloride	95 mmol/L	98-107 mmol/L
Bicarbonate	25 mmol/L	21-30 mmol/L
Anion gap	17	4-16
Blood Urea Nitrogen	51 mg/dL	9-20 mg/dL
Creatinine	17.05 mg/dL	0.66-1.25 mg/dL
Glucose	147 mg/dL	70-99 mg/dL
Calcium	9.7 mg/dL	8.6-10.2 mg/dL
Magnesium	2.7 mg/dL	1.6-2.6 mg/dL
Total Protein	7.8 g/dL	6.3-8.2 g/dL
Albumin	4.3 g/dL	3.5-5.2 g/dL
Aspartate Transaminase	22 units/L	17-59 units/L
Alanine Transaminase	25 units/L	0-49 units/L
Bilirubin Total	0.7 mg/dL	0.3-1.2 mg/dL
Alkaline Phosphatase	64 units/L	38-126 units/L
Cardiac Troponin I	0.02 ng/mL	<0.06 ng/mL

K, thousand; mcL, microliter; g, grams; dL, deciliter; mmol, millimole; L, liter; mg, milligram.

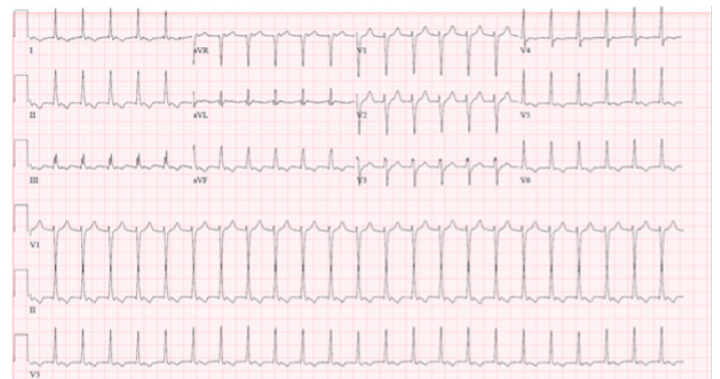
patient was initially thought to be in atrial flutter given his heart rate of approximately 150 bpm; however, on repeat ECG, the patient's heart rate was in the 120s bpm and his rhythm was thought to be most consistent with sinus tachycardia with premature atrial complexes. Therefore, given that the patient also appeared dehydrated, a 500 mL bolus of intravenous fluids (IVF) was given and the patient was observed. His heart rate improved to 100-110s bpm. Two hours later, however, his heart rate increased to 166 bpm and his blood pressure was 135/57 mm Hg. A repeat ECG was obtained (Image 3). At that time, he was thought to be in atrial fibrillation with rapid ventricular response. He was then given metoprolol 5 milligrams (mg) IV and his heart rate improved to 140 bpm.

Shortly thereafter, his heart rate increased to 164 bpm and his blood pressure was 110/58 mm Hg. He was given two 250-mL boluses of IVF and three doses of metoprolol 5 mg IV, five minutes apart. His heart rate improved to 98 bpm and his blood pressure decreased to 94/58 mm Hg. He appeared to be in normal sinus rhythm after these interventions. The patient then reported chest tightness and was given a dose of aspirin 324 mg. About one hour later, he became hypotensive (76/60 mm Hg) with a heart rate of 148 bpm. His rhythm was

**Image 1.** Chest radiograph of a 55-year-old male on hemodialysis who presented to the emergency department with fatigue.

interpreted as atrial fibrillation with rapid ventricular response. He was sedated with ketamine and cardioverted using a 100-joule biphasic shock, which resulted in conversion to sinus tachycardia with a rate of 105 bpm and blood pressure of 115/78 mm Hg. Subsequently, the patient was started on a heparin infusion. He had two serial troponins obtained, both of which were within normal limits (0.04 nanograms (ng)/mL and lastly 0.05 ng/mL).

While boarding in the ED awaiting admission to cardiology, the patient was reassessed three hours later and was found to be dizzy, diaphoretic, and pale, with a heart rate of 159 bpm and blood pressure of 92/55 mm Hg. An ECG

**Image 2.** Initial electrocardiogram of a 55-year-old male on hemodialysis who presented to the emergency department with fatigue.

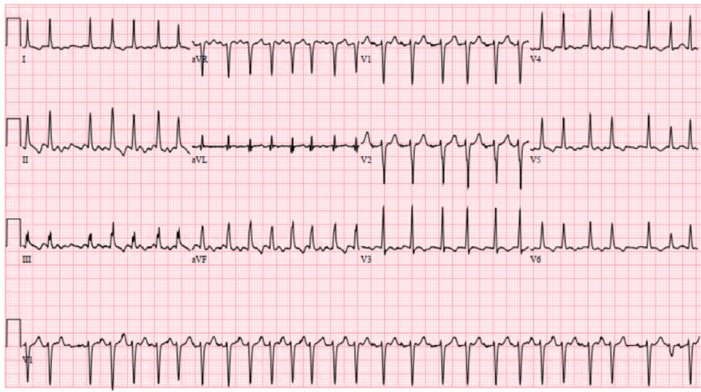


Image 3. Repeat electrocardiogram of a 55-year-old male on hemodialysis who presented to the emergency department with fatigue.

was obtained and read as atrial fibrillation with rapid ventricular response. He was given metoprolol 5 mg IV, metoprolol 12.5 mg orally, and an amiodarone bolus of 300mg IV followed by an infusion. Then a test was performed, and a diagnosis was made.

CASE DISCUSSION (DR. GUYTHER)

Based on the first few lines of the patient presentation, this case seems simple and straightforward: a middle-aged man with ESRD who was not feeling well and was dehydrated due to heat exposure, who was given IV fluids. He then develops unstable vital signs and decompensates while in the ED. Looking at the patient's chief complaint (fatigue and weakness), I feel fatigued myself. The combined differential of weakness, fatigue, and ESRD is overwhelming. I decided to look at the individual clues to narrow down and help me solve the puzzle of this patient's presentation.

The history is supposed to lead you to the diagnosis in most cases. Here our history of present illness is unhelpful. The patient went to dialysis, suggesting that he is compliant with his medications and medical treatments. He received a small bolus of IVF prior to dialysis initiation, which seems logical in the setting of poor oral intake and being outside in the heat, but he was unable to tolerate his full session of dialysis because he did not "feel well." At this point in the case, I am not sure what to do with that last piece of information, but I am concerned that such a small amount of fluid would make the patient feel he needs to stop his dialysis.

He seems to be on appropriate medications for his history of ESRD, including three antihypertensive medications. I did not gain any additional clues from his past surgical history, allergies, family history or social history. His extensive review of systems also did not add any helpful information.

Moving to the physical exam, his dry lips suggest low intravascular volume. His vital signs are significant for tachycardia to 142 bpm and, for this patient with a history of hypertension, a likely relative hypotensive blood pressure of

103/69 mm Hg. He is not in acute distress and he is alert and oriented to person, place and time, suggesting he isn't in shock due to these vital signs. It is also important to note that he has no fever, tachypnea, or hypoxia.

The results of his blood testing are consistent with what would be expected for a dialysis-dependent patient: mild anemia and thrombocytopenia, as well as an elevated blood urea nitrogen and creatinine. His troponin was normal. His CXR shows cardiomegaly, which would also be expected in patients with ESRD. The first ECG showed a rate of about 150 bpm with visible p-waves and t-wave inversions in the inferior and lateral leads. The patient was given a 500 mL bolus of IVF with improvement of his heart rate to 110 bpm. About three hours later the patient's heart rate was in the 160s bpm and his new ECG showed atrial flutter with variable conduction. His heart rate remained elevated and he became increasingly hypotensive despite multiple doses of beta blockers and fluid boluses. The patient then went into atrial fibrillation with a rapid ventricular response and required cardioversion in the setting of persistent hypotension. Looking through his history and medications, I found he did not have any known problems with dysrhythmias. The patient experienced some chest tightness and while his troponins increased slightly, I would expect an elevation after a tachydysrhythmic episode and a cardioversion.

Overall, there are two large pieces of this puzzle: ESRD and atrial tachydysrhythmias. I find it easier to focus first on the differential for fast heart rates compared to the complaints of dizziness and fatigue.

The patient was reported to be in supraventricular tachycardia by EMS. The initial ECG done in the ED showed concern for atrial flutter with variable conduction. The causes of atrial flutter include myocardial ischemia (MI), hypoxia, congestive heart failure (CHF), chronic obstructive pulmonary disease (COPD), pericarditis, and hyperthyroidism. Anything that causes irritation of the myocardium could cause a dysrhythmia. Myocardial ischemia and CHF should remain on the differential based on the patient's risk factors and CXR findings. The patient was never hypoxic and although he does have a 12.5 pack year history of smoking, he has no pulmonary or CXR findings to support the diagnosis of COPD, so this can be removed from the list. The patient does not have clinical manifestations of hyperthyroidism, aside from the tachycardia, and I would not have expected such a drastic decline from this pathology alone while in the ED.

When I cross-referenced this differential diagnosis of atrial flutter with the causes of atrial fibrillation, the diagnoses of CHF, cardiomyopathy, MI, and pericarditis remain high on the differential for this patient. Endocarditis can remain on the differential as the patient is at risk for bacteremia given his intermittent dialysis access and his elevated white blood cell count. Acquired or native cardiac valvular disease, like atrial septal defects and mitral stenosis, as well as the procedures needed to correct these defects, can cause atrial fibrillation,

but these are not supported by the patient's past medical history and exam. Noncardiac causes for atrial fibrillation include pulmonary embolism, pneumonia, and hypoxia, as well as alcohol or cocaine use, sepsis, and hyperthyroidism. His social history does not support substance abuse. I would expect the patient to have some hypoxia or shortness of breath with a massive pulmonary embolism, so this condition falls much lower down on my differential diagnosis.

I used the cardiac complications of ESRD to further refine my differential of MI, CHF, and endocarditis and less likely hyperthyroidism. The cardiac complications of ESRD include coronary artery disease, CHF, and pericardial effusion due to uremia. Although the patient was experiencing chest tightness and did have some ECG changes, his troponins did not significantly elevate and repeat ECGs did not show ST changes, so the patient probably wasn't taken to the cardiac catheterization lab to diagnose an MI. The patient likely has some underlying component of CHF, but he doesn't have the findings on physical exam or CXR to suggest a hypervolemia severe enough to cause a dysrhythmia. The patient is uremic on his labs, so he may have a uremic pericardial effusion.

Taking everything into account, especially how the patient decompensated after starting the heparin drip, my highest concern would be for a uremic pericardial effusion that has now converted into a hemorrhagic effusion with tamponade. An echocardiogram would confirm this diagnosis.

CASE OUTCOME (DR. NICHOLS)

The diagnostic test was an echocardiogram that demonstrated a pericardial effusion and cardiac tamponade. The patient underwent emergency pericardiocentesis with drain placement in the cardiac catheterization lab; 960 mL of dark red fluid was drained with subsequent improvement in the patient's hemodynamics. He was discharged on post-operative day 4.

RESIDENT DISCUSSION (DR. NICHOLS)

Cardiac tamponade is defined as compression of all cardiac chambers resulting in a reduction of venous return and thus a decrease in cardiac output.¹ There are four types: acute; subacute; low pressure; and regional. Acute cardiac tamponade presents with the classic symptoms of chest pain and dyspnea as well as the classic exam findings, which are Beck's triad (hypotension, JVD, and muffled heart sounds), tachycardia, and pulsus paradoxus. Tachycardia is a physiological compensation to offset the loss in cardiac output due to a decrease in stroke volume. Pulsus paradoxus is defined as a 10 mm Hg decrease in systolic pressure on inspiration and occurs because of reduction of left heart filling on inspiration.² Subacute tamponade is generally more insidious, with patients presenting with nonspecific symptoms such as chest discomfort or fullness, dyspnea, peripheral edema, or feeling easily fatigued. Low pressure occurs in patients who are severely hypovolemic (for example, those who experienced a traumatic hemorrhage, undergo

hemodialysis, or are over-diuresed).¹ Giving these patients an IVF challenge will actually elicit tamponade pathophysiology due to the increase in fluids in the pericardial sac. Regional tamponade occurs when there is a loculated or eccentric effusion or localized hematoma. It is important to emphasize that patients with low pressure or regional tamponade do not typically present with the classic physical exam, hemodynamic, and echocardiographic findings.

Etiologies of pericardial effusions are idiopathic, infectious, autoimmune/inflammatory, neoplastic, cardiac (post-cardiac injury [Dressler's syndrome], myocarditis, dissecting aortic aneurysm, early infarction pericarditis), traumatic, metabolic (hypothyroidism, uremia, ovarian hyperstimulation syndrome), or drug-induced (procainamide, isoniazid, and hydralazine). Idiopathic, infectious, and neoplastic causes are most common.³ Findings on ECG include the following: tachycardia; low voltage, electrical alternans (beat-to-beat changes in QRS amplitude or axis); and evidence of pericarditis (diffuse ST elevations, PR depressions, down-sloping TP segments).¹

Echocardiography can be used to identify the pericardial effusion and evaluate for signs of tamponade.⁴ These signs include the following: chamber collapse (diastolic collapse of the right atrium and ventricle as well as left-sided chamber collapse)^{4,5}; respiratory variations in volumes and flows (increased flow across mitral and tricuspid valves on inspiration)⁶; and inferior vena cava (IVC) dilation and decreased collapsibility.⁷ Right atrial collapse is highly sensitive and specific (100% and 82%, respectively).⁸ Right ventricular collapse is not as sensitive as it may be absent in patients with increased right ventricular pressure (for example, pulmonary hypertension, right ventricular hypertrophy, constrictive pericardial disease, etc), but it is very specific (82% and 90%, respectively).⁹ Left-sided collapse occurs only in about 25% of patients because of how muscular the left side of the heart is, but it is frequently found in patients with regional cardiac tamponade.^{10,11}

Cardiac tamponade patients should be treated with emergent drainage of the effusion.¹² This can be accomplished at the bedside or in the cardiac catheterization laboratory by pericardiocentesis (either blind or ultrasound-guided) with or without catheter placement for continued drainage. If patients are stable, they can be taken to the operating room for open surgical drainage with or without pericardiectomy (pericardial window) or video-assisted thoracoscopic pericardiectomy.¹³ Surgical drainage may be preferable in patients with small effusions, loculated effusions, aortic dissection, myocardial rupture, or those requiring biopsies.⁴

FINAL DIAGNOSIS

Cardiac tamponade

KEY TEACHING POINTS

- Shortness of breath, chest pain, or fatigue in a dialysis (or cancer) patient should prompt a point-of-care ultrasound

to evaluate for a pericardial effusion.

- Classic exam findings of cardiac tamponade include the following: Beck's triad (hypotension, JVD, and muffled heart sounds), as well as tachycardia and pulsus paradoxus, but these findings may not be present in patients with low blood pressure or regional tamponade.
- Echocardiographic findings suggestive of cardiac tamponade include right atrial/ventricular and left heart collapse, increased flow across the mitral and tricuspid valve on inspiration, and a plethoric IVC.

The authors attest that their institution requires neither Institutional Review Board approval, nor patient consent for publication of this case report. Documentation on file.

Address for Correspondence: Zachary D.W. Dezman, MD, MS, MS, University of Maryland School of Medicine, Department of Emergency Medicine, 110 S Poca Street, 6th Floor, Suite 200, Baltimore, MD 21201. Email: zdezman@som.umaryland.edu.

Conflicts of Interest: By the CPC-EM article submission agreement, all authors are required to disclose all affiliations, funding sources and financial or management relationships that could be perceived as potential sources of bias. The authors disclosed none.

Copyright: © 2021 Nichols et al. This is an open access article distributed in accordance with the terms of the Creative Commons Attribution (CC BY 4.0) License. See: <http://creativecommons.org/licenses/by/4.0/>

REFERENCES

1. Spodick DH. Acute cardiac tamponade. *N Engl J Med*. 2003;349(7):684-90.
2. Fitchett DH and Sniderman AD. Inspiratory reduction in left heart filling as a mechanism of pulsus paradoxus in cardiac tamponade. *Can J Cardiol*. 1990;6(8):348-54.
3. Permyer-Miralda G. Acute pericardial disease: approach to the aetiologic diagnosis. *Heart*. 2004;90(3):252-4.
4. Adler Y, Charron P, Imazio M, et al. 2015 ESC guidelines for the diagnosis and management of pericardial diseases: The Task Force for the Diagnosis and Management of Pericardial Diseases of the European Society of Cardiology (ESC) Endorsed by: The European Association for Cardio-Thoracic Surgery (EACTS). *Eur Heart J*. 2015;36(42):2921-64.
5. Reydel B and Spodick DH. Frequency and significance of chamber collapses during cardiac tamponade. *Am Heart J*. 1990;119(5):1160-3.
6. Klein AL, Abbara S, Agler DA, et al. American Society of Echocardiography clinical recommendations for multimodality cardiovascular imaging of patients with pericardial disease: endorsed by the Society for Cardiovascular Magnetic Resonance and Society of Cardiovascular Computed Tomography. *J Am Soc Echocardiogr*. 2013;26(9):965-1012.e15.
7. Himelman RB, Kircher B, Rockey DC, et al. Inferior vena cava plethora with blunted respiratory response: a sensitive echocardiographic sign of cardiac tamponade. *J Am Coll Cardiol*. 1988;12(6):1470-7.
8. Gillam LD, Guyer DE, Gibson TC, et al. Hydrodynamic compression of the right atrium: a new echocardiographic sign of cardiac tamponade. *Circulation*. 1983;68(2):294-301.
9. Armstrong WF, Schilt BF, Helper DJ, et al. Diastolic collapse of the right ventricle with cardiac tamponade: an echocardiographic study. *Circulation*. 1982;65(7):1491-6.
10. Reydel B and Spodick DH. Frequency and significance of chamber collapses during cardiac tamponade. *Am Heart J*. 1990;119(5):1160-3.
11. Chuttani K, Pandian NG, Mohanty PK, et al. Left ventricular diastolic collapse. An echocardiographic sign of regional cardiac tamponade. *Circulation*. 1991;83(6):1999-2006.
12. Reddy PS, Curtiss EI, O'Toole JD, et al. Cardiac tamponade: hemodynamic observations in man. *Circulation*. 1978;58(2):265-72.
13. Uramoto H and Hanagiri T. Video-assisted thoracoscopic pericardiectomy for malignant pericardial effusion. *Anticancer Res*. 2010;30(11):4691-4.

Physician and Pharmacist Liability: Medicolegal Cases That are Tough Pills to Swallow

John C.S. Schupbach, MD, MBA Mayo Clinic, Department of Emergency Medicine, Rochester, Minnesota
Maria C. Kaisler, MD
Gregory P. Moore, MD, JD
Benjamin J. Sandefur, MD

Section Editor: Melanie Heniff, MD

Submission history: Submitted January 23, 2021; Revision received April 3, 2021; Accepted April 10, 2021

Electronically published May 10, 2021

Full text available through open access at http://escholarship.org/uc/uciem_cpccem

DOI: 10.5811/cpcem.2021.4.51851

We present four medicolegal cases involving medication errors, which led to patient harm and subsequent settlements or jury awards to patients. These cases each involved scenarios in which a medication was inappropriately prescribed and/or inappropriately dispensed. In such cases, it is often not obvious whether the physician or pharmacist is at fault. These cases highlight the importance of understanding the roles and responsibilities of the physician and pharmacist in medication prescription and dispensation. [Clin Pract Cases Emerg Med. 2021;5(2):139–143.]

Keywords: *Malpractice; medication error; prescribing; liability.*

INTRODUCTION

Physicians and pharmacists each have different roles and responsibilities in the process of safely prescribing and dispensing medications. Despite technology and systems designed to prevent harm, errors and oversights persist. The responsibility of an emergency physician to independently warn a patient of medication side effects is well established. A case that illustrates this duty is that of a woman with a history of migraines who had presented many times to the emergency department (ED) and received the same treatment regimen, which she had tolerated well previously. After receiving her usual treatment, however, she was discharged without being warned that the medicine could cause sedation. Shortly after discharge, she was involved in a motor vehicle accident that left her paraplegic. She litigated for “failure to warn” and was awarded \$1.3 million.¹

Our intention in this article is to capture the nuances involved when both a physician and a pharmacist are involved, such as when a medication is prescribed by a physician and dispensed by a pharmacist. Although the cases we discuss below are not specific to emergency medicine (EM), the principles apply to medication prescribing and dispensing in an EM setting.

Case 1 - *Lovecchio v Rosenthal*

An 82-year-old man was discharged from the hospital after a cardiology admission. Upon discharge, the cardiologist prescribed outpatient amiodarone 1200 milligrams (mg) three times daily. A typical dose is 400 mg three times daily. The patient promptly filled the prescription. The pharmacist did not notice the excessive dose. At home, the patient took the first dose and four hours later suffered a cerebrovascular accident (CVA) that was later deemed by experts to be due to hypotension. He died 18 months later as a result of complications of the CVA. A lawsuit was filed claiming that the physician was in error for writing a prescription for 1200 mg three times daily and that the pharmacist should not have filled the prescription as written. A jury awarded a verdict of \$1 million. The physician was responsible for \$750,000, and the pharmacist was responsible for \$250,000.²

Case 2 - *Anonymous v Miller Pharmacy*

A 67-year-old cancer survivor picked up her regular prescription for methadone that was prescribed as 15 mg (three 5 mg tablets) twice daily. Four days later, she was found dead. It was discovered that she had been dispensed 10 mg tablets in error. The technician had typed the wrong dose and

the pharmacist did not notice the error. The pharmacy and pharmacist settled for \$325,000.³

Case 3 - *Quick v Acaylar, Parnell, and Marlboro Drug Company*

A two-year-old female was prescribed ranitidine for gastrointestinal reflux by her pediatrician. After the pharmacist dispensed the medication at the prescribed dose, the child gradually developed tremors, shaking, ataxia, left eye deviation, and somnolence. Her parents litigated and claimed that their daughter was chronically overdosed with ranitidine. The usual dose was three-fourths of a teaspoon twice daily, and the child had been prescribed 3¼ teaspoons twice daily for 2-4 weeks. They claimed the pediatrician erred in prescribing that dose and that the pharmacist unsafely dispensed the medication. The pediatrician settled the case for a confidential amount. The pharmacist and pharmacy settled for \$25,000.⁴

Case 4 - *Anton v Brown*

A 37-year-old man was prescribed methadone for opioid addiction by his physician. The dose was 60 mg twice daily for 10 days followed by 30 mg twice daily for 10 days. The pharmacist called the physician to report there were no 60 mg tablets. The dose was changed to 1.5 tablets of 40 mg tablets twice daily. No future reduction in dose was discussed. Federal law at the time limited dosing to a maximum of 40 mg total daily. The patient developed nausea but was unable to reach his physician. A call to the pharmacist resulted in instructions to continue the medication until the physician was contacted. The patient was found dead the next day. Autopsy cited the drug interaction between escitalopram and methadone, which had been recently prescribed by the primary physician. The physician settled the lawsuit for \$1 million, and the pharmacist contributed another \$900,000 to the settlement.⁵

DISCUSSION

Adverse Drug Events

These four cases illustrate different sources of medication dosing errors, each of which lead to detrimental harm. Unfortunately, medication errors are not as rare as we would hope. Approximately 1 in 20 patients is exposed to preventable harm, and 25% of such incidents are medication-related.⁶ The landmark report *To Err is Human; Building a Safer Health System* by the Institute of Medicine estimated medication errors cause 1 of 131 outpatient and 1 of 854 inpatient deaths.⁷ In a study of adverse drug events in the ambulatory setting, the medication classes most frequently involved in adverse drug events were selective serotonin reuptake inhibitor (SSRI) agents (10%), beta-blockers (9%), angiotensin-converting-enzyme (ACE) inhibitors (8%), and nonsteroidal anti-inflammatory (NSAID) agents (8%).⁸

Traditionally, pharmacists have been viewed as protected from the duty to warn patients about their prescribed medications; this duty has historically rested upon the physician and drug companies. This legal concept will be discussed further below. However, some courts have recently ruled that pharmacists do have a duty to warn, particularly in cases in which there are known contraindications or clear errors in the prescription (for example, excessive dosing, as demonstrated in the cases above).⁹

A 2013 retrospective review of pharmacist liability insurance claims from 2002-2011 by Health Providers Service Organization (HPSO), a national provider of professional liability insurance for more than 70,000 pharmacists, demonstrated 162 closed pharmacist and pharmacy technician claims. A claim is considered closed when all of the following criteria occur: there is a medication-related incident; there is an adverse patient outcome; a claim is filed against the insured pharmacist or technician; and there is payout on behalf of the insured party. Individually insured pharmacists accounted for 93.8% of closed claims. Wrong drug (43.8%) and wrong dose (31.5%) claims together represented 75.3% of all the closed claims in the study sample. Failure to identify overdosing encompassed only 3.1% of all the closed claims in the analysis. However, the average paid overdose indemnity was substantially higher than the overall average paid indemnity. All claims except one in the “failure to identify overdose” category involved opioids.¹⁰

In a subsequent 2018 retrospective review sampling of HPSO pharmacist malpractice claims from 2012-2016, the annual number of closed claims more than doubled and the average total incurred payout per claim increased by 22.8%, to \$124,407. While wrong drug and wrong dose errors continued to be the leading reasons for initiation of a claim, both decreased significantly relative to other causes with wrong drug claims accounting for 36.8% (from 43.8%) and wrong dose claims accounting for 15.3% (from 31.5%). These relative decreases are a result of large increases in other categories of allegations.¹¹

Although the specific percentage of “failure to identify overdosing” claims is not explicitly stated in the 2018 report, it occurred the “most infrequently of all closed claims in the analysis.” However, the average total incurred claim payout for such “failure to identify overdosing” claims was \$544,600. This represents 167% more than the next highest category (compounding calculation and/or preparation error) and 337% that of the overall average payout of \$124,407. Overdose also represented the leading cause of death in the sample, accounting for 73.7% of claims associated with medication-related patient death.¹⁰

Medications and Interactions

To further explore and illustrate the complexity of even a single dosing error and interaction, we take a closer evaluation of Case 4, *Anton v Brown*. This case involves concerns for

both an excessive initial dose of methadone and potential interaction between methadone and the patient's ongoing escitalopram treatment.

Methadone

Methadone is a μ -opioid receptor agonist and likely N-methyl-D-aspartate receptor antagonist that is approved by the United States Food and Drug Administration (FDA) for opioid detoxification and maintenance therapy of opioid use disorder. Opioid agonist treatment with either methadone or combination of buprenorphine and naloxone has been proven to safely and effectively suppress illicit opioid use and reduce the risk of death.¹² Methadone requires careful initiation, dose titration, medication changes, and discontinuation due to its pharmacokinetic properties, which vary widely from patient to patient. Characteristics that make methadone particularly difficult to safely administer include a long and highly variable half-life of 24-40 hours, a tendency for the medication to accumulate during initial treatment, and a risk of hazardous medication interactions.¹¹

Methadone is metabolized by cytochrome P450 isozymes. Therefore, cytochrome P450 inducers, such as antiretrovirals, rifampin, barbiturates, and phenytoin, can accelerate metabolism of the drug, leading to earlier withdrawal. Alternatively, cytochrome P450 inhibitors, such as fluconazole, ketoconazole, cimetidine, fluoxetine, paroxetine, ciprofloxacin, macrolide antibiotics, and grapefruit juice, can prevent methadone metabolism, causing higher methadone plasma concentrations than intended and increasing the risk of sedation and overdose.¹¹ Methadone has two primary hazards: respiratory depression and QT prolongation, particularly at higher doses. For these reasons, methadone is frequently administered as part of close monitoring programs—often daily—to ensure appropriate dosing and response to treatment.¹¹ Treatment is initiated when there are no signs of sedation or intoxication and the patient shows signs of withdrawal.

Methadone dosing of 20-30 mg (maximum dose 30 mg) is administered orally initially. In patients with a low expected tolerance (ie, have not taken opioids for more than five days), lower initial dosing is recommended. The patient is reassessed 2-4 hours after the first dose. If additional dosing is determined necessary, an additional 5-10 mg can be administered. The maximum recommended total daily dose on the first day of treatment is 40 mg. Over the first week, dosing is adjusted cautiously based upon control of withdrawal symptoms 2-4 hours after administration. Over time, maintenance therapy targets a dosage that prevents opioid withdrawal for 24 hours, generally 80-120 mg/day. During discontinuation of therapy, dosing is decreased slowly, by no more than 10% in 10- to 14-day intervals, to prevent withdrawal.¹¹

Escitalopram

Escitalopram is an SSRI and S-enantiomer of racemic citalopram. Escitalopram is approved by the FDA for the

treatment of major depressive disorder. It functions by enhancing serotonergic activity in the central nervous system (CNS) as a result of its inhibition of serotonin (5-HT) reuptake in CNS neurons.¹³

Escitalopram is metabolized by cytochrome P450 isozymes.¹⁴ Although the specific isozymes differ from those used by methadone and neither methadone nor escitalopram are known cytochrome P450 inhibitors or inducers, the potential for unknown and unpredictable interactions does exist.

Numerous hazards of escitalopram have been reported, including serotonin syndrome, QT prolongation, and torsades de pointes. Furthermore, SSRIs as a class have been shown to increase the risk of suicidal thinking and behavior in children, adolescents, and young adults with major depressive disorder and other psychiatric disorders in short-term studies. However, in patients beyond age 24, short-term studies did not show an increase in the risk of suicidality with antidepressants compared with placebo. Furthermore, in patients 65 and older, there was a reduction in risk of suicidal thinking and behavior with antidepressants compared with placebo.

Escitalopram is contraindicated in patients with hypersensitivity to citalopram or escitalopram, as well as patients who received a monoamine oxidase inhibitor in the previous 14 days, as these can interact to cause serotonin syndrome. Escitalopram also has a long list of medication interactions. For instance, strong evidence supports contraindication with linezolid and major interactions with lithium, both due to increased risk of serotonin syndrome, and risk with concurrent NSAID therapy due to increased risk of bleeding.¹² A major drug-drug interaction warning exists between escitalopram and methadone due to concern for increased risk of both serotonin syndrome and QT prolongation.¹²

Duty and Responsibility when Prescribing and Dispensing Medication

Pharmacists and physicians have separate duties when medications are prescribed and dispensed. Two cases clearly describe these respective duties.

The duty to warn patients of medication side effects rests with the prescribing physician. In *Morgan v Wal-Mart Stores, Inc.*, a 12-year-old boy was prescribed desipramine for attention deficit hyperactivity disorder. The prescribing physician testified that she had shown the patient's mother common side effects of desipramine in the *Physicians' Desk Reference*. Two years later, after multiple physician visits, the child died of hypereosinophilic syndrome, a rare but known complication of desipramine. The parents filed suit against Wal-Mart for negligence "by failing to properly warn intended users of the hazards and harms associated with the use of the product." The court ruled that the prescribing physician was liable and that the pharmacist had no duty to warn of medication side effects.¹⁵

Multiple other state courts have agreed that it is the physician's duty to warn of these potential side effects. In *Frye v Walgreen*, the court ruled that pharmacists are not obligated to warn of all potential medication side effects. Simply placing warning labels on medication bottles does not imply that a pharmacist is accepting shared liability for a physician's duty to warn.¹⁶ This leads to a dilemma for physicians: "How can I logistically warn patients of every side effect for every medication I prescribe?" In the ED, this can be practically accomplished by delegating the duty to the patient to "read the package inserts of prescribed medications" when discussing and providing discharge instructions. It is imperative for physicians to consider these warnings carefully when they add new medications or change doses of existing medications.

Pharmacists, on the other hand, have a duty to safely fill prescriptions and can be held liable for adverse outcomes if a prescription that a reasonable pharmacist would deem to be unsafe is still filled and dispensed. In *Brooks v Wal-Mart Stores, Inc.*, the court ruled against a pharmacist who had filled a prescription for an excessive dose of prednisone (80 mg four times daily). The dose was confirmed with the physician at the time. The patient subsequently developed *Nocardia pneumonia* and cerebral aspergillosis. He underwent numerous surgeries and hospitalizations, ultimately developing renal failure. Despite confirming the initial dose with the physician, the pharmacist was nevertheless held solely liable for the medication error. The result was an award to the patient for \$2.5 million. Although the physician is responsible for warning of side effects, the pharmacist must "exercise his [or her] own judgement as to whether any dosage prescribed, even if confirmed by the prescriber, would be harmful" and has an obligation to not fill a prescription he or she deems harmful.¹⁷

CONCLUSION

We have presented four medicolegal cases involving medication prescription and dispensation errors that led to patient harm and subsequent settlements or jury awards to patients. These cases each involved scenarios in which a medication was inappropriately prescribed and/or inappropriately filled. Heretofore, it may not have been obvious to emergency care providers whether the physician or pharmacist is at fault. These cases have highlighted the importance of understanding the roles and responsibilities of the prescribing physician and filling pharmacist in medication prescription and dispensation. Although these legal cases do not originate in the ED, the legal principles hold true for ED practices. The above legal cases have established the legal duties of the physician who must warn and the pharmacist who must safely dispense. In some situations, these liabilities may be shared as noted in the cases above.

Take-home Points

1. The physician has a duty to warn patients of side effects and interactions of medications.

2. The pharmacist has no duty to warn patients of side effects but does have a duty to safely fill and dispense prescribed medications, including ensuring that a prescribed dose is safe.
3. We recommend that a physician reduce liability by directing patients to read the packaging inserts of their prescribed medications.
4. "Wrong drug" and "wrong dose" claims are the most common medication errors leading to monetary awards among pharmacy malpractice claims.
5. "Failing to identify overdose" is associated with the largest monetary awards among pharmacy malpractice claims.
6. The most common medications involved in outpatient adverse drug events are SSRIs, beta-blockers, ACE inhibitors, and NSAIDs.

The authors attest that their institution requires neither Institutional Review Board approval, nor patient consent for publication of this case report. Documentation on file.

Address for Correspondence: John Schupbach, MD, MBA, Mayo Clinic, Department of Emergency Medicine, 200 First Street SW, Rochester, MN 55905. Email: schupbach.john@mayo.edu.

Conflicts of Interest: By the *CPC-EM* article submission agreement, all authors are required to disclose all affiliations, funding sources and financial or management relationships that could be perceived as potential sources of bias. The authors disclosed none.

Copyright: © 2021 Schupbach et al. This is an open access article distributed in accordance with the terms of the Creative Commons Attribution ([CC BY 4.0](http://creativecommons.org/licenses/by/4.0/)) License. See: <http://creativecommons.org/licenses/by/4.0/>

REFERENCES

1. West v Columbia Medical Center. Texas 5th Circuit Court No. cv00594 1997.
2. Lovecchio v Rosenthal. Orleans Parish (LA) District Court No. 13-5432.
3. Anonymous v Miller Pharmacy. Walworth County (WI) No. 16CV-469.
4. Quick v Acaylar MD, Pharmacist, and Marlboro Drug Company Inc. Marlboro County (SC) Common Pleas Court No 2014CP3400176.
5. Anton v Brown. Medical Malpractice: Verdicts, Settlements, & Experts. Volume 29, N 8, Page 16,17.
6. Panagioti M, Khan K, Keers RN, et al. Prevalence, severity, and nature of preventable patient harm across medical care settings: systematic review and meta-analysis. *BMJ*. 2019;366:14185.
7. Institute of Medicine (US) Committee on Quality of Health Care in America. (2000). To Err is Human: Building a Safer Health System. In Kohn LT, Corrigan JM, Donaldson MS (Eds). Washington (DC): National Academies Press (US).

8. Gandhi TK, Weingart SN, Borus J, et al. Adverse drug events in ambulatory care. *N Engl J Med*. 2003;348(16):1556-64.
9. National Association of Chain Drug Stores. Warn. 2016. Available at: https://www.nacds.org/pdfs/membership/duty_to_warn.pdf. Accessed January 19, 2020.
10. Healthcare Providers Service Organization. 2013 Pharmacist Liability: A Ten-Year Analysis. 2013. Available at: http://www.hpso.com/Documents/pdfs/Pharmacist_Claim_Report_2013.pdf. Accessed January 19, 2020.
11. Healthcare Providers Service Organization. Pharmacist Liability Claim Report: 2nd Edition. 2019. Available at: <http://www.hpso.com/Documents/Risk%20Education/individuals/Claim-Reports/Pharmacist/HPSO-CNA-Pharmacist-Claim-Report-2019.pdf>. Accessed January 19, 2020.
12. Truven Health Analytics. Methadone. 2020. Available at: <http://micromedex.com/>. Accessed September 14, 2020.
13. Truven Health Analytics. Escitalopram. 2020. Available at: <http://micromedex.com/>. Accessed September 14, 2020.
14. Rao N. The clinical pharmacokinetics of escitalopram. *Clin Pharmacokinet*. 2007;46(4):281-90.
15. Morgan v Wal-Mart Stores Inc. No. 03-99-00700-CV (Tex. App. Dist. – Austin 1926).
16. Frye v Walgreen. 605 N.E.2d at 558.
17. Brooks v Wal-Mart Stores Inc. No. COA 99-430, Aug. 29, 2000.

A Pain in the Butt: A Case Series of Gluteal Compartment Syndrome

Jessica Ray Jackson, MD
Kraftin Schreyer, MD

Temple University Hospital, Department of Emergency Medicine, Philadelphia, Pennsylvania

Section Editor: R. Gentry Wilkerson, MD

Submission history: Submitted January 19, 2021; Revision received March 11, 2021; Accepted March 5, 2021

Electronically published April 19, 2021

Full text available through open access at http://escholarship.org/uc/uciem_cpchem

DOI: 10.5811/cpchem.2021.3.51801

Introduction: Gluteal compartment syndrome is a rare and difficult-to-diagnose form of compartment syndrome.

Case Series: We present three patients with gluteal compartment syndrome and review the clinical presentation, imaging, and laboratory findings that assist in diagnosis. Suggestions for more readily diagnosing gluteal compartment syndrome are provided.

Conclusion: Emergency physicians must be familiar with the diagnosis and management of gluteal compartment syndrome to prevent the significant associated morbidity and mortality. [Clin Pract Cases Emerg Med. 2021;5(2):144–147.]

Keywords: *Gluteal compartment syndrome; fentanyl.*

INTRODUCTION

Compartment syndrome occurs when increased pressure in a closed fascial area leads to decreased tissue perfusion. Gluteal compartment syndrome (GCS) is a rare form of compartment syndrome that is difficult to diagnose and lacks clear diagnostic guidelines.¹ Any of the three gluteal compartments, the anterior tensor fascia lata compartment, the gluteus medius and minimus compartment, or the posterior gluteus maximus compartment, can be affected.² Approximately 50% of cases are due to prolonged immobilization secondary to surgery, or alcohol or substance use.³ Benns et al showed that compartment syndrome in patients with opioid use disorder (OUD) was more likely to be gluteal (31.8%) when compared to other etiologies and led to prolonged hospital admissions.

Delays in seeking care and in diagnosis have been shown to lead to complications including tissue loss in 27% of patients, the need for hemodialysis in 36.4% of patients, and residual motor or sensory deficits.^{3,4} One series found that patients treated with surgery had no subsequent neurologic deficits, while all patients managed conservatively had some residual deficit.⁵ Therefore, GCS should be considered a surgical emergency.

As a significant proportion of cases are related to intoxication, diagnosis is often complicated by a limited history and exam. Patients may have altered mental status prior to presentation or may present to the emergency department (ED) obtunded. Aside from elevated creatine kinase (CK), GCS can lead to several lab derangements that may aid in diagnosis. Both alanine aminotransferase (ALT) and aspartate aminotransferase (AST) are found in skeletal muscle, although ALT is more specific for the liver. As a result, compartment syndrome may lead to elevated AST and ALT, which can be incorrectly interpreted as hepatic dysfunction.⁶ Similarly, patients with rhabdomyolysis have shown to have a false-positive troponin rate of 17%, without any association with cocaine use or renal failure.⁷ Patients may also have elevated creatinine and potassium.

The following cases series includes three patients who developed GCS in the setting of substance use, likely secondary to prolonged immobilization. All patients presented to the ED of the Episcopal Campus of Temple University Health System, a community affiliate located in the Kensington section of Philadelphia, Pennsylvania. In 2018, Kensington saw the greatest number of nonfatal overdoses and the highest number of naloxone administrations in

Philadelphia.^{8,9} In 2019, 13.5% of the 46,000 annual visits to the Episcopal ED were related to OUD. Episcopal Hospital has an associated crisis response center (CRC) that provides 24-hour psychiatric emergency services; however, consultative services, including surgery, are not available. Patients who need emergent surgical evaluation are transferred to the main academic center. All patients in this series were diagnosed clinically without measurement of compartment pressures.

CASE SERIES

Case 1

Case 1 was a 38-year-old female with past medical history (PMH) of substance use disorder (SUD) who presented in January 2020 with altered mental status. The patient complained of right shoulder pain but was minimally cooperative due to suspected phencyclidine intoxication. A radiograph of her right shoulder did not show any acute pathology, and she was discharged. She later presented to the CRC where she was placed in observation due to concern for intoxication and was discharged after two hours. She returned to the ED one hour later via emergency medical services (EMS) with weakness and difficulty walking after being found outside. Her initial vital signs were as follows: 147/106 millimeters of mercury (mm Hg); heart rate 95 beats per minute; respiration rate 20 breaths per minute; oxygen saturation of 100% on room air; and initial temperature less than 80° Fahrenheit. She received multiple doses of lorazepam for agitation, and continued to complain of muscle cramping and right shoulder pain. Initial laboratory results were hemolyzed.

Repeat laboratory studies after initiation of intravenous fluids were notable for the following: creatinine 3.77 milligrams per deciliter (mg/dL) (reference range 0.90-1.30 mg/dL); potassium 5.6 millimoles per liter (mmol/L) (3.5-5.2 mmol/L); ALT 2440 units per liter (U/L) (0-44 U/L); AST 7087 U/L (0-34 U/L); troponin 4.1 nanograms per milliliter (ng/mL) (0.00-0.10 ng/mL); CK 296,865 U/L (49-174 U/L); and a urine drug screen (UDS) positive for fentanyl, cocaine, and phencyclidine. The elevated CK prompted reassessment and she was found to have a firm right shoulder and left buttock without associated skin changes. This was best appreciated while the patient was standing, which revealed an obvious difference in the size of the right and left buttocks. When prone, her gluteal compartments were not notably firm.

She was then transferred emergently for surgery evaluation, and a computed tomography (CT) series was performed. The CT chest showed right lateral chest wall edema and possible aspiration; the CT abdomen and pelvis showed a collection in her left gluteal musculature representing hematoma or abscess, and intermuscular edema along the anterior and posterior compartments of the left thigh. Ultimately, she was taken to the operating room (OR) for right shoulder fasciotomy. On hospital day three, she was taken back to the OR for left gluteal fasciotomy and was

CPC-EM Capsule

What do we already know about this clinical entity?

Gluteal compartment syndrome (GCS) is rare and difficult to diagnose. About 50% of cases are due to prolonged immobilization secondary to surgery, or alcohol or substance use.

What makes this presentation of disease reportable?

This case series demonstrates the importance of labs and of examining patients while they are standing in order to diagnose GCS, as well as the association of GCS with fentanyl use.

What is the major learning point?

Providers must keep a high index of suspicion for GCS, particularly in patients who use fentanyl.

How might this improve emergency medicine practice?

More rapid diagnosis of gluteal compartment syndrome can help prevent subsequent morbidity and mortality.

started on hemodialysis. She later had renal recovery and was able to discontinue hemodialysis prior to discharge on hospital day 25.

Case 2

Case 2 was a 37-year-old male with a PMH of SUD who presented to the ED in June 2020. He had reportedly been given naloxone from EMS after using opioids and reported not feeling well. He was uncooperative and shouting on arrival and complained of possible assault, noting right hip and back pain. His initial creatinine was 4.33 mg/dL and potassium was 6.9 mmol/L, which prompted reassessment for compartment syndrome. Examination with the patient standing showed edema and erythema of the right buttock. The left buttock, although less edematous, was also tense. Given those findings, he was transferred for emergent surgery evaluation. Additional laboratory studies included a CK of 218,142 U/L and a UDS positive for fentanyl, cocaine, cannabinoids, and amphetamines. He subsequently had CT imaging of his head, chest, abdomen and pelvis, which was remarkable for left lateral gluteal and pelvic musculature swelling, as well as edema of the right anterior abdominal musculature and right gluteus that were presumed to be secondary to blunt injury. He was taken to the OR that evening for left gluteal fasciotomy and was started on hemodialysis. On hospital day two, his

right buttock was noted to be firm and he was taken back to the OR for right-sided gluteal fasciotomy. He also had renal recovery and was discharged on hospital day 18.

Case 3

Case 3 presented to the ED as an unidentified male in July 2020. He was subsequently identified as a 34-year-old with a PMH of SUD and schizophrenia. He was brought in by EMS after being found unresponsive on the sidewalk and was given naloxone prior to arrival. On arrival to the ED, he had a Glasgow Coma Scale of seven with increased work of breathing. He was intubated for airway protection and shortly after was found to have elevated creatinine of 1.81 mg/dL and potassium of 6.7 mmol/L. This prompted a repeat examination and he was found to have a firm right buttock without skin findings. His other labs subsequently resulted and were remarkable for ALT 114 U/L, AST 205 U/L, troponin 0.31 ng/mL, CK 16,854 U/L, and UDS was positive for fentanyl, cocaine, cannabinoids, phencyclidine, and benzodiazepines.

He underwent CT imaging prior to transfer to assess for any traumatic injuries. His CT head was notable for sulcal effacement, ventricular narrowing, and multifocal hypoattenuation likely acute infarction. The CT chest showed nodular and consolidative ground glass opacities; CT abdomen and pelvis showed right buttock with large expansile phlegmon, and ultrasound was recommended to assess for drainable collection. Shortly after transfer he became hypoxic from worsening pulmonary infiltrates consistent with acute respiratory distress syndrome. He then suffered cardiac arrest but achieved return of spontaneous circulation after multiple rounds of cardiopulmonary resuscitation. Due to critical illness, he had a bedside gluteal fasciotomy. Unfortunately, he was found to have catastrophic anoxic brain injury. The family agreed to terminal extubation on hospital day six. He did not require hemodialysis.

DISCUSSION

Although rare, GCS may be the most common form of opioid-related compartment syndrome. With the national increase in OUD, providers must be vigilant for this entity. Each patient in this case series had multiple substances on their UDS and, notably, all were positive for fentanyl. Compared to other opioids, fentanyl is more potent and is known to cause rapid respiratory depression, unconsciousness, and muscle rigidity.¹⁰ This combination may have contributed to the development of compartment syndrome in these patients. While GCS has been linked to OUD, we have not seen previous documentation of the relationship with fentanyl specifically.

Compartment pressures can be used in the diagnosis of GCS but may be difficult to obtain. Most authors suggest an intracompartmental pressure of 30 mm Hg as the threshold for initiating treatment, but GCS is ultimately a clinical diagnosis.¹¹ Patients who are unable to give a reliable history or participate in an exam are even more difficult to diagnose.

We suggest having patients stand to more easily assess the gluteal compartments and compare contralateral edema. The deeper gluteus medius and minimus compartment is frequently affected. Compartment syndrome may not be detected if the overlying gluteus maximus is soft, and the patient is lying prone.

No patients in this case series were found to have traumatic injuries, as determined by CT, nor signs of injection drug use in the affected areas on examination. The areas that were later identified as compartment syndrome were described as either hematoma or abscess based on CT findings. Providers should be aware that GCS cannot be diagnosed based on imaging findings and may appear infectious or post-traumatic.

Of the two patients who had hepatic function tests and troponin performed, all levels were elevated with AST higher than ALT. Neither was determined to have a primary hepatobiliary or cardiac issue. All three patients had elevated creatinine and potassium, which may be the first clue to the diagnosis and should prompt reassessment of all compartments. While an elevated CK should also trigger reassessment, the laboratory may have to perform serial dilutions, which could delay reporting of the result. In this series, Case 2 and Case 3 were both transferred for surgical evaluation before their CK resulted.

CONCLUSION

This case series shows that multiple deleterious outcomes can be associated with gluteal compartment syndrome. It further highlights the challenges in diagnosing GCS and its association with OUD, particularly with fentanyl use. Providers must maintain a high index of suspicion with early recognition of a constellation of abnormal laboratory values and thorough physical examination to prevent subsequent morbidity and mortality in patients who may be unable to assist in diagnosis.

The authors attest that their institution requires neither Institutional Review Board approval, nor patient consent for publication of this case report. Documentation on file.

Address for Correspondence: Jessica Ray Jackson, MD, Temple University Hospital, Department of Emergency Medicine, 3401 North Broad Street, Jones Hall 10th Floor, Philadelphia, PA. Email: Jessica.jackson@tuhs.temple.edu.

Conflicts of Interest: By the *CPC-EM* article submission agreement, all authors are required to disclose all affiliations, funding sources and financial or management relationships that could be perceived as potential sources of bias. The authors disclosed none.

Copyright: © 2021 Jackson et al. This is an open access article distributed in accordance with the terms of the Creative Commons Attribution ([CC BY 4.0](https://creativecommons.org/licenses/by/4.0/)) License. See: <http://creativecommons.org/licenses/by/4.0/>

REFERENCES

1. Tiwari A, Haq AI, Myint F, et al. Acute compartment syndromes. *Br J Surg*. 2002;89(4):397-412.
2. Elkbuli A, Sanchez C, Hai S, et al. Gluteal compartment syndrome following alcohol intoxication: case report and literature review. *Ann Med Surg (Lond)*. 2019;44:98-101.
3. Henson JT, Roberts CS, Giannoudis PV. Gluteal compartment syndrome. *Acta Orthop Belg*. 2009;75(2):147-52.
4. Bennis M, Miller K, Harbrecht B, et al. Heroin-related compartment syndrome: an increasing problem for acute care surgeons. *Am Surg*. 2017;83(9):962-5.
5. Kuhlman GD and Gwathmey KG. Gluteal compartment syndrome with neurologic impairment: report of 2 cases and review of the literature. *Muscle Nerve*. 2018;57(2):325-30.
6. Lim AK. Abnormal liver function tests associated with severe rhabdomyolysis. *World J Gastroenterol*. 2020;26(10):1020-8.
7. Li SF, Zapata J, Tillem E. The prevalence of false-positive cardiac troponin I in ED patients with rhabdomyolysis. *Am J Emerg Med*. 2005;23(7):860-3.
8. City of Philadelphia Department of Public Health. Opioid Misuse and Overdose Report. 2019. Available at: <https://www.phila.gov/media/20191126111554/Substance-Abuse-Data-Report-11.25.19.pdf>. Accessed December 30, 2019.
9. Percy J. Trapped by the 'Walmart of heroin.' 2018. Available at: <https://www.nytimes.com/2018/10/10/magazine/kensington-heroin-opioid-philadelphia.html>. Accessed October 24, 2019.
10. Torralva R and Janowsky A. Noradrenergic mechanisms in fentanyl-mediated rapid death explain failure of naloxone in the opioid crisis. *J Pharmacol Exp Ther*. 2019;371(2):453-75.
11. Diaz Dileria F, Zaidenberg EE, Gamsie S, et al. Gluteal compartment syndrome secondary to pelvic trauma. *Case Rep Orthop*. 2016;2016:2780295.

Nebulized Tranexamic Acid for Pediatric Post-tonsillectomy Hemorrhage: A Report of Two Cases

Cecilia Monteilh, MD*
Lydia Rabon, MD*
Ilana Mayer-Hirshfeld, MD†
Jon McGreevy, MD*

*Phoenix Children's Hospital, Department of Emergency Medicine, Phoenix, Arizona
†Valleywise Health Medical Center, Department of Emergency Medicine, Phoenix, Arizona

Section Editor: Melanie Heniff, MD

Submission history: Submitted November 9, 2020; Revision received January 30, 2021; Accepted February 9, 2021

Electronically published March 12, 2021

Full text available through open access at http://escholarship.org/uc/uciem_cpccem

DOI: 10.5811/cpccem.2021.2.50799

Introduction: Tranexamic acid (TXA) use in pediatrics to control hemorrhage has gained interest in recent years, but there is limited literature on nebulized TXA especially regarding dosing and adverse effects. Tranexamic acid has anti-fibrinolytic properties via competitive inhibition of plasminogen activation making it a logical approach to promote hemostasis in cases of post-tonsillectomy hemorrhage.

Case Report: We describe two cases of post-tonsillectomy hemorrhage managed with nebulized TXA. In both cases, bleeding was stopped after TXA administration.

Conclusion: To our knowledge, this is the first case report to describe the use of nebulized TXA without an adjunct pharmacotherapy. Our two cases add additional reportable data on the safety of nebulized TXA and possible effectiveness on post-tonsillectomy hemorrhage. [Clin Pract Cases Emerg Med. 2021;5(2):148–151.]

Keywords: *post-tonsillectomy hemorrhage; nebulized tranexamic acid; tranexamic acid.*

INTRODUCTION

Tonsillectomy is one of the most common surgical procedures in pediatrics. Approximately 1-10% of patients who have tonsillectomies will have their course complicated by post-tonsillectomy hemorrhage.¹⁻³ Post-tonsillectomy hemorrhages are defined as primary or secondary based on their timing. Primary hemorrhage occurs within the first 24 hours postoperatively.^{1,2} Secondary hemorrhage occurs after the first 24-hour period, most commonly between days five and ten, usually from sloughing of the eschar, trauma due to food ingestion, or infection of the tonsil bed, among other causes.^{1,2} Most of these hemorrhages are self-limited, but some are serious and can lead to death from hemorrhagic shock or airway obstruction.⁴

If on presentation to the emergency department (ED) the patient is actively bleeding, the treatment modalities consist of ice water gargles, topical or racemic epinephrine, and applying direct pressure.¹ These treatments are not always effective,

which then necessitates a return to the operating room (OR). Recent research supports the use of tranexamic acid (TXA) for treating a variety of bleeding issues following surgical procedures, but there are only two case reports of its use in post-tonsillectomy bleeding. One of these cases was in an adult patient and the other in a pediatric patient.^{1,5} Our goal in reporting this case was to add evidence supporting the use of nebulized TXA in post-tonsillectomy hemorrhages.

CASE REPORT

Case 1

A three-year-old male with a history of obstructive sleep apnea presented to the pediatric emergency department (PED) on postoperative day (POD) three with a chief complaint of hematemesis. The morning of presentation, the patient awoke fussy and subsequently began to vomit. His mother witnessed a clot in the emesis with frank hematemesis with continued bleeding coming from the

oropharynx, and she transported him via personal vehicle to the hospital. Upon arrival, the patient was afebrile at 37.5°C, with a heart rate of 137 beats per minute, respiratory rate of 28 breaths per minute, oxygen saturation of 98% on room air, blood pressure of 111/85 millimeters mercury (mm Hg), and weight of 12 kilograms (kg). On exam, the patient appeared pale and tachycardic with active retching, and with blood pooled in the posterior oropharynx that obscured visualization of the tonsillar beds.

A complete blood count (CBC), coagulation profile, and type and cross were obtained, and ondansetron was administered intravenously (IV). A cold-water rinse was attempted; however, the patient did not tolerate this intervention. Nebulized TXA was administered by using 250 milligrams (mg) (50mg/per milliliter) IV solution via direct nebulization at a flow rate of eight liters over four minutes without additive of normal saline solution. After administration of TXA, the patient had no obvious bleeding from the posterior pharynx and his retching improved. He was then admitted to the general pediatric inpatient service for further monitoring with pediatric otolaryngology (ENT) consultation. The CBC and coagulation studies were within the normal range on admission with hemoglobin 12.0 grams per deciliter (gm/dL) (normal range 11.5-14.5 gm/dL), prothrombin time (PT) 13.8 seconds (sec) (11.7-14.7 sec), and partial thromboplastin time (PTT) 33.3 sec (25-35 sec).

These lab tests were not repeated during his hospitalization. After an initial refusal of oral intake requiring maintenance IV fluids the patient was able to be transitioned to a soft diet, which he tolerated, and he was discharged on hospital day three. He had no further bleeding, and no adverse effects from nebulized TXA were documented. The patient's initial surgery was performed at an outside facility, and no follow-up visits were done at our institution for review.

Case 2

A two-year-old male presented to the PED on POD two with a chief complaint of hematemesis and concern for active post-tonsillectomy hemorrhage. The patient was accompanied by his mother. She stated that the patient had been taking medication approximately one hour before arrival, began to gag, and then had an episode of hematemesis. The mother immediately transported the patient via personal vehicle to the PED with two more episodes of hematemesis en route. On arrival, the patient was afebrile at 36.7°C, with a heart rate of 150 beats per minute, oxygen saturation of 99% on room air, blood pressure of 90/60 mm Hg, and weight of 14.2 kg. On exam, he appeared pale and in distress in triage, and so was taken to a resuscitation room where an IV was established, and a normal saline bolus (20 cubic centimeters/kg) was initiated.

Active bleeding of the tonsillar bed was appreciated with blood pooling in the posterior oropharynx and there was an inability to appreciate laterality of source, for which ENT was immediately called. During this time, nebulized TXA was

CPC-EM Capsule

What do we already know about this clinical entity?

Recent research supports the use of tranexamic acid (TXA) for bleeding following surgical procedures.

What makes this presentation of disease reportable?

Two pediatric patients presented to our emergency department with post-tonsillectomy hemorrhage and were successfully managed with nebulized TXA without adjunct pharmacotherapy.

What is the major learning point?

Nebulized TXA may be a viable single-therapy option in managing pediatric post-tonsillectomy hemorrhage.

How might this improve emergency medicine practice?

Initiation of nebulized TXA for pediatric post-tonsillectomy hemorrhage may temporize bleeding while awaiting definitive management by otolaryngology.

administered using 250 mg (50mg/mL) IV solution via direct nebulization without additive of normal saline solution. The bleeding stopped within 10 minutes of nebulized TXA administration. Initial labs resulted as follows: hemoglobin 10.7 gm/dL; PT 15.6 sec; PTT 26.2 sec. The patient was then transported to the OR by ENT for definitive management.

The following was noted in the operative report documentation by the surgeon: 1) normal palate; 2) normal postoperative changes of the adenoids without active bleeding; and 3) a clot on the left tonsillar pillar, which was removed. No active bleeding was noted otherwise, and the bilateral fossa was cauterized. The patient was then admitted to the general pediatric inpatient service for further monitoring overnight. A hemoglobin check performed the following morning was 8.4 gm/dL. The patient tolerated a soft diet the next day and was discharged home with return precautions and ENT follow-up. There were no documented adverse effects during hospitalization, and no ENT follow-up documentation was available for our review in the health record despite initial surgery at our facility.

DISCUSSION

Post-tonsillectomy hemorrhage represents a gray area not only in definition but in management. There are several

treatment options with variable success, many of which are complicated in the pediatric patient. This has led to institutional preference and wide variability in management algorithms. Even with a definitive treatment option available and operative management, there is a need for temporizing or bridging measures. As a result of this, TXA has gained attention. Tranexamic acid is an antifibrinolytic that competitively inhibits plasminogen activation, thus promoting hemostasis and decreasing bleeding by forming a reversible complex that displaces plasminogen from fibrin, resulting in inhibition of fibrinolysis. It also works by inhibiting the proteolytic activity of plasmin.^{1,6-9} Its use in pediatrics has been seen with scoliosis repair, congenital heart repair, and craniosynostosis repair, but has also been increasingly reported in pediatric trauma, such as in the Clinical Randomization of an Antifibrinolytic in Significant Hemorrhage (CRASH-2) trial, diffuse alveolar hemorrhage (DAH), and more recently with post-tonsillectomy hemorrhage.¹⁻¹¹ As a result of broadening use with limited patient numbers actual dosing parameters are not well established, nor is the safety profile when used for these indications.

The use of TXA as a preventative medication for post-tonsillectomy hemorrhage has been studied with little reported benefit but did show an overall reduction in mean blood loss and mean duration of bleeding intraoperatively.⁸ Systemic administration of TXA has been shown to have minor side effects ranging from nausea and vomiting to more severe side effects such as seizures and renal toxicity in those patients with already decreased function.⁷⁻⁹ Most of these side effects have only been described in adult patients, and seizures seem to be related to high-dose administration, especially in cardiac surgery.⁹ Maeda et al found that prolonging drug delivery time during the early postoperative period may lead to a reduction in seizure events.⁷ Other studies have found that administration of TXA during tonsillectomy has side effects such as nausea, headache, vomiting, and dizziness.¹² It appears that these side effects may be dose related, but due to lack of standardized dosing for its various uses this is difficult to extrapolate.⁷

Poppe and Grimaldo described a 22-year-old male who presented to the ED with an active post-tonsillectomy hemorrhage. He became hypotensive and received emergent IV fluids, massive transfusion protocol, and nebulized TXA. After completion of the nebulized TXA, the patient's bleeding was controlled.⁵ This was the first case in the emergency medicine literature that described the use of nebulized TXA in an adult to achieve hemostasis in post-tonsillectomy hemorrhage. Swartz et al administered nebulized TXA to achieve hemostasis in a pediatric patient with associated bleeding cessation prior to definitive operative management as well.¹ However, these are the only two case reports describing the use of nebulized TXA to control post-tonsillectomy bleeding.

In the case report by Schwarz et al, dosing was extrapolated from the literature on DAH at 250 mg of

nebulized TXA to be used for post-tonsillectomy hemorrhage for children less than 25 kg and 500 mg for those greater than 25 kg after a failed attempt to stop the hemorrhage with nebulized racemic epinephrine.^{1,11} Poppe and Grimaldo used nebulized TXA (1000 mg/10 mL) 5 mL and normal saline 5 mL in an adult patient, which allowed for the mitigation of a massive post-tonsillectomy hemorrhage until ENT could arrive at bedside to perform a coagulation cautery.⁵ This dosing was also based on the aforementioned DAH dosing.¹¹ In the two previous studies describing nebulized TXA, neither showed any adverse effects locally or systemically.^{1,2,5} This was our experience as well and supplements the safety data in addition to providing a specific effective dose.

Our two patients did not receive racemic epinephrine prior to the administration of nebulized TXA. This differs from Schwarz et al, where they used racemic epinephrine prior to their TXA trial, which may have introduced a complementary mechanism to the cessation of bleeding in their case.¹ Our cases demonstrate that nebulized TXA alone may allow for the cessation of post-tonsillectomy hemorrhages without adjunct pharmacotherapy.

CONCLUSION

To our knowledge, this is the first pediatric case report to describe the use of nebulized TXA without any adjunct pharmacotherapy. Our two cases add additional data on the safety of nebulized TXA and possible effectiveness for the treatment of post-tonsillectomy hemorrhage. A multicenter randomized control trial would be the ideal manner to delineate effectiveness and safety profile, but given the rarity of cases it would be difficult to accomplish especially without preliminary experience to show it as a reasonable treatment modality. However, based on existing data nebulized TXA appears to be a safe and potentially effective option in acute post-tonsillectomy bleeding.

The authors attest that their institution requires neither Institutional Review Board approval nor patient consent for publication of this case report. Documentation on file.

Address for Correspondence: Cecilia Monteilh, MD, Phoenix Children's Hospital, Department of Emergency Medicine, 1919 E Thomas Rd, Phoenix, AZ 85016. Email: cmonteilh@phoenixchildrens.com.

Conflicts of Interest: By the CPC-EM article submission agreement, all authors are required to disclose all affiliations, funding sources and financial or management relationships that could be perceived as potential sources of bias. The authors disclosed none.

Copyright: © 2021 Monteilh et al. This is an open access article distributed in accordance with the terms of the Creative Commons Attribution (CC BY 4.0) License. See: <http://creativecommons.org/licenses/by/4.0/>

REFERENCES

1. Schwarz W, Ruttan T, Bundick K. Nebulized tranexamic acid use for pediatric secondary post-tonsillectomy hemorrhage. *Ann Emerg Med.* 2019;73(3):269-71.
2. Liu JH, Anderson KE, Willging JP, et al. Posttonsillectomy hemorrhage: What is it and what should be recorded? *Arch Otolaryngol Head Neck Surg.* 2001;127(10):1271-5.
3. Mitchell RB, Archer SM, Ishman SL, et al. Clinical practice guideline: tonsillectomy in children (update). *Otolaryngol Head Neck Surg.* 2019;160(1_suppl):S1-42.
4. Whelan RL, Shaffer A, Anderson ME, et al. Reducing rates of operative intervention for pediatric post-tonsillectomy hemorrhage. *Laryngoscope.* 2018;128(8):1958-62.
5. Poppe M and Grimaldo F. A case report of nebulized tranexamic acid for post-tonsillectomy hemorrhage in an adult. *Clin Pract Cases Emerg Med.* 2020;4(3):443-5.
6. Booth DY, Cruz JE, Benson CL. Nebulized tranexamic acid for the use of epistaxis: a case report. *J Emerg Med.* 2019;S0736-4679(19)30934-5.
7. Maeda T, Sasabuchi Y, Matsui H, et al. Safety of tranexamic acid in pediatric cardiac surgery: a nationwide database study. *J Cardiothorac Vasc Anesth.* 2017;31(2):549-53.
8. Chan CC, Chan YY, Tanweer F. Systematic review and meta-analysis of the use of tranexamic acid in tonsillectomy. *Eur Arch Otorhinolaryngol.* 2013;270(2):735-48.
9. Hunt BJ. The current place of tranexamic acid in the management of bleeding. *Anaesthesia.* 2015;70 Suppl 1:50-3, e18.
10. Nishijima DK, VanBuren J, Hewes HA, et al. Traumatic injury clinical trial evaluating tranexamic acid in children (TIC-TOC): study protocol for a pilot randomized controlled trial. *Trials.* 2018;19(1):593.
11. Bafaqih H, Chehab M, Almohaimeed S, et al. Pilot trial of a novel two-step therapy protocol using nebulized tranexamic acid and recombinant factor VIIa in children with intractable diffuse alveolar hemorrhage. *Ann Saudi Med.* 2015;35(3):231-9.
12. Koizumi M, Ishimaru M, Matsui H, et al. Tranexamic acid and post-tonsillectomy hemorrhage: propensity score and instrumental variable analyses. *Eur Arch Otorhinolaryngol.* 2019;276(1):249-54.

The “Spiked Helmet” Sign Associated with ST-Elevation Myocardial Infarction: A Case Report

Bruno Minotti, MD*
Jörg Scheler, MD*
Robert Sieber, MD*
Eva Scheler, MD†

*Cantonal Hospital of St. Gallen, Department of Emergency Medicine, St. Gallen, Switzerland
†Cantonal Hospital of St. Gallen, Department of Cardiology, St. Gallen, Switzerland

Section Editor: Rick A. McPheeters, DO

Submission history: Submitted November 20, 2020; Revision received January 4, 2021; Accepted January 11, 2021

Electronically published May 10, 2021

Full text available through open access at http://escholarship.org/uc/uciem_cpem

DOI: 10.5811/cpcem.2021.1.50921

Introduction: The “spiked helmet” sign was first described in 2011 by Littmann and Monroe in a case series of eight patients. This sign is characterized by an ST-elevation atypically with the upward shift starting before the onset of the QRS complex. Nowadays the sign is associated with critical non-cardiac illness.

Case Report: An 84-year-old man with a history of three-vessel disease presented to the emergency department with intermittent pain in the upper abdomen. The electrocardiogram revealed the “spiked helmet” sign. After ruling out non-cardiac conditions the catheterization lab was activated. The coronary angiography revealed an acute occlusion of the right coronary artery, which was balloon-dilated followed by angioplasty. The first 24 hours went uneventfully with resolution of the “spiked helmet” sign. On the second day, however, the patient died suddenly and unexpectedly.

Conclusion: Despite the association with non-cardiac illness, the “spiked helmet” sign can be seen by an acute coronary artery occlusion as an ST-elevation myocardial infarction (STEMI). Reciprocal ST-depression in these cases should raise the suspicion of STEMI. [Clin Pract Cases Emerg Med. 2021;5(2):152–154.]

Keywords: *spiked helmet sign; upper abdomen pain; chest pain; STEMI; emergency department; case report.*

INTRODUCTION

In 2011 Littmann and Monroe described for the first time a particular electrocardiogram (ECG) sign in a case series of eight patients.¹ This sign has been characterized by an ST-elevation with atypically upward shift starting before the onset of the QRS complex. None of these patients had critical cardiac illness. Acute myocardial infarction was ruled out by cardiac serum markers. The sign has been associated with a rapid increase in thoracic or intra-abdominal pressure.² Association with confirmed coronary artery occlusion has never been reported.

CASE REPORT

An 84-year-old man was brought to our emergency department by ambulance with intermittent pain in the

upper abdomen and shortness of breath for three hours. He had a history of coronary three-vessel disease (first diagnosis 2004) with prediabetes, hypertension, hyperlipidemia, and past history of active smoking. Vital signs were in the normal range. Rapid first clinical assessment was unremarkable. The first ECG was seen on the monitor in lead II (Image 1).

The ECG “strip” showed sinus rhythm at 76 beats per minute with apparent ST-segment elevation, but with the upward shift starting before the onset of the QRS complex. This pattern was consistent with the “spiked helmet” sign. Lung auscultation showed bilateral vesicular breath sounds. Abdomen was soft and nontender with reduced peristalsis. Focused point-of-care ultrasound was performed with




Image 1. Electrocardiographic (lead II) taken from the Monitor System demonstrating the “spiked helmet” sign.

ubiquitous pleural sliding excluding a large pneumothorax and abdominal examination ruling out free fluid and gastrointestinal distension. We obtained in parallel a 12-lead ECG (Image 2).

The ECG showed a sinus rhythm at 78 beats per minute with first-degree atrioventricular block, right bundle branch block and ST-elevation in the inferior leads, again with the upward shift starting before the onset of the QRS complex. Due to the reciprocal ST-depression in lead I and aVL, the catheterization lab was activated and the patient underwent coronary angiography. The cardiologist found an occlusion of the distal right coronary artery (RCA), which was the dominant vessel. The occlusion of the RCA was balloon-dilated followed by angioplasty. A post-interventional ECG with asymptomatic patient was obtained (Image 3).

The “spiked helmet” sign had resolved, with all that remained a nonspecific intraventricular block in the inferior leads and a slightly long corrected QT interval (QTc) of 480 milliseconds. The first 24 hours after intervention was uneventful. However, on the second day the patient had a fulminant collapse with hemodynamic instability. The patient had declared earlier to abstain from further intensive care therapy. Supportive therapy was performed and he died a few hours later.

DISCUSSION

We report this case of a patient with the “spiked helmet” sign and an acute coronary artery occlusion with ST-elevation myocardial infarction. In the first case series by Littmann and Monroe, the “spiked helmet” sign was present exclusively in the inferior leads, as was noted in our case. The postulated

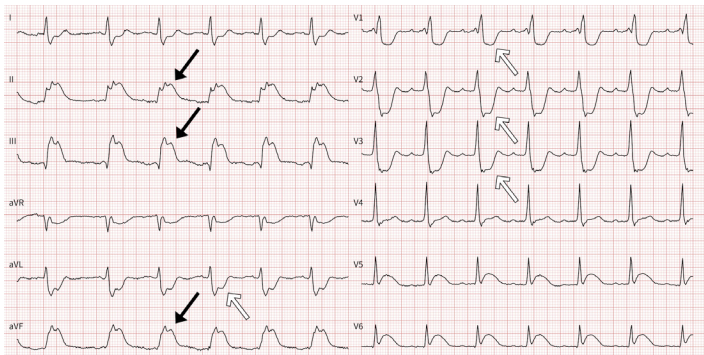


Image 2. 12-lead electrocardiogram at the presentation demonstrating the “spiked helmet” sign (black arrows) with reciprocal changes (white arrows).

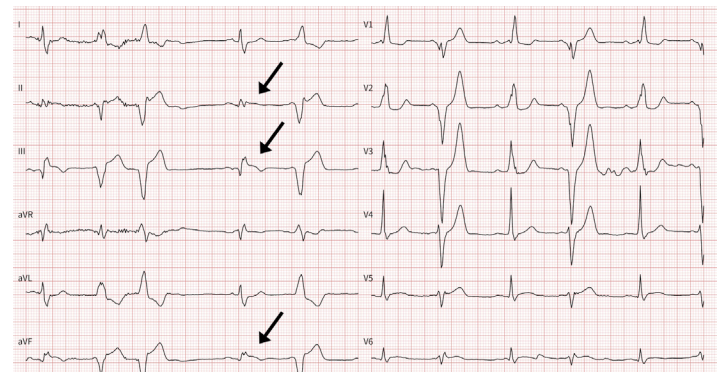


Image 3. Post-interventional electrocardiogram with resolution of the “spiked helmet” sign (arrows).

CPC-EM Capsule

What do we already know about this clinical entity?
The “spiked helmet” sign is characterized by an ST-Elevation with the upward shift starting before the onset of the QRS complex. This sign is associated with critical non-cardiac illness.

What makes this presentation of disease reportable?
We report the case of a patient presenting to the emergency department with chest pain and the “spiked helmet” sign on electrocardiogram (ECG). An acute coronary artery occlusion was responsible for the ECG changes.

What is the major learning point?
The “spiked helmet” sign can be seen by an acute coronary artery occlusion as an ST-elevation myocardial infarction (STEMI). Reciprocal ST-depression in these cases should raise the suspicion of STEMI.

How might this improve emergency medicine practice?
The “spiked helmet” sign can be seen in various diseases, including myocardial infarction. Differential diagnosis of ST-Elevation on ECG is broad and has to be scrutinized with care.

mechanism of this phenomenon is an epidermal or diaphragmatic “stretch” due to an acute rise in the intrathoracic or intra-abdominal pressure. In fact, Tomcsany et al described the “spiked helmet” sign in one case of gastric distension and one case of pneumothorax.² Littmann and Monroe also described a case of real-time recognition of the “spiked helmet” sign in a patient with pneumothorax.³

However, the sign has also been described in patients with subarachnoid hemorrhage and after ablation of the left stellate ganglion, in which an adrenergic excess was postulated as the mechanism associated with Takotsubo cardiomyopathy and long QT.⁴ Independent of the etiology, the “spiked helmet” sign has been associated with a very high mortality.¹ We found only one report of a patient with the “spiked helmet” sign interpreted as a myocardial infarction, but the documentation is poor and coronary angiography was not performed.⁵ In our case we can clearly associate the “spiked helmet” sign to an acute major coronary artery occlusion resulting in myocardial infarction. A nonspecific intraventricular block in the inferior leads and a slightly long QTc could have played a role leading to this particular ECG configuration. The prognostic role of this sign in cardiac disease remains unclear.

Finally, we would like to emphasize that the definition of the “spiked helmet” sign is not unambiguous, because just defined as an ST-elevation with the upward shift starting before the onset of the QRS complex. A recent case of Crinion et al showed the “spiked helmet” sign by a patient with septic shock, where however the upward shift preceding the QRS complex could have been given by a negative T wave, and not necessarily by an elevation of the isoelectric line.⁶ Interobserver agreement should be investigated in future studies. The differential diagnoses for ST-elevations remain broad and should be scrutinized with attention. The history, physical exam, and clinical picture with possibly venous blood gas analysis with electrolytes, and point-of-care ultrasound could rapidly help to lead to the final diagnosis.

CONCLUSION

Despite the association with non-cardiac illnesses, the “spiked helmet” sign can be seen in acute coronary artery occlusion as an ST-elevation myocardial infarction (STEMI). Reciprocal ST-depression in these cases should raise the suspicion of STEMI.

The authors attest that their institution requires neither Institutional Review Board approval, nor patient consent for publication of this case report. Documentation on file.

Address for Correspondence: Bruno Minotti, MD, Cantonal Hospital of St. Gallen, Department of Emergency Medicine, Rorschacher Strasse 95, 9007 St. Gallen, Switzerland. Email: bruno.minotti@kssg.ch.

Conflicts of Interest: By the CPC-EM article submission agreement, all authors are required to disclose all affiliations, funding sources and financial or management relationships that could be perceived as potential sources of bias. The authors disclosed none.

Copyright: © 2021 Minotti et al. This is an open access article distributed in accordance with the terms of the Creative Commons Attribution (CC BY 4.0) License. See: <http://creativecommons.org/licenses/by/4.0/>

REFERENCES

1. Littmann L and Monroe MH. The “spiked helmet” sign: a new electrocardiographic marker of critical illness and high risk of death. *Mayo Clin Proc.* 2011;86(12):1245-6.
2. Tomcsányi J, Frész T, Proctor P, et al. Emergence and resolution of the electrocardiographic spiked helmet sign in acute noncardiac conditions. *Am J Emerg Med.* 2015;33(1):127.e5-7.
3. Littmann L and Proctor P. Real time recognition of the electrocardiographic “spiked helmet” sign in a critically ill patient with pneumothorax. *Int J Cardiol.* 2014;173(3):e51-2.
4. Simon A and Járαι Z. Is the spiked helmet sign the manifestation of long QT syndrome? *J Electrocardiol.* 2019;55:16-9.
5. Oluyadi F, Kariyanna PT, Jayarangaiah A, et al. Helmet sign on EKG: a rare indicator of poor prognosis in critically ill patients. *Am J Med Case Rep.* 2019;7(10):260-3.
6. Crinion D, Abdollah H, Baranchuk A. An ominous ECG sign in critical care. *Circulation.* 2020;141(25):2106-9.

Legionella Pneumonia on Point-of-care Ultrasound in the Emergency Department: A Case Report

Robert W. Lopez, BS*
Matthew K. Hysell, MD†
Jereme P. Long, DO†
Joseph Longobardi, DO†

*Des Moines University College of Osteopathic Medicine, Des Moines, Iowa
†Spectrum Health - Lakeland, Emergency Medicine, St. Joseph, Michigan

Section Editor: Christopher Sampson, MD

Submission history: Submitted October 25, 2020; Revision received January 17, 2021; Accepted January 14, 2021

Electronically published March 1, 2021

Full text available through open access at http://escholarship.org/uc/uciem_cpccem

DOI: 10.5811/cpcem.2021.1.50314

Introduction: *Legionella* is an uncommon, atypical organism that can cause community-acquired pneumonia. Commonly associated with high fevers, gastrointestinal symptoms, and hyponatremia, it can be easily overlooked, especially during the coronavirus disease of 2019 (COVID-19) pandemic. *Legionella* has specific antibiotic treatment that will improve outcome; thus, its recognition is important.

Case Report: We present a case of *Legionella* pneumonia in a man presenting with shortness of breath and fever. The patient's initial chest radiography was negative. With the use of point-of-care ultrasound (POCUS) the changes of atypical pneumonia could be seen. Ultimately *Legionella* was confirmed with urine antigen testing, and appropriate antibiotic treatment was started.

Discussion: Given the increased awareness of COVID-19 it is important to consider a broad differential with respiratory illness. *Legionella* pneumonia on POCUS is consistent with atypical pneumonia descriptions on ultrasound. Point-of-care ultrasound can be used to diagnose atypical pneumonia, specifically caused by *Legionella* in our case.

Conclusion: *Legionella* is evident on POCUS but is difficult to distinguish from other infections with POCUS alone. One should consider *Legionella* if POCUS is positive for signs of atypical infection. [Clin Pract Cases Emerg Med. 2021;5(2):155–158.]

Keywords: *Ultrasound; Legionella; atypical pneumonia; case report.*

INTRODUCTION

Legionella is commonly known as an infection causing pneumonia, gastrointestinal symptoms, hyponatremia, and high fevers with an association to cooling towers.^{1,2} *Legionella* is one of several bacteria that can cause atypical pneumonias including chlamydia and mycoplasma.² Atypical pneumonias are responsible for roughly 14% of community-acquired pneumonias with *Legionella* being responsible for roughly 3% of those cases.³ Typically, atypical pneumonias are acquired from the community and present with a broad range of symptoms, including cough, fever, and dyspnea, as well as upper respiratory symptoms such as rhinitis and odynophagia.² Diagnosis of these diseases is challenging since each pathogen requires specific testing, which

can be overlooked with the current coronavirus disease of 2019 (COVID-19) pandemic pushing to the top of our differentials.

Traditional chest radiograph (CXR) imaging has been shown to not offer the highest sensitivity in identifying a pneumonia.⁴ In this regard, point-of-care ultrasound (POCUS) has been demonstrated to show a much higher sensitivity for respiratory infection.⁴ While there are generous amounts of data being produced on COVID-19, there are very limited descriptions of the POCUS appearance of *Legionella*.

CASE REPORT

A 62-year-old male with a history of sarcoidosis and rheumatoid arthritis on adalimumab presented to the

emergency department (ED) with a 4- to 5-day history of a minimally productive cough, fever, and dyspnea. He had previously called his primary care physician's office and had a negative COVID-19 screen and was put on, but did not start, oral levofloxacin. The patient had no hemoptysis, no nausea or vomiting, and no abdominal pain. He was a nonsmoker. Vital signs at triage were blood pressure 127/68 millimeters of mercury, heart rate of 112 beats per minute, respiratory rate of 38 breaths per minute, and temperature 103.3° Fahrenheit (39.6° Celsius). The patient's oxygen saturation was 96% on room air at rest, although it would drop to the high 80s with minimal exertion. He had bilateral rhonchi on exam. He was hyponatremic with a sodium of 129 milliequivalents per liter (mEq/L) (reference range: 135-145 mEq/L). White blood cell count was 11.4×10^3 per microliter (μl) ($4.5\text{-}11 \times 10^3 \mu\text{l}$), which was 83% neutrophils (40-75%). A CXR (Image 1) was performed and read as negative. Point-of-care ultrasound

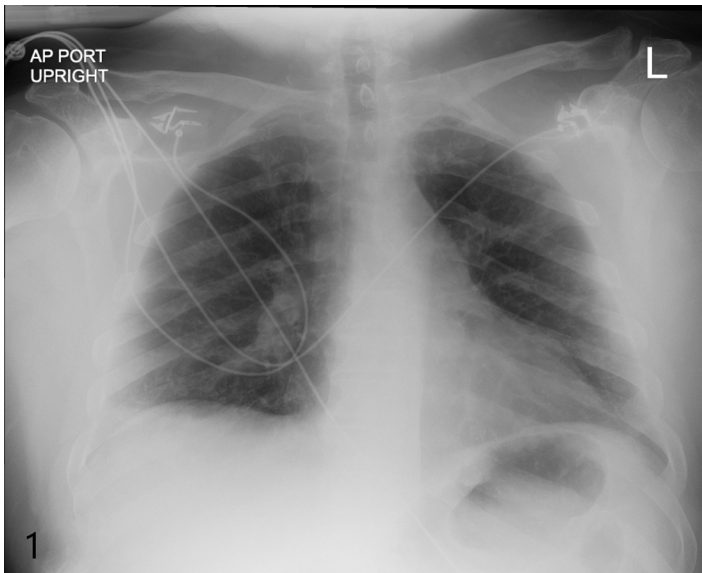


Image 1. Clear anterior posterior portable chest radiograph taken in the emergency department.

(Image 2A-B) was performed after the negative radiograph. The ultrasound showed multiple B-lines (Image 2A) with skip lesions and small consolidations (Image 2B).

Despite the negative CXR, the POCUS coupled with the presentation maintained pneumonia as the primary differential. Given the hypoxia and tachypnea the patient was admitted and started on a combination therapy of ceftriaxone and doxycycline. Chest computed tomography angiography was performed by the inpatient team to investigate for pulmonary embolus after the COVID-19 test was resulted negative. The study showed bilateral multifocal areas of irregular consolidation and nodularity (Image 3). Ground-glass opacities and infiltrates were seen within the posterior aspects of the lower lobes. Ultimately, a urine antigen test for

CPC-EM Capsule

What do we already know about this clinical entity?

Legionella pneumonia is an atypical pneumonia presenting with a broad range of symptoms including cough, fever, and dyspnea.

What makes this presentation of disease reportable?

There are few confirmed descriptions of the ultrasound appearance of Legionella.

What is the major learning point?

Legionella pneumonia is an example of an atypical pneumonia that is difficult to distinguish from viral pneumonias such as those caused by coronavirus disease of 2019.

How might this improve emergency medicine practice?

This case serves as a reminder that Legionella pneumonia presents on ultrasound as an atypical pneumonia and should be considered on the differential.

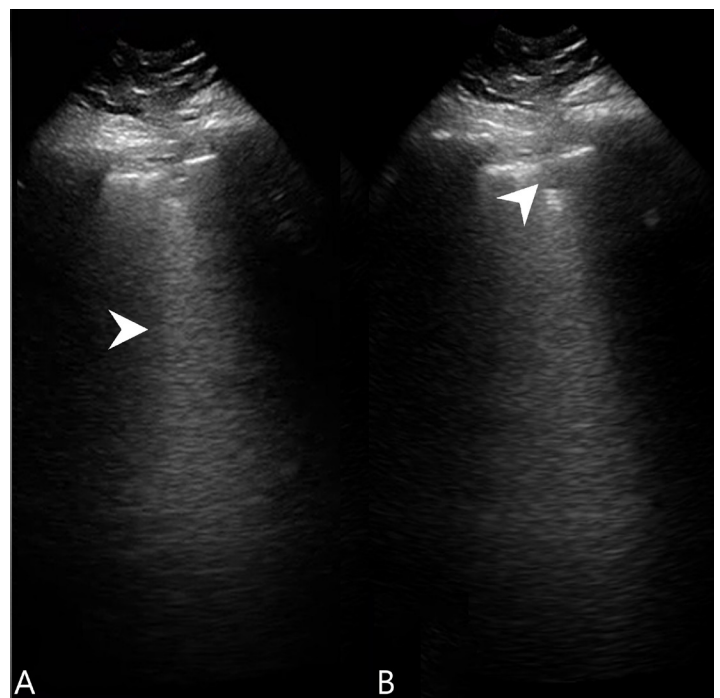

Image 2. A) Lung ultrasound showing a B-line (arrowhead), and B) lung ultrasound showing a subpleural consolidation (arrowhead).

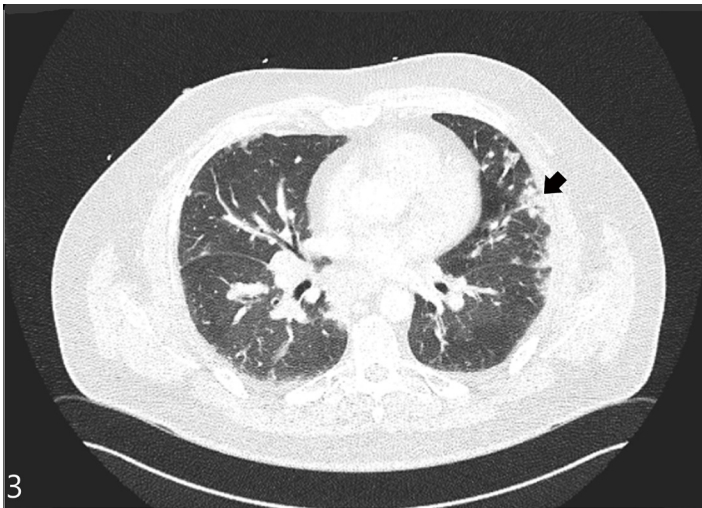


Image 3. Computed tomography angiography displaying evidence of pleural consolidations (black arrowhead).

Legionella pneumophila was positive and his antibiotic therapy was switched to intravenous (IV) levofloxacin. With the addition of albuterol nebulizer treatment, the patient's clinical course improved over the next couple of days. He was discharged on day three of admission and continued seven more days of levofloxacin.

DISCUSSION

Atypical pneumonia is on the differential for every dyspneic patient to come into the ED. However, it can be easily overshadowed by COVID-19, which can present similarly on POCUS. COVID-19 appears to have irregular pleural lines, B-lines, and subpleural consolidations.⁵ Our patient also demonstrated each of these findings. Atypical pneumonias of either bacterial or viral etiology can contain multiple small consolidations on ultrasound, which are often bilateral.⁶ Typical bacterial pneumonias, in comparison, tend to have larger and more solitary consolidations.⁶

Little has been documented in current literature on the POCUS appearance of *Legionella* pneumonia specifically. One prior case report described a case of *Legionella* pneumonia noted as a hypoechoic lesion with irregular boundaries and bronchograms.⁷ We did find small consolidations, but also multiple B-lines. When B-lines alternate with unaffected parenchyma it creates an effect known as skip lesions, also present here.⁸ While we did not specifically describe bronchograms on our case, they can be expected when infectious or inflammatory processes are in the lungs.⁹ The B-lines can be expected in pneumonia.¹⁰ While POCUS in sarcoidosis will reveal irregular pleural lines, B-lines are an uncommon finding present in less than 5%.¹¹ The appearance of the small subpleural consolidations is in accordance with how an atypical pneumonia would be expected to manifest; however, it can be seen in sarcoidosis as well.^{6, 11}

Lung ultrasound shows high sensitivity, of roughly 95% for diagnosing pneumonia.⁴ Computed tomography remains the gold standard for the diagnosis of pneumonia, although it is often impractical. Point-of-care ultrasound offers a more rapid way of assessing the patient especially amidst a global pandemic. It is also worth mentioning that the use of POCUS in our case helped in ruling out other causes for the patient's dyspnea, such as pulmonary edema or even cardiac causes, while at bedside.⁸

Once *Legionella* was confirmed the inpatient team transitioned from ceftriaxone and doxycycline to IV levofloxacin. *Legionella* can be effectively treated with levofloxacin or azithromycin, both of which seem to be equally effective options of treatment.¹²

CONCLUSION

Respiratory infections have a broad range of microbial etiologies to consider. We must remain vigilant when considering the etiology of the infection. Atypical bacterial causes of pneumonia, such as *Legionella*, have many overlapping characteristics on POCUS with COVID-19 making it hard to differentiate between the two. When COVID-19 is negative we must consider atypical pneumonias so that our therapy can be tailored appropriately.

The authors attest that their institution requires neither Institutional Review Board approval, nor patient consent for publication of this case report. Documentation on file.

Address for Correspondence: Robert W. Lopez, BS, Des Moines University, College of Osteopathic Medicine, 3200 Grand Ave, Des Moines, IA 5031. Email: robert.w.lopez@dmu.edu.

Conflicts of Interest: By the CPC-EM article submission agreement, all authors are required to disclose all affiliations, funding sources and financial or management relationships that could be perceived as potential sources of bias. The authors disclosed none.

Copyright: © 2021 Lopez et al. This is an open access article distributed in accordance with the terms of the Creative Commons Attribution (CC BY 4.0) License. See: <http://creativecommons.org/licenses/by/4.0/>

REFERENCES

1. Hugosson A, Hjorth M, Bernander S, et al. A community outbreak of Legionnaires' disease from an industrial cooling tower: assessment of clinical features and diagnostic procedures. *Scand J Infect Dis*. 2007;39(3):217-24.
2. Sharma L, Loiser A, Tolbert T, et al. Atypical pneumonia. *Clin Chest Med*. 2017;38(1):45-58.
3. Marchello C, Dale AP, Thai TN, et al. Prevalence of atypical

- pathogens in patients with cough and community-acquired pneumonia: a meta-analysis. *Ann Fam Med.* 2016;14(6):552-66.
4. Ye X, Xiao H, Chen B, et al. Accuracy of lung ultrasonography versus chest radiography for the diagnosis of adult community-acquired pneumonia: review of the literature and meta-analysis. *PLoS One.* 2015;10(6):e0130066.
 5. Duggan NM, Liteplo AS, Shokoohi H, et al. Using lung point-of-care ultrasound in suspected COVID-19: case series and proposed triage algorithm. *Clin Pract Cases Emerg Med.* 2020;4(3):289-94.
 6. Berce V, Tomazin M, Gorenjak M, et al. The usefulness of lung ultrasound for the aetiological diagnosis of community-acquired pneumonia in children. *Sci Rep.* 2019;9(1):17957.
 7. D'Angelo A, De Simone C, Pagnottella M, et al. A case of *Legionella pneumophila* evaluated with CT and ultrasound. *J Ultrasound.* 2017;20(3):243-5.
 8. Millington SJ, Koenig S, Mayo P, et al. Lung ultrasound for patients with coronavirus disease 2019 pulmonary disease. *Chest.* 2021;159(1):205-11.
 9. Stadler JAM, Andronikou S, Zar HJ. Lung ultrasound for the diagnosis of community-acquired pneumonia in children. *Pediatr Radiol.* 2017;47(11):1412-9.
 10. Reissig A and Copetti R. Lung ultrasound in community-acquired pneumonia and in interstitial lung diseases. *Respiration.* 2014;87(3):179-89.
 11. Piprek M, Kryger M, Kosiak W, et al. The utility of transthoracic lung ultrasound in assessing pulmonary sarcoidosis. *Eur Respir J.* 2019;54(63):1947.
 12. Garcia-Vidal C, Sanchez-Rodriguez I, Simonetti AF, et al. Levofloxacin versus azithromycin for treating *Legionella* pneumonia: a propensity score analysis. *Clin Microbiol Infect.* 2017;23(9):653-8.

Angioedema Secondary to tPA Use in Acute Ischemic Stroke Patient with Hypertension: A Case Report

Chris Kim, DO
Andrea Hladik, MD

Eisenhower Medical Center, Department of Emergency Medicine, Rancho Mirage, California

Section Editor: Steven Walsh, MD

Submission history: Submitted August 21, 2020; Revision received January 13, 2021; Accepted January 27, 2021

Electronically published April 23, 2021

Full text available through open access at http://escholarship.org/uc/uciem_cpem

DOI: 10.5811/cpem.2021.1.49582

Introduction: A well-documented complication of administering tissue plasminogen activator (tPA) in stroke patients is acute intracranial bleeding. A lesser known but still significant complication is angioedema secondary to tPA administration, which can develop in certain individuals with risk factors such as angiotensin converting enzyme (ACE) inhibitor use and location of the stroke. Knowing the potential for this life-threatening complication and being prepared for its proper management is vital for emergency physicians.

Case Report: We report a 53-year-old Black female who presented to the emergency department with sudden onset of slurred speech and a facial droop. She was found to have an acute ischemic stroke and tPA was administered. She subsequently developed angioedema. Retrospectively, the patient was found to have risk factors that are thought to predispose patients to tPA-induced angioedema.

Conclusion: Risk factors associated with angioedema secondary to tPA administration have been documented in patients taking ACE inhibitors, as well as patients who develop strokes in the frontal lobe. While many cases may be mild, some patients may develop life-threatening angioedema. Although this complication does not necessarily contraindicate tPA use, it is prudent for the emergency physician to be vigilant for its development, prepared for its treatment, and to be diligent in assessing the need for control of the patient's airway. [Clin Pract Cases Emerg Med. 2021;5(2):159–162.]

Keywords: *tPa; angioedema; stroke.*

INTRODUCTION

The risk of intracranial hemorrhage is a known complication of tissue plasminogen activator (tPA) administration in stroke patients. Although reported rates vary, the risk is thought to be around 6%.¹ Because of the devastating effects of this complication, multiple precautions and restrictions to the use of tPA have been outlined in approved guidelines set forth by the American Heart Association and the American Stroke Association.² Multiple cases of tPA-associated angioedema have been documented in the literature with an estimated incidence of approximately 5%.¹ Review of the published literature (including database searches in PubMed) shows discussion of the acute

management of tPA-associated angioedema. Additionally, while the pathophysiologic mechanism for the development of angioedema in this circumstance has been proposed, it has not been confirmed. Angioedema secondary to tPA infusion can range from mild to severe and may require intubation for protection of the airway.³

Given that tPA-associated angioedema can be trivial or life-threatening, awareness and preparation should be discussed prior to administration of the drug. This case we report here helps highlight the known risk factors of tPA-associated angioedema, as well as the therapeutic interventions currently suggested for management of such cases. In addition, this case helps corroborate previously published literature regarding risk

factors thought to contribute to the development of angioedema with tPA infusion.

CASE REPORT

A 53-year old Black female presented to the emergency department (ED) with sudden onset of a facial droop and slurring of her words. The patient was last seen well 45 minutes prior to arrival. She had previously been seen three days earlier in the ED for hypertension and admitted to stopping her antihypertensives four months prior. She was prescribed antihypertensives at that time with recommendations to follow up with her primary care provider. A day prior to her presentation she had restarted lisinopril 20 milligrams (mg) daily, amlodipine 5 mg daily, and furosemide 20 mg daily as instructed by her primary care provider. Additional home medications included metformin 500 mg twice daily and potassium chloride.

The patient denied any headache, visual changes, dizziness, or numbness. She was found to be hypertensive upon arrival with blood pressure of 200/106 millimeters mercury (mm Hg), heart rate 130 beats per minute, respiratory rate 20 respirations per minute, pulse oximetry of 98% on room air, and temperature of 98.7° Fahrenheit. Initial neurologic exam showed the patient to be oriented to person, place, and time, with an obvious right-sided facial droop, deviation of tongue to the right side, and slurred speech. There were no initial motor deficits noted in her extremities as she was able to lift both her upper and lower extremities against gravity. Visual fields were grossly intact as was finger-to-nose testing. The remainder of her physical exam was otherwise unremarkable. Initial National Institutes of Health (NIH) stroke scale score was calculated to be approximately 2-3. The patient was taken for a computed tomography (CT) angiography of head and neck with and without contrast immediately after her initial exam.

The CT angiography of head and neck with and without contrast showed no acute intracranial findings, and no high-grade stenosis or occlusion in the head and neck through the internal carotid arteries. Vertebral artery imaging was obscured secondary to movement, and a thyroid goiter was also present. Upon return from CT, serial neurological exams were performed, which revealed right upper extremity weakness, thus increasing the NIH stroke scale score to 3-4. Tele-neurology was consulted and tPA was recommended. The patient and her husband agreed with the treatment plan regarding recommendations for tPA infusion. Tissue plasminogen activator was then administered for a total of 72.19 mg. A single dose of labetalol for 10 mg intravenous (IV) was initiated for blood pressure control.

During tPA infusion, the patient developed swelling of the right upper lip and right side of the tongue. It was believed that the tPA was the cause of her angioedema, and she was subsequently given diphenhydramine 50 mg IV in addition to

CPC-EM Capsule

What do we already know about this clinical entity?

Angioedema secondary to tissue-plasminogen activator (tPA) use is a well-documented occurrence in patients presenting with an acute ischemic stroke

What makes this presentation of disease reportable?

This case report corroborates the risk factors associated with angioedema secondary to (tPA) use as well as current recommendations for management of this condition.

What is the major learning point?

The major learning point is to recognize the condition and to take steps to ensure airway protection and resolution of the condition, should it arise.

How might this improve emergency medicine practice?

This case report highlights risk factors that can lead to this condition to allow physicians to readily recognize this condition and appropriately manage it with current guidelines.

methylprednisolone 125 mg IV. The infusion of tPA had coincidentally finished as the patient first began to develop angioedema. As a result, there was no need to discontinue the infusion, which is usually recommended when angioedema occurs. The patient remained hemodynamically stable, was able to maintain her airway, and did not require intubation while observed in the ED. She was subsequently admitted to the intensive care unit with the diagnosis of acute ischemic stroke.

Prior to leaving the ED, serial neurological exams revealed improvement in her right upper extremity weakness, but she continued to have lingering facial droop. Reassessment of the patient's angioedema showed improvement with only minimal swelling of the right upper lip and right side of tongue. She continued to maintain a patent airway. Initial laboratory studies included complete blood count, electrolyte panel, and prothrombin time/international normalized ratio and returned normal, except for mild hypokalemia of 3.1 millimoles per liter (mmol/L) (reference range 3.5-5.0 mmol/L) and elevated glucose of 226 (60-126 mg/dL).

After admission to the hospital, the patient underwent magnetic resonance imaging, which-identified a subacute

evolving infarct in the posterior left frontal lobe with a possible additional area of evolving infarct in the right frontal lobe as well. Magnetic resonance angiography revealed no primary vascular lesion such as an aneurysm, arteriovenous malformation, or arterial narrowing. During her hospital course, she continued to show improvement in her right upper extremity weakness and some improvement in the facial droop. Continued observation showed improvement in the angioedema over the course of a couple of days as well.

DISCUSSION

Angioedema occurs due to an increase in local vascular permeability in submucosal or subcutaneous tissue. Histamine and bradykinin are vasoactive mediators usually involved in the development of angioedema, with most cases being mediated by one or the other.⁴ Some investigators indicate that both may be involved in certain cases.⁵ The use of tPA leads to fibrinolysis by hydrolyzing plasminogen to plasmin. Plasmin may play a role in the development of angioedema by activating the kinin pathway, which in turn leads to the formation of bradykinin. Plasmin also activates the complement system, leading to the eventual degranulation of mast cells and the release of histamine,^{3,6} which results in the formation of tissue swelling.

Angioedema after tPA infusion is a known complication and has an incidence of approximately 1-5%.⁷ Additionally, it is suggested that angioedema will typically occur on the contralateral side of the ischemic hemisphere.⁶ Several studies have proposed certain predisposing factors to the development of angioedema with the administration of tPA. A study performed by Hurford et al. identified that the use of angiotensin converting enzyme (ACE) inhibitors increases the risk of angioedema post-tPA use.⁸ Another study performed by Myslimi et al. suggests that when patients with hypertension are treated with ACE inhibitors and receive tPA, the rate of angioedema can occur as frequently as 1 in 6 patients.⁹ Fröhlich et al. suggests that angioedema secondary to tPA in patients with ischemic stroke in the insulo-opercular region is due to bradykinin effects causing vasodilation and increasing vascular permeability as described above.¹⁰ Other studies have also suggested that acute stroke in the frontal and insular cortex of the brain increases the risk of angioedema post-tPA use.⁶ The rate of angioedema in acute ischemic stroke cases involving a total insular infarct is suggested to occur in about 1 in 10 patients.⁹

These findings support and align with the presentation of our patient. Prior to her arrival to the ED, she was restarted on ACE inhibitors to manage her hypertension. She subsequently presented with an ischemic stroke to the left frontal lobe with a resulting hemi-orolingual angioedema on the right side after receiving tPA. The use of ACE inhibitors as well as the development of a left frontal lobe stroke are likely to have

increased her risk of developing hemi-orolingual angioedema and is supported by the above findings.

As previously mentioned, angioedema associated with the use of tPA is typically mild, although there have been severe cases leading to airway compromise as well as death.^{3,11} As a result of this risk, caution must be taken to monitor the patient's airway to avoid any respiratory compromise. Management should include protection of the airway, discontinuation of the tPA-infusion if still in process, holding any ACE inhibitors, and the rapid administration of methylprednisolone 125 mg, diphenhydramine 50 mg, and ranitidine 50 mg or famotidine 20 mg. If the angioedema does not resolve, 0.1% epinephrine in 0.3 milliliters (mL) as a intramuscular injection or 0.5mL nebulizer treatment can also be administered. In cases of refractory angioedema, it has been suggested that complement component (C1)-esterase inhibitors can be considered as an additional therapeutic measure.^{12,13}

For our patient, these medications were chosen based on recommendations and guidelines for tPA-associated angioedema on UpToDate (Wolters Kluwer Health, Waltham, MA). There is questionable efficacy of these medications for the treatment of tPA-associated angioedema (and angioedema in general); these medications seem to have varying to limited degrees of success with administration. This may be due to the kallikrein-bradykinin pathway that can lead to angioedema and that corticosteroids and antihistamines do not directly act on bradykinin. Other agents described by Powers et al. include C1-esterase inhibitors. However, these agents have unproven efficacy in current literature and should be used with prudent judgment.

CONCLUSION

This case report exemplifies the typical patient possessing the possible risk factors associated with the development of angioedema secondary to use of tPA in the treatment of acute stroke. Our patient was on an ACE inhibitor and she was shown to have developed an infarct in the frontal lobe. Prompt management of stroke patients is key for patient outcomes, and being aware of all the complications associated with the use of tPA is vital to properly managing these patients. Fortunately, our patient did not develop life-threatening angioedema. However, she was certainly at risk given the clinical presentation and all factors considered. Tissue plasminogen activator does not necessarily need to be withheld in such a patient, but emergency physicians must be well acquainted with the possibility of this life-threatening complication in order to deal with it should the need arise.

The authors attest that their institution requires neither Institutional Review Board approval, nor patient consent for publication of this case report. Documentation on file.

Address for Correspondence: Andrea Hladik, MD, Eisenhower Medical Center, Department of Emergency Medicine, 39000 Bob Hope Drive, Rancho Mirage, CA 92270. Email: ajhladik@me.com.

Conflicts of Interest: By the CPC-EM article submission agreement, all authors are required to disclose all affiliations, funding sources and financial or management relationships that could be perceived as potential sources of bias. The authors disclosed none.

Copyright: © 2021 Kim et al. This is an open access article distributed in accordance with the terms of the Creative Commons Attribution (CC BY 4.0) License. See: <http://creativecommons.org/licenses/by/4.0/>

REFERENCES

1. Miller DJ, Simpson JR, Silver B. Safety of thrombolysis in acute ischemic stroke: a review of complications, risk factors, and newer technologies. *Neurohospitalist*. 2011;1(3):138-47.
2. Powers WJ, Rabinstein AA, Ackerson T, et al. Guidelines for the early management of patients with acute ischemic stroke: 2019 update to the 2018 Guidelines for the Early Management of Acute Ischemic Stroke: A Guideline for Healthcare Professionals From the American Heart Association/American Stroke Association. *Stroke*. 2019;50(12):e344-e418. Erratum in: *Stroke*. 2019;50(12):e440-1.
3. Sczepanski M and Bozyk P. Institutional incidence of severe tPA-Induced angioedema in ischemic cerebral vascular accidents. *Crit Care Res Pract*. 2018;2018:9360918.
4. Li HH. Angioedema. 2018. Available at: <https://emedicine.medscape.com/article/135208-overview>. Accessed September 17, 2019.
5. Asero R, Bavbek S, Blanca M, et al. Clinical management of patients with a history of urticaria/angioedema induced by multiple NSAIDs: an expert panel review. *Int Arch Allergy Immunol*. 2013;160(2):126-33.
6. Hill MD, Lye T, Moss H, et al. Hemi-oro-lingual angioedema and ACE inhibition after alteplase treatment of stroke. *Neurology*. 2003;60(9):1525-7.
7. Burd M, McPheeters C, Scherrer LA. Oro-lingual angioedema after tissue plasminogen activator administration in patients taking angiotensin-converting enzyme inhibitors. *Adv Emerg Nurs J*. 2019;41(3):204-14.
8. Hurford R, Rezvani S, Kreimei M, et al. Incidence, predictors and clinical characteristics of oro-lingual angio-oedema complicating thrombolysis with tissue plasminogen activator for ischaemic stroke. *J Neurol Neurosurg Psychiatry*. 2015;86(5):520-3.
9. Myslimi F, Caparros F, Dequatre-Ponchelle N, et al. Oro-lingual angioedema during or after thrombolysis for cerebral ischemia. *Stroke*. 2016;47(7):1825-30.
10. Fröhlich K, Macha K, Gerner ST, et al. Angioedema in stroke patients with thrombolysis. *Stroke*. 2019;50(7):1682-7.
11. Hill MD, Buchan A, Canadian Alteplase for Stroke Effectiveness Study (CASES) Investigators. Thrombolysis for acute ischemic stroke: results of the Canadian Alteplase for Stroke Effectiveness Study. *CMAJ*. 2005;172(10):1307-12.
12. Pahs L, Droege C, Kneale H, et al. A novel approach to the treatment of oro-lingual angioedema after tissue plasminogen activator administration. *Ann Emerg Med*. 2016;68(3):345-8.
13. Powers WJ, Rabinstein AA, Ackerson T, et al. 2018 Guidelines for the Early Management of Patients with Acute Ischemic Stroke: A Guideline for Healthcare Professionals from the American Heart Association/American Stroke Association. *Stroke*. 2018;49(3):e46-e110. Erratum in: *Stroke*. 2018;49(3):e138.

Transient Quadriplegia: A Case-Based Approach to Cervical Trauma

Raymond Jabola, DO*
Benjamin Boswell, DO*
Robert H. Lutz, MD†
Jack Casey†
Anthony Ceraulo, DO‡

*Case Western Reserve University School of Medicine, Department of Emergency Medicine, Cleveland, Ohio
†Davidson College, Department of Sports Medicine, Davidson, North Carolina
‡Duke University Medical Center, Department of Orthopedics, Durham, North Carolina

Section Editor: Scott Goldstein, MD

Submission history: Submitted July 30, 2020; Revision received December 12, 2020; Accepted December 12, 2020

Electronically published February 23, 2021

Full text available through open access at http://escholarship.org/uc/uciem_cpccem

DOI: 10.5811/cpcem.2020.12.49364

Introduction: Spinal cord injuries are a common reason for presentation to the emergency department (ED). Sports-related spinal injuries are one of the least common spinal injuries, falling behind vehicular accidents, acts of violence, and falls.

Case Report: This case report describes a case of transient quadriplegia in a 17-year-old male who presented to the ED after a helmet-to-helmet collision while participating in football.

Conclusion: Emergency physicians should be cognizant of potential spinal cord injury using clinical decision tools and radiologic imaging to properly disposition a patient presenting with cervical spine injury. [Clin Pract Cases Emerg Med. 2021;5(2):163–166.]

Keywords: *transient; quadriplegia; neuropraxia; cervical; trauma.*

INTRODUCTION

Since 2015, 7.8% of spinal cord injuries (SCI) have been attributed to a sports incident.¹ There are approximately 17,810 new SCI cases each year in the United States (approximated population 329 million in 2020).¹ The annual incidence of sports-related SCI is estimated to be 1389 cases per year. Because a majority of SCI cases are due to vehicular accidents, acts of violence, and falls, sports-related SCI are regarded as rare, varying in demographics and difficult to predict in healthy individuals. Patients who present in the emergency department (ED) with SCI must be properly triaged and evaluated to reduce the risk of neurological damage.

The severity of SCI can range from transient to permanent injury. On this spectrum, the least severe injury is known as neuropraxia, which is defined as a transient loss of motor or sensory function that can last from less than 15 minutes to 48 hours. Cervical cord neuropraxia occurs most commonly in contact sports, with the highest rates found in football players estimated to be 7.3 per 10,000 individuals.² In this case report,

cervical cord neuropraxia will be considered synonymous with transient quadriplegia (TQ). The mechanism of injury in TQ results from hyperflexion, hyperextension, or direct axial load of the cervical spine. In football injuries, this tends to occur from flexion of the cervical spine in addition to a concurrent axial force. The resulting neurological dysfunction can be anxiety-inducing to both the individual and the medical teams involved in patient care. When approaching traumatic cervical injuries, appropriate ED response is comprised of concise clinical decision-making, proper imaging studies, and appropriate consultations.

The case we present here pertains to a football player who presented to the ED with TQ. The purpose of this case report is to discuss the pathophysiology and presentation of TQ, as well as recommendations for the ED approach to SCI, particularly cervical spine injury.

CASE REPORT

A 17-year-old Black male presented to the ED with weakness. Prior to arrival to the ED, the patient was involved

in a helmet-to-helmet collision while participating in a football game. Physicians from both teams were called onto the field by the athletic trainer after the patient reported paralysis of bilateral upper and lower extremities as well as loss of sensation from the neck down. The cervical spine was manually stabilized and emergency medical services (EMS) were alerted. While the patient's cervical spine was stabilized, his helmet and shoulder pads were removed. Over the course of 10 minutes as EMS was pending arrival, he regained sensation and movement of his extremities. After regaining movement and sensation, on-site examination demonstrated sixth cervical (C6) vertebral tenderness to palpation, but no other abnormalities. The patient's cervical spine was manually held and he was placed onto a backboard. He was then transferred to the ED.

Ancillary information was provided indicating the patient had a similar episode two weeks prior. That episode involved a similar helmet-to-helmet collision that resulted in a sensation of "shock" in which he could not move for several seconds but was ultimately able to stand on his own. On-site physical exam was negative and without any acute physical findings. A concussion screen was performed, which was normal.

Upon ED arrival, the patient denied having a headache, change in vision, tinnitus, loss of consciousness, nausea, vomiting, confusion, chest pain, shortness of breath, back pain, or abdominal pain. He remembered the entire event and had no history of concussions. His vital signs included a blood pressure of 119/53 millimeters of mercury, pulse of 84 beats per minute, respiratory rate of 25 respirations per minute, a temperature of 100.1° Fahrenheit (37.8° Celsius), and an oxygen saturation of 100% on room air. He was oriented, well appearing, and in no acute distress. Head and cervical spine computed tomography (CT) were unremarkable, and he had no fractures.

Cervical spine lateral flexion-extension radiographs did not show any cervical instability (Images 1 and 2). He ambulated normally following removal of the cervical collar and was alert with normal mood and affect. His physical exam and neurological exam were unremarkable. He had no cranial nerve deficits, and he had full strength and sensation in upper and lower extremities bilaterally. The ED determined the patient likely sustained brachial plexus neuropraxia, known in the sports medicine world as a "stinger." He was discharged with return precautions and a follow-up appointment with sports medicine.

The patient followed up with sports medicine three days following the injury and was asymptomatic. Magnetic resonance imaging (MRI) was ordered, which showed congenital cervical spinal canal narrowing at C4 with a canal width of 11 millimeters (mm) (normal range 15-27 mm) (Image 3). He also had C3-C4 bilateral spinal cord contusions and a C6 bone contusion. He was referred to a spine surgeon who recommended permanent disqualification from participation in contact sports.

CPC-EM Capsule

What do we already know about this clinical entity?

Transient quadriplegia has been associated with patients who have cervical stenosis and can occur in populations with no known previous medical history.

What makes this presentation of disease reportable?

The presentation of transient quadriplegia is important due to the potential complications from inadequate evaluation of cervical trauma.

What is the major learning point?

The major learning point is to discuss appropriate evaluation of patients presenting to the emergency department with concerns for cervical trauma.

How might this improve emergency medicine practice?

This case report is aimed to increase emergency physician awareness and discuss the approach to cervical trauma that can occur in sports related injuries.

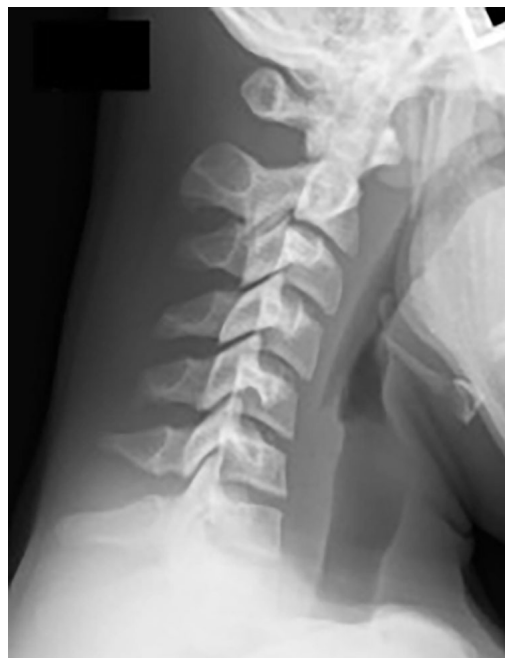

Image 1. Plain lateral cervical radiograph in flexion without abnormalities.

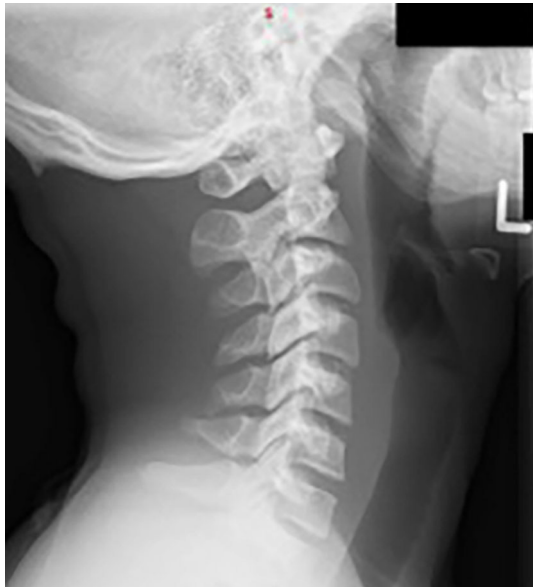

Image 2. Plain lateral cervical radiograph in extension without abnormalities.

DISCUSSION

The pathophysiology of TQ involves a non-neutral cervical position in addition to an axial force. In football injuries, this is usually seen in hyperflexion of the cervical spine with an axial force, which can occur during helmet-to-helmet collision. This causes pincer-like compression of the cervical spine between two vertebrae within the

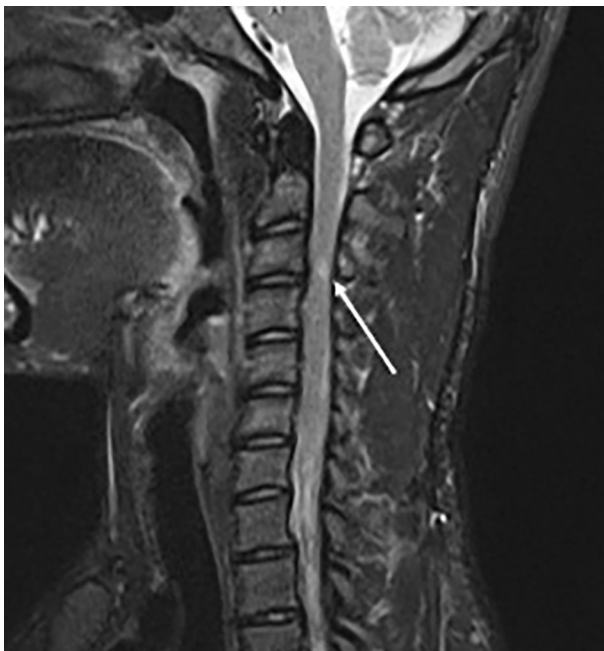

Image 3. Magnetic resonance imaging with arrow demonstrating cervical spinal cord edema at the site of congenital spinal canal narrowing of 11 millimeters.

spinal canal. It is theorized that the compression causes a prolonged depolarization of the neural tissue, thus inhibiting further action potentials (seen in in-vitro studies).³ Patients at risk for TQ are those with a smaller ratio of spinal canal diameter to vertebral body diameter.⁴ This is known as the Torg-Pavlov ratio, coined after orthopedic surgeon Joseph S. Torg and radiologist Helene Pavlov who introduced the ratio method for measuring cervical cord stenosis in the 1980s.

Most patients presenting to the ED with SCI have associated injuries. According to *Advanced Trauma Life Support* (ATLS), 10th ed, 55% of spinal injuries occur in the cervical region, 15% in the thoracic region, 15% in the thoracolumbar junction, and 15% in the lumbosacral junction.⁵ Therefore, in patients with high concern for spinal trauma, high precautions should be placed. Based on the ATLS trauma algorithm, primary and secondary surveys should be performed in a stepwise pattern to ensure a traumatic injury is not missed. Of patients who present with a spinal injury, 25% of these spinal injuries will have a concurrent brain injury.⁵ Hence, the disability assessment should include a Glasgow Coma Scale to trend mental status changes, and proper radiologic imaging to diagnose traumatic injuries including possible head trauma.

In patients who present to the ED with TQ, they do not commonly experience neck pain and loss of cervical range of motion around the time of injury.⁶ Approximately 74% of these patients will have a resolution of neural symptoms within 15 minutes. Only 11% will have symptoms lasting greater than 24 hours. Approximately 80% of these patients will have neural deficits in all four limbs.⁷ In patients who present to the ED, emergency physicians must determine the necessary imaging for each patient.

Two commonly used clinical decision tools help emergency physicians assess whether a patient requires cervical imaging: the National Emergency X-ray Utilization Study (NEXUS); and the Canadian Cervical Spine Rules. Incorporated in these tools are history and physical examination findings, which would indicate the need for radiologic imaging. Such findings would include midline cervical spine tenderness, paresthesia, and mechanism of action. A systematic review of the two clinical decision tools from 2012 found the sensitivity of the Canadian Cervical Spine Rules ranges from 0.90 to 1.00 with a specificity ranging from 0.01 to 0.77, and the sensitivity of the NEXUS criteria ranges from 0.83 to 1.00 with a specificity ranging from 0.02 to 0.46. Due to their high sensitivity, these decision tools are often used in the ED to rule out the need for imaging in patients with suspected cervical spine injury.⁸

In determining the best imaging study, CT of the cervical spine has become the gold standard for screening in cervical spine trauma. According to the 2009 Eastern Association for the Surgery of Trauma (EAST) practice management guidelines, the recommended primary modality of imaging of the cervical

spine in those suspected to have a cervical spine injury is axial CT. Plain radiographs provide no additional information and are advised against due to low sensitivity. In a non-altered patient with negative neurological deficits, a negative CT of the cervical spine is sufficient and EAST guidelines recommend against any further imaging. Should there be a neurological deficit attributable to cervical spine injury, EAST recommends an MRI and neurosurgical consultation.⁹ The practice of using MRI in an acute traumatic setting is variable and differs from institution to institution; it is based on the select populations of interest such as obtunded patients.

Appropriate consultation should take place, whether that be in the hospital or outpatient setting. Neurosurgical spine consultation should be considered in patients with unstable injuries or those with neurological dysfunction. If a proper ED evaluation is performed with negative findings without any residual neurological deficits, a referral to a sports medicine physician would be of value to patients to discuss risks and benefits of returning to contact sports.

CONCLUSION

Sports-related injuries are unpredictable and cause a spectrum of disability to patients. When this patient population presents to the ED, appropriate assessment, clinical decision-making, and imaging is of great importance to reduce prolonged disability. In the case discussed, the patient presented after a 10-minute episode of quadriplegia caused by helmet-to-helmet contact during a football game. After evaluation in the ED, the patient was discharged home with sports medicine follow-up, where an MRI was performed and he was found to have spinal cord contusion at C3-C4. Emergency physicians should be cognizant of potential spinal cord injury using clinical decision tools and radiologic imaging to properly disposition a patient presenting with cervical spine injury. In those patients who are diagnosed with transient quadriplegia, they will need to have an informed discussion with their sports medicine physician or neurosurgeon to reduce the risk of future morbidity.

ACKNOWLEDGMENTS

The authors would like to thank the Great Lakes Chapter Division of AAEM for sponsoring the publication of this article.

The authors attest that their institution requires neither Institutional Review Board approval, nor patient consent for publication of this case report. Documentation on file.

Address for Correspondence: Raymond Jabola, DO, University Hospitals, Cleveland Medical Center, Department of Emergency Medicine, CEM B517, 11100 Euclid Ave, Cleveland, OH, 44106. Email: Raymond.jabola@uhhospitals.org.

Conflicts of Interest: By the CPC-EM article submission agreement, all authors are required to disclose all affiliations, funding sources and financial or management relationships that could be perceived as potential sources of bias. The authors disclosed none.

Copyright: © 2021 Jabola et al. This is an open access article distributed in accordance with the terms of the Creative Commons Attribution (CC BY 4.0) License. See: <http://creativecommons.org/licenses/by/4.0/>

REFERENCES

1. National Spinal Cord Injury Statistical Center. Spinal Cord Injury Facts and Figures at a Glance. 2020. Available at: <https://www.nscisc.uab.edu/Public/Facts and Figures 2020.pdf>. Accessed June 3, 2020.
2. Torg JS, Corcoran TA, Thibault LE, et al. Cervical cord neurapraxia: classification, pathomechanics, morbidity, and management guidelines. *J Neurosurg.* 1997;87(6):843-50.
3. Torg JS, Thibault L, Sennett B, et al. The Nicolas Andry Award. The pathomechanics and pathophysiology of cervical spinal cord injury. *Clin Orthop Relat Res.* 1995;(321):259-69.
4. Torg JS, Naranja RJ Jr, Pavlov H, et al. The relationship of developmental narrowing of the cervical spinal canal to reversible and irreversible injury of the cervical spinal cord in football players. *J Bone Joint Surg Am.* 1996;78(9):1308-14.
5. Stewart RM. (2018). Spine and Spinal Cord Trauma. In: Merrick, C (Ed.). *ATLS: Advanced Trauma Life Support Student Course Manual* (p. 130). Chicago, IL: Am Coll Surg.
6. Page S, Guy JA. Neurapraxia, "stingers," and spinal stenosis in athletes. *South Med J.* 2004;97(8):766-9.
7. Torg JS, Pavlov H, Genuario SE, et al. Neurapraxia of the cervical spinal cord with transient quadriplegia. *J Bone Joint Surg Am.* 1986;68(9):1354-70.
8. Michaleff ZA, Maher CG, Verhagen AP, et al. Accuracy of the Canadian C-spine rule and NEXUS to screen for clinically important cervical spine injury in patients following blunt trauma: a systematic review. *CMAJ.* 2012;184(16):E867-76.
9. Como JJ, Diaz JJ, Dunham CM, et al. Practice management guidelines for identification of cervical spine injuries following trauma: update from the Eastern Association for the Surgery of Trauma practice management guidelines committee. *J Trauma.* 2009;67(3):651-9.

Spontaneous Ureteric Rupture and Its Implications in the Emergency Department: A Case Report

Tallie Wei Lin Chua, MBBS, MMed, MRCEM, FAMS
Evelyn Wong, MBBS, FRCSEd, FRCEM, FAMS

Singapore General Hospital, Department of Emergency Medicine,
Outram Road, Singapore

Section Editor: Austin Smith, MD

Submission history: Submitted November 2, 2020; Revision received February 2, 2021; Accepted February 1, 2021

Electronically published March 12, 2021

Full text available through open access at http://escholarship.org/uc/uciem_cpchem

DOI: 10.5811/cpchem.2021.2.50652

Introduction: Spontaneous ureteric rupture is uncommon and has a wide range of presentations. Accurate diagnosis and timely treatment is necessary to avoid potential serious complications.

Case Report: We present the case of a 55-year-old female who presented with severe right lower abdominal pain with rebound tenderness, vomiting, and a single episode of hematuria. A computed tomography with intravenous contrast of the abdomen and pelvis showed a 0.3-centimeter right upper ureteric calculus, with hydronephrosis and ureteric rupture. In view of the scan findings, a diagnosis of spontaneous ureteric rupture secondary to urolithiasis was made. The patient underwent a percutaneous nephrostomy and ureteric stenting.

Conclusion: Spontaneous rupture of the ureter is an uncommon diagnosis for which clinical and laboratory signs may not always be reliably present. A high index of suspicion is required for diagnosis, which is usually confirmed on advanced imaging. It may occur in serious complications of urinoma and abscess formation. As such, accurate diagnosis and timely treatment is crucial. [Clin Pract Cases Emerg Med. 2021;5(2):167–170.]

Keywords: *Spontaneous ureteric rupture; urolithiasis.*

INTRODUCTION

Spontaneous ureteric rupture, or extravasation of the urine from the ureter in the absence of trauma or iatrogenic ureteric manipulation, is a rare condition. The literature, especially in emergency medicine, is fairly sparse. It may mimic many other causes of acute abdomen and itself requires prompt treatment. Thus, it is a diagnosis for which emergency physicians (EP) should have a high index of suspicion. We report a case of spontaneous ureteric rupture in the presence of a small, obstructing ureteric calculus. Informed consent was obtained from the patient for publication of this case report.

CASE REPORT

A 55-year-old female presented to the emergency department (ED) with acute onset right lower abdominal pain a few hours prior. The pain was non-radiating, constant, and gradually increasing in intensity. She reported one episode of gross hematuria at home with the onset of the pain but the

hematuria resolved subsequently. The patient had vomiting with the pain but did not have any other gastrointestinal symptoms. She did not have any fever or chills.

The patient had no past medical problems but a previous surgical history of a total hysterectomy and bilateral salpingo-oophorectomy performed four years prior and a laparoscopic procedure converted to open deroofing of a hepatic cyst three years prior. During a computed tomography (CT) of the abdomen and pelvis ordered by her hepatobiliary surgeon three years prior, a small, right kidney mid-pole stone was noted. However, as it was not causing any symptoms and was relatively small in size, it was conservatively managed.

On physical examination in the ED, she was afebrile and hemodynamically stable. Examination of the abdomen revealed tenderness over the right flank and iliac fossa with rebound tenderness but no guarding.

Initial blood investigations showed a total white cell count of 11×10^3 per microliter (μL) (reference range $4.5 - 11.0 \times 10^3/\mu\text{L}$)

with mild neutrophilia. Serum electrolyte and creatinine levels were within normal range. Urinalysis showed microscopic hematuria with no casts. Point-of-care ultrasound did not reveal any intraperitoneal free fluid or the presence of an abdominal aortic aneurysm, and no findings suggestive of cholecystitis.

The differential diagnosis in this patient was broad and included appendicitis, renal colic, diverticulitis, etc. However, the presence of rebound tenderness and persistent pain prompted the decision for the patient to undergo a CT of the abdomen and pelvis in the ED. Meanwhile, intravenous ceftriaxone was administered in view of the presence of peritonitis. The contrast-enhanced CT showed no evidence of acute appendicitis but found a 0.3-centimeter right upper ureteric calculus, with upstream hydronephrosis and ureteric rupture (Image 1–3).

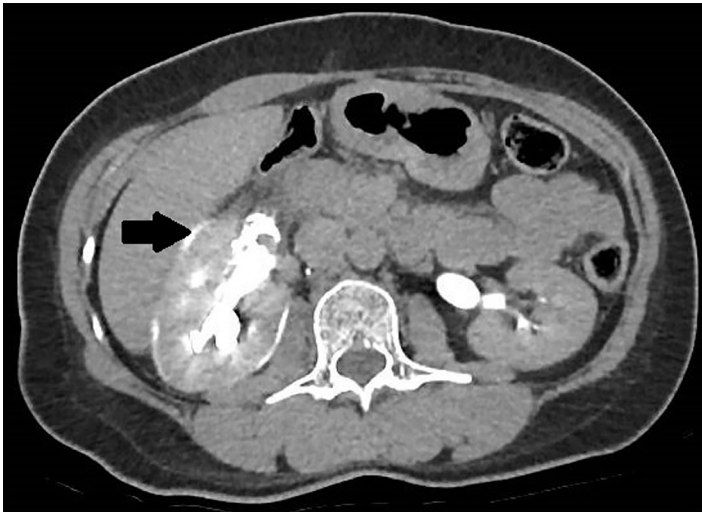

Image 1. Axial view of computed tomography with intravenous contrast administered showing perinephric leakage (arrow) of contrast showing evidence of ureteric rupture.

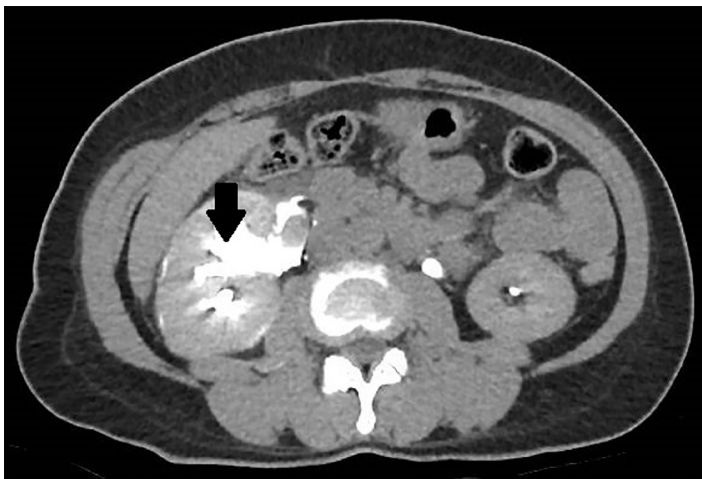


Image 2. Axial view of computed tomography with intravenous contrast administered showing hydronephrosis (arrow) of the right renal pelvis.

CPC-EM Capsule

What do we already know about this clinical entity?

Spontaneous ureteric rupture is a rare urological emergency that has only been described in case reports and series, mainly in surgical and urological literature.

What makes this presentation of disease reportable?

Neither symptoms nor simple radiological or lab tests are reliable for diagnosis. Only computed tomography (CT) done in view of peritonitis revealed the diagnosis.

What is the major learning point?

Ureteric rupture requires prompt treatment. Providers need to be aware of this condition and when a CT should be done to minimize diagnostic delay.

How might this improve emergency medicine practice?

By increasing awareness about this rare disease, emergency physicians may have a higher index of suspicion and be better able to diagnose and manage this emergency.

Given the imaging findings, the patient was admitted to the urology service. She underwent urgent right percutaneous nephrostomy on the day of admission. Three days later, antegrade ureteric stenting was performed with a confirmatory nephrostogram the following day. She was subsequently discharged with a follow-up CT of the kidneys, ureters, and bladder in three weeks and urology clinic follow-up after the scan.

DISCUSSION

Spontaneous ureteric rupture is a rare urological emergency, which to our knowledge, has only been described in case reports and case series. The most common cause is lithiasis; other possible etiologies include metastatic invasion of the ureter, urinary retention from neurogenic bladder, connective tissue diseases, retroperitoneal fibrosis,¹ pregnancy,² ureteral strictures from a variety of causes such as previous instrumentation or radiation, autoimmune, or neoplastic causes.³ The majority of the cases described are in the urological and surgical literature. The focus of these articles is often describing various treatment techniques

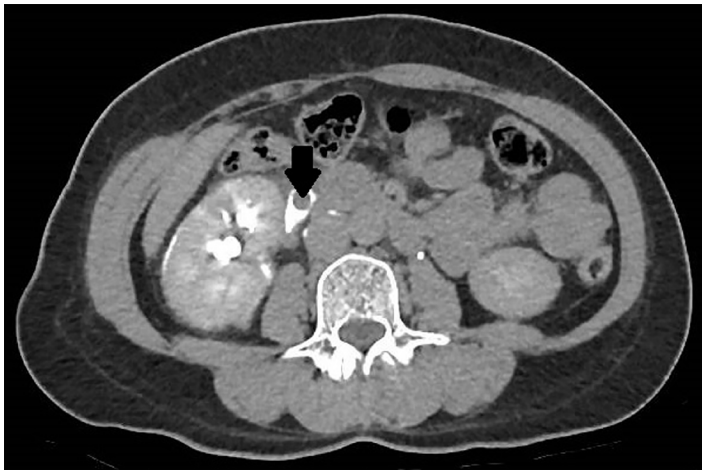


Image 3. Axial view of computed tomography with intravenous contrast administered, showing filling defect (arrow) in the right ureter suggestive of ureteric stone.

employed, as there are no definitive guidelines for treatment given its rarity.⁴

The clinical presentation of this condition is more relevant to the ED environment, but the existing literature provides little information on this topic. Sudden onset of abdominal or flank pain seems to be common.^{5,6} From case reports, urinary symptoms were not always present, costovertebral angle tenderness was present in some cases but not in others,^{7,8} and signs of peritonitis or fever were also not reliably present in all cases.⁹ In many of the cited cases, laboratory findings such as leukocytosis or elevated inflammatory markers ranged from normal to elevated, which makes these unreliable for diagnosis. Urinalysis also showed mixed results, and hematuria or pyuria was not reliably observed in all cases.

Point-of-care ultrasound detection of urolithiasis and hydronephrosis has limitations,¹⁰ especially in smaller stones.¹¹ Contrast-enhanced CT with normal portal venous and excretory phases confirms the diagnosis and potentially gives information on the level of injury, which would in turn assist in planning treatment.^{12,13} Knowing when to obtain a CT is critical to diagnosing ureteric rupture. Presence of peritonitis, persistent pain, or even recurrence and worsening pain¹³ were among the most commonly cited reasons a CT was ordered in the cited cases. Serial abdominal examinations and regular re-examinations of patients in the ED are hence vital in detecting the aforementioned signs, which would subsequently prompt further investigation and imaging. As urolithiasis is the most common cause of ureteric rupture, it is important that patients observed in the ED for ureteric colic are regularly reviewed. Sudden worsening of pain, unabating pain, or peritonitis in such patients should prompt the EP to re-evaluate the diagnosis of ureteric colic only.

Complications that may arise from this condition, which EPs should be cognizant of, include formation of urinomas, or perinephric or retroperitoneal abscesses. Urosepsis and its

attendant risks is also possible following ureteric or perinephric rupture. Thus, prompt treatment and admission of this diagnosis, once made, is necessary.

CONCLUSION

Spontaneous ureteric rupture is an uncommon urological emergency. Not only are signs and symptoms varied and at times non-specific, laboratory and plain radiographic studies also provide little definitive evidence for diagnosis. Diagnosis is usually only made if emergency physicians order advanced imaging. To avoid potential complications, EPs need to be aware and have a high index of suspicion of this condition to make an accurate and timely diagnosis of ureteric rupture.

The authors attest that their institution requires neither Institutional Review Board approval, nor patient consent for publication of this case report. Documentation on file.

Address for Correspondence: Chua Wei Lin Tallie, MBBS, MMed, Singapore General Hospital, Department of Emergency Medicine, Outram Road, Singapore 169608. Email: tallie.chua.w.l@singhealth.com.sg.

Conflicts of Interest: By the CPC-EM article submission agreement, all authors are required to disclose all affiliations, funding sources and financial or management relationships that could be perceived as potential sources of bias. The authors disclosed none.

Copyright: © 2021 Chua et al. This is an open access article distributed in accordance with the terms of the Creative Commons Attribution (CC BY 4.0) License. See: <http://creativecommons.org/licenses/by/4.0/>

REFERENCES

1. Eken A, Akbas T, Arpacı T. Spontaneous rupture of the ureter. *Singapore Med J.* 2015;56(2):e29-31.
2. Nathan S, Kerwin R, Lorge F, et al. An uncommon cause of acute abdominal pain: spontaneous ureteral rupture. *Clin Surg.* 2019;4:2369.
3. Stravodimos K, Adamakis I, Koutalellis G, et al. Spontaneous perforation of the ureter: clinical presentation and endourologic management. *J Endourol.* 2008;22(3):479-84.
4. Low LS and Nair SM. Spontaneous distal ureteric rupture: a rare case report and review of literature. *Asian J Urol.* 2020;7(1):61-3.
5. Chen G-H, Hsiao P-J, Chang Y-H, et al. Spontaneous ureteral rupture and review of the literature. *Am J Emerg Med.* 2014;32(7):772-4.
6. Paajanen H, Kettunen J, Tainio H, et al. Spontaneous peripelvic extravasation of urine as a cause of acute abdomen. *Scand J Urol Nephrol.* 1993;27(3):333-6.
7. Akpınar H, Kural AR, Tüfek I, et al. Spontaneous ureteral rupture: Is

- immediate surgical intervention always necessary? Presentation of four cases and review of the literature. *J Endourol.* 2002;16(3):179-83.
8. Liu S-Y, Lin J-N, Huang C-Y, et al. Spontaneous rupture of the ureter mimicking acute appendicitis: two case reports. *J Acute Med.* 2011;1(2):61-3.
 9. Pace K, Spiteri K, German K. Spontaneous proximal ureteric rupture secondary to ureterolithiasis. *J Surg Case Rep.* 2017;2016(11):rjw192.
 10. Moak JH, Lyons MS, Lindsell CJ. Bedside renal ultrasound in the evaluation of suspected ureterolithiasis. *Am J Emerg Med.* 2012;30(1):218-21.
 11. Riddell J, Case A, Wopat R, et al. Sensitivity of emergency bedside ultrasound to detect hydronephrosis in patients with computed tomography-proven stones. *West J Emerg Med.* 2014;15(1):96-100.
 12. Ratkowski KL, Lin M, Bhalla S. Spontaneous ureteral injury. *Appl Radiol.* 2018;47(7):38-9.
 13. Pampana E, Altobelli S, Morini M, et al. Spontaneous ureteral rupture diagnosis and treatment. *Case Rep Radiol.* 2013;2013:851859.

Acute Demyelinating Encephalomyelitis Following Measles Infection Due to Vaccine Failure: A Case Report

Robert J. McMickle, MD
Lauren Fryling, MD
Ross J. Fleischman, MD, MCR

Harbor-UCLA Medical Center, Department of Emergency Medicine, Torrance, California

Section Editor: Rick A. McPheeters, DO

Submission history: Submitted November 18, 2020; Revision received January 28, 2021; Accepted February 9, 2021

Electronically published March 24, 2021

Full text available through open access at http://escholarship.org/uc/uciem_cpccem

DOI: 10.5811/cpcem.2021.2.49481

Introduction: Local outbreaks of measles infection are primarily mediated by international travel of persons from endemic areas, with subsequent spread of the virus via undervaccinated populations. Recent resurgences of measles in communities where vaccination rates are non-ideal secondary to philosophical objections require the emergency physician to more routinely consider the diagnosis. In cases of measles complicated by acute encephalitis or encephalopathy, the diagnosis can be especially difficult to make due to lack of a reliable primary historian.

Case report: Here we present a case of altered mental status and new-onset bilateral lower extremity weakness in a fully vaccinated young woman diagnosed with measles infection caused by acute disseminated encephalomyelitis in the setting of vaccine failure.

Conclusion: Despite a documented history of immunization, acute measles infection and its uncommon sequelae are possible. Recognizing vaccine failure and appropriately isolating patients are of paramount importance. [Clin Pract Cases Emerg Med. 2021;5(2):171–173.]

Keywords: *Measles; acute demyelinating encephalomyelitis; vaccine failure; case report.*

INTRODUCTION

Measles, or rubeola, is a highly contagious viral illness spread via larger respiratory droplets (ie, cough, sneeze) as well as smaller airborne transmission (ie, breathing, speaking).¹ Patients typically develop symptoms after an incubation period of 10-12 days after initial exposure (range 7-21 days).¹ Patients will first develop fever followed by the classic triad of cough, coryza, and conjunctivitis a few days before a rash appears.¹ The prototypical rash starts on the face and spreads to the extremities, eventually forming a confluence. Patients are considered contagious for 1-2 days prior to symptom onset and for four days after the initial appearance of the rash.^{1,2} Rash is common, although immunocompromised patients including those with leukemias, lymphomas, or human immunodeficiency virus may never develop a rash.¹

The current standard two-dose vaccination schedule was established in response to primary vaccine failure, and in total provides up to 97-99% protection against measles throughout life, although the incidence of disease is heavily impacted by the

effectiveness of herd immunity. Primary vaccine failure is a relatively rare event, occurring in roughly 1% of patients due to failure of a patient to generate antibodies from antigenic stimuli.⁴

Complications from measles infection are common, occurring in upwards of 40% of all measles infection.⁵ Serious neurologic complications occur in roughly 1 in 1000 patients presenting with measles, including isolated measles encephalitis or meningitis, and acute demyelinating encephalomyelitis (ADEM), which typically presents as acute multifocal neurologic symptoms associated with encephalopathy, paraparesis or quadriparesis, sensory deficits, oculomotor deficits, and/or dysarthria.⁶ Severe cases can present as coma, seizure, or obtundation and carry a high rate of morbidity and mortality of 10-20%.^{2,3}

CASE REPORT

A 25-year-old otherwise healthy, fully-vaccinated young woman working as a nursing assistant in an urgent care clinic presented to the emergency department (ED) via ambulance

for worsening mental status over the day preceding presentation. The patient had one week of a viral prodrome including rhinorrhea, congestion, cough, malaise, and facial rash. Her symptoms progressed until the morning of admission, when the patient's partner noticed her to be more confused with repetitive speech, disorientation, and unresponsiveness. The partner also noticed decreased movement in her lower extremities and an inability to ambulate beginning earlier in the day of admission.

It was revealed that the patient had a known exposure to a measles-positive patient (an international traveler from an endemic region) whom she encountered in the clinic where she was employed. Within one week of exposure to the patient, she developed fever and rash beginning on her face, and spreading down her neck to her chest and arms. Serological titers were drawn one week prior to presentation by local department of public health officials and she was found to have low immunoglobulin G (IgG) titers. Booster vaccination was deferred at the time due to the patient having active fever.

On arrival to the ED, our patient was immediately placed in an airborne isolation room. She was tachycardic to 120 beats per minute with a low-grade fever to 38°C. She was alert but oriented only to her name, and was speaking nonsensically. On exam she was observed to have a maculopapular rash on her face extending to her neck and chest. She was unable to cooperate with a complete neurologic exam to assess for motor function, but withdrew only weakly to painful stimuli in the bilateral lower extremities. Deep tendon reflexes were normal. She was given a two-liter bolus of normal saline, and was empirically started on meningitic dosing of vancomycin and ceftriaxone. With no preceding oral lesions or history of herpes simplex infection, addition of acyclovir was deferred.

Initial white blood cell count was 13.4 K/cubic millimeters (mm³) (normal range 4.5– 10.0 K/mm³), with 79% (44% - 71%) neutrophils; hemoglobin 13.6 grams per deciliter (g/dL) (12 - 14.6 g/dL); platelet count 256 K/ mm³ (160 – 360 K/ mm³); sodium 136 millimoles per liter (mmol/L) (136 – 144 mmol/L); potassium 4.3 mmol/L (3.6– 5.1 mmol/L); bicarbonate 20 mmol/L (22 – 32 mmol/L); blood urea nitrogen 37 milligrams (mg/dL) (8– 20 mg/dL); creatinine 2.0 mg/dL (0.44– 1.03 mg/dL); glucose 148 mg/dL (41– 118 mg/dL); aspartate transaminase 65 units per liter (U/L) (15– 41 U/L); alanine transaminase 47 U/L (7– 35 U/L); and bilirubin 1.0 mg/dL (0.3 – 1.2 mg/dL).

A lumbar puncture was performed in the ED, with clear cerebrospinal fluid (CSF) and an opening pressure of 16 centimeters (cm) water (H₂O) (normal range 7 – 18 cm H₂O); nucleated cell count 134/ mm³ (0 – 5/ mm³), with 67% segmented neutrophils (0 - 6%); 23% lymphocytes (40 - 80%); 8% monocytes/histiocytes (no reference range available); and 2% plasma cells (no reference range available). Her CSF glucose was 71 mg/dL (40– 75 mg/dL), and CSF protein was 70mg/dL (15– 45 mg/dL). A CSF Gram stain and

CPC-EM Capsule

What do we already know about this clinical entity?

Measles vaccine failure is an uncommon yet possible occurrence, and acute measles infection in older individuals may present as an undifferentiated encephalitis.

What makes this presentation of disease reportable?

Rare and severe manifestations of measles including neurologic complications such as acute demyelinating encephalomyelitis are possible despite vaccination.

What is the major learning point?

Emergency providers cannot exclude measles in vaccinated individuals presenting with a prototypical viral exanthem or neurologic sequelae of disease.

How might this improve emergency medicine practice?

Early isolation and consideration of the diagnosis of measles can curb spread in communities experiencing outbreaks due to philosophical objections to vaccination.

CSF viral polymerase chain reaction (PCR) panel (not including measles virus) were negative.

The patient was admitted to the internal medicine service with infectious disease consultation. Measles IgM and IgG were both elevated in sputum and plasma. She was treated with intramuscular vitamin A 200,000 international units for two days and continued on meningitis dosing of antibiotics until CSF cultures proved negative. Her mental status improved over the subsequent two days with a return to baseline, but she continued to have bilateral lower extremity weakness and new acute urinary retention. She was diagnosed with ADEM after magnetic resonance imaging (MRI) and nerve conduction studies were consistent with the diagnosis. She was started on high-dose methylprednisolone (30mg/kilogram) for five days with gradual improvement in symptoms. The patient was discharged on hospital day five with significantly improved neurologic function, although still not independently ambulatory and requiring an indwelling urinary catheter.

DISCUSSION

Since its initial eradication in the United States in 2000, measles has had multiple resurgent outbreaks occurring yearly

since 2010.⁷ A record-high 1282 cases confirmed in 31 states were observed throughout 2019, primarily via travel-related introductions of virus and spread through undervaccinated subpopulations in urban areas or healthcare settings.^{7,8} In light of this resurgence, even persons with documented vaccination history may be at risk of acquiring infection and may present with severe features.

A febrile exanthem and a CSF pleocytosis in encephalopathic patients can suggest a viral cause, and suspicion should be raised in patients with known exposures or who live or work in high-risk environments (ie, healthcare). Emergency providers will often presume a diagnosis of measles based on clinical criteria in the absence of viral studies. Measles-specific IgM antibody and measles ribonucleic acid by real-time PCR in respiratory specimens and a serum sample and throat swab should be obtained at first contact if suspicion is high.⁹

The mainstay of treatment for measles infection remains supportive. In this case vitamin A, which is known to decrease morbidity and mortality in children with measles by replenishing stores of vitamin A lost via destruction of epithelial surfaces by the virus,¹⁰ was administered, and the patient's mental status recovery was sufficient enough to not warrant additional therapy with ribavirin or intravenous immunoglobulin. Administration of the measles-mumps-rubella vaccine within 72 hours of exposure or immunoglobulin within six days of exposure can be given in the ED as well. Patients should be placed as soon as possible in a single-patient airborne isolation room to prevent spread to the healthcare team or other patients. They should remain isolated for four days after they develop a rash.

Acute demyelinating encephalomyelitis is considered a diagnosis of exclusion. Magnetic resonance imaging of spinal series and brain with gadolinium should be obtained if suspicion for ADEM is high and may demonstrate patchy hyperintense lesions and edema throughout the brain and spinal cord. In this case, an MRI demonstrated leptomeningeal enhancement in the thoracic spine. High-dose solumedrol (30mg/kg) was administered for five days with subsequent improvement of patient's bilateral lower extremity weakness. Intravenous immunoglobulin and plasma exchange may also be employed in non-improving patients,⁶ although typically these are not initiated in the ED without infectious disease consultation.

CONCLUSION

Even in patients with a documented history of immunization, acute measles infection and its uncommon sequelae are possible. The emergency provider may be tempted to use history of vaccination as a screening tool to exclude such illnesses in their differential diagnosis; however, it is important for initial providers to be aware that vaccine failure, although uncommon, is possible and should be considered in the multiple vaccine-preventable illnesses including varicella, influenza, and *Haemophilus influenzae*. In addition to making an accurate diagnosis to initiate appropriate therapy, the initial

evaluation by emergency providers must also include appropriately isolating suspect patients to prevent spread to the healthcare team or other patients.

The authors attest that their institution requires neither Institutional Review Board approval, nor patient consent for publication of this case report. Documentation on file.

Address for Correspondence: Robert J. McMickle, MD, Harbor-UCLA Medical Center, Department of Emergency Medicine, 1000 W. Carson St, Hospital Bldg: D9, Box 21, Torrance, CA 90509. Email: robertmcmickle2@gmail.com.

Conflicts of Interest: By the CPC-EM article submission agreement, all authors are required to disclose all affiliations, funding sources and financial or management relationships that could be perceived as potential sources of bias. The authors disclosed none.

Copyright: © 2021 McMickle et al. This is an open access article distributed in accordance with the terms of the Creative Commons Attribution (CC BY 4.0) License. See: <http://creativecommons.org/licenses/by/4.0/>

REFERENCES

- McLean HQ, Fiebelkorn AP, Temte JL, et al. Prevention of measles, rubella, congenital rubella syndrome, and mumps, 2013: summary recommendations of the Advisory Committee on Immunization Practices (ACIP). *MMWR Recomm Rep.* 2013;62(RR-04):1-34. Erratum in: *MMWR Recomm Rep.* 2015;64(9):259.
- O'donnell S, Davies F, Vardhan M, et al. Could this be measles? *Emerg Med J.* 2019;36(5):310-4.
- Ives graber EM, Andrade FJ, Bost W, et al. An Update and review of measles for emergency physicians. *J Emerg Med.* 2020;58(4):610-5.
- Moss WJ and Pollack FP. Immune responses to measles and measles vaccine: challenges for measles control. *Viral Immunol.* 2001;14:297-309.
- Weida JA. (2019). Measles (rubeola). In: Kellerman RD, and Rakel D (Eds.), *Conn's Current Therapy* (p. 580-582). Philadelphia, PA: Elsevier.
- Pohl D, Alper G, Van Haren K, et al. Acute disseminated encephalomyelitis: updates on an inflammatory CNS syndrome. *Neurology.* 2016;87(9 Suppl 2):S38-45.
- Centers for Disease Control and Prevention. Healthcare Professionals: Clinical Resources. 2020. Available at: <https://www.cdc.gov/measles/hcp/index.html>. Accessed November 24, 2020.
- Paules CI, Marston HD, Fauci AS. Measles in 2019 - going backward. *N Engl J Med.* 2019;380(23):2185-7.
- Centers for Disease Control and Prevention. Healthcare Professionals: Clinical Resources. 2020. Available at: <https://www.cdc.gov/measles/hcp/index.html>. Accessed November 24, 2020.
- Rumore MM. Vitamin A as an immunomodulating agent. *Clin Pharm.* 1993;12(7):506-14.

Arterial-embolic Strokes and Painless Vision Loss Due to Phase II Aortitis and Giant Cell Arteritis: A Case Report

Kaitlin Endres, BSc*

Omar Anjum, BSc, MD*†

Nicholas Costain, MD, FRCPC*†

*University of Ottawa, Department of Medicine, Ottawa, Ontario, Canada

†The Ottawa Hospital, Department of Emergency Medicine, Ottawa, Ontario, Canada

Section Editor: Scott Goldstein, MD

Submission history: Submitted December 11, 2020; Revision received February 3, 2021; Accepted February 9, 2021

Electronically published April 19, 2021

Full text available through open access at http://escholarship.org/uc/uciem_cpchem

DOI: 10.5811/cpchem.2021.2.51143

Introduction: Aortitis refers to abnormal inflammation of the aorta, most commonly caused by giant cell arteritis (GCA). Herein, we present a 57-year-old female with aortitis and arterial-embolic strokes secondary to GCA.

Case Report: Our patient presented to the emergency department following an episode of transient, monocular, painless vision loss. Computed tomography angiogram head and neck demonstrated phase II aortitis, and magnetic resonance imaging revealed evidence of arterial-embolic strokes.

Conclusion: Cerebrovascular accident is a rare complication of large-vessel vasculitis and can occur due to multiple underlying etiologies including intracranial vasculitis, aortic branch proximal occlusion, or arterial-embolic stroke. [Clin Pract Cases Emerg Med. 2021;5(2):174–177.]

Keywords: *aortitis; giant cell arteritis; arterial-embolic stroke; painless vision loss.*

INTRODUCTION

Aortitis refers to abnormal inflammation of the aorta with the most common causes being non-infectious, such as giant cell arteritis (GCA) and Takayasu arteritis.¹ While aortitis is rare, it can also be potentially fatal.² Here we report a case of aortitis secondary to GCA, causing multiple arterial-embolic strokes in a patient presenting with painless, transient, monocular vision loss. This case is novel as our patient presented with signs of GCA as well as neurological symptoms which did not coincide with a single vascular territory. To our knowledge, this is the first case report of a patient presenting to the emergency department (ED) with evidence of arterial-embolic strokes secondary to aortitis induced by GCA.

CASE REPORT

A 57-year-old female with a past medical history of hypothyroidism presented to the ED following an episode of sudden left-sided, painless, vision loss that resolved within 30 minutes. This episode occurred in the context of a five-month history of fatigue, 15-kilogram weight loss,

periodic night sweats, and generalized subjective weakness, along with a two-month history of intermittent headaches and jaw claudication. For the prior month, she also endorsed transient neurologic deficits, predominantly weakness of the left arm and right leg. At the time of assessment, she complained of persistent left-sided hand clumsiness.

On examination, the patient's vitals were stable. She had a normal cardiopulmonary exam. Her neurologic exam included normal cranial nerves, a normal gait and cerebellar exam, as well as normal gross sensation. Her motor exam was unremarkable except for weak elbow extension (3/5) and shoulder abduction (4/5) of the left arm. She had normal visual acuity, normal pupil size and reactivity, and intact extraocular movements. Her slit lamp exam revealed normal lids, lashes, lacrimal system, conjunctivae, cornea, and anterior chamber. Her fundoscopy was normal. Laboratory data revealed the following: leukocytosis; anemia; thrombocytosis; and elevated inflammatory markers (erythrocyte sedimentation rate [ESR]: 122 millimeters per hour (mm/hr) [normal in females 0-20 mm/hr], and C-reactive protein [CRP]: 119.4

milligrams per liter (mg/L) [normal: ≤ 10 mg/L), overall suspicious for an underlying reactive process. Due to concern for concomitant cerebrovascular accident (CVA), a computed tomography (CT) head and CT angiogram (CTA) head and neck were performed. While initial imaging did not reveal an acute stroke, CTA showed prominent circumferential wall thickening of the descending aorta, aortic arch and great vessels of the neck and chest (including the left common carotid artery and left subclavian artery). Her CTA revealed no evidence of luminal narrowing or aneurysm formation.

The patient's clinical picture was most consistent with large vessel vasculitis, likely GCA with ophthalmologic and possible central nervous system (CNS) involvement. In consultation with rheumatology, she was started on high-dose pulse glucocorticosteroids with methylprednisolone 500 mg intravenous daily for three days followed by prednisone 60 mg daily with a slow taper. A complete CT chest/abdomen/pelvis was performed that revealed diffuse aortic wall thickening (Image). Neurology was consulted, and a magnetic resonance imaging (MRI) was recommended which revealed subacute cortical infarcts in the right frontal lobe, left parietal lobe, and remote lacunar infarcts. Based on expert opinions from stroke neurology and neuroradiology, these strokes were felt to be arterial-embolic in nature, secondary to aortitis.

The treatment for arterial embolic stroke secondary to aortitis is management of the underlying vasculitis (ie, steroids). Anti-platelet therapy is usually included as well.

CPC-EM Capsule

What do we already know about this clinical entity?

Aortitis, or aorta inflammation, is most commonly caused by giant cell arteritis (GCA). Stroke is a rare but devastating complication of GCA.

What makes this presentation of disease reportable?

This is a unique case of a patient presenting to the emergency department (ED) with evidence of arterial-embolic strokes secondary to aortitis induced by GCA.

What is the major learning point?

Evidence of aortitis on computed tomography (CT) angiogram head/neck for routine stroke workup should prompt a CT aortogram to rule out phase III aortitis findings.

How might this improve emergency medicine practice?

Recognition of aortitis by emergency physicians helps ensure early consultation to specialists for management, helping prevent progression and sequelae.

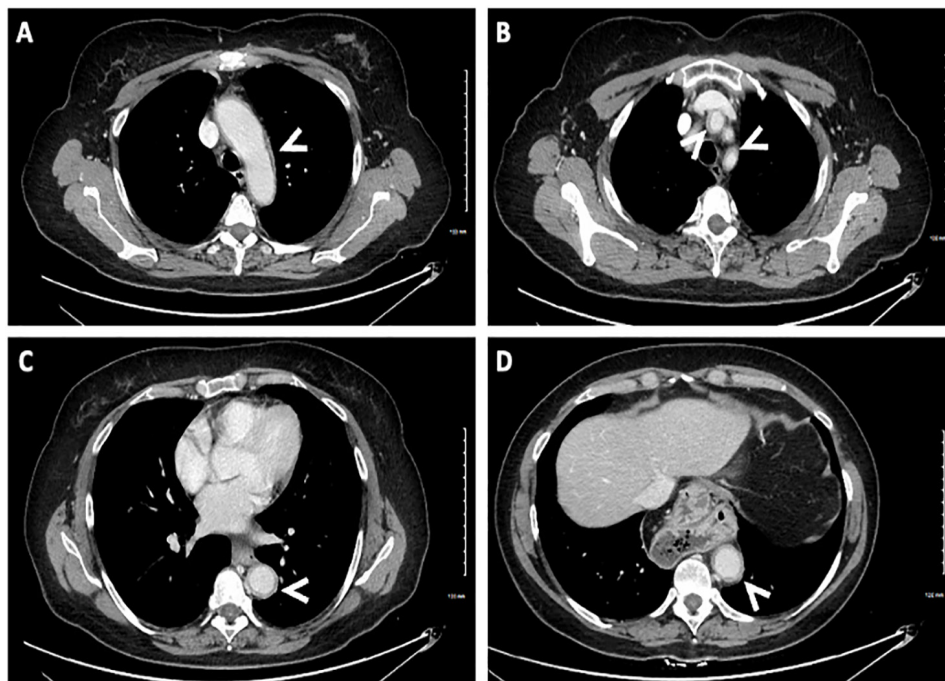


Image. Axial views of computed tomography chest and abdomen demonstrating prominent wall thickening of the aorta (white arrows). (A) aortic arch, (B) left common carotid artery and left subclavian artery, and (C and D) descending aorta which all demonstrate diffuse and circumferential wall thickening without luminal narrowing, suggestive of phase II aortitis.

The role of tissue plasminogen activator and endovascular treatment is based on consultation with stroke neurology and determination of size, location, and timing of the strokes. Ophthalmology performed a temporal artery biopsy, which ultimately revealed a diagnosis of GCA in this patient. She was discharged after five days in stable condition with no new symptoms, and with outpatient rheumatology follow-up.

DISCUSSION

Aortitis is commonly classified into three phases. Phase I presents with non-specific signs of systemic inflammation including fever, arthralgias, and elevated acute phase reactants.³ Phase II involves vascular inflammation causing arterial pain and/or tenderness, and phase III involves permanent arterial wall injury from ischemia secondary to occlusion of proximal and distal aortal branches.³ Our patient had no intraluminal narrowing on CTA to suggest phase III aortitis; however, imaging did show diffuse and circumferential aortic wall inflammation consistent with phase II aortitis. While any evidence of aortitis should alert emergency physicians to consult specialists for management options, it is optimal to diagnose aortitis in the earliest phase possible to prevent future sequelae from subsequent phases. An additional take-home message for emergency physicians is that if there is evidence of aortitis on CTA head and neck for routine stroke workup, it is worth performing a CT aortogram to ensure no abnormal phase III findings such as intraluminal narrowing, dilation and acute aortic syndromes.

Vision loss in the setting of GCA is usually secondary to arteritic anterior ischemic optic neuropathy and, less commonly, central retinal artery occlusion. Regardless of the pathophysiology, abrupt onset of visual disturbance in suspected GCA, especially transient monocular vision loss, indicates optic nerve ischemia. Immediate management with pulse glucocorticosteroids and urgent ophthalmology consult to arrange for temporal artery biopsy are required.

The condition of GCA is classified as a vasculitis of medium- and large-sized vessels with evidence of aortitis in approximately 15% of cases.⁴ Although one of the most common causes of aortitis, GCA is rare, affecting only 18.9 out of 100,000 Americans over the age of 50 each year.⁵ Interestingly, our patient presented with virtually all classic GCA findings. Most diagnostic algorithms suggest temporal artery biopsy with high suspicion for GCA and one of the following symptoms: new headache (72% prevalence); transient monocular visual loss (32%); jaw claudication (40%); constitutional signs and symptoms (25%); or elevated ESR and/or CRP (90%)⁶.

A CVA is a rare but devastating complication of GCA, occurring in only 3-4% of GCA patients.⁷ Weakness in the setting of GCA may be due to many causes including CVA or extracranial vessel involvement.⁸ Here we highlight the

potential causes for our patient's weakness: 1) CVA in the setting of GCA is most commonly caused by stenosis of the carotid and/or vertebral arteries or alternatively; 2) intracranial vasculitis as a CNS manifestation of the systemic disease (however, neither of these explanations were supported by her imaging);⁹ 3) In the setting of phase III aortitis, GCA can cause upper and lower extremity claudication secondary to arterial occlusive disease involving aortic branch vessels and larger peripheral arteries (however, there was no evidence of pain with the patient's extremity weakness); and 4) a rare cause of CVA in the setting of GCA is inflammation-induced aortic thrombus formation, resulting in release of emboli that cause distal occlusion. This was thought to be the most likely pathophysiology for our patient's weakness based on expert opinions from stroke neurology and neuroradiology given the MRI findings of multiple subacute cortical and lacunar infarcts.

CONCLUSION

This case presentation highlights several important learning points on aortitis in the setting of GCA for emergency physicians. There are three distinct phases of aortitis which can be distinguished based on differences in signs and symptoms and imaging findings. Vision loss in the setting of suspected GCA necessitates pulse glucocorticosteroids before arranging for temporal artery biopsy in order to prevent progression to bilateral or permanent vision loss. A CVA in the setting of large-vessel vasculitis can be due to multiple causes including intracranial vasculopathy or vasculitis, proximal occlusion of aortic branches (phase III aortitis) or, more rarely, arterial-embolic stroke.

The authors attest that their institution requires neither Institutional Review Board approval, nor patient consent for publication of this case report. Documentation on file.

Address for Correspondence: Omar Anjum, BSc, MD, University of Ottawa, Department of Medicine, 1053 Carling Avenue, K1Y 1J8, Ottawa, Ontario, K1Y 4E9. Email: oanjum@toh.ca.

Conflicts of Interest: By the CPC-EM article submission agreement, all authors are required to disclose all affiliations, funding sources and financial or management relationships that could be perceived as potential sources of bias. The authors disclosed none.

Copyright: © 2021 Endres et al. This is an open access article distributed in accordance with the terms of the Creative Commons Attribution (CC BY 4.0) License. See: <http://creativecommons.org/licenses/by/4.0/>

REFERENCES

1. Gornik HL and Creager MA. Aortitis. *Circulation*. 2008;117(23):3039-51.
2. Ostberg G. Temporal arteritis in a large necropsy series. *Ann Rheum Dis*. 1971;30(3):224-35.
3. Restrepo CS, Ocazonez D, Suri R, et al. Aortitis: imaging spectrum of the infectious and inflammatory conditions of the aorta. *Radiographics*. 2011;31(2):435-51
4. Bossert M, Prati C, Balblanc JC, et al. Aortic involvement in giant cell arteritis: current data. *Joint Bone Spine*. 2011;78(3):246-51.
5. Babigumira JB, Li M, Boudreau DM, et al. Estimating the cost of illness of giant cell arteritis in the United States. *Rheumatol Ther*. 2017;4(1):111-9.
6. Zhang Y, Wang D, Yin Y, et al. Clinical comparisons of patients with giant cell arteritis with versus without fever at onset. *J Int Med Res*. 2019;47(11):5613-5622.
7. Cox BC, Fulgham JR, Klaas JP. Recurrent stroke in giant cell arteritis despite immunotherapy. *Neurologist*. 2019;24(4):139-41.
8. de Boysson H, Liozon E, Larivière D, et al. Giant cell arteritis-related stroke: a retrospective multicenter case-control study. *J Rheumatol*. 2017;44(3):297-303.
9. Solans-Laqué R, Bosch-Gil JA, Molina-Catenario CA, et al. Stroke and multi-infarct dementia as presenting symptoms of giant cell arteritis: report of 7 cases and review of the literature. *Medicine (Baltimore)*. 2008;87(6):335-44.

Pneumopericardium after Laparoscopic Hernia Repair Presents with ST-segment Changes: A Case Report

Demi Galindo, MS*
Emily Martin, MD†
Douglas Franzen, MD, MEd†

*University of Washington School of Medicine, Seattle, Washington
†University of Washington, Department of Emergency Medicine, Seattle, Washington

Section Editor: R. Gentry Wilkerson, MD

Submission history: Submitted December 4, 2020; Revision received February 9, 2021; Accepted February 16, 2021

Electronically published March 24, 2021

Full text available through open access at http://escholarship.org/uc/uciem_cpccem

DOI: 10.5811/cpccem.2021.2.51069

Introduction: Although rare, iatrogenic cases of pneumopericardium have been documented following laparoscopic surgery and mechanical ventilation. Electrocardiogram (ECG) changes, including ST-segment depressions and T-wave inversions, have been documented in cases of pneumopericardium, and can mimic more concerning causes of chest pain including myocardial ischemia or pulmonary embolism.

Case Report: This unique case describes a patient who presented with chest pain and ST-segment changes on ECG hours after a laparoscopic inguinal hernia repair and who was found to have pneumopericardium.

Conclusion: While iatrogenic pneumopericardium is often self-limiting and rarely requires intervention, it is critical to differentiate pneumopericardium from other etiologies of chest pain, including myocardial ischemia and pulmonary embolism, to prevent unnecessary intervention. [Clin Pract Cases Emerg Med. 2021;5(2):178–181.]

Keywords: *case report; pneumopericardium; Hamman's sign.*

INTRODUCTION

Pneumopericardium is a rare occurrence and typically results from blunt injury, barotrauma, infection, or abnormal communication between mediastinal structures.¹ Rare cases have been observed with mechanical ventilation in difficult to ventilate patients, after using high peak airway and positive end expiratory pressures.² While rare, pneumopericardium has been documented after laparoscopy and is thought to occur as gas dissects from the peritoneum into the mediastinum and pericardium via the diaphragmatic hiatus.^{3,4,5} Electrocardiogram (ECG) changes including ST-segment depressions have been described in cases of pneumopericardium.⁶ This case describes a patient who presented with pneumopericardium and ST-segment changes on ECG several hours after a laparoscopic inguinal hernia repair, which to our knowledge has only been described once before in the literature.⁴

CASE REPORT

A 26-year-old woman presented to the emergency department (ED) with chest pain radiating to the left shoulder, following a laparoscopic inguinal hernia repair performed several hours prior to presentation. The patient reported the pain started shortly following the procedure and worsened despite taking acetaminophen and oxycodone, prompting her presentation. She endorsed associated shortness of breath and mild nausea. Her review of systems was negative for associated fevers, chills, cough, abdominal pain, vomiting, or leg swelling. The patient's medical and surgical history was notable only for appendectomy five years prior to presentation. The patient reported an intrauterine contraceptive device, but no other medications. She reported no allergies. She reported no family history of bleeding or clotting disorders. She reported occasional alcohol and marijuana use.

On arrival to the ED the patient was in no acute distress, with initial vital signs notable for heart rate of 114 beats per minute, blood pressure of 110/66 millimeters of mercury, respiratory rate of 20 breaths per minute, oxygen saturation of 100%, and temperature of 36.5 degrees Celsius. An ECG performed in triage demonstrated sinus tachycardia with T-wave inversions in the inferior leads (II, III) and ST-segment depressions in the anterior leads (V3-V5) (Image 1).

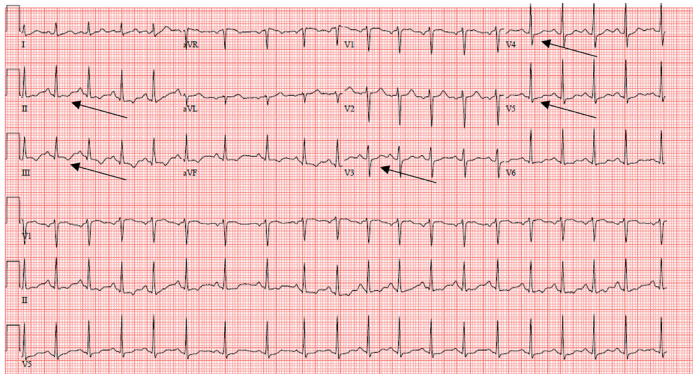


Image 1. Electrocardiogram demonstrating sinus tachycardia at 115 beats per minute with T-wave inversions in leads II, III (black arrows) and ST-segment depressions in leads V3, V4, V5 (black arrows).

On exam, the patient was alert and oriented with moist mucous membranes. Her cardiovascular exam was notable for a regular tachycardia and a holosystolic crunching murmur heard best at the precordium. Palpation of the anterior chest wall revealed crepitus and reproduced her chest pain. Her lungs were clear to auscultation. She had no jugular venous distension or peripheral edema. She had no calf swelling or tenderness, and no discomfort with passive dorsiflexion of either foot. Her abdominal surgical incisions were clean and dry. The remainder of her physical exam was normal.

Initial workup in the ED included chest radiograph (CXR) and labs including complete blood count (CBC), basic metabolic panel (BMP), troponin, and D-dimer. The patient was given 324 milligrams of aspirin. Her laboratory results were notable for a white blood count of 12.97 thousand cells per cubic millimeter (10^3 cells/ mm^3) (reference range 4.5-11.0 $\times 10^3$ cells/ mm^3) with otherwise normal CBC and normal BMP. Her troponin was negative at less than 0.03 nanograms per milliliter (ng/mL) (0-0.3 ng/mL), and her D-dimer was negative at 0.38 micrograms per milliliter (mcg/mL) (0-0.5 mcg/mL). Her CXR demonstrated pneumoperitoneum, subcutaneous emphysema, and pneumopericardium (Image 2).

Given no evidence of pulmonary embolism, acute coronary syndrome, pneumothorax, pneumonia, or other findings to explain the patient's chest pain, the subcutaneous emphysema and pneumopericardium were presumed to be

CPC-EM Capsule

What do we already know about this clinical entity?

Iatrogenic pneumopericardium has been reported after abdominal laparoscopic surgery, presumed secondary to passage of insufflated gas into the mediastinum via the diaphragmatic hiatus.

What makes this presentation of disease reportable?

This case describes a patient who presented with pneumopericardium and ST-segment changes hours after laparoscopic hernia repair, which has only been described once before.

What is the major learning point?

Although typically benign, pneumopericardium can present with chest pain and electrocardiogram changes mimicking more concerning entities like acute coronary syndrome or pulmonary embolism.

How might this improve emergency medicine practice?

Emergency medicine clinicians should be familiar with the signs and symptoms of pneumopericardium, and should be able to distinguish pneumopericardium from alternative causes of chest pain.

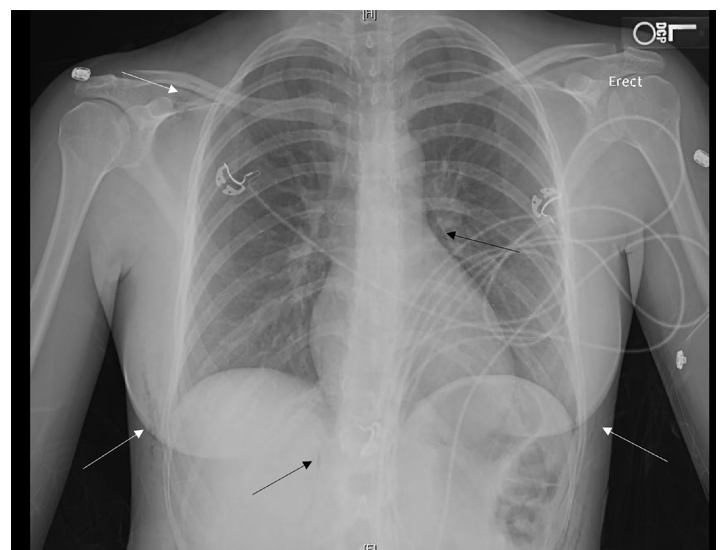


Image 2. Chest radiograph demonstrating pneumoperitoneum (lower black arrow), subcutaneous emphysema (white arrows), and pneumopericardium (upper black arrow).

the etiology of the patient's symptoms. Both laparoscopic insufflation and mechanical ventilation were considered as possible causes of her pneumopericardium. Review of the anesthesia records confirmed that the patient was ventilated with low positive end-expiratory pressures, making mechanical ventilation an unlikely culprit. The presence of subcutaneous emphysema suggested laparoscopic insufflation as the likely cause of the pneumopericardium. Insufflated gas was presumed to have traveled through the diaphragmatic hiatus into the pericardial space via the mediastinum. Following administration of aspirin, the patient's pain improved and her tachycardia resolved. She remained hemodynamically stable throughout her stay in the ED. She was discharged home with follow-up with general surgery and strict return precautions. Unfortunately, she did not follow up in clinic, but is presumed to have recovered without complication.

DISCUSSION

Pneumopericardium can have significant complications, including cardiovascular and respiratory collapse and cardiac tamponade.¹ However, iatrogenic pneumopericardium is typically self-limited, resolves spontaneously, and does not often necessitate intervention.^{2,7} The diagnosis of pneumopericardium is made by chest radiography. Pneumopericardium can be differentiated from pneumomediastinum on radiography by gas sharply demarcating the pericardial sac around the left ventricle and right atrium (Image 2). Additionally, demarcation of gas can be seen tracing the pulmonary artery and ascending aorta, which form the superior margin of the pericardium. Conversely, gas in pneumomediastinum typically traces the aortic arch and superior vena cava.¹

Nonspecific ECG changes such as T-wave inversions and ST-segment depressions can be seen in pneumopericardium.⁶ In previous cases of pneumopericardium with ECG changes, patients have been treated for myocardial ischemia or taken for cardiac catheterization unnecessarily.^{5,6} In our patient, we considered multiple other underlying etiologies, including pulmonary embolism, pneumothorax, or myocardial ischemia before determining that pneumopericardium was the likely etiology of her symptoms. Differentiating between the pneumopericardium and other etiologies of chest pain is critical to prevent unnecessary intervention.

Hamman's sign was first described by Louis Hamman in 1937 as a crunching, bubbling, clicking, or popping holosystolic murmur present on cardiac auscultation. It is postulated to be due to physical displacement of air-filled tissues with each heartbeat, and has been described as audible without the use of a stethoscope.⁸ Hamman first described the finding in a case of pneumomediastinum, and a review of literature suggests that Hamman's sign is found in roughly 30% of patients with spontaneous pneumomediastinum.^{9,10} Hamman suggested the finding to be pathognomonic for pneumomediastinum, but the murmur has also been described

in cases of left-sided pneumothorax.¹¹ Although the test characteristics of this clinical finding have not been described, Hamman's sign is likely highly specific for pneumomediastinum or pneumothorax, and if auscultated should prompt further investigation.

CONCLUSION

Pneumopericardium is a rare diagnosis, and can present with chest pain and ECG changes mimicking more concerning diagnoses such as pulmonary embolism or myocardial ischemia. Differentiating between pneumopericardium, which is often self-limiting and typically does not require intervention, and other more concerning etiologies of chest pain is therefore critical. A history of recent laparoscopic surgery or mechanical ventilation should alert the clinician to the possibility of iatrogenic pneumopericardium. Hamman's sign, a crunching holosystolic murmur due to displacement of air-filled tissue, is likely highly specific for pneumomediastinum and should prompt further investigation. Chest radiography is diagnostic, and will demonstrate gas demarcating the pericardial sac.

The authors attest that their institution requires neither Institutional Review Board approval, nor patient consent for publication of this case report. Documentation on file.

Address for Correspondence: Emily Martin, MD, University of Washington, Department of Emergency Medicine, 325 9th Avenue, Box 359702, Seattle, WA 98104. Email: martiem@uw.edu.

Conflicts of Interest: By the *CPC-EM* article submission agreement, all authors are required to disclose all affiliations, funding sources and financial or management relationships that could be perceived as potential sources of bias. The authors disclosed none.

Copyright: © 2021 Galindo et al. This is an open access article distributed in accordance with the terms of the Creative Commons Attribution ([CC BY 4.0](http://creativecommons.org/licenses/by/4.0/)) License. See: <http://creativecommons.org/licenses/by/4.0/>

REFERENCES

1. Brander L, Ramsay D, Dreier D, et al. Continuous left hemidiaphragm sign revisited: a case of spontaneous pneumopericardium and literature review. *Heart*. 2002;88(4):e5.
2. Bhakta P, McNamara JR, O'Brien B, et al. Isolated pneumopericardium caused by positive pressure ventilation: a rare complication. *J Clin Anesth*. 2018;49:5-6.
3. Nicholson RD and Berman ND. Pneumopericardium following laparoscopy. *Chest*. 1979;76(5):605-7.
4. Knos GB, Sung YF, Toledo A. Pneumopericardium associated with

- laparoscopy. *J Clin Anesth.* 1991;3(1):56-9.
5. Beaver J and Safran D. Pneumopericardium mimicking acute myocardial ischemia after laparoscopic cholecystectomy. *South Med J.* 1999;92(10):1002-4.
 6. El Haj Chehade A, Debal G, Mansour W, et al. Pneumopericardium, pneumomediastinum and air travel: a case report in a patient with Gardner syndrome. *Respir Med Case Rep.* 2020;31:101271.
 7. Mishra B, Joshi MK, Rattan A, et al Pneumopericardium. *Bull Emerg Trauma.* 2016;4(4):250-1.
 8. Thakeria P, Danda N, Gupta A, et al. Smartphone aiding in analysis of Hamman's sign. *BMJ Case Rep.* 2019;12(11):e231418.
 9. Hamman L. Spontaneous mediastinal emphysema. *Bull John Hopkins Hosp.* 1939;64:1-21.
 10. Takada K, Matsumoto S, Hiramatsu T, et al. Spontaneous pneumomediastinum: an algorithm for diagnosis and management. *Ther Adv Respir Dis.* 2009;3(6):301-7.
 11. Baumann MH and Sahn SA. Hamman's sign revisited. Pneumothorax or pneumomediastinum? *Chest.* 1992;102(4):1281-2.

A Report of Two Cases: Unlearning Lactic Acidosis

Sanjay Mohan, MD*
David S. Goldfarb, MD†
Robert S. Hoffman, MD*

*NYU Grossman School of Medicine, Ronald O. Perelman Department of Emergency Medicine, New York, New York
†NYU Grossman School of Medicine, Division of Nephrology, New York, New York

Section Editor: Scott Goldstein, MD

Submission history: Submitted January 12, 2021; Revision received February 24, 2021; Accepted February 22, 2021

Electronically published April 8, 2021

Full text available through open access at http://escholarship.org/uc/uciem_cpem

DOI: 10.5811/cpcem.2021.2.51634

Introduction: The term “lactic acidosis” reinforces the misconception that lactate contributes to acidemia. Although it is common to discover an anion gap acidosis with a concomitant elevated lactate concentration, the two are not mutually dependent.

Case Report: Here we describe two patients exhibiting high lactate concentrations in the setting of metabolic alkalemia.

Conclusion: Lactate is not necessarily the direct cause of acid-base disturbances, and there is no fixed relationship between lactate and the anion gap or between lactate and pH. The term “metabolic acidosis with hyperlactatemia” is more specific than “lactic acidosis” and thus more appropriate. [Clin Pract Cases Emerg Med. 2021;5(2):182–185.]

Keywords: *lactate; anion gap; acidosis; alkalosis.*

INTRODUCTION

Demystifying acid-base disorders is a staple of medical education and clinical practice.^{1,2} Year after year, medical students, house staff, and senior clinicians alike tackle the intricacies of anion gaps and delta gaps, and apply Winters’ formula, all in an effort to elucidate the metabolic and respiratory status of their patients.³ More specifically, when confronted with a metabolic acidosis of unclear etiology, mnemonics such as “MUDPILES” or “KULTS” are often used to develop and refine a differential diagnosis.

Any discussion of acid-base disturbance inevitably leads to discourse regarding the contribution of lactate. Serial monitoring of lactate has become a cornerstone in the management of the critically ill. Lactate is commonly used to delineate the severity of sepsis, interpreted as a prognostic marker, and regarded as a surrogate for tissue perfusion.^{4,5} Under most circumstances, an elevated lactate concentration implies impaired tissue perfusion. However, high lactate concentrations may represent toxin-induced impairment of cellular metabolism without overt evidence of systemic hypoperfusion; examples include metformin, cyanide, and carbon monoxide to name a few.⁶

Given the ubiquity of lactate and metabolic acidosis in clinical practice, it is common parlance to use the term

“lactic acidosis” when both conditions are present. However, we believe that this term reinforces the misconception that lactate itself contributes to acidemia. Instead, we prefer “metabolic acidosis with hyperlactatemia” to recognize two coexistent events that are not necessarily directly related. To illustrate this concept, we describe two patients exhibiting high lactate concentrations in the context of profound metabolic alkalosis. We will then discuss the relationship between lactate and acid-base physiology.

CASE REPORTS

Case 1

A 48-year-old man with metastatic hepatocellular carcinoma presented to the emergency department (ED) with three days of nausea and vomiting. He was discharged from an outside facility one month prior and was placed on home hospice care. For the three days preceding admission, he had intermittent fevers and nausea, and persistent episodes of profuse non-bloody, non-bilious emesis. During this time, the patient was unable to tolerate liquids or solids by mouth.

On physical examination, his vital signs included a blood pressure of 87/49 millimeters mercury (mm Hg), a

pulse of 128 beats per minute, a respiratory rate of 18 breaths per minute, a temperature of 103.2°F, an oxygen saturation of 99% (room air), and a point-of-care glucose of 88 milligrams per deciliter (mg/dL) (Reference Range: 70 - 100 mg/dl). He was ill appearing, cachectic, jaundiced, and oriented to name only. Mucous membranes were dry. Heart and lung examinations were unremarkable aside from tachycardia. His abdomen was soft and nontender, and melena was noted on rectal examination. The initial laboratory data is shown in the table.

Other pertinent findings included leukocytosis, anemia, hyperbilirubinemia of 15.9 mg/dL (reference range: 0.2 – 1.2 mg/dL and elevations of aspartate and alanine amino transferases (228 and 177 IU/L, respectively; reference ranges: 5 – 34 IU/L and 0 – 37 IU/L respectively).

Blood and urine cultures were obtained and the patient was started on broad spectrum antibiotics. Volume resuscitation consisted of two liters of 0.9% sodium chloride. Approximately two hours later, a repeat venous blood gas demonstrated a pH of 7.51, a partial pressure of carbon dioxide (pCO₂) of 42 mm Hg, and a lactate of 10.6 millimoles per liter (mmol/L). In discussion with the family, the patient was given only comfort care and no subsequent laboratory values were drawn. Antibiotics were discontinued two days after admission, and the patient expired one week after initial presentation. Blood cultures grew *Enterococcus faecalis*.

Case 2

A 39-year-old woman with chronic back pain was brought to the ED for altered mental status. According to family, she became depressed over the prior few months as a result of unemployment and the pandemic. Over the preceding two days, she had stopped eating and began to have episodes of non-bilious, non-bloody emesis. On the morning of presentation, she was found unresponsive at home and emergency medical services were called.

On physical examination, her vital signs included a blood pressure of 107/80 mm Hg, a pulse of 100 beats per minute, a respiratory rate of 16 breaths per minute, a temperature of 98.3°F, an oxygen saturation of 100% (bag valve mask on 10 L of oxygen), and a point-of care glucose

of 93 mg/dL. On general inspection, the patient appeared to be an incoherent, mumbling woman with poor hygiene and dried vomitus around her mouth. She was tachycardic, with normal heart sounds and clear lungs. Abdominal examination was notable for diffuse tenderness. She was subsequently intubated for airway protection. The initial laboratory data is shown in the table.

Other than leukocytosis the rest of her laboratory evaluation was not contributory. Blood and urine cultures were drawn. The electrocardiogram was significant for a prolonged absolute QT interval of 557 milliseconds (reference

CPC-EM Capsule

What do we already know about this clinical entity?

Serial monitoring of lactate is a cornerstone in the management of the critically ill patient and is often associated with a concomitant acidemia.

What makes this presentation of disease reportable?

We report the infrequent occurrence of an elevated lactate in the context of a profound metabolic alkalemia.

What is the major learning point?

The presence of lactate does not inherently indicate a coexisting acidemia. In fact, there is no fixed relationship between lactate and the anion gap.

How might this improve emergency medicine practice?

“Lactic acidosis” implies that lactate contributes to an acidemia. Instead, “metabolic acidosis with hyperlactatemia” is more appropriate in education and practice.

Table. Case 1: Initial laboratory studies of patient with hepatocellular carcinoma. Case 2: Initial laboratory studies of patient presenting with altered mental status.

	Na ⁺ mmol/L	K ⁺ mmol/L	Cl ⁻ mmol/L	Bicarbonate mmol/L	BUN mg/dl	Cr mg/dl	Anion Gap	pH	pCO ₂ mmHg	Lactate mmol/L
Case 1	142	4.2	59	38	104	4.7	45	7.58	40	22
Case 2	138	2.4	62	>40	36	1.0	N/A	7.61	60	9.3
Reference Range	136-145	3.5-4.8	98-107	22-29	7-20	0.6-1.1	6-14	7.35-7.45	35-45	0-1.9

Na⁺, sodium; K⁺, potassium; Cl⁻, chloride; BUN, blood urea nitrogen; Cr, creatinine; pCO₂, partial pressure of carbon dioxide; mmol/L, millimoles per liter; mg/dL, milligrams per deciliter; mm Hg, millimeters mercury.

range in women: < 460 milliseconds). Computed tomography of the head, chest, abdomen, and pelvis was negative for acute pathology. In the ED, the patient received broad spectrum antibiotics, thiamine, two liters of 0.9% sodium chloride, and a total of 80 milliequivalents of potassium supplementation.

Thereafter, she was admitted to the medical intensive care unit (MICU). While in the MICU, blood cultures grew *Staphylococcus aureus* and urine cultures grew *Proteus mirabilis*. The patient was continued on antibiotics, fluids, and potassium supplementation. She was extubated on hospital day two and transferred to the medical floor. Prior to leaving against medical advice on day four, her venous blood gas demonstrated a pH of 7.50, a pCO₂ of 38 mm Hg, and a lactate of 1.0 mmol/L.

DISCUSSION

To understand lactate and the associated changes in acid-base status, a brief discussion of both aerobic and anaerobic metabolism is warranted. Glycolysis (summarized in Figure, Equation A) converts one glucose molecule into two molecules of pyruvate. Glycolysis is anaerobic and occurs in the cytosol without the need for mitochondria.

In the presence of oxygen, pyruvate is transported into mitochondria and converted to acetyl coenzyme-A by the pyruvate dehydrogenase complex. Acetyl coenzyme-A then enters the citric acid cycle to drive adenosine triphosphate (ATP) synthesis. However, under anaerobic circumstances, in which oxygen cannot act as the final electron acceptor, pyruvate is converted to lactate in order to regenerate nicotinamide adenine dinucleotide via lactate dehydrogenase (Figure, Equation B). It is noteworthy that the conversion of pyruvate to lactate consumes a proton. Moreover, pyruvate and lactate are close to 100% ionized at a physiologic pH. Thus, the production of lactate in and of itself cannot account for the acidemia that often coexists with an elevated lactate concentration. As is summarized in figure, equation C, following glycolysis there is a net gain of two molecules of ATP without any change in hydrogen ion concentration.

Rather, it is the utilization of ATP under anaerobic conditions that generates a change in pH (Figure, Equation D). Despite this fact, there is a tendency to sum the reactions for anaerobic glycolysis (Figure, Equation C) and ATP hydrolysis (Figure, Equation D) resulting in Figure, Equation E, thus implying that lactate generation is inherently associated with an acidosis. However, it is imperative to recognize that these two processes are not intrinsically related.

When evaluating the differential of an elevated anion gap, classic teaching often stresses that organic acids, particularly lactic acid, should be suspected.⁷ However, the anion gap has a low sensitivity as a screening test for hyperlactatemia; in fact, elevated lactate concentrations should also be included in the differential of a non-anion gap acidosis.⁸ To account for hyperlactatemia in the presence of a normal anion gap, it is necessary to evaluate for hyperchloremia (often due to

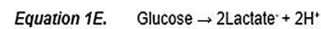
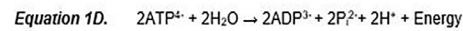
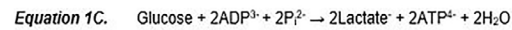
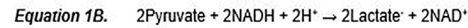
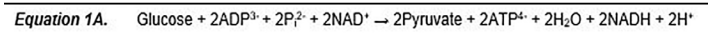


Figure. Anaerobic metabolism. A. Glycolysis; B. Reduction of pyruvate; C. Net glycolytic reaction under anaerobic conditions; D. ATP utilization under anaerobic conditions; E. Summation of anaerobic glycolysis and ATP utilization. ADP, adenosine diphosphate; P_i, phosphate; NAD, nicotinamide adenine dinucleotide; ATP, adenosine triphosphate; H₂O, water; NADH, nicotinamide adenine dinucleotide hydrogen; H⁺ hydrogen ion.

electrolyte-free water deficits or resuscitation with high chloride fluids), hypoalbuminemia, or the presence of mixed acid-base disturbance. While it is common to discover an anion gap acidosis and acidemia with a concomitant elevated lactate concentration, these two conditions are not mutually dependent.

In fact, alkalemia stimulates lactic acid production.⁹ Several in-vitro studies demonstrated that pH has a profound influence over certain rate-limiting enzymes of glycolysis.¹⁰ Phosphofructokinase (PFK), one such glycolytic enzyme, is particularly sensitive to pH. Inhibition of PFK by acidosis leads to reduced serum lactate, whereas alkalotic conditions potentiate a rise in lactate.⁷ This mechanism is felt to help normalize pH under anaerobic conditions, allowing for optimal intracellular enzymatic functioning, especially during times of metabolic stress.¹¹ In the context of an elevated pH, most elevations in serum lactate concentrations are modest as there is often an equally large increase in hepatic lactate consumption.¹² When marked elevation of lactate is noted, sepsis, shock, or tissue hypoperfusion are often simultaneously identified.¹³

However, a “true” lactic acidosis is possible in which the presence of an elevated lactate and metabolic acidemia are inherently linked. This is best illustrated by the metabolism of propylene glycol, a pharmaceutical diluent and an antifreeze. Following successive oxidation by alcohol and aldehyde dehydrogenases, propylene glycol is ultimately metabolized to lactic acid.^{14,15}

CONCLUSION

Both of the described cases demonstrate profoundly elevated lactate concentrations in the setting of alkalemia. By highlighting these cases and describing the biochemical nuances of energy metabolism, our aim is to disentangle hyperlactatemia and metabolic acidosis. While both conditions often coexist, the presence of one does not inherently indicate that the other is present. The generation of lactate is not directly associated with a change in pH. Rather, it is the hydrolysis and consumption of ATP that creates an acidosis. Moreover, while lactate is considered in the differential diagnosis of an anion gap acidosis, there is no fixed

relationship between lactate and the anion gap. Confounding factors such as hyperchloremia, hypoalbuminemia, or mixed acid-base disturbances, should be evaluated as they may lead to hyperlactatemia with a non-anion gap acidosis.

It is our hope that the term “lactic acidosis” be avoided as it implies that lactate itself contributes to an acidemia. Instead, “metabolic acidosis with hyperlactatemia” appears to be more specific and thus more appropriate, both for medical education and clinical practice.

The authors attest that their institution requires neither Institutional Review Board approval, nor patient consent for publication of this case report. Documentation on file.

REFERENCES

1. Berend K, de Vries AP, Gans RO. Physiological approach to assessment of acid-base disturbances. *N Engl J Med*. 2014;371(15):1434-45. Erratum in: *N Engl J Med*. 2014;371(20):1948.
2. Rein JL, Sparks MA, Hilburg R, et al. Tackling acid-base disorders, one Twitter poll at a time. *Adv Physiol Educ*. 2020;44(4):706-8.
3. Albert MS, Dell RB, Winters RW. Quantitative displacement of acid-base equilibrium in metabolic acidosis. *Ann Intern Med*. 1967;66(2):312-22.
4. Rivers E, Nguyen B, Havstad S, et al. Early goal-directed therapy in the treatment of severe sepsis and septic shock. *N Engl J Med*. 2001;345(19):1368-77.
5. Fuller BM and Dellinger RP. Lactate as a hemodynamic marker in the critically ill. *Curr Opin Crit Care*. 2012;18(3):267-72.
6. Kraut JA and Madias NE. Lactic acidosis. *N Engl J Med*. 2014;371(24):2309-19.
7. Emmett M and Narins RG. Clinical use of the anion gap. *Medicine (Baltimore)*. 1977;56(1):38-54.
8. Iberti TJ, Leibowitz AB, Papadakos PJ, et al. Low sensitivity of the anion gap as a screen to detect hyperlactatemia in critically ill patients. *Crit Care Med*. 1990;18(3):275-7.
9. Huckabee WE. Relationships of pyruvate and lactate during anaerobic metabolism. I. Effects of infusion of pyruvate or glucose and of hyperventilation. *J Clin Invest*. 1958;37(2):244-54.
10. Relman AS. Metabolic consequences of acid-base disorders. *Kidney Int*. 1972;1(5):347-59.
11. Madias NE. Lactic acidosis. *Kidney Int*. 1986;29(3):752-74.
12. Bersin RM and Arief AI. Primary lactic alkalosis. *Am J Med*. 1988;85(6):867-71.
13. Kilburn KH. Shock, seizures, and coma with alkalosis during mechanical ventilation. *Ann Intern Med*. 1966;65(5):977-84.
14. Reynolds HN, Teiken P, Regan ME, et al. Hyperlactatemia, increased osmolar gap, and renal dysfunction during continuous lorazepam infusion. *Crit Care Med*. 2000;28(5):1631-4.
15. Van de Wiele B, Rubinstein E, Peacock W, et al. Propylene glycol toxicity caused by prolonged infusion of etomidate. *J Neurosurg Anesthesiol*. 1995;7(4):259-62.

Address for Correspondence: Sanjay Mohan, MD, NYU Grossman School of Medicine, Ronald O. Perelman Department of Emergency Medicine, 455 First Avenue, Room 124, New York, New York 10016. Email: sanjay.mohan@nyumc.org.

Conflicts of Interest: By the CPC-EM article submission agreement, all authors are required to disclose all affiliations, funding sources and financial or management relationships that could be perceived as potential sources of bias. The authors disclosed none.

Copyright: © 2021 Mohan et al. This is an open access article distributed in accordance with the terms of the Creative Commons Attribution (CC BY 4.0) License. See: <http://creativecommons.org/licenses/by/4.0/>

Point-of-care Ultrasound in Early Diagnosis of Cardiomyopathy in a Child with Viral Myocarditis: A Case Report

Ayush Gupta, MD*
Trevor Eckenswiler, MD†

*Children's Hospital of New Orleans, Department of Pediatric Emergency Medicine, New Orleans, Louisiana

†William Beaumont Hospital, Department of Emergency Medicine, Royal Oak, Michigan

Section Editor: Shadi Lahham, M.D.

Submission history: Submitted December 12, 2020; Revision received February 5, 2021; Accepted February 23, 2021

Electronically published April 19, 2021

Full text available through open access at http://escholarship.org/uc/uciem_cpem

DOI: 10.5811/cpcem.2021.2.51266

Introduction: Pediatric myocarditis is a commonly missed diagnosis in the pediatric emergency department (ED) with high morbidity and mortality. The presentation of cardiogenic shock secondary to myocarditis and septic shock can be difficult to differentiate during initial resuscitation, and incorrect treatment can lead to poor prognosis. Early diagnosis may provide a better prognosis for this life-threatening condition.

Case Report: We report a case of a five-year-old female who presented to the ED with non-specific symptoms of myocarditis. Rapid point-of-care ultrasound led to early diagnosis, correct management, and great prognosis for the patient.

Conclusion: Providers must maintain a high index of suspicion for cardiogenic shock in patients with nonspecific symptoms and fluid unresponsiveness. Point-of-care ultrasound can help in the identification of cardiac disorders and guide practitioners in their management plans. [Clin Pract Cases Emerg Med. 2021;5(2):186–189.]

Keywords: POCUS; myocarditis; diagnostics; case report; pediatric.

INTRODUCTION

Point-of-care ultrasonography (POCUS) is a safe, effective imaging modality with a rapidly expanding array of life-saving, time-saving, and cost-saving applications in pediatric emergency medicine. The American Academy of Pediatrics recently published the first policy statement endorsing the use of POCUS by pediatric emergency physicians (EP). An accompanying technical report concluded: "It is our responsibility to our patients to stay abreast of the most current advances in medicine and provide the safest, most efficient, state-of-art care. Point-of-care [ultrasound] will help us meet that goal." Rapid ultrasound for shock and hypotension (RUSH) exam includes standardized views of the heart, inferior vena cava (IVC), lungs, and abdomen to further categorize the type of shock (eg, hypovolemic, cardiogenic, obstructive, distributive).¹

Focused cardiac ultrasound enables pediatric EPs trained in its use to diagnose pericardial effusions, assess cardiac contractility, and left ventricular enlargement with 91% accuracy.² It should be considered for assessing patients with signs or symptoms potentially related to cardiac dysfunction or effusion, such as shortness of breath, chest pain, syncope, hypotension/shock, or a new murmur.³

Myocarditis is rare in children, with an estimated annual incidence of 1-2 per 100,000 children.⁴ A higher incidence of myocarditis is noted in autopsy studies of infants and children who died suddenly and unexpectedly; evidence of myocarditis was noted in approximately 10-20% of such cases. These data represent that the true incidence of pediatric myocarditis is probably underestimated. The diagnosis is challenging due to the nonspecific symptoms such as respiratory distress or gastrointestinal symptoms (anorexia, abdominal pain, and

vomiting), which may be the most prominent features at presentation. Reported mortality rates during the acute illness for children with myocarditis range from 7-15%.⁵

In the pediatric ED several tests aid in the diagnosis of this life-threatening condition. Electrocardiogram (ECG) and troponin levels are performed when the suspicion is high. The RUSH exam conducted to evaluate shock may be of determinant help in assessing cardiac contractility and enlargement. We report a case of a five-year-old female who presented to the pediatric ED with non-specific symptoms of myocarditis. Rapid POCUS led to early diagnosis, correct management, and great outcome for this patient.

CASE REPORT

A five-year-old female presented to the pediatric ED with a chief complaint of vomiting. According to her parents, the patient had been having three days of fever and vomiting up to 10 times a day, which was non-bilious and non-bloody. She was also noted to have a sore throat, poor appetite, decreased sleep, and mild cough. The patient had seen her primary care physician the day before the pediatric ED visit; rapid streptococcal antigen test was negative, and she was sent home. The patient had no other past medical or surgical problems, no allergies, and was not taking any medications.

Her vitals on presentation was a temperature of 96.6°F orally, heart rate of 159 beats per minute, respiratory rate of 66 breaths per minute, blood pressure of 93/42 millimeters mercury (mm Hg), and oxygen saturation of 98% on room air. The patient was lethargic on examination, had dry mucous membranes, weak peripheral pulses, and capillary refill of 3-4 seconds. She had no abnormal lung sounds or heart murmur, and no hepatosplenomegaly.

In the pediatric ED, she was immediately connected to a monitor, and point-of-care blood glucose was obtained (146 milligrams per deciliter [mg/dL]; normal range 90-130 mg/dL). The differential diagnosis was broad and included dehydration, viral gastroenteritis, sepsis, appendicitis, obstruction, and pneumonia. Due to poor perfusion, no blood tests could be obtained but a peripheral intravenous access was established through which a 20 milliliters per kilogram (kg) normal saline bolus was given rapidly. Her initial capillary blood gas showed a pH of 7.30 (7.35-7.45), partial pressure of carbon dioxide of 26 mm Hg (35-45 mm Hg), and bicarbonate of 12 milliequivalents per liter (mEq/L) (22-28 mEq/L).

A POCUS was conducted (Videos 1, 2, 3) using a Sonosite 5-1 megahertz phased array probe (FUJIFILM Sonosite, Inc., Bothell, WA) to examine the cardiac function. The parasternal long-axis view demonstrated global hypokinesis with left ventricular ejection fraction (LVEF) less than 30%. The right ventricle was mildly dilated. The apical 4-chamber view showed slight pericardial effusion and decreased LVEF. We then conducted the sub-xyphoid IVC view, which showed a plethoric IVC with small pericardial effusion and small pleural effusion posteriorly with B lines.

CPC-EM Capsule

What do we already know about this clinical entity?

Cardiogenic shock is not uncommon in pediatric population but the diagnosis is often missed or delayed due to lack of specific clinic features.

What makes this presentation of disease reportable?

This child presented with non-specific symptoms of myocarditis but the early diagnosis was critical to prevent poor outcome.

What is the major learning point?

Point-of-care ultrasound (POCUS) can be useful in diagnosing cardiogenic shock in children.

How might this improve emergency medicine practice?

By using POCUS, providers can make early diagnosis and improve outcome of children in the emergency department.

A chest radiograph (Figure 1) and ECG were performed (Figure 2). The patient was diagnosed with myocarditis with cardiogenic shock based on physical examination and rapid POCUS. The cardiology team agreed with the diagnosis, and troponin later resulted at 30.40 nanograms/mL (normal is <0.03 ng/ml). In the pediatric ED, the patient had worsening mental status, increased tachypnea, and lethargy. Fluids were stopped and epinephrine drip was started, which resulted in improvement in her condition. She was transferred to the pediatric cardiac intensive care unit (PCICU).

The same day in the PCICU, the patient became bradycardic and lost pulses. Cardiopulmonary resuscitation was initiated, and the patient was placed on extracorporeal membrane oxygenation. She stayed in the hospital for 10 days and recovered almost completely. She was discharged with some left-sided weakness, and mild speech and swallowing difficulty for which she is undergoing rehabilitation. The final diagnosis was fulminant viral myocarditis (due to enterovirus) with cardiogenic shock.

DISCUSSION

Pediatric myocarditis is a commonly missed diagnosis in the pediatric ED. In up to 50% of cases, an etiology is never identified; therefore, most cases are deemed idiopathic. The most common identified source in the developed world

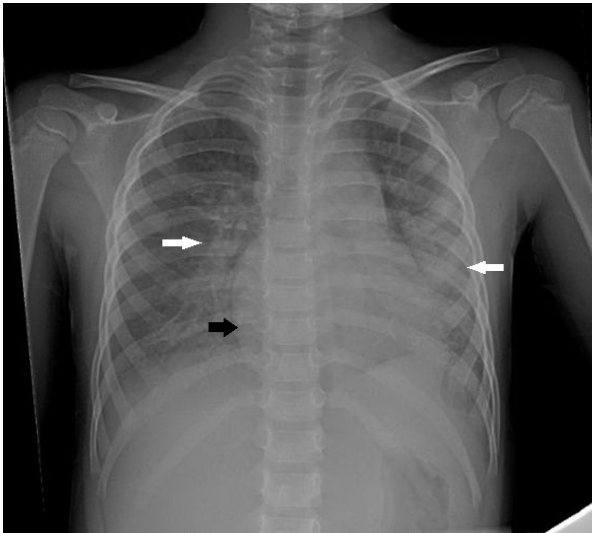


Image 1. Chest radiograph showing cardiomegaly (black arrow) and pulmonary edema (white arrows).

is viral. However, it can be caused by systemic disorders, bacteria, fungi, parasites, and toxins. Chagas disease is the most prevalent cause worldwide.⁶ The presentation can vary, but common symptoms can include fatigue, fever, chest discomfort, dyspnea, and vomiting. On examination, tachycardia is usually exaggerated compared to fever or discomfort, but unfortunately only presents 46-58% of the time.⁷ Hepatomegaly in the presence of non-specific symptoms should increase the suspicion.

Electrocardiogram is abnormal in most cases, but not specific. Changes can include sinus tachycardia, widening of QRS complex, and possible ST-segment changes. Pericarditis can be concomitant. Troponin is frequently elevated, and elevated inflammatory markers can aid in diagnosis. The gold standard for diagnosis is cardiac biopsy, which is rarely performed before the death of the patient.⁸ Signs and symptoms of myocarditis overlap with many other more common diseases. As in our case, the presentation of cardiogenic shock can be difficult to differentiate from hypovolemic or distributive shock during initial resuscitation.

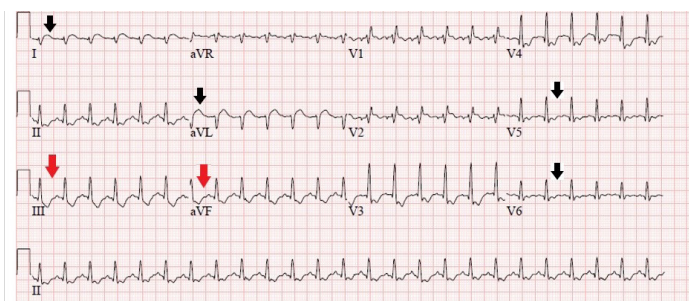


Image 2. Electrocardiogram showing sinus tachycardia, ST-segment elevation in lateral leads (I, aVL, V5-V6) (black arrows), T-wave inversion in inferior leads (III, aVF) (red arrows).

Fluid resuscitation needs to be evaluated as volume overload is deleterious, but these patients can present hypovolemic. In such a case, small crystalloid boluses of 5-10 cubic centimeters/kg can be administered slowly. It is to be noted that cardiogenic shock is a form of cold shock and has a low cardiac output and high systemic vascular resistance. Vasopressor selection is often debated, but inotropic support with epinephrine is a reasonable first choice.⁹

Pediatric POCUS is an emerging modality that physicians are becoming more comfortable with implementing in their practice. Visualization with ultrasound is a fast and easy tool that can be used upon arrival before any laboratory tests have been released. The advantages of POCUS also entail immediate diagnosis, increased accuracy, and minimal radiation dose.¹⁰ In myocarditis with cardiogenic shock, POCUS may reveal global left ventricular or biventricular dysfunction, dilated cardiomyopathy, and reduced LVEF usually from global hypokinesis. Studies have shown conflicting evidence on use of IVC measurements to assess volume status and fluid responsiveness. In general the two poles of volume status, hypovolemia and fluid overload, can be evaluated in the adult patient using IVC measurements. This can be extrapolated to the pediatric population within reason.^{11,12,13}

In this case, the patient was presumed to have septic shock and received rapid fluid bolus until POCUS altered our management. The echocardiogram also allowed effective management of laboratory studies, as it was extremely difficult to obtain blood secondary to poor perfusion. It was elected to send troponin as the only initial serum test until central venous access could be obtained. Implementing POCUS in critically ill-appearing patients with non-specific symptoms can increase the sensitivity and efficiency of detecting myocarditis early in the ED as well as guiding the resuscitation team accordingly.

CONCLUSION

Providers must maintain a high index of suspicion for cardiogenic shock in patients with nonspecific symptoms and unresponsive to fluids. Myocarditis is the leading cause of cardiogenic shock in the pediatric population. Point-of-care ultrasound can help in the identification of cardiac disorders and guide management in such patients.

Video 1. Parasternal long-axis view. Point-of-care ultrasound in parasternal long-axis view demonstrating global hypokinesis. Left ventricular ejection fraction less than 30%. Right ventricle mildly dilated.

LV, left ventricle; RV, right ventricle; LA, left atrium.

Video 2. Apical 4-chamber view. Point-of-care ultrasound in apical 4-chamber view demonstrating slight pericardial effusion and decreased left ventricular ejection fraction.

Video 3. Sub-xiphoid inferior vena cava (IVC) view. Point-of-care ultrasound in sub-xiphoid IVC view demonstrating a plethoric IVC and a small pericardial effusion. Also noted is a small pericardial effusion posteriorly with B-lines.

The authors attest that their institution requires neither Institutional Review Board approval, nor patient consent for publication of this case report. Documentation on file.

Address for Correspondence: Ayush Gupta, MD, Children's Hospital of New Orleans, Department of Pediatric Emergency Medicine, 200 Henry Clay Avenue, New Orleans, LA 70118. Email: ayush.gupta@lcmchealth.org.

Conflicts of Interest: By the CPC-EM article submission agreement, all authors are required to disclose all affiliations, funding sources and financial or management relationships that could be perceived as potential sources of bias. The authors disclosed none.

Copyright: © 2021 Gupta et al. This is an open access article distributed in accordance with the terms of the Creative Commons Attribution (CC BY 4.0) License. See: <http://creativecommons.org/licenses/by/4.0/>

REFERENCES

- Birenbaum DS and Kalra S. What's new in emergencies, trauma and shock? Shock, sonography and survival in emergency care! *J Emerg Trauma Shock*. 2015;8(1):1-2.
- Farsi D, Hajsadeghi S, Hajighanbari MJ, et al. Focused cardiac ultrasound (FOCUS) by emergency medicine residents in patients with suspected cardiovascular diseases. *J Ultrasound*. 2017;20(2):133-8.
- Marin JR and Lewiss RE. Point-of-care ultrasonography by pediatric emergency medicine physicians. *Pediatrics*. 2015;135(4):e1113-22.
- Lipshultz SE, Sleeper LA, Towbin JA, et al. The incidence of pediatric cardiomyopathy in two regions of the United States. *N Engl J Med*. 2003;348(17):1647-55.
- Rodriguez-Gonzalez M, Sanchez-Codez MI, Lubian-Gutierrez M, et al. Clinical presentation and early predictors for poor outcomes in pediatric myocarditis: a retrospective study. *World J Clin Cases*. 2019;7(5):548-61.
- Global Burden of Disease Study 2013 Collaborators. Global, regional, and national incidence, prevalence, and years lived with disability for 301 acute and chronic diseases and injuries in 188 countries, 1990-2013: a systematic analysis for the Global Burden of Disease Study 2013. *Lancet*. 2015;386(9995):743-800.
- Durani Y, Egan M, Baffa J, et al. Pediatric myocarditis: presenting clinical characteristics. *Am J Emerg Med*. 2009;27(8):942-7.
- Schultz JC, Hilliard AA, Cooper LT Jr, et al. Diagnosis and treatment of viral myocarditis. *Mayo Clin Proc*. 2009;84(11):1001-9.
- Ventura AM, Shieh HH, Bousso A, et al. Double-blind prospective randomized controlled trial of dopamine versus epinephrine as first-line vasoactive drugs in pediatric septic shock. *Crit Care Med*. 2015;43(11):2292-302.
- Myslik F, Lim R, Poonai N. The emerging role of point-of-care ultrasound in pediatric emergency medicine. *J Radiol Nurs*. 2018;37(3):173-80.
- McLean AS. Echocardiography in shock management. *Crit Care*. 2016 20;20:275.
- Park DB, Presley BC, Cook T, et al. Point-of-care ultrasound for pediatric shock. *Pediatr Emerg Care*. 2015;31(8):591-8; quiz 599-601.
- Millington SJ. Ultrasound assessment of the inferior vena cava for fluid responsiveness: easy, fun, but unlikely to be helpful. *Can J Anaesth*. 2019;66(6):633-8.

Atezolizumab-induced Autoimmune Diabetes in a Patient with Metastatic Breast Cancer: A Case Report

Robert Clontz, MD
Duc M. Dang, MD
Michelle A. Hieger, DO
Brent A. Becker, MD

Wellspring York Hospital, Department of Emergency Medicine, York, Pennsylvania

Section Editor: R. Gentry Wilkerson, MD

Submission history: Submitted January 7, 2021; Revision received March 1, 2021; Accepted February 23, 2021

Electronically published May 10, 2021

Full text available through open access at http://escholarship.org/uc/uciem_cpchem

DOI: 10.5811/cpchem.2021.2.51508

Introduction: Immune checkpoint inhibitors (ICI) are a class of immunotherapy drugs used increasingly in the treatment of multiple types of cancer. Major side effects include immune-related adverse effects, potentially resulting in damage to normal tissue across multiple different organ systems.

Case Report: A 74-year-old woman with a history of triple negative metastatic breast cancer treated with the ICI atezolizumab presented with new-onset autoimmune diabetes in diabetic ketoacidosis. She required fluid resuscitation, insulin infusion, vasopressors, and initial hospitalization in the intensive care unit. The patient was subsequently discharged on bolus dose insulin and remained an insulin-dependent diabetic at three-month follow-up.

Conclusion: Autoimmune diabetes is a rare, but life-threatening, adverse event associated with ICIs such as atezolizumab. To our knowledge this is the only case report of atezolizumab causing autoimmune diabetes in the setting of metastatic breast cancer. As ICIs become more common in the treatment of cancer, emergency physicians should remain vigilant for the various immune-mediated complications associated with this class of immunotherapy drugs. [Clin Pract Cases Emerg Med. 2021;5(2):190–193.]

Keywords: *Atezolizumab; autoimmune diabetes mellitus; immune checkpoint inhibitors; case report.*

INTRODUCTION

Immune checkpoint inhibitors (ICI) are a class of immunotherapy drugs used increasingly in the treatment of multiple types of cancer. Immune checkpoint inhibitors function by removing inhibitory signals for T-cells and facilitating antitumor activity; however, this can also result in autoimmune-mediated damage to normal tissue. Known as immune-related adverse effects (irAE), these side effects most often affect the skin and gastrointestinal, and endocrine systems. Hypophysitis and thyroid dysfunction are the most common endocrine abnormalities.^{1,2}

Atezolizumab is a monoclonal ICI, first approved by the US Food and Drug Administration (FDA) in 2016 for the treatment of metastatic urothelial cancer. It is currently used in multiple other malignancies, including urothelial

carcinoma and triple negative breast cancer.^{1,3} We describe a case of atezolizumab-induced, new-onset diabetes presenting with diabetic ketoacidosis (DKA) in a patient with metastatic breast cancer.

CASE REPORT

A 74-year-old woman presented to the emergency department with two days of nausea, vomiting, dyspnea, lightheadedness, and malaise. The patient had been diagnosed with invasive ductal carcinoma of the right breast 12 months prior to presentation. The malignancy was estrogen receptor, progesterone receptor, and human epidermal growth factor receptor 2 negative with known metastasis to the bone. After initial treatment with doxorubicin hydrochloride, cyclophosphamide and paclitaxel, the patient was transitioned

to atezolizumab and paclitaxel combination therapy. She had completed 14 cycles over the preceding 52 weeks, and oncology reported her disease to be well controlled and stable. She carried a prior diagnosis of paroxysmal atrial fibrillation managed with diltiazem, metoprolol and warfarin.

The patient had no history of diabetes or insulin resistance and had previously demonstrated consistently normal serum glucose levels. There was no preceding starvation, insulin use, thromboembolic event, or ischemic process. She had been started on low-dose steroid of prednisone 5 milligrams (mg) daily three months prior for autoimmune-mediated arthritis and chemotherapy-induced neuropathy of her left lower extremity. Her non-fasting blood glucose level two months prior to presentation on routine blood work was 135 mg/dL (reference range 70 - 139 mg/dL).

On initial assessment, her vital signs were temperature 36.3°C, blood pressure 126/78 millimeters of mercury (mm Hg), heart rate 123 beats per minute, respiratory rate 24 breaths per minute, and oxygen saturation 96% on room air. She had atrial fibrillation with rapid ventricular response. Physical exam was significant for Kussmaul respirations, bibasilar rales, and mild subcostal retractions. Her body mass index was 39.4 kilograms per meter squared (kg/m²) (18.5 – 24.9 kg/m²).

Initial laboratory results are shown in the Table. She had marked hyperglycemia with an elevated anion gap acidosis, ketonuria, evidence of urinary tract infection, and supratherapeutic anticoagulation. Electrocardiography showed atrial fibrillation with rapid ventricular rate and no evidence of acute ischemic changes. Based on history, physical, and laboratory data it was determined that her presentation was most consistent with new-onset diabetes mellitus with DKA. Her case was further complicated by severe sepsis secondary to a urinary tract infection and atrial fibrillation with rapid ventricular response. The patient was treated with sodium chloride 0.9% at 150 milliliters (mL) per hour and an infusion of regular insulin (250 units in 250 mL of 0.9% sodium chloride) at 0.1 units/kg per hour. Her urinary tract infection was treated empirically with intravenous cefepime 1 gram and she received two 50 mL boluses of 8.4% sodium bicarbonate for severe metabolic acidosis.

The patient was persistently hypotensive with a blood pressure of 95/49 mm Hg following fluid resuscitation. She was subsequently started on norepinephrine 4 mg in 250 mL premix at 0.01 micrograms/kg per minute and transferred to the medical intensive care unit (ICU) for management of DKA and septic shock. Her urine culture later revealed greater than 100,000 colony-forming units/mL *Escherichia coli* at 48 hours. After three days in the ICU, the patient was transitioned to the general medical floor on a regimen of insulin glargine 30 units every morning and insulin lispro 7 units three times daily with meals.

During hospital admission, her C-peptide level was 0.10 nanograms/mL (ng/mL) (reference range 0.80-3.85 ng/mL).

CPC-EM Capsule

What do we already know about this clinical entity?

Immune checkpoint inhibitors are associated with rare yet potentially fatal immune-related adverse effects and can damage almost any organ system.

What makes this presentation of disease reportable?

To our knowledge this is the only case report of atezolizumab causing autoimmune diabetes in the setting of triple negative metastatic breast cancer.

What is the major learning point?

When treating cancer patients in the ED, it is crucial to determine the cancer diagnosis and treatment history including past and present types of therapeutics.

How might this improve emergency medicine practice?

Early recognition and diagnosis of immune-related adverse effects by emergency physicians can help provide timely acute management and improve patient outcomes.

Glutamic acid decarboxylase antibodies were less than 5 international units per milliliter (IU/mL) (<5 IU/mL). The diagnosis of new-onset diabetes was deemed autoimmune in nature and attributed to her use of atezolizumab over the prior year. She was discharged on hospital day eight on insulin lispro and insulin detemir and remained an insulin-dependent diabetic at three-month follow-up.

DISCUSSION

We present a rare case of atezolizumab-induced autoimmune diabetes mellitus in a patient treated for metastatic breast cancer. While cases of ICI-induced autoimmune DKA have been previously reported related to the treatment of urothelial, skin, lung, and renal cancer, no prior case has been described in the setting of metastatic breast cancer treatment.¹

Atezolizumab is a humanized monoclonal antibody to programmed death-ligand 1 (PD-L1) and is classified as an ICI. Atezolizumab is FDA approved for the treatment of various types of cancer, including metastatic non-small cell lung cancer, locally advanced or metastatic urothelial carcinoma, and triple-negative breast cancer in patients who

Table. Initial laboratory values of a patient with hyperglycemia, elevated anion gap metabolic acidosis, and evidence of urinary tract infection.

Laboratory Name (reference range with units)	Patient's Results
Basic Metabolic Panel	
Sodium (135-145 mmol/L)	127
Potassium (3.5-5.3 mmol/L)	5.7
Chloride (98-107 mmol/L)	91
Carbon dioxide (21-31 mmol/L)	6
Blood urea nitrogen (7-25 mg/dL)	35
Creatinine (0.06-1.2 mg/dL)	1.39
Glucose (70-99 mg/dL)	845
Calcium (8.6-10.3 mg/dL)	9.0
Estimated glomerular filtration rate (>90 mL/min/1.73m ²)	37.4
Anion gap (3-11 mmol/L)	30
Complete Blood Count	
White blood cell count (4-11 K/mcL)	17.4
Hemoglobin (11.5-15.5 g/dL)	13.5
Hematocrit (34.5-47.0%)	42.6
Platelets (140-400 K/mcL)	465
Absolute neutrophils (1.7-7.8 K/mcL)	13.81
Coagulation Studies	
Prothrombin time (9.4-12.4 seconds)	46.2
International normalized ratio (0.8-1.2)	4.6
Other Laboratory Values	
Venous pH (7.35-7.45)	7.06
Beta hydroxybutyrate (0.0-0.3 mmol/L)	12.3
Lactic acid (0.5-2.0 mmol/L)	2.6
Hemoglobin A1c (<5.7%)	7.1
Urinalysis	
Urine color (yellow, light yellow, dark yellow)	Yellow
Urine clarity (clear)	Cloudy
Leukocyte esterase (negative)	Trace
Nitrite (negative)	Negative
Urine glucose (negative mg/dL)	>1000
Urine ketones (negative mg/dL)	≥ 80
Urine blood (negative)	Moderate
Urine red blood cells (0-23 mcL)	14
Urine white blood cells (0-28 mcL)	396
Urine squamous epithelial (0-31 mcL)	5
Urine bacteria (0-358 mcL)	184

mmol/L, millimole per liter; mg/dL, milligrams per deciliter; mL/min/1.73m², milliliters per minute per 1.73 meters squared; K/mcL, thousands per microliter; g/dL, grams per deciliter; mcL, microliter.

experience disease progression after platinum-based chemotherapy. The recommended dose is 840 mg administered

as an intravenous infusion every three weeks until disease progression or unacceptable toxicity is noted.⁴

Atezolizumab functions by inhibiting the binding of programmed cell death 1 (PD-1), which is expressed on T cells, to PD-L1, which is expressed on antigen-presenting cells and tumor cells (Figure, A). This inhibition allows the T cells to activate and proliferate against tumor cells. Unfortunately, pancreatic islet cells also express PD-L1. Atezolizumab can inhibit the binding of PD-1 to PD-L1 and activate the T cell against the pancreatic islet cells. Subsequent destruction of pancreatic islet cells results in autoimmune-induced diabetes (Figure, B).

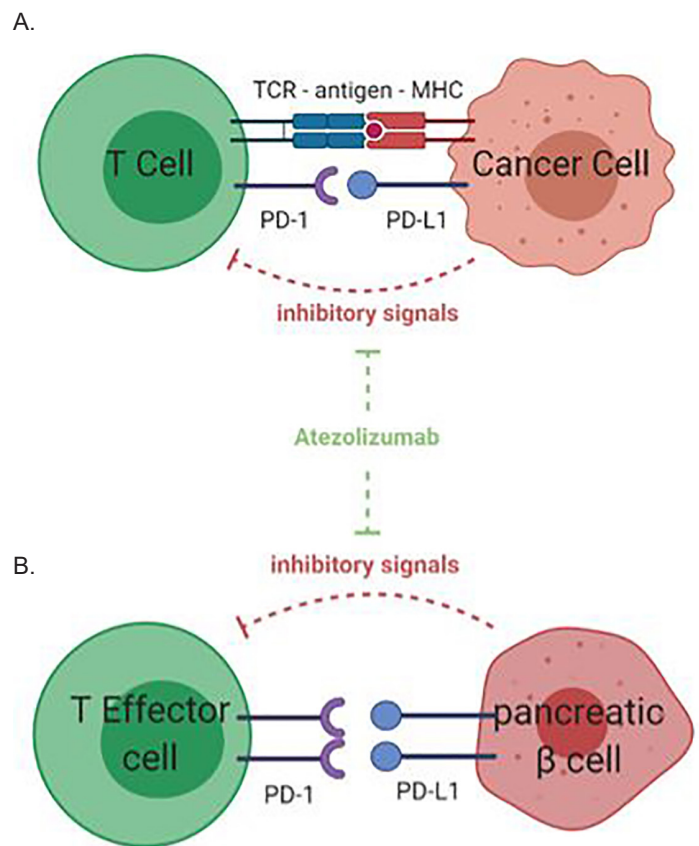


Figure. (A) Mechanism of anti-PD-L1, atezolizumab, on T-cell response to cancer cell. PD-L1 is expressed on cancer cells and inhibits T-cell activation when binding to the PD-1 receptor on T-cell surface. Anti-PD-1/PD-L1 treatment with atezolizumab leads to the inhibition of this inhibitory pathway and subsequent enhanced T-cell activity against tumor cells. **(B)** Mechanism of action of anti-PD-L1 agent on immune tolerance in the pancreas. PD-1/PD-L1 interaction between effector T cells and pancreatic insulin-secreting β cells inhibits T-cell activation against the pancreas. The anti-PD-L1 agent, atezolizumab, blocks the PD-1/PD-L1 interaction, leading to activation of self-reactive T cells and destruction of the pancreatic islet cells of Langerhans. This results in immunotherapy-induced autoimmune diabetes. Figures created with BioRender.com (Toronto, ON, Canada). MHC, major histocompatibility complex; TCR, T-cell receptor; PD-L1, programmed death – ligand 1; PD-1, programmed death – 1.

The onset of ICI-mediated autoimmune diabetes has been shown to range from a single dose in the first week to 228 weeks, with a median onset of 20 weeks, after drug initiation.^{3,5-7} In this case, the time to onset was 52 weeks. The treatment of ICI-induced diabetes is similar to the treatment of new-onset diabetes of other causes. In our patient, DKA was identified and an insulin infusion was initiated and continued until the patient's anion gap normalized. She was then switched to subcutaneous short- and long-acting insulin therapy. In ICI-induced diabetes, immunosuppression with corticosteroids can be attempted, but may be futile given that typically 80–95% of the insulin-producing pancreatic beta cells will have been permanently destroyed.² This is in contrast to most other irAE where glucocorticoids are considered first-line therapy.³

In the majority of cases involving irAE secondary to ICI therapy, the emergency physician should discuss with oncology whether urgent initiation of glucocorticoids is indicated. Most patients can continue taking the ICI after stabilization of glucose levels because the majority of insulin-producing pancreatic cells have already been eliminated.² The ICI-induced endocrine injury is typically permanent. To date, there have been no reported cases of diabetes remission with the cessation of ICIs.⁵

In addition to diabetes, there are a multitude of other immune-mediated complications associated with ICIs. A meta-analysis of anti-cytotoxic T-lymphocyte-associated protein 4 (CTLA-4) antibodies found the overall incidence of adverse events to be 72% with 24% involving high-grade complications.⁸ Such adverse events included skin lesions (rash, pruritus, and vitiligo), colitis, hepatitis, hypophysitis, thyroiditis, sarcoidosis, uveitis, Guillain-Barré syndrome, immune-mediated cytopenia, and polymyalgia rheumatica.⁸ Another study examining all three major classes of ICIs (CTLA-4, PD-1, and PDL-1) found 32.7% of emergency department patients on an ICI were diagnosed with an immune-mediated toxicity. Colitis (38.8%), hepatitis (19.4%), and pneumonitis (14.3%) were the most common immune-mediated toxicities. Of the 300 patients included in the study, DKA remained a rare presentation (0.3%).⁹ The incidence of thyroid disorders (hypothyroidism, thyrotoxicosis, painless thyroiditis, or thyroid storm) is estimated to be approximately 10% in patients treated with a single agent anti-PD-1/PD-L1.¹⁰

CONCLUSION

Autoimmune diabetes is a rare but significant potential side effect of immune checkpoint inhibitor therapy. Emergency physicians should be aware of this and other immune-mediated complications in patients receiving ICI immunotherapy. Emergency physicians are likely to encounter more patients on ICIs and should routinely consider diabetes, diabetic ketoacidosis, and other acute conditions related to underlying immune-related adverse effects.

The authors attest that their institution requires neither Institutional Review Board approval, nor patient consent for publication of this case report. Documentation on file.

Address for Correspondence: Robert Clontz, MD, Wellspan York Hospital, Department of Emergency Medicine, 1001 South George Street, York, PA 17403. Email: rclontz@wellspan.org.

Conflicts of Interest: By the CPC-EM article submission agreement, all authors are required to disclose all affiliations, funding sources and financial or management relationships that could be perceived as potential sources of bias. The authors disclosed none.

Copyright: © 2021 Clontz et al. This is an open access article distributed in accordance with the terms of the Creative Commons Attribution (CC BY 4.0) License. See: <http://creativecommons.org/licenses/by/4.0/>

REFERENCES

- Hickmott L, De La Peña H, Turner H, et al. Anti-PD-L1 atezolizumab-induced autoimmune diabetes: a case report and review of the literature. *Target Oncol.* 2017;12(2):235-41.
- González-Rodríguez E and Rodríguez-Abreu D. Immune checkpoint inhibitors: review and management of endocrine adverse events. *Oncologist.* 2016;21(7):804-16.
- Yeung SJ, Qdaisat A, Chaftari P, et al. Diagnosis and management of immune-related adverse effects of immune checkpoint therapy in the emergency department. *J Am Coll Emerg Physicians Open.* 2020;1(6):1637-59.
- Fujisawa R, Haseda F, Tsutsumi C, et al. Low programmed cell death-1 (PD-1) expression in peripheral CD4(+) T cells in Japanese patients with autoimmune type 1 diabetes. *Clin Exp Immunol.* 2015;180(3):452-7.
- Smati S, Buffier P, Bouillet B, et al. Expert opinion on immunotherapy induced diabetes. *Ann Endocrinol (Paris).* 2018;79(5):545-9.
- Stamatouli AM, Quandt Z, Perdigoto AL, et al. Collateral damage: insulin-dependent diabetes induced with checkpoint inhibitors. *Diabetes.* 2018;67(8):1471-80.
- Kapke J, Shaheen Z, Kilari D, et al. Immune checkpoint inhibitor-associated type 1 diabetes mellitus: case series, review of the literature, and optimal management. *Case Rep Oncol.* 2017;10(3):897-909.
- Bertrand A, Kostine M, Barnetche T, et al. Immune related adverse events associated with anti-CTLA-4 antibodies: systematic review and meta-analysis. *BMC Med.* 2015;13:211.
- Cooksley T, Gupta A, Al-Sayed T, et al. Emergency presentations in patients treated with immune checkpoint inhibitors. *Eur J Cancer.* 2020;130:193-7.
- Ferrari SM, Fallahi P, Galetta F, et al. Thyroid disorders induced by checkpoint inhibitors. *Rev Endocr Metab Disord.* 2018;19(4):325-33.

Rhabdomyolysis: A Case Report of an Extrapulmonary Presentation of *Mycoplasma pneumoniae*

Michael Gulenay, DO
V. Andres Sasson, MD
Kevin Taylor, MD

St. Lucie Medical Center, Palm Beach Consortium for Graduate Medical Education,
Department of Emergency Medicine, Port St. Lucie, Florida

Section Editor: Scott Goldstein, MD

Submission history: Submitted November 28, 2019; Revision received September 15, 2020; Accepted September 20, 2020

Electronically published March 12, 2021

Full text available through open access at http://escholarship.org/uc/uciem_cpem

DOI: 10.5811/cpcem.2020.9.46024

Introduction: We present an unusual case of rhabdomyolysis secondary to *Mycoplasma pneumoniae* in a healthy 27-year-old female. *M. pneumoniae* is associated with numerous extrapulmonary manifestations, including acute hepatitis, Stevens-Johnson syndrome, and rhabdomyolysis. Most documented cases affect the pediatric population, with only five cases in adults reported in the literature.

Case Report: The patient presented with complaints of myalgia and intractable cough. In this case the initial presentation demonstrated hypoxia requiring supplemental oxygen, and a creatine kinase of 7,646 units per liter (U/L) (reference range 26-192 U/L) with a peak of 29,427. During her hospitalization, she also remained persistently hypoxic for several days but ultimately was successfully weaned off all supplemental oxygen. She was discharged home after a seven-day hospitalization.

Conclusion: This patient's presentation of an insidious, upper respiratory infection along with the subsequent development of rhabdomyolysis with reactive antibodies to *M. pneumoniae* demonstrates a link between these two clinically important conditions. [Clin Pract Cases Emerg Med. 2021;5(2):194–197.]

Keywords: *Rhabdomyolysis; Mycoplasma pneumoniae; extrapulmonary manifestations.*

INTRODUCTION

Mycoplasma pneumoniae is the most common cause of community-acquired pneumonia in healthy young patients under age 40.^{1,2} It can affect people of any age group but is typically associated with ages 5-20.^{1,2} It is transmitted from person to person via respiratory droplets and has a subtle and lingering presentation.^{1,2} The incubation period is approximately 2-3 weeks and symptoms are characteristic of most viral infections. It is differentiated by the intractable and progressively worsening cough. It is worth noting that many patients who become infected with *M. pneumoniae* are asymptomatic.^{1,2} In rare circumstances patients develop extrapulmonary disease including dermatological, gastrointestinal, neurological, and musculoskeletal manifestations.¹⁻³ Rhabdomyolysis is one of these rare manifestations; a literature review reveals that most cases affect the pediatric population and a handful of cases reported in healthy adults.³⁻¹² We present an unusual case of

rhabdomyolysis secondary to *M. pneumoniae* in a healthy young adult female with hypoxia and myalgia.

CASE REPORT

A 27-year-old female with a pertinent medical history of tobacco use and intrauterine device implantation presented to the emergency department (ED) with a chief complaint of progressively worsening shortness of breath for two days. Associated symptoms included a non-productive cough, tactile fevers, diaphoresis, muscle aches, and chest pain when coughing. Symptoms were present for two weeks and were felt to be improving until four days prior. The patient was also evaluated in the ED the previous day and was prescribed prednisone and doxycycline for a diagnosis of atypical pneumonia. Additional review of symptoms was negative for hemoptysis, extremity pain or swelling, history of venous thromboembolic disease, or any travel.

Physical examination was significant for an anxious and diaphoretic female in moderate respiratory distress. She appeared uncomfortable and was in a tripod position. Auscultation revealed bilaterally diminished breath sounds with mild expiratory wheezing. The rest of the examination was unremarkable except for tachycardia. Initial vital signs were a temperature of 98.1° degrees Fahrenheit (36.7° Celsius), pulse of 107 beats per minute, blood pressure of 134/75 millimeters of mercury, respiratory rate of 24 breaths per minute, and pulse oximetry of 91% on two liters oxygen via nasal cannula.

In view of the patient's respiratory distress, she was given nebulized ipratropium bromide and albuterol, in addition to an intravenous (IV) anxiolytic. This resulted in an improvement in her respiratory effort and work of breathing. The hypoxia improved through the implementation of 100% oxygen via a non-rebreather mask, which was subsequently converted to a high-flow nasal cannula. Oxygen saturations stabilized and remained greater than 95% after she received the above treatments. The patient was empirically treated with IV ceftriaxone and doxycycline and two liters of IV normal saline. Both plain chest radiograph and computed tomography angiography of the chest were negative for acute findings.

Laboratory findings were significant for leukocytosis of 15.4×10^3 microliters (μL) (reference range $3.6\text{--}11 \times 10^3/\mu\text{L}$); lactic acid of 2.3 millimoles per liter (mmol/L) (reference range 0.4 – 2.0 mmol/L); C-reactive protein of 5.12 milligrams per deciliter (mg/dL) (ref range 0.00–0.30 mg/dL); creatine kinase of 7,646 units/L (ref range 26–192 U/L); and creatine kinase MB (CK-MB) of 42.0 nanograms per milliliter (ng/mL) (ref range 0.0–5.6 ng/mL). Rapid influenza diagnostic testing was negative. *M. pneumoniae* antibody testing and viral panel studies were also collected but did not result until later in the admission. Patient denied illicit drug use, including methamphetamine abuse, which was confirmed by a negative urine drug screen. She was admitted to the intensive care unit and treated with aggressive IV hydration therapy, supplemental oxygen, and antibiotics.

During her hospitalization, both the serum creatine kinase and CK-MB levels were monitored serially and continued to rise with peaks on day two of 29,427 U/L and 87.3 ng/mL, respectively. These levels gradually trended down to a normal reference range by day seven and day four, respectively (Figures 1 and 2). Renal function was unaffected and remained normal with an initial creatinine of 0.76 mg/dL and a peak of 0.79 (reference range 0.43 to 1.13 mg/dL). Relevant admission findings included reactive immunoglobulin M antibodies to *M. pneumoniae*. She also remained persistently hypoxic for several days but ultimately was successfully weaned off all supplemental oxygen and discharged home after a seven-day hospitalization.

DISCUSSION

Rhabdomyolysis is a rare extrapulmonary manifestation of *M. pneumoniae*, and literature review reveals it to be

CPC-EM Capsule

What do we already know about this clinical entity?

Mycoplasma pneumoniae (*M. pneumoniae*) has been linked with numerous extrapulmonary conditions and it has been postulated that the activation of inflammatory mediators such as cytokines leads to the muscle damage.

What makes this presentation of disease reportable?

Rhabdomyolysis secondary to M. pneumoniae in a healthy young adult is a rare presentation. A literature review reveals that most cases affect the pediatric population, rather than healthy adults.

What is the major learning point?

As emergency physicians, we must maintain a wide differential and high suspicion to avoid missing potentially important secondary diagnoses critical to favorable patient outcome.

How might this improve emergency medicine practice?

The case highlights the need to maintain suspicion for life-threatening causing extrapulmonary manifestations in patients with straightforward-appearing upper respiratory infections.

infrequently described in healthy adults.^{3–7} The rod-shaped bacterium is excreted from the respiratory tract weeks after the acute infection and has been associated with acute hepatitis, immune thrombocytopenic purpura, Stevens-

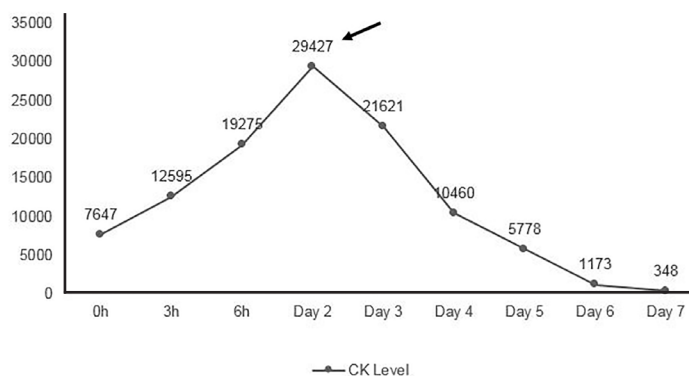


Figure 1. Creatine kinase (CK) trend during hospitalization. The peak CK value is denoted by the arrow. All values measured in units per liter (U/L) with a reference range of 26–192 U/L.

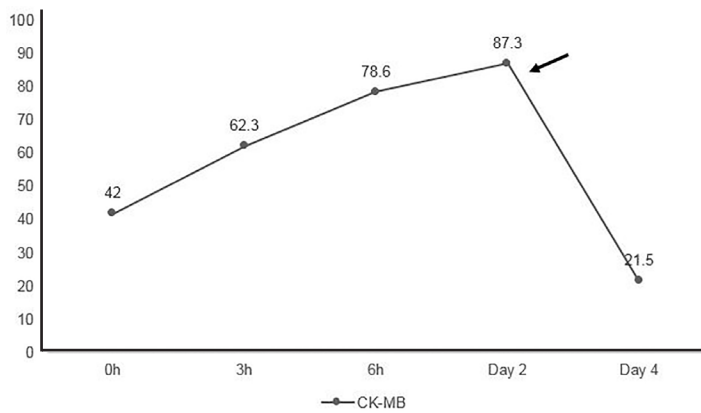


Figure 2. Creatine kinase MB (CK-MB) trend during hospitalization. The peak CK-MB value is denoted by the arrow. All values measured in nanograms per milliliter (ng/mL) with a reference range of 0.0-5.6 ng/mL.

Johnson syndrome, and transverse myelitis.^{1,2} The pathogenicity of *M. pneumoniae* has been linked to the activation of inflammatory mediators such as cytokines.^{1,2} However, the mechanism of muscle damage due to infection has not been established and remains unclear. One theory postulates direct invasion and toxic degeneration of the muscle fibers.^{1,2}

The pathophysiology of rhabdomyolysis, however, is well understood and involves the release of intracellular components secondary to skeletal muscle necrosis.^{1,2} This results in large quantities of potentially toxic intracellular substances being released into the plasma including creatinine kinase and myoglobin. The myoglobin precipitates into the glomerular filtrate resulting in nephrotoxicity and acute kidney injury. It clinically presents as myalgia and dark urine and is diagnosed when the creatine kinase level is five times the upper limit of normal.^{1,2} There are numerous causes of rhabdomyolysis including trauma, extreme exertion, heatstroke, medication side effect, illicit drug use, and infections.

Infectious causes include both viral and bacterial pathogens such as influenza A/B, coxsackievirus, *M. pneumoniae*, *Legionella* species, and *Salmonella* species.^{1-2,11-12} This patient's presentation of an insidious upper respiratory infection along with the subsequent development of rhabdomyolysis with reactive antibodies to *M. pneumoniae* demonstrates a link between these two clinically important conditions. It is noteworthy to mention that the recent upper respiratory symptoms and the new complaints of chest pain and shortness of breath raised initial concern for myopericarditis. This concern was mitigated by normal serial troponins and transthoracic echocardiogram.

CONCLUSION

The case highlights the need to maintain suspicion for life-threatening risk and morbidity causing extrapulmonary

manifestations in patients with otherwise straightforward-appearing upper respiratory infections. The diagnosis can be challenging, such as in this case, as patients may not initially complain of muscle soreness or cramping, which is often representative of rhabdomyolysis. The extrapulmonary presentation of rhabdomyolysis secondary to *Mycoplasma pneumoniae* is rare; to our knowledge there are only five previously documented cases in healthy adults.³⁻⁷ As emergency physicians, we must maintain a wide differential and high suspicion to avoid missing potentially important secondary diagnoses critical to favorable patient outcome.

The authors attest that their institution requires neither Institutional Review Board approval, nor patient consent for publication of this case report. Documentation on file.

Address for Correspondence: Michael Gulenay, DO, St. Lucie Medical Center, Department of Emergency Medicine, 1800 SE Tiffany Avenue, Port St. Lucie, FL 34952. Email: michaelgu@pcom.edu.

Conflicts of Interest: By the CPC-EM article submission agreement, all authors are required to disclose all affiliations, funding sources and financial or management relationships that could be perceived as potential sources of bias. The authors disclosed none. This research was supported (in whole or in part) by HCA Healthcare and/or an HCA Healthcare affiliated entity. The views expressed in this publication represent those of the author(s) and do not necessarily represent the official views of HCA Healthcare or any of its affiliated entities.

Copyright: © 2021 Gulenay et al. This is an open access article distributed in accordance with the terms of the Creative Commons Attribution (CC BY 4.0) License. See: <http://creativecommons.org/licenses/by/4.0/>

REFERENCES

1. Wolfson AB, Cloutier RL, Hendej GW, et al. (2014). *Harwood-Nuss' Clinical Practice of Emergency Medicine*. Philadelphia, PA: Lippincott Williams & Wilkins.
2. De Guzman M, Jung L, Muscal E, et al. Rhabdomyolysis. 2018. Available at: <https://emedicine.medscape.com/article/1007814-overview>. Accessed October 18, 2019.
3. Kaler J, Mukhtar O, Khan B, et al. Rhabdomyolysis: An unusual presentation of *Mycoplasma pneumoniae* Infection in an adult: a case report and literature review. *Case Rep Med*. 2018;2018:6897975.
4. Khan FY and Sayed H. Rhabdomyolysis associated with *Mycoplasma pneumoniae* pneumonia. *Hong Kong Med J*. 2012;18(3):247-9.

5. Gosselt A, Olijhoek J, Wierema T. Severe asymptomatic rhabdomyolysis complicating a *Mycoplasma pneumoniae*. *BMJ Case Rep.* 2017;2017:bcr2016217752.
6. Gupta R, Gupta A, Goyal V, et al. *Mycoplasma pneumoniae* associated with rhabdomyolysis and the Guillain-Barré syndrome. *Indian J Chest Dis Allied Sci.* 2005;47(4):305-8.
7. Daxböck F, Brunner G, Popper H, et al. A case of lung transplantation following *Mycoplasma pneumoniae* infection. *Eur J Clin Microbiol Infect Dis.* 2002;21(4):318-22.
8. Alaygut D, Torun bayram M, Kasap B, et al. Rhabdomyolysis with different etiologies in childhood. *World J Clin Pediatr.* 2017;6(4):161-8.
9. Song WJ, Kang B, Lee HP, et al. Pediatric infection presenting with acute cholestatic hepatitis and other extrapulmonary manifestations in the absence of pneumonia. *Pediatr Gastroenterol Hepatol Nutr.* 2017;20(2):124-9.
10. Berger RP and Wadowksy RM. Rhabdomyolysis associated with infection by *Mycoplasma pneumoniae*: a case report. *Pediatrics.* 2000;105(2):433-6.
11. Wakabayashi Y, Nakano T, Kikuno T, et al. Massive rhabdomyolysis associated with influenza A infection. *Intern Med.* 1994;33(7):450-3.
12. Pesik NT and Otten EJ. Severe rhabdomyolysis following a viral illness: a case report and review of the literature. *J Emerg Med.* 1996;14(4):425-8.

Point-of-care Ultrasound to Distinguish Subgaleal and Cephalohematoma: Case Report

Josie Acuña, MD
Srikar Adhikari, MD, MS

University of Arizona, Department of Emergency Medicine, Tucson, Arizona

Section Editor: Shadi Lahham, MD, MS

Submission history: Submitted December 29, 2020; Revision received February 19, 2021; Accepted March 5, 2021

Electronically published April 19, 2021

Full text available through open access at http://escholarship.org/uc/uciem_cpchem

DOI: 10.5811/cpchem.2021.3.51375

Introduction: Cephalohematomas generally do not pose a significant risk to the patient and resolve spontaneously. Conversely, a subgaleal hematoma is a rare but more serious condition. While it may be challenging to make this diagnostic distinction based on a physical examination alone, the findings that differentiate these two conditions can be appreciated on point-of-care ultrasound (POCUS). We describe two pediatric patient cases where POCUS was used to distinguish between a subgaleal hematoma and a cephalohematoma.

Case Reports: We describe one case of a 14-month-old male brought to the pediatric emergency department (PED) with concern for head injury. A POCUS examination revealed a large fluid collection that did not cross the sagittal suture. Thus, the hematoma was more consistent with a cephalohematoma and less compatible with a subgaleal hematoma. Given these findings, further emergent imaging was deferred in the PED and the patient was kept for observation. In the second case an 8-week-old male presented with suspected swelling over the right parietal region. A POCUS examination was performed, which demonstrated an extensive, simple fluid collection that extended across the suture line, making it more concerning for a subgaleal hematoma. Given the heightened suspicion for a subgaleal hematoma, the patient was admitted for further imaging and evaluation.

Conclusion: Point-of-care ultrasound can be used to help differentiate between a subgaleal hematoma and a cephalohematoma to risk-stratify patients and determine the need for further imaging. [Clin Pract Cases Emerg Med. 2021;5(2):198–201.]

Keywords: *Ultrasound; emergency medicine; pediatrics; point-of-care; case report.*

INTRODUCTION

A cephalohematoma is a subperiosteal hematoma. It typically occurs over the parietal bones and is bound by the suture lines, meaning it cannot cross the midline. This restriction distinguishes it from a subgaleal hematoma. A subgaleal hematoma is caused by rupture of the emissary veins between the dural sinuses and scalp veins and is not bound by suture lines. Cephalohematomas generally do not pose a significant risk to the patient and resolve spontaneously.¹ Conversely, a subgaleal hematoma is a rare but more serious condition. Because the hematoma can spread through a large plane with subgaleal hemorrhage, the amount of blood loss can be significant.^{2,3} It is important to distinguish between these two

diagnoses as they can lead to distinct evaluation and treatment pathways. While it may be challenging to make this distinction based on a physical examination alone, the findings that differentiate these two conditions can be appreciated on point-of-care ultrasound (POCUS). We describe two cases of pediatric patients where POCUS was used to differentiate between a subgaleal hematoma and a cephalohematoma. The clinical utility of POCUS in the initial evaluation of these patients who present with an undifferentiated scalp mass are highlighted.

CASE REPORTS

In the first case, a 14-month-old male was brought to the pediatric emergency department (PED) by his mother with

concern for a head injury. The mother described that the patient was playing with his 3-year-old sister several days prior, who pushed him backward, causing him to fall from standing, hitting the right side of his head on the tile floor. She noticed a small bump on the back of his head the following day and brought the child to his pediatrician who did not feel that imaging was indicated at that time and recommended close observation at home. However, the mother described that the region continued to grow and became quite large, covering the majority of the right side of his head.

Upon initial presentation, vitals signs were as follows: temperature (tympanic) 36.8° Celsius; heart rate 156 beats per minute; respiratory rate 24 breaths per minute; blood pressure 121/88 millimeters of mercury (mm Hg); and oxygen saturation 96% on room air. On physical examination, the patient was found to be alert and interactive with no focal neurological deficits. A large, boggy area on the right parietal skull, roughly 10 centimeters (cm) in diameter, was palpated. We performed a POCUS examination to evaluate the area of concern over the patient's head. The POCUS examination revealed a large fluid collection that did not cross the sagittal suture. Thus, the hematoma was more consistent with a cephalohematoma and less consistent with a subgaleal hematoma. Given these findings, further emergent imaging was deferred and the patient was admitted overnight for observation. The next morning, the size of the hematoma remained stable. The risks and benefits of further imaging were discussed with the mother. She opted to proceed with additional imaging given her significant concerns regarding the changes prior to arrival. A computed tomography (CT) was done, which confirmed the presence of a cephalohematoma, without any findings such as a fracture or intracranial bleed. The patient was discharged home shortly after in stable condition.

In the second case, an 8-week-old, otherwise healthy male presented to the PED with suspected swelling over the right parietal region, which was noted by the patient's mother the day prior. The region of swelling had progressed significantly per the mother. No recent trauma was reported. The patient was born via a vaginal delivery, without forcep or vacuum assistance. A hematoma was not noted during the initial hospital stay. Presenting vitals were as follows: temperature (axillary) 36.9°C; heart rate 151 beats per minute; respiratory rate 32 breaths per minute; blood pressure 90/65 mm Hg; and oxygen saturation 96% on room air. On physical examination, the patient was alert and well-appearing. He had a normal neurological exam. There was a 7-cm boggy mass palpated on the right posterior scalp. A POCUS examination was performed, which demonstrated a large, simple fluid collection that extended across the suture line, making it more concerning for a subgaleal hematoma rather than a cephalohematoma. Given the heightened suspicion for a subgaleal hematoma, CT was performed in the PED. The CT showed a subgaleal hematoma, crossing the coronal suture posteriorly. It demonstrated normal appearance of the skull base structures with no findings of fracture or intracranial hemorrhage.

CPC-EM Capsule

What do we already know about this clinical entity?

It is challenging to differentiate a subgaleal from a cephalohematoma based on physical findings alone. This diagnostic distinction is needed to guide management.

What makes this presentation of disease reportable?

The use of point-of-care ultrasound to distinguish between a subgaleal and a cephalohematoma in the pediatric emergency department has yet to be described in the literature.

What is the major learning point?

Point-of-care ultrasound can be used to help differentiate between a subgaleal hematoma and a cephalohematoma.

How might this improve emergency medicine practice?

Point-of-care ultrasound can be used to risk-stratify patients and assist in determining the need for further imaging.

As no known trauma was reported, concern for a bleeding disorder or possible non-accidental trauma was considered. The patient was admitted for further evaluation so that serial head circumferences could be obtained. A skeletal survey was obtained, which showed no acute fractures or osseous abnormalities. Labs were drawn and were overall unremarkable. There were no findings to suggest a coagulopathy. Social work was also consulted. Unfortunately, during the patient's hospital stay it was discovered that he had experienced a non-accidental trauma involving a head injury that resulted in the subgaleal hematoma. The patient had no interval increase in the size of the hematoma.

A linear, high-frequency transducer was used to obtain both sets of images. The first patient had a POCUS examination that revealed an anechoic fluid collection that did not cross the sagittal suture. These findings were consistent with a cephalohematoma (Image 1). The second patient had a POCUS examination that demonstrated an anechoic fluid collection that crossed over the sagittal suture. These findings were consistent with a subgaleal hematoma (Image 2).

DISCUSSION

The findings that differentiate a cephalohematoma from a subgaleal hematoma can be appreciated on POCUS and

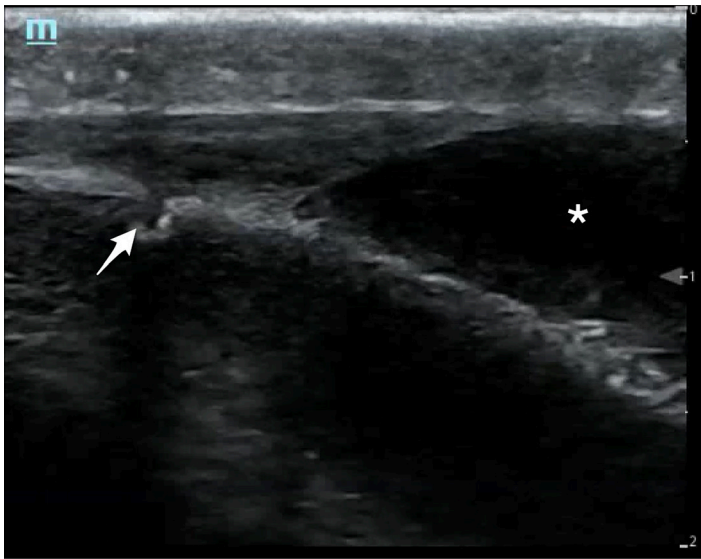


Image 1. Point-of-care ultrasound demonstrating a cephalohematoma (*) that does not cross over the suture line (arrow).

involve a technique easily learned by the emergency physician. A high-frequency linear transducer is used for this exam. Both images should be scanned in at least two perpendicular planes throughout the length of the hematoma to fully view the cranium below. The hematoma will typically be visualized sonographically as a superficial anechoic fluid collection. Deep to the fluid collection, the periosteum and skull are visualized as a thick line, hyperechoic to surrounding structures (Image 3).

The hematoma should be scanned throughout its entirety. While scanning through the hematoma, special attention should be made to the location of the underlying suture lines. The discontinuity is seen as a thin anechoic gap in the cranium.⁴ If the fluid collection crosses over the suture line,

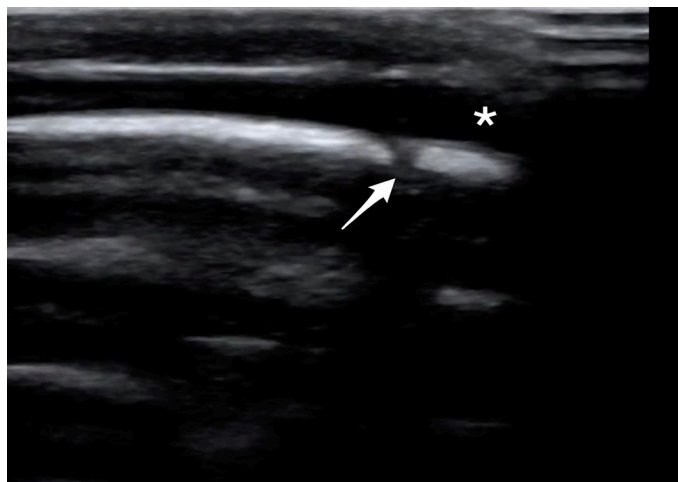


Image 2. Point-of-care ultrasound demonstrating a subgaleal hematoma (*) that is seen to cross over the suture line (arrow).

findings are consistent with a subgaleal hematoma. If the fluid collection does not cross the suture line, results are more consistent with a cephalohematoma.

Cephalohematomas generally do not pose a significant risk to the patient and resolve spontaneously.⁵⁻⁷ Conversely, a subgaleal hematoma is a rare but more serious condition. It describes bleeding in the potential space between the periosteum and the galea aponeurosis. This potential space is quite extensive, allowing bleeding to spread anteriorly to the orbital margins, posteriorly to the nuchal ridge, and laterally to the temporal fascia. Because blood is able to spread through such a large tissue plane, blood loss may be massive before hypovolemia becomes evident.⁸ Early recognition of this diagnosis is key in optimizing the outcomes for these young pediatric patients as they require careful monitoring. Patients usually require observation for frequent assessment of vital signs and head circumference measurements. A coagulopathy evaluation is often initiated as well.⁸ Although optimal imaging for subgaleal hemorrhage is by CT or magnetic resonance imaging, these studies frequently require the pediatric patient to receive some amount of sedation, or may not be readily available at the time of the patient's presentation. Point-of-care ultrasound can be performed rapidly at the bedside and can assist in screening these patients early on, identifying those with high suspicion for subgaleal hematoma and prioritizing imaging.

CONCLUSION

The above cases highlight the clinical utility of POCUS in the initial evaluation of pediatric patients who present with an undifferentiated scalp mass. Point-of-care ultrasound can be used to help differentiate between a subgaleal hematoma and a cephalohematoma. It is possible that these findings could assist in risk-stratifying patients and determining the need for further imaging. The approach

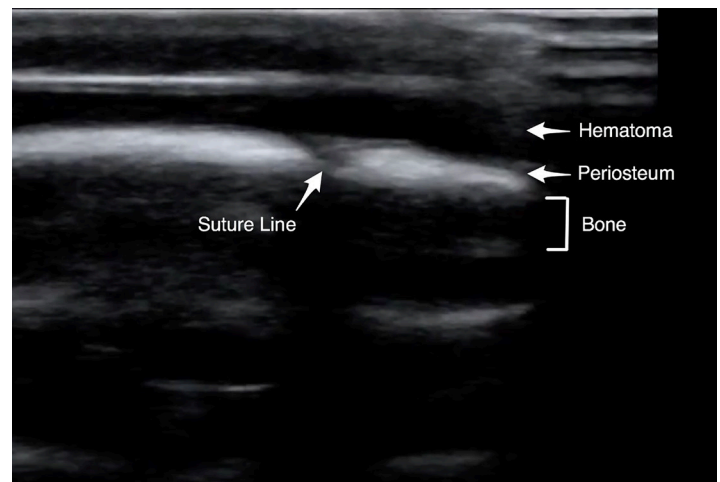


Image 3. A point-of-care ultrasound demonstrating a normal cranium with an open suture line. An overlying hematoma is also identified.

to performing the POCUS examination is straightforward, requiring basic ultrasound technique that can be easily learned by the emergency physician.

The authors attest that their institution requires neither Institutional Review Board approval, nor patient consent for publication of this case report. Documentation on file.

Address for Correspondence: Josie Acuña, MD, University of Arizona, Department of Emergency Medicine, PO Box 245057, Tucson, AZ 85724-5057. Email: jacuna@aemrc.arizona.edu.

Conflicts of Interest: By the CPC-EM article submission agreement, all authors are required to disclose all affiliations, funding sources and financial or management relationships that could be perceived as potential sources of bias. The authors disclosed none.

Copyright: © 2021 Acuña et al. This is an open access article distributed in accordance with the terms of the Creative Commons Attribution (CC BY 4.0) License. See: <http://creativecommons.org/licenses/by/4.0/>

REFERENCES

1. Raines DA, Krawiec C, Jain S. Cephalohematoma. 2020. Available at: <https://www.ncbi.nlm.nih.gov/books/NBK470192/>. Accessed October 1, 2020.
2. Davis DJ. Neonatal subgaleal hemorrhage: diagnosis and management. *CMAJ*. 2001;164(10):1452-3.
3. Vu TT, Guerrero MF, Hamburger EK, et al. Subgaleal hematoma from hair braiding: case report and literature review. *Pediatr Emerg Care*. 2004;20(12):821-3.
4. Okamoto T, Nuri T, Harada A, et al. Cranial suture measurement by 2-point method in ultrasound screening of craniosynostosis. *Plast Reconstr Surg Glob Open*. 2019;7(5):e2225.
5. Choudhary G, Udayasankar U, Saade C, et al. A systematic approach in the diagnosis of paediatric skull lesions: what radiologists need to know. *Pol J Radiol*. 2019;84:e92-111.
6. Glass RB, Fernbach SK, Norton KI, et al. The infant skull: a vault of information. *Radiographics*. 2004;24(2):507-22.
7. Ojumah N, Ramdhan RC, Wilson C, et al. Neurological neonatal birth injuries: a literature review. *Cureus*. 2017;9(12):e1938.
8. Davis DJ. Neonatal subgaleal hemorrhage: diagnosis and management. *CMAJ*. 2001;164(10):1452-3.

Can't Dissolve Me Now: A COVID-19 Provoked Venous Thromboembolism Breaks Through Apixaban: Case Report

Alexander W. Arena, MD
Ahmad Hussein, MD
Ellen J. Kurkowski, DO
Miriam L. Kulkarni, MD

St. John's Riverside Hospital, Department of Emergency Medicine, Yonkers, New York

Section Editor: Scott Goldstein, MD

Submission history: Submitted October 29, 2020; Revision received February 24, 2021; Accepted March 5, 2021

Electronically published April 28, 2021

Full text available through open access at http://escholarship.org/uc/uciem_cpem

DOI: 10.5811/cpem.2021.3.50505

Introduction: Coronavirus disease 2019 (COVID-19) is a multisystem process with a growing evidence of its endotheliopathy effects, with subsequent hypercoagulability states.

Case Report: We present an emergency department case of a COVID-19-provoked deep venous thrombosis and pulmonary embolism without a history of venous thromboembolism (VTE), with extension of the VTE despite adherence to apixaban.

Conclusion: This case demonstrates the importance of further research and protocols for optimal dosage and treatment to prevent worsening VTE in COVID-19 patients. [Clin Pract Cases Emerg Med. 2021;5(2):202–205.]

Keywords: *Case report; COVID-19; endotheliopathy; venous thromboembolism; apixaban.*

INTRODUCTION

By the end of 2019, a novel coronavirus was identified as the pathogen causing a collection of respiratory cases to appear in Wuhan, China. In early 2020 the World Health Organization designated this new disease as coronavirus disease 2019 (COVID-19).¹ Severe acute respiratory syndrome coronavirus 2 (SARS-CoV-2), the virus that causes COVID-19, is a non-segmented, positive-sense ribonucleic acid virus that is part of the family of coronaviruses that includes SARS and Middle East respiratory syndrome due to its high homology.² It is known that SARS-CoV-2 binds via the angiotensin-converting enzyme 2 receptor that is located along intestinal epithelium, vascular endothelium, and type two alveolar cells.³

Initially, it was believed that COVID-19, due to its injurious mechanism to the vascular endothelium, caused acute respiratory distress syndrome (ARDS).⁴ However, studies have shown the hypercoagulability state associated with COVID-19. This is evidenced by the endothelial injury from viral particles inside endothelial cells on autopsy, increased angiogenesis, and

elevated circulating prothrombotic factors such as D-dimer, fibrinogen, and von Willebrand factor.⁵ At the time of writing, there were over 19 million cases of coronavirus throughout the world, with cases in the United States just over three million, and still with a linear rise.⁶

We present a case of a 59-year-old female with a recent history of an active COVID-19 infection who was diagnosed with an acute extension of deep vein thrombosis (DVT) despite a month of anticoagulation therapy for her previously diagnosed pulmonary embolism (PE) and DVT.

CASE REPORT

A 59-year-old female presented to the emergency department (ED) with a chief complaint of right lower extremity pain and swelling. Vital signs at triage were temperature (oral) 98.2° Fahrenheit; heart rate 83 beats per minute; respiratory rate 17 breaths per minute; pulse oximetry 99% on room air; and blood pressure of 135/78 millimeters of mercury (mm Hg). The patient had a hospital admission 40 days prior to presentation for PE and right popliteal DVT with

a positive nasopharyngeal COVID-19 test. She denied a familial history of hypercoagulable states or a personal history of thromboembolic disease prior to her COVID-19 infection. In the ED, she underwent an ultrasound of the right lower extremity. The ultrasound showed the previously seen right popliteal DVT (Image 1), as well as interval development of right mid-femoral DVT (Image 2).

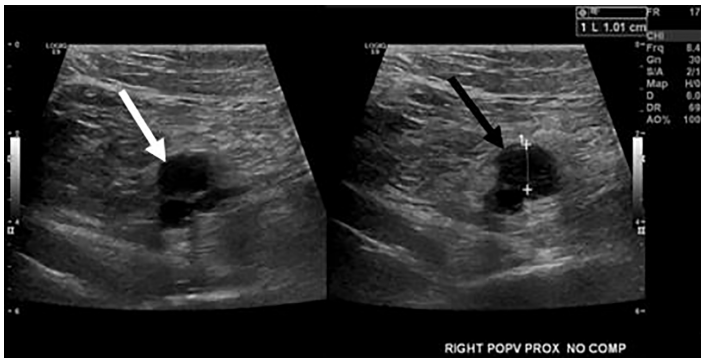


Image 1. Ultrasound image of the popliteal vein on the right side without compression (white arrow) and with compression (black arrow). The popliteal vein was uncompressible, consistent with a venous thrombosis.

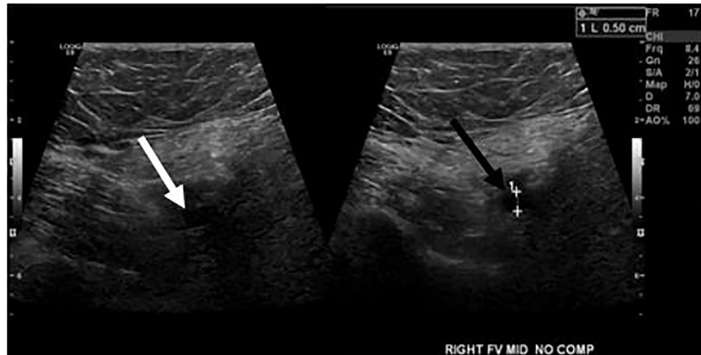


Image 2. Ultrasound image of the femoral vein on the right side without compression (white arrow) and with compression (black arrow). The femoral vein was uncompressible, consistent with a venous thrombosis.

Repeat COVID-19 nasopharyngeal swab testing was negative. Per the patient, when she was discharged previously she was unable to follow up with a hematologist/oncologist due to COVID-19-related lockdown restrictions but maintained compliance with her apixaban at five milligrams (mg) twice per day. Her international normalized ratio (INR) on presentation was 1.36 (reference range: 0.83-1.09) and her D-dimer was 2054 nanograms per milliliter (ng/mL) (0-500 ng/mL). She was admitted for anti-coagulation and started on low molecular weight heparin

CPC-EM Capsule

What do we already know about this clinical entity?

COVID-19 (coronavirus disease 2019) induced endotheliopathy is known to exist with patients afflicted with the virus. As such, they develop deep venous thrombosis and pulmonary embolism.

What makes this presentation of disease reportable?

This is one of the few known cases of extended venous thromboembolism during COVID-19 despite direct oral anticoagulation.

What is the major learning point?

COVID-19 induced endotheliopathy treatment cannot be universal because of potential risk of recurrent venous thromboembolism.

How might this improve emergency medicine practice?

This will improve practice by helping physicians consider using anticoagulation in COVID-19 patients and consider venous thromboembolism as a differential diagnosis.

(LMWH) at 1 mg per kilogram. Throughout her hospital course, she was placed on warfarin with INR values ranging from 0.98 to 4.14. An echocardiogram was performed that showed a normal size, thickness, and function of the left ventricle. In addition, the right ventricle was normal in size and function. The patient was discharged with 12 mg of warfarin daily with hematology follow-up.

The patient had been admitted approximately 40 days prior for submassive bilateral central PE with a right popliteal DVT (Image 3). A detailed report of her previous admission is warranted given the patient’s previous DVT and PE findings with a positive COVID-19 nasopharyngeal swab test.

On ED arrival during the first admission, vital signs at triage were heart rate 120 beats per minute; blood pressure of 150/109 mm Hg; respiratory rate of 22 breaths per minute; and pulse oximetry of 89% on room air. Laboratory studies revealed a 0.89 ng/mL troponin I (0.00-0.05 ng/mL) with the additional following labs: D-dimer 5397 ng/mL and INR of 1.0. The chest computed tomography angiography showed acute bilateral central PE with probable right heart strain with multiple small bilateral peripheral ground glass infiltrates suggestive of COVID-19 pneumonitis. The patient was given

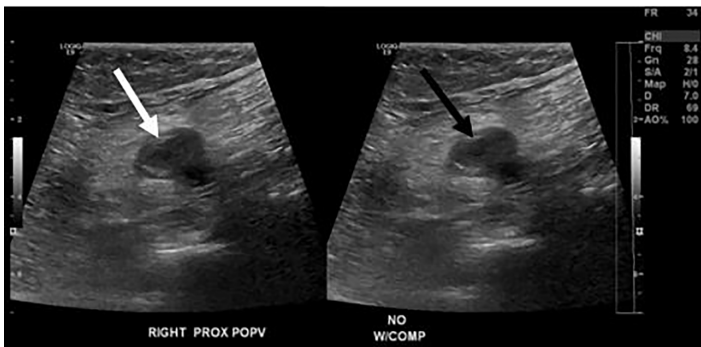


Image 3. Ultrasound image from the patient's previous admission showing the popliteal vein on the right side without compression (white arrow) and with compression (black arrow). The popliteal vein at the time of this presentation was uncompressible, consistent with a venous thrombosis.

at the time a heparin infusion with a bolus based on actual body weight and protocols.

She was admitted to the intensive care unit (ICU) and underwent urgent thrombolysis with thrombectomy. During the procedure, one mg per hour of alteplase was catheter directed while mechanical thrombectomy was performed. The total amount of alteplase received was 24 mg. Repeat angiography approximately 24 hours later showed significant improvement in blood flow to the right and left main as well as segmental and subsegmental pulmonary arteries with significant decrease in central clot burden but with residual central filling defects. An echocardiogram was performed during her admission. However, due to all images being suboptimal in quality, the study was technically limited with "probable normal LV systolic function... right ventricle is not well visualized." During her hospital course, she was placed on 10 mg of apixaban twice a day for one week and transitioned to 5 mg twice a day with which she was discharged on the same schedule. The patient underwent rehabilitation, which included daily exercising. She stated she was compliant with her apixaban medication at 5 mg twice a day.

DISCUSSION

Since the initial stages of COVID-19, our understanding of the disease process has expanded to encompass multiple organ systems. While initially COVID-19 was associated with respiratory failure meeting the Berlin Criteria for ARDS, there has been a disseverment between pulmonary function and gas exchange at the alveolar level. There have been cases where patients with refractory respiratory failure while on mechanical ventilation with shock improved quantitatively after administration of alteplase.⁷ Postmortem examination of 21 individuals with COVID-19 found microthrombi within the alveolar capillaries of 45% of the individuals.⁸ The evidence of dysregulation of the coagulation cascade became apparent when the incidence of VTE was highest within the ICU, sometimes accounting for 69% of cases.⁹

Direct oral anticoagulants (DOAC) can be used prophylactically to reduce the incidence of VTE in patients hospitalized for acute infectious lung diseases.¹⁰ The use of DOACs can stabilize the clot to prevent further embolization from the vessel. However, a persistence of VTE despite anticoagulation with extension of VTE presents as a rare event. A meta-analysis performed to evaluate the rates of treatment failures in those patients treated with oral anticoagulants showed that one of the most common manifestations of treatment failure was the development of VTE with more than half of the patients transitioning to a vitamin K antagonist after DOAC failure.¹¹

There have been numerous publications in regard to endotheliopathy in COVID-19 patients. Recently, a cross-sectional study found that patients in the ICU had significant elevation of markers of endothelial cell and platelet activation compared to non-ICU patients.¹² The patients were noted to have von Willebrand factor antigen concentrations markedly elevated with mortality correlation.¹² In addition, the endotheliopathy process is unique in comparison to other viral infections, namely influenza A virus subtype H1N1 (H1N1). In postmortem studies, alveolar capillary microthrombi were nine times as prevalent in patients with COVID-19 as compared to patients with H1N1.¹³ Furthermore, these studies found evidence of a higher density of intussusceptive angiogenesis as compared to H1N1 patients.¹³

While COVID-19 and H1N1 shared patterns of diffuse alveolar damage, COVID-19 was distinctive in that the thrombi were more diffuse throughout the pulmonary vasculature.¹³ Due to the uncertainty of what the proper dosage is for prophylaxis for VTE in patients with COVID-19, there has been increasing debate that current dosages may not be sufficient to provide adequate prophylaxis.¹⁴ In a randomized, double-blinded study of VTE patients treated with apixaban compared to placebo, recurrent VTE occurred in 8.8% of patients who received placebo compared to 1.7% who received 5 mg of apixaban.¹⁵ Given the low recurrence rate, it is plausible that recurrence of thromboembolic events are mediated by the COVID-19 disease process. While the evidence of COVID-19-induced hypercoagulability exists, there is limited data on how long it lasts. Thus, various institutions have developed protocols suggesting anticoagulation throughout the hospitalization with agents such as LMWH when admitted for COVID-19.

CONCLUSION

Propagation of a known VTE in the setting of oral anticoagulation use is a rare event. This rare case outlines a patient with no prior medical history or risk factors for VTE or PE other than having COVID-19 with an extension of a VTE despite over 40 days of anticoagulation use. This case suggests further research and discussion is needed to properly evaluate the pharmaceutical anticoagulation choice when treating patients with COVID-19 and VTE.

The authors attest that their institution requires neither Institutional Review Board approval, nor patient consent for publication of this case report. Documentation on file.

Address for Correspondence: Alexander Arena, MD, St. John's Riverside Hospital, Department of Emergency Medicine, 967 N Broadway, Yonkers, NY 10701. Email: aarena@riversidehealth.org.

Conflicts of Interest: By the CPC-EM article submission agreement, all authors are required to disclose all affiliations, funding sources and financial or management relationships that could be perceived as potential sources of bias. The authors disclosed none.

Copyright: © 2021 Arena et al. This is an open access article distributed in accordance with the terms of the Creative Commons Attribution (CC BY 4.0) License. See: <http://creativecommons.org/licenses/by/4.0/>

REFERENCES

- World Health Organization. Naming the coronavirus disease (COVID-19) and the virus that causes it. 2020. Available at: [https://www.who.int/emergencies/diseases/novel-coronavirus-2019/technical-guidance/naming-the-coronavirus-disease-\(covid-2019\)-and-the-virus-that-causes-it](https://www.who.int/emergencies/diseases/novel-coronavirus-2019/technical-guidance/naming-the-coronavirus-disease-(covid-2019)-and-the-virus-that-causes-it). Accessed July 20, 2020.
- Jaimes JA, André NM, Chappie JS, et al. Phylogenetic analysis and structural modeling of SARS-CoV-2 spike protein reveals an evolutionary distinct and proteolytically sensitive activation loop. *J Mol Biol.* 2020;432(10):3309-25.
- Farkas J. COVID-19. Available at: <https://emcrit.org/ibcc/covid19/>. Published July 03, 2020. Accessed July 9, 2020.
- Marini JJ and Gattinoni L. Management of COVID-19 respiratory distress. *JAMA.* 2020;323(22):2329-30.
- Singhania N, Bansal S, Nimmatoori DP, et al. Current overview on hypercoagulability in COVID-19. *Am J Cardiovasc Drugs.* 2020;20(5):393-403.
- Dong E, Du H, Gardner L. An interactive web-based dashboard to track COVID-19 in real time. *Lancet Infect Dis.* 2020;20(5):533-4. Erratum in: *Lancet Infect Dis.* 2020;20(9):e215.
- Poor HD, Ventetuolo CE, Tolbert T, et al. COVID-19 critical illness pathophysiology driven by diffuse pulmonary thrombi and pulmonary endothelial dysfunction responsive to thrombolysis. *Clin Transl Med.* 2020;10(2):e44.
- Menter T, Haslbauer JD, Nienhold R, et al. Postmortem examination of COVID-19 patients reveals diffuse alveolar damage with severe capillary congestion and variegated findings in lungs and other organs suggesting vascular dysfunction. *Histopathology.* 2020;77(2):198-209.
- Llitijs JF, Leclerc M, Chochois C, et al. High incidence of venous thromboembolic events in anticoagulated severe COVID-19 patients. *J Thromb Haemost.* 2020;18(7):1743-6.
- Cohoon KP, Sanctis YD, Haskell L, et al. Rivaroxaban for thromboprophylaxis among patients recently hospitalized for acute infectious diseases: a subgroup analysis of the MAGELLAN study. *J Thromb Haemost.* 2018;16(7):1278-87.
- Kajj M, Mathew A, Ramappa P. Treatment failures of direct oral anticoagulants. *Am J Ther.* 2021;28(1):e87-95.
- Goshua G, Pine AB, Meizlish ML, et al. Endotheliopathy in COVID-19-associated coagulopathy: evidence from a single-centre, cross-sectional study. *Lancet Haematol.* 2020;7(8):e575-82.
- Ackermann M, Verleden SE, Kuehnel M, et al. Pulmonary vascular endothelialitis, thrombosis, and angiogenesis in Covid-19. *N Engl J Med.* 2020;383(2):120-8.
- Connors JM and Levy JH. COVID-19 and its implications for thrombosis and anticoagulation. *Blood.* 2020;135(23):2033-40.
- Agnelli G, Buller HR, Cohen A, et al. Apixaban for extended treatment of venous thromboembolism. *N Engl J Med.* 2013;368(8):699-708.

Reversible Total Vision Loss Caused by Severe Metformin-associated Lactic Acidosis: A Case Report

Andrew Koons, DO
Alexandra M. Amaducci, DO
Kenneth D. Katz, MD

Lehigh Valley Health Network, Department of Emergency and Hospital Medicine,
Allentown, Pennsylvania

Section Editor: Anna McFarlin, MD

Submission history: Submitted December 11, 2020; Revision received March 3, 2021; Accepted March 5, 2021

Electronically published May 6, 2021

Full text available through open access at http://escholarship.org/uc/uciem_cpccem

DOI: 10.5811/cpccem.2021.3.51141

Introduction: Metformin is a biguanide used to treat diabetes mellitus (DM). Metformin-associated lactic acidosis (MALA) carries a high mortality and can occur in patients with renal failure from drug bioaccumulation. Reversible vision loss is a highly unusual, rarely reported complication of MALA. We present a case of a patient whose serum metformin concentration was unusually high and associated with vision loss.

Case Report: A 60-year-old woman presented to an outside hospital emergency department with acute vision loss after being found at home confused, somnolent, and hypoglycemic, having last being seen normal two days prior. She reported vomiting and diarrhea during that time and a recently treated urinary tract infection. The visual loss resolved with continuous renal replacement therapy.

Conclusion: This novel case of a patient with Type II DM prescribed metformin and insulin who developed reversible vision loss while suffering from MALA highlights the potential for vision loss in association with MALA. [Clin Pract Cases Emerg Med. 2021;5(2):206–209.]

Keywords: *Metformin; metabolic; diabetic; vision loss; concentrations; case report.*

INTRODUCTION

Metformin-associated lactic acidosis (MALA) is a potentially life-threatening adverse effect of metformin use with the incidence ranging from approximately 10–11 in 100,000 persons per year.^{1,2} Historically, from 1960–2000, it carried a 50% mortality rate; however, the mortality rate has improved to approximately 25–30% since 2000.^{3,4} Reversible vision loss is a highly unusual complication of MALA and has very rarely been reported.^{5–9}

Metformin is a small drug (165 kilodalton) with an oral bioavailability of 50%. Since it is not metabolized by the liver, tubular secretion is the primary elimination route.¹⁰ The mechanism of action of metformin includes affecting the formation of adenosine triphosphate production by decreasing the efficiency of mitochondrial oxidative phosphorylation.¹¹ Another mechanism of metformin includes the inhibition of mitochondrial glycerophosphate dehydrogenase. When this is affected, the balance of cytosolic nicotinamide adenine dinucleotide and hydrogen (NADH) is altered. There is then more NADH available, which decreases lactate to pyruvate conversion.¹² Therefore, lactate can accrue, either as a result of increased metformin ingestion or decreased clearance.¹³ To maintain

acid-base homeostasis, lactate is metabolized by gluconeogenesis or oxidation after converting to pyruvate, and the proton reacts with bicarbonate to form water and carbon dioxide.¹³ The kidney replenishes bicarbonate by reabsorption at the tubular level or net acid secretion.^{14,15} However, once these compensatory mechanisms are exhausted, bicarbonate is depleted, and lactate accumulates. Despite administering intravenous (IV) sodium bicarbonate to replace the depleted bicarbonate stores, the patient may require extracorporeal removal of these substances to aid in combating the effects of metformin by both removing metformin and correcting the acid-base disturbances.

CASE REPORT

A 60-year-old woman with past medical history of diabetes mellitus prescribed insulin and metformin developed total vision loss. She was transported to the emergency department (ED) after being discovered at home confused, somnolent, and hypoglycemic, and last seen normal two days prior. The patient reported vomiting, diarrhea, and a recently treated urinary tract infection (UTI). She was never able to provide an exact history, but her sister reported to the ED staff that she had developed a

UTI treated with an unknown antibiotic approximately one week prior to the current visit. The patient also reported to her sister diarrhea and weakness for one day prior to arrival to ED. Per emergency medical services (EMS), her initial blood glucose was 42 milligrams per deciliter (mg/dL) (reference range: 70-100 mg/dL) and improved after IV administration of 25 grams of glucose in a 50-cubic centimeter prefilled syringe (50% dextrose). No suspicion of surreptitious ingestion of medications was described by either EMS or family.

In the ED the patient's vital signs were as follows: temperature 31.1°C (88°F); heart rate 58 beats per minute; respiratory rate 22 breaths per minute; blood pressure 90/43 millimeters mercury; and oxygen saturation 100% on room air. On physical examination, she was awake but ill-appearing and confused, demonstrating neither any vision perception nor blink reflex. Notable laboratory results are listed in the Table.

Table. Notable lab results for patient presenting with total vision loss.

Test name	Result (reference range)
WBC	28,900 K/cmm (4.0-10.0 K/cmm)
Hgb	10.7 g/dL (11.5-14.5 g/dL),
Hct	36.6% (35.0-43.0%)
Platelet	261,000 (140-350 thou/cmm)
Glucose	216 mg/dL (70-100 mg/dL)
BUN	74 mg/dL (7-18 mg/dL)
Creatinine	9.38 mg/dL (0.40-1.00 mg/dL)
Na ⁺	135 mmol/L (136-145 mmol/L)
K ⁺	5.8 mmol/L (3.5-5.1 mmol/L)
Cl ⁻	93 mmol/L (98-107 mmol/L)
HCO ₃ ⁻	4 mmol/L (21-32 mmol/L)
CPK	285 U/L (less than 201 U/L)
Lipase	857 U/L (73-393 U/L)
Lactate	22.3 mmol/L (0.4-2.0 mmol/L)
Troponin I	0.06 ng/mL (0.00-0.05 ng/mL)
Pro-BNP	3912 pg/mL (0-125 pg/mL)
Prothrombin time	19.2 sec (12.0-14.6 sec)
Initial arterial blood gas on 4 liters nasal cannula	pH <6.94 (7.35-7.45), CO ₂ <20 mmol/L (32-45 mmol/L), pO ₂ 188 mm Hg (83-108 mm Hg)
Acetaminophen, salicylate, ethanol, and toxic alcohol panel	All negative

WBC, white blood cells; K, thousands; cmm, cubic millimeter; Hgb, hemoglobin; g, grams; dL, deciliter; Hct, hematocrit; thou, thousands; mg, milligrams; BUN, blood urea nitrogen; Cr, creatinine; Na⁺, sodium; mmol, millimoles per liter; K⁺, potassium; Cl⁻, chloride; HCO₃⁻, bicarbonate; CPK, creatine phosphokinase; U, units; ng, nanograms; mL, milliliters; pg, picograms; sec, seconds; CO₂, carbon dioxide; pO₂, partial pressure of oxygen; mm Hg, millimeters of mercury.

CPC-EM Capsule

What do we already know about this clinical entity?

Metformin Associated Lactic Acidosis (MALA) is a life-threatening adverse effect of metformin usage with a mortality rate of approximately 25-30%.

What makes this presentation of disease reportable?

This case presents a rare symptom of MALA, reversible vision loss.

What is the major learning point?

In order for emergency physicians to expedite proper critical care, recognizing the common and uncommon signs of MALA is crucial.

How might this improve emergency medicine practice?

By noticing the symptoms of metformin associated lactic acidosis, it will allow emergency physicians to provide best practice patient care.

Rewarming measures, IV fluids, and IV infusions of sodium bicarbonate, vasopressors (norepinephrine and vasopressin), folic acid, thiamine, 4-methylpyrazole, and empiric antibiotics (vancomycin and cefepime) were all administered. The patient received 4-methylpyrazole due to initial diagnostic uncertainty and significantly low bicarbonate concentration; it was discontinued when toxic alcohol ingestion was eliminated. The patient was moved to an intensive care unit (ICU) at a tertiary care referral center.

In the ICU the patient received continuous renal replacement therapy due to anuria. Continuous renal replacement therapy was initiated instead of hemodialysis due to persistent hypotension despite multiple vasopressors. She also was treated with IV sodium bicarbonate given her profound and persistent acidemia. Her vision improved, and she was able to track movement and perform extraocular movements. Eventually she had total resolution of her visual deficits. However, she developed pulmonary edema requiring intubation and, despite some improvement in acidemia and kidney function (Figure), she required maximal vasopressor support including IV infusions of epinephrine, norepinephrine, vasopressin, angiotensin, methylene blue, and steroids.

Admission and subsequent daily serum metformin concentrations measured 57 micrograms per milliliter (µg/mL), 42 µg/mL, and 13 µg/mL (therapeutic 1-2 µg/mL; MALA typically associated with more than 5 µg/mL). Serum liquid

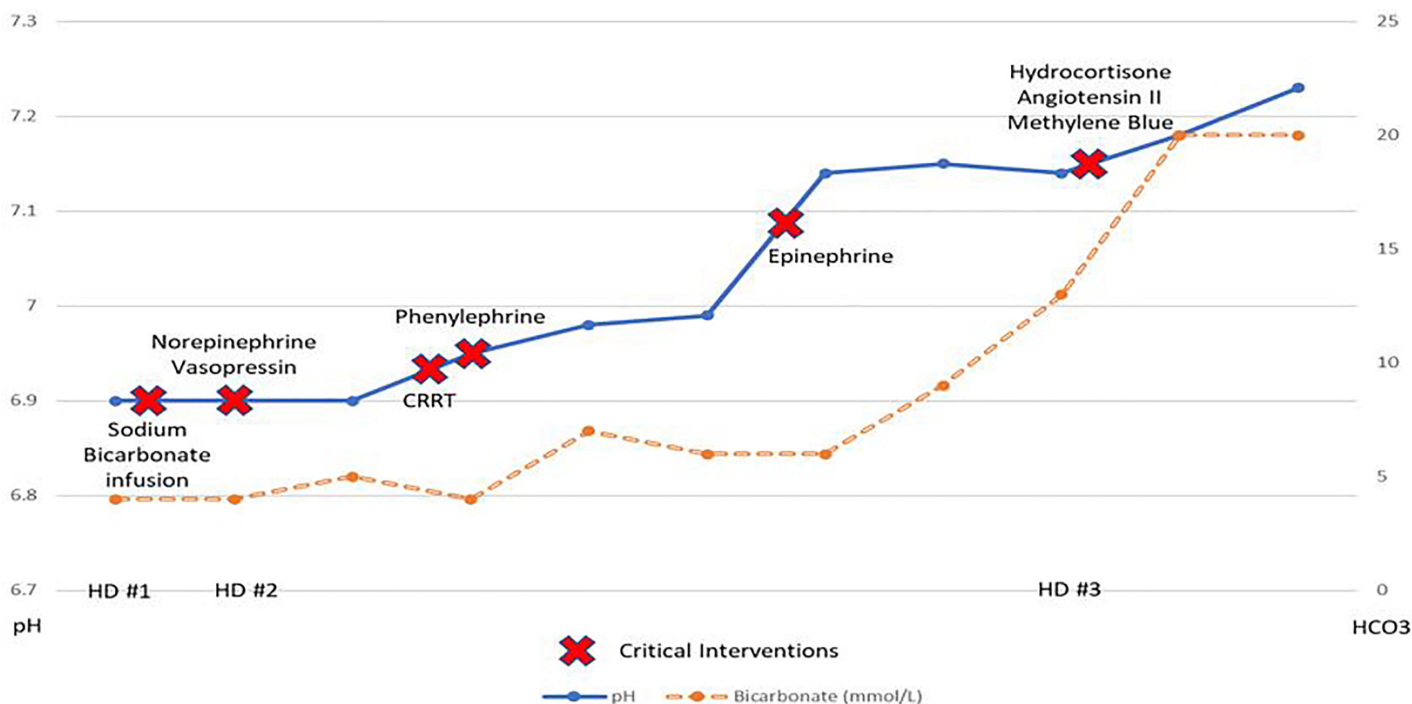


Figure. Laboratory findings of patient during hospital stay. HD, hospital days; CCRT, continuous renal replacement therapy; HCO_3 , bicarbonate.

chromatography and mass spectroscopy toxicology screen did not include metformin concentrations and detected no other xenobiotics. Blood cultures, viral panels, chest radiograph, and chest, abdomen and pelvis computed tomography were unrevealing other than “minimal enterocolitis.” The patient unfortunately expired on hospital day three.

DISCUSSION

Recommended indications (and associated levels of evidence) for extracorporeal treatment for metformin poisoning include the following: lactate concentration greater than 20 millimoles per liter on day one, pH less than or equal to 7.0 (day one), shock (day one), failure of standard supportive measures (day one), and decreased level of consciousness on day two.⁴

Documented vision loss associated with MALA and reversible blindness is very rare, and especially unique to this case is the highest recorded, concurrent metformin concentration (57 $\mu\text{g}/\text{mL}$). Kreshak et al reported a metformin concentration of 28 $\mu\text{g}/\text{mL}$ in a patient with vision loss; the patient fully recovered after hemodialysis.⁵ Cigarran et al described a 54-year-old male patient with fundoscopic examination findings revealing bilateral proliferative diabetic retinopathy with vitreous hemorrhage. This patient also had recovery of vision, but no serum concentration was available.⁶

The proposed mechanism of MALA-induced vision loss is that function of the retinal cells is related to the potential hydrogen (pH).⁵ Studies demonstrate in certain animal species such as fish, tiger, and salamanders that there is a pH-sensitive response to light by the retinal horizontal cells.⁵ These cells are

laterally interconnecting neurons located in the inner nuclear layer of the retina that help integrate input from multiple photoreceptor cells. Animal models demonstrate that this transmission is disrupted in acidosis with a serum pH less than 7.0. If extrapolated to humans, this could explain the reason for loss of vision in the associated severe acidosis.⁶ Sudden vision loss has also been reported previously with both diabetic and alcoholic ketoacidosis. The common denominator among these patients was both a severe metabolic acidosis and reversal of abnormal vision symptoms with correction of serum pH.⁷ This patient had improvement and then resolution of her vision loss as her pH rose above 7.0. The patient’s serum metformin concentration of 57 $\mu\text{g}/\text{mL}$ (therapeutic range 1-2 $\mu\text{g}/\text{mL}$) is the highest reported concentration associated with MALA-induced vision loss.

CONCLUSION

This is a novel case of a patient with Type II diabetes mellitus prescribed metformin and insulin who developed MALA-induced, reversible vision loss with the highest measured, concurrent metformin concentration. Because MALA portends a high mortality, it is crucial for emergency physicians to recognize both the common and uncommon signs and symptoms to expedite proper critical care.

The authors attest that their institution requires neither Institutional Review Board approval, nor patient consent for publication of this case report. Documentation on file.

Address for Correspondence: Kenneth D. Katz, Lehigh Valley Health Network, Department of Emergency and Hospital Medicine, 2545 Schoenersville Road, Bethlehem, PA 18017. Email: Kenneth_D.Katz@lvhn.org.

Conflicts of Interest: By the CPC-EM article submission agreement, all authors are required to disclose all affiliations, funding sources and financial or management relationships that could be perceived as potential sources of bias. The authors disclosed none.

Copyright: © 2021 Koons et al. This is an open access article distributed in accordance with the terms of the Creative Commons Attribution (CC BY 4.0) License. See: <http://creativecommons.org/licenses/by/4.0/>

REFERENCES

1. Richey FF, Sabido-Espin M, Guedes S, et al. Incidence of lactic acidosis in patients with type 2 diabetes with and without renal impairment treated with metformin: a retrospective cohort study. *Diabetes Care*. 2014;37(8):2291-5.
2. Li L, Jick S, Gopalakrishnan C, et al. Metformin use and risk of lactic acidosis in people with diabetes with and without renal impairment: a cohort study in Denmark and the UK. *Diabet Med*. 2017;34(4):485-9.
3. Kajbaf F and Lalau JD. The prognostic value of blood pH and lactate and metformin concentrations in severe metformin-associated lactic acidosis. *BMC Pharmacol Toxicol*. 2013;14:22.
4. Calello DP, Liu KD, Wiegand TJ, et al. Extracorporeal treatment for metformin poisoning: systematic review and recommendations from the Extracorporeal Treatments in Poisoning Workgroup. *Crit Care Med*. 2015;43(8):1716-30.
5. Kreshak AA and Clark RF. Transient vision loss in a patient with metformin-associated lactic acidosis. *Am J Emerg Med*. 2010;28(9):1059.e5-7.
6. Cigarrán S, Rodríguez ML, Pousa M, et al. Transient vision loss in a patient with severe metformin-associated lactic acidosis. *QJM*. 2012;105(8):781-3.
7. Hashmi M, Mahmood SN, Madhwani V, et al. Turning a blind eye: acute vision loss from an unexpected cause. *Am J Respir Crit Care Med*. 2018;197:A6876.
8. Jeon JW, Choi W, Kim HR, et al. Transient blindness in a patient with severe metformin-associated lactic acidosis (MALA). *Electrolyte Blood Press*. 2019;17(1):16-20.
9. Ryu S, Oh SK, Son SH, et al. Reversible acute blindness in suspected metformin-associated lactic acidosis. *J Emerg Med*. 2019;57(5):e153-6.
10. Peters N, Jay N, Barraud D, et al. Metformin-associated lactic acidosis in an intensive care unit. *Crit Care*. 2008;12(6):R149.
11. Andrzejewski S, Gravel SP, Pollak M, et al. Metformin directly acts on mitochondria to alter cellular bioenergetics. *Cancer Metab*. 2014;2:12.
12. Madiraju AK, Erion DM, Rahimi Y, et al. Metformin suppresses gluconeogenesis by inhibiting mitochondrial glycerophosphate dehydrogenase. *Nature*. 2014;510(7506):542-6.
13. Yeh HC, Ting IW, Tsai CW, et al. Serum lactate level and mortality in metformin-associated lactic acidosis requiring renal replacement therapy: a systematic review of case reports and case series. *BMC Nephrol*. 2017;18(1):229.
14. Abu Hossain S, Chaudhry FA, Zahedi K, et al. Cellular and molecular basis of increased ammoniogenesis in potassium deprivation. *Am J Physiol Renal Physiol*. 2011;301(5):F969-78.
15. Jacobs RA, Meinild AK, Nordsborg NB, et al. Lactate oxidation in human skeletal muscle mitochondria. *Am J Physiol Endocrinol Metab*. 2013;304(7):E686-94.

A Traumatic Tick Bite: A Case Report

Daniel Finnin, MD, MBA
Christopher Hanowitz, MD

Albany Medical Center, Department of Emergency Medicine, Albany, New York

Section Editor: Melanie Heniff, MD

Submission history: Submitted December 29, 2020; Revision received February 21, 2021; Accepted March 12, 2021

Electronically published April 19, 2021

Full text available through open access at http://escholarship.org/uc/uciem_cpem

DOI: 10.5811/cpcem.2021.3.50514

Introduction: Human granulocytic anaplasmosis is a tick-borne disease with an increasing incidence associated with morbidity and mortality. Uncertainty remains whether a prophylactic dose of doxycycline is effective in prevention.

Case Report: We present a case of an 80-year-old female with syncope, resultant facial trauma, and fever two weeks after a tick bite for which she received prophylaxis. Workup revealed anaplasmosis, and treatment led to symptomatic improvement.

Conclusion: We review the presenting symptoms, laboratory findings, and treatment of anaplasmosis, as well as give caution about the limitations in prescribing a prophylactic dose of doxycycline following a tick bite. [Clin Pract Cases Emerg Med. 2021;5(2):210–213.]

Keywords: Case report; trauma; anaplasmosis; tick.

INTRODUCTION

Human granulocytic anaplasmosis (HGA) is a tick-borne illness caused by the rickettsial bacterium *Anaplasma phagocytophilum* and transmitted by the *Ixodes scapularis* tick (Image).¹ Symptoms are typically mild resembling viral illness and often self-resolve; however, as many as 3% of victims may have significant morbidity, with up to 1% having meningoencephalitis and 1% mortality.^{1,3} The incidence has been increasing since the disease was first recognized in the mid-1990s. In 2018, the most recent year for which data is available, there were 4008 reported cases in the United States. The highest incidence for the disease is in New York, Connecticut, and Wisconsin.^{3,4} Coinfection with Lyme disease and babesiosis is common as they are transmitted by the same vector.⁵ Studies in affected areas show a seroprevalence of 8.9-36%.¹

We present a case of HGA that may have contributed to a syncopal episode leading to traumatic facial injury in a patient who had taken doxycycline prophylaxis for a tick bite.

CASE REPORT

An 80-year-old female with history of mild chronic obstructive pulmonary disease, mitral valve prolapse, and herniated discs presented to the emergency department (ED) by private vehicle for a facial injury after being struck in the



Image. *Ixodes scapularis* tick.²

face by a dresser drawer. Leading up to the injury she reported feeling lightheaded, and at the point of losing consciousness she attempted to steady her balance by grabbing a dresser, causing it to fall on her chest pinning her against the wall for approximately five hours. She denied significant pain and noted that the top of her scalp superior to the laceration was

insensate. She experienced persistent oozing from the wound and her nose since the injury. A 10-point review of systems was otherwise negative with the exception of fever during the preceding two days to a maximum of 103.3°F on the day of presentation. Notably, she had a tick, which she had removed approximately two weeks prior that was attached for about 24 hours. She was prescribed a one-time dose of 200 milligrams (mg) of doxycycline for Lyme disease prophylaxis, which she had taken on the day of removal by her primary care provider.

On exam, vital signs were notable for heart rate of 102 beats per minute and were otherwise unremarkable. She had a six-centimeter laceration over her left upper forehead with evidence of an open fracture of the frontal sinus on exam with bone fragments visible within the wound. Given the mechanism of injury and her age, we ordered computed tomography of the head, maxillofacial, cervical spine, chest, abdomen, and pelvis, which demonstrated left frontal calvarial fractures. Lab work included the following: a complete blood count; complete metabolic panel; troponin; creatinine kinase; prothrombin time and international normalized ratio; tick panel (Lyme disease immunoglobulin G/immunoglobulin M, *Ehrlichia chaffeensis* polymerase chain reaction [PCR]); *Anaplasma phagocytophilum* PCR; *Babesia microti* PCR; respiratory viral panel; coronavirus disease 2019 PCR; and lactic acid. Notable results are shown in

Table 1. Lab results for 80-year-old patient with history of tick exposure.

Lab	Facility lab range	Admission	Hospital day two
Sodium	135-145 mEq/L	134 mEq/L	133 mEq/L
Potassium	3.4-5.2 mEq/L	4.1 mEq/L	3.3 mEq/L
Chloride	99-109 mEq/L	100 mEq/L	103 mEq/L
Bicarbonate	21-30 mEq/L	24 mEq/L	22 mEq/L
Blood urea nitrogen	7-22 mg/dL	24 mg/dL	13 mg/dL
Creatinine	0.6-1.2 mg/dL	1.77 mg/dL	0.95 mg/dL
Glucose	65-99 mg/dL	124 mg/dL	135 mg/dL
Aspartate transaminase	5-45 IU/L	99 IU/L	
Alanine transaminase	5-60 IU/L	60 IU/L	
Creatine kinase	30-225 IU/L	1495 IU/L	
Troponin I	0-0.04 ng/mL	0.05 ng/mL	0.03 ng/mL
Hemoglobin	11.0-14.7 g/dL	12.1 g/dL	10.0 g/dL
Hematocrit	33.0-44.0%	36.3%	30.6%
White blood cells	4.1-9.3 10 ³ /uL	3.7 10 ³ /uL	1.7 10 ³ /uL
Platelets	130-350 10 ³ /uL	81 10 ³ /uL	40 10 ³ /uL

mEq, milliequivalent; *L*, liter; *mg*, milligrams; *dL*, deciliter; *IU*, international units; *ng*, nanograms; *mL*, milliliter; *g*, grams; *uL*, microliter.

CPC-EM Capsule

What do we already know about this clinical entity?

Human granulocytic anaplasmosis is a tick-borne disease with an increasing incidence associated with morbidity and mortality.

What makes this presentation of disease reportable?

We discuss a rare disease with a presentation including a syncopal episode and traumatic injury found to have findings consistent with anaplasmosis.

What is the major learning point?

This report highlights the classic historical and laboratory findings of anaplasmosis with caution about limitations of doxycycline in Lyme disease prophylaxis.

How might this improve emergency medicine practice?

This case may lead to increased recognition of a rare tick-borne illness to assist with timely diagnosis and treatment.

Table 1. An electrocardiogram demonstrated normal sinus rhythm, and the patient was maintained on the cardiac monitor without event. The patient was treated empirically with tetanus toxoid and ampicillin/sulbactam for coverage of the open sinus fracture. Plastic surgery was consulted for evaluation of the open sinus fracture and facial laceration, which they repaired at bedside in the ED. Intravenous fluids were also administered, and trauma surgery was consulted for admission of the patient to their service for further workup and management.

During the hospital course, the patient continued to spike fevers and had worsening thrombocytopenia, hyponatremia, and leukopenia as demonstrated in Table 1. To further evaluate for a cardiac etiology of her syncope, an echocardiogram was performed, which did not demonstrate any abnormalities. The *Anaplasma phagocytophilum* PCR ultimately returned positive on hospital day two revealing the diagnosis. She was started on doxycycline 100 mg twice daily with improvement of symptoms and hematologic parameters, and she was subsequently discharged on hospital day six.

DISCUSSION

Anaplasmosis typically presents with nonspecific symptoms including fever, chills, headaches, and myalgias with associated leukopenia, thrombocytopenia, and elevated

transaminases.⁶ The diagnosis should be suspected in a patient with a history of tick bite or tick exposure presenting with these signs and symptoms. Symptoms typically manifest a median of nine days after a tick bite, and patients typically present for healthcare evaluation a few days later.³ Diagnosis is confirmed by PCR, buffy coat testing, or serology with a reported sensitivity of 77-80% for both PCR and buffy coat examination.⁶ In our case, the patient was able to relate the history of tick exposure and fever, which helped to guide our workup.

The presentation of HGA as syncope leading to a traumatic event is unusual. There is one report of HGA leading to encephalopathy leading to a motor vehicle crash causing injury.⁷ Another case reported syncope thought to be due to a traumatic splenic rupture caused by HGA requiring resuscitation and surgical intervention.⁸

The specific etiology of syncope in this case is unclear. The suspicion is that HGA could have led to orthostatic hypotension from high fevers leading to increased metabolic demands and dehydration. The patient had an elevated creatinine on presentation that had improved by hospital day two with resuscitation. Human granulocytic anaplasmosis has been previously associated with acute renal failure.¹ A cardiac etiology is also possible and, notably, the patient had a mild elevation in creatinine kinase and troponin I on presentation, with repeat troponin the next day negative. The troponin elevation could have been from rhabdomyolysis, an arrhythmia that was not identified, non-ST elevation myocardial infarction, blunt cardiac injury, or it could have been direct myocyte injury from HGA, which has been previously described.^{9,10}

The treatment of choice is doxycycline, which typically leads to rapid improvement and is continued for 10 days per Infectious Diseases Society of America guidelines. A failure to respond to doxycycline within 48 hours should prompt evaluation for other causes including babesiosis.⁶ Rifampin can be a possible alternative for those with doxycycline intolerance.¹⁰

There is no data regarding the effectiveness of a single 200-mg dose of doxycycline in preventing non-Lyme tick-borne illness. Doxycycline prophylaxis, a single dose of 200 mg, following a tick bite has been recommended for Lyme disease prevention with criteria as shown in Table 2 with a study demonstrating effectiveness of prevention as 87%. But it is as yet unknown whether this would be helpful for

Table 2. Criteria for doxycycline prophylaxis after tick bite.

The tick is identified as an adult or nymph <i>Ixodes scapularis</i> .
Prophylaxis is started within 72 hours of removing tick.
Local rate of infection is $\geq 20\%$.
Doxycycline is not contraindicated.
The tick has been attached for ≥ 36 hours based on time of exposure or engorgement.

HGA or babesiosis, especially given the preferred treatment with atovaquone and azithromycin in babesiosis.^{6,10,11} A prophylactic dose of doxycycline was not sufficient to prevent development of HGA in our patient. The emergency clinician should be aware of the limitations of the prophylactic dose and maintain a high index of suspicion for other tickborne illnesses in endemic areas with the appropriate patient history. Further research is needed to determine whether doxycycline prophylaxis following a tick bite is helpful in preventing HGA, but it did not appear to be helpful in this case.

CONCLUSION

Anaplasmosis is an emerging disease that is increasing in frequency in endemic areas. In the evaluation of fever, hematologic abnormalities, and elevated transaminases with the proper travel history or location, human granulocytic anaplasmosis should certainly be considered as a possible cause. The effectiveness of doxycycline in prophylaxis of HGA has not been evaluated, and the emergency clinician should be aware of its limitations.

The authors attest that their institution requires neither Institutional Review Board approval, nor patient consent for publication of this case report. Documentation on file.

Address for Correspondence: Daniel Finnin, MD, MBA, Albany Medical Center, Department of Emergency Medicine, Mail Code 139, 47 New Scotland Avenue, Albany, NY 12208. Email: finnind@amc.edu.

Conflicts of Interest: By the CPC-EM article submission agreement, all authors are required to disclose all affiliations, funding sources and financial or management relationships that could be perceived as potential sources of bias. The authors disclosed none.

Copyright: © 2021 Finnin et al. This is an open access article distributed in accordance with the terms of the Creative Commons Attribution (CC BY 4.0) License. See: <http://creativecommons.org/licenses/by/4.0/>

REFERENCES

- Bakken JS and Dumler JS. Human granulocytic anaplasmosis. *Infect Dis Clin North Am.* 2015;29(2):341-55.
- Gathany J. *Ixodes scapularis*. 2004. Available at: https://commons.wikimedia.org/wiki/File:Ixodes_scapularis.jpg. Accessed March 6, 2021.
- Ismail N and McBride JW. Tick-borne emerging infections: ehrlichiosis and anaplasmosis. *Clin Lab Med.* 2017;37(2):317-40.
- Centers for Disease Control and Prevention. Anaplasmosis. 2020. Available at: <https://www.cdc.gov/anaplasmosis/stats/index.html>. Accessed June 8, 2020.

5. Pujalte GGA, Marberry ST, Libertin CR. Tick-borne illnesses in the United States. *Prim Care*. 2018;45(3):379-91.
6. Sanchez E, Vannier E, Wormser GP, et al. Diagnosis, treatment, and prevention of Lyme disease, human granulocytic anaplasmosis, and babesiosis: a review. *JAMA*. 2016;315(16):1767-77.
7. Joshi M, Suresh SC, Shaikh IA, et al. Tick-borne trauma: an unusual presentation of anaplasmosis. *Conn Med*. 2013;77(7):417-20.
8. Khan R and Ali A. Non-traumatic splenic rupture in a patient with human granulocytic anaplasmosis and focused review of the literature. *Ticks Tick Borne Dis*. 2018;9(3):735-7.
9. Li SF, Zapata J, Tillem E. The prevalence of false-positive cardiac troponin I in ED patients with rhabdomyolysis. *Am J Emerg Med*. 2005;23(7):860-3.
10. Dumler JS. Anaplasma and Ehrlichia infection. *Ann N Y Acad Sci*. 2005;1063:361-73.
11. Wormser GP, Dattwyler RJ, Shapiro ED, et al. The clinical assessment, treatment, and prevention of Lyme disease, human granulocytic anaplasmosis, and babesiosis: clinical practice guidelines by the Infectious Diseases Society of America. *Clin Infect Dis*. 2006;43(9):1089-134. Erratum in: *Clin Infect Dis*. 2007;45(7):941.
12. Nadelman RB, Nowakowski J, Fish D, et al. Prophylaxis with single-dose doxycycline for the prevention of Lyme disease after an *Ixodes scapularis* tick bite. *N Engl J Med*. 2001;345(2):79-84.

A Case Report of Cardiogenic Syncope Due to Loperamide Abuse: Acute Presentation and Novel Use of Buprenorphine

David J. Betting, MD
James A. Chenoweth, MD
Angela F. Jarman, MD

UC Davis Medical Center, Department of Emergency Medicine, Sacramento, California

Section Editor: Steven Walsh, MD

Submission history: Submitted December 13, 2020; Revision received March 8, 2021; Accepted March 12, 2021

Electronically published May 10, 2021

Full text available through open access at http://escholarship.org/uc/uciem_cpem

DOI: 10.5811/cpem.2021.3.51152

Introduction: Loperamide is a non-prescription anti-diarrheal agent targeting μ -opioid receptors in the intestinal tract. At high doses it crosses the blood-brain barrier, where μ -opioid agonism can cause euphoric effects. Misuse has been increasing for both the euphoric effects and as an alternative treatment for opioid dependence and withdrawal.

Case Report: Here we report the case of a 30-year-old woman presenting with syncope, who was found to have severe myocardial conduction delays in the setting of chronic loperamide abuse.

Conclusion: Treatment with sodium bicarbonate and hypertonic sodium resulted in improvement of her conduction abnormalities. Prior to discharge she was initiated on buprenorphine for her opioid use disorder. [Clin Pract Cases Emerg Med. 2021;5(2):214–217.]

Keywords: *Loperamide; buprenorphine; dysrhythmia; syncope.*

INTRODUCTION

Loperamide is an over-the-counter synthetic opioid used to treat diarrhea. According to the National Poison Data System there has been a 91% increase in the reported nonmedical use of loperamide between 2010–2015.¹ At therapeutic dosing, the drug's effects are mainly targeted to the μ -opioid receptors in the intestinal mucosa. However, due to its relatively inexpensive cost and ease of accessibility there are reports of patients taking up to 800 milligrams (mg) per day for its euphoric effects. Additionally, high-dose loperamide is being used by some with opioid dependence as an over-the-counter treatment for opioid withdrawal symptoms.

Multidrug P-glycoprotein efflux pumps found on the digestive tract and blood-brain barrier (BBB) are normally effective at keeping the drug isolated to the digestive system and out of the brain at therapeutic drug concentrations. At higher doses, however, loperamide can overcome these pumps allowing it to enter the systemic circulation and cross the BBB resulting in stimulation of central nervous system opioid receptors. This can manifest as euphoria and result in significant respiratory

depression.^{2,3} Additionally, there are reports of patients co-administering medications that inhibit the P-glycoprotein pumps (quinidine or piperine, found in black pepper) or slow down metabolism of the loperamide using cytochrome P450 3A4 inhibitors (cimetidine, grapefruit juice) to prolong its half-life.²

In June 2016 the US Food and Drug Administration released a warning regarding loperamide abuse and life-threatening adverse cardiac events.⁴ There have been multiple reports of QRS and QTc prolongation, torsades de pointes (TdP), Takotsubo cardiomyopathy, and cardiac arrest associated with loperamide abuse.^{2,5,6} Despite these warnings there has been a continuing trend toward abuse of loperamide with some touting it as the “poor man’s methadone.” Here we describe a case of cardiac toxicity and the novel subsequent treatment of loperamide abuse with medication for opioid use disorder (MOUD) using buprenorphine/naloxone.

CASE REPORT

A 30-year-old female was brought in by ambulance after a witnessed syncopal event while shopping. Emergency

medical services were called by bystanders, and upon initial evaluation a 12-lead electrocardiogram (ECG) revealed a wide complex tachycardia. The patient initially refused transport despite reporting another syncopal event earlier that day, stating that these episodes were common for her. Eventually, after speaking with medical control at our facility, the patient agreed to come to the hospital for further evaluation. On arrival to the emergency department (ED) the patient was alert and oriented with a heart rate of 77 beats per minute, blood pressure of 135/93 millimeters mercury, respiratory rate of 20 breaths per minute, oxygen saturation of 100% on room air, and a temperature of 36.6°C.

She had no remarkable physical exam findings except for a small forehead abrasion suffered during her recent syncopal event. During the review of her social history the patient reported that she had been taking 50-200 (2 mg) tablets of loperamide every day for a year and a half. Over the prior six months she had been having more frequent syncopal episodes that were preceded by a feeling of heart fluttering. She did not seek care because she had no other symptoms and returned to her baseline immediately after the episodes. She denied prior opioid use but did have a prior history of alcohol abuse. She had been incarcerated a year earlier, during which time she had learned about and started using loperamide for its euphoric effects. She had also recently been briefly hospitalized for bradycardia, hypotension, nausea, vomiting, and diarrhea, possibly from unrecognized loperamide withdrawal. Her initial ECG, performed on arrival in the ED, showed a rate of 77 beats per minute, a tall R wave in aVR, QRS of 194 milliseconds (ms) (reference range: 80-100), and a QTc of 777 ms (350-460) (Image 1).

As treatment for her widened QRS and prolonged QTc interval the patient was given 2 grams (g) of magnesium, 1 g of calcium chloride, and five 50 milliequivalents of sodium bicarbonate boluses, given as intravenous pushes approximately five minutes apart for five doses. She then received a 30-milliliter bolus of 3% hypertonic saline due

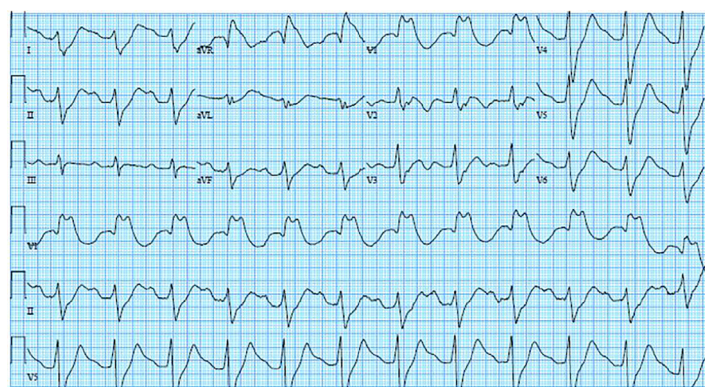

Image 1. Initial emergency department electrocardiogram, prior to treatment initiation of the patient's loperamide ingestion. The patient had a normal heart rate, but widened QRS and QTc with a terminal R wave in aVR.

CPC-EM Capsule

What do we already know about this clinical entity?
Loperamide is a non-prescription anti-diarrheal medication that acts by targeting gastrointestinal μ -opioid receptors to slow gastrointestinal motility.

What makes this presentation of disease reportable?
High doses of loperamide can exert systemic opioid effects and cause life-threatening cardiac conduction abnormalities.

What is the major learning point?
Identification and treatment of drug-induced cardiac conduction abnormalities, and subsequent opioid use disorder management.

How might this improve emergency medicine practice?
Learning to rapidly identify and treat drug-related conduction abnormalities can be lifesaving and treating the opioid use disorder may help prevent reoccurrences.

to concerns that further alkalization could lower her potassium and potentially worsen QTc prolongation (serum electrolyte values were not yet available). Despite these therapies, an ECG performed just prior to admission to the medical intensive care unit (ICU) still showed a QRS of 180 ms and a QTc of 717 ms (Image 2). Her initial electrolyte

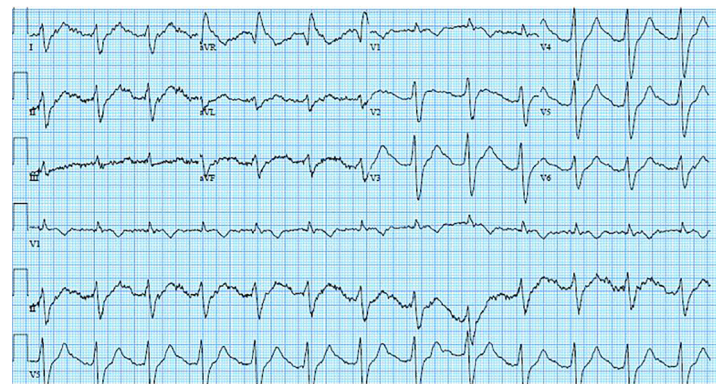


Image 2. Electrocardiogram following treatment with intravenous magnesium, calcium chloride, five boluses of sodium bicarbonate, and a 30 ml bolus of 3% hypertonic saline in the emergency department. Her QRS and QTc remained prolonged and the terminal R wave in aVR is still present.

values on presentation to the ED were as follows: potassium 4.4 millimoles per liter (mmol/L) (reference range: 3.3-5.0 mmol/L); magnesium 1.8 mg/deciliter (dL) (1.5-2.6 mg/dL); and total calcium 9.0 mg/dL (8.6-10.5 mg/dL).

The patient was then placed on an isotonic sodium bicarbonate drip for a day in the ICU with frequent ECG, pH, and electrolyte evaluations. After four days her QRS improved to 142 ms, QTc to 494 ms, and the R wave in aVR was greatly improved (Image 3).

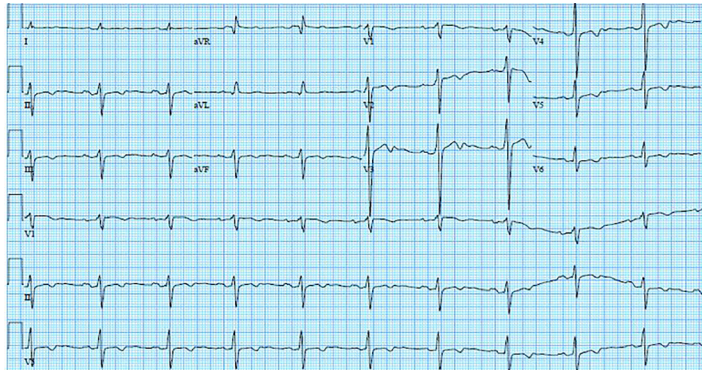


Image 3. In the intensive care unit the patient was started on a sodium bicarbonate drip and frequent electrolyte and pH evaluations. Electrocardiogram prior to patient discharge showed improvement in the QRS and QTc, with near resolution of the terminal R wave in aVR.

Following this clinical improvement, the patient was started on MOUD with buprenorphine 4 mg daily. The day after discharge she returned to the hospital with nausea and vomiting concerning for ongoing withdrawal symptoms. She was found to again have a prolonged QRS of 134 ms and a QTc of 620 ms. Electrolytes were found to be in the normal ranges. Her QRS and QTc improved to 126 ms and 488 ms, respectively, with additional sodium bicarbonate treatment and maintenance of her serum electrolytes. Her nausea and vomiting also improved during her stay, and her buprenorphine was increased to 8 mg daily prior to discharge. On an outpatient visit three days later she had been continuing her buprenorphine with improvement of her withdrawal symptoms and denied any further cravings for loperamide.

DISCUSSION

Here we present a case of a previously healthy young woman with increasing syncopal events preceded by palpitations in the setting of loperamide abuse. It has been shown previously that high doses of loperamide can result in significant toxicity. At high levels, loperamide can overwhelm the P-glycoprotein efflux pumps and cross the BBB resulting in euphoria and respiratory depression, similar to other opioid agonists. Like other opioids, the respiratory depression and mental status changes are dose dependent and

appear to respond to naloxone treatment.⁷ However, unlike most opioids, at high doses loperamide causes antagonism of fast sodium channels and potassium-rectifying channels on cardiac myocytes causing widening of the QRS complex and prolongation of the QTc interval.²

These conduction abnormalities potentiate the risk for life-threatening arrhythmias such as torsades de pointes (TdP). Of note, conduction delays may pose an even greater risk to women, who have longer QTc intervals at baseline; this slower repolarization is thought to be caused by the relative lack of rectifier potassium channels in comparison to men.⁸ The risk of developing TdP is mitigated by tachycardia, which shortens the QTc interval and the risk of an “R on T” phenomenon; thus, this patient’s relatively slow rate combined with significant conduction delay put her at high risk of malignant arrhythmia. Given her presentation, it is likely that the palpitations she described prior to her syncopal events were due to a cardiac arrhythmia.

Prior reports have proposed treatment strategies for the cardiac conduction abnormalities attributed to high levels of loperamide and its metabolites. These include electrolyte repletion (potassium, magnesium, and calcium) to minimize QTc prolongation. Sodium bicarbonate or hypertonic saline can be used to increase the extracellular sodium concentration in an attempt to overcome the sodium channel blockade.^{9,10} Caution must be taken with sodium bicarbonate, however, as alkalinization may lead to decreases in serum potassium and ionized calcium, which could cause further QTc prolongation and other dysrhythmias. Class IB antiarrhythmic drugs, such as lidocaine, can also be used to reduce sodium channel blockade due to their rapid binding and dissociation times compared with other drugs.¹¹ Finally, measures such as lipid emulsion rescue therapy, chemical or electrical pacing, and even extracorporeal membrane oxygenation have been attempted with varying degrees of success.^{2,12}

Although not always thought of as a drug of abuse, loperamide is an opioid agonist and as such carries the risk of physiologic dependence and withdrawal, especially at the high doses seen in our patient. The use of buprenorphine for the treatment of opioid use disorder is well documented, but there is limited data on its use for loperamide.^{13,14} Our patient agreed to start MOUD with buprenorphine/naloxone to help treat her loperamide use disorder, and at her last documented office visit she was continuing treatment with no further cravings for loperamide.

CONCLUSION

The prevalence of loperamide abuse has been increasing, and early recognition and treatment of the resulting cardiac toxicity by emergency physicians can be lifesaving. Syncopal events may be the first indication that a significant cardiac abnormality is present, and cardiac toxicity should be considered when reviewing ECGs on these patients. Patients with widened QRS or prolongation of the QTc interval, in

particular, should be questioned about their medication and drug use including prescription, recreational, and over the counter. Emergency providers must be familiar with the treatment strategies for life-threatening cardiac conduction delays caused by sodium channel blockade. Addressing the underlying loperamide abuse should also be a priority as many people generally consider over-the-counter medications to be safe. This case also reinforces the potential efficacy and safety of buprenorphine in the treatment of non-traditional opioid use disorders.¹³⁻¹⁵

The authors attest that their institution requires neither Institutional Review Board approval, nor patient consent for publication of this case report. Documentation on file.

Address for Correspondence: David Betting, MD, UC Davis Medical Center, Department of Emergency Medicine, 4150 V Street, PSSB 2100, Sacramento, CA 95817. Email: djbetting@ucdavis.edu.

Conflicts of Interest: By the CPC-EM article submission agreement, all authors are required to disclose all affiliations, funding sources and financial or management relationships that could be perceived as potential sources of bias. The authors disclosed none.

Copyright: © 2021 Betting et al. This is an open access article distributed in accordance with the terms of the Creative Commons Attribution (CC BY 4.0) License. See: <http://creativecommons.org/licenses/by/4.0/>

REFERENCES

- Vakkalanka JP, Charlton NP, Holstege CP. Epidemiologic trends in loperamide abuse and misuse. *Ann Emerg Med.* 2017;69(1):73-8.
- Wu PE and Juurlink DN. Clinical review: loperamide toxicity. *Ann Emerg Med.* 2017;70(2):245-52.
- MacDonald R, Heiner J, Villarreal J, et al. Loperamide dependence and abuse. *BMJ Case Rep.* 2015;2015:bcr20152090705.
- Food and Drug Administration. FDA drug safety communication: FDA warns about serious heart problems with high doses of the antidiarrheal medicine loperamide (Imodium), including from abuse and misuse. Available at: <http://www.fda.gov/Drugs/DrugSafety/>. Accessed October 28, 2020.
- Katz KD, Cannon RD, Cook MD, et al. Loperamide-induced torsades de pointes: a case series. *J Emerg Med.* 2017;53(3):339-44.
- Akel T and Bekheit S. Loperamide cardiotoxicity: "a brief review." *Ann Noninvasive Electrocardiol.* 2018;23(2):e12505.
- Friedli G and Haenggeli CA. Loperamide overdose managed by naloxone. *Lancet.* 1980;1(8183):1413.
- Salama G and Bett GC. Sex differences in the mechanisms underlying long QT syndrome. *Am J Physiol Heart Circ Physiol.* 2014;307(5):H640-8.
- Brucoleri RE and Burns MM. A literature review of the use of sodium bicarbonate for the treatment of QRS widening. *J Med Toxicol.* 2016;12(1):121-9.
- McKinney PE and Rasmussen R. Reversal of severe tricyclic antidepressant-induced cardiotoxicity with intravenous hypertonic saline solution. *Ann Emerg Med.* 2003;42(1):20-4.
- Foianini A, Joseph Wiegand T, Benowitz N. What is the role of lidocaine or phenytoin in tricyclic antidepressant-induced cardiotoxicity? *Clin Toxicol (Phila).* 2010;48(4):325-30.
- Parker BM, Rao T, Matta A, et al. Loperamide induced cardiac arrhythmia successfully supported with veno-arterial ECMO (VA-ECMO), molecular adsorbent recirculating system (MARS) and continuous renal replacement therapy (CRRT). *Clin Toxicol (Phila).* 2019;57(11):1118-22.
- Wolfrum LA, Nordmeyer AS, Racine CW, et al. Loperamide-associated opioid use disorder and proposal of an alternative treatment with buprenorphine. *J Addict Med.* 2019;13(3):245-7.
- Toce MS, Chai PR, Burns MM, et al. Pharmacologic treatment of opioid use disorder: a review of pharmacotherapy, adjuncts, and toxicity. *J Med Toxicol.* 2018;14(4):306-22.
- Khazaeli A, Jerry JM, Vazirian M. Treatment of kratom withdrawal and addiction with buprenorphine. *J Addict Med.* 2018;12(6):493-5.

Neonatal Parotitis: A Case Report

Ayush Gupta, MD*†
Tyler Kingdon, MD†
Andrew McKernan, MD†

*Children's Hospital Of New Orleans, Department of Pediatric Emergency Medicine, New Orleans, Louisiana
†Louisiana State University Health Sciences Center, Department of Pediatrics, New Orleans, Louisiana

Section Editor: Joel Moll, MD

Submission history: Submitted January 6, 2021; Revision received March 7, 2021; Accepted March 12, 2021

Electronically published May 6, 2021

Full text available through open access at http://escholarship.org/uc/uciem_cpccem

DOI: 10.5811/cpccem.2021.3.51501

Introduction: Acute suppurative parotitis is a rare finding in the neonate. It is commonly caused by *Staphylococcus aureus*, but other bacterial isolates may be emerging. It is a novel disease for this age group and requires unique management. Only 32 cases of neonatal suppurative parotitis have been described in the English-language literature over the last 35 years.

Case Report: We describe a case of a 14-day-old male who presented to the pediatric emergency department with a 24-hour history of swelling and redness of the right cheek. On examining him, purulent material was seen inside his oral cavity. He was subsequently hospitalized with a diagnosis of neonatal suppurative parotitis and received five days of parenteral antibiotics with improvement in swelling and redness. He was discharged home with oral antibiotics.

Conclusion: Although neonatal suppurative parotitis is rare, it should be suspected in newborns presenting with an erythematous pre-auricular mass with or without any predisposing factors. We describe a rare case of acute suppurative parotitis in a neonate and review the published literature. [Clin Pract Cases Emerg Med. 2021;5(2):218–221.]

Keywords: Parotitis; neonate; purulent.

INTRODUCTION

Acute suppurative parotitis is a rare finding in the neonate. It is commonly caused by *Staphylococcus aureus*, but other bacterial isolates may be emerging. It is a novel disease for this age group and requires unique management. We describe a case and present a literature review of neonatal parotitis based on a 14-day-old male who presented to the pediatric emergency department (ED) with swelling and redness of the right cheek and was diagnosed with acute suppurative parotitis.

CASE REPORT

A 14-day-old male presented to the ED with a 24-hour history of swelling and redness of the right cheek. He had been doing well since birth. His mother noticed that he was crying between his feeds and appeared fussier. The parents denied fever, any kind of rash, or contact with a sick person. The cheek swelling was associated with the skin redness. The baby was born at 38 weeks twin delivery, cesarean section, no complications at birth, and was gaining weight appropriately.

In the ED, the patient was afebrile with normal vitals for his age. On exam, he had right facial redness and crying with palpation of the right cheek (Image 1). The left side was normal. The right tympanic membrane could not be visualized due to edema. Oral mucosa was normal, but purulent material was seen coming out of the mouth. When parotid massage was performed more purulent material was expressed inside the mouth from

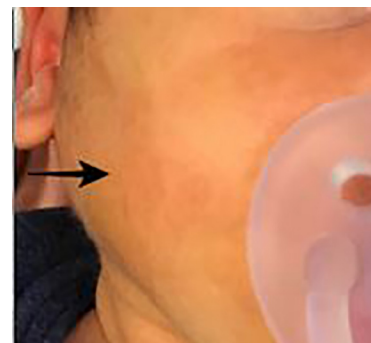

Image 1. Black arrow shows swelling and erythema over the right side of the face in neonate with suppurative parotitis.

the opening of the right Stensen duct. No other significant exam findings were noted. A presumptive diagnosis of acute suppurative parotitis was made.

His laboratory tests showed a normal complete blood count. His comprehensive metabolic panel was also within normal limits except for total bilirubin and direct bilirubin

Table 1. Laboratory test results for neonate with suppurative parotitis.

	Patient's results	Reference range
White blood cell	16,630 / μ L	5,000-20,000 / μ L
Neutrophils	56% (\uparrow)	25-55%
Hemoglobin	13.5 g/dL	12.9-20.5 g/dL
Hematocrit	38%	39-59%
Platelets	450,000 / μ L	150,000-450,000 / μ L
Total bilirubin	16.1 mg/dL (\uparrow)	0.3–1.0 mg/dL
Direct bilirubin	0.7 mg/dL (\downarrow)	> 2 mg /dL
C-reactive protein	0.6 mg/dL	< 1mg /dL
Procalcitonin	0.17 ng/mL	< 0.5ng /ml

μ L, microliter; g, gram; dL, deciliter; mg, milligram; ng, nanogram.

levels (Table 1). A respiratory panel was obtained and was negative. A point-of-care ultrasound of the soft tissue, head, and neck was performed, which showed a swollen, hypervascular right parotid gland likely representing changes of parotitis. There was no evidence of ductal dilation, obvious calcification shadowing, or changes to suggest abscess (Images 2 and 3). This was the main contribution to the diagnosis. Ear nose throat (ENT) and infectious disease specialists were consulted from the ED and agreed with the diagnosis. Even though the baby was afebrile, he received a full septic

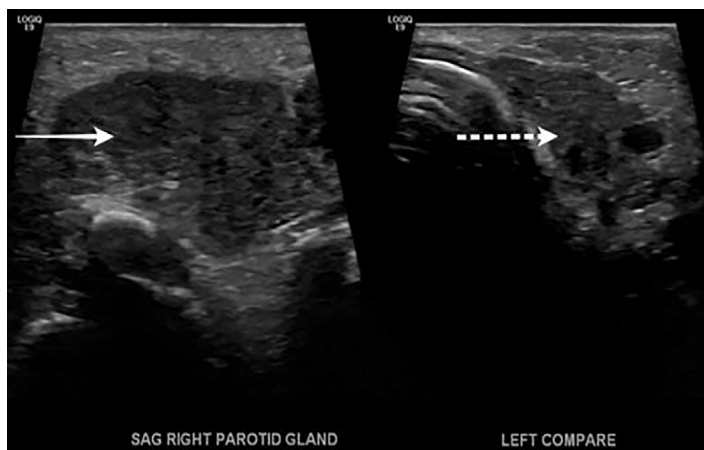

Image 2. Parotid point-of-care ultrasound: swollen right-side parotid gland (solid white arrow) compared to the left-side parotid gland (dotted white arrow).

CPC-EM Capsule

What do we already know about this clinical entity?
Neonatal suppurative parotitis is a rare condition. Diagnosis is made clinically with purulent material exuded from the Stensen duct being a pathognomonic sign.

What makes this presentation of disease reportable?
This patient presented with purulent fluid coming out of his mouth and redness of face. Use of point-of-care ultrasound (POCUS) with clinical findings, prompted early laboratory testing and antibiotics.

What is the major learning point?
Use of POCUS and cultures from purulent fluid help in diagnosis and need for full sepsis workup as suppurative parotitis can lead to bacteremia and meningitis.

How might this improve emergency medicine practice?
Neonatal suppurative parotitis is an uncommon infectious presentation without fever needing prompt recognition and management.

work-up. Because neonatal suppurative parotitis (NSP) causes complications such as bacteremia and meningitis in many cases, it needs to be identified and recognized early. Blood, urine, and cerebrospinal fluid (CSF) analysis was

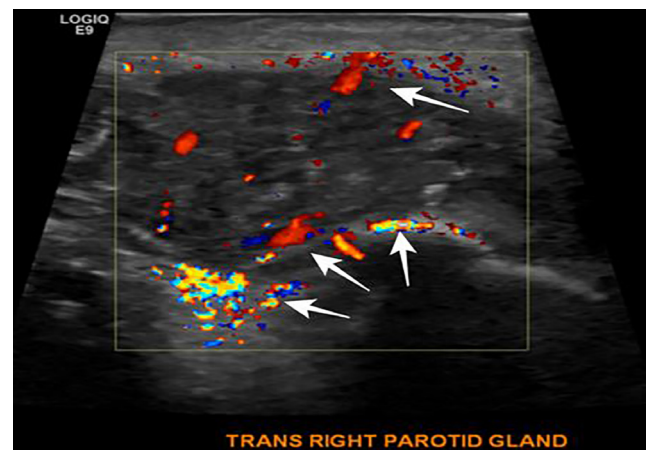


Image 3. Parotid point-of-care ultrasound with Doppler showing increased vascularity (multiple white arrows) around the swollen right parotid gland, confirming parotitis.

Table 2. Results of cerebrospinal fluid analysis shows traumatic lumbar puncture.

	Patient's results	Reference range
Glucose	46 mg/dL	38-175 mg/dL
Protein	142 mg/dL	29-160 mg/dL
Red blood cells	7,301 / μ L (\uparrow)	0-236 / μ L
White blood cells	0 / μ L	0-13 / μ L

μ L, microliters; dL, deciliters; mg, milligrams.

done (Table 2). Meningitis BioFire polymerase chain reaction panel (BioFire Diagnostics, Salt Lake City, UT) was negative. Urinalysis was a catheterized specimen that showed 2+ blood likely due to trauma associated with catheterization but no other findings. Cerebrospinal fluid analysis was normal. Intravenous (IV) antibiotics vancomycin, cefepime, and metronidazole were started to cover staphylococcal, streptococcal, and anaerobic species commonly responsible for causing acute suppurative parotitis. In the hospital, ENT recommended warm compresses and massage of the parotid gland that briefly expressed purulent drainage. However, cultures were not taken due to lack of availability of staff and minor duration of purulent drainage. Blood and CSF cultures did not show any growth, but urine cultures grew 10,000 colony forming units per milliliter *S. aureus*. After 48 hours of IV antimicrobials rapid clinical improvement was noticed. After five days of IV antibiotics, he was transitioned to oral clindamycin for 10 days with a resolution. He was sent home and the parents were advised to follow up with his pediatrician.

DISCUSSION

Neonatal suppurative parotitis is an uncommon disease, with a prevalence of 3.8:10,000 of neonatal admissions in an Italian study by Speigel et al in 2004.¹ The same study reviewed all papers published in the English since 1970, reporting 32 cases.¹ Decembrino et al² reported 16 more cases of NSP described since 2004.

The parotid gland is more frequently infected than the other salivary glands because of its exclusive serous secretion without the bacteriostatic properties of the mucoid component.² Although acute parotitis may affect normal healthy neonates, it seems to be more common in premature infants with low birth weight.³⁻⁵ This is presumptively related to a higher risk for dehydration, which may reduce salivary secretion causing salivary stasis. This stasis promotes bacterial ascent along the salivary duct.² Bacterial seeding of the parotid gland can also occur hematogenously.³ Other risk factors implicated in parotitis are nasogastric intubation, sepsis, structural glandular abnormalities, cephalic or facial trauma, and immunodeficiency/immunosuppression.³ Transient immunoglobulin A deficiency is found in neonates, which affects mucociliary clearance and can lead to head and neck

infections including rhinosinusitis, otitis media, mastoiditis, adenotonsillitis, and parotitis.⁶

Staphylococcus aureus is the most common pathogen isolated. Less-frequent agents are other Gram-positive cocci (*Streptococcus pyogenes*, *Streptococcus agalactiae*, *Streptococcus viridans*), Gram-negative bacilli (*Escherichia coli*, *Klebsiella pneumoniae*, *Pseudomonas aeruginosa*), and rarely anaerobic agents (*Peptostreptococcus* species, *Bacteroides melaninogenicus*, *Fusobacterium nucleatum*, *Prevotella* species).^{2,4-7} Although theoretically anaerobes are far more common in the normal oral flora, outnumbering aerobes by 10-100 times,⁸ most cases are still caused by *S. aureus*.

The diagnosis is based on clinical findings. In most cases NSP was unilateral and the most prevalent sign at the time of admission was swelling with or without redness of the parotid region. Fever is found in less than half of the cases. Bacteremia is present in up to 90% of cases and there can be meningitis associated with 33%. Purulent material exuded from Stensen's duct is a pathognomonic sign of NSP.^{1,9}

The differential diagnosis includes infectious and non-infectious etiologies. Infectious causes include lymphadenitis, cellulitis, soft-tissue abscess, osteomyelitis, buccinator muscle infection, and parotitis.^{2,3,10,11} Cellulitis-adenitis syndrome represents another possible focal manifestation of late-onset group B *Streptococcus* (GBS) infection, which is more common than parotitis, with an incidence estimated at 4%.⁷ Similarly to NSP, it presents with inflammatory signs typically involving unilateral facial or submandibular regions, which can be hard to distinguish from parotitis.^{11,12} Non-infectious etiologies of NSP include facial trauma, subcutaneous fat necrosis, and tumors such as lymphangiomas, hemangiomas, lipomas, or adenomas.²⁻⁵

Ultrasound findings can confirm the diagnosis, as in our case. Ultrasound can also be useful to identify soft tissue abscesses requiring surgical intervention, or non-infectious etiologies.¹³ Laboratory results are usually nonspecific, with leukocytosis and neutrophilia the most predominant findings. The serum amylase level is elevated in only a few cases, probably due to the immaturity of this salivary isoenzyme activity in newborns, rendering it unhelpful to the diagnosis.¹ Cultures obtained from blood and purulent material from Stensen's duct are essential for accurate diagnosis and therapy guidance. Lumbar puncture for CSF analysis should ideally be performed to safely determine adequate antibiotic therapy and its duration, as well as for outcome and follow-up purposes.^{9,10,13}

The diagnosis of NSP in our patient was made based on clinical findings and with ultrasonography confirmation. After collecting the blood cultures, urine cultures, and CSF cultures, empiric IV antibiotic therapy with vancomycin and cefepime was immediately started. This covered the most common pathogens such as *S. aureus*, other Gram-positives such as GBS, and Gram-negatives. Based on the possible anaerobic causes, metronidazole was added. Most authors recommend starting therapy with an association of an anti-staphylococcal agent and

an effective antibiotic against Gram-negatives, with adjustments after the results from the cultures are available.^{1,2,5,10} The increase of methicillin-resistant staphylococci may require the use of vancomycin. In the presence of an anaerobic cause, the treatment may include a combination of metronidazole and a macrolide or penicillin and β -lactamase inhibitor (clavulanate).³ A period of 7-10 days of this therapy appears to be adequate^{2,3} and generally leads to clinical improvement within the first 48 hours.

Most cases are managed conservatively, with prompt antibiotic therapy and adequate hydration essential for a good outcome. Surgical intervention is reserved for the rare cases with an inadequate response to medical therapy or for those with organized abscesses.^{13,14} The infection has a good prognosis, rare recurrence, and complications (facial palsy, fistula, mediastinitis and extension to the external auditory canal).¹⁴

CONCLUSION

Although neonatal suppurative parotitis is rare, it should be suspected in newborns presenting with an erythematous pre-auricular mass with or without any predisposing factors. *S. aureus* is the most common pathogen isolated from infants with NSP. Exudate culture should be sent for testing. Most patients can be treated conservatively, provided that the empiric antibiotic treatment covers the causative agents according to the local sensitivity pattern and is started early. The prognosis of the disease is generally excellent.

Patient consent has been obtained and filed for the publication of this case report.

Address for Correspondence: Ayush Gupta, MD, Tulane University School of Medicine, Department of Emergency Medicine, 200 Henry Clay Avenue, New Orleans, LA 70118. Email: Ayush.gupta@lcmchealth.org.

Conflicts of Interest: By the CPC-EM article submission agreement, all authors are required to disclose all affiliations, funding sources and financial or management relationships that could be perceived as potential sources of bias. The authors disclosed none.

Copyright: © 2021 Gupta et al. This is an open access article distributed in accordance with the terms of the Creative Commons Attribution (CC BY 4.0) License. See: <http://creativecommons.org/licenses/by/4.0/>

REFERENCES

1. Spiegel R, Miron D, Sakran W, et al. Acute neonatal suppurative parotitis: case reports and review. *Pediatr Infect Dis J*. 2004;23(1):76-8.
2. Decembrino L, Ruffinazzi G, Russo F, et al. Monolateral suppurative parotitis in a neonate and review of literature. *Int J Pediatr Otorhinolaryngol*. 2012;76(7):930-3.
3. Özdemir H, Karbuz A, Ciftçi E, et al. Acute neonatal suppurative parotitis: a case report and review of the literature. *Int J Infect Dis*. 2011;15(7):e500-2.
4. Ayala Curiel J, Galán del Río P, Poza del Val C, et al. Parotiditis aguda supurativa neonatal [neonatal acute suppurative parotitis]. *An Pediatr (Barc)*. 2004;60(3):274-7.
5. Nso Roca AP, Baquero-Artigao F, García-Miguel MJ, et al. Parotiditis aguda neonatal por *Streptococcus agalactiae* [Acute neonatal parotitis due to *Streptococcus agalactiae*]. *An Pediatr (Barc)*. 2007;67(1):65-7.
6. De Vincentiis GC, Sitzia E, Bottero S, et al. Otolaryngologic manifestations of pediatric immunodeficiency. *Int J Pediatr Otorhinolaryngol*. 2009;73 Suppl 1:S42-8.
7. Gilbey P, Bretler S, Even-Tov E, et al. Accidental out-of-hospital delivery complicated by acute neonatal parotitis: case report and a review of the literature. *Int J Pediatr Otorhinolaryngol Extra*. 2011;6:6385-7.
8. Yagupsky P and Moses S. Purulent parotitis in the newborn. *Harefuah*. 1982;102:154-5.
9. MacDorman MF, Minino AM, Strobino DM, et al. Annual summary of vital statistics--2001. *Pediatrics*. 2002;110(6):1037-52.
10. Walter C, Noguera A, Gene A, et al. Group B streptococcal late-onset disease presenting with parotitis. *J Paediatr Child Health*. 2009;45(12):764-6.
11. Herrera Guerra AA and Osguthorpe RJ. Acute neonatal parotitis caused by *Streptococcus pyogenes*: a case report. *Clin Pediatr (Phila)*. 2010;49(5):499-501.
12. SolerPalacín P, Monfort Gil R, Castells Vilella L, et al. Group B Streptococcus late-onset disease presenting as cellulitis-adenitis syndrome. *An Pediatr (Barc)*. 2004;60:75-9.
13. Dias Costa F, Ramos Andrade D, Cunha FI, et al. Group B streptococcal neonatal parotitis. *BMJ Case Rep*. 2015;2015:bcr2014209115.
14. Ismail EA, Seoudi TM, Al-Amir M, et al. Neonatal suppurative parotitis over the last 4 decades: Report of three new cases and review. *Pediatr Int*. 2013;55(1):60-4.

When the Red Tide Rolls In: A Red Tide Associated Angioedema Case Report

Sarah Rabinowitz, BS, BFA
Joshua J. Solano, MD

Charles E. Schmidt College of Medicine, Department of Emergency Medicine, Boca Raton, Florida

Section Editor: Rick A. McPheeters, DO

Submission history: Submitted January 26, 2021; Revision received March 4, 2021; Accepted March 12, 2021

Electronically published April 23, 2021

Full text available through open access at http://escholarship.org/uc/uciem_cpccem

DOI: 10.5811/cpcem.2021.3.51920

Introduction: Histamine-mediated angioedema is a potentially life-threatening reaction following exposures that incite mast cell activation. In Florida, red tides are a frequent phenomenon caused by overgrowth of the harmful algae species *Karenia brevis*, which contain environmentally detrimental brevetoxins. Even in low concentrations, brevetoxins can cause disease in humans through inducing histamine release. We report the first documented case of angioedema associated with red tide exposure.

Case Report: A 52-year-old-male presented with severe angioedema encompassing both lips within a few hours after exposure to red tide algae. Other symptoms included voice changes and difficulty swallowing. Laboratory findings revealed complement factors that were within reference range, which ruled out a bradykinin-mediated pathology and supported the diagnosis of histaminergic angioedema. Symptoms resolved after 24 hours in the intensive care unit under management with epinephrine, diphenhydramine, methylprednisolone, and famotidine.

Conclusion: In coastal regions, red tide algae should be recognized as a rare cause of acute angioedema. Emergency management of histamine-mediated angioedema should focus on preventing respiratory compromise with frequent airway monitoring and treatment with steroids, antihistamines, and epinephrine. [Clin Pract Cases Emerg Med. 2021;5(2):222–225.]

Keywords: Case report; angioedema; red tide; harmful algae; brevetoxin.

INTRODUCTION

Angioedema is a localized, non-pitting edema of the deep dermis and submucosal tissues commonly affecting the eyelids, lips, tongue, and larynx as a result of vasodilation and increased vascular permeability mediated by histamine or bradykinin.¹ It can be acquired, hereditary, or idiopathic and have both acute and chronic presentations.^{1,2} Emergency departments (ED) in the United States treat over 100,000 cases of angioedema annually.^{1,3} Of the different subtypes, acute histamine-mediated angioedema following allergic exposure is the most common, comprising 40-70% of all cases.^{1,2} There are also various environmental factors that can induce histamine release and cause angioedema.²

In Florida, blooms of the red tide algae *Karenia brevis* mainly occur along the Gulf of Mexico, affecting the

southwest and northwest coasts of Florida.⁴ The algae blooms in response to increased macro-nutrients in coastal waters, and contributing factors include both natural ecological processes and artificial sources, such as sewage, industrial waste, and land runoffs.^{4,5} Red tides are considered “harmful algae blooms,” as exposure is highly toxic to marine life.⁴ Historically, significant blooms occurred infrequently; however, the Florida Fish and Wildlife Conservation (FWC) Research Institute has reported blooms with high concentrations of *K. brevis* annually since 2014 along the west coast of Florida.⁶ To date, there had been no known documented cases of angioedema induced by red tide exposure. We report one of the first cases of histamine-mediated angioedema occurring after exposure to red tide algae during a rare, east coast bloom.

CASE REPORT

A 52-year-old man with a past medical history of gastroesophageal reflux disease, chronic pancreatitis, chronic pain syndrome, hypertension, anxiety and depression presented to the ED for evaluation of worsening swelling in his upper and lower lips onset three hours prior to arrival. His symptoms began with spontaneous right lower lip swelling that quickly progressed to encompass both lips and caused mild voice changes. Review of systems was negative for difficulty breathing, difficulty swallowing, rashes, nausea, vomiting, diarrhea, and abdominal pain.

The patient denied personal and family history of angioedema reactions, prior red tide exposure, known food or drug allergies, seafood or nut intake, and new medication exposure. He reported no changes to his medication regimen and endorsed compliance with his bupropion, pantoprazole, and methadone. The patient had started taking vitamins B12 and D regularly two days prior and had taken these vitamins in the past without issue. He did not recall any insect bites or stings and had been desensitized to bee stings in childhood. The patient's only notable exposure was to an outbreak of red tide algae at a Palm Beach County beach that morning just prior to symptom onset.

Vital signs showed that the patient was afebrile with a blood pressure of 163/119 millimeters mercury, heart rate of 68 beats per minute, respiratory rate of 15 breaths per minute, and pulse oximetry of 94% on room air. Physical exam was notable only for isolated, severe bilateral lip edema (Image) not involving the soft palate, tongue, and uvula.

The patient was placed on two liters per minute of oxygen via nasal cannula, which improved his oxygen saturation to 96%. Initial doses of diphenhydramine, methylprednisolone, and famotidine were administered with no improvement. While still in the ED, his edema progressed, and the patient began to experience difficulty swallowing. Intramuscular epinephrine was then administered with only mild improvement two hours later. He was diagnosed with angioedema of unclear etiology and admitted to the intensive care unit (ICU) for further management. Labs were significant for leukocytosis at a white blood cell count of 10.3 thousand cells per microliter (thousand/mcL) (reference range: 5.0-10.0

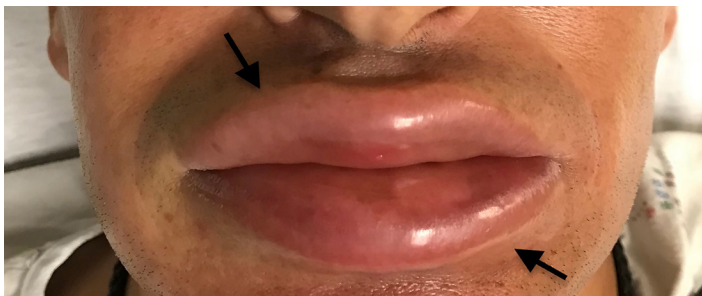

Image. Impressive angioedema diffusely encompassing both lips (arrows).

CPC-EM Capsule

What do we already know about this clinical entity?

Angioedema is an inflammation of the deeper dermis and subcutaneous tissues. It can be hereditary or acquired by exposure to allergens, toxins, or physical insults

What makes this presentation of disease reportable?

While red tides are known to cause respiratory disease, this is the first reported case of histaminergic angioedema associated with red tide algae exposure.

What is the major learning point?

Exposure to brevetoxins released from red tide algae may trigger angioedema reactions through mast cell activation and histamine release.

How might this improve emergency medicine practice?

Clinicians should be aware of local environmental triggers of histaminergic angioedema to rapidly identify and initiate appropriate treatment.

thousand/mcL) with increased neutrophils. Immunology/serology showed no abnormalities: C4 complement level of 37 milligrams per deciliter (mg/dL) (16-38 mg/dL), C1q Qn of 12.3 mg/dL (11.8-23.8 mg/dL), C1 esterase inhibitor 39 mg/dL (8-40 mg/dL) and C1 ester inhibitor function of 111 (reference range: greater than 67).

In the ICU, the angioedema improved after additional doses of diphenhydramine, methylprednisolone, and famotidine. He did not require higher oxygen supplementation or intubation. Repeat complete blood count in the morning showed resolution of the leukocytosis. With the angioedema subsided, the patient had no difficulty breathing with an oxygen saturation of 98% on room air. He felt well enough the next day for discharge and did not experience symptom recurrence over two years.

DISCUSSION

Brevetoxins are lipophilic neurotoxins found in the red tide algae *K. brevis*.⁵ Toxic exposure causing illness in humans mainly occurs through toxin inhalation and consumption of contaminated water and shellfish.^{4,5} Brevetoxins become aerosolized when the force of crashing waves lyses the cells

of the *K. brevis*.⁴ The brevetoxin aerosols carried by the wind can travel up to a mile inland from their source.⁷ Their lipid solubility and small particle size enable them to penetrate skin, mucosa, and cell membranes and travel through the respiratory tract.⁸ In animal model studies, it has been demonstrated that once inside the body brevetoxins are able to disrupt voltage-gated sodium channels, causing an influx of sodium and subsequent depolarization with acetylcholine release.^{8,9} Consequently, this can trigger mast cell degranulation, cell apoptosis, and induce the release of inflammatory cytokines and histamine.⁸

While there are no documented cases of angioedema induced by red tides, numerous reports exist of respiratory, gastrointestinal, and neurological illnesses caused by brevetoxins.^{4,5,8,9} Studies previously found that red tide blooms are positively correlated with an increased incidence of ED visits for asthma exacerbations and respiratory illnesses in coastal areas.^{5,8,10}

Our patient came in with severe lip angioedema of unclear etiology. His only significant novel exposure was to the outbreak of red tide algae at the beach on the same morning he developed symptoms. The October 2018 red tide bloom to which our patient had been exposed was the first red tide outbreak to affect the east coast of Florida in the last decade.^{6,11} According to data collected by the research institute of the Florida Fish and Wildlife Conservation Commission (Figure), the patient may have been exposed to medium to low concentrations of *K. brevis*.^{6,11} The presence of *K. brevis* in any concentration has the potential to cause symptoms in humans.⁵⁻⁷

The patient's symptoms developed rapidly after a brief exposure and subsided within 24 hours, a clinical picture

consistent with other reports of brevetoxin-induced illness, as well as non-urticarial histaminergic angioedema.^{1,2,8,9} The pathophysiology of angioedema and brevetoxin-induced illness described in the literature suggests a potential link, as both involve direct mast cell activation with histamine release and follow similar disease timeline.^{2,8,9}

Acute histaminergic angioedema is the most common form of angioedema.¹ One subtype of histaminergic angioedema is allergic angioedema, which often occurs after exposure to allergens or environmental triggers.^{1,2} It follows a type 1 hypersensitivity reaction process with immunoglobulin E (IgE) as the mediator of histamine release from mast cells and basophils.² Less commonly, a non-allergic, non-IgE mediated form of histaminergic angioedema results from the direct activation of mast cells following exposure to similar triggers, physical stimuli, drugs, infections, and idiopathic events.² Aside from the mechanism of mast cell activation, non-allergic and allergic histaminergic angioedema involve the same inflammatory reactions and clinical manifestations.^{2,12}

Clinically, histamine-mediated angioedema presents rapidly within 60 minutes of an inciting exposure and resolves 24-48 hours later.^{1,2} Similar to anaphylactic reactions, symptoms include hypotension, tachycardia, urticaria, flushing, pruritus, bronchospasm, wheezing, laryngeal edema, nausea, vomiting, and abdominal pain.^{1,2} Airway compromise from laryngeal edema can manifest as stridor, voice changes, and difficulty swallowing.^{1,2} It is important to note that both pathways of histaminergic angioedema can present with or without urticaria and, therefore, absence of urticaria does not exclude the diagnosis.^{1,2} The diagnosis is clinical.^{1,2} Patients are often hemodynamically stable, but the systemic vasodilation can induce hypovolemic shock and respiratory distress.²

Routine workup may show leukocytosis, as seen in our case.¹ Acute histamine-mediated angioedema can have normal or elevated serum tryptase levels, but this is not routinely obtained.¹ Otherwise, in the ED setting there are no specific laboratory findings that will indicate the diagnosis and guide management. Unlike in bradykinin-mediated angioedema, the levels and function of complement proteins (C4, C1q, C1 esterase inhibitor) are normal in histamine-mediated angioedema.^{1,2,12} Management involves airway preservation, epinephrine, steroids, and histamine H1/ H2 receptor blockers.^{1,2} In the ED setting, improvement of the angioedema in response to these treatments supports the diagnosis of histamine-mediated angioedema, even in cases without obvious urticaria or allergic manifestations.^{1,2}

This is essential to recognize, as bradykinin-mediated angioedema subtypes follow along different pathways involving complement factor deficiencies; thus, they do not respond to treatment with steroids, epinephrine, and antihistamines, have higher rates of reoccurrence, and worse clinical outcomes.^{1,2} Therefore, early identification of a histaminergic process is crucial for emergency management, as treatment of bradykinin-mediated angioedema focuses

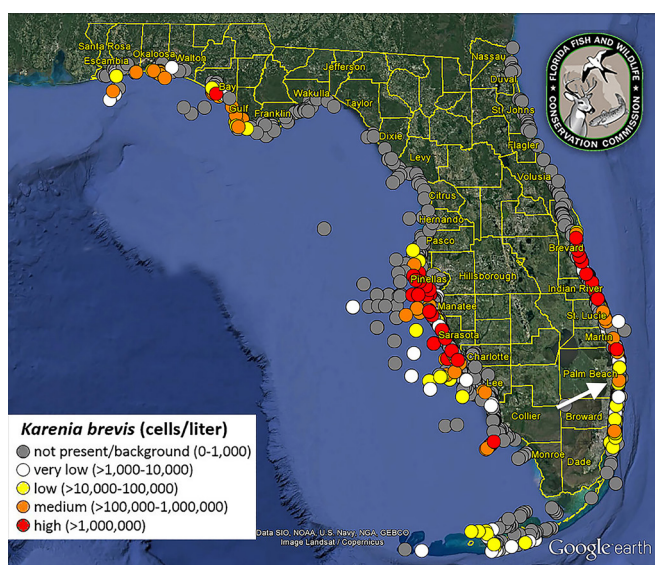


Figure. Map showing the statewide *Karenia brevis* concentrations October 1-31, 2018. Location of patient's red tide exposure (white arrow). Reprinted with permission from the research institute of the Florida Fish and Wildlife Conservation Commission.¹¹

on correcting the underlying complement deficiencies.¹ Delays in initiating appropriate therapeutic intervention can become disastrous in the setting of worsening shock and respiratory compromise.^{1,2}

Lastly, it is important to address the likelihood of the patient's medications as underlying causes of his angioedema. There have been several case reports of urticarial angioedema occurring within the first four weeks after initiating bupropion therapy.^{13,14} Unlike the cases described in the literature, our patient had been taking a consistent dose of bupropion for longer than four weeks. Furthermore, his bupropion was continued throughout admission with resolution of his angioedema, which supports that his angioedema process was most likely unrelated to his bupropion exposure. Likewise, hypersensitivity reactions to opiates, proton pump inhibitors, and vitamin capsule ingredients have been occasionally cited as possible triggers causing urticaria and angioedema.^{2,15} However, complete resolution of symptoms would be dependent on discontinuing exposure to the substance.^{2,15} Our patient's pantoprazole was also continued throughout admission, with methadone and vitamins resumed prior to discharge without issue. Re-exposure to these substances would have resulted in another episode of angioedema; therefore, it is unlikely that these medications were the cause.

LIMITATIONS

The patient did not clarify the nature and duration of his red tide exposure. Therefore, it is unclear whether he had gone into the water and was still at the beach when his symptoms began.

CONCLUSION

Acute histamine-mediated angioedema is a common yet potentially fatal edematous reaction to triggers of mast cell degranulation and histamine release. Early recognition of a histamine-mediated etiology is essential for both acute treatment and long-term management, which depends on avoiding the inciting event. We present the first documented case of red tide-associated angioedema. In coastal areas where red tide blooms are common, it is important to consider *K. brevis* brevetoxins as a possible etiology in a patient presenting with acute onset of angioedema.

Patient consent has been obtained and filed for the publication of this case report.

REFERENCES

- Long BJ, Koyfman A, Gottlieb M. Evaluation and management of angioedema in the emergency department. *West J Emerg Med.* 2019;20(4):587-600.
- Busse PJ and Smith T. Histaminergic angioedema. *Immunol Allergy Clin North Am.* 2017;37(3):467-81.
- Kelly M, Donnelly JP, McAnnally JR, et al. National estimates of emergency department visits for angioedema and allergic reactions in the United States. *Allergy Asthma Proc.* 2013;34(2):150-4.
- Patel SS, Lovko VJ, Lockey RF. Red tide: overview and clinical manifestations. *J Allergy Clin Immunol Pract.* 2020;8(4):1219-23.
- Hoagland P, Jin D, Beet A, et al. The human health effects of Florida red tide (FRT) blooms: an expanded analysis. *Environ Int.* 2014;68:144-53.
- Florida Fish and Wildlife Conservation Commission. Red Tide. Available at: <https://myfwc.com/research/redtide/>. Updated December 23, 2020. Accessed December 28, 2020.
- Cheng YS, Zhou Y, Pierce RH, et al. Characterization of Florida red tide aerosol and the temporal profile of aerosol concentration. *Toxicol.* 2010;55(5):922-9.
- Fleming LE, Kirkpatrick B, Backer LC, et al. Review of Florida red tide and human health effects. *Harmful Algae.* 2011;10(2):224-33.
- Abraham WM, Bourdelais AJ, Sabater JR, et al. Airway responses to aerosolized brevetoxins in an animal model of asthma. *Am J Respir Crit Care Med.* 2005;171(1):26-34.
- Kirkpatrick B, Fleming LE, Backer LC, et al. Environmental exposures to Florida red tides: effects on emergency room respiratory diagnoses admissions. *Harmful Algae.* 2006;5(5):526-33.
- FWC Fish and Wildlife Research Institute Statewide *Karenia brevis* Concentrations October 1-31, 2018. 2018. Available at: <https://www.flickr.com/photos/myfwc/31121209017/in/album-72157635398013168/>. Accessed January 1, 2021.
- Wu MA, Perego F, Zanichelli A, et al. Angioedema phenotypes: disease expression and classification. *Clin Rev Allergy Immunol.* 2016;51(2):162-9.
- Tackett AE and Smith KM. Bupropion-induced angioedema. *Am J Health Syst Pharm.* 2008;65(17):1627-30.
- Tuman TC, Tuman BA, Göksügür N, et al. Urticaria and angioedema associated with bupropion: three cases. *Prim Care Companion CNS Disord.* 2016;18(4).
- Bowlby HA and Dickens GR. Angioedema and urticaria associated with omeprazole confirmed by drug rechallenge. *Pharmacotherapy.* 1994;14(1):119-22.

Pediatric Innominate Artery Pseudoaneurysm Rupture in Vascular Ehlers-Danlos Syndrome: A Case Report

Aimee Vos, MD
Katharine M. Burns, MD

Advocate Christ Medical Center, Department of Emergency Medicine, Oak Lawn, Illinois

Section Editor: Melanie Heniff, MD

Submission history: Submitted January 17, 2021; Revision received March 11, 2021; Accepted March 19, 2021

Electronically published April 23, 2021

Full text available through open access at http://escholarship.org/uc/uciem_cpem

DOI: 10.5811/cpem.2021.3.51787

Introduction: Ehlers-Danlos syndrome is a well classified connective tissue disorder recognized by its features of hyperextensibility of joints and hyperelasticity of the skin. However, the rare vascular type (Ehlers-Danlos type IV) is more difficult to identify in the absence, rarity, or subtlety of the classical physical features. Patients presenting to the emergency department (ED) with acute complications of vascular Ehlers-Danlos syndrome may be critically ill, requiring accurate diagnosis and tailored management.

Case Report: This report details a case of spontaneous innominate artery pseudoaneurysm rupture in a pediatric patient with previously undiagnosed Ehlers-Danlos syndrome. Initial ED evaluation was followed by urgent operative intervention and subsequent genetic testing to confirm final diagnosis.

Conclusion: Due to its high morbidity and mortality, vascular type Ehlers-Danlos syndrome should be considered in the differential for otherwise unexplained spontaneous vascular injury. [Clin Pract Cases Emerg Med. 2021;5(2):226–229.]

Keywords: *Pseudoaneurysm; pediatric vascular injury; Ehlers-Danlos syndrome; case report.*

INTRODUCTION

Ehlers-Danlos syndrome (EDS) is a broad class of connective tissue disorders unified by a variable degree of joint hypermobility and skin involvement, including fragility, hyperelasticity and/or bruising.¹ The various forms of EDS can be distinguished on the basis of clinical presentation, inheritance (generally autosomal dominant), the altered gene, and the underlying mechanism that renders extracellular collagen deficient. The vascular type of EDS (vEDS) is a rare condition with an estimated prevalence of one in 50,000–250,000 individuals.^{2,3} Characteristic features of vEDS include fragility of the arteries, intestine, and uterus. Outward features often include a characteristic facial appearance (deeply set and prominent eyes, narrow nasal bridge, thin lips), translucent skin with dystrophic scars, frequent occurrence of bruising without an identified cause, and tapered fingers with an aged appearance known as acrogeria.²

Notably absent in vEDS is the prominent joint hypermobility typically associated with the more common hypermobile, or classical, presentations of EDS.^{3,4,5} If present in vEDS, joint laxity is often limited to the distal extremities. Less consistent features include clubfoot deformity, spontaneous pneumothorax, and cavernous sinus fistula. Unlike all other forms of EDS, vEDS is caused by mutations in the gene (*COL3A1*) encoding type III collagen.¹

The diagnosis of vEDS in childhood most often occurs as a consequence of a dedicated clinical evaluation and molecular testing after diagnosis of a family member. The majority of additional diagnoses occur on the basis of a life-threatening vascular or gastrointestinal event, highlighting the need for increased clinical awareness of the signs and symptoms of this disorder. This report details a pediatric patient with a spontaneous innominate artery pseudoaneurysm rupture serving as the inciting incident, leading to his formal diagnosis of vEDS.

CASE REPORT

A 15-year-old male presented to the emergency department for evaluation of neck and chest pain. He was running at a brisk pace when he felt a sudden sharp pain in his neck followed by sustained pain in the center of his chest and neck. He reported the sensation of shortness of breath and nausea, but no dysphagia or dysphonia. There was no history of trauma to the head, neck, or chest. He was previously healthy with no prior medical problems or prior surgeries and had no history of familial or congenital medical conditions. Most notably, the patient had no family history of sudden cardiac death, aortic disease, or connective tissue disease. The patient endorsed having no known allergies and did not take any medications on a daily basis.

On arrival, he displayed mild tachypnea with a respiratory rate of 22 breaths per minute, but otherwise had normal vital signs with a blood pressure of 128/80 millimeters of mercury, heart rate 66 beats per minute, temperature 37 degrees Celsius, with 98% oxygen saturation on room air. His airway showed no evidence of impending compromise. He appeared to be in moderate distress secondary to pain. He demonstrated respiratory splinting and held his neck and shoulders still to prevent worsening of pain. He had mild nasal flaring, but his lungs were clear to auscultation bilaterally. He had no evidence of stridor. Palpation of the chest revealed tenderness near the right sternoclavicular region of his chest. Pulses were palpable and equal in all extremities.

A chest radiograph showed lung markings to the periphery bilaterally, no consolidations, and no opacities (Image 1). The mediastinum appeared widened, which prompted a computed

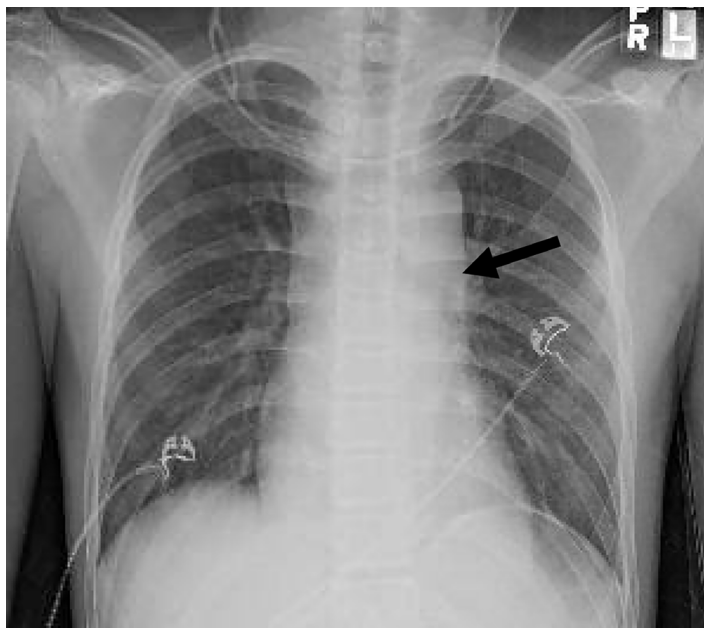


Image 1. Upright chest radiograph showing a widened mediastinum (arrow) in a 12-year-old with vascular Ehlers-Danlos Syndrome.

CPC-EM Capsule

What do we already know about this clinical entity?

Vascular type Ehlers-Danlos syndrome (EDS), a genetic connective tissue disorder, is characterized by vascular and organ fragility.

What makes this presentation of disease reportable?

Vascular type EDS can present initially with critical and potentially devastating organ or vascular injuries.

What is the major learning point?

Vascular type EDS should be considered in the differential for otherwise unexplained spontaneous vascular injury.

How might this improve emergency medicine practice?

Prompt diagnosis of vascular type EDS will significantly influence medical decision-making, allowing tailored care to the underlying pathology.

tomography (CT) angiogram of the chest and neck to better evaluate vascular anatomy. This revealed a pseudoaneurysm of the proximal innominate artery (Image 2). There was also high

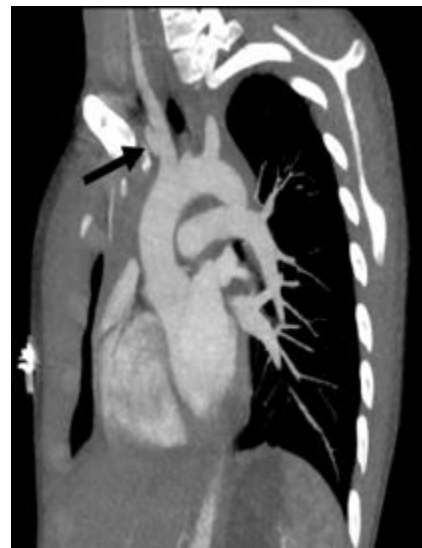

Image 2. Pseudoaneurysm (arrow) of the innominate artery as it extends off of the arch of the aorta, as seen in the coronal axis on computed tomography angiogram imaging of a 12-year-old with vascular Ehlers-Danlos Syndrome.

attenuation blood tracking from the superior mediastinum to the descending aorta suggesting rupture of the pseudoaneurysm and formation of a mediastinal hematoma (Image 3).

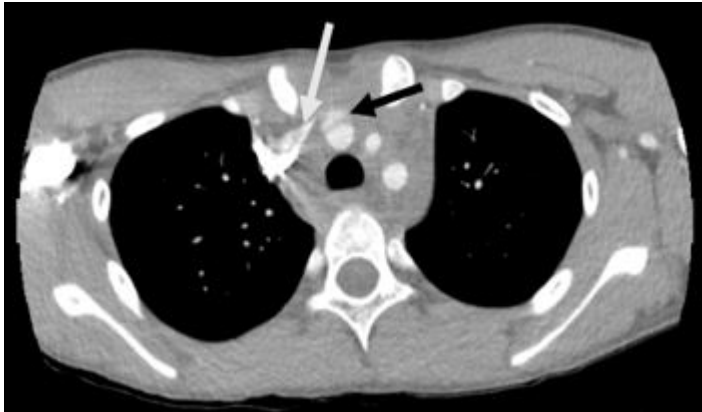

Image 3. Pseudoaneurysm of the innominate artery (black arrow) seen in the transverse axis on computed tomography angiogram imaging with contrast. Mediastinal hematoma (white arrow) is seen layering anterior to the hyperdense subclavian vein as contrast extravasates out of the ruptured pseudoaneurysm.

The patient was taken to the operating room where he was found to have an extensive tear of the proximal innominate artery about one centimeter from its origin. The rupture was contained by the adventitia and surrounding soft tissue. The patient received an ascending aortic to innominate artery extra-anatomic bypass graft, and drains were placed to reduce the mediastinal hematoma. He was evaluated by geneticists postoperatively who suspected a connective tissue disorder. High on the differential was vEDS given his exam exhibiting flexible digits, easy bruising, and normal aortic root dimension. The patient was discharged home on postoperative day five, and nearly three weeks later, genetic testing confirmed a pathogenic *COL3A1* mutation diagnostic of vEDS.

DISCUSSION

The Ehlers-Danlos phenotype was first described by Van Meekeren in 1682 after reporting a patient with hyperelastic skin. It was not until Ehlers and Danlos further classified the additional classical characteristics in the early 1900s that the collection of signs and symptoms became recognized as a syndrome.⁶ Throughout the 1960s the syndrome was further classified into distinct types.⁴ Finally in 1997, after up to 11 types had been described, the Villefranche nosology classified the syndrome into the six types commonly referenced in medicine today: classical; hypermobility; vascular; kyphoscoliosis; arthrochalasia; and dermatosparaxis.^{7,8} These classifications were based on clinical phenotype, inheritance pattern, and biochemical and molecular defects.³ Vascular type, otherwise known as type IV, is rare but also the most malignant of the six types.

Clinical diagnosis of vEDS includes two of the four main criteria: 1) easy bruising; 2) thin skin and visible veins; 3) facial characteristics including prominent eyes, narrow nasal bridge, and thin lips; and 4) uterine, arterial, or intestinal rupture.^{3,5} Factors favoring this diagnosis in the described case include the young age associated with vascular event and the absence of aortic root enlargement, which is a common finding in other vascular connective tissue diagnoses including Marfan syndrome and Loeys-Dietz syndrome. Laboratory diagnosis is used to confirm clinical suspicion. Identification of a pathogenic *COL3A1* mutation shows great sensitivity and specificity for the diagnosis of vEDS. Approximately half of cases are due to new mutations that occur sporadically with no family history of connective tissue disorder.³

The morbidity of vEDS is quite high. In a review of 220 index patients and 199 affected relatives performed by Pepin et al in 2000, median survival was reported to be 48 years, but a quarter of patients had their first complications before 20 years of age, with average age of first complication 23.5 years. At the age of 40, 80% of patients reported having at least one major complication including arterial dissection or rupture (46%), gastrointestinal perforation (19%), or other organ rupture (5%). Arterial events are associated with a high rate of fatality.⁵ Common sites of initial arterial events include the aortic arch and branch vessels or the descending aorta in the chest or abdomen. Less common sites for arterial rupture include the carotid, subclavian, ulnar, popliteal, and tibial arteries.⁷ This report describes an innominate artery pseudoaneurysm defined as an incomplete vascular rupture extending through the intima and media, but contained by the adventitia and surrounding soft tissue.

While there is no definitive treatment for vEDS, there are approaches that can be used to reduce morbidity and mortality including the use of high-dose vitamin C to promote collagen cross-linking, antihypertensive agents to reduce hemodynamic stress and to mitigate abnormal cellular signaling events in the arterial wall, and frequent noninvasive imaging to identify emerging vascular lesions.³ Pregnancy is considered high risk given the potential for uterine rupture and should be managed by high-risk specialists. Patients should be encouraged to avoid contact sports or other activities with risk of traumatic injury.^{2,3}

Invasive procedures such as angiography should be avoided in patients with vEDS if possible, as pseudoaneurysm formation, dissection, or vessel rupture has been associated with arterial manipulation.^{3,6,9} If angiography is necessary for diagnosis in a symptomatic patient, contrast injection should be performed at low pressure to avoid injury to the vessels. Caution is indicated with regard to endovascular diagnostic procedures or therapy given the potential for vascular fragility or rupture. As a general precaution, stent procedures are avoided in vEDS due to the potential for vessel rupture or stent migration.³ The benefit of prophylactic surgical intervention in vEDS must be weighed against the risks imposed by tissue fragility. Conservative management is typically favored unless a potentially fatal complication is identified.²

CONCLUSION

In the ED, young patients with vEDS can present with potentially catastrophic complications prior to receiving a formal diagnosis of a connective tissue disorder. Emergency physicians need to be wary of complaints of chest pain or abdominal pain in patients with known or suspected vEDS as this may be the presenting complaint due to a severe vascular injury. Even if symptoms appear minor, vascular imaging is crucial to detecting underlying injury. Angiography and operative intervention, while risky, may be necessary if a life-threatening vascular abnormality or hemorrhage is identified. If vascular injury is ruled out, the emergency physician should have a high index of suspicion for other associated complications including bowel rupture, uterine rupture, or spontaneous pneumothorax. The morbidity and mortality of these complications could be mitigated by an increased awareness of systemic manifestations and an appropriate clinical suspicion by both primary care and emergency physicians.

ACKNOWLEDGMENTS

We would like to thank Harry Dietz, III, MD, Professor of Genetic Medicine at Johns Hopkins Hospital for his input into the patient's disease management and expert knowledge in reviewing the details of this case report.

The authors attest that their institution requires neither Institutional Review Board approval, nor patient consent for publication of this case report. Documentation on file.

REFERENCES

1. Malfait F, Francomano C, Byers P, et al. The 2017 international classification of the Ehlers-Danlos syndromes. *Am J Med Genet Part C Semin Med Genet*. 2017;175(1):8-26.
2. Germain DP. Ehlers-Danlos syndrome type IV. *Orphanet J Rare Dis*. 2007;2:32.
3. Eagleton MJ. Arterial complications of vascular Ehlers-Danlos syndrome. *J Vasc Surg*. 2016;64(6):1869-80.
4. Beighton P. Lethal complications of the Ehlers-Danlos syndrome. *Br Med J*. 1968;656-9.
5. Pepin M, Schwarze U, Superti-Furga A, et al. Clinical and genetic features of Ehlers-Danlos syndrome type IV, the vascular type. *N Engl J Med*. 2000;342(10):673-80.
6. Cikrit DF, Miles JH, Silver D. Spontaneous arterial perforation: the Ehlers-Danlos specter. *J Vasc Surg*. 1987;5(2):248-55.
7. Oderich GS, Panneton JM, Bower TC, et al. The spectrum, management and clinical outcome of Ehlers-Danlos syndrome type IV: a 30-year experience. *J Vasc Surg*. 2005;42(1):98-106.
8. Nanayakkara PW, van Bunderen CC, Simsek S, et al. Vascular type of Ehlers-Danlos syndrome in a patient with a ruptured aneurysm of the splenic artery. *Neth J Med*. 2006;64(10):374-6.
9. Mirza FH, Smith PL, Lim WN. Multiple aneurysms in a patient with Ehlers-Danlos syndrome: angiography without sequelae. *AJR Am J Roentgenol*. 1979;132(6):993-5.

Address for Correspondence: Aimee Vos, MD, Advocate Christ Medical Center, Department of Emergency Medicine, Suite 1320M, 4440 West 95th Street, Oak Lawn, IL 60453. Email: Aimee.vos@aah.org.

Conflicts of Interest: By the CPC-EM article submission agreement, all authors are required to disclose all affiliations, funding sources and financial or management relationships that could be perceived as potential sources of bias. The authors disclosed none.

Copyright: © 2021 Vos et al. This is an open access article distributed in accordance with the terms of the Creative Commons Attribution (CC BY 4.0) License. See: <http://creativecommons.org/licenses/by/4.0/>

Profound Weakness and Blurry Vision in a Pandemic: A Case Report

Jacy M. O’Keefe, MD*

*HealthPartners/Regions Hospital, Department of Emergency Medicine, St. Paul, Minnesota

Kristi J.H. Grall, MD, MHPE†

†University of Minnesota, Department of Emergency Medicine, Minneapolis, Minnesota

Section Editor: R. Wilkerson, MD

Submission history: Submitted December 7, 2020; Revision received March 24, 2021; Accepted March 19, 2021

Electronically published May 6, 2021

Full text available through open access at http://escholarship.org/uc/uciem_cpchem

DOI: 10.5811/cpchem.2021.3.51104

Introduction: Neuro-Behçet’s disease (NBD) is a manifestation of Behçet’s disease, a relapsing inflammatory multisystem disease. Data on patients with autoimmune disease in the setting of severe acute respiratory syndrome coronavirus-2 (SARS-CoV-2) is limited.

Case Report: We discuss the case of a 22-year-old male with SARS-CoV-2 who presented to the emergency department with weakness and vision changes. Brain imaging showed enhancing lesions. History revealed possible autoimmune disease. A diagnosis of NBD exacerbated by SARS-CoV-2 was made.

Conclusion: Patients with SARS-CoV-2 are presenting with exacerbations of systemic illnesses. Although NBD is uncommon, medical professionals need to consider this in the differential of central nervous system disorders, as it is a potentially treatable condition. [Clin Pract Cases Emerg Med. 2021;6(2):230–233.]

Keywords: *Emergency medicine; case report; neuro-Behçet’s disease; SARS-CoV2.*

INTRODUCTION

Neuro-Behçet’s disease (NBD) is one of the more serious manifestations of Behçet’s disease (BD), a relapsing inflammatory multisystem disease.¹ Data on patients with systemic autoimmune disease in the setting of severe acute respiratory syndrome coronavirus-2 (SARS-CoV-2) is limited, but it has been hypothesized that those with underlying disease processes may have worse outcomes.⁵ However, little has been published on this topic.

CASE REPORT

A 22-year-old Black male with a past medical history of asthma and migraines presented to the emergency department (ED) with diffuse weakness and vision changes. Paramedics reported that they were called to the patient’s home by his mother due to profound weakness. The patient’s history was limited by his somnolence, but he noted progressive weakness, intermittent headaches, and blurred vision in his left eye over the prior three weeks. The

patient denied drug or alcohol use or recent head trauma, and reported his immunizations were up to date. He denied a fever, neck pain or stiffness, recent sick contacts, urinary incontinence, saddle anesthesia, or numbness/paresthesia. His mother also reported significant anorexia and weight loss. She stated he had been living in a home with possible black mold. The patient delayed seeking medical attention due to the current SARS-CoV-2 pandemic but agreed to be evaluated after he lost the ability to ambulate.

Vital signs were as follows: blood pressure of 111/75 millimeters of mercury; heart rate of 74 beats per minute; temperature of 97.5°F, respiratory rate of 10 breaths per minute; and oxygen saturation of 99%. Physical examination was notable for left ocular strabismus and anisocoria, with the left pupil measuring 3 millimeters (mm) and the right pupil measuring 5 mm, both reactive to light. He had normal extraocular movements. The patient was symmetrically weak with notable bradykinesia; otherwise the neurologic exam was without abnormality. The remainder of the physical exam was

noted to have no significant external findings of head trauma, conjunctivae were clear, Brudzinski's sign was not present, and there was no nuchal rigidity or photosensitivity. He had no rashes on his exposed skin.

Initial laboratory analysis including a complete blood count, basic metabolic panel, lactate, magnesium, thyroid stimulating hormone, ethanol level, and urinalysis was without abnormality. A chest radiograph and non-contrast computed tomography (CT) of the head showed no abnormalities. Polymerase chain reaction was positive for SARS-CoV-2.

Due to the patient's profound weakness and abnormal ocular findings raising concerns for possible underlying demyelinating disease, malignancy, stroke, or infection, the decision was made by the emergency physician to obtain a brain magnetic resonance imaging (MRI) (Image). With the exception of worsening drowsiness, the patient's clinical status was unchanged during his ED course.

Upon further questioning, the patient reported recurrent oral and genital ulcers, headaches, and vision problems. He denied any respiratory symptoms and his vital signs remained stable in the setting of SARS-CoV-2 infection. He was subsequently admitted to the hospital.

The differential diagnosis included neurosyphilis or other sexually transmitted infection, human immunodeficiency virus, central nervous system (CNS) lymphoma, sarcoidosis, lupus, other autoimmune disease, infectious etiology (toxoplasmosis, Lyme disease, Whipple disease, tuberculosis, neurocysticercosis, cryptococcus, blastomycosis, histoplasmosis, abscess, and SARS-CoV-2), and

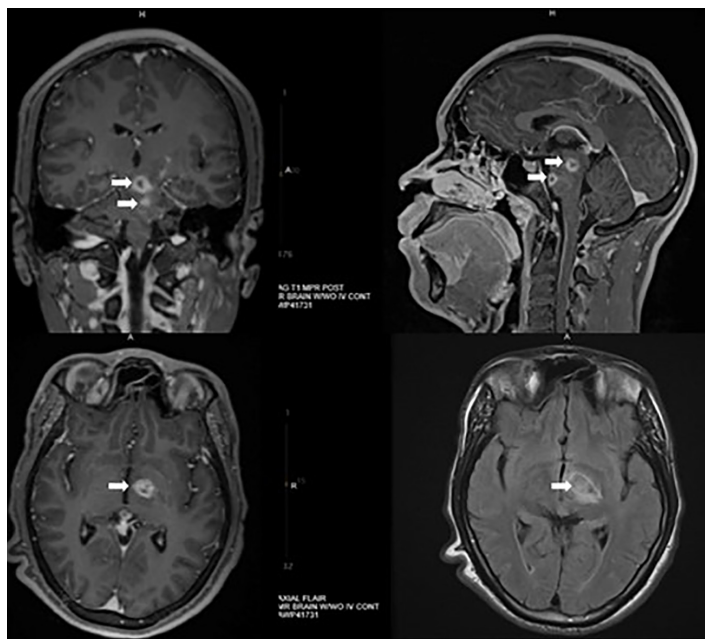


Image. Magnetic resonance imaging of the brain with/without intravenous contrast: multifocal abnormal enhancing lesions (white arrows) in the bilateral cerebral hemispheres, left thalamus, and brainstem.

CPC-EM Capsule

What do we already know about this clinical entity?

Data is limited on autoimmune disorders, such as Behçet's disease (BD), in the setting of severe acute respiratory syndrome coronavirus-2 (SARS-CoV-2).

What makes this presentation of disease reportable?

Neuro-Behçet's disease (NBD), a rare manifestation of BD, in a patient with underlying SARS-CoV-2 is an unusual diagnosis.

What is the major learning point?

Neuro-Behçet's disease is a rare but treatable manifestation of BD that may be exacerbated due to delay in seeking medical care during the coronavirus disease 2019 pandemic.

How might this improve emergency medicine practice?

Early diagnosis of NBD can result in improved patient outcomes.

paraneoplastic process. Per the radiology report, the lesions did not appear to be consistent with multiple sclerosis.

During the patient's admission to the hospital, consultations with rheumatology, infectious disease, and neurology were obtained. Additional history obtained during his admission included a report that he had been previously worked up for Crohn's disease, but no formal diagnosis had been made. Additionally, the patient had previously been diagnosed with uveitis. His mother denied any family history of autoimmune or neurologic disorders. A CT of the chest, abdomen, and pelvis was performed, which did not reveal malignancy or abnormality. A CT cerebral venography was negative for thrombosis. A testicular ultrasound was normal. A lumbar puncture was performed and cerebrospinal fluid (CSF) analysis was significant for neutrophilic leukocytosis with elevated protein, but was otherwise negative for viral, bacterial, fungal, parasitic, or malignant etiologies. Neurosurgery did not recommend biopsy of the lesions due to the location.

After ruling out other etiologies, a diagnosis of BD and NBD was made, using the International Clinical Criteria for Behçet's Disease (ICCBD) (the condition is clinically diagnosed rather than serologically) and the International Consensus Recommendation (ICR) criteria for NBD diagnosis, respectively (Table). Per the ICCBD, the patient must have recurrent oral

Table. International Consensus Recommendation criteria for neuro-Behçet's disease.¹

The ICCBD states patients must present with:

1. Recurrent oral ulcerations (aphthous or herpetiform) at least three times in one year.

Additionally, patients must present with any two of the following:

1. Recurrent genital ulcerations
2. Eye lesions (uveitis or retinal vasculitis) observed by an ophthalmologist
3. Skin lesions
4. Positive pathergy test read by a physician within 24-48 hours

The ICR for NBD states definite NBD meeting all of the following three criteria:

1. Satisfy the ICCBD
2. Neurological syndrome (with objective neurological signs) recognized to be caused by Behçet's disease and supported by relevant and characteristic abnormalities seen on either or both:
 - a. Neuroimaging
 - b. CSF
3. No better explanation for the neurological findings

Probable NBD meeting one of the following two criteria in the absence of a better explanation for the neurological findings:

1. Neurological syndrome as in definite NBD, with systemic BD features but not satisfying the ICCBD
2. A non-characteristic neurological syndrome occurring in the context of ICCBD-supported BD

NBD, neuro-Behçet's disease; *BD*, Behçet's disease *CSF*, cerebrospinal fluid; *ICCBD*, International Clinical Criteria for Behçet's Disease; *ICR*, International Consensus Recommendation.

ulcerations as well as two of the following: recurrent genital ulcerations; eye lesions; or skin lesion to make the diagnosis of BD. The patient received points for recurrent oral and genital ulcerations and uveitis.¹ According to the ICR, he met criteria for NBD due to neuroimaging findings, CSF analysis, and the lack of a better explanation for the neurological symptoms.

DISCUSSION

Neuro-Behçet's disease is a serious manifestation of BD, which is a relapsing inflammatory multisystem disease.¹ Between 5-30% of BD patients will present with neurological changes on initial evaluation and up to 49% will develop neurological involvement at some point in their disease course.⁷ Although serious neurologic flares are considered rare, the manifestations of NBD can be severe with a high mortality rate. This condition is potentially treatable; so medical professionals need to consider NBD in the differential diagnosis of inflammatory, infective, or demyelinating CNS disorders. When patient's present with neurologic changes and a reported history of recurrent oral or genital ulcers, uveitis, or other systemic features of BD, NBD should be considered.

Neuro-Behçet's disease is often compared with multiple sclerosis (MS); accordingly, MS was high on the differential for this patient. Certain neurological features such as sensory

complications, optic neuritis, internuclear ophthalmoplegia, limb ataxia, and cerebellar dysarthria are more common in MS, while headaches, motor symptoms, pseudobulbar speech, and cognitive-behavioral changes are more common in NBD.² Unmatched CSF oligoclonal bands are present in the majority of MS patients and are uncommon in NBD.⁴ In NBD, CSF will show more white blood cells with neutrophils predominating, while in MS neutrophils are scarce and lymphocytes generally predominate.³ Radiologically, NBD usually involves the white matter, brainstem, basal ganglia, and thalamus, whereas in MS the lesions are periventricular, with infrequent involvement of the basal ganglia or internal capsule.⁸ Cerebral MRI findings often reveal T1 iso/hypointense and T2 hyperintense lesions in NBD, similar to MS.⁸

There is no level I evidence on treatments for NBD and, therefore, no US Food and Drug Administration- approved medications. For an acute or sub-acute parenchymal NBD flare, high-dose intravenous (IV) corticosteroids (one gram methylprednisolone) is recommended for 4-5 days, followed by an oral corticosteroid for up to six months (60 milligrams [mg] prednisone daily). Colchicine, azathioprine, tumor necrosis factor (TNF)-alpha inhibitors (adalimumab, infliximab, among others), or interferon alpha can be considered. These medications can improve or completely resolve lesions of NBD if initiated early enough in the disease course.¹

Data on patients with systemic autoimmune disease and concomitant SARS-CoV-2 is limited, but reports have recently been released in Europe.^{5,6} In one case series, 10 SARS-CoV-2 positive BD patients were evaluated.⁴ Except one patient who was off treatment; all of the other nine were using one of the following drugs either alone or in combination: colchicine (n=5); azathioprine (n=3); anti-TNF agents (n=3); or prednisolone (n=2). Of the patients involved in the case series, in addition to skin mucosa lesions, four had eye involvement, one had both eye and neurological involvement, and one had large vessel disease. The patient in this series who was off treatment ultimately died secondary to respiratory failure. Another patient had NBD and was hospitalized with deep venous thrombosis. Four patients were diagnosed with SARS-CoV-2 pneumonia. Three of these were hospitalized with one requiring intensive care unit admission. Three patients had exacerbations of oral ulcers or arthralgias. Four patients had no complications associated with BD during their course with SARS-CoV-2.

During the admission of our patient, he continued to be weak and developed aphasia, right hemiparesis with spasticity, uncontrollable laughter, and urinary incontinence. Initially, steroids were avoided due to SARS-CoV-2, but with worsening neurologic symptoms, it was decided that the benefits outweighed the risks and he was started on one gram IV methylprednisolone daily for five days. He was also started on anticoagulation therapy due to both BD and SARS-CoV-2 being associated with hypercoagulable states. Prior to discharge after a 16-day admission, he had improvement in his neurologic symptoms, and repeat MRI demonstrated significant improvement with

near resolution of brain lesions. He was discharged on 40 mg subcutaneous adalimumab every two weeks and 60 mg oral prednisone daily with close rheumatology follow-up. Although the patient never developed typical symptoms of SARS-CoV-2, he did have a severe exacerbation of NBD, which may have been in part due to this underlying viral illness and his delay in seeking medical attention due to the pandemic.

CONCLUSION

More research is needed to understand the relationship between SARS-CoV-2 and the effect it has on autoimmune diseases, such as Behçet's disease. It must also be noted that during the COVID-19 pandemic patients were initially avoiding seeking medical care, resulting in critical presentations requiring emergent intervention.

Patient consent has been obtained and filed for the publication of this case report.

REFERENCES

1. Kalra S, Silman A, Akman-Demir G, et al. Diagnosis and management of neuro-Behçet's disease: International Consensus Recommendations. *J Neurol*. 2014;261(9):1662-76.
2. Motomura S, Tabira T, Kuriowa Y, et al. A clinical comparative study of multiple sclerosis and neuro-Behçet syndrome. *J Neurol Neurosurg Psychiatry*. 1998;43:210-3.
3. McLean BN, Miller D, Thompson EJ. Oligoclonal banding of IgG in CSF, blood-brain barrier function, and MRI findings in patients with sarcoidosis, systemic lupus erythematosus, and Behçet's disease involving the nervous system. *J Neurol Neurosurg Psychiatry*. 1995;58:548-54.
4. Yurttaş B, Oztas M, Tunc A, et al. Characteristics and outcomes of Behçet's syndrome patients with coronavirus disease 2019: a case series of 10 patients. *Intern Emerg Med*. 2020;15(8):1567-71.
5. Emmi G, Bettiol A, Mattioli I, et al. SARS-CoV-2 infection among patients with systemic autoimmune diseases. *Autoimmun Rev*. 2020;19(7):102575.
6. Alomari SO, Abou-Mrad Z, Bydon A. COVID-19 and the central nervous system. *Clin Neurol Neurosurg*. 2020;198:106116.
7. Siva A, Altintas A, Saip S, et al. Behçet's syndrome and the nervous system. *Curr Opin Neurol*. 2004;17(3):347-57.
8. Mohame C, Najib K, Essaadouni L, et al. Radiological findings in Behçet disease. *Pan Afr Med J*. 2015;20:51.

Address for Correspondence: Jacy O'Keefe, MD, HealthPartners/Regions Hospital, Department of Emergency Medicine, 640 Jackson Street St. Paul, MN 55101. Email: jacy.m.okeefe@healthpartners.com.

Conflicts of Interest: By the CPC-EM article submission agreement, all authors are required to disclose all affiliations, funding sources and financial or management relationships that could be perceived as potential sources of bias. The authors disclosed none.

Copyright: © 2021 O'Keefe et al. This is an open access article distributed in accordance with the terms of the Creative Commons Attribution (CC BY 4.0) License. See: <http://creativecommons.org/licenses/by/4.0/>

Chloroquine Ingestion to Prevent SARS-CoV-2 Infection: A Report of Two Cases

Jonathan Graff, DO*

Michelle Geyer Thompson, DO†

Zachary Berriochoa, MD‡

Bryan Kuhn, PharmD‡

Anne-Michelle Ruha, MD‡§

Christopher Lipinski, MD¶

*Banner Baywood Medical Center, Department of Emergency Medicine, Mesa, Arizona

†Banner-University Medical Center Phoenix, Department of Medical Toxicology, Phoenix, Arizona

‡Banner Poison and Drug Information Center, Phoenix, Arizona

§University of Arizona College of Medicine-Phoenix, Departments of Emergency Medicine and Internal Medicine, Phoenix, Arizona

¶Midwestern University, Glendale, Arizona

Section Editor: Steven Walsh, MD

Submission history: Submitted December 28, 2020; Revision received March 13, 2021; Accepted March 19, 2021

Electronically published May 7, 2021

Full text available through open access at http://escholarship.org/uc/uciem_cpchem

DOI: 10.5811/cpchem.2021.3.51329

Introduction: Amid the global pandemic caused by severe acute respiratory syndrome coronavirus 2 (SARS-CoV-2), chloroquine and hydroxychloroquine were being studied as agents to prevent and treat coronavirus disease 2019. Information about these agents and their effects circulated throughout the general public media, raising the concern for self-directed consumption of both pharmaceutical and non-pharmaceutical products.

Case Report: We present two cases of chloroquine toxicity that occurred after ingestion of an aquarium disinfectant that contained chloroquine phosphate in a misguided attempt to prevent infection by SARS-CoV-2. One patient had repeated emesis and survived, while the other was unable to vomit, despite attempts, and suffered fatal cardiac dysrhythmias.

Conclusion: These cases illustrate the spectrum of toxicity, varied presentations, and importance of early recognition and management of chloroquine poisoning. In addition, we can see the importance of sound medical guidance in an era of social confusion compounded by the extremes of public and social media. [Clin Pract Cases Emerg Med. 2021;5(2):234–238.]

Keywords: *Chloroquine overdose; COVID-19; fish tank cleaner; SARS-CoV2; case report.*

INTRODUCTION

Chloroquine and its less toxic derivative, hydroxychloroquine, were first synthesized as antimalarial medications and received US Food and Drug Administration (FDA) approval in 1949 and 1955, respectively. Over the past 70 years, they have been repurposed as anti-inflammatory, antimicrobial, and immunomodulatory agents for rheumatologic syndromes, such as rheumatoid arthritis, Sjogren's syndrome, lupus erythematosus, and various infections, such as extraluminal amoebiasis, Whipple's disease, and Q fever.¹⁻³ They may also have benefit as an antitumoral or in some neurological diseases.⁴ Early in the global coronavirus disease 2019 (COVID-19)

pandemic, research emerged examining the efficacy of chloroquine and hydroxychloroquine against severe acute respiratory syndrome coronavirus 2 (SARS-CoV-2) replication.^{5,6}

Commentary on these publications quickly spread across social media. The FDA temporarily provided emergency use authorization (EUA) on March 28, 2020, for possible management of SARS-CoV-2 and COVID-19, but revoked the EUA on June 15, 2020.⁷ Given the fast-paced dissemination of information from the medical community to the general public during the pandemic, it is critical for emergency physicians to recognize acute toxicity of chloroquine and implement early aggressive management.

Chloroquine has a very narrow therapeutic window, and is considered a “one pill can kill” exposure in the pediatric patient.⁸ Severe chloroquine toxicity is characterized by nausea, vomiting, diarrhea, seizures, abrupt decompensation due to cardiovascular collapse, and death within one to three hours of ingestion.⁹ Importantly, hypokalemia is a common finding and correlates with the severity of poisoning.¹⁰ Management must focus on early gastric decontamination including activated charcoal, timely hemodynamic support, mechanical ventilation, and electrolyte management. Fatal outcomes following overdose of chloroquine are associated with ingestions of greater than 5 grams (g), systolic blood pressure less than 80 millimeters of mercury (mm Hg), and QRS duration greater than 120 milliseconds (ms).^{9,10} In a very small study of 22 case reviews, where more than 5 g of chloroquine were ingested, the combination of preemptive mechanical ventilation, high-dose diazepam, and epinephrine infusion prior to the start of cardiac dysrhythmias appeared to increase the survival rate from 10% to 91%.⁹ Because of the risk of early fatality following toxic ingestions, it is imperative to quickly intervene following acute chloroquine poisoning.

We describe two cases of chloroquine toxicity that occurred simultaneously after a husband and wife each ingested a teaspoon of aquarium disinfectant containing 98% by weight chloroquine phosphate (Image 1) dissolved in carbonated water, believing it would help prevent infection by SARS-CoV-2.




Image 1. Chloroquine phosphate aquarium disinfectant.

CASE 1

The husband, a 68-year-old White man with a history of hypertension and dyslipidemia, developed diarrhea and nausea without emesis within 20 minutes of the ingestion. His wife called for medical assistance 90 minutes after the ingestion when he developed dyspnea. Paramedics found him to be alert, oriented, and diaphoretic with a blood pressure of 110/67 millimeters mercury (mm Hg), heart rate of 93 beats

CPC-EM Capsule

What do we already know about this clinical entity?

Chloroquine has been widely used for decades with multiple applications. It has a narrow therapeutic window, is rapidly absorbed and has significant cardiac toxicities.

What makes this presentation of disease reportable?

The couple ingested the chloroquine in a misguided attempt to prevent SARS-CoV-2. We see their side-by-side response, and associated bidirectional tachycardia

What is the major learning point?

This pandemic and social media have compounded public fears and confusion. Sound local and regional medical leadership can help significantly with our society's health.

How might this improve emergency medicine practice?

These cases can stimulate us to be more involved in our communities' leadership and better prepared to intervene when minutes count.

per minute, respiratory rate (RR) of 20 breaths per minute, and oxygen saturation of 90% on ambient air. His initial rhythm strip showed normal sinus rhythm. Paramedics administered sodium bicarbonate 100 milliequivalents (mEq) after communicating with the local poison control center, as well as 15 liters per minute (L/min) oxygen via non-rebreather mask and a normal saline (NS) bolus, amounting to about 300 mL. Upon arrival to the emergency department (ED), the patient became unresponsive, had a generalized tonic-clonic seizure, and developed a pulseless electrical activity (PEA) arrest. He was intubated, cardiopulmonary resuscitation (CPR) was initiated, and a total of epinephrine 3 milligrams (mg), sodium bicarbonate 50 mEq, atropine 2 mg and magnesium 1g were administered, along with continued NS infusion. The patient had recurrent episodes of wide complex ventricular tachycardia (Image 2).

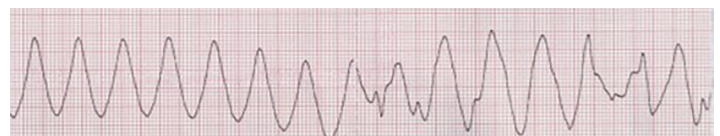


Image 2. Wide complex ventricular tachycardia in patient who ingested chloroquine phosphate aquarium disinfectant.

In addition, an early rhythm showed bidirectional ventricular tachycardia (Image 3), which has not been previously reported with chloroquine toxicity. The patient received diazepam 10 mg

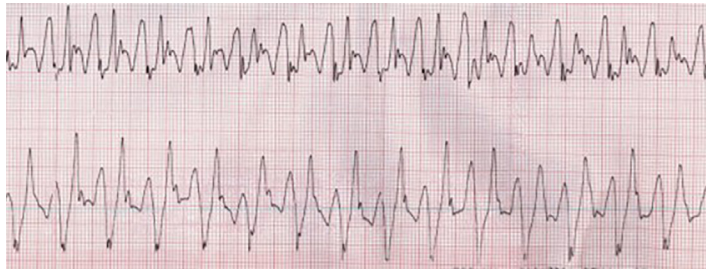

Image 3. Bidirectional tachycardia in a patient who ingested chloroquine phosphate aquarium disinfectant.

intravenously (IV), which dose was readily available, and he had return of spontaneous circulation (ROSC) within two minutes (within 10 minutes of cardiac arrest). The electrocardiogram (ECG) (Image 4) showed sinus tachycardia with a rate of 111, QRS duration of 108 ms, and QTcFri (corrected QT interval using the Fridericia calculation, $QTc = 8.22 \sqrt[3]{RR}$, where RR is the pulse period) interval prolonged to 491 ms. Seven minutes later, the patient had another PEA arrest with subsequent CPR.

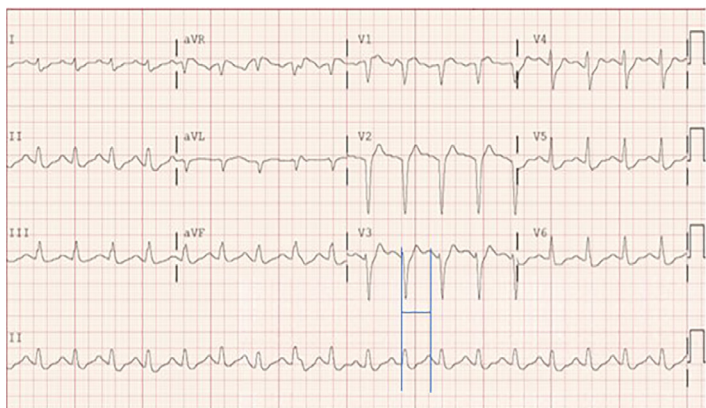


Image 4. Sinus tachycardia and prolonged QTcFri interval 491 milliseconds in a patient who ingested chloroquine phosphate aquarium disinfectant.

He received epinephrine 4 mg, sodium bicarbonate 50 mEq and calcium chloride 1g in total, and ROSC was achieved 11 minutes later. Epinephrine and norepinephrine infusions were started to augment blood pressure. A third and final PEA arrest occurred nine minutes after ROSC, and again CPR was performed with a total administration of epinephrine 9 mg, diazepam 10 mg, sodium bicarbonate 50 mEq, atropine 1mg, and magnesium sulfate 3g. Resuscitation was terminated

27 minutes later without successful resuscitation. The patient was declared deceased three hours and 22 minutes after time of ingestion. The perimortem serum chloroquine concentration was 6.2 mg/L. Pharmacogenomic testing revealed normal metabolism status of cytochrome P(CYP)2D6 and CYP3A4 but intermediate metabolism of CYP3A5.

CASE 2

The wife, a 62-year-old White female with a history of anxiety and insomnia developed nausea, recurrent emesis, mild diarrhea, and abdominal pain 25 minutes after the ingestion. She was transported to the local ED immediately after her husband where she reported dizziness, shakiness, and blurry vision. Initial vital signs showed a blood pressure of 104/72 mm Hg, heart rate of 73 beats per minute, RR of 17 breaths per minute, and room air oxygen saturation of 97%. Her initial ECG obtained 150 minutes post-ingestion showed sinus rhythm with a QRS duration of 108 ms and average QTcFri interval of 646 ms (Image 5). Labs revealed

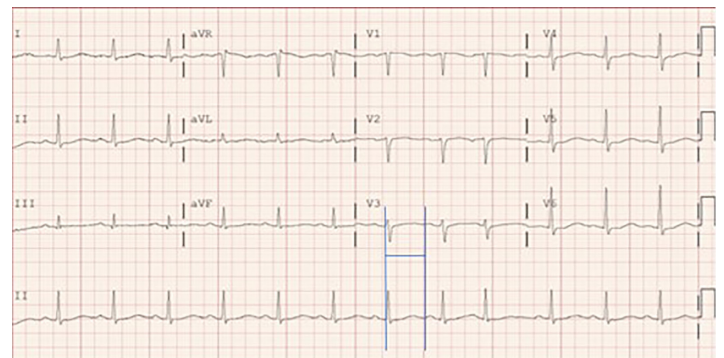


Image 5. Prolonged QTcFri interval, 646 milliseconds in a patient who ingested chloroquine phosphate aquarium disinfectant.

hypokalemia (3.3 millimoles [mmol] per L [reference range: 3.6-5.3 mmol/L]). Sodium bicarbonate 50 mEq, ondansetron 4 mg, and magnesium sulfate 2 g were administered. She was transferred to a tertiary care hospital for further management. There, a repeat ECG obtained seven hours post-ingestion showed sinus rhythm of 79 beats/minute, with a QRS duration of 99 ms and QTcFri interval of 603 ms. She received a sodium bicarbonate infusion, lactated Ringer's bolus, magnesium sulfate 2 g, lorazepam 0.5 mg and potassium chloride 20 mEq. Eleven hours post-ingestion her ECG showed a sinus rhythm 77 beats/minute, QRS 109 ms, and QTcFri of 560 ms. She complained of nausea, lightheadedness, and fatigue over the next 48 hours and had recurrent episodes of emesis and diarrhea. Sodium bicarbonate infusion was weaned without complication or widening of the QRS. Her symptoms of emesis resolved, and an ECG at the time of discharge showed a QRS duration of 90 ms and

QTcFri interval of 428 ms. Serum chloroquine concentrations obtained three and 16 hours after ingestion were 1.1 mg/L and 0.4 mg/L, respectively. Pharmacogenomic testing revealed normal metabolism status of CYP2D6 and CYP3A4 but poor metabolism of CYP3A5.

DISCUSSION

As demonstrated by these cases, chloroquine toxicity is difficult to manage and potentially fatal. Chloroquine is rapidly absorbed from the gastrointestinal tract, and serum concentrations peak within 1-2 hours of ingestion.¹² Chloroquine is metabolized by various cytochrome P450 isoenzymes, with CYP2C8, CYP2D6 and CYP3A4/5 being the major catalysts of deethylation.¹³ The active metabolite, desethylchloroquine, can be detected in plasma within 30 minutes of an oral dose of chloroquine¹² and can be found in serum for 30-60 days. Serum chloroquine concentrations greater than 5 mg/L are associated with fatality.¹⁴ This is consistent with the husband's outcome. Due to the large volume of distribution of chloroquine, there is some thought that intralipid infusion may have benefit; however, this therapy has not been shown to be effective.¹⁵

The couple reported that they each consumed a single "heaping" teaspoon of chloroquine; however, the precise amount of ingested product is unknown. Since the wife developed recurrent emesis, she likely absorbed less chloroquine, had lower peak serum concentrations, and was at lower risk for developing cardiac dysrhythmias. This relationship is described in the literature and indicates that cardiac dysrhythmias are less likely if emesis occurs or gastric lavage is performed, even following ingestion of a fatal dose.¹⁶ Activated charcoal binds 95% of chloroquine when administered soon after ingestion and is recommended to supersede the use of gastric lavage due to the rapid absorption of chloroquine from the gastrointestinal tract.¹⁷ Importantly, both patients' pharmacogenetic profiles showed similar variances in the function of CYP450 enzymes relevant to the metabolism of chloroquine. Although CYP2C8 status was not determined in either patient, it seems unlikely that pharmacogenetic differences explain the disparity in severity of illness and outcome.

In the second case, sodium bicarbonate was administered for the treatment of presumed sodium blockade. Mindful of the presence of hypokalemia and the risk of worsening both hypokalemia and QT prolongation with administration of sodium bicarbonate, potassium was aggressively replete. Upon transfer to the tertiary care hospital, the QRS had narrowed and signified a response to sodium bicarbonate administration.

Cardiotoxicity following chloroquine ingestion occurs as a result of inhibition of sodium, calcium, and potassium channels within the myocardium, leading to delayed depolarization, slowed conduction, prolonged refractory period, impaired contractility, reentrant dysrhythmias, and hypotension.¹⁸ In

cases where more than 5 g of chloroquine are ingested, the combination of preemptive mechanical ventilation, high-dose diazepam (2 mg per kilogram [kg] IV over 30 minutes, followed by 2 mg/kg/day), and epinephrine infusion (0.25 micrograms/kg/minute to maintain a systolic blood pressure >100 mm Hg) during hemodynamic and electrocardiographic changes, has been a strategy in combating dysrhythmias and ultimately decreasing the risk of mortality.^{9,10}

CONCLUSION

During this time of heightened public fear and anxiety, information and misinformation about therapeutics for COVID-19 disease will continue to spread through the press and social media. It is important for public health officials and clinicians to effectively communicate the limitations and dangers of using unproven therapies to prevent or treat SARS-CoV-2 infection. Additionally, the cases presented serve as a critical reminder that emergency physicians must be prepared to quickly recognize, assess, and treat toxicities from acute poisoning by chloroquine and hydroxychloroquine.

ACKNOWLEDGMENTS

The authors would like to acknowledge Peter Peil, RN, CSPI, Banner Poison and Drug Information Center, Phoenix, Arizona, and Aym O'Connor, MD, Dept. of Medical Toxicology, Banner-University Medical Center Phoenix, Depts. of Emergency Medicine and Internal Medicine, University of Arizona College of Medicine-Phoenix, Phoenix, Arizona.

Patient consent has been obtained and filed for the publication of this case report.

Address for Correspondence: Jonathan W. Graff, DO, Banner Baywood Medical Center, Department of Emergency Medicine, 6644 E. Baywood Avenue, Mesa, AZ 85206. Email: jonathan_graff@teamhealth.com.

Conflicts of Interest: By the CPC-EM article submission agreement, all authors are required to disclose all affiliations, funding sources and financial or management relationships that could be perceived as potential sources of bias. The authors disclosed none.

Copyright: © 2021 Graff et al. This is an open access article distributed in accordance with the terms of the Creative Commons Attribution (CC BY 4.0) License. See: <http://creativecommons.org/licenses/by/4.0/>

REFERENCES

1. Rolain JM, Colson P, Raoult D. Recycling of chloroquine and its hydroxyl analogue to face bacterial, fungal and viral infections in the 21st century. *Int J Antimicrob Agents*. 2007;30(4):297-308.

2. Savarino A, Boelaert JR, Cassone A, et al. Effects of chloroquine on viral infections: an old drug against today's diseases. *Lancet Infect Dis.* 2003;3(11):722-7.
3. Vincent MJ, Bergeron E, Benjannet S, et al. Chloroquine is a potent inhibitor of SARS coronavirus infection and spread. *Virology.* 2005;2:69.
4. Plantone D and Koudriavtseva T. Current and future use of chloroquine and hydroxychloroquine in infectious, immune, neoplastic, and neurological diseases: a mini-review. *Clin Drug Investig.* 2018;38:653-71.
5. Liu J, Cao R, Xu M, et al. Hydroxychloroquine, a less toxic derivative of chloroquine, is effective in inhibiting SARS-CoV-2 infection in vitro. *Cell Discov.* 2020;6(1):1-4.
6. Gautret P, Lagier JC, Parola P, et al. Hydroxychloroquine and azithromycin as a treatment of COVID-19: results of an open-label non-randomized clinical trial. *Int J Antimicrob Agents.* 2020;56(1):105949.
7. Federal Drug Administration. Emergency Use Authorization of chloroquine phosphate and hydroxychloroquine sulfate. 2020. Available at: <https://www.fda.gov/media/136534/download>. Accessed February 16, 2021.
8. Koren G. Medications which can kill a toddler with one tablet or teaspoonful. *J Toxicol Clin Toxicol.* 1993;31(3):407-13.
9. Riou B, Barriot P, Rimailho A, et al. Treatment of severe chloroquine poisoning. *New Engl J Med.* 1988;318(1):1-6.
10. Riou B, Rimailho A, Galliot M, et al. Protective cardiovascular effects of diazepam in experimental acute chloroquine poisoning. *Intensive Care Med.* 1988;14(6):610-6.
11. Clemessy JL, Taboulet P, Hoffman JR, et al. Treatment of acute chloroquine poisoning: a 5-year experience. *Crit Care Med.* 1996;24(7):1189-95.
12. Walker O, Dawodu A, Adeyokunnu A, et al. Plasma chloroquine and desethylchloroquine concentrations in children during and after chloroquine treatment for malaria. *Br Journal Clin Pharmacol.* 1983;16(6):701-5.
13. Projean D, Baune B, Farinotti R, et al. In vitro metabolism of chloroquine: identification of CYP2C8, CYP3A4, and CYP2D6 as the main isoforms catalyzing N-desethylchloroquine formation. *Drug Metab Dispo.* 2003;31(6):748-54.
14. Stead A and Moffat A. A collection of therapeutic, toxic and fatal blood drug concentrations in man. *Human Exp Toxicol.* 1983;2(3):437-64.
15. Haesendonck R, Winter S de, Verelst S. Intravenous lipid emulsion for intentional chloroquine poisoning. *Clin Toxicol (Phila).* 2012;50(3):223.
16. Britton W and Kevau I. Intentional chloroquine overdosage. *Med Journal Aust.* 1978;2(9):407-10.
17. Kivistö KT and Neuvonen PJ. Activated charcoal for chloroquine poisoning. *BMJ.* 1993;307(6911):1068.
18. White NJ. Cardiotoxicity of antimalarial drugs. *Lancet Infect Dis.* 2007;7(8):549-58.

Metronidazole, an Uncommon Cause of Dizziness and Ataxia in the Emergency Department: A Case Report

Mary E. Starrs, MD
Onur M. Yenigun, MD

Stanford University Medical Center, Department of Emergency Medicine, Palo Alto, California

Section Editor: Steven Walsh, MD

Submission history: Submitted February 3, 2021; Revision received March 18, 2021; Accepted March 19, 2021

Electronically published May 10, 2021

Full text available through open access at http://escholarship.org/uc/uciem_cpem

DOI: 10.5811/cpem.2021.3.52046

Introduction: Metronidazole, a nitroimidazole antibiotic, is a well-known antibacterial and antiprotozoal agent that is generally well tolerated without many serious side effects. Most adverse reactions affect the gastrointestinal or genitourinary system, but the central nervous system may also be afflicted. In addition to headache and dizziness, cerebellar dysfunction can occur with metronidazole use.

Case Report: We discuss the clinical presentation and imaging findings of metronidazole-induced encephalopathy in a 12-year-old male. The patient had a history of Crohn's disease and chronic *Clostridium difficile* infection for which he had received metronidazole for approximately 75 days prior to arrival to a local emergency department (ED). He presented with five days of progressive vertigo, nausea, vomiting, and ataxia. Subsequent magnetic resonance imaging showed symmetric hyperintense dentate nuclei lesions, characteristic of metronidazole-induced encephalopathy. The patient's symptoms improved rapidly after cessation of metronidazole, and his symptoms had completely resolved by discharge on hospital day two.

Conclusion: Metronidazole-induced encephalopathy is a rare cause of vertigo and ataxia that can lead to permanent sequela if not identified and treated promptly. Thus, it is important for physicians to keep this diagnosis in mind when evaluating patients on metronidazole who present to the ED with new neurologic complaints. [Clin Pract Cases Emerg Med. 2021;5(2):239–241.]

Keywords: *Metronidazole; case report; ataxia.*

INTRODUCTION

Metronidazole has been used to fight various bacterial and protozoal infections globally for more than 50 years. The majority of adverse reactions are minor, and the drug is generally well tolerated. The most common side effects reported include nausea, headache, and metallic taste. The central nervous system (CNS) is not spared, however, as metronidazole easily penetrates the blood-brain barrier and can accumulate, leading to neurologic toxicity. In a systemic review of metronidazole-induced encephalopathy (MIE), Sorensen et al found that most patients with CNS involvement present with dysarthria (63%), followed by gait instability (55%). Other clinical findings include limb dyscoordination and vertigo (53% and 18%, respectively).¹

These findings suggest that the cerebellum serves as a primary site of metronidazole accumulation, as this region of the CNS is the major regulator of motor movement and coordination. Magnetic resonance imaging (MRI) data of patients with MIE support this finding. Specifically, on T2-weighted and fluid-attenuated inversion recovery sequences (FLAIR), symmetric hyperintense dentate nuclei lesions were the most common abnormal findings (90%).² The following report describes a patient with MIE who was ultimately diagnosed and treated after MRI.

CASE REPORT

A 12-year-old male with Crohn's disease on prednisone, chronic granulomatous disease, as well as chronic *Clostridium*

difficile infection on metronidazole presented to the emergency department (ED) with a chief complaint of dizziness. The patient and his mother reported that he had experienced several intermittent episodes of vertigo, sometimes associated with movement, as well as nausea and vomiting over the prior five days. Additionally, over the previous three days, the patient had become progressively more unstable with ambulation and required assistance to get to and from the bathroom. He otherwise denied headache, ear pain, recent infection, or other focal neurologic deficits. In consultation with his outpatient providers, the patient's prednisone dose was increased from a baseline of 5 milligrams (mg) to 10 mg, and then up to 15 mg after one and two days of symptoms, respectively, due to concern for adrenal insufficiency.

Upon examination in the ED, the patient was noted to have normal vital signs for age, as well as normal cardiopulmonary and abdominal examinations. A detailed neurologic exam was notable for an unsteady, wide-based gait, at which time the patient reported a sensation of significant imbalance and intermittent vertigo. The remainder of his neurologic exam, including cranial nerves, sensation, motor strength, Romberg's test, and heel-to-shin as well as finger-nose-finger testing, was normal. Given that these findings were concerning for a cerebellar pathology, neurology was consulted and the patient was admitted to the general pediatric floor for further workup.

An MRI of the brain obtained the following morning demonstrated T2/FLAIR hyperintensity in the dentate nuclei of the cerebellum. These findings were consistent with metronidazole toxicity as described above.² The patient's metronidazole was subsequently stopped in the afternoon. The following morning he had a significant improvement in symptoms. He had no further vertigo, vomiting, or gait unsteadiness and was discharged the following day.

DISCUSSION

Metronidazole-induced encephalopathy is a rare adverse effect of prolonged metronidazole use. In the aforementioned systematic review of 136 cases, the duration of treatment with the antibiotic before the onset of CNS dysfunction varied from a lower quartile of 14 days to an upper quartile of 52.5 days, with an average of 47.2 days.¹ Our patient had been consistently taking metronidazole for approximately 75 days before the development of symptoms. A leading theory is that the pathogenesis may be secondary to axonal swelling caused by vasogenic edema, possibly due to impairment in vitamin B1 activity given metronidazole's conversion to a thiamine analog *in vivo*.³

It has been shown in previous studies that metronidazole-induced neurologic symptoms often improve within a few days after drug withdrawal.⁴ In the systematic review by Sorenson et al of 136 patients, 119 patients had either improvement or complete resolution of CNS symptoms after stopping metronidazole. Twelve of 136 patients had unfavorable outcomes including death or persisting neurologic deficits. Of these, almost all had previous premorbid conditions including

CPC-EM Capsule

What do we already know about this clinical entity?

Metronidazole is a commonly used antibiotic often associated with minor side effects affecting the gastrointestinal system, such as nausea and diarrhea.

What makes this presentation of disease reportable?

Metronidazole toxicity is an uncommon but often reversible cause of new neurologic symptoms in patients presenting to the emergency department with these complaints.

What is the major learning point?

Prolonged metronidazole use has been associated with new neurologic symptoms and characteristic magnetic resonance imaging findings that often are reversible with discontinuation of use.

How might this improve emergency medicine practice?

Broadening the differential when evaluating a patient with new neurologic complaints will aid in early diagnosis of metronidazole toxicity.

organ failure or cancer. Interestingly, six of these surviving patients had cerebral white matter lesions on MRI in addition to the dentate nuclei lesions, suggesting that these lesions may be associated with worse prognosis (Image).¹ Other studies have shown that steroid treatment may hasten recovery.⁵ It is believed that the immunosuppressive effects of steroids serve to decrease the vasogenic edema that may contribute to metronidazole's neurotoxicity as discussed above.⁴ Our patient's neurologic symptoms resolved completely within 24 hours of stopping the metronidazole. This rapid recovery may have been in part attributable to the recent increase in his prednisone dosage.

CONCLUSION

This case highlights the importance of thorough history-taking, including prescribed medications, when evaluating symptoms of vertigo and cerebellar dysfunction. Furthermore, we highlight key, specific MRI findings that are suggestive of metronidazole-induced encephalopathy. Due to its rarity, MIE diagnosis may be delayed. However, since the first case of MIE was reported in 1978, there have been at least 135 documented cases. Of these, 50 have been reported in the last five years, thus

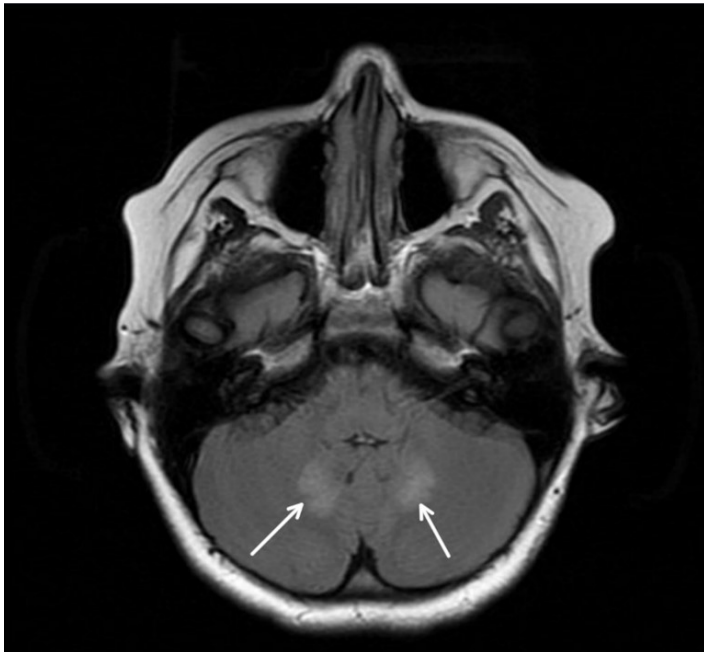


Image. T2 and fluid-attenuation inversion recovery sequence magnetic resonance imaging of brain showing symmetric hyperintense dentate nuclei lesions that are characteristic of metronidazole-induced encephalopathy.

emphasizing the increasing prevalence of the condition.¹ Additionally, the importance of diagnosis is crucial as some patients may develop persistent neurologic deficits or even death.^{5,6} As the ED is often the first place of contact for patients with new neurological deficits, it is important the emergency physician keep this rare, but often reversible, diagnosis in mind when evaluating a patient with a new neurologic complaint.

The authors attest that their institution requires neither Institutional Review Board approval, nor patient consent for publication of this case report. Documentation on file.

Address for Correspondence: Mary E. Starrs, MD, Stanford University Medical Center, Department of Emergency Medicine, 900 Welch Road, Suite 350, Palo Alto, CA 94304. Email: mstarrs@stanford.edu.

Conflicts of Interest: By the CPC-EM article submission agreement, all authors are required to disclose all affiliations, funding sources and financial or management relationships that could be perceived as potential sources of bias. The authors disclosed none.

Copyright: © 2021 Starrs et al. This is an open access article distributed in accordance with the terms of the Creative Commons Attribution (CC BY 4.0) License. See: <http://creativecommons.org/licenses/by/4.0/>

REFERENCES

1. Sorensen CG, Karlsson WK, Amin FM, et al. Metronidazole-induced encephalopathy: a systemic review. *J Neurol.* 2020;267(1):1-13.
2. Bond KM, Brinjikji LJ, Eckel DF, et al. Dentate update: imaging features of entities that affect the dentate nucleus. *AJNR AM J Neuroradiol.* 2017;38(8):1467-74.
3. Frasca D, Dahyot-Fizeier C, Adier C, et al. Metronidazole and hydroxymetronidazole central nervous system distribution: 1. Microdialysis assessment of brain extracellular fluid concentrations in patients with acute brain injury. *Antimicrob Agents Chemother.* 2014;58(2):1019-23.
4. Agah E, Habib A, Naderi H, et al. Metronidazole-induced neurotoxicity presenting with sudden bilateral hearing loss, encephalopathy, and cerebellar dysfunction. *Eur J Clin Pharmacol.* 2017;73(1):249-50.
5. Li L, Tang X, Li W, et al. A case of methylprednisolone treatment for metronidazole-induced encephalopathy. *BMC Neuro.* 2019;19(49):1-4.
6. Hobbs K, Stern-Nezer S, Buckwalter MS, et al. Metronidazole-induced encephalopathy: not always reversible. *Neurocrit Care.* 2015;22(3):429-36.

Salmonella Aortitis in an Elderly Male, a Rare but Deadly Cause of Abdominal Pain: A Case Report

Kevin M. Yanushefski, MD
Sukhdip Kaur, MD
Mary Eberhardt, MD

St. Luke's University Health Network, Department of Emergency Medicine,
Bethlehem, Pennsylvania

Section Editor: Austin Smith, MD

Submission history: Submitted January 2, 2021; Revision received March 25, 2021; Accepted April 1, 2021

Electronically published May 10, 2021

Full text available through open access at http://escholarship.org/uc/uciem_cpccm

DOI: 10.5811/cpcem.2021.4.51408

Introduction: Infectious aortitis is a rare condition with mortality rates approaching 100% without surgical intervention. Symptoms and findings may be vague. Computed tomography (CT) with intravenous (IV) contrast, once the gold standard of diagnosis, may only show subtle findings. More recently, CT angiography (CTA) and magnetic resonance angiography have become the diagnostic modalities of choice.

Case Report: A 58-year-old diabetic male presented to our emergency department with nausea, vomiting, diarrhea, fevers, and abdominal pain of two weeks duration. The patient had been seen just days before at another facility with the same complaints. He received an abdominal CT with IV contrast that was reported as negative and discharged with the diagnosis of gastroenteritis. He failed to improve and presented to our facility. On presentation, the patient was diaphoretic and uncomfortable. A repeat abdominal CT with IV contrast revealed a mantle of low density around the aorta. The patient was started on IV antibiotics, and a follow-up CTA of the abdomen and pelvis showed an irregular saccular aneurysm. Vascular surgery was consulted, and the patient underwent vascular reconstruction.

Conclusion: Because of the high level of mortality seen in infectious aortitis and improvement in patient outcomes with surgical intervention, a high index of suspicion needs to be maintained in patients presenting with fever and chest, abdominal, and back pain, especially in the setting of risk factors and bacteremia. The clinician should be aware that the usual modality for the evaluation of abdominal pain, CT with IV contrast, may not be adequate to make the diagnosis. [Clin Pract Cases Emerg Med. 2021;5(2):242–245.]

Keywords: *Case report; aortitis; enteritis; salmonella; mycotic aneurysm.*

INTRODUCTION

Infectious aortitis is a rare condition most commonly related to bacteremic seeding of pre-existing intimal injury. Mortality rates approach 100% without surgical intervention.¹⁻³ Symptoms are frequently vague and include abdominal and back pain, fevers, vomiting, and diarrhea. An initial workup in the emergency department (ED) using computed tomography (CT) with intravenous (IV) contrast may not be adequate to make the diagnosis. Computed tomography angiography (CTA) and magnetic resonance angiography (MRA) may need to be added

to the diagnostic workup to attain the diagnosis.^{4,5} Once infectious aortitis is suspected, early initiation of broad-spectrum antibiotics and vascular surgery consultation are critical.⁴ Given the high mortality rate of this condition if not properly identified and treated, it is imperative that emergency physicians be aware that CT with IV contrast alone may not diagnose this deadly disease.

CASE REPORT

A 58-year-old male presented to the ED for lower abdominal pain. The patient described two weeks of initially

diffuse abdominal pain, which then localized to bilateral lower quadrants with associated nausea and vomiting. Pain was exacerbated with food. The patient also reported subjective fevers, chills, decreased appetite, and diarrhea. There were no other sick contacts at home and no recent travel. The patient denied additional symptoms. His past medical history consisted of perforated diverticulitis in 1998 with 20 centimeters of bowel resection, type 2 diabetes, and hypertension. The patient had visited another hospital a few days prior and had a CT with IV contrast of the abdomen and pelvis, which reportedly was negative, and he was discharged home.

On presentation, the patient was afebrile with the following vitals: temperature 36.4 degrees Celsius; pulse 86 beats per minute; respiratory rate 18 breaths per minute; blood pressure 162/106 millimeters mercury; and 97% oxygen saturation on room air. On physical exam, he was diaphoretic and in mild distress with dry mucous membranes. Abdominal examination was significant only for moderate bilateral lower quadrant tenderness without peritoneal signs.

The patient's initial lab work revealed a white blood cell count of 18.52 thousand cells per cubic millimeter (mm^3) (reference range: 4.5 thousand to 11 thousand cells/ mm^3), and a lactic acid of 2.3 millimoles per liter (mmol/L) (zero to 2.3 mmol/L). The rest of the patient's labs were within normal limits. A CT of abdomen and pelvis with IV contrast was performed, which showed a mantle of low density surrounding the middle aorta with surrounding stranding and adjacent aortic calcification. A follow-up CTA abdomen and pelvis showed an irregular saccular aneurysm involving the anterior infrarenal abdominal aorta below the level of the inferior mesenteric artery with periaortic low density concerning for inflammatory or infectious aneurysm. The patient was initially placed on vancomycin and piperacillin/tazobactam for broad-spectrum antibiotic coverage. Vascular surgery was subsequently consulted.

On the following day the patient had excision of the infected aortic aneurysm, and reconstruction with homograft performed. Operative findings included a purulent hematoma anterior to the infrarenal aorta with surrounding inflammatory changes. The patient was found to have salmonella bacteremia. Infectious disease was consulted and changed antibiotic coverage to cefepime and then ceftriaxone based on sensitivities. After a 14-day admission, the patient was discharged home with no complications. He had a negative rheumatologic workup, a screening measure typically performed in the setting of infectious aortitis, and he was ultimately continued on six weeks of ceftriaxone through a peripherally inserted central catheter.

DISCUSSION

Aortitis is a relatively rare condition characterized by inflammation of the tunica media or intima layers of the aorta. If inflammation is isolated to the adventitia layer then it is referred to as periaortitis.^{6,7} The vast majority of cases

CPC-EM Capsule

What do we already know about this clinical entity?

Infectious aortitis is a rare condition which can occur in the setting of bacterial gastroenteritis and is associated with high mortality rates if not recognized and treated.

What makes this presentation of disease reportable?

This presentation demonstrates classic symptoms of the disease in a member of the traditionally at-risk population and despite this was not initially recognized.

What is the major learning point?

Computed tomography alone may not be enough to identify infectious aortitis, and computed tomography angiography should be considered in the appropriate clinical setting.

How might this improve emergency medicine practice?

This is an important addition to the emergency physician's differential diagnosis for febrile patients with chest and abdominal pain with potentially lifesaving consequences.

are non-infectious and are secondary to a rheumatologic etiology, the most common causes being giant cell arteritis and Takayasu arteritis.^{4,6} Additional non-infectious causes include rheumatoid arthritis, human leukocyte antigen B27-associated spondyloarthropathies, granulomatosis with polyangiitis, eosinophilic granulomatosis with polyangiitis, Behçet's disease, Cogan syndrome, and sarcoidosis.^{4,6} Infectious causes are particularly rare, but early identification is critical given a mortality rate approaching 100% without surgical intervention.¹⁻³

Pathogens involved in infectious aortitis are *Staphylococcus aureus* (the most common,) non-typhoidal salmonella as seen in our patient, *Streptococcus pneumoniae*, and group A streptococcus. Less common infectious causes include tuberculosis and syphilis. Prior to widespread vaccination, *Haemophilus influenzae* was another common cause.^{4,5}

Infectious aortitis is most commonly related to bacteremic seeding of a pre-existing intimal injury or atherosclerotic plaque. Additional mechanisms include spread of septic emboli to the vasa vasorum, which is often related to endocarditis, contiguous spread of local infection ultimately

extending to the wall of the aorta, or direct bacterial inoculation from trauma or manipulation.^{2,3} Infectious aortitis is commonly associated with mycotic aneurysms although it may occur as isolated aortitis as well.^{4,6} Aneurysmal involvement may be secondary to seeding of pre-existing aortic aneurysm or directly caused by destruction from inflammation.^{5,8} Neutrophilic infiltration of the vessel wall ultimately leads to breakdown of collagen and elastin, which can then progress to a saccular aneurysm. These aneurysms rapidly progress and are more likely to rupture than non-infected aneurysms.⁵ Risk factors include male gender, age > 50, diabetes, recent history of invasive catheterization, vascular risk factors such as hypertension and atherosclerosis, particularly a history of known aortic atherosclerosis, coronary artery disease, immunodeficiency, and solid organ cancer.^{1,3,5}

Classic symptoms observed in cases of aortitis are fever as well as back and abdominal pain.⁹ If there is an associated aneurysm, patients may have a pulsatile abdominal mass.⁵ Fever is present in approximately 75% of patients.² Symptoms typically present indolently with average duration of symptoms of around one month described in one case series.⁹ If associated with nontyphoidal salmonella (NTS), the patient may additionally have symptoms of nausea, vomiting, and diarrhea.

Standard lab evaluation includes complete blood count, erythrocyte sedimentation rate, C-reactive protein, and blood cultures.^{4,9} As most cases of aortitis are non-infectious, a rheumatologic panel to screen for non-infectious etiology is also reasonable.⁴ Leukocytosis is seen in 65-83% of patients.² Blood cultures are positive in the majority of cases.^{7,9} Of note, 5% of patients with NTS gastroenteritis ultimately develop bacteremia, of whom 40% go on to develop extraintestinal infection.¹ About 25% of patients over 50 found to have NTS bacteremia develop additional endovascular complications.³

Diagnosis is primarily made radiographically with multiple modalities showing utility. Computed tomography with IV contrast was originally the gold standard and is still recommended by some sources, although CTA and MRA have largely replaced it as the imaging modalities of choice.^{2,5} In particular, CTA allows for early visualization of vessel wall changes that can facilitate more timely diagnosis.¹⁰ Magnetic resonance imaging with gadolinium has shown utility and is used in conjunction with edema weighted technique.² Radiologic findings may include mural thickening, periaortic soft tissue density, vessel wall enhancement, periaortic gas, stranding, and aneurysm formation.² Point-of-care ultrasound is useful in screening for abdominal aortic aneurysm, although it is limited in its utility as an imaging modality for isolated aortitis.⁴

Once infectious aortitis is suspected, early initiation of broad-spectrum antibiotics and vascular surgery consultation are crucial.⁴ Antibiotics should be continued for two to four weeks prior to surgery, as long as the patient remains hemodynamically stable, to decrease inflammation and optimize local surgical conditions prior to intervention.^{1,2} Even

with early surgical intervention combined with antibiotics, the mortality rate of salmonella aortitis is around 40%.⁹ Surgical intervention involves extra anatomic bypass grafting or in situ graft placement.⁵ Endovascular aneurysm repair has utility as a temporizing measure in hemodynamically unstable patients with aortic rupture.³ Following surgical intervention, patients require a prolonged course of antibiotics, typically in the range of 6-12 weeks, although some sources recommend lifelong suppressive therapy in select cases.^{1,2,3,5} Clinical response and duration of treatment can be assessed through clearance of blood cultures and trending of inflammatory markers.^{3,4}

CONCLUSION

Infectious aortitis is a rare condition; however, given its high level of mortality and the dramatic difference in survival rates between patients intervened on surgically vs those treated medically, it should be considered in the differential diagnosis in patients presenting with fever, chest pain, and back pain, particularly in men over 50 with vascular risk factors. This is particularly true of patients found to be bacteremic. In patients specifically with NTS bacteremia following a primary gastrointestinal infection, it is important to maintain a high index of suspicion, particularly in the aforementioned high-risk group and especially when the patient fails to respond clinically to optimized medical therapy alone.

The authors attest that their institution requires neither Institutional Review Board approval, nor patient consent for publication of this case report. Documentation on file.

Address for Correspondence: Kevin M. Yanushefski, MD, St. Luke's University Health Network, Department of Emergency Medicine, 744 Ostrum St., Fountain Hill, PA 18015. Email: kevin.yanushefski@sluhn.org.

Conflicts of Interest: By the *CPC-EM* article submission agreement, all authors are required to disclose all affiliations, funding sources and financial or management relationships that could be perceived as potential sources of bias. The authors disclosed none.

Copyright: © 2021 Yanushefski et al. This is an open access article distributed in accordance with the terms of the Creative Commons Attribution ([CC BY 4.0](https://creativecommons.org/licenses/by/4.0/)) License. See: [http://creativecommons.org/licenses/by/4.0/](https://creativecommons.org/licenses/by/4.0/)

REFERENCES

1. Gardini G, Zanotti P, Pucci A, et al. Non-typhoidal salmonella aortitis. *Infection*. 2019;47(6):1059-63.
2. Lopes R, Almeida J, Dias P, et al. Infectious thoracic aortitis: a literature review. *Clin Cardiol*. 2009;32(9):488-90.

3. Hakim S, Davila F, Amin M, et al. Infectious aortitis: a life-threatening endovascular complication of nontyphoidal salmonella bacteremia. *Case Rep Med*. 2018;2018:1-5.
4. Gornik HL and Creager MA. Aortitis. *Circulation*. 2008;117(23):3039-51.
5. Deipolyi AR, Czaplicki CD, Oklu R. Inflammatory and infectious aortic diseases. *Cardiovasc Diagn Ther*. 2018;8(Suppl 1): S61-70.
6. Stone JR, Bruneval P, Angelini A, et al. Consensus statement on surgical pathology of the aorta from the Society for Cardiovascular Pathology and the Association for European Cardiovascular Pathology: I. Inflammatory Diseases. *Cardiovasc Pathol*. 2015;24(5):267-78.
7. Døssing A and Mattsson N. Infectious aortitis: Could early radiology improve patient outcome? *Eur J Case Rep Inten Med*. 2018;5(11):000967.
8. Barry IP. Mycotic Abdominal aortic aneurysm in the endovascular era. *Cureus*. 2019;11(11):e61119.
9. Soravia-Dunand VA, Loo VG, Salit IE. Aortitis due to salmonella: report of 10 cases and comprehensive review of the literature. *Clin Infect Dis*. 1999;29(4):862-8.
10. Rabiyeaneuh P. Eurorad: panaortitis. 2019. Available at: <https://www.eurorad.org/case/16437>. Accessed March 3, 2021.

Accidental Arthrotomy Causing Aseptic Monoarthritis Due to Agave Sap: A Case Report

Sam T. Ontiveros, MD
Alicia B. Minns, MD

University of California, San Diego, Department of Emergency Medicine, San Diego, California

Section Editor: Steven Walsh, MD

Submission history: Submitted January 20, 2021; Revision received March 24, 2021; Accepted April 1, 2021

Electronically published May 6, 2021

Full text available through open access at http://escholarship.org/uc/uciem_cpem

DOI: 10.5811/cpcem.2021.4.51835

Introduction: Aseptic inflammatory arthritis has been reported from thorns or cactus needles after inadvertent arthrotomy. Agave sap irritants may cause an aseptic inflammatory arthritis mimicking a septic joint.

Case Report: A 27-year-old male presented with left knee pain and swelling two hours after suffering an accidental stab wound to his left lateral knee by an agave plant spine. Synovial fluid white blood cell count was 92,730 mm³ with 75% neutrophils and no crystals. Surgical washout was remarkable for turbid fluid and no foreign body. Synovial fluid and blood cultures remained without growth. At two-week follow-up, the patient had recovered.

Conclusion: Penetrating injuries from agave thorns can cause an inflammatory arthritis that mimics septic arthritis. [Clin Pract Cases Emerg Med. 2021;5(2):246–248.]

Keywords: *Agave; septic arthritis; inflammatory arthritis; plant.*

INTRODUCTION

Agave is a genus of flowering plants native to hot and arid regions. Most agave species have a sharp terminal spine and are very fibrous. *Agave Americana* is one of 300 species of agave and is native to the southwestern United States and Mexico.¹ Contact with agave has previously been reported to cause both vesiculopapular and purpuric dermatitis. Causative agents are believed to be steroidal saponins and calcium oxalate crystals in agave sap.¹ Aseptic inflammatory arthritis has been reported from foreign bodies such as thorns or cactus needles after inadvertent arthrotomy. Here we describe a case of aseptic inflammatory arthritis caused by agave sap irritants without foreign body that mimicked septic arthritis.

CASE REPORT

A 27-year male presented to the emergency department (ED) with malaise, left knee pain, and swelling two hours after suffering an accidental stab wound to his left lateral knee by an agave plant spine. The patient rapidly developed knee pain, swelling, erythema, and inability to range the joint,

prompting his ED visit. He had no history of intravenous drug use, sexually transmitted infection, or current genitourinary complaints. On examination, he had a temperature of 97.3°F, blood pressure 143/73 millimeters mercury, heart rate of 89 beats per minute, and oxygen saturation of 99% on room air. Exam revealed a warm, erythematous, and swollen joint with a range of motion limited by significant pain. He had a small puncture wound noted to the lateral aspect of his left knee. The patient provided a photograph of the actual plant for identification (Image 1).

Diagnostic testing included a white blood cell count (WBC) of 14 (1,000/ cubic millimeters [mm³]), erythrocyte sedimentation rate of 2 millimeters per hour (mm/hr) (normal 0-15 mm/hr), C-reactive protein of 2.2 milligrams per deciliter (mg/dL) (normal < 0.5mg/dL), and serum lactate was 2.6 millimoles per liter (mmol/L) (normal 0.5-2.0 mmol/L). The remainder of his complete blood count and basic metabolic panel was within normal limits. Radiograph of the knee demonstrated a moderately sized joint effusion without foreign bodies or bony abnormalities (Image 2). Arthrocentesis performed in the



Image 1. Photograph taken by patient of agave plant.




Image 2. Radiograph of the left knee demonstrating a moderately sized effusion (arrow) without foreign body in a patient whose knee was punctured by an Agave plant spine.

ED showed synovial fluid WBC was 92,730 mm³ with 75% neutrophils and no crystals. Gram stain was negative. The patient was taken for a left knee arthrotomy where approximately 100 cubic centimeters of purulent fluid was drained, and his knee was irrigated. No foreign body was found. Synovial fluid cultures (bacterial and fungal) and blood cultures remained without growth. Urine gonorrhea/chlamydia polymerase chain reaction testing was negative. Biopsy of the left knee synovium and fat demonstrated mild neutrophilic infiltrates and no fungal elements. Intravenous antibiotics (vancomycin and piperacillin/tazobactam) were started prior to incision and drainage; however, they were stopped on postoperative day 1. At a two-week follow-up appointment, he reported minimal residual discomfort that was treated with naproxen.

DISCUSSION

We present a case of penetrating injury with an agave spine mimicking septic arthritis. Interestingly, no foreign body was

CPC-EM Capsule

What do we already know about this clinical entity?

Exposure to Agave plants has been reported to cause skin irritation and rashes. Plant arthrotomies can lead to an inflammatory arthritis and a foreign body is often found during surgery.

What makes this presentation of disease reportable?

To our knowledge, accidental arthrotomy from an Agave plant leading to inflammatory arthritis has not been reported.

What is the major learning point?

The irritating sap of the Agave can cause an inflammatory arthritis that mimics septic arthritis if introduced into a joint.

How might this improve emergency medicine practice?

Although rare, physicians need to consider plant injury when evaluating patients with a rapidly developing monoarticular arthritis.

found during operative washout, making this case unlike prior reported cases of monoarticular arthritis from plant injuries. There are published case reports describing plant injuries causing a monoarticular arthritis, such as plant thorn synovitis; however, in almost all cases, a foreign body was found during arthroscopy or arthrotomy.^{2,3} Salient features in these reported cases include the rapid onset of symptoms from time of injury and the presence of a penetrating wound, which were also present in our case. In many published cases, radiograph is of limited diagnostic benefit as a foreign body is not always seen. Imaging is helpful in excluding other etiologies of joint pain, especially if a history of plant injury is not provided.^{2,4} Formal or point-of-care ultrasonography was not performed in this case, but it has been demonstrated to be helpful in localizing foreign bodies not seen on plain radiography.⁵ Ultrasound guidance may also improve aspiration success during arthrocentesis.⁶

As a general rule, the causative bacteria in most cases of septic arthritis are Gram-positive organisms such as *Staphylococcus aureus*, with increasing incidence of methicillin resistance. *Neisseria gonorrhoeae* usually occurs in younger adults, although these patients typically present with migratory polyarthritis, a pustular rash, and urethritis.⁷

While a rare cause of septic arthritis, Lyme arthritis is the most common manifestation of late-stage Lyme disease, and should be considered in patients who reside in endemic areas.⁸ Septic arthritis caused by plant injuries have been infrequently described, but should be considered when evaluating patients presenting with a monoarticular arthritis. *Pantoea agglomerans* is a Gram-negative bacterium belonging to the family Enterobacteriaceae, and can be found in human and animal feces and in plants.⁹ *P. agglomerans* is rare, but has been described in several cases of arthritis or synovitis caused by plant thorns, classically the palm tree thorn.⁴ Diagnosis is often delayed due to the low virulence of this organism and difficulty in culturing it.⁹

Agave americana, the causative plant in this case, has historically been used to create rope, vinegar, syrups, and fermented drinks, in addition to its contemporary use as a decorative plant.¹ *A. americana* is more commonly known as the “century plant” because it was originally believed to only flower once every 100 years.¹⁰ *A. americana* contains calcium oxalate crystals and saponins, which have been reported to cause cutaneous reactions after contact, such as irritant dermatitis and vesiculopapular eruptions.^{1,10} Bundles (raphides) of sharp calcium oxalate crystals also occur in other plants such as *Dieffenbachia amoena* (a common house plant also known as dumb cane) and are notorious for causing irritation to skin and mucous membranes on contact.¹¹ We postulate that in our case the severely irritating sap of *A. americana* caused an acute inflammatory arthritis when introduced into the joint.

CONCLUSION

Although plant injuries to the joint are uncommon, it should be considered in cases of rapidly developing acute monoarticular arthritis. A history of penetrating injury from a plant is often overlooked. It is recommended that in the presence of a penetrating injury, arthroscopic washout or formal arthrotomy with inspection of the joint be pursued, because there are multiple published examples of recurrent episodes of joint sepsis/synovitis due to retained plant material.³ In our case a history of plant injury was provided, and the irritating sap of agave caused an inflammatory arthritis without foreign body.

The authors attest that their institution requires neither Institutional Review Board approval, nor patient consent for publication of this case report. Documentation on file.

Address for Correspondence: Alicia B. Minns, MD, University of California, San Diego, Department of Emergency Medicine, 200 West Arbor Drive, MC 8676, San Diego, CA 92103. Email: aminns@health.ucsd.edu.

Conflicts of Interest: By the CPC-EM article submission agreement, all authors are required to disclose all affiliations, funding sources and financial or management relationships that could be perceived as potential sources of bias. The authors disclosed none.

Copyright: © 2021 Ontiveros et al. This is an open access article distributed in accordance with the terms of the Creative Commons Attribution (CC BY 4.0) License. See: <http://creativecommons.org/licenses/by/4.0/>

REFERENCES

1. Brazzelli V, Romano E, Balduzzi A, et al. Acute irritant contact dermatitis from *Agave americana* L. *Contact Dermatitis*. 1995;33(1):60-1.
2. Olenginski TP, Bush DC, Harrington TM. Plant thorn synovitis: an uncommon cause of monoarthritis. *Semin Arthritis Rheum*. 1991;21(1):40-6.
3. Clarke JD and McCaffrey DD. Thorn injury mimicking a septic arthritis of the knee. *Ulster Med J*. 2007;76(3):164-5.
4. Kratz A, Greenberg D, Barki Y, et al. *Pantoea agglomerans* as a cause of septic arthritis after palm tree thorn injury; case report and literature review. *Arch Dis Child*. 2003;88(6):542-4.
5. Bray H, Stringer DA, Poskitt K, et al. Maple tree knee: a unique foreign body--value of ultrasound and CT examination. *Pediatr Radiol*. 1991;21(6):457-8.
6. Wu T, Dong Y, Song Hx, et al. Ultrasound-guided versus landmark in knee arthrocentesis: a systematic review. *Semin Arthritis Rheum*. 2016;45(5):627-32.
7. Long B, Koyfman A, Gottlieb M. Evaluation and management of septic arthritis and its mimics in the emergency department. *West J Emerg Med*. 2019;20(2):331-41.
8. Long KC and Cohn KA. Lyme arthritis: an update for clinical practice. *Pediatr Emerg Care*. 2018;34(8):588-591.
9. Rave O, Assous MV, Hashkes PJ, et al. *Pantoea agglomerans* foreign body-induced septic arthritis. *Pediatr Infect Dis J*. 2012;31(12):1311-2.
10. Cherpelis BS and Fenske NA. Purpuric irritant contact dermatitis induced by *Agave americana*. *Cutis*. 2000;66(4):287-8.
11. Kerner J, Mitchell J, Maibach HI. Irritant contact dermatitis from *Agave americana* L. Incorrect use of sap as “hair restorer.” *Arch Dermatol*. 1973;108(1):102-3.

Bilateral Luxatio Erecta Humeri

Miguel A. Martinez-Romo, MD
Shahram Lotfipour, MD, MPH
C. Eric McCoy, MD, MPH

University of California, Irvine Medical Center, Department of Emergency Medicine,
Orange, California

Section Editor: Melanie Heniff, MD

Submission history: Submitted December 18, 2020; Revision received January 21, 2021; Accepted January 14, 2021

Electronically published March 1, 2021

Full text available through open access at http://escholarship.org/uc/uciem_cpem

DOI: 10.5811/cpcem.2021.1.51255

Case Presentation: We describe a middle-aged male presenting to the emergency department with bilateral shoulder pain, holding both arms in abduction after trauma. Radiographs demonstrated a bilateral inferior dislocation of the glenohumeral joints consistent with luxatio erecta humeri.

Discussion: We review the clinical presentation of luxatio erecta and its complications. We also describe the characteristic presentation on radiographs. Our case illustrates the hallmark findings of luxatio erecta of an abducted humeral shaft parallel to the scapular spine. [Clin Pract Cases Emerg Med. 2021;5(2):249–250.]

Keywords: *Luxatio erecta; bilateral luxatio erecta; luxatio erecta humeri; shoulder dislocation; inferior glenohumeral dislocation.*

CASE PRESENTATION

A 53-year-old male with a history of diabetes presented to the emergency department (ED) with bilateral shoulder pain. He was the victim of a carjacking; he held on to his car as the perpetrator sped away, was subsequently dragged, and then run over by the vehicle. He presented with both arms fully abducted and fixed. Imaging revealed bilateral inferior dislocation of the glenohumeral joint consistent with bilateral luxatio erecta, which were reduced in the ED (Images 1-3).

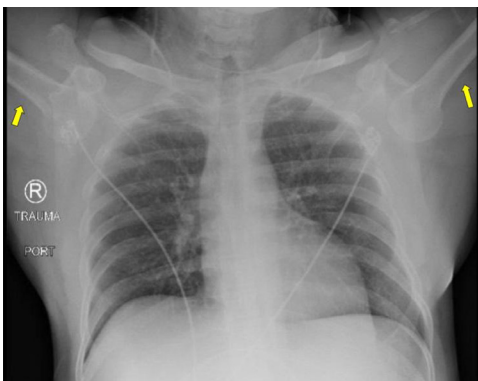

Image 1. The patient presented with his humeri in fixed abduction (yellow arrows).

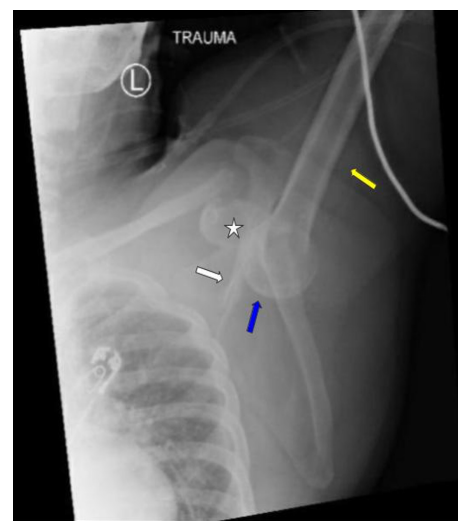


Image 2. Left shoulder radiograph demonstrating the shaft of the humerus (yellow arrow) in fixed abduction. The humeral head (blue arrow) is inferior to the glenoid fossa (star). Note the scapular spine (white arrow) is almost parallel to the shaft of the humerus (yellow arrow).

DISCUSSION

Luxatio erecta humeri is the inferior dislocation of the glenohumeral joint.^{1,2} Luxatio erecta makes up 0.5% of all

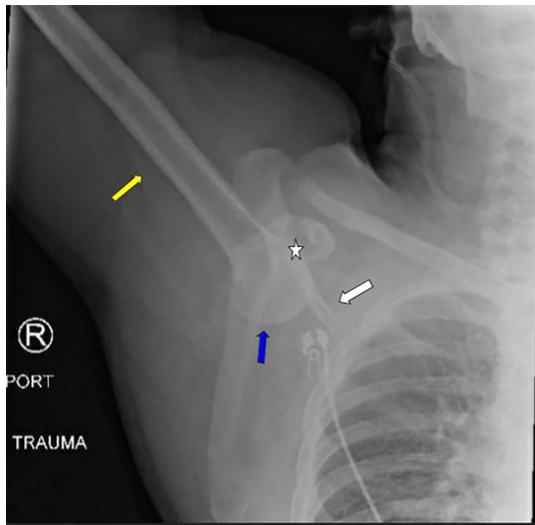


Image 3. Right shoulder radiograph demonstrating the shaft of the humerus (yellow arrow) in fixed abduction. The humeral head (blue arrow) is inferior to the glenoid fossa (star). Note the scapular spine (white arrow) is almost parallel to the shaft of the humerus (yellow arrow).

shoulder dislocations, making a bilateral presentation even more rare.^{1,2} By comparison, anterior dislocations make-up 95-97% of dislocations, while posterior dislocations make up 2-4% of all dislocations.¹ Luxatio erecta can happen in any age group, infants to elderly, with the classic presentation being a person who presents with fixed hyperabduction of the arm at the shoulder, flexion at the elbow, and pronation of the forearm.^{1,2} The mechanism of injury is a direct loading force on a full abducted arm or a sudden hyperabduction of an abducted arm.²

Radiographs will demonstrate the humeral heads at the subglenoid region, with an abducted humeral shaft almost parallel to the scapular spine.³ Treatment involves reduction of the joint, which can be achieved by performing procedural sedation followed by the traction-countertraction technique.^{1,4} Thereafter, the patient's arm is put into a sling in full adduction for immobilization, and 1-2 week orthopedic follow-up should be arranged.^{1,2,4} Complications include avulsed shoulder capsule, torn rotator cuff tendons or injury to adjacent muscles, fractures of the acromion, clavicle, inferior glenoid fossa, or greater tuberosity, brachial plexus injuries, and axillary vessel injury.^{1,3}

The authors attest that their institution requires neither Institutional Review Board approval, nor patient consent for publication of this case report. Documentation on file.

CPC-EM Capsule

What do we already know about this clinical entity?

Luxatio erecta humeri is a rare presentation of a shoulder dislocation, with a bilateral presentation being even more rare.

What is the major impact of the image(s)?

Patients have a hyperabducted arm, imaging reveals a subglenoid humeral head, and treatment involves reduction.

How might this improve emergency medicine practice?

Proper recognition allows for reduction, immobilization, and arrangement of Orthopedic follow-up, all of which can potentially reduce long-term sequelae.

Address for Correspondence: C. Eric McCoy, MD, MPH, University of California, Irvine Medical Center, Department of Emergency Medicine, 333 City Boulevard West, Suite 640, Orange, CA 92868. Email: cmccoy@hs.uci.edu.

Conflicts of Interest: By the CPC-EM article submission agreement, all authors are required to disclose all affiliations, funding sources and financial or management relationships that could be perceived as potential sources of bias. The authors disclosed none.

Copyright: © 2021 Martinez-Romo et al. This is an open access article distributed in accordance with the terms of the Creative Commons Attribution (CC BY 4.0) License. See: <http://creativecommons.org/licenses/by/4.0/>

REFERENCES

1. Grate I. Luxatio erecta: a rarely seen, but often missed shoulder dislocation. *Am J Emerg Med.* 2000;18(3):317-21.
2. Petty K, Price J, Kharasch M, et al. Bilateral luxatio erecta: a case report. *J Emerg Med.* 2014;46(2):176-9.
3. Ngam PI, Hallinan JT, Sia DSY. Sequelae of bilateral luxatio erecta in the acute post-reduction period demonstrated by MRI: a case report and literature review. *Skeletal Radiol.* 2019;48(3):467-73.
4. Mills LD, Barrows T, Benitez F. Bilateral luxatio erecta. *J Emerg Med.* 2003;24(1):61-3.

Adolescent Male with Severe Groin Pain Due to Traumatic Injury

Hirofumi Ohno, MD*
Shinsuke Takeda, MD, PhD*†
So Mitsuya, MD*†
Ken-ichi Yamauchi, MD, PhD*

*Toyohashi Municipal Hospital, Department of Orthopedic Surgery, Toyohashi Aichi, Japan
†Toyohashi Municipal Hospital, Trauma and Microsurgery Center, Toyohashi Aichi, Japan

Section Editor: Anna McFarlin, MD

Submission history: Submitted September 5, 2020; Revision received November 28, 2020; Accepted December 7, 2020

Electronically published March 24, 2021

Full text available through open access at http://escholarship.org/uc/uciem_cpem

DOI: 10.5811/cpcem.2020.12.49730

Case Presentation: A 14-year-old boy presented to the emergency department complaining of severe groin pain on the right side following a minor fall. Computed tomography and magnetic resonance imaging revealed a hematoma in his right iliacus muscle. He was diagnosed with a traumatic iliacus hematoma, and he recovered spontaneously with short-term oral analgesics.

Discussion: Traumatic iliacus hematomas are rare entities and subside with conservative management in most cases. However, this condition may be associated with femoral nerve palsy, and surgery is indicated in severe cases. Traumatic iliacus hematoma should be considered in the differential diagnosis of severe groin pain. [Clin Pract Cases Emerg Med. 2021;5(2):251–252.]

Keywords: *Traumatic iliacus hematomas; Iliacus hematomas.*

CASE PRESENTATION

A 14-year-old boy with no past medical history presented to the emergency department (ED) complaining of severe groin pain on the right side following a minor fall incurred while playing handball. On physical examination, he could not actively move his right hip and was unable to walk. He had no neurological symptoms. Computed tomography (CT) showed swelling of the right iliacus muscle (Image 1). Therefore, magnetic resonance imaging (MRI) was performed to confirm this mass (Image 2). The final diagnosis was traumatic iliacus hematoma.

DISCUSSION

Iliacus hematomas are rare, and but they are often complicated in patients with hemophilia and in those receiving anticoagulants¹; however, some cases of post-traumatic hematomas have been reported previously.^{2,3} The most prevalent cause of iliacus hematomas is traumatic injuries, particularly those that are sports-related and that occur in young patients.² Such injuries are often complicated by femoral nerve palsy. Because the femoral nerve travels between the psoas and iliacus muscles, hematoma of these muscles tends to compress the femoral

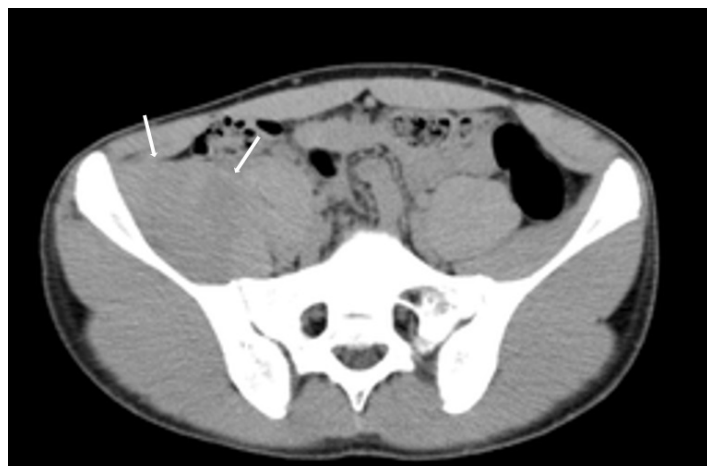

Image 1. Contrast-enhanced computed tomography showing the enlarged right iliacus muscle (arrows).

nerve.¹ This condition is clinically characterized by weakness of the iliopsoas muscle, loss of the knee-jerk reflex, and anteromedial thigh hypoesthesia.⁴

Conservative management is preferred for patients with mild symptoms, as the hematoma may subside by the tamponade

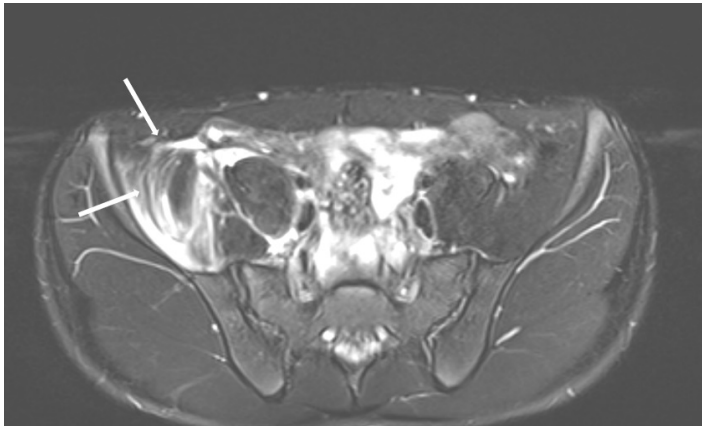


Image 2. T2-weighted magnetic resonance imaging showing a high-intensity lesion in the right iliac muscle (arrows).

effect. However, if symptoms progress, invasive interventions such as CT-guided drainage and surgical decompression should be considered. In this case, two weeks of oral acetaminophen alleviated the symptoms. Emergency physicians should consider traumatic iliacus hematoma in the differential diagnoses of severe groin pain, regardless of the patient's medical history.

Patient consent has been obtained and filed for the publication of this case report.

Address for Correspondence: Shinsuke Takeda, MD, PhD, Toyohashi Municipal Hospital, Department of Trauma and Microsurgery, 441-8570, 50, Hachikennishi, Aotakecho, Toyohashi, Aichi, Japan. Email: s7.takeda.jpn@gmail.com.

Conflicts of Interest: By the CPC-EM article submission agreement, all authors are required to disclose all affiliations, funding sources and financial or management relationships that could be perceived as potential sources of bias. The authors disclosed none.

Copyright: © 2021 Takeda et al. This is an open access article distributed in accordance with the terms of the Creative Commons Attribution (CC BY 4.0) License. See: <http://creativecommons.org/licenses/by/4.0/>

CPC-EM Capsule

What do we already know about this clinical entity?

Traumatic iliacus hematoma is a benign and rare condition caused by traumatic injuries, especially those that are sports related. In some cases, it might be complicated by femoral nerve palsy.

What is the major impact of the image(s)?

Computed tomography is not enough for diagnosis of iliacus hematoma. If this condition is suspected, a magnetic resonance imaging should be performed.

How might this improve emergency medicine practice?

Emergency physicians should consider traumatic iliacus hematoma in the differential diagnosis of severe groin pain. Regarding our case, those who have no medical condition can suffer traumatic iliacus hematoma.

REFERENCES

1. Lefevre N, Bohu Y, Klouche S, et al. Complete paralysis of the quadriceps secondary to post-traumatic iliopsoas hematoma: a systematic review. *Eur J Orthop Surg Traumatol.* 2015;25(1):39-43.
2. Kim SJ, Park HS, Lee DW. Iliacus hematoma syndrome: a systematic review of recent literature and case report. *Injury.* 2020;51(8):1744-50.
3. Murray IR, Perks FJ, Beggs I, et al. Femoral nerve palsy secondary to traumatic iliacus haematoma: a young athlete's injury. *BMJ Case Rep.* 2010;2010:bcr0520103045.
4. Yi TI, Yoon TH, Kim JS, et al. Femoral neuropathy and meralgia paresthetica secondary to an iliacus hematoma. *Ann Rehabil Med.* 2012;36(2):273-7.

A Young Boy with Neck Pain

Hirofumi Ohno, MD*

Shinsuke Takeda, MD, PhD**

So Mitsuya, MD**

Hisatake Yoshihara, MD, PhD**

Ken-ichi Yamauchi, MD, PhD*

*Toyohashi Municipal Hospital, Department of Orthopedic Surgery, Toyohashi, Japan

†Toyohashi Municipal Hospital, Department of Trauma and Microsurgery, Toyohashi, Japan

‡Toyohashi Municipal Hospital, Department of Spine Surgery, Toyohashi, Japan

Section Editor: Melanie Heniff, MD

Submission history: Submitted October 13, 2020; Revision received November 28, 2020; Accepted December 9, 2020

Electronically published March 24, 2021

Full text available through open access at http://escholarship.org/uc/uciem_cpem

DOI: 10.5811/cpem.2020.12.50242

Case Presentation: A five-year-old boy presented to our emergency department with severe posterior neck pain that was exacerbated upon neck movement. Cervical spine radiography revealed calcification in the cervical intervertebral disk 3-4.

Discussion: Pediatric idiopathic intervertebral disk calcification is a benign, rare condition that might be complicated by associated severe neurological symptoms. In this case, the symptoms gradually subsided with conservative management alone. [Clin Pract Cases Emerg Med. 2021;5(2):253–254.]

Keywords: *Pediatric idiopathic intervertebral disk calcification; neck pain; PIIVDC calcification.*

CASE PRESENTATION

A five-year-old male with a history of asthma presented with complaints of neck pain that had persisted for one month. The pain exacerbated on bowing or exercising. Physical examination revealed that pain was elicited on performing neck movements, especially flexion-extension; neurological symptoms were not noted. Cervical spine radiograph was obtained (Image).

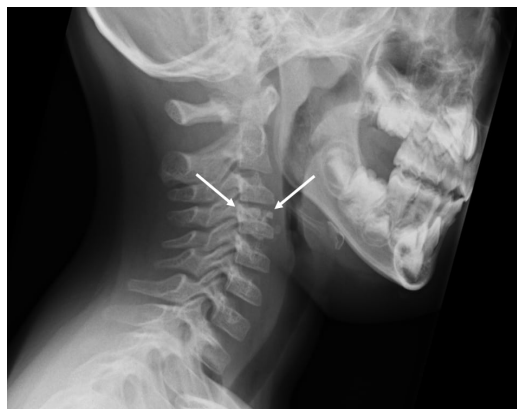

Image. Cervical spine lateral radiograph showing the calcification in the cervical intervertebral disk 3-4 (arrow). This radiological abnormality is not clearly visible on an anterior-posterior view.

DISCUSSION

Pediatric idiopathic intervertebral disk calcification (PIIVDC) is a rare cause of neck pain in children, especially boys, 5-12 years of age, and is attributed to calcification of the intervertebral disks.^{1,2} Since its first description in 1924, more than 300 cases of PIIVDC have been reported, but it is not well known to emergency physicians. PIIVDC can affect any spinal cord region, although it mostly affects the cervical spine, especially the cervical intervertebral disk 3-4 or 6-7.¹ The etiology of PIIVDC remains unclear. Trauma, infection, nutritional supply, metabolic disorders, and hereditary deficit may be related to PIIVDC.² The most common clinical symptoms of PIIVDC are neck pain and stiffness followed by muscle spasm, low-grade fever, radiating pain, and torticollis due to local inflammation of the nucleus pulposus.^{1,2}

Neurological complications develop when the calcification herniates and compresses the nerve root or spinal cord.¹ Conservative management, including administration of analgesics, nonsteroidal anti-inflammatory medication, muscle relaxants, use of cervical soft collars, and rest, is preferred in most cases because the symptoms are generally self-limiting and resolve within a few months. The calcified lesions may remain asymptomatic for some time.^{1,2} If neurological impairment progresses, surgical treatment, such as laminectomy or discectomy and fusion, should be considered.³

In our case, the symptoms gradually improved with conservative treatment. Physicians involved in emergency care should consider PIIVDC during the differential diagnosis of children with neck pain.

Documented patient informed consent and/or Institutional Review Board approval has been obtained and filed for publication of this case report.

Address for Correspondence: Shinsuke Takeda, MD, PhD, Trauma and Microsurgery Center, Toyohashi Municipal Hospital, 50 Aza Hachiken Nishi, Aotake-Cho, Toyohashi, Aichi 441-8570, Japan. Email: s7.takeda.jpn@gmail.com.

Conflicts of Interest: By the CPC-EM article submission agreement, all authors are required to disclose all affiliations, funding sources and financial or management relationships that could be perceived as potential sources of bias. The authors disclosed none.

Copyright: © 2021 Ohno et al. This is an open access article distributed in accordance with the terms of the Creative Commons Attribution (CC BY 4.0) License. See: <http://creativecommons.org/licenses/by/4.0/>

REFERENCES

1. Tsutsumi S, Yasumoto Y, Ito M. Idiopathic intervertebral disc calcification in childhood: a case report and review of literature. *Childs Nerv Syst.* 2011;27(7):1045-51.
2. Dushnicky MJ, Okura H, Shroff M, et al. Pediatric idiopathic intervertebral disc calcification: single-center series and review of the literature. *J Pediatr.* 2019;206:212-6.
3. Chu J, Wang T, Pei S, et al. Surgical treatment for idiopathic intervertebral disc calcification in a child: case report and review of the literature. *Childs Nerv Syst.* 2015;31(1):123-7.

CPC-EM Capsule

What do we already know about this clinical entity?

Pediatric idiopathic intervertebral disc calcification (PIIVDC) is a benign, rare condition with unclear etiology.

What is the major impact of the image(s)?

PIIVDC is easily diagnosed with a plain radiograph. We should consider cervical spine radiograph as the initial test for children with neck pain.

How might this improve emergency medicine practice?

Emergency physicians should consider PIIVDC in their differential diagnosis of children with neck pain.

Rare but Foreseeable: Rapidly Expanding Retropharyngeal Hematoma After Fall from Height

Alexander Bracey, MD*
Christine S. Ahn, MD†
Ryan N. Barnicle, MD†
Michael P. Frost, MD†
Marshall N. Leonard, MD†
Brian J. Wright, MD†

*Albany Medical Center, Department of Emergency Medicine, Albany, New York
†Stony Brook University, Department of Emergency Medicine, Stony Brook, New York

Section Editor: Melanie Heniff, MD

Submission history: Submitted December 9, 2020; Revision received January 28, 2021; Accepted February 2, 2021

Electronically published March 12, 2021

Full text available through open access at http://escholarship.org/uc/uciem_cpccem

DOI: 10.5811/cpcem.2021.2.51119

Case Presentation: An elderly man presented to the emergency department after a fall from a 15-foot height. Initial examination revealed signs of head and neck trauma without airway compromise. Computed tomography imaging identified cervical fractures at the first and second level with a retropharyngeal hematoma. In discussion with the trauma service, the patient was admitted to the hospital for airway monitoring. After 10 hours he clinically deteriorated, resulting in acute respiratory failure, and ultimately required intubation. The patient was intubated with a hyperangulated video laryngoscopy, and a surgical set-up was also prepared. The intubation was uncomplicated and resulted in clinical improvement. The patient was extubated after three days without difficulty and was ultimately discharged following an uncomplicated hospital course.

Discussion: Retropharyngeal hematoma is a rare but significant clinical condition. Rapid decline and airway compromise have been described. Patients often require intubation and mechanical ventilation to avoid airway obstruction and respiratory failure. Coagulopathies should be reversed, if present. Prompt recognition and treatment of this condition is crucial to successful management. [Clin Pract Cases Emerg Med. 2021;5(2):255–257.]

Keywords: *Critical care; airway; trauma; retropharyngeal hematoma.*

CASE PRESENTATION

A 79-year-old man with Parkinson dementia presented to the emergency department after an unwitnessed fall from a 15-foot ladder. The patient was amnesic to the event. He did not take anticoagulant or antiplatelet medications. He had facial bruising on exam and midline cervical spine tenderness, but no stridor or increased respiratory effort. The trauma team was activated, and the patient underwent emergent computed tomography, including arterial angiography of the head and neck (Image 1 and 2) as part of routine screening for blunt cerebrovascular injury. These images revealed displaced fractures at the first and second cervical levels with associated active retropharyngeal hematoma at the level of the hypoglottis.

Computed tomography of the chest, abdomen, and pelvis were also obtained as part of a trauma Level 1 activation order

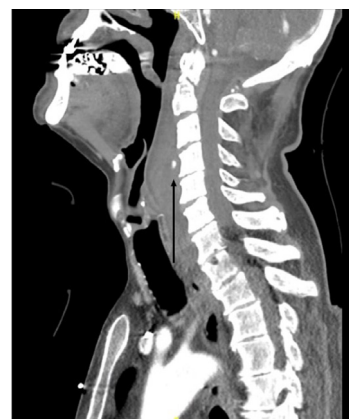

Image 1. Computed tomography neck angiography demonstrating retropharyngeal hematoma with contrast extravasation (arrow) at the third and fourth cervical level, sagittal view.

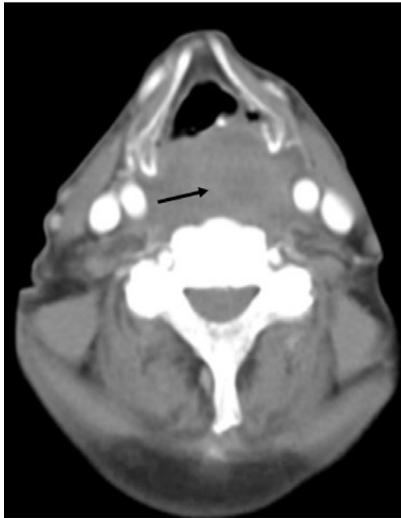


Image 2. Computed tomography neck angiography demonstrating a 2.72-centimeter retropharyngeal hematoma, axial view (arrow).

set. Nearly 10 hours after initial presentation, the patient developed respiratory distress and desaturated, requiring endotracheal intubation. This was performed by anesthesia using hyperangulated video laryngoscopy with an unobstructed view of the glottic structures resulting in a first-pass success and clinical improvement. Neurosurgery was consulted for possible embolization; however, no intervention was performed as it was a venous bleed. The patient was extubated after three days without complication and was discharged after an uncomplicated hospital course.

DISCUSSION

Retropharyngeal hematoma is a rare but important clinical condition. The retropharyngeal space is small, with the average space between the vertebral body and the posterior aspect of the upper airway ranging between 3-14 millimeters depending on the cervical level.¹ Blunt and penetrating neck trauma is a common cause, and it also appears to be associated with anticoagulant use and displaced cervical spine fracture.^{2,3} Other reported causes include vigorous coughing, retropharyngeal infection, local surgery, pharyngeal foreign bodies, spontaneous hemorrhage, and parathyroid tumors.⁴ Risk factors associated with the development of retropharyngeal hematoma include anticoagulant use, coagulopathies, vascular lesions, and vertebral bone disorders. Rapid decline can occur especially when signs of respiratory compromise exist, which may result in anoxic injury and death; therefore, emergency physicians should have a low threshold to secure the airway and coagulopathies should be promptly reversed if present.^{3,5}

A double endotracheal and surgical airway setup should be strongly considered, as it may not be possible to pass an endotracheal tube from above the larynx depending on the size and extent of the hematoma.⁴ Emergent surgical airway (eg, cricothyroidotomy, tracheostomy) may be preferable to endotracheal intubation in the presence of airway obstruction

CPC-EM Capsule

What do we already know about this clinical entity?

Retropharyngeal hematoma is rare. Displaced cervical fractures and anticoagulant use are risk factors for retropharyngeal hematoma and may cause airway compromise.

What is the major impact of the image(s)?

The images demonstrate that the retropharyngeal space is small. Even relatively minor bleeding in this space can compress airway structures and cause respiratory failure.

How might this improve emergency medicine practice?

This disease may go unrecognized initially as signs of airway compromise may be delayed. Standard and surgical airway set-ups should be prepared if the airway must be controlled.

to avoid disruption of the hematoma.⁶ High suspicion and prompt management are necessary to successfully treat patients present with retropharyngeal hematoma. Definitive treatment may include arterial embolization or decompressive surgery, although conservative management is often adequate.^{6,7}

The authors attest that their institution requires neither Institutional Review Board approval, nor patient consent for publication of this case report. Documentation on file.

Address for Correspondence: Alexander Bracey, MD, Albany Medical Center, Department of Emergency Medicine, 43 New Scotland Ave, Albany, NY 12208. Email: braceya@amc.edu.

Conflicts of Interest: By the CPC-EM article submission agreement, all authors are required to disclose all affiliations, funding sources and financial or management relationships that could be perceived as potential sources of bias. The authors disclosed none.

Copyright: © 2021 Bracey et al. This is an open access article distributed in accordance with the terms of the Creative Commons Attribution (CC BY 4.0) License. See: <http://creativecommons.org/licenses/by/4.0/>

REFERENCES

1. Wholey MH, Bruwer AJ, Baker HL Jr. The lateral roentgenogram of the neck; with comments on the atlanto-odontoid-basion

- relationship. *Radiology*. 1958;71(3):350-6.
2. Karmacharya P, Pathak R, Ghimire S, et al. Upper airway hematoma secondary to warfarin therapy: a systematic review of reported cases. *N Am J Med Sci*. 2015;7(11):494-502.
 3. Iizuka S, Morita S, Otsuka H, et al. Sudden asphyxia caused by retropharyngeal hematoma after blunt thyrocervical artery injury. *J Emerg Med*. 2012;43(3):451-6.
 4. Duvillard C, Ballester M, Romanet P. Traumatic retropharyngeal hematoma: a rare and critical pathology needed for early diagnosis. *Eur Arch Otorhinolaryngol*. 2005;262(9):713-5.
 5. Tenofsky PL, Porter SW, Shaw JW. Fatal airway compromise due to retropharyngeal hematoma after airbag deployment. *Am Surg*. 2000;66(7):69-4.
 6. Lin JY, Wang CH, Huang TW. Traumatic retropharyngeal hematoma: case report. *Auris Nasus Larynx*. 2007;34(3):423-5.
 7. Shaw CB, Bawa R, Snider G, et al. Traumatic retropharyngeal hematoma: a case report. *Otolaryngol Head Neck Surg*. 1995;113(4):485-8.

Case of Displaced Glenoid Fracture After Fall: Subtle Findings with Significant Implications for Trauma Patients

Solomon Sebt, MD
Mathias Barden, MD
Eric Leroux, MD, MBA

Eisenhower Medical Center, Department of Emergency Medicine, Rancho Mirage, California

Section Editor: Christopher Sampson, MD

Submission history: Submitted December 3, 2020; Revision received January 27, 2021; Accepted February 1, 2021

Electronically published March 24, 2021

Full text available through open access at http://escholarship.org/uc/uciem_cpccem

DOI: 10.5811/cpcem.2021.2.51053

Case Presentation: A 64-year-old man presented to the emergency department with a chief complaint of left shoulder pain after a mechanical fall from standing. Plain radiography revealed a displaced fracture of the inferior glenoid rim. A computed tomography further characterized the fracture and the patient was taken emergently by an orthopedic surgeon for open reduction and internal fixation.

Discussion: Scapula fractures, especially isolated glenoid rim fractures, are rare and most typical of high-energy mechanism traumas. A missed or delayed diagnosis can result in long-term suffering and disability. Awareness of radiographic as well as physical findings and the subsequent classification system described below can optimize outcomes for trauma patients with glenoid fractures. [Clin Pract Cases Emerg Med. 2021;5(2):258–260.]

Keywords: *Scapula fracture; trauma; glenoid fracture; case report.*

CASE PRESENTATION

A 64-year-old man presented to the emergency department (ED) complaining of an inability to move his left arm following a mechanical fall during which he landed on his shoulder. On physical exam, the patient was unable to actively abduct, internally or externally rotate the shoulder, and resisted the passive performance of these movements. Radial and ulnar pulses were symmetric and intact. Sensation to light touch was intact throughout the deltoid, forearm, and hand. Symmetric and full strength was observed on wrist flexion and extension, symmetric and full strength with finger adduction and abduction, and no limitation in active extension of the metacarpophalangeal joints. Plain radiography revealed a fracture of the inferior glenoid rim (Image 1). The case was then discussed with the on-call orthopedic surgeon who requested a computed tomography (CT) with three-dimensional (3D) reconstruction (Image 2).

DISCUSSION

Scapular fractures are rare and commonly missed in patients with high-impact blunt trauma.⁴ The two strongest

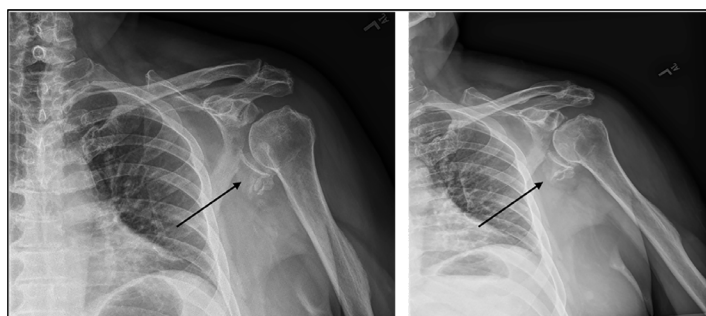


Image 1. Anteroposterior (left) and oblique (right) views of the left shoulder plain radiograph, showing the inferior rim of the fractured glenoid with extension through the body displaced inferiorly (arrows). Based on the Ideberg classification system of glenoid fractures, this fracture pattern is type II.

predictors for missing these fractures are the experience of the emergency physician and the timeliness of orthopedic consultation – earlier intervention associated with better outcomes.⁴ When inappropriately treated, glenoid fractures can cause severe morbidity in all age groups, such as

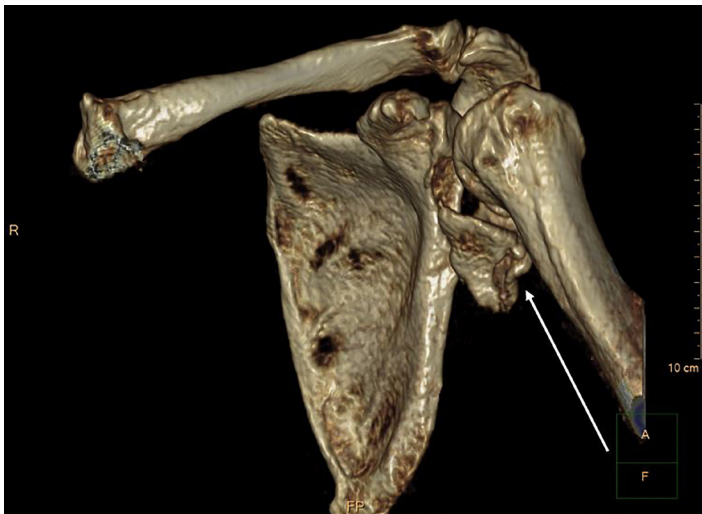


Image 2. Computed tomography three-dimensional reconstruction of the shoulder showing proper articulation of humeral head within the glenoid fossa at the correct level. Fracture fragment noted by the arrow.

nonunion, severe osteoarthritis, and superior shoulder suspensory complex injury, which plays a key role in shoulder joint stability.³

Accurate and expeditious identification and classification of this injury type is critical for optimizing patient outcomes. The Ideberg classification characterizes six glenoid fracture types and is the most commonly used system to describe fractures of the glenoid fossa and rim (Table).^{1,5} Our patient’s fracture was classified as type II glenoid fossa fracture with inferior neck extension (Image 1). Typically, fractures within type II or greater require some measure of surgical intervention. Physical exam findings such as positive apprehension, relocation, and hyperabduction tests are highly specific for glenohumeral instability and subsequent glenoid fractures. Plain radiography is the appropriate imaging choice for

Table. Ideberg classification of glenoid fractures.

Type	Fracture description
Ia	Anterior glenoid rim fracture
Ib	Posterior glenoid rim fracture
II	Glenoid fossa fracture with inferior neck/body extension
III	Glenoid fossa fracture with superior neck/body extension
IV	Glenoid fossa fracture with medial body extension
Va	Glenoid fossa fracture with medial and inferior extension (II+IV)
Vb	Glenoid fossa fracture with medial and superior extension (III+IV)
Vc	Glenoid fossa fracture with medial, inferior, superior extension (II+III+IV)
VI	Glenoid fossa fracture with severe comminution

CPC-EM Capsule

What do we already know about this clinical entity?

Scapular fractures are rare and commonly missed in patients with high-impact blunt trauma but even more so in the setting of low-velocity trauma.

What is the major impact of the image(s)?

If inappropriately treated, glenoid fractures can cause severe morbidity, such as nonunion, severe osteoarthritis, and shoulder joint instability.

How might this improve emergency medicine practice?

Recognizing glenoid fractures and ensuring that surgical candidates are promptly identified have significant implications on long-term patient morbidity.

identifying these glenoid fractures.⁴ The recommended radiographic views for detecting this fracture pattern include true anteroposterior and oblique. Computed tomography (CT) combined with 3D reconstruction is recommended if intra-articular involvement or significant displacement is suspected, as these images permit accurate classification of the fracture and inform subsequent surgical decisions (Image 2).¹ The American Osteopathic Foundation also offers a widely used classification system for glenoid fractures: F0 = fracture of the articular segment, not involving the glenoid fossa; F1 = simple glenoid fossa fractures; and F2 = multi-fragmentary glenoid fossa fractures.¹ The Ideberg classification is the system preferred by the orthopedic community as it is more descriptive in its characterization of fracture patterns.

The patient described above suffered an F1 fracture, for which non-operative treatment is typically indicated, as 90% are stable and heal well with two weeks of sling stabilization followed by early motion.² However, our patient also demonstrated greater than 10 millimeters (mm) of intra-articular displacement and therefore appropriately was offered and underwent surgery. Indications for surgical repair include involvement of greater than 25% of glenoid with subluxation of the humerus, greater than 5 mm of glenoid articular step off, or greater than 10 mm of intra-articular displacement on CT imaging.³ However, operative decisions are informed by the entire clinical picture, including the degree of shoulder joint instability and the patient’s lifestyle goals.

Comprehensive care of patients with scapula or shoulder injuries in the ED is facilitated through a combination of a thorough and targeted physical exam, appropriate radiographic studies, and consultation with an orthopedic specialist. Recognizing glenoid fractures and ensuring that surgical candidates are promptly identified have significant implications on long-term patient morbidity.

The authors attest that their institution requires neither Institutional Review Board approval, nor patient consent for publication of this case report. Documentation on file.

REFERENCES

1. Frich LH and Larsen MS. How to deal with a glenoid fracture. *EFORT Open Rev.* 2017 May 11;2(5):151-7.
2. Maquieira GJ, Espinosa N, Gerber C, et al. Non-operative treatment of large anterior glenoid rim fractures after traumatic anterior dislocation of the shoulder. *J Bone Joint Surg Br.* 2007;89(10):1347-51.
3. Gramstad GD and Marra G. Treatment of glenoid fractures. *Tech Shoulder Elb Surg.* 2002;3(2):102-10.
4. Uzkeser M, Emet M, Kılıç M, et al. What are the predictors of scapula fractures in high-impact blunt trauma patients and why do we miss them in the emergency department? *Eur J Trauma Emerg Surg.* 2012;38(2):157-62.
5. Goss TP. Fractures of the glenoid cavity. *J Bone Joint Surg Am.* 1992;74(2):299-305.

Address for Correspondence: Solomon Sebt, MD, Eisenhower Medical Center, Department of Emergency Medicine, 39000 Bob Hope Dr., AHSB Suite 201, Rancho Mirage, CA 92270. Email: ssebt@eisenhowerhealth.org.

Conflicts of Interest: By the CPC-EM article submission agreement, all authors are required to disclose all affiliations, funding sources and financial or management relationships that could be perceived as potential sources of bias. The authors disclosed none.

Copyright: © 2021 Sebt et al. This is an open access article distributed in accordance with the terms of the Creative Commons Attribution (CC BY 4.0) License. See: <http://creativecommons.org/licenses/by/4.0/>

Hemithorax Westermark Sign Secondary to Complete Pulmonary Artery Occlusion from Pulmonary Embolus

Michael Louthan, MD
Daniel Ng, MD

Riverside Community Hospital, Department of Emergency Medicine, Riverside, California

Section Editor: Scott Goldstein, MD

Submission history: Submitted December 2, 2020; Revision received January 28, 2021; Accepted February 1, 2021

Electronically published March 1, 2021

Full text available through open access at http://escholarship.org/uc/uciem_cpccem

DOI: 10.5811/cpcem.2021.2.51043

Case Presentation: We describe a complete right hemithorax Westermark sign found in a patient with a near-complete, right pulmonary artery trunk occlusion secondary to a pulmonary embolus.

Discussion: We review the sensitivity and specificity of a Westermark sign in the identification of a pulmonary embolism, and how this aided us in managing our patient in the emergency department. [Clin Pract Cases Emerg Med. 2021;5(2):261–262.]

Keywords: *Westermark; pulmonary embolism; radiology.*

CASE PRESENTATION

An elderly female with a history of chronic obstructive pulmonary disease, recent left fibular fracture, and prior lung cancer now in remission presented to the emergency department secondary to dyspnea for six days. While she did report some decreased mobility, she would not be described as immobilized, as she was still able to care for herself independently. Her vital signs were as follows: temperature of 97.5° Fahrenheit; heart rate of 89 beats per minute; blood pressure of 171/74 millimeters of mercury; respiratory rate of 18 breaths per minute; and pulse oximetry of 88% oxygen on room air. Her hypoxemia corrected with supplemental oxygen via nasal cannula, albuterol/ipratropium nebulizer, and intravenous (IV) steroids. Chest radiograph noted an increased translucency within the right hemithorax, consistent with Westermark sign (Image 1). Further evaluation via computed tomography pulmonary angiogram was notable for a pulmonary embolus (PE) within the right pulmonary artery trunk extending into nearly all segmental and subsegmental branches (Images 2, 3). The patient was treated with IV heparin and admitted for further work-up.

DISCUSSION

We describe a case of undifferentiated dyspnea that was found to have an impressive Westermark sign on chest radiograph due to a proximal and occlusive PE. First described in 1938, Westermark sign refers to an increased lucency in a portion of lung due to PE. This hyperlucency is due to

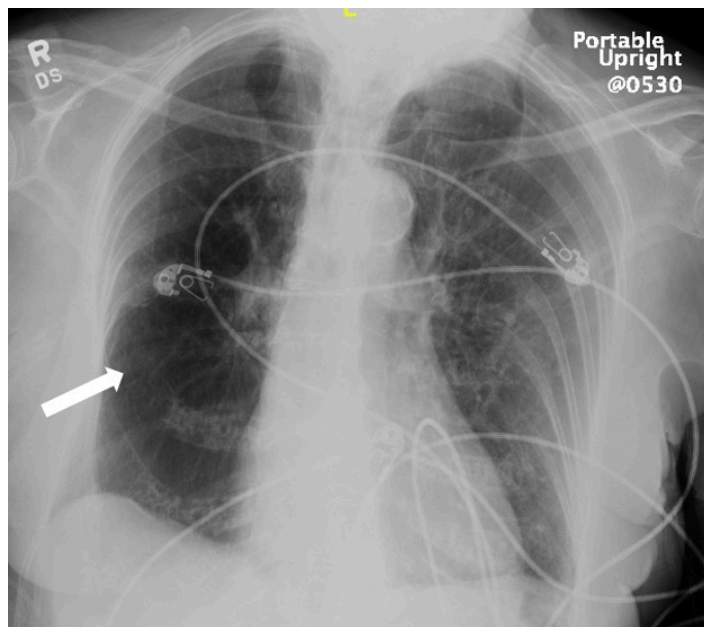


Image 1. Chest radiograph. Image is notable for increased lucency within the right hemithorax (arrow).

proximal mechanical obstruction of blood flow leading to impaired vascularization and resultant oligemia of affected lung fields. Westermark sign has a 14% sensitivity and 92%

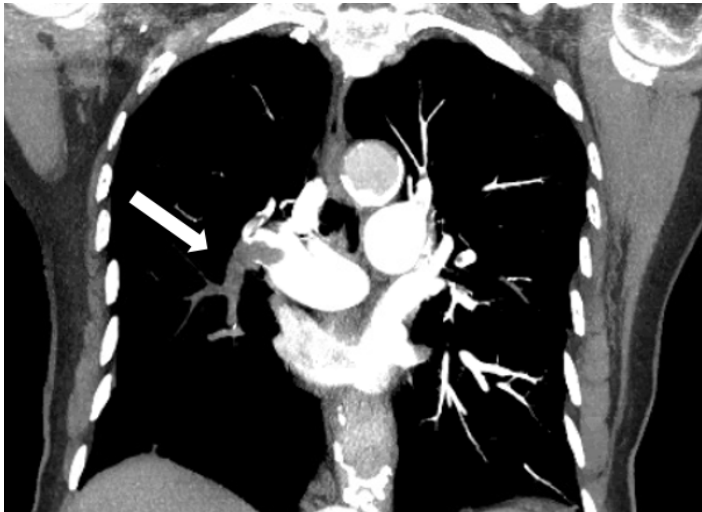

Image 2. Coronal view of the computed tomography pulmonary angiogram. Image is notable for pulmonary embolus within right pulmonary artery trunk with almost complete occlusion of segmental branches (arrow).

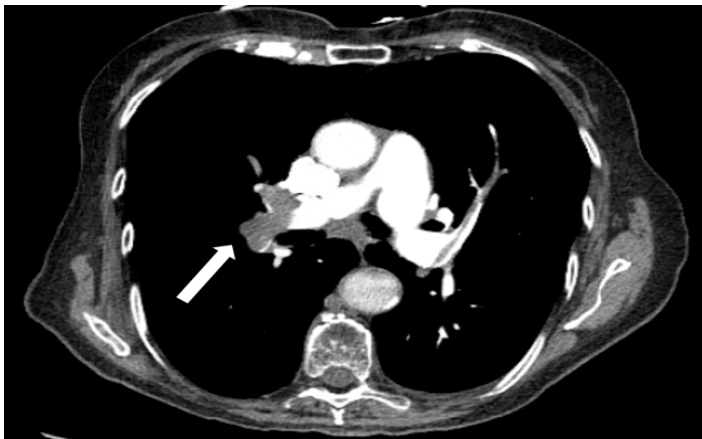

Image 3. Transverse view of the computed tomography pulmonary angiogram. Image redemonstrates the almost-complete occlusion of the right pulmonary artery trunk with the pulmonary embolus (arrow).

specificity for PE identification.^{2,3} Although not diagnostic alone, Westermark sign can be helpful in pursuing the diagnosis of PE.

The authors attest that their institution requires neither Institutional Review Board approval, nor patient consent for publication of this case report. Documentation on file.

CPC-EM Capsule

What do we already know about this clinical entity?

Westermark sign has low sensitivity but high specificity for pulmonary embolism identification.

What is the major impact of the image(s)?

Complete occlusion of a pulmonary artery trunk can lead to a hemithorax Westermark sign.

How might this improve emergency medicine practice?

When faced with increased translucency of a hemithorax, physicians must consider near-occlusion of a proximal pulmonary artery and treat accordingly.

Address for Correspondence: Michael Louthan, MD, Riverside Community Hospital, Department of Emergency Medicine, Graduate Medical Education Office, 4445 Magnolia Ave, Riverside, CA 92501. Email: michael.louthan@hcahealthcare.com.

Conflicts of Interest: By the CPC-EM article submission agreement, all authors are required to disclose all affiliations, funding sources and financial or management relationships that could be perceived as potential sources of bias. The authors disclosed none.

Copyright: © 2021 Louthan et al. This is an open access article distributed in accordance with the terms of the Creative Commons Attribution (CC BY 4.0) License. See: <http://creativecommons.org/licenses/by/4.0/>

REFERENCES

1. Westermark N. On the roentgen diagnosis of lung embolism: brief review of the incidence, pathology and clinical symptoms of lung embolism. *Acta Radiol.* 1938;19(4):357-72.
2. Worsley DF, Alavi A, Aronchick JM, et al. Chest radiographic findings in patients with acute pulmonary embolism: observations from the PIOPED study. *Radiology.* 1993;189(1):133-6.
3. Stein PD, Beemath A, Matta F, et al. Clinical characteristics of patients with acute pulmonary embolism: data from PIOPED II. *Am J Med.* 2007;120(10):871-9.

Ultrasonographic Findings in Fat Embolism Syndrome

Shun Yonezaki, MD
Kazuya Nagasaki, MD
Hiroyuki Kobayashi, MD, PhD

Mito Kyodo General Hospital, Department of Internal Medicine, Ibaraki, Japan

Section Editor: Scott Goldstein, MD

Submission history: Submitted December 20, 2020; Revision received February 8, 2021; Accepted February 14, 2021

Electronically published March 12, 2021

Full text available through open access at http://escholarship.org/uc/uciem_cpccem

DOI: 10.5811/cpccem.2021.2.51270

Case Presentation: A 93-year-old man living in a nursing home presented to our emergency department with altered mental status. Examination revealed hypotension and severe hypoxia. Chest radiograph showed infiltrates in the right upper lobe, and computed tomography of the abdomen and pelvis demonstrated a left femoral neck fracture. A point-of-care transthoracic echocardiogram (TTE) revealed an enlarged right ventricle, severe tricuspid regurgitation, and numerous white floating dots moving toward the right atrium from the inferior vena cava (IVC), leading to the diagnosis of fat embolism syndrome (FES).

Discussion: Although imaging studies can facilitate diagnosis, the diagnosis of FES is typically made by clinical history and presentation, making a swift diagnosis often difficult in those who are critically ill. Recent case reports have described that TTE can detect fat emboli, seen as flowing hyperechoic particles in IVC. This image demonstrates the utility of TTE to diagnose FES. [Clin Pract Cases Emerg Med. 2021;5(2):263–264.]

Keywords: *fat embolism syndrome; ultrasonographic findings.*

CASE PRESENTATION

A 93-year-old man living in a nursing home presented to our emergency department with altered mental status, which occurred suddenly over the previous one hour. An initial history elicited from the nursing home staff failed to identify any risk factors. Examination revealed hypotension and severe hypoxia with oxygen saturation of 85% on 15 liters per minute oxygen with a non-rebreather mask. Chest radiograph showed infiltrates in the right upper lobe, but contrast computed tomography (CT) showed no pulmonary embolism. Suspecting an occult organ pathology, we ordered CT of the abdomen and pelvis, which demonstrated a left femoral neck fracture. Further inquiry of the nursing home staff revealed that the patient had fallen earlier on the same day, striking his hip on the floor. A point-of-care transthoracic echocardiogram (TTE) revealed an enlarged right ventricle, severe tricuspid regurgitation, and numerous white floating dots moving toward the right atrium from the inferior vena cava (IVC) (Image and Video), leading to the diagnosis of fat embolism syndrome (FES). Intravenous crystalloid and oxygen administration were initiated, but the patient expired five hours after admission despite supportive care.

DISCUSSION

Fat embolism syndrome is a rare condition defined by the presence of fat globules in respiratory circulation.¹ Fat embolism

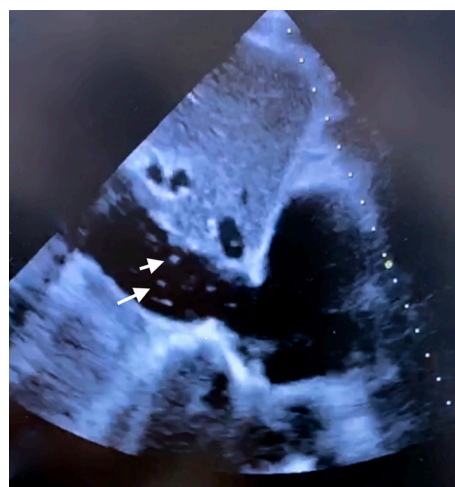


Image. A transthoracic echocardiogram showing numerous white floating dots (arrows) in the inferior vena cava suggestive of fat embolism syndrome.

syndrome typically manifests after long bone and pelvic fractures. Hypoxemia, neurologic abnormalities, and petechial rash are the classic triad of FES¹; however, none are specific for FES. There is no definitive treatment, although supportive care is the standard treatment.² Although chest and brain imaging studies can

facilitate diagnosis, the diagnosis of FES is typically made by clinical history and presentation, making a swift diagnosis often difficult in those who are critically ill. Previous reporting suggests that fat emboli can be detected using transesophageal echocardiography during orthopedic surgery.³ Recent case reports have described that TTE can detect fat emboli, seen as flowing hyperechoic particles in IVC.⁴ This image emphasizes the utility of TTE to diagnose FES.

ACKNOWLEDGMENTS

The authors thank Dr. Gautam Anil Deshpande for editing the manuscript. We also thank Dr. Naoki Iso and Dr. Sayaka Aoyama for their help in collecting the important findings of transthoracic echocardiogram.

Video. Transthoracic echocardiogram. The video shows numerous white floating dots moving toward the right atrium (RA) from the inferior vena cava (IVC) suggestive of fat embolism syndrome.

The authors attest that their institution requires neither Institutional Review Board approval, nor patient consent for publication of this case report. Documentation on file.

Address for Correspondence: Kazuya Nagasaki, MD, Mito Kyodo General Hospital, Department of Internal Medicine, 3-2-7, Miya-machi, Mito, Ibaraki, 310-0015, Japan. Email: kazunagasaki@yahoo.co.jp.

Conflicts of Interest: By the CPC-EM article submission agreement, all authors are required to disclose all affiliations, funding sources and financial or management relationships that could be perceived as potential sources of bias. The authors disclosed none.

Copyright: © 2021 Nagasaki et al. This is an open access article distributed in accordance with the terms of the Creative Commons Attribution (CC BY 4.0) License. See: <http://creativecommons.org/licenses/by/4.0/>

CPC-EM Capsule

What do we already know about this clinical entity?

Fat embolism syndrome (FES) is defined by the presence of fat globules in respiratory circulation; its diagnosis is often challenging.

What is the major impact of the image(s)?

Floating fat emboli can be detected using point-of-care ultrasound, which facilitates the diagnosis of FES.

How might this improve emergency medicine practice?

Point-of-care transthoracic ultrasound is an essential diagnostic tool to evaluate patients with suspected FES.

REFERENCES

1. Kosova E, Bergmark B, Piazza G. Fat embolism syndrome. *Circulation*. 2015;131(3):317-20.
2. Kwiatt ME and Seamon MJ. Fat embolism syndrome. *Int J Crit Illn Inj Sci*. 2013;3(1):64-8.
3. Pell AC, Christie J, Keating JF, et al. The detection of fat embolism by transoesophageal echocardiography during reamed intramedullary nailing. A study of 24 patients with femoral and tibial fractures. *J Bone Joint Surg Br*. 1993;75(6):921-5.
4. Maghrebi S, Cheikhrouhou H, Triki Z, et al. Transthoracic echocardiography in fat embolism: a real-time diagnostic tool. *J Cardiothor Vasc An*. 2017;31(3):e47-8.

Young Woman with Leg Lesions

Daniel Finnin, MD, MBA

Albany Medical Center, Department of Emergency Medicine, Albany, New York

Section Editor: Christopher Sampson, MD

Submission history: Submitted January 15, 2021; Revision received February 25, 2021; Accepted March 5, 2021

Electronically published April 16, 2021

Full text available through open access at http://escholarship.org/uc/uciem_cpem

DOI: 10.5811/cpcem.2021.3.51733

Case Presentation: The patient was a 33-year-old woman with inflammatory bowel disease presenting for worsening lower leg lesions with significant pain recalcitrant to oral doxycycline.

Discussion: Pyoderma gangrenosum is a rare ulcerative skin condition with significant pain that is often associated with other systemic diseases typically treated with immunosuppressive medications aimed at the underlying cause. [Clin Pract Cases Emerg Med. 2021;5(2):265–266.]

Keywords: *Pyoderma gangrenosum; case report; ulcerative colitis.*

CASE PRESENTATION

The patient was a 33-year-old female with a history of untreated ulcerative colitis who presented to the emergency department for evaluation of painful leg lesions. The lesions had developed four days prior and she presented to an outside facility where incision and drainage was performed on one of the lesions. She was prescribed doxycycline on discharge. The lesions continued to spread and were associated with worsening pain. On exam she had multiple, tender violaceous nodules with surrounding erythema on the legs and one similar lesion on the right antecubital fossa at the site of a prior intravenous catheter from the outside facility (Images 1 and 2).

Laboratory results were notable for elevated inflammatory markers. A wound culture was negative. The patient was admitted for further workup and pain control following

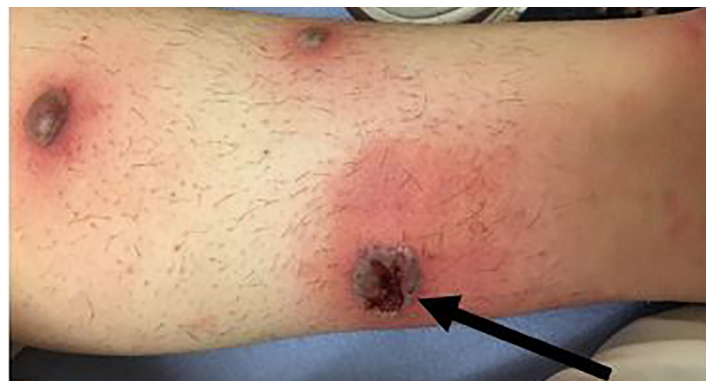


Image 2. Patient's left leg with site of incision and drainage marked by arrow.

treatment with intravenous methylprednisolone. A biopsy later performed ultimately supported the suspected diagnosis of pyoderma gangrenosum.

DISCUSSION

Pyoderma gangrenosum is a rare ulcerative skin condition frequently associated with systemic disease, most often inflammatory bowel disease.¹ It is classically considered a “diagnosis of exclusion,” although a recent consensus statement proposes criteria to aid diagnosis (Table).² A diagnosis of pyoderma gangrenosum is met with the major criterion and at least four of eight minor criteria with a sensitivity of 86% and a specificity of 90%.

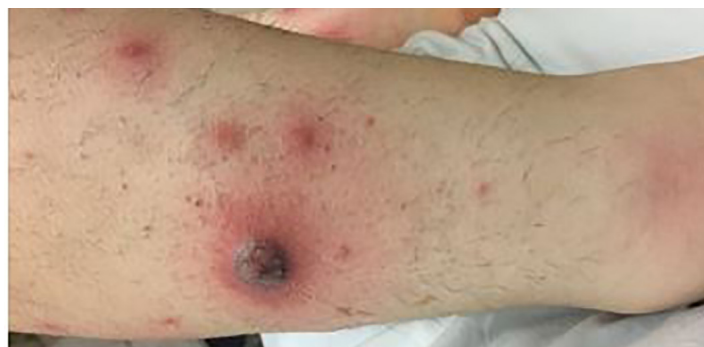

Image 1. Patient's right leg demonstrating the lesions.

Table. Diagnostic criteria for pyoderma gangrenosum.²

Major criterion: Biopsy demonstrating neutrophilic infiltrate at the ulcer's edge
Minor criteria: Infection excluded Pathergy History of inflammatory bowel disease or inflammatory arthritis History of papule, pustule, or vesicle ulcerating within four days of appearing Peripheral erythema, undermining border, and tenderness at ulceration site Multiple ulcerations, at least one on an anterior lower leg Cribriform or "wrinkled paper" scar at healed ulcer sites Decrease in ulcer size within one month of initiating immunosuppressants

This patient exhibited several classic features of pyoderma gangrenosum, including a history of inflammatory bowel disease, rapidly progressing painful ulcerative skin lesions with surrounding erythema, and evidence of pathergy (appearance of lesions at sites of trauma). Treatment of pyoderma gangrenosum is aimed at addressing the underlying disease process.³ Systemic corticosteroids are often required for successful treatment.⁴ Our patient was placed on a prednisone taper on discharge with improvement in symptoms and a plan for outpatient gastroenterology follow-up for ulcerative colitis control.

The authors attest that their institution requires neither Institutional Review Board approval, nor patient consent for publication of this case report. Documentation on file.

REFERENCES

1. States V, O'Brien S, Rai JP, et al. Pyoderma gangrenosum in inflammatory bowel disease: a systematic review and meta-analysis. *Dig Dis Sci.* 2020;65(9):2675-85.
2. Maverakis E, Ma C, Shinkai K, et al. Diagnostic criteria of ulcerative pyoderma gangrenosum: a Delphi consensus of international experts. *JAMA Dermatol.* 2018;154(4):461-6.
3. Miller J, Yentzer BA, Clark A, et al. Pyoderma gangrenosum: a review and update on new therapies. *J Am Acad Dermatol.* 2010;62(4):646-54.
4. Partridge ACR, Bai JW, Rosen CF, et al. Effectiveness of systemic treatments for pyoderma gangrenosum: a systematic review of observational studies and clinical trials. *Br J Dermatol.* 2018;179(2):290-5.

CPC-EM Capsule

What do we already know about this clinical entity?

Pyoderma gangrenosum is a rare, painful ulcerative skin condition often associated with other systemic diseases typically treated with immunosuppressive medications.

What is the major impact of the image(s)?

This visual representation of pyoderma gangrenosum may assist with recognition for emergency providers.

How might this improve emergency medicine practice?

We review the presentation and management of pyoderma gangrenosum to aid providers in delivering effective and timely treatment.

Address for Correspondence: Daniel Finnin, MD, MBA, Albany Medical Center, Department of Emergency Medicine, Mail Code 139, 47 New Scotland Avenue, Albany, NY 12208. Email: finnind@amc.edu.

Conflicts of Interest: By the CPC-EM article submission agreement, all authors are required to disclose all affiliations, funding sources and financial or management relationships that could be perceived as potential sources of bias. The authors disclosed none. I am a military service member or federal/contracted employee of the United States government. This work was prepared as part of my official duties. Title 17 U.S.C. 105 provides that 'copyright protection under this title is not available for any work of the United States Government.' Title 17 U.S.C. 101 defines a U.S. Government work as work prepared by a military service member or employee of the U.S. Government as part of that person's official duties.

Copyright: © 2021 Finnin. This is an open access article distributed in accordance with the terms of the Creative Commons Attribution (CC BY 4.0) License. See: <http://creativecommons.org/licenses/by/4.0/>

An Unusual ECG Artifact Caused by Faulty Cardiac Monitor Leads

Bryan Imhoff, MD, MBA
Wesley Casey, RN, BSN

University of Kansas Health System, Department of Emergency Medicine, Kansas City, Kansas

Section Editor: Manish Amin, DO

Submission history: Submitted January 14, 2021; Revision received March 8, 2021; Accepted March 12, 2021

Electronically published April 23, 2021

Full text available through open access at http://escholarship.org/uc/uciem_cpccem

DOI: 10.5811/cpccem.2021.3.51694

Case Presentation: We present the case of a 74-year-old female patient who presented to the emergency department with lower extremity weakness found to have a fixed frequency square wave artifact in all leads of her electrocardiogram (ECG). After troubleshooting, faulty external cardiac monitor leads were identified as the cause of this unique artifact.

Discussion: The ECG is an important diagnostic tool for medical providers. Electrocardiogram artifacts are extremely common, and knowledge of artifacts is necessary to prevent inappropriate interpretation, diagnostic error, and unnecessary workup. Medical providers should have a low threshold for suspicion when ECG findings do not correlate with the patient's chief complaint or history of present illness. They must also be familiar with the most frequent ECG artifact variants and be prepared to follow a stepwise approach to troubleshoot less frequent variants. [Clin Pract Cases Emerg Med. 2021;5(2):267–269.]

Keywords: ECG; artifact; emergency department; cardiac monitor.

CASE PRESENTATION

A 74-year-old female presented to the emergency department for progressive left leg weakness that had

resulted in multiple falls. An electrocardiogram (ECG) was obtained per Image 1. The ECG had a fixed frequency square wave artifact in all leads, not present on previous

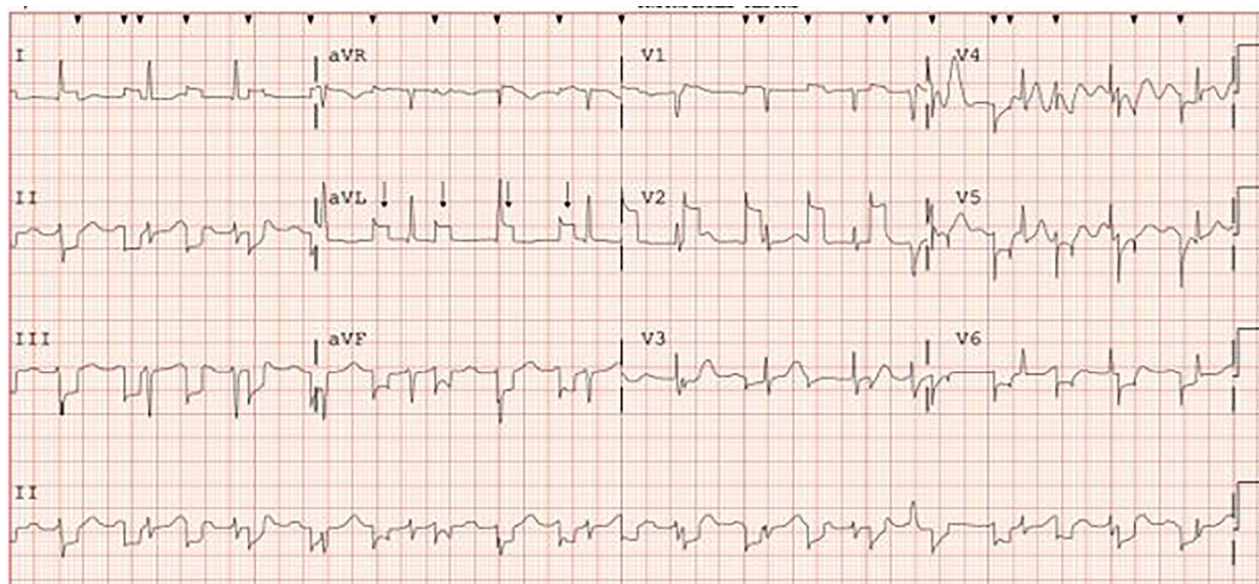


Image 1. Electrocardiogram, demonstrating a fixed frequency square wave artifact (arrows).

ECGs. The patient reported no implanted pacemaker and no neural stimulator, but he was wearing a BioTel event monitor (BioTelemetry, Inc, Malvern, PA), which had been placed in the prior month for syncope. The nurse turned off and removed the event monitor and replaced the ECG machine main cable. A repeat ECG was unchanged. The nurse then exchanged the room's cardiac monitor leads. A repeat ECG showed complete resolution of the artifact, shown in Image 2. The initial set of cardiac monitor leads showed no visible damage but appeared to be the cause of this unique artifact.

DISCUSSION

Electrocardiogram artifact is common and can be generated by physiologic and non-physiologic causes as summarized in the table below.^{1,2} Studies of the effect of electromagnetic interference (EMI) on medical devices represent a large body of literature. For example, due to their ubiquity, cell phones have been extensively studied and identified as a source of potential EMI, including their effect on ECG capture.³ The effects of EMI on implanted devices, particularly cardiac pacemakers, have also been studied extensively due to the potential of negative outcomes from device malfunction.^{4,5} Malfunction of an ECG machine cable is documented in the literature as a potential cause of ECG artifact; however, to the best of our knowledge no case studies exist demonstrating a separate external cardiac monitor, or its leads, causing ECG interference and artifact. Medical practitioners must have a low threshold

for suspicion when ECG findings do not correlate with the patient's chief complaint or history of present illness. In

Educational Merit Capsule

What do we already know about this clinical entity?

Electrocardiogram (ECG) artifact as a general topic has been studied extensively.

What is the major impact of the image(s)?

This image represents a new, not previously documented, case of ECG artifact, and the accompanying discussion presents a more holistic list of other potential causes of artifact.

How might this improve emergency medicine practice?

Recognition of ECG artifact is necessary to prevent inappropriate interpretation, diagnostic error, and unnecessary workup in the emergency department.

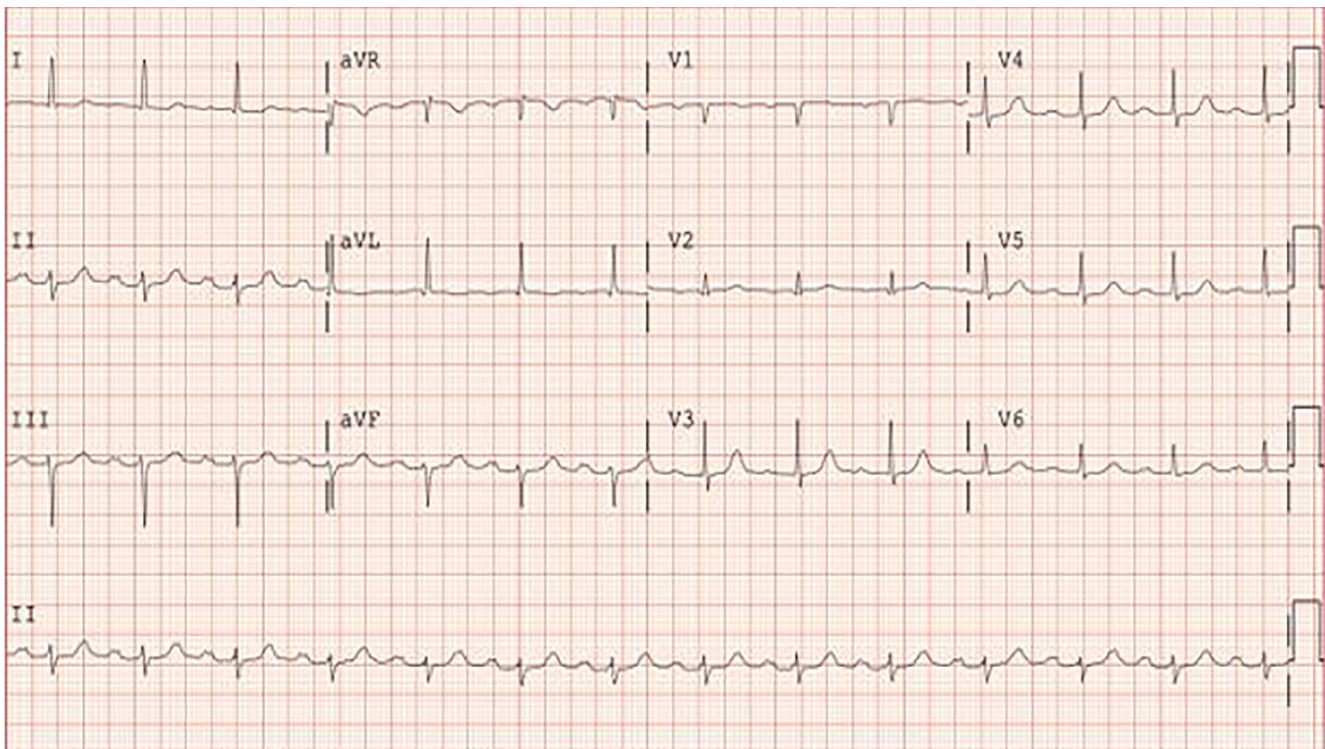


Image 2. Repeat electrocardiogram, demonstrating resolution of artifact after exchanging cardiac monitor leads.

Table. Categories and sources of electrocardiogram artifact.

Category	Source of artifact
Physiologic	<ul style="list-style-type: none"> • Patient muscle activity • Patient motion
Non- physiologic	<ul style="list-style-type: none"> • Electromagnetic interference <ul style="list-style-type: none"> • Implanted medical devices (eg. electrostimulators) • Nearby electrical medical devices (eg, hemodialysis machines, cardiopulmonary bypass machines, ventilators, intravenous fluid warmers, endoscopes, temperature monitors, irrigation pumps, electrocauteries, magnetic resonance imaging machines) • Other non-medical devices (eg, light fixtures, cell phones) • Cable and electrode malfunction <ul style="list-style-type: none"> • Insufficient amount of electrode gel • Fractured wires • Inappropriate filter settings • Loose connections • Misplaced leads • Accumulation of static energy

the presence of a presumed artifact, the practitioner should employ a stepwise approach to isolating the source.

The authors attest that their institution requires neither Institutional Review Board approval, nor patient consent for publication of this case report. Documentation on file.

Address for Correspondence: Bryan Imhoff, MD, MBA, University of Kansas Health System, Department of Emergency Medicine, 3900 Rainbow Boulevard, Kansas City, KS 66160. Email: bimhoff@kumc.edu.

Conflicts of Interest: By the *CPC-EM* article submission agreement, all authors are required to disclose all affiliations, funding sources and financial or management relationships that could be perceived as potential sources of bias. The authors disclosed none.

Copyright: © 2021 Imhoff et al. This is an open access article distributed in accordance with the terms of the Creative Commons Attribution ([CC BY 4.0](https://creativecommons.org/licenses/by/4.0/)) License. See: <http://creativecommons.org/licenses/by/4.0/>

REFERENCES

1. Baranchuk A, Shaw C, Alanazi H, et al. Electrocardiography pitfalls and artifacts: the 10 commandments. *Crit Care Nurse*. 2009;29(1):67-73. Erratum in: *Crit Care Nurse*. 2009;29(2):24.
2. Patel SI and Souter MJ. Equipment-related electrocardiographic artifacts: causes, characteristics, consequences, and correction. *Anesthesiology*. 2008;108(1):138-48.
3. Baranchuk A, Kang J, Shaw C, et al. Electromagnetic interference of communication devices on ECG machines. *Clin Cardiol*. 2009;32(10):588-92.
4. Dyrda K and Khairy P. Implantable rhythm devices and electromagnetic interference: myth or reality? *Expert Rev Cardiovasc Ther*. 2008;6(6):823-32.
5. Kainz W, Alesch F, Chan DD. Electromagnetic interference of GSM mobile phones with the implantable deep brain stimulator, ITREL-III. *Biomed Eng Online*. 2003;2:11.

“One Note Higher”: A Unique Pediatric Hand Fracture

Scott Szymanski, MD
Michael Zylstra, MD
Aicha Hull, MD

Madigan Army Medical Center, Department of Emergency Medicine, Tacoma, Washington

Section Editor: Christopher S. Sampson, MD

Submission history: Submitted January 18, 2021; Revision received March 9, 2021; Accepted March 12, 2021

Electronically published May 6, 2021

Full text available through open access at http://escholarship.org/uc/uciem_cpccem

DOI: 10.5811/cpcem.2021.3.51806

Case Presentation: An otherwise healthy, 12-year-old male presented to the emergency department after a fall down the stairs in which he landed on his right hand. Radiographs demonstrated a Salter-Harris II fracture at the base of the proximal phalanx of the fifth digit with ulnar deviation, also known as an “extra-octave” fracture. Orthopedic surgery was consulted and the fracture was reduced and placed in a short-arm cast. The patient was discharged and scheduled for orthopedic follow-up.

Discussion: A Salter-Harris II fracture at the base of the proximal phalanx of the fifth digit with ulnar deviation is referred to as an “extra-octave” fracture due to the advantage a pianist would gain in reach of their fifth phalanx if not reduced. However, reduction is needed if the fracture is displaced and can be achieved by several described methods including the “90-90” or “pencil” methods followed by cast or splint application. Percutaneous pinning is rarely needed. Complications include flexor tendon entrapment, collateral ligament disruption, and malunion leading to a “pseudo-claw” deformity. We recommend that all extra-octave fractures receive orthopedic follow-up in one to two weeks or sooner if severely displaced. [Clin Pract Cases Emerg Med. 2021;5(2):270–272.]

Keywords: *Extra-octave; Salter-Harris type II; fracture; pencil method; 90-90 method.*

CASE PRESENTATION

A 12-year-old male presented to the emergency department (ED) after falling awkwardly on his right hand. The patient experienced immediate pain and an obvious deformity of the fifth digit. He had increased pain with active and passive movements but denied altered sensation. Exam showed swelling, ulnar displacement, and decreased range of motion at the fifth metacarpophalangeal (MCP) joint. Capillary refill and sensation were normal throughout. Radiographs showed an “extra-octave” fracture (Image 1).

An “extra-octave fracture” is a Salter-Harris II fracture at the base of the fifth proximal phalanx with ulnar deviation. A digital block was performed followed by reduction using traction and adduction, using the provider’s finger as a fulcrum. The patient was placed in a short-arm cast and scheduled for orthopedic follow-up.

DISCUSSION

Hand fractures make up more than 2% of all ED visits in the pediatric population.¹ Given this high incidence,

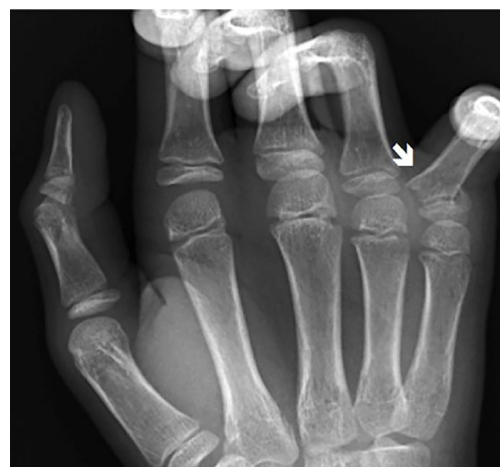

Image 1. Radiograph with white arrow pointing to ulnar deviation of the fifth metacarpophalangeal due to an “extra-octave” fracture.

emergency physicians will treat many of these fractures. Thus, proper identification and management of higher risk

injuries is necessary. An “extra-octave” fracture is a type of Salter-Harris II fracture at the base of the fifth proximal phalanx with ulnar deviation, although some classify it as a juxtaepiphyseal II fracture rather than Salter-Harris II.^{2,3} The term “extra-octave” fracture refers to the advantage a pianist would gain in reaching an “extra octave” if his fracture was not reduced (Image 2).⁴ It is the most common fracture type

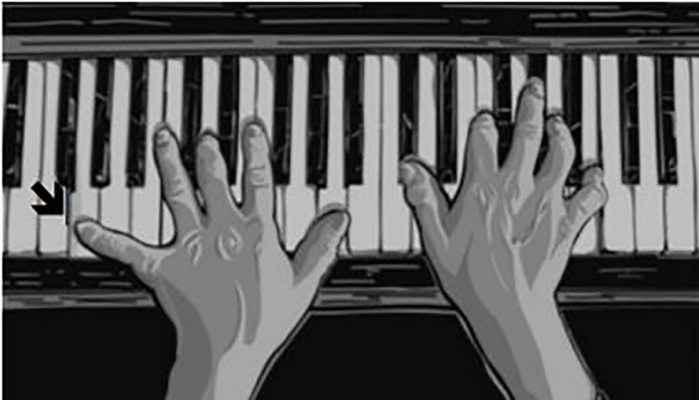

Image 2. A pianist striking an “extra-octave” (arrow), possibly due to inadequate treatment of a remote fracture.⁴ (Open access article reprinted with written permission from the authors).

at the proximal phalanx in children, occurring at a mean age of 10 years.^{2,4} Reduction can be best achieved by using the so-called “pencil” or “90-90” methods (Image 3), with similar outcomes.⁴

The former is accomplished by placing a pencil in the web space of the fourth and fifth digits and using it as a fulcrum while applying traction, mild flexion, and adduction at the MCP joint (Image 3, left). The “90-90” method involves flexing the MCP and applying force in a volar direction on the metacarpal shaft and a dorsal direction on the proximal interphalangeal (PIP) joint (Image 3, right). Care must be taken during reduction and immobilization to ensure the finger is not trapped in residual extension. This can lead to a “pseudo-claw” deformity, in which with active extension, the finger is deformed in 10-15 degrees of hyperextension at the MCP and 10-15 degrees of flexion at the PIP joint. To avoid this, Al-Qattan recommends immobilization with an ulnar gutter splint or cast and the MCP flexed at 90 degrees.⁵ Other complications of the more severely displaced “Type II” fractures include flexor tendon entrapment and collateral ligament disruption.⁵ These fractures can make closed reduction difficult and necessitate more advanced orthopedic intervention such as open reduction.⁵ Overall, most patients do not require surgery and will regain full range of motion.⁴

CPC-EM Capsule

What do we already know about this clinical entity?

An extra octave is a type of Salter Harris II fracture named for the advantage a pianist would gain in reaching an “extra octave” if not adequately reduced.

What is the major impact of the image(s)?

The ulnar displacement associated with this fracture may require special reduction techniques to achieve optimal re-alignment.

How might this improve emergency medicine practice?

Knowledge of this specific fracture, these reduction techniques, and the appropriate management of this injury may help minimize associated complications.

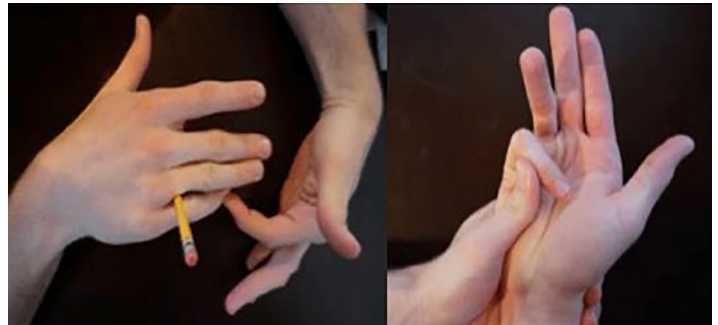

Image 3. The “pencil” (left) and “90-90” (right) methods of reduction.⁴ (Open access article reprinted with written permission from the authors).

To date, no report of this type of fracture has appeared in the emergency medicine literature. Based on the review of the available orthopedic and pediatric literature, we recommend that all “extra-octave” fractures receive orthopedic follow-up in one to two weeks, and the more severe “Type II” fractures receive more expeditious follow-up to avoid the complications described above.

The authors attest that their institution requires neither Institutional Review Board approval, nor patient consent for publication of this case report. Documentation on file.

Address for Correspondence: Scott Szymanski, MD, Madigan Army Medical Center, Department of Emergency Medicine, 4961 Main St., #416, Tacoma, WA 98407. Email: scott.a.szymanski2.mil@mail.mil.

Conflicts of Interest: By the CPC-EM article submission agreement, all authors are required to disclose all affiliations, funding sources and financial or management relationships that could be perceived as potential sources of bias. The authors disclosed none. The views expressed here are those of the authors and do not reflect the official policy of the Department of the Army, the Department of Defense, or the U.S. Government.

Copyright: © 2021 Szymanski et al. This is an open access article distributed in accordance with the terms of the Creative Commons Attribution (CC BY 4.0) License. See: <http://creativecommons.org/licenses/by/4.0/>

REFERENCES

1. Nellans KW and Chung KC. Pediatric hand fractures. *Hand Clin.* 2013;29(4):569-78.
2. Al-Qattan MM, Al-Zahrani K, Al-Boukai AA. The relative incidence of fractures at the base of the proximal phalanx of the fingers in children. *J Hand Surg Eur Vol.* 2008;33(4):465-8.
3. Mims L and Khodae M. Extra-octave fracture in a 14-year-old basketball player. *J Pediatr.* 2017;186:206-e1.
4. Ryan C and Hennrikus W. Outcomes of extra-octave fractures in children. *Ann Musculoskelet Med.* 2019;3(2):11-3.
5. Al-Qattan MM. Juxta-epiphyseal fractures of the base of the proximal phalanx of the fingers in children and adolescents. *J Hand Surg Br.* 2002;27(1):24-30.

A Rare Case of Cranial Nerve VII Neuropraxia Associated with Alveolar Nerve Blocks

Stephen Allegra, MD, MPH
Richard Church, MD
Veera Sudireddy, MD

University of Massachusetts Memorial Medical Center, Department of Emergency Medicine, Worcester, Massachusetts

Section Editor: Shadi Lahham, MD

Submission history: Submitted December 20, 2020; Revision received March 21, 2021; Accepted April 1, 2021

Electronically published May 10, 2021

Full text available through open access at http://escholarship.org/uc/uciem_cpem

DOI: 10.5811/cpem.2021.4.51264

Case Presentation: A 26-year-old male presented to our emergency department for six days of right-sided facial myasthenia and parasthesias following a dental procedure using anesthetic nerve blocks.

Discussion: Iatrogenic cranial nerve VII neuropraxia, a peripheral nerve injury, is an uncommon complication of alveolar nerve blocks with few documented cases specifically due to dental anesthesia. Treatment usually involves use of oral corticosteroid and/or antiviral medications along with close follow-up in clinic with a neurologist and/or otolaryngologist. [Clin Pract Cases Emerg Med. 2021;5(2):273–274.]

Keywords: Alveolar nerve block; Bell's palsy; facial neuropraxia.

CASE PRESENTATION

A 26-year-old male with no significant medical history presented to our emergency department for several days of persistent, right-sided facial numbness and weakness. He had visited the dentist six days prior for an extensive cleaning under local anesthesia, receiving right superior and inferior alveolar nerve blocks. He had immediate and unabated loss of motor function to the right side of his face after this procedure along with an inability to close his right eye and mouth. The patient denied any history of recent oral herpes lesions, rash, headaches, dysarthria, dysphagia, tick bites, outdoor activities, or recent eye, ear or oral infections. This patient's history and physical exam findings suggested diagnosis.

DISCUSSION

Iatrogenic Right Cranial Nerve VII Neuropraxia

Cranial nerve (CN) VII palsy is a common physical exam finding; however, the presumed etiology of neuropraxia following a dental block is a rare complication, and images are not readily found in the emergency medicine literature.¹ Bell's palsy (or CN VII palsy) is described as an acute, unilateral peripheral nerve palsy that leads to temporary paralysis of the affected side of the face and forehead.² On exam, the patient had

right CN VII palsy involving the right forehead (Images 1-3). The neurology service was consulted, and recommendations were for initiation of oral prednisone and valacyclovir daily along with outpatient follow-up for magnetic resonance imaging of the brain and right facial nerve.

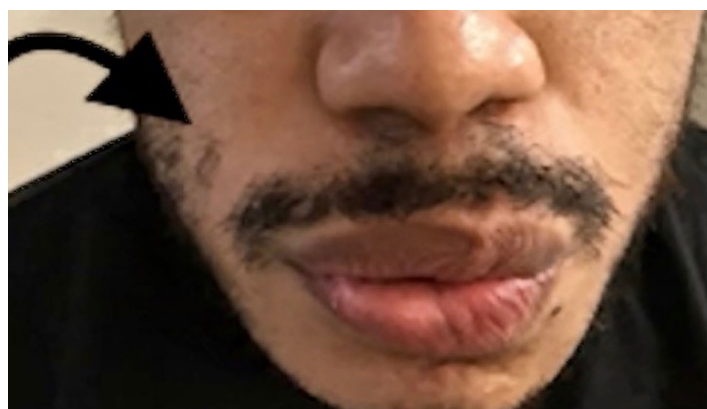

Image 1. Flattening of the right nasolabial fold with inability to contract right-side of orbicularis oris muscle.



Image 2. Inability to contract frontalis muscle on right side.

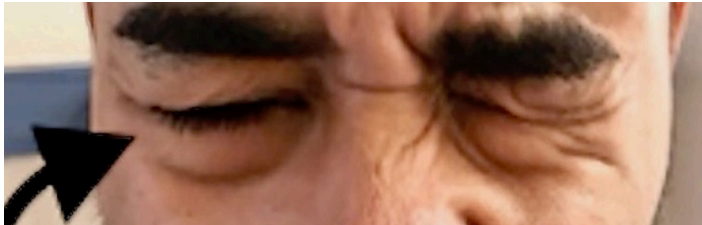

Image 3. Inability to contract right orbicularis oculi muscle.

Although our patient had an acute onset of Bell's palsy following a dental nerve block, the etiology is often uncertain and includes viral infection, autoimmune inflammatory disorders, inherited predisposition, and vascular ischemia.¹⁻⁴ Patients should be given close follow-up with a neurologist and/or otolaryngologist for continued treatment and management as an outpatient with corticosteroid and antiviral medications.^{3,5}

Patient consent has been obtained and filed for the publication of this case report.

REFERENCES

1. Vasconcelos BC, Bessa-Nogueira RV, Maurette PE, et al. Facial nerve paralysis after impacted lower third molar surgery: a literature review and case report. *Med Oral Patol Oral Cir Bucal*. 2006;11(2):E175-8.
2. Chevalier V, Arbab-Chirani R, Tea SH, et al. Facial palsy after inferior alveolar nerve block: case report and review of the literature. *Int. J. Oral Maxillofac. Surg*. 2010;39:1139-42.
3. Tzermpos FH, Cocos A, Kleftogiannis M, et al. Transient delayed facial nerve palsy after inferior alveolar nerve block anesthesia. *Anesth Prog*. 2012;59(1):22-7.
4. Tiwari IB and Keane T. Hemifacial palsy after inferior dental block for dental treatment. *Br Med J*. 1970;1(5699):798.
5. Hato N, Yamada H, Kohno H, et al. Valacyclovir and prednisolone treatment for Bell's palsy: a multicenter, randomized, placebo-controlled study. *Otol Neurotol*. 2007;28(3):408-13.

CPC-EM Capsule

What do we already know about this clinical entity?

Iatrogenic seventh cranial nerve palsy is a rare procedural complication not well reported in the emergency medicine literature.

What is the major impact of the image(s)?

Neuropraxia following a dental block is a rare complication that requires close follow-up with a neurologist and/or otolaryngologist for continued management.

How might this improve emergency medicine practice?

Rapid identification will aid in treatment of an uncommon facial nerve palsy that can be managed in the outpatient setting.

Address for Correspondence: Stephen Allegra, MD, University of Massachusetts Memorial Medical Center, Department of Emergency Medicine, 55 N. Lake Avenue, Worcester, MA 01655. Email: stephen.allegra@umassmemorial.org.

Conflicts of Interest: By the CPC-EM article submission agreement, all authors are required to disclose all affiliations, funding sources and financial or management relationships that could be perceived as potential sources of bias. The authors disclosed none.

Copyright: © 2021 Allegra et al. This is an open access article distributed in accordance with the terms of the Creative Commons Attribution (CC BY 4.0) License. See: <http://creativecommons.org/licenses/by/4.0/>

This Article Corrects: “Subacute Presentation of Central Cord Syndrome Resulting from Vertebral Osteomyelitis and Discitis: A Case Report”

Thomas Dang, BA*
Fanglong Dong, PhD*
Greg Fenati, DO*†
Massoud Rabieli, BS*
Melinda Cerda, MM*
Michael M. Neeki, DO, MS*†
Sara Wattenbarger, DO*‡

*Arrowhead Regional Medical Center, Department of Emergency Medicine, Colton, California
†California University of Science and Medicine, Department of Emergency Medicine, San Bernardino, California
‡Kaweah Delta Medical Center, Department of Emergency Medicine, Visalia, California

Electronically published May 6, 2021

Full text available through open access at http://escholarship.org/uc/uciem_westjem

DOI: 10.5811/cpcem.2021.4.52958

Clin Pract Cases Emerg Med. 2020 May;4(2):267–271.

Subacute Presentation of Central Cord Syndrome Resulting from Vertebral Osteomyelitis and Discitis: A Case Report

Dang T, Dong F, Fenati G, Rabieli M, Cerda M, Neeki MM, Wattenbarger S

Erratum in

Clin Pract Cases Emerg Med. 2021 May;5(2):275. Author name and affiliation missing. The seventh author, Sara Wattenbarger, DO and her corresponding affiliations have been added.

Abstract

Introduction: Central cord syndrome (CCS) is a clinical syndrome of motor weakness and sensory changes. While CCS is most often associated with traumatic events. There have been few documented cases being caused by abscesses resulting from osteomyelitis.

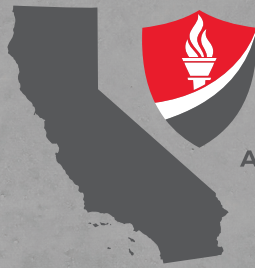Case Report: A 56-year-old male presented to a regional trauma center complaining of excruciating neck and bilateral upper extremity pain. Computed tomography of the cervical and thoracic regions revealed severe discitis and osteomyelitis of the fourth and fifth cervical (C4-C5) with near-complete destruction of the C4 vertebral body, as well as anterolisthesis of C4 on C5 causing compression of the central canal. Empiric intravenous (IV) antibiotic therapy with ampicillin/sulbactam and vancomycin was initiated, and drainage of the abscess was scheduled. After the patient refused surgery, he was planned to be transferred to a skilled nursing facility to receive a six-week course of IV vancomycin therapy. A month later, patient returned to emergency department with the same complaint due to non-compliance with antibiotic therapy.

Discussion: Delayed diagnosis and treatment of osteomyelitis can result in devastating neurological sequelae, and literature supports immediate surgical debridement. Although past evidence has suggested surgical intervention in similar patients with presence of abscesses, this case may suggest that antibiotic treatment may be an alternative approach to the management of CCS due to an infectious etiology. However, the patient had been non-compliant with medication, so it is unknown whether there was definite resolution of the condition.

Conclusion: In patients presenting with non-traumatic central cord syndrome, it is vital to identify risk factors for infection in a thoroughly obtained patient history, as well as to maintain a low threshold for diagnostic imaging.

PMCID: PMC7220002 [PubMed]

**JOIN
CAL/AAEM!**



CALAAEM

CALIFORNIA CHAPTER DIVISION OF THE
AMERICAN ACADEMY OF EMERGENCY MEDICINE

*Championing
individual physician rights
and workplace fairness*

BENEFITS

- *Western Journal of Emergency Medicine* Subscription
- CAL/AAEM News Service email updates
- Discounted AAEM pre-conference fees
- And more!

CAL/AAEM NEWS SERVICE

- Healthcare industry news
- Public policy
- Government issues
- Legal cases and court decisions

In collaboration with our official journal

WestJEM Integrating Emergency Care
with Population Health




FACEBOOK.COM/CALAAEM



FOLLOW US @CALAAEM

[HTTP://WWW.CALAAEM.ORG](http://www.calaaem.org)



ADVANCED **ED** >

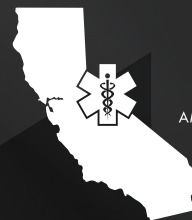SAVE THE DATE

> CALIFORNIA ACEP'S ANNUAL CONFERENCE 2021

Education is targeted to Medical Students and Residents, but all are welcome to attend.

Friday, September 10, 2021

Westin San Diego Gaslamp Quarter



CALIFORNIA ACEP
AMERICAN COLLEGE OF EMERGENCY PHYSICIANS