

Ruptured Ovarian Artery Aneurysm in a Postmenopausal Female: Case Report

Raj Patel, DO
Amy Russell, MD
Melanie M. Randall, MD

Riverside University Health System, Department of Emergency Medicine,
Moreno Valley, California

Section Editor: Austin Smith, MD

Submission history: Submitted August 28, 2023; Revision received October 27, 2023; Accepted November 2, 2023

Electronically published March 25, 2024

Full text available through open access at http://escholarship.org/uc/uciem_cpccem

DOI: [10.5811/cpcem.1643](https://doi.org/10.5811/cpcem.1643)

Introduction: Ovarian artery aneurysm is a rare diagnosis, primarily associated with late pregnancy and the postpartum period. It can cause life-threatening hemorrhage when ruptured. Even more rare are ovarian artery aneurysms in postmenopausal women.

Case Report: We present a case of a postmenopausal female presenting to the emergency department with flank pain. Point-of-care ultrasound showed free fluid in the abdomen. She was diagnosed with an ovarian artery aneurysm on computed tomography angiography and treated successfully with embolization.

Conclusion: Ruptured ovarian artery aneurysm is an uncommon cause of intra-abdominal hemorrhage in women. [Clin Pract Cases Emerg Med. 2024;8(2)143–146.]

Keywords: *intra-abdominal hemorrhage; ovarian artery; aneurysm; case report.*

INTRODUCTION

Ovarian artery aneurysms (OAA) and pseudoaneurysms are primarily diagnosed during the late pregnancy and early postpartum periods. Hemodynamic and endocrine changes during pregnancy can lead to aneurysm formation.¹ Other less common risk factors include trauma and chronic inflammatory conditions. The most common presenting symptom is significant abdominal and flank pain. Rupture of the aneurysm results in intraperitoneal and/or retroperitoneal hemorrhage often requiring emergent intervention. Incidence of this diagnosis is low.² We present an uncommon case of a postmenopausal female found to have a ruptured left OAA.

CASE REPORT

A 51-year-old, postmenopausal, gravida three, para three female presented to our emergency department (ED) with worsening left flank pain and new left-sided abdominal pain. She had been discharged from our hospital two days prior. During that admission, she underwent a left renal biopsy that was complicated by a perirenal and intraabdominal

hematoma. Her medical history included systemic lupus erythematosus, chronic kidney disease, antiphospholipid syndrome, and hypertension. Her gynecologic history was significant for a prior cesarean section and a tubal ligation. She was on warfarin due to her hypercoagulable state.

Upon presentation to the ED, her vital signs were temperature 36.6° Celsius, heart rate 69 beats per minute, blood pressure 116/75 millimeters (mm) of mercury, respiratory rate 16 per minute, and oxygen level 96% on room air. Physical exam revealed a tired-looking female in mild distress. She exhibited left flank tenderness near her renal biopsy site with no external signs of bleeding or infection. Additionally, she had abdominal tenderness in the left upper quadrant (LUQ). There was no abdominal rigidity or signs of peritonitis. A point-of-care ultrasound was positive for free fluid in the LUQ ([Image 1](#)).

Her laboratory values were hemoglobin 6.6 grams per deciliter (g/dL) (reference range 12.1–15.1 g/dL), platelet count 374×10^9 per liter ($\times 10^9/L$) ($150\text{--}450 \times 10^9/L$), blood urea nitrogen 63 milligrams per dL (mg/dL) ($7\text{--}30$ mg/dL), creatinine 3.7 mg/dL ($0.7\text{--}1.2$ mg/dL), prothrombin time

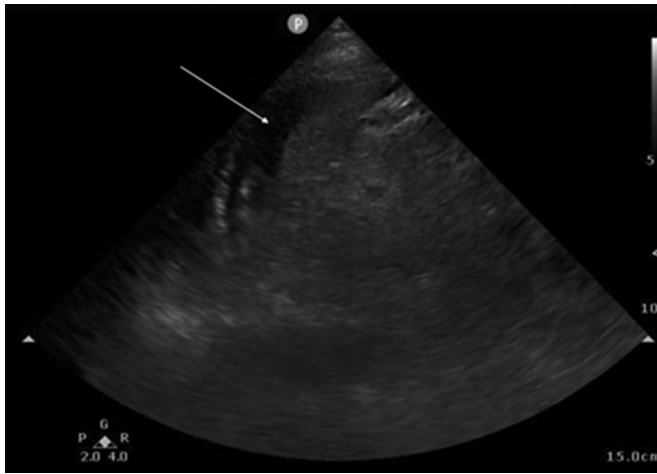


Image 1. Point-of-care ultrasound showing free fluid in the left upper quadrant abdomen between the spleen and kidney (arrow).

15.8 seconds (10–13 seconds), and international normalized ratio 1.3 (0.89–1.16). The patient's hemoglobin level three days prior was 9 g/dL.

Interventional radiology (IR) was consulted due to the patient's recent complicated biopsy, new laboratory derangements, and free fluid on ultrasound. Computed tomography (CT) angiography was recommended to assess for bleeding location and rule out abscess, perforation, or ischemia. Computed tomography of the abdomen and pelvis revealed a new 10 mm enhancement within the intra-abdominal hemorrhage. This abnormality was identified as a ruptured, bleeding distal OAA (*Image 2*). The patient was given one unit of packed red blood cells and taken to IR for definitive management. She underwent gelfoam and coil embolization of the left gonadal artery, resulting in cessation of bleeding (*Image 3*). After an uncomplicated hospital course, she was discharged.

DISCUSSION

Ovarian artery aneurysm rupture is a rare but life-threatening diagnosis. The clinical presentation is

non-specific but can include flank pain, abdominal pain, and hemodynamic instability. Imaging will show intraperitoneal and/or retroperitoneal fluid. Point-of-care ultrasound may assist in diagnosis if adequate intraperitoneal fluid volume is present. Definitive diagnosis requires CT angiography, traditional angiography, or direct operative visualization. Management requires IR embolization in a hemodynamically stable patient or laparotomy with ligation in an unstable patient.^{2,3}

Although symptomatology and physical examination are non-specific, medical history may be helpful in the

CPC-EM Capsule

What do we already know about this clinical entity?

Ovarian artery aneurysms are rare and most often related to pregnancy. Rupture can lead to life-threatening hemorrhage.

What makes this presentation of disease reportable?

Few ovarian artery aneurysms have been described in postmenopausal women or presenting to the emergency department.

What is the major learning point?

Ovarian artery aneurysm is a rare but serious diagnosis that can present with significant intra-abdominal hemorrhage.

How might this improve emergency medicine practice?

This case adds to the existing differential diagnoses for intra-abdominal hemorrhage of unknown origin.

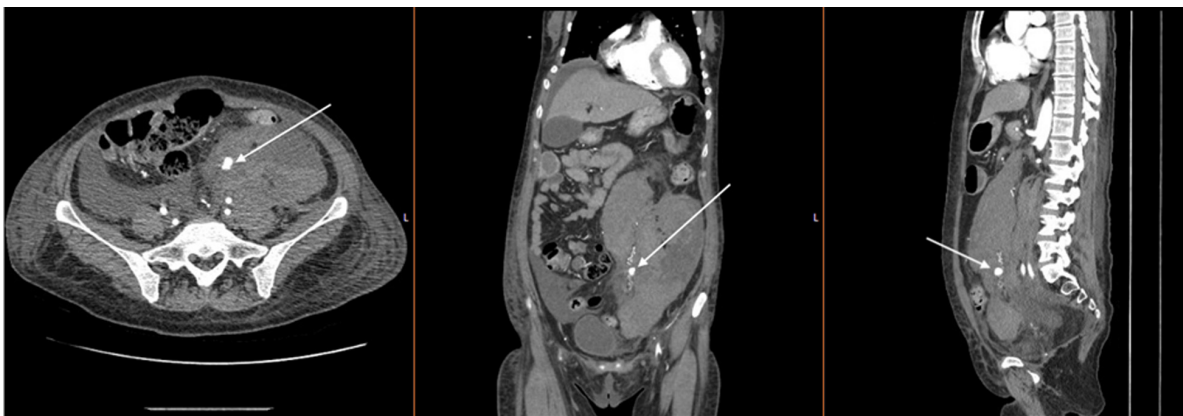


Image 2. Computed tomography angiography demonstrating extravasation from left ovarian artery aneurysm (arrows).

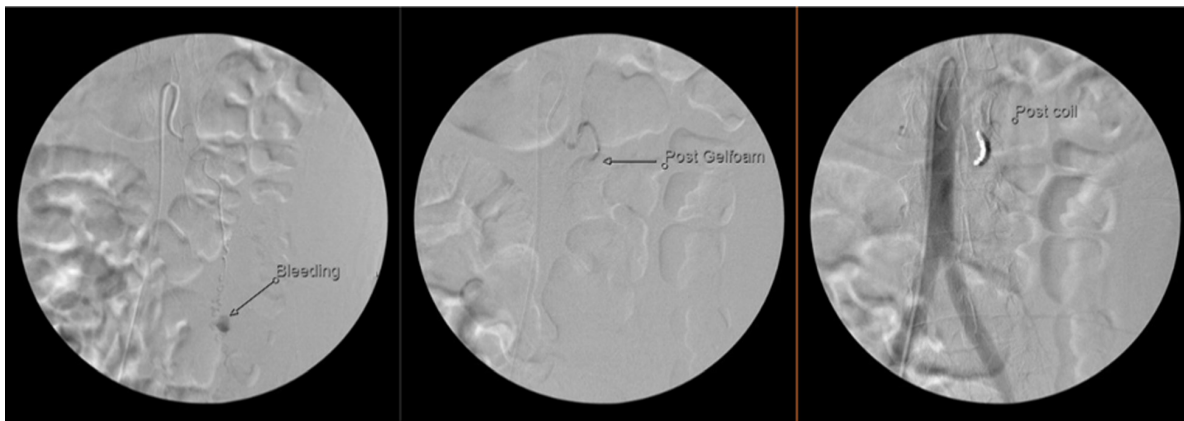


Image 3. Angiography illustrating from left to right the ovarian artery aneurysm with active bleeding; after gelfoam embolization; and after coiling.

consideration of the diagnosis and the choice of imaging. While most commonly associated with pregnancy, OAA has also been described in patients with fibroids, chronic hypertension, trauma, vasculopathy, and in the postoperative phase.^{2–11} Increased plasma volume, increased cardiac output, and hormonal changes during pregnancy have been proposed as factors predisposing patients to OAA. Most documented cases occurred in multiparous women, suggesting that repeat pregnancy may be a risk factor due to the compounding effect of these physiologic changes.^{2,4}

Finally, there are independent cases of OAA patients with chronic inflammatory conditions including chronic lymphocytic leukemia, rheumatoid arthritis, HIV, and lupus.^{6,7,9} The exact influence of chronic inflammation on aneurysm formation or growth is unclear.

CONCLUSION

Ovarian artery aneurysm is a rare and serious disease most commonly associated with pregnancy. We present a rare presentation in a postmenopausal female in the ED. Due to its emergent nature, OAA can be considered in the differential diagnosis of a female patient presenting with nontraumatic abdominal or flank pain with certain appropriate risk factors.

The authors attest that their institution requires neither Institutional Review Board approval, nor patient consent for publication of this case report. Documentation on file.

Address for Correspondence: Melanie Randall, MD, Riverside University Health System, Department of Emergency Medicine, 26520 Cactus Avenue, Moreno Valley, CA 92555.
Email: m.randall@ruhealth.org

Conflicts of Interest: By the CPC-EM article submission agreement, all authors are required to disclose all affiliations, funding sources and financial or management relationships that could be perceived

as potential sources of bias. Melanie Randall receives a monthly administrative stipend from Vituity Emergency Physicians Partnership as the Research Director for the Riverside University Health System emergency department.

Copyright: © 2024 Patel et al. This is an open access article distributed in accordance with the terms of the Creative Commons Attribution (CC BY 4.0) License. See: <http://creativecommons.org/licenses/by/4.0/>

REFERENCES

1. Enakpene CA, Stern T, Barzallo Salazar MJ, et al. Spontaneous rupture of an ovarian artery aneurysm: a rare postpartum complication. *Case Rep Obstet Gynecol.* 2016;2016:1029561.
2. Wada K, Aoyagi S, Matsuura Y, et al. Pregnancy-unrelated spontaneous rupture of a right ovarian artery aneurysm. *Radiol Case Rep.* 2021;16(11):3270–4.
3. Almuhanna AF, Alkhalifa MA, Altaweel FY, et al. Traumatic ovarian artery pseudoaneurysm post-ovum pickup: a rare complication. *Cureus.* 2021;13(12):e20825.
4. Hu YH, Ouh YT, Kim C, et al. Spontaneous rupture of ovarian artery aneurysm in a postmenopausal woman: a case report and literature review. *J Menopausal Med.* 2021;27(2):102–5.
5. Chao LW and Chen CH. Spontaneous rupture of an ovarian artery aneurysm: case report and review of the literature. *Gynecol Obstet Invest.* 2009;68(2):104–7.
6. Zorrilla AM, Fein LA, James K, et al. Retroperitoneal hematoma secondary to spontaneous rupture of ovarian artery pseudoaneurysms: case report and review of literature. *J Obstet Gynaecol.* 2019;39(3):422–4.
7. Kirk JS, Deitch JS, Robinson HR, et al. Staged endovascular treatment of bilateral ruptured and intact ovarian artery aneurysms in a postmenopausal woman. *J Vasc Surg.* 2009;49(1):208–10.
8. Nakajo M, Ohkubo K, Fukukura Y, et al. Embolization of spontaneous rupture of an aneurysm of the ovarian artery supplying the uterus with fibroids. *Acta Radiol.* 2005;46(8):887–90.

9. Herskowitz MM, Wong CM, Leonardo RF. Ruptured ovarian artery pseudoaneurysm in a postmenopausal patient treated with transcatheter embolization. *Case Rep Radiol.* 2020;2020:6728318.
10. Erdoes LS and Entzian D. Ruptured traumatic ovarian artery pseudoaneurysm in a pregnant patient. *J Vasc Surg Cases.* 2015;1(1):36–8.
11. Tao Y, Matsubara S, Yagi K, et al. Intra-abdominal hemorrhage due to segmental arterial mediolysis of an ovarian artery pseudoaneurysm and concomitant aneurysmal subarachnoid hemorrhage: illustrative case. *J Neurosurg Case Lessons.* 2022;4(5):CASE22233.