

CPC Emergency Medicine

Volume 8, Number 2, May 2024

Open Access at www.cpcem.org

ISSN: 2474-252X

Clinical Practice and Cases in Emergency Medicine

In Collaboration with the *Western Journal of Emergency Medicine*

Clinicopathological Cases from the University of Maryland

- 83 **54-year-old Woman with Chest Pain**
Zachary R. Wynne, Kami M. Hu, Laura J. Bontempo, John David Gatz

Case Series

- 90 **Using Point-of-care Ultrasonography to Diagnose Traumatic Arthrotomy of the Knee: A Case Series**
Jordan Mullings, Henry Ashworth, Matthew Kongkatong, Daniel Mantuani

Case Report

- 95 **A Critical Combination of Esophageal Rupture and Upside-down Stomach: A Case Report**
Kay Nicole Tipton, Daniel Schroder
- 99 **Acute Abdominal Pain and a Whirlpool Sign on Computed Tomography: A Case Report**
Christopher Libby, Evan Stern, Robyn Hoelle
- 102 **Cardiac Arrest During a Ferric Derisomaltose Infusion Followed by Complete Heart Block: A Case Report**
Michael Scott, Natalie Jansen, Leslie A. Bilello
- 107 **Defibrillator Lead Perforation Leading to Concerning Electrocardiogram Findings: Case Report**
Bryan Rosenberg, Max Hockstein, Cyrus Hadadi
- 111 **Diabetic Ketoacidosis: A Case Report**
April Brill, Nirav Chheda, Daniel Strama, Ramesh Soundarajan
- 115 **Emergency Department Doppler Assessment of a Central Retinal Artery Occlusion: Case Report**
Duncan McGuire, Robert Calleja, Eric Pai, Amit Bahl

Contents continued on page iii



UC Irvine Health



A Peer-Reviewed, International Professional Journal



**ACOEPE stands with all emergency
physicians and providers on the
front line. We thank you for your
tireless work and effort.**



Penn State Health Emergency Medicine

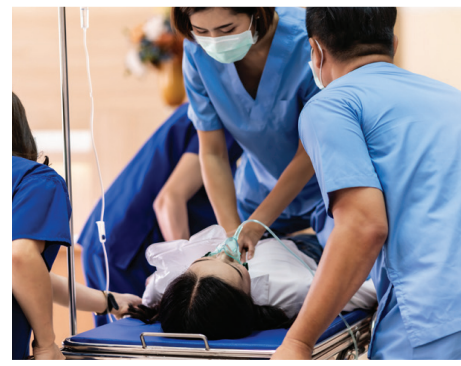About Us:

Penn State Health is a multi-hospital health system serving patients and communities across central Pennsylvania. We are the only medical facility in Pennsylvania to be accredited as a Level I pediatric trauma center and Level I adult trauma center. The system includes Penn State Health Milton S. Hershey Medical Center, Penn State Health Children's Hospital, and Penn State Cancer Institute based in Hershey, Pa.; Penn State Health Hampden Medical Center in Enola, Pa.; Penn State Health Holy Spirit Medical Center in Camp Hill, Pa.; Penn State Health St. Joseph Medical Center in Reading, Pa.; Penn State Health Lancaster Pediatric Center in Lancaster, Pa.; Penn State Health Lancaster Medical Center (opening fall 2022); and more than 3,000 physicians and direct care providers at more than 126 outpatient practices in 94 locations. Additionally, the system jointly operates various health care providers, including Penn State Health Rehabilitation Hospital, Hershey Outpatient Surgery Center, Hershey Endoscopy Center, Horizon Home Healthcare and the Pennsylvania Psychiatric Institute.

We foster a collaborative environment rich with diversity, share a passion for patient care, and have a space for those who share our spark of innovative research interests. Our health system is expanding and we have opportunities in both academic hospital as well community hospital settings.

Benefit highlights include:

- Competitive salary with sign-on bonus
- Comprehensive benefits and retirement package
- Relocation assistance & CME allowance
- Attractive neighborhoods in scenic central Pa.



PennState Health

FOR MORE INFORMATION PLEASE CONTACT:
Heather Peffley, PHR CPRP - Penn State Health Lead Physician Recruiter
hpeffley@pennstatehealth.psu.edu

Penn State Health is fundamentally committed to the diversity of our faculty and staff. We believe diversity is unapologetically expressing itself through every person's perspectives and lived experiences. We are an equal opportunity and affirmative action employer. All qualified applicants will receive consideration for employment without regard to age, color, disability, gender identity or expression, marital status, national or ethnic origin, political affiliation, race, religion, sex (including pregnancy), sexual orientation, veteran status, and family medical or genetic information.

Clinical Practice and Cases in Emergency Medicine

Indexed in PubMed and full text in PubMed Central

Rick A. McPheeters, DO, Editor-in-Chief
Kern Medical/UCLA- Bakersfield, California

R. Gentry Wilkerson, MD, Deputy Editor
University of Maryland School of Medicine

Mark I. Langdorf, MD, MHPE, Senior Associate Editor
University of California, Irvine School of Medicine- Irvine, California

Shahram Lotfipour, MD, MPH, Senior Associate Editor
University of California, Irvine School of Medicine- Irvine, California

Shadi Lahham, MD, MS, Associate Editor
Kaiser Permanente- Orange County, California

Manish Amin, DO, Associate Editor
Kern Medical/UCLA- Bakersfield, California

John Ashurst, DO, Decision Editor/ ACOEP Guest Editor
Kingman Regional Health Network, Arizona

Anna McFarlin, MD, Decision Editor
Louisiana State University Health Science Center- New Orleans, Louisiana

Lev Libet, MD, Decision Editor
Kern Medical/UCLA- Bakersfield, California

Christopher Sampson, MD, Decision Editor
University of Missouri- Columbia, Missouri

Joel Moll, MD, Decision Editor
Virginia Commonwealth University School of Medicine- Richmond, Virginia

Steven Walsh, MD, Decision Editor
Einstein Medical Center Philadelphia-Philadelphia, Pennsylvania

Melanie Heniff, MD, JD, Decision Editor
University of Indiana School of Medicine- Indianapolis, Indiana

Austin Smith, MD, Decision Editor
Vanderbilt University Medical Center-Nashville, Tennessee

Rachel A. Lindor, MD, JD, Decision Editor
Mayo Clinic College of Medicine and Science

Jacqueline K. Le, MD, Decision Editor
Desert Regional Medical Center

Christopher San Miguel, MD, Decision Editor
Ohio State University Wexner Medical Center

Editorial Board

Amin A. Kazzi, MD, MAAEM
The American University of Beirut, Beirut,
Lebanon

Barry E. Brenner, MD, MPH
Case Western Reserve University

Brent King, MD, MMM
University of Texas, Houston

Daniel J. Dire, MD
University of Texas Health Sciences Center
San Antonio

Edward Michelson, MD
Texas Tech University

Edward Panacek, MD, MPH
University of South Alabama

Erik D. Barton, MD, MBA
Icahn School of Medicine, Mount Sinai,
New York

Francesco Dellacorte, MD
Azienda Ospedaliera Universitaria "Maggiore
della Carità," Novara, Italy

Gayle Galleta, MD
Sørlandet Sykehus HF, Akershus
Universitetssykehus, Lorenskog, Norway

Hjalti Björnsson, MD
Icelandic Society of Emergency Medicine

Leslie Zun, MD, MBA
Chicago Medical School

Linda S. Murphy, MLIS
University of California, Irvine School of
Medicine Librarian

Niels K. Rathlev, MD
Tufts University School of Medicine

Pablo Aguilera Fuenzalida, MD
Pontificia Universidad Católica de Chile,
Región Metropolitana, Chile

Peter A. Bell, DO, MBA
Baptist Health Science University

Peter Sokolove, MD
University of California, San Francisco

Robert Suter, DO, MHA
UT Southwestern Medical Center

Robert W. Derlet, MD
University of California, Davis

Scott Rudkin, MD, MBA
University of California, Irvine

Scott Zeller, MD
University of California, Riverside

Steven Gabaeff, MD
Clinical Forensic Medicine

Steven H. Lim, MD
Changi General Hospital, Simei, Singapore

Vijay Gautam, MBBS
University of London, London, England

Wirachin Hoonpongsimanont, MD, MSBATS
Siriraj Hospital, Mahidol University, Bangkok,
Thailand

Advisory Board

Amal Khalil, MBA
UC Irvine Health School of Medicine

Elena Lopez-Gusman, JD
California ACEP
American College of Emergency Physicians

DeAnna McNett, CAE
American College of Osteopathic Emergency
Physicians

John B. Christensen, MD
California Chapter Division of AAEM

Randy Young, MD
California ACEP
American College of Emergency
Physicians

Mark I. Langdorf, MD, MHPE
UC Irvine Health School of Medicine

Jorge Fernandez, MD
California ACEP
American College of Emergency Physicians
University of California, San Diego

Peter A. Bell, DO, MBA
American College of Osteopathic Emergency
Physicians
Baptist Health Science University

Robert Suter, DO, MHA
American College of Osteopathic Emergency
Physicians
UT Southwestern Medical Center

Shahram Lotfipour, MD, MPH
UC Irvine Health School of Medicine

Brian Potts, MD, MBA
California Chapter Division of AAEM
Alta Bates Summit-Berkeley Campus

Editorial Staff

Isabelle Nepomuceno, BS
Executive Editorial Director

Visha Bajaria, BS
CPC-EM Editorial Director

Emily Kane, MA
CPC-EM Editorial Director

Stephanie Burmeister, MLIS
CPC-EM Staff Liaison

Cassandra Saucedo, MS
Executive Publishing Director

Nicole Valenzi, BA
CPC-EM Publishing Director

June Casey, BA
Copy Editor

Official Journal of the California Chapter of the American College of Emergency Physicians, the American College of Osteopathic Emergency Physicians, and the California Chapter of the American Academy of Emergency Medicine



Available in MEDLINE, PubMed, PubMed Central, Google Scholar, eScholarship, DOAJ, and OASPA.

Editorial and Publishing Office: WestJEM/Department of Emergency Medicine, UC Irvine Health, 3800 W. Chapman Ave. Suite 3200, Orange, CA 92868, USA

Office: 1-714-456-6389; Email: Editor@westjem.org

Clinical Practice and Cases in Emergency Medicine

Indexed in PubMed and full text in PubMed Central

This open access publication would not be possible without the generous and continual financial support of our society sponsors, department and chapter subscribers.

Professional Society Sponsors

AMERICAN COLLEGE OF OSTEOPATHIC EMERGENCY PHYSICIANS
CALIFORNIA ACEP

CALIFORNIA CHAPTER DIVISION OF
AMERICAN ACADEMY OF EMERGENCY MEDICINE

Academic Department of Emergency Medicine Subscribers

Albany Medical College Albany, NY	INTEGRIS Health Oklahoma City, OK	Robert Wood Johnson University Hospital New Brunswick, NJ	University of Florida, Jacksonville Jacksonville, FL
American University of Beirut Beirut, Lebanon	Kaweah Delta Health Care District Visalia, CA	Rush University Medical Center Chicago, IL	University of Illinois at Chicago Chicago, IL
Arrowhead Regional Medical Center Colton, CA	Kennedy University Hospitals Turnersville, NJ	Southern Illinois University Carbondale, IL	University of Illinois College of Medicine Peoria, IL
Augusta University Augusta GA	Kern Medical Bakersfield, CA	St. Luke's University Health Network Bethlehem, PA	University of Iowa Iowa City, IA
Baystate Medical Center Springfield, MA	Lakeland HealthCare St. Joseph, MI	Stanford/Kaiser Emergency Medicine Residency Program Stanford, CA	University of Louisville Louisville, KY
Beaumont Hospital Royal Oak, MI	Lehigh Valley Hospital and Health Network Allentown, PA	Staten Island University Hospital Staten Island, NY	University of Maryland Baltimore, MD
Beth Israel Deaconess Medical Center Boston, MA	Loma Linda University Medical Center Loma Linda, CA	SUNY Upstate Medical University Syracuse, NY	University of Michigan Ann Arbor, MI
Boston Medical Center Boston, MA	Louisiana State University Health Sciences Center New Orleans, LA	Temple University Philadelphia, PA	University of Missouri, Columbia Columbia, MO
Brigham and Women's Hospital Boston, MA	Madigan Army Medical Center Tacoma, WA	Texas Tech University Health Sciences Center El Paso, TX	University of Nebraska Medical Center Omaha, NE
Brown University Providence, RI	Maimonides Medical Center Brooklyn, NY	University of Alabama, Birmingham Birmingham, AL	University of South Alabama Mobile, AL
Carl R. Darnall Army Medical Center Fort Hood, TX	Maricopa Medical Center Phoenix, AZ	University of Arkansas for Medical Sciences Little Rock, AR	University of Southern California/Keck School of Medicine Los Angeles, CA
Conemaugh Memorial Medical Center Johnstown, PA	Massachusetts General Hospital Boston, MA	University of California, Davis Medical Center Sacramento, CA	University of Tennessee, Memphis Memphis, TN
Desert Regional Medical Center Palm Springs, CA	Mayo Clinic College of Medicine Rochester, MN	University of California Irvine Orange, CA	University of Texas, Houston Houston, TX
Doctors Hospital/Ohio Health Columbus, OH	Mt. Sinai Medical Center Miami Beach, FL	University of California, Los Angeles Los Angeles, CA	University of Texas Health San Antonio, TX
Eastern Virginia Medical School Norfolk, VA	North Shore University Hospital Manhasset, NY	University of California, San Diego La Jolla, CA	University of Warwick Library Coventry, United Kingdom
Einstein Healthcare Network Philadelphia, PA	Northwestern Medical Group Chicago, IL	University of California, San Francisco San Francisco, CA	University of Washington Seattle, WA
Emory University Atlanta, GA	Ohio State University Medical Center Columbus, OH	UCSF Fresno Center Fresno, CA	University of Wisconsin Hospitals and Clinics Madison, WI
Genesys Regional Medical Center Grand Blanc, Michigan	Ohio Valley Medical Center Wheeling, WV	University of Chicago, Chicago, IL	Wake Forest University Winston-Salem, NC
Hartford Hospital Hartford, CT	Oregon Health and Science University Portland, OR	University of Colorado, Denver Denver, CO	Wright State University Dayton, OH
Hennepin County Medical Center Minneapolis, MN	Penn State Milton S. Hershey Medical Center Hershey, PA	University of Florida Gainesville, FL	
Henry Ford Hospital Detroit, MI	Presence Resurrection Medical Center Chicago, IL		

State Chapter Subscribers

ARIZONA CHAPTER DIVISION OF THE
AMERICAN ACADEMY OF EMERGENCY MEDICINE
CALIFORNIA CHAPTER DIVISION OF THE
AMERICAN ACADEMY OF EMERGENCY MEDICINE
FLORIDA CHAPTER DIVISION OF THE
AMERICAN ACADEMY OF EMERGENCY MEDICINE

GREAT LAKES CHAPTER DIVISION OF THE
AMERICAN ACADEMY OF EMERGENCY MEDICINE
TENNESSEE CHAPTER DIVISION OF THE
AMERICAN ACADEMY OF EMERGENCY MEDICINE

UNIFORMED SERVICES CHAPTER DIVISION OF THE
AMERICAN ACADEMY OF EMERGENCY MEDICINE
VIRGINIA CHAPTER DIVISION OF THE
AMERICAN ACADEMY OF EMERGENCY MEDICINE

International Society Partners

EMERGENCY MEDICINE ASSOCIATION OF TURKEY
LEBANESE ACADEMY OF EMERGENCY MEDICINE
MEDITERRANEAN ACADEMY OF EMERGENCY MEDICINE

NORWEGIAN SOCIETY FOR EMERGENCY MEDICINE
SOCIEDAD ARGENTINA DE EMERGENCIAS

SOCIEDAD CHILENO MEDICINA URGENCIA
THAI ASSOCIATION FOR EMERGENCY MEDICINE

To become a *WestJEM* departmental sponsor, waive article processing fee, receive print and copies for all faculty and electronic for faculty/residents, and free CME and faculty/fellow position advertisement space, please go to <http://westjem.com/subscribe> or contact:

Stephanie Burmeister
WestJEM Staff Liaison
Phone: 1-800-884-2236
Email: sales@westjem.org

JOURNAL FOCUS

Clinical Practice and Cases in Emergency Medicine (CPC-EM) is a MEDLINE-indexed internationally recognized journal affiliated with the *Western Journal of Emergency Medicine* (WestJEM). It offers the latest in patient care case reports, images in the field of emergency medicine and state of the art clinicopathological and medicolegal cases. CPC-EM is fully open-access, peer reviewed, well indexed and available anywhere with an internet connection. CPC-EM encourages submissions from junior authors, established faculty, and residents of established and developing emergency medicine programs throughout the world.

Table of Contents

- 120 Face-off Droop: A Case Report of Pediatric Stroke**
Duncan Robertson, Hayden F. Peirce, Marek D. Nicpon, Eric M. Otterson, Laurel O'Connor, Julia G. Rissmiller, Zachary W. Binder
- 125 Inferior Pancreaticoduodenal Artery Pseudoaneurysm Causing Biliary Obstruction: A Case Report**
Patrick Meloy, Will S. Lindquister, Jeffrey Stebbins, Elaine Bromberek
- 129 Peritonsillar Abscess and Post-aspiration Bleed Identified with Point-of-care Ultrasound Using Endocavitary Probe: A Case Report**
Jaclyn Floyd, Brandon Dahl, Matthew Whited, Ami Kurzweil
- 133 Permissive Hypotension in a Patient with Severe Hyponatremia: A Case Report**
Andrea Hlady, David Kerner, Laura E. Walker
- 138 Profound Alkalosis and Prolonged QT Interval Due to Inappropriate Gastrostomy Tube Loss: A Case Report**
Forrest Turner, Brandon Friedman, H. Pendell Meyers, Stephen W. Smith
- 143 Ruptured Ovarian Artery Aneurysm in a Postmenopausal Female: Case Report**
Raj Patel, Amy Russell, Melanie M. Randall
- 147 Severely Painful and Pruritic Forearm Rash: A Case of Caterpillar Envenomation in South Florida**
Cody M. Autrey, Stephanie A. Martinez, Michael Remaly, Eric Boccio
- 151 Silicone Embolism Syndrome Causing Altered Mental Status and Respiratory Failure After an Unlicensed Gluteal Silicone Injection: A Case Report**
Christopher Lin, Jeremiah Robison
- 155 Transcatheter Arterial Embolization for Atraumatic Splenic Rupture in TEE-negative Endocarditis: A Case Report**
Daniel P. High, Jose M. Acosta-Rullan, Danay Herrera, Mauricio Danckers, Daniel Heller, Daniel Zapata
- 159 Use of Point-of-care Ultrasound to Diagnose Rectus Abdominis Strain in the Acute Setting: A Case Report**
Alejandro J. Sanoja, Michael Shalaby
- 163 When Educational Images Don't Reflect the Population: Phlegmasia Cerulea Dolens, a Case Report**
Kasha Bornstein, Elizabeth LaRosa, Kelsey Byrd, Dan Laney, Hector Ferral, Heather Murphy-Lavoie

Images in Emergency Medicine

- 168 Atraumatic Orbital Emphysema in a Young Woman**
Eladio Alborno, Janet Wildemuth, Josephine Valenzuela

Policies for peer review, author instructions, conflicts of interest and human and animal subjects protections can be found online at www.westjem.com.

JOURNAL FOCUS

Clinical Practice and Cases in Emergency Medicine (CPC-EM) is a MEDLINE-indexed internationally recognized journal affiliated with the *Western Journal of Emergency Medicine* (WestJEM). It offers the latest in patient care case reports, images in the field of emergency medicine and state of the art clinicopathological and medicolegal cases. CPC-EM is fully open-access, peer reviewed, well indexed and available anywhere with an internet connection. CPC-EM encourages submissions from junior authors, established faculty, and residents of established and developing emergency medicine programs throughout the world.

Table of Contents *continued*

- 171 **Child with Closed Head Injury and Persistent Vomiting**
Abdullah Khan
- 174 **Clinical Images in Emergency Medicine: Cushing's Disease**
Jason D. Vadhan, Nathaniel Hansen, Fernando L. Benitez, Larissa I. Velez
- 176 **One in a Million: A Woman Presenting with Unilateral Painful Ophthalmoplegia**
Kevin Bennett, Eric Boccio
- 179 **Rash and Fever in a Returned Traveler**
Helena Kons, Elliott D. Herron, Zachary S. Pacheco, Erin F. Shufflebarger

Policies for peer review, author instructions, conflicts of interest and human and animal subjects protections can be found online at www.westjem.com.

CPC*EM* Clinical
Practice
& Cases

CALL FOR CPC-EM SECTION EDITORS!

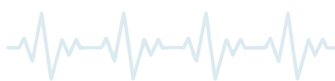- Medical-Legal Case Reports
- Case Reports/Images in
Emergency Medicine

**Send your CV and letter of interest to
editor@cpcem.org**

**Clinical Practice and Cases in
Emergency Medicine (CPC*EM*) is
now indexed on Scopus – Elsevier's
Abstract and Citation Database!**



CPC*EM* Clinical
Practice
& Cases



PubMed[®]

Also indexed in PubMed and PubMed Central

Call for Section Editors

- Behavioral Emergencies
- Cardiac Care
- Geriatrics
- Musculoskeletal
- Trauma
- Toxicology
- Legal Medicine

WestJEM Integrating Emergency Care
with Population Health
westjem.org

Send CV and letter of interest to
Editor@WestJEM.org

CALL FOR REVIEWERS!

WestJEM Integrating Emergency Care
with Population Health
westjem.org

CPCEM Clinical
Practice
& Cases

Send CV and letter of interest to
editor@cpcem.org

54-year-old Woman with Chest Pain

Zachary R. Wynne, MD*†
Kami M. Hu, MD‡§
Laura J. Bontempo, MD, MEd§
J. David Gatz, MD§

*University of Maryland Medical Center, Department of Emergency Medicine, Baltimore, Maryland

†University of Maryland Medical Center, Department of Medicine, Baltimore, Maryland

‡University of Maryland School of Medicine, Department of Medicine, Baltimore, Maryland

§University of Maryland School of Medicine, Department of Emergency Medicine, Baltimore, Maryland

Section Editor: Joel Moll, MD

Submission history: Submitted September 13, 2023; Revision received November 21, 2023; Accepted December 1, 2023

Electronically published March 26, 2024

Full text available through open access at http://escholarship.org/uc/uciem_cpccem

DOI: 10.5811/cpcem.1666

Chest pain is a common presentation to the emergency department (ED) that can be caused by a multitude of etiologies. It can be challenging to differentiate life-threatening conditions from more benign causes. A 54-year-old woman presented to the ED complaining of chest pain with dyspnea in the setting of recent blunt trauma. This case offers a thorough yet practical approach to the diagnostic workup of chest pain with dyspnea in the ED setting. The surprising final diagnosis and case outcome are then revealed. [Clin Pract Cases Emerg Med. 2024;8(2)83–89.]

CASE PRESENTATION (DR. WYNNE)

A 54-year-old woman was brought into the emergency department (ED) by emergency medical services (EMS) for suspected intoxication. The EMS personnel found the patient in front of a convenience store who stated, “a fat lady fell on me.” She complained of diffuse chest pain, which was worse with deep breaths, and shortness of breath. Prehospital vital signs were unremarkable. No treatments were initiated, and the patient was transported to the ED. Upon arrival, the patient told the ED staff that earlier that day, someone had fallen on top of her. She denied head trauma and had no loss of consciousness. Not long afterward, she tried to drive home but began to feel lightheaded and pulled over at the convenience store. The patient complained of ongoing, continuous chest pain without radiation. There was no associated diaphoresis, paresthesias, or cough. The patient did complain of shortness of breath and again stated that her chest pain worsened with deep breathing. She denied any fevers or chills, abdominal pain, nausea, vomiting, diarrhea, urinary symptoms, neck pain, or back pain.

Her medical history was notable for chronic obstructive pulmonary disease (COPD) for which she used home oxygen. She also had a remote history of breast cancer previously treated with bilateral lumpectomies. Her home medications included an as needed albuterol inhaler, fluticasone nasal

spray, and five milligram tablets of oxycodone as needed for chronic back pain. The patient reported a history of tobacco use, alcohol use (less than seven drinks a week), and occasional marijuana, cocaine, and ecstasy use. She was adamant she had not used any substances within the prior 24 hours.

On initial presentation, the patient’s vital signs were temperature 36° Celsius, heart rate 98 beats per minute, blood pressure 79/64 millimeters of mercury (mm Hg), respiratory rate 25 breaths per minute, and oxygen saturation 99% on room air. Her estimated body mass index was 21 kilograms per square meter. On examination, the patient was not diaphoretic and not in acute distress. Her pupils were equal and reactive without miosis. Her head showed no signs of trauma. Her neck had full range of motion with no cervical spine tenderness and no jugular venous distention. Her heart had regular rhythm, with borderline tachycardia, and with no murmurs. She had some left lateral chest wall tenderness without crepitus, deformity, or flail. Her lungs were clear to auscultation and symmetric bilaterally. On abdominal exam, she exhibited right upper and lower quadrant tenderness without rebound tenderness or guarding. Examination of the extremities showed no edema or tenderness. She was neurologically intact with a Glasgow Coma Scale score of 15 and no focal deficits.

Table 1. Initial laboratory results of a 54-year-old woman with chest pain.

Test	Patient value	Normal value
Complete blood count		
White blood cell count	23.0 × 10 ³ /μL	4.0–10.0 × 10 ³ /μL
Hemoglobin	11.8 g/dL	12.0–14.7 g/dL
Hematocrit	37.9%	36.0–45.0%
Platelets	467 × 10 ³ /μL	166–362 × 10 ³ /μL
Serum chemistries		
Sodium	139 mmol/L	136–145 mmol/L
Potassium	4.3 mmol/L	3.5–5.1 mmol/L
Chloride	100 mmol/L	98–107 mmol/L
Bicarbonate	22 mmol/L	21–30 mmol/L
Blood urea nitrogen	26 mg/dL	7–17 mg/dL
Creatinine	1.5 mg/dL	0.52–1.04 mg/dL
Glucose	295 mg/dL	70–99 mg/dL
Anion gap	17 mmol/L	
Calcium	9.5 mg/dL	8.6–10.2 mg/dL
Magnesium	2.6 mg/dL	1.6–2.6 mg/dL
Lactate - initial	3.8 mmol/L	0.5–2.2 mmol/L
Lactate - repeat	3.1 mmol/L	0.5–2.2 mmol/L
Hepatic studies		
Aspartate aminotransferase	55 U/L	14–36 U/L
Alanine aminotransferase	13 U/L	0–34 U/L
Alkaline phosphatase	144 U/L	38–126 U/L
Total bilirubin	0.4 mg/dL	0.3–1.2 mg/dL
Cardiac studies		
Troponin	0.9 ng/mL	<0.06 ng/mL
NT-proBNP	402 pg/mL	<300 pg/mL
D-dimer	5138 ng/mL FEU	<499 ng/mL FEU
Urinalysis studies		
White blood cell count	50 per hpf	0–5 per hpf
Red blood cell count	15–29 per hpf	0–2 per hpf
Leukocyte esterase	2+	Negative
Nitrite	Negative	Negative
Bacteria	Negative	Negative
Urine pregnancy test	Negative	Negative

K, thousand; *mL*, microliter; *g*, gram; *dL*, deciliter; *mmol*, millimole; *L*, liter; *mg*, milligram; *u*, units; *ng*, nanogram; *pg*, picogram; *FEU*, fibrinogen equivalent units; *hpf*, high-power field; *NT-proBNP*, N-Terminal Pro-Brain Natriuretic Peptide.

Laboratory studies were completed (Table 1). Complete blood count was notable for leukocytosis, mild anemia, and thrombocytosis. Basic metabolic panel was notable for an

elevated blood urea nitrogen (BUN) and creatinine. Liver function tests were notable for an elevated aspartate aminotransferase (AST) with a normal alanine aminotransferase (ALT) level along with an elevated alkaline phosphatase with normal total bilirubin. Urinalysis was notable for pyuria, hematuria, and leukocyte esterase. Initial lactate was 3.8 millimoles per liter (mmol/L), which trended down to 3.1 mmol/L after crystalloid and vasopressor therapy initiation. Troponin biomarker was elevated along with NT-pro-B-natriuretic peptide and D-dimer. An electrocardiogram (ECG) and a chest radiograph (CXR) were obtained as well (Images 1 and 2).

The patient received intravenous (IV) fluid resuscitation with crystalloid. Concurrently, she was started on a norepinephrine infusion to maintain a mean arterial pressure (MAP) of greater than 65 mm Hg. As her MAP improved, the infusion was then discontinued. The patient was started on empiric antibiotics with piperacillin/tazobactam due to the concern for sepsis of unknown etiology as the cause of her hypotension. A test was subsequently ordered, and a diagnosis was made.

CASE DISCUSSION (DR. HU)

Presented is a 54-year-old woman complaining of left-sided, pleuritic chest pain, lightheadedness, and shortness of breath after reported blunt trauma. There is concern from the accompanying medic that illicit substance use may be contributory, and the patient freely admits to substance use—but over 24 hours prior to symptom onset. There are no symptoms of recent illness or infection and, specifically pertinent to a trauma evaluation, no other pains and no hematologic issues.

The patient's past medical history includes a diagnosis of COPD on supplemental oxygen at baseline, which might predispose her to a spontaneous or traumatic pneumothorax if she experienced a bleb rupture. Her history of breast cancer, presumably in remission, does give me pause—a recurrence of local or metastatic disease or secondary pathology such as a pulmonary embolism (PE) related to malignancy-associated hypercoagulability could potentially be related to her presentation as well. Her surgical history and medication list do not seem out of the ordinary for her provided history. As noted previously, she admits to occasional marijuana, methylenedioxymethamphetamine (commonly known as MDMA, “ecstasy,” or “molly”), and cocaine use, which can certainly cause coronary artery vasospasm and the symptoms associated with ischemia.

Her physical exam findings are most remarkable for hypotension with a quite narrow pulse pressure, borderline tachycardia, and tachypnea despite an otherwise normal cardiopulmonary auscultatory exam, including a normal saturation without her home oxygen. This raises concern for heart failure, volume loss, and cardiac tamponade. Aortic stenosis as a cause of the narrow pulse pressure is unlikely

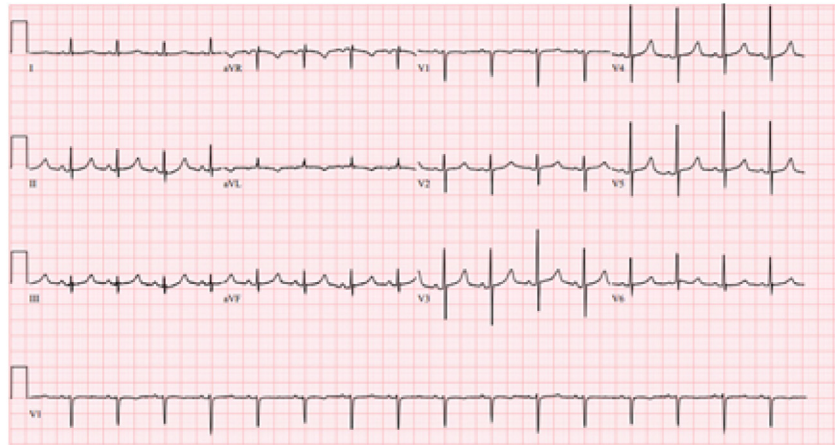


Image 1. Electrocardiogram of a 54-year-old woman with chest pain.

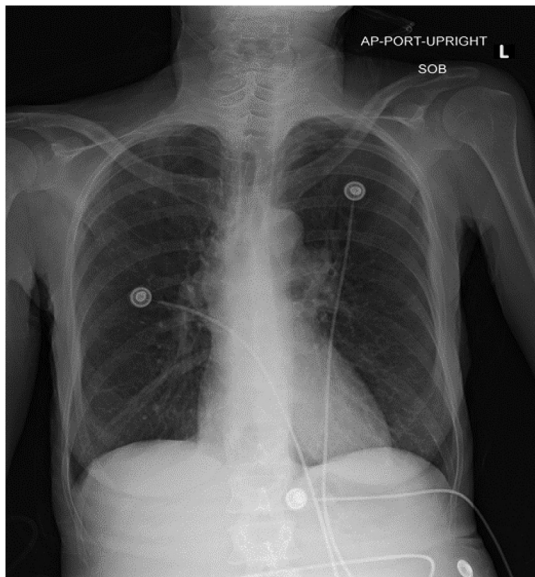


Image 2. Chest radiograph of a 54-year-old woman with chest pain.

given that no murmur was auscultated on her examination. The patient is not only tender over her left chest wall, but on the right side of her abdomen as well, despite previously denying abdominal pain. This raises concern for intrabdominal pathology such as trauma-related liver injury. She has, notably, no other signs of injury.

The majority of the positive lab findings are non-specific, and their chronicity is unclear: the leukocytosis and thrombocytosis could be reactive or inflammatory, and the anemia is borderline. Her BUN and creatinine are elevated; however, even if it were acute, kidney injury does not narrow the differential diagnosis. The transaminitis is mild, and an elevated AST could mean injury to the liver, skeletal muscle, heart, kidney, or brain. Of note, the ALT, which is more specific to the liver, is within normal limits, as is the total

bilirubin level, thus making primary liver pathology less likely. The most interesting lab abnormalities are the elevated troponin, natriuretic peptide, and D-dimer levels, as well as the lactate that does not clear with IV fluid administration.

Her CXR is generally unremarkable, without the classic (although uncommon) findings associated with PE such as Hampton hump, Westermark sign, parenchymal consolidation, Fleischner sign, or pleural effusion.¹ The clear CXR eliminates a large hydro/pneumothorax or a flail chest as the etiology of her symptoms. Her ECG demonstrates a normal sinus rhythm, with normal intervals, normal axis, and an isolated T-wave inversion in lead aVL, eliminating acute coronary syndrome as the cause of her chest pain.

Primarily neurologic disorders are excluded from the differential diagnosis, given the lack of any central nervous system related physical exam findings and the presence of hypotension. Pathologies causing a secondary increase in intracranial pressure would be accompanied by a normal or elevated blood pressure and bradycardia rather than hypotension. Similarly excluded are isolated psychiatric disorders and milder illnesses such as gastritis, bronchitis, and muscle strains, which could be consistent with her complaints but are inconsistent with her vital sign abnormalities.

The patient has an elevated glucose and a mild anion gap, but a diagnosis of diabetic ketoacidosis does not explain the rest of her cardiac lab abnormalities. She is not bradycardic and has no other cardinal signs or complaints associated with hypothyroidism such as myxedema or hypothermia, nor does she have the hypertension, headaches, palpitations, or flushing usually associated with pheochromocytoma. Her electrolytes and blood pressure improvement with fluids make a diagnosis of adrenal insufficiency unlikely, while the lab findings of an elevated platelet count and normal total bilirubin exclude the hematologic emergency thrombotic

thrombocytopenic purpura or other hemolytic anemias as a cause of her symptoms. A leukocytosis can be indicative of hematologic malignancy, but the white count elevation is too mild to be a cause of leukostasis leading to cardiac issues, and the leukemias are not typically associated with hypotension without other pathology.

While some toxicologic entities can cause hemodynamic instability, an elevated lactate, and cardiovascular lab abnormalities, it is unlikely for this patient's pathology to be attributable to cocaine use or something such as tricyclic antidepressant toxicity without notable findings on her ECG (such as T-wave and ST-segment changes in the case of the former, and PR-segment prolongation or QRS-complex widening in the latter). The lack of other supporting evidence or history for a toxin ingestion or exposure makes early cyanide toxicity and carbon monoxide poisoning unlikely as well.

The patient's vital signs did improve after receiving a broad-spectrum antibiotic and IV fluids, which could support a diagnosis of sepsis related to an unidentified infection. Infectious possibilities include a urinary tract infection or other etiologies that would cause chest pain, such as mediastinitis, septic arthritis, endocarditis, herpes zoster with or without bacterial cellulitis, and pneumonia with or without empyema. Left-sided chest wall pain is not likely to involve a bony joint, and with a clear CXR and no other symptoms or physical findings to support these diagnoses, the potentially positive urinalysis is the only indication of infection. A urinary tract infection is not much of a diagnostic dilemma, and one would expect a decreased diastolic pressure in sepsis from vasodilation rather than isolated systolic hypotension. Infectious etiologies are, therefore, removed from the differential diagnosis.

Gastrointestinal (GI) pathologies such as esophageal rupture, peptic ulcer disease with hemorrhage, and pancreatitis can cause some of the symptomatology, including chest pain, with which the patient presented, although again, there are no findings on her radiographs to indicate any of these. Her lipase is not elevated, and she has no history of chronic pancreatitis or alcohol use that might indicate a burnt-out pancreas incapable of causing an elevated lipase despite the presence of acute pancreatitis or pancreatic trauma. Although her smoking history does put her at higher risk of *Helicobacter pylori* infection, she is not on any medications that would predispose her to ulcer formation, and overall, a primary GI etiology to her presentation is unlikely.

What is left then are the primarily cardiovascular and traumatic diagnoses that could lead to her presentation. Even within these categories, the differential diagnosis for chest pain is vast and not significantly narrowed by the additional complaint of dyspnea. Incorporating the findings of hypotension and clear lungs, however, allows refinement of

the differential to a more manageable list that permits directed intervention and stabilization.

As previously noted, a relatively bland ECG and no mention of palpitations or other arrhythmias will strike acute coronary syndrome and unstable arrhythmias from the differential diagnosis. Although not 100% sensitive, a clear CXR without shift in the cardiac silhouette or sign of effusion makes a hemodynamically significant hemothorax or pneumothorax unlikely; so these will come off the differential diagnosis as well. Lower rib fractures could cause liver or splenic lacerations, but to cause hypotension these entities should cause a more pronounced anemia, and they do not really account for the pronounced cardiac lab abnormalities and normal ALT. What remains on my differential diagnosis then are cardiomyopathy, PE, cardiac tamponade, and aortic injury. Despite the elevated cardiac markers, isolated cardiomyopathy without an inciting factor is not enough of a diagnosis. There are no signs indicative of a sudden decompensated heart failure due to chronic illness, such as pulmonary edema for left heart failure, or hypoxia due to severe pulmonary hypertension leading to right heart failure with lower extremity edema or hepatic congestion.

Aortic injury can be associated with secondary coronary ischemia or even tamponade, but her traumatic event is not consistent with the high shear stress that causes aortic trauma, which typically occurs with high-speed motor vehicle collisions or falls from great height. Both PE and cardiac tamponade can be associated with an acute-onset obstructive shock, with an elevated D-dimer, troponin, and natriuretic peptide, with hepatic congestion and elevated transaminases, with chest pain and dyspnea, and with clear lungs. Looking specifically at the transaminases, the elevation of AST without ALT leans more toward injury of a non-hepatic tissue, such as the cardiac muscle, rather than simple hepatic congestion. Returning to the provided ECG with these two diagnoses in mind, electrical alternans is noted to be present. Thus, considering all the above factors and in the setting of an admittedly unusual but definite blunt trauma, the most likely diagnosis is cardiac tamponade, with a point-of-care ultrasound being the diagnostic test of choice.

CASE OUTCOME (DR. WYNNE)

The patient was sent for a computed tomography, which showed moderate hemothorax with no PE or aortic dissection. She then had a formal echocardiogram in the ED, which showed a moderate to large pericardial effusion with impending cardiac tamponade. The patient was ultimately transferred to a trauma center and taken immediately to the operating room on arrival. Sternotomy and pericardial window were performed at which time 300 milliliters of blood was evacuated. The surgical team discovered that the apex of the heart had ruptured, and this was repaired intraoperatively.

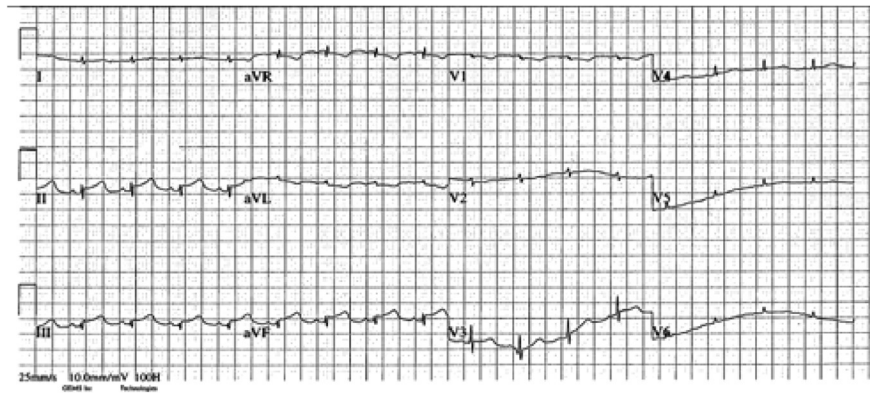


Image 3. Postoperative electrocardiogram of a 54-year-old woman with chest pain.

The following day, the patient had an ECG (Image 3) that showed an inferior ST-segment elevation myocardial infarction. Repeat transthoracic echocardiogram showed apical hypokinesis. Coronary angiography done the same day showed a stumped left anterior descending artery, likely secondary to the recent surgical repair. Her postoperative course was complicated by multiple pneumothoraces, but she was ultimately discharged from the hospital several weeks later.

RESIDENT DISCUSSION

Cardiac tamponade remains a relatively rare but striking presentation of obstructive circulatory shock caused by an accumulating pericardial effusion. The pericardial effusion can be a result of multiple etiologies including blunt trauma (as in our patient), penetrating trauma, malignancy, infection (such as tuberculosis), autoimmune conditions, uremia, and others.^{2,3}

Physiologically, cardiac tamponade is more appropriately considered as a spectrum of disease rather than simply as being present or absent.⁴ Initially, the patient will have a pericardial effusion without physiologic signs. With accumulation of this effusion, there will be an increase in the pressure exerted by the pericardium on the cardiac chambers. Patients are often asymptomatic at this stage but are considered at risk for tamponade.⁵ The rate of accumulation of the fluid determines the volume threshold at which symptomatic cardiac tamponade occurs.^{3,5} Quickly accumulating effusions, such as those seen in blunt or penetrating cardiac injuries, will lead to tamponade physiology developing at lower effusion volumes. This is due to the inability of the fibrous pericardial sac to stretch rapidly.⁵ In the case of subacute or chronic effusions, the pericardial sac can compensate over time, leading to effusion volumes as high as one liter prior to the development of cardiac tamponade.⁵

Once the pericardial pressure exceeds the right atrial pressure, venous inflow from the vena cava is impaired due to diastolic collapse of the right atrium. This can initially be

overcome with increased central venous pressure through fluid resuscitation.³ Eventually, increasing pericardial pressure leads to right atrial collapse in systole (sensitive for cardiac tamponade) and ventricular collapse in diastole (specific for cardiac tamponade).^{6,7} Next, the pericardial effusion begins to overcome diastolic filling pressures of all four chambers. This leads to increased interventricular dependence, the state in which all four chambers must share a fixed intrapericardial volume.⁸ During inspiration, decreased intrathoracic pressure and subsequent decreased pulmonary vascular resistance leads to increased filling of right-sided chambers with consequent decreased filling of left chambers in this fixed volume. The opposite occurs during expiration in which left-sided chambers are filled more so than the right-sided chambers due to increased resistance encountered by the right-sided chambers. This phenomenon leads to respiratory variation in cardiac output, known as pulsus paradoxus (defined by a decline by 10 mm Hg or greater in systolic blood pressure during inspiration).^{8,9}

Cardiac output is initially maintained by increases in heart rate as well as increased systemic vascular resistance by endogenous catecholamines. These patients are often hypertensive early in their course;⁵ however, decreased stroke volumes from decreased chamber filling eventually leads to hypotension. Narrow pulse pressure remains a physiologic hallmark of cardiac tamponade due to worsening cardiac output. Eventually, pressures of the four cardiac chambers equalize and pericardial pressures begin to increase exponentially. A critical volume is reached after which the significantly decreased cardiac output is unable to perfuse the coronary arteries sufficiently, known as “last drop phenomenon.” Patients often then have a vagal response and develop cardiac arrest due to coronary arterial hypoperfusion.⁵

Typical symptoms of cardiac tamponade include dyspnea, chest discomfort or pain, and tachypnea.⁵ Patients with late-stage cardiac tamponade may show clinical signs of circulatory shock such as altered mental status and cool

extremities. Patients will often have clear lung sounds if no other pathologic process is present. Subacute forms of cardiac tamponade will show signs of right heart failure, such as lower extremity edema and jugular venous distension.^{3,5} Beck triad (jugular venous distension, muffled heart sounds, and hypotension) has often been taught in medical schools to clinically diagnose cardiac tamponade,¹⁰ but recent research suggests that these findings, separate or in combination, may not sufficiently exclude or rule in cardiac tamponade.^{11,12} Electrocardiogram findings such as low QRS-complex voltage and electrical alternans can suggest cardiac tamponade but are neither sensitive nor specific to the condition.¹³

As clinical diagnosis can be inaccurate, point-of-care or formal echocardiogram should be obtained in patients with undifferentiated dyspnea with concern for possible cardiac tamponade.^{10,14} The presence of a pericardial effusion should warrant further investigation. The size of the effusion alone will not determine where a patient falls on the spectrum of illness of cardiac tamponade. Right atrial collapse during systole is sensitive for cardiac tamponade while right ventricular diastolic collapse and left atrial systolic collapse are specific.⁵⁻⁷ A plethoric inferior vena cava without respiratory variation, although nonspecific, further supports a diagnosis of cardiac tamponade, while its absence makes it unlikely. Other sonographic findings include mitral inflow velocity respiratory variation (also known as sonographic pulsus paradoxus), and hepatic flow reversal (measured by pulsed wave Doppler).^{6,7,15}

Management of the obstructive circulatory shock caused by cardiac tamponade focuses on removal of the pericardial effusion.^{10,14} Prior to removal of fluid, patients can be initially stabilized with fluid resuscitation if they appear hypovolemic.³ Often, these patients have maximum intrinsic catecholamine stimulation, and further inotropic support does not lead to improved hemodynamics.⁵ Positive pressure ventilation should be used cautiously and only if absolutely necessary due to the risk of further decreases in venous return from increased intrathoracic pressure.³ Removal of the pericardial effusion can be accomplished in several ways. Bedside pericardiocentesis can be performed in the setting of impending or ongoing cardiac arrest or persistent hypotension despite fluid resuscitation and vasopressor use.^{5,10,14} Patients with purulent effusions or effusions in the setting of trauma can have pericardial drain placement done in the operating room, angiography suite or by interventional radiology. In patients with traumatic arrests, thoracotomy with pericardiectomy can be done to rapidly decompress the pericardium and assess for other traumatic injuries of the thorax.¹⁶

FINAL DIAGNOSIS

Cardiac tamponade from ventricular apex rupture in the setting of blunt cardiac trauma

KEY POINTS

1. Patients who present early in the course of cardiac tamponade will often be tachycardic and hypertensive with narrow pulse pressures. Hypotension and signs of end-organ failure are late findings.
2. The pressure, not the volume, of the pericardial effusion will determine when a patient develops clinical evidence of cardiac tamponade. A slower accumulation rate of pericardial fluid will allow greater effusion volumes prior to signs and symptoms appearing.
3. Consider early point-of-care echocardiography in patients with undifferentiated dyspnea who have no obvious pulmonary etiology.

The authors attest that their institution requires neither Institutional Review Board approval, nor patient consent for publication of this case report. Documentation on file.

Address for Correspondence: J. David Gatz, MD, University of Maryland, Department of Emergency Medicine, 110 S Poca Street, 6th Floor, Suite 200, Baltimore, MD 21201. Email: jgatz@som.umaryland.edu

Conflicts of Interest: By the CPC-EM article submission agreement, all authors are required to disclose all affiliations, funding sources and financial or management relationships that could be perceived as potential sources of bias. Dr. Gatz was supported by a grant from the National Foundation of Emergency Medicine during this time.

Copyright: © 2024 Wynne et al. This is an open access article distributed in accordance with the terms of the Creative Commons Attribution (CC BY 4.0) License. See: <http://creativecommons.org/licenses/by/4.0/>

REFERENCES

1. Coche E, Verschuren F, Hainaut P, et al. Pulmonary embolism findings on chest radiographs and multislice spiral CT. *Eur Radiol.* 2004;14(7):1241–8.
2. Azarbal A and LeWinter MM. Pericardial effusion. *Cardiol Clin.* 2017;35(4):515–24.
3. Mekontso Dessap A and Chew MS. Cardiac tamponade. *Intensive Care Med.* 2018;44(6):936–9.
4. Reddy PS, Curtiss EI, Uretsky BF. Spectrum of hemodynamic changes in cardiac tamponade. *Am J Cardiol.* 1990;66(20):1487–91.
5. Spodick DH. Acute cardiac tamponade. *N Engl J Med.* 2003;349(7):684–90.
6. Alerhand S and Carter JM. What echocardiographic findings suggest a pericardial effusion is causing tamponade? *Am J Emerg Med.* 2019;37(2):321–6.
7. Alerhand S, Adrian RJ, Long B, et al. Pericardial tamponade: a comprehensive emergency medicine and echocardiography review. *Am J Emerg Med.* 2022;58:159–74.

8. Petit M and Vieillard-Baron A. Ventricular interdependence in critically ill patients: from physiology to bedside. *Front Physiol.* 2023;14:1232340.
9. Swami A and Spodick DH. Pulsus paradoxus in cardiac tamponade: a pathophysiologic continuum. *Clin Cardiol.* 2003;26(5):215–7.
10. Chiabrando J, Bonaventura A, Vecchié A, et al. Management of acute and recurrent pericarditis. *J Am Coll Cardiol.* 2020;75(1):76–92.
11. Stolz L, Valenzuela J, Situ-LaCasse E, et al. Clinical and historical features of emergency department patients with pericardial effusions. *World J Emerg Med.* 2017;8(1):29–33.
12. Roy CL, Minor MA, Brookhart MA, et al. Does this patient with a pericardial effusion have cardiac tamponade? *JAMA.* 2007;297(16):1810–8.
13. Goyal M, Woods KM, Atwood JE. Electrical alternans: a sign, not a diagnosis. *South Med J.* 2013;106(8):485–9.
14. Adler Y, Charron P, Imazio M, et al. ESC Scientific Document Group. 2015 ESC guidelines for the diagnosis and management of pericardial diseases: the task force for the diagnosis and management of pericardial diseases of the European Society of Cardiology (ESC) endorsed by: The European Association for Cardio-Thoracic Surgery (EACTS). *Eur Heart J.* 2015;36(42):2921–64.
15. Ginhina C, Beladan CC, Iancu M, et al. Respiratory maneuvers in echocardiography: a review of clinical applications. *Cardiovasc Ultrasound.* 2009;7:42.
16. Ishida K, Kinoshita Y, Iwasa N, et al. Emergency room thoracotomy for acute traumatic cardiac tamponade caused by a blunt cardiac injury: a case report. *Int J Surg Case Rep.* 2017;35:21–4.

Using Point-of-care Ultrasonography to Diagnose Traumatic Arthrotomy of the Knee: A Case Series

Jordan Mullings, MD*
Henry Ashworth, MD, MPH*
Matthew Kongkatong, MD†
Daniel Mantuani, MD*

*Alameda Health System, Department of Emergency Medicine, Highland Hospital, Oakland, California

†University of Virginia Health System, Department of Emergency Medicine, Charlottesville, Virginia

Section Editor: Shadi Lahham, MD

Submission history: Submitted October 3, 2023; Revision received October 26, 2023; Accepted November 16, 2023

Electronically published February 13, 2024

Full text available through open access at http://escholarship.org/uc/uciem_cpem

DOI: 10.5811/cpcem.1919

Introduction: Accurate diagnosis of traumatic arthrotomy of the knee (TAK) is critical for patients presenting to the emergency department (ED) to ensure timely treatment. Current diagnostic modalities including plain radiography, computed tomography (CT), and the saline load test (SLT) have advantages and disadvantages. Point-of-care-ultrasonography (POCUS) offers a possible timely, low-cost, and efficient alternative method of diagnosing TAK. In this case series we present three cases where POCUS was used to diagnose TAK in the ED.

Case Series: Three patients in their early 20s presented to the ED complaining of knee trauma with wounds in proximity to the joint. Mechanisms of injury included a gunshot wound in one case and blunt trauma (motor vehicle collision and bicycle crash) in two cases. In all three cases TAK was suggested on POCUS examinations by the presence of intra-articular hyperechoic foci consistent with air artifact. All three cases had TAK confirmed by orthopedic evaluation.

Discussion: Ultrasound may have utility in the evaluation of patients presenting with knee trauma where TAK is a concern. The SLT is generally considered the gold standard test for diagnosis of TAK, but it is invasive and has a wide range of diagnostic accuracy. Intra-articular air has been found to be a sensitive marker for TAK in CT studies. Thus, additional investigations into the diagnostic accuracy of POCUS for this finding should be undertaken. [Clin Pract Cases Emerg Med. 2024;8(2)90–94.]

Keywords: case report; POCUS; traumatic arthrotomy; intra-articular air; musculoskeletal ultrasound.

INTRODUCTION

Traumatic arthrotomy of the knee (TAK) involves damage to the capsule or supporting structures (eg, ligaments) that results in violation of the joint space.¹ Typically, traumatic arthrotomies are treated by operative irrigation and debridement, although there is emerging evidence that small, noncontaminated defects can be safely treated at the bedside.² Delay in diagnosis and treatment can result in the development of septic arthritis resulting in significant increases in morbidity (50%) and mortality (11–15%).³

Previous studies have documented the diagnostic modalities that are most effective at detecting TAK in cases

where it is not obvious on physical examination.⁴ These include a saline load test (SLT) with or without methylene blue and computed tomography (CT). Radiographs are commonly obtained in the evaluation of joint injuries. They have reasonable sensitivity (78%) and high specificity (90%) for TAK when intra-articular air is detected. However, this finding may be subtle and overlooked if the reader is concentrating on evaluation for bony injury.¹

The SLT as a diagnostic tool can be unpredictable, with sensitivities reliant on multiple factors.⁵ While an increased amount of injected saline leads to improved sensitivity (99% for 175 milliliters (mL), results vary based on joint location, patient tolerance of injection, and time spent on procedure.^{1,5}

Passive ranging of the joint while performing the SLT has also shown some improvements in the sensitivity of the test; however, combining the SLT with methylene blue injections has shown little to no benefit.⁵ There are also some studies reporting that operator proficiency can lead to false negative and false positive results.^{5,6} The SLT is also painful, particularly when large volumes are used, which may limit the operator's ability to perform the test thoroughly.

Computed tomography has been investigated as an alternative test for traumatic arthrotomy in recent years. The modality has been shown to be both highly sensitive (100%) and specific for TAK in a cohort of 62 emergency department (ED) patients presenting with wounds around the knee.⁷ In these protocols intra-articular air is used to make the diagnosis and CT is sensitive enough to detect as little as 0.1 mL of air.⁸ Computed tomography has been shown to have similar performance in the evaluation of traumatic arthrotomy of other joints as well.^{1,9} Computed tomography can also better characterize fracture patterns and inform treatment decisions compared to radiograph.¹⁰ However, high utilization of CT exposes patients to increased amounts of ionizing radiation, incurs significant cost to the healthcare system, and requires that the patient leave the treatment area.

Since intra-articular air appears to be a useful imaging finding to diagnose TAK, point-of-care-ultrasonography (POCUS) may be a useful bedside test, allowing for rapid diagnosis while sparing patients ionizing radiation and painful diagnostic procedures. Below we describe the sonographic steps to diagnose TAK, followed by three cases demonstrating the utility of ultrasound in identifying TAK.

Knee joints were scanned using a high-frequency linear probe in the sagittal plane, starting at the anterior knee in the suprapatellar region (*Image 1A*). Initial orientation of the probe collected views of the following structures in relation to the probe marker: patella (inferior aspect of the view); joint

Population Health Research Capsule

What do we already know about this clinical entity?

Traumatic knee arthrotomies can lead to septic arthritis if not identified and treated appropriately.

What makes this presentation of disease reportable?

To our knowledge, this is only the second case series where point-of-care-ultrasound (POCUS) was used to accurately diagnose traumatic arthrotomies in living patients.

What is the major learning point?

Intra-articular air is readily seen on POCUS of knee joints and has precedent of being a good marker for arthrotomy in other modalities.

How might this improve emergency medicine practice?

Identification of intra-articular air on POCUS of joints may allow for the rapid, noninvasive diagnosis of traumatic arthrotomy.

capsule; and distal femur (superior aspect of the view), as seen in *Image 1B* (normal view). Images captured include various views in the described orientation along a

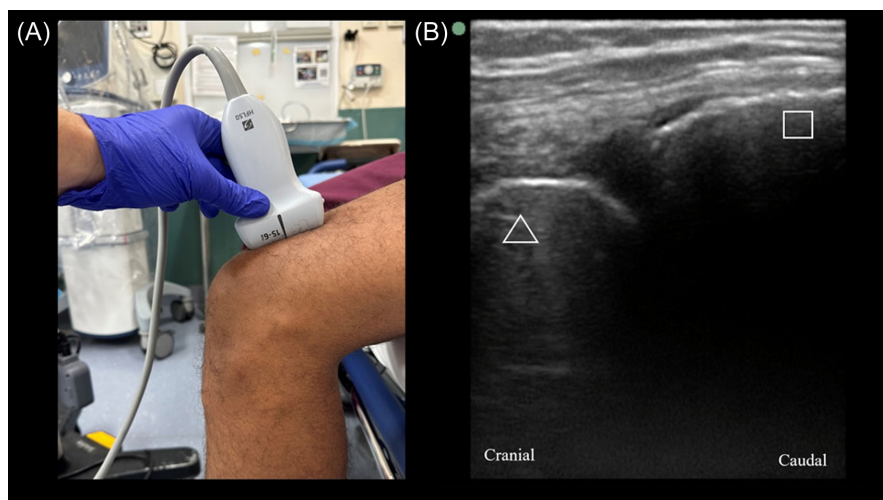


Image 1. (A) The orientation of the probe placed in the sagittal plane in the suprapatellar region with the probe marker oriented cranially; (B) a scan showing a normal knee with the triangle indicating the distal femur and the square marking the patella.

medio-lateral path. Abnormal findings were collected and are documented below.

CASE SERIES

Case 1

A 20-year-old male presented to the ED with a gunshot wound to the anterior, right knee. He reported difficulty walking and limited range of motion of the knee. On physical examination, he had two missile wounds on the medial aspect of his leg: one superior to the patella and one inferior to the tibial plateau. The initial radiograph showed no occult fracture but demonstrated bullet fragments near the knee joint. A POCUS examination by the emergency physician (EP) scanning the suprapatellar recess showed internal hyperechoic linear structures concerning for free air (*Image 2*, Case 1) within hypoechoic effusion with anechoic bubbles concerning for lipohemarthrosis. The EP made the preliminary diagnosis of TAK. A CT was ordered to confirm TAK, but due to the overnight burden of trauma patients it was not performed until seven hours after presentation with interpretation taking an additional hour. Orthopedics took the patient to the operating room (OR) the following day for irrigation and debridement where TAK was confirmed. The patient was given a prophylactic seven-day course of cephalexin 500 milligrams (mg) every six hours and a one-week follow-up with orthopedics.

Case 2

A 20-year-old male presented to the ED with a deep laceration to the left knee after a bicycle accident five hours prior. On examination, there was a deep, 15-centimeter (cm) long infrapatellar laceration with exposed but intact tendon. The patient was ambulatory, without neurologic deficits, and had full range of motion of the left knee. A POCUS examination of the left knee was performed by the EP and showed a hypoechoic joint effusion in the suprapatellar space

that contained numerous mobile, hyperechoic structures with posterior shadowing along the superior aspect of the fluid collection, suggestive of TAK (*Image 2*, Case 2). Subsequent radiographs of the knee demonstrated no bony injury but a possible small focus of gas in the suprapatellar recess. Computed tomography confirmed the presence of gas within the knee joint with the additional finding of a small, left femoral condyle avulsion fracture. The wound was irrigated with normal saline and dressed. Orthopedics was consulted, and the patient was started on vancomycin intravenously. He was taken to the OR the next day for irrigation and primary repair of the joint capsule.

Case 3

A 23-year-old female presented to the ED with a laceration near the right knee after a moderate-speed motor vehicle collision. On examination she had a 4-cm long laceration medial to the patella that extended into the subcutaneous tissue and significant pain with passive ranging of the knee. Radiographs of the knee did not demonstrate bony injury, but lucencies suspicious for air were noted by the EP in the region of the suprapatellar recess.

A POCUS examination of the knee joint was performed by the EP showing a hypoechoic joint effusion in the suprapatellar recess with hyperechoic structures with posterior shadowing (*Image 3*). These findings were interpreted as a hemarthrosis with intra-articular air bubbles suspicious for TAK. Orthopedics was consulted, which confirmed the arthrotomy with a positive SLT. The patient was treated with one gram of cefazolin and tetanus vaccination update. Orthopedics performed saline irrigation of the joint and primary repair of the capsule laceration at the bedside. The patient was discharged on a prophylactic course of cephalexin 500 mg every six hours for five days. At two-week follow-up with orthopedics she had no signs of joint infection.

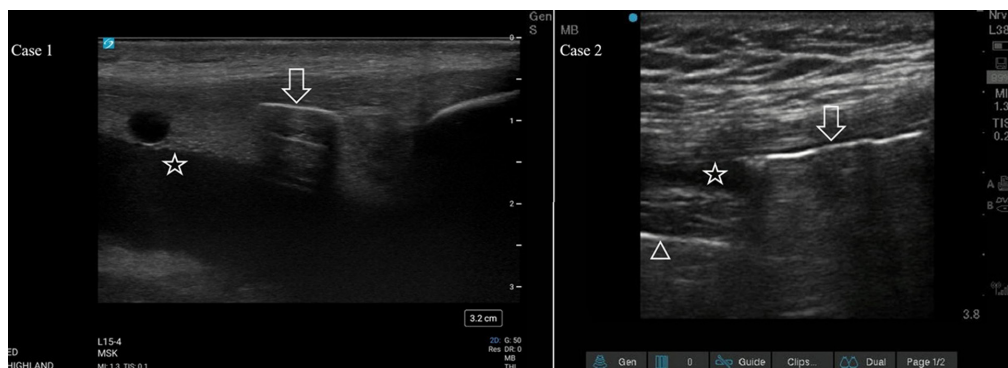


Image 2. Case 1) A sagittal view of the suprapatellar recess showing a hyperechoic focus of air with posterior shadowing (arrow) within an effusion (star). The effusion has multiple components, which is indicative of lipohemarthrosis. Case 2) A sagittal view of the suprapatellar recess showing a hyperechoic focus of air with posterior shadowing and reverberation artifact (arrow). Note how the signal from the cortex of the femur (triangle) is obscured by the shadowing. A small joint effusion is also visualized (star).

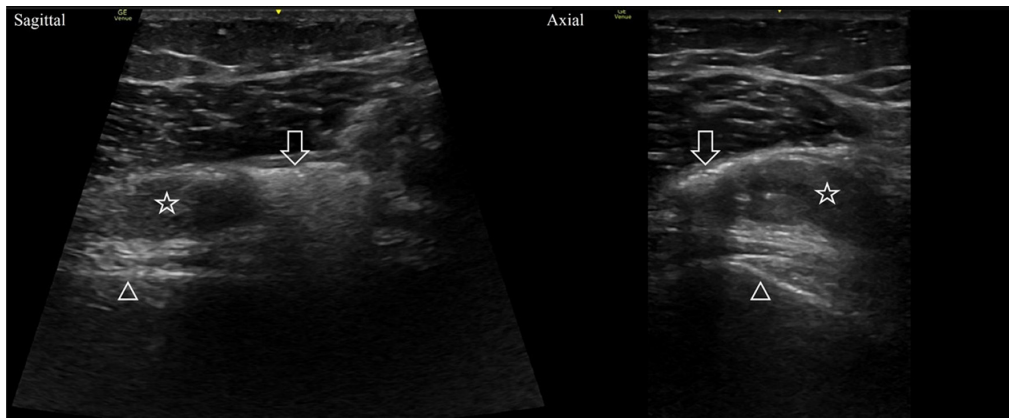


Image 3. Sagittal and axial views of the distal femur showing hyperechoic foci with posterior acoustic shadowing (arrows) within a hypoechoic hemarthrosis (stars). Note the shadowing obscures the signal from the femur cortex (triangles).

DISCUSSION

Traumatic arthrotomy should be considered during the evaluation of a patient with periarticular wounds due to the risk of septic arthritis. Currently, the SLT is recommended to diagnose traumatic arthrotomy in cases where arthrotomy is not obvious on physical examination. Point-of-care ultrasonography is an alternative, non-invasive imaging modality that has been demonstrated to have utility in evaluating various knee pathologies. One meta-analysis found that ultrasound had a sensitivity of 85% and specificity of 93% for traumatic and atraumatic knee effusions compared to magnetic resonance imaging.¹¹ Another prospective trial of patients with acute knee trauma found that ultrasonography was highly accurate compared to radiography in diagnosing intra-articular knee fractures when lipohemarthrosis was present.¹² Point-of-care ultrasonography has the benefit of being free of ionizing radiation and lower cost than CT, with the drawback of being operator-dependent. Computed tomography is also a highly used resource, which may lead to delays in diagnosis such as in Case 1.

Here we describe three patients with proven TAK first detected by POCUS examinations. Prior to this writing, our literature review resulted in only one German-language case series where POCUS examinations diagnosed TAK in patients presenting with knee trauma and periarticular wounds.¹³ As in our series, the finding of intra-articular air led to the correct diagnosis. The acoustic impedance mismatch between air and soft tissue makes air highly echogenic with resultant posterior shadowing (Video). Reverberation artifacts may also be seen with larger air bubbles.¹⁴ Literature regarding the diagnostic performance of POCUS for diagnosing knee arthrotomy in live patients is lacking. One cadaver study found a sensitivity of 65% and specificity of 75% for 1 mL of intra-articular air.¹⁵ The diagnostic performance of POCUS for TAK should be further investigated.

CONCLUSION

Point-of-care-ultrasonography has a wide array of applications in the evaluation of ED patients, including bone and joint pathology. This series suggests that POCUS may be effective in diagnosing traumatic arthrotomy of the knee, using intra-articular air as the positive finding. So far, the finding of intra-articular air in other modalities has been shown to be highly sensitive and specific for TAK. Additional studies should be undertaken to better elucidate the diagnostic performance of POCUS as a modality to diagnose TAK.

Video. Intra-articular air is visualized as a hyperechoic line with posterior shadowing (white arrow) that obscures the underlying cortex signal (black arrow).

Patient consent has been obtained and filed for the publication of this case report.

Address for Correspondence: Matthew Kongkatong MD, University of Virginia Health System, Department of Emergency Medicine, 1215 Lee Street Charlottesville, VA 22908.

Email: mk3wk@uvahealth.org

Conflicts of Interest: By the CPC-EM article submission agreement, all authors are required to disclose all affiliations, funding sources and financial or management relationships that could be perceived as potential sources of bias. The authors disclosed none.

Copyright: © 2024 Mullings et al. This is an open access article distributed in accordance with the terms of the Creative Commons Attribution (CC BY 4.0) License. See: <http://creativecommons.org/licenses/by/4.0/>

REFERENCES

1. Colmer HG 4th, Piroette M, Koyfman A, et al. High risk and low prevalence diseases: traumatic arthrotomy. *Am J Emerg Med.* 2022;54:41–5.

2. McKnight RR, Ruffolo M, Wally MK, et al. Traumatic arthrotomies: Do they all need the operating room? *J Orthop Trauma*. 2021;35(11):612–8.
3. Goldenberg DL. Septic arthritis. *Lancet*. 1998;351(9097):197–202.
4. Brubacher JW, Grote CW, Tilley MB. Traumatic arthrotomy. *J Am Acad Orthop Surg*. 2020;28(3):102–11.
5. Browning BB, Ventimiglia AV, Dixit A, et al. Does the saline load test still have a role in the orthopaedic world? A systematic review of the literature. *Acta Orthop Traumatol Turc*. 2016;50(6):597–600.
6. Konda SR, Howard D, Davidovitch RI, et al. The saline load test of the knee redefined. *J Orthop Trauma*. 2013;27(9):491–7.
7. Konda SR, Davidovitch RI, Egol KA. Computed tomography scan to detect traumatic arthrotomies and identify periarticular wounds not requiring surgical intervention: an improvement over the saline load test. *J Orthop Trauma*. 2013;27(9):498–504.
8. Konda SR, Howard DO, Gyftopoulos S, et al. Computed tomography scan to detect intra-articular air in the knee joint: a cadaver study to define a low radiation dose imaging protocol. *J Orthop Trauma*. 2013;27(9):505–8.
9. Perloff E, Posner A, Murtaza H, et al. CT scan versus saline load test for detection of traumatic wrist arthrotomy. *J Wrist Surg*. 2021;11(2):154–60.
10. Konda SR, Howard D, Davidovitch RI, et al. The role of computed tomography in the assessment of open periarticular fractures associated with deep knee wounds. *J Orthop Trauma*. 2013;27(9):509–14.
11. Meyer R, Lin C, Yenokyan G, et al. Diagnostic utility of ultrasound versus physical examination in assessing knee effusions: a systematic review and meta-analysis. *J Ultrasound Med*. 2022;41(1):17–31.
12. Bonnefoy O, Diris B, Moinard M, et al. Acute knee trauma: role of ultrasound. *Clinical Imaging*. 2007;31(2):147.
13. Grechenig W, Clement H, Peicha G, et al. Sonographischer Nachweis von Luft im Kniegelenk - eine experimentelle Studie und klinischer Fallbericht. *Ultraschall Med*. 2002;23(01):47–51.
14. Buttar S, Cooper DJr, Olivieri P, et al. Air and its sonographic appearance: understanding the artifacts. *J Emerg Med*. 2017;53(2):241–7.
15. Kongkatong M, Thom C, Moak J. Can ultrasound identify traumatic knee arthrotomy in a cadaveric model? *J Emerg Med*. 2019;57(3):362–6.

A Critical Combination of Esophageal Rupture and Upside-down Stomach: A Case Report

Kay Nicole Tipton, DO, MS*†
Daniel Schroder, DO*†

*UNC Health Southeastern, Department of Emergency Medicine,
Lumberton, North Carolina

†Campbell University, School of Medicine, Emergency Medicine Residency,
Lumberton, North Carolina

Section Editor: Joel Moll, MD

Submission history: Submitted January 15, 2023; Revision received October 5, 2023; Accepted October 10, 2023

Electronically published April 17, 2024

Full text available through open access at http://escholarship.org/uc/uciem_cpccm

DOI: [10.5811/cpcem.58206](https://doi.org/10.5811/cpcem.58206)

Introduction: Spontaneous esophageal rupture, or Boerhaave syndrome, and upside-down stomach are rare pathologies associated with grave sequelae. Boerhaave syndrome can have a mortality rate as high as 44%. Upside-down stomach accounts for less than 5% of hiatal hernias and can lead to incarceration and volvulus.

Case Report: An 80-year-old woman presented to the emergency department with sudden onset, severe epigastric pain. Physical examination revealed normal vital signs with mild epigastric tenderness. Imaging obtained revealed a large hiatal hernia and findings concerning for esophageal perforation. The patient was started on 3.375 grams of intravenous piperacillin/tazobactam, and transfer to a tertiary care facility was initiated. After transfer, esophagography confirmed a perforation near the gastroesophageal junction and findings consistent with an upside-down stomach. The patient underwent successful repair of the esophageal perforation and gastropexy followed by intensive care unit admission and ultimately discharge.

Conclusion: Boerhaave syndrome and upside-down stomach are two conditions with high associated morbidity and mortality requiring prompt intervention. Information obtained in the history and physical examination including acute onset of chest pain after vomiting, tachypnea, subcutaneous emphysema, and hypoxia can assist in the diagnosis of the described pathologies. These signs and symptoms can be subtle on examination but are important in raising clinical suspicion for an otherwise rare etiology for acute onset chest pain. [Clin Pract Cases Emerg Med. 2024;8(2)95–98.]

Keywords: *esophageal rupture; Boerhaave syndrome; upside-down stomach; hiatal hernia; case report.*

INTRODUCTION

Spontaneous esophageal rupture, or Boerhaave syndrome, is rare with an incidence as low as 3.1 per one million people per year and a mortality rate that triples with a delay in diagnosis of 48 hours from symptom onset.^{1,2} This condition was first described in a patient who vomited after a large meal and subsequently developed chest pain by Hermann Boerhaave, a Dutch professor of medicine.¹ Upside-down stomach or a type IV hiatal hernia is the rarest form of hiatal hernia, accounting for less than 5% of all hiatal hernias.³

This combination of pathology—Boerhaave syndrome in the setting of an upside-down stomach—has only been described once previously in the surgical literature.⁴ Each condition can individually lead to significant morbidity and mortality. Upside-down stomach has a high documented risk of incarceration, can lead to esophageal outlet obstruction and perforation, and has previously been suggested as a contributing factor to the development of spontaneous esophageal rupture.^{4,5} Boerhaave syndrome, if not urgently diagnosed and treated, can rapidly lead to mediastinitis and septic shock with a mortality rate of up to 44%.⁶

CASE REPORT

An 80-year-old woman with a history of gastroesophageal reflux and hypertension presented to the emergency department (ED) with sudden onset, severe, sharp epigastric pain with radiation to her back. The pain began after an episode of emesis immediately following the ingestion of polyethylene glycol approximately 11 hours prior to arrival. Upon her presentation to the ED, the patient was in apparent distress secondary to pain; however, her vital signs were normal with a temperature of 36.7° Celsius (C), blood pressure of 142/65 millimeters of mercury, heart rate of 80 beats per minute, and respiratory rate of 18 breaths per minute. Physical examination revealed only mild epigastric tenderness. No subcutaneous emphysema was present in the tissue overlying the neck or chest. Due to the patient's acute distress and comorbidities, a broad differential was considered for evaluation of critical etiologies of her clinical presentation including aortic dissection, bowel perforation, esophageal rupture, acute coronary syndrome, mediastinitis, bowel obstruction, and pancreatitis.

A chest radiograph (CXR) (*Image 1*) showed a large hiatal hernia with trace bilateral pleural effusions and displacement of the gastric bubble to the right. Computed tomography (CT) with contrast of the chest/abdomen/pelvis (*Images 2* and *3*) demonstrated a large hiatal hernia with most of the stomach in the chest, associated volvulus, bilateral pleural effusions, right greater than left, and a complex, partially fluid-filled collection along the posterior aspect of the hiatal

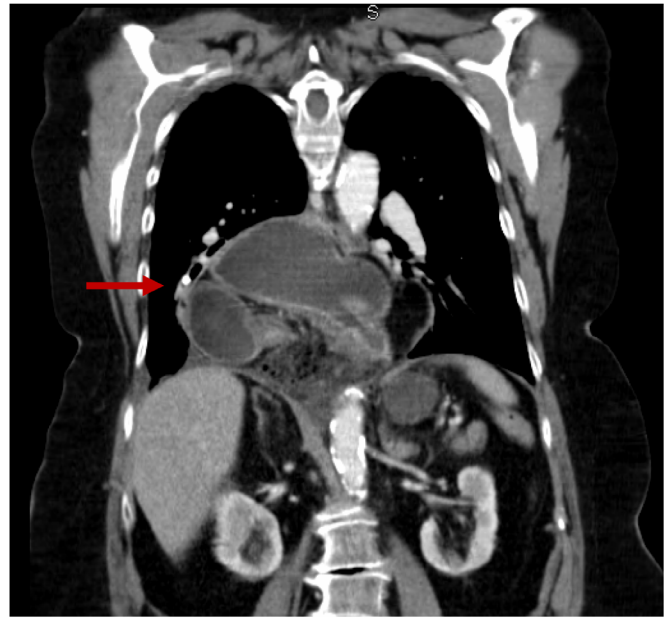


Image 2. Coronal view of computed tomography of the chest/abdomen/pelvis showing large hiatal hernia (arrow).

hernia just above the diaphragm. Laboratory studies revealed neutrophilic leukocytosis with 83.7 % neutrophils and a white cell count of 16.4×10^9 per liter (L) ($4.8\text{--}10.8 \times 10^9/\text{L}$) and elevated lactic acid of 2.3 millimoles per liter (mmol/L) ($0.5\text{--}2.2$ mmol/L). The patient was given 3.375 g of piperacillin/tazobactam intravenously for coverage of gastrointestinal flora, and transfer to a tertiary care facility was initiated. While in the ED, the patient developed room air hypoxia, which resolved with three liters of oxygen therapy via nasal cannula.

After transfer, a contrast esophagram was performed and showed a perforation near the gastroesophageal junction.

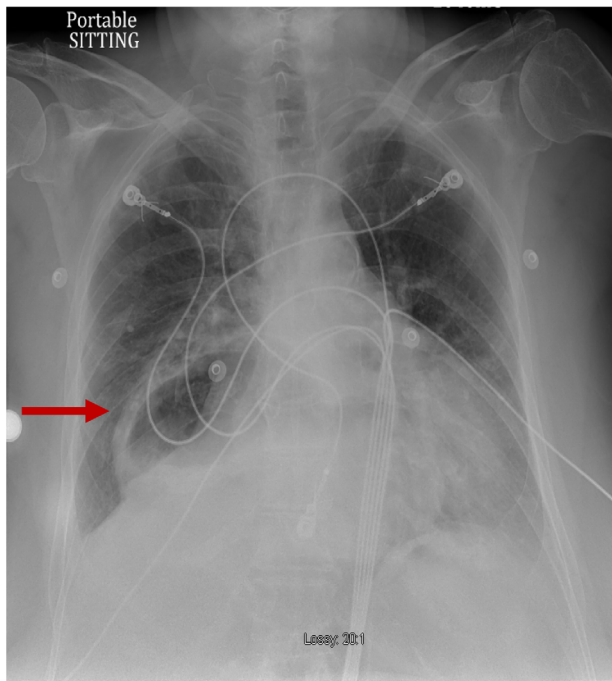


Image 1. Anterior-posterior chest radiograph demonstrating large hiatal hernia with displacement of the gastric bubble (arrow) from left to right.

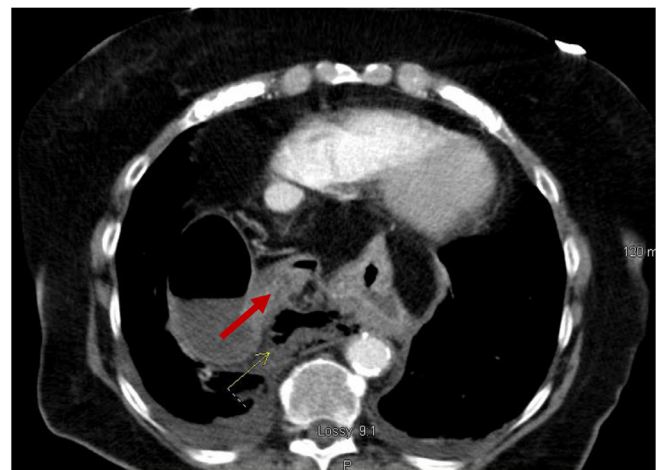


Image 3. Transverse view of computed tomography of the chest/abdomen/pelvis with an arrow indicating partially fluid-filled collection posterior to a large hiatal hernia suspicious for esophageal perforation.

The patient underwent an exploratory laparotomy, which confirmed the presence of an esophageal rupture near the squamocolumnar junction and revealed the presence of a giant hiatal hernia with an associated upside-down stomach. Surgical repair of the esophageal perforation and gastropexy was performed. The patient was admitted to the surgical intensive care unit for a total of five days during which she had an episode of atrial fibrillation with rapid ventricular response that resolved after metoprolol and diltiazem.

On day five of her hospitalization, she was transferred to a cardiac telemetry unit after being weaned off supplemental oxygen. She was continued on intravenous (IV) fluconazole 400 milligrams (mg) daily, piperacillin/tazobactam 3.375 g every eight hours, and vancomycin dosed and monitored by pharmacy for a total of 14 days. Multiple esophagrams were performed, which revealed a persistent leak from the esophagus; however, this resolved spontaneously with monitoring throughout the remainder of the hospital course. The patient was ultimately discharged on hospital day 18 with continued antibiotic therapy on amoxicillin-potassium clavulanate 600–42.9 mg twice daily for seven days. After discharge, the patient was seen for multiple follow-up visits, with the last follow-up occurring approximately 16 months after her original presentation.

DISCUSSION

Esophageal rupture is a rare condition with high morbidity and mortality that is iatrogenic in nature in approximately 70% of cases.² The spontaneous form of this condition is estimated to account for between 15–30% of cases.^{1,7,8} Boerhaave syndrome is thought to be caused by a sudden increase in intraesophageal pressure leading to a transmural tear through the esophageal tissue.⁴ Although it is important to maintain a comprehensive differential diagnosis, physicians must have a high suspicion for this condition as it is frequently misdiagnosed as perforated ulcers, myocardial infarction, or pulmonary emboli.⁴

This condition is an essential diagnosis for emergency physicians due to a mortality rate reaching as high as 44%. Risk factors for developing spontaneous esophageal rupture include male gender and alcohol abuse.¹ As described in the case above, there have been documented cases associated with polyethylene glycol ingestion for colonoscopy preparation. This preparation requires ingesting a large amount and can lead to forceful vomiting.⁹ In patients with Boerhaave syndrome, the most common presenting complaint is pain that is usually associated with the site of perforation and can occur in the neck, chest, or abdomen.² This may be associated with vomiting, painful swallowing, and voice change, or fever and physical examination may reveal the presence of tachycardia, tachypnea, and subcutaneous emphysema.^{1,2}

A CXR may show evidence of perforation; however, CT is preferred due to the lower sensitivity of plain radiography. If

suspicion remains high for the condition, a contrast esophagram is the preferred diagnostic modality. Barium should be avoided due to the possible development of mediastinitis if an esophageal leak is present; instead, water-soluble contrast should be used.¹ Although not commonly included in the standard diagnosis of Boerhaave syndrome, bedside point-of-care ultrasound has been used in specific cases. Findings on ultrasound include the presence of free fluid in the upper quadrants of the abdomen and air within the pericardium blocking the normal visualization of cardiac windows.¹⁰

Although the patient in this case did require surgical intervention, this is not true of all esophageal perforations. For non-operative management, patients must have small defects without significant involvement of structures outside the esophagus. These patients are treated with IV antibiotics for at least 7–10 days and supportive care measures including cardiac monitoring, supplemental oxygen, if necessary, and adequate analgesia. According to a 2010 article by Kaman et al, there are no clear recommendations for patients who should undergo surgical intervention although it likely includes, “early postemetic perforation, hemodynamic instability, intra-abdominal perforation, extravasations of contrast into adjacent body cavities and presence of underlying malignancy, obstruction or stricture in the region of the perforation and surgically fit patient.”²

Factors that increase the morbidity and mortality of this condition include time to diagnosis, size of the defect, cause of the defect, and association with neutrophilic leukocytosis.^{6,8} Possibly the most important factor is the time to diagnosis. A delay in diagnosis leads to an increased possibility of developing mediastinitis and sepsis secondary to the leakage of gastric enzymes and gastrointestinal flora. As little as a 48-hour delay can lead to a three-fold increase in mortality.²

Upside-down stomach is a type IV hiatal hernia, most commonly caused by the weakening of the diaphragmatic crura, which accounts for less than 5% of all diagnosed hiatal hernias.^{3,5} Although some patients may be asymptomatic, approximately one-third will develop life-threatening complications including volvulus, incarceration, perforation, severe gastric bleeding, and gastric ischemia.^{3,4} Surgical repair, often laparoscopic, is recommended urgently; however, emergent repair is only recommended when complications have occurred, due to the increased risks associated with emergent surgical repairs.^{3,5} In a previously described case of combined upside-down stomach and esophageal rupture, it was proposed that the large hiatal hernia resulted in blockage of the gastric outlet leading to forceful vomiting and ultimate rupture.⁴

CONCLUSION

Emergency physicians must consider broad differential diagnoses in all patients to ensure that time-sensitive diagnoses of conditions are made even in those patients who

present initially stable. In the above case, the patient presentation of abrupt onset epigastric pain immediately after an episode of emesis following the ingestion of polyethylene glycol led to rapid diagnosis of these rare conditions. Although the patient did decompensate in the ED with the development of tachypnea and hypoxia, rapid management of her condition with antibiotic therapy, oxygen administration, prompt transfer, and surgical intervention led to a favorable outcome.

The authors attest that their institution requires neither Institutional Review Board approval, nor patient consent for publication of this case report. Documentation on file.

Address for Correspondence: Kay Nicole Tipton, DO, MS, UNC Health Southeastern, 300 W 27th St., Lumberton, NC 28358.
Email: Nictip616@gmail.com

Conflicts of Interest: By the CPC-EM article submission agreement, all authors are required to disclose all affiliations, funding sources and financial or management relationships that could be perceived as potential sources of bias. No author has professional or financial relationships with any companies that are relevant to this study. There are no conflicts of interest or sources of funding to declare.

Copyright: © 2024 Tipton et al. This is an open access article distributed in accordance with the terms of the Creative Commons Attribution (CC BY 4.0) License. See: <http://creativecommons.org/licenses/by/4.0/>

REFERENCES

1. Turner AR and Turner SD. Boerhaave syndrome. In: *StatPearls*. Stat Pearls Publishing: Treasure Island, FL, 2022. Available at: <https://www.ncbi.nlm.nih.gov/books/NBK430808/>.
2. Kaman L, Iqbal J, Kundil B, et al. Management of esophageal perforation in adults. *Gastroenterol Res*; 2010;3(6):235–44.
3. Schiergens TS, Thomas MN, Hüttl TP, et al. Management of acute upside-down stomach. *BMC Surg*. 2013;13:55.
4. Saito S, Hosoya Y, Kurashina K, et al. Boerhaave's syndrome in a patient with an upside down stomach: a case report, *Int. J. Surg. Case Rep*. 2016;19:51–4.
5. Merza N, Lung J, Bazzaz O, et al. Rare case of upside-down stomach in advanced hiatal hernia. *SRCCC*. 2019;7(31):52–5.
6. Zimmermann M, Hoffmann M, Jungbluth T, et al. Predictors of morbidity and mortality in esophageal perforation: retrospective study of 80 patients. *Scand J Surg*. 2017;106(2):126–32.
7. Søreide JA, Konradsson A, Sandvik OM, et al. Esophageal perforation: clinical patterns and outcomes from a patient cohort of Western Norway. *Dig Surg*. 2012;29(6):494–502.
8. Kim JD. Prognostic factors of esophageal perforation and rupture leading to mortality: a retrospective study. *J Cardiothorac Surg*. 2021;16(1):291.
9. Yu JY, Kim SK, Jang EC, et al. Boerhaave's syndrome during bowel preparation with polyethylene glycol in a patient with postpolypectomy bleeding. *World J Gastrointest Endosc*. 2013;5(5):270–2.
10. Derr C and Drake JM. Esophageal rupture diagnosed with bedside ultrasound. *Am J Emerg Med*. 2012;30(9):2093.e1–3.

Acute Abdominal Pain and a Whirlpool Sign on Computed Tomography: A Case Report

Christopher Libby, MD, MPH*
Evan Stern, MD^{†‡}
Robyn Hoelle, MD^{†‡}

*Cedars Sinai Health System, Department of Emergency Medicine,
Los Angeles, California

[†]HCA Florida North Florida Hospital, Department of Graduate Medical Education,
Gainesville, Florida

[‡]University of Central Florida/HCA Florida Healthcare, Gainesville, Florida

Section Editor: Manish Amin, MD

Submission history: Submitted May 23, 2023; Revision received October 23, 2023; Accepted November 6, 2023

Electronically published February 13, 2024

Full text available through open access at http://escholarship.org/uc/uciem_cpccem

DOI: 10.5811/cpcem.1394

Introduction: Mesenteric volvulus is a rare cause of abdominal pain and bowel obstruction in elderly patients. When a mesenteric volvulus occurs in adult patients, the symptoms are often non-specific, which contributes to delays in diagnosis.

Case Report: We present a case of a 75-year-old female who presented with non-specific abdominal pain. The rare whirlpool sign on computed tomography identified a mesenteric volvulus as the cause of small bowel obstruction. She was taken to the operating room and, after successful resection of the small bowel, she recovered and ultimately was discharged home.

Conclusion: Early identification of a whirlpool sign and early surgical consultation are key to providing the best chance for salvage of ischemic small bowel due to mesenteric volvulus and to prevent a fatal outcome. [Clin Pract Cases Emerg Med. 2024;8(2)99–101.]

Keywords: *mesenteric volvulus; malrotation; midgut volvulus; whirlpool sign; acute abdominal pain.*

INTRODUCTION

While approximately 90% of midgut volvulus cases occur before the age of one year, cases are identified in patients of all ages.¹ Adult-onset midgut volvulus is especially rare with an incidence of only 0.2–0.5%.^{2,3} When adults present with midgut volvulus, the condition presents as acute onset only 10–15% of the time.⁴ Acute onset midgut volvulus presents similarly to patients with acute bowel obstructions; however, subacute presentations present more insidiously. Patients with subacute to chronic presentations may have non-specific gastrointestinal symptoms such as cramping, bloating, weight loss, nausea, and vomiting that may come and go for weeks to months until an acute presentation or a diagnosis is made on advanced imaging. Without a high degree of suspicion, patients with subacute midgut volvulus may suffer from a delay in diagnosis in the emergency department (ED) and definitive surgical treatment.⁵ In the patient presented here, initial symptoms were suggestive of numerous

abdominal pathologies. Diagnosis was ultimately revealed on computed tomography (CT) by identification of the whirlpool sign, which prompted life-saving surgical intervention.

CASE REPORT

A 75-year-old woman presented to the ED for evaluation of sudden onset of left lower quadrant abdominal pain. She reported that she began feeling the abdominal pain approximately four hours prior to arrival but did not come to the ED until she began to experience nausea and dry heaving with associated chills. She reported passing flatus but had not had a bowel movement in the preceding 24 hours. She denied any recent trauma to the abdomen or pelvis and did not report any abdominal surgical history. The patient reported a vague history of “abdominal infections” without a diagnosis by her primary care physician or gastroenterology. She denied drinking well water, traveling recently, or camping.

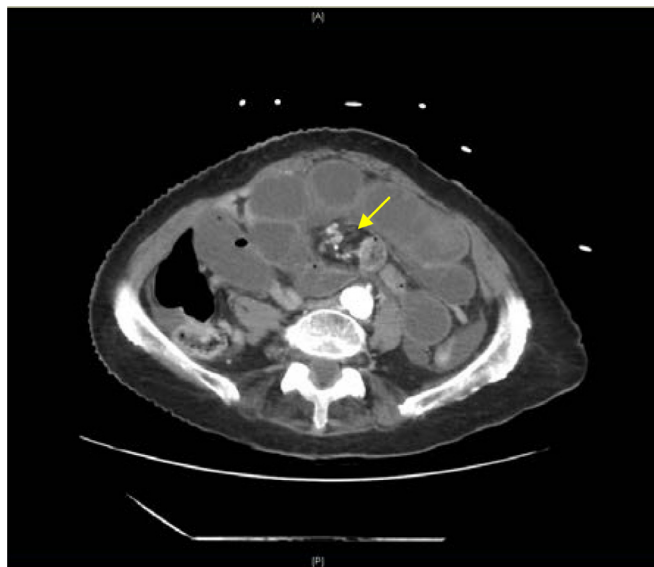

Image. Computed tomography abdomen with intravenous contrast demonstrating dilated, fluid-filled loops of small bowel and a pattern of swirling mesenteric vessels called the whirlpool sign (arrow).

She reported a history of pulmonary emboli 10 years prior, but held her warfarin dose that morning because her international normalized ratio (INR) was “high.”

On presentation the patient was in no acute distress but was clammy and tachycardic at a rate of 118 beats per minute. On exam, her abdomen was diffusely tender without distention or peritoneal signs. She had an elevated white blood cell count at 17×10^3 per microliter (K/ μ L) (reference range 4.5–11.0 K/ μ L), an INR of 5.5, and a lactic acid of 3.7 millimoles per liter (mmol/L) (0.4–2.0 mmol/L). An abdomen and pelvis CT with intravenous (IV) contrast showed findings suspicious for closed loop, small bowel obstruction. The CT also demonstrated evidence of swirling of the mesenteric root, known as a whirlpool sign (Image, Video). The findings of the whirlpool sign on CT suggested mesenteric volvulus as the cause of her bowel obstruction and prompted emergent surgical consultation.

The patient received fresh frozen plasma and vitamin K for reversal of her INR in preparation for emergent surgery. Intraoperatively, her mesenteric volvulus was reduced and eight feet (~243 cm) of jejunum was resected due to ischemia. She remained nil-per-os for seven days post-surgery before beginning a clear liquid diet, and she remained in the hospital for a total of nine days before being discharged to acute rehabilitation. She continued to recover and returned to baseline activities over the following month.

DISCUSSION

Although history, physical exam, and laboratory tests aid in diagnosing midgut volvulus, imaging is the most useful. Abdominal radiographs are very quick and can be done in the ED at bedside to rule out other causes of abdominal

Population Health Research Capsule

What do we already know about this clinical entity?

Mesenteric volvulus is a rare cause of small bowel obstruction. It can be difficult to distinguish from other causes without appropriate imaging.

What makes this presentation of disease reportable?

The whirlpool sign—swirling of the mesenteric vessels on computed tomography (CT) of the abdomen—is a classic finding for a mesenteric volvulus.

What is the major learning point?

A mesenteric volvulus is a surgical emergency, and delays in diagnosis in emergency department patients increase morbidity and mortality.

How might this improve emergency medicine practice?

When identifying a whirlpool sign on abdominal CT, emergency physicians should consider midgut volvulus and obtain surgical consultation.

pathology. However, radiographs are often inconclusive in midgut volvulus because even a positive “double bubble” sign indicating a small bowel obstruction does not rule out a concomitant midgut volvulus.⁷ Computed tomography with IV contrast gives much greater detail of the abdomen and can provide evidence suggestive of a midgut volvulus. Classic CT imaging findings include a whirlpool sign of twisted mesentery, malrotated bowel configuration, inverted superior mesenteric artery and superior mesenteric vein relationship, bowel obstruction, and free fluid/free gas in advanced cases.⁸ The whirlpool sign seen on CT represents the mesentery and superior mesenteric vein wrapping around the superior mesenteric artery in a counterclockwise direction.

The diagnosis of a midgut volvulus is considered a surgical emergency.⁹ Surgical consultation should not be delayed for additional testing once the history and imaging are suggestive of a volvulus. Time to surgical correction is the most important factor in mortality, which ranges from 0–25% in acute onset volvulus like our patient presented.⁶ When corrected before necrosis of the bowel has occurred, mortality can decrease to as low as 3–9%.¹ In addition to

standard treatment for a bowel obstruction, antibiotics covering against anaerobes and gram-negative organisms of the gut flora should be given to patients with midgut volvulus due to the high risk of translocation of bacteria secondary to bowel ischemia.¹⁰

CONCLUSION

Abdominal pain in the elderly population is a common chief complaint in the ED with many etiologies. Small bowel obstructions with concomitant mesenteric volvulus is a surgical emergency that requires early identification and surgical consultation, which can often be missed in subacute presentations with non-specific gastrointestinal complaints. Diagnosis by CT abdomen and pelvis with contrast remains the imaging modality of choice to identify midgut volvulus. Emergency clinicians should be familiar with the common CT findings for both small bowel obstructions and the mesenteric whirlpool sign suggestive of midgut volvulus, as it drastically changes the patient's prognosis and need for emergent surgical care.

Video. Computed tomography of the abdomen and pelvis with intravenous contrast shows the superior mesenteric artery branching off from the aorta and ultimately swirling with the mesentery to create the whirlpool sign, diagnostic of a midgut volvulus. Additionally, the swirl serves as a transition point for the small bowel obstruction seen in the video as dilated loops of fluid-filled small bowel.

The authors attest that their institution requires neither Institutional Review Board approval, nor patient consent for publication of this case report. Documentation on file.

Address for Correspondence: Christopher Libby, MD, MPH, Cedars Sinai Medical Center, Department of Emergency Medicine, 8700 Beverly Boulevard, Los Angeles, CA 90048. Email: Christopher.Libby@csmc.edu

Conflicts of Interest: By the *CPC-EM* article submission agreement, all authors are required to disclose all affiliations, funding sources and financial or management relationships that could be perceived as potential sources of bias. This research was supported (in whole

or in part) by HCA Healthcare and/or an HCA Healthcare affiliated entity. The views expressed in this publication represent those of the author(s) and do not necessarily represent the official views of HCA Healthcare or any of its affiliated entities.

Copyright: © 2024 Libby et al. This is an open access article distributed in accordance with the terms of the Creative Commons Attribution (CC BY 4.0) License. See: <http://creativecommons.org/licenses/by/4.0/>

REFERENCES

1. Fischer JE and Bland KI. *Mastery of Surgery*. 6th ed. Philadelphia, PA: Lippincott Williams & Wilkins; 2012.
2. Singh S, Das A, Chawla AS, et al. A rare presentation of midgut malrotation as an acute intestinal obstruction in an adult: two case reports and literature review. *Int J Surg Case Rep*. 2013;4(1):72–5.
3. Emanuwa OF, Ayantunde AA, Davies TW. Midgut malrotation first presenting as acute bowel obstruction in adults: a case report and literature review. *World J Emerg Surg*. 2011;6(1):22.
4. Durkin ET, Lund D, Shaaban A, et al. Age-related differences in diagnosis and morbidity of intestinal malrotation. *J Am Coll Surg*. 2008;206(4):658–63.
5. Butterworth WA and Butterworth JW. An adult presentation of midgut volvulus secondary to intestinal malrotation: a case report and literature review. *Int J Surg Case Rep*. 2018;50:46–9.
6. Dietz DW, Walsh RM, Grundfest-Broniatowski S, et al. Intestinal malrotation: a rare but important cause of bowel obstruction in adults. *Dis Colon Rectum*. 2002;45(10):1381–6.
7. Reeder MM and Felson B. *Reeder and Felson's Gamuts in Radiology, Comprehensive Lists of Roentgen Differential Diagnosis*, 4th ed. New York, NY: Springer Verlag; 2003.
8. Peterson CM, Anderson J, Hara A, et al. Volvulus of the gastrointestinal tract: appearances at multimodality imaging. *Radiographics*. 2009;29(5):1281–93.
9. Valsdottir E and Marks J. Volvulus: small bowel and colon. *Clin Colon Rectal Surg*. 2008;21(2):91–3.
10. Zheng L, Yu E, Zhang W, et al. Appropriate treatment of acute sigmoid volvulus in the emergency setting. *World J Gastroenterol*. 2013;19(30):4979–83.

Cardiac Arrest During a Ferric Derisomaltose Infusion Followed by Complete Heart Block: A Case Report

Michael Scott, PharmD
Natalie Jansen, MD, PhD
Leslie A. Bilello, MD

Beth Israel Deaconess Medical Center, Department of Emergency Medicine,
Boston, Massachusetts

Section Editor: Melanie Heniff, MD, JD

Submission history: Submitted September 5, 2023; Revision received January 3, 2024; Accepted January 5, 2024

Electronically published April 17, 2024

Full text available through open access at http://escholarship.org/uc/uciem_cpccm

DOI: [10.5811/cpcem.1650](https://doi.org/10.5811/cpcem.1650)

Introduction: Ferric derisomaltose is the newest available parenteral iron formulation. Studies have demonstrated a good safety profile with improved tolerability compared to alternative parenteral iron formulations. To date there have been no reported acute, life-threatening cardiac events associated with ferric derisomaltose.

Case Report: An 86-year-old male who had previously tolerated routine iron infusions received a first dose of ferric derisomaltose at an outpatient infusion clinic. Six minutes into the infusion the patient became unresponsive with no palpable pulse. Return of spontaneous circulation was achieved after two minutes of chest compressions. Electrocardiogram showed complete heart block requiring transcutaneous pacing and vasopressor administration. The patient was transferred to the emergency department for stabilization and then admitted to the cardiac intensive care unit. During admission, the patient received a dual-chamber, permanent pacemaker without complication and was ultimately discharged.

Conclusion: It may be reasonable to consider parenteral iron as a toxicological etiology for patients presenting with complete heart block temporally associated with parenteral iron administration, particularly in patients with underlying conduction abnormalities. [Clin Pract Cases Emerg Med. 2024;8(2)102–106.]

Keywords: *ferric compounds; iron; heart block; case report.*

INTRODUCTION

Parenteral iron is frequently utilized to treat iron deficiency anemia. A variety of parenteral iron products are available; the newest product in the United States is ferric derisomaltose (FDI) following US Food and Drug Administration approval in January 2020. Ferric derisomaltose was introduced in Europe in 2010 under the name iron isomaltoside. While serious adverse events caused by parenteral iron infusions are rare and typically characterized as anaphylactic-type reactions, FDI allows for high-dose rapid iron infusion with improved tolerability compared to older formulations. Ferric derisomaltose can provide full iron repletion with a single dose, thus reducing the number of infusions required.^{1,2} Here we describe a case

of cardiac arrest six minutes after initiation of FDI, with no obvious signs of anaphylaxis, followed by persistent complete heart block upon achieving return of spontaneous circulation (ROSC).

CASE REPORT

An 86-year-old, Farsi-speaking male with a past medical history of type 2 diabetes, chronic kidney disease stage IIIb (baseline serum creatinine 1.7–2.2 milligrams per deciliter (mg/dL), iron deficiency anemia, gastroesophageal reflux disease, peptic ulcer disease, colon cancer status post resection, coronary artery disease status post percutaneous coronary intervention in 2016, and Parkinson disease presented to an outpatient infusion clinic for a routine iron

infusion. He had previously received ferumoxytol infusions twice monthly with no documented reactions and was being switched to FDI to decrease infusion requirements. Home medications included atorvastatin, calcitriol, carbidopa-levodopa, furosemide, lisinopril, tamsulosin, aspirin, and sodium bicarbonate. He had no known allergies.

Ferric derisomaltose was initiated at 10:10 AM. At 10:16 AM the patient became unresponsive with agonal breathing and no palpable pulse. Chest compressions were initiated, and ROSC was achieved after one two-minute round of compressions. Epinephrine was not administered. Post-ROSC blood pressure (BP) was 60/30 millimeters of mercury (mm Hg), and point-of-care blood glucose was 220 mg/dL (reference range during fasted state: 70–100 mg/dL). A normal saline 1,000 mL bolus was initiated. The patient was placed on 100% oxygen via nonrebreather mask (NRB); intubation was not required. The patient was transferred to a nearby emergency department (ED) and found to be in complete heart block with significant ST depressions in the precordial leads ([Image 1](#)). Transcutaneous pacing was initiated. Heart rate at the time of transcutaneous pacing initiation was not reported. Norepinephrine and vasopressin were initiated following the placement of right tibial intraosseous and right femoral central lines. Pacing was discontinued after a heart rate above the pacing threshold was achieved (60 beats per minute [bpm]). Vasopressin was discontinued, and the patient was transferred to our tertiary-care ED by emergency medical services.

Upon arrival, the patient's vital signs were documented as heart rate 92 bpm, BP 136/49 mm Hg, and oxygen saturation 92% on NRB with respiratory rate range 12–37 breaths per minute. Norepinephrine was the only medication infusing for

CPC-EM Population Health Research Capsule

What do we already know about this clinical entity?

Ferric derisomaltose is the most recently approved parenteral iron product by the US Food and Drug Administration.

What makes this presentation of disease reportable?

We report a case of complete heart block that may have been precipitated by parenteral iron therapy.

What is the major learning point?

Although well-tolerated, newer parenteral iron formulations may pose risks that have not yet been elucidated.

How might this improve emergency medicine practice?

It may be reasonable for emergency physicians to consider iron chelation therapy if parenteral iron is the suspected etiologic agent of complete heart block.

hemodynamic support and was continued at 0.25 micrograms per kilogram per minute. Calcium gluconate 1 gram intravenous (IV) and magnesium sulfate 2 grams IV

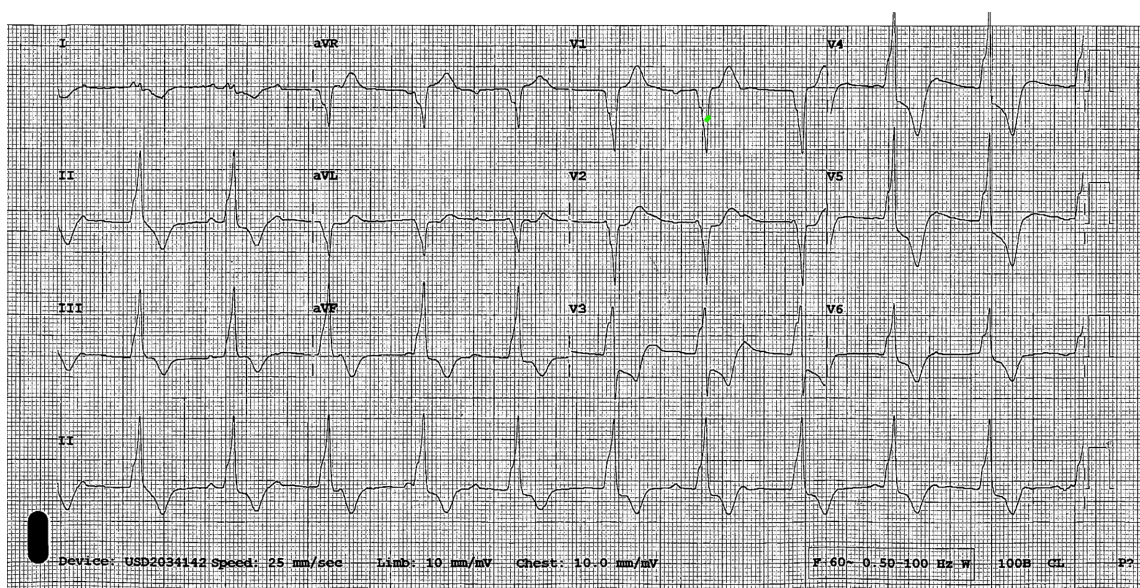


Image 1. Electrocardiogram showing complete heart block with ST depressions in precordial leads upon initial emergency department presentation at 11:14 AM.

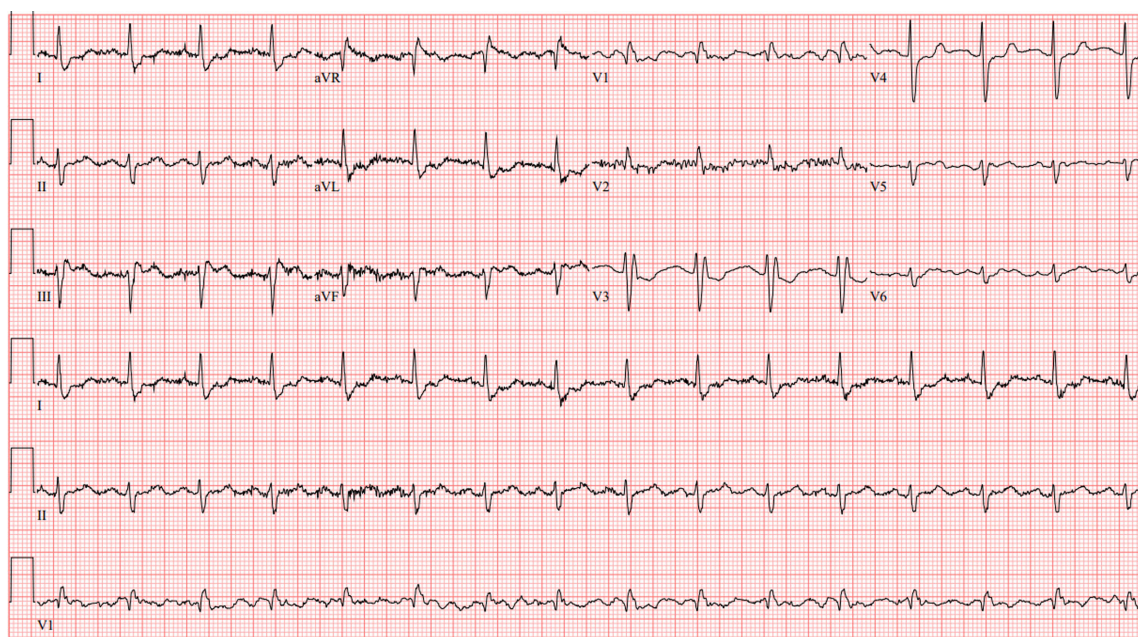


Image 2. Electrocardiogram upon arrival to tertiary-care emergency department at 1:26 PM.

were administered empirically. On exam, the patient was alert and oriented and exhibited bilateral lower extremity edema. Upon arrival to our ED, electrocardiogram (ECG) was repeated with resolution of previously appreciated ST depressions (Image 2). Therefore, a posterior ECG to investigate for posterolateral myocardial infarction was not performed. Troponin T was slightly elevated at 0.11 nanograms (ng) per mL (reference range 0–0.01 ng/mL) in the setting of chronic kidney disease. Creatinine kinase-MB isoenzyme resulted within normal limits (Table), making acute coronary syndrome less likely. No further acute interventions were required in the ED.

The patient was admitted to the cardiac intensive care unit (ICU), and vital signs at time of transfer from the ED to the cardiac ICU were documented as heart rate 75 bpm, BP 134/64 mm Hg, and oxygen saturation 99% on 1 liter nasal cannula. The patient was afebrile throughout his ED course. Upon electrophysiology evaluation in the cardiac ICU, the patient was found to have a right bundle branch block and left anterior fascicular block. During admission a dual-chamber, permanent pacemaker was placed with no complications, and the patient was discharged shortly afterward.

DISCUSSION

While the exact sequence of events preceding the patient's cardiac arrest is unknown, we suspect an association between the arrest and FDI. Notably, it is unclear whether the iron infusion precipitated heart block leading to cardiac arrest or if an anaphylactic-type reaction precipitated the arrest. However, an anaphylactic-type reaction seems less likely as there were no associated respiratory, cutaneous, or

Table. Lab results for elderly patient who suffered cardiac arrest following a high-dose rapid iron infusion.

Laboratory test	Result	Reference range
Thyroid stimulating hormone	2.2 μ IU/mL	0.27–4.2 μ IU/mL
Lyme VslE/PepC10	Positive	Negative
Lyme disease antibody	Negative	Negative
Iron	33 μ g/dL	45–160 μ g/dL
Total iron binding capacity	243 μ g/dL	260–470 μ g/dL
Ferritin	68 ng/mL	30–400 ng/mL
Transferrin	187 mg/dL	200–360 mg/dL
Potassium	4.5 mEq/L	3.5–5.4 mEq/L
Calcium	8.2 mg/dL	8.4–10.3 mg/dL
Magnesium	1.5 mg/dL	1.6–2.6 mg/dL
Phosphorous	3.1 mg/dL	2.7–4.5 mg/dL
Troponin T	0.11 ng/mL	< 0.10 ng/mL
Creatinine	1.9 mg/dL	0.5–1.2 mg/dL
CK-MB	6 ng/mL	0–10 ng/mL

μ IU, micro-international unit; mL, milliliter; VslE/PepC10, *Borrelia burgdorferi* antigens; μ g, microgram; dL, deciliter; ng, nanogram; mg, milligram; mEq, milliequivalent; L, liter; CK-MB, creatinine kinase-myoglobin binding.

gastrointestinal symptoms, and the acute event resolved without epinephrine administration.

As to other etiologies of the patient's cardiac arrest, there was no reported family history of premature coronary artery disease, dysrhythmia, cardiomyopathy, or sudden cardiac death. His most recently available ECG taken two years prior to the cardiac arrest showed a right bundle branch

block and left anterior fascicular block. The patient's family reported several episodes of syncope over the previous month. An ECG was not recorded surrounding these episodes. One episode occurred after using the bathroom, and another occurred while sitting in a chair. These prior syncopal events and the arrest may have been precipitated by complete heart block or vasovagal syncope. However, vagal etiology seems less likely as complete heart block episodes during inpatient admission showed a sinus rate in the 90s and ventricular escape in the 60s.

Laboratory results indicated that Lyme carditis, hyperkalemia, and hypothyroidism were also unlikely etiologies (Table), and the patient was not prescribed any atrioventricular blocking medications. Hypophosphatemia has been associated with parenteral iron administration, including the iron isomaltoside/FDI formulation³ and may result in myocardial contractility impairment and sudden cardiac death. However, lab results showed phosphorous levels within normal limits. Iron overload may exacerbate preexisting conduction disease and lead to heart block, but iron studies were within normal limits during admission, making iron overload an unlikely etiology⁴ (Table 1).

In the absence of other obvious causes, the iron infusion may have exacerbated an underlying conduction abnormality and precipitated the arrest. However, one limitation of this report is that this patient had multiple comorbidities, including prior syncopal events. While the FDI infusion was temporally associated with this patient's cardiac arrest, we cannot conclude for certain that the infusion was the sole contributor to the event as additional factors may have played a role.

The pathophysiologic basis for FDI causing cardiac arrest is not entirely clear. Animal models have demonstrated that acute iron toxicity leads to decreased myocardial contractility and cardiac output.^{5,6} While these effects have not been previously described following parenteral iron administration, we hypothesize that FDI may have exacerbated this patient's underlying cardiac abnormalities and precipitated the cardiac arrest. Rose and colleagues demonstrated that chronic iron overload reduces voltage dependent L type alpha 1D subunit calcium channel (Ca_v1.3) expression in the sinoatrial node, atria, atrioventricular node, and proximal ventricular conduction system leading to bradycardia, PR-interval prolongation, heart block, and conduction deficits.⁴

While our patient did not have chronic iron overload based on lab results, it is conceivable that rapid administration of IV iron could acutely precipitate similar effects in a patient with underlying conduction abnormalities, despite the administered iron not yet having sufficient time to distribute to the tissues. Another possible pathophysiologic explanation may be Kounis syndrome, a syndrome characterized by acute coronary events including

allergic coronary vasospasm, allergic myocardial infarction, or stent thrombosis secondary to a hypersensitivity reaction.⁷ Kounis syndrome has also been implicated in manifesting as fatal complete heart block.⁸ Considering parenteral iron's history of inducing acute hypersensitivity reactions, it is plausible that parenteral iron may induce Kounis syndrome and precipitate complete heart block and cardiac arrest in a patient with underlying conduction abnormalities.

Serious adverse events caused by parenteral iron infusions are rare and typically characterized as anaphylactic-type reactions, with one study finding only two documented serious adverse events requiring epinephrine administration out of 35,737 unique iron infusions.¹ Ferric derisomaltose has been demonstrated as safe and well tolerated compared to more commonly used parenteral iron products.⁹ One study comparing FDI to iron sucrose (IS) found sinus node dysfunction in 1/1,019 patients (0.1%) and 1/506 (0.2%) patients receiving FDI and IS, respectively, and 1/1,019 (0.1%) patients receiving FDI had cardiac arrest compared to 2/506 (0.4%) in the IS group.¹⁰ Another study comparing FDI to usual care (no iron or oral iron) reported bradycardia rates of 2/559 (0.4%) vs 1/568 (0.2%), complete atrioventricular block rates of 1/559 (0.2%) vs 3/568 (0.5%), and cardiac arrest rates of 6/559 (1.1%) vs 15/568 (2.6%), respectively.¹¹ It is unknown whether documented cardiac effects occurred acutely following parenteral iron administration or they occurred at another time during the study period as both studies analyzed the long-term safety of FDI.

Bradycardia and heart block are rarely reported in the FDI literature and are not referenced as a warning or precaution in the package insert.¹² However, iron dextran carries a warning to use with caution in patients with preexisting cardiovascular disease.¹³ Based on this case, it may be prudent to consider this warning for newer parenteral iron products as well.

CONCLUSION

Bradycardia and heart block are rarely reported in the parenteral iron literature. Although rare, it may be reasonable to consider parenteral iron as a toxicological etiology for patients presenting with complete heart block temporally associated with a parenteral iron infusion, particularly in patients with underlying conduction abnormalities. In the case of ongoing clinical instability when other causes have been sufficiently ruled out and acute iron toxicity or chronic iron overload is suspected, consultation with the local poison control center for consideration of deferoxamine for iron chelation may be reasonable.

The authors attest that their institution requires neither Institutional Review Board approval, nor patient consent for publication of this case report. Documentation on file.

Address for Correspondence: Michael Scott, PharmD, BCPS, BCEMP, Beth Israel Deaconess Medical Center, Department of Emergency Medicine, 185 Pilgrim Rd., Baker Building, Suite BA-0101, Boston, MA 02215-5412. Email: msscott10@bidmc.harvard.edu

Conflicts of Interest: By the CPC-EM article submission agreement, all authors are required to disclose all affiliations, funding sources and financial or management relationships that could be perceived as potential sources of bias. The authors disclosed none.

Copyright: © 2024 Scott et al. This is an open access article distributed in accordance with the terms of the Creative Commons Attribution (CC BY 4.0) License. See: <http://creativecommons.org/licenses/by/4.0/>

REFERENCES

- Arastu A, Elstrott B, Martens K, et al. Analysis of adverse events and intravenous iron infusion formulations in adults with and without prior infusion reactions. *JAMA Netw Open*. 2022;5(3):e224488.
- Cancado R and Munoz M. Intravenous iron therapy: how far have we come? *Rev Bras Hematol Hemoter*. 2011;33(6):461–9.
- Schaefer B, Tobiasch M, Viveiros A, et al. Hypophosphatemia after treatment of iron deficiency with intravenous ferric carboxymaltose or iron isomaltoside – a systematic review and meta-analysis. *Br J Clin Pharmacol*. 2021;87(5):2256–73.
- Rose RA, Sellan M, Simpson JA, et al. Iron overload decreases CaV1.3-dependent L-Type Ca²⁺ currents leading to bradycardia, altered electrical conduction, and atrial fibrillation. *Circ Arrhythm Electrophysiol*. 2011;4(5):733–42.
- Artman M, Olson R, Boerth R. Depression of myocardial contractility in acute iron toxicity in rabbits. *Toxicol Appl Pharmacol*. 1982;66(3):329–37.
- Vernon D, Banner W, Dean M. Hemodynamic effects of experimental iron poisoning. *Ann Emerg Med*. 1989;18(8):863–6.
- Kounis NG. Coronary hypersensitivity disorder: the Kounis syndrome. *Clin Ther*. 2013;35(5):563–71.
- Kounis NG. Caspofungin-induced fatal complete heart block: another manifestation of Kounis syndrome. *J Pharmacol Pharmacother*. 2013;4(2):161–2.
- Pollock R and Biggar P. Indirect methods of comparison of the safety of ferric derisomaltose, iron sucrose and ferric carboxymaltose in the treatment of iron deficiency anemia. *Expert Rev Hematol*. 2020;13(2):187–95.
- Ambrosy A, Haehling S, Kalra P, et al. Safety and efficacy of intravenous ferric derisomaltose compared to iron sucrose for iron deficiency anemia in patients with chronic kidney disease with and without heart failure. *Am J Cardiol*. 2021;152:138–45.
- Kalra P, Cleland J, Petrie M, et al. Intravenous ferric derisomaltose in patients with heart failure and iron deficiency in the UK (IRONMAN): an investigator-initiated, prospective, randomised, open-label, blinded-endpoint trial. *Lancet*. 2022;400(10369):2199–209.
- Monoferric. Package insert. Pharmacosmos Therapeutics Inc. 2020. Available at: https://www.accessdata.fda.gov/drugsatfda_docs/label/2020/208171s000lbl.pdf. Accessed July 14, 2023.
- INFeD. Package insert. Allergan USA, Inc. 2021. Available at: https://www.accessdata.fda.gov/drugsatfda_docs/label/2021/017441s179lbl.pdf. Accessed July 14, 2023.

Defibrillator Lead Perforation Leading to Concerning Electrocardiogram Findings: Case Report

Bryan Rosenberg, MD*
Max Hockstein, MD*
Cyrus Hadadi, MD†

*Medstar Washington Hospital Center; Department of Emergency Medicine; Washington, District of Columbia

†Medstar Washington Hospital Center; Department of Cardiology; Washington, District of Columbia

Section Editor: Manish Amin, DO

Submission history: Submitted June 27, 2023; Revision received October 5, 2023; Accepted October 9, 2023

Electronically published March 25, 2024

Full text available through open access at http://escholarship.org/uc/uciem_cpccm

DOI: [10.5811/cpcem.1466](https://doi.org/10.5811/cpcem.1466)

Introduction: Implantable cardioverter-defibrillator (ICD) lead perforation through the myocardium may result in chest pain and electrocardiogram (ECG) changes concerning for ST-segment elevation myocardial infarction. The clinical context of the ECG aids in appropriate management.

Case Report: We report the case of a 71-year-old woman experiencing chest pain after an ICD placement two weeks earlier. On presentation, she exhibited ST-segment elevation on her ECG. Computed tomography confirmed ICD lead migration. The patient's hemodynamics were normal, and she was discharged home after a five-day hospital stay following a lead revision.

Conclusion: Although rare, ICD lead perforation is a potential cause of chest pain and ischemic ECG changes. Emergency physicians should consider lead perforation as a potential differential diagnosis when evaluating chest pain in patients with ICDs, taking into account the potential complications of coronary angiography. [Clin Pract Cases Emerg Med. 2024;8(2)107–110.]

Keywords: case report; ICD; lead perforation; current of injury; ECG.

INTRODUCTION

We present a case of a right ventricular (RV) implantable cardioverter-defibrillator (ICD) lead perforating the pericardium, resulting in a patient experiencing chest pain with an electrocardiogram (ECG) concerning for ST-segment elevation myocardial infarction (STEMI). While rare, RV lead migration is crucial for emergency medicine physicians to identify. Our case appears to be the first presentation of chest pain and new ST-segment elevation from RV lead perforation. The consequence of misclassifying this presentation may have grave consequences.

CASE REPORT

A 71-year-old female presented to the emergency department (ED) with mild pleuritic chest pain and a twitching felt in her left chest. The patient had recently incurred a cardiac arrest due to ventricular fibrillation and had undergone ICD placement for secondary prevention two

weeks earlier. She was seen earlier in the day at electrophysiology clinic and was noted to have changes in RV lead impedances and diaphragmatic stimulation during threshold testing. Therefore, she was sent to the ED for further management. Upon arrival to the ED, an ECG was performed ([Image 1](#)), which showed a normal sinus rhythm, left axis deviation, and significant ST-segment elevation across the precordial and high lateral leads.

With a history of ischemic-type chest pain, this ECG was concerning for an acute STEMI. However, with the patient's history of recent ICD placement in addition to large and diffuse ST-segment elevations, it was deemed more likely to be an ICD complication causing a current of injury than an ischemic event. A high sensitivity troponin was found to be within normal limits, and point-of-care ultrasound showed preserved left ventricular function and no evidence of pericardial effusion. Computed tomography chest demonstrated the RV lead tip extending through the

myocardium, epicardial fat, and pericardium, with its tip in the pericardial fat, again without evidence of pericardial effusion or mediastinal collection (Image 2).

The patient exhibited no hemodynamic perturbations throughout her ED stay, and she was admitted to the electrophysiology service for continued care. During her hospital stay, serial troponins remained low, and the perforated RV lead was revised. The ECG from after the RV lead revision showed resolution of the ST-segment changes (Image 3). Her hospital course was complicated by an episode of ventricular tachycardia with an effective ICD shock in the setting of likely coronary vasospasm. The patient recovered well and was discharged five days after initial presentation.

DISCUSSION

A combination of chest pain with concerning ECG findings may prompt immediate interventional cardiology consultation for STEMI in the correct clinical context. In this case, the added information from the patient's electrophysiology visit earlier that day provided the necessary context to guide care. Changes in RV lead impedance and diaphragmatic stimulation during threshold testing provided the clinicians with a more likely explanation for the patient's twitching sensation and ECG changes.

Implantable cardioverter-defibrillator lead perforation is a rare (0.14%) but potentially life-threatening complication of ICD placement.¹ Predictors for perforation of ICD include older age, female gender, left bundle branch block, worsened heart failure class, higher than normal left

Population Health Research Capsule

What do we already know about this clinical entity?

Lead perforation of an implantable cardioverter-defibrillator (ICD) is a rare (0.14%) but potentially life-threatening complication of ICD placement.

What makes this presentation of disease reportable?

Our case appears to be the first presentation of chest pain and new ST-segment elevations on electrocardiogram (ECG) from right ventricular lead perforation.

What is the major learning point?

History of recent ICD placement with ST-segment elevation should prompt concern for lead migration. Anticoagulating a patient with a perforated ICD can lead to mortality.

How might this improve emergency medicine practice?

Emergency physicians should be aware of this rare but important addition to their differential diagnosis when contextualizing a worrisome ECG with a clinical history.

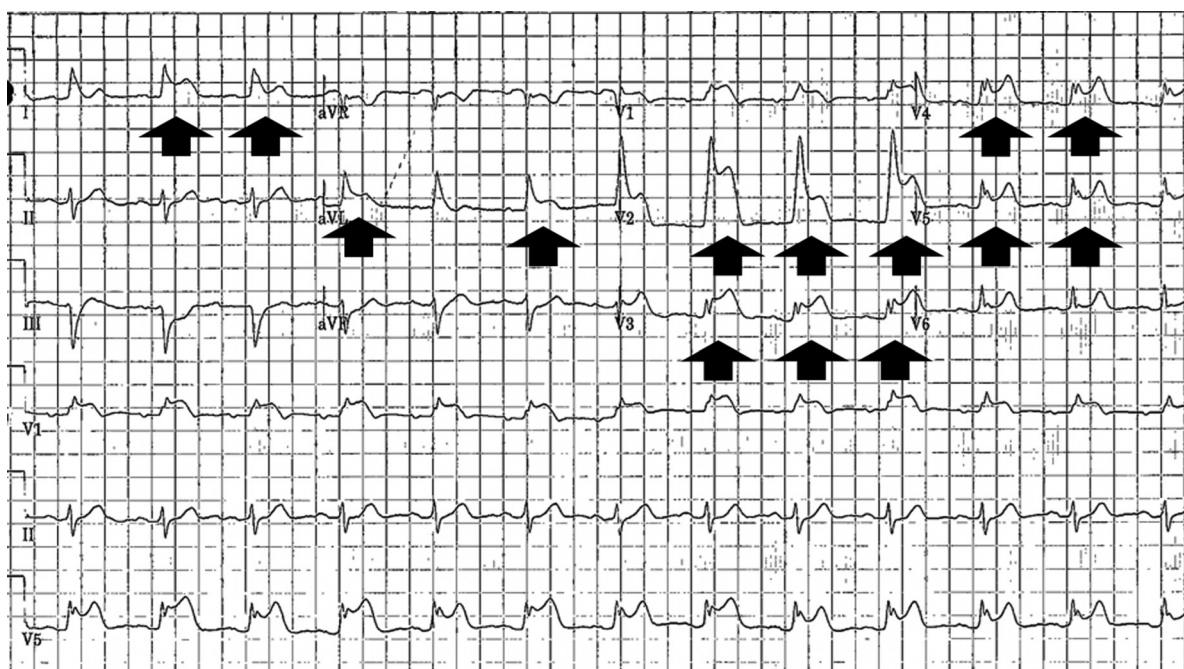


Image 1. Initial electrocardiogram on presentation to the emergency department showing ST-segment elevations (arrows) across the precordial and high lateral leads.

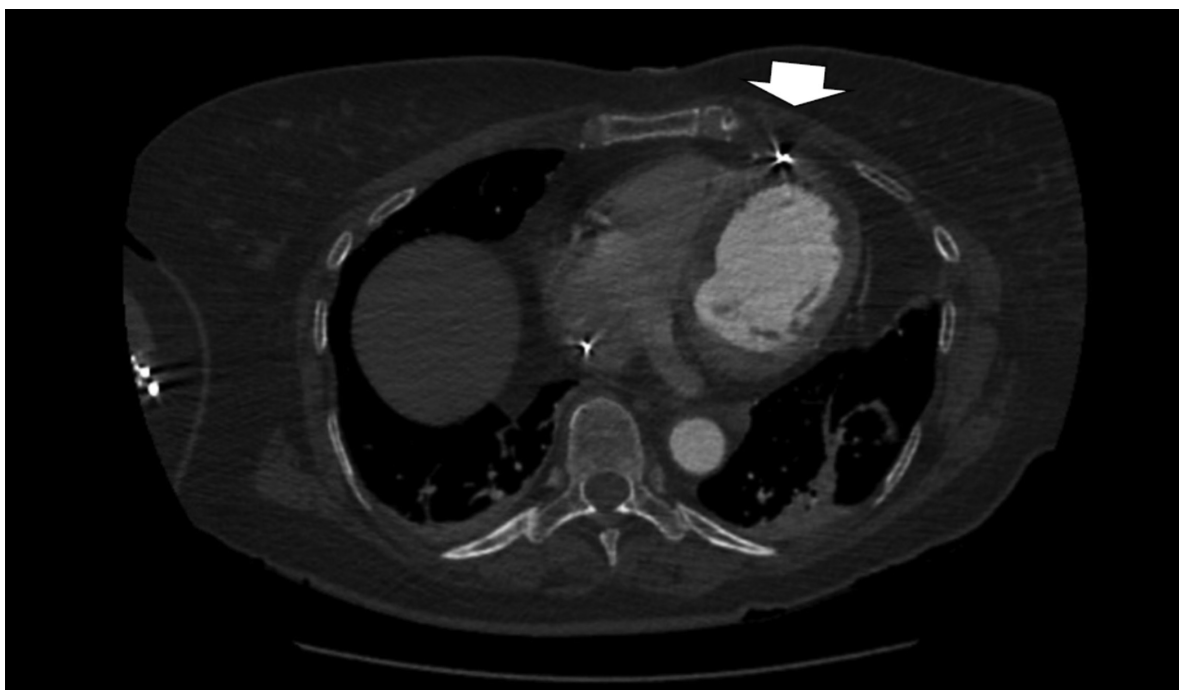


Image 2. Computed tomography chest showing the right ventricular lead tip perforating into the pericardial fat (arrow).

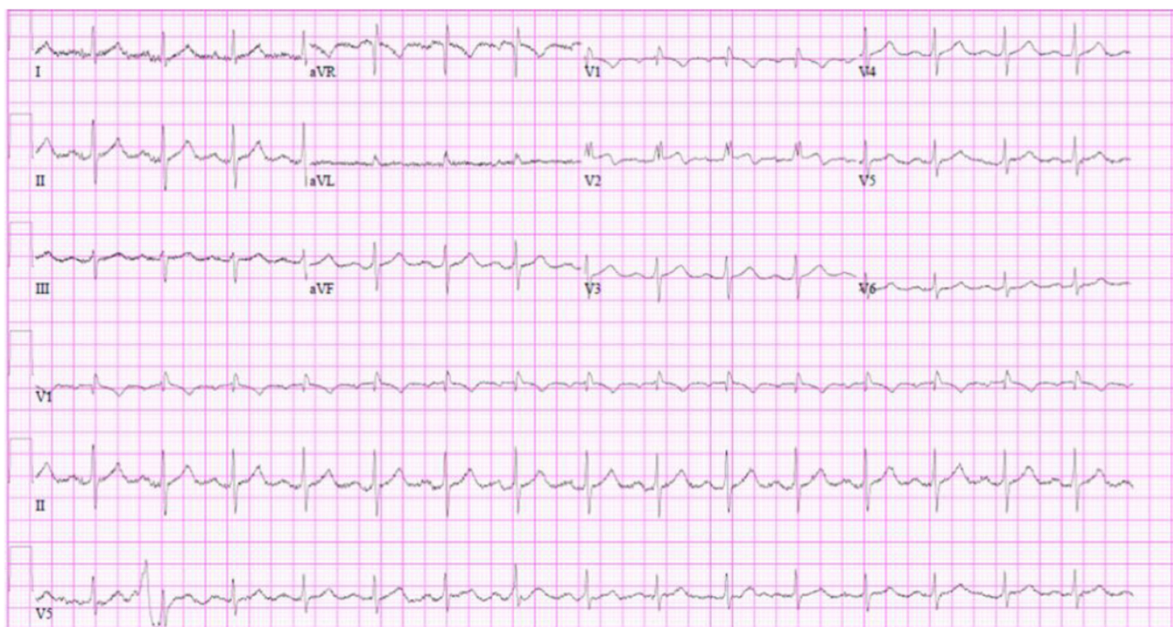


Image 3. Electrocardiogram showing resolution of ST-segment elevations after perforated pacer lead was successfully revised.

ventricular ejection fraction, and non–single-chamber ICD implant.¹ The majority of pacemaker or defibrillator lead perforations are either acute or sub-acute, occurring within 30 days of implantation. Delayed or chronic perforations occurring after 30 days of implantation are uncommon. There are isolated reports of ICD leads perforating anatomic structures including ribs without pleural or pericardial

effusion or other complications, the mediastinum complicated by sepsis, and the coronary sinus ostium presenting without symptoms.^{2–5}

In this presentation, there was no arrhythmia, pericardial effusion, hematoma, or other dangerous pathology found. It appears to be a novel presentation of an ECG concerning for STEMI leading to a diagnosis of RV lead migration. The

pathophysiology of ECG changes from pacemaker lead perforation relates to current of injury, which can be described as the flow of current from the damaged area of the heart to the undamaged portion. The damaged area remains depolarized, and the current of injury points toward the undamaged area, leading to the ST-segment elevations seen on our patient's ECG.

Any patient with an ICD, chest pain, and ECG changes requires immediate intervention if hemodynamically unstable. If vital signs are normal, workup should include serial troponins and ECGs. If there is concern for lead perforation, advanced cardiac imaging with or without electrophysiology consultation should be considered.

CONCLUSION

Implantable cardioverter-defibrillator lead perforation is a rare complication of lead implantation as evidenced by the minimal available literature surrounding its epidemiology and clinical course. The constellation of chest pain and ischemic ECG changes in patients with ICDs is even more rare. Not only does this case broaden the required differential of ECGs demonstrating current of injury to include ICD lead perforation, but it also serves as guidance for the emergency physician tasked with working up chest pain and ECG changes in a patient with an ICD. Clinicians should likewise appreciate the potential for misdiagnosis, leading to potential complications such as pericardial effusion associated with anticoagulation in a catheterization laboratory. The appreciation of device lead complications should provide the emergency physician with a less common but important addition to their differential diagnosis when contextualizing a worrisome ECG with a clinical history.

While there is no clear guidance that can be provided to physicians given the limited experience, there are three take-home points we believe every emergency physician should keep in mind when evaluating a patient with an ICD and chest pain:

1. History of recent ICD placement with ST-segment elevation should prompt concern for lead migration: without an electrophysiology visit earlier that day cluing the authors into potential lead perforation, interventional cardiology would have likely been called for possible intervention. Imaging is required to secure the diagnosis.
2. Anticoagulating a patient with a perforated ICD can lead to mortality: should the patient's history be unrecognized,

the patient would be at risk for receiving anticoagulation during coronary angiography, potentially leading to life-threatening pericardial tamponade.

3. Predictors for perforation of ICD include older age, female gender, left bundle branch block, worsened heart failure class, higher left ventricular ejection fraction, and non-single-chamber ICD implant¹: these factors, in combination with the ECG and full clinical picture, may help guide the emergency and cardiology teams when presented with a patient with ICD placement and ECG changes, especially within 30 days of ICD implantation.

The authors attest that their institution requires neither Institutional Review Board approval, nor patient consent for publication of this case report. Documentation on file.

Address for Correspondence: Bryan Rosenberg, MD, Medstar Washington Hospital Center; Department of Emergency Medicine, 110 Irving St. NW, Washington, DC 20010. Email: Bryan.Rosenberg@medstar.net

Conflicts of Interest: By the *CPC-EM* article submission agreement, all authors are required to disclose all affiliations, funding sources and financial or management relationships that could be perceived as potential sources of bias. The authors disclosed none.

Copyright: © 2024 Rosenberg et al. This is an open access article distributed in accordance with the terms of the Creative Commons Attribution (CC BY 4.0) License. See: <http://creativecommons.org/licenses/by/4.0/>

REFERENCES

1. Hsu JC, Varosy PD, Bao H, et al. Cardiac perforation from implantable cardioverter-defibrillator lead placement. *Circ Cardiovasc Qual Outcomes*. 2013;6(5):582–90.
2. Herr MJ, Cottrell JM, Garrett HE Jr, et al. Erosion of a right ventricular pacemaker lead into the left chest wall. *Surg Case Rep*. 2020;6(1):262.
3. Jain N, Ravipati V, Kerut EK. Late pacemaker lead tip perforation documented by chest CT. *Echocardiography*. 2016;(9):1419–21.
4. Huang D, Wilson J, Ganti L. Isolated shoulder pain secondary to pacemaker lead perforation. *J Am Coll Emerg Physicians Open*. 2022;3(2):e12615.
5. Nakao T, Fujii K, Uehara M, et al. Asymptomatic long-term cardiac perforation by a pacemaker lead. *Intern Med*. 2019;58(16):2409–10.

Diabetic Ketoacidosis: A Case Report

April Brill, DO*
Nirav Chheda, DO*
Daniel Strama, DO†
Ramesh Soundararajan, MD*

*Franciscan Health Olympia Fields, Emergency Department, Olympia Fields, Illinois
†Midwestern University Chicago College of Osteopathic Medicine,
Downers Grove, Illinois

Section Editor: Rachel Lindor, MD, JD

Submission history: Submitted May 19, 2023; Revision received November 15, 2023; Accepted November 17, 2023

Electronically published February 13, 2024

Full text available through open access at http://escholarship.org/uc/uciem_cpchem

DOI: [10.5811/cpcem.1389](https://doi.org/10.5811/cpcem.1389)

Introduction: Diabetic ketoacidosis (DKA) is a common diagnosis in the emergency department (ED). However, one must consider other causes for acid-base disturbances when the pattern is not consistent with typical presentation.

Case Report: A 52-year-old female with a history of insulin-dependent diabetes mellitus type 2 presented to the ED with abdominal pain, nausea, and vomiting for three days. Her diagnostic workup revealed diabetic ketoacidosis but with concurrent metabolic alkalosis. Standard treatment for DKA was initiated, and there was improvement of her mentation and resolution of metabolic derangements.

Conclusion: Overlooking a diagnosis of DKA because of alkalosis on venous blood gas testing could lead to inappropriate treatment and, therefore, increased risk of morbidity and mortality in the affected patient. [Clin Pract Cases Emerg Med. 2024;8(2)111–114.]

Keywords: DKA; diabetic ketoacidosis; baking soda ingestion; case report.

INTRODUCTION

According to National Diabetes Statistics Report 2020, approximately 34.2 million people in the United States alone had been diagnosed with diabetes, which accounted for about 10% of the total population.¹ Complications relating to hyperglycemic episodes accounted for 224,000 visits to emergency departments (ED) in 2016 alone.¹ It has been estimated that the total cost of care related to diabetes has increased by 49 billion dollars between 2012–2017. Since diabetic complaints and complications are common, emergency physicians must be familiar with the disease process and sequelae.¹ Morbidity and mortality due to diabetes and related disorders accounted for greater than 270,000 deaths in 2017 and was the seventh leading cause of death in the US in 2017.¹ Here we describe a case of a 52-year-old female presenting with a unique cause of a mixed acid-base disorder for a diagnosis that is commonly encountered in the ED. We discuss in depth the evaluation of mixed acid-base disturbance. The case demonstrates the importance of obtaining a detailed history and physical exam whenever possible.

CASE REPORT

A 52-year-old female presented to the ED by ambulance from home for evaluation of hyperglycemia. She reported complaints of abdominal pain, nausea, and vomiting over the prior three days. She noted that she administered her own medications, but the remainder of the history was limited due to encephalopathy. Further history was obtained from the paramedic report and electronic health record review because there was no family present at bedside. On chart review it was found that she had a past medical history of insulin-dependent diabetes type 2, gastroparesis, hypertension, seizure disorder, hyperlipidemia, depression, substance use (tobacco, cocaine, and marijuana), pancreatitis, and a hiatal hernia. Brief review of systems was significant only for nausea and vomiting, and she denied suicidality or use of drugs at that time. Surgical history was notable for pancreatectomy with partial autologous transplant and appendectomy. Reported home medications on the chart were as follows: amylase-lipase-protease 12,000–38,000–60,000 units delayed release capsule; sodium phosphate; di/mono and potassium phosphate monobasic

250 milligram (mg) tablet, aspirin 81 mg tablet, atorvastatin 40 mg tablet, calcium-vitamin D 500 mg-200 unit per tablet, docusate sodium 100 mg capsule, and insulin glargine U-100 100 units per milliliter (mL) vial.

On physical exam, vitals were temperature 36.4° Celsius, heart rate 80 beats per minute, respiratory rate 18 breaths per minute, blood pressure 135/72 millimeters mercury (mm Hg), oxygen saturation 97% on room air, and weight of 36 kilograms. She was ill-appearing and cachectic with dry mucous membranes, and her abdominal exam revealed focal epigastric tenderness without guarding, rebound, or rigidity. Her capillary refill and skin turgor were normal. She displayed no focal neurologic deficits and was alert and oriented to person, place, and time. However, her responses were tangential, and she displayed poor insight into her current situation and health problems.

Initial abnormal chemistry laboratory findings were sodium 126 milliequivalents per liter (mEq/L) (reference range 133–144 mEq/L), potassium 2.0 mEq/L (3.5–5.1 mEq/L), chloride 33 mEq/L (98–107 mEq/L), bicarbonate greater than 45 mEq/L (21–31 mEq/L), glucose 448 mg/deciliter (dL) (70–99 mg/dL), blood urea nitrogen (BUN) 75 mg/dL (7–25 mg/dL), creatinine 3.3 mg/dL (0.6–1.2 mg/dL), anion gap 48 mEq/L (6.2–14.7 mEq/L), and moderate acetone (negative). The mixed venous blood gas was also abnormal with a pH 7.64 (7.35–7.45); partial pressure of carbon dioxide 65.1 mm Hg (35–45 mm Hg); hemoglobin 11.9 grams (g)/dL (14–18 g/dL); and calculated bicarbonate 71.1 millimoles (mmol)/L (22–26 mmol/L). Serum alcohol was <10 mg/dL (<10 mg/dL). The full labs are listed in the [Table](#). A chest radiograph revealed no acute cardiopulmonary findings, and a single view abdomen radiograph demonstrated a non-obstructive bowel gas pattern. Electrocardiogram was read as normal sinus rhythm, QTc 490 milliseconds, and no acute ST-T changes.

Given the markedly abnormal metabolic derangements, initial treatment in the ED consisted of the following: two 1-L fluid boluses of 0.9 normal saline intravenous (IV); ondansetron 4 mg IV push, and potassium chloride (KCl) 60 mEq IV over six hours followed by normal saline with 20 mEq KCl at 150 mL per hour. There was concern for diabetic ketoacidosis (DKA) given the laboratory studies and a venous blood gas that demonstrated a mixed acid-base disorder with an elevated anion gap, moderate acetone, and elevated glucose. Insulin was initially ordered but cancelled when the potassium had not corrected enough prior to her admission to the intensive care unit (ICU). Due to the complexity of expected management of the metabolic derangements as well as acute kidney injury, critical care and nephrology were consulted to discuss further management.

During her stay in the ICU, she was eventually started on a continuous insulin infusion and dextrose 5% in water with 20 mEq KCl. Her anion gap closed, and her metabolic derangements resolved. She was switched back to her prior long-acting and sliding-scale insulin regimen. On day three of

Population Health Research Capsule

What do we already know about this clinical entity?

Diabetic ketoacidosis is a common diagnosis in the emergency department (ED), and at least 224,000 visits in 2016 were due to complications of hyperglycemia.

What makes this presentation of disease reportable?

This case demonstrates the setting of an altered patient who was found to be hyperglycemic but alkalotic secondary to exogenous ingestion of baking soda.

What is the major learning point?

This case discusses the importance of reviewing all lab values and the importance of fluids and electrolyte replacement as a standard of resuscitation.

How might this improve emergency medicine practice?

A thorough history and physical exam in cases of mixed acid-base disorders can provide pertinent information to help counsel patients on appropriate home management of diabetes and when to seek medical care.

her stay, she was more cognizant and reported that she had been consuming baking soda at home for her symptoms prior to presentation. Once stabilized, she was downgraded to the general medical floor and discharged home on her previous medication regimen on hospital day six.

DISCUSSION

The current literature reports on several cases of diabetic ketoalkalosis, a mixed metabolic acidosis and alkalosis disorder, in the setting of hypochloremia, although it remains a rare diagnosis.² Metabolic alkalosis with hypochloremia can be secondary to excess vomiting, metabolic compensation, fasting or starvation state, or ingestion.^{2–5} We discuss the specific ingestion of baking soda as a cause for the patient's metabolic derangements. Baking soda misuse has been shown to cause metabolic derangements resulting in hypokalemic metabolic alkalosis.^{2,6} Baking soda functions as an excess base with one teaspoon providing 59 mEq of bicarbonate compared to the 7.7 mEq found in a 650 mg tablet of sodium bicarbonate.⁷ Therefore, this ingestion also led to markedly decreased levels of chloride.⁸ Hypokalemic metabolic

Table. Initial laboratory results with reference ranges in parenthesis of a patient with diabetic ketoalkalosis.

Complete blood count	Complete metabolic profile
WBC 5.8 (4.0–11.0 10 ³ /uL)	Na 126 (133–144 mEq/L)
Hg 11.7 (12.0–15.3 g/dL)	K 2.0 (3.5–5.1 mEq /L)
Platelet 561 (150–450 10 ³ /uL)	Cl 33 (98–107 mEq /L)
Acetone: moderate (negative)	CO ₂ >45.0 (21.0–31.0 mEq /L)
Lactic acid: 2.3 (0.5–2.0 mmol/L)	Glucose 448 (70–99 mg/dL)
Mixed venous blood gas:	BUN 75 (7–25 mg/dL)
pH 7.647 (7.350–7.450)	Cr 3.3 (0.6–1.2 mg/dL)
PO ₂ 91.1 (80.0–95.0 mm Hg)	Calcium 10.1 (8.6–10.3 mg/dL)
PCO ₂ 65.1 (35.0–45.0 mm Hg)	Total protein 8.8 (6.4–8.9 g/dL)
Hg 11.9 (14.0–18.0 g/dL)	Albumin 4.6 (3.5–5.7 g/dL)
HCO ₃ 71.1 (22–26 mmol/L)	Total bilirubin 0.8 (0.0–1.0 mg/dL)
	Alkaline phosphatase 169 (34–104 U/L)
	AST 37 (13–39 U/L)
	ALT 15 (7–52 U/L)
	Anion gap 48 (6.2–14.7 mEq/L)
	Mg 2.5 (1.6–2.6 mg/dL)
	Lipase 88 (11–82 U/L)
Urinalysis:	
Color: yellow (yellow)	Bilirubin: negative (negative)
Appearance: hazy (clear)	Protein 100 mg/dl (negative)
Ph 7 (5–8)	Blood urine: moderate (negative)
Specific gravity 1.010 (1.005–1.030)	Urobilinogen: negative (negative)
Glucose >500 mg/dl (negative)	Nitrite: negative (negative)
Ketones 20 mg/dl (negative)	Leukocyte esterase: negative (negative)
RBC 0–2 (0–2/hpf)	Bacteria: none seen (none seen)
WBC 0–5 (0–5/hpf)	Yeast: present (none seen)

WBC, white blood count; μ L, microliter; Hg, hemoglobin; g, gram; dL, deciliter; mmol, millimole; L, liter; PO₂, partial pressure of oxygen; mm Hg, millimeters of mercury; PCO₂, partial pressure of carbon dioxide; HCO₃, bicarbonate; mg, milligram; hpf, high power field; RBC, red blood cell; NA, sodium; mEq, milliequivalent; K, potassium; Cl, chloride; CO₂, carbon dioxide; BUN, blood urea nitrogen; Cr, creatinine; U, unit; AST, aspartate aminotransferase; ALT, alanine transaminase; Mg, magnesium.

alkalosis due to excess baking soda consumption can occur even in patients with normal kidney function. However, this patient's poor renal function, as indicated by her BUN and creatinine, further contributed to her inability to expel excess ingested bicarbonate, leading to an elevated level.^{8,9} This

elevated level of bicarbonate along with the patient's developing DKA resulted in a diabetic ketoalkalosis.

Besides the metabolic derangements, excess base ingestion can put patients at risk for dysrhythmias, seizures, and cardiopulmonary arrest.⁹ Treatment of the excess baking soda ingestion as well as the concomitant diabetic ketoalkalosis does not differ from that of DKA. After discontinuing use of the offending agent and initiating therapy with fluids, insulin, and potassium, all derangements normalized.^{2,10} It is significant to also discuss that insulin therapy is not recommended until hypokalemia is corrected to >3.3 mmol/L to decrease risk of arrhythmia and muscle weakness.¹¹

The patient's significantly elevated anion gap of 48 mEq/L confirms the metabolic acidosis, which was from DKA. Her severely elevated bicarbonate level in the chemistry panel of greater than 45 mEq/L, as well a blood gas with a calculated bicarbonate level of 71 mmol/L, confirms a significant metabolic alkalosis. This can also be corroborated by her pH of 7.647. Without the calculated bicarbonate level available from a blood gas, the modified delta gap could be used to screen for a mixed metabolic acid-base disorder. The formula is Delta gap = Na⁺ - Cl⁻ - 36.¹² In this case the delta gap was +9 and signified presence of a concomitant metabolic alkalosis since the rise in the anion gap was less than the fall of the bicarbonate level.¹²

In the case of this patient, at the onset of her symptoms she may have had simple hyperglycemia that resulted in gastroparesis with nausea and vomiting. The home remedy of baking soda may have caused her to progress into DKA as well as delay her presentation to healthcare personnel. Patients must be counseled on the potential risks of home remedies that can raise bicarbonate levels. This is especially true of those considering an alkaline diet or consuming a sodium bicarbonate antacid as this can predispose patients to hypokalemic metabolic alkalosis.^{8,13}

CONCLUSION

This case highlights the need for a thorough history and physical exam in cases of mixed acid-base disorders, since the offending agent was not identified until hospital day three. Although her treatment algorithm would not have changed with this information, it would have provided pertinent information to help counsel the patient on appropriate home management of her diabetes and when to seek medical attention.

The Institutional Review Board approval has been documented and filed for publication of this case report.

Address for Correspondence: April Brill, DO, Franciscan Health Olympia Fields, Emergency Department, 20201 Crawford Ave, Olympia Fields, IL 60461. Email: abrill@midwestern.edu

Conflicts of Interest: By the *CPC-EM* article submission agreement, all authors are required to disclose all affiliations, funding sources and financial or management relationships that could be perceived as potential sources of bias. The authors disclosed none.

Copyright: © 2024 Brill et al. This is an open access article distributed in accordance with the terms of the Creative Commons Attribution (CC BY 4.0) License. See: <http://creativecommons.org/licenses/by/4.0/>

REFERENCES

- Centers for Disease Control and Prevention. National diabetes statistics report 2020: estimates of diabetes and its burden in the United States. Available at: <https://www.cdc.gov/diabetes/pdfs/data/statistics/national-diabetes-statistics-report.pdf>. Accessed May 8, 2023.
- Nanavati S, Kumar V, Melki G, et al. Diabetic ketoalkalosis: misnomer or undiagnosed variant of diabetic ketoacidosis. *BMJ Case Reports*. 2018;2018:bcr2018226092.
- Yasuda K, Hayashi M, Murayama M, et al. Acidosis-induced hypochloremic alkalosis in diabetic ketoacidosis confirmed by the modified base excess method. *J Clin Endocrinol Metab*. 2016;101(6):2390–5.
- Funk GC, Zauner C, Bauer E, et al. Compensatory hypochloremic alkalosis in diabetic ketoacidosis. *Diabetologia*. 2003;46(6):871–3.
- Bayat M and Møller N. Diabetisk ketoacidose maskeret af metabolisk alkalose [Diabetic ketoacidosis masked by metabolic alkalosis]. *Ugeskr Laeger*. 2013;175(46):2800–1.
- Al-Abri SA and Kearney T. Baking soda misuse as a home remedy: case experience of the California Poison Control System. *J Clin Pharm Ther*. 2014;39(1):73–7.
- Al-Abri SA and Olson KR. Baking soda can settle the stomach but upset the heart: case files of the Medical Toxicology Fellowship at the University of California, San Francisco. *J Med Toxicol*. 2013;9(3):255–8.
- Cervantes CE, Menez S, Jaar BG, et al. An unusual cause of metabolic alkalosis: hiding in plain sight. *BMC Nephrol*. 2020;21(1):296.
- Solak Y, Turkmen K, Atalay H, et al. Baking soda induced severe metabolic alkalosis in a haemodialysis patient. *NDT Plus*. 2009;2(4):280–1.
- Soifer JT and Kim HT. Approach to metabolic alkalosis. *Emerg Med Clin North Am*. 2014;32(2):453–63.
- Gosmanov AR, Gosmanova EO, Kitabchi AE. Hyperglycemic crises: diabetic ketoacidosis and hyperglycemic hyperosmolar state. (2021). In: Feingold KR, Anawalt B, Blackman MR, et al. (Eds.), *Endotext* [Internet]. South Dartmouth MA: MDText.com, Inc. Available at: <https://www.ncbi.nlm.nih.gov/books/NBK279052/>. Accessed October 17, 2023.
- Tsapenko MV. Modified delta gap equation for quick evaluation of mixed metabolic acid-base disorders. *Oman Med J*. 2013;28(1):73–4.
- Hoorn EJ, Bovée DM, Geerse DA, et al. Diet-exercise-induced hypokalemic metabolic alkalosis. *Am J Med*. 2020;133(11):e667–9.

Emergency Department Doppler Assessment of a Central Retinal Artery Occlusion: Case Report

Duncan McGuire, DO*
Robert Calleja, MD[†]
Eric Pai, MD[†]
Amit Bahl, MD[‡]

*Ascension Providence Hospital, Department of Emergency Medicine, Southfield, Michigan
[†]Beaumont Health, Department of Emergency Medicine, Royal Oak, Michigan
[‡]Corewell Health, Department of Emergency Medicine, Royal Oak, Michigan

Section Editor: Shadi Lahham, MD

Submission history: Submitted July 13, 2023; Revision received November 2, 2023; Accepted November 16, 2023

Electronically published March 26, 2024

Full text available through open access at http://escholarship.org/uc/uciem_cpce

DOI: 10.5811/cpcem.1520

Introduction: Vision loss is a symptom found frequently in patients presenting to the emergency department (ED). Central retinal artery occlusion (CRAO) is an uncommon yet time-sensitive and critical cause of painless vision loss in which delayed diagnosis can lead to significant morbidity. Emergency medicine literature documents the ability to diagnose a CRAO using ultrasound by identifying the hyperechoic thrombus—coined the retrobulbar spot sign.

Case Report: We present the case of a patient presenting with painless monocular vision loss for which CRAO was diagnosed in the ED using point-of-care ultrasound enhanced by the utilization of serial Doppler examinations as well as calculation of the central retinal artery resistive index.

Conclusion: Despite the pre-existing literature on point-of-care ultrasound investigation of central retinal artery occlusion, there are no emergency medicine case reports describing serial examination of the central retinal artery by spectral Doppler or calculation of arterial resistive index to improve this evaluation and monitor progression of the pathology. [Clin Pract Cases Emerg Med. 2024;8(2)115–119.]

Keywords: *central retinal artery occlusion; point-of-care-ultrasound; retrobulbar spot sign; resistive index; case report.*

INTRODUCTION

Vision loss is a frequently encountered symptom resulting in numerous ED visits.¹ While some ocular pathologies can be readily identified with limited history and evaluation, others require exhaustive approaches including dilated fundoscopic examination, specialized equipment, ophthalmology consultation, and even advanced imaging. Point-of-care ultrasound (POCUS) of the eye is a diagnostic modality that can be applied as an initial screening tool to help identify some higher risk diagnoses efficiently and accurately.² This imaging modality allows for high-resolution evaluation of anterior and posterior chamber anatomy, as well as retrobulbar structures including the central retinal artery which travels within the optic nerve sheath.

Central retinal artery occlusion (CRAO) is the sudden blockage of the central retinal artery by occlusive thrombus or embolus that requires immediate evaluation and treatment at a comprehensive stroke center.³ As CRAO is an uncommon yet time-sensitive and critical cause of painless vision loss that may be difficult to distinguish from other benign causes, delayed diagnosis of CRAO is an unfortunate reality. The emergency medicine literature documents the ability to identify CRAO using POCUS by identifying a retrobulbar hyperechoic structure within the distal optic nerve sheath, representing central retinal artery thrombus (called the retrobulbar spot sign).⁴

There is, however, a paucity of literature describing the ED application of serial spectral Doppler examination as well as calculation of the central retinal artery resistive index

(RI) to improve this evaluation and monitor pathology progression. We present the case of an ED using POCUS examination, enhanced by the utilization of serial Doppler examinations as well as RI calculation, to monitor disease progression.

CASE REPORT

A 60-year-old female presented to a tertiary-care ED with a chief complaint of painless, right-sided monocular vision loss beginning 16 hours prior to arrival while she was eating dinner. At that time, she experienced an acute onset right-sided headache associated with painless vision loss in her right eye. The headache spontaneously resolved after three minutes; however, the persistence of visual deficits prompted her ED evaluation. Upon arrival to the ED, the patient endorsed a worsening right-sided superior quadrantanopia. She denied trauma, other neurologic deficits, headache recurrence, systemic symptoms, or a history of similar occurrence.

Gross ocular examination demonstrated pupils that were dilated to four millimeters (mm) bilaterally. The right pupil had delayed constriction after both direct and indirect light exposure compared to the left, consistent with a relative afferent pupillary defect. The patient's right eye could perceive movement only out of the right upper quadrant field. Visual acuity was 20/200 oculus dexter (OD) and 20/25 oculus sinister (OS). Intraocular pressure was 16 millimeters of mercury (mm Hg) OD and 17 mm Hg OS. An ocular POCUS examination was performed by emergency physicians shortly after ED arrival. This demonstrated right optic nerve sheath diameter of 0.58 centimeters (cm) and left optic nerve sheath diameter of 0.57 cm (*Image 1*). There was no evidence of retinal detachment, posterior vitreous

Population Health Research Capsule

What do we already know about this clinical entity?

Vision loss is a frequently encountered symptom in the ED.

What makes this presentation of disease reportable?

Point-of-care ultrasound (POCUS) can be rapidly performed in the ED to prevent delays in diagnosis of central retinal artery occlusions (CRAO), a potentially vision-threatening pathology.

What is the major learning point?

Serial POCUS examination in the ED can be used to both diagnose and monitor disease progression in CRAO.

How might this improve emergency medicine practice?

This case emphasizes the importance of POCUS in evaluating patients with painless vision loss to clinch the diagnosis and monitor progression of CRAO.

detachment, vitreous hemorrhage, retrobulbar hematoma, or lens dislocation. Upon closer examination of the optic nerve sheath, a hyperechoic signal at the distal aspect of the

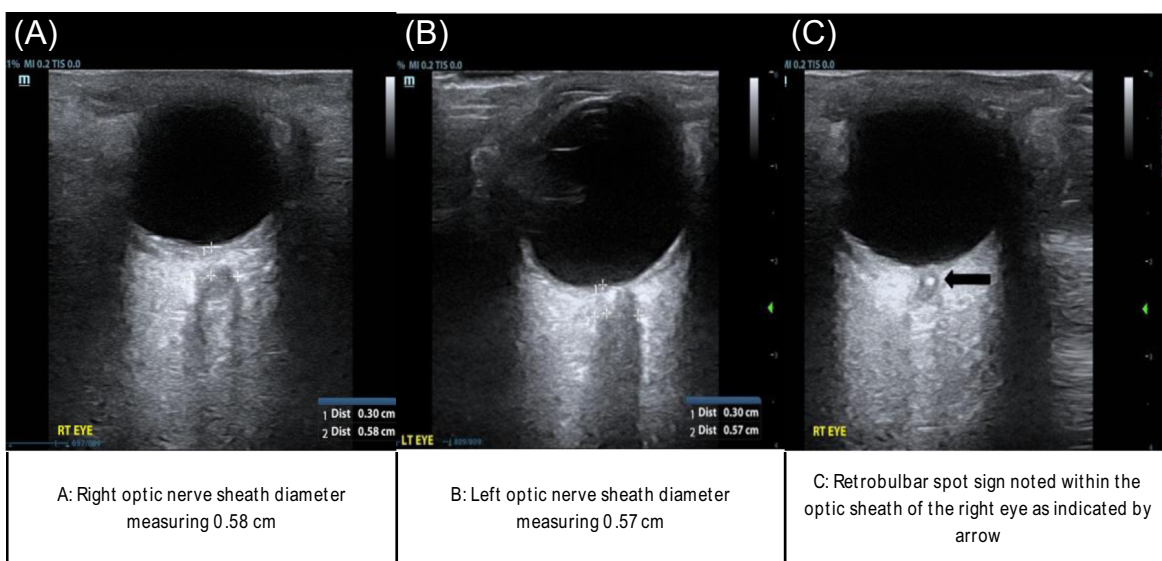


Image 1. Point-of-care-ultrasound findings demonstrating normal right- (A) and left-sided (B) optic nerve sheath diameters, as well as an acute thrombus in the central retinal artery called the retrobulbar spot sign (C). *cm*, centimeter.

sheath, known as a retrobulbar spot sign, was appreciated (*Image 1*).

Color Doppler was applied to assess for central retinal arterial flow, and application of pulsed wave Doppler revealed an arterial flow pattern with an RI ($[(\text{peak systolic velocity} - \text{end diastolic velocity})/\text{peak systolic velocity}]$) calculated to be 0.71 (*Image 2*). After POCUS examination, the patient underwent additional imaging, ophthalmology, and laboratory evaluation. A non-contrast head computed tomography (CT) did not demonstrate acute intracranial pathology. Fundoscopic exam performed by ophthalmology demonstrated retinal whitening with superior macular sparing in the right eye with supero-nasal chorioretinal hyperpigmentation. The cup to disc ratio was 0.2:1 bilaterally.

Upon repeat POCUS examination one hour later, there was no evident central retinal arterial flow indicating complete CRAO (*Image 2*). Due to this devascularization, a central retinal artery RI was unable to be recalculated. Because of the delayed ED presentation after symptom onset, the patient was not a candidate for tissue plasminogen activator (tPA); therefore, ocular massage therapy was initiated, and she was given a drop of brimonidine 0.1% ocular solution in the affected eye. Anterior chamber decompression was recommended; however, the patient declined. Given the atypical headache associated with the patient's vision loss, erythrocyte sedimentation rate (ESR) and C-reactive protein (CRP) were ordered in the ED and were elevated (ESR = 40 mm/hr [reference range = 0–20 mm/hr] and CRP 23.4 milligrams per liter [mg/L] [reference range = <3 mg/L]). In case the vision loss occurred

secondary to temporal arteritis, the patient was started on high-dose solumedrol (250 mg every six hours for 12 doses followed by prednisone 80 mg daily).

Neurology was also consulted in the ED, and the patient was admitted to the hospital for further management. Her hospital stay included a complete evaluation for stroke and inflammatory pathologies. She was discharged four days later on steroid, brimonidine, and aspirin therapy. The patient was provided with instructions to follow up with neurology, ophthalmology, cardiology, and rheumatology for continued evaluation and management. On subsequent reevaluation one month following her CRAO, the patient's vision had improved to 20/70 -3 OD with extreme enhanced corneal compensation and 20/30+2 OS. Ophthalmology advised her to continue brimonidine eye drops and maintain strict blood glucose, blood pressure, and lipid control.

DISCUSSION

Central retinal artery occlusion should be a consideration in patients experiencing painless vision loss, and dilated fundoscopic examination is the gold standard diagnostic approach.⁵ Given the nuances of the procedure including availability of specialized equipment, time needed for dilation, and environmental factors, emergency physicians are limited in their ability to accurately and efficiently perform fundoscopic evaluations. As ophthalmology consultation is not always readily available in many EDs, identifying CRAO can be a diagnostic conundrum with inevitable delays. Central retinal artery occlusion is a time-sensitive diagnosis and results in damage to retinal cells in as little as 12–15 minutes, underscoring the importance of early

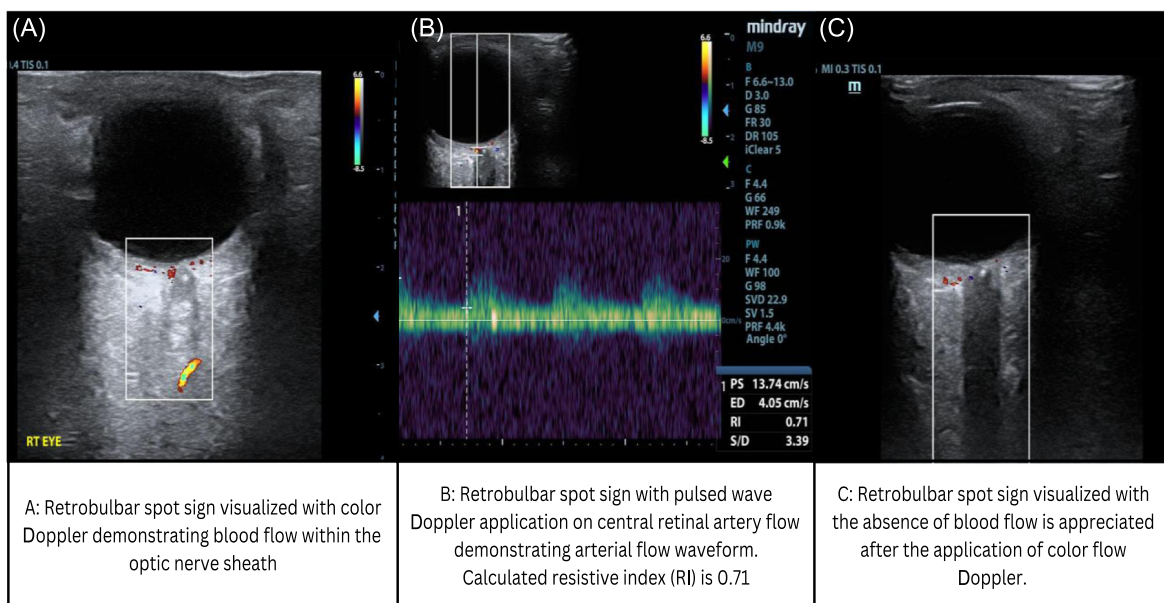


Image 2. Central retinal artery with acute thrombus and color flow on color Doppler evaluation (A), central retinal artery with increased resistance to flow and an elevated resistive index (B), and absence of central retinal artery color Doppler flow upon repeat evaluation (C).

detection.⁵ Fortunately, emergency physician exposure to ocular POCUS is rapidly increasing, with the American College of Emergency Physicians recognizing ocular ultrasound as one of 12 core emergency ultrasound applications.⁶

While both globe and retrobulbar structures can be readily identified using ocular POCUS, evaluation for CRAO is only sparsely described in emergency medicine case reports or series.⁷ Additionally, there are no emergency medicine accounts of serial color Doppler exams performed on patients with the diagnosis of CRAO enhanced by the calculation of an RI. There are several ultrasound findings that may be present in the ocular POCUS examination of a patient suffering from a CRAO, including the following: an absence of pulsatile central retinal artery blood flow using color and pulsed wave Doppler, an increased RI measured using pulsed wave Doppler, and the retrobulbar spot sign.³ The retrobulbar spot sign is a hyperechoic structure found posterior to the eye within the optic nerve sheath. It is postulated that this structure has a hyperechoic sonographic appearance because it is a calcified cholesterol and thrombin embolus lodged within the central retinal artery.⁴

A color Doppler gait can be applied to the optic nerve sheath, revealing pulsatile flow within the central retinal artery.⁸ Once this is identified, a pulsed wave gait can be laid over this arterial color pattern. This allows for the calculation of the central retinal artery's RI, the amount of resistance to blood flow within a vessel. It is calculated by detecting the variation in peak systolic and end diastolic velocities. A normal central retinal artery RI is less than 0.7.⁹ Presumably, the RI would be elevated in CRAO, although additional research is warranted to evaluate for the efficacy of this modality in predicting accurate central retinal artery vascular resistance.¹⁰ Additionally, there may be an absence of central retinal artery Doppler flow if there is complete occlusion of the vessel.

Currently, orbital CT angiography or fluorescein angiography are the imaging modalities recommended when attempting to diagnose CRAO.⁵ Diffusion-weighted magnetic resonance imaging can also be performed to evaluate for this pathology and retinal anatomy.¹¹ However, these tests are not without their flaws as they take time to perform, expose the patient to radiation and intravenous contrast, are expensive, and are susceptible to motion artifact. By using POCUS as an adjunct diagnostic modality in patients suspected to have this diagnosis, emergency physicians can clinch this vision-threatening diagnosis, thereby avoiding further delays in the diagnostic and therapeutic pathways.

CONCLUSION

Within the ED, ocular point-of-care ultrasound in patients experiencing acute onset painless vision loss can enable

physicians to rapidly diagnose and accelerate treatment of central retinal artery occlusion. Our case highlights a novel use of POCUS in diagnosing and monitoring progression of this critical entity by using serial examinations aided by the application of spectral Doppler as well as resistive index calculation.

The authors attest that their institution requires neither Institutional Review Board approval, nor patient consent for publication of this case report. Documentation on file.

Address for Correspondence: Duncan McGuire, DO, FAWM, Ascension Providence Hospital, Department of Emergency Medicine, 3601 W 13 Mile Rd, Royal Oak, MI 48073.
Email: mcguire.duncan@gmail.com

Conflicts of Interest: By the *CPC-EM* article submission agreement, all authors are required to disclose all affiliations, funding sources and financial or management relationships that could be perceived as potential sources of bias. The authors disclosed none.

Copyright: © 2024 McGuire et al. This is an open access article distributed in accordance with the terms of the Creative Commons Attribution (CC BY 4.0) License. See: <http://creativecommons.org/licenses/by/4.0/>

REFERENCES

1. Channa R, Zafar SN, Canner JK, et al. Epidemiology of eye-related emergency department visits. *JAMA Ophthalmol.* 2016;134(3):312.
2. Propst SL, Kirschner JM, Strachan CC, et al. Ocular point-of-care ultrasonography to diagnose posterior chamber abnormalities. *JAMA Netw Open.* 2020;3(2):e1921460.
3. Rojas-Bartolomé L, Ayo-Martín Ó, García-García J, et al. Contribution of orbital ultrasound to the diagnosis of central retinal artery occlusion. *J Clin Med.* 2022;11(6):1615.
4. Nedelmann M, Graef M, Weinand F, et al. Retrobulbar spot sign predicts thrombolytic treatment effects and etiology in central retinal artery occlusion. *Stroke.* 2015;46(8):2322–2324.
5. Mac Grory B, Schrag M, Biousse V, et al. Management of Central Retinal Artery Occlusion: A Scientific Statement From the American Heart Association. *Stroke.* 2021;52(6):e282–94.
6. America College of Emergency Physicians. Ultrasound Guidelines: Emergency, Point-of-Care, and Clinical Ultrasound Guidelines in Medicine. 2023. Available at: <https://www.acep.org/patient-care/policy-statements/ultrasound-guidelines-emergency-point-of-care-and-clinical-ultrasound-guidelines-in-medicine>. Accessed June 10, 2023.
7. Galust H, Banks S, Riscinti M. Point-of-care ultrasound in the detection of central retinal artery occlusion in a patient with recent COVID-19. *J Am Coll Emerg Physicians Open.* 2022;3(6):e12842.

8. Williamson TH, Baxter GM, Dutton GN. Colour Doppler velocimetry of the arterial vasculature of the optic nerve head and orbit. *Eye*. 1993;7(1):74–9.
9. Khatri M, Saxena S, Kumar M, et al. Resistive index of central retinal artery is a bioimaging biomarker for severity of diabetic retinopathy. *Int J Retina Vitreous*. 2019;5(1):38.
10. Polska E, Kircher K, Ehrlich P, et al. RI in central retinal artery as assessed by CDI does not correspond to retinal vascular resistance. *Am J Physiol Heart Circ Physiol*. 2001;280(4):H1442–7.
11. Siebert E, Rossel-Zemkhou M, Villringer K, et al. Detectability of retinal diffusion restriction in central retinal artery occlusion is linked to inner retinal layer thickness. *Clin Neuroradiol*. 2022;32(4):1037–44.

Face-off Droop: A Case Report of Pediatric Stroke

Duncan Robertson, MD*
 Hayden F. Peirce, MD†
 Marek D. Nicpon, MD‡
 Eric M. Otterson, PA-C*
 Laurel O'Connor, MD*
 Julia G. Rissmiller, MD‡
 Zachary W. Binder, MD†

*University of Massachusetts, Chan Medical School, Department of Emergency Medicine, Worcester, Massachusetts
 †University of Massachusetts, Chan Medical School, Department of Pediatrics, Worcester, Massachusetts
 ‡University of Massachusetts, Chan Medical School, Department of Radiology, Worcester, Massachusetts

Section Editor: Joel Moll, MD

Submission history: Submitted November 27, 2023; Revision received January 26, 2024; Accepted January 29, 2024

Electronically published April 24, 2024

Full text available through open access at http://escholarship.org/uc/uciem_cpccm

DOI: 10.5811/cpcem.6586

Introduction: Cerebrovascular accidents rarely occur in children; the incidence of ischemic stroke in patients <16 years of age is between 0.6–7.9/100,000. However, they are the fourth most common cause of acute neurological deficits in the pediatric population, and possible cases should be evaluated with a high index of suspicion to ensure timely intervention.

Case Report: We describe a previously healthy 17-year-old male who presented to the pediatric emergency department with a left facial droop and hemiparesis consistent with a stroke. The patient's age and lack of comorbidities made this an extremely uncommon presentation. Our patient's neurologic symptoms were believed to have been caused by a recent traumatic clavicular injury sustained two weeks prior, which subsequently led to vascular insult.

Conclusion: Cerebrovascular accidents are an important cause of morbidity and mortality in pediatric patients. Cerebrovascular accidents in children are most often secondary to congenital causes; however, care should be taken to assess for acquired causes, such as trauma to major blood vessels. While rarely implicated in traumatic injuries, arterial structures posterior to the medial clavicle can result in severe complications. [Clin Pract Cases Emerg Med. 2024;8(2)120–124.]

Keywords: *stroke; clavicle fracture; pseudoaneurysm.*

INTRODUCTION

While more common in older adults, strokes, or cerebrovascular accidents (CVA), rarely occur in children. The incidence of ischemic stroke in children <16 years of age is between 0.6–7.9/100,000, and in young adults <45 years old is between 8–100/100,000 per year.^{1,2} The traditional risk factors for stroke—hypertension, smoking, diabetes, and hypercholesterolemia—are less prevalent in pediatric patients. In children, CVAs are more commonly associated with cardiac conditions, hematologic conditions, vasculopathies, and metabolic disorders.¹ Pregnancy, exogenous hormone use, smoking, illicit drug use, and premature atherosclerosis can increase the risk of CVA in young adults.¹ We present the case of a healthy adolescent

male who presented to the pediatric emergency department (PED) with a stroke despite having no identifiable risk factors. Written permission from the patient's guardians and assent from the patient were obtained to present this case.

CASE REPORT

Emergency medical services (EMS) responded to a hockey rink for a chief complaint of “neck injury.” Paramedics encountered a 17-year-old male lying supine on the locker room floor. The patient's trainer reported that the patient had collapsed on the ice and could not stand. The patient complained of light-headedness and was noted to have left-sided facial droop and paralysis of his left upper extremity. He denied headache or neck pain. There was no reported

traumatic injury on the day of presentation. The patient denied medical or surgical history, drug use, or alcohol use. A video of the incident was obtained (Video 1).

The exam performed by EMS was notable for tachycardia, left-sided facial droop, and absent strength of the left shoulder, elbow, forearm, hand, and fingers. Spinal precautions were applied, and EMS bypassed a community hospital in favor of the regional pediatric trauma center. Upon arrival to the PED, the patient was activated as a trauma. On assessment in the resuscitation bay, a persistent left lower facial droop, a Glasgow Coma Scale of 15, and a negative extended focused assessment with sonography in trauma was present. No external signs of trauma were noted on the exam.

At that time the patient was identified as a suspected stroke with a National Institute of Health Stroke Scale score of three. Pediatric neurology was consulted, and the patient was emergently taken for computed tomography (CT) head, CT cervical spine, and CT angiogram (CTA) of the head and neck. Computed tomography did not demonstrate any acute intracranial abnormality or fracture of the cervical spine. The CTA of the head and neck showed “a 1.8 cm amorphous hyperdensity abutting the anterior aspect of the junction of the brachiocephalic and right common carotid arteries with an apparent neck extending from the brachiocephalic artery, suggesting pseudoaneurysm or contained rupture” (Image 1).

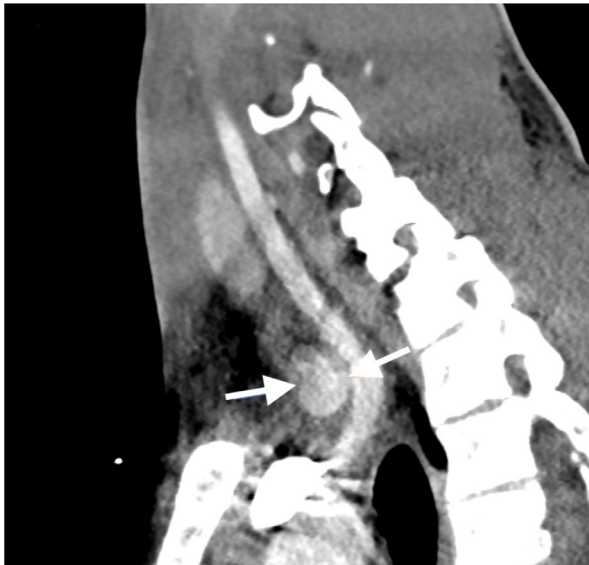

Image 1. Sagittal multiplanar reconstruction of the computed tomography angiogram of the head and neck demonstrates a 1.8 cm amorphous, hyperdense, oval structure abutting the anterior aspect of the junction of the brachiocephalic and right common carotid arteries, with an apparent connecting neck extending from the brachiocephalic artery (arrows), suggesting a pseudoaneurysm or contained rupture.

Population Health Research Capsule

What do we already know about this clinical entity?

Cerebrovascular accident (CVA) is a major cause of morbidity and mortality for patients of all ages and can arise from many different etiologies.

What makes this presentation of disease reportable?

Our young patient had no risk factors for stroke except for an occult injury that arose from prior trauma. This initially confounded the cause during initial presentation.

What is the major learning point?

Although CVA is relatively rare in the pediatric population, it must remain on the differential as remote traumatic injury may create a nidus for thromboembolism.

How might this improve emergency medicine practice?

Expedient care of CVA in the ED is dependent on quick recognition and must be considered even in those with few perceived risk factors.

A non-occlusive filling defect in the proximal right subclavian artery was suggestive of thrombus and raised concern for an embolic process. Decreased flow in the right distal second segment and third segments of the right vertebral artery supported a concern for a thrombus. There were no large vessel occlusions or significant stenoses of the major intracranial arteries. Finally, a Salter-Harris I fracture of the right clavicular head with surrounding contusion/hematoma was noted, along with dislocation of the sternoclavicular joint. The posteriorly displaced clavicle was noted to abut the pseudoaneurysm/contained rupture (Image 2).

After these findings were made radiographically, the patient was asked specifically about injury to his right upper chest. He reported that two weeks earlier he had sustained a blunt injury to the area during hockey practice. He had been evaluated by his school trainer, and radiographs had been obtained that were interpreted as negative. He had continued to play hockey over the subsequent two weeks with moderate but improving pain. As part of the patient's trauma evaluation, a chest radiograph was performed, which demonstrated left tracheal deviation, likely due to the clavicle fracture. Laboratory data revealed normal coagulation studies and lipid profile.

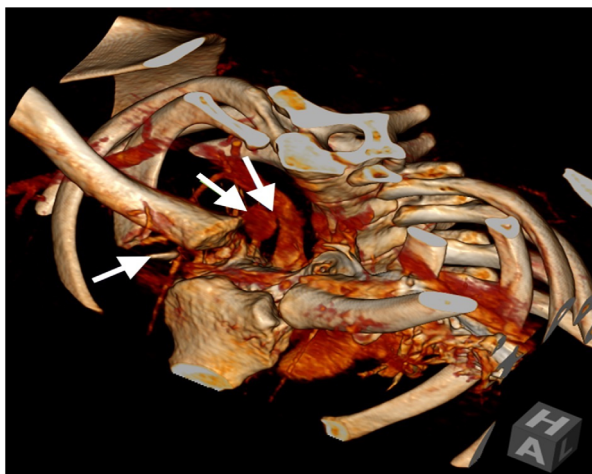


Image 2. Three-dimensional reconstruction of the thoracic inlet using the computed tomography angiogram of the head and neck demonstrates fracture of the right clavicular head with an anterior fracture fragment posterior displacement of the clavicle with abutment of the pseudoaneurysm/contained rupture (arrows). The connecting neck extending from the brachiocephalic artery is also depicted.

Once the subclavian artery was identified as an apparent thrombotic source, consultations were placed to vascular surgery and cardiothoracic surgery. The patient was taken emergently to the operating room for repair of the right innominate artery pseudoaneurysm via sternotomy. Additionally, an embolectomy of the right subclavian artery was performed. The patient awoke post-operatively with a strong right radial pulse and neurologically intact.

Magnetic resonance imaging (MRI) performed the following day revealed several small acute infarcts to the right frontal lobe, the posterior margin of the right insular cortex (*Image 3*), and the right parietal lobe. These findings support the hypothesis that an embolic process caused our patient's presenting neurologic symptoms. He was placed on aspirin (81 milligrams daily for three months) and was

discharged neurologically intact on postoperative day three with plans for vascular surgery follow-up and interval repair of the clavicular dislocation by orthopedic surgery.

DISCUSSION

This case describes a 17-year-old male who presented to the PED with weakness of his left face and arm. Imaging revealed a pseudoaneurysm of the brachiocephalic artery likely due to a right clavicular fracture. The pseudoaneurysm was repaired, and the patient was discharged from the hospital without neurological deficits. There are several noteworthy considerations in this case. First, CVA is rare in children, especially in those without medical comorbidities.^{1,2} Older patients experiencing a CVA tend to present with signs of aphasia, visual disturbance, and hemiparesis. In contrast, pediatric patients may present with altered mental status, lethargy, and seizures.^{3,4}

Pediatric stroke secondary to cardiac disease is associated with bilateral deficits, anterior and posterior circulation involvement, and seizures.⁴ Conversely, stroke secondary to trauma or embolic phenomenon is associated with posterior circulation involvement, and is more likely to present with dysarthria, hemiparesis, visual field defect, or ataxia.⁵ While rare, stroke is the fourth most common cause of acute focal neurological deficit in children after hemiplegic migraine, seizure, and Bell's palsy.⁶ Paramount to the evaluation of stroke is imaging. Diffusion-weighted MRI coupled with vascular MR angiography is the gold standard in the evaluation of ischemic stroke.^{7,8} If unavailable within the first hour of presentation, guidelines recommend non-contrast CT and CTA of the head and neck.⁸ While radiation is a factor to consider in the evaluation of pediatric patients, the benefits of CT imaging in this circumstance outweigh potential harm.

The management of pediatric stroke requires a multidisciplinary approach involving the ED, neurology, pharmacy, the patient, and the patient's family.

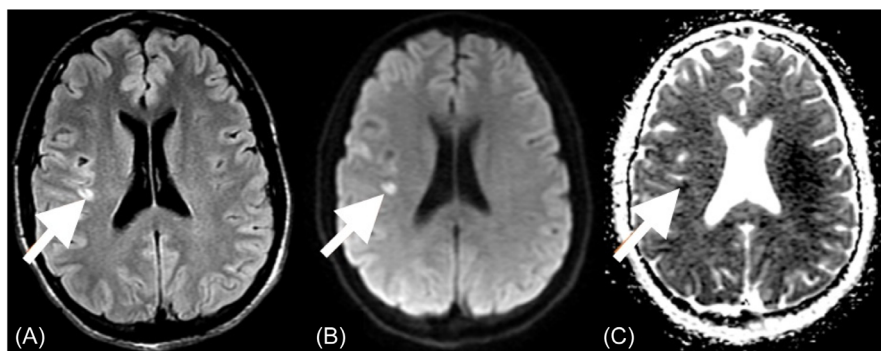


Image 3. Non-contrast brain magnetic resonance imaging demonstrates a hyperintense lesion on the axial T2-weighted image in the posterior right insular cortex (A) with restricted diffusion as demonstrated by focus of hyperintense signal on the diffusion weighted image (B), and a focus of hypointense signal on the apparent diffusion coefficient map (C), consistent with an acute infarct. Similar lesions were also identified in the anterior right frontal lobe and anterior aspect of the right parietal lobe.

Antiepileptics should be initiated if seizures are present.^{7–10} Treatment of acute ischemic stroke with tissue plasminogen activator (tPA) or endovascular intervention have shown benefits in adults; however, these therapies remain controversial in children. A joint statement by the American Heart Association/American Stroke Association recommends that tPA or endovascular intervention be considered in pediatric patients who have radiographically confirmed large artery occlusion and persistent disabling neurological deficits, in consultation with neurology and endovascular surgery.¹⁰

It is suspected that the pseudoaneurysm and subsequent emboli formation in our patient's subclavian artery were the most likely cause of his CVA. Two potential mechanisms have been suggested: 1) direct embolization from the subclavian artery clot into the carotid artery; or 2) migration of the brachiocephalic artery clot into the subclavian artery with smaller emboli then transiting through the carotid artery.

Another remarkable aspect of this case was the profound sequela of the patient's clavicular injury. His neurologic symptoms ultimately arose from a clavicle fracture that had occurred two weeks prior. We suspect that the fracture caused the initial insult to the brachiocephalic artery, which then led to the formation of the pseudoaneurysm. Clavicle fractures are managed based on their location, angulation, and the degree of compromise to surrounding tissue. Distal and midshaft clavicular fractures are typically managed conservatively with a sling and orthopedic surgery follow-up.¹¹ Fractures of the medial clavicle, such as the one sustained by our patient, are rare, representing 2–6% of all clavicle fractures.^{12,13}

The medial clavicular physis closes between 22–25 years of age. As a result, fractures of the medial clavicle most often occur in patients <25 years old.¹⁴ These fractures are associated with injuries to vascular structures within the mediastinum such as the brachiocephalic artery, aorta, and subclavian artery.¹⁴ Attention must be taken to ensure that these vascular structures are not injured when evaluating medial clavicular fractures.¹⁵ A review of the literature yielded a single report of a similar incident where a traumatic clavicular injury caused a secondary CVA in a young adult; however, there is little available data on the incidence of CVA caused by blunt traumatic injury in pediatric or adult patients.¹⁶

Finally, early and effective communication between teams can minimize delays in the assessment and management of patients with time-sensitive and/or uncommon ED presentations. In this case, EMS diverted to a pediatric trauma center and the multidisciplinary team was present on arrival. Once acute trauma was deemed less likely, the patient was identified as a suspected stroke victim, which resulted in expedited neurological evaluation. This identification of a stroke may not have happened as rapidly without a

conscientious assessment by EMS and frontline paramedics. Any delay could have resulted in permanent neurologic injury. Our patient likely benefitted from being transported directly to a medical center with the appropriate resources to treat his rare presentation.

CONCLUSION

While rarer than in adults, CVAs are an important cause of morbidity and mortality in pediatric patients. Cerebrovascular accidents in children are most often secondary to congenital causes; however, care should be taken to assess for acquired causes, as occurred in our patient. The region posterior to the medial clavicle, while rarely implicated in traumatic injury, holds many important arterial structures. As a result, injuries to this area should be evaluated with a high index of suspicion. Finally, when pediatric stroke is being considered it is important to use all available resources to obtain prompt imaging and expedite evaluation to increase the chances of a favorable outcome.

Video 1. The patient (#22) can be seen initially at the right of the video. As the camera pans toward the right, the patient is seen at the center. As he skates backward he falls. On multiple attempts to get back up, it appears his left leg and arm have decreased coordination and weakness. He is escorted off the ice to be evaluated by medical personnel.

The Institutional Review Board approval and Patient Consent have been documented and filed for publication of this case report.

Address for Correspondence: Duncan Robertson, MD, University of Massachusetts, Chan Medical School, Department of Emergency Medicine, 55 Lake Ave. North, Worcester, MA 01655. Email: duncan.robertson@umassmemorial.org

Conflicts of Interest: By the *CPC-EM* article submission agreement, all authors are required to disclose all affiliations, funding sources and financial or management relationships that could be perceived as potential sources of bias. The project described was supported by the National Center for Advancing Translational Sciences, National Institutes of Health, through Grant KL2TR001454. The NIH had no role in the design and conduct of the study. The content is solely the responsibility of the authors and does not necessarily represent the official views of the NIH.

Copyright: © 2024 Robertson et al. This is an open access article distributed in accordance with the terms of the Creative Commons Attribution (CC BY 4.0) License. See: <http://creativecommons.org/licenses/by/4.0/>

REFERENCES

1. Putaala J, Metso AJ, Metso TM, et al. Analysis of 1008 consecutive patients aged 15 to 49 with first-ever ischemic stroke. *Stroke*. 2009;40(4):1195–203.

2. Giroud M, Lemesle M, Gouyon JB, et al. Cerebrovascular disease in children under 16 years of age in the city of Dijon, France: a study of incidence and clinical features from 1985 to 1993. *J Clin Epidemiol*. 1995;48(11):1343–8.
3. Mallick AA, Ganesan V, Kirkham FJ, et al. Childhood arterial ischaemic stroke incidence, presenting features, and risk factors: a prospective population-based study. *Lancet Neurol*. 2014;13(1):35–43.
4. Abend NS, Beslow LA, Smith SE, et al. Seizures as a presenting symptom of acute arterial ischemic stroke in childhood. *J Pediatr*. 2011;159(3):479–83.
5. Asakai H, Cardamone M, Hutchinson D, et al. Arterial ischemic stroke in children with cardiac disease. *Neurology*. 2015;85(23):2053–9.
6. Shellhaas RA, Smith SE, O'Tool E, et al. Mimics of childhood stroke: characteristics of a prospective cohort. *Pediatrics*. 2006;118(2):704–9.
7. Ferriero DM, Fullerton HJ, Bernard TJ, et al. Management of Stroke in Neonates and Children: a scientific statement from the American Heart Association/American Stroke Association. *Stroke*. 2019;50(3):e51–96.
8. Bernard TJ, Friedman NR, Stence NV, et al. Preparing for a “pediatric stroke alert.” *Pediatric neurology*. 2016;56:18–24.
9. Royal College of Paediatrics and Child Health. Stroke In Childhood - Clinical Guideline for Diagnosis, Management and Rehabilitation. 2017. Available at: <http://www.rcpch.ac.uk/stroke-guideline>. Accessed: March 8, 2023
10. Ferriero DM, Fullerton HJ, Bernard TJ, et al. Management of stroke in neonates and children: a scientific statement from the American Heart Association/American Stroke Association. *Stroke*. 2019;50(3):e51–96.
11. Canadian Orthopaedic Trauma Society. Nonoperative treatment compared with plate fixation of displaced midshaft clavicular fractures. A multicenter, randomized clinical trial. *J Bone Joint Surg Am*. 2007;89(1):1–10.
12. Goldfarb CA, Bassett GS, Sullivan S, et al. Retrosternal displacement after physeal fracture of the medial clavicle in children treatment by open reduction and internal fixation. *J Bone Joint Surg Br*. 2001;83(8):1168–72.
13. Kihlström C, Möller M, Lönn K, et al. Clavicle fractures: epidemiology, classification and treatment of 2,422 fractures in the Swedish Fracture Register; an observational study. *BMC Musculoskelet Disord*. 2017;18(1):82.
14. Khan LA, Bradnock TJ, Scott C, et al. Fractures of the clavicle. *J Bone Joint Surg Am*. 2009;91(2):447–60.
15. Hoogervorst P, van Schie P, van den Bekerom MP. Midshaft clavicle fractures: current concepts. *EFORT Open Rev*. 2018;3(6):374–80.
16. Ghazaleh D, Salari A, Mohl L, et al. Acute ischemic stroke with devastating consequences can occur due to posterior sternoclavicular joint dislocation. *Life (Basel)*. 2022;12(11):1836.

Inferior Pancreaticoduodenal Artery Pseudoaneurysm Causing Biliary Obstruction: A Case Report

Patrick Meloy, MD*
 Will S. Lindquister, MD†
 Jeffrey Stebbins, PA-C*
 Elaine Bromberek, MD*

*Emory University School of Medicine, Department of Emergency Medicine, Atlanta, Georgia
 †Emory University School of Medicine, Division of Interventional Radiology and Image-guided Medicine, Atlanta, Georgia

Section Editor: Christopher San Miguel, MD

Submission history: Submitted August 8, 2023; Revision received November 24, 2023; Accepted December 1, 2023

Electronically published March 26, 2024

Full text available through open access at http://escholarship.org/uc/uciem_cpem

DOI: 10.5811/cpsem.1598

Introduction: Visceral arterial aneurysms and pseudoaneurysms are rare but dangerous pathologies, with reported incidence of 0.01–0.2% of the worldwide population, as found on autopsy. Pancreaticoduodenal artery pathology accounts for approximately 2% of all visceral aneurysms; it is commonly caused by chronic inflammatory processes, such as pancreatitis or adjacent pseudocysts. Morbidity and mortality commonly result from rupture of the aneurysm itself, leading to life-threatening hemorrhage into the peritoneum or gastrointestinal tract.

Case Report: Here we present the case of a 64-year-old male patient with previous history of alcohol use disorder leading to chronic pancreatitis and prior embolization of an inferior pancreaticoduodenal pseudoaneurysm, who presented to the emergency department (ED) with abdominal pain, nausea, and vomiting, and was found to have a large recurrent inferior pancreaticoduodenal pseudoaneurysm with associated obstructive cholangitis and pancreatitis via contrast-enhanced computed tomography (CT) of the abdomen and pelvis. The patient was managed emergently by interventional radiology angiography with embolic coiling and percutaneous biliary catheter placement, and he subsequently underwent biliary duct stenting with gastroenterology. The patient was successfully discharged after a brief hospitalization after resolution of his pancreatitis and associated hyperbilirubinemia.

Conclusion: Pancreaticoduodenal artery aneurysms and pseudoaneurysms are rare and dangerous visceral pathologies. Patients can be diagnosed rapidly in the ED with CT imaging and need urgent endovascular management to prevent morbidity and mortality. [Clin Pract Cases Emerg Med. 2024;8(2)125–128.]

Keywords: case report; visceral pseudoaneurysm; pancreaticoduodenal pseudoaneurysm; obstructive jaundice; alcohol use disorder.

INTRODUCTION

Visceral artery aneurysms are clinically rare entities and are typically found incidentally on abdominal imaging or via autopsy.^{1,2} Patients who present with symptoms, such as abdominal pain, vomiting, or gastrointestinal bleeding, are more likely to be experiencing a true emergency, with 8.5% of all cases resulting in death.² Aneurysms of the pancreaticoduodenal arteries represent 2% of all visceral aneurysms and are the most life-threatening.² Compared to

true aneurysms, patients with pseudoaneurysms have profoundly higher rupture rates, up to 76% compared to 3%, and require emergent treatment for stabilization.³

In this case, the patient presented with symptomatic abdominal pain and tenderness and was found to have a very large recurrent pseudoaneurysm of the inferior pancreaticoduodenal artery, the size of which led to obstructive biliary disease and cholangitis. The patient underwent emergent embolization of his pseudoaneurysm

and percutaneous biliary catheter placement with interventional radiology (IR) to manage his severe disease process.

CASE REPORT

A 64-year-old male patient with a past medical history of pancreatitis, alcohol use disorder, glaucoma, and prior gastrointestinal bleed, presented to the emergency department (ED) complaining of two weeks of abdominal pain, nausea, and vomiting. He reported that he had chronic abdominal pain that had worsened in the prior two weeks. He was hospitalized at an outside facility one month prior for a gastrointestinal bleed, but a source of bleeding was never identified. His surgical history was significant for coil embolization of an inferior pancreaticoduodenal artery (IPDA) pseudoaneurysm sac, measuring 2.2 centimeters (cm) at the time of embolization, with additional coiling of the gastroduodenal artery (GDA) to prevent collateral filling of the pseudoaneurysm. He had also undergone total knee replacement.

On arrival, his vital signs were temperature 36.8° Celsius (C) (oral), heart rate 85 beats per minute, respiratory rate 16 breaths per minute, blood pressure 139/67 millimeters of mercury, and oxygen saturation 99% on room air. His physical exam was notable for scleral icterus and moderate abdominal tenderness, worse over the epigastrium, but without rebound tenderness or guarding. Intravenous (IV) access was established, labs were drawn, and the patient was given one liter lactated Ringer's, 4 milligrams (mg) IV morphine, and 4 mg IV ondansetron.

The patient's laboratory studies were significant for an initial white blood cell count (WBC) of 14.0 per microliter (10^9 /liter) (reference range $4.5\text{--}11.0 \times 10^9$ /liter), hemoglobin 8.6 grams per deciliter (g/dL) ($14\text{--}18$ g/dL), hematocrit 26.6% (41–50%), and platelets of 486×10^9 /liter ($150\text{--}400 \times 10^9$ /liter). Lipase was elevated at 225 units per liter (U/L) (0–160 U/L). Liver function tests were also obtained and were concerning for total bilirubin 6.0 mg/dL (0.1–1.2 mg/dL), aspartate transaminase 102 U/L (8–33 U/L), and alanine transaminase 127 U/L (7–56 U/L). The patient had evidence of coagulopathy with prothrombin time of 21 seconds (10–13 seconds) and international normalized ratio 1.86 (reference range less than 1.1), despite lack of any systemic anticoagulation.

Initial computed tomography (CT) with IV contrast of the abdomen and pelvis revealed a 6.6-cm enhancing lesion in the region of the pancreatic head and common bile duct, consistent with a large visceral pseudoaneurysm without arterial extravasation (Images 1 and 2). Coils from the prior embolization were present within the pseudoaneurysm sac, indicating that this was a recurrence with significant enlargement of the previously treated pseudoaneurysm. Severe intrahepatic biliary ductal dilation and diffuse dilation of the gallbladder was also seen, with the presumed

Population Health Research Capsule

What do we already know about this issue?
Visceral artery aneurysms are rare but dangerous. Pancreatitis is a cause of pancreaticoduodenal artery aneurysm, and rupture can lead to hemorrhage into the peritoneum.

What was the research question?
This case details an aneurysm present in up to 0.2% of the worldwide population. Its size and location led to biliary obstruction, which aided in rapid diagnosis.

What was the major finding of the study?
Visceral artery aneurysms are diagnosed with CT angiography; consideration should be given to urgent interventional radiology coiling or embolization for stability.

How does this improve population health?
Clinicians should consider visceral artery aneurysms in patients with unexplained obstructive biliary pathology and obtain CT angiography for diagnosis.

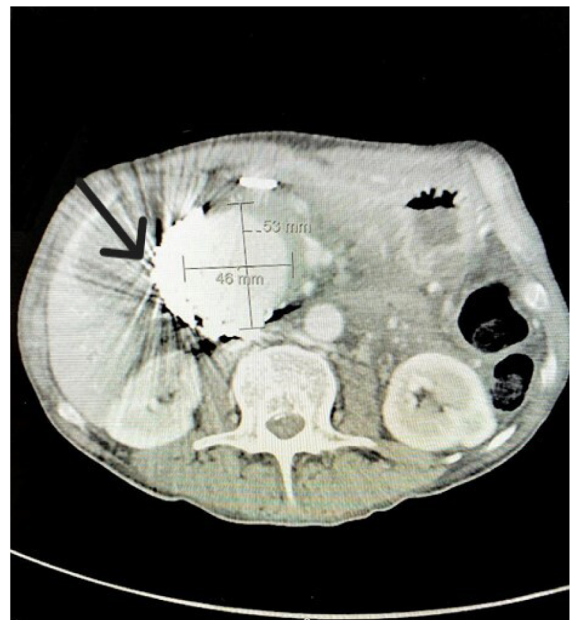


Image 1. Axial contrast-enhanced computed tomography in the arterial phase, pre-procedure, demonstrating a large visceral pseudoaneurysm in the right upper quadrant (brackets with measurements); and an artifact from the endovascular coils within the lesion from prior embolization (arrow).

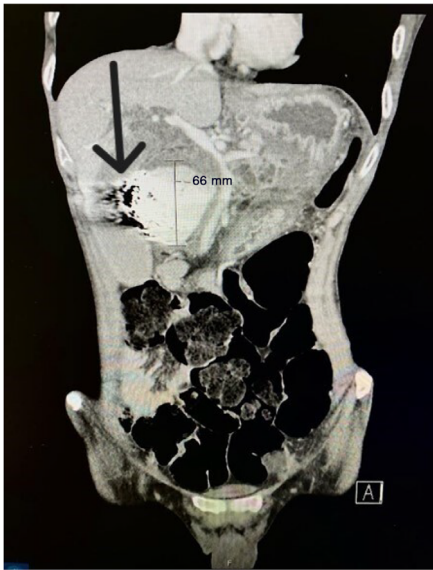

Image 2. Coronal contrast-enhanced computed tomography in the arterial phase, pre-procedure, demonstrating a large visceral pseudoaneurysm in the right upper quadrant (brackets with measurements); and an artifact from the endovascular coils within the lesion from prior embolization (arrow).

GDA pseudoaneurysm causing mass effect on the common bile duct (**Image 3**).

The imaging results were discussed immediately with IR, and the patient was prepped for emergent embolization. Additionally, IR planned urgent percutaneous biliary catheter placement given concern for cholangitis in the setting of an elevated WBC count and obstructive cholangiopathy. Angiography demonstrated a large IPDA pseudoaneurysm arising from the branches of the superior mesenteric artery. Coil embolization of the arterial inflow and outflow was successful with no persistent filling of the pseudoaneurysm

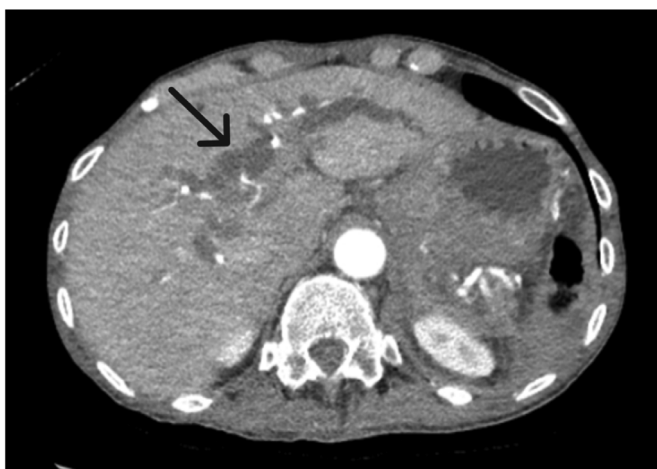

Image 3. Axial contrast-enhanced computed tomography in the arterial phase, pre-procedure, demonstrating severe intra-hepatic biliary ductal dilation (arrow).

post embolization, with associated preservation of the surrounding jejunal arteries via collaterals.

Given that the patient was also found to have biliary ductal dilation with obstruction and concern for cholangitis, a left-sided biliary drain was placed for decompression. The patient tolerated the initial procedure and was admitted to the surgical intensive care unit for ongoing monitoring. Over the following four days, he had improvement of his liver function tests and leukocytosis and was subsequently discharged home. Five weeks after discharge, the patient had repeat imaging of the abdomen and pelvis, which did not show any patent pseudoaneurysm present. He subsequently underwent biliary stent placement with gastroenterology and removal of his biliary catheter.

DISCUSSION

A pseudoaneurysm is defined as an encapsulated hematoma in communication with the lumen of the ruptured vessel, where the external wall consists of adventitia, perivascular tissue, fibrosis, or clot.² Pseudoaneurysms usually occur in the proximity of pseudocysts, which erode into and communicate with a vessel to create a pseudoaneurysm.^{2,3} Pseudoaneurysms usually do not occur immediately after an episode of acute pancreatitis but are more commonly found 3–5 weeks after the initial episode. Bleeding and hemorrhage have been seen anywhere from two months to eight years after a single episode of pancreatitis.^{5,6} Gastroduodenal artery pseudoaneurysms are seen in up to 20% of arterial pseudoaneurysms complicated by pancreatitis, while pancreaticoduodenal arteries are involved in up to 10% of cases.^{2,5}

Although pancreatic pseudoaneurysms are uncommon, it is important to recognize this condition early, as it can result in life-threatening complications. Patients will typically present with gastrointestinal bleeding or abdominal pain.² Pseudoaneurysms may cause gastrointestinal bleeding by erosion into the adjacent bowel or they may directly rupture, causing bleeding into the retroperitoneum.¹ Computed tomography usually provides appropriate diagnostic images; however, angiography has been demonstrated to be the most informative investigation for diagnosis as well as treatment. Computed tomography angiography has a high rate of sensitivity and specificity but does not facilitate intervention concurrently. Angiography defines the character and location of the lesions, as well as provides an opportunity to gain control over the bleeding by transcatheter embolization or possible stenting.¹ A series of 35 patients from 1993–2003 indicated 95% of pseudoaneurysms were detected with angiography while only 90% were detected with CT angiography.¹ Although CT angiography is an important tool in the ED to diagnose these cases, management per the IR team is paramount for success.

Endovascular use of metallic coils is frequently used as the definitive treatment of these pseudoaneurysms. Other tools including covered stents, detachable balloons, gel foam, or particles have also been used with success rates of up to 85%.¹

Surgical treatment has been shown to be challenging and associated with high morbidity rates, thus reserving surgical intervention in cases of failed embolization or hemodynamically unstable patients.¹ The reported incidence of recurrent hemorrhage after thrombosis is as high as 30%, with embolization of pancreatic pseudoaneurysms requiring long-term follow-up in these patients.¹³ In the case of our patient, IR was able to successfully embolize the large IPDA pseudoaneurysm with follow-up imaging demonstrating ongoing resolution.

CONCLUSION

Pancreaticoduodenal and gastroduodenal artery pseudoaneurysms are rare and dangerous visceral pathologies. Pseudoaneurysms usually occur in the proximity of pseudocysts or chronic inflammatory conditions and are a known complication of chronic pancreatitis. Patients can be diagnosed in the ED with CT angiography and need urgent endovascular management with interventional radiology to prevent morbidity and mortality. Due to high rates of recurrent hemorrhage after thrombosis, patients should have close follow-up and serial imaging to assess for pseudoaneurysm or aneurysm recurrence.

The authors attest that their institution requires neither Institutional Review Board approval, nor patient consent for publication of this case report. Documentation on file.

Address for Correspondence: Patrick Meloy, MD, Emory University School of Medicine, Department of Emergency Medicine, 531 Asbury Circle, Annex Building, Suite N340, Atlanta, GA 30322. Email: patrickmeloy@emory.edu

Conflicts of Interest: By the CPC-EM article submission agreement, all authors are required to disclose all affiliations, funding sources and financial or management relationships that could be perceived as potential sources of bias. The authors disclosed none.

Copyright: © 2024 Meloy et al. This is an open access article distributed in accordance with the terms of the Creative Commons Attribution (CC BY 4.0) License. See: <http://creativecommons.org/licenses/by/4.0/>

REFERENCES

1. Pitton MB, Dappa E, Jungmann F, et al. Visceral artery aneurysms: incidence, management, and outcome analysis in a tertiary care center over one decade. *Eur Radiol.* 2015;25(7):2004–14.
2. Kumar V, Abbas AK, Aster JC. *Robbins Basic Pathology*. 10th ed. (Kumar V, Abbas AK, Aster JC, eds.). Elsevier - Health Sciences Division; 2021.
3. Mendelson RM, Anderson J, Marshall M, et al. Vascular complications of pancreatitis. *ANZ J Surg.* 2005;75(12):1073–9.
4. Yamaguchi K, Futagawa S, Ochi M, et al. Pancreatic pseudoaneurysm converted from pseudocyst: transcatheter embolization and serial CT assessment. *Radiat Med.* 2000;18(2):147–50.
5. Dorffel Y, Wruck U, Ruckert RI, et al. Vascular complications in acute pancreatitis assessed by color duplex ultrasonography. *Pancreas.* 2000;21(2):126–33.
6. Balthazar EJ. Acute Pancreatitis: Assessment of severity with clinical and CT evaluation. *Radiology.* 2002;223(3):603–13.
7. Boudghène F, L'Herminé C, Bigot JM. Arterial complications of pancreatitis: diagnostic and therapeutic aspects in 104 cases. *J Vasc Interv Radiol.* 1993;4(4):551–8.
8. Agrawal G, Johnson PT, Fishman EK. Splenic artery aneurysms and pseudoaneurysms: clinical distinctions and CT appearances. *AJR Am J Roentgenol.* 2007;188(4):992–9.
9. Bradley EL. Complications of chronic pancreatitis. *Surg Clin North Am.* 1989;69(3):481–97.
10. Vázquez-Ruiz J, López-Flor V, Aguado-Pérez M, et al. Pancreatic pseudoaneurysms: forms of presentation and therapeutic options. *Cir Cir (English Edition).* 2015;83(5):454–5.
11. Bergert H, Dobrowolski F, Caffier S, et al. Prevalence and treatment of bleeding complications in chronic pancreatitis. *Langenbeck's Arch Surg.* 2004;389(6):504–510.
12. Guillon R, Garcier JM, Abergel A, et al. Management of splenic artery aneurysms and false aneurysms with endovascular treatment in 12 patients. *Cardiovasc Intervent Radiol.* 2003;26(3):256–260.
13. de Perrot M, Berney T, Buhler LH, et al. Management of bleeding pseudoaneurysms in patients with pancreatitis. *Br J Surg.* 1999;86(1):29–32.

Peritonsillar Abscess and Post-aspiration Bleed Identified with Point-of-care Ultrasound Using Endocavitary Probe: A Case Report

Jaclyn Floyd, MD
Brandon Dahl, DO
Matthew Whited, MD
Ami Kurzweil, MD

Eisenhower Medical Center, Department of Emergency Medicine, Rancho Mirage, California

Section Editor: Joel Moll, MD

Submission history: Submitted August 30, 2023; Revision received November 15, 2023; Accepted November 17, 2023

Electronically published March 26, 2024

Full text available through open access at http://escholarship.org/uc/uciem_cpccem

DOI: 10.5811/cpcem.1645

Introduction: Peritonsillar abscesses form between the tonsillar capsule, the superior constrictor, and palatopharyngeus muscles. Physicians traditionally make this diagnosis clinically; however, ultrasound allows clinicians to further identify and differentiate between peritonsillitis, peritonsillar abscess, and phlegmon formation. By increasing both the sensitivity and specificity, ultrasound improves the diagnostic accuracy for patients with peritonsillar abscesses. This case demonstrates the utilization of ultrasound in peritonsillar abscesses and the application of point-of-care ultrasound (POCUS) in identifying complications of procedures used for treatment in the emergency department (ED).

Case Report: A 19-year-old male presented to the ED with complaints of severe sore throat and fever for the prior five days. A POCUS using an endocavitary probe with sterile cover demonstrated hypoechoic debris with a “swirl sign.” Ultrasound was used to successfully guide needle aspiration by using in-plane needle guidance. The patient had significant bleeding after needle aspiration, and repeat POCUS clearly identified a new pocket of blood that had formed and was contained in the soft tissue. We monitored the size of the hematoma in real time with ultrasound to ensure the hematoma had no rapid expansion and was stable.

Conclusion: Among the differential diagnoses for sore throat, the diagnosis of peritonsillar abscess is particularly concerning as it is both common and generally requires swift intervention. Presentations can range from a mild infection to a life-threatening emergency with potential airway compromise. The two primary avenues for treatment include either needle aspiration or incision and drainage. Ultrasound can successfully identify the abscess and other landmarks for safe and successful drainage, as well as early identification of complications. [Clin Pract Cases Emerg Med. 2024;8(2)129–132.]

Keywords: *peritonsillar abscess; endocavitary ultrasound probe; ultrasound; otolaryngology; case report.*

INTRODUCTION

Peritonsillar abscess is the most common deep-space infection of the head and neck. Cases are commonly polymicrobial but most commonly caused by streptococcus. Patients may present with fever, odynophagia, dysphagia, trismus and possibly a muffled voice colloquially known as

“hot potato voice.” Diagnosis of peritonsillar abscess using history and physical alone has a sensitivity and specificity of 75% and 50%, respectively. Diagnosis using ultrasound, in addition to history and physical, using an endocavitary probe placed intraorally showed a sensitivity and specificity of 91% and 75%, respectively, while transcervical showed a

sensitivity and specificity of 80% and 81%, respectively.⁷ This case highlights an interesting complication of acute bleed demonstrated by point-of-care ultrasound (POCUS) during peritonsillar drainage. Ultrasound identification of peritonsillar abscess is on the consensus list for competencies in emergency medicine residency³; proficiency in ultrasound is increasingly expected in trainees, and this particular scenario exemplifies its utility.

CASE PRESENTATION

A 19-year-old male with no past medical history presented to the emergency department (ED) with the complaint of six days of sore throat, primarily on the right side. He also had fever and chills, otalgia, and odynophagia. On physical exam the patient's voice had a muffled tone, he felt warm to touch, and there was swelling next to the right tonsil with uvular deviation. He was not having any difficulty breathing, and no stridor was noted. Computed tomography (CT) had been ordered, which returned showing a right peritonsillar abscess measuring 23 × 32 × 45 millimeters, enlargement of Waldeyer's ring, and right-sided level II and III lymphadenopathy. A POCUS using the endocavitary probe with sterile cover demonstrated encapsulated, swirling echogenic debris approximately 3 centimeters (cm) deep. This was used to clearly mark the location for needle aspiration.

Needle aspiration was performed with removal of 10 milliliters (mL) of purulence, and the patient started to have significant bleeding, approximately 200 milliliters of both blood and saliva in the suction cannister within a few minutes. A solution of 4% cocaine was soaked onto long cotton tips, and pressure was held for 10 minutes. Repeat ultrasound was performed every two minutes, which showed a hyperechoic pocket, likely representing fresh hematoma, not expanding. Two physicians were in the room, with one physician continuing to hold pressure, although moving slightly laterally at each two-minute interval to allow space for the second physician to perform a repeat ultrasound. Each repeat ultrasound demonstrated stability of the hematoma, and at 10 minutes the hematoma was considered controlled. Clinically at this point, the patient had no further oropharyngeal bleeding.

Otolaryngology was consulted regarding the findings and recommended additional incision and drainage (I&D) given the initial size of the abscess found on CT. In addition, they recommended intravenous (IV) antibiotics, IV dexamethasone, soft diet, and admission. The I&D was performed in the operating room, and the patient was discharged the following day on clindamycin, orally and a medrol dose pack.

DISCUSSION

Peritonsillar abscess is a frequently made diagnosis both in urgent care and in the ED. It affects an estimated 45,000 people per year, with over half being admitted for further treatment.¹⁰ Physical exam will reveal a unilateral (rarely bilateral) swelling above and lateral to the tonsils with

Population Health Research Capsule

What do we already know about this clinical entity?

Peritonsillar abscess is the most common deep-space infection of the head and neck.

What makes this presentation of disease reportable?

This case highlights the rapid onset of a hematoma following needle aspiration and the use of ultrasound to monitor its progression.

What is the major learning point?

Hematoma development may be one cause of bleeding after needle aspiration of peritonsillar abscess and this can be seen with a point-of-care ultrasound.

How might this improve emergency medicine practice?

Clinicians can utilize ultrasound guidance to help manage complications of needle aspirations for peritonsillar abscess, with an image and video for reference.

contralateral deviation of the uvula. Peritonsillar abscess is a medical emergency due to the possibility of upper airway obstruction and the patient's inability to protect their own airway. Diagnosis is clinical; however, ultrasound can be used to differentiate between peritonsillitis and peritonsillar abscess. Treatment includes I&D or needle aspiration and antibiotics.

Ultrasound can be used to perform I&D or needle aspiration and has been shown helpful in identifying the location of the abscess and increasing the safety of the procedure by aiding in identifying arterial vasculature such as the underlying carotid artery and its distance from the abscess pocket (*Image*). While ultrasound can help minimize complications, they can still occur. The most frequent complications of peritonsillar abscess include mediastinitis, necrotizing fasciitis, Lemierre syndrome, and retropharyngeal abscess.² Antibiotic treatment should cover staphylococcus and streptococcus, anaerobes, *Eikenella corrodens*, and *Haemophilus influenzae*. Intravenous antibiotic options include ampicillin/sulbactam, piperacillin/tazobactam, clindamycin or ceftriaxone. Outpatient antibiotic options include clindamycin or amoxicillin/clavulanate.

Ultrasound can be helpful in identifying crucial aspects of each of these complications. For example, in necrotizing

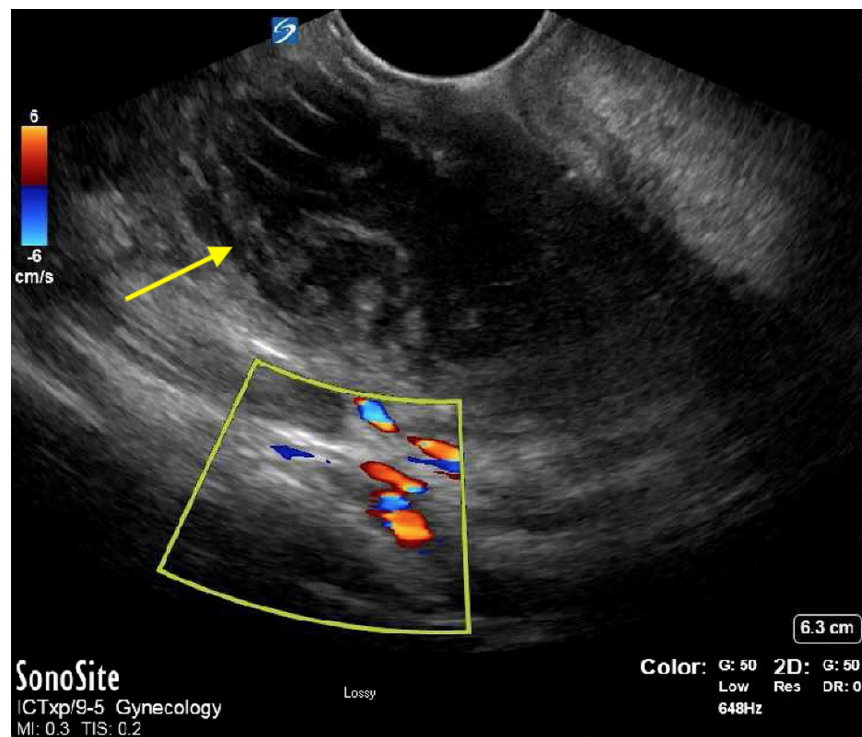


Image. Point-of-care ultrasound with endocavitary probe demonstrating swirling echogenic debris encapsulated approximately 3 centimeters deep, representing initial abscess (arrow). Color box represents vasculature, including carotid artery.

fasciitis ultrasound has a high sensitivity in identifying free air.⁹ For retropharyngeal abscess, ultrasound can identify the pocket of fluid, a utilization that has mostly been described in pediatrics.¹¹ This case shows an unexpected complication of needle aspiration. The hematoma shown in Video was monitored using the endocavitary probe to ensure it was not rapidly expanding as pressure was held on the cavity exteriorly. Pressure was held continuously for 10 minutes, while the endocavitary probe was used every two minutes to monitor the hematoma. This case exemplifies how the endocavitary probe approach can be extremely useful in helping to manage a peritonsillar abscess as well as complications that may arise.

CONCLUSION

The skill of using ultrasound to detect peritonsillar abscess is acknowledged as a key competency for emergency medicine residents.³ This case study demonstrates the utility of point-of-care ultrasound in both identifying peritonsillar abscesses and providing guidance during the aspiration procedure. Gaining a visual diagnosis when complications arise can prove to be exceptionally valuable.

Video. Point-of-care ultrasound demonstrating hyperechoic pocket, representing fresh hematoma (arrow).

The authors attest that their institution requires neither Institutional Review Board approval, nor patient consent for publication of this case report. Documentation on file.

Address for Correspondence: Jaclyn Floyd, MD, Eisenhower Medical Center, Department of Emergency Medicine, 39000 Bob Hope Dr, Rancho Mirage, CA 92270. Email: jfloyd@eisenhowerhealth.org

Conflicts of Interest: By the CPC-EM article submission agreement, all authors are required to disclose all affiliations, funding sources and financial or management relationships that could be perceived as potential sources of bias. The authors disclosed none.

Copyright: © 2024 Floyd et al. This is an open access article distributed in accordance with the terms of the Creative Commons Attribution (CC BY 4.0) License. See: <http://creativecommons.org/licenses/by/4.0/>

REFERENCES

1. Chang BA, Thamboo A, Burton MJ, et al. Needle aspiration versus incision and drainage for the treatment of peritonsillar abscess. *Syst Rev.* 2016;12(12):CD006287.
2. Klug TE, Greve T, Hentze M. Complications of peritonsillar abscess. *Ann Clin Microbiol Antimicrob.* 2020;19(1):32.
3. Haidar D, Peterson W, Minges P, et al. A consensus list of ultrasound competencies for graduating emergency medicine residents. *AEM Educ Train.* 2022;6(6):e10817.
4. Bryczkowski C, Haussner W, Rometti M, et al. Impact of bedside ultrasound on emergency department length of stay and admission in patients with a suspected peritonsillar abscess. *Cureus.* 2022;14(12):e32207.

5. Mills LD, May K, Mihlon F. Peritonsillar abscess with uvular hydrops. *West J Emerg Med.* 2010;11(1):83–5.
6. Kim DJ, Burton JE, Hammad A, et al. Test characteristics of ultrasound for the diagnosis of peritonsillar abscess: a systematic review and meta-analysis. *Acad Emerg Med.* 2023;30(8):859–69.
7. Donaldson R, Swartz J, Lu K, et al. Peritonsillar abscess. WikEM. 2021. Available at: https://wikem.org/wiki/Peritonsillar_abscess. Accessed February 26, 2023.
8. Ballew JD. Unlocking Common ED procedures - peritonsillar abscess drainage. EmDOCs.net - Emergency Medicine Education, EmDOCs. 2019. Available at: <https://www.emdocs.net/unlocking-common-ed-procedures-peritonsillar-abscess-drainage/>. Accessed February 26, 2023.
9. Yen ZS, Wang HP, Ma HM, et al. Ultrasonographic screening of clinically suspected necrotizing fasciitis. *Acad Emerg Med.* 2009;9(12):1448–51.
10. Glasier CM, Stark JE, Jacobs RF, et al. CT and ultrasound imaging of retropharyngeal abscesses in children. *AJNR Am J Neuroradiol.* 1992;13(4):1191–5.
11. Ortega BK, Short S, Kane BG, et al. Management of peritonsillar abscess within a local emergency department: a quality analysis study. *Cureus.* 2021;13(8):e17545.

Permissive Hypotension in a Patient with Severe Hyponatremia: A Case Report

Andrea Hlady, MD*
David Kerner, MD†
Laura E. Walker, MD, MBA†

*Mayo Clinic Health System, Department of Emergency Medicine,
Alberta Lea, Minnesota

†Mayo Clinic, Department of Emergency Medicine, Rochester, Minnesota

Section Editor: Anna McFarlin, MD

Submission history: Submitted May 31, 2023; Revision received October 18, 2023; Accepted November 1, 2023

Electronically published March 25, 2024

Full text available through open access at http://escholarship.org/uc/uciem_cpccem

DOI: [10.5811/cpcem.1422](https://doi.org/10.5811/cpcem.1422)

Introduction: Severe hyponatremia is a critical situation, and when coupled with intravascular depletion and hypotension can create a treatment dilemma.

Case Report: We present the case of a medically complex patient who had gradually worsening alteration of mental status and mean arterial pressures in the 50s on presentation to the emergency department.

Conclusion: Final diagnoses included severe hyponatremia and hypovolemic shock secondary to poor oral intake. We used judicious fluid repletion with gradual improvement in sodium levels and permissive hypotension to avoid rapid osmotic shifts. Balancing reperfusion and the risk for osmotic effects of aggressive fluid resuscitation can be a challenging situation for the multidisciplinary team. [Clin Pract Cases Emerg Med. 2024;8(2)133–137.]

Keywords: *metabolic disturbance; hyponatremia; permissive hypotension; case report.*

INTRODUCTION

Mental status change in older adults is a common presenting complaint and often due to systemic processes such as infection, trauma, central nervous system (CNS) impairment, medications, metabolic derangements, cardiopulmonary dysfunction, or iatrogenic effects.¹ Taken as a multifactorial process, risk of delirium is increased by nursing home residents' cognitive impairment, hearing impairment, and history of stroke, with potential strong associations with frailty and malnutrition.² Due to the broad differential, evaluations for delirium and mental status changes often include screening for underlying infections, metabolic derangements, dehydration, primary CNS causes, trauma, and other causes of end organ damage.

Hyponatremia, serum sodium greater than 145 milliequivalents per liter (mEq/L), is common in older adults, and nursing home residents are particularly at risk as oral rehydration can be challenging.³ Most cases are found at the extremes of age, when individuals are less able to act on or detect thirst. Additional causes include insensible losses,

gastrointestinal losses, central or nephrogenic causes, and diuresis. Increased oral intake of sodium without concomitant free water can also result in hyponatremia. Treating both the underlying condition and restoring normal physiology underlies the approach to care in the emergency department (ED). Acute vs chronic onset of hyponatremia determines the rate at which sodium is corrected to avoid iatrogenic cerebral edema.⁴ We describe a case in which hemodynamic instability and severe hyponatremia presented together, creating a complex scenario for ED resuscitation.

We adhered to the CARE guidelines for reporting case studies.⁵

Patient Information

A 64-year-old woman was transported to the ED via emergency medical services (EMS) with altered mental status and generalized weakness. Her medical history was significant for contractures of unknown etiology, osteoporosis, psoriatic arthritis, bullous pemphigoid,

paroxysmal supraventricular tachycardia, hypertension, and mild cognitive impairment. She required ongoing nursing care due to her limited mobility caused by her contractures.

Upon ED arrival she was unable to contribute to the history secondary to her mental status changes. Family informed the ED team that she had been unwell for the prior three days with decreased oral intake and increased confusion. They had noticed that she was not eating at her recent birthday celebration and that her speech seemed “off” when speaking via telephone. On the day of presentation she had not called her family and, therefore, a family member requested that a nurse check in on her. They also visited the patient later that day finding her confused, prompting activation of EMS.

Clinical Findings

On arrival to the ED her blood pressure was initially measured at 101/64 millimeters of mercury (mm Hg) but within 30 minutes was 75/63 mm Hg, heart rate 137 beats per minute, respiratory rate 34 breaths per minute with normal saturations of 97%, and a temperature of 36.6° Celsius (C). Her weight was 35.3 kilograms. She was confused and unable to answer questions or follow commands. She appeared cachectic, with bitemporal wasting. Her eyes were sunken, and there was purulent drainage from the right eye. Mucous membranes were dry. Her eyes were open, she was moaning with incomprehensible speech, and she withdrew from pain. She had weak peripheral pulses. Cardiopulmonary exam revealed tachycardia and clear lungs bilaterally. Her abdomen was soft, although she did appear to have voluntary guarding. She had severe contractions of the upper and lower extremities. Her skin was warm and dry.

With her hemodynamic abnormalities the priority after primary survey was to obtain intravenous (IV) access. This was impaired by the diffuse contractures as well as hypovolemia. Ultrasound-guided peripheral IV and central venous catheter access were attempted, but veins appeared to be non-compressible and concerning for diffuse clot burden precluding additional attempts. Intraosseous access was obtained, and the patient was given a bolus of one liter normal saline and started on lactated Ringer’s at a rate of 200 milliliters per hour (mL/hr). A timeline of patient care is presented in the [Table 1](#).

Diagnostic Assessment

Lab studies included electrolytes, complete blood count, lactate, coagulation profile, blood cultures, and COVID-19 and influenza swabs, as well as urinalysis. Significant findings are shown in the [Table 2](#). Upon discovery that her sodium was 176 mEq/L, fluid resuscitation was paused to determine appropriate rate of administration for safe correction.

Table 1. A timeline of the patient episode of care.

Elapsed Time	Event
00:00	Patient arrival
00:12	Initial physician evaluation
00:18	Attempts at peripheral access unsuccessful HR: 137; BP: 101/64
00:29	1 liter 0.9% normal saline bolus initiated
00:44	Point-of-care glucose 87 mg/dL Labs drawn
00:48	HR: 136; BP: 75/63
00:53	Complete blood count resulted
01:07	Lactate resulted
01:16	Basic metabolic panel resulted
01:18	HR: 136; BP: 75/65
01:48	HR: 140; BP: 75/58
01:51	Urinalysis resulted Family present to provide additional history
1:58	Intraosseous needle placed
02:00	HR: 140; BP: 114/98
02:29	Bedside echocardiogram: hyperdynamic myocardium, collapsed IVC noted
02:48	HR: 116
02:50	Urine osmolality resulted
03:03	HR: 131; BP: 73/55
03:24	Peripheral IV access obtained
04:31	Point-of-care venous blood gas obtained, repeat lactate improving
04:33	Piperacillin/sulbactam administered, lactated Ringer’s initiated at 200 mL/hour HR: 122; BP: 73/46
04:47	Arterial line placed
04:48	HR 118; BP: 73/47
05:03	HR 114; BP: 76/48
05:18	Heparin drip initiated due to concern for clot HR: 119; BP: 71/43
05:21	Imaging results reassuring, decision to admit to medical intensive care unit
05:48	HR: 122; BP: 83/51
06:03	HR: 122; NP: 81/49 Patient transported to intensive care unit
8:00–30:00	D5W administered at varying rates BP (MAP) ranges from 55-69
86:00	Sodium level 145 mEq/L

HR, heart rate; BP, blood pressure; IVC, inferior vena cava; IV, intravenous; mL, milliliters; D5W, dextrose 5% in water; MAP, mean arterial pressure; mg/dL, milligrams per deciliter; mEq/L, milliequivalents per liter.

Table 2. Notable lab studies.

WBC	27.4 × 10 ⁹ /L
Neutrophil count	21.89 cells/L
Hematocrit	47.6%
Sodium	176 mEq/L
Chloride	131 mEq/L
Creatinine	2.85 mg/dL (baseline 0.7)
BUN	85 mg/dL
INR	1.8
Lactate	3.7 mEq/L
Urine	Red appearance, cloudy; + RBCs, + WBCs, + ketones, + nitrites, + leukocyte esterase

WBC, white blood cells; BUN, blood urea nitrogen; INR, international normalized ratio; RBC, red blood cells; mEq/L, milliequivalents per liter; mg/dL, milligrams per deciliter.

Her hypotension, apparent abdominal discomfort, and concern for diffuse clotting prompted several imaging studies. These were delayed secondary to difficulty obtaining IV access and concern for potential significant clot burden. Ultimately when they were obtained computed tomography (CT) of the abdomen and pelvis demonstrated no acute findings, CT of the brain showed no apparent abnormalities, and lower extremity ultrasound did not reveal acute deep vein thrombosis.

The patient continued to have tachycardia and hypotension following the initial liter of crystalloid provided. The discovery of profound hyponatremia prompted a treatment dilemma, in which slow correction of sodium was pursued rather than rapid correction of hemodynamics. Our assessment, based on the history provided by the family, was that this was likely a chronic development of hyponatremia. Clinically, she appeared dehydrated and in need of additional fluids. In addition to dehydration and resulting hyponatremia, we considered the possibility of sepsis with a possible urinary source. Her elevated lactate, creatinine, and urinary ketones, as well as her hemodynamics, were evidence of a need for additional fluids. The degree of sodium elevation she had is associated with a risk of mortality of 75%⁶; additionally, her elevated lactate in the setting of infection contributed additional risk of mortality within 28 days.⁷

Therapeutic Intervention

After the initial one liter of normal saline was given and we discovered her hyponatremia, we adjusted fluid administration to achieve a goal rate of sodium correction between 10–12 mEq/L per day, starting with lactated Ringer's at 200 cc/hr. An ED pharmacist assisted to ensure appropriate therapy. She was treated empirically for possible

urosepsis with piperacillin-sulbactam (2.25 g) pending culture results.

During her ED stay our team struggled with the conflicting desires to treat her hypotension and tachycardia and provide resuscitation for her sepsis/hypovolemia while managing her hyponatremia. Aggressive rehydration would have likely resulted in cerebral edema and a very poor outcome. We opted to pursue permissive hypotension in the ED, and this course of care was continued into the intensive care unit (ICU). Upon ICU admission, she was started on dextrose 5% in water at a rate of 100 milliliters per hour (mL/hr) with additional free water administered via nasogastric tube at 50 mL/hr.

Follow-up and Outcomes

During hospitalization, nutritional studies revealed severe malnutrition. Additional history at that time uncovered she had over 20% weight loss over the course of the prior year. She was transferred to the regular medical floor when her sodium reached 152 mEq/mL, two days after admission. Her hospital course was characterized by difficulty with oral intake. A palliative care consult was performed, and a family decision was made to pursue feeding via nasogastric tube followed by percutaneous endogastric tube. Anemia developed following rehydration, thought to also be associated with frequent lab draws, and she was transfused with one unit of packed red blood cells. She had episodes of aspiration with resulting tachycardia and tachypnea. Imaging studies revealed an exudative pleural effusion with negative cultures. Her symptoms improved without antibiotics. She remained stable for the remainder of her hospitalization and was discharged on hospital day 24 to a skilled nursing facility with parenteral feeding. [Figure 1](#) demonstrates the rate of sodium correction along with representative mean arterial pressure (MAP) during this period.

DISCUSSION

Management of hyponatremia is a “bread and butter” topic in emergency medicine. However, the role of permissive hypotension in resuscitation is most often cited in reference to patients with trauma and severe hemorrhage,⁸ ruptured abdominal aortic aneurysm,⁹ and vasodilatory shock.¹⁰ Neither at the time care was provided, nor subsequently, did we identify literature discussing the tenuous resuscitation of patients with severe hypovolemia and hypotension in the setting of profound hyponatremia.

The immediate care for this patient presented a situation that was stressful for the ED team. Persistent hypotension and tachycardia in the ED were noted by team members including nursing, physician trainees, and pharmacists. This was remediated by good team communication and collaboration. A shared understanding of the order of operations we would undertake and the reasoning behind

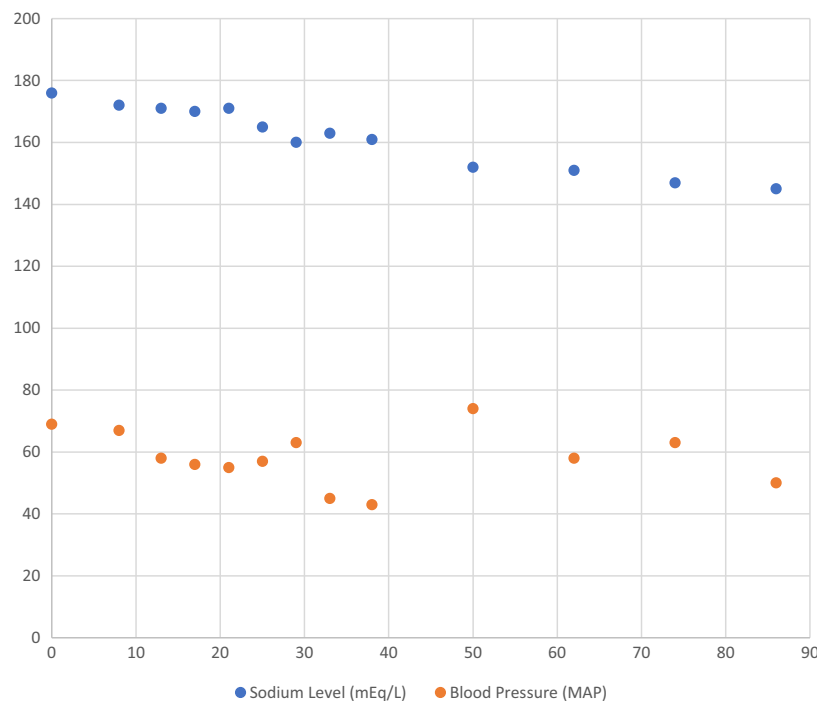


Figure. Hourly trends of sodium level and mean arterial pressure. MAP, mean arterial pressure; mEq/dL, milliequivalents per deciliter.

permissive hypotension was crucial to providing appropriate care for the patient. When we are pushed out of our typical algorithm of “airway, breathing, circulation” and instead need to tend to long-term survivability due to potential metabolic/neurologic compromise, the smooth care we typically aim to provide is disrupted. Knowing when and how to go “off protocol” from the basic approach to resuscitation is a key skill in emergency medicine.

The goal of treating hypotension is to reduce end organ injury. This is primarily achieved through fluid resuscitation and vasopressors. However, there are times when either fluids or vasopressors may be detrimental. Consider aggressive fluid resuscitation in pulmonary embolism or hypernatremia, crystalloid resuscitation in hemorrhagic shock, or high vasopressor use and tissue hypoxia as well as increased mortality in vasodilatory and hemorrhagic shock.^{8,11–15} In these instances, permissive hypotension may be in the best interest of the patient, but what are the effects of long-term controlled permissive hypotension and what degree of hypotension should we allow?

There are very few studies discussing this issue and even fewer that can direct our practice. Most studies are focused on the effects of hemorrhagic shock. A retrospective cohort study of ICU patients suggests that the MAP at which terminal cardiovascular collapse occurs is somewhere between 30–46 mm Hg¹⁵; and we are taught that 65 mm Hg is the optimal MAP goal, and in some instances higher (eg, post-operative spinal cord perfusion). In a randomized control trial evaluating ICU patients ≥ 65 years comparing

permissive hypotension to usual care, they did not find a statistically significant difference in 90-day mortality and no difference in serious adverse events. Most adverse events related to acute renal failure and supraventricular cardiac arrhythmias. Cognitive decline and health-related quality of life at 90 days and at one year were similar between the two groups.¹⁰ Allowing permissive hypotension and deferring to other priorities in resuscitation may offer an advantage with minimal downside in cases such as severe hypernatremia and volume depletion.

The primary take-aways from this case include the importance of rapid reassessment and pivoting from aggressive crystalloid resuscitation when hypernatremia was identified; and the use of permissive hypotension in hypovolemic hypernatremia to prioritize central nervous system stability and establish a shared understanding of the treatment priorities for ED team members. We believe that ED and subsequent ICU care were essential to the patient’s survival to discharge.

The authors attest that their institution requires neither Institutional Review Board approval, nor patient consent for publication of this case report. Documentation on file.

Address for Correspondence: Laura E. Walker, MD, MBA, Mayo Clinic, Department of Emergency Medicine, 200 First St. SW, Rochester, MN 55902. Email: Walker.laura@Mayo.edu

Conflicts of Interest: By the CPC-EM article submission agreement, all authors are required to disclose all affiliations, funding sources and financial or management relationships that could be perceived as potential sources of bias. The authors disclosed none.

Copyright: © 2024 Hlady et al. This is an open access article distributed in accordance with the terms of the Creative Commons Attribution (CC BY 4.0) License. See: <http://creativecommons.org/licenses/by/4.0/>

REFERENCES

- Han JH and Wilber ST. Altered mental status in older patients in the emergency department. *Clin Geriatr Med.* 2013;29(1):101–36.
- Oliveira JESL, Berning MJ, Stanich JA, et al. Risk factors for delirium in older adults in the emergency department: a systematic review and meta-analysis. *Ann Emerg Med.* 2021;78(4):549–65.
- Morley JE. Dehydration, hypernatremia, and hyponatremia. *Clin Geriatr Med.* 2015;31(3):389–99.
- Muhsin SA and Mount DB. Diagnosis and treatment of hypernatremia. *Best Pract Res Clin Endocrinol Metab.* 2016;30(2):189–203.
- Riley DS, Barber MS, Kienle GS, et al. CARE guidelines for case reports: explanation and elaboration document. *J Clin Epidemiol.* 2017;89:218–35.
- Kim SW. Hyponatremia : successful treatment. *Electrolyte Blood Press.* 2006;4(2):66–71.
- Shapiro NI, Howell MD, Talmor D, et al. Serum lactate as a predictor of mortality in emergency department patients with infection. *Ann Emerg Med.* 2005;45(5):524–8.
- Woodward L and Alsabri M. Permissive hypotension vs. conventional resuscitation in patients with trauma or hemorrhagic shock: a review. *Cureus.* 2021;13(7):e16487.
- Moreno DH, Cacione DG, Baptista-Silva JC. Controlled hypotension versus normotensive resuscitation strategy for people with ruptured abdominal aortic aneurysm. *Cochrane Database Syst Rev.* 2018;6(6):CD011664.
- Mouncey PR, Richards-Belle A, Thomas K, et al. Reduced exposure to vasopressors through permissive hypotension to reduce mortality in critically ill people aged 65 and over: the 65 RCT. *Health Technol Assess.* 2021;25(14):1–90.
- Belenkie I, Dani R, Smith ER, et al. Effects of volume loading during experimental acute pulmonary-embolism (In English). *Circulation.* 1989;80(1):178–88.
- Francis S and Kabrhel C. Current controversies in caring for the critically ill pulmonary embolism patient (In English). *Emerg Med Clin N Am.* 2020;38(4):931–44.
- Harjola VP, Mebazaa A, Celutkiene J, et al. Contemporary management of acute right ventricular failure: a statement from the Heart Failure Association and the Working Group on Pulmonary Circulation and Right Ventricular Function of the European Society of Cardiology (In English). *Eur J Heart Fail.* 2016;18(3):226–41.
- Lamontagne F, Day AG, Meade MO, et al. Pooled analysis of higher versus lower blood pressure targets for vasopressor therapy septic and vasodilatory shock. *J Intensive Care Med.* 2018;44(1):12–21.
- Brunauer A, Kokofer A, Bataar O, et al. The arterial blood pressure associated with terminal cardiovascular collapse in critically ill patients: a retrospective cohort study. *Crit Care.* 2014;18(6):719.

Profound Alkalosis and Prolonged QT Interval Due to Inappropriate Gastrostomy Tube Loss: A Case Report

Forrest Turner, MD*
Brandon Friedman, MD*
H. Pendell Meyers, MD*
Stephen W. Smith, MD†

*Carolinas Medical Center, Department of Emergency Medicine, Charlotte, North Carolina
†Hennepin Healthcare and University of Minnesota School of Medicine, Department of Emergency Medicine, Minneapolis, Minnesota

Section Editor: Joel Moll, MD

Submission history: Submitted July 14, 2023; Revision received January 17, 2024; Accepted January 25, 2024

Electronically published April 30, 2024

Full text available through open access at http://escholarship.org/uc/uciem_cpem

DOI: [10.5811/cpcem.1519](https://doi.org/10.5811/cpcem.1519)

Introduction: Severe metabolic alkaloses are relatively rare but can carry a high mortality rate. Treatment involves supportive care and treatment of underlying causes.

Case Report: A 55-year-old male dependent on a gastrojejunostomy tube presented to the emergency department for altered mental status. The patient had metabolic alkalosis, electrolyte abnormalities, and prolonged QT interval on electrocardiogram. Examination and history revealed that chronic drainage of gastric fluid via malfunctioning a gastrojejunostomy tube resulted in profound alkalosis. The patient recovered with supportive care, electrolyte repletion, and gastrojejunostomy tube replacement.

Conclusion: This case highlights the importance of gastrointestinal acid-base pathophysiology. [Clin Pract Cases Emerg Med. 2024;8(2)138–142.]

Keywords: *metabolic alkalosis; prolonged QT interval; case report.*

INTRODUCTION

Metabolic alkalosis accounts for approximately half of acid-base derangements in hospitalized patients. However, cases of severe alkalosis (pH > 7.55) are less common and carry a surprisingly high mortality.^{1–4} Anderson et al reported a mortality of 27.9% in patients with pH > 7.48, rising to 48.5% in patients with pH > 7.60.⁵ Metabolic alkalosis, which is characterized by elevated plasma pH and serum bicarbonate and decreased serum chloride, can result in elevated partial pressure of carbon dioxide (pCO₂) via respiratory compensation. It is often associated with hypokalemia.

Metabolic alkaloses related to diuretic use or gastrointestinal losses are referred to as chloride responsive, as they are associated with the depletion of sodium chloride and volume. This results in a secondary hyperaldosteronism, thereby exacerbating potassium wasting and retention of bicarbonate within the nephron. Therapy is focused on repleting volume and electrolytes. Non-chloride responsive metabolic alkalosis has many causes including

hyperaldosteronism of any etiology (eg, primary, secondary, exogenous mineralocorticoid), hypomagnesemia, hypokalemia, or exogenous alkali in the setting of renal insufficiency. Clinical manifestations of metabolic alkalosis can be non-specific and will often overlap with other associated electrolyte derangements; these include confusion, muscle cramping, tetany, seizure, cardiac dysrhythmia, and hypoventilation.⁶

CASE REPORT

A 55-year-old male with past medical history of cerebral palsy, spastic quadriplegia, seizure disorder, and dysphagia, and dependent on a gastrojejunostomy tube presented from a skilled nursing facility with altered mental status. The patient was more lethargic and less interactive as compared to his baseline, according to staff at the facility. Otherwise, he had no communicable complaints and a limited review of systems due to lethargy. He could state his name and follow simple commands but was unable to articulate his symptoms. The patient had not been prescribed diuretic medications and had

no history of recent vomiting or diarrhea. Initial vital signs included heart rate of 57 beats per minute (BPM), blood pressure 103/65 millimeters of mercury (mm Hg), respiratory rate of 12 breaths per minute, and an oxygen saturation of 93% on two liters of oxygen by nasal cannula. (The patient had no baseline oxygen requirement.)

Initial laboratory studies were notable for hyponatremia, hypochloremia, hypokalemia, hypocalcemia, acute kidney injury, and a serum bicarbonate above measurable range for the lab. These studies are summarized in the Table. The initial venous blood gas measured a pH of 7.61 (reference range: 7.31–7.41); pCO₂ 77 mm Hg (35–45 mm Hg); bicarbonate 77 millimoles per liter (mmol/L) (24–28 mmol/L) and base excess 47 (–2 – +2). The initial electrocardiogram (Image 1) was notable for sinus bradycardia at a rate of 56 BPM and markedly prolonged QT or QU interval of approximately 690 milliseconds (ms), with diffuse T-wave flattening and biphasic morphology, likely followed by prominent U waves.

On closer inspection the gastric port of the patient's feeding tube was noted to be draining by gravity into a Foley collection bag. The staff at the nursing facility reported that the patient's gastric fluid was allowed to drain to gravity into a Foley bag for unclear reasons, yielding approximately 200 milliliters per day that was then discarded for an unclear number of weeks. The gastric port was disconnected from the collection bag and sealed. The patient was administered intravenous (IV) normal saline and electrolyte infusions.

The patient was admitted to the intensive care unit and maintained on continuous cardiac telemetry for high risk of ventricular dysrhythmias. His electrolyte derangements began to improve, and his QT interval normalized to approximately 450 ms within 24 hours, as shown in Image 2. He did not experience any significant dysrhythmias, but he did have one uncomplicated breakthrough seizure. By hospital day 2, physicians noticed intermittent dysfunction

Table. Initial lab values of patient in severe metabolic alkalosis.

Serum	Patient result	Reference range
Sodium (mEq/L)	120	136–145
Chloride (mEq/L)	50	98–106
Potassium (mEq/L)	2.0	3.5–5.0
Bicarbonate (45 mmol/L)	>45 ^a	20–29
Blood urea nitrogen (mg/dL)	30	8–20
Creatinine (mg/dL)	0.54 ^b	0.7–1.3 (male)
Calcium (mg/dL)	4.2	8.6–10.2
Magnesium (mEq/L)	2.2	1.6–2.6

^aBicarbonate level was above the lab's measurable range.

^bPatient's prior baseline creatinine noted to be 0.25 mg/dL. mEq/L, milliequivalents per liter; mmol/L, millimoles per liter; mg/dL, milligrams per deciliter.

Population Health Research Capsule

What do we already know about this clinical entity?

Metabolic alkalosis is frequently encountered in the emergency department. The management of severe alkalosis is well documented in the literature.

What makes this presentation of disease reportable?

Severe metabolic alkalosis is less commonly encountered by emergency physicians. We describe the first reported case due to inappropriate gastrostomy tube losses.

What is the major learning point?

This case highlights the presentation and recognition of severe metabolic alkalosis and underlying pathophysiology and describes management strategies.

How might this improve emergency medicine practice?

Severe metabolic alkalosis carries a high mortality. By highlighting its recognition and management, we could improve the resuscitation of these patients.

and clogging of the jejunostomy lumen of his gastrojejunostomy tube, requiring replacement by interventional radiology. Physicians surmised that feeding tube dysfunction and inability to tolerate gastric secretions likely led to symptoms that, unfortunately, inspired nursing facility staff to vent his gastric port to gravity, and the underlying cause was not addressed until hospital admission. His encephalopathy, alkalosis, hypokalemia, and other electrolyte derangements had resolved by discharge on hospital day 7.

DISCUSSION

This case illustrates a critically ill patient with complex metabolic derangements. The patient had ongoing gastric secretion losses over a period of weeks, resulting in a slow but steady loss of volume, as well as loss of hydrogen, chloride, sodium, and potassium ions.⁷ The initial insult was maintained not only by continuous losses in the patient over time but by hypovolemia and the increasing activity of aldosterone. This resulted in further loss of potassium and impaired the kidney's ability to excrete bicarbonate.⁶

For a patient with severe metabolic alkalosis and bradycardia, the most imminently life-threatening

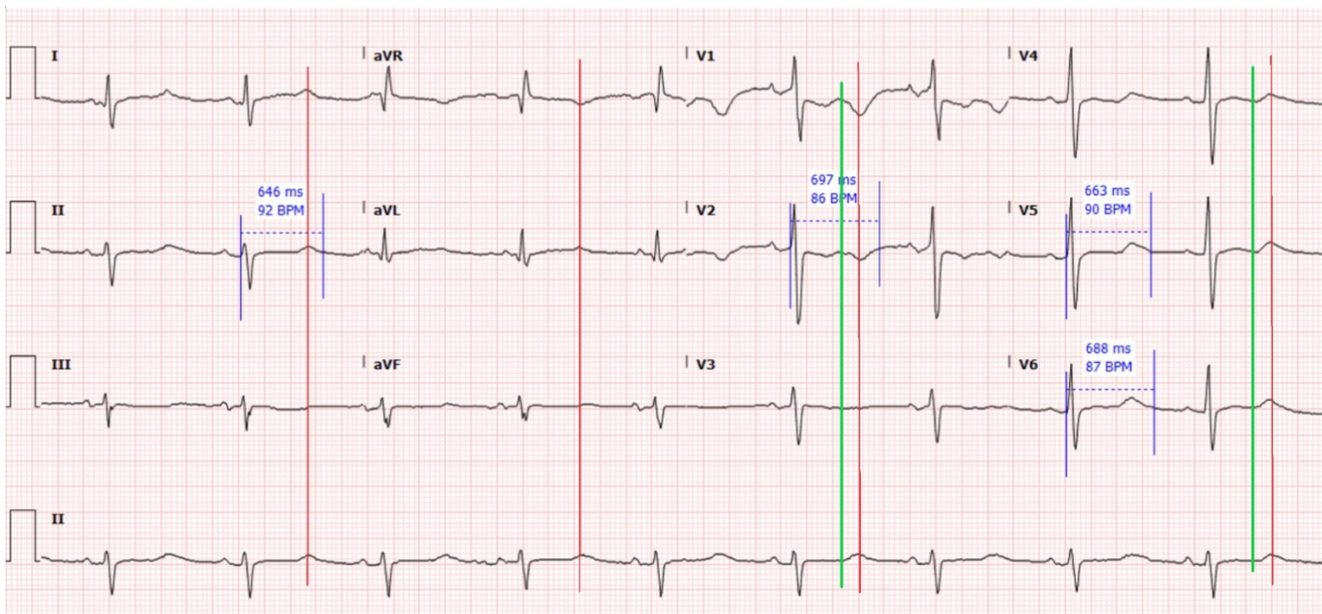


Image 1. The patient’s electrocardiogram on arrival to the emergency department, with additional annotations showing sinus rhythm without obvious ischemia and extremely prolonged QT or QU interval. Several example measurements for the QU interval are shown in blue. In the precordial leads, green vertical lines mark the approximate position of the T wave, which appears flat in many leads. Red lines mark the position of the terminal component of repolarization, which are best described as U waves. *ms*, milliseconds; *BPM*, beats per minute.

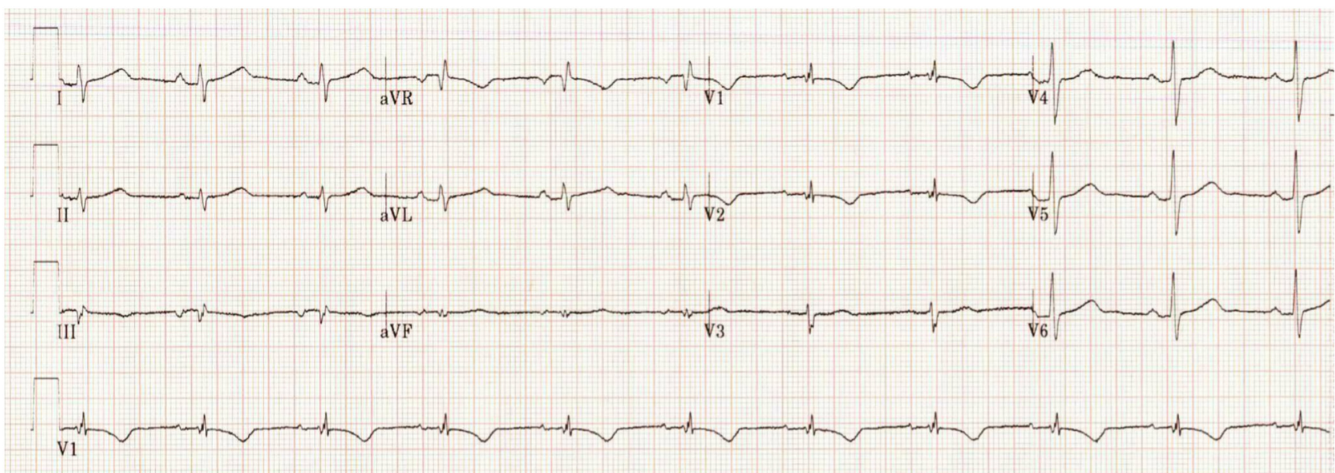


Image 2. The patient’s electrocardiogram following repletion of electrolytes demonstrating improvement in QT interval.

complication is ventricular dysrhythmias including ventricular fibrillation and polymorphic ventricular tachycardia. Prolonged QT interval is considered a risk factor for torsades de pointes (TdP), which is a form of polymorphic ventricular tachycardia preceded by long QT interval. A QT interval (or corrected QT interval when the heart rate is greater than 60 BPM) greater than 485–500 ms by the Bazett formula is considered a risk factor for the development of TdP. While the patient in this case did have a profoundly prolonged QT interval, he did not suffer any acute dysrhythmias.

Most cases of metabolic alkalosis can be adequately treated with correction of the precipitating cause and simple repletion of volume and electrolytes. In more severe or complicated cases, additional treatments with the goal of directly improving the alkalosis may be indicated. Acetazolamide inhibits carbonic anhydrase, preventing conversion of hydrogen and bicarbonate ions to carbon dioxide and water, resulting in renal loss of sodium and bicarbonate, resulting in diminution of the alkalosis. Intravenous (IV) administration of acetazolamide 500 milligrams (mg) every 12 hours has shown a small but

statistically significant effect in reducing bicarbonate levels and is equivalent to more frequent dosing schedules.⁸ In patients with gastric acid loss as the cause of the alkalosis, histamine-2 receptor antagonists or proton pump inhibitors have been used as an adjunctive therapy while addressing the underlying cause.⁹ In renally impaired patients, dialysis by various methods can be used to directly lower serum bicarbonate quickly and effectively using either normal or low-bicarbonate dialysate.^{10,11}

Intravenous acid solutions, most commonly hydrochloric acid, have also been used in the management of metabolic alkalosis. It is indicated when metabolic alkalosis is not correcting or not anticipated to correct with less aggressive management. Multiple case reports and case series demonstrate the safety of hydrochloric acid infusions.^{12–14} Two case reports cite chest wall necrosis resulting from hydrochloric acid infusions, highlighting the importance of administering infusions via central lines confirmed to be in good position and via the most distal port.^{15,16} Hydrochloric acid infusion dosing can be estimated by calculating the amount of hydrogen ion required via calculating the bicarbonate excess.

Bicarbonate excess can be roughly calculated by multiplying the desired decrease in plasma bicarbonate (in milliequivalents per liter [mEq/L]) by the total body water content in liters, which is roughly 60% of lean body mass in kilograms (kg) for males and 50% of lean body mass in females.¹⁷ Hydrochloric acid solutions with concentrations of 0.1 to 0.2 mmol/kg/hour—otherwise known as 0.1 to 0.2 normal (N) solutions—are safe formulations, with higher concentrations associated with worsened renal outcomes. A liter of 0.1 N hydrochloric acid contains 100 mEq each of hydrogen and chloride ions. Suggested maximum infusion rates include 125 mL/hour or 0.2 mEq/kg/hour. Infusions can be repeated, guided by serial electrolyte testing, and IV tubing should be changed every 12 hours due to theoretical concerns about breakdown of plastic.

Alternatives to hydrochloric acid infusions include ammonium chloride and arginine monohydrochloride, although these are both dependent on hepatic metabolism.¹⁸ Finally, controlled hypoventilation has been proposed as an option for critically ill intubated patients with severe alkalosis. While no data exists to suggest specific targets of minute ventilation or pCO₂ in severe metabolic alkalosis, a few case reports mention using controlled hypoventilation to exaggerate the physiologic respiratory compensation of alkalemia in mechanically ventilated patients.¹⁴

Although loss of gastrointestinal secretions is one of the most common causes of metabolic alkalosis, prior case reports of severe metabolic alkalosis caused by mistakenly intentional prolonged gastrostomy tube drainage are not in the literature. Drainage or venting of a gastrostomy tube can be a temporary therapy to treat symptoms such as

fullness or bloating or in cases of obstruction¹⁹; however, prolonged drainage of gastrointestinal secretions without addressing the underlying problem can be detrimental to the patient.

CONCLUSION

This case, which highlights fundamental understanding of gastrointestinal and acid-base physiology, demonstrates the dangers of ongoing loss of gastric secretions and metabolic alkalosis. It serves as an example of identifying the underlying cause of alkalosis and subsequent treatment options.

The authors attest that their institution requires neither Institutional Review Board approval, nor patient consent for publication of this case report. Documentation on file.

Address for Correspondence: Forrest Turner, MD, Carolinas Medical Center, Department of Emergency Medicine, 1000 Blythe Blvd., Charlotte, NC 28203. Email: forrestturnermd@gmail.com

Conflicts of Interest: By the CPC-EM article submission agreement, all authors are required to disclose all affiliations, funding sources and financial or management relationships that could be perceived as potential sources of bias. The authors disclosed none.

Copyright: © 2024 Turner et al. This is an open access article distributed in accordance with the terms of the Creative Commons Attribution (CC BY 4.0) License. See: <http://creativecommons.org/licenses/by/4.0/>

REFERENCES

1. Soifer JT and Kim HT. Approach to metabolic alkalosis. *Emerg Med Clin North Am.* 2014;32(2):453–63.
2. Patel KB, Espinosa J, Wiley J, et al. Severe alkalemia (pH 7.85): compatible with life? A triple acid-base conundrum. *Mathews J Case Rep.* 2016;1(2):10.
3. Mennen M and Slovid CM. Severe metabolic alkalosis in the emergency department. *Ann Emerg Med.* 1988;17(4):354–7.
4. Tripathy S. Extreme metabolic alkalosis in intensive care. *Indian J Crit Care Med.* 2009;13(4):217–20.
5. Anderson LE and Henrich WL. Alkalemia-associated morbidity and mortality in medical and surgical patients. *South Med J.* 1987;80(6):729–33.
6. DuBose T Jr. Acidosis and alkalosis. In: *Harrison's Principles of Internal Medicine*, 20th ed. New York, NY: McGraw Hill; 2018.
7. Lyu HG and Smink D. Stomach & duodenum. In: *Current Diagnosis & Treatment: Surgery*, 15th ed. New York, NY: McGraw Hill; 2020.
8. Faisy C, Meziani F, Planquette B, et al. Effect of acetazolamide vs placebo on duration of invasive mechanical ventilation among patients with chronic obstructive pulmonary disease: a randomized clinical trial. *JAMA.* 2016;315(5):480–8.

9. Kirsch BM, Sunder-Plassmann G, Schwarz C. Metabolic alkalosis in a hemodialysis patient-successful treatment with a proton pump inhibitor. *Clin Nephrol.* 2006;66(5):391–4.
10. Hsu SC, Wang MC, Liu HL, et al. Extreme metabolic alkalosis treated with normal bicarbonate hemodialysis. *Am J Kidney Dis.* 2001;37(4):E31.
11. Ayus JC, Olivero JJ, Adrogé HJ. Alkalemia associated with renal failure. Correction by hemodialysis with low-bicarbonate dialysate. *Arch Intern Med.* 1980;140(4):513–5.
12. Brimiouille S, Vincent JL, Dufaye P, et al. Hydrochloric acid infusion for treatment of metabolic alkalosis: effects on acid-base balance and oxygenation. *Crit Care Med.* 1985;13(9):738–42.
13. Guffey JD, Haas CE, Crowley A, et al. Hydrochloric acid infusion for the treatment of metabolic alkalosis in surgical intensive care unit patients. *Ann Pharmacother.* 2018;52(6):522–6.
14. Jones MW and Williams M. Acid-base correction: a case report and review of the literature. *J Intensive Care Soc.* 2010;11(2):126–9.
15. Jankauskas SJ, Gursel E, Antonenko DR. Chest wall necrosis secondary to hydrochloric acid use in the treatment of metabolic alkalosis. *Crit Care Med.* 1989;17(9):963–4.
16. Buchanan IB, Campbell BT, Peck MD, et al. Chest wall necrosis and death secondary to hydrochloric acid infusion for metabolic alkalosis. *South Med J.* 2005;98(8):822–4.
17. Mehta A and Emmett M. Treatment of metabolic alkalosis. In: *UpToDate.* Alphen aan den Rijn, Netherlands; Wolters Kluwer: 2022. Available at: https://www.uptodate.com/contents/treatment-of-metabolic-alkalosis?search=metabolic+alkalosis&source=search_result&selectedTitle=2~150&usage_type=default&display_rank=2. Accessed June 15, 2023.
18. Martin WJ and Matzke GR. Treating severe metabolic alkalosis. *Clin Pharm.* 1982;1(1):42–8.
19. Gleeson NC, Hoffman MS, Fiorica JV, et al. Gastrostomy tubes after gynecologic oncologic surgery. *Gynecol Oncol.* 1994;54(1):19–22.

Ruptured Ovarian Artery Aneurysm in a Postmenopausal Female: Case Report

Raj Patel, DO
Amy Russell, MD
Melanie M. Randall, MD

Riverside University Health System, Department of Emergency Medicine,
Moreno Valley, California

Section Editor: Austin Smith, MD

Submission history: Submitted August 28, 2023; Revision received October 27, 2023; Accepted November 2, 2023

Electronically published March 25, 2024

Full text available through open access at http://escholarship.org/uc/uciem_cpccem

DOI: [10.5811/cpcem.1643](https://doi.org/10.5811/cpcem.1643)

Introduction: Ovarian artery aneurysm is a rare diagnosis, primarily associated with late pregnancy and the postpartum period. It can cause life-threatening hemorrhage when ruptured. Even more rare are ovarian artery aneurysms in postmenopausal women.

Case Report: We present a case of a postmenopausal female presenting to the emergency department with flank pain. Point-of-care ultrasound showed free fluid in the abdomen. She was diagnosed with an ovarian artery aneurysm on computed tomography angiography and treated successfully with embolization.

Conclusion: Ruptured ovarian artery aneurysm is an uncommon cause of intra-abdominal hemorrhage in women. [Clin Pract Cases Emerg Med. 2024;8(2)143–146.]

Keywords: *intra-abdominal hemorrhage; ovarian artery; aneurysm; case report.*

INTRODUCTION

Ovarian artery aneurysms (OAA) and pseudoaneurysms are primarily diagnosed during the late pregnancy and early postpartum periods. Hemodynamic and endocrine changes during pregnancy can lead to aneurysm formation.¹ Other less common risk factors include trauma and chronic inflammatory conditions. The most common presenting symptom is significant abdominal and flank pain. Rupture of the aneurysm results in intraperitoneal and/or retroperitoneal hemorrhage often requiring emergent intervention. Incidence of this diagnosis is low.² We present an uncommon case of a postmenopausal female found to have a ruptured left OAA.

CASE REPORT

A 51-year-old, postmenopausal, gravida three, para three female presented to our emergency department (ED) with worsening left flank pain and new left-sided abdominal pain. She had been discharged from our hospital two days prior. During that admission, she underwent a left renal biopsy that was complicated by a perirenal and intraabdominal

hematoma. Her medical history included systemic lupus erythematosus, chronic kidney disease, antiphospholipid syndrome, and hypertension. Her gynecologic history was significant for a prior cesarean section and a tubal ligation. She was on warfarin due to her hypercoagulable state.

Upon presentation to the ED, her vital signs were temperature 36.6° Celsius, heart rate 69 beats per minute, blood pressure 116/75 millimeters (mm) of mercury, respiratory rate 16 per minute, and oxygen level 96% on room air. Physical exam revealed a tired-looking female in mild distress. She exhibited left flank tenderness near her renal biopsy site with no external signs of bleeding or infection. Additionally, she had abdominal tenderness in the left upper quadrant (LUQ). There was no abdominal rigidity or signs of peritonitis. A point-of-care ultrasound was positive for free fluid in the LUQ ([Image 1](#)).

Her laboratory values were hemoglobin 6.6 grams per deciliter (g/dL) (reference range 12.1–15.1 g/dL), platelet count 374×10^9 per liter ($\times 10^9/L$) ($150\text{--}450 \times 10^9/L$), blood urea nitrogen 63 milligrams per dL (mg/dL) ($7\text{--}30$ mg/dL), creatinine 3.7 mg/dL ($0.7\text{--}1.2$ mg/dL), prothrombin time

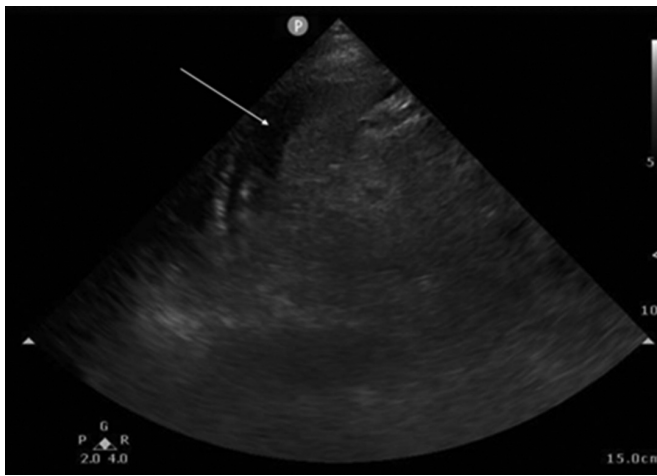


Image 1. Point-of-care ultrasound showing free fluid in the left upper quadrant abdomen between the spleen and kidney (arrow).

15.8 seconds (10–13 seconds), and international normalized ratio 1.3 (0.89–1.16). The patient’s hemoglobin level three days prior was 9 g/dL.

Interventional radiology (IR) was consulted due to the patient’s recent complicated biopsy, new laboratory derangements, and free fluid on ultrasound. Computed tomography (CT) angiography was recommended to assess for bleeding location and rule out abscess, perforation, or ischemia. Computed tomography of the abdomen and pelvis revealed a new 10 mm enhancement within the intra-abdominal hemorrhage. This abnormality was identified as a ruptured, bleeding distal OAA (*Image 2*). The patient was given one unit of packed red blood cells and taken to IR for definitive management. She underwent gelfoam and coil embolization of the left gonadal artery, resulting in cessation of bleeding (*Image 3*). After an uncomplicated hospital course, she was discharged.

DISCUSSION

Ovarian artery aneurysm rupture is a rare but life-threatening diagnosis. The clinical presentation is

non-specific but can include flank pain, abdominal pain, and hemodynamic instability. Imaging will show intraperitoneal and/or retroperitoneal fluid. Point-of-care ultrasound may assist in diagnosis if adequate intraperitoneal fluid volume is present. Definitive diagnosis requires CT angiography, traditional angiography, or direct operative visualization. Management requires IR embolization in a hemodynamically stable patient or laparotomy with ligation in an unstable patient.^{2,3}

Although symptomatology and physical examination are non-specific, medical history may be helpful in the

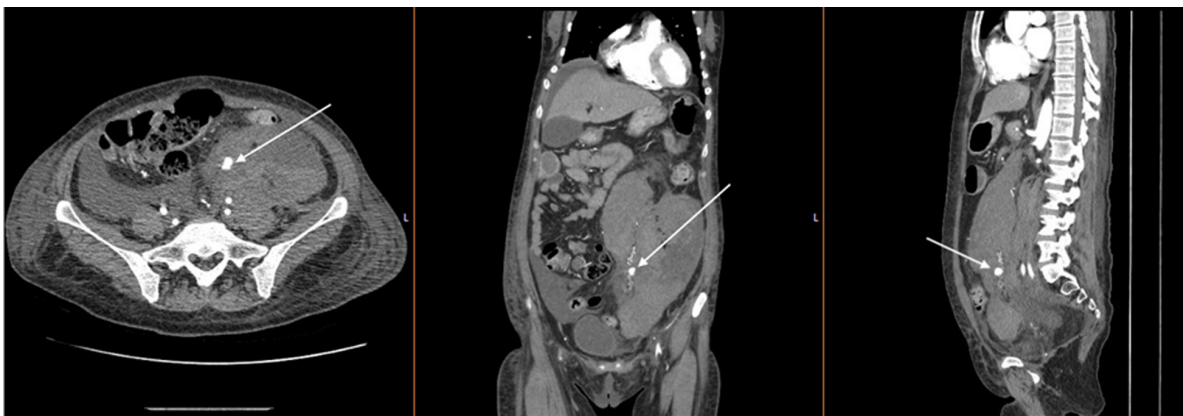


Image 2. Computed tomography angiography demonstrating extravasation from left ovarian artery aneurysm (arrows).

CPC-EM Capsule

What do we already know about this clinical entity?

Ovarian artery aneurysms are rare and most often related to pregnancy. Rupture can lead to life-threatening hemorrhage.

What makes this presentation of disease reportable?

Few ovarian artery aneurysms have been described in postmenopausal women or presenting to the emergency department.

What is the major learning point?

Ovarian artery aneurysm is a rare but serious diagnosis that can present with significant intra-abdominal hemorrhage.

How might this improve emergency medicine practice?

This case adds to the existing differential diagnoses for intra-abdominal hemorrhage of unknown origin.

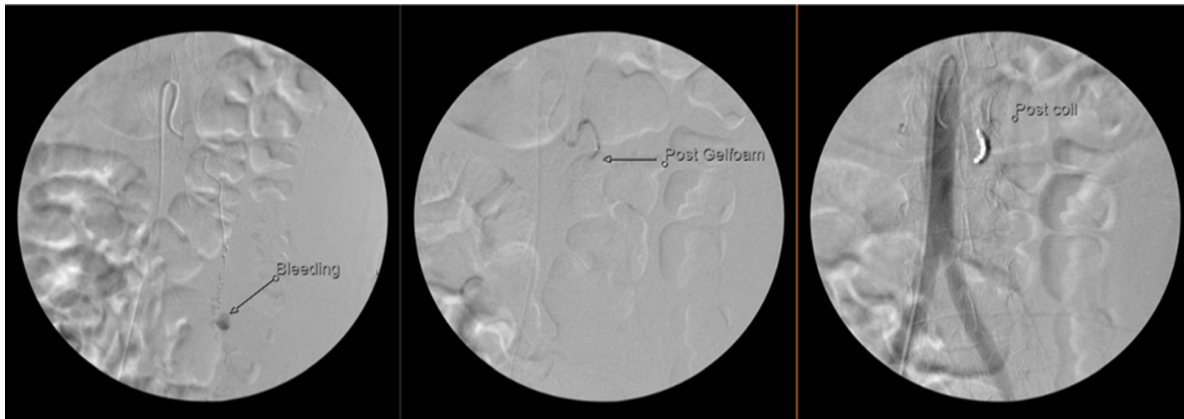


Image 3. Angiography illustrating from left to right the ovarian artery aneurysm with active bleeding; after gelfoam embolization; and after coiling.

consideration of the diagnosis and the choice of imaging. While most commonly associated with pregnancy, OAA has also been described in patients with fibroids, chronic hypertension, trauma, vasculopathy, and in the postoperative phase.^{2–11} Increased plasma volume, increased cardiac output, and hormonal changes during pregnancy have been proposed as factors predisposing patients to OAA. Most documented cases occurred in multiparous women, suggesting that repeat pregnancy may be a risk factor due to the compounding effect of these physiologic changes.^{2,4}

Finally, there are independent cases of OAA patients with chronic inflammatory conditions including chronic lymphocytic leukemia, rheumatoid arthritis, HIV, and lupus.^{6,7,9} The exact influence of chronic inflammation on aneurysm formation or growth is unclear.

CONCLUSION

Ovarian artery aneurysm is a rare and serious disease most commonly associated with pregnancy. We present a rare presentation in a postmenopausal female in the ED. Due to its emergent nature, OAA can be considered in the differential diagnosis of a female patient presenting with nontraumatic abdominal or flank pain with certain appropriate risk factors.

The authors attest that their institution requires neither Institutional Review Board approval, nor patient consent for publication of this case report. Documentation on file.

Address for Correspondence: Melanie Randall, MD, Riverside University Health System, Department of Emergency Medicine, 26520 Cactus Avenue, Moreno Valley, CA 92555.
Email: m.randall@ruhealth.org

Conflicts of Interest: By the CPC-EM article submission agreement, all authors are required to disclose all affiliations, funding sources and financial or management relationships that could be perceived

as potential sources of bias. Melanie Randall receives a monthly administrative stipend from Vuity Emergency Physicians Partnership as the Research Director for the Riverside University Health System emergency department.

Copyright: © 2024 Patel et al. This is an open access article distributed in accordance with the terms of the Creative Commons Attribution (CC BY 4.0) License. See: <http://creativecommons.org/licenses/by/4.0/>

REFERENCES

1. Enakpene CA, Stern T, Barzallo Salazar MJ, et al. Spontaneous rupture of an ovarian artery aneurysm: a rare postpartum complication. *Case Rep Obstet Gynecol.* 2016;2016:1029561.
2. Wada K, Aoyagi S, Matsuura Y, et al. Pregnancy-unrelated spontaneous rupture of a right ovarian artery aneurysm. *Radiol Case Rep.* 2021;16(11):3270–4.
3. Almuhanna AF, Alkhalifa MA, Altaweel FY, et al. Traumatic ovarian artery pseudoaneurysm post-ovum pickup: a rare complication. *Cureus.* 2021;13(12):e20825.
4. Hu YH, Ouh YT, Kim C, et al. Spontaneous rupture of ovarian artery aneurysm in a postmenopausal woman: a case report and literature review. *J Menopausal Med.* 2021;27(2):102–5.
5. Chao LW and Chen CH. Spontaneous rupture of an ovarian artery aneurysm: case report and review of the literature. *Gynecol Obstet Invest.* 2009;68(2):104–7.
6. Zorrilla AM, Fein LA, James K, et al. Retroperitoneal hematoma secondary to spontaneous rupture of ovarian artery pseudoaneurysms: case report and review of literature. *J Obstet Gynaecol.* 2019;39(3):422–4.
7. Kirk JS, Deitch JS, Robinson HR, et al. Staged endovascular treatment of bilateral ruptured and intact ovarian artery aneurysms in a postmenopausal woman. *J Vasc Surg.* 2009;49(1):208–10.
8. Nakajo M, Ohkubo K, Fukukura Y, et al. Embolization of spontaneous rupture of an aneurysm of the ovarian artery supplying the uterus with fibroids. *Acta Radiol.* 2005;46(8):887–90.

9. Herskowitz MM, Wong CM, Leonardo RF. Ruptured ovarian artery pseudoaneurysm in a postmenopausal patient treated with transcatheter embolization. *Case Rep Radiol.* 2020;2020:6728318.
10. Erdoes LS and Entzian D. Ruptured traumatic ovarian artery pseudoaneurysm in a pregnant patient. *J Vasc Surg Cases.* 2015;1(1):36–8.
11. Tao Y, Matsubara S, Yagi K, et al. Intra-abdominal hemorrhage due to segmental arterial mediolysis of an ovarian artery pseudoaneurysm and concomitant aneurysmal subarachnoid hemorrhage: illustrative case. *J Neurosurg Case Lessons.* 2022;4(5):CASE22233.

Severely Painful and Pruritic Forearm Rash: A Case of Caterpillar Envenomation in South Florida

Cody M. Autrey, BS*
Stephanie A. Martinez, MPH*
Michael Remaly, DO[†]
Eric Boccio, MD, MPH[†]

*Florida International University, Herbert Wertheim College of Medicine, Miami, Florida

[†]Memorial Healthcare System, Department of Emergency Medicine, Hollywood, Florida

Section Editor: Shadi Lahham, MD

Submission history: Submitted September 20, 2023; Revision received November 22, 2023; Accepted December 1, 2023

Electronically published March 26, 2024

Full text available through open access at http://escholarship.org/uc/uciem_cpce

DOI: 10.5811/cpcem.1697

Introduction: The asp caterpillar (*Megalopyge opercularis*) is endemic to the southeastern United States, with most sightings in Florida, Texas, and Louisiana. A few hundred caterpillar envenomations are reported annually with most cases occurring in July–November. Asp caterpillars have hollow spines along their backs that contain venom. Contact with these spines is what produces the characteristic “sting” resulting in contact dermatitis and a localized hypersensitivity reaction collectively referred to as lepidopterism. Symptoms of lepidopterism may include severe burning pain, pruritis, edema, nausea, vomiting, abdominal pain, and headache. Symptoms are often self limited, and treatment should focus on expedited removal of implanted spines and aggressive symptom management.

Case Report: We present the case of a patient presenting to the emergency department (ED) with acute-onset severe left forearm pain with associated pruritic rash incurred while working in a retail store. Initial therapeutic management included administration of analgesics, antihistamines, and steroids. After obtaining a comprehensive history and consulting with the Poison Control Center, we suspected an asp caterpillar envenomation. Following extraction of the caterpillar spines with silk tape, the patient’s symptoms improved. After a period of observation in the ED, the patient was discharged home without any known sequelae.

Conclusion: Although asp caterpillars typically inhabit trees and foliage, human exposure to the caterpillar may occur in developed environments. Effective history-taking, prompt communication with toxicologic experts, and complete removal of intact spines are essential for early identification and effective clinical management of asp caterpillar envenomation. [Clin Pract Cases Emerg Med. 2024;8(2)147–150.]

Keywords: *Megalopyge opercularis*; asp caterpillar; caterpillar envenomation; lepidopterism; case report.

INTRODUCTION

The asp caterpillar (*Megalopyge opercularis*), also known as the woolly slug caterpillar or puss caterpillar, is the larva form of the southern flannel moth. It has a wide geographic distribution stretching from Maryland to Mexico and is endemic to the southeastern United States with most sightings in Florida, Texas, and Louisiana.¹ Peak months of

asp caterpillar reports occur between July–November.² The asp caterpillar is typically 2.5–4 centimeters (cm) in length, and its hairs range in color from gray to yellow-brown giving it its characteristic woolly appearance. Within the dense hair coat are hidden spines called setae, which are hollow and contain a poison gland. Contact may cause the setae to fracture and inject venom, resulting in both toxic effects and

type IV hypersensitivity/immunoglobulin E-mediated reactions. The asp caterpillar sting is reported to be the most potent of all caterpillar stings in the United States.³

While most caterpillar envenomations are benign and do not necessitate medical evaluation, various clinical sequelae have been described. The asp caterpillar sting causes a characteristic grid-like, hemorrhagic eruption, and the rash is associated with excruciating pain and irritation, puncture wounds, pruritis, and edema.⁴ Sting reactions include erucism (localized urticarial dermatitis), lepidopterism (skin and systemic reactions), ophthalmia nodosa (ocular inflammatory reaction), and lonomism (a potentially life-threatening bleeding diathesis).⁵ Systemic toxicity may manifest as lymphadenopathy, headache, nausea, vomiting, abdominal pain, and pseudoappendicitis.⁶⁻⁸ The reaction is often self-limiting; management should focus on expeditious removal of any remaining implanted setae and aggressive symptom management. Albeit rare, there have been several reports of anaphylactic shock resulting from caterpillar envenomation.⁹

We report an unusual cause of acute, sudden onset, severe left forearm pain and pruritis in an adult male who was at work in a retail store in South Florida. Although these caterpillars typically inhabit trees and foliage, this case highlights that human exposure to asp caterpillars may occur in developed environments. Effective history-taking, heightened clinical suspicion, prompt communication with toxicologic experts, and complete removal of intact spines are essential for early identification and effective clinical management of asp caterpillar envenomation.

CASE REPORT

A 20-year-old male with no known past medical history or allergies presented to the emergency department (ED) complaining of acute, sudden onset, left forearm pain and rash. The patient was working at an eyeglasses and contacts store and stated that the pain started when he knelt to lift something up from ground level. In doing so, he placed his left elbow on his left thigh. He immediately felt a stinging sensation in his left elbow with severe 10/10 pain radiating down the extremity to the left forearm and hand. Shortly afterward he noticed the affected area had become erythematous, thus he presented to the ED for an emergent medical evaluation. Pertinent negatives included absence of fever, chills, cough, shortness of breath, chest pain, nausea, vomiting, diarrhea, urinary complaints, back pain, and headache.

The patient arrived hypertensive with initial blood pressure measuring 130/91 millimeters of mercury. Triage vital signs were otherwise normal. On physical examination, the patient appeared anxious. The primary survey of airway, breathing, and circulation was unremarkable. Focused examination of the affected region demonstrated an approximately 1 × 2-cm area of erythema and edema over

Population Health Research Capsule

What do we already know about this clinical entity?

Asp caterpillar (Megalopyge opercularis) envenomation is an unusual cause of a severely painful rash affecting patients in the southeastern United States.

What makes this presentation of disease reportable?

While exposure risks are greatest outdoors near trees and foliage, caterpillar stings may also occur in commercial buildings and residential settings.

What is the major learning point?

Comprehensive history-taking, heightened clinical suspicion, interdisciplinary collaboration, and effective therapeutic management are necessary to treat envenomation.

How might this improve emergency medicine practice?

Awareness of exposure risks and symptoms of erucism and recognition of the characteristic erythematous rash will facilitate timely diagnosis and proper treatment.

the proximal posterior forearm with an associated grid-like pattern of raised urticaria. The rash was localized and did not exhibit desquamation ([Image 1](#)).

The left upper extremity was otherwise neurovascularly intact with a palpable radial pulse and capillary refill less than three seconds. Assessment of motor function and active and passive range of motion at the elbow was normal. Laboratory assessment and imaging were determined to be of no utility and were not ordered. Upon further inquiry, the patient mentioned that his arm may have contacted a caterpillar, which was found on the ground at the site where his pain first began. A photo of the caterpillar was eventually obtained and provided on the patient's smartphone ([Image 2](#)).

The emergency physician called the Poison Control Center (PCC) hotline, which confirmed that the symptoms were likely the result of an asp caterpillar envenomation. Of note, the expert at the PCC mentioned that the presentation was particularly unusual given that it occurred in a commercial building devoid of trees and foliage. Other diagnoses considered were allergic reaction, insect bite/sting, contact dermatitis, cellulitis, and traumatic injury.

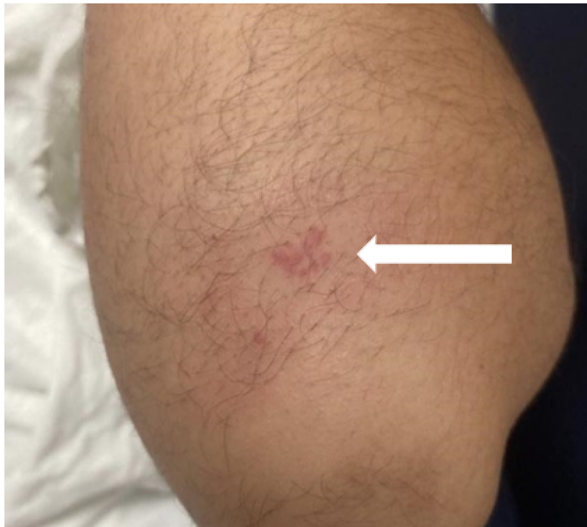


Image 1. Erythematous spots appearing at the site of asp caterpillar envenomation on the posterior proximal forearm (arrow).

Therapeutic management focused on aggressive symptom management. Due to concern for a developing hypersensitivity reaction, dexamethasone 8 milligrams (mg) intravenous (IV), acetaminophen-codeine 300-30 mg per os (PO), famotidine 20 mg IV, ketorolac 30 mg IV, and diphenhydramine 25 mg IV were administered. Upon further inspection of the affected area, several spines were visualized penetrating the patient's skin. Silk tape was applied to the affected area and carefully removed, thus stripping away the



Image 2. Photo from smartphone of an asp caterpillar (*Megalopyge opercularis*) on the carpeted floor of an eyeglass and contact lens store.

offending spines. The patient's pain rapidly improved. The patient received an additional 25 micrograms of fentanyl IV after reassessment an hour later. He underwent a period of observation in the ED and was discharged with prescriptions for methylprednisolone 4 mg PO and oxycodone-acetaminophen 5-325 mg PO. Attempts to contact him after discharge to arrange follow-up and a wound check were unsuccessful. There were no subsequent patient encounters documented in the electronic health record.

DISCUSSION

We describe a case report of a 20-year-old male with no known past medical history or allergies who presented to the ED with severe localized pain, erythema, and swelling of the left forearm. A focused assessment revealed an erythematous, swollen, and tender area containing several raised erythematous lesions in a grid-like pattern. Upon closer inspection, several spines were visualized remaining in the skin. Effective history-taking, recognition of the characteristic rash, timely involvement of an interdisciplinary team that included toxicologic experts at the PCC and species identification using available technologies facilitated timely diagnosis and appropriate clinical management.

Typically, asp caterpillar stings occur in outdoor settings when an individual unknowingly brushes against the caterpillar or the caterpillar falls from a tree where it normally resides. This case challenges the conventional exposure risks to asp caterpillars, describing an encounter that occurred indoors in an area devoid of any surrounding trees or foliage. It is possible that the caterpillar was carried into the store while attached to the patient's clothing, within infested goods, or on a delivery package. The absence of detailed entomological investigations limited our ability to definitively ascertain how the asp caterpillar may have entered the store.

Interdisciplinary team collaboration played an essential role in this case. Effective communication between healthcare professionals and local toxicologic experts at the PCC was instrumental in establishing the diagnosis and guiding therapeutic management. The content knowledge regarding regional insect patterns and venomous species possessed by toxicologic experts aided in species identification and reliable prognostication.

Due to the paucity of reports in the literature and presumed underreporting in the clinical environment, the prevalence of atypical and severe presentations of asp caterpillar envenomation is unknown. The therapeutic management of asp caterpillar envenomation is variable. Usually benign and self-limiting, management should focus on removing the offending agent and symptom management. Administration of analgesics can be supplemented with topical and injected local anesthetics.^{10,11} An analysis of asp caterpillar stings reported to Texas Poison Centers found

that numerous treatments such as dilution, irrigation and washing, antihistamines, steroids, and antibiotics have been effectively used.⁴ While analgesics, antihistamines, and steroids are the staples of caterpillar envenomation, no consensus guidelines exist for its management in the ED setting.

CONCLUSION

Although asp caterpillars typically inhabit trees and foliage, human exposure may occur in developed environments. Caterpillar envenomation is most likely underreported and mistreated due to the lack of patient and clinician knowledge, lack of detail in the history of present illness, and common mimics of erucism. Effective history-taking, heightened clinical suspicion, prompt communication with toxicologic experts, and complete removal of intact spines are essential for early identification and effective clinical management of asp caterpillar envenomation. The relatively high prevalence of asp caterpillar envenomation justifies future study of its venom, development of a potential antivenom, and guidelines for clinical management.

Patient consent has been obtained and filed for the publication of this case report.

Address for Correspondence: Eric Boccio, MD, MPH, Memorial Healthcare System, Department of Emergency Medicine, 3501 Johnson Street, Hollywood, FL 33021. Email: eboccio@mhs.net

Conflicts of Interest: By the CPC-EM article submission agreement, all authors are required to disclose all affiliations, funding sources and financial or management relationships that could be perceived as potential sources of bias. The authors disclosed none.

Copyright: © 2024 Autrey et al. This is an open access article distributed in accordance with the terms of the Creative Commons Attribution (CC BY 4.0) License. See: <http://creativecommons.org/licenses/by/4.0/>

REFERENCES

1. Eagleman DM. Envenomation by the asp caterpillar (*Megalopyge opercularis*). *Clin Toxicol (Phila)*. 2008;46(3):201–5.
2. Goldman BS and Bragg BN. Caterpillar and moth bites. In: *StatPearls* [Internet]. 2023. Available at: <https://www.ncbi.nlm.nih.gov/books/NBK539851/?report=reader>. Accessed November 9, 2023.
3. McGovern JP, Barkin GD, McElhenney TR, et al. *Megalopyge opercularis*: observations of its life history, natural history of its sting in man, and report of an epidemic. *JAMA*. 1961;175(13):1155–8.
4. Forrester MB. *Megalopyge opercularis* caterpillar stings reported to Texas poison centers. *Wilderness Environ Med*. 2018;29(2):215–20.
5. Hossler EW. Caterpillars and moths. *Dermatol Ther*. 2009;22(4):353–66.
6. Koehler AW and Zaveri KG. Lepidopterism caused by the puss caterpillar. *J Am Assoc Nurse Pract*. 2021;34(1):169–71.
7. Konstat-Korzenny E, Yudovich A, Morgenstern-Kaplan D. Lepidopterism: case report and review of the literature. *Cureus*. 2020;12(1):e6567.
8. Greene SC and Carey JM. Puss caterpillar envenomation: erucism mimicking appendicitis in a young child. *Pediatr Emerg Care*. 2020;36(12):e732–4.
9. Morales-Cabeza C, Prieto-García A, Acero S, et al. Systemic mastocytosis presenting as occupational IgE-mediated anaphylaxis to pine processionary caterpillar. *Ann Allergy Asthma Immunol*. 2016;117(3):333–4.e1.
10. Branco MMP, Borrasca-Fernandes CF, Prado CC, et al. Management of severe pain after dermal contact with caterpillars (erucism): a prospective case series. *Clin Toxicol (Phila)*. 2019;57(5):338–42.
11. Torrents R, Simon N, Schmitt C, et al. Envenomation by caterpillars of the genus *Megalopyge* in French Guiana with an atypical clinical presentation, based on three observations. *Clin Toxicol (Phila)*. 2015;53(8):844–5.

Silicone Embolism Syndrome Causing Altered Mental Status and Respiratory Failure After an Unlicensed Gluteal Silicone Injection: A Case Report

Christopher Lin, MD
Jeremiah Robison, DO

Saint Barnabas Hospital, Department of Emergency Medicine, Bronx, New York

Section Editor: Joel Moll, MD

Submission history: Submitted July 19, 2023; Revision received December 22, 2023; Accepted December 28, 2023

Electronically published March 26, 2024

Full text available through open access at http://escholarship.org/uc/uciem_cpchem

DOI: [10.5811/cpchem.1441](https://doi.org/10.5811/cpchem.1441)

Introduction: Unlicensed cosmetic procedures, which come at increased risk of infection and potential surgical complications, have introduced new challenges in healthcare. Physicians should be aware of presentations that may arise secondary to these procedures.

Case Report: We describe a case in which a previously healthy, 28-year-old female presented with new-onset seizures and acute respiratory distress syndrome (ARDS) in the setting of a recent cosmetic procedure with silicone injections to the gluteal region. The patient's hospital course was complicated by altered mental status, respiratory failure, rapid hemodynamic compromise, and eventual death.

Conclusion: In rare cases, one possible complication of cosmetic procedures is silicone embolism syndrome, which is characterized by pneumonitis, alveolar hemorrhage, and ARDS. The patient described in this report also experienced neurologic symptoms including seizure and altered mental status. This is a clinical diagnosis that relies upon thorough history-taking and detailed physical exam. Documentation on this phenomenon is limited, and medical management has not yet been standardized for this condition. Morbidity and mortality remain high. [Clin Pract Cases Emerg Med. 2024;8(2)151–154.]

Keywords: *case report; silicone embolization syndrome; ARDS; cosmetic surgery.*

INTRODUCTION

Unlicensed cosmetic procedures have resulted in complications including infection and cosmetic deformities. Treatment of these complications may require antibiotic therapy, hospital admission, and at times surgical intervention.^{1–3} Limited documentation in cases of unlicensed cosmetic surgery brings additional challenges to uncovering history and patient management.^{4–7} Silicone injections are not approved by the US Food and Drug Administration due to their association with infection, permanent disfigurement, embolism, and death. These restrictions have prompted individuals to seek certain cosmetic procedures by unlicensed practitioners within the United States or abroad. In these cases, practitioners may be unqualified for the cosmetic interventions performed. Additionally, the

cosmetic fillers used may be prone to impurities due to the absence of regulations.²

The increased prevalence of medical tourism for cosmetic procedures has contributed to complications secondary to unlicensed medical practice. Within the US, the majority of patients who undergo medical tourism are Hispanic females; travel destinations are primarily within Latin America, with the Dominican Republic the most frequented destination.¹ While data is limited, it is suspected that individuals pursue cosmetic options in foreign countries due to lower financial costs; one study found that the majority of patients affected are Medicaid recipients and of lower socioeconomic backgrounds.²

Liquid silicone (polydimethylsiloxane) is a commonly used substance for cosmetic injections, primarily as a soft tissue expander. In rare cases, silicone embolism syndrome

(SES), a complication associated with illicit cosmetic modifications involving silicone injections, can occur. This condition is associated with pneumonitis, alveolar hemorrhage, and acute respiratory distress syndrome (ARDS).⁴⁻⁷ Current literature suggests that the pulmonary findings are caused by a silicone embolism from direct intravenous injection. Alternatively, they may be caused after local tissue destruction. After reaching lung tissue, the silicone triggers a cascade of inflammatory responses including proteolysis and recruitment of neutrophils.⁴ The embolus itself can result in occlusion of microvasculature, further affecting pulmonary function. Pulmonary hemorrhage and edema can occur rapidly.

Symptoms have been reported as early as within 72 hours of cosmetic surgery. However, delayed presentations up to 18 years after initial surgery have been documented.^{4,8} Due to the limited number of case reports regarding this condition, the average time course from surgery to symptom onset is unclear. Presentations vary, although most reports indicate symptom onset within hours to days. Imaging reports are largely consistent between cases, with computed tomography (CT) revealing diffuse alveolar infiltrates or ground-glass opacities.⁴⁻⁸

CASE REPORT

An otherwise healthy, 28-year-old Hispanic female with no known past medical history was brought to the emergency department by emergency medical services. According to the history provided, the patient had been walking with a friend before experiencing sudden onset abdominal pain followed by seizure activity. After an episode of emesis and repeat seizure during initial triage evaluation, the patient was taken to the resuscitation bay for further evaluation. Further history-taking from family revealed that the patient had attended a “cosmetic party” earlier that day (within the prior 24 hours) and received gluteal soft-tissue injections.

Initial vitals were notable for tachycardia with a heart rate of 116 beats per minute (bpm), and tachypnea with a respiratory rate of 34 breaths per minute. The patient was also found to be hypoxic at 70% saturation on pulse oximetry. Temperature and blood pressure were 98.3° Fahrenheit and 137/82 millimeters of mercury (mm Hg), respectively. Seizure activity was controlled with 4 milligrams (mg) of lorazepam. The patient remained unable to provide history or follow commands, with continued hypoxia and signs of respiratory distress despite supplemental oxygen with a nonrebreather mask. Due to respiratory failure, rapid sequence intubation was performed. The physical exam was notable for findings suggestive of recent gluteal injections, with surgical pen markings, injection sites, and oozing of clear liquid. After intubation, bloody fluid from the endotracheal tube was suggestive of alveolar hemorrhage.

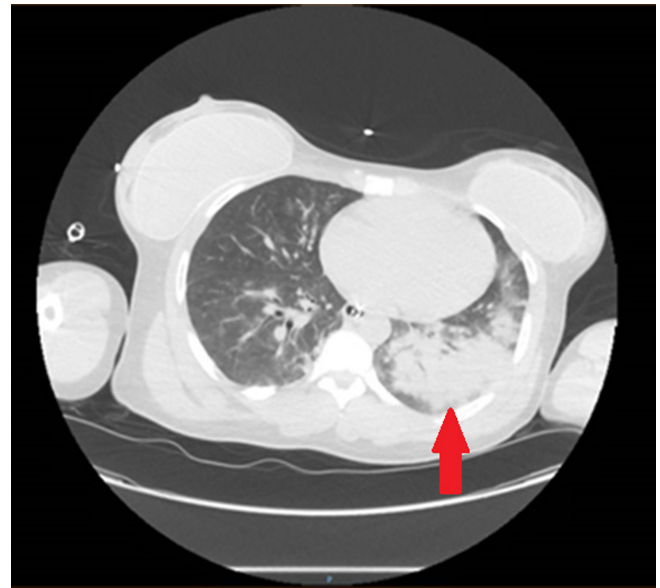


Image 1. Computed tomography of the chest with contrast demonstrating bilateral pulmonary airspace disease, more pronounced in the left lung (arrow).

Chest radiograph obtained immediately after intubation demonstrated left-sided, ground-glass opacities. Computed tomography demonstrated extensive bilateral pulmonary airspace disease as well as opacities in the gluteal area suggestive of cosmetic injections, consistent with the physical exam (Images 1 and 2). A subsegmental pulmonary embolism was also present. Broad spectrum antibiotics were initiated due to concern for a surgical site infection, given subcutaneous emphysema also present on CT (Image 3). Blood gas results were notable for a lactic acidosis with a pH of 7.24 (reference range 7.35–7.45). A decreased ratio of arterial oxygen partial pressure to fractional inspired oxygen

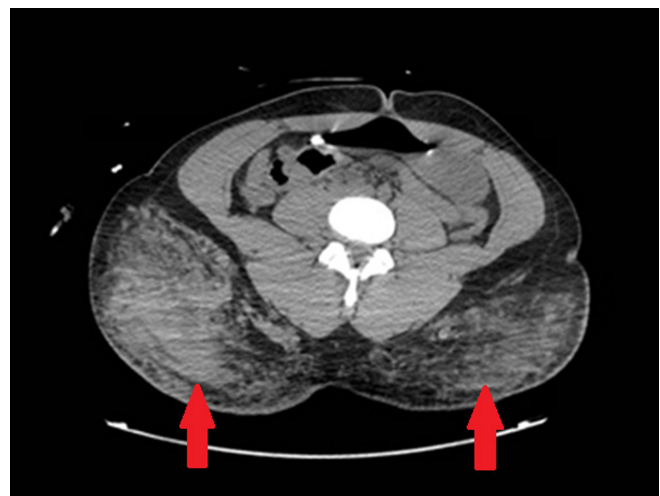

Image 2. Computed tomography of the abdomen and pelvis with contrast demonstrating opacities in gluteal subcutaneous fat, suggestive of inflammation from silicone injections (arrows).

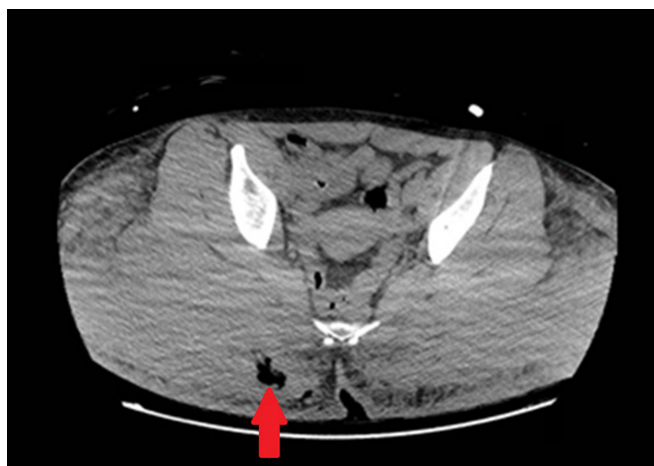


Image 3. Computed tomography of the abdomen and pelvis with contrast demonstrating subcutaneous emphysema in the right gluteal region (arrow).

of 73 was also present, suggestive of severe ARDS. Altered mental status and respiratory failure are suspected to be secondary to effects of silicone emboli.

The patient was admitted to the intensive care unit for further management. The hospital course was complicated by further hemodynamic instability and worsening acidemia. The patient experienced rapidly worsening tachycardia and hypotension, with the heart rate increasing to 144 bpm and mean arterial pressure decreasing to 60 mm Hg within a one-hour time span. Increasing troponin levels from 0.49 nanograms per milliliter (ng/mL) to 1.64 ng/mL (reference range 0–0.5 ng/mL) were also noted. Seven hours after arrival at the hospital, the patient experienced a cardiac arrest. Despite aggressive intervention involving one hour of cardiopulmonary resuscitation and the administration of alteplase for suspected embolism, the patient was pronounced dead.

Review by the medical examiner later confirmed initial clinical impressions. Exam was remarkable for multiple puncture marks at the gluteal region. Multiple cysts filled with viscous material and granulation tissue were present. The patient was noted to have multiple emboli systemically, present in the lungs, kidneys, heart, and brain. Alveolar hemorrhage of the lungs was noted; histological analysis demonstrated lipid material in the vasculature as well as within macrophages. Microscopic analysis of embolic material was consistent with silicone. The autopsy report identified evidence of silicone embolism to microvascular structures of the brain, with ischemic changes noted.

DISCUSSION

Isolated case reports have documented pulmonary complications secondary to liquid silicone injections. Silicone embolism syndrome results in multiple systemic findings, including mental status changes, seizure activity,

ARDS, and alveolar hemorrhage.^{4–8} Here, we describe a case of SES resulting in respiratory failure, although this was also associated with rapid hemodynamic instability and death. For this patient case, clinical findings in addition to autopsy results confirmed that recent cosmetic surgery by an unlicensed practitioner resulted in silicone embolism to multiple organ systems. Seizure activity as noted during the initial patient presentation was likely attributed to silicone embolism to the brain. These findings suggest that silicone emboli can directly affect multiple organ systems; we suspect that involvement of the central nervous system, characterized by emboli and ischemic changes within the brain, is associated with increased mortality and rapid clinical deterioration.

Although medical management of SES has not yet been standardized, of the case reports that detail this phenomenon, resolution of ARDS and overall recovery have been associated with corticosteroid use and lung-protective mechanical ventilation.^{4–8} Intravenous methylprednisolone has most commonly been used in the treatment of respiratory distress in the setting of SES. Improved outcomes are believed to be secondary to decreased airway inflammation.^{4–7} Other case studies noted improvement after the use of extracorporeal membrane oxygenation (ECMO) in the setting of respiratory failure and persistent hypotension.^{9,10} Neurologic manifestations, including altered mental status and coma, may occur and are associated with poorer outcomes.^{6,9,11} Seizure onset, as documented in this case study, is an atypical presentation that has not been extensively documented in other reports. Cases of survival have been reported; prognosis may depend on volume of silicone and pressure of injection.^{4–7}

One 2019 case report describes a case of SES that responded to a regimen of methylprednisolone 125 mg every six hours. The patient in that case, who also received ECMO, recovered. Presentation was acute and within two days of a silicone injection.¹¹ Another 2013 study also reported administration of methylprednisolone at the same dosing with patient survival. Onset was also within two days of a gluteal injection.⁷ These patient cases, in addition to the one described in our case report, describe a relatively quick onset of symptoms after cosmetic surgery.

With regard to clinical practice, silicone injections create a challenge in which the underlying etiology of a critically ill, otherwise healthy patient, may not be readily apparent. The location of potential cosmetic surgery may be revealed by a thorough physical exam or CT. With unlicensed procedures, a full history may not be available from health records alone. Patients may not be forthcoming with sensitive history regarding cosmetic surgery, especially if appearing not to be directly related to new-onset pulmonary changes. In critically ill patients, verbal history may not be available. Physicians should consider the diagnosis of silicone embolism in young patients with acute hemodynamic or mental status changes,

when history or exam findings are suggestive of recent cosmetic surgery.

CONCLUSION

Unlicensed cosmetic procedures have resulted in complications that introduce new medical challenges for emergency physicians. In rare cases, embolization of silicone may result in acute respiratory failure and may progress to systemic findings that include neurologic changes and cardiopulmonary compromise. Volume of silicone injection, in addition to the extent of embolization, may be factors that affect mortality. In the case we report here the sudden hemodynamic changes and mental status changes were likely secondary to widespread silicone emboli, which were identified in multiple organ systems. Early identification of potential silicone embolism syndrome and aggressive supportive care appear to be beneficial. Further studies documenting interventions and outcomes will help guide future management.

The authors attest that their institution requires neither Institutional Review Board approval, nor patient consent for publication of this case report. Documentation on file.

Address for Correspondence: Christopher Lin, MD, Saint Barnabas Hospital, Department of Emergency Medicine, Braker Building Floor 4, 4422 3rd Ave., Bronx, NY 10457.
Email: clin7@mail.einstein.yu.edu

Conflicts of Interest: By the CPC-EM article submission agreement, all authors are required to disclose all affiliations, funding sources and financial or management relationships that could be perceived as potential sources of bias. The authors disclosed none.

Copyright: © 2024 Lin et al. This is an open access article distributed in accordance with the terms of the Creative Commons Attribution (CC BY 4.0) License. See: <http://creativecommons.org/licenses/by/4.0/>

REFERENCES

1. McAuliffe PB, Muss TEL, Desai AA, et al. Complications of aesthetic surgical tourism treated in the USA: a systematic review. *Aesthetic Plast Surg.* 2023;47(1):455–64.
2. Zheng C, Quentzel J, Brust JCM. Complications of silicone cosmetic procedures among medical tourists from the Bronx, New York: a retrospective analysis. *J Clin Aesthet Dermatol.* 2019;12(10):24–8.
3. Mayer JE and Goldberg DJ. Injuries attributable to cosmetic procedures performed by unlicensed individuals in the United States. *J Clin Aesthet Dermatol.* 2015;8(10):35–7.
4. Ng BH, Mat WRW, Abeed NNN, et al. Silicone pneumonitis after gluteal filler: a case report and literature review. *Respirol Case Rep.* 2020;8(3):e00538.
5. Eckle VS, Lambiris N, Grund D, et al. Akutes respiratorisches versagen durch silikon-injektion [Acute respiratory failure after silicone injection]. *Pneumologie.* 2019;73(10):582–5.
6. Cleland DA, Tsai CHH, Vo J, et al. COVID-19 infection or buttock injections? The dangers of aesthetics and socializing during a pandemic. *J Crit Care Med (Targu Mures).* 2022;8(1):49–54.
7. Essenmacher AC and Astani SA. Respiratory disease following illicit injection of silicone: a case report. *Case Rep Med.* 2013;2013:743842.
8. Arora A, Inaty H, Mukhopadhyay S, et al. Chronic pulmonary silicone embolism related to saline breast implants. *Ann Am Thorac Soc.* 2016;13(1):139–41.
9. Madan N, Khan U, Martins A, et al. Recurrent silicone embolism syndrome requiring VA ECMO. *Respir Med Case Rep.* 2022;36:101576.
10. Molina CF and Retalis ZP. Pulmonary embolism secondary to silicone injection. *Int J Med Stud.* 2019;7(2):41–4.
11. Singarajah A, Wang A, Sayegh J, et al. “Botched”: a case report of silicone embolism syndrome after penile and scrotal injection. *Clin Pract Cases Emerg Med.* 2020;4(4):595–8.

Transcatheter Arterial Embolization for Atraumatic Splenic Rupture in TEE-negative Endocarditis: A Case Report

Daniel P. High, MD*
Jose M. Acosta-Rullan, MD[†]
Danay Herrera, DO[†]
Mauricio Danckers, MD*
Daniel Heller, MD, FCCP*
Daniel Zapata, MD[‡]

*HCA Florida Aventura Hospital, Department of Pulmonary and Critical Care Medicine, Aventura, Florida
[†]HCA Florida Aventura Hospital, Department of Internal Medicine, Aventura, Florida
[‡]HCA Florida Kendall Hospital, Department of Pulmonary and Critical Care Medicine, Miami, Florida

Section Editor: Lev Libet, MD

Submission history: Submitted May 24, 2023; Revision received November 2, 2023; Accepted November 16, 2023

Electronically published February 13, 2024

Full text available through open access at http://escholarship.org/uc/uciem_cpchem

DOI: 10.5811/cpcem.1399

Introduction: Spontaneous splenic rupture is an extremely rare complication of infective endocarditis.

Case Report: We present a case of a 56-year-old immunocompetent female with porcine bioprosthetic mitral valve replacement, automated implanted cardioverter-defibrillator, and atrial fibrillation on apixaban who was found to have in-hospital atraumatic splenic rupture complicating infective endocarditis with *Haemophilus parainfluenza*. The rupture was treated successfully by endovascular embolization. Usual treatment with six weeks of antibiotics provided durable cure without further complication, and no surgical intervention was needed for either the valve or spleen.

Conclusion: Transcatheter arterial embolization should be considered early in atraumatic splenic rupture. Relevant abdominal and cerebral imaging should be considered in all cases of suspected or confirmed infective endocarditis where unexplained symptoms are present. [Clin Pract Cases Emerg Med. 2024;8(2)155–158.]

Keywords: atraumatic splenic rupture; splenic artery embolization; endocarditis; case report.

INTRODUCTION

The spleen, an encapsulated hematopoietic organ, is the most frequently injured visceral organ during abdominal blunt trauma.¹ Patients who suffer from a splenic rupture often present with non-specific and subtle symptoms that may include sudden onset left upper quadrant abdominal pain (LUQ), abdominal distention, a rapid decrease in blood pressure and, if severe enough, alterations in mental status. While blunt trauma is the leading cause of splenic rupture, atraumatic splenic rupture (ASR) is a life-threatening condition that can occur spontaneously and in the absence of any apparent injury. Liu et al report ASR as a rare condition with an estimated incidence rate of 3.2% of all splenic ruptures, and Akoury et al points out that it is often misdiagnosed for other, more common causes of LUQ abdominal pain such as pancreatitis.^{2,3}

Atraumatic splenic rupture carries a high mortality rate estimated at 12.2% because delays in diagnosis may lead to persistent internal bleeding, hemodynamic instability and, subsequently, death. Here we report our team's emergent management of a rare case of *Haemophilus parainfluenzae* endocarditis-associated atraumatic splenic rupture. This subset of atraumatic splenic rupture is quite rare, and the use of endovascular rather than surgical treatment is also relatively novel. In a review of the literature we found no other similar cases treated this way.

CASE REPORT

A 56-year-old immunocompetent woman with nonischemic cardiomyopathy with automated implanted cardioverter defibrillator (AICD), bioprosthetic mitral valve replacement secondary to rheumatic heart disease, paroxysmal atrial fibrillation on anticoagulation, and history

of nephrolithiasis presented to the emergency department (ED) with LUQ pain. She denied any recent history of trauma. Laboratory data and computed tomography (CT) of the abdomen and pelvis with intravenous (IV) contrast were unremarkable. Secondary review of imaging done by an independent radiologist for publication confirmed a lack of splenic pathology. The patient was noted to have hematuria and discharged from the ED with suspicion for nephrolithiasis-associated renal colic from a stone that had already been passed out of the urethra. Five days later, she was asked to return to the hospital due to positive blood cultures growing *Haemophilus parainfluenzae*. On admission, she met modified Duke criteria for possible infective endocarditis (IE). She was started on IV ceftriaxone and continued on apixaban home regimen. A transesophageal echocardiogram (TEE) was performed without evidence of AICD lead or valvular vegetations, although mild mitral valve regurgitation was noted.

Persistent LUQ pain by hospital day three prompted a follow-up CT with oral and IV contrast of the abdomen and pelvis that revealed a large hemoperitoneum with a splenic hematoma measuring $15 \times 9 \times 15$ centimeters. (Image) There was no definitive contrast blush, but active splenic hemorrhage was strongly favored by the reading radiologist. Her hemoglobin had dropped from 11.9 grams per deciliter (g/dL) to 7.1 g/dL (reference range: 11.2–15.7 g/dL). Emergent angiogram confirmed active extravasation at the inferior pole of the spleen during selective angiography of the

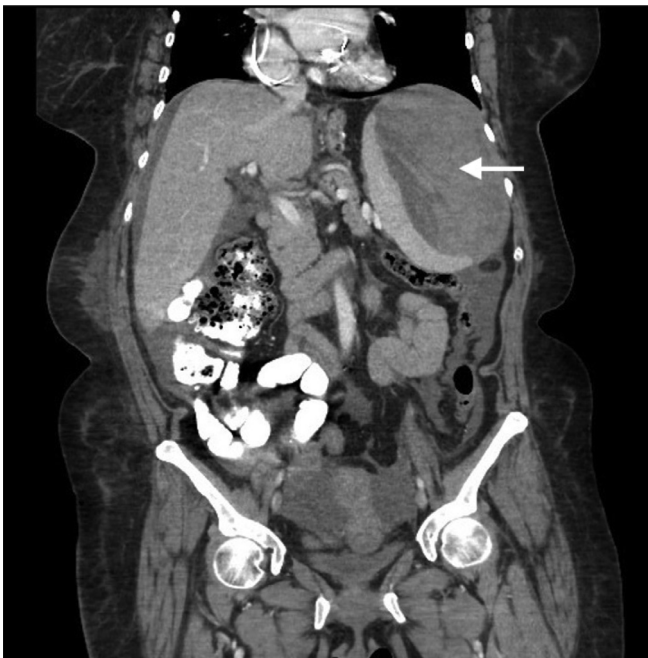


Image. Contrast-enhanced coronal computed tomography of the abdomen demonstrating a large ($15 \times 9 \times 15$ centimeter) perisplenic hematoma (arrow) with concomitant hemoperitoneum due to atraumatic rupture.

Population Health Research Capsule

What do we already know about this clinical entity?

Atraumatic splenic rupture rarely complicates infection, malignancy, and inflammatory disease. Treatment follows pathways for more common traumatic splenic injuries.

What makes this presentation of disease reportable?

We describe definitive management of late, atraumatic splenic rupture complicating transesophageal echocardiogram-negative endocarditis using splenic embolization and antibiotics.

What is the major learning point?

Rare clinical entities can coexist and will not always be readily identifiable during an initial emergency department visit.

How might this improve emergency medicine practice?

Transcatheter splenic artery embolization should be considered early as a safe alternative to surgical management of atraumatic splenic rupture.

splenic artery, and the splenic artery was embolized with seven coils and gel foam. The patient received three units of packed red blood cells. Apixaban had been held for more than 12 hours, and no reversal agent was indicated. Further intensive care unit and hospital course were uncomplicated, and the patient was discharged on day eight to complete a six-week course of IV ceftriaxone on home anticoagulation regimen.

She returned to a nearby hospital the next day for continued abdominal pain. No evidence of bleeding was seen at that time, but anticoagulation was held for a total of four months. No neurovascular complications were evidenced during this period nor recurrence of bleeding when anticoagulation was restarted. Surveillance cultures after antibiotic regimen completion were negative, and follow-up TEE did not show new findings.

DISCUSSION

Atraumatic splenic rupture can be further divided into two categories: pathological (93%) and idiopathic (7%). The pathological etiologies include malignancies (30%), infectious (30%) inflammatory diseases (15%), medical

treatments (10%), or mechanical causes (7%).³ Less commonly, ASR has also been reported as a fatal complication of IE (first reported case by Lake and Kevin in 1919).⁴ Here, we present a rare case of non-traumatic, spontaneous splenic rupture in the setting of *H parainfluenzae* endocarditis.

Spontaneous splenic rupture is an extremely rare complication of IE. While rare, missing the diagnosis may be catastrophic; therefore, a high index of suspicion is needed. In case series the condition carries a mortality rate of 15–58%.⁶ The mortality rate is variable depending on the etiology: neoplastic (21.4%), infectious (8.7%), inflammatory (9.5%), medical treatment (13%), mechanical (17%), and idiopathic (2%).⁷ Risk stratification and choice of intervention should be undertaken with these baseline mortality risks in mind.⁷

It is crucial to inquire regarding recent infections, surgical history, bleeding disorders, and use of anticoagulants, antiplatelets, or nonsteroidal anti-inflammatory drugs. There are three pathophysiological mechanisms of splenic rupture in endocarditis: 1) rupture of splenic abscess; 2) rupture of a mycotic aneurysm; and 3) rupture of a hematoma secondary to suppurating intrasplenic vessel, subcapsular dissection, and delayed capsular tear.⁸ Computed tomography is the current imaging modality of choice to diagnose splenic injury, but incorporating magnetic resonance imaging of the abdomen and brain may also be considered with concurrent IE as it has been shown to upgrade certainty of IE diagnosis or change treatment in 28% of IE cases.¹⁰

Surgical splenectomy is the most common intervention for ASR, although organ-preserving splenorrhaphy can also be done less commonly when appropriate; pediatric cases, for example, are more commonly managed conservatively or with organ-preserving treatment.⁷ Transcatheter arterial embolization (TAE) is becoming a more frequent treatment modality, particularly in cases involving anticoagulants, viral or protozoan etiology, or with active bleeding as this method may allow more rapid and safer hemostasis than surgery alone.¹²

The diagnosis of IE was made using five minor Duke endocarditis criteria for fever, mitral valve replacement, presumed splenic emboli, glomerulonephritis presumed based on hematuria without biopsy proof, and blood cultures not meeting major criteria. Circumstances precluded timely repeat blood cultures to obtain blood culture major criteria, and repeat cultures were taken after five days of antibiotics. There was unnecessary risk to the patient that precluded kidney biopsy to prove hematuria was related to glomerulonephritis given it would not have changed management. As splenectomy was not performed, no histopathology was performed on the spleen to prove embolism vs intrinsic splenic pathology. No repeat TEE was performed during the hospital course or that were available

after discharge. In the setting of delayed splenic rupture, risk of ongoing infection was too high to justify a shorter antibiotic treatment course.

CONCLUSION

When patients with possible or definitive IE have unexplained symptoms, there should be a low threshold of clinical suspicion for advanced imaging of the brain and abdomen to assess for embolic phenomena including splenic lesions. Such clinical information can prove crucial for identifying major complications in cases of TEE-negative endocarditis such as the one presented here. In addition, TAE can be a stabilizing and temporizing measure used in combination with critical care monitoring and intervention even if definitive surgical management may sometimes be needed later. Clinicians should consider TAE early in ASR and consider it a primary option during interdisciplinary decision-making to achieve favorable patient outcomes in this time-sensitive and high-risk clinical entity. We demonstrate here favorable and uncomplicated survival using TAE as definitive management in adjunct to usual antibiotic treatment of ASR complicating *H parainfluenzae* IE.

ACKNOWLEDGMENTS

This research was supported (in whole or in part) by HCA Florida Aventura Hospital. The views expressed in this publication represent those of the author(s) and do not necessarily represent the official views of HCA Florida Aventura Hospital or any of its affiliated entities. We wish to thank Kevin Jaszewski, MD, for image-processing assistance.

Patient consent has been obtained and filed for the publication of this case report.

Address for Correspondence: Daniel P. High, MD, HCA Florida Aventura Hospital, Department of Pulmonary and Critical Care Medicine, 20900 Biscayne Blvd., Aventura, FL 33180. Email: danphigh@gmail.com

Conflicts of Interest: By the *CPC-EM* article submission agreement, all authors are required to disclose all affiliations, funding sources and financial or management relationships that could be perceived as potential sources of bias. This study was funded in whole by the authors and HCA Florida Aventura Hospital.

Copyright: © 2024 High et al. This is an open access article distributed in accordance with the terms of the Creative Commons Attribution (CC BY 4.0) License. See: <http://creativecommons.org/licenses/by/4.0/>

REFERENCES

1. Isenhour JL and Marx J. Advances in abdominal trauma. *Emerg Med Clin North Am*, 2007;25(3):713–33.

2. Liu J, Feng Y, Li A, et al. Diagnosis and treatment of atraumatic splenic rupture: experience of 8 cases. *Gastroenterol Res Pract*. 2019;2019:5827694.
3. Akoury T and Whetstone DR. Splenic rupture. *StatPearls*. 2022. Available at: <https://www.ncbi.nlm.nih.gov/books/NBK525951/>. Accessed Oct 25, 2023.
4. Lake NC and Kevin HK. Three uncommon abdominal cases illustrating some pitfalls. *The Lancet*. 1919;194(5001):13.
5. Dimitrakakis G, Von Oppell U, Zilidis G, et al. Splenic rupture complicating aortic valve replacement for bacterial endocarditis. *Interact Cardiovasc Thorac Surg*. 2008;7(1):138–40.
6. Hershman-Sarafov M, Paz A, Potasman I. Echo-negative endocarditis: analysis of 538 consecutive transesophageal echocardiographies. *Open Forum Infect Dis*. 2016;3(suppl1):1105.
7. Renzulli P, Hostettler A, Schoepfer AM, et al. Systematic review of atraumatic splenic rupture. *Br J Surg*. 2009;96(10):1114–21.
8. Vergne R. Rupture of the spleen in infective endocarditis. *Arch Intern Med*. 1975;135(9):1265–7.
9. Walker A and Foley E. Surgical management of atraumatic splenic rupture. *Int Surg J*. 2016;3(4):2280–8.
10. Lung B, Klein I, Mourvillier B, et al. Respective effects of early cerebral and abdominal magnetic resonance imaging on clinical decisions in infective endocarditis. *Eur Heart J Cardiovasc Imaging*. 2012;13(8):703–10.
11. Murdoch DR. Clinical presentation, etiology, and outcome of infective endocarditis in the 21st century. *Arch Intern Med*. 2009;169(5):463.
12. Tonolini M, Ierardi AM, Carrafiello G. Atraumatic splenic rupture: an underrated cause of acute abdomen. *Insights Imaging*. 2016;7(4):641–6.
13. Gedik E, Girgin S, Aldemir M, et al. Non-traumatic splenic rupture: report of seven cases and review of the literature. *World J Gastroenterol*. 2008;14(43):6711.

Use of Point-of-care Ultrasound to Diagnose Rectus Abdominis Strain in the Acute Setting: A Case Report

Alejandro J. Sanoja, MD
Michael Shalaby, MD

Mount Sinai Medical Center, Department of Emergency Medicine, Miami Beach, Florida

Section Editor: Shadi Lahham, MD

Submission history: Submitted September 14, 2023; Revision received December 6, 2023; Accepted December 7, 2023

Electronically published March 26, 2024

Full text available through open access at http://escholarship.org/uc/uciem_cpccm

DOI: 10.5811/cpcem.1670

Introduction: Rectus abdominis muscle strains are common and can be debilitating in both professional and amateur athletes who engage in strenuous activity.

Case Report: We report a rare case of rectus abdominis muscle tear in an amateur bodybuilder diagnosed by point-of-care ultrasound (POCUS) in the emergency department (ED). The patient had presented to the ED three separate times after strenuous exercise, received costly diagnostic workups, and ultimately was diagnosed on the third visit with grade 2 bilateral rectus abdominis tear. The patient was given appropriate education and sports medicine follow-up. He underwent rehabilitation focused on trunk and core stability. At eight-week follow-up, the patient had made a full recovery.

Conclusion: To our knowledge, a case of bilateral rectus abdominis tear diagnosed by ultrasound in the emergency setting has not been previously published. Our case report highlights the utility of POCUS in diagnosing musculoskeletal pathology and preventing costly bounce-back visits. [Clin Pract Cases Emerg Med. 2024;8(2)159–162.]

Keywords: *rectus abdominis; ultrasound; muscle tear; emergency department; case report.*

INTRODUCTION

Rectus abdominis muscle strains are common and debilitating in both professional and amateur athletes but can be easily misdiagnosed in an emergency setting or by physicians who do not treat athletes regularly.^{1–10} Point-of-care ultrasound (POCUS) is a helpful tool to aid in expedient diagnosis and grade the degree of severity of rectus abdominis strain.⁷ Here we describe a case of rectus abdominis muscle strain that highlights the utility of POCUS, the importance of discriminating between intra-abdominal and abdominal wall pathology, and the prevention of poor functional outcomes.

CASE REPORT

The patient was a 40-year-old male recreational bodybuilder with no significant prior medical history who presented to the emergency department (ED) with lower abdominal pain. He trained five days a week with a focus on

weightlifting and included a variety of endurance exercises in his regimen. Of note, he had recently increased his endurance training and core isolation exercises.

At the patient's first ED visit, he complained of debilitating abdominal pain that was located below the umbilicus, constant and progressively worsening. His pain was aggravated by running, abdominal isolation exercises, and deadlifting. The patient had not tried any medications to alleviate the pain. He denied any constitutional symptoms, dysuria, hematuria, vomiting, or diarrhea. Physical exam was significant for severe suprapubic tenderness to palpation. Lab work was within normal limits, and computed tomography (CT) of the abdomen and pelvis with oral and intravenous contrast revealed no abnormalities. The patient was given ondansetron, normal saline, viscous lidocaine, and famotidine and was discharged home with primary care follow-up.

The patient returned three months later with persistent lower abdominal pain. He reported that his aggravating and

alleviating factors had not changed, but that his abdominal pain had progressed. He had not followed up with a primary care physician or any other specialist since his first visit. He once again had labs drawn and CT abdomen and pelvis imaging, which were again within normal limits. The patient was again given pain medicines and was discharged home with a diagnosis of “unspecified lower abdominal pain,” and given follow-up with gastroenterology and urology.

The patient presented again after another three months with continued abdominal pain, which he noted still occurred after the same exacerbating exercises from prior. Physical examination was significant for pain elicited with flexion of the abdominal muscles and palpation. Additionally, the patient was evaluated by soft tissue ultrasound over the most painful area of the abdomen. Point-of-care ultrasound (POCUS) of the abdominal rectus muscle demonstrated disrupted abdominal muscle fibers bilaterally with anechoic fluid between abdominal muscle layers (Image 1) and streaks of edema intramuscularly (Image 2). The emergency physician diagnosed the patient with rectus abdominis strain and instructed him to rest and follow up with a sports medicine physician.

The patient was contacted two months after discharge from the ED. He had stopped performing the culprit exercises until his abdomen no longer hurt. He modified aggravating isolation abdominal exercises and progressively over the course of two months returned to his previous normal activity without pain.

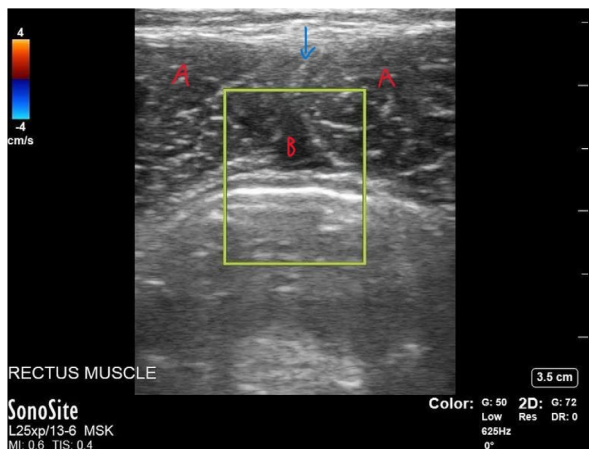


Image 1. Point-of-care ultrasound of the rectus abdominis in short-axis view demonstrating a small, 1 × 2-centimeter collection of fluid. In the near field is skin and subcutaneous tissue. The hyperechoic midline stripe between the two triangular rectus abdominis muscle bellies (“A”) on either side is the linea alba (blue arrow). The hypoechoic area (labeled “B”) between the rectus abdominis muscles and below the linea alba is likely edema. The yellow rectangle is a color flow application, which indicates arterial (red) or venous (blue) blood flow. In this case, there is no flow, which is expected in the case of edema.

Population Health Research Capsule

What do we know about this clinical entity?
Rectus abdominis muscle strains are easily misdiagnosed in the emergency setting. Point of care ultrasound (POCUS) has been shown to aide in diagnosis in the sports medicine literature.

What makes this presentation of disease reportable?
There has never been a reported case of rectus abdominis strain that was diagnosed by POCUS in the emergency medicine literature.

What is the major learning point?
This case report emphasizes how POCUS is an important, sensitive, and cost-effective aide in evaluating abdominal wall pathology.

How might this improve emergency medicine practice?
This may encourage emergency medicine physicians to routinely use POCUS when suspecting musculoskeletal pathology.

DISCUSSION

Abdominal rectus injuries are overall a rare entity in the general population; however, they occur in physically active individuals who engage in frequent strenuous exercise.¹ The literature describes these injuries in a diversity of professional and recreational athletes, including recreational

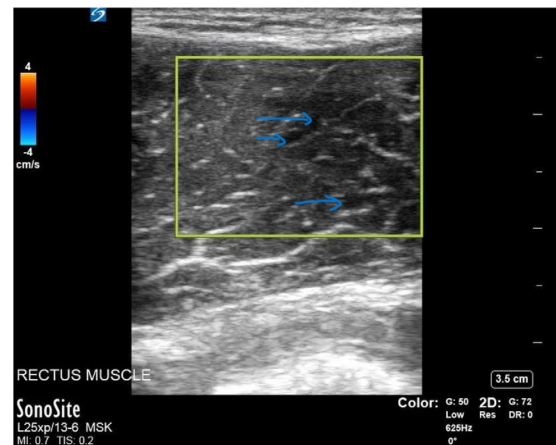


Image 2. Point-of-care ultrasound of the right rectus abdominis muscle in the short-axis view demonstrating muscle fiber elongation with intramuscular edema indicated by the blue arrows. Again, the yellow rectangle demonstrates no evidence of small vascular structures.

weightlifters.¹⁻⁹ Clinically, there are notable historical and examination findings that are helpful to distinguish abdominal wall from visceral pathology. Abdominal wall injuries tend to be more localized, elicited by movement, and are tender to palpation regardless of muscle contractility. The Carnett sign is elicited when the point of maximal abdominal tenderness persists when the patient's abdomen is palpated while tensed. If the Carnett sign is positive, then the pain is likely to arise from the abdominal wall.¹ Visceral pain can be more diffuse, referred, constant, and is elicited when the muscles are relaxed. Additionally, there is a notable absence of nausea, vomiting, diarrhea, constitutional symptoms, or other symptoms common in intra-abdominal pathologies.¹ As in this case, the presentation can be ambiguous, and POCUS is a powerful tool that can be used to aid in diagnosis.

In this case, both improved physical exam and ultrasound were invaluable in reliably diagnosing the patient with rectus abdominis muscle tear and preventing further delay in treatment. A few case reports highlight ultrasound as a tool to both diagnose and treat abdominal muscle tears.^{1-7,9} Ruff et al and Maquirriain et al recommend using ultrasound to estimate disease severity. The goal of ultrasonography in the setting of suspected muscular pathology is to identify a tear, as this prognosticates time to recovery and to sport.⁷ Tears are characterized by disturbed muscle fibers, intramuscular edema, and fluid collections. As with our patient, rectus abdominis strain can be easily overlooked when a patient is in acute distress due to pain. The patient presented three times to the ED before a correct diagnosis was made. This can lead to unnecessary testing and inappropriate treatment.

Revision of CT imaging by an attending emergency physician after ultrasound diagnosis showed no significant acute abnormality. Revision by a radiologist was not performed, but the second CT report included a revision of the first scan for comparison. Both CT studies, read by two different radiologists, showed no acute abdominal wall pathology. Ultrasound and magnetic resonance imaging are preferred tests to evaluate for muscular pathology due to increased sensitivity and specificity.^{1,2,10} Computed tomography has limited utility for muscular lesional evaluation but will assess for fracture and intrabdominal pathology. As discussed above, ultrasound is both specific and sensitive in detecting muscle tears.¹⁰ Magnetic resonance imaging can provide additional information and is typically ordered for the professional athlete. However, numerous studies have shown POCUS to be both sensitive and specific in detecting muscular pathology and has the added benefit of being cost-effective and rapidly available in most EDs.^{4,7,10}

Treatment for most rectus abdominal tears is conservative. The cornerstone of treatment in the acute period is rest, ice, analgesia, and avoidance of the offending action.^{1,5} Early rehabilitation is considered key to reducing time to play.⁵ Rehabilitation focuses on functional

restoration exercises.^{1,5-8} Several case reports support the use of platelet rich therapies and corticosteroid injection in professional athletes in addition to rehabilitation.^{3,4} The patient discussed here improved with conservative management and a progressive return to weightlifting.

CONCLUSION

Identification of abdominal wall injury is easily overlooked by acute care physicians, but it is crucial to prevent delayed treatment, poor functional outcomes, and costly medical workup. This case demonstrates how ultrasonography can be used to diagnose abdominal muscle tears in both the ED and outpatient clinic. Ultrasound is reliable, quick, and cost-effective. To our knowledge, there are fewer than 12 case reports on this topic, with none occurring in the ED that resulted in real-time diagnosis. We support the routine use of POCUS to evaluate musculoskeletal pathology in the ED and in the outpatient setting.

The authors attest that their institution requires neither Institutional Review Board approval, nor patient consent for publication of this case report. Documentation on file.

Address for Correspondence: Alejandro Sanoja, MD, Mount Sinai Medical Center, Department of Emergency Medicine, 4300 Alton Road, Miami Beach, FL 33140.
Email: alejandro.sanoja@msmc.com

Conflicts of Interest: By the CPC-EM article submission agreement, all authors are required to disclose all affiliations, funding sources and financial or management relationships that could be perceived as potential sources of bias. The authors disclosed none.

Copyright: © 2024 Sanoja et al. This is an open access article distributed in accordance with the terms of the Creative Commons Attribution (CC BY 4.0) License. See: <http://creativecommons.org/licenses/by/4.0/>

REFERENCES

1. Johnson R. Abdominal wall injuries: rectus abdominis strains, oblique strains, rectus sheath hematoma. *Curr Sports Med Rep.* 2006;5(2):99-103.
2. Maquirriain J, Ghisi JP, Kokalj AM. Rectus abdominis muscle strains in tennis players. *Br J Sports Med.* 2007;41(11):842-8.
3. Dauty M, Menu P, Dubois C. Uncommon external abdominal oblique muscle strain in a professional soccer player: a case report. *BMC Res Notes.* 2014;7:684.
4. Stevens KJ, Crain JM, Akizuki KH, et al. Imaging and ultrasound-guided steroid injection of internal oblique muscle strains in baseball pitchers. *Am J Sports Med.* 2010;38(3):581-5.
5. Bayer ML, Hoegberget-Kalish M, Svensson RB, et al. Chronic sequelae after muscle strain injuries: influence of heavy resistance training on

- functional and structural characteristics in a randomized controlled trial. *Am J Sports Med.* 2021;49(10):2783–94.
6. Gozubuyuk OB, Koksal C, Tasdemir EN. Rehabilitation of a patient with bilateral rectus abdominis full thickness tear sustained in recreational strength training: a case report. *Physiother Theory Pract.* 2022;38(13):3216–25.
 7. Ruff AN, Cornelson SM, Panter AS, et al. Rectus abdominis muscle tear diagnosed with sonography and its conservative management. *J Ultrasound.* 2020;23(3):401–6.
 8. Kawama R, Ike A, Soma A, et al. Side-to-side difference in electromyographic activity of abdominal muscles during asymmetric exercises. *J Sports Sci Med.* 2022;21(4):493–503.
 9. Guermazi A, Roemer FW, Robinson P, et al. Imaging of muscle injuries in sports medicine: sports imaging series. *Radiology.* 2017;285(3):1063. Erratum for: *Radiology.* 2017;282(3):646–63.
 10. Draghi F, Cocco G, Richelmi FM, et al. Abdominal wall sonography: a pictorial review. *J Ultrasound.* 2020;23(3):265–78.

When Educational Images Don't Reflect the Population: Phlegmasia Cerulea Dolens, a Case Report

Kasha Bornstein, MD, MPH*
Elizabeth LaRosa, MD, MPH†
Kelsey Byrd, DO†
Dan Laney, MD‡
Hector Ferral, MD‡
Heather Murphy-Lavoie, MD†

*Louisiana State University Health Sciences Center, Department of Internal and Emergency Medicine, New Orleans, Louisiana

†Louisiana State University Health Sciences Center, Department of Emergency Medicine, New Orleans, Louisiana

‡Louisiana State University Health Sciences Center, Department of Interventional Radiology, New Orleans, Louisiana

Section Editor: Rachel Lindor, MD, JD

Submission history: Submitted October 4, 2023; Revision received January 4, 2024; Accepted January 8, 2024

Electronically published April 17, 2024

Full text available through open access at http://escholarship.org/uc/uciem_cpccm

DOI: [10.5811/cpcem.1905](https://doi.org/10.5811/cpcem.1905)

Introduction: Phlegmasia cerulea dolens (PCD) is an uncommon, potentially life-threatening complication of acute deep venous thromboses that requires a timely diagnosis. The name of the condition, the visual diagnostic criteria, and the preponderance of cases in the literature referencing findings exclusively in patients with lighter skin complexions means that PCD may not be on the differential diagnosis for the patient with more melanated skin who is experiencing this time-sensitive vascular emergency.

Case Report: We describe one case of PCD in a patient with darker skin complexion and the importance of identifying clinical findings, regardless of skin color, given the paucity of reference images for PCD in darker complected patients. Our literature review yielded 60 case reports for PCD. Only two papers included images referencing patients of color.

Conclusion: Accurate diagnosis requires recognition of diagnostic findings, which may vary significantly between phenotypically distinct populations. Many pathognomonic physical exam findings rely on descriptors based on presentation in phenotypically white patients. [Clin Pract Cases Emerg Med. 2024;8(2)163–167.]

Keywords: *case report; health disparities; deep venous thrombosis.*

INTRODUCTION

Phlegmasia cerulea dolens (PCD) is a rare and potentially life-threatening complication of acute deep venous thrombosis (DVT), especially if delayed in diagnosis. It is characterized by marked extremity swelling, pain, and skin color change. Additional findings include non-palpable distal pulses and paresthesias.¹ Phlegmasia cerulea dolens results from critical thrombosis of both the deep and superficial venous systems of the limb, leading to arterial ischemia, gangrene, and limb loss. The mortality rate for PCD ranges between 20–40%; lethal complications include pulmonary emboli (PE), rhabdomyolysis, fluid sequestration, hyperkalemia, and shock.² Even with

aggressive intervention, amputation rates are between 12–50%.³ The existing literature has a paucity of reference images for PCD in patients with darker skin tones. We describe one case of PCD in a patient with a darker skin complexion, highlighting distinctions in exam findings in patients of color.

CASE REPORT

A 68-year-old man with a history of pulmonary adenocarcinoma presented to the emergency department (ED) reporting progressive generalized weakness and right lower extremity pain for 10 days. One month prior, he had been hospitalized for shortness of breath and diagnosed with

a malignant pleural effusion. This was managed with a tunneled pleural catheter for continuous drainage. During that hospitalization, he was found to have bilateral DVTs of the posterior tibial veins and segmental emboli to the left pulmonary artery. He was started on anticoagulation at that time but subsequently developed hemorrhagic pleural drainage. Anticoagulation was held, and interventional radiology (IR) placed an inferior vena cava (IVC) filter. He was discharged home to continue oncologic treatment.

Upon his second ED presentation, his exam was significant for sinus tachycardia, normoxemic tachypnea, and hypotension. The skin around the right pleural catheter was clean, dry, and non-erythematous. Pleural catheter drainage was scant and clear. Pulmonary exam was otherwise unremarkable without adventitious lung sounds. His right lower extremity had circumferential, non-pitting edema from the foot to the groin, with areas of erythema, mottling, and purpling about the digits, shin, and knee. His right foot was darkened and cool to touch (**Image 1**).

Popliteal, posterior tibial, and dorsalis pedis pulses were palpable. He endorsed pain on passive motion, paresthesias, and decreased sensation distal to the knee. He was able to flex and extend at the hip joint but had complete paralysis below the knee. His left lower extremity was warm and well-perfused, with no edema or neurologic abnormalities. The remainder of his physical exam was unrevealing. Laboratory analyses were notable for normocytic anemia with hemoglobin of 7.7 grams per deciliter (g/dL) (reference range 13.2–16.6 g/dL), consistent with his prior admission,

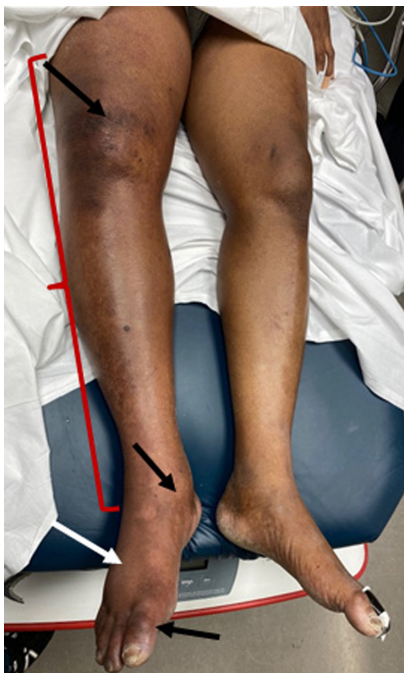

Image 1. Patient's right leg with evidence of enlargement (red bracket), darkening of skin around joints (black arrows), subtle reddening and purpling of tissues (white arrow).

CPC-EM Capsule

What do we already know about this clinical entity?

Phlegmasia cerulea dolens (PCD) is a potentially life-threatening sequela of deep vein thrombosis characterized by extremity swelling, pain, and skin color change.

What makes this presentation of the disease reportable?

We describe a case of PCD in a patient with darker complexion, emphasizing distinctions in exam findings.

What is the major learning point?

Physicians are not primed to visually diagnose conditions in patients with darker-complected skin, as the literature almost uniformly references findings in White patients.

How might this improve emergency medicine practice?

Phenotypic differences confer significant variation upon exam findings. Diagnosis requires recognition of pathology between distinct populations.

leukocytosis of 12.8×10^3 per microliter (μL) ($4.5\text{--}11 \times 10^3/\mu\text{L}$), potassium of 5.5 millimoles per liter (mmol/L) ($3.5\text{--}5$ mmol/L), creatinine of 1.76 milligrams (mg)/dL ($0.74\text{--}1.35$ mg/dL), up from 1.22 mg/dL on prior discharge. Lactate was elevated to 2.7 mmol/L (reference range <2). COVID-19 polymerase chain reaction was negative. Lower extremity duplex ultrasonography was performed, demonstrating complete thrombosis of the right common femoral, greater saphenous, popliteal, and calf veins (**Image 2A, 2B**).

Additional thrombi were identified in the left femoral, popliteal, and upper calf veins. This clot burden was greater than had been seen during the prior admission; ultrasound at that time revealed thrombi in the right peroneal and the left popliteal veins. Computed tomography (CT) of the chest revealed no evidence of PE. Computed tomography of the abdomen and pelvis demonstrated extensive bilateral ilio-femoral DVT extending to the IVC filter (**Image 2C**).

The patient was fluid resuscitated and started on a heparin infusion. Interventional radiology was consulted and performed percutaneous venous thromboaspiration from the popliteal veins to the IVC. Flow was successfully restored throughout the right lower venous vasculature, and 70% of

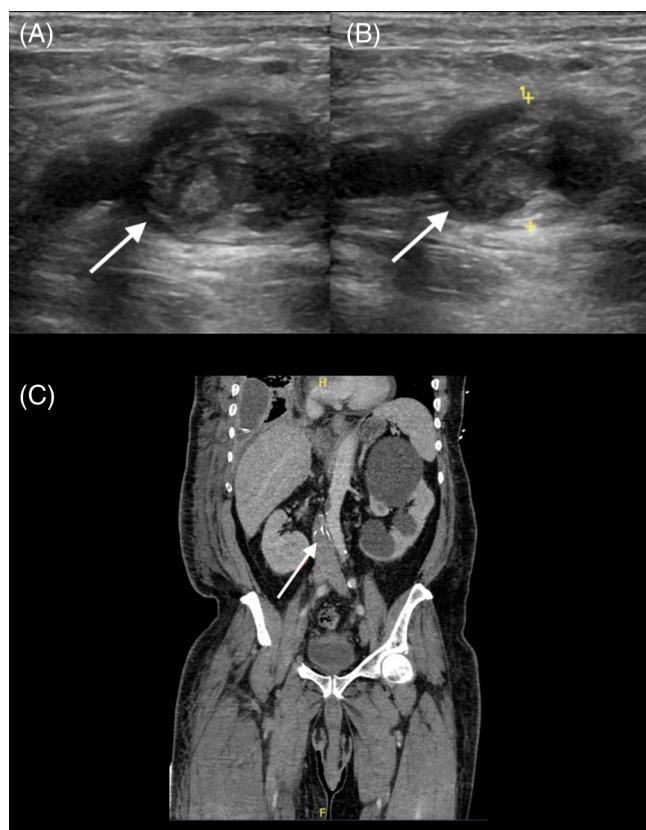


Image 2. Top: Ultrasound of the right common femoral vein demonstrating clot (A) with incompressibility of the vein (B). Bottom: Computed tomography of the abdomen and pelvis demonstrating thrombosis of the inferior vena cava to the level of implanted inferior vena cava filter (C).

the thrombotic burden was aspirated from the IVC (Image 3). Following intervention, the patient was admitted to the intensive care unit for continued management of hypotension and anticoagulation. Right lower extremity discoloration, edema, and paresthesias resolved within 24 hours following intervention. His hemodynamics improved, and he was transferred to Internal Medicine. He was discharged to a skilled nursing facility on hospital day 15.

DISCUSSION

Phlegmasia cerulea dolens is an uncommon, life-threatening manifestation of DVT, resulting from critical thrombosis of the deep and superficial venous systems leading to arterial compromise and decreased perfusion. Risk factors for PCD are similar to other DVT and include malignancy, hereditary coagulopathies, surgery, trauma, IVC filter placement, pregnancy, smoking, and use of hormonal contraception.^{4,5} Unlike simple DVT, PCD also carries risk of compartment syndrome, rhabdomyolysis, electrolyte disturbances, tissue ischemia, gangrene and limb loss, fluid sequestration leading to hemodynamic compromise, and consequent multiorgan failure.³

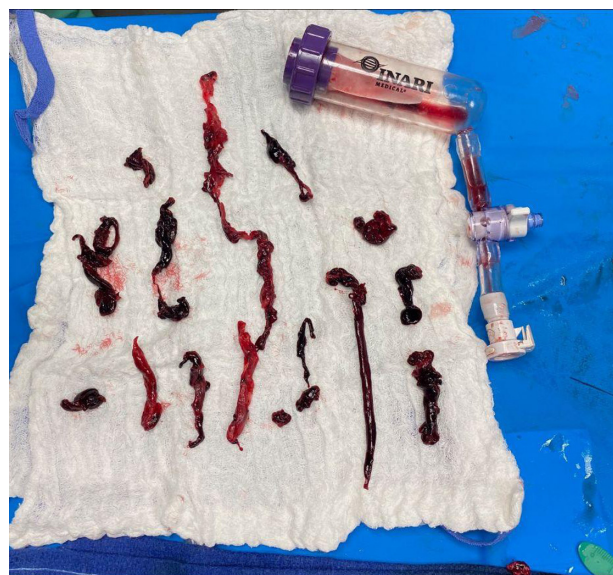

Image 3. Demonstration of clot burden following thromboaspiration by Interventional radiology service using clot retriever device.

Recognizing this serious condition is essential. Exam findings suggestive of PCD include darkening of the limb(s), extremity edema, decreased skin sensation, paresis, and muscular or superficial tenderness. Crucial physical exam components include inspection and palpation of the entire extremity to evaluate arterial pulses, temperature, and capillary refill. A detailed neurological exam should assess sensory and motor function of the limb. Early duplex ultrasound is critical for assessing non-compressible veins from the distal to proximal vasculature of the affected extremity. As a time-sensitive condition, angiography and other vascular imaging is unnecessary unless suspicion is raised for concomitant PE. Management includes hemodynamic stabilization, treatment of electrolyte derangements, initiation of anticoagulation, and vascular surgery or IR consultation for thrombectomy.²

Accurate diagnosis and management of life- or limb-threatening conditions is an essential role of emergency physicians. We believe this case illustrates that this objective was achieved in the care of this patient. However, our aim was not simply to illustrate a case of PCD. We present this case to emphasize the potential consequences of medical education resources that insufficiently depict PCD in non-white patients. Although this patient had many of the risk factors and classic physical exam findings of PCD, (active malignancy, presence of an IVC filter, extremity pain, and paresis) the diagnosis was briefly delayed by difficulty recognizing these features in a patient whose leg physiologically could not be blue. By virtue of the condition's name—painful blue inflammation—physicians are not primed to visually diagnose this condition in

darker-complected skin, as educational resources almost uniformly reference exam findings in white patients.

Case reports on patients with light-complected skin predominate the medical literature on PCD, implicitly making paler skin the default. Cases in patients with darker skin may be missed or misdiagnosed simply because of unfamiliarity with skin that appears more ashen, purple, or hyperpigmented rather than blue.⁶ This patient did not present with the ostensibly pathognomonic “bright blue leg” frequently encountered in both educational resources and clinical imaging series published in academic journals.^{7,8} Many other clinical exam findings including cyanosis, livedo reticularis, jaundice, and purpura are distinct between patient populations of different skin complexion but are based on a reference frame of patients with lightly complected skin. Expecting to see blue, rather than hyperpigmented, purpuric, or ashen skin can undergird ascertainment bias and diagnostic errors, with delayed disposition and treatment in this and other critical illnesses. In a case report about a patient with toxic epidermal necrolysis, Lester, Taylor, and Chren (2021) describe a patient who spent many hours in the hospital waiting room decompensating, their care delayed because “the characteristic redness” facilitating diagnosis “can be subtle in skin of color.”⁹

These subtleties are under-represented in the medical literature. Our literature review yielded 60 case reports on PCD. Only two included images involving patients of color. In a study assessing representation of skin color in dermatology-related Google searches, Kurrti, Austin and Jagdeo et al found that 91.7% displayed light skin.¹⁰ Although Black people comprise 13.5% of the United States population, Black physicians account for only 5% of the physician workforce in the US as of 2019. People of color more generally account for fewer than one-third of physicians.^{11,12} Physician demographic disparities derive from multiple interconnected causes including structural and institutional racism, historical segregation in medical education, and marginalization of historically Black medical schools.⁷

The 1910 Flexner Report, which instigated major reforms in medical education in the US, also prompted the closure of all but two historically Black medical schools in an era during which modern biomedical diagnostics were established.¹³ Flexner's view of the role for Black physicians was providing “hygiene” for Black communities to prevent hookworm and tuberculosis from affecting White populations.¹³ It is no historical accident that many contemporary descriptors for clinical exam findings reflect their presentation in White patients; the privilege of elaborating anatomopathological nomenclature to describe features of disease was deliberately restricted to White physicians whose practice was carried out in racially segregated environments. Consequentially, medical practice today involves unexamined use of terminology that may unintentionally bias the user away from correct diagnosis.

CONCLUSION

Accurate diagnosis requires recognition of pathology and various diagnostic criteria, which may visually vary significantly between phenotypically distinct populations. Many pathognomonic physical exam findings involve descriptors based on their presentation in White patients. While race is not a biological phenomenon, phenotypic differences confer significant distinctions in manifestation of pathologic findings. Historical racism situating whiteness as default influenced the development of clinical nomenclature, potentially limiting the appropriateness and full diagnostic scope of terms for many clinical exam findings. As a time-sensitive condition, the naming of phlegmasia cerulea dolens can be a disservice to clinicians and patients alike. Emergency clinicians should be conscious of the core features seen in this clinical entity; significant discoloration to an entire extremity with associated pain, swelling, and paresthesia, particularly in a patient with an underlying acquired or inherited thrombophilia.

The authors attest that their institution requires neither Institutional Review Board approval, nor patient consent for publication of this case report. Documentation on file.

Address for Correspondence: Kasha Bornstein MD, MPH, Louisiana State University Health Sciences Center, Department of Internal and Emergency Medicine, 2021 Perdido St., Room 5141, New Orleans, LA 70112. Email: borns@lsuhsc.edu

Conflicts of Interest: By the *CPC-EM* article submission agreement, all authors are required to disclose all affiliations, funding sources and financial or management relationships that could be perceived as potential sources of bias. The authors disclosed none.

Copyright: © 2024 Bornstein et al. This is an open access article distributed in accordance with the terms of the Creative Commons Attribution (CC BY 4.0) License. See: <http://creativecommons.org/licenses/by/4.0/>

REFERENCES

- Gardella L and Faulk JB. Phlegmasia alba and cerulea dolens. In: *StatPearls*. Treasure Island (FL) 2023. Available at: <https://www.ncbi.nlm.nih.gov/books/NBK563137/>. Accessed July 8, 2022.
- Chaochankit W and Akaraborworn O. Phlegmasia cerulea dolens with compartment syndrome. *Ann Vasc Dis*. 2018;11(3):355–7.
- Chinsakchai K, Ten Duis K, Moll FL, et al. Trends in management of phlegmasia cerulea dolens. *Vasc Endovascular Surg*. 2010;45(1):5–14.
- Chi WK, Tan GM, Yan BP. May-Thurner syndrome results in life-threatening condition: phlegmasia cerulea dolens and rhabdomyolysis. *J Invasive Cardiol*. 2020;32(7):E190.
- Nickler M, Haubitz S, Mendez A, et al. Phlegmasia cerulea dolens - an uncommon but alarming manifestation of deep vein thrombosis. *Vasa*. 2020;49(5):422–6.

6. Penedo Alonso JR, Aranda-Garcia Y, Ly-Pen D, et al. Incidence and characteristics of phlegmasia cerulea dolens. A 17- year, descriptive study in a third-level hospital in Madrid. *Int J Contemp Med Res*. 2019;6(11):K7–9.
7. Baker W and Kim S. Risking life and limb: management of phlegmasia alba and cerulea dolens. 2015. Available at: <https://www.emra.org/emresident/article/risking-life-and-limb-management-of-phlegmasia-alba-and-cerulea-dolens>. Accessed July 8, 2022.
8. Thurman RJ and Stack L. Blue leg. 2015. Available at: <https://www.emra.org/emresident/article/blue-leg>. Accessed July 8, 2022.
9. Lester JC, Taylor SC, Chren M-M. Under-representation of skin of colour in dermatology images: not just an educational issue. *Br J Dermatol*. 2019;180(6):1521–2.
10. Kurtti A, Austin E, Jagdeo J. Representation of skin color in dermatology-related Google image searches. *J Am Acad Dermatol*. 2022;86(3):705–8.
11. Guevara JP, Wade R, Aysola J. Racial and ethnic diversity at medical schools — Why aren't we there yet? *N Engl J Med*. 2021;385(19):1732–4.
12. Diversity in Medicine: Facts and Figures 2019. 2019. Available at: <https://www.aamc.org/data-reports/workforce/report/diversity-medicine-facts-and-figures-2019>. Accessed July 8, 2022.
13. Laws T. How should we respond to racist legacies in health professions education originating in the Flexner Report? *AMA J Ethics*. 2021;23(3):E271–5.

Atraumatic Orbital Emphysema in a Young Woman

Eladio Albornoz, BS*
Janet Wildemuth, MSPAS[†]
Josephine Valenzuela, MD^{‡§}

*Arizona State University, Department of Medical Studies, Phoenix, Arizona
[†]Valleywise Health, Departments of Emergency Medicine and Internal Medicine, Phoenix, Arizona
[‡]Creighton University of Phoenix, Phoenix, Arizona
[§]University of Arizona Phoenix, Phoenix, Arizona

Section Editor: Steven Walsh, MD

Submission history: Submitted September 28, 2023; Revision received January 3, 2024; Accepted January 5, 2024

Electronically published March 26, 2024

Full text available through open access at http://escholarship.org/uc/uciem_cpchem

DOI: 10.5811/cpcem.1897

Case Presentation: We describe the presentation, evaluation, and management of a young female patient presenting to the emergency department with atraumatic orbital emphysema, a rare condition. This patient was diagnosed using point-of-care ultrasound and computed tomography and was managed expectantly.

Discussion: Atraumatic orbital emphysema is a rare clinical condition more common in early middle-aged female patients with certain historical features such as chronic sinusitis, facial surgery or trauma, tobacco smoking, or current upper respiratory symptoms. While most cases will resolve spontaneously, rarely this condition can lead to vision-threatening orbital compartment syndrome, requiring lateral canthotomy or needle decompression. [Clin Pract Cases Emerg Med. 2024;8(2)168–170.]

Keywords: atraumatic orbital emphysema; point-of-care ultrasound; case report.

CASE PRESENTATION

A 36-year-old woman presented to the emergency department with pain and swelling around her right eye after blowing her nose the evening prior (**Image 1**). She denied headache, fever, eye discharge, and visual changes. She denied any history of trauma, recent surgery, or upper respiratory symptoms. Physical examination was notable for periorbital swelling. There was crepitus to palpation of the area. Pupils were equal, round, and reactive to light. Visual acuity was 20/30 in both eyes, with an elevated intraocular pressure in the affected eye of 32 millimeters of mercury (mm Hg) (reference range 10–20 mm Hg), but without proptosis. Eye movements were normal and painless. There was no conjunctival injection, hemorrhage, tearing, or discharge from the eye.

The patient was laid supine, and a point-of-care ultrasound was performed with a linear transducer (**Image 2**). Notable findings included “dirty shadowing” and ring-down artifact consistent with air in the periorbital soft tissue. Computed tomography (CT) confirmed a defect in the lamina papyracea of the ethmoid

sinus (the medial orbital wall), with air trapped in the orbit (**Image 3**).

DISCUSSION

Orbital emphysema is an uncommon condition that results from trapping of air in the orbit and periorbital tissue.¹ Typical signs and symptoms include periorbital swelling, crepitus, pain, proptosis, chemosis, vision changes, and relative afferent pupillary defect.¹ It is normally associated with trauma, although dozens of other etiologies have been reported, including sneezing, nose-blowing, coughing, postoperative complication, and use of a continuous positive airway pressure device.^{1–3} Non-traumatic etiologies are more common in patients who are early middle-aged, female, and have a history of facial trauma, surgery, sinusitis, or tobacco smoking, or have current upper respiratory symptoms.⁴ It is theorized that chronic inflammation and/or remote trauma can weaken the lamina papyracea of the ethmoid sinus, so that positive pressure then causes a fracture and air entry into the orbit.² The differential diagnosis of atraumatic orbital emphysema

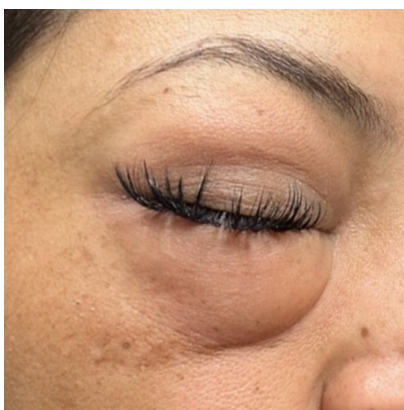

Image 1. Periorbital swelling of the right eye in a female patient.

should include orbital cellulitis, malignancy, orbital foreign body, and hematoma.¹ Apart from age and gender, this patient had no additional risk factors.

When suspected on history and physical examination, a diagnosis is made on CT of the face. Point-of-care ultrasound findings demonstrating air in the subcutaneous tissue can increase the index of suspicion for this entity but cannot definitively establish the diagnosis. Regarding management, most cases resolve in 7–10 days spontaneously. In rare cases, orbital compartment syndrome can develop, with trapped air compressing either the optic nerve itself or the ophthalmic artery, causing ischemia. This is a vision-threatening complication requiring emergent lateral canthotomy and cantholysis or needle decompression.⁵ Orbital compartment syndrome is detected by increased intraocular pressure and abnormal visual acuity on physical examination.⁵

Population Health Research Capsule

What do we already know about this clinical entity?

Orbital emphysema is an uncommon clinical condition usually caused by trauma, though atraumatic etiologies have been reported as well.

What is the major impact of the images?

While examples of orbital emphysema are common, this is the first published example of a point-of-care ultrasound of this condition.

How might this improve emergency medicine practice?

Familiarity with this condition may prompt the clinician to select suitable imaging, screen for orbital compartment syndrome, and consult a specialist.

In this case, the patient's intraocular pressure was only mildly elevated, with normal visual acuity; thus, our on-call ophthalmologist and plastic surgeon recommended expectant management. The patient followed up in plastic surgery clinic three days later with significantly reduced pain and swelling. She was asked to continue to follow sinus precautions, including no nose-blowing, sneezing with mouth closed, straw usage, diving, flying on airplanes, or smoking, for several more weeks.

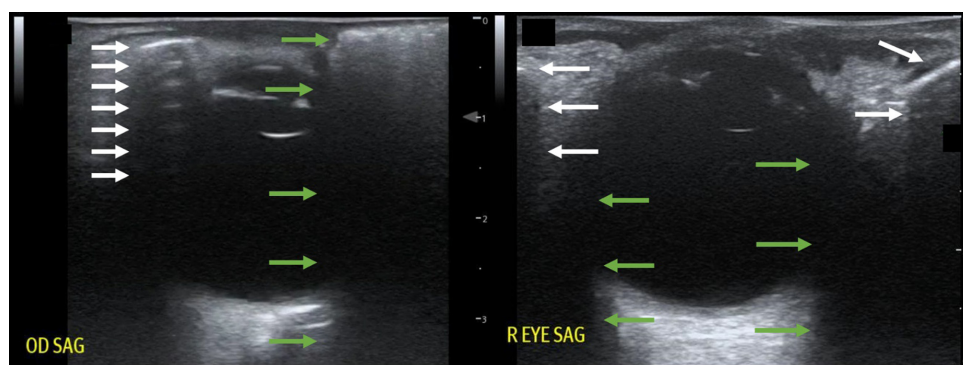


Image 2. Point-of-care ultrasound of the patient's eye (left) compared with a normal eye ultrasound (right). In the patient's ultrasound on the left, a hyperechoic line is seen just below the skin surface (top white arrow), which represents the air-tissue interface of subcutaneous emphysema. Below are equally spaced, repeating lines of reverberation artifact (additional white lines), typical of highly reflective air-tissue interfaces, analogous to "A-lines" on normal lung ultrasound. Comparatively, in the right image, the shadow of the bony orbit in a normal eye ultrasound (white arrows) originates deeper below the skin surface, is sharply demarcated at the edges, and lacks reverberation artifact. Also shown in the patient's ultrasound on the left is the "dirty shadowing" associated with subcutaneous air (green arrows.). Compared to the shadows of edge artifact indicated by the green arrows in the normal ultrasound on the right, these "dirty shadows" originate from an irregular surface, appear more "smeared," and are not well-demarcated at the edges.

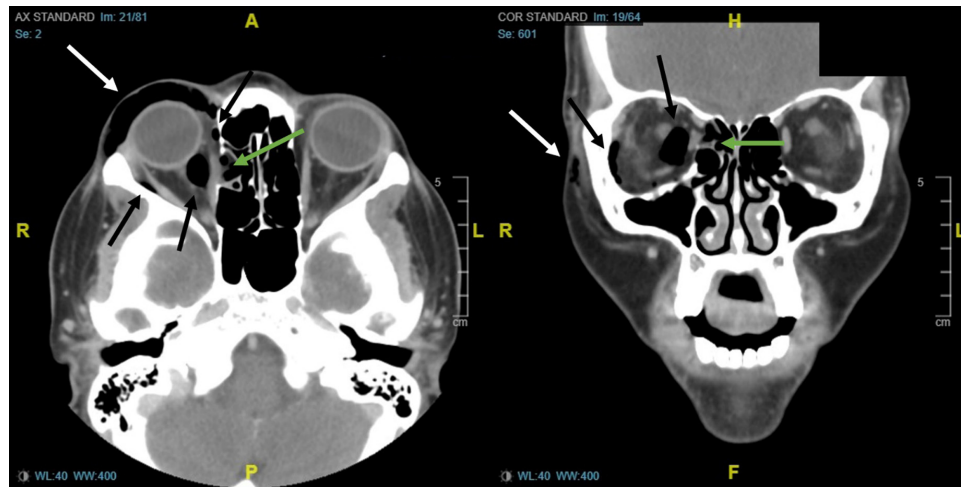


Image 3. Computed tomography of the facial bones, axial view on the left and coronal view on the right, demonstrating subcutaneous periorbital emphysema (white arrows), intraconal orbital space emphysema (black arrows), with a defect in the lamina papyracea of the ethmoid sinus (green arrows).

The authors attest that their institution exempted this case report from Institutional Review Board approval. The patient provided informed consent for publication of this case report. Documentation on file.

Address for Correspondence: Josephine Valenzuela, MD, Department of Emergency Medicine, 2601 E. Roosevelt St., Phoenix, AZ 85008. Email: Josephine_Valenzuela@dmgaz.org

Conflicts of Interest: By the CPC-EM article submission agreement, all authors are required to disclose all affiliations, funding sources and financial or management relationships that could be perceived as potential sources of bias. The authors disclosed none.

Copyright: © 2024 Albornoz et al. This is an open access article distributed in accordance with the terms of the Creative Commons Attribution (CC BY 4.0) License. See: <http://creativecommons.org/licenses/by/4.0/>

REFERENCES

1. Roelofs KA, Starks V, Yoon MK. Orbital emphysema: a case report and comprehensive review of the literature. *Ophthalmic Plast Reconstr Surg.* 2019;35(1):1–6.
2. Gonzalez F, Cal V, Elhendi W. Orbital emphysema after sneezing. *Ophthalmic Plast Reconstr Surg.* 2005;21(4):309–11.
3. Rosh AJ and Sharma R. Orbital emphysema after nose blowing. *J Emerg Med.* 2008;34(3):327–9.
4. Komro JJ, Williams PJ, Lin DJ. Orbital defect and emphysema after nose blowing: a case report and literature review. *Cureus.* 2022;14(12):E32958.
5. McCallum E, Keren S, Lapira M, et al. Orbital compartment syndrome: an update with review of the literature. *Clin Ophthalmol.* 2019;12(6):2189–94.

Child with Closed Head Injury and Persistent Vomiting

Abdullah Khan, MD, FAAD, FACEP

Sidra Medical and Research Centre, Department of Emergency Medicine,
Doha, Qatar

Section Editor: Melanie Heniff, MD, JD

Submission history: Submitted October 28, 2023; Revision received January 17, 2024; Accepted January 26, 2024

Electronically published April 17, 2024

Full text available through open access at http://escholarship.org/uc/uciem_cpccem

DOI: 10.5811/cpcem.4814

Case Presentation: We present the case of a six-year-old child with autism who presented with persistent vomiting in the setting of a closed head injury (CHI). Computed tomography of the head was normal, but due to persistent vomiting a radiograph of the abdomen was done, which showed multiple, rare-earth magnets in the abdomen. There was no history of witnessed ingestion. These magnets had caused enteroenteric fistula formation leading to persistent vomiting.

Discussion: In the setting of CHI, vomiting can be a sign of concussion or intracranial hemorrhage. In cases of CHI where intracranial pathology is ruled out and vomiting still persists, it is important to explore intra-abdominal causes of vomiting, especially in developmentally challenged children as they have higher incidence of unwitnessed foreign body ingestions. [Clin Pract Cases Emerg Med. 2024;8(2)171–173.]

Keywords: *closed head injury; rare-earth magnets; vomiting.*

CASE PRESENTATION

A six-year-old autistic child presented to the emergency department with multiple episodes of non-bloody, non-bilious vomiting after sustaining a closed head injury (CHI). The patient had fallen face forward on the ground from a height of five to six stairsteps. No associated loss of consciousness, seizures, abdominal pain, difficulty breathing, ear, eye, or nasal discharges were reported. The physical examination revealed a two-centimeter contusion on the forehead. The rest of the ocular, auditory, abdominal, respiratory examinations including Glasgow Coma scale were normal. Initially the patient received ondansetron, but vomiting continued after the medication. Due to persistent vomiting, complete blood count, blood electrolytes, liver function tests, lipase level, and urinalysis were obtained from the laboratory, and CT of the head without contrast was performed. All lab tests and CT were normal. A radiograph of the abdomen incidentally showed a cluster of small round balls of rare-earth magnets with no signs of obstruction or pneumoperitoneum (Image 1).

There was no history of witnessed ingestion. General surgery was consulted, and the patient was admitted to the hospital. Initially, the patient was managed conservatively with antiemetics and laxatives; but due to persistent vomiting and lack of movement of the magnets, the patient was taken

to the operating room. During the laparotomy, it was noticed that the magnets had caused formation of an enteroenteric fistula (Image 2). The fistula was divided, the magnets were extracted, and the edges of the fistula were closed. (Image 3). The patient recovered without any complications and was discharged from the hospital.

DISCUSSION

Rare-earth magnets (neodymium magnets) are commercially sold as 3–6 millimeters round recreational objects; they are five to 10 times more powerful than normal magnets. When more than one of these magnets are ingested, the bowel can get compressed between them, which leads to obstruction, necrosis, perforation, and fistula formation.¹ Due to the small size of these magnets, patients can develop localized intestinal perforations and fistulas without significant symptoms and radiologic findings. Therefore, in patients with ingestion of multiple rare-earth magnets, surgical or endoscopic removal of the magnets should be performed even in asymptomatic patients.² The incidence of foreign body ingestion is higher in toddlers and preschool children, whereas a higher incidence of ingestion is noticed at older age in children with neurological disabilities.³ Because foreign body ingestions in these children are often unwitnessed, it presents a challenge in diagnosis.^{1,3} In

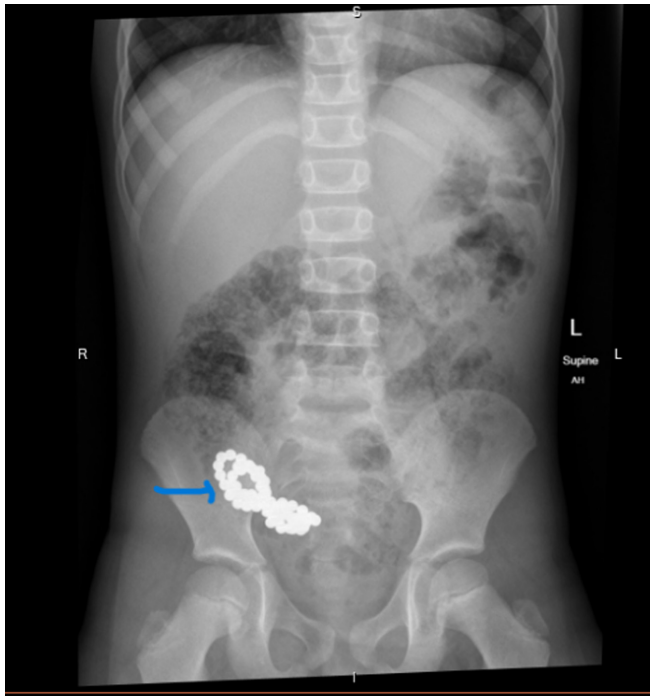


Image 1. Supine radiograph of the abdomen showing multiple rare-earth magnets (blue arrow).

Population Health Research Capsule

What do we already know about this clinical entity?

Rare-earth magnets are more powerful than regular magnets, and when ingested in multiple numbers can cause intestinal complications.

What is the major impact of the image(s)?

In an autistic child presenting with closed head injury, abdominal imaging incidentally showed ingested rare-earth magnets.

How might this improve emergency medicine practice?

Foreign body ingestions should be considered in the differential diagnosis of vomiting, especially when evaluating children with neurodevelopmental disabilities.

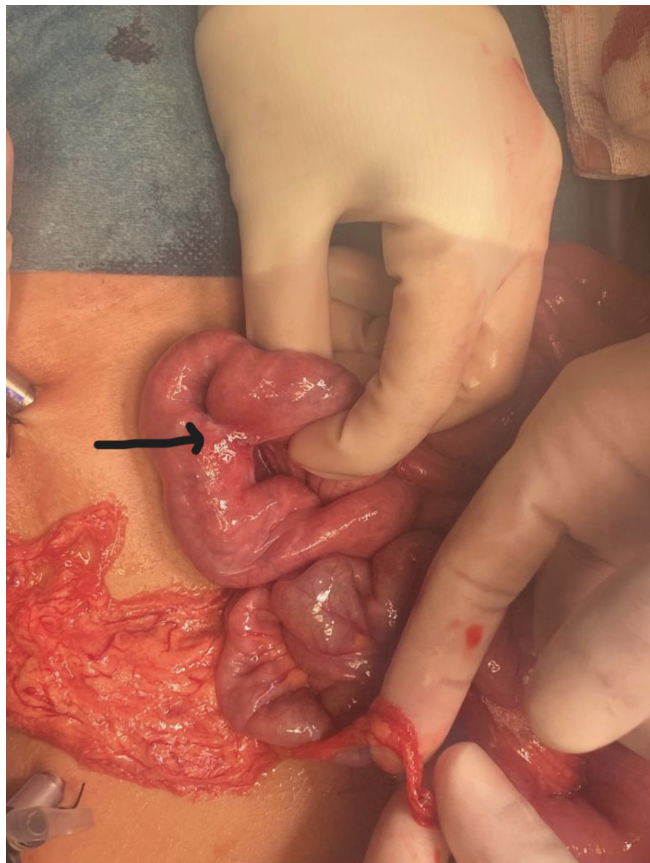


Image 2. View of bowel during laparotomy showing enteroenteric fistula (black arrow).

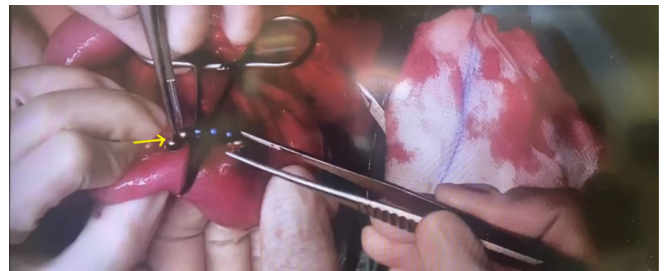

Image 3. Intraoperatively, fistula is resected, and rare-earth magnets are removed (yellow arrow).

summary, foreign body ingestions should be in the differential diagnosis in children with neurological disability presenting with unexplained vomiting. Additionally, in cases with ingestion of multiple rare-earth magnets, conservative management may *not* be the appropriate choice.

The author attest that their institution requires neither Institutional Review Board approval, nor patient consent for publication of this case report. Documentation on file.

Address for Correspondence: Abdullah Khan, MD, FAAD, FACEP, Sidra Medicine Department of Emergency Medicine, Al Gharrafa Street, Ar-Rayyan, Doha, Qatar, PO BOX 3050.
Email: abdullahkhan120@gmail.com

Conflicts of Interest: By the CPC-EM article submission agreement, all authors are required to disclose all affiliations, funding sources and financial or management relationships that could be perceived as potential sources of bias. The authors disclosed none.

Copyright: © 2024 Khan This is an open access article distributed in accordance with the terms of the Creative Commons Attribution (CC BY 4.0) License. See: <http://creativecommons.org/licenses/by/4.0/>

REFERENCES

1. Khan A, Eldos Y, Alansari K. Clinical presentation and outcome of multiple rare earth magnet ingestions in children of Qatar. a single-center experience. *Qatar Med J.* 2023;2023(1):9.
2. Zheng Y, Zhang Z, Yan K, et al. Retrospective analysis of pediatric patients with multiple rare-earth magnets ingestion: a single-center experience from China. *BMC Pediatr.* 2021;21(1):179.
3. Destro F, Caruso AM, Mantegazza C, et al. Foreign body ingestion in neurologically impaired children: a challenging diagnosis and management in pediatric surgery. *Children.* 2021;8(11):956.

Clinical Images in Emergency Medicine: Cushing's Disease

Jason D. Vadhan, DO
Nathaniel Hansen, MD
Fernando L. Benitez, MD
Larissa I. Velez, MD

UT Southwestern Medical Center, Department of Emergency Medicine, Dallas, Texas

Section Editor: Melanie Heniff, MD

Submission history: Submitted October 29, 2023; Revision received July 12, 2023; Accepted July 13, 2023

Electronically published April 9, 2024

Full text available through open access at http://escholarship.org/uc/uciem_cpccem

DOI: 10.5811/cpcem.59302

Case Presentation: A 22-year-old female presented to the emergency department with a two-month history of worsening fatigue, unintentional weight gain, and progressive facial swelling. Physical examination findings included hirsutism, moon facies, and abdominal striae. Subsequent brain magnetic resonance imaging revealed the presence of a 2.4-centimeter pituitary macroadenoma, confirming the diagnosis of Cushing's disease. The patient was then admitted for neurosurgical tumor resection.

Discussion: Cushing's disease is exceedingly rare and often presents with symptoms resembling more prevalent disorders, contributing to delays in diagnosis. Therefore, maintaining a high index of suspicion for this disease is crucial for emergency physicians. [Clin Pract Cases Emerg Med. 2024;8(2)174–175.]

Keywords: *Cushing's disease; Cushing syndrome; pituitary adenoma; case report.*

CASE PRESENTATION

A 22-year-old female with a past medical history of hypertension and diabetes presented to the emergency department with two months of abdominal striae, persistent fatigue, unintentional weight gain exceeding 30 pounds, and progressive facial swelling. Physical exam revealed the presence of abdominal striae (**Image 1**), facial and trapezius adiposity (**Image 2**), and hirsutism (**Image 3**). Since the patient was not receiving steroid therapy at the time, her

symptoms raised suspicion for Cushing's disease. Subsequently, a brain magnetic resonance imaging (MRI) with intravenous contrast was performed, revealing a 2.4-centimeter pituitary macroadenoma causing severe upward displacement of the optic chiasm (**Supplementary Image**). Neurosurgery was sought, and the patient was admitted for operative management.

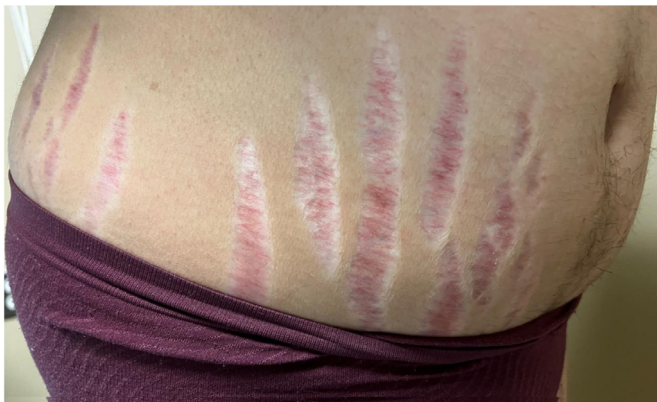

Image 1. Lower abdominal striae due to hypercortisolism.

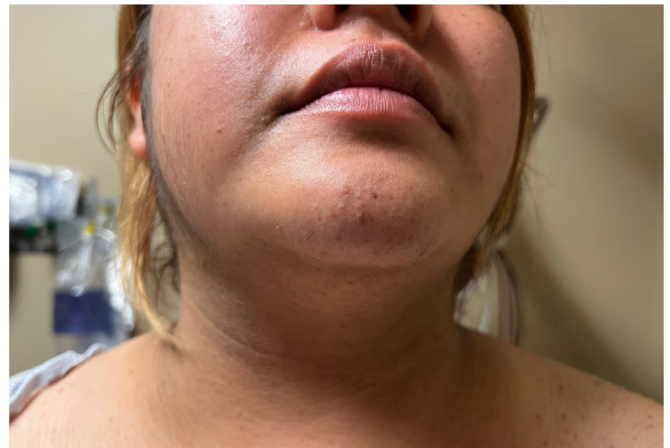

Image 2. Facial and trapezius adiposity, colloquially referred to as "moon facies" and a "buffalo hump."

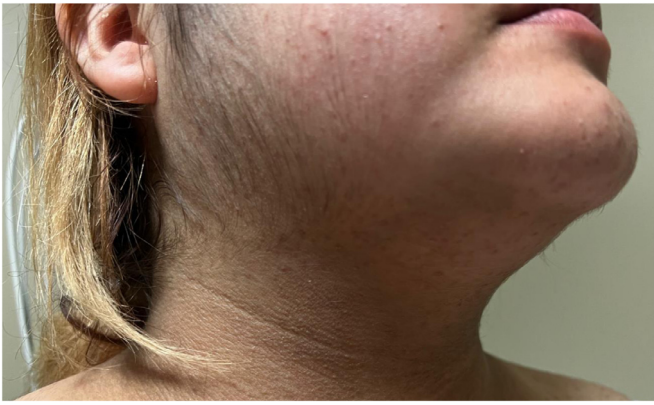

Image 3. Hirsutism of the face due to increased adrenocorticotropic hormone production, resulting in hyperandrogenism.

DISCUSSION

Cushing's disease is a rare disorder characterized by excessive cortisol production from the adrenal glands, which can either be from the adrenals directly or from corticotropin-releasing tumors in the lungs or pituitary gland.¹ The term "Cushing's disease" refers explicitly to the presentation of Cushing's syndrome caused by a pituitary tumor. Cushing's disease is more commonly observed among women, typically appearing between 20–40 years of age.¹ Clinical manifestations are attributed to increased cortisol production, which causes weight gain, fatigue, poor concentration, hypertension, hyperglycemia, excess hair growth, abdominal striae, adipose deposition, and menstrual irregularity.² Unfortunately, these symptoms are nonspecific and overlap with common medical conditions such as diabetes, hypertension, and polycystic ovarian syndrome. Consequently, the diagnosis of Cushing's disease is often delayed, with an average time to diagnosis exceeding three years from symptom onset.³

The evaluation for Cushing's disease is typically initiated in an outpatient setting and involves various tests, including midnight salivary cortisol measurement, low-dose dexamethasone suppression test, or 24-hour urine-free cortisol level assessment.² However, in the emergency department, obtaining a brain MRI may be warranted to detect a visible pituitary tumor, which can be seen approximately 50% of the time, as in this case.² When pituitary tumors are discovered, neurosurgical consultation and operative resection are often necessary.

Patient consent has been obtained and filed for the publication of this case report.

CPC-EM Capsule

What do we already know about this clinical entity?

Cushing's disease, caused by pituitary adenomas, often leads to delayed diagnosis due to nonspecific symptoms.

What makes this presentation of disease reportable?

This report highlights the classic clinical presentation of Cushing's disease including distinctive physical exam findings.

What is the major learning point?

Maintaining a high index of suspicion for rare diseases like Cushing's in the emergency department is essential for timely diagnosis.

How might this improve emergency medicine practice?

Prompt recognition of Cushing's disease symptoms can lead to a timely diagnosis and appropriate definitive care, ultimately improving patient outcomes.

Address for Correspondence: Jason D. Vadhan, UT Southwestern Medical Center, Department of Emergency Medicine, 5200 Harry Hines Blvd, Dallas, TX 53235. Email: jason.vadhan@phhs.org.

Conflicts of Interest: By the CPC-EM article submission agreement, all authors are required to disclose all affiliations, funding sources and financial or management relationships that could be perceived as potential sources of bias. The authors disclosed none.

Copyright: © 2024 Vadhan et al. This is an open access article distributed in accordance with the terms of the Creative Commons Attribution (CC BY 4.0) License. See: <http://creativecommons.org/licenses/by/4.0/>

REFERENCES

1. Gardner DG, Shoback DM. *Greenspan's Basic and Clinical Endocrinology*. New York, NY: McGraw-Hill Education; 2017.
2. Nieman L, Swearingen B. Cushing's syndrome and Cushing's disease. *CMM Global*. 2013;1–12.
3. Rubinstein G, Osswald A, Hoster E, et al. Time to diagnosis in Cushing's syndrome: a meta-analysis based on 5367 patients. *J Clin Endocrinol Metab*. 2019;105(3):e12–22.

One in a Million: A Woman Presenting with Unilateral Painful Ophthalmoplegia

Kevin Bennett, MD
Eric Boccio, MD, MPH

Memorial Healthcare System, Department of Emergency Medicine, Hollywood, Florida

Section Editor: Jacqueline Le, MD

Submission history: Submitted October 9, 2023; Revision received November 22, 2023; Accepted January 8, 2023

Electronically published April 17, 2024

Full text available through open access at http://escholarship.org/uc/uciem_cpceem

DOI: [10.5811/cpcem.2582](https://doi.org/10.5811/cpcem.2582)

Case Presentation: A 52-year-old female presented to the emergency department with four days of right periorbital pain, ipsilateral temporal headache, diplopia, and photophobia. Physical examination of the right eye revealed painful ophthalmoplegia, cranial nerves III and VI paresis, increased intraocular pressure, and mild proptosis. Magnetic resonance venogram and magnetic resonance imaging orbits with contrast demonstrated an abnormal signal surrounding the right cavernous sinus/petrous apex. Tolosa-Hunt syndrome (THS) was diagnosed. Per neurology recommendations, the patient was placed on a steroid regimen over the course of three weeks. She was discharged on hospital day nine following resolution of symptoms. She had no recurrence of symptoms or residual deficits noted at her two-week follow-up appointment.

Discussion: With an estimated annual incidence of one case per million, THS is a sinister etiology of unilateral headache, painful ophthalmoplegia, and oculomotor palsy. Tolosa-Hunt syndrome is caused by granulomatous inflammation in the cavernous sinus and is highly responsive to corticosteroids. Magnetic resonance imaging studies of the cavernous sinus and orbital apex are highly sensitive for THS and characteristically show enlargement and focal-enhancing masses within the affected cavernous sinus. [Clin Pract Cases Emerg Med. 2024;8(2)176–178.]

Keywords: *Tolosa-Hunt syndrome; ophthalmoplegia; cavernous sinus.*

CASE PRESENTATION

A 52-year-old Black female with history of iron deficiency anemia presented to the emergency department with four days of right periorbital pain, ipsilateral temporal headache, diplopia, and photophobia. Incidentally, the patient reported sinus congestion one month prior that had responded to fluticasone propionate intranasal. Triage vital signs were within normal limits. Physical examination of the right eye demonstrated blurry vision with positive light perception, pupil equal, round, and reactive to light, an increased ocular pressure of 39 millimeters of mercury (mm Hg) (reference range: 10–21 mm Hg), and mild proptosis. Cranial nerves III and VI paresis was observed resulting in ptosis and impaired abduction, adduction, and upward and downward gaze. The patient did not tolerate a fundoscopic examination and voluntarily kept her right eyelid closed due to photophobia.

Laboratory tests, including a complete blood count, basic metabolic panel, and urine pregnancy, were unremarkable.

The electrocardiogram demonstrated a normal sinus rhythm. Computed tomography (CT) brain and CT angiogram brain and carotids revealed a cavernous sinus filling defect concerning for sinus venous thrombosis, and a heparin infusion was initiated. Magnetic resonance venogram and magnetic resonance imaging orbits with contrast demonstrated an abnormal signal surrounding the right cavernous sinus and petrous apex ([Image 1](#)).

Tolosa-Hunt syndrome (THS) was diagnosed, and the heparin infusion was discontinued. Neurology was consulted; 250 milligrams (mg) solumedrol intravenous (IV) was administered, and the patient was admitted to the intermediate medical care unit. She underwent a lumbar puncture, which demonstrated a normal opening pressure and negative cerebrospinal fluid analysis. Per neurology recommendations, she was placed on a steroid regimen consisting of three days of 250 mg solumedrol IV daily followed by one week of 80 mg prednisone per os daily followed by a taper of 20 mg per week

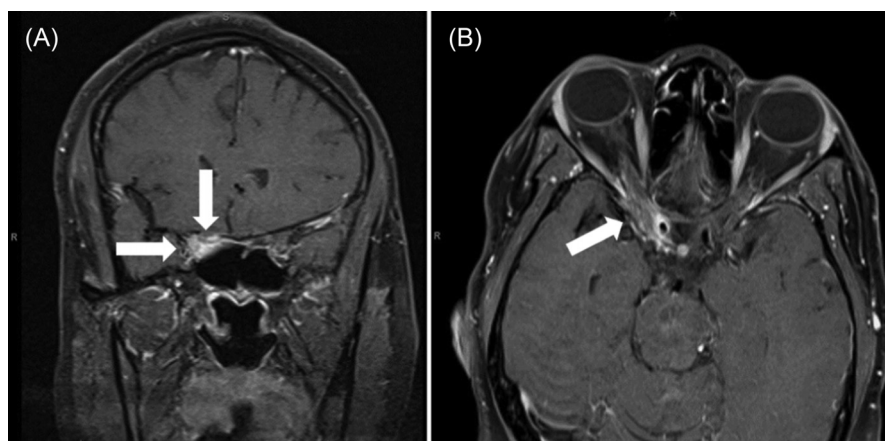


Image 1. Coronal (A) and axial (B) slices of magnetic resonance imaging orbits with contrast demonstrating an abnormal signal surrounding the right cavernous sinus and petrous apex suspicious for Tolosa-Hunt syndrome (arrows).

CPC-EM Capsule

What do we already know about this clinical entity?

Tolosa-Hunt syndrome (THS) is a rare cause of headache, painful ophthalmoplegia, and oculomotor palsy with characteristic findings on MRI.

What is the major impact of the image?

Magnetic resonance imaging of the orbits demonstrating focal enhancement of the affected cavernous sinus and petrous apex is characteristic of THS.

How might this improve emergency medicine practice?

Recognizing the appropriate radiographic modality and findings of THS will lead to earlier diagnosis and therapeutic management while avoiding unnecessary tests.

over the course of three weeks. The patient was discharged on hospital day 9 following resolution of symptoms. She had no recurrence of symptoms nor residual deficits noted at her two-week follow-up appointment.

DISCUSSION

With an estimated annual incidence of one case per million, THS is a sinister etiology of unilateral headache, painful ophthalmoplegia, and oculomotor palsy.^{1,2} The reported average age of onset is 41 years old. (Pediatric cases have only

rarely been described).³ Granulomatous inflammation involving lymphocytes and plasma cells increases the pressure within the cavernous sinus and may result in compression of cranial nerves III, IV, and VI as well as the sympathetic plexus surrounding the internal carotid artery.^{4,5} While the etiology is presumed to be idiopathic, there is a strong association with autoimmune disorders such as systemic lupus erythematosus and sarcoidosis.^{6,7} Magnetic resonance imaging studies of the cavernous sinus and petrous apex are highly sensitive for THS and characteristically show enlargement and focal-enhancing masses within the affected cavernous sinus.^{8,9} While there is no consensus nor are there guidelines for managing symptoms attributed to THS, high-dose steroids are considered first line.¹⁰ Rapid response to steroid therapy is the hallmark of THS, and patients typically recover with no residual deficits.¹¹

The authors attest that their institution requires neither Institutional Review Board approval, nor patient consent for publication of this case report. Documentation on file.

Address for Correspondence: Eric Boccio, MD, MPH, Department of Emergency Medicine, Memorial Healthcare System, 703 N Flamingo Road, Pembroke Pines, FL 33028. Email: eboccio@mhs.net

Conflicts of Interest: By the CPC-EM article submission agreement, all authors are required to disclose all affiliations, funding sources and financial or management relationships that could be perceived as potential sources of bias. The authors disclosed none.

Copyright: © 2024 Bennett et al. This is an open access article distributed in accordance with the terms of the Creative Commons Attribution (CC BY 4.0) License. See: <http://creativecommons.org/licenses/by/4.0/>

REFERENCES

1. Bugeme M, Cissé O, Mukuku O, et al. Tolosa-Hunt syndrome: a painful ophthalmoplegia. *Case Rep Neurol Med.* 2020;2020:8883983.

2. Amrutkar C and Burton EV. Tolosa-Hunt syndrome. In: *StatPearls* [Internet]. 2023. Available at: <https://www.ncbi.nlm.nih.gov/books/NBK459225/>. Accessed October 9, 2023.
3. Tsirigotaki M, Ntoullos G, Lioumpas M, et al. Tolosa-Hunt syndrome: clinical manifestations in children. *Pediatr Neurol*. 2019;99:60–3.
4. Gladstone JP and Dodick DW. Painful ophthalmoplegia: overview with a focus on Tolosa-Hunt syndrome. *Curr Pain Headache Rep*. 2004;8(4):321–9.
5. Kahl N and Pelucio M. Case report of a man with right eye pain and double vision. *J Educ Teach Emerg Med*. 2022;7(1):V22–5.
6. Calistri V, Mostardini C, Pantano P, et al. Tolosa-Hunt syndrome in a patient with systemic lupus erythematosus. *Eur Radiol*. 2002;12(2):341–4.
7. Brandy-García A, Suárez-Cuervo C, Caminal-Montero L. Tolosa-Hunt syndrome as an initial presentation of sarcoidosis. *Reumatol Clin (Engl Ed)*. 2021;17(3):178–9.
8. Cakirer S. MRI findings in Tolosa-Hunt syndrome before and after systemic corticosteroid therapy. *Eur J Radiol*. 2003;45(2):83–90.
9. Jain R, Sawhney S, Koul RL, et al. Tolosa-Hunt syndrome: MRI appearances. *J Med Imaging Radiat Oncol*. 2008;52(5):447–51.
10. Kose A, Bozkurt S, Umay ST, et al. A case of headache, double vision and ptosis in emergency department: Tolosa-Hunt syndrome. *Turk J Emerg Med*. 2017;18(3):134–6.
11. Beckham S, Kim H, Truong A. Painful ophthalmoplegia of the right eye in a 20-year-old man. *J Emerg Med*. 2013;44(2):e231–4.

Rash and Fever in a Returned Traveler

Helena Kons, MD
Elliott D. Herron, BS
Zachary S. Pacheco, MD
Erin F. Shufflebarger, MD, MSPH

University of Alabama at Birmingham Heersink School of Medicine,
Department of Emergency Medicine, Birmingham, Alabama

Section Editor: Steven Walsh, MD

Submission history: Submitted September 30, 2023; Revision received December 8, 2023; Accepted December 11, 2023

Electronically published March 26, 2024

Full text available through open access at http://escholarship.org/uc/uciem_cpccem

DOI: [10.5811/cpcem.1911](https://doi.org/10.5811/cpcem.1911)

Case Presentation: A 21-year-old, otherwise healthy female presented to the emergency department with fever among other nonspecific symptoms after recently returning from Ghana. On physical exam, she had a characteristic upper extremity rash, and a tourniquet test revealed numerous petechiae. The diagnosis of dengue was suspected and subsequently confirmed.

Discussion: Dengue is one of many viral illnesses that should be considered in returning travelers presenting with fever and other nonspecific symptoms. Emergency physicians must keep a broad differential when evaluating fever in returned travelers and prioritize history and physical exam findings to help narrow the diagnosis and provide appropriate management and supportive care while awaiting further confirmatory testing. [Clin Pract Cases Emerg Med. 2024;8(2)179–181.]

Keywords: *fever in returned traveler; tropical medicine; dengue.*

CASE PRESENTATION

A 21-year-old, otherwise healthy female presented to the emergency department (ED) with fever after recently returning from Ghana. She reported intermittent fever, headache with photophobia, diarrhea, joint pains, and generalized weakness. She also noticed a diffuse, intermittently pruritic rash. While in Ghana, she volunteered at a refugee hospital, ate local street food, and had exposure to local animals including dogs, sheep, and a monkey.

On arrival to the ED, she had a temperature of 39.4° Celsius and was tachycardic at 126 beats per minute. Her other vital signs were within normal limits. Physical exam revealed an uncomfortable-appearing female with a maculopapular rash to the extremities and chest, confluent erythema noted in some areas (Image 1), and scattered papules with some surrounding excoriation around the ankles, which the patient stated were mosquito bites. Initial lab results revealed mildly elevated transaminases with alanine transaminase 58 units per liter (U/L) (reference range 7–52 U/L), aspartate aminotransferase 42 U/L (12–39 U/L), thrombocytopenia with platelets 125.3×10^3 per cubic millimeter (mm^3) ($150\text{--}400 \times 10^3/\text{mm}^3$), and leukopenia with white blood cells $2.78 \times 10^3/\text{cmm}$ ($4\text{--}11 \times 10^3/\text{mm}^3$).

A bedside tourniquet test¹ was performed (Image 2) to assess for capillary fragility.

The patient received intravenous fluids and acetaminophen for fever and was started on empiric oral doxycycline to cover for tick-related illness prior to admission for observation. Her labs remained stable, and her symptoms, including fever, improved during her 36-hour hospital stay. Approximately one week after discharge from the hospital, both the dengue fever virus antibodies immunoglobulin G and M resulted positive.

DISCUSSION

Dengue is an acute viral febrile illness transmitted by the *Aedes aegypti* mosquito.² It is endemic to Southeast Asia, Latin America, and Africa.² Within the United States, it remains an uncommon diagnosis, with 814 documented cases reported in 2021.³ Dengue commonly presents with nonspecific symptoms including fever, headache, vomiting, transient macular rash, myalgias and arthralgias.² This nonspecific presentation mimics other viral, bacterial, and parasitic illnesses, making it difficult to diagnose in the acute setting. For example, chikungunya symptoms can mirror those of dengue with fever, rash, and myalgias.⁴

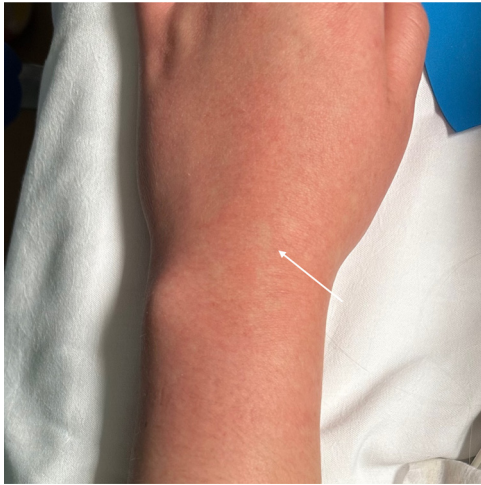


Image 1. Rash on upper extremity with characteristic confluent erythema and small areas of spared skin (arrow).

Malaria is also mosquito-borne and can present with fever and thrombocytopenia.⁴

Focusing on specific details including region(s) visited, timing of fever relative to incubation period, exposures encountered, symptoms experienced, physical exam findings, and lab results can narrow down the pathogen.⁴ Detection of dengue virus antigens remains the diagnostic gold standard; however, this requires time and specialized equipment.⁵ Therefore, emergency physicians must keep a broad differential when evaluating fever in returned travelers and prioritize history and physical exam findings to help narrow

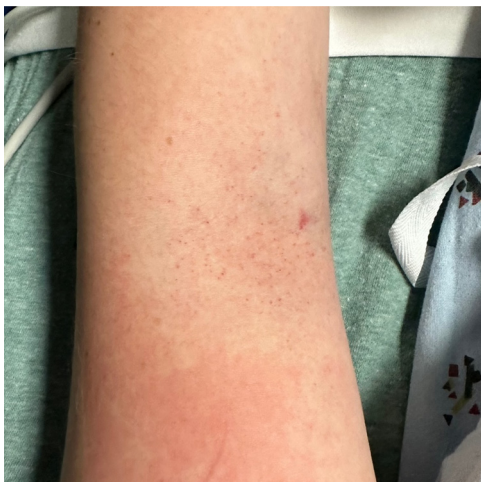

Image 2. Appreciable petechiae visible in the antecubital fossa after inflating a blood pressure cuff around the upper arm for five minutes at a pressure halfway between the patient's systolic and diastolic blood pressure. This "tourniquet test" is deemed positive if more than 10 petechiae are present within a square inch of skin, suggesting capillary fragility.¹

CPC-EM Capsule

What do we already know about this clinical entity?

An acute viral febrile illness transmitted by mosquito, dengue is endemic to Southeast Asia, Latin America, and Africa.

What makes this presentation of disease reportable?

This nonspecific presentation of fever and rash illustrates the challenge of diagnosing mosquito-borne viruses.

What is the major impact of the image?

A "tourniquet test" revealing petechiae helped narrow the diagnosis.

How might this improve emergency medicine practice?

It is necessary to keep a broad differential when evaluating fever in returned travelers and to prioritize history and physical exam findings.

the diagnosis and provide appropriate management while awaiting confirmatory testing.

The authors attest that their institution requires neither Institutional Review Board approval, nor patient consent for publication of this case report. Documentation on file.

Address for Correspondence: Erin F. Shufflebarger, MD, University of Alabama Birmingham Heersink School of Medicine, Department of Emergency Medicine, GSB Suite 203, 521 19th Street South, Birmingham, AL 35233. Email: erinshufflebarger@uabmc.edu

Conflicts of Interest: By the CPC-EM article submission agreement, all authors are required to disclose all affiliations, funding sources and financial or management relationships that could be perceived as potential sources of bias. The authors disclosed none.

Copyright: © 2024 Kons et al. This is an open access article distributed in accordance with the terms of the Creative Commons Attribution (CC BY 4.0) License. See: <http://creativecommons.org/licenses/by/4.0/>

REFERENCES

- Grande AJ, Reid H, Thomas E, et al. Tourniquet test for dengue diagnosis: systematic review and meta-analysis of diagnostic test accuracy. *PLoS Negl Trop Dis.* 2016;10(8):e0004888.

2. World Health Organization. Dengue and severe dengue. 2023. Available at: <https://www.who.int/en/news-room/fact-sheets/detail/dengue-and-severe-dengue>. Accessed September 29, 2023.
3. Centers for Disease Control and Prevention. Dengue: historic data (2010–2022). 2022. Available at: <https://www.cdc.gov/dengue/statistics-maps/2020.html>. Accessed August 1, 2023.
4. Thwaites GE and Day N. Approach to fever in the returning traveler. *N Engl J Med*. 2017;376(6):548–60.
5. Yow KS, Aik J, Tan EY, et al. Rapid diagnostic tests for the detection of recent dengue infections: an evaluation of six kits on clinical specimens. *PLoS One*. 2021;16(4):e0249602.

JOIN
CAL/AAEM!



CALAAEM

CALIFORNIA ACADEMY OF THE
EMERGENCY MEDICINE SOCIETY

*Championing
individual physician rights
and workplace fairness*

BENEFITS

- Western Journal of Emergency Medicine Subscription
- CAL/AAEM News Service email updates
- Discounted AAEM pre-conference fees
- And more!

CAL/AAEM NEWS SERVICE

- Healthcare industry news
- Public policy
- Government issues
- Legal cases and court decisions

In collaboration with our official journal

WestJEM Integrating Emergency Care
with Population Health



[FACEBOOK.COM/CALAAEM](https://www.facebook.com/CALAAEM)



FOLLOW US @CALAAEM

[HTTP://WWW.CALAAEM.ORG](http://www.calaaem.org)



CALIFORNIA ACEP

AMERICAN COLLEGE OF EMERGENCY PHYSICIANS

MEDI-CAL RATE INCREASE

**CALIFORNIA ACEP SECURED
\$200M ANNUALLY TO
INCREASE MEDI-CAL
REIMBURSEMENT FOR
EMERGENCY PHYSICIANS!**

**EMERGENCY MEDICINE IS THE ONLY
SPECIALTY WITH ITS OWN BUDGET
ALLOCATION.**

@CALIFORNIAACEP

www.californiaacep.org