

## Removal of an Aural Foreign Body by Magnetism

Emily Prentice, BA\*  
Emily Bartlett, MD, MS†  
Jonathan S. Ilgen, MD, PhD‡

\*University of Washington School of Medicine, Seattle, Washington  
†University of New Mexico, Albuquerque, Department of Emergency Medicine,  
New Mexico  
‡University of Washington, Department of Emergency Medicine, Seattle, Washington

Section Editor: Christopher Sampson, MD

Submission history: Submitted June 13, 2024; Revision received October 2, 2024; Accepted November 3, 2024

Electronically published January 1, 2025

Full text available through open access at [http://escholarship.org/uc/uciem\\_cpccem](http://escholarship.org/uc/uciem_cpccem)

DOI: 10.5811/cpcem.24845

**Case Presentation:** A male patient in his thirties with a history of polysubstance use presented to the emergency department (ED) due to an abrasion on his left forehead caused by banging his head against a wall in self-injurious behavior. A non-contrast computed tomography of the head obtained to rule out intracranial injury incidentally demonstrated a radiodense foreign body in the left external ear canal. A round metallic foreign body was subsequently visualized on otoscopic examination. The aural foreign body (AFB) was identified as a metallic bead that the patient had placed into his own ear; however, he reported no associated discomfort, hearing changes, or discharge. Traditional approaches for removing AFBs were considered; however, due to the position and smooth surface of the bead, there was concern they would be unsuccessful. Recognizing the metallic nature of the AFB, the clinician held a ceramic donut magnet adjacent to the patient's ear and subsequently extracted the AFB without complication or patient discomfort.

**Discussion:** Aural foreign bodies account for a significant number of visits to EDs annually. Removal of AFBs can be challenging, often requiring specialized equipment or specialty referral for management. Using magnetism over short distances for the purpose of extracting metallic AFBs presents a low-cost, low-risk intervention. When used in applicable scenarios, this technique can decrease the need for specialty referral and can especially benefit patients seeking care in less-resourced settings. [Clin Pract Cases Emerg Med. 2025;19(1):114-116.]

**Keywords:** *aural foreign body; magnetic bead.*

### CASE PRESENTATION

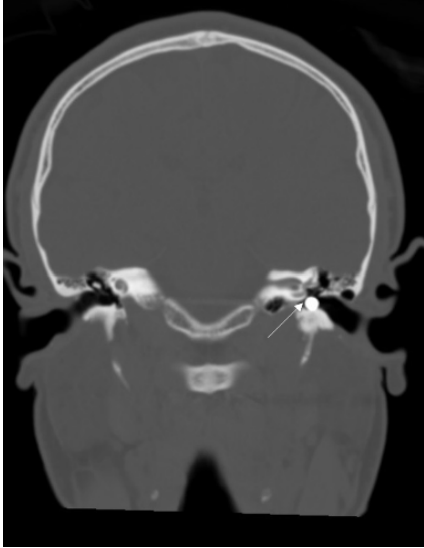
A male patient in his thirties with a history of polysubstance use was evaluated in the emergency department after hitting his head against a wall in self-injurious behavior. He had an abrasion to his left forehead and an otherwise unremarkable physical examination. A non-contrast computed tomography of the head was obtained, which ruled out intracranial injury. This imaging incidentally demonstrated a radiodense foreign body in the left external auditory canal, and a round metallic foreign body was subsequently visualized on otoscopic examination (Image 1).

When questioned, the patient reported placing a string of magnetic beads in his left ear, previously using the magnetic forces of other beads to remove these foreign bodies on his


own. He was aware that a metallic foreign object remained in his external auditory canal but had been unsuccessful in attempts to remove it. He experienced no discomfort or other auditory complaints in the context of this foreign body.

We considered several approaches to remove the aural foreign body (AFB).<sup>1</sup> Due to the positioning of the round sphere in the ear canal, a speculum or jet of fluid would not have been able to reach around it and would likely have pushed the AFB further into the canal. Use of cyanoacrylate glue on the tip of a swab was also considered; however, there was concern it would not adhere well to the smooth metal surface. Specialized suction catheters were not readily available in our ED. A ceramic donut magnet from the code cart—typically used to temporarily induce pacemakers into

asynchronous mode—was obtained. When the donut magnet was held adjacent to the patient's left ear, the magnetic sphere emerged from the ear canal and adhered to the magnet (Image 2). The procedure was well tolerated by the patient with no reported discomfort or complications.



**Image 1.** Coronal view of non-contrast computed tomography of the head. White arrow points to metallic foreign body in the patient's left external auditory canal.



**Image 2.** White arrow pointing to magnetic foreign body on the ceramic donut magnet after removal from the patient's external auditory canal.

## DISCUSSION

Spherical, non-graspable foreign bodies often require specialist referral and potential removal under anesthesia.<sup>1</sup> In this case, we quickly and easily removed a magnetic spherical foreign object using a ceramic donut magnet, obviating the need for specialty consultation. Although the use of magnetized instruments for this purpose has been described anecdotally,<sup>2</sup>

### *CPC-EM Capsule*

What do we already know about this clinical entity?

*Removal of aural foreign bodies (AFB) can be challenging, often requiring specialized equipment or specialty referral for management.*

What is the major impact of the image(s)?

*Using a ceramic donut magnet, a device commonly available in emergency departments, to remove a metallic AFB is a low-cost and easily accessible intervention.*

How might this improve emergency medicine practice?

*This low-cost, low-risk intervention would be especially useful in settings with less access to specialty care.*

to our knowledge this is the first published report of removal of an AFB by magnetic force acting over a distance. Magnets are commonly found in EDs, and this technique could be readily adopted without the need to purchase specialized equipment. Additionally, the use of magnets to remove AFBs may be applicable to objects that are permanent magnets as well as metallic foreign bodies susceptible to induced magnetism.<sup>3</sup>

A study using the National Electronic Injury Surveillance System reported that over a five-year period 250,000 ED visits were due to AFBs.<sup>4</sup> However, access to otolaryngology for specialized management varies widely depending on location, and 65.7% of counties in the United States do not have a practicing otolaryngologist.<sup>5</sup> This case describes the use of a low-cost, low-risk intervention for removal of magnetic foreign bodies, which can aid in patient care especially in lower resource settings with less access to specialty care.

---

*Address for Correspondence:* Jonathan Ilgen, MD, PhD, Department of Emergency Medicine, University of Washington, Harborview Medical Center, 325 9th Avenue, Box 359702, Seattle, WA, 98104. Email: [ilgen@uw.edu](mailto:ilgen@uw.edu).

*Conflicts of Interest:* By the *CPC-EM* article submission agreement, all authors are required to disclose all affiliations, funding sources and financial or management relationships that could be perceived as potential sources of bias. The authors disclosed none.

*Copyright:* © 2025 Prentice et al. This is an open access article distributed in accordance with the terms of the Creative Commons Attribution ([CC BY 4.0](http://creativecommons.org/licenses/by/4.0/)) License. See: <http://creativecommons.org/licenses/by/4.0/>

---

Documented patient informed consent has been obtained and filed for publication of this case report. The authors attest that their institution does not require Institutional Review Board approval for publication of this case report. Documentation on file.

## REFERENCES

1. Friedman EM. Removal of Foreign Bodies from the Ear and Nose. *N Engl J Med*. 2016;374(7):E7-U6.
2. Mellick LB. Using a magnetic pick-up tool for ear foreign body removal. Available at: <https://www.youtube.com/watch?v=HiVtldiwIS8>. Accessed October 31, 2024.
3. Brod RC and Schlang HA. Removal of metallic foreign body by magnetic force. *JAMA*. 1962;179:164-5.
4. Svider PF, Vong A, Sheyn A, et al. What are we putting in our ears? A consumer product analysis of aural foreign bodies. *Laryngoscope*. 2015;125(3):709-14
5. Vickery TW, Weterings R, Cabrera-Muffly C. Geographic distribution of otolaryngologists in the United States. *Ear, Nose, Throat J*. 2016;95(6):218-23.