

The Daughter Cyst

Adrianna Kyle, DO
Maxwell Cooper, MD
Katrina Destree, MD
Lauren Oliveira, DO
Matthew Lawrence, MD

Naval Medical Center Portsmouth, Department of Emergency Medicine, Portsmouth, Virginia

Section Editor: Rick A. McPheeters, DO

Submission history: Submitted September 12, 2016; Revision received November 22, 2016; Accepted November 28, 2016

Electronically published January 23, 2017

Full text available through open access at http://escholarship.org/uc/uciem_cpem

DOI: 10.5811/cpcem.2016.11.32453

[Clin Pract Cases Emerg Med. 2017;1(1):69–70.]

CASE REPORT

A 35-year-old woman, gravida 4 para 3 estimated at 9+1 weeks gestational age by uncertain last menstrual period, presented with vaginal bleeding. She endorsed unprotected intercourse eight weeks prior and took Plan B One-Step (“morning-after pill”) within 48 hours. Quantitative human chorionic gonadotropin (hcg) resulted at 30 mIU/ml. Bedside transabdominal ultrasound was concerning for ectopic pregnancy (Video). Is this ectopic pregnancy?

Radiology performed a transvaginal ultrasound, which was negative for intrauterine or ectopic pregnancy. Obstetric consultants were uncertain if the structure seen at bedside represented an ectopic (Image). Radiology believed that this

structure, which appeared initially to be an extra-uterine yolk sac, was instead a daughter cyst. The patient was well appearing and hemodynamically stable. She was discharged with ectopic precautions and a repeat 48-hour quantitative hcg, which ultimately trended to 0.

DISCUSSION

The daughter cyst sign indicates an uncomplicated ovarian cyst.¹ It is a peripherally based simple cyst within a larger simple cyst.² On pathology, it represents a stimulated ovarian follicle.² This sonographic finding must be differentiated from an ectopic pregnancy in any woman with the potential to become pregnant.¹ Previously documented cases in the literature

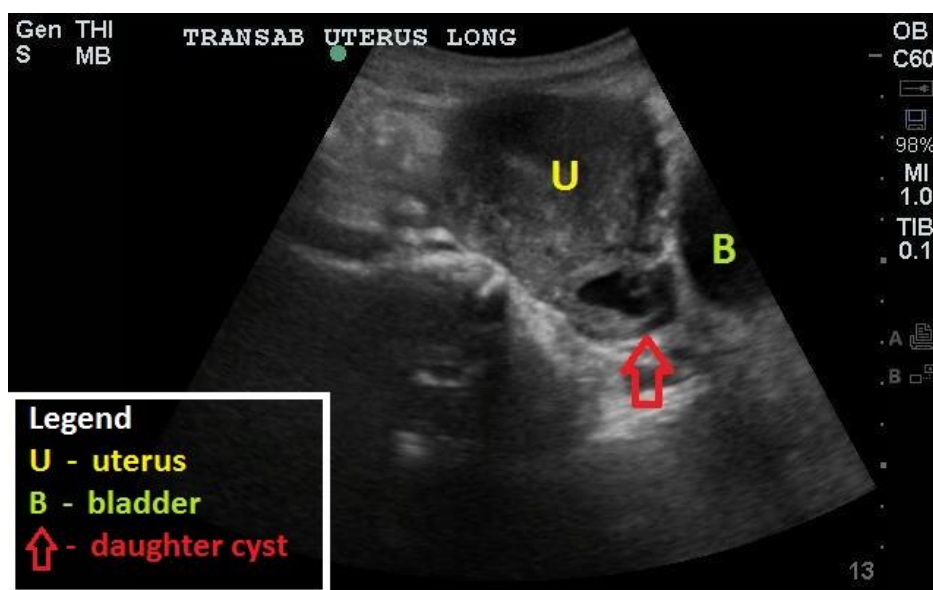


Image. Point-of-care transabdominal ultrasound demonstrating the uterus and daughter cyst in the sagittal plane.

are limited to case reports involving pediatric females with McCune –Albright Syndrome and precocious puberty, as well as fetuses with incidental cysts mimicking ectopic pregnancy.^{1,2} Differentiation can be made with a quantitative hcg, which is negative in the case of the daughter cyst. Differentiation is also made sonographically with a “ring of fire” sign on the structure’s periphery, indicative of increased color Doppler flow to an ectopic pregnancy, whereas a true daughter cyst has no increased flow.¹ In the case of our patient, she had a down-trending hcg due to recent administration of Plan B for unwanted pregnancy, and an incidentally noted daughter cyst that was initially concerning for an ovarian pregnancy.

Video. Point-of-care transabdominal ultrasound video clip demonstrating the uterus and daughter cyst in the axial plane.

Address for Correspondence: Adrianna Kyle, DO, Naval Medical Center Portsmouth, 620 John Paul Jones Circle, Portsmouth, VA 23708. Email: aamarillo831@gmail.com.

Conflicts of Interest: By the *CPC-EM* article submission agreement, all authors are required to disclose all affiliations, funding sources and financial or management relationships

that could be perceived as potential sources of bias. The views expressed in this article are those of the author and do not necessarily reflect the official policy or position of the Department of the Navy, Department of Defense or the United States Government.

I am a military service member. This work was prepared as part of my official duties. Title 17 U.S.C. 105 provides that ‘Copyright protection under this title is not available for any work of the United States Government.’ Title 17 U.S.C 101 defines a United States Government work as a work prepared by a military service member or employee of the United States Government as part of that person’s official duties.

Copyright: © 2017 Kyle et al. This is an open access article distributed in accordance with the terms of the Creative Commons Attribution ([CC BY 4.0](http://creativecommons.org/licenses/by/4.0/)) License. See: <http://creativecommons.org/licenses/by/4.0/>

REFERENCES

1. Randazzo WT, Franco A, Hoossainy S, et al. Daughter cyst sign. *J Radiol Case Rep.* 2012;6(11):43-7.
2. Quarello E, Gorincour G, Merrot T, et al. The ‘daughter cyst sign’: a sonographic clue to the diagnosis of fetal ovarian cyst. *Ultrasound Obstet Gynecol.* 2003;22(4):433-4.