

Play Turned Painful: A Teenager's Tibial Pilon Fracture from A Simple Jump

Victoria M Koniuk, BS, OMS IV
Brody M Fogleman, BS, OMS IV
Lindsay Tjiattas-Saleski, DO, MBA

Edward Via College of Osteopathic Medicine – Carolinas, Department of
Emergency Medicine, Spartanburg, South Carolina

Editor: R. Gentry Wilkerson, DO

Submission history: Submitted September 9, 2024; Revision received November 16, 2024; Accepted December 5, 2024

Electronically published January 26, 2025

Full text available through open access at http://escholarship.org/uc/uciem_cpceem

DOI: 10.5811/cpceem.35491

Case Presentation: An 18-year-old male presented with severe left ankle pain and inability to bear weight after jumping from a three-foot platform. Physical examination revealed decreased range of motion of the left ankle without visible deformity or neurovascular deficits. Imaging studies showed a vertical fracture of the distal tibia—a pilon fracture without fibular involvement.

Discussion: Pilon fractures involve the distal tibial articular surface and are rare. They typically result from high-energy trauma and often involve the fibula. This case illustrates a low-energy mechanism resulting in a pilon fracture without fibular involvement in a young patient without typical risk factors. It highlights the importance of considering pilon fractures in low-energy ankle injuries and the need for appropriate management even in less-complex cases. [Clin Pract Cases Emerg Med. 2025;19(1):102-104.]

Keywords: *tibial pilon fracture; tibial plafond fracture; low-energy trauma; open reduction internal fixation.*

CASE PRESENTATION

An 18-year-old male presented to the emergency department with severe pain and inability to bear weight on his left leg following a jump from a three-foot-high platform while playing an airsoft game. The patient remembered landing equally on both feet at the time of impact. Physical examination revealed decreased range of motion of the left ankle, no visible deformity, and intact neurovasculature. An ankle plain-film radiograph and follow-up computed tomography were obtained as seen in Image 1 and Image 2, respectively.

DISCUSSION

Pilon fractures, also known as tibial plafond fractures, are a subtype of lower extremity fractures that involve the distal articular surface of the tibia, accounting for less than 1% of all lower extremity fractures¹ and 7-10% of all tibial

fractures.² Approximately 90% of pilon fractures are associated with concomitant fibula fractures.³ Mechanisms of injury are most often high-energy, axial loading¹ injuries causing the talus to advance distally resulting in impaction and comminution of the tibial metaphysis.⁴ Although low-energy mechanisms of injury are less common, studies have postulated that risk factors include increased age and a history of osteoporosis, neither of which were applicable to this patient.⁵

Although current management strategies are based upon research focusing on highly comminuted fibula-involving pilon fractures, there is less evidence on appropriate management of low-energy, fibula-sparing cases. Current literature shows that splinting or external fixation along with orthopedic consultation is the necessary initial management.⁵ This case emphasizes the importance of including pilon

fractures in a differential diagnosis and investigating appropriate management for low-energy, less-complex fracture subtypes, even when the affected patient's demographics do not necessarily match the associated risk factors for this condition.

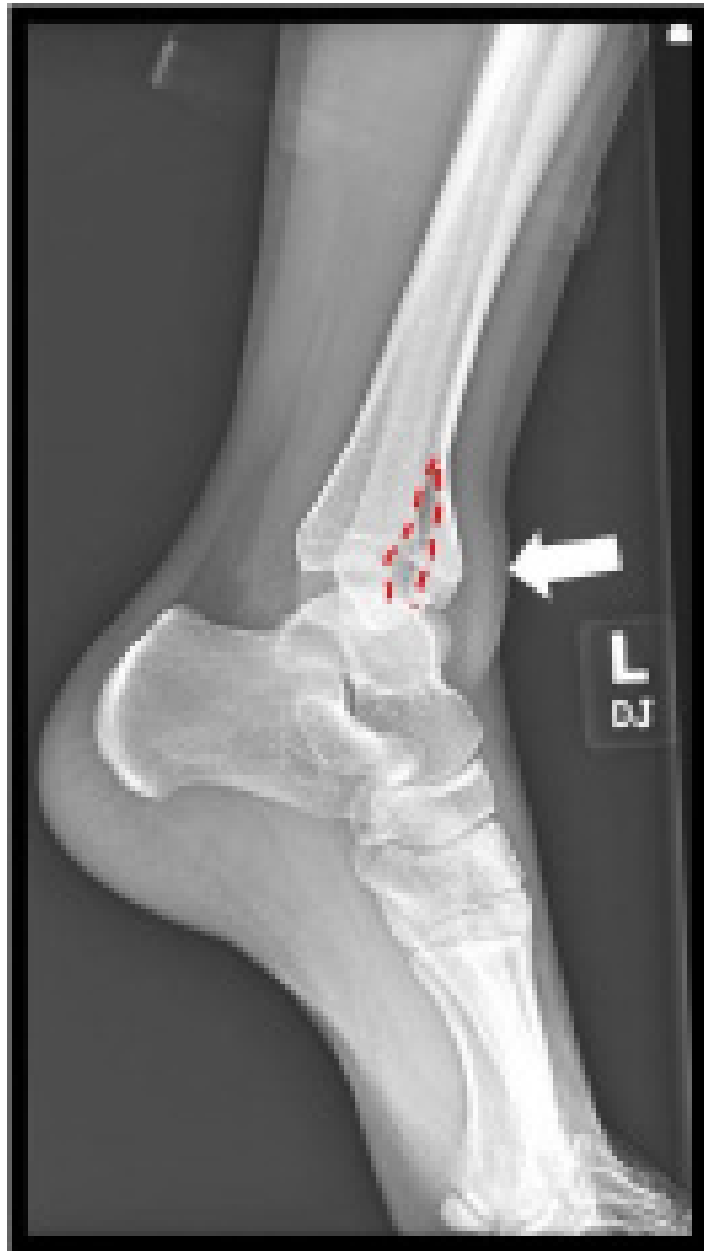

Image 1. Lateral view plain film reveals a vertical fracture of the distal tibia (red dashed line) and soft-tissue swelling (white arrow).

CPC-EM Capsule

What do we already know about this clinical entity?

Pilon fractures are rare tibial fractures involving the distal articular surface, typically from high-energy trauma, often with fibula fractures.

What is the major impact of the image(s)?

The lateral plain film and computed tomography reveal a vertical tibial fracture without fibular involvement, offering a visual representation of a low-energy pilon fracture.

How might this improve emergency medicine practice?

This case emphasizes the need to consider pilon fractures in low-energy trauma, the importance of imaging for appropriate management, and highlights unusual demographics.

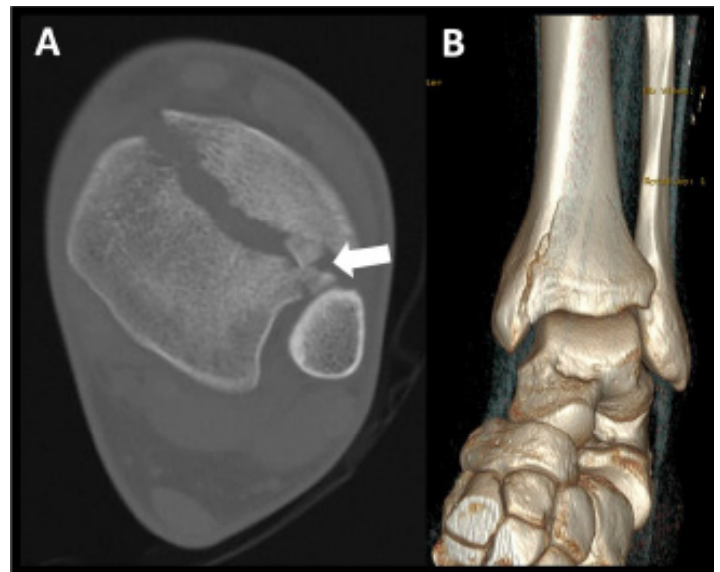


Image 2. Computed tomography without contrast in the transverse plane shows a distal fracture line with bone fragments interposed, as indicated by the white arrow (A), and a three-dimensional rendering (B) reveals a fracture of the distal tibia without fibular involvement.

The authors attest that their institution does not require Institutional Review Board approval for publication of this case report. Patient consent has been obtained and filed for the publication of this case report.

Address for Correspondence: Victoria Mae Koniuk, BS, OMS IV, Edward Via College of Osteopathic Medicine – Carolinas, Department of Emergency Medicine, 350 Howard St, Spartanburg, SC 29303. Email: vkoniuk@carolinas.vcom.edu.

Conflicts of Interest: By the CPC-EM article submission agreement, all authors are required to disclose all affiliations, funding sources and financial or management relationships that could be perceived as potential sources of bias. The authors disclosed none.

Copyright: © 2025 Koniuk et al. This is an open access article distributed in accordance with the terms of the Creative Commons Attribution (CC BY 4.0) License. See: <http://creativecommons.org/licenses/by/4.0/>

REFERENCES

1. Saad BN, Yingling JM, Liporace FA, et al. Pilon fractures: challenges and solutions. *Orthop Res Rev.* 2019;11:149-57.
2. Prabhu S, Neelakrishnan R, Barathiselvan V, et al. Prospective and retrospective study of managing tibial pilon fractures using various modalities of treatment. *Int J Orthop Sci.* 2020;6(4):554-61.
3. Bastias C and Lagos L. New Principles in Pilon Fracture Management: Revisiting Rüedi and Allgöwer Concepts. *Foot Ankle Clin.* 2020;25(4):505–21.
4. Jacob N, Amin A, Giotakis N, et al. Management of high-energy tibial pilon fractures. *Strategies Trauma Limb Reconstr.* 2015;10(3):137-47.
5. Mair O, Pflüger P, Hoffeld K, et al. Management of pilon fractures—current concepts. *Front Surg.* 2021;8:764232.