

CPC Emergency Medicine

Volume I, Number 2, May 2017

Open Access at www.cpcem.org

ISSN: 2474-252X

Clinical Practice and Cases in Emergency Medicine

In Collaboration with the Western Journal of Emergency Medicine

Clinicopathological Cases from the University of Maryland

- 76 **13-year-old Girl with Fevers**
M Cobb, E Gorman, LJ Bontempo, ZDW Dezman

Case Reports

- 81 **Inadvertent Intrathecal Administration of Local Anesthetics Leading to Spinal Paralysis with Lipid Emulsion Rescue**
A Gupta, GL Procopio, PH Charles, M Hernandez, R Patel
- 84 **Nonspecific Headache Diagnosed as a Brain Colloid Cyst with Hydrocephalus**
C Carroll, M Riddle
- 87 **Avulsion of the Lesser Trochanter Following a Shot Put Sport Session**
MH Grissa, N Bzeouich, M Zrig, H Boubaker, MA Msolli, A Abid, S Nouira, A Montgomery
- 89 **Pyogenic Flexor Tenosynovitis in an Infant**
Jl Gragg, R Olsen, SB Stringham
- 92 **Emphysematous Pyelonephritis: Bedside Ultrasound Diagnosis in the Emergency Department**
G McCafferty, A Shorette, S Singh, G Budhram
- 95 **Wernicke's Encephalopathy in a Patient Without Chronic Alcohol Abuse**
D Thota, S Rudinsky
- 98 **Burn-induced Myxedema Crisis**
AS Batista, LL Zane, LM Smith
- 101 **A Novel Source of Chest Pain in the Emergency Department**
I Isa, JS Bush, S Watson, J Schoepf
- 104 **Phelgmasia Cerulea Dolens Diagnosed by Point-of-Care Ultrasound**
M Schroeder, A Shorette, S Singh, G Budhram
- 108 **Intermittent Ovarian Torsion in Pregnancy**
R Young, K Cork

Contents continued on page iii



UC Irvine Health



A Peer-Reviewed, International Professional Journal

ACOEP's

SCIENTIFIC ASSEMBLY

SAVE THE DATE

NOVEMBER 4-8, 2017

HYATT REGENCY, DENVER, COLORADO

Save the Date for ACOEP's Flagship Conference

Don't miss out on:

- Keynote speaker Zubin Damania, MD, aka ZDogg
- Kickoff Party in downtown Denver presented by Island Medical Management
- Expanded Tachy Track
- Customizable experience through breakout lecture series
- Pre-Conference Tracks including: Wilderness Medicine, Resuscitation, Advanced Ultrasound, Advanced Airway
- 7th Annual FOEM Legacy Gala: Dinner and Awards Ceremony presented by US Acute Care Solutions
- ...and much more!

Visit www.acoep.org/scientific for more information!

Clinical Practice and Cases in Emergency Medicine

In Collaboration with the *Western Journal of Emergency Medicine*

Rick A. McPheeters, DO, Editor-in-Chief
Kern Medical

Manish Amin, DO, Associate Editor
Kern Medical

Mark I. Langdorf, MD, MHPE, Associate Editor
University of California, Irvine School of Medicine

Shadi Lahham, MD, MS, Associate Editor
University of California, Irvine School of Medicine

Shahram Lotfipour, MD, MPH, Managing Associate Editor
University of California, Irvine School of Medicine

Editorial Board

Erik D. Barton, MD, MBA
University of California, Irvine

Peter A. Bell, DO, MBA
*Ohio University, Heritage
College of Osteopathic Medicine*

Barry E. Brenner, MD, MPH
Case Western Reserve University

David F.M. Brown, MD
*Massachusetts General Hospital/
Harvard Medical School*

Francis Counselman, MD
Eastern Virginia Medical School

Robert W. Derlet, MD
University of California, Davis

Daniel J. Dire, MD
*University of Texas Health
Sciences Center San Antonio*

Steven Gabaeff, MD
Clinical Forensic Medicine

Brent King, MD, MMM
University of Texas, Houston

Edward Michelson, MD
Texas Tech University

Linda S. Murphy, MLIS
*University of California, Irvine
School of Medicine Librarian*

Jonathan Olshaker, MD
Boston University

Edward Panacek, MD, MPH
University of South Alabama

Niels K. Rathlev, MD
*University of Massachusetts
Baystate School of Medicine*

Robert M. Rodriguez, MD
*University of California, San
Francisco*

Scott Rudkin, MD, MBA
University of California, Irvine

Peter Sokolove, MD
*University of California, San
Francisco*

Samuel J. Stratton, MD, MPH
Orange County, CA, EMS Agency

Robert Suter, DO, MHA
UT Southwestern Medical Center

Scott Zeller, MD
University of California, Riverside

Leslie Zun, MD, MBA
Chicago Medical School

Advisory Board

Peter A. Bell, DO, MBA
*American College of Osteopathic
Emergency Physicians
Ohio University, Heritage
College of Osteopathic Medicine*

John B. Christensen, MD
*California Chapter Division of
AAEM*

Amal Khalil, MBA
UC Irvine Health SOM

Mark I. Langdorf, MD, MHPE
UC Irvine Health SOM

Elena Lopez-Gusman
*California ACEP
American College of Emergency
Physicians*

Shahram Lotfipour, MD, MPH
UC Irvine Health SOM

Trevor Mills, MD, MPH
*California Chapter Division of
AAEM
LSU Medical Center*

Aimee Moulin, MD
*California ACEP
American College of Emergency
Physicians
University of California, Davis*

Nicholas T. Sawyer, MD, MBA
*California ACEP
American College of Emergency
Physicians
University of California, Davis*

Robert Suter, DO, MHA
*American College of Osteopathic
Emergency Physicians
UT Southwestern Medical Center*

Jan Wachtler
*American College of Osteopathic
Emergency Physicians*

International Editorial Board

Pablo Aguilera, MD
*Pontificia Universidad Catolica
de Chile, Santiago, Chile*

Anwar Al-Awadhi, MD
*Mubarak Al-Kabeer Hospital,
Jabriya, Kuwait*

Arif A. Cevik, MD
*Eskisehir Osmangazi University
Medical Center, Eskisehir, Turkey*

Francesco Dellacorte, MD
*Azienda Ospedaliera
Universitaria "Maggiore della
Carità," Novara, Italy*

Abhinandan A. Desai, MD
*University of Bombay Grant
Medical College, Bombay, India*

Gayle Galleta, MD
*Sørlandet Sykehus HF, Akershus
Universitetssykehus, Lorenskog,
Norway*

Vijay Gautam, MBBS
*University of London, London,
England*

Wirachin Hoonpongsimanont,
MD, MSBATS

*Siriraj Hospital, Mahidol
University, Bangkok, Thailand*

Rosidah Ibrahim, MD
*Hospital Serdang, Selangor,
Malaysia*

Katsuhiko Kanemaru, MD
*University of Miyazaki Hospital,
Miyazaki, Japan*

Amin A. Kazzi, MAAEM, MD
*The American University of
Beirut, Beirut, Lebanon*

Steven H. Lim, MD
*Changi General Hospital, Simei,
Singapore*

Khrongwong Musikatavorn, MD
*King Chulalongkorn Memorial
Hospital, Chulalongkorn
University, Bangkok, Thailand*

Bandr Mzahim, MD
*King Fahad Medical City, Riyadh,
Saudi Arabia*

Jacob (Kobi) Peleg, PhD, MPH
*Tel-Aviv University, Tel-Aviv,
Israel*

Editorial Staff

Joyce Y. Kim, BS
Editorial Director

Usman Alam, BS
Marketing Director

June Casey, BA
Copy Editor

Maryam Farooqui, BS
Associate Editorial Director

Alissa Fiorentino
WestJEM Staff Liaison

Ahdilah Haswary, BS
Associate Publishing Director

Nancy Hernandez, BA
Associate Publishing Director

Samantha Shwe, BS
Publishing Director

Clinical Practice and Cases in Emergency Medicine

In Collaboration with the *Western Journal of Emergency Medicine*

This open access publication would not be possible without the generous and continual financial support of our society sponsors, department subscribers, and chapter subscribers.

Professional Society Sponsors

AMERICAN COLLEGE OF OSTEOPATHIC EMERGENCY PHYSICIANS

CALIFORNIA ACEP

CALIFORNIA CHAPTER DIVISION OF

AMERICAN ACADEMY OF EMERGENCY MEDICINE

Academic Department of Emergency Medicine Subscriber

Allegheny Health Network Pittsburgh, PA	INTEGRIS Health Oklahoma City, OK	Oklahoma University Norman, OK	University of Illinois at Chicago Chicago, IL
American University of Beirut Beirut, Lebanon	Kaweah Delta Health Care District Visalia, CA	Oregon Health and Science University Portland, OR	University of Iowa Iowa City, IA
Arrowhead Regional Medical Center Colton, CA	Kennedy University Hospitals Turnersville, NJ	Penn State Milton S. Hershey Medical Center Hershey, PA	University of Louisville Louisville, KY
Baystate Medical Center/Tufts University Springfield, MA	Kern Medical Bakersfield, CA	Presence Resurrection Medical Center Chicago, IL	University of Maryland Baltimore, MD
Beaumont Hospital Royal Oak, MI	Lakeland HealthCare St. Joseph, MI	Regions Hospital/ Health Partners Institute for Education and Research St. Paul, MN	University of Massachusetts Medical School Worcester, MA
Beth Israel Deaconess Medical Center Boston, MA	Lehigh Valley Hospital and Health Network Allentown, PA	Robert Wood Johnson Hospital New Brunswick, NJ	University of Michigan Ann Arbor, MI
Boston Medical Center Boston, MA	Loma Linda University Medical Center Loma Linda, CA	Southern Illinois University Carbondale, IL	University of Missouri Columbia, MO
Brigham and Women's Hospital Boston, MA	Louisiana State University Health Sciences Center New Orleans, LA	Stanford University Palo Alto, CA	University of Nebraska Medical Center Omaha, NE
Brown University Providence, RI	Madigan Army Medical Center Tacoma, WA	SUNY Upstate Medical Center Syracuse, NY	University of Nevada Las Vegas, NV
California Chapter Division of AAEM Milwaukee, WI	Maimonides Medical Center Brooklyn, NY	Temple University Philadelphia, PA	University of Oklahoma Norman, OK
California State University Fresno Fresno, CA	Maricopa Medical Center Phoenix, AZ	University of Alabama, Birmingham Birmingham, AL	University of South Alabama Mobile, AL
Carl R. Darnall Army Medical Center Fort Hood, TX	Massachusetts General Hospital Boston, MA	University of Arizona Tucson, AZ	University of Southern California/ Keck School of Medicine Los Angeles, CA
Eastern Virginia Medical School Norfolk, VA	Mayo Clinic College of Medicine Rochester, MN	University of California, Davis Medical Center Sacramento, CA	University of Tennessee, Memphis Memphis, TN
Emory University Atlanta, GA	Medical College of Wisconsin Milwaukee, WI	University of California, San Francisco San Francisco, CA	University of Texas Houston, TX
Florida Hospital Medical Center Orlando, FL	Mt. Sinai Medical Center Miami Beach, FL	University of California Irvine Orange, CA	University of Warwick Library Coventry, United Kingdom
Good Samaritan Hospital Medical Center West Islip, NY	National University Hospital Singapore, Singapore	University of California, Los Angeles Los Angeles, CA	University of Washington Seattle, WA
Hennepin County Medical Center Minneapolis, MN	North Shore University Hospital Manhasset, NY	University of California San Diego La Jolla, CA	University of Wisconsin Hospitals and Clinics Madison, WI
Henry Ford Medical Center Detroit, MI	Northwestern Medical Group Chicago, IL	University of Chicago Chicago, IL	York Hospital York, ME
Highland Hospital Oakland, CA	Ohio State University Medical Center Columbus, OH	University of Colorado & Denver Health Denver, CO	Wake Forest University Winston-Salem, NC
		University of Florida Jacksonville, FL	Wright State University Dayton, OH

State Chapter Subscriber

ARIZONA CHAPTER DIVISION OF THE
AMERICAN ACADEMY OF EMERGENCY MEDICINE

CALIFORNIA CHAPTER DIVISION OF THE
AMERICAN ACADEMY OF EMERGENCY MEDICINE

FLORIDA CHAPTER DIVISION OF THE
AMERICAN ACADEMY OF EMERGENCY MEDICINE

GREAT LAKES CHAPTER DIVISION OF THE
AMERICAN ACADEMY OF EMERGENCY MEDICINE

TENNESSEE CHAPTER DIVISION OF THE
AMERICAN ACADEMY OF EMERGENCY MEDICINE

UNIFORMED SERVICES CHAPTER DIVISION OF THE
AMERICAN ACADEMY OF EMERGENCY MEDICINE

VIRGINIA CHAPTER DIVISION OF THE
AMERICAN ACADEMY OF EMERGENCY MEDICINE

International Society Partners

SOCIEDAD ARGENTINA DE EMERGENCIAS
SOCIEDAD CHILENO MEDICINA URGENCIA
MEDITERRANEAN SOCIETY OF EMERGENCY MEDICINE

THAI ASSOCIATION FOR EMERGENCY MEDICINE
EMERGENCY MEDICINE ASSOCIATION OF TURKEY

NORWEGIAN SOCIETY FOR EMERGENCY MEDICINE
LEBANESE ACADEMY OF EMERGENCY MEDICINE

Alissa Fiorentino
CPC Emergency Medicine Staff Liaison
Phone: 1-800-884-2236

Clinical Practice and Cases in Emergency Medicine

In Collaboration with the *Western Journal of Emergency Medicine*

JOURNAL FOCUS

Clinical Practice and Cases in Emergency Medicine (CPC-EM) is an internationally recognized journal affiliated with the MEDLINE-indexed *Western Journal of Emergency Medicine* (WestJEM). It will offer the latest in patient care case reports, images in the field of emergency medicine and state of the art clinicopathological cases. CPC-EM is fully open-access, peer reviewed, well indexed and available anywhere with an internet connection. CPC-EM encourages submissions from junior authors, established faculty, and residents of established and developing emergency medicine programs throughout the world.

Table of Contents *continued*

- 111 **Bilateral Chylothorax Due to Blunt Trauma Without Radiographic Evidence of Traumatic Injury**
M Mohamed, W Alshenawy, C Kegarise, D Betten
- 115 **Spinal Epidural Abscess Complicated by Meningitis, Sepsis and Thrombocytopenia in a Patient Lacking Traditional Risk Factors**
C Spano, M Ward, N Zigelbaum
- 118 **Quality Initiatives May Affect Diagnostic Accuracy: STEMI Mimics in an Age of Decreasing Door to Balloon Time**
JL Villa-Uribe, EM Schoenfeld
- 122 **Should Pharmacies Be Included in Medication Reconciliation? A Report of Recurrent Valproic Acid Toxicity**
BT Cutshall, SP Shah, MA Van Berkel, S Patterson, LJ Harris, JV Rivera
- 126 **Acute ST Segment Elevation Myocardial Infarction and Massive Pericardial Effusion Due to Infective Endocarditis**
M Thompson, DC Pigott, J Gullett, B Gibson
- 129 **Normokalemic Thyrotoxic Periodic Paralysis with Acute Resolution in the Emergency Department**
Jl Gragg, M Federico, LB Mellick
- 132 **Indicators of Subarachnoid Hemorrhage as a Cause of Sudden Cardiac Arrest**
J Zachariah, JA Stanich, SA Braksick, EFM Wijdicks, RL Campbell, MR Bell, R White
- 136 **No Room for Error: Empiric Treatment for Fulminant Pneumonia**
ME Prekker, SW Smith

IMAGES IN EMERGENCY MEDICINE

- 140 **The Aortomesenteric Angle as an Aid in Diagnosing Superior Mesenteric Artery Syndrome**
KE Kane, AL Koons
- 142 **Intercostal Lung Herniation**
D Manthey, AW Nickle

Policies for peer review, author instructions, conflicts of interest and human and animal subjects protections can be found online at www.cpcem.org.

Clinical Practice and Cases in Emergency Medicine

In Collaboration with the *Western Journal of Emergency Medicine*

Table of Contents *continued*

- 144 **Adult Female with a Headache**
KA Wittbold, J Boehme, HH Kimberly, SE Frasure
- 146 **Phytophotodermatitis**
LG Smith, C Kabhrel
- 148 **Spontaneous Hemoperitoneum from Rupture of Massive Leiomyoma**
A Schwitkis, S Shen, E Vos, SS Torbati
- 150 **Use of Ultrasound to Diagnose Pneumonia**
DL Monette, SE Frasure

VITAL STATISTICS

Clinical Practice and Cases in Emergency Medicine (CPC-EM) is an internationally recognized journal affiliated with the MEDLINE-indexed *Western Journal of Emergency Medicine* (WestJEM). CPC-EM is distributed electronically to 23,278 emergency medicine scholars. This includes our sponsors: California ACEP, the American College of Osteopathic Emergency Physicians, California Chapter of AAEM, and over 80 academic department of emergency medicine subscribers as well as six AAEM State Chapters.

Official Journal of the California Chapter of the American College of Emergency Physicians, the American College of Osteopathic Emergency Physicians, and the California Chapter of the American Academy of Emergency Medicine



Available in Google Scholar.

Editorial and Publishing Office: CPCEM/Department of Emergency Medicine, UC Irvine Health, 333 City Blvd, West, Rt 128-01, Orange, CA 92868, USA

Office: 1-714-456-6389; Email: Editor@cpcem.org

13-year-old Girl with Fevers

Megan Cobb, MD, DPT*

Emily Gorman, MD†

Laura J Bontempo, MD, MEd†

Zachary DW Dezman, MD, MS†

*University of Maryland Medical Center, Baltimore, Maryland

†University of Maryland School of Medicine, Department of Emergency Medicine,
Baltimore, Maryland

Section Editor: Rick A. McPheeters, DO

Submission history: Submitted March 8, 2017; Revision received March 15, 2017; Accepted March 15, 2017

Electronically published March 21, 2017

Full text available through open access at http://escholarship.org/uc/uciem_cpccem

DOI: 10.5811/cpcem.2017.3.34163

[Clin Pract Cases Emerg Med. 2017;1(2):76–80.]

CASE PRESENTATION

A 13-year-old African-American female presented to our pediatric emergency department (ED) with fever for eight days, as high as 103°F at home. Her fevers responded to antipyretics but would return without an identifiable pattern, often within a few hours, sometimes longer; but the fever would always return by the next day. She also complained of odynophagia, headache, fatigue, and dizziness. The patient had been seen in another ED two days prior for these symptoms. She had been diagnosed as having streptococcal pharyngitis because of a positive rapid test and was prescribed amoxicillin. She came into our ED because her symptoms had worsened despite compliance with her antibiotics. Specifically, the patient had developed gradually worsening joint pains in her ankles, knees and shoulders. Her mother noted the patient's joints had become swollen that day and she had developed a facial rash. The patient denied any nausea, vomiting, diarrhea, abdominal pain, or respiratory symptoms such as coughing or wheezing.

Her past medical history included seizures of an unknown etiology occurring between birth and three years of age. She saw her pediatrician regularly. While she lacked a current influenza vaccination, all of her other immunizations were up to date. Her only medication was the amoxicillin she had been prescribed two days prior to presentation. She had no known drug allergies. Her family medical history was significant for a sibling with idiopathic pancreatitis and several family members with type 2 diabetes and hypertension. The patient had not travelled recently, she was post-menarchal, and was not sexually active. Her last menstrual period was two weeks prior to presentation. When questioned without family present, the patient denied any form of abuse.

At the time of her ED evaluation, the patient was afebrile (37.2°C) with a heart rate of 80 beats/minute, respiratory rate of 20 breaths/minute, blood pressure of 118/73 mmHg, and she had an oxygen saturation of 99% on room air. She was 5

feet 1 inch tall (1.35m) and weighed 90 pounds (41kg), giving her a body mass index of 17. This placed her at the 25th percentile for height and weight for her age.

Physical examination revealed a well-developed and nourished adolescent female in no acute distress who appeared fatigued. Her head was normocephalic and atraumatic with bilateral periorbital edema. Her conjunctiva and sclera were normal. Her mucous membranes were moist and she had no nasal discharge. The posterior oropharynx was erythematous without exudates. Her tongue was normal and no intra-oral lesions were seen. Her neck was supple with bilateral cervical lymphadenopathy, the largest node measuring 1.5cm in length. Her lungs were clear to auscultation bilaterally. Her heart was regular without murmurs, rubs or gallop. Her abdomen was soft and non-tender without organomegaly.

She had mild joint pain with passive movement of her extremities, but she had full range of motion except for pain-limited plantar and dorsiflexion of her ankles. There was bilateral pedal edema. Examination of her skin revealed an erythematous midface rash with nasolabial and perioral sparing. No rashes were present elsewhere. Her cranial nerves were intact. The patient had full motor strength throughout all of her extremities. Her coordination, balance, speech, and comprehension were all normal.

Her initial laboratory results are shown in Tables 1 and 2. Based on the suspicion of the clinician, an additional laboratory test was sent that confirmed the diagnosis.

CASE DISCUSSION

What immediately struck me about this case was that this 13-year-old girl was sick. A fever for eight days, not getting better and having an increasing number of symptoms despite taking amoxicillin for a presumed strep throat raised my suspicions that something bad was going on. My initial thoughts were infectious versus autoimmune etiologies.

Table 1. Hematology and coagulation studies of a 13-year-old girl with a fever.

Complete Blood Cell Count	
White blood cells	5.0 K/mcL
Hemoglobin	8.7 g/dL
Hematocrit	26.8%
Platelets	80 K/mcL
Coagulation Studies	
Prothrombin time	15.3 seconds
International normalized ratio	1.2
Activated partial thromboplastin time	39.2 seconds

Table 2. Chemistry results of a 13-year-old girl with a fever.

Serum Chemistries	
Sodium	139 mmol/L
Potassium	4.2 mmol/L
Chloride	104 mmol/L
Bicarbonate	29 mmol/L
Blood Urea Nitrogen	6 mg/dL
Creatinine	4.2 mmol/L
Magnesium	2.0 mg/dL
Phosphorous	4.0 mg/dL
Calcium	8.2 mmol/L
Total Protein	7.5 g/dL
Albumin	2.8 g/dL
Total bilirubin	0.4 mg/dL
AST	71 U/L
ALT	41 U/L
Alk Phos	92 units/L
Additional Labs	
LDH	1098 U/L
CRP	2.2 mg/L
ESR	125 mm/hour

AST, aspartate aminotransferase; ALT, alanine aminotransferase; Alk Phos, alkaline phosphatase; LDH, lactate dehydrogenase; CRP, C-reactive protein; ESR, erythrocyte sedimentation rate.

This case contained so much information that the first challenge was to focus on the pertinent features. The patient's fever, rash, joint pain, periorbital edema, pedal edema, and thrombocytopenia seemed to all be important clues. The patient's laboratory work also suggested a hemolytic anemia (low hematocrit with elevated lactate dehydrogenase [LDH]). I did not believe amoxicillin played a role in the patient's presentation, and in fact it could have been a red herring. The secondary clues that I thought were important for narrowing down the differential included the fatigue, headache, sore throat, lack of a flu shot, normal renal function and a sibling with pancreatitis. I split my initial differential diagnoses into the same three categories I use every day in the ED: life-threats; common; and rare.

- **Life-Threats**

Meningitis, herpes simplex virus (HSV) encephalitis, Kawasaki disease, pericarditis, endocarditis, hemolytic-uremic syndrome (HUS), thrombotic thrombocytopenic purpura (TTP), pancreatitis

- **Common**

Influenza, juvenile rheumatoid arthritis (JRA), mononucleosis, drug rash/fever, mycoplasma

- **Rare**

Measles, rheumatic fever (RF), disseminated gonococcus, malaria, systemic lupus erythematosus (SLE), Zika virus, scarlet fever, tertiary syphilis

There is a large differential for fever, and we can't easily test for all of these diagnoses in the ED. But this challenge is the crux of emergency medicine – being able to think of all of these possibilities and work through why each is or isn't a possible cause of the patient's symptoms. There were several I was able to cross off the list quickly.

- **Meningitis/Encephalitis**

I was able to cross these off the list because the patient had a supple neck, a normal neurological exam, no known exposure to HSV, and while the patient had a rash, it was inconsistent with meningococcus.

- **Kawasaki Disease**

The patient was older than the usual age range (under five years old), and she did not have the conjunctivitis, a "strawberry tongue," or rash consistent with Kawasaki disease.

- **Pericarditis/Endocarditis**

The patient did not have a precordial rub, murmur, or chest pain. As it wasn't a part of the presented history, I am assuming the patient did not use intravenous street drugs and therefore

was not at elevated risk for endocarditis.

- **Drug Rash/Fever**

The patient's symptoms had been present for nearly a week prior to her being given amoxicillin. The patient did not take any other medications.

- **Mycoplasma**

The lack of cough or other respiratory symptoms make this diagnosis less likely.

- **Measles**

The patient was vaccinated, did not have any sick contacts or exposures to measles, and was not known to be immunocompromised.

- **Disseminated Gonococcus/Syphilis**

While we should always be skeptical in emergency medicine, the patient stated she was not sexually active and had no history of congenital infections.

- **Malaria/Zika**

The patient had not travelled recently and had no history of contact with a known case of either disease.

- **Scarlet Fever**

The patient had a positive rapid strep test, but she didn't have the all-over sandpaper rash classically associated with scarlet fever. Similarly, hemolytic anemia is not known to be associated with scarlet fever.

Once I had narrowed my differential to the eight remaining diagnoses, I went through each one, listing history and physical exam items that pointed to or away from each possibility.

HUS-TTP spectrum. Crude as it is, I remembered the "FAT RN" mnemonic for TTP – **F**ever, **A**nemia, **T**hrombocytopenia, **R**enal failure, **N**eurologic symptoms. This patient had a fever, anemia, and thrombocytopenia. A urinalysis, especially if it showed proteinuria, would have been helpful. The patient's creatinine was normal, however, which is not consistent with this diagnosis. Headache may be considered a neurologic symptom, but that is a soft call. HUS is usually characterized by diarrhea, which our patient did not have. The rash was only on her face and not the typical purpura of TTP. Based on this, I felt HUS-TTP spectrum was unlikely to be the diagnosis and crossed it off my differential.

Pancreatitis. Pancreatitis can have a rare complication of hemolytic anemia, which would support this diagnosis. The patient's LDH was elevated, and her sibling presumably had hereditary pancreatitis. I was missing the lipase, but in light of the fact that the patient did not have abdominal pain or vomiting and had so many other symptoms that did not fit with pancreatitis, I felt that

pancreatitis was unlikely and crossed it off my differential.

Influenza. The patient had not been vaccinated, so influenza was still on the differential. Fever, joint aches, headache and fatigue all pointed toward a flu-like illness. However, hemolytic anemia is a very rare complication and influenza has not been known to cause pedal edema or a facial rash. I therefore crossed influenza off the list.

Rheumatic Fever. I personally have never seen this rare¹ disease. However, the patient's fever, joint pain and positive rapid strep test made me seriously consider rheumatic fever. The patient did not have a murmur, chorea, or an all-over rash, all of which pointed against RF. Thrombocytopenia is not a known complication of the disease. Given all the clues that point away from this diagnosis and the rarity of it, I crossed rheumatic fever off the list.

Mononucleosis. The patient had many historical and physical exam clues that pointed towards this diagnosis. She was the right age and she had a fever, sore throat, fatigue, and lymphadenopathy. The development of a rash after taking amoxicillin for presumed streptococcal pharyngitis, when the true cause is mononucleosis, is a well-documented phenomenon.² While it is rare, hemolytic anemia is a complication of mononucleosis. The patient's facial rash points away from mononucleosis, however, since that rash is typically widespread. Pedal edema and joint pain are also not typical of mononucleosis. The patient did not have splenomegaly, although this can be difficult to detect on exam, or it might not yet have developed at this point in the disease. In the end, the heterophile antibody test can be run quickly and easily in the ED, so I kept mononucleosis on my differential.

JRA/SLE. I have a hard time separating these two diseases. SLE has a malar rash and is associated with constitutional symptoms like those in this case, so I focused on SLE. It is rare but SLE can present in the teenage years. Our patient had many of the classic symptoms – malar rash, joint pain, edema, hemolytic anemia, and thrombocytopenia, as well as decreased dorsi- and plantar-flexion. Although she did not have renal involvement, this is often a later development of the disease and does not necessarily point away from the diagnosis. According to the Systemic Lupus International Collaborating Clinics/ American College of Rheumatology, four or more of the following criteria are needed to make the diagnosis of SLE: cutaneous involvement, renal impairment, neurologic symptoms, hematologic involvement, arthritic symptoms, serositis, and positive immunological tests.³ Our patient had a malar rash (cutaneous), hemolytic anemia and thrombocytopenia (hematologic), joint pain and edema (arthritic). If she had either a positive antinuclear antibody (ANA) or anti-double-stranded DNA (anti-dsDNA) test, she would have SLE. SLE therefore remained on my

differential diagnosis list.

My final differential included mononucleosis or SLE. In the real world I would send tests looking for heterophile, antinuclear and anti-dsDNA antibodies, and admit the patient for further workup/management. In the winter months, I would also send a flu swab. But the malar rash is classic for SLE and not for mononucleosis or influenza. Serum ANA can be elevated in several autoimmune syndromes;⁴ so, if I were forced to choose one diagnosis and one test, I would pick SLE and test for anti-dsDNA antibodies.

CASE OUTCOME

The diagnostic test sent was an anti-dsDNA antibody. Her level was significantly elevated at 97 IU/mL (normal range <5 IU/mL). She was formally diagnosed with SLE and started on high-dose glucocorticoids. Her joint pain and swelling responded well to intravenous methylprednisolone over the following three days. On hospital day four, she was transitioned to a 20-day prednisone taper. She was given ranitidine to prevent steroid-induced gastrointestinal distress and acetaminophen for pain, and was discharged home.

Two months later the patient was transitioned from daily prednisone to hydroxychloroquine. She experienced a near-complete resolution of the physical signs of SLE but continued to complain of fatigue two to three times per week and occasional joint pains. Her hemoglobin improved from 8.7 g/dL to 11.4 g/dL. Her sedimentation rate decreased from 125 mm/hour to 72 mm/hour (normal 0-29 mm/hr for women), and her c-reactive protein decreased from 2.2 mg/L to 0.9 mg/L (normal <0.8 mg/L).

RESIDENT DISCUSSION

SLE is found in all age groups – 1-6:100,000 in children and 1:1,500 in adults.^{5,6} The incidence increases to 1:700 in women of childbearing age.^{6,7} Juvenile SLE is often diagnosed between prepubescent and early adolescent ages. The disease is nine times more common in women, and two to three times more common in African Americans and Latinos than Caucasians.^{6,8} Because SLE is so rare in the pediatric population, patients often undergo multiple negative workups before they are correctly diagnosed.^{9,10} The prolonged fever, rash and swelling may be mistaken for Kawasaki disease or streptococcal infections. Arthralgias may be called growing pains. The fatigue, malaise and nonspecific symptoms may be attributed to a viral syndrome. Only when taken in total do these often non-specific symptoms point toward SLE.

The pathophysiology begins with the formation of apoptotic cellular bodies and an incomplete clearance of intracellular debris. The release of auto-antigens stimulates immune complex formation with auto-antibodies. Most commonly these are anti-nuclear, anti-dsDNA, anti-Smith, and anti-histone autoantibodies.¹⁰ Once the immune complexes

form, they deposit into tissues throughout the body, causing a systemic vasculitis through a type-III hypersensitivity reaction. Though rare in children, 40-50% of adult patients with SLE also produce an anti-phospholipid autoantibody, which inactivates prothrombin, protein C, and protein S.¹¹ These are critical regulatory enzymes in the coagulation cascade, and their inactivation is responsible for the increased risk of bleeding and thromboembolic events found in patients with SLE.

Based on the 2015 guidelines by the American College of Rheumatology and Systemic Lupus International Collaborating Clinics, the revised diagnostic criteria for SLE include cutaneous and neuropsychiatric manifestations, renal and hematologic abnormalities, and autoimmune laboratory values.^{3,12} In a multicenter study, childhood-onset SLE symptoms were most commonly hematologic (72%), cutaneous (70%), musculoskeletal (64%), renal (50%), and fever (58%).¹⁰ It is unlikely that a patient will display enough findings during one ED visit for a definitive diagnosis.^{9,10} However, a thorough history and physical can prove useful in placing SLE higher on the differential diagnosis list.

Our patient had the typical presentation of a case of pediatric SLE: fever, rash, fatigue, arthralgia or polyarthritis, anemia, thrombocytopenia, and renal disease.¹⁰ In adults, the presentation can be less severe and generally favors cardiopulmonary disease.¹³ Necrotizing vasculitis can occur in any tissue in SLE patients, including involvement of intestinal, cutaneous, pulmonary, and cardiac tissues.¹⁴ Lupus nephritis is common and may vary from mild renal insufficiency to frank renal failure.¹⁵ Deep vein thrombosis, pulmonary embolism, mesenteric ischemia, and cerebrovascular insults may occur in those with *and* without anti-phospholipid syndrome.¹⁶ A rare but important manifestation of SLE in both children and adult patients is shrinking lung syndrome, which is a progressive and irreversible restrictive lung disease that often presents with dyspnea and fatigue.

If SLE is suspected, laboratory studies that are both widely available and likely to result quickly during an ED visit include the basics: complete blood count, basic metabolic panel, chest radiograph, and urinalysis. Rheumatologic testing is less useful in the acute setting as these studies generally take hours to days to perform. ANA is considered sensitive but not specific, while anti-dsDNA and anti-Smith autoantibodies are considered confirmatory tests. If drug-induced lupus is suspected, then anti-histone autoantibody is the test of choice. In the setting of acute illness complicated by SLE, the emergency physician should address any acute medical conditions as usual. In addition to routine care, the clinician should consider consulting a rheumatologist and administering high-dose steroids for rapid immunosuppression, if an SLE flare is suspected.¹⁷

FINAL DIAGNOSIS

Juvenile systemic lupus erythematosus.

TAKE-HOME POINTS

- Patients with SLE:
 - More common in adult women, African Americans and Hispanics
- The diagnosis of systemic lupus erythematosus is made by the presence of four of the following:
 - Cutaneous involvement
 - Neurologic symptoms
 - Hematologic involvement
 - Renal impairment
 - Serositis
 - Arthritic symptoms
 - Positive immunological testing
- Immunological testing includes
 - ANA (sensitive but not specific)
 - Anti-dsDNA and anti-Smith (specific but not sensitive)
 - Anti-histone (in drug-induced SLE)
- Patients with SLE often have a disordered coagulation cascade.
 - 40-50% of patients with SLE have anti-phospholipid syndrome.
 - Deactivates prothrombin and proteins C and S
- In patients with acute manifestations of SLE, consider treating with high-dose steroids.

Address for Correspondence: Zachary DW Dezman, MD, MS, University of Maryland School of Medicine, 110 Paca Street, Suite 200, 6th floor, Baltimore, MD 21201. Email: zdezman@em.umaryland.org.

Conflicts of Interest: By the CPC-EM article submission agreement, all authors are required to disclose all affiliations, funding sources and financial or management relationships that could be perceived as potential sources of bias. The authors disclosed none.

Copyright: © 2017 Dezman et al. This is an open access article distributed in accordance with the terms of the Creative Commons Attribution (CC BY 4.0) License. See: <http://creativecommons.org/licenses/by/4.0/>

REFERENCES

1. Shulman ST, Stollerman G, Beall B, et al. Temporal changes in streptococcal M protein types and the near-disappearance of acute rheumatic fever in the United States. *Clin Infect Dis*. 2006;42(4):441-7.
2. Chovel-Sella A, Tov AB, Lahav E, et al. Incidence of rash after amoxicillin treatment in children with infectious mononucleosis. *Pediatrics*. 2013;131(5):e1424-7.
3. Petri M, Orbai AM, Alarcón GS, et al. Derivation and validation of the Systemic Lupus International Collaborating Clinics classification criteria for systemic lupus erythematosus. *Arthritis Rheum*. 2012;64(8):2677-86.
4. McGhee JL, Kickingbird LM, Jarvis JN. Clinical utility of antinuclear antibody tests in children. *BMC Pediatr*. 2004;4(1):13.
5. Mina R, Brunner HI. Update on differences between childhood-onset and adult-onset systemic lupus erythematosus. *Arthritis Res Ther*. 2013;15(4):218.
6. Danchenko N, Satia JA, Anthony MS. Epidemiology of systemic lupus erythematosus: a comparison of worldwide disease burden. *Lupus*. 2006;15(5):308-18.
7. Mccarty DJ, Manzi S, Medsger TA, et al. Incidence of systemic lupus erythematosus race and gender differences. *Arthritis Rheum*. 1995;38(9):1260-70.
8. Waseem M, Alsheikh M, Hana A. Presentation of systemic lupus erythematosus in emergency department. *Pediatr Emerg Care*. 2007; 23(4): 238-41.
9. Olowu W. Childhood-onset systemic lupus erythematosus. *J Natl Med Assoc*. 2007;99(7):777.
10. Bader-Meunier B, Armengaud JB, Haddad E, et al. Initial presentation of childhood-onset systemic lupus erythematosus: a French multicenter study. *J Pediatr*. 2005;146(5):648-53.
11. Petri M. Epidemiology of the antiphospholipid antibody syndrome. *J Autoimmun*. 2000;15(2):145-51.
12. Salehi-Abari I. ACR/SLICC revised criteria for diagnosis of systemic lupus erythematosus. *Autoimmune Dis Ther Approaches*. 2015;2(1):114.
13. Tucker LB, Menon S, Schaller JG, et al. Adult-and childhood-onset systemic lupus erythematosus: a comparison of onset, clinical features, serology, and outcome. *Br J Rheumatol*. 1995;34(9):866-72.
14. Kamran M, Wachs J, Putterman C. Necrotizing fasciitis in systemic lupus erythematosus. *Semin Arthritis Rheum*. 2008;37(4):236-42.
15. Feldman CH, Hiraki LT, Liu J, et al. Epidemiology and sociodemographics of systemic lupus erythematosus and lupus nephritis among US adults with Medicaid coverage, 2000–2004. *Arthritis Rheum*. 2013;65(3):753-63.
16. Wahl DG, Bounameaux H, de Moerloose P, et al. Prophylactic antithrombotic therapy for patients with systemic lupus erythematosus with or without antiphospholipid antibodies: do the benefits outweigh the risks? A decision analysis. *Arch Intern Med*. 2000;160(13):2042.
17. Mina R, Brunner HI. Update on differences between childhood-onset and adult-onset systemic lupus erythematosus. *Arthritis Res Ther*. 2013;15(4):218.

Inadvertent Intrathecal Administration of Local Anesthetics Leading to Spinal Paralysis with Lipid Emulsion Rescue

Amit Gupta, MD*

Gabrielle L. Procopio, PharmD[†]

Patrick H. Charles, DO*

Monica Hernandez, MD*

Ruchi Patel, PharmD[†]

*Hackensack University Medical Center, Department of Emergency Medicine, Hackensack, New Jersey

[†]Hackensack University Medical Center, Department of Pharmacy, Hackensack, New Jersey

Section Editor: Rick A. McPheeters, DO

Submission history: Submitted November 1, 2016; Revision received November 26, 2016; Accepted December 8, 2016

Electronically published January 27, 2017

Full text available through open access at http://escholarship.org/uc/uciem_cpchem

DOI: 10.5811/cpchem.2016.12.33046

Bupivacaine and ropivacaine are local anesthetics frequently used for interscalene nerve blocks, which are generally well tolerated; however, some complications include pneumothorax, Horner syndrome, nerve injury and cardiovascular toxicity from vascular injection. On rare occasions, it may be associated with spinal paralysis. While the treatment is mostly supportive, we report an unusual case of administering intravenous lipid emulsion (ILE) as part of resuscitative efforts to hasten neurological recovery from spinal shock. [Clin Pract Cases Emerg Med. 2017;1(2):81–83.]

INTRODUCTION

Interscalene nerve block refers to the technique of anesthetizing the roots or trunks of the brachial plexus in the neck between the anterior and middle scalene muscles. It is a commonly used procedure to provide anesthesia or analgesia for surgery of the shoulder and upper arm with rare complications. Several case reports have reported complete spinal cord paralysis and cardiovascular collapse after this procedure due to inadvertent epidural or subdural introduction of local anesthetic(s).¹⁻³ Treatment in these cases was primarily supportive.

Bupivacaine/ropivacaine are commonly used local anesthetics for peripheral nerve blocks, belonging to the amide group. They function by reversibly binding to the intracellular portion of voltage-gated sodium channels, thereby blocking sodium influx into nerve cells, which prevents depolarization and failure to initiate and propagate action potentials.⁴ This effect slows impulse conduction in the sinoatrial and atrioventricular nodes, the His-Purkinje system, and atrial/ventricular muscle, which can lead to its most feared complications of myocardial depression, refractory ventricular dysrhythmias, and possible cardiac arrest due to inadvertent cardiovascular administration.⁵ Local anesthetic toxicity (LAT) is often refractory to conventional therapy, but an effective antidote is 20% intravenous lipid emulsion (ILE), Intralipid®.

We report a case of a patient who had complete spinal shock leading to quadriplegia and cardiovascular collapse after an interscalene block.

CASE REPORT

A 43-year-old male presented to the emergency department (ED) for evaluation of acute respiratory arrest. Prior to arrival, the patient was at an outpatient surgical center being prepared for a right shoulder arthroscopic surgery under regional anesthesia. The anesthesiologist injected 10 mL of bupivacaine and 30 mL of ropivacaine, of unknown concentrations, while attempting to perform an interscalene block. Soon thereafter, the patient complained of difficulty breathing and subsequently developed complete paralysis and respiratory arrest requiring emergent endotracheal intubation prior to hospital arrival. No additional medications were administered at the time of intubation.

Physical exam revealed dilated pupils nonreactive to light, complete flaccid paralysis and inability to withdraw from noxious stimuli. The patient immediately received two liters of 0.9% normal saline and a dopamine infusion, initiated at 5 mcg/kg/min, due to persistent bradycardia (heart rate of 44 bpm) and hypotension. The local poison control center was contacted for recommendations on potential LAT. The decision was made to administer 20% ILE, with a bolus of

125 mL (1.5 mL/kg) over one minute, about 90 minutes after presentation. Shortly after, propofol was initiated for post-intubation sedation at 10 mcg/kg/min. The remaining volume of ILE (125 mL) was then immediately infused over two hours at a rate of 0.013 mL/kg/min.

Approximately 30 minutes after the initiation of ILE, the patient began to regain brainstem reflexes and eye movement, which progressed to head nods, then movement of his upper extremities. In addition, during that time period, his blood pressure and heart rate improved to within normal parameters. Sixty minutes later, the patient was able to communicate by writing down responses to questions. One hour after that, he had full recovery and was extubated. The patient recovered completely without any evidence of neurological sequelae and was discharged 30 hours after presentation.

DISCUSSION

Bupivacaine and ropivacaine are frequently used for interscalene nerve blocks, since it has shown to provide rapid and effective local anesthesia. Although interscalene blocks are generally well tolerated, on rare occasions they may be associated with severe complications. During an interscalene block, the nerves are anesthetized at the root level of the brachial plexus located at the interscalene groove. In a rare occurrence, intrathecal injection may track back along the plexus roots into the epidural space. Intrathecal injection can also occur from either needle misplacement through an intervertebral foramina or via injection into a dural cuff.^{6,7} Injection into either the external jugular vein or vertebral artery is also possible. The complications from LAT range from dyspnea, bilateral arm weakness and apnea to hemodynamic collapse and in this case paralysis.^{8,9}

Although the treatment is mostly supportive while the drug “wears off,” we report an unusual case of administering ILE as part of our resuscitative effort to hasten neurological recovery. Because of general lack of familiarity with the pharmacokinetic alterations with intrathecal route and toxicity associated with these drugs, it was decided to institute lipid emulsion early in the course. Pharmacokinetic properties are dependent on the total dose, drug concentration, route of administration and vascularity of the administration site. Data primarily exist regarding pharmacokinetic parameters for intravenous and epidural routes; information is limited when these drugs are administered via intrathecal route. A study by Rose et al. would suggest plasma pharmacokinetic parameters for intrathecal route lie in between the intravenous and epidural routes.¹⁰

ILE is an extensively studied agent for the management of LAT and has been demonstrated to be an effective antidote in a number of case reports. In a recent study surveying 45 United States poison control centers, 89% and 96% of medical directors surveyed stated they would “always” or “often” recommend ILE for patients

experiencing shock or cardiac arrest from bupivacaine, respectively.¹¹ Although most data are limited to case reports, current evidence suggests potential benefit when given as salvage therapy in patients presenting with overdoses involving lipophilic molecules.¹²

While several mechanisms have been proposed for its effectiveness, the most widely accepted theory is the creation of a lipid sink to sequester lipid-soluble drugs and thus remove them from the site of toxicity. ILE may pull the drug out of the aqueous plasma, which bathes the tissue, and redistributes the drug away from the site of toxicity into an area with high lipid fat compartment of the plasma.

The safety of using ILE to treat overdoses is largely unknown due to limited reporting. Rare complications including laboratory interference, pancreatitis, and acute respiratory distress syndrome have been reported with ILE use.^{13,14} Additional complications associated with ILE are extrapolated from the extended use as a part of total parenteral nutrition, including hypertriglyceridemia, fat embolism, and infection.¹⁵⁻¹⁷

In this case, since the patient began to show signs of neurologic recovery 30 minutes from the initiation of the bolus infusion there was no need to continue lipid therapy infusion. It should be noted that another lipid-based product, propofol, was also administered concomitantly with ILE; however, this is manufactured in a 10% lipid emulsion. The pharmacodynamics of propofol and ILE acting synergistically, and whether they provide a larger lipid sink, are unknown.

In addition to the uncertainty surrounding the safety of ILE for this indication, the appropriate dosing has yet to be determined. The dosing protocol most widely reported in the literature consists of an intravenous bolus of 1 to 1.5 mL/kg administered as a bolus followed by an infusion of 0.25 to 0.5 mL/kg/min for a duration of 30-60 minutes or until hemodynamic recovery.^{18,19} The bolus may be repeated one or two times in the event of continued asystole. In our case, the local poison center recommendation for ILE was based on the assumption that the premixed Intralipid® bag was 500 mLs. Our patient received half the recommended total volume as the premixed bag in stock only contained 250 mLs and providers were instructed to give the remainder of the bag’s contents, after the bolus, over two hours. While the recommended bolus dose was administered to our patient, an infusion of 125mL was administered over two hours (0.013 mL/kg/min), which was lower than that suggested.

To our knowledge, this is the first case report documenting ILE administration for spinal shock due to intrathecal administered of local anesthetics. In light of these uncertainties, it is reasonable to administer ILE for reversal of local anesthetic-induced toxicity. In summary, intrathecal anesthetic toxicity treatment is primarily supportive and due to its safety profile, ILE rescue may be attempted.

Address for Correspondence: Amit Gupta, MD, Hackensack University Medical Center, 30 Prospect Avenue, Hackensack, NJ 07601. Email: agupta1@hotmail.com.

Conflicts of Interest: By the CPC-EM article submission agreement, all authors are required to disclose all affiliations, funding sources and financial or management relationships that could be perceived as potential sources of bias. The authors disclosed none.

Copyright: © 2016 Gupta et al. This is an open access article distributed in accordance with the terms of the Creative Commons Attribution (CC BY 4.0) License. See: <http://creativecommons.org/licenses/by/4.0/>

REFERENCES

- Mostafa RM and Mejadi A. Quadriplegia after interscalene block for shoulder surgery in sitting position. *Br J Anaesth*. 2013;111(5):846-7.
- Porhomayon J and Nader ND. Acute quadriplegia after interscalene block secondary to cervical body erosion and epidural abscess. *Middle East J Anaesthesiol*. 2012;21(6):891-4.
- Benumof JL. Permanent loss of cervical spinal cord function associated with interscalene block performed under general anesthesia. *Anesthesiology*. 2000;93(6):1541-4.
- Covino BG. Pharmacology of local anaesthetic agents. *Br J Anaesth*. 1986;58(7):701-16.
- Clarkson CW and Hondeghem LM. Mechanism for bupivacaine depression of cardiac conduction: fast block of sodium channels during the action potential with slow recovery from block during diastole. *Anesthesiology*. 1985;62(4):396-405.
- Scammell SJ. Case report: inadvertent epidural anaesthesia as a complication of interscalene brachial plexus block. *Anaesth Intensive Care*. 1979;7(1):56-7.
- Gutton C, Choquet O, Antonini F, et al. [Ultrasound-guided interscalene block: Influence of anatomic variations in clinical practice]. *Ann Fr Anesth Reanim*. 2010;29(11):770-5.
- Warren JA, Thoma RB, Georgescu A, et al. Intravenous lipid infusion in the successful resuscitation of local anesthetic-induced cardiovascular collapse after supraclavicular brachial plexus block. *Anesth Analg*. 2008;106(5):1578-80.
- Rosenblatt MA, Abel M, Fischer GW, et al. Successful use of a 20% lipid emulsion to resuscitate a patient after a presumed bupivacaine-related cardiac arrest. *Anesthesiology*. 2006;105(1):217-8.
- Rose FX, Estebe JP, Ratajczak M, et al. Epidural, intrathecal pharmacokinetics, and intrathecal bioavailability of ropivacaine. *Anesth Analg*. 2007;105(3):859-67.
- Christian MR, Pallasch EM, Wahl M, et al. Lipid rescue 911: Are poison centers recommending intravenous fat emulsion therapy for severe poisoning?. *J Med Toxicol*. 2013;9(3):231-4.
- Geib AJ, Liebelt E, Manini AF, et al. Clinical experience with intravenous lipid emulsion for drug-induced cardiovascular collapse. *J Med Toxicol*. 2012;8(1):10-4.
- Cave G, Harvey M, Graudins A. Intravenous lipid emulsion as antidote: a summary of published human experience. *Emerg Med Australas*. 2011;23(2):123-41.
- Weinberg GL. Lipid emulsion infusion: resuscitation for local anesthetic and other drug overdose. *Anesthesiology*. 2012;117(1):180-7.
- Levine M, Brooks DE, Franken A, et al. Delayed-onset seizure and cardiac arrest after amitriptyline overdose, treated with intravenous lipid emulsion therapy. *Pediatrics*. 2012;130(2):e432-8.
- Driscoll DF. Lipid injectable emulsions: Pharmacopeial and safety issues. *Pharm Res*. 2006;23(9):1959-69.
- Levine M, Skolnik AB, Ruha AM, et al. Complications Following Antidotal Use of Intravenous Lipid Emulsion Therapy. *J Med Toxicol*. 2014;10(1):10-4.
- Guidelines. The Association of Anaesthetists of Great Britain and Ireland. Available at: <http://www.aagbi.org/publications/publications-guidelines>. Accessed Jun 21, 2013.
- Neal JM, Bernards CM, Butterworth JF, et al. ASRA practice advisory on local anesthetic systemic toxicity. *Reg Anesth Pain Med*. 2010;35(2):152-61.

Nonspecific Headache Diagnosed as a Brain Colloid Cyst with Hydrocephalus

Christine Carroll, DO
Mark Riddle, DO

Carl R. Darnall Army Medical Center, Department of Emergency Medicine, Fort Hood, Texas

Section Editor: Rick A. McPheeters, DO

Submission history: Submitted October 20, 2016; Revision received November 23, 2016; Accepted December 8, 2016

Electronically published March 6, 2017

Full text available through open access at http://escholarship.org/uc/uciem_cpem

DOI: 10.5811/cpcem.2016.12.32939

A 29-year-old male presented to our emergency department with complaints of a left frontal headache, similar to his prior headaches. He also reported about 30 minutes of facial and tongue numbness, left arm weakness, slurred speech and changes in hearing that had resolved prior to his arrival. Despite the short duration of the other neurologic symptoms, he also endorsed persistent “dizziness.” Despite his history of recurrent headaches, he had never had any neuroimaging. This, as well as his reports of new neurological symptoms, prompted his care team to obtain a non-contrast brain computed tomography. The findings were consistent with a mass with mild hydrocephalus. Patient underwent neurosurgical resection of the mass at a tertiary center. He did well after surgery and was discharged on postop day 6 with a diagnosis of colloid cyst. [Clin Pract Cases Emerg Med. 2017;1(2):84–86.]

INTRODUCTION

Colloid cysts (CC) are slow growing, benign developmental lesions that occur at the roof of the third cerebral ventricle close to the foramen of Monroe.^{1,2,3} They account for 0.5%–2% of all intracranial^{1,2,3} and 15%–20% of all intraventricular tumors.¹ They may also be found in other locations such as the fourth ventricle, posterior fossa, brainstem or cerebellum.² Men are more affected than women, and they are diagnosed mostly in the third and fifth decades.³ CCs generally range in size from 2-50mm in diameter,^{1,3,4} and they may contain colloid material including cholesterol and fats.³ Despite their rare occurrence, these cysts are of important clinical significance. Because of a ball-valve effect within the ventricle, they can interfere with the cerebrospinal fluid (CSF) outflow and cause hydrocephalus, irrespective of their size.^{1,3,4} Because of this effect, early detection and treatment is recommended as they can cause acute deterioration and even sudden death, which is more common if the cyst is more than 1cm in diameter.^{1,4}

CASE REPORT

A 29-year-old male with a past medical history only significant for hypertension arrived to our emergency department

(ED) with complaints of headache and dizziness. The patient stated that in the past he had experienced similar headaches of similar intensity; however, with this headache he experienced changes in vision, which was a new phenomenon. He described his headache as frontal and stated it started about three hours prior to arrival. Shortly after the onset of the headache he had approximately 30 minutes of blurry vision, numbness to left face, tongue and left arm. His wife also noticed slurred speech with deficits in hearing that also lasted approximately 30 minutes. The neurologic symptoms completely resolved by the time he arrived to the ED; however, his headache continued and he was experiencing worsening dizziness.

Upon arrival, his blood pressure was 151/88, pulse 80, pulse ox 99% and temperature of 97.9. Blood glucose was 132. Visual acuity was normal uncorrected. Electrocardiogram (EKG) showed normal sinus rhythm with normal intervals. Lab work obtained included a complete blood count, complete metabolic panel, and troponin I, which were found to be unremarkable. The only medication the patient was taking was lisinopril (10mg) for hypertension. He had an unremarkable physical exam. He endorsed a history of similar headaches, except for his complaint of subjective dizziness, and we found no neurologic deficits on our exam. Pupils were round and reactive to light. There was no peripheral vision

deficit. Speech was clear. Cranial nerves II-XII were intact. Lungs were clear to auscultation bilaterally. Cardiac and abdominal exams were benign. Extremities had 5/5 strength bilaterally, 2/4 patellar reflexes and sensation was intact. Romberg test was negative. Recurrent headaches without prior neuroimaging and his reported neurologic phenomena prior to arrival prompted a non-contrast computed tomography (CT) of his brain in the ED. The CT revealed a 2.3 cm tumor versus mass versus CC in the third ventricle causing hydrocephalus (Image 1). Because of the patient's presentation and the CT findings the decision was made to transfer him to a tertiary center with neurosurgery service available.

At the tertiary center the patient underwent magnetic resonance imaging of the brain with contrast that revealed a 1.2x1.7x2 cm lobulated mass at the anterior aspect of the third ventricle with mild hydrocephalus without mass defect. Patient was started on levetiracetam, labetalol, hydralazine and cefazolin sodium. On hospital day 2 he had an endoscopic resection of the mass through a frontal incision and an intraventricular shunt was placed. The mass was sent for pathology, which reported results consistent with a CC.

On postop day 1 a head CT was done secondary to patient complaining of continued headache. It demonstrated a moderate amount of intraventricular hemorrhage, pneumocephalus and subcutaneous gas seen along left prefrontal soft tissues (Image 2). All findings were thought to be secondary to surgery.

On postop day 3 the patient complained of headache with photophobia. Repeat head CT demonstrated mild residual ventriculomegaly with interval decrease in postop pneumocephalus and decrease in the intraventricular hemorrhage.

The patient continued to improve, had normal vitals and normal lab values and he was released home on postop day 6.

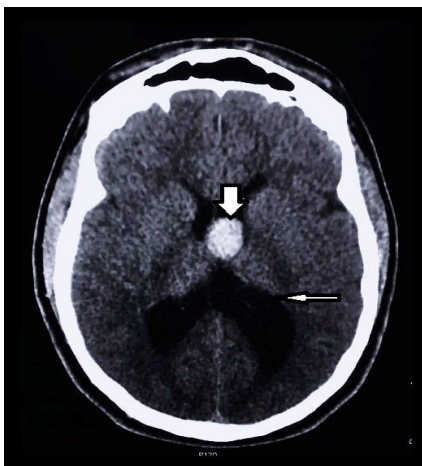


Image 1. Initial noncontrast computed tomography head demonstrating the presence of the colloid cyst (thick arrow) with associated hydrocephalus (thin arrow).

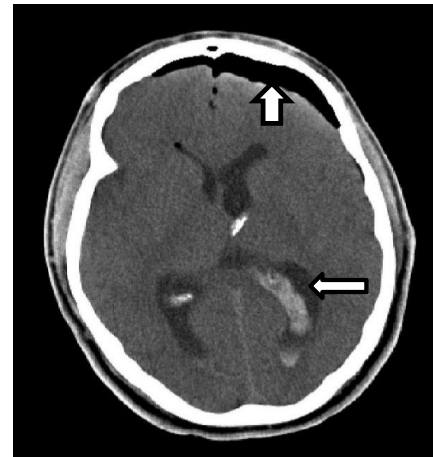


Image 2. Postoperative noncontrast computed tomography head with presence of pneumocephalus (thick arrow) and intraventricular hemorrhage (thin arrow).

DISCUSSION

More than three million people present yearly to the ED with headaches as the presenting symptom.⁵ The emergency physician (EP) has two major responsibilities in diagnosis and management of headaches. These responsibilities are to simultaneously evaluate for life-threatening causes of headaches in a timely manner and treat the patient to alleviate suffering.⁵ Following diverse algorithms of classification and management of headaches may distract the EP from the above most important priorities in ED.⁵ Anchoring on a "headache similar as those in the past" statement can lead to a delayed or missed diagnosis with catastrophic consequences for the patient. Other pitfalls that can lead to missed diagnoses are the following: relying on relief of pain with medications as an end of diagnostic evaluation, dismissing the possibility of secondary headache in patients with known primary headaches, and believing that the cause of headache is hypertension.⁵ The prudent EP would thus have a high index of suspicion for any headache that is sudden and at its maximal intensity at onset and if the patient expresses concerns that the symptoms deviate from their regular pattern. Imaging is recommended if any of the "red flags" are present: focal neurologic deficits, any cranial nerve abnormality, or onset of new symptoms with prior diagnosis of primary headaches. Any of the above presentations can be more or less obvious in patients who have an undiagnosed CC.

Headache is present in 68-100% of patients with CCs.^{3,4,6} The headaches can be intermittent or severe and are often relieved by recumbency or sleep.^{3,4} The headaches usually start in the frontal area and are characterized by their short duration, often improving with changes in position.⁴ Other common symptoms are nausea, vomiting, visual changes, short-term memory loss and gait disturbances generally caused by obstruction of the foramen of Monroe.^{3,4,6} Less common symptoms are stroke, psychiatric problems, incontinence,

behavioral changes, generalized weakness, syncope and sudden death.⁴ In rare cases they may present with endocrine abnormalities such as oligomenorrhea, galactorrhea and hypogonadotropic hypogonadism.⁶

Patients may have frequent similar headaches that are generally responsive to pain control measures, potentially leading to a delayed diagnosis in the ED. Patients like ours may describe them as similar as prior headaches, which can decrease the EP's concern and delay brain imaging. Despite availability of early diagnosis with imaging, other conditions must be kept in mind to reduce delays in treatment. These may include things such as CCs, arachnoid cysts, craniopharyngioma, pituitary gland tumors, aneurysms, or Rathke cleft cysts.^{2,6}

There is no general agreement on the treatment of CCs, and the optimal management has been a debatable issue. Some of the treatment options include open and microsurgical resection, stereotactic aspiration, endoscopic removal, or simple shunt application.^{1,4,6} Some neurosurgeons suggest aggressive resection of CCs, while others recommend only fenestration and suction of the cyst contents since they believe these cysts usually do not relapse.⁶ However, despite the lack of agreement of how to best treat the CCs, the microsurgical approach has been considered the gold standard for treatment since complete resection can be achieved.¹ Should endoscopic resection be chosen as the treatment option, it has been shown to have lower complication rates, less surgery time, shorter hospital stay and lower infection rates, but the cysts tend to recur more often than with microsurgery.¹

CONCLUSION

In conclusion, physicians should have a low threshold for imaging presenting headaches with subjective changes from baseline even if neurologic exam is normal. Shared decision-making and listening to the patient along with a thorough physical exam is of utmost importance. In our case, the patient's increasing concerns regarding his symptoms along with the changes noted by his wife ultimately led us to the final unexpected diagnosis.

Address for Correspondence: Christine Carroll DO, Darnall Army Medical Center, 36065 Santa Fe, Fort Hood, TX 76544. Email: christine.c.carroll2.mil@mail.mil.

Conflicts of Interest: By the CPC-EM article submission agreement, all authors are required to disclose all affiliations, funding sources and financial or management relationships that could be perceived as potential sources of bias. Any opinions, findings, conclusions, or recommendations expressed in this article are those of the authors and do not necessarily reflect the views of the United States Army, Department of Defense, or the US government.

Copyright: © 2016 Carroll. This is an open access article distributed in accordance with the terms of the Creative Commons Attribution (CC BY 4.0) License. See: <http://creativecommons.org/licenses/by/4.0/>

REFERENCES

1. Sharifi G, Bakhtevvari MH, Samadian M, et al. Endoscopic surgery in nonhydrocephalous third ventricular colloid cysts: a feasibility study. *World Neurosurg.* 2015;84(2):398-404.
2. Paniraj GL, Panigrahi M, Reddy AK, et al. Suprasellar colloid cyst: an unusual location. *World Neurosurg.* 2014;81(1):202.e15-8.
3. Fraisse T and Sirvain S. Colloid cyst of third ventricle. *Eur Geriatr Med.* 2010;1(5),308-9.
4. Algin O, Ozmen E, Arslan H. Radiologic manifestations of colloid cysts: a pictorial essay. *Can Assoc Radiol J.* 2013;64(1):56-60.
5. Swadron SP. Pitfalls in the management of headache in the emergency department. *Emerg Med Clin North Am.* 2010;28(1):127-47, viii-ix.
6. Bender B, Honegger JB, Beschorner R, et al. MR imaging findings in colloid cysts of the sellar region: comparison with colloid cysts of the third ventricle and Rathke's cleft cysts. *Acad Radiol.* 2013;20(11):1457-65.

Avulsion of the Lesser Trochanter Following a Shot Put Sport Session

Mohamed H. Grissa, MD*
Nasri Bzeouich, MD*†
Makram Zrig, MD‡
Hamdi Boubaker, MD*†
Mohamed A. Msolli, MD*†
Abderrazak Abid, MD‡
Semir Nouira, MD*†
Amanda Montgomery, MD§

*University of Monastir, Department of Emergency Medicine, Research Laboratory (LR12SP18), Monastir, Tunisia

†Fattouma Bourguiba University Hospital, Department of Emergency Medicine, Monastir, Tunisia

‡Fattouma Bourguiba University Hospital, Department of Orthopedics, Monastir, Tunisia

§Kern Medical, Department of Emergency Medicine, Bakersfield, California

Section Editor: Rick A. McPheeters, DO

Submission history: Submitted September 21, 2016; Revision received October 27, 2016; Accepted December 8, 2016

Electronically published March 13, 2017

Full text available through open access at http://escholarship.org/uc/uciem_cpem

DOI: 10.5811/cpem.2016.12.32605

Avulsion of the lesser trochanter is an uncommon injury. In children and adolescents it usually occurs as a sports injury via traumatic avulsion of the psoas major tendon. In adults, isolated fractures of the lesser trochanter are most commonly pathological due to metastatic tumor invasion of the proximal femur. This case report documents how a 14-year-old boy, who presented with an avulsion of the lesser trochanter of the proximal femur following a seemingly atraumatic shot put session at a track and field event, was diagnosed and successfully treated with a conservative approach. [Clin Pract Cases Emerg Med. 2017;1(2):87–88.]

INTRODUCTION

Avulsion of the lesser trochanter during a sports event may remain undetected in a child. Emergency department (ED) diagnosis based on history and physical examination is made more difficult by the fact that this traumatic lesion is rarely associated with throwing the shot put. As this activity involves primarily the upper body, the emergency physician may not suspect an indication to order lower extremity imaging in the absence of obvious trauma.

CASE REPORT

A 14-year-old male with no medical history reported feeling pain in his right groin region during a shot put session. The mechanism of injury was a forceful abduction and external rotation of the hip, sustained while the subject was throwing the weight (a five-kilogram steel ball).

The child was evaluated in the ED at the University Hospital of Monastir-Tunisia. Physical examination revealed a thin boy with antalgic gait of the left lower extremity. There was no obvious deformity, edema, or ecchymosis; however, he was tender on the medial aspect of the left hip. While

no limitation of passive movement was appreciated, active flexion was painful. Strength was decreased, especially with flexion greater than 90 degrees. No neurological deficits were detected. Pulses were present and symmetrical in both legs. Right hip and pelvic radiographs revealed a single fragment avulsion of the lesser trochanter with 1 centimeter of cranial displacement (Images 1, 2).

A conservative therapeutic approach was implemented. The patient was treated with analgesics. He was confined to bed rest for two weeks, after which he was made non-weight bearing, on crutches, for another four weeks. After the six-week rest period, the patient was enrolled in a four-week intensive rehabilitation program designed to help him regain strength and range of motion.

DISCUSSION

Isolated fractures of the lesser trochanter are rare injuries in childhood accounting for only 0.3 percent of proximal femur fractures.¹ Avulsion fractures typically occur during adolescence. They are usually seen in children between the ages of 7-16 years, but most commonly occur at the age of 14.²

Avulsion of the lesser trochanter usually occurs from an acute injury most commonly related to sporting events.³ The main cause of such avulsions is forceful contraction of the iliopsoas tendon during hip flexion. The excessive stress concentrated at the site leads to a tensile failure of the apophysis of the lesser trochanter.⁴ The diagnosis may be suggested by the patient's age and mechanism of injury. However, other causes of pediatric hip pathology, including septic arthritis, slipped capital femoral epiphysis, osteosarcoma and Perthes' disease, must be ruled out in this age group.^{2,5}

The most frequent presenting clinical scenario is groin pain and limp, with little external evidence of trauma. The physical examination often reveals tenderness over the medial aspect of the hip and pain with hip flexion greater than 90 degrees (Ludloff sign). The diagnosis is confirmed with radiography and is classified as a Salter-Harris Type I fracture. The avulsed fragment is most frequently displaced proximally by the pull of the iliopsoas tendon.⁶

Symptomatic treatment is recommended, with limited

weight-bearing on crutches for three to four weeks and analgesia as required. Complete healing can take up to two months, and sports should be avoided during this time.³ Surgical intervention is indicated where a non-union or fibrous union has occurred, resulting in chronic pain with motion at the fracture site. If the avulsed fragment is displaced more than three centimeters, surgical reattachment or excision is advised.⁴ However, a study by Fernbarch and Wilkonson demonstrated that operative treatment is rarely indicated.⁷ This study looked at 20 male adolescents engaged in competitive sports. Results of those treated conservatively were comparable to open reduction and internal fixation of the fragment, regardless of the degree of displacement.

The majority of patients with this type of injury eventually become asymptomatic and are able to return to original activity levels. This is true even in the setting of persistent radiographic abnormalities.

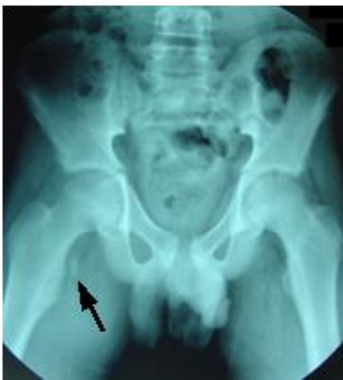

Image 1. Radiograph of the pelvis of a 14-year-old patient showing an avulsion of the right lesser trochanter (arrow) compared to the left normal hip.

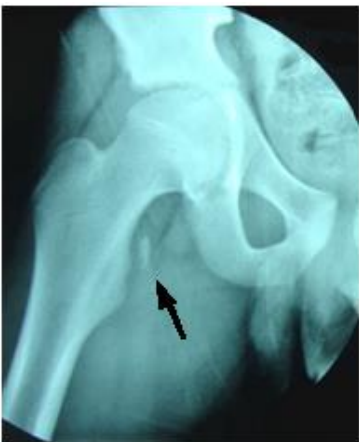

Image 2. Apophyseal avulsion fracture of lesser trochanter with proximal displacement of fracture fragment (arrow).

Address for Correspondence: Mohamed Habib Grissa MD, Fattouma Bourguiba University Hospital, Rue 1er Juin 5000, Monastir, Tunisia. Email: grissa.med.habib@gmail.com.

Conflicts of Interest: By the CPC-EM article submission agreement, all authors are required to disclose all affiliations, funding sources and financial or management relationships that could be perceived as potential sources of bias. The authors disclosed none.

Copyright: © 2017 Grissa et al. This is an open access article distributed in accordance with the terms of the Creative Commons Attribution (CC BY 4.0) License. See: <http://creativecommons.org/licenses/by/4.0/>

REFERENCES

1. Theologis TN, Epps H, Latz K, et al. Isolated fractures of the lesser trochanter in children. *Injury*. 1997;28(5-6):363-4.
2. Fasting OJ. Avulsion of the less trochanter. *Arch Orthop Trauma Surg*. 1978;91(1):81-3.
3. Reider B. *Sports Medicine: The School-Age Athlete*. Philadelphia: Saunders. 1996;(2):720-1.
4. Linni K, Mayr J, Höllwarth ME. [Apophyseal fractures of the pelvis and trochanter minor in 20 adolescents and 2 young children]. *Unfallchirurg*. 2000;103(11):961-4.
5. Naude M, Lindeque BGP, Janse van Rensburg DC. Avulsion fractures of the pelvis. *SAJM*. 2003;15:18-24.
6. Afra R, Boardman DL, Kabo JM, et al. Avulsion fracture of the lesser trochanter as a result of a preliminary malignant tumor of bone. A report of four cases. *J Bone Joint Surg Am*. 1999;81(9):1299-304.
7. Sundar M, Carty H. Avulsion fractures of the pelvis in children: a report of 32 fractures and their outcome. *Skeletal Radiol*. 1994;23(2):85-90.
8. Fernbach SK, Wilkinson RH. Avulsion injuries of the pelvis and proximal femur. *AJR Am J Roentgenol*. 1981;137(3):581-4.

Pyogenic Flexor Tenosynovitis in an Infant

James I. Gragg, DO
Ryder Olsen, DO
S. Briant Stringham, DO

Carl R. Darnall Army Medical Center, Department of Emergency Medicine, Fort Hood, Texas

Section Editor: Rick McPheeters, DO

Submission history: Submitted July 11, 2016; Revision received December 5, 2016; Accepted December 9, 2016

Electronically published March 13, 2017

Full text available through open access at http://escholarship.org/uc/uciem_cpem

DOI: 10.5811/cpcem.2016.12.31521

Pyogenic flexor tenosynovitis is a rare, though well known infectious process of the flexor tendon sheath of the hand. This condition is generally diagnosed in adults by the observance of the four Kanavel signs. Application of the Kanavel signs to diagnosis in the pediatric population, however, is of unknown utility. We present the case of a 13-month-old male with pyogenic flexor tenosynovitis who presented with all four of the Kanavel signs. [Clin Pract Cases Emerg Med. 2017;1(2):89–91.]

INTRODUCTION

Pyogenic flexor tenosynovitis (PFT) is an acute or subacute infectious process of the flexor tendon sheath of the digits. Dr. Kanavel first described the process in 1912 in his textbook on surgical infections of the hand. At the time he outlined three cardinal signs and symptoms of the disease: excessive tenderness over the course of the sheath; symmetric enlargement of the whole finger; excruciating pain on extending the finger.¹ Later, he described the finger being held slightly flexed.¹ Together, these four signs and symptoms are now known as the Kanavel signs and should lead the clinician to suspect pyogenic infection of the tendon sheath.

There are three main mechanisms of infection, the most common being direct inoculation from trauma, laceration, or bite. Less frequently, contiguous spread from a local infection such as a felon or paronychia, or hematogenous spread may occur. Precipitous spread of the infection occurs due to the avascular nature of the synovial sheath. The sheath receives all blood supply from surrounding tissue; as such, the infection is relatively protected from the immune response.² Rapid assessment and diagnosis is imperative to prevent both short-term and long-term sequelae: stiffness, loss of motion across the inter-phalangeal joints, deformity with soft-tissue loss, osteomyelitis, or spread of infection with resultant amputation.³

Unfortunately, despite the use of the Kanavel signs over the past century, there are no studies to validate the

sensitivity or specificity of these signs, nor their ability to positively diagnose PFT. The disease has a low incidence, and lack of studies is likely related to limited patient presentations with the resultant non-feasibility of prospective trials. In one retrospective review of 75 cases of PFT, fusiform swelling was found in 97%, pain with passive extension in 72%, flexed position in 69% and tenderness along the tendon sheath in 64% of patients.⁴ This report looked only at adult patients, however, and there are minimal reports of tenosynovitis in the pediatric population. As such, the reliability of the Kanavel signs for diagnosis in pediatric patients is of unknown certainty.

CASE REPORT

We present a rare case of PFT in a 13-month-old male. The patient presented during a morning shift to the emergency department (ED) with the chief complaint of finger swelling. His father reported a swollen and erythematous right index finger that started roughly four hours prior to arrival in the ED. The night before he had gone to bed uneventfully, with a normal appearing hand. He awoke tearful the next morning and was brought to the ED for evaluation. The father denied any known injuries or periods of unobserved play.

On physical exam, all four Kanavel signs were present. The finger was held in flexion and circumferentially swollen from fingertip to metacarpal-phalangeal joint (Image 1). When the flexor surface of the finger was palpated or passively

extended, the child immediately cried and appeared distressed. A pustule was also noted on the palmar surface over the proximal interphalangeal (PIP) joint. He was afebrile with normal vital signs, appropriate interactions and non-distressed when left to his own accord. Laboratory studies demonstrated a total leukocyte count of 13.3×10^9 cells/L, an erythrocyte sedimentation rate of 25 mm/hr, and a C-reactive protein level of <0.5 mg/L. On radiograph, a metallic foreign body was identified near the PIP joint (Image 2).

With concern for PFT, orthopedics consultation was obtained and the patient was started on intravenous clindamycin. He was taken to the operating room (OR) emergently for washout and foreign body removal. Pus was noted to be draining from the subcutaneous tissue, but the flexor tendon sheath was not felt to be involved at that time. Unfortunately, the patient had clinical worsening and was taken back to the OR two days later. During the second surgery purulent material was noted within the flexor tendon sheath tracking proximally to the distal palmar crease. Another very small radiolucent foreign body was also discovered and removed. Group A *Streptococcus* was isolated from his

wound culture and after an uneventful 24 hours of observation, he was discharged home on a course of oral antibiotics. A single blood culture was negative after five days of growth. On post-operative day 10, a clinic follow-up visit demonstrated well healing surgical wounds and absence of any of the Kanavel signs.

DISCUSSION

PFT is a serious medical condition requiring emergency surgery to halt progression of infection and limit potential sequelae. While a rare entity in the general population, there are even less data on pediatric tenosynovitis. A case series of only three cases has suggested that the infection is typically preceded by a penetrating injury.⁵ While there was no known injury in our case, the presence of a foreign body and pustule highly suggests a penetrating injury. Additional unique risk factors in the pediatric population include thumb sucking and fingernail biting.⁶ The local trauma induced from these habits weakens the integumentary barrier and can facilitate infection. Not surprisingly, *Staphylococcus* and *Streptococcus* are the most commonly isolated organisms in the adult population,

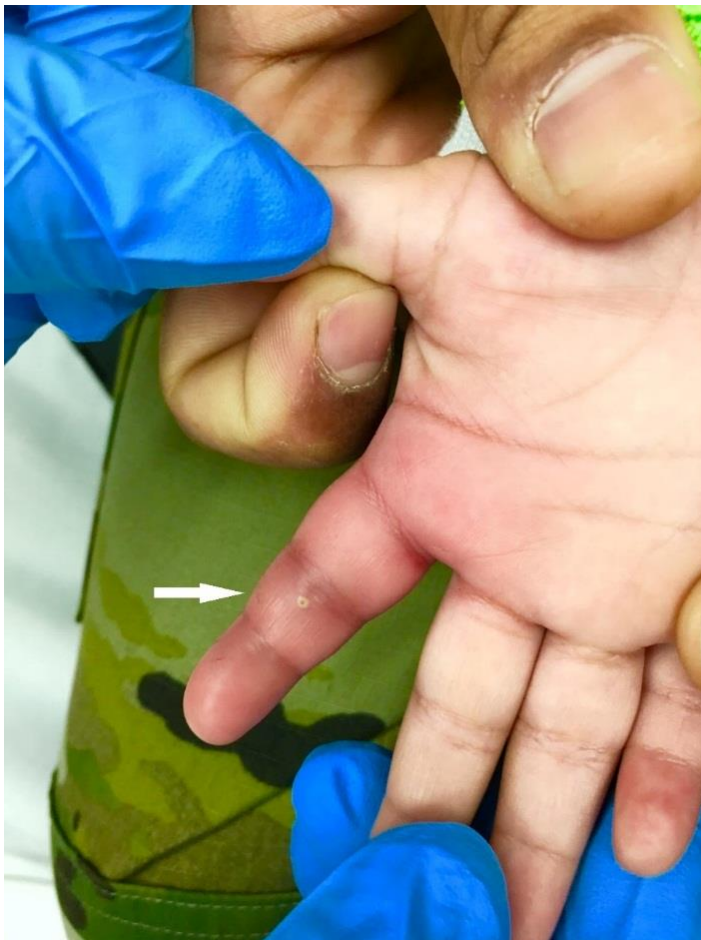

Image 1. Right index finger with fusiform swelling and erythema. Note the pustule over the proximal inter-phalangeal joint (arrow).

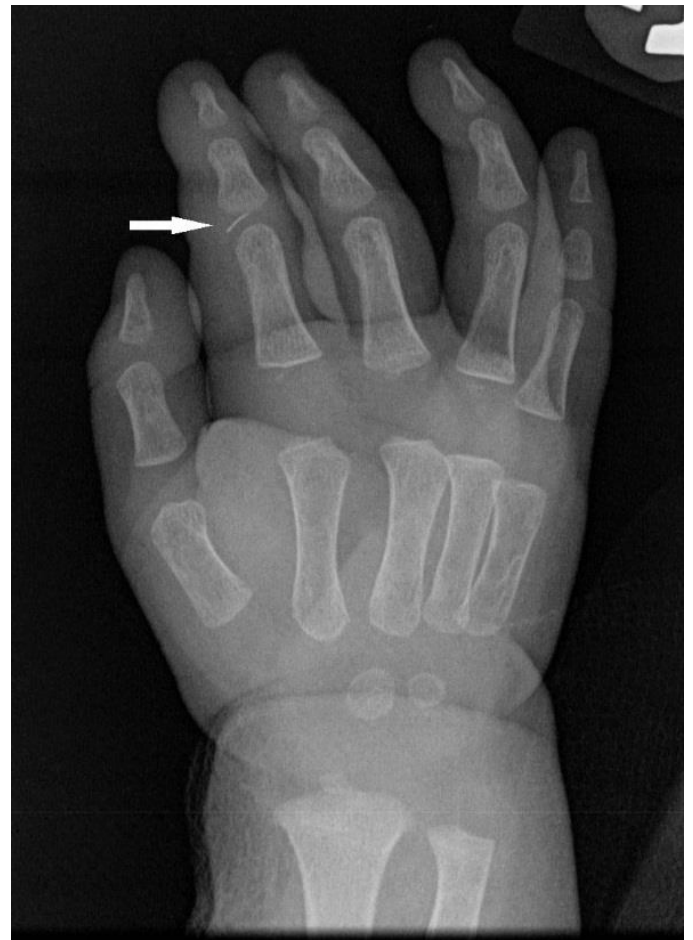

Image 2. Radiograph of right hand: Note the foreign body within the index finger proximal inter-phalangeal joint (arrow).

a trend also seen in pediatric hand infections.⁶ Antibiotics should, therefore, be targeted against natural skin flora while awaiting surgical infection control.

A high index of suspicion is needed to make the diagnosis of PFT. Definitive diagnosis is confirmed by wound culture, although the clinical presentation suggests the need for surgery. As mentioned, the Kanavel signs have not been prospectively validated in children. The Luria and Haze case series had two cases presenting with all four Kanavel signs and another case presenting with only two.⁵ Interestingly, the last case presented with the fingers held in extension rather than the expected flexion.⁵ Our patient did have all four signs present on admission.

Additionally, patients will typically be afebrile and radiographs are usually normal, making the diagnosis more difficult. While the clinical presentation may be sufficient to proceed directly with surgery, other imaging modalities may help in the evaluation. Magnetic resonance imaging, if available, may show fluid collection in the tendon sheath.⁷ Point-of-care ultrasound is another option for the evaluation of indeterminate cases. A stand-off pad or water bath is best used to identify hypochoic fluid within the tendon sheath; comparison to the normal contralateral digit will aid the interpretation.⁸ Ultimately the decision to proceed with surgery is made by the consulting service; however, the emergency physician should not hesitate to begin intravenous antibiotics.

CONCLUSION

PFT is a rare infection that can be easily mistaken for other infectious states such as cellulitis or septic arthritis. This report demonstrates that the Kanavel signs may help the clinician with early identification of PFT in the pediatric population and facilitate prompt treatment.

Address for Correspondence: James Gragg DO, Carl R. Darnall Army Medical Center, 36065 Santa Fe Avenue, Fort Hood, TX 76544. Email: gragg.james@gmail.com.

Conflicts of Interest: By the *CPC-EM* article submission agreement, all authors are required to disclose all affiliations, funding sources and financial or management relationships that could be perceived as potential sources of bias. Any opinions, findings, conclusions, or recommendations expressed in this article are those of the authors and do not necessarily reflect the views of the United States Army, Department of Defense, or the US government. Authors have no financial conflicts of interest to disclose.

Copyright: © 2017 Gragg et al. This is an open access article distributed in accordance with the terms of the Creative Commons Attribution ([CC BY 4.0](http://creativecommons.org/licenses/by/4.0/)) License. See: <http://creativecommons.org/licenses/by/4.0/>

REFERENCES

1. Kanavel AB. Infections of the Hand. Lea & Febiger. 1912(1):201–26.
2. Draeger RW, Bynum DK Jr. Flexor tendon sheath infections of the hand. *J Am Acad Orthop Surg*. 2012;20(6):373-82.
3. Kennedy CD, Huang JI, Hanel DP. In Brief: Kanavel's Signs and Pyogenic Flexor Tenosynovitis. *Clin Orthop Relat Res*. 2016;474(1):280-4.
4. Pang HN, Teoh LC, Yam AK, et al. Factors affecting the prognosis of pyogenic flexor tenosynovitis. *J Bone Joint Surg Am*. 2007;89(8):1742-8.
5. Luria S, Haze A. Pyogenic flexor tenosynovitis in children. *Pediatr Emerg Care*. 2011;27(8):740-1.
6. Harness N, Blazar PE. Causative microorganisms in surgically treated pediatric hand infections. *J Hand Surg Am*. 2005;30(6):1294-7.
7. Ceroni D, Merlini L, Salvo D, et al. Pyogenic flexor tenosynovitis of the finger due to *Kingella kingae*. *Pediatr Infect Dis J*. 2013;32(6):702-3.
8. Cohen SG, Beck SC. Point-of-Care Ultrasound in the Evaluation of Pyogenic Flexor Tenosynovitis. *Pediatr Emerg Care*. 2015;31(11):805-7.

Emphysematous Pyelonephritis: Bedside Ultrasound Diagnosis in the Emergency Department

Gillian McCafferty, MD*
 Amanda Shorette, MD†
 Sukhdeep Singh, MD†
 Gavin Budhram, MD†

*Lahey Hospital and Medical Center, Department of Emergency Medicine, Burlington, Massachusetts

†University of Massachusetts Medical School-Baystate Health Springfield Campus, Baystate Medical Center, Department of Emergency Medicine, Springfield, Massachusetts

Section Editor: Shadi Lahham, MD, MS

Submission history: Submitted September 30, 2016; Revision received November 30, 2016; Accepted December 12, 2016

Electronically published March 14, 2017

Full text available through open access at http://escholarship.org/uc/uciem_cpccem

DOI: 10.5811/cpcem.2016.12.32714

Emphysematous pyelonephritis (EPN) is a rare, life-threatening infection, and misdiagnosis as uncomplicated pyelonephritis is potentially fatal. Point-of-care ultrasound (POCUS) is a valuable tool for evaluation of the kidneys in patients with septic shock and pyelonephritis. While used primarily to assess for the complication of obstruction and hydronephrosis, POCUS may also detect signs of EPN and prompt surgical consultation for nephrectomy. We present a case in which the emergency physician diagnosed EPN by POCUS in a patient with septic shock and pyelonephritis. [Clin Pract Cases Emerg Med. 2017;1(2):92–94.]

INTRODUCTION

Emphysematous pyelonephritis (EPN) is a rare, life-threatening, necrotizing complication of pyelonephritis, which is usually associated with uncontrolled diabetes mellitus (DM) or ureteral obstruction.^{1,2} Misdiagnosis as uncomplicated pyelonephritis is potentially fatal since mortality is as high as 71-80% in those treated with antibiotics alone but improves to 20-29% with nephrectomy.^{3,4} In this report we describe a case of EPN that presented with abdominal pain and peritonitis and was diagnosed by point-of-care ultrasound (POCUS).

CASE REPORT

An 84-year-old woman with diabetes, hypertension, and chronic kidney disease presented to our emergency department with four days of right flank pain with nausea, vomiting, and anorexia. She was febrile (39°C/102.2°F), tachycardic (heart rate 132), tachypneic (respiratory rate 27), and hypotensive (98/63 mmHg). On examination she was ill appearing, diaphoretic, and had tenderness in the right flank and right costophrenic angle.

In addition to performing a rapid ultrasound in shock (RUSH) examination to assess cardiac function, fluid status and sources of shock, ultrasound showed an enlarged

right kidney with echogenic foci in the renal medulla and reverberation artifacts representing air, referred to as “dirty shadowing” (Image 1).⁵ This was concerning for EPN, prompting emergent urology consultation.

Significant laboratory tests included a white blood cell

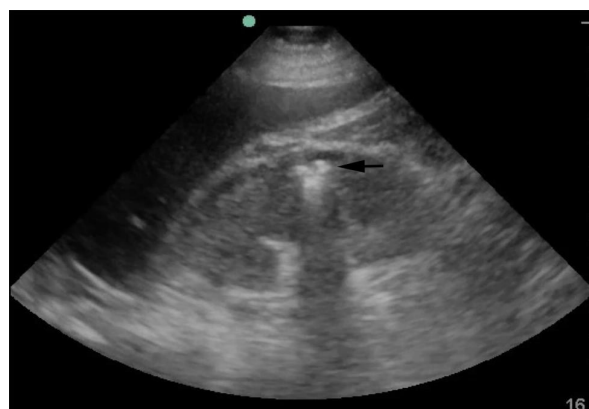

Image 1. Point-of-care ultrasound demonstrating emphysematous pyelonephritis. In this still image, air can be seen in the renal cortex as a hyperechoic focus (black arrow) with posterior “dirty shadowing” as a result of reverberation artifact.

count of 14,600/mm³, an anion gap acidosis with bicarbonate of 14mmol/L, lactate of 8.4mmol/L, pH 7.26, and kidney injury with creatinine 4.0mg/dL. Urinalysis showed heavy bacteria and pyuria. The computed tomography (CT) demonstrated air in the right kidney consistent with EPN (Image 2). Antibiotics were started and the consulting urologist recommended conservative management and admission to the intensive care unit.

For the next few days the patient appeared to be improving, but on hospital day six she developed altered mental status, fever, and hypotension requiring vasopressors. She was taken emergently to the operating room where an open right nephrectomy was performed. Following surgery her condition improved, renal function returned to baseline, and delirium resolved. After a short stay in a rehabilitation facility she returned home.

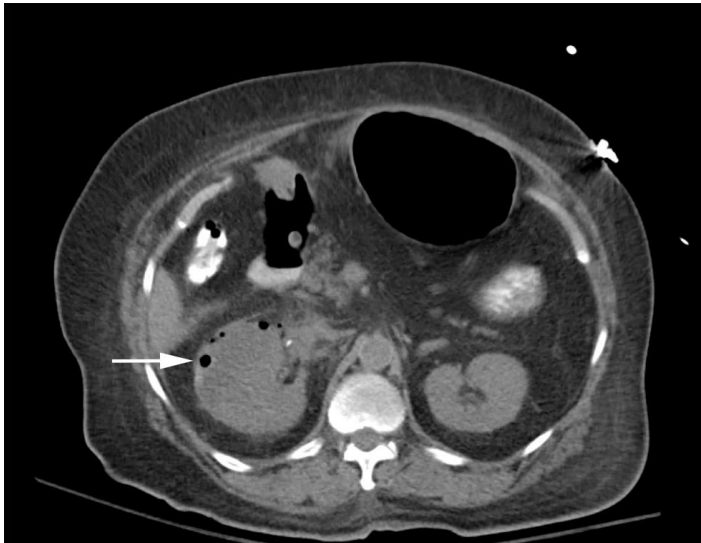

Image 2. Computed tomography of the abdomen and pelvis showing an enlarged right kidney with perinephric stranding and air in the renal cortex (white arrow) consistent with emphysematous pyelonephritis.

DISCUSSION

Emphysematous pyelonephritis (EPN) is an acute, severe, necrotizing bacterial infection of the renal parenchyma and surrounding tissues associated with high mortality. Kelly and MacCallum reported the first case of EPN in 1898, referring to the diagnosis as pneumaturia.⁶ Initially thought to be extremely rare, the increased use of CT has resulted in more reported cases.⁷ Although described as a rare disease process, the exact incidence of EPN in recent years is poorly described.

The majority of patients have a history of diabetes mellitus. There is also a female predominance (75%), which

is likely due to the higher rate of urinary tract infections in women.⁸ Urinary tract obstruction is the most frequent cause of EPN in the absence of diabetes mellitus. Ureteral obstruction was described in 50% of diabetic EPN cases and 100% of non-diabetic EPN cases.⁹

The clinical presentation is often similar to acute pyelonephritis with complaints of fever, chills, abdominal or flank pain, dysuria, nausea, vomiting, lethargy, and confusion. Laboratory findings often consist of pyuria, thrombocytopenia, and acute kidney injury.^{1,2} Emergency physicians (EP), however, must have a high level of suspicion for more serious acute renal infections in patients presenting with sepsis, shock, or those who have not responded to previous antibiotic treatment.

The diagnosis of EPN is most often made by CT that demonstrates air within the renal parenchyma or renal sinus.⁹ Although no studies exist that directly compare the test characteristics of CT and ultrasound for EPN, several authors have advocated POCUS as an early diagnostic tool to facilitate surgical management.¹⁰ In a 2011 retrospective study of 206 patients with acute pyelonephritis, 60.9% had structural abnormalities detected on POCUS. In 34.3%, the ultrasound findings effectively diverted the patient to receive surgical interventions including percutaneous nephrostomy, abscess aspiration, ureteroscopic stone manipulation, lithotripsy, or nephrectomy.¹¹ In patients with suspected EPN or established diagnosis of EPN by POCUS, a non-contrast CT should be obtained to confirm the diagnosis and to provide details regarding the extent of infection.¹²⁻¹⁴

Characteristic ultrasound findings of EPN include echogenic foci in the kidney with posterior “dirty shadowing” caused by reverberation artifact from air. This should be differentiated from the posterior acoustic shadowing of intrarenal calculi, which have a distinctive echo-free shadow distal to the calculus.¹⁵ If fluid collections are present, EPs may note ring-down artifact from air trapped within fluid collections. In severe cases in which there is a significant amount of air or perinephric fluid, the artifact may completely obscure the kidney and make visualization difficult or even impossible.^{7,15}

Treatment of EPN includes aggressive resuscitation, antibiotics, percutaneous drainage, or open nephrectomy. Causative organisms are most commonly *E. coli* and *K. pneumoniae*.⁷ Classic treatment of EPN involves broad spectrum antibiotics and emergent nephrectomy, although with less severe cases of EPN antibiotics and percutaneous drainage may effectively treat the infection.¹⁶ The overall mortality of EPN is estimated to be 25-42%.^{10,15} One study reports a survival rate of 29% with antibiotics alone but a 71% survival rate if both antibiotics and surgical intervention are implemented.¹⁰ Other studies report a mortality rate as high as 50-70% with antibiotics alone but improved mortality of 7-13.5% with antibiotics plus surgery or percutaneous drainage.^{9,10,15}

CONCLUSION

EPs using POCUS in the evaluation of critically ill patients with pyelonephritis should be aware of the sonographic appearance of emphysematous pyelonephritis. In these patients, the characteristic appearance of echogenic foci and dirty shadowing within the kidney can expedite treatment and urology consultation for nephrectomy.

Address for Correspondence: Amanda Shorette MD, Baystate Medical Center, 759 Chestnut Street Springfield, MA 01199. Email: Amanda.ShoretteMD@baystatehealth.org.

Conflicts of Interest: By the CPC-EM article submission agreement, all authors are required to disclose all affiliations, funding sources and financial or management relationships that could be perceived as potential sources of bias. The authors disclosed none.

Copyright: © 2017 McCafferty et al. This is an open access article distributed in accordance with the terms of the Creative Commons Attribution (CC BY 4.0) License. See: <http://creativecommons.org/licenses/by/4.0/>

REFERENCES

1. Michaeli J, Mogle P, Perlberg S, et al. Emphysematous pyelonephritis. *J Urol.* 1984;131(2):203-8.
2. Pontin AR, Barnes RD, Joffe J, et al. Emphysematous pyelonephritis in diabetic patients. *Br J Urol.* 1995;75(1):71-4.
3. Evanoff GV, Thompson CS, Foley R, et al. Spectrum of gas within the kidney. Emphysematous pyelonephritis and emphysematous pyelitis. *Am J Med.* 1987;83(1):149-54.
4. Klein FA, Smith MJ, Vick CW III, et al. Emphysematous pyelonephritis: diagnosis and treatment. *South Med J.* 1986;79(1):41-6.
5. Perera P, Mailhot T, Riley D, et al. The RUSH Exam 2012: Rapid ultrasound in shock in the evaluation of the critically ill patient. *Ultr Clin.* 2012;7:255-78.
6. Kelly H, MacCallum W. Pneumaturia. *JAMA.* 1898; 31:375-81.
7. Huang JJ, Tseng CC. Emphysematous pyelonephritis: clinicoradiological classification, management, prognosis, and pathogenesis. *Arch Intern Med.* 2000;160(6):797-805.
8. Shokeir AA, El-Azab M, Mohsen T, et al. Emphysematous pyelonephritis: a 15-year experience with 20 cases. *Urology.* 1997;49(3):343-6.
9. Stone SC, Mallon WK, Childs JM, et al. Emphysematous pyelonephritis: clues to rapid diagnosis in the emergency department. *J Emerg Med.* 2005;28(3):315-9.
10. Jain SK, Agarwal N, Chaturvedi SK. Emphysematous pyelonephritis: a rare presentation. *J Postgrad Med.* 2000;46(1):31-2.
11. Chen KC, Hung SW, Seow VK, et al. The role of emergency ultrasound for evaluating acute pyelonephritis in the ED. *Am J Emerg Med.* 2011;29(7):721-4.
12. Ahlering TE, Boyd SD, Hamilton CL, et al. Emphysematous pyelonephritis: a 5-year experience with 13 patients. *J Urol.* 1985;134(6):1086-8.
13. Hoddick W, Jeffrey RB, Goldberg HI, et al. CT and sonography of severe renal and perirenal infections. *AJR Am J Roentgenol.* 1983;140(3):517-20.
14. Vas W, Carlin B, Salimi Z, et al. CT diagnosis of emphysematous pyelonephritis. *Comput Radiol.* 1985;9(1):37-9.
15. Allen HA III, Walsh JW, Brewer WH, et al. Sonography of emphysematous pyelonephritis. *J Ultrasound Med.* 1984;3(12):533-7.
16. Cardinael AS, De Blay V, Gilbeau JP. Emphysematous pyelonephritis: successful treatment with percutaneous drainage. *AJR Am J Roentgenol.* 1995;164(6):1554-5.

Wernicke's Encephalopathy in a Patient Without Chronic Alcohol Abuse

Darshan Thota, MD
Sherri Rudinsky, MD

Naval Medical Center, Department of Emergency Medicine, San Diego, California

Section Editor: Rick A. McPheeters, DO

Submission history: Submitted October 5, 2016; Revision received December 8, 2016; Accepted December 12, 2016

Electronically published March 14, 2017

Full text available through open access at http://escholarship.org/uc/uciem_cpem

DOI: 10.5811/cpem.2016.12.32769

Wernicke's encephalopathy (WE) is traditionally seen in the emergency department in patients with chronic alcohol abuse. WE can result in significant morbidity and mortality if untreated, making early diagnosis and intervention paramount. We discuss a case of WE in a 63-year-old female with no history of chronic alcohol abuse, who presented with bilateral ophthalmoplegia that resolved after intravenous thiamine administration. This case report highlights the varied clinical settings other than chronic alcohol abuse in which the diagnosis of WE should be considered. [Clin Pract Cases Emerg Med. 2017;1(2):95–97.]

INTRODUCTION

Wernicke's encephalopathy (WE) is traditionally associated with chronic alcohol abuse and characterized by some combination of ataxia, ophthalmoplegia, and altered mental status. Chronic alcohol abuse is the most commonly recognized presentation in the emergency department (ED). However, WE has been increasingly recognized in other high-risk clinical settings such as anorexia, post gastric bypass surgery, hyperemesis, AIDS, TPN, and malignancy. WE is still greatly under-recognized based on autopsy data.¹ Atypical presentations are important to recognize because treatment with thiamine can prevent serious adverse effects such as permanent mental impairment and coma. We present a case of one such atypical presentation to highlight the various risk factors and clinical settings in which WE can occur.

CASE REPORT

A 63-year old-female presented to the ED with three days of headache, diplopia, and gait instability. The symptoms began while the patient was watching television and progressively worsened over three days. The headache was described as a pressure, located on the left temple without associated neck stiffness or photophobia. The diplopia was binocular and horizontal. She described her gait instability as "walking like I am drunk." She reported decreased oral intake over the previous day due to "not feeling well." Recent medical history included community-acquired pneumonia, currently on day 5 of 10 of moxifloxacin. She had no recent

travel or changes in her daily activities. The patient had no history of stroke, bariatric surgery or recent vomiting. The patient and family denied a history of alcohol use.

On exam, blood pressure 139/80, heart rate 67, respiratory rate 16, room air oxygen saturation 98% and temperature 97.3 degrees Fahrenheit. She was well nourished, well developed and in no acute distress. Her head was atraumatic with moist mucous membranes. The patient was awake, alert, and oriented to person, place and time. Her eyes were anicteric and the left eye displayed ptosis. Her left pupil was sluggish compared to the right, but both were reactive. Uncorrected visual acuity was 20/60 OD and 20/60 OS. Left eye demonstrated complete paralysis of extraocular movements; right eye demonstrated 10-15 degrees of movement in all directions, and nystagmus in right eye on lateral gaze. The remaining cranial nerves were intact. She had intact strength and sensation to light touch throughout the upper and lower extremities. Cerebellar testing was remarkable for past pointing on the left with finger to nose, and her gait was characterized by small, unsteady steps with ambulation in the ED. The remainder of her exam was unremarkable.

Ancillary testing in the ED was remarkable for a white blood cell count of 14,400/uL, hemoglobin of 15.0 g/uL, hematocrit of 43.4%, and platelet count of 527,000/uL. Chemistry panel, liver function studies and erythrocyte sedimentation rate were all within normal limits.

An emergent, non-contrast head computed tomography (CT) was performed, which did not show an acute intracranial

hemorrhage, mass effect or midline shift. A brain and neck magnetic resonance imaging and angiography (MRI/MRA) were obtained, which did not demonstrate a cortical lesion, aneurysm or other vascular defect to explain her symptoms. Her case was discussed further with neurology and she was started on high-dose thiamine for concerns of WE and admitted to the internal medicine service for further evaluation. No thiamine level was obtained during her initial admission.

Her symptoms did improve after parenteral high-dose thiamine. She was discharged on hospital day three with continued oral thiamine supplementation. At her one-month neurology follow-up appointment she still had a mild ophthalmoplegia but was otherwise back to her baseline functional status.

DISCUSSION

The symptom cluster of ataxia, ophthalmoplegia, and encephalopathy was first described as "polioencephalitis hemorrhagica superioris" by Carl Wernicke in 1881 in a 20-year-old female who developed pyloric stenosis and projectile vomiting after an unintentional sulfuric acid ingestion.² Thiamine deficiency was not identified as the underlying cause of WE until the 1940s.² In the United States, WE is most commonly recognized in the setting of nutritional deficiencies related to chronic alcohol abuse. The prevalence of WE is 2% in the general population but up to 12.5% in chronic alcoholics.³ However, Wernicke's original case and our patient both highlight the importance of considering this diagnosis in clinical settings other than chronic alcohol abuse.

Any patient with a nutritional deficiency has the potential to develop WE. In one retrospective autopsy study, 12 of 52 (23%) cases of WE did not occur in alcoholics.⁴ A growing number of predisposing factors and clinical settings have been associated with the development of WE and have been reported in the literature to include anorexia nervosa, gastrointestinal surgery including gastric bypass surgery, cyclic vomiting, hyperemesis gravidarum, cancer and chemotherapeutic agents specifically 5-Fluorouracil and Cisplatin, peritoneal and hemodialysis, chronic TPN, thyrotoxicosis and AIDS.⁵⁻¹³ Given the varied clinical presentations, a high index of clinical suspicion is needed.

WE is a clinical diagnosis characterized by ophthalmoplegia, mental status changes, and unsteadiness of stance and gait. This symptom triad is only seen in up to 16% of cases.¹⁴ No specific lab tests or radiographs are pathognomonic in diagnosing WE. Only one or two symptoms from the triad may be present upon initial presentation and symptoms vary for each component. Nystagmus is the ocular abnormality most commonly recognized and occurs in up to 29% of patients; it can be either horizontal or vertical in direction.¹ Other reported ocular abnormalities include ophthalmoplegia, gaze palsies, anisocoria, and retinal hemorrhages.¹

Changes in mental status are common at presentation, occurring in 80-90% based on retrospective reviews.¹ These changes can range from confusion, memory difficulty, mild

delirium, confabulation, apathy, decreased concentration, and coma. Neuropsychiatric symptoms, such as hallucinations, delusions, and agitation, which may mimic acute psychosis, have also been described.¹ Ataxia can present as both truncal and gait based with loss of vestibular equilibrium affecting the cerebellar vermis in 23% of patients.¹

Given the varied spectrum of disease, WE can be a difficult diagnosis to make. A combination of four operational criteria has demonstrated improvement in the identification of WE in chronic alcoholics.¹⁵ Demonstrating two of four criteria – dietary deficiencies, oculomotor abnormalities, cerebellar dysfunction, and altered mental status or mild memory impairment – results in a sensitivity and specificity of 100% and 98% respectively. Expanding the definition to include dietary deficiencies improved the sensitivity in diagnosing WE from 22% to 85% in one retrospective review.¹⁵ Our patient met two of the four criteria, lacking altered mental status and dietary deficiency. Expanding the traditional definition of WE to include any dietary deficiency and recognizing the spectrum of presenting symptoms will improve provider recognition of WE.

WE remains a clinical diagnosis without definitive laboratory studies, imaging, cerebrospinal fluid or electroencephalograph findings. Though not overly sensitive, MRI can sometimes help in confirming the diagnosis of suspected WE. The most specific MRI findings are cytotoxic and vasogenic edema in the third ventricle, mammillary bodies, midbrain tectal plate, and periaqueductal area.¹⁶ These changes typically occur within 2-3 weeks of thiamine deficiency.¹ The sensitivity and specificity of MRI for diagnosing WE have been reported as 53% and 93% respectively.¹⁷ The MRI findings noted above are not specific to WE and may be seen in other disease processes.¹⁸

WE is a medical emergency and left untreated can progress to Korsakoff syndrome and beriberi. Korsakoff is seen in 80% of acute Wernicke's episodes and is characterized by confabulation and deficits in working memory.¹⁹ Beriberi can either be cardiogenic resulting in heart failure and edema, or neuropathic resulting in paresthesias. With the significant morbidity of Korsakoff syndrome and reported 17% mortality rate of WE, early treatment with thiamine is of key importance. Classic teaching dictates correction of hypoglycemia prior to thiamine administration to prevent worsening WE. However, a recent review of 14 articles found no data to support this recommendation and stressed importance of treating symptomatic hypoglycemia acutely.²⁰ There is a paucity of data regarding the optimal intravenous or enteral thiamine replacement strategies. However, 500 mg thiamine dissolved in 100 ml of normal saline infused intravascularly over 30 minutes acutely in the ED followed by a maintenance dose of 500 mg IV three times a day for 2-3 days is thought to be optimal treatment for WE. Clinical improvement is anticipated in 2-3 days and if seen, 250 mg orally daily is then given for 3-5 days.¹ Nystagmus and ophthalmoplegia typically resolve within hours to days, while ataxia and mental status changes can take up to

weeks to months to resolve completely.⁵

Several other disease states may mimic WE. In our differential diagnosis we considered intracranial mass lesions, hemorrhage, infarcts, meningitis and other infection to include syphilis and Lyme disease, glaucoma, hypoglycemia, electrolyte abnormalities, Miller Fisher variant of Guillain-Barré syndrome, Horner's syndrome, and multiple sclerosis. Our patient's CT showed no structural disease. Her physical exam and history were inconsistent for meningitis and she had no recent travel to suggest Lyme. In our patient, an extensive evaluation for other etiologies to explain her symptoms was negative. Though moxifloxacin is known to cause peripheral neuropathies, it is unlikely to be the cause of the patient's ophthalmoplegia. Thyroid disease and HIV can cause ocular symptoms and cranial neuropathies; however, both HIV and thyroid function tests were negative in our patient.

CONCLUSION

Our case report highlights the varied clinical settings in which WE may present and the need to entertain the diagnosis and look for predisposing factors in any patient presenting with ataxia, ophthalmoplegia or mental status changes regardless of history of chronic alcohol use. Given the high morbidity and mortality and simple therapeutic interventions, emergency physicians have the ability to make a timely and dramatic impact in the outcome of these patients' disease course.

Address for Correspondence: Darshan Thota MD, Naval Medical Center San Diego, 3rd Medical Battalion, 3rd MLG, Camp Foster, H and S Company Unit 38447, Okinawa, FPO AP 96373. Email: darshan.s.thota.mil@mail.mil.

Conflicts of Interest: By the CPC-EM article submission agreement, all authors are required to disclose all affiliations, funding sources and financial or management relationships that could be perceived as potential sources of bias. Disclaimer: The views expressed herein are our own and do not necessarily reflect the official policy or position of the Department of the Navy, Department of Defense, or the U.S. Government.

Copyright: © 2017 Thota et al. This is an open access article distributed in accordance with the terms of the Creative Commons Attribution (CC BY 4.0) License. See: <http://creativecommons.org/licenses/by/4.0/>

REFERENCES

- Sechi G, Serra A. Wernicke's encephalopathy: new clinical settings and recent advances in diagnosis and management. *Lancet Neurol*. 2007;6(5):442-55.
- Campbell ACP, Biggart JH. Wernicke's encephalopathy (polioencephalitis hæmorrhagica superior): Its alcoholic and non-alcoholic incidence. *J Pathol*. 1939;48(2): 245-62.
- Donnino MW, Vega J, Miller J, et al. Myths and misconceptions of Wernicke's encephalopathy: what every emergency physician should know. *Ann Emerg Med*. 2007;50(6):715-20.
- Lindboe CF, Løberg EM. Wernicke's encephalopathy in non-alcoholics. An autopsy study. *J Neurol Sci*. 1989;90(2):125-9.
- Saad L, Silva LF, Banzato CE, et al. Anorexia nervosa and Wernicke-Korsakoff syndrome: a case report. *J Med Case Rep*. 2010;4:217.
- Walker J, Kepner A. Wernicke's encephalopathy presenting as acute psychosis after gastric bypass. *J Emerg Med*. 2012;43(5):811-4.
- Baer TE, DiVasta A. An unusual complication of rapid weight loss. *Adolesc Med State Art Rev*. 2012;23(2):215-21.
- Kotha VK, De Souza A. Wernicke's encephalopathy following Hyperemesis gravidarum. A report of three cases. *Neuroradiol J*. 2013;26(1):35-40.
- Kondo K, Fujiwara M, Murase M, et al. Severe acute metabolic acidosis and Wernicke's encephalopathy following chemotherapy with 5-fluorouracil and cisplatin: case report and review of the literature. *Jpn J Clin Oncol*. 1996;26(4):234-6.
- Jagadha V, Deck JH, Halliday WC, et al. Wernicke's encephalopathy in patients on peritoneal dialysis or hemodialysis. *Ann Neurol*. 1987;21(1):78-84.
- Hahn JS, Berquist W, Alcorn DM, et al. Wernicke encephalopathy and beriberi during total parenteral nutrition attributable to multivitamin infusion shortage. *Pediatrics*. 1998;101(1):E10.
- Bonucchi J, Hassan I, Policeni B, et al. Thyrotoxicosis associated Wernicke's encephalopathy. *J Gen Intern Med*. 2008;23(1):106-9.
- Boldorini R, Vago L, Lechi A, et al. Wernicke's encephalopathy: occurrence and pathological aspects in a series of 400 AIDS patients. *Acta Biomed Ateneo Parmense*. 1992;63(1-2):43-9.
- Harper CG, Giles M, Finlay-Jones R. Clinical signs in the Wernicke-Korsakoff complex: a retrospective analysis of 131 cases diagnosed at necropsy. *J Neurol Neurosurg Psychiatry*. 1986;49(4):341-5.
- Caine D, Halliday GM, Kril JJ, et al. Operational criteria for the classification of chronic alcoholics: identification of Wernicke's encephalopathy. *J Neurol Neurosurg Psychiatry*. 1997;62(1):51-60.
- Jung YC, Chanraud S, Sullivan EV. Neuroimaging of Wernicke's encephalopathy and Korsakoff's syndrome. *Neuropsychol Rev*. (2012);22(2):170-80.
- Antunez E, Estruch R, Cardenal C, et al. Usefulness of CT and MR imaging in the diagnosis of acute Wernicke's encephalopathy. *AJR Am J Roentgenol*. 1998;171(4):1131-7.
- Weidauer S, Nichtweiss M, Lanfermann H, et al. Wernicke encephalopathy: MR findings and clinical presentation. *Eur Radiol*. 2003;13(5):1001-9.
- Victor M, Adams RD, Collins GH. The Wernicke-Korsakoff Syndrome and Related Neurologic Disorders Due to Alcoholism and Malnutrition. F.A. Davis Company. 1989(2).
- Schabelman E, Kuo D. Glucose before thiamine for Wernicke encephalopathy: a literature review. *J Emerg Med*. 2012;42(4):488-94.

Burn-induced Myxedema Crisis

Ann S. Batista, MD
Laura L. Zane, PharmD
Lane M. Smith, MD, PhD

Wake Forest School of Medicine, Department of Emergency Medicine, Winston-Salem, North Carolina

Section Editor: Rick A. McPheeters, DO

Submission history: Submitted June 16, 2016; Revision received December 10, 2016; Accepted December 12, 2016

Electronically published March 14, 2017

Full text available through open access at http://escholarship.org/uc/uciem_cpccem

DOI: 10.5811/cpcem.2016.16.31301

Myxedema crisis (MC) is a rare but life-threatening illness characterized by multi-system organ impairment from thyroid hormone deficiency that is often brought on by an eliciting event. We present the case of MC with a rapid progression of hypothermia, altered mental status, and respiratory failure that was instigated by a flash burn to the face. The patient's condition was refractory to rewarming and supportive efforts until thyroid hormone was replaced. This case illustrates the need for a high index of suspicion for patients with a rapid onset of metabolic encephalopathy immediately after an injury or burn. [Clin Pract Cases Emerg Med. 2017;1(2):98–100.]

INTRODUCTION

Myxedema crisis (MC) is a rare, life-threatening illness caused by a severe deficiency of thyroid hormone. Precipitating factors include infection, medications (withdrawal of levothyroxine, opiates, lithium, amiodarone, anesthetics, and sedatives), cerebrovascular accident, congestive heart failure, hypothermia, and trauma.¹ The signs and symptoms of MC encompass multiple organ systems and are non-specific. They include hypothermia, generalized edema, ptosis, dry or coarse hair, fatigue, constipation, sinus bradycardia, bundle branch block, complete heart block, delayed reflex relaxation, and decreased mentation.² A high index of suspicion is critical to early diagnosis since mortality approaches 60% if not quickly treated.³ Treatment includes supportive measures, replacing thyroid hormones, stress dose glucocorticoids, and addressing the inciting event or illness.⁴ We present a case of MC with rapid progression of hypothermia, altered mental status, and respiratory failure that was instigated by a flash burn to the face.

CASE REPORT

A 49-year-old female poured gasoline into a running leaf blower resulting in a flash explosion that burned her face and hands. She ran from the scene into her house where she was reportedly still on fire until her family rendered first aid. She was taken to the nearest emergency department (ED) where she received a tetanus shot, wound care to her face, opiate analgesia (4 mg hydromorphone), and benzodiazepines (2 mg lorazepam) over a two-hour period. Records from the outside

hospital document her as confused but normothermic at the time of arrival. She was transferred to our ED for further evaluation and management.

On arrival, she had a heart rate of 68 beats per minute, blood pressure 126/81 mm Hg, respiration rate of 7 breaths per minute, temperature 31.8 °C (89.2 °F), and an oxygen saturation of 97% on 3 liters of oxygen via nasal cannula. First- and second-degree burns were noted on her face and hands. She appeared to be in a stupor, but would awaken to verbal stimuli and follow commands with prompting. Her altered mental status and hypothermia were initially attributed to polypharmacy, and rewarming was begun with a forced-air rewarming blanket and warmed intravenous (IV) fluids. Plastic surgery evaluated her burns and recommended gentle washing with soap and water, applying bacitracin, and outpatient follow-up. However, her overall clinical picture of persistent hypothermia despite rewarming efforts and the new development of vomiting prompted additional laboratory and imaging studies. Her complete blood count, metabolic panel, lactic acid, and urinalysis were normal. An arterial blood gas showed a respiratory acidosis (7.268/55.1/136.2/24.3/-3.2). Her thyroid function revealed an elevated thyroid stimulating hormone (TSH, 25.8 μ IU/ml) and depressed free thyroxine (T4) (0.8 ng/dL) consistent with hypothyroidism. A chest radiograph was obtained showing atelectasis without infiltrate, and she clinically had no evidence of pneumonia prior to being burned. Two peripheral blood cultures were sent and negative for growth at 72 hours.

Based on her elevated TSH, brief periods of bradycardia,

episodes of vomiting (suggesting an ileus), respiratory failure, and history of an inciting event, she met criteria for MC. She was given 200 mcg IV levothyroxine and 100 mg IV hydrocortisone. Her mental status improved quickly with this treatment, and her temperature increased to 34.7 °C (94.5 °F) prior to being moved to her inpatient bed. She continued to improve rapidly after receiving hormone replacement with resolution of her vital sign abnormalities and respiratory failure within 24 hours of admission. She was transitioned to oral levothyroxine, and further steroids were withheld due to normal cortisol levels. She was discharged after two nights with outpatient resources for her burns and levothyroxine for hypothyroidism.

DISCUSSION

We present the unusual case of MC brought on by severe burns to the face. MC is a rare condition with vague, non-specific clinical features that often lead to delays in diagnosis and worse outcomes.⁴ Establishing the diagnosis depends on the patient having characteristic features such as hypothermia, mental status changes, laboratory findings characteristic of hypothyroidism, and exclusion of other causes. A diagnostic scoring system exists (Table) but is rarely used due to the small number of patients from which it is derived.⁵ Scores between 20-60 are considered at risk for MC, while scores greater than 60 are considered high risk or diagnostic. This patient reached a score of 80 based on the degree of hypothermia, somnolence, presence of a precipitating event, gastrointestinal manifestations of ileus, and respiratory failure.

While trauma and burns are recognized as rare precipitating factors for MC, there are no studies defining their incidence.⁶ In addition, most patients will describe some features of hypothyroidism prior to the onset of illness, but this is not uniform.¹ Prior to injury, the patient was healthy and without obvious symptoms of hypothyroidism, although she later recalled having abnormal thyroid function several years prior to this incident. Her presentation was rapid with severe hypothermia, brief periods of bradycardia, altered mental status, and respiratory failure developing within four hours of being burned. This suggests that she was among a small percentage of patients with compensated hypothyroidism whose symptoms manifested due to an impaired stress response.⁷

One confounding or contributing factor in this case was the amount of opiates and benzodiazepine that she received prior to arrival at our hospital. A total of 4 mg of hydromorphone was administered over a two-hour period due to severe pain prior to arrival at our facility. Further doses of opiates and other sedating substances were withheld due to her depressed mental status on arrival. While one could argue that a mixed narcotic-benzodiazepine overdose could cause hypothermia, ileus and altered mental status in the absence of hypothyroidism, we noted that her symptoms persisted for five hours after arrival and more than six hours after her last dose of sedating medications. In addition, her hypothermia was refractory to attempts at active rewarming, and only corrected

Table. Diagnostic scoring system for myxedema crisis

Precipitating Event	
Absent	0
Present	10
Gastrointestinal Findings	
Anorexia/abdominal pain/constipation	5
Decreased intestinal motility	10
Paralytic ileus	15
Cardiovascular Dysfunction	
Heart Rate 50-59	10
Heart Rate 40-49	20
Heart Rate <40	30
Other ECG Changes*	10
Pericardial / Pleural Effusion	10
Pulmonary edema	15
Cardiomegaly	15
Hypotension	20
Metabolic Disturbances	
Hyponatremia	10
Hypoglycemia	10
Hypoxemia	10
Present 10% Decrease in GFR	10
Hypercarbia	10
Thermoregulatory Dysfunction (°C)	
> 35	0
32-35	10
<32	20
Central Nervous System Disturbance	
Absent	0
Lethargic	10
Obtunded	15
Stupor	20
Coma / Seizures	30

ECG, electrocardiogram; GFR, glomerular filtration rate

*Includes: Heart blocks, Non-specific ST changes, bundle branch blocks

when thyroid hormone was replaced. Moreover, iatrogenic overdose may explain some of her clinical features, but it would not explain the characteristic elevation in TSH and depression in her free T4. Thus, we feel that polypharmacy possibly contributed to development of MC, but does not itself account for the entire clinical picture.

Despite cases of myxedema coma being reported as early as the 1800s, very little is known about optimal treatment.^{8,9} Large, randomized controlled trials are hindered by the rarity of the disease; therefore, treatment recommendations are based on case series and reports as well as expert opinion. Holvey and

colleagues estimated that approximately 500 mcg IV thyroxine (T4) is required to replete deficiencies seen in MC, and they demonstrated the efficacy of T4 doses ranging from 200-500 mcg in a case series of seven patients. Vital signs improved within 6-12 hours, and subjects returned to consciousness within the following 24-36 hours.⁸ Another case series of 11 patients found a trend toward lower mortality when high-dose T4 (500 mcg IV) was administered as compared to lower doses.¹⁰

Hydrocortisone and triiodothyroine (T3) are often given despite some controversy surrounding the use of T3 due to reports of cardiovascular complications.⁹ T4 requires conversion to the active hormone T3, and patients with severe illness have impaired conversion.¹¹ Unfortunately, T3 is associated with increased mortality from cardiovascular effects in patients with advanced age, cardiac comorbidity, and high initial doses of T4 (>500 mcg) or T3 (>75 mcg).¹² Thus, low-dose T3 (10-20 mcg) is often reserved for young patients without cardiovascular disease.^{6,9} In addition, adrenal insufficiency is common in patients presenting with symptoms of MC and can be difficult to distinguish from primary hypothyroidism. While there are no studies showing a clear benefit to hydrocortisone use, the potential benefit is considered to outweigh the risk.⁴

We started therapy with 200 mcg of T4 and 100 mg of hydrocortisone. A 10 mg dose of T3 was ordered but not given in the ED. Because the patient's condition markedly improved prior to reaching her inpatient bed, the admitting team opted to withhold T3 due to the potential for cardiovascular complications associated with this drug.

CONCLUSION

In summary, this rare case of MC brought on by burns to the face was quickly diagnosed when the clinical picture was noted to be out of proportion to the initial injury. A rapid escalation of diagnostics and therapeutics resulted in significant improvement and a favorable outcome. This highlights the need for a heightened index of suspicion in trauma and burn cases that have sudden, unexplained systemic symptoms.

Address for Correspondence: Lane Smith MD PhD, Wake Forest Baptist Medical Center, Meads Hall 2nd Floor, Medical Center Blvd., Winston-Salem, NC 27157. Email: lmsmith@wakehealth.edu.

Conflicts of Interest: By the CPC-EM article submission agreement, all authors are required to disclose all affiliations, funding sources and financial or management relationships that could be perceived as potential sources of bias. The authors disclosed none.

Copyright: © 2017 Batista et al. This is an open access article distributed in accordance with the terms of the Creative Commons Attribution (CC BY 4.0) License. See: <http://creativecommons.org/licenses/by/4.0/>

REFERENCES

1. Klubo-Gwiedzinska J, Wartofsky L. Thyroid emergencies. *Med Clin North Am.* 2012;96(2):385-403.
2. Dubbs SB, Spangler R. Hypothyroidism: causes, killers, and life-saving treatments. *Emerg Med Clin North Am.* 2014;32(2):303-17.
3. Gupta KJ. Myxedema coma: a sleeping giant in clinical practice. *Am J Med.* 2013;126(12):e3-4.
4. Garber JR, Cobin RH, Gharib H, et al. Clinical practice guidelines for hypothyroidism in adults: cosponsored by the American Association of Clinical Endocrinologists and the American Thyroid Association. *Endocr Pract.* 2012;18(6):988-1028.
5. Popoveniuc G, Chandra T, Sud A, et al. A diagnostic scoring system for myxedema coma. *Endocr Pract.* 2014;20(8):808-17.
6. Mathew V, Misgar RA, Ghosh S, et al. Myxedema coma: a new look into an old crisis. *J Thyroid Res.* 2011;2011:493462.
7. Benediktsson R, Toft AD. Management of the unexpected result: compensated hypothyroidism. *Postgrad Med J.* 1998;74(878):729-32.
8. Holvey DN, Goodner CJ, Nicoloff JT, et al. Treatment of myxedema coma with intravenous thyroxine. *Arch Intern Med.* 1964;113:89-96.
9. Kwaku MP, Burman KD. Myxedema coma. *J Intensive Care Med.* 2007;22(4):224-31.
10. Rodríguez I, Fluiters E, Pérez-Méndez LF, et al. Factors associated with mortality of patients with myxedema coma: prospective study in 11 cases treated in a single institution. *J Endocrinol.* 2004;180(2):347-50.
11. Wartofsky L, Burman KD. Alterations in thyroid function in patients with systemic illness: the "euthyroid sick syndrome". *Endocr Rev.* 1982;3(2):164-217.
12. Yamamoto T, Fukuyama J, Fujiyoshi A. Factors associated with mortality in myxedema coma: Report of eight cases and literature survey. *Thyroid.* 1999;9(12):1167-74.

A Novel Source of Chest Pain in the Emergency Department

Ibrahim Isa, MD*
Jeffrey S. Bush, MD*
Simon Watson, MD*
Joseph Schoepf, MD†

*Medical University of South Carolina, Department of Emergency Medicine,
Charleston, South Carolina

†Medical University of South Carolina, Department of Radiology, Charleston, South
Carolina

Section Editor: Rick A. McPheeters, DO

Submission history: Submitted August 10, 2016; Revision received December 9, 2016; Accepted December 13, 2016

Electronically published March 14, 2017

Full text available through open access at http://escholarship.org/uc/uciem_cpccm

DOI: 10.5811/cpcem.2016.12.32030

This is a case report of a patient with an unusual presentation of an inferior vena cava (IVC) filter migration with a delayed presentation, and without electrical or valvular abnormalities. We discuss considerations and potential complications from IVC filter placement from the emergency physician perspective. [Clin Pract Cases Emerg Med. 2017;1(2):101–103.]

INTRODUCTION

This is a case report of a patient with an unusual presentation of an inferior vena cava (IVC) filter migration with a delayed presentation, and without electrical or valvular abnormalities. Familiarity with IVC filters and their potential complications are important considerations in the clinical evaluations of many emergency department (ED) patients.

CASE REPORT

The patient is a 38-year-old male with a history of coronary artery disease, hypertension and morbid obesity status post gastric bypass who presented to the ED with a chief complaint of chest pain. He stated that the pain began insidiously approximately five hours before he presented to the ED. He characterized the pain as a “pricking” sensation in his right anterior chest that radiated to his right scapula. He rated the pain as a 3-4 severity on a 10-point pain scale. He stated that the pain was continuous and currently present. The pain was unrelated to exertion. He denied any associated symptoms including fever, chills, cough, dyspnea, dizziness, diaphoresis, nausea, vomiting and diarrhea.

The patient had a past medical history significant for obesity, hypertension, hyperlipidemia, gastroesophageal reflux disease, deep venous thrombosis (DVT) and two prior ischemic strokes. Previous work-up of his prior cerebrovascular accidents revealed a patent foramen ovale, believed to be the underlying etiology. He denied congestive heart failure and prior myocardial infarction. Surgical history included gastric bypass three years earlier at which point an IVC filter had been placed. The IVC filter was never removed. However, after the procedure, a trans-esophageal and trans-

thoracic echocardiogram, chest radiograph (CXR), magnetic resonance imaging/angiography of the abdomen and pelvis, and ultrasound of the aorta, IVC, and iliac vessels were all negative for the IVC filter. Per the medical record, it was concluded that the filter never deployed because it could not be located with the above imaging.

On initial presentation, the patient was conversational and in no acute distress. Physical exam revealed a well appearing, obese male who appeared his stated age with normal vital signs. A nine-system exam was unremarkable. The lungs were clear to auscultation bilaterally. The cardiac exam demonstrated regular rate and rhythm with no audible murmur, rub, or gallop. He was not diaphoretic, his jugular veins were flat and he had equal pulses without edema in his lower extremities. The chest, flank and back were not tender to palpation.

The patient declined pain medications. A chest pain work-up was done, which included a CXR, complete blood count, basic metabolic panel, troponin and an electrocardiogram (EKG).

Portable CXR showed stable cardiomegaly, interpreted by radiology to be consistent with prior radiographs. His EKG was normal without evidence of ST segment changes or T wave abnormalities. Bedside troponin was 0.00. Given that the patient had significant risk factors, we decided to perform a computed tomography triple rule-out (CT TRO) study of the chest to rule out pulmonary embolism (PE), aortic disease and to assess for coronary artery disease. The CT showed no evidence of significant coronary artery disease, pulmonary embolus, or acute aortic injury; however, it did demonstrate an IVC filter lodged in the right ventricle, seemingly adherent to the moderator band and right ventricular trabeculation. The

patient's CT was reconstructed to create the image below (Image) in which the IVC filter is clearly seen lodged in the right ventricle.

The patient was subsequently admitted into the cardiology service and multiple consultations were obtained. Interventional radiology and interventional cardiology did not believe they could safely extract the filter percutaneously due to concerns that they would injure the tricuspid valve. Cardiothoracic (CT) surgery recommended that the device be extracted via an open procedure that included sternotomy, cardiopulmonary bypass, and a brief period of cardioplegic arrest. The patient requested a second opinion from a CT surgery consultant who also recommended that the filter be removed. The patient had not yet made a decision and was subsequently discharged home on warfarin while considering his options.

DISCUSSION

In 1973 Dr. Lazar Greenfield introduced his IVC filter permitting continuous flow with blockade of distal emboli. Since then, these devices have seen expanded use and development in an effort to prevent potentially fatal pulmonary emboli (PE). Their indications have expanded and now include patients undergoing bariatric surgery who are considered high risk for post-surgical DVT. In 1994 an article by BA Smith – “Vena Cava Filters” in *Emergency Medical Clinics of North America* – recognized that “the patient with a caval filter poses a challenge to the emergency physician.”¹ In 1999 an estimated 49,000 IVC filters were placed.² Since then,

the use of the IVC filter has continued to expand and increase. The early 2000s saw the development of retrievable IVC filters, which extended the indication for placement to prevent vaso-thrombotic events in high-risk patients before surgery, including bariatric surgery. An estimated 220,000 bariatric surgeries were performed in 2009.³ Clearly, the number of IVC filters will continue to increase and so will the incidence of complication.

There is little emergency medicine literature discussing IVC filter-related complications; however, the surgery and vascular surgery literature over the last two decades outlines a number of complications. There are multiple cases of IVC filter migration to the right atrium or ventricle, as in the patient above.^{4,5,6} While there are similar reports in the literature, most of these have presented shortly after the IVC filter was placed. Also, most previous reports have focused on cardiac electrical irregularities caused by the IVC filter migration while this patient had a normal EKG. It is unclear why the initial imaging failed to reveal the IVC filter location. A possible explanation is that the filter had not yet migrated to the right ventricle at the time of the echocardiogram. CXR performed on the day the patient presented to the ED likely failed to reveal the presence of the filter as it was overlying the spine on the AP projection. Patients can have recurrent or “missed” PE in 2-4% of cases. There can also be delayed fracture of pieces of the filter, which can migrate and potentially cause perforations.⁷ There is also the long-term risk of direct erosion and perforation of the IVC itself.⁸ Additional complications can include IVC thrombus formation at the filter site and some other more immediate surgical issues including perforation, intimal tears, and air emboli.

In 2010 the FDA released a safety warning aimed at emergency medicine and surgery specialties. Since 2005 the FDA has received 921 device adverse-event reports involving IVC filters, of which 328 involved device migration, 146 embolizations (detachment of device components), 70 perforations of the IVC, and 56 filter fractures. Some of these events led to adverse clinical outcomes in patients. These types of events may be related to a retrievable filter remaining in the body for long periods of time, beyond the time when the risk of PE has subsided. The FDA is concerned that these retrievable IVC filters, intended for short-term placement, are not always removed once a patient's risk for PE subsides.⁹

A limited, non-systematic literature search suggests the FDA is right; many retrievable filters are not actually removed, and these filters may then be associated with the aforementioned complications. Published work in peer-reviewed journals has reported technical success rates for removing filters ranging from 70-100%. However, reviews of actual clinical practice reveal retrieval rates as low as 22%.¹⁰ A systematic review in 2011, which included 37 studies and 6,834 patients, suggests that the mean retrieval rate was 34% and that “most of the filters became permanent devices.”¹¹

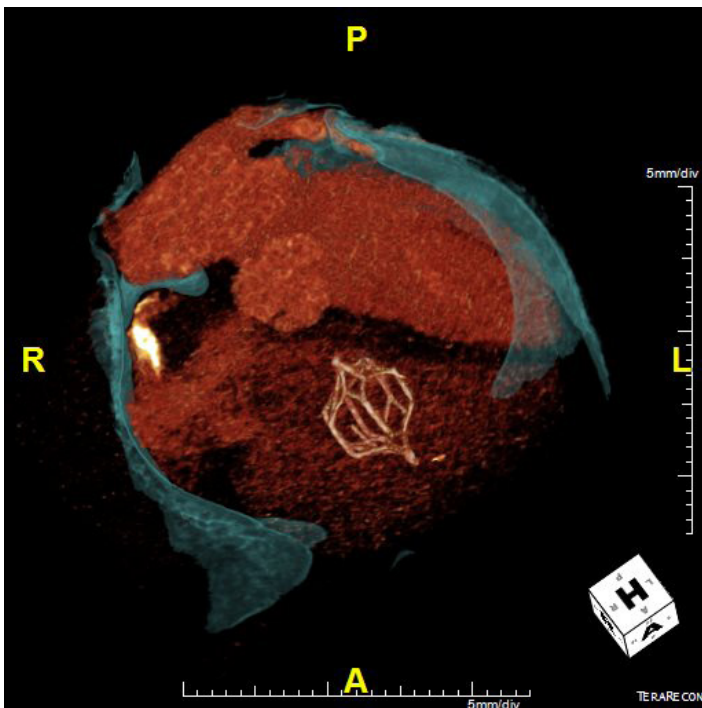


Image. Computed tomography reconstruction displaying inferior vena cava filter lodged in right ventricle

CONCLUSION

For emergency physicians there are a few significant pearls to remember about IVC filters. As IVC filter placement increases, the incidence of IVC filters and their complications will increase. Unfortunately, IVC filters do not totally preclude the incidence of PE. In fact, the PREPIC (Prevention du Risque d'Embolie Pulmonaire par Interruption Cave) study randomized 400 patients with DVTs to either an IVC filter or no-filter group and found no significant difference in fatal pulmonary emboli and overall survival at eight-year follow-up.¹² There are multiple IVC filter-related complications that can cause significant abdominal and cardiopulmonary morbidity. If a patient has received an IVC filter, ask if it was ever removed. Many migrated IVC filters are found incidentally; be sure to arrange close follow-up in otherwise asymptomatic patients.

Address for Correspondence: Ibrahim Isa, MD, Medical University of South Carolina, 29 Archdale St. Unit A, Charleston, SC 29401. Email: isai@musc.edu.

Conflicts of Interest: By the CPC-EM article submission agreement, all authors are required to disclose all affiliations, funding sources and financial or management relationships that could be perceived as potential sources of bias. The authors disclosed none.

Copyright: © 2017 Isa et al. This is an open access article distributed in accordance with the terms of the Creative Commons Attribution (CC BY 4.0) License. See: <http://creativecommons.org/licenses/by/4.0/>

REFERENCES

1. Smith BA. Vena caval filters. *Emerg Med Clin North Am.* 1994; 12(3):645-56.

2. Stein PD, Kayali F, Olson RE. Twenty-one-year trends in the use of inferior vena cava filters. *Arch Intern Med.* 2004;164(14):1541-5.
3. Elliott VS. Bariatric surgery maintains, doesn't gain. *American Medical News.* Available at: <http://www.amednews.com/article/20120423/business/304239976/4/>. Accessed Jun 26, 2016.
4. Janjua M, Omran FM, Kastoon T, et al. Inferior vena cava filter migration: updated review and case presentation. *J Invasive Cardiol.* 2009;21(11):606-10.
5. Shmutter Z, Frederic FI, Gill JR. Fatal migration of vena caval filters. *Forensic Sci Med Pathol.* 2008;4(2):116-21.
6. Emaminia A, Fedoruk LM, Hagspiel KD, et al. Inferior vena cava filter migration to the heart. *Ann Thorac Surg.* 2008;86(5):1664-5.
7. Chandra PA, Nwokolo C, Chuprun D, et al. Cardiac tamponade caused by fracture and migration of inferior vena cava filter. *South Med J.* 2008;101(11):1163-4.
8. Durack JC, Westphalen AC, Kekulawela S, et al. Perforation of the IVC: rule rather than exception after longer indwelling times for the Günther Tulip and Celec retrievable filters. *Cardiovasc Intervent Radiol.* 2012;35(2):299-308.
9. Inferior Vena Cava (IVC) Filters: Initial Communication: Risk of Adverse Events with Long Term Use. U.S. Food & Drug Administration. Available at: <http://www.fda.gov/Safety/MedWatch/SafetyInformation/SafetyAlertsforHumanMedicalProducts/ucm221707.htm>. Accessed Jun 26, 2016.
10. Dixon A, Stavropoulos SW. Improving retrieval rates for retrievable inferior vena cava filters. *Expert Rev Med Devices.* 2013;10(1):135-41.
11. Angel LF, Tapson V, Galgon RE, et al. Systematic review of the use of retrievable inferior vena cava filters. *J Vasc Interv Radiol.* 2011;22(11):1522-30.e3.
12. Greenfield LJ. The PREPIC Study Group. Eight-year follow-up of patients with permanent vena cava filters in the prevention of pulmonary embolism: the PREPIC (Prevention du Risque d'Embolie Pulmonaire par Interruption Cave) Randomized Study. *Perspect Vasc Surg Endovasc Ther.* 2006;18(2):187-8.

Phlegmasia Cerulea Dolens Diagnosed by Point-of-Care Ultrasound

Michele Schroeder, MD
Amanda Shorette, MD
Sukhdeep Singh, MD
Gavin Budhram, MD

University of Massachusetts Medical School-Baystate Health Springfield Campus,
Baystate Medical Center, Department of Emergency Medicine, Springfield,
Massachusetts

Section Editor: Rick A. McPheeters, DO

Submission history: Submitted September 30, 2016; Revision received December 11, 2016; Accepted December 13, 2016

Electronically published March 13, 2017

Full text available through open access at http://escholarship.org/uc/uciem_cpccem

DOI: 10.5811/cpcem.2016.12.32716

Phlegmasia cerulea dolens (PCD) is a rare entity that is associated with significant morbidity and mortality, including limb ischemia and pulmonary embolism. Point-of-care ultrasound (POCUS) can expedite the diagnosis, leading to earlier life- and limb-saving treatment. Although primarily used for assessing for the presence of deep venous thrombosis, in the appropriate clinical setting POCUS can also be used to diagnosis PCD as well as to distinguish between venous and arterial occlusion, which can lead to a difference in management. We present a case of phlegmasia cerulea dolens after mild trauma in a patient with an underlying hypercoagulability disorder diagnosed by an emergency physician using POCUS, which expedited treatment with catheter-directed thrombolytic therapy. [Clin Pract Cases Emerg Med. 2017;1(2):104–107.]

INTRODUCTION

Phlegmasia cerulea dolens (PCD), or massive proximal venous thrombosis of the lower extremity, is a rare entity that is associated with significant morbidity and mortality, necessitating rapid diagnosis and treatment. Point-of-care ultrasound (POCUS) can expedite the diagnosis, leading to earlier life- and limb-saving treatment. PCD is most often associated with hypercoagulable states, but can be precipitated by trauma. We present a case of phlegmasia cerulea dolens after mild trauma in a patient with an underlying hypercoagulability disorder diagnosed by an emergency physician using POCUS, which expedited treatment with catheter-directed thrombolytic therapy.

CASE REPORT

A 21-year-old female college student presented to the emergency department (ED) with severe pain in her left hip, thigh, and calf. The pain started suddenly when she was playing basketball a few hours earlier. She twisted her torso to shoot the ball and heard a “pop” in her left hip with immediate onset of pain, and she subsequently fell to her knees. She was initially able to ambulate but had worsening pain and rapid progression of swelling and mottling in the left leg from

her hip to her ankle. She denied any pain or swelling in that extremity prior to the injury during the basketball game. With the exception of oral contraceptive use, she had no significant medical or family history.

On examination her left extremity was mottled, dusky, and cool to the touch from the hip to the toes and she had decreased dorsalis pedis and posterior tibial pulses when compared with the right extremity. The leg was markedly tender to palpation and sensation to light touch was diminished. Passive range of motion of the hip, knee, and ankle elicited severe pain.

POCUS was performed at the bedside to evaluate for arterial blood flow and deep venous thrombosis. This demonstrated normal color flow in the femoral and popliteal arteries (Image 1), but echogenic material was noted within the left common femoral vein extending distally to the popliteal vein and the veins were non-compressible (Images 2A and 2B). Vascular surgery was immediately consulted, and while awaiting their arrival to the ED the patient was sent for an emergent computed tomography (CT) angiogram, which confirmed arterial patency and extensive deep venous thrombosis in the left popliteal, femoral, and iliac veins (Image 3). A heparin bolus was given and the patient was

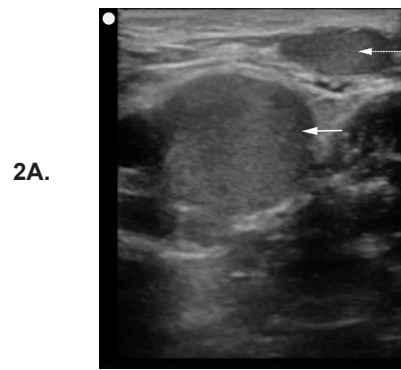
then taken to interventional radiology where she underwent partial thrombectomy, catheter-directed tissue plasminogen activator (tPA) treatment, and placement of an inferior vena cava (IVC) filter. By the next morning her leg was noted to be well-perfused, non-tender, and without swelling, and her pain had resolved. A workup for hypercoagulable states revealed heterozygosity for the Factor V Leiden mutation. She was discharged one week later on warfarin after bridging from enoxaparin.

DISCUSSION

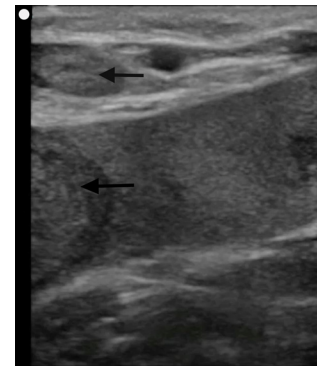
PCD is a rare form of deep vein thrombosis in which acute massive proximal venous thrombosis results in obstruction of the venous drainage of an extremity. Symptoms include sudden severe pain, swelling, edema, and cyanosis, leading

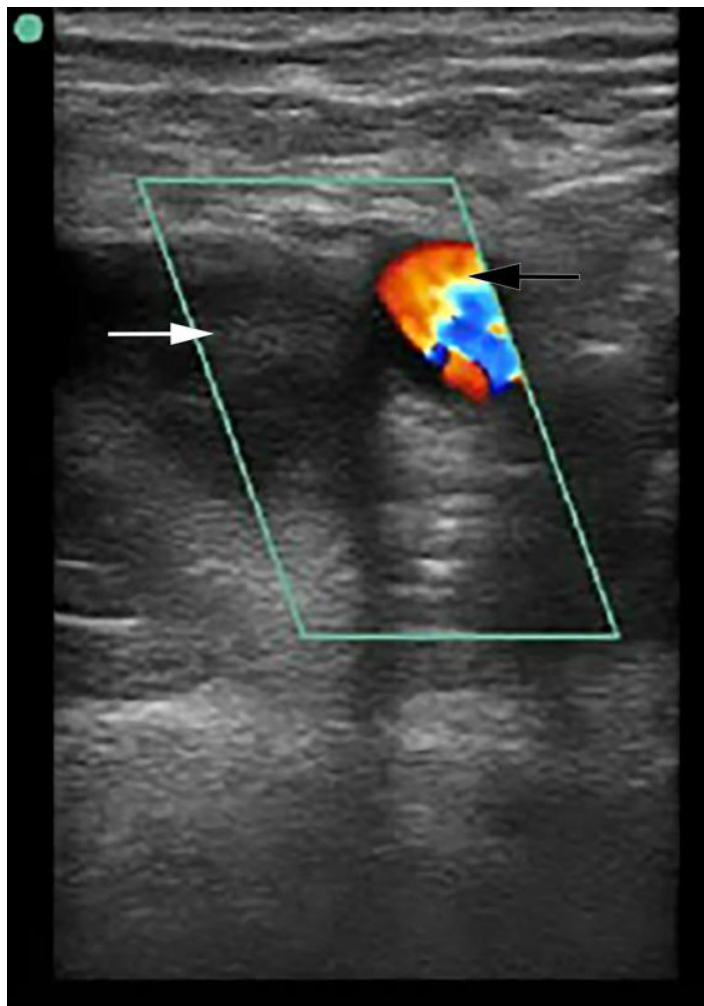

Image 1. Point-of-care ultrasound demonstrating complete thrombotic occlusion of the femoral vein. In this still image, application of color Doppler shows normal flow through the femoral artery (black arrow) but absence of flow in the femoral vein. Echogenic material is visualized within the femoral vein (white arrow).



2A.



2B.

Image 2A and 2B. Point of care ultrasound demonstrating extensive venous thrombosis of the left lower extremity. In image 2A, echogenic material is seen within the left common femoral vein (white arrow) and the greater saphenous vein (dashed white arrow). In image 2B, more echogenic material was visualized distally within the popliteal veins (black arrows).

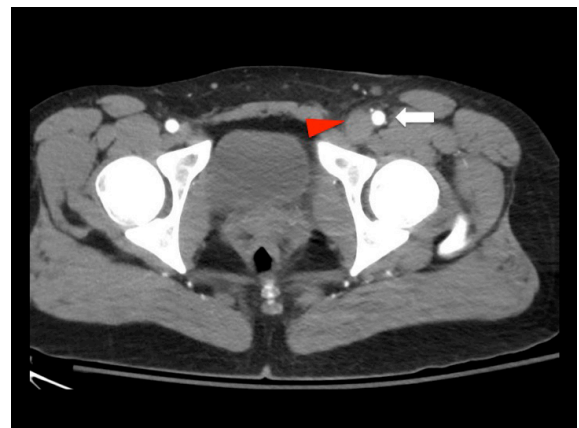

Image 3. Axial view of computed tomography angiogram at the level of the common femoral artery and vein. The femoral artery is patent (white arrow) while the common femoral vein is distended and filled with clot (red arrow).

to venous gangrene and compartment syndrome.^{1,2} Prompt diagnosis and treatment is necessary to return circulation and prevent circulatory collapse, and a delay in treatment may result in loss of the patient's limb or even death.^{3,4} The condition can have either a gradual or a fulminant course.⁵

Most cases of PCD are associated with an underlying hypercoagulable disorder, most often malignancy.⁶ There are case reports, however, of fulminant PCD resulting from trauma, including one patient with a hip dislocation.^{7,8} The traumatic injury is unclear in the current case as the ED imaging was negative for any fracture or dislocation, although hip subluxation/dislocation with spontaneous reduction has been described in adolescents.⁹ This patient reported a "popping" sensation suggestive of this mechanism of injury and she additionally reported a fall from standing immediately after the onset of pain. This mild trauma in conjunction with an underlying hypercoagulability disorder is the likely etiology of her massive lower extremity venous thrombosis.

Angiography at this stage will typically demonstrate patent arterial flow as clinical mottling occurs due to peripheral vasospasm and severe edema from thrombosis. PCD can mimic acute arterial occlusion, but rather than a lack of blood inflow, venous gangrene results from stasis due to lack of outflow. Both conditions are initially treated with heparin, but since massive pulmonary embolism is an immediate threat with PCD, procedural interventions such as thrombectomy, catheter-directed tPA and IVC filter placement may be warranted even if perfusion improves with heparin.^{10,11}

The diagnosis of PCD employs a combination of clinical and radiologic findings. Manifestations of phlegmasia alba dolens (the clinical precursor to PCD) include edema, pain and blanching. As the disease progresses, cyanosis develops, and can lead to bleb and bullae formation and venous gangrene.¹² Ultrasound is commonly used to identify venous thrombosis, and a POCUS performed by an emergency physician can quickly establish this time-sensitive diagnosis. Previous studies have demonstrated that POCUS performed by emergency physicians is sensitive (89-100%) and specific (75-99%) when compared to radiology department ultrasound for the evaluation of deep venous thrombosis.¹³⁻¹⁷ The clinician should be aware, however, that thrombosis of the iliac veins may not be seen by ultrasound. CT venography is commonly used to diagnosis proximal thrombosis but is not always readily available at some institutions.

In this patient, massive lower extremity venous thrombosis was easily visualized by the emergency physician using POCUS. Further support for the diagnosis in this patient (and against arterial insufficiency) was the presence of Doppler flow in the arterial system. While ultrasound alone may not be able to distinguish DVT from PCD, the finding of non-compressible proximal veins in combination with a mottled, cool, and painful extremity should be sufficient to raise the suspicion of PCD.

CONCLUSION

PCD is a rare disease with significant morbidity and mortality. Early diagnosis and treatment is necessary to prevent severe complications such as limb ischemia or massive pulmonary embolism. Point of care ultrasound can facilitate earlier diagnosis of significant vascular pathology, including phlegmasia cerulea dolens.

Address for Correspondence: Amanda Shorette, MD, University of Massachusetts Medical School-Baystate Health Springfield Campus, 759 Chestnut Street, Springfield, MA 01199. Email: Amanda.ShoretteMD@baystatehealth.org.

Conflicts of Interest: By the CPC-EM article submission agreement, all authors are required to disclose all affiliations, funding sources and financial or management relationships that could be perceived as potential sources of bias. The authors disclosed none.

Copyright: © 2017 Schroeder. This is an open access article distributed in accordance with the terms of the Creative Commons Attribution (CC BY 4.0) License. See: <http://creativecommons.org/licenses/by/4.0/>

REFERENCES

1. Sarwar S, Narra S, Munir A. Phlegmasia cerulea dolens. *Tex Heart Inst J.* 2009;36(1):76-7.
2. Haimovici H. The ischemic forms of venous thrombosis. 1. Phlegmasia cerulea dolens. 2. Venous gangrene. *J Cardiovasc Surg (Torino).* 1965;5(6):Suppl:164-73.
3. Kalagher SD and Kane DD. Phlegmasia cerulea dolens: before and after lysis. *Intern Emerg Med.* 2015;10(1):103-4.
4. Suwanabol PA, Tefera G, Schwarze M. Syndromes associated with the deep veins: phlegmasia cerulea dolens, May-Thurner syndrome, and nutcracker syndrome. *Perspect Vasc Surg Endovasc Ther.* 2010;22(4):223-30.
5. Khandker SR. Images in emergency medicine. A case of painful swollen leg. Phlegmasia cerulea dolens. *Ann Emerg Med.* 2012;59(3):176,208.
6. Brockman SK and Vasko JS. Phlegmasia cerulea dolens. *Surg Gynecol Obstet.* 1965;121(6):1347-56.
7. Hu H, Cai Y, Wang C, et al. Successful treatment of posttraumatic phlegmasia cerulea dolens by reconstructing the external iliac vein: a case report. *J Med Case Rep.* 2014;8:149.
8. Wilson B, Hawkins ML, Mansberger AR Jr. Posttraumatic phlegmasia cerulea dolens: an indication for the Greenfield filter. *South Med J.* 1989;82(6):780-2.

9. Herrera-Soto JA and Price CT. Traumatic hip dislocations in children and adolescents: pitfalls and complications. *J Am Acad Orthop Surg.* 2009;17(1):15-21.
10. Chinsakchai K, Ten Duis K, Moll FL, et al. Trends in management of phlegmasia cerulea dolens. *Vasc Endovascular Surg.* 2011;45(1):5-14.
11. Meissner MH. Rationale and indications for aggressive early thrombus removal. *Phlebology.* 2012;27 Suppl 1:78-84.
12. Mahomed A and Williams D. Phlegmasia cerulea dolens and venous gangrene. *Br J Surg.* 1996;83(8):1160-1.
13. Crisp JG, Lovato LM, Jang TB. Compression ultrasonography of the lower extremity with portable vascular ultrasonography can accurately detect deep venous thrombosis in the emergency department. *Ann Emerg Med.* 2010;56(6):601-10.
14. Frazee BW, Snoey ER, Levitt A. Emergency Department compression ultrasound to diagnose proximal deep vein thrombosis. *J Emerg Med.* 2001;20(2):107-12.
15. Jacoby J, Cesta M, Axelband J, et al. Can emergency medicine residents detect acute deep venous thrombosis with a limited, two-site ultrasound examination? *J Emerg Med.* 2007;32(2):197-200.
16. Jang T, Docherty M, Aubin C, et al. Resident-performed compression ultrasonography for the detection of proximal deep vein thrombosis: fast and accurate. *Acad Emerg Med.* 2004;11(3):319-22.
17. Theodoro D, Blaivas M, Duggal S, et al. Real-time B-mode ultrasound in the ED saves time in the diagnosis of deep vein thrombosis (DVT). *Am J Emerg Med.* 2004;22(3):197-200.

Intermittent Ovarian Torsion in Pregnancy

Randall Young, MD, MMM*
Kelly Cork, MD†

*Kaiser Permanente San Diego Medical Center, Department of Emergency Medicine,
San Diego, California

†Kaiser Permanente San Diego Medical Center, Department of Obstetrics and
Gynecology, San Diego, California

Section Editor: Rick A. McPheeters, DO

Submission history: Submitted October 20, 2016; Revision received December 12, 2016; Accepted December 19, 2016

Electronically published March 15, 2017

Full text available through open access at http://escholarship.org/uc/uciem_cpccem

DOI: 10.5811/cpccem.2016.12.32932

Ovarian torsion during pregnancy is a fairly uncommon complication with a high patient morbidity and fetal mortality if not immediately treated. Ovarian torsion should be considered a clinical diagnosis, and a high level of clinical suspicion is needed by the practitioner to ensure that this diagnosis is not missed. We present an unusual case of intermittent ovarian torsion discussing both the presentation and the operative and post-operative management. [Clin Pract Cases Emerg Med. 2017;1(2):108–110.]

INTRODUCTION

Ovarian torsion is a disorder with a very high patient morbidity. When the patient is pregnant this can also lead to fetal mortality and potential loss of fertility for the patient. The presentation of ovarian torsion can mimic many other intraabdominal pathologic conditions. It requires a high level of clinical suspicion from the provider to not miss this potentially devastating diagnosis. Imaging and laboratory results may be used as support; however, the diagnosis should primarily be made on a strong history and physical exam. When the physical examination is not congruent with the level of patient distress, ischemic pain from an ovarian torsion must be considered.

CASE REPORT

The patient was a 34-year-old gravid 1 para 0 female at approximately 10 weeks gestational age by last menstrual period who presented to a community emergency department (ED) with complaints of right lower quadrant abdominal pain. The patient reported that the pain woke her up from sleep at 3 a.m. The patient arrived to the ED approximately three hours after the onset of pain. The patient described the pain as a “constant pinching” localized only in the right lower quadrant and it was unrelieved by acetaminophen. The patient denied nausea or vomiting. She also denied any vaginal bleeding or discharge.

A physical exam revealed a temperature of 36.8

Celsius, pulse of 82 beats per minute (BPM), respiratory rate of 18 breaths per minute, and blood pressure of 125/67 mmHg. At the time of the initial examination the patient appeared comfortable and in no acute distress. Her abdominal exam revealed a soft abdomen with normal bowel sounds. No masses, distention or tenderness were detected. Pelvic exam was conducted and was noted to have no vaginal discharge or bleeding, and no pelvic masses were appreciated by the provider. However, it was noted that body habitus limited the exam.

A formalized pelvic ultrasound (US) showed a single live intrauterine pregnancy with a fetal heart rate of 163 BPM. Large right ovarian cysts were noted and there was arterial flow noted centrally in both the left and right ovaries. The right ovary measured 7.7 cm x 4.8 cm x 5.9 cm, whereas the left ovary was only 1.9 cm x 1.4 cm x 1.6 cm.

The case was discussed with the on-call obstetrician who stated that it was most likely a corpus luteal cyst and the pain should resolve on its own. Since the pain had completely resolved the patient was discharged home with scheduled follow-up in two days with obstetrics and gynecology (OB/GYN).

The patient had an unplanned return to the ED nine hours from time of discharge with recurrence of her abdominal pain. The patient reported that the pain was located in the same location and felt similar, although now it was much more intense and was not resolving. She was also very nauseated and actively vomiting.

Reexamination revealed a temperature of 36.1 degrees Celsius, pulse rate of 64 BPM, respiratory rate of 18 breaths per minute and a blood pressure of 133/78 mmHg. At the time of reevaluation the patient appeared in acute distress, doubled over and moaning in pain. The patient was intermittently vomiting what appeared to be gastric contents. However, her abdominal exam again showed no peritoneal signs, no focal tenderness and no masses. The patient's abdominal examination did not match her level of distress. OB was again consulted and requested an additional formal US.

This time, repeat US again showed an enlarged right ovary with multiple cysts. At the time of the repeat US the right ovary measured 8.23 cm x 8.41 cm x 5 cm, whereas the left ovary was 2.22 cm x 2.94 cm x 3.22 cm. Using color Doppler, blood flow was not demonstrated in the right ovary, whereas left ovary demonstrated adequate blood flow.

OB evaluated this patient and took her to the operating room. The patient had an exploratory laparoscopy performed, which revealed that the right infundibulopelvic (IP) ligament was twisted times three. A laparoscopic needle and syringe were used to drain two simple ovarian cysts. The right ovary was manually detorsed and healthy viable ovarian tissue returned. Postoperatively the patient was started on intravaginal progesterone 200mg for the following four weeks. At term the patient had a spontaneous vaginal delivery of a healthy girl.

DISCUSSION

Ovarian torsion during pregnancy is a fairly uncommon complication with a high patient morbidity and fetal mortality if not immediately treated.¹ Torsion more commonly occurs on the right rather than the left with an incidence of 3:2.¹ Ovarian torsion rises fivefold in pregnancy to approximately five in 10,000. This typically occurs between the sixth and fourteenth weeks of gestation. The most common cause is the growth of a corpus luteal cyst, which usually spontaneously regresses by the second trimester. The reason that ovarian torsion is thought to occur more commonly on the right rather than the left is because it is believed that the sigmoid colon limits the mobility of the left ovary.² If the IP ligament is successfully detorsed, it is common practice to excise or drain the cysts that are believed to have caused the torsion to prevent repeat torsion. Since the typical cyst in the first trimester is a corpus luteal cyst, which supports the pregnancy until the placenta is adequately developed at the end of the first trimester, drainage or excision of the cyst could result in pregnancy loss. Therefore, some obstetricians opt to treat with supplemental progesterone to support the pregnancy until the placenta can be further developed, usually in the second trimester.

CONCLUSION

The diagnosis of ovarian torsion must be made clinically. As demonstrated in this case, a normal Doppler ultrasound does not

exclude intermittent ovarian torsion. Torsion must be considered in any female with sudden onset, severe lower abdominal pain. As in this case, the abdominal examination often does not correspond with the level of distress that the patient would present with. When torsion is considered, early consultation with OB/GYN should be obtained as both current and future fertility are at stake. Successful detorsion must be performed in a timely manner to protect fertility.

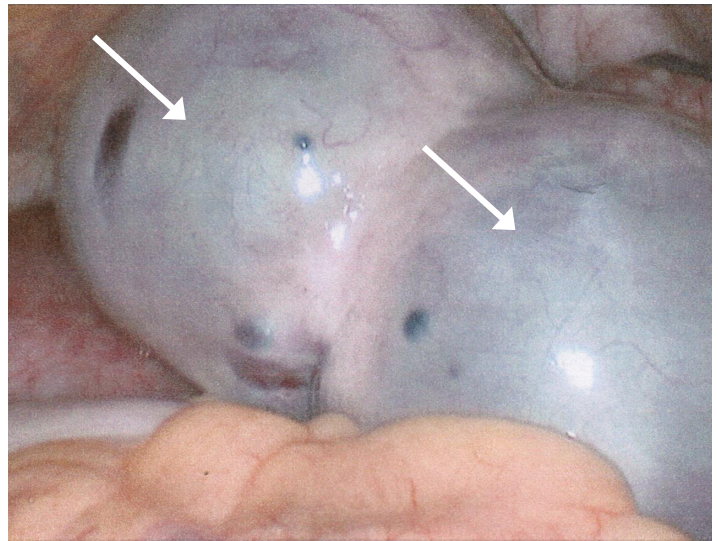


Image 1. Intraoperative laparoscopic view of two large ovarian cysts with ischemic discoloration of the tissue.

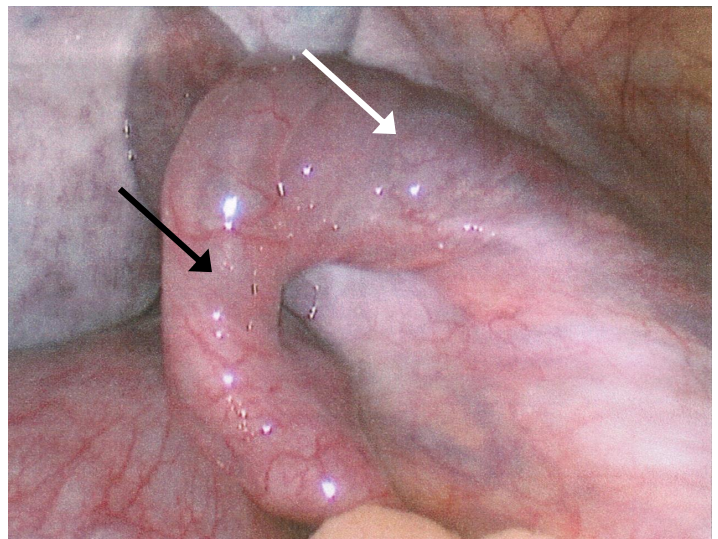


Image 2. Intraoperative laparoscopic view status post drainage of cysts (white arrow) and detorsion of infundibulopelvic ligament (black arrow); note return of healthy pink tissue.

Address for Correspondence: Randall Young, MD, MMM, Kaiser Permanente Medical Center, 4647 Zion Avenue, San Diego, CA 92120. Email: rjyoungmd@kaiser-ed.com.

Attribution ([CC BY 4.0](http://creativecommons.org/licenses/by/4.0/)) License. See: <http://creativecommons.org/licenses/by/4.0/>

Conflicts of Interest: By the *CPC-EM* article submission agreement, all authors are required to disclose all affiliations, funding sources and financial or management relationships that could be perceived as potential sources of bias. The authors disclosed none.

Copyright: © 2017 Young et al. This is an open access article distributed in accordance with the terms of the Creative Commons

REFERENCES

1. Lentz GM, Lobo RA, Gershenson D, et al. Comprehensive Gynecology. Mosby, Inc. 2012;(6): 383-432.
2. Sasaki KJ, Miller CE. Adnexal torsion: review of the literature. *J Minim Invasive Gynecol.* 2014;21(2):196-202.

Bilateral Chylothorax Due to Blunt Trauma Without Radiographic Evidence of Traumatic Injury

Mohamed Mohamed, MD
Weam Alshenawy, MD
Christen Kegarise, DO
David Betten, MD

Sparrow Hospital, Department of Emergency Medicine, Lansing, Michigan

Section Editor: Rick A. McPheeters, DO

Submission history: Submitted October 24, 2016; Revision received December 13, 2016; Accepted December 19, 2016

Electronically published March 15, 2017

Full text available through open access at http://escholarship.org/uc/uciem_cpccm

DOI: 10.5811/cpcem.2016.12.32937

Chylothorax represents an uncommon clinical entity with multiple etiologies. Chylothorax following blunt thoracic trauma is typically associated with posterior rib fractures or thoracic vertebral fractures or dislocations. The occurrence of a traumatic chylothorax in the absence of associated injuries is a rare event. We report a case of a 51-year-old patient who developed bilateral chylothorax after sustaining blunt trauma without radiographic evidence of traumatic injury. A 51-year-old male presented to the emergency department complaining of progressively worsening shortness of breath and associated chest pain for the prior one week following a fall down several concrete steps. On evaluation, the patient was found to have bilateral pleural effusions with no radiographic evidence of traumatic injury, including posterior rib or thoracic vertebral fractures. Subsequent thoracentesis and pleural fluid analysis were performed confirming the diagnosis of chylothorax. Management included repeated thoracentesis, diet modification and octreotide administration, which resulted in dramatic improvement and eventual resolution of symptoms. Non-iatrogenic traumatic bilateral chylothorax in the absence of other radiographically demonstrated bony or soft tissue injury is a rare event. Chylothorax should be considered in the differential diagnosis of patients presenting with chest pain or shortness of breath following blunt trauma and evidence of pleural effusion, even in the absence of obvious traumatic fracture or injury on radiographic imaging. [Clin Pract Cases Emerg Med. 2017;1(2):111–114.]

INTRODUCTION

Chylothorax is the accumulation of chyle in the pleural cavity and represents a rare clinical entity. It occurs due to disruption of the thoracic duct with etiologies that are primarily non-traumatic. Specifically, traumatic chylothorax is very uncommon with a reported incidence of 0.2–3.0% following blunt thoracic trauma and 0.9%–1.3% after penetrating trauma.^{1,2} Quincke was first to describe chylothorax in the setting of trauma in 1875 and its association with an ominous and grave prognosis. Mortality rates remain high with an incidence up to 15.5%.³ Diagnosis is often challenging and frequently delayed.^{4,5} The clinical scenario in the trauma setting typically involves associated rib or vertebral fractures, or dislocations that may directly disrupt the thoracic duct. The presence of significant bilateral chylothorax is an infrequently reported sequela of blunt trauma, especially in a patient without evidence of other injury. We herein report

a case of a 51-year-old patient who developed bilateral chylothorax after sustaining blunt trauma in the absence of associated traumatic injury.

CASE PRESENTATION

A 51-year-old male presented to the emergency department (ED) with progressively worsening shortness of breath associated with left-sided chest pain for one week. This followed falling down four concrete steps in which he had struck his back and chest against the staircase railing. While initially painful, symptoms improved over the next several days and the patient resumed his work as a manual laborer. By post-injury day five, there was acute and progressive worsening of symptoms, which led him to seek medical care. On presentation, the patient had chest pain of moderate intensity with radiation to the upper back, in addition to dyspnea worsened by coughing and supine position. He

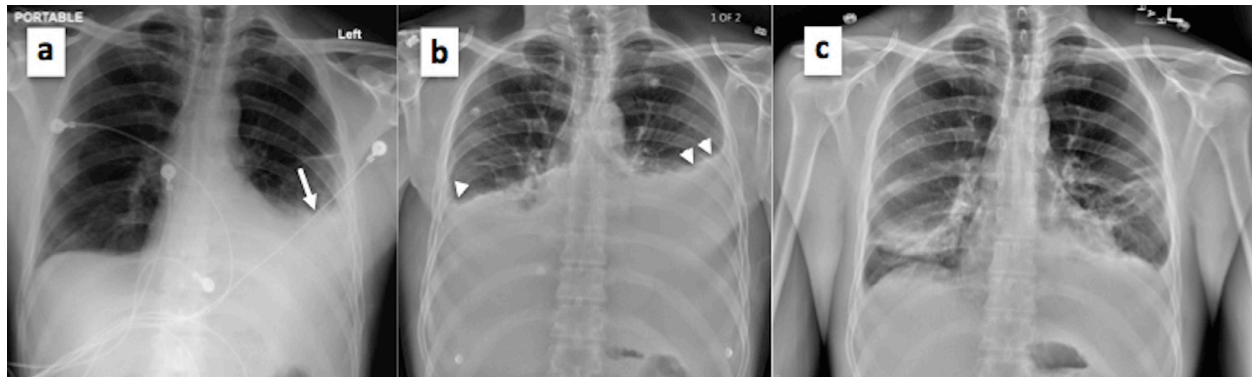


Image 1(a-c). Plain radiograph of the chest showing (a) obliteration of the left costophrenic angle on initial presentation (white arrow); (b) reaccumulation of chylothorax with bilateral obliteration of costophrenic angles on second patient admission (white arrow heads); and (c) resolution of chylothorax effusion prior to final patient discharge.

reported no fever, palpitations, syncope, dysphagia, nausea or vomiting. Past medical history was non-significant.

On examination, the patient appeared in obvious discomfort. Vital signs revealed a respiratory rate of 20 breaths/minute, heart rate of 65 beats/minute and blood pressure of 126/90, with an oxygen saturation of 92% on room air. Chest examination revealed diminished breath sounds on the middle and lower left lung zones. There was no chest wall tenderness, rhonchi or rales. Examination of other body systems was unremarkable. Plain chest radiograph demonstrated obliteration of the left costophrenic angle (Image 1a). Computed tomography (CT) of the chest with contrast revealed moderate to large left pleural effusion and small to moderate right pleural effusion with no evidence of pneumothorax, rib or vertebral fractures (Image 2). The patient was admitted to the hospital with bilateral pleural

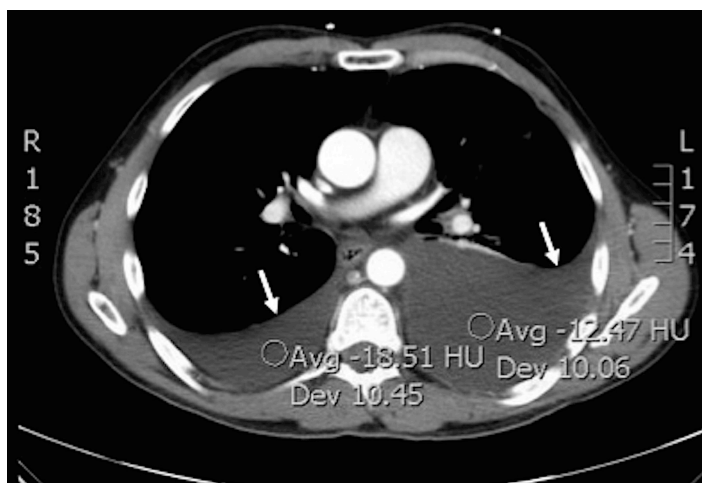

Image 2. Computed tomography of the chest with contrast showing bilateral pleural effusions more remarkable on the left side (white arrows).

effusions of unclear etiology. A left-sided thoracentesis was subsequently performed and approximately 1.4 liters of milky white effusion were drained. Laboratory analysis of the pleural fluid was consistent with chylothorax revealing triglycerides of 4,750 mg/dL, leucocytes of 729 cells/uL, red blood cells of 1,000 cells/uL, LDH of 277 U/L, and total protein of 4.0 g/L, with absence of malignant cells on cytological analysis and no growth on microbiological examination.

The patient was placed on a fat-free diet with supplementation of medium chain triglycerides, monitored for worsening dyspnea, and assessed for fluid reaccumulation on serial radiographs. Upon improvement, he was discharged on post-admission day three while having only minimal dyspnea and with stable oxygen saturation. Three days later, however, his dyspnea worsened and he presented to the ED with oxygen saturation of 90% on room air and evidence of fluid reaccumulation on chest radiograph (Image 1b). Bilateral thoracentesis performed upon readmission drained two liters of chylous effusion from each hemithorax. Fat-free diet and medium chain triglycerides were reinstated in addition to subcutaneous octreotide administration. Serial follow-up chest radiography remained stable (Image 1c) with no increase in effusion volumes, and the patient was subsequently discharged three days later. On follow up three weeks later, the patient was doing well.

DISCUSSION

Chyle is composed of ingested fat from the gastrointestinal tract and lymphatic fluid from the peritoneal cavity and lower extremities.² The thoracic duct represents the main vessel that transports chyle.² Causes of non-traumatic chylothorax primarily include neoplastic, congenital, inflammatory, and idiopathic etiologies.^{3,6} Malignancy (usually lymphoma) is considered the most common cause in non-traumatic cases.^{4,6} In the less commonly occurring traumatic chylothorax, iatrogenic etiologies (approximately 80% of cases) are usually the cause.^{2,7}

Because the thoracic duct is protected posteriorly by the thoracic and lumbar spine and anteriorly by the mediastinum, the occurrence of chylothorax after blunt trauma is uncommon.^{5,7} Classically, high velocity and/or sudden deceleration mechanisms are involved and the presence of nearby vertebral or posterior rib fractures, or vertebral dislocations is what usually disrupts the thoracic duct.^{3,7,8} Other mechanisms have been proposed to explain thoracic duct injury in the absence of fractures or dislocations. In a case by Apostolakis et. al., existing osteophytes/exostosis were suggested as being the likely culprit that resulted in puncturing of the thoracic duct following blunt trauma.⁷ Alternatively, after blunt trauma, sudden flexion/hyperextension of the lower thoracic spine or exposure to the shearing forces of the diaphragm may result in duct injury.^{3,7}

We have encountered only a few case reports in the literature of isolated traumatic chylothorax in the absence of obvious significant traumatic injury. In one report, there were no chest or spine fractures; however, effusion was unilateral.⁹ In the second report, effusion was also unilateral but the involvement of associated fractures or dislocations on imaging was not documented, making it difficult to conclude that such injuries were non-existent, especially in the context of trauma being caused by a horn injury from a bull.¹ In the remaining three reports,^{3,5,7} chylothorax was bilateral. Of those, there was similarly no documentation of fractures or dislocations in two reports;^{3,5} however, the mechanisms of injury were motor vehicle crash with bilateral hemothorax in one case, and water skiing injury at 40 mph in the other. Lastly was the case (mentioned earlier) reported by Apostolakis et. al.⁷ As such, it is likely that our case represents the fourth to be reported in the English-language medical literature with bilateral traumatic chylothorax in absence of obvious traumatic injury over the last decade.

Chylothorax typically possesses a latency period of 2-7 days from injury to the development of signs and symptoms, and a median of seven days from trauma to diagnosis.^{5,9} Two suggested possible reasons exist for this: 1) slow collection of chyle and lymph in the posterior mediastinum before rupturing into the pleural space up to 7 – 10 days later; and 2) possible relative interruption of normal diet following trauma; it is known that a fasting state may significantly reduce the chyle flow rate from the normal 100 ml/h after eating to 14 ml/h.^{2,4,9} This gradual evolution makes chylothorax better tolerated and may delay symptoms and diagnosis until the effusion becomes large enough.

The clinical picture primarily consists of progressive dyspnea and chest pain. Electrolyte abnormalities may develop including hypocalcemia, hyponatremia and acidosis from continued loss of chyle into the pleural space.^{2,4,9} If left untreated, signs and symptoms of malnutrition and hypovolemia may prevail.⁹ Additional loss of immunoglobulins and T-lymphocytes can further lead to

immunosuppression.^{4,9} Early diagnosis and recognition is warranted to avoid the detrimental effects of malnutrition, hypovolemia and immunocompromised state.

In the trauma setting, a plain radiograph demonstrating a pleural effusion often leads to subsequent CT to evaluate the possible underlying etiologies. Thoracentesis will demonstrate pleural fluid that is odorless, milky-white (in 50% of cases) but may be serous or serosanguinous if hemothorax is associated.² Presumptive diagnosis is made via quantitative analysis of the pleural fluid that reveals a triglyceride level >110 mg/dl (99% diagnostic).^{4,10} Lipoprotein electrophoresis of the pleural fluid demonstrating chylomicrons is confirmatory and remains the gold standard, especially when triglyceride levels are below 110 mg/dl; however, it may not be readily available.^{2,4,6} In our case, this was not required because triglyceride levels were considerably higher. Fasting and nutritional status however, should be considered while interpreting results as it may contribute to lower triglyceride levels. Maldonado et, al. reported 14% of patients with chylomicron-positive pleural fluid but with triglyceride levels <100 mg/dl.⁶ Other secondary diagnostic characteristics of the pleural fluid in chylothorax may include a pH of 7.4-7.8, specific gravity of 1.012 or higher, lymphocytic predominance of >1,000 cells/ul, fluid to serum cholesterol ratio of <1, and a triglyceride ratio of >1.^{6,9,10} Lymphangiography may further demonstrate the site of injury.⁶ Pseudochylothorax, a cholesterol-rich effusion commonly associated with chronic inflammatory disorders, and empyema may also result in milky effusions. Differentiation may be achieved via the simple addition of ethyl ether to the fluid demonstrating disappearance of the milky appearance in the former, and fluid centrifugation displaying a clear supernatant in the latter.^{2,4}

Conservative management consists of thoracentesis (to allow lung re-expansion), reducing chyle flow via starvation diet (to allow healing of the thoracic duct), and total parenteral nutrition (TPN) to address nutritional and metabolic complications. Success rate of this approach is said to range from 20-80%.² Using medium chain triglycerides is advocated because they are directly absorbed into the portal system bypassing the intestinal lymph system.⁶ Agents such as somatostatin and octreotide may also be used to reduce intestinal chyle production, thereby reducing chyle flow through the thoracic duct. Although in our case TPN was not instituted, the combination of thoracentesis, fat-free diet, medium chain triglycerides, and octreotide eventually led to the cessation of chylous effusion.

Patients who fail conservative management (usually within two weeks) with progression to malnutrition or electrolyte abnormalities may be candidates for surgical intervention.² Timing, however, is individualized, with early surgical consultation recommended in all cases of traumatic chylothorax. Previously used criteria suggesting a need for surgical intervention include the following: 1) a chyle leak of

>1.5 L/day; 2) output greater than 1L/day for five or more days; 3) persistent flow for > 2 weeks; or 4) rapid deterioration in nutritional status.² Percutaneous thoracic duct embolization is a safe alternative to surgical intervention and represents the first line of treatment at some institutions with reported success rates of approximately 70%.^{5,11} However, despite having a lower morbidity rate compared to surgical intervention, it is performed in only a few centers, the reason possibly being the rarity of expertise in a technically challenging procedure.^{5,11}

Overall, mortality rates have been lowered over the years due to introduction of various aggressive therapeutic approaches that aid in reversing the detrimental effects of chyle loss.⁶ Early recognition and diagnosis are still paramount for achieving better outcomes.

CONCLUSION

Non-iatrogenic traumatic bilateral chylothorax is unusual, and its occurrence in the absence of posterior rib or thoracic vertebral fractures, as in our case, is exceedingly rare. Chylothorax should be considered in the differential diagnosis of patients presenting with chest pain or shortness of breath within one to two weeks following blunt trauma, even in the absence of traumatic fracture or injury on radiographic imaging. In our case, admission and conservative management led to excellent results.

Address for Correspondence: Mohamed Mohamed, MD, Sparrow Hospital, 1215 E Michigan Avenue, Lansing, MI 48912. Email: mo_rahman@hotmail.com.

Conflicts of Interest: By the CPC-EM article submission agreement, all authors are required to disclose all affiliations, funding sources and financial or management relationships that could be perceived as potential sources of bias. The authors disclosed none.

Copyright: © 2017 Mohamed et al. This is an open access article distributed in accordance with the terms of the Creative Commons Attribution (CC BY 4.0) License. See: <http://creativecommons.org/licenses/by/4.0/>

REFERENCES

1. Shah PP, Deshmukh S, Tulshibagwala, RK. Chylothorax: a case report. *Int J of Pharmacol Clin Sci.* 2012;1(4):115-7.
2. Pillay TG, Singh B. A review of traumatic chylothorax. *Injury.* 2016;47(3):545-50.
3. Kumar S, Mishra B, Krishna A, et al. Nonoperative management of traumatic chylothorax. *Indian J Surg.* 2013;75(Suppl 1):465-8.
4. Chinnock BF. Chylothorax: case report and review of the literature. *J Emerg Med.* 2003;24(3):259-62.
5. Kurklinsky AK, McEachen JC, Friese JL. Bilateral traumatic chylothorax treated by thoracic duct embolization: a rare treatment for an uncommon problem. *Vasc Med.* 2011;16(4):284-7.
6. Babu A, Rattan A, Ranjan P, et al. Chylothorax due to blunt torso trauma: a rare etiology. *J Trauma Treat.* 2015;4(2):243-7.
7. Apostolakis E, Akinosoglou K, Koletsis E, et al. Traumatic Chylothorax Following Blunt Thoracic Trauma: Two Conservatively Treated Cases. *J Card Surg.* 2009;24(2):220-2.
8. Sendama W, Shipley M. Traumatic chylothorax: A case report and review. *Respir Med Case Rep.* 2015;14:47-8.
9. Seitelman E, Arellano JJ, Takabe K, et al. Chylothorax after blunt trauma. *J Thorac Dis.* 2012;4(3):327-30.
10. Serin-Ezer S, Oğuzkurt P, Ince E, et al. Bilateral chylothorax after blunt thoracic trauma: a case report. *Turk J Pediatr.* 2009;51(5):504-6.
11. Allison S, Rainey M, Aarabi S, et al. Traumatic laceration of the cisterna chyli treated by lymphangiography and percutaneous embolization. *Cardiovasc Intervent Radiol.* 2014;37(1):267-70.

Spinal Epidural Abscess Complicated by Meningitis, Sepsis and Thrombocytopenia in a Patient Lacking Traditional Risk Factors

Christian Spano, MD*
Michael Ward, DO†
Nicole Zagelbaum, DO†

*Orange Regional Medical Center, Department of Emergency Medicine,
Middletown, New York

†Touro College of Osteopathic Medicine, Middletown, New York

Section Editor: Rick A. McPheeters, DO

Submission history: Submitted October 28, 2016; Revision received December 13, 2016; Accepted December 19, 2016

Electronically published March 15, 2017

Full text available through open access at http://escholarship.org/uc/uciem_cpem

DOI: 10.5811/cpem.2016.12.33001

Spinal epidural abscess is a rare diagnosis with a classic triad of fever, spinal pain and neurologic deficits. Only a small proportion of patients have all three findings, making the diagnosis challenging. Here we present a case of cervical and thoracic spinal epidural abscess complicated by meningitis, sepsis and thrombocytopenia in a patient lacking traditional risk factors. The patient was initially treated non-operatively secondary to thrombocytopenia but subsequently required transfer to a tertiary care facility for surgical drainage after clinical deterioration. This case report highlights the need for a high index of suspicion and low threshold for imaging when considering this rare but potentially deadly condition. [Clin Pract Cases Emerg Med. 2017;1(2):115–117.]

INTRODUCTION

Epidural abscesses remains a diagnosis of concern among emergency physicians, as they often present with non-specific symptoms that can quickly progress to permanent disability and death if not identified and treated early.¹ Pre-disposing risk factors include a history of intravenous (IV) drug use, immunodeficiency, skin and soft tissue infections, trauma, and degenerative joint disease.² Iatrogenic causes have been identified to be a result of procedures including neurostimulation, epidural injections, and catheterization.³⁻⁵ Although the diagnosis remains rare, the number of confirmed cases has doubled over the past two decades from one of every 20,000 admissions to one of every 10,000.² Explanations for the dramatic rise include better detection via magnetic resonance imaging (MRI) and increased use of invasive spinal instrumentation, as well as increasing IV drug use.^{6,7}

The most common presenting symptoms include back pain and fever, which progress to focal neurologic deficits and bowel/urine incontinence.^{2,8} Existing case reports have outlined rare presenting symptoms including abdominal pain, anterior chest pain, and cauda equina syndrome highlighting the frequent delay in diagnosis.⁹⁻¹¹ Here we present a case of a healthy white male lacking traditional risk factors who presented to our community emergency department (ED)

with a chief complaint of shortness of breath who was found to have a cervical and thoracic spinal epidural abscess that was complicated by meningitis, sepsis and thrombocytopenia, thwarting immediate surgical decompression.

CASE REPORT

The patient was a 65-year-old healthy, white, married, non-drinking, non-smoking educated male who presented to our ED complaining of generalized illness and shortness of breath. He reported experiencing generalized fatigue with rapid breathing over the prior 2 - 3 days but denied any cough, lower extremity edema, rashes or chest pain. He reported feeling “feverish” but did not take his temperature during the course of his illness. Although the patient didn’t initially complain of neck or back pain, review of systems revealed mild neck discomfort with bilateral hand paresthesias, but the patient quickly dismissed these symptoms as related to chronic neck pain exacerbated by increased physical activity over the prior one week. He also reported a mild headache. The patient’s son reported that he appeared to be confused at times over the preceding week. The patient denied any previous medical history and his surgical history was only significant for a transmetatarsal amputation one-year prior for a traumatic foot injury. The patient denied any history of IV drug use.

Vital signs of note included a rectal temperature of 100.4, oxygen saturation of 94% on room air, a heart rate of 110 beats per minute and a respiratory rate of 22 respirations per minute. His lungs were clear to auscultation and he did not have any cardiac murmurs. Skin exam revealed a chronic-appearing draining sinus at the site of a previous transmetatarsal amputation of the right foot. There was no surrounding cellulitis or purulent drainage from the wound, which was draining serous fluid at time of exam. His strength and reflexes were normal, but sensation to light touch was decreased along the C5 and C6 dermatome bilaterally. Neck exam revealed nuchal rigidity. There was no midline bony tenderness on the cervical, thoracic or lumbar spine.

Initial ED laboratory evaluation was significant for leukocytosis of $20.7 \times 10^3/\mu\text{L}$ with 80% neutrophils and 12% bands, and thrombocytopenia of $71 \times 10^3/\mu\text{L}$. The patient's basic metabolic profile was unremarkable with a glucose of 126 mg/dL. Given the patient's fever, nuchal rigidity and reported confusion by family members, meningitis remained high on the differential diagnosis. A lumbar puncture was performed in the ED, which yielded cloudy cerebral spinal fluid (Image 1b) with a glucose of 10 mg/dL, white blood cell count of 1670 cells/ μL and red blood cell count of 78 cells/ μL . Cerebrospinal fluid microscopy revealed many polymorphonuclear leukocytes (Image 1a) but the Gram stain was reported to be negative. A computed tomography of the brain was performed prior to lumbar puncture, which was negative. The patient was placed on broad spectrum antibiotics and admitted to the intensive care unit.

Although the patient lacked any classic risk factors for epidural abscess, an emergent MRI of the cervical and thoracic spine was ordered from the ED due to the patient's decreased bilateral upper extremity sensation, which couldn't be explained by meningitis alone. The MRI revealed an 8 cm epidural abscess involving C2 through C6 (Image 2).

Vancomycin and piperacillin/tazobactam were administered in the ED. An emergent consult was placed

to neurosurgery but surgery was deferred secondary to thrombocytopenia. Blood and urine cultures on day two grew methicillin-sensitive *Staphylococcus aureus*. The serous fluid draining from the patient's chronic foot wound was never Gram stained or cultured.

Over the subsequent 48 hours after admission, the patient's leukocytosis and thrombocytopenia worsened and a follow-up MRI revealed an extension of the abscess to 12 cm. Clinically, the patient began to have alternating episodes of apnea and tachypnea. As a result of the patient's deteriorating condition, he was transferred to a tertiary care facility for planned surgical drainage.

DISCUSSION

Our patient presented to a community ED complaining only of generalized illness and rapid breathing, which was likely the result of the patient's sepsis with systemic inflammatory response syndrome at the time of presentation. Upon further evaluation, the patient was found to have clinical and laboratory signs of meningitis. The patient's neurologic complaints elicited on review of systems and mild decreased upper extremity sensation on exam were confounded by his history of chronic neck pain and almost dismissed, but they prompted an MRI in the ED confirming the diagnosis of cervical and thoracic spinal epidural abscess. Our patient was not an IV drug user and was previously healthy and lacking traditional risk factors for this relatively rare diagnosis. He did, however, have a chronically draining wound at a previous transmetatarsal amputation site that we presume was the source of the patient's bacteremia, causing hematogenous seeding to the epidural space.

CONCLUSION

Given the rarity of spinal epidural abscesses, medical professionals rely on retrospective case series and case reports as the basis for the scientific literature on this topic. Symptoms are often atypical and the diagnosis of spinal

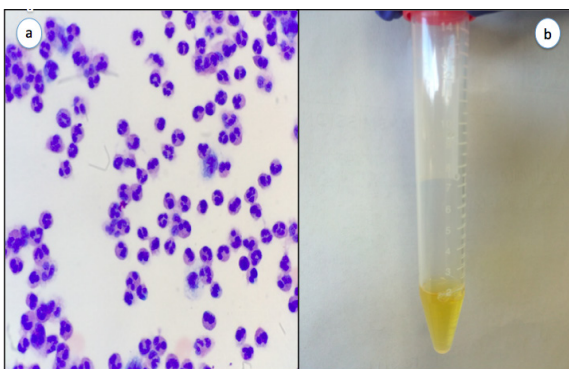


Image 1. a) Slide of CSF demonstrating many polymorphonuclear leukocytes; b) CSF of patient showing xanthochromia. *CSF*, cerebrospinal fluid

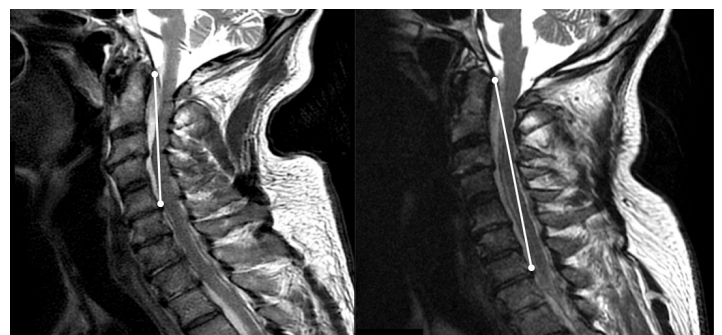

Image 2. Left: C spine sagittal T2 weighted image taken on day of presentation with lesion from C2-C5. Right: C spine sagittal T2 weighted image 3 days post-admission with larger lesion now from C2-C7.

epidural abscess is often delayed. Our case highlights the need for emergency physicians to have a high index of suspicion and a low threshold for imaging to evaluate for spinal epidural abscesses even in patients lacking traditional risk factors and without classic presentations, as a missed or delayed diagnosis can have devastating consequences.

Address for Correspondence: Christian Spano, MD, Orange Regional Medical Center, 707 East Main Street, Middletown, NY 10940. Email: cspano@ormg.org.

Conflicts of Interest: By the CPC-EM article submission agreement, all authors are required to disclose all affiliations, funding sources and financial or management relationships that could be perceived as potential sources of bias. The authors disclosed none.

Copyright: © 2017 Spano. This is an open access article distributed in accordance with the terms of the Creative Commons Attribution (CC BY 4.0) License. See: <http://creativecommons.org/licenses/by/4.0/>

REFERENCES

1. Reihnsaus E, Waldbaur H, Seeling W. Spinal epidural abscess: a meta-analysis of 915 patients. *Neurosurg Rev*. 2000;23:175–204.
2. Darouiche RO. Spinal epidural abscess. *N Engl J Med*. 2006;355:2012–20.
3. McKernan N, Anderson J. (379) Delayed presentation of an epidural abscess with resultant meningitis following an uneventful neurostimulator trial; a case report. *The Journal of Pain*. 2015;16(4):S70.
4. Noh SH, Heo DH. Whole cerebrospinal axis infection after lumbar epidural injection: a case report. *European Spine Journal*. 2015;24(4):525–8.
5. Van Rappard JRM, Tolenaar JL, Smits AB, et al. Spinal epidural abscess and meningitis following short-term epidural catheterisation for postoperative analgesia. *BMJ Case Reports*. 2015: bcr2015210867.
6. Arko L 4th, Quach E, Nguyen V, et al. Medical and surgical management of spinal epidural abscess: A systematic review. *Neurosurg Focus*. 2014;37(2):E4.
7. Schoenfeld AJ, Wahlquist TC. Mortality, complication risk, and total charges after the treatment of epidural abscess. *Spine J*. 2015;15(2):249–55.
8. Shweikeh F, Saeed K, Bukavina L, et al. An institutional series and contemporary review of bacterial spinal epidural abscess: current status and future directions. *Neurosurg Focus*. 2014;37(2):E9.
9. Liou JH, Su YJ. Unusual cervical spine epidural abscess. *Am J Emerg Med*. 2015;33(10):1543.e1-2.
10. Bremer AA, Darouiche RO. Spinal epidural abscess presenting as intra-abdominal pathology: a case report and literature review. *J Emerg Med*. 2004;26(1):51-6.
11. Agarwal N, Shah J, Hansberry DR, et al. Presentation of cauda equina syndrome due to an intradural extramedullary abscess: a case report. *The Spine Journal*. 2015;14:e1-6.

Quality Initiatives May Affect Diagnostic Accuracy: STEMI Mimics in an Age of Decreasing Door to Balloon Time

Jose L Villa-Uribe, MD*
Elizabeth M Schoenfeld, MD†

*University of Massachusetts Medical School- Baystate, Department of Emergency Medicine, Springfield, Massachusetts

†University of Massachusetts Medical School- Baystate, Department of Emergency Medicine, Center for Quality of Care Research, Springfield, Massachusetts

Section Editor: Rick A. McPheeters, DO

Submission history: Submitted October 28, 2016; Revision received December 13, 2016; Accepted December 19, 2016

Electronically published March 15, 2017

Full text available through open access at http://escholarship.org/uc/uciem_cpem

DOI: 10.5811/cpcem.2016.12.33009

A 53-year-old male with several cardiac risk factors presented to the emergency department with back pain and an electrocardiogram concerning for an anterior ST-elevation myocardial infarction. The patient decompensated hemodynamically and a point-of-care ultrasound revealed a small pericardial effusion. An aortic dissection was ruled out by computed tomography angiography and coronary catheterization did not reveal a culprit lesion. The diagnosis of tamponade was made in the catheterization laboratory after measurement of intra-cardiac diastolic pressures and the patient's symptoms resolved after drainage of 100 mL of pericardial fluid. [Clin Pract Cases Emerg Med. 2017;1(2):118–121.]

INTRODUCTION

ST-segment elevation in an electrocardiogram (ECG) immediately suggests ST-elevation myocardial infarction (STEMI) as a likely diagnosis for patients with cardiac symptoms. This ECG finding, however, can be present in a variety of other entities such as myocarditis, pericarditis, vasospasm, aortic dissection, cardiac tamponade, Brugada syndrome, left bundle branch block, and intracranial hemorrhage.^{1–8} Providers need to consciously and consistently consider these alternative diagnoses as they face continued emphasis on improving door-to-balloon (DTB) times for patients with STEMI. In this article, we report a case of cardiac tamponade that presented with ST-segment elevation.

CASE REPORT

A 53-year-old male with a history of hypertension, hyperlipidemia, and type-2 diabetes mellitus presented to our emergency department (ED) with a three-day history of worsening back pain. The pain was diffuse in the thoracic and lumbar areas and did not improve despite ibuprofen and oxycodone/acetaminophen. The patient denied chest pain, shortness of breath, fevers, chills, or any traumatic injuries. He had been evaluated at an urgent care center twice since the onset of his symptoms.

On arrival to the ED, the patient was afebrile, had a blood

pressure of 104/69 mmHg, and a heart rate of 125 bpm. An ECG revealed ST-segment elevation in leads V1-V5 (Image 1) and the cardiac catheterization laboratory was activated due to concern for an anterior STEMI. During this time, the patient's blood pressure decreased to 85/74 mmHg, which did not increase despite a one-liter bolus of normal saline. A bedside cardiac echocardiogram performed by the ED provider showed a small pericardial effusion (Image 2) and a portable upright chest radiograph showed a widened mediastinum (11 cm). The patient's hypotension and imaging findings were concerning for an aortic dissection, leading the ED provider, in conjunction with the interventional cardiologist, to obtain an emergent computed tomography angiography (CTA) of the chest. The patient was started on peripheral norepinephrine given his continued hemodynamic instability and, after the CTA was negative for dissection, he was transported to the catheterization laboratory.

An intra-aortic balloon pump was placed in the catheterization lab, and evaluation of the coronary arteries showed minimal non-obstructive coronary disease. An emergent (cardiologist-performed) transthoracic echocardiogram in the catheterization lab once again showed a small circumferential pericardial effusion (Image 3). A Swan-Ganz catheter was placed and showed equalization of diastolic pressures across the cardiac

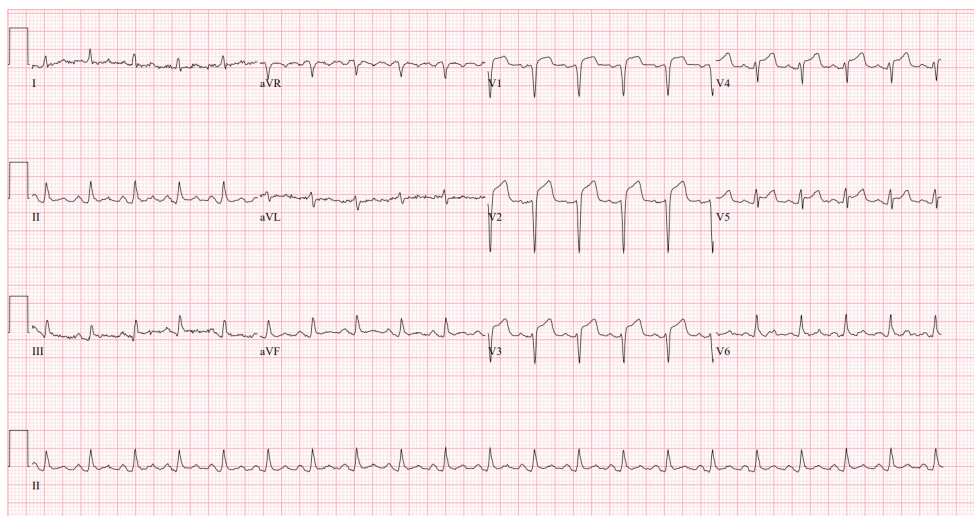


Image 1. Electrocardiogram showed ST-segment elevation in leads V1-V5

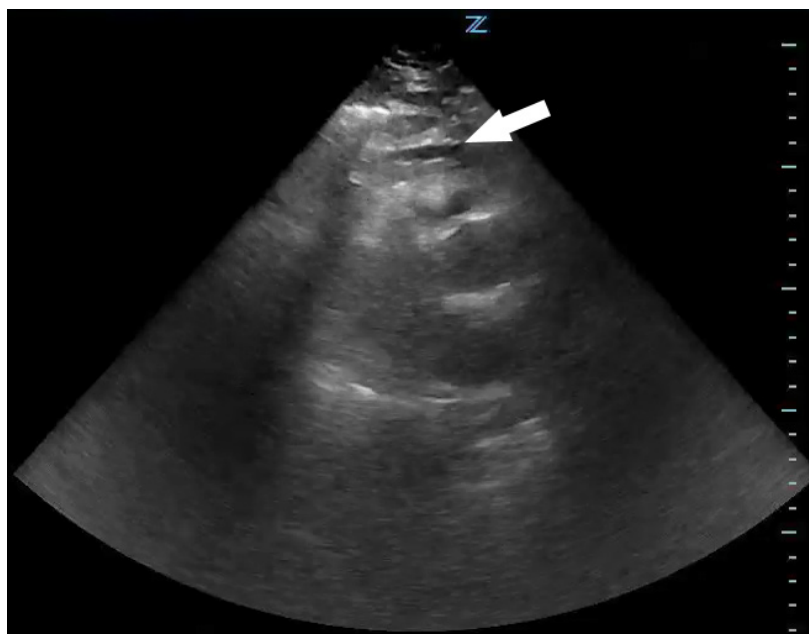

Image 2. Point-of-care cardiac ultrasound, parasternal long axis view, showing a small pericardial effusion (arrow). See the supplemental file "Video1.mp4" for a video of this ultrasound.

chambers. A pericardiocentesis was then performed with drainage of 100 mL of straw-colored fluid, after which the patient's mean arterial pressure improved to 95 mmHg off vasopressors. This procedure also led to immediate relief of his back pain. A pericardial drain was left in place, the intra-aortic balloon pump was removed, and the patient was transported to the cardiac intensive care unit for further management.

Lab work revealed an elevated troponin T (0.15 ng/mL) with normal creatinine kinase (36 U/L), elevated white blood cell count (19,900/mm³), elevated erythrocyte sedimentation rate (84 mm/hr), and elevated C-reactive protein (39.1 mg/dL), suggesting the diagnosis of

pericarditis. The patient was started on colchicine and ibuprofen and continued to be hemodynamically stable through his hospital stay. No infectious, malignant, traumatic, pharmaceutical, or autoimmune factors were identified as the etiology for his pericarditis during his hospital stay. A repeat echocardiogram showed resolution of the pericardial effusion. The pericardial drain was removed and the patient was discharged on hospital day three with scheduled outpatient follow up.

DISCUSSION

We present a case of pericardial tamponade presenting as a possible STEMI. Although this patient's symptoms were

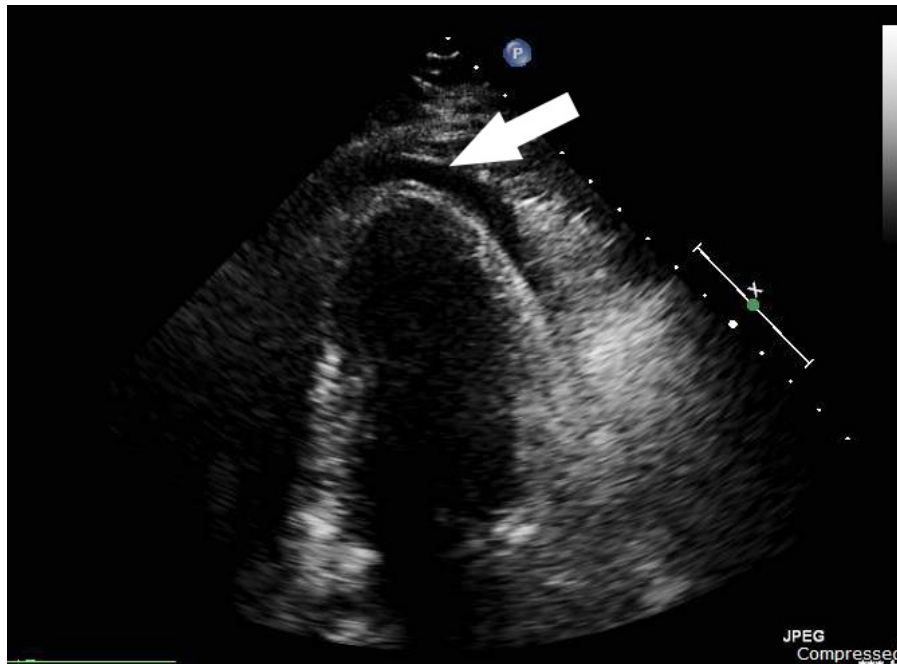


Image 3. Emergent transthoracic echocardiogram performed in the cardiac catheterization lab prior to pericardiocentesis: two-chamber apical view showing a small pericardial effusion (arrow). See the supplemental file “Video2.mp4” for a video of this ultrasound.

atypical and the ECG did not show reciprocal changes, his comorbidities and ST-elevations made acute coronary syndrome (ACS) the leading concern. The clinicians retained their skepticism and identified aortic dissection as an alternative diagnosis as his clinical picture evolved. Once this was ruled out, however, the focus immediately returned to ACS. In the end, the final diagnosis of tamponade was not made without invasive testing. This case highlights the need for providers to remain vigilant for alternative diagnoses in patients with presumed STEMI despite the pressures to decrease DTB time.

Lower DTB times are known to improve mortality in STEMI,⁹⁻¹¹ and many initiatives around the world have successfully decreased these times.¹²⁻¹⁴ These aggressive efforts to improve DTB time, however, can predispose healthcare providers to cognitive errors such as anchoring or premature closure when an ECG shows ST-segment elevations in a patient with a plausible history of present illness. A recent study by Fanari et al. quantifies this effect: while an aggressive DTB improvement initiative did lead to lower times to therapy (76 to 61 minutes, $p=0.001$), the rate of false-positive STEMI (FP-STEMI) increased significantly (7.7% to 16.5%, $p=0.02$). More concerning was the increase of in-hospital mortality for FP-STEMI (5.6% to 21.6%, $p=0.03$). These preliminary findings led to a quality improvement initiative aimed at recognizing non-STEMI causes of ST-segment elevation along with the pre-existing DTB initiative. Although the rate of FP-STEMI remained high after implementation (16.5% to 20.3%, $p=0.30$), there was a significant decrease in hospital mortality for this group (21.6%

to 4.5%, $p=0.03$).¹⁵ These results are encouraging in showing that decreasing FP-STEMI mortality is possible in the era of ever-decreasing DTB times.

Address for Correspondence: Jose L Villa-Uribe, MD, Baystate Medical Center, 759 Chestnut St., Springfield, MA 01199. Email: Jose.Villa-UribeMD@bhs.org.

Conflicts of Interest: By the CPC-EM article submission agreement, all authors are required to disclose all affiliations, funding sources and financial or management relationships that could be perceived as potential sources of bias. The authors disclosed none.

Copyright: © 2017 Villa-Uribe et al. This is an open access article distributed in accordance with the terms of the Creative Commons Attribution (CC BY 4.0) License. See: <http://creativecommons.org/licenses/by/4.0/>

REFERENCES

1. Wu BT, Li CY, Chen YT. Type A Aortic Dissection Presenting with Inferior ST-Elevation Myocardial Infarction. *Acta Cardiol Sin.* 2014;30(3):248-52.
2. Pyxaras SA, Lardieri G, Milo M, et al. Chest pain and ST elevation: not always ST-segment-elevation myocardial infarction. *J Cardiovasc Med (Hagerstown).* 2010;11(8):615-8.

3. Leeies M, Weldon E. STEMI stymie: Metastatic cancer and cardiac tamponade presenting as inferior STEMI. *Ann Emerg Med.* 2011;57(3):221-4.
4. Deshmukh A, Pant S, Dibu G, et al. The masquerading act of ST elevation. *Acta Cardiol.* 2012;67(1):105-7.
5. Cima K, Grams A, Metzler B. Subarachnoid haemorrhage mimicking a STEMI. *Eur Heart J Acute Cardiovasc Care.* 2016:1-2.
6. Brywczynski J, Mckinney J, Brown A, et al. Discerning STEMI Mimics in the Field. *J Emerg Med Serv.* 2013;38(12):1-10.
7. Wang K, Asinger RW, Marriott HJ. ST-Segment Elevation in Conditions Other Than Acute Myocardial Infarction. *N Engl J Med.* 2003;349(22):2128-35.
8. Pollak P, Brady W. Electrocardiographic Patterns Mimicking ST Segment Elevation Myocardial Infarction. *Cardiol Clin.* 2012;30(4):601-15.
9. McNamara RL, Wang Y, Herrin J, et al. Effect of Door-to-Balloon Time on Mortality in Patients With ST-Segment Elevation Myocardial Infarction. *J Am Coll Cardiol.* 2006;47(11):2180-6.
10. Rathore SS, Curtis JP, Chen J, et al. Association of door-to-balloon time and mortality in patients admitted to hospital with ST elevation myocardial infarction: national cohort study. *BMJ.* 2009;338:b1807.
11. Lambert L, Brown K, Segal E, et al. Association between timeliness of reperfusion therapy and clinical outcomes in ST-elevation myocardial infarction. *J Am Med Assoc.* 2010;303(21):2148-55.
12. Nallamothu BK, Krumholz HM, Peterson ED, et al. Door-to-Balloon Times in Hospitals Within the Get-With-The-Guidelines Registry After Initiation of the Door-to-Balloon (D2B) Alliance. *Am J Cardiol.* 2009;103(8):1051-5.
13. Chua SK, Cheng JJ, Shyu KG, et al. Improvement in Door-to-Balloon (D2B) Time in Acute ST-Elevation Myocardial Infarction Through the D2B Alliance --experience of 15 primary percutaneous coronary intervention centers in Taiwan. *Circ J.* 2013;77(2):383-9.
14. Bradley EH, Nallamothu BK, Herrin J, et al. National Efforts to Improve Door-to-Balloon Time. Results From the Door-to-Balloon Alliance. *J Am Coll Cardiol.* 2009;54(25):2423-9.
15. Fanari Z, Abraham N, Kolm P, et al. Aggressive Measures to Decrease "door to Balloon" Time and Incidence of Unnecessary Cardiac Catheterization: Potential Risks and Role of Quality Improvement. *Mayo Clin Proc.* 2015;90(12):1614-22.

Should Pharmacies Be Included in Medication Reconciliation? A Report of Recurrent Valproic Acid Toxicity

B. Tate Cutshall, PharmD*
Samarth P. Shah, PharmD†
Megan A. Van Berkel, PharmD†
Shanise Patterson, PharmD‡
L. Jeff Harris, MD, MS§
Jessica V. Rivera, PharmD†

*Houston Methodist Hospital, Department of Pharmacy, Houston, Texas
 †Methodist LeBonheur Healthcare-University Hospital, Department of Pharmacy, Memphis, Tennessee
 ‡Methodist LeBonheur Healthcare-South Hospital, Department of Pharmacy, Memphis, Tennessee
 §University of Tennessee Health Science Center, Department of Emergency Medicine, Memphis, Tennessee

Section Editor: Rick A. McPheeters

Submission history: Submitted October 28, 2016; Revision received December 15, 2016; Accepted December 27, 2016

Electronically published March 15, 2017

Full text available through open access at http://escholarship.org/uc/uciem_cpchem

DOI: 10.5811/cpchem.2016.12.33002

Including outpatient pharmacies in the medication reconciliation process upon hospital discharge is not commonly performed. This case highlights the consequences of a patient refilling a discontinued prescription for valproic acid (VPA). We present a 32-year old male found unresponsive after ingesting delayed release divalproex sodium. Cerebral edema was visualized on magnetic resonance imaging. Hemodialysis and levo-carnitine treatment led to improved mental status, and VPA was discontinued. The same patient presented with VPA overdose eight months later after he continued to fill an outdated prescription. This case highlights consequences of VPA toxicity; it also demonstrates an opportunity to improve patient safety and high-value care by collaborating with outpatient pharmacies in the medication reconciliation process upon hospital discharge. [Clin Pract Cases Emerg Med. 2017;1(2):122–125.]

INTRODUCTION

Inaccurate medication reconciliation is the source of many medication-related misadventures leading to hospital admissions and patient morbidity and mortality.¹ In randomized controlled studies, pharmacist-led discharge medication reconciliation interventions result in hospital cost avoidance and improve patient safety.¹ Valproic acid (VPA) is an antiepileptic medication commonly used to treat seizures, bipolar disorder, and migraine headache.² Its mechanism of action includes sodium channel inhibition, T-type calcium channel inhibition, suppression of glutamate, and inhibition of γ -aminobutyric acid (GABA) metabolism. VPA is available in a variety of dosage forms, and peak plasma concentrations are achieved rapidly (within 1-5 hours).³ With toxic ingestions, absorption and subsequent peak may be delayed; one case report reported peak serum levels 17 hours post ingestion.⁴ Therapeutic concentrations of VPA range from 50 to 100 $\mu\text{g/L}$, and it is 80–90% plasma protein bound.³ Elimination occurs via first-order kinetics with a half-life of 5-20 hours; however, this can be prolonged up to 30 hours with toxicity.³

At toxic levels, VPA can cause central nervous system (CNS) depression, respiratory depression, acute kidney injury, anion-gap metabolic acidosis, and electrolyte abnormalities (i.e. hypernatremia and hypocalcemia). VPA is also associated with hepatotoxicity, pancreatitis, hyperammonemic encephalopathy, cerebral edema, and blood dyscrasias such as leukopenia, anemia, and thrombocytopenia.

Treatment of VPA toxicity is largely supportive; however, it can include enhanced elimination methods such as charcoal hemoperfusion and hemodialysis (HD). HD is known to clear toxins that are water soluble, have low volume of distribution, and are not highly bound to plasma proteins. VPA exhibits high plasma protein binding with therapeutic concentrations; however, saturation of plasma proteins may occur in the setting of acute intoxication and result in increased free VPA concentrations amenable to HD.⁵⁻⁶ While published data are limited, high-flux HD has been shown to be sufficient without the need for concomitant charcoal hemoperfusion.⁷ Furthermore, HD should be considered to remove ammonia or correct severe metabolic disturbances during VPA toxicity.

Hyperammonemia caused by VPA toxicity is a complex process; it involves depletion of carnitine stores and ultimately results in inhibition of carbamoyl-phosphate synthetase, the primary enzyme responsible for ammonia incorporation into the urea cycle. The use of L-carnitine in the treatment of VPA-induced hyperammonemia is secondary to its ability to assist in the metabolism of long-chain fatty acids.

We present a patient with two presentations of VPA toxicity, eight months apart, each successfully treated with HD and L-carnitine. The cases presented provide insight on the detrimental effects that VPA toxicity can cause and review current evidence-based treatment options. Additionally, the second presentation sheds light on the unfortunate repercussions that an incomplete discharge reconciliation can have, namely the lack of patient care transition from inpatient to outpatient when a significant medication event occurred in hospital and subsequent medication changes were made.

CASE REPORT

First Presentation

A 32-year-old African-American male with a history of bipolar disorder, hypertension, and previous suicide attempts was brought to the emergency department (ED) with altered mental status (AMS). The patient ingested an unknown amount of his prescription medications with the timing unknown. He was prescribed lisinopril 10mg by mouth (PO) daily, hydrochlorothiazide 25mg PO daily, and divalproex sodium delayed release 500mg PO every morning and 1000mg PO nightly. Upon presentation, the patient was responsive only to painful stimuli with a Glasgow Coma Score (GCS) of 12. Vitals included a blood pressure of 152/70 mmHg and heart rate of 110 beats per minute. Computed tomography of the brain/head was unremarkable. However, magnetic resonance imaging (MRI) revealed cerebral edema and possible laminar necrosis.

On presentation, pertinent laboratory values included the following: VPA 481.9 µg/dL, lactate 6.9 mmol/L, ammonia 303 µmol/L, and platelets 135×10^3 microL and serum creatinine 2.61 mg/dL. Other chemistries and liver function tests were within normal limits (WNL). The urine drug screen, serum alcohol level, acetaminophen level, and salicylate level were unremarkable.

The patient required intubation for AMS and acute respiratory failure, and a temporary dialysis catheter was emergently placed for HD. Prior to HD and three hours after initial presentation, VPA level rose to greater than 600 µg/mL (Figure).

The patient was dialyzed six hours after presentation for a total of six hours; post HD he was started on intravenous (IV) L-carnitine 1,300 mg q4h (15mg/kg/dose) based on literature recommendations and received lactulose 30 grams PO once.⁸ During his hospitalization, platelets reached a nadir of 63×10^3 microL, but other pertinent laboratory results remained WNL. The patient improved clinically to include a GCS of 15, allowing successful extubation on hospital day 2. VPA was not to be continued upon discharge and he was transferred to a

psychiatric facility for further evaluation.

Second Presentation

During the second presentation, the patient was found unconscious and diaphoretic in his bedroom by his caregiver. He had AMS (GCS 12) and was unable to communicate effectively. Home medications included venlafaxine 75 mg PO daily, benztropine 2 mg PO daily and divalproex sodium DR 500 mg PO twice daily. Although he was not discharged on divalproex sodium during his last visit, he had continued to refill this prescription at his outpatient pharmacy. Notably, the patient also had been using marijuana regularly the previous week.

Baseline laboratory values on arrival include the following abnormalities: ammonia 48 µmol/L, VPA level 420 µg/mL, lactate 2.6 mmol/L, glucose 67 mg/dL, and platelets 127×10^3 microL. Other laboratory values were WNL.

Although he did not immediately require HD, nephrology was emergently consulted in light of the complications of his previous admission. A repeat VPA level of 272 µg/mL was drawn five hours after the initial level before HD (Figure), and the patient was dialyzed for four hours. L-carnitine 2,640 mg PO q8h (32 mg/kg/dose) and lactulose 10 g PO four times a day were initiated. Laboratory findings one hour after HD included ammonia 84 µmol/L and VPA level 105 µg/mL. His mental status and symptoms improved (GCS 15), and the patient was able to follow commands appropriately. He was discharged on hospital day 2 to a psychiatric facility with instructions to continue L-carnitine 2,640 mg PO every eight hours given continued elevation in ammonia levels. This presentation scored a 10 on the Naranjo scale indicating a definite adverse drug reaction.⁹

DISCUSSION

We present a unique patient with two separate presentations of VPA toxicity necessitating aggressive measures and treatment with HD and L-carnitine. On the first admission, cerebral edema was visualized on MRI and a peak VPA level of greater than 600 µg/mL was reduced to 199 µg/L at the end of a six-hour HD session. During the second admission, a peak level of 420 µg/mL decreased to 105 µg/mL after a four-hour HD session. While VPA is highly protein bound, plasma proteins become saturated during VPA toxicity, causing an increase in unbound VPA that contributes to the signs and symptoms of toxicity. These small molecules become amenable to elimination via HD allowing for more rapid decline in the serum concentration and subsequent improvement in symptoms of toxicity, as evidenced by the patient's first presentation.^{5,6}

Historically, charcoal hemoperfusion was used for the treatment of VPA toxicity.⁹ However, previous case reports describe the effectiveness of using HD alone. What remains unclear is the threshold in VPA concentrations where HD may be useful. Based on the literature available, the EXTRACORPOREAL TREATMENTS IN POISONING (EXTRIP) workgroup recommends

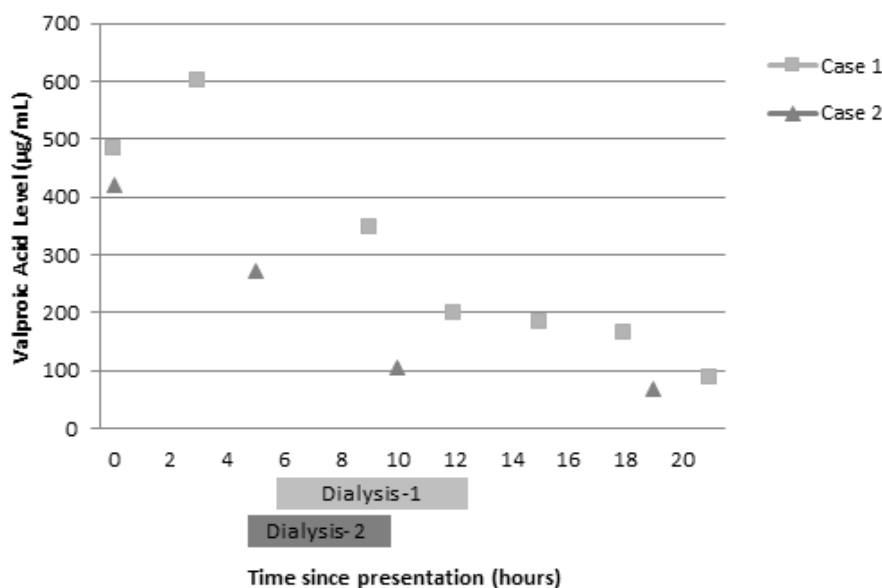


Figure. Serum valproic acid (VPA) levels during admission of patient with suspected VPA toxicity on two separate occasions

dialysis in patients with a VPA concentration greater than 1,300 mg/L, the presence of cerebral edema, or shock.⁷ Dialysis may be used when VPA concentrations are greater than 900 µg/mL, in the presence of coma, respiratory depression requiring mechanical ventilation, acute hyperammonemia, or pH less than 7.1.⁷ Similarly, a review article evaluating extracorporeal elimination of VPA advises HD in severe VPA toxicity (coma or hemodynamic compromise) and a plasma VPA level >850 µg/mL.⁹ During our patient's first presentation, the suggested criteria for HD were met due to the presence of cerebral edema on MRI and the need for mechanical ventilation. In the second presentation, AMS and his ingestion history drove the decision for HD. In a patient with therapeutic VPA concentrations, HD should not significantly impact VPA levels; it may be a viable option in acute toxicity by reducing free drug and improving clinical condition.

Hemodialysis is a viable option for treatment of VPA-induced hyperammonemia. VPA is metabolized primarily in the liver by means of glucuronic acid conjugation and oxidative pathways via the cytochrome P450 system. The major metabolites are 2-en-VPA, 4-en-VPA, and propionic acid derivatives which are active. 2-en-VPA has a long half-life and causes cerebral edema and coma, while 4-en-VPA causes reversible hepatotoxicity. Propionic acid is responsible for causing hyperammonemia by three proposed mechanisms. Its interaction with and depletion of carnitine impairs the transportation and metabolism of long-chain fatty acids. Also, it prevents glutamine production in the kidneys, which reduces ammonia levels in the brain. Lastly, it inhibits carbamoyl-

phosphate synthetase, a hepatic mitochondrial enzyme responsible for eliminating ammonia within the urea cycle. The cumulative result is accumulation of ammonia, causing encephalopathy. L-carnitine has the ability to transport and metabolize long-chain fatty acids; thus, it has shown to be beneficial in VPA-induced hyperammonemia, especially in patients with hepatotoxicity, hyperammonemia, or significant CNS depression.¹¹⁻¹⁶

An interesting aspect of our case was the reported increase in cannabis use during the week prior to the second VPA ingestion. To our knowledge, there are no reports of VPA toxicity caused by cannabis ingestion. However, cannabidiol, a component of marijuana, weakly inhibits the CYP2C9 pathway. In addition, delta-9-tetrahydrocannabinoid has high plasma lipoprotein binding. The potential for weak inhibition of VPA metabolism via CYP2C9 and displacement of protein binding due to cannabis could have contributed to the toxicity, but this interaction has not been studied.¹⁷

Of most interest, is the demonstration of the importance of involving a patient's outpatient pharmacy when a medication is discontinued for toxicity. This patient's VPA was discontinued upon discharge after the first overdose; unfortunately, measures were not put in place to prevent patient access to medication. Thus, he continued to fill this medication from his outpatient pharmacy. Including a pharmacist in hospital discharge medication reconciliation has been previously shown to decrease 30-day hospital readmission.^{18,19} This service is commonly provided to patients with multiple comorbidities and complicated medication regimens; however, a second occurrence of toxicity

in this patient demonstrates that coordinating discharge care for patients with high-risk overdoses should be performed. Methods for reliably informing outpatient pharmacies of discharge medication reconciliation after acute care episodes are expected to improve patient safety.

CONCLUSION

VPA toxicity causing hyperammonemic encephalopathy should be treated as a medical emergency. The use of HD is essential to decrease free VPA levels in some patients. Usage of L-carnitine at recommended doses of 50-100 mg/kg/day may aid in resolution of hyperammonemic encephalopathy due to its effect on the transportation and metabolism of long-chain fatty acids. While lactulose is a preferred treatment for hyperammonemia due to hepatic encephalopathy, routine use provides little benefit given the mechanism behind VPA-induced hyperammonemia. While this case presentation adds to the body of literature supporting high-flux HD for treatment of VPA toxicity, it further emphasizes the importance of including outpatient pharmacies upon medication reconciliation. This is especially relevant in cases where medications are discontinued due to toxicity or adverse effects. While we were able to manage the patient appropriately, proper communication after the first presentation could have prevented the second occurrence altogether. Having a multidisciplinary approach in improving communication between providers and outpatient pharmacies is vital in ensuring optimal patient care.

ACKNOWLEDGMENTS

Dr. Cutshall and Dr. Shah contributed equally as first authors.

Address for Correspondence: Jessica V Rivera, PharmD, Methodist Healthcare - University Hospital, 1265 Union Ave, Memphis, TN 38104. Email: jvrivera@uabmc.edu.

Conflicts of Interest: By the CPC-EM article submission agreement, all authors are required to disclose all affiliations, funding sources and financial or management relationships that could be perceived as potential sources of bias. The authors disclosed none.

Copyright: © 2017 Cutshall et al. This is an open access article distributed in accordance with the terms of the Creative Commons Attribution (CC BY 4.0) License. See: <http://creativecommons.org/licenses/by/4.0/>

REFERENCES

1. Sebaaly J, Parsons LB, Pilch NA, et al. Clinical and Financial Impact of Pharmacist Involvement in Discharge Medication Reconciliation at an Academic Medical Center: A Prospective Pilot Study. *Hosp Pharm*. 2015;50(6):505-13.
2. Divalproex sodium [package insert]. AbbVie Inc. 2016.
3. McNamara JO. Drugs effective in the therapy of the epilepsies. In Hardman JG, Limbird LE, Molinoff PB, et al (Ed.). Goodman & Gilman's The Pharmacological basis of therapeutics. The McGraw-Hill Companies, Inc. 1996;476.
4. Graudins A, Aaron CK. Delayed peak serum valproic acid in massive divalproex overdose--treatment with charcoal hemoperfusion. *J Toxicol Clin Toxicol*. 1996;34(3):335-41.
5. Zaccara G, Messori A, Moroni F. Clinical pharmacokinetics of valproic acid--1988. *Clin Pharmacokinet*. 1988;15(6):367-89.
6. Hicks LK, McFarlane PA. Valproic acid overdose and haemodialysis. *Nephrol Dial Transplant*. 2001;16(7):1483-6.
7. Ghannoum M, Laliberté M, Nolin TD, et al. Extracorporeal treatment for valproic acid poisoning: systematic review and recommendations from the EXTRIP workgroup. *Clin Toxicol (Phila)*. 2015;53(5):454-65.
8. Howland MA. Antidotes in depth: L-carnitine. In Nelson LS, Lewin NA, Howland MA, et al (Ed.). Goldfrank's Toxicologic Emergencies. The McGraw-Hill Companies, Inc. 2011;9:711.
9. Naranjo CA, Busto U, Sellers EM, et al. A method for estimating the probability of adverse drug reactions. *Clin Pharmacol Ther*. 1981;30(2):239-45.
10. Doyon S. Chapter: Anticonvulsants. In Nelson LS, Lewin NA, Howland MA, et al (Ed.). Goldfrank's Toxicologic Emergencies. The McGraw-Hill Companies, Inc. 2011;9:698-713.
11. Temel V, Arıkan M, Temel G. High-flux hemodialysis and levocarnitine in the treatment of severe valproic Acid intoxication. *Case Rep Emerg Med*. 2013;2013:526469.
12. Fontanet EP, Farré M, López MJ, et al. A case of acute valproic acid poisoning treated successfully with L-carnitine. *Eur J Emerg Med*. 2012;19(1):57-62.
13. Wadzinski J, Franks R, Roane D, et al. Valproate-associated hyperammonemic encephalopathy. *J Am Board Fam Med*. 2007;20(5):499-502.
14. Bohan TP, Helton E, McDonald I, et al. Effect of L-carnitine treatment for valproate-induced hepatotoxicity. *Neurology*. 2001;56(10):1405-9.
15. Ohtani Y, Endo F, Matsuda I. Carnitine deficiency and hyperammonemia associated with valproic acid therapy. *J Pediatr*. 1982;101(5):782-5.
16. Laub MC, Paetzke-Brunner I, Jaeger G. Serum carnitine during valproic acid therapy. *Epilepsia*. 1986;27(5):559-62.
17. Yamreudeewong W, Wong HK, Brausch LM, et al. Probable interaction between warfarin and marijuana smoking. *Ann Pharmacother*. 2009;43(7):1347-53.
18. Mekonnen AB, McLachlan AJ, Brien JA. Pharmacy-led medication reconciliation programmes at hospital transitions: a systematic review and meta-analysis. *J Clin Pharm Ther*. 2016;41(2):128-44.
19. Phatak A, Prusi R, Ward B, et al. Impact of pharmacist involvement in the transitional care of high risk patients through medication reconciliation, medication education, and postdischarge call-backs (IPITCH study). *J Hosp Med*. 2016;11(1):39-44.

Acute ST Segment Elevation Myocardial Infarction and Massive Pericardial Effusion Due to Infective Endocarditis

Maxwell Thompson, MD
David C. Pigott, MD
John Gullett, MD
Blayne Gibson, MD

The University of Alabama at Birmingham, Department of Emergency Medicine,
Birmingham, Alabama

Section Editor: Rick A. McPheeters, DO

Submission history: Submitted September 27, 2016; Revision received December 14, 2016; Accepted December 27, 2016

Electronically published March 16, 2017

Full text available through open access at http://escholarship.org/uc/uciem_cpccem

DOI: 10.5811/cpcem.2016.12.32674

Chest pain is a common complaint evaluated in the emergency department. While chest pain in a 22-year-old patient is typically a complaint of low acuity, high-acuity cases that rival those of the older patient population are well documented. We describe a case of complicated infective endocarditis in which point-of-care ultrasound (POCUS) aided the diagnosis of ST-elevation myocardial infarction secondary to a septic thrombus in a 22-year-old female with a history of intravenous drug use. Emergency physicians should be aware of the rare high-acuity cases as well as the impact of POCUS on rapid clinical assessment and treatment of patients of all ages presenting with chest pain. [Clin Pract Cases Emerg Med. 2017;1(2):126–128.]

INTRODUCTION

Chest pain, one of the most common emergency department (ED) complaints, is associated with numerous underlying etiologies with varying treatment and management strategies. Chest pain with accompanying ST segment elevation often places a patient in a pre-defined, institution-dependent pathway involving an interventional cardiologist and/or intravenous thrombolysis due to a presumed atherothrombotic event. In a young patient without significant risk factors for coronary artery disease, it is important to remember that, although rare, other life-threatening causes of ST segment elevation myocardial infarction (STEMI) exist that may require specific management strategies.

CASE REPORT

A 22-year-old white female with a history of intravenous drug use (IVDU) presented to our ED with a two-day history of sharp, substernal chest pain. She had been in a substance abuse rehabilitation facility when her chest pain became so severe that emergency medical services was called. On arrival to the ED, an electrocardiogram revealed sinus tachycardia with STEMI in a right coronary artery (RCA) distribution (Image 1). Cardiology was consulted

and the patient was prepped for percutaneous intervention for revascularization. Given the patient's age, history of IVDU and lack of risk factors for primary cardiac disease, point-of-care ultrasonography (POCUS) was performed by emergency physicians to evaluate for other causes of the patient's presentation.

POCUS revealed a large pericardial effusion with fibrinous stranding without evidence of tamponade physiology (Image 2). Additionally, a thickened posterior mitral valve leaflet was noted, concerning for vegetation (Image 2). The remainder of the cardiac exam, aortic root and thoracic aorta appeared normal in appearance.

The patient was taken emergently for revascularization. Left heart catheterization (LHC) showed a large infectious thrombus causing 100% occlusion of the mid-RCA. This thrombus was aspirated and coronary flow was reestablished. Due to the risk of infection, stenting was not performed at that time. Transesophageal echocardiography (TEE) showed large vegetations on the anterior and posterior mitral valve leaflets with severe mitral regurgitation (Image 3). The patient became acutely hypotensive during the procedure and an emergent intra-aortic balloon pump was placed for hemodynamic support.

The patient was transported to the cardiac intensive care unit in critical condition. She subsequently developed worsening cardiogenic shock and expired shortly after admission.

DISCUSSION

This patient's diagnostic evaluation was complicated by an atypical presentation of infective endocarditis (IE). The patient presented to the ED with chest pain associated with ST segment elevation and a recent history of fever and chills in the setting of known IV polysubstance abuse. IE is a not uncommon complication of IV drug abuse with incidence ranging from 1.7 to 6.2 cases per 100,000 person-years.¹

Several factors make IV drug users susceptible to IE. First, venipuncture using nonsterile technique can lead to bacteremia. Secondly, the caustic effect of both the drug injected as well as any adulterants (e.g., talcum powder) may cause subclinical damage to the myocardial endothelium, predisposing the surface for vegetation accumulation.²

Additionally, underlying structural lesions in the endocardium can predispose a patient to developing left-sided bacterial endocarditis. Mitral valve prolapse is implicated in a large number of such cases in the industrialized world, while rheumatic heart disease commonly affects those in developing countries.^{1,3,4}

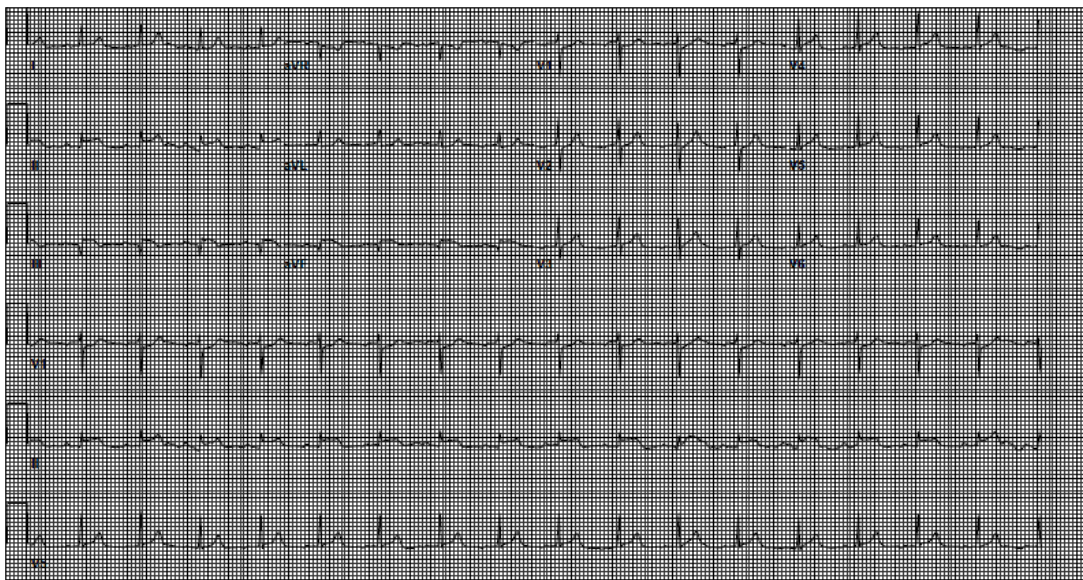


Image 1. Electrocardiogram revealing sinus tachycardia with ST segment elevation in leads II, III, aVF.

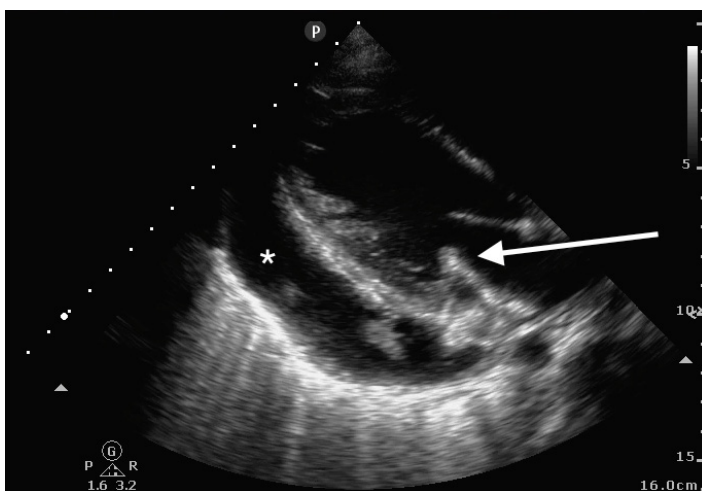


Image 2. Parasternal long-axis transthoracic view showing pericardial effusion (star) and thickened posterior mitral valve leaflet (arrow).

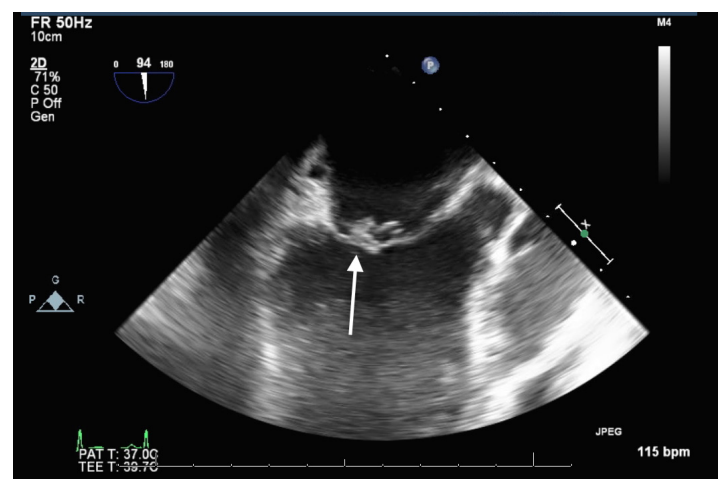


Image 3. Transesophageal echocardiography Midesophageal longitudinal image of mitral valve showing vegetation (arrow) on anterior leaflet.

IE is most often due to a single organism with *Staphylococcus aureus* being the most implicated organism. Other organisms commonly seen include streptococcal species, *Pseudomonas*, and enterococci. Polymicrobial endocarditis is also seen with IVDU and carries a high morbidity and mortality.⁵

Sequelae of left-sided endocarditis are most often due to thromboembolic events that occur when infected materials are dislodged from the endocardium and enter the systemic circulation. Septic emboli may affect virtually any organ system. Janeway lesions, splinter hemorrhages, and more serious complications such as stroke, renal and splenic infarction are well described.⁶ In our case, the patient also sustained multiple splenic infarctions diagnosed on chest computed tomography (CT) angiogram, as well as the septic coronary artery embolism causing the patient's acute MI.

There are also a number of immunologic features of IE and Osler's nodes. Immunologic factors are also implicated in the development of pericardial effusions.^{7,8}

The etiology of pericardial effusions in patients with mitral valve IE is likely multifactorial. As previously discussed, the proinflammatory state and high titers of circulating immune complexes can certainly play a role. Additionally, a periannular abscess can lead to development of an aortocavitary fistula, causing severe pericardial effusions and poor outcomes.⁸

CONCLUSION

The case presented here is unique in the fact that the mitral valve vegetation was readily identifiable on point-of-care ultrasound by emergency physicians. With the history of fevers, IVDU, splenic infarcts on CT and the vegetation seen on ultrasound, it was clear that the cause of this patient's STEMI was likely due to infective endocarditis, rather than atherosclerotic coronary artery disease. Despite the patient's poor outcome, this case demonstrates the utility of point-of-care ultrasound in the diagnosis of specific cardiac abnormalities that led to a rapid diagnosis of the patient's underlying disease, and the initiation of potentially life-saving interventions.

Video 1. Parasternal long-axis transthoracic view showing fibrinous pericardial effusion and thickened posterior mitral valve leaflet.

Address for Correspondence: Courtney B Gibson, MD, University of Alabama-Birmingham, 1720 2nd Ave South, Birmingham, AL 35294. Email: cbgibson@uabmc.edu.

Conflicts of Interest: By the CPC-EM article submission agreement, all authors are required to disclose all affiliations, funding sources and financial or management relationships that could be perceived as potential sources of bias. The authors disclosed none.

Copyright: © 2017 Thompson et al. This is an open access article distributed in accordance with the terms of the Creative Commons Attribution (CC BY 4.0) License. See: <http://creativecommons.org/licenses/by/4.0/>

REFERENCES

1. Mylonakis E, Calderwood SB. Infective endocarditis in adults. *N Engl J Med.* 2001;345(18):1318-30.
2. Colville T, Sharma V, Albouaini K. Infective endocarditis in intravenous drug users: a review article. *Postgrad Med J.* 2016;92(1084):105-11.
3. Rossi EG, Grinberg M, Mansur AJ, et al. [Mitral valve prolapse in infective endocarditis. Incidence and characteristics]. *Arq Bras Cardiol.* 1990;54(2):101-4.
4. McKinsey DS, Ratts TE, Bisno AL. Underlying cardiac lesions in adults with infective endocarditis. The changing spectrum. *Am J Med.* 1987;82(4):681-8.
5. Sousa C, Botelho C, Rodrigues D, et al. Infective endocarditis in intravenous drug abusers: an update. *Eur J Clin Microbiol Infect Dis.* 2012;31(11):2905-10.
6. Slabbekoorn M, Horlings HM, van der Meer JT, et al. Left-sided native valve *Staphylococcus aureus* endocarditis. *Neth J Med.* 2010;68(11):341-7.
7. Servy A, Valeyrie-Allanore L, Alla F, et al. Prognostic value of skin manifestations of infective endocarditis. *JAMA Dermatol.* 2014;150(5):494-500.
8. Regueiro A, Falces C, Cervera C, et al. Risk factors for pericardial effusion in native valve infective endocarditis and its influence on outcome. *Am J Cardiol.* 2013;112(10):1646-51.

Normokalemic Thyrotoxic Periodic Paralysis with Acute Resolution in the Emergency Department

James I. Gragg, DO*
Massimo Federico, MD*
Larry B. Mellick, MD, MS†

*Carl R. Darnall Army Medical Center, Department of Emergency Medicine,
Fort Hood, Texas

†Augusta University Medical Center, Department of Emergency Medicine,
Augusta, Georgia

Section Editor: Rick A. McPheeters, DO

Submission history: Submitted November 21, 2016; Revision received December 21, 2016; Accepted January 11, 2017

Electronically published March 15, 2017

Full text available through open access at http://escholarship.org/uc/uciem_cpccem

DOI: 10.5811/cpcem.2017.1.33211

Thyrotoxic periodic paralysis is a rare cause of acute paralysis in the emergency department (ED). The disorder is generally thought to be due to acute hypokalemia leading to paralysis. Treatment is generally targeted at correcting the thyrotoxic state with careful potassium repletion. We present a rare case of normokalemic, thyrotoxic periodic paralysis with acute resolution while in the ED. [Clin Pract Cases Emerg Med. 2017;1(2):129–131.]

INTRODUCTION

Thyrotoxic periodic paralysis (TPP) is a lesser known cause of intermittent, potentially curable, muscle weakness. The presentation is most commonly seen in Asian men and is usually associated with hypokalemia, which is believed to play a role in the underlying pathophysiology. The diagnosis is usually not made in the emergency department (ED). Instead, it is made after hospital admission when electrolyte abnormalities are corrected, anti-thyroid treatments are initiated and the weakness improves. Although extremely rare, fatalities have been reported. These fatalities may occur through two possible mechanisms: weakness significantly affecting the respiratory muscles leading to respiratory arrest, or severe hypokalemia leading to ventricular tachycardia or fibrillation.¹ Patients must be monitored closely for evidence of respiratory compromise or the development of life-threatening arrhythmias. Clinicians should include this disease process in their differential diagnoses along with other paralyzing disorders such as Guillain-Barré, multiple sclerosis, transverse myelitis, tick paralysis, conversion disorder or hysteria.

Treatment of TPP is not well established and must be individualized to each presentation. Even though potassium supplementation has traditionally been used to hasten recovery of weakness, caution is advised because significant rebound hyperkalemia may result. Treatment of the underlying thyroid disorder should also be addressed. In this paper we present a

case of TPP in a patient with a normal potassium level who recovered fully while in the ED.

CASE REPORT

A 26-year-old black, male, active duty soldier presented to the ED via emergency medical services for evaluation of bilateral lower extremity weakness. The patient reported that his symptoms began earlier in the morning while he was running with his unit during physical fitness training. Throughout the course of the three-mile run he described being unable to maintain pace and felt weighed down by his legs. At the completion of the training his symptoms worsened and when he attempted to get out of his car, he could not move his legs. Specifically, he reported that he could not move either of his thighs or lower extremities, but maintained motion of his feet and toes. Unable to move, bystanders assisted him to his local clinic where he was assessed and then emergently brought to the ED for continued evaluation.

Upon initial assessment the patient had a mild tachycardia but with otherwise normal vital signs. Neurological assessment demonstrated intact cranial nerves, absence of cerebellar signs, and preserved upper extremity motor and sensory exams. On examination of his lower extremities, he had 2/5 strength of hip flexion, hip extension, and knee extension. Dorsi- and plantar-flexion of the feet were intact bilaterally. Sensory exam was intact to light touch throughout his lower extremities. Gait was unable to

be assessed secondary to his inability to ambulate or stand without assistance.

His past medical history was significant only for a dermatitis that was treated with triamcinolone and over-the-counter medications. He did admit to using multiple supplements two to three times daily to boost muscle strength, but took no prescribed daily medications. He denied any other symptoms, recent illnesses, vaccinations, travel, military deployments or prior neurologic symptoms. Family history was significant for systemic lupus erythematosus and an unknown thyroid disorder in his mother, as well as an unknown thyroid disorder in his younger brother. Laboratory investigations were significant for a urine specific gravity of 1.032, a thyroid stimulating hormone level below assay detection, free thyroxine level of 18.8 ng/dL (0.7-1.9 ng/dl), creatine kinase of 501 U/L, aspartate aminotransferase of 55 U/L, alanine aminotransferase of 71 U/L, and phosphate level of 2.2 mg/dL. Importantly, his potassium level was normal at a level of 3.8 mmol/L. Electrocardiogram was significant for sinus tachycardia and left ventricular hypertrophy. After one liter of normal saline, the patient fully regained muscle strength, including the abilities to ambulate without difficulty, perform squats, single-leg stance and jumping jacks.

Given complete resolution of symptoms and abnormal thyroid function tests, the patient was discharged with a diagnosis of normokalemic, thyrotoxic periodic paralysis. In consultation, he was initiated on propranolol 10 mg three times daily and methimazole 20 mg daily. Outpatient follow-up with endocrinology was also secured, with subsequent testing demonstrating elevations in free triiodothyronine (FT3) at 12.2 pg/mL (1.7-3.7 pg/mL), thyroperoxidase antibody at 209 IU/mL (0-34 IU/mL), and percent thyroid-stimulating immunoglobulins of 294% (0-139%). A diagnosis of Graves' disease was made and at follow-up the patient continued to do well. Five months after his initial presentation, he has required only minor adjustments in medication, without any repeated neurologic deficits.

DISCUSSION

This case represents a unique presentation of TTP, as well as a unique resolution of symptoms while in the ED. The disease process has been well described in the Asian population, where among patients with thyrotoxicosis there is an incidence of roughly 2%. TTP is now more commonly recognized in non-Asian populations; however, the incidence is still only 0.1% of patients with thyrotoxicosis.² Heavy carbohydrate loads or extreme exercise are thought to play a role in the thyrotoxic-primed pathophysiology of the disorder. With hyperthyroidism the Na⁺/K⁺ ATPase is upregulated in skeletal muscle, which serves as a large potassium reservoir in the body. In the setting of a large carbohydrate load the resulting hyperinsulinemia further activates the Na⁺/K⁺ ATPase, thereby driving potassium into the cell. Similarly,

with exercise, endogenous catecholamines and adrenergic stimulation activate the Na⁺/K⁺ ATPase. Both scenarios lead to a sequestration of potassium in skeletal muscle that results in the relative hypokalemia and paralysis observed in these patients.³ Our patient, however, had a potassium level within the normal range, thus calling into question the requirement of hypokalemia in making the diagnosis. However, significant shifts of potassium most likely still take place at the muscle cellular level. And, another case report demonstrated that normokalemia can be present on admission. However, in that case potassium levels continued to fall during admission.⁴ Conversely, our patient's potassium remained normal on repeat laboratory tests. Normokalemia, therefore, should not be used as a single laboratory evaluation to rule out TTP.

The treatment of TTP is not well defined. Traditionally, potassium repletion has been the mainstay of treatment. Studies suggest that restoration of potassium levels leads to resolution of paralysis, with potassium decreasing the time to resolution from 13 hours to six hours.⁵ However, the physiology of TTP suggests that patients are not truly deficient in potassium stores and exogenous potassium repletion can cause rebound hyperkalemia. Clinicians choosing to give potassium should be prepared to monitor for and treat hyperkalemia. However, since the potassium level may actually continue to fall despite potassium supplementation, careful monitoring is in order as heart block and cardiogenic shock from hypokalemia may result.⁶ The typical course of the disease process is still not well defined and continued research is needed. For now, it is best to closely monitor these patients and frequently repeat laboratory tests to determine electrolyte trends. Finally, in conjunction with hypokalemia, a concurrent hypomagnesemia or hypophosphatemia may also be present.⁷

Treatment should also address the underlying thyrotoxic state. As in thyroid storm, given its non-selective pharmacology, propranolol is the preferred beta-blocker. Blockade of the adrenergic hyperstimulation halts the Na⁺/K⁺ ATPase, preventing further potassium sequestration. Propranolol alone has been shown to effectively reverse both the paralysis and electrolyte abnormalities in TTP.⁸ Given the inherent risks of large-dose potassium repletion in the absence of severe hypokalemia, it may be reasonable to withhold supplementation while treating with propranolol. Evaluation of the etiology of the thyrotoxic state should also be undertaken with treatments targeting the underlying cause. Graves' disease remains the most common precipitating cause, as was seen in our patient.

CONCLUSION

Thyrotoxic periodic paralysis is a lesser known disease that should be considered in any patient with an unexplained, objective weakness. While hypokalemia is commonly reported, it should be recognized that normokalemia may also occur. Treatment is aimed at correcting the underlying thyrotoxic state and low serum levels of potassium. However, potassium repletion

must be undertaken with extreme caution to avoid rebound hyperkalemia and arrhythmia. Finally, even though the condition is most commonly seen in Asian men, TTP may also be found in non-Asian populations as occurred with our patient.

Address for Correspondence: James Gragg, DO, Carl R. Darnall Army Medical Center, 36065 Santa Fe Ave, Fort Hood, TX 76544. Email: gragg.james@gmail.com.

Conflicts of Interest: By the *CPC-EM* article submission agreement, all authors are required to disclose all affiliations, funding sources and financial or management relationships that could be perceived as potential sources of bias. Drs. Gragg and Federico are active duty United States Army soldiers, however, any opinions, findings, conclusions, or recommendations expressed in this article are those of the authors and do not necessarily reflect the views of the United States Army, Department of Defense, or the US government. The authors have no financial conflicts of interest to disclose.

Copyright: © 2017 Gragg et al. This is an open access article distributed in accordance with the terms of the Creative Commons Attribution ([CC BY 4.0](http://creativecommons.org/licenses/by/4.0/)) License. See: <http://creativecommons.org/licenses/by/4.0/>

REFERENCES

1. Wu C, Wu, Lin J, et al. Thyrotoxic periodic paralysis complicated by acute hypercapnic respiratory failure and ventricular tachycardia. *Thyroid*. 2008;18(12):1321–4.
2. Ober KP. Thyrotoxic periodic paralysis in the United States. Report of 7 cases and review of the literature. *Medicine*. 1992;71:109–20.
3. Lin S, Huang C. Mechanism of thyrotoxic periodic paralysis. *J Am Soc Nephrol*. 2012;23(6):985–8.
4. Chakrabarti S. Normokalemic thyrotoxic periodic paralysis with preserved reflexes- a unique case report. *J Clin Diagn Res*. 2015;9(2):OD05-6.
5. Lu K, Hsu Y, Chiu J, et al. Effects of potassium supplementation on the recovery of thyrotoxic periodic paralysis. *Am J Emerg Med*. 2004;22(7):544–7.
6. Wang H, Tsai S, Pan M, et al. Complete heart block during potassium therapy in thyrotoxic periodic paralysis. *J Emerg Med*. 2013;44(1):61–4.
7. Kung AWC. Thyrotoxic periodic paralysis: a diagnostic challenge. *J Clin Endocrinol Metabol*. 2006;91(7):2490–5.
8. Lin SH, Lin YF. Propranolol rapidly reverses paralysis, hypokalemia, and hypophosphatemia in thyrotoxic periodic paralysis. *Am J Kidney Dis*. 2001;37(3):620–3.

Indicators of Subarachnoid Hemorrhage as a Cause of Sudden Cardiac Arrest

Joseph Zachariah, DO*

Jessica A. Stanich, MD†

Sherri A. Braksick, MD*

Eelco FM. Wijdicks, MD, PhD*

Ronna L. Campbell, MD, PhD†

Malcolm R. Bell, MD‡

Roger White, MD§

*Mayo Clinic, Department of Neurology, Rochester, Minnesota

†Mayo Clinic, Department of Emergency Medicine, Rochester, Minnesota

‡Mayo Clinic, Department of Internal Medicine, Division of Cardiovascular Diseases, Rochester, Minnesota

§Mayo Clinic, Departments of Anesthesiology and Internal Medicine, Division of Cardiovascular Diseases, Rochester, Minnesota

Section Editor: Rick A. McPheeters, DO

Submission history: Submitted November 3, 2016; Revision received December 27, 2016; Accepted January 11, 2017

Electronically published March 16, 2016

Full text available through open access at http://escholarship.org/uc/uciem_cpccm

DOI: 10.5811/cpccm.2017.1.33061

Subarachnoid hemorrhage (SAH) may present with cardiac arrest (SAH-CA). We report a case of SAH-CA to assist providers in distinguishing SAH as an etiology of cardiac arrest despite electrocardiogram findings that may be suggestive of a cardiac etiology. SAH-CA is associated with high rates of return of spontaneous circulation, but overall poor outcome. An initially non-shockable cardiac rhythm and the absence of brain stem reflexes are important clues in identifying SAH-CA. [Clin Pract Cases Emerg Med. 2017;1(2):132–135.]

INTRODUCTION

Subarachnoid hemorrhage (SAH) as a cause of out-of-hospital cardiac arrest (OHCA) is rare.¹⁻³ Most patients will present with pulseless electrical activity or asystole. SAH-CA is not typically due to intrinsic cardiac disease although numerous changes can be seen on electrocardiography.^{4,5} We report a case of SAH-CA to review the pathophysiology and remind clinicians to consider intracranial hemorrhage as a cause of death in any patient presenting with a non-shockable rhythm and lack of brainstem reflexes.

CASE REPORT

A 55-year-old man with no cardiac history collapsed at work. Bystander cardiopulmonary resuscitation (CPR) was initiated promptly, and initial rhythm on emergency medical services (EMS) personnel arrival was asystole. Return of spontaneous circulation (ROSC) was achieved within four minutes of CPR and epinephrine administration. Endotracheal intubation was performed without sedative or paralytic agents and the patient was transported to the emergency department (ED). A prehospitalization 12-lead electrocardiogram (ECG) demonstrated diffuse anterolateral ST segment depression and aVR ST segment elevation (Image 1a). Upon arrival to

the ED, the patient was found to be pulseless with electrical activity and required an additional seven minutes of CPR and multiple doses of epinephrine before ROSC was achieved. Point-of-care ultrasound demonstrated depressed left ventricular function without signs of right ventricular strain, aortic enlargement, or apical ballooning syndrome. The patient had fixed and dilated pupils, no spontaneous respiratory efforts, no response to painful stimuli, and required continuous epinephrine to maintain his blood pressure.

Based on the prehospital ECG, a posterior ST segment elevation myocardial infarction was considered as a cause of his arrest, although a repeat ECG demonstrated substantial resolution of the prehospital electrocardiographic abnormalities (Image 1b).

The case was discussed with the critical care cardiologist, and the cardiac catheterization laboratory was activated. The absence of an initial shockable rhythm raised diagnostic uncertainty and a computed tomography (CT) of the head was obtained prior to catheterization. CT of the head demonstrated diffuse SAH with intraventricular extension and mild hydrocephalus. Follow-up CT angiogram revealed a small anterior communicating artery aneurysm. The plan for coronary angiography was cancelled. Soon after admission to

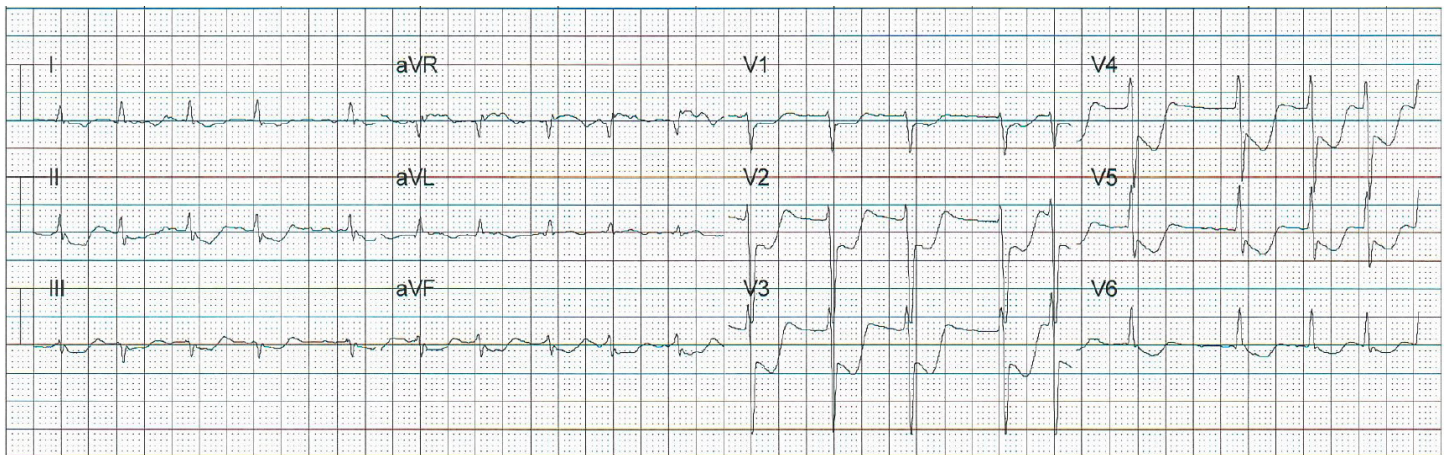


Image 1a. Post-resuscitation electrocardiogram on scene demonstrating atrial fibrillation with rapid ventricular rate of 114 bpm and diffuse ST depressions and ST elevation in aVR, in patient with cardiac arrest secondary to subarachnoid hemorrhage. *bpm*, beats per minute

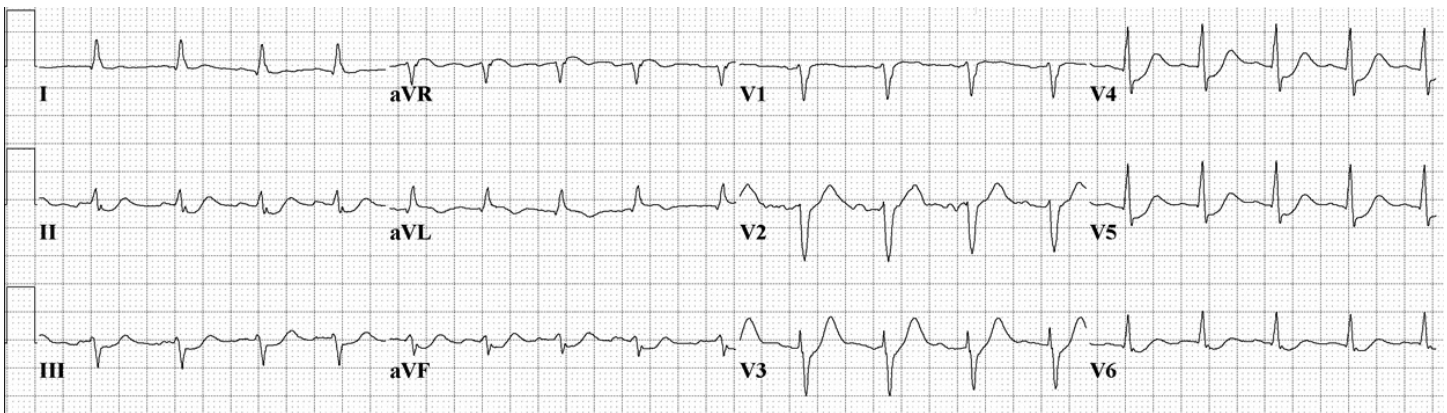


Image 1b. Electrocardiogram on admission showing normal sinus rhythm and substantial improvement in the prehospital electrocardiographic abnormalities.

the neurosciences intensive care unit the patient was declared brain dead and became an organ donor.

DISCUSSION

It is estimated that only 2-8%¹⁻³ of OHCA are caused by SAH. More than half of SAH-CA patients collapse without preceding headache and 12% may never reach medical attention.⁶⁻⁹ Non-cardiac causes of OHCA more often present with a non-shockable rhythm, like pulseless electrical activity (PEA) and asystole. Almost all patients with SAH have been shown to have ECG changes, and nearly two-thirds had changes suggestive of myocardial infarction or ischemia.¹⁰⁻¹⁴ ECG changes in the setting of SAH can include sinus tachycardia, atrial fibrillation, ST segment elevation or depression, QT prolongation, and rarely torsades de pointe, ventricular tachycardia and ventricular fibrillation (VF).^{10,11} VF after an initially non-shockable rhythm is likely secondary to CPR and epinephrine administration,¹⁴ VF and torsades de pointe in patients with OHCA secondary to SAH are uncommon.^{4,10,11,14}

Anoxic ischemic brain injury from primary cardiac causes of sudden cardiac arrest preferentially affect the cortex and diencephalon and spare the brainstem.¹⁵⁻¹⁷ Absent pupillary, corneal, oculocephalic responses, spontaneous breathing or a Full Outline of UnResponsiveness (FOUR) score of 0 is highly unusual after CPR and ROSC unless associated with extremely prolonged resuscitation or exsanguination.^{18,19} A FOUR score is a 20-point clinical grading scale (with scores of 0 to 16) designed to assess patients with an impaired level of consciousness.¹⁹ The FOUR score assesses eye responses, motor responses, brainstem reflexes, and breathing pattern. It can be used in place of the Glasgow Coma Scale in intubated patients with traumatic or nontraumatic brain injuries and has been validated in the ED.²⁰ The FOUR score would test several brainstem reflexes and breathing drive not identified with a GCS of 3.

Why does massive SAH lead to cardiac arrest? Why do patients with SAH-CA present with asystole or PEA? The cause of SAH-CA is not due to intrinsic cardiac disease, as

coronary angiography and autopsy data have frequently shown patients have normal coronary arteries.^{10,11} In contrast, focal ischemia causes regional electrophysiological abnormalities and triggered automaticity, resulting in VF.¹⁷ The proposed pathophysiologic mechanism for cardiac arrest secondary to SAH is summarized in Image 2. Mechanisms for SAH-CA include (1) massive catecholamine release and sympathetic surge leading to cardiac stunning, or (2) sudden massive intracranial pressure (ICP) increase leading to brainstem dysfunction with respiratory arrest and hypoxia.^{20,21} The latter theory is supported in that the frequency of stress cardiomyopathy has been shown to be comparable among SAH patients regardless of cardiac arrest.³

A massive ICP surge results in a loss of brainstem reflexes leading to respiratory arrest and anoxia. Severe hypoxia triggers a cascade of biochemical changes, eventually triggering an endogenous release of adenosine acting on the

heart to decrease contractility, atrioventricular conduction and pacemaker automaticity.¹² Profound bradycardia and cardiac arrest can also occur as a result of an intense Cushing reflex.

A non-shockable rhythm in the setting of sudden cardiac arrest should raise suspicion for a primary non-cardiac etiology despite ECG changes suggestive of myocardial infarction or ischemia. The absence of brainstem reflexes should heighten suspicion for an intracranial process and an emergent head CT should be performed, given that a substantial proportion of cardiac arrest patients with non-shockable rhythms who achieve ROSC are patients with SAH.^{3,5} We propose that “hemorrhage” be added to the “H’s and T’s” differential for PEA or asystolic arrests originally described in the resuscitation guidelines.¹⁷ Remember that cardiorespiratory support should be maintained for brain death determination and possible organ donation, as SAH-CA is associated with poor outcomes.^{1,21-23}

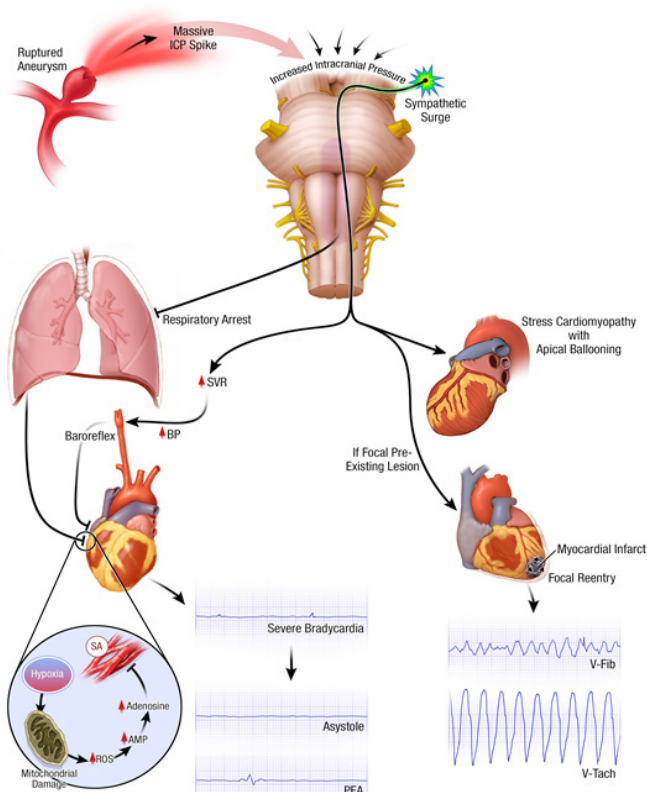


Image 2. Pathophysiologic mechanism of cardiac arrest secondary to subarachnoid hemorrhage. Massive catecholamine release and sympathetic surge may stun cardiac tissue and/or cause an intense Cushing reflex; hypertension and bradycardia. A sudden massive increase in intracranial pressure may cause brainstem dysfunction and respiratory arrest from hypoxia. Severe hypoxia may trigger a cascade of biochemical changes, ultimately triggering endogenous release of adenosine, which causes profound bradycardia. ICP, Intracranial pressure; ROS, reactive oxygen species; AMP, activated protein kinase; PEA, pulseless electrical activity; BP, blood pressure; SA, striated muscle

Address for Correspondence: Jessica Stanich, MD, Mayo Clinic, 200 First St. SW, Rochester, MN 55905. Email: Stanich.Jessica@mayo.edu.

Conflicts of Interest: By the CPC-EM article submission agreement, all authors are required to disclose all affiliations, funding sources and financial or management relationships that could be perceived as potential sources of bias. The authors disclosed none.

Copyright: © 2017 Zachariah et al. This is an open access article distributed in accordance with the terms of the Creative Commons Attribution (CC BY 4.0) License. See: <http://creativecommons.org/licenses/by/4.0/>

REFERENCES

1. Arnaout M, Mongardon N, Deye N, et al. Out-of-hospital cardiac arrest from brain cause: epidemiology, clinical features, and outcome in a multicenter cohort*. *Crit Care Med.* 2015;43(2):453-60.
2. Mitsuma W, Ito M, Kodama M, et al. Clinical and cardiac features of patients with subarachnoid haemorrhage presenting with out-of-hospital cardiac arrest. *Resuscitation.* 2011;82(10):1294-7.
3. Toussaint LG 3rd, Friedman JA, Wijdicks EF, et al. Survival of cardiac arrest after aneurysmal subarachnoid hemorrhage. *Neurosurgery.* 2005;57(1):25-31; discussion 25-31.
4. Davis TP, Alexander J, Lesch M. Electrocardiographic changes associated with acute cerebrovascular disease: a clinical review. *Prog Cardiovasc Dis.* 1993;36(3):245-60.
5. Di Pasquale G, Pinelli G, Andreoli A, et al. Holter detection of cardiac arrhythmias in intracranial subarachnoid hemorrhage. *Am J Cardiol.* 1987;59(6):596-600.
6. Inamasu J, Miyatake S, Tomioka H, et al. Subarachnoid haemorrhage as a cause of out-of-hospital cardiac arrest: a prospective computed

- tomography study. *Resuscitation*. 2009;80(9):977-80.
7. Shin J, Kim K, Lim YS, et al. Incidence and clinical features of intracranial hemorrhage causing out-of-hospital cardiac arrest: a multicenter retrospective study. *Am J Emerg Med*. 2016;34(12):2326-30.
 8. Kırkcıyan I, Meron G, Sterz F, et al. Spontaneous subarachnoid haemorrhage as a cause of out-of-hospital cardiac arrest. *Resuscitation*. 2001;51(1):27-32.9.
 9. Schievink WI, Wijdicks EF, Parisi JE, et al. Sudden death from aneurysmal subarachnoid hemorrhage. *Neurology*. 1995;45(5):871-4.
 10. Brouwers PJ, Wijdicks EF, Hasan D, et al. Serial electrocardiographic recording in aneurysmal subarachnoid hemorrhage. *Stroke*. 1989;20(9):1162-7.
 11. Randell T, Tanskanen P, Scheinin M, et al. QT dispersion after subarachnoid hemorrhage. *J Neurosurg Anesthesiol*. 1999;11(3):163-6.
 12. Park I, Kim YJ, Ahn S, et al. Subarachnoid hemorrhage mimicking ST-segment elevation myocardial infarction after return of spontaneous circulation. *Clin Exp Emerg Med*. 2015;2(4):260-3.
 13. Kuroiwa T, Morita H, Tanabe H, et al. Significance of ST segment elevation in electrocardiograms in patients with ruptured cerebral aneurysms. *Acta Neurochir (Wien)*. 1995;133(3-4):141-6.
 14. Straznitskas AD, Wong S, Kupchik N, et al. Secondary ventricular fibrillation or pulseless ventricular tachycardia during cardiac arrest and epinephrine dosing. *Am J Crit Care*. 2015;24(3):e22-7.
 15. Ornato JCCRIRCEC, Principles and Practice. Humana Press; 2005. Pg 529.
 16. Schmidt JM, Crimmins M, Lantigua H, et al. Prolonged elevated heart rate is a risk factor for adverse cardiac events and poor outcome after subarachnoid hemorrhage. *Neurocrit Care*. 2014;20(3):390-8.
 17. Luqman N, Sung RJ, Wang CL, et al. Myocardial ischemia and ventricular fibrillation: pathophysiology and clinical implications. *Int J Cardiol*. 2007;119(3):283-90.
 18. Wijdicks EF, Bamlet WR, Maramattom BV, et al. Validation of a new coma scale: The FOUR score. *Ann Neurol*. 2005;58(4):585-93.
 19. Kornbluth J and Bhardwaj A. Evaluation of coma: a critical appraisal of popular scoring systems. *Neurocrit Care*. 2011;14(1):134-43.
 20. Stead LG, Wijdicks EF, Bhagra A, et al. Validation of a new coma scale, the FOUR score, in the emergency department. *Neurocrit Care*. 2009;10(1):50-4.
 21. Khanal K, Bhandari SS, Shrestha N, et al. Comparison of outcome predictions by the Glasgow coma scale and the Full Outline of UnResponsiveness score in the neurological and neurosurgical patients in the Intensive Care Unit. *IJCCM*. 2016;20(8):473-6.
 22. Fukuda T, Ohashi-Fukuda N, Kondo Y, et al. Epidemiology, risk factors, and outcomes of out-of-hospital cardiac arrest caused by stroke: a population-based study. *Medicine (Baltimore)*. 2016; 95(14):e3107.
 23. Inamasu J, Saito R, Nakamura Y, et al. Survival of a subarachnoid hemorrhage patient who presented with prehospital cardiopulmonary arrest: case report and review of the literature. *Resuscitation*. 2001;51(2):207-11.

No Room for Error: Empiric Treatment for Fulminant Pneumonia

Matthew E. Prekker, MD, MPH^{*†‡} *Hennepin County Medical Center, Department of Emergency Medicine, Minneapolis, Minnesota
Stephen W. Smith, MD^{*‡}

†Hennepin County Medical Center, Department of Medicine, Division of Pulmonary and Critical Care Medicine, Minneapolis, Minnesota

‡University of Minnesota Medical School, Minneapolis, Minnesota

Section Editor: Rick McPheeters, DO

Submission history: Submitted November 21, 2016; Revision received December 29, 2016; Accepted January 11, 2017

Electronically published March 13, 2017

Full text available through open access at http://escholarship.org/uc/uciem_cp cem

DOI: 10.5811/cpcem.2017.1.33213

Early antibiotic administration is critical in cases of sepsis and severe community-acquired pneumonia, which is frequently due to *Streptococcus pneumoniae*, *Staphylococcus aureus*, *Legionella* species, or influenza. We describe the case of a 29-year-old previously healthy man who presented to an urban emergency department (ED) in the North Central U.S. with fever, hip pain, severe hypoxemia, and diffuse pulmonary infiltrates. He was intubated and received piperacillin/tazobactam, levofloxacin, vancomycin, and oseltamivir; given his fulminant presentation and predicted high mortality, doxycycline, methylprednisolone, and amphotericin B were also administered empirically in the ED. A respiratory culture eventually grew *Blastomyces dermatitidis*, and the patient survived. Severe acute respiratory distress syndrome due to fulminant pneumonitis carries a high mortality. Faced with this scenario and no room for error, it is important that the emergency physician cover for all possible pathogens, including zoonotic bacteria and endemic fungi. [Clin Pract Cases Emerg Med. 2017;1(2):136–139.]

INTRODUCTION

Severe community-acquired pneumonia (CAP) is a frequent cause of sepsis and the acute respiratory distress syndrome (ARDS).¹ However, a fulminant presentation of these syndromes in an otherwise healthy patient in the emergency department (ED) is uncommon.² Severe CAP is usually due to one of a familiar list of bacterial and viral pathogens (*Streptococcus pneumoniae*, *Staphylococcus aureus*, *Legionella* sp., and influenza A&B viruses), and effective antimicrobial therapy in the first hour after presentation to the ED improves the likelihood of a good outcome.^{3,4} Furthermore, seasoned emergency physicians (EP) understand the importance of matching the intensity and timeliness of their interventions (including empiric antimicrobial therapy) to the severity and tempo of the patient's illness; in general, a fulminant presentation of sepsis and pneumonia in a young adult demands rapid, definitive intervention to preserve life. Surprisingly, existing literature and guidelines give little guidance to the EP regarding an approach to empiric antimicrobial therapy for fulminant, immediately life-threatening pneumonia.

CASE REPORT

A 29-year-old previously healthy male presented with high fever, tachycardia, hypoxia and bilateral, dense pulmonary infiltrates. The patient had no prior medical history. He was from a farming community in rural Minnesota, and had been outside working in the month of May. He had been feeling well until five days prior when he developed severe right-sided hip and back pain and sought medical attention, for which he received an unspecified spinal "injection." Two days later (three days prior to ED presentation) he developed a cough and was prescribed azithromycin. During the following two days his cough became worse and, on the morning of presentation, he awoke with dyspnea. He presented to a clinic and was found to be hypoxic and febrile, and was sent to the local community ED. On arrival, the patient was in severe distress, with a temperature of 40 degrees C, tachycardia, and an oxygen saturation of 45% on room air. He was intubated and placed on mechanical ventilation. A chest radiograph showed diffuse pulmonary infiltrates, and he was administered 2 grams (g) of ceftriaxone and prepared for transfer to a tertiary care

center. Prior to departure, on recommendation of the accepting facility, piperacillin/tazobactam 4.5 g, vancomycin 2 g (approximately 22 milligrams per kilogram [mg/kg]), as well as methylprednisolone 125 mg were given intravenously.

On arrival at the tertiary care center, the patient was a well-developed, well-nourished young male who was intubated, sedated, and pharmacologically paralyzed. Pulse was 160 beats per minute, blood pressure 200/100 mm Hg with bounding pulses, temperature 39 degrees C, and an oxygen saturation of 88% on 100% inspired oxygen fraction (F_{iO_2}). Breath sounds were equal and very coarse. A chest radiograph showed bilateral pulmonary infiltrates (Image 1), and an electrocardiogram showed only sinus tachycardia.

Point-of-care cardiac ultrasound showed hyperdynamic function and an ultrasonic cardiac output monitor (USCOM®) calculated a cardiac output of 19 liters/minute, with stroke volume of 120 milliliters and systemic vascular resistance of 550 dyn·s/cm⁵. Using point-of-care ultrasonography, we found that the inferior vena cava was neither distended nor collapsed and the painful hip showed no excess joint fluid.

Electrolytes were normal. Hemoglobin was 14.2 g/dL. Leukocyte count was 46,300 cells/mm³ with 68% neutrophils and 23% band forms. Arterial blood gas returned with a pH of 7.21, pCO₂ of 48 mm Hg, pO₂ of 74 mm Hg, and bicarbonate of 18 mEq/L. The lactate was 3.2 mEq/L, albumin 2.6 g/dL. The international normalized ratio was 1.6. Human immunodeficiency virus antibody was nonreactive. A sputum

sample obtained by tracheal aspirate showed a negative gram stain, and sputum and blood cultures were sent for analysis.

Several liters of normal saline were administered in bolus fashion without change in vital signs. A positive end-expiratory pressure (PEEP) of 10 cm H₂O was administered, with improvement in pulse oximetry to 91%. With the assessment that this patient required immediate, effective empirical antimicrobial therapy for a fulminant pneumonia of unknown etiology, the patient received levofloxacin 750 mg IV, oseltamivir 150 mg enterally, doxycycline 100 mg IV, and liposomal amphotericin B 300 mg IV (approximately 3 mg/kg) in the ED.

A computed tomography of the chest and abdomen was done to better define the pattern of pneumonitis and to further investigate the severe back and hip pain. It only showed pathology in the chest (Image 2).

The patient was admitted to the medical intensive care unit (ICU). Broad spectrum antimicrobials were continued. The next day, broad-based budding yeast were seen on a silver stain of bronchoalveolar lavage (BAL) fluid, and subsequently fungal cultures of both sputum and BAL samples grew *Blastomyces dermatitidis*. Liposomal amphotericin B was continued and all other antimicrobials were discontinued. After one week of amphotericin and supportive care, the patient began to recover. Eight months later, he was being treated with itraconazole (planned 12-month course); he had a normal chest radiograph, but still had some airflow limitation and dyspnea on exertion.

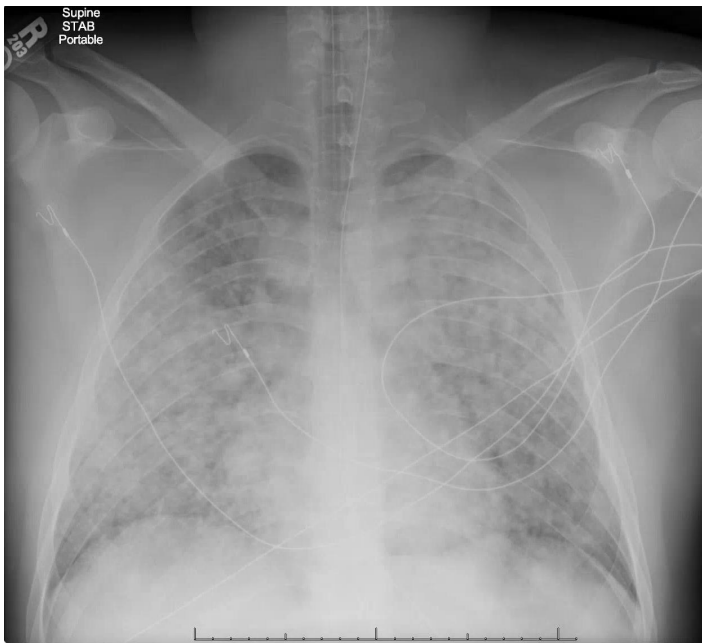


Image 1. Anteroposterior chest radiograph taken in the emergency department showing bilateral, diffuse pulmonary opacities consistent with the acute respiratory distress syndrome.

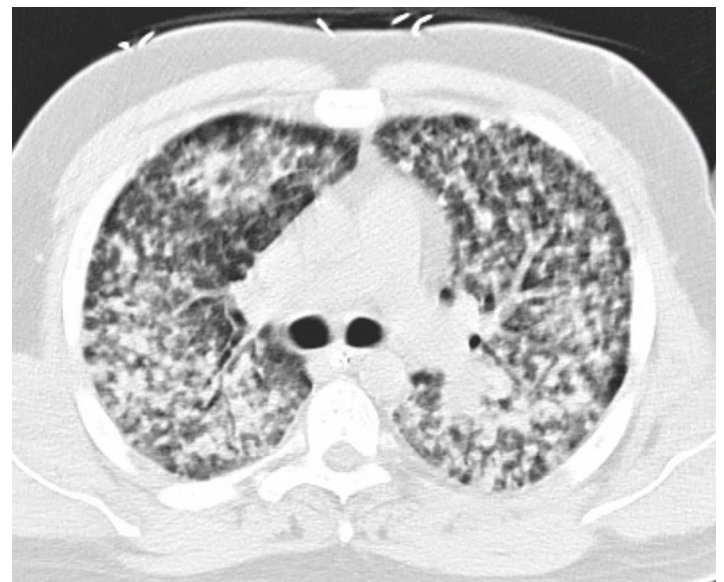


Image 2. Axial image at the level of the mainstem bronchi taken from a computed tomography of the chest obtained in the emergency department, showing diffuse, nodular opacities in both lungs.

DISCUSSION

This case is, to our knowledge, the first report of ARDS due to fulminant pulmonary blastomycosis in the emergency medicine literature. While this entity is uncommon, it has been described in ICU patients. Of note, an experienced EP, faced with a young patient with undifferentiated, near-fatal CAP, recognized the importance of definitive antimicrobial therapy and prescribed broad spectrum antibiotics including doxycycline (for zoonotic bacterial pathogens), as well as empiric antiviral and antifungal therapy. This patient's blastomycosis was covered empirically (and as it turns out, definitively) with amphotericin from the time of his arrival in the ED. This report addresses one potential approach to fulminant pneumonitis from an unknown pathogen, which represents an important gap in existing guidelines on early antimicrobial therapy.

There is ample evidence that a delay in definitive antibiotic therapy negatively affects outcomes in severe bacterial infection. This delay is most often due to unrecognized infection, failure to initiate antibiotic therapy in the ED, or failure to anticipate antimicrobial resistance. In fact, among hypotensive ICU patients with septic shock (nearly 40% of whom had pneumonia), each hour delay in effective antimicrobial therapy after the first hour was associated with an average decrease in survival of 8%.³ The Surviving Sepsis Campaign, while not addressing fulminant pneumonia specifically, does recommend that empiric antimicrobial therapy include one or more drugs that have activity and adequate tissue penetration against "all likely pathogens," including viruses and fungi.⁵ Professional society guidelines on the management of critically ill patients with severe CAP highlight the need to cover empirically for resistant organisms including *Pseudomonas aeruginosa* and community-acquired methicillin-resistant *Staphylococcus aureus* (CA-MRSA).⁶ In our experience, patients with septic shock rarely receive antifungal or antiviral therapy. Besides knowledge of non-bacterial pathogens endemic to a certain geographic area (e.g. *Coccidioides* spp. and hantavirus in the southwestern U.S.), these guidelines are of limited utility to an EP caring for an intubated patient because treatment is initiated before a detailed travel and exposure history can be obtained.

A diverse list of pathogens can cause fulminant pneumonia and ARDS in an immunocompetent host. In fact, there is evidence that multilobar lung involvement is independently associated with a twofold increased likelihood of treatment failure in CAP.^{7,8} Usual pathogens include standard or atypical bacteria, such as *Streptococcus pneumoniae*, *Haemophilus influenzae*, *Staphylococcus aureus*, Group A Streptococcus, *Legionella* spp., or aerobic gram-negative bacteria, including *Pseudomonas aeruginosa*. Massive aspiration can lead to a polymicrobial pneumonia that often includes anaerobes, or in the case of freshwater aspiration, infection with *Aeromonas hydrophila*.⁹ In our

case, antibacterial coverage included piperacillin-tazobactam, levofloxacin, and vancomycin. Endemic fungal infections, such as blastomycosis, histoplasmosis, or coccidioidomycosis, have also been associated with fulminant pneumonia; thus, we gave amphotericin. One must also consider viruses such as influenza A and B (for which we gave oseltamivir), but also varicella zoster virus¹⁰ or herpes simplex,¹¹ and thus it may be prudent to administer acyclovir in the appropriate setting. Respiratory viruses that are prevalent, detectable on polymerase chain reaction-based assays but without specific treatment include respiratory syncytial virus, parainfluenza virus, rhinovirus, adenovirus, human metapneumovirus, multiple coronaviruses (the etiologic agents of severe acute respiratory syndrome [SARS] and of Middle East respiratory syndrome [MERS]), and hantaviruses (responsible for the hantavirus pulmonary syndrome [HPS]). Fulminant pneumonia can also be caused by rare zoonotic bacteria often recognized in the U.S. for their potential as biological weapons, namely *Bacillus anthracis* (anthrax), *Francisella tularensis* (tularemia), and *Yersinia pestis* (pneumonic plague), for which we gave doxycycline. Lastly, fulminant pneumonitis can be due to non-infectious vasculitic or idiopathic disorders, which are typically corticosteroid-responsive, and methylprednisolone was given in this case.

Blastomycosis can be asymptomatic or mimic bacterial pneumonia following the inhalation of aerosolized spores from the *Blastomyces dermatitidis* mold living in moist soil. This endemic fungus is found most commonly surrounding the Great Lakes and the St. Lawrence, Ohio, and Mississippi Rivers.¹² In states where blastomycosis is a reportable disease (Arkansas, Louisiana, Michigan, Minnesota, and Wisconsin), it is relatively rare; annual incidence rates vary from 1-2 cases per 100,000 population to as high as 10-40 cases per 100,000 population in several northern Wisconsin counties.^{13,14} Fulminant pneumonia leading to ARDS and respiratory failure occurs in a minority of cases, with mortality of 50-89%. (Contemporary mortality may be lower in the era of extracorporeal membrane oxygenation support).^{15,16} Extrapulmonary blastomycosis can occur by hematogenous spread of yeast to the skin, bones, and joints. Delay in diagnosis is relatively common; clinicians even in endemic areas often fail to consider blastomycosis in the initial differential for severe CAP. The diagnosis is made by isolating the organism in culture. Rapid evidence of blastomycosis is often obtained by visualizing the broad-based budding yeast forms in a sputum smear or potassium hydroxide prep. In severe infections, *Blastomyces* can cross-react with the urine *Histoplasma* antigen assay yielding a positive result before the final culture is available, as occurred in our case. Treatment of severe pulmonary or disseminated blastomycosis is with liposomal amphotericin B for 1-2 weeks until clinical improvement is noted, then daily itraconazole for at least one year.¹⁷

CONCLUSION

Truly fulminant cases of community-acquired pneumonia in ED patients are rare but life-threatening, as in this case of acute pulmonary blastomycosis presenting as ARDS. In such patients with no room for error (where a delay in definitive antimicrobial therapy may be disastrous), consider extending empiric therapy to cover endemic fungi (amphotericin B) and zoonotic infections such as pneumonic plague or tularemia (doxycycline or an aminoglycoside).

Address for Correspondence: Matthew E. Prekker, MD, MPH, Hennepin County Medical Center, 701 Park Avenue, Mailcode G5, Minneapolis, MN 55415. Email: Matthew.Prekker@hcmcd.org.

Conflicts of Interest: By the CPC-EM article submission agreement, all authors are required to disclose all affiliations, funding sources and financial or management relationships that could be perceived as potential sources of bias. The authors disclosed none.

Copyright: © 2017 Prekker et al. This is an open access article distributed in accordance with the terms of the Creative Commons Attribution (CC BY 4.0) License. See: <http://creativecommons.org/licenses/by/4.0/>

REFERENCES

- Bellani G, Laffey JG, Pham T, et al. Epidemiology, patterns of care, and mortality for patients with acute respiratory distress syndrome in intensive care units in 50 countries. *JAMA*. 2016;315(8):788-800.
- Fuller BM, Mohr NM, Miller CN, et al. Mechanical ventilation and ARDS in the ED: A multicenter, observational, prospective, cross-sectional study. *Chest*. 2015;148(2):365-74.
- Kumar A, Roberts D, Wood KE, et al. Duration of hypotension before initiation of effective antimicrobial therapy is the critical determinant of survival in human septic shock. *Crit Care Med*. 2006;34(6):1589-96.
- Jain S, Self WH, Wunderink RG, et al. Community-acquired pneumonia requiring hospitalization among U.S. adults. *N Engl J Med*. 2015;373(5):415-27.
- Dellinger RP, Levy MM, Rhodes A, et al. Surviving sepsis campaign: international guidelines for management of severe sepsis and septic shock: 2012. *Crit Care Med*. 2013;41(2):580-637.
- Mandell LA, Wunderink RG, Anzueto A, et al. Infectious Diseases Society of America/American Thoracic Society consensus guidelines on the management of community-acquired pneumonia in adults. *Clin Infect Dis*. 2007;44 Suppl 2:S27-72.
- Menéndez R, Torres A, Zalacaín R, et al. Risk factors of treatment failure in community acquired pneumonia: implications for disease outcome. *Thorax*. 2004;59(11):960-5.
- Rosón B, Carratalà J, Fernández-Sabé N, et al. Causes and factors associated with early failure in hospitalized patients with community-acquired pneumonia. *Arch Intern Med*. 2004;164(5):502-8.
- Gonçalves JR, Brum G, Fernandes A, et al. *Aeromonas hydrophila* fulminant pneumonia in a fit young man. *Thorax*. 1992;47(6):482-3.
- Beby-Defaux A, Brabant S, Chatellier D, et al. Disseminated varicella with multiorgan failure in an immunocompetent adult. *J Med Virol*. 2009;81(4):747-9.
- Hunt DP, Muse VV, Pitman MB. Case Records of the Massachusetts General Hospital. Case 12-2013. An 18-year-old woman with pulmonary infiltrates and respiratory failure. *N Engl J Med*. 2013;368(16):1537-45.
- Davies SF, Sarosi GA. Epidemiological and clinical features of pulmonary blastomycosis. *Semin Respir Infect*. 1997;12(3):206-18.
- Benedict K, Roy M, Chiller TM, et al. Epidemiologic and ecologic features of blastomycosis: a review. *Curr Fungal Infect Rep*. 2012;6(4):327-35.
- Blastomycosis Statistics. Centers for Disease Prevention and Control. Available at: <https://www.cdc.gov/fungal/diseases/blastomycosis/statistics.html>. Accessed Dec 29, 2016.
- Lemos LB, Baliga M, Guo M. Acute respiratory distress syndrome and blastomycosis: presentation of nine cases and review of the literature. *Ann Diagn Pathol*. 2001;5(1):1-9.
- Bednarczyk JM, Kethireddy S, White CW, et al. Extracorporeal membrane oxygenation for blastomycosis-related acute respiratory distress syndrome: a case series. *Can J Anaesth*. 2015;62(7):807-15.
- Limper AH, Knox KS, Sarosi GA, et al. An official American Thoracic Society statement: Treatment of fungal infections in adult pulmonary and critical care patients. *Am J Respir Crit Care Med*. 2011;183(1):96-128.

The Aortomesenteric Angle as an Aid in Diagnosing Superior Mesenteric Artery Syndrome

Kathleen E. Kane, MD*[†]
Andrew L. Koons, DO[†]

*University of South Florida Morsani College of Medicine, Tampa, Florida
[†]Lehigh Valley Hospital-Muhlenberg, Department of Emergency Medicine, Allentown, Pennsylvania

Section Editor: Rick A. McPheeters, DO

Submission history: Submitted April 20, 2016; Revision received December 22, 2016; Accepted December 27, 2016

Electronically published March 16, 2017

Full text available through open access at http://escholarship.org/uc/uciem_cpchem

DOI: 10.5811/cpchem.2016.12.30676

[Clin Pract Cases Emerg Med. 2017;1(2):140–141.]

CASE REPORT

We present a case of a 22-year-old female with a history of intravenous drug abuse and homelessness presenting with four days of vomiting and abdominal pain. She noted significant weight loss in the preceding weeks; this was surmised to be secondary to increased drug usage. Examination revealed a diffusely tender but non-peritoneal abdomen. Computed tomography (CT) demonstrated duodenal obstruction with findings consistent with superior mesenteric artery (SMA) syndrome, which presents as high intestinal obstruction. While SMA syndrome can present due to medical conditions such as achalasia, it may also be seen in malnutrition related to substance abuse.

DISCUSSION

Symptoms are caused by duodenal compression by the narrow angle of the SMA pressing against the posterior structures. The narrow angle of the SMA is due to lack of fat surrounding the vessel.¹ When paired with appropriate clinical suspicion, diagnosis of SMA syndrome is facilitated by measurement of the angle between the aorta and the SMA by CT or ultrasonography (US). Aortomesenteric (AOM) angles less than 22 to 28 degrees with an AOM distance between 2-8mm are strongly suggestive of SMA syndrome in the correct patient setting (see Image).²⁻⁵ The normal AOM angle is between 45 and 60 degrees, and the normal AOM distance is between 10-20mm.^{6,7} As these values drop, the likelihood of SMA syndrome increases. When paired with any one symptom of SMA syndrome (postprandial epigastric pain, anorexia, vomiting, weight loss), the cutoff of 22 degrees has a sensitivity of 42.8% and specificity of 100%; the cutoff of 8mm has a sensitivity and specificity of 100%.⁵ These values can be obtained from a CT or US. Our patient's CT showed an AOM angle of 21 degrees and AOM distance of 4mm, helping confirm her diagnosis. Treatment is aimed at improving nutrition and treating the underlying cause of weight loss.

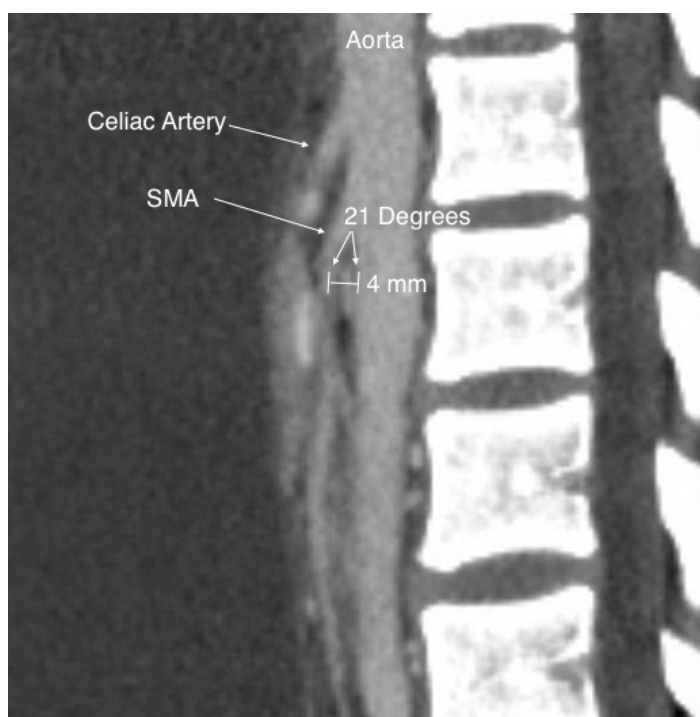

Image. Angle between the aorta and the superior mesenteric artery (SMA) in patient with SMA syndrome.

Address for Correspondence: Kathleen E. Kane, MD, Lehigh Valley Hospital-Muhlenberg, 5th floor, EM Residency Suite, 2545 Schoenersville Road, Bethlehem, PA 18107. Email: katekane831@gmail.com.

Conflicts of Interest: By the CPC-EM article submission agreement, all authors are required to disclose all affiliations, funding sources and financial or management relationships that could be perceived as potential sources of bias. The authors disclosed none.

Copyright: © 2017 Kane et al. This is an open access article distributed in accordance with the terms of the Creative Commons Attribution (CC BY 4.0) License. See: <http://creativecommons.org/licenses/by/4.0/>

REFERENCES

1. Ozkurt H, Cenker MM, Bas N, et al. Measurement of the distance and angle between the aorta and superior mesenteric artery: normal values in different BMI categories. *Surg Radiol Anat.* 2007;29(7):595-9.
2. Agrawal GA, Johnson PT, Fishman EK. Multidetector row CT of superior mesenteric artery syndrome. *J Clin Gastroenterol.* 2007;41(1):62-5.
3. Raman SP, Neyman EG, Horton KM, et al. Superior mesenteric artery syndrome: spectrum of CT findings with multiplanar reconstructions and 3-D imaging. *Abdom Imaging.* 2012;37(6):1079-88.
4. Unal B, Aktaş A, Kemal G, et al. Superior mesenteric artery syndrome: CT and ultrasonography findings. *Diagn Interv Radiol.* 2005;11(2):90-5.
5. Superior Mesenteric Artery Syndrome. EBSCO host, DynaMed Web site. Available at: <http://web.a.ebscohost.com/dynamed/detail?vid=2&sid=7c1fe2ab-a1c3-442b-b516-a0144b3cd0ba%40sessionmgr4010&hid=4212&bdata=JnNpdGU9ZHluYW1lZC1saXZlJnNjb3BIPXNpdGU%3d#AN=114160&db=dme>. Accessed Sept 12, 2015.
6. Kothari TH, Machnicki S, Kurtz L. Superior mesenteric artery syndrome. *Can J Gastroenterol.* 2011;25(11):599–600.
7. Ranschaert, E and Weerakkody Y. Superior mesenteric artery syndrome. Radiopaedia.org. Available at: <https://radiopaedia.org/articles/superior-mesenteric-artery-syndrome>. Accessed Sept 12, 2015.

Intercostal Lung Herniation

David Manthey, MD
Alexander W. Nickle, MD

Wake Forest School of Medicine, Department of Emergency Medicine, Winston-Salem, North Carolina

Section Editor: Rick A. McPheeters, DO

Submission history: Submitted November 21, 2016; Revision received December 20, 2016; Accepted December 27, 2016

Electronically published March 15, 2017

Full text available through open access at http://escholarship.org/uc/uciem_cpem

DOI: 10.5811/cpcem.2016.12.33212

[Clin Pract Cases Emerg Med. 2017;1(2):142–143.]

CASE REPORT

A pleasant 51-year-old gentleman began to experience right chest wall discomfort approximately one month prior to his presentation to the emergency department (ED). He had a history of chronic obstructive pulmonary disease (COPD) and had fractured ribs secondary to coughing paroxysms. He had no history of direct trauma to his chest. He acutely developed a recurrence of his pain and presented to the ED. He stated that he had a coughing paroxysm and developed right-sided posterolateral chest pain. On exam there was a tender, palpable mass in his posterior chest with associated crepitus expanding with inspiration. Portable chest radiograph revealed rib fractures in various stages of healing and right lung outside of his rib cage without pneumothorax. He underwent a computed tomography (CT) of the chest, which confirmed acute rib fractures of ribs 8 and 9 posterolaterally and a chest wall hernia through the eighth intercostal space (Image).

DISCUSSION

Intercostal Lung Herniation: Plain radiography revealed a lung herniation outside of the rib cage on the right. A subsequent CT showed acute fractures of the eighth and ninth ribs with herniation of the lung through the eighth intercostal space (Image). Surgery was performed to plate the eighth rib and repair the hernia under thoracoscopy.

Lung herniation is relatively rare and usually occurs in the setting of trauma (penetrating or blunt external force) or surgery.¹ Spontaneous lung herniation is even more rare, resulting from an increased intrathoracic pressure.² The necessary increase in pressure can be caused by coughing, sneezing, or heavy lifting. The “classic” history for this rare event is sudden onset chest pain after a coughing paroxysm in a male smoker with COPD.³ In this case, the patient’s coughing paroxysms were strong enough in force to both fracture ribs and cause a lung herniation. Treatment of lung herniation can include reduction with or without ultrasound guidance, expectant management, and surgical repair.

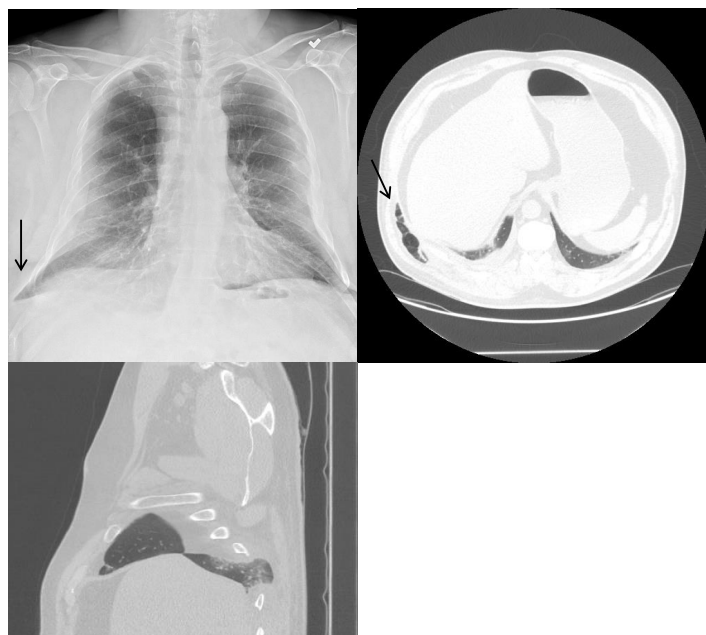

Image. Computed tomography and chest radiograph demonstrating right-sided intercostal lung herniation (arrow).

Address for Correspondence: David E. Manthey, MD, Wake Forest School of Medicine, Winston-Salem, NC 27157. Email: DManthey@wakehealth.edu.

Conflicts of Interest: By the CPC-EM article submission agreement, all authors are required to disclose all affiliations, funding sources and financial or management relationships that could be perceived as potential sources of bias. The authors disclosed none.

Copyright: © 2017 Manthey et al. This is an open access article distributed in accordance with the terms of the Creative Commons Attribution (CC BY 4.0) License. See: <http://creativecommons.org/licenses/by/4.0/>.

REFERENCES:

1. Weissberg D, Rafaely Y. Hernia of the Lung. *Ann Thorac Surg.* 2002;74(6):1963-6.
2. Jastrow KM 3rd, Chu D, Jaroszewski D, et al. Posterior lung herniation after a coughing spell: a case report. *Cases J.* 2009;2(1):86.
3. Goverde P, Van Schil P, Van den Brande F, et al. Chronic herniation of the lung in a patient with chronic obstructive pulmonary disease. *Thorac Cardiovasc Surg.* 1998;46(3):164-6.

Adult Female with a Headache

Kelley A. Wittbold, MD*
 Jacqueline Boehme, MD†
 Heidi H. Kimberly, MD*
 Sarah E. Frasure, MD*

*Brigham and Women's Hospital, Department of Emergency Medicine, Boston, Massachusetts

†Massachusetts General Hospital, Department of Medicine, Boston, MA

Section Editor: Rick A. McPheeters, DO

Submission history: Submitted November 29, 2016; Revision received December 27, 2016; Accepted January 11, 2017

Electronically published March 15, 2017

Full text available through open access at http://escholarship.org/uc/uciem_cpccem

DOI: 10.5811/cpcem.2017.1.33237

[Clin Pract Cases Emerg Med. 2017;1(2):144–145.]

CASE REPORT

A 38 year old female with a history of a right foot drop after medial facetectomies (L4-L5, L5-S1) and micro-discectomy (L4-L5) eight weeks prior presented to the emergency department (ED) with two weeks of headache and neck pain. She denied fever or chills. In the ED, her vital signs were stable and her physical exam demonstrated an area of fluctuance along a well-healed surgical incision at L4-S1 that was most prominent when she sat upright. There was no overlying erythema or tenderness to palpation. The emergency physician ordered blood work, pain medication, and performed a point-of-care ultrasound along the area of fluctuance with a linear transducer (5-12 MHz). The ultrasound images demonstrated a large, hypoechoic fluid collection that tracked to the spine (Image 1, Video). A magnetic resonance image (MRI) of the lumbosacral spine confirmed the suspected diagnosis (Image 2).

DISCUSSION

Pseudomeningocele. The patient was taken to the operating room where a defect in the dura was identified. A pseudomeningocele is an abnormal cerebrospinal fluid collection that communicates with the dura mater surrounding the brain or spinal cord. The symptoms of pseudomeningocele include back pain, neck pain, and headache. The sensation of headache is rarely due to injury to the brain parenchyma itself, but rather due to tension, traction, dilation, or inflammation of pain-sensitive structures such as blood vessels or the dura mater.¹ Patients with pseudomeningocele may also present with signs and symptoms of acute or chronic meningitis.² MRI is considered the imaging modality of choice in the assessment of a pseudomeningocele. In this case, the clinician used point-of-care ultrasound to identify a simple fluid collection at the surgical site, which tracked from the soft tissue to the level of the dura. There was no evidence of soft tissue cobblestoning, loculations, or wall thickening of the collection to suggest

cellulitis or abscess. Furthermore, there was no hyperechoic debris that is generally found inside an abscess on ultrasound imaging. MRI confirmed the suspected diagnosis.

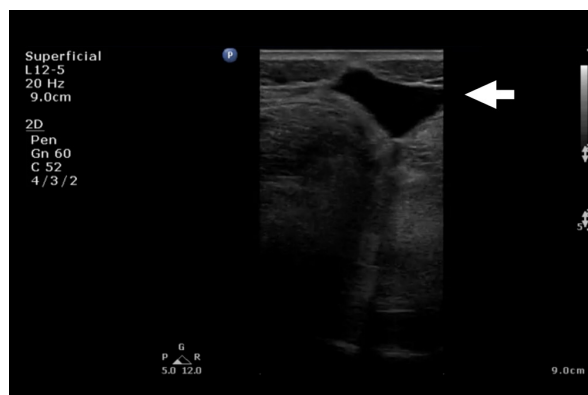


Image 1. Sagittal ultrasound image of a simple fluid collection (arrow) tracking from the skin to the spine.

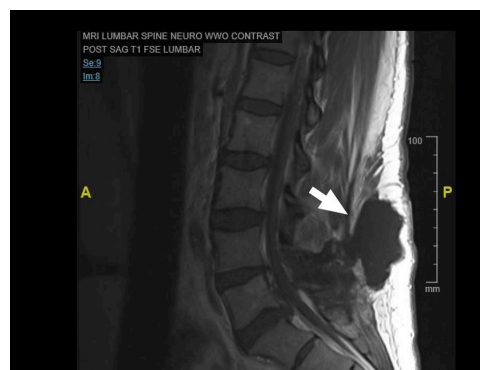

Image 2. Sagittal T1-weighted magnetic resonance imaging of the lumbosacral spine demonstrating the pseudomeningocele (arrow) identified initially on ultrasound.

Video. This sagittal ultrasound video clip, performed by the emergency physician with a linear transducer (5-12 MHz), demonstrates a simple fluid collection without overlying cobblestoning or wall thickening.

Copyright: © 2016 Wittbold et al. This is an open access article distributed in accordance with the terms of the Creative Commons Attribution (CC BY 4.0) License. See: <http://creativecommons.org/licenses/by/4.0/>

Address for Correspondence: Sarah E. Frasure, MD, Brigham and Women's Hospital, 75 Francis Street, Neville House – 236A, Boston, MA 02115. Email: sarahfrasure@yahoo.com.

Conflicts of Interest: By the CPC-EM article submission agreement, all authors are required to disclose all affiliations, funding sources and financial or management relationships that could be perceived as potential sources of bias. The authors disclosed none.

REFERENCES

1. Adams JG, Barton ED, Collings JL, et al. Emergency Medicine: Clinical Essentials. Saunders. 2013;(2).
2. Gass H, Goldstein AS, Ruskin R, et al. Chronic postmyelogram headache. Isotopic demonstration of dural leak and surgical cure. *Arch Neurol.* 1971;25(2):168-70.

Phytophotodermatitis

Liza G. Smith, MD*
Christopher Kabhrel, MD†

*Baystate Medical Center, Department of Emergency Medicine, Springfield, Massachusetts

†Massachusetts General Hospital, Department of Emergency Medicine, Boston, Massachusetts

Section Editor: Shadi Lahham, MD, MS

Submission history: Submitted October 3, 2016; Revision received January 9, 2017; Accepted January 11, 2017

Electronically published March 16, 2017

Full text available through open access at http://escholarship.org/uc/uciem_cpccem

DOI: 10.5811/cpcem.2017.1.32739

[Clin Pract Cases Emerg Med. 2017;1(2):146–147.]

CASE REPORT

A 22-year-old college student presented to the emergency department with a painful rash to her left upper extremity. She had returned from a spring-break trip to Ecuador the day prior to presentation and the rash had developed on the third day of her six-day stay. On further history, she endorsed squeezing limes into guacamole on the first day of her trip and did recall getting the juice on her arm, as well as spending many hours sunbathing.

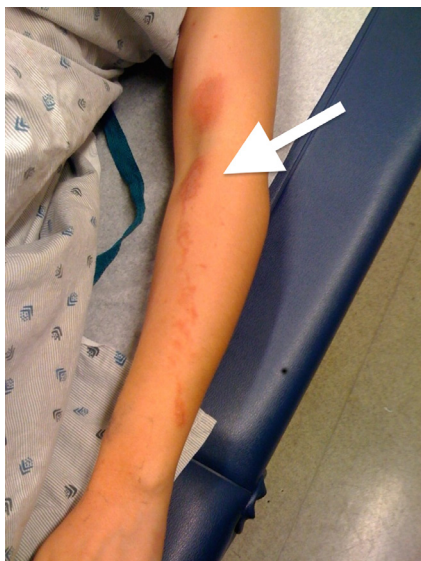

Image. An erythematous, blistering rash (arrow) demonstrating a splash pattern with evidence of direct transfer across the flexor surface of the elbow.

Due to her history of exposure to lime juice and the particular distribution of her rash, demonstrating a splash pattern with evidence of direct transfer across the flexor surfaces of her elbow, a diagnosis of phytophotodermatitis was made.

DISCUSSION

Phytophotodermatitis is a cutaneous reaction resulting from the interaction between sensitizing botanical substances and ultraviolet radiation. It is a direct phototoxic reaction entirely independent of the immune system. It typically presents as a painful, erythematous and sometimes blistering rash, often in linear, streaking patterns isolated to sun-exposed areas of skin.¹

Several plant families are known to elicit phototoxic reactions, and one of the most commonly responsible chemical agents is furocoumarin, particularly the psoralen isomers, found in citrus fruits, notably lemons and limes.²

The pain is due to necrosis of the involved epidermis, and treatment is mainly symptomatic. Non-steroidal anti-inflammatory medications may be helpful for the pain, and topical steroids may be used if the eruption is severe. Residual hyperpigmentation is common.²

Address for Correspondence: Liza G. Smith, MD, Baystate Medical Center, 759 Chestnut Street Springfield, MA 01199.
Email: Liza.SmithMD@BaystateHealth.org.

Conflicts of Interest: By the CPC-EM article submission agreement, all authors are required to disclose all affiliations, funding sources and financial or management relationships that

could be perceived as potential sources of bias. The authors disclosed none.

Copyright: © 2017 Smith et al. This is an open access article distributed in accordance with the terms of the Creative Commons Attribution (CC BY 4.0) License. See: <http://creativecommons.org/licenses/by/4.0/>

REFERENCES

1. Friedman BT, Harper R, Glucksberg A, et al. In the Limelight. *J Emerg Med.* 2016;50(3):504-5.
2. Kung AC, Stephens MB, Darling T. Phytophotodermatitis: bulla formation and hyperpigmentation during spring break. *Mil Med.* 2009;174(6):657-61.

Spontaneous Hemoperitoneum from Rupture of Massive Leiomyoma

Arielle Schwitkis, BA*
Steven Shen, BA*
Elaine Vos, BA†
Sam S. Torbati, MD*

*Cedars-Sinai Medical Center, Department of Emergency Medicine, Los Angeles, California

†Western Michigan University Homer Stryker M.D. School of Medicine, Kalamazoo, Michigan

Section Editor: Rick A. McPheeters, DO

Submission history: Submitted November 18, 2016; Revision received January 11, 2017; Accepted January 15, 2017

Electronically published March 16, 2017

Full text available through open access at http://escholarship.org/uc/uciem_cpccem

DOI: 10.5811/cpcem.2017.1.33190

[Clin Pract Cases Emerg Med. 2017;1(2):148–149.]

CASE REPORT

A 34-year-old woman presented to the emergency department (ED) with acute onset of severe abdominal pain and distention with associated diffuse tenderness and guarding. Her medical history was significant for a two-year history of fibroids, which contributed to mild menorrhagia. Within 30 minutes of arrival, the patient developed signs of shock with a blood pressure of 89/67 mmHg, heart rate of 115 beats per minute, and a drop in serial hemoglobin measurements from 8.4 g/dL to 6.8 g/dL. Point-of-care ultrasound showed a large amount of free fluid in the abdomen associated with a large abdominal mass originating in the pelvis. Emergent computed tomography (CT) imaging demonstrated a large amount of intra-peritoneal bleeding associated with massive fibroids as shown in Images 1-2. Exploratory laparotomy discovered 3L of hemoperitoneum as well as a roughly 30-week-sized uterus with multiple fibroids, two of which were torsed and actively bleeding. The patient received four units of packed red blood cells, underwent emergent supracervical hysterectomy without additional complications, and was eventually discharged on post-operative day 3. Surgical pathology demonstrated normal endocervical and endometrial tissue, as well as multiple intramural and subserosal leiomyomas measuring up to 17.8 cm in length.

DISCUSSION

Leiomyomas, often called fibroids, are common in women of reproductive age.¹⁻³ Hemoperitoneum as a result of spontaneous fibroid rupture or torsion is extremely rare with only one case report found in the emergency medicine literature within the last 20 years and is associated with fibroids greater than 10 cm.¹⁻³ Other etiologies of spontaneous hemoperitoneum include hepatic and splenic rupture, ovarian cyst and ectopic pregnancy rupture, vascular rupture, and bleeding disorders.⁴ All may have similar initial presentations to the ED with acute onset of abdominal pain and signs of hemorrhagic shock.

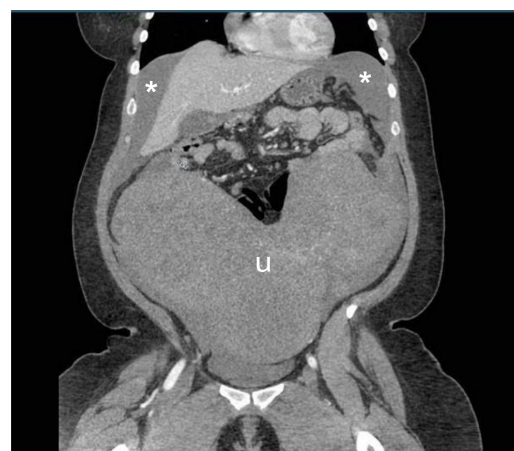


Image 1. Abdominal computed tomography, coronal view, demonstrating massive fibroid filled uterus (u) and hemoperitoneum (asterisks).

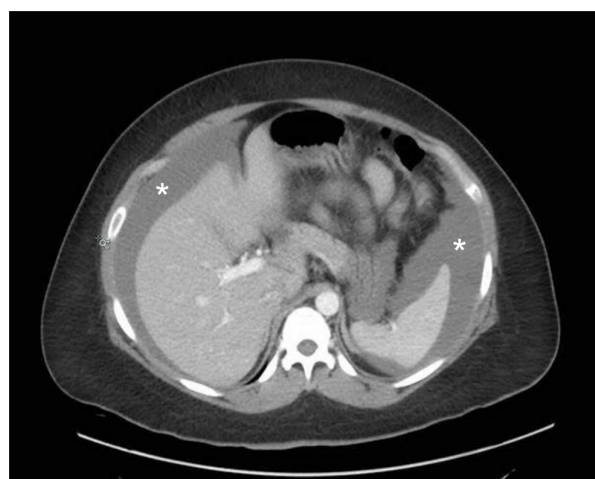

Image 2. Abdominal computed tomography, cross section, demonstrating location of hemoperitoneum (asterisks).

Address for Correspondence: Arielle Schwitkis, BA, Cedars-Sinai Medical Center, 8700 Beverly Blvd., Los Angeles, CA 90048.
Email: Arielle.Schwitkis@cshs.org.

Conflicts of Interest: By the *CPC-EM* article submission agreement, all authors are required to disclose all affiliations, funding sources and financial or management relationships that could be perceived as potential sources of bias. The authors disclosed none.

Copyright: © 2017 Schwitkis et al. This is an open access article distributed in accordance with the terms of the Creative Commons Attribution ([CC BY 4.0](http://creativecommons.org/licenses/by/4.0/)) License. See: <http://creativecommons.org/licenses/by/4.0/>

REFERENCES

1. Lotterman S. Massive hemoperitoneum resulting from spontaneous rupture of uterine leiomyoma. *Am J Emerg Med.* 2008;26(8):974.e1-2.
2. Peng CR, Chen CP, Wang KG, et al. Spontaneous rupture and massive hemoperitoneum from uterine leiomyomas and adenomyosis in a nongravid and unscarred uterus. *Taiwan J Obstet Gynecol.* 2015;54(2):198-200.
3. Wong L, Ching TW, Kok TL, et al. Spontaneous hemoperitoneum from a uterine leiomyoma in pregnancy. *Acta Obstet Gynecol Scand.* 2005;84(12):1208-9.
4. Lucey BC, Varghese JC, Soto JA. Spontaneous hemoperitoneum: causes and significance. *Curr Probl Diagn Radiol.* 2005;34(5):182-95.

Use of Ultrasound to Diagnose Pneumonia

Derek L. Monette, MD
Sarah E. Frasure, MD

Brigham and Women's Hospital, Department of Emergency Medicine, Boston, Massachusetts

Section Editor: Rick A. McPheeters, DO

Submission history: Submitted November 19, 2016; Revision received December 21, 2016; Accepted January 23, 2017

Electronically published March 16, 2016

Full text available through open access at http://escholarship.org/uc/uciem_cpccm

DOI: 10.5811/cpcem.2017.1.33199

[Clin Pract Cases Emerg Med. 2017;1(2):150–151.]

CASE REPORT

A 31-year-old female with a history of intravenous drug use presented to the emergency department with three days of fever, cough, and pleuritic pain. She denied orthopnea, leg swelling, chest pain, back pain, urinary frequency, sore throat, exotic travel, or recent hospitalization. Her vital signs were notable for tachycardia to 140 beats per minute. Her physical exam demonstrated left basilar crackles and a systolic murmur in the left upper sternal border. The emergency physician performed a point-of-care thoracic ultrasound (Image 1), and subsequently ordered a plain film of the chest (Image 2), which confirmed the diagnosis.

DISCUSSION

The patient was admitted for pneumonia to the medical service and provided with intravenous antibiotics. The patient was admitted to the medical service and provided with intravenous antibiotics. Blood cultures grew *Streptococcus gordonii*. A transthoracic echocardiogram demonstrated the presence of a tricuspid vegetation. She was presumed to have both a community-acquired pneumonia (CAP) and long-standing endocarditis. Pneumonia remains a common cause of death in the United States and is associated with considerable morbidity and mortality, particularly in elderly and immunocompromised patients. Common causes of pneumonia include *Streptococcus pneumoniae* and respiratory viruses.¹ A growing body of literature demonstrates the superiority of thoracic ultrasound over plain radiography in the identification of pneumonia. Classic ultrasound findings of pneumonia include air or fluid bronchograms, focal B-lines, pleural effusions, and sub-pleural consolidations.² These unique findings were recognized by the emergency physician using point-of-care thoracic ultrasound, facilitating prompt diagnosis and treatment of pneumonia.

Video 1. This ultrasound video clip, performed by the emergency physician, demonstrates a sub-pleural consolidation with surrounding asymmetric B-lines, consistent with pneumonia.

Video 2. This comprehensive ECHO, performed by the cardiology service during the patient's admission, demonstrates a large tricuspid vegetation. *ECHO*, echocardiogram

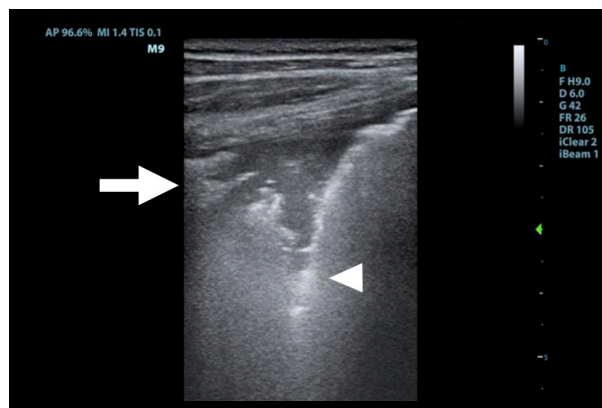


Image 1. This longitudinal image of the left chest wall, performed with a linear transducer (4–12 MHz), demonstrates both a sub-pleural consolidation (arrow) and hyperechoic B-lines (arrowhead) MHz, Megahertz

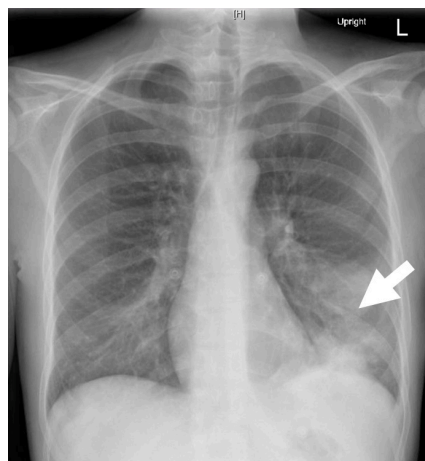


Image 2. This plain film of the chest demonstrates a left lower lobe consolidation (arrow).

Address for Correspondence: Sarah E. Frasure, MD, Brigham and Women's Hospital, Neville House – 236A, 75 Francis Street, Boston, MA 02115. Email: sarahfrasure@yahoo.com.

Attribution ([CC BY 4.0](http://creativecommons.org/licenses/by/4.0/)) License. See: <http://creativecommons.org/licenses/by/4.0/>

Conflicts of Interest: By the *CPC-EM* article submission agreement, all authors are required to disclose all affiliations, funding sources and financial or management relationships that could be perceived as potential sources of bias. The authors disclosed none.

Copyright: © 2017 Monette et al. This is an open access article distributed in accordance with the terms of the Creative Commons

REFERENCES

1. Jain S, Self WH, Wunderink RG, et al. Community-acquired pneumonia requiring hospitalization among U.S. adults. *N Engl J Med.* 2015;373(5):415-27.
2. Blaivas M. Lung ultrasound in evaluation of pneumonia. *J Ultrasound Med.* 2012;31(6):823-6.

Call for Section Editors

- Neurosciences
- Cardiac Care
- Behavioral Emergencies
- Injury Prevention
- Trauma
- Pediatric Emergency Medicine
- Public Health

Please send your CV and letter of interest to editor@westjem.org

Now offering CME credit



Call for

- REVIEWERS -

Please send your CV and letter
of interest to
editor@westjem.org

**Me
Mc** MEDITERRANEAN
EMERGENCY MEDICINE CONGRESS

GREAT NETWORK CONGRESS
FOCUS ON INNOVATIONS AND TRANSLATIONAL
RESEARCH IN EMERGENCY MEDICINE

6-10 September 2017
Lisbon, Portugal



**JOIN
CAL/AAEM!**

*Championing
individual physician rights
and workplace fairness*

BENEFITS

- Western Journal of Emergency Medicine Subscription
- CAL/AAEM News Service email updates
- Discounted AAEM pre-conference fees
- And more!

CAL/AAEM NEWS SERVICE

- Healthcare industry news
- Public policy
- Government issues
- Legal cases and court decisions



In collaboration with our official journal

WestJEM Integrating Emergency Care
with Population Health



FACEBOOK.COM/CALAAEM



FOLLOW US @CALAAEM

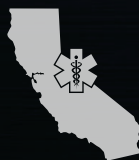[HTTP://WWW.CALAAEM.ORG](http://www.calaaem.org)

2017



LEGISLATIVE
LEADERSHIP
CONFERENCE

MAY 2
SACRAMENTO



CALIFORNIA ACEP
AMERICAN COLLEGE OF EMERGENCY PHYSICIANS