

A Case of Ureter Herniation in the Petit Triangle

Atsuhito Tanaka, MD*
Yuka Kamitani, MD†

*Tokyo Bay Urayasu Ichikawa Medical Center, Department of Emergency and Critical Care Medicine, Chiba, Japan
†Kobe City Medical Center General Hospital, Emergency Care Center/Emergency Department, Kobe, Japan

Section Editor: Ezhilkugan Ganessane, MD

Submission history: Submitted July 22, 2025; Revision received September 21, 2025; Accepted November 17, 2025

Electronically published March 29, 2026

Full text available through open access at http://escholarship.org/uc/uciem_cpem

DOI: 10.5811/cpem.49084

Case Presentation: An 88-year-old man was brought to our emergency department due to altered mental status and hemodynamic shock due to a urinary tract infection. Computed tomography showed an incarcerated ureter in the Petit triangle. Urology was consulted, and the hernia was reduced back into the retroperitoneal cavity.

Discussion: Petit hernia is rare; moreover, there is no literature to our knowledge discussing the ureter as the herniated structure. Interventional radiology can be considered as a reductive option. [Clin Pract Cases Emerg Med. XXXX;X(X):X–X.]

Keywords: *ureter herniation; Petit triangle.*

CASE PRESENTATION

An 88-year-old man was transferred to our emergency department with a decreased level of consciousness and elevated inflammatory markers. His past medical conditions included osteomyelitis and cerebral infarction. No history of surgery or trauma was noted. On arrival, he was in septic shock for which vasopressor infusion and antibiotics were administered. Blood tests revealed elevated creatinine, and point-of-care ultrasound demonstrated dilatation of the right renal pelvis. Computed tomography (CT) of the abdomen was performed to determine the etiology of altered mental status and possible post-renal obstruction. Abdominal CT revealed an incarcerated right ureter that had herniated through the Petit triangle in the inferior lumbar region, accompanied by right renal pelvic dilatation (Images 1-3). Urology was consulted, and the ureter was retrogradely reduced back into the

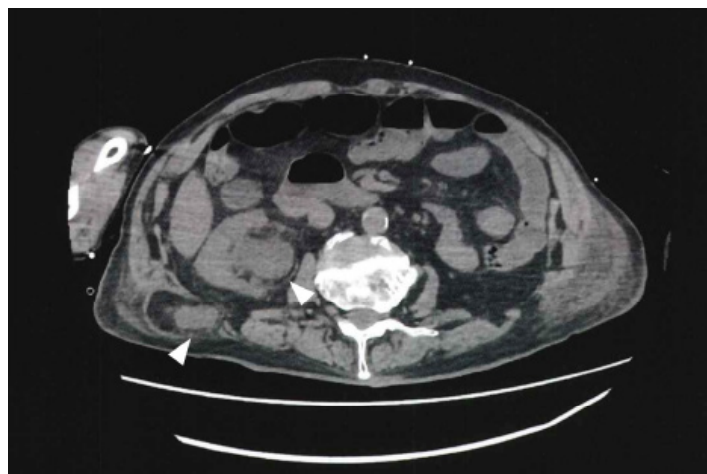


Image 1. Computed tomography (axial view) showing the dilated renal pelvis and herniated ureter from the Petit triangle.

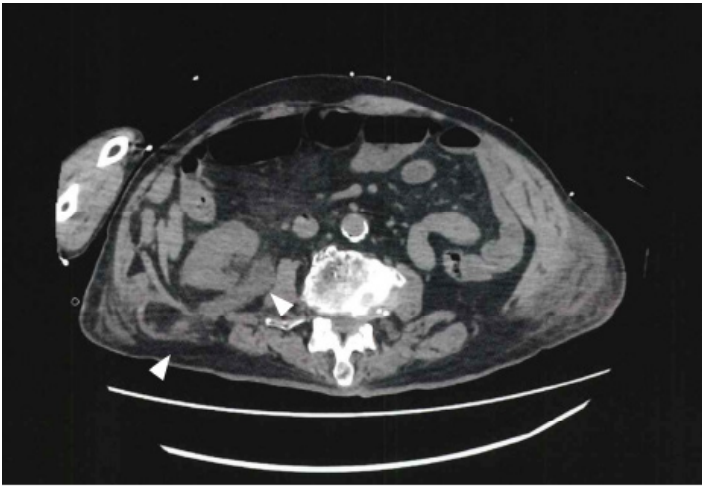


Image 2. Computed tomography (axial view) caudal of Image 1, showing the dilated ureter and herniation.

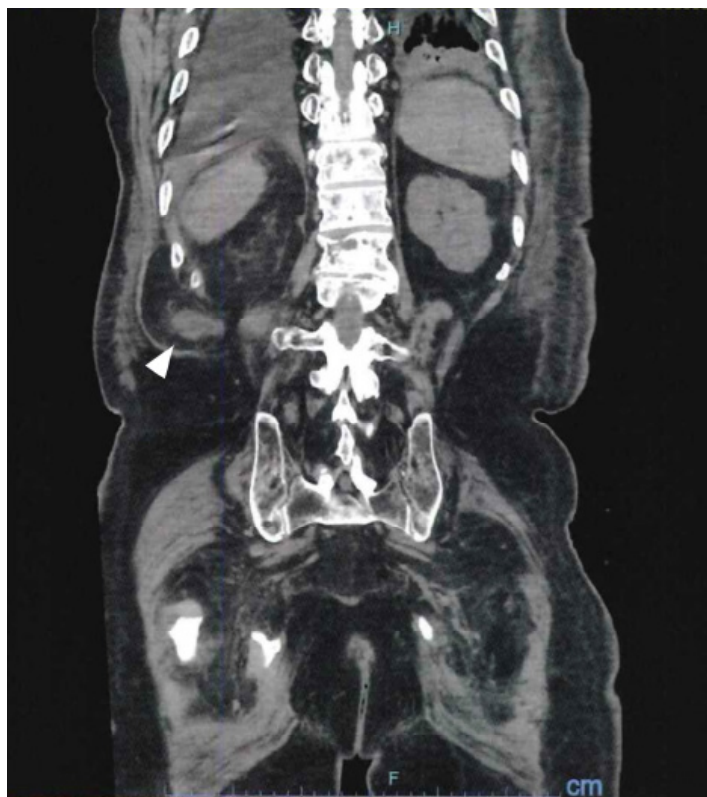

Image 3. Computed tomography (coronal view) showing the herniated ureter through the Petit triangle (arrow).

CPC-EM Capsule

What do we already know about this clinical entity?

Petit lumbar hernia is a rare type of lumbar hernia.

What is the major impact of the image(s)?

The images confirm a rare ureteral herniation into the Petit triangle while validating a successful endourological treatment option.

How might this improve emergency medicine practice?

Ureteral lumbar hernia should be on the differential for acute kidney injury and validates endourological reduction as a minimally invasive approach.

retroperitoneal cavity via cystoscopy. Renal function improved after the intervention, with a decrease in serum creatinine from 2.57 milligrams per deciliter (mg/dL) to 1.83 mg/dL (reference range: 0.61-1.04 mg/dL). The patient recovered and was discharged on day 10.

DISCUSSION

Petit hernia, a rare type of lumbar hernia, occurs through the space formed by the iliac crest, external oblique muscle, and latissimus dorsi muscle in the posterior abdomen, representing 1.5-2% of all hernias.¹ Most reported cases discuss herniation of the colon or small bowel, often requiring surgical intervention. Ureteral hernias are uncommon clinical entities, making this specific combination unprecedented.^{2,4,5} Considering the patient's age and clinical status, a less-invasive approach was chosen over surgical intervention. Zandrino et al described a percutaneous anterograde approach to resolve a lumbar hernia in the first case report of a hernia retrogradely reduced back into the retroperitoneal cavity via cystoscopy and guidewire manipulation. This suggests that minimally invasive radiological or endourological techniques could be a primary therapeutic option in such rare cases.

The authors attest that their institution requires neither Institutional Review Board approval, nor patient consent for publication of this case report. Documentation on file.

Address for Correspondence: Atsuhito Tanaka, MD, Department of Emergency and Critical Care Medicine, Tokyo Bay Urayasu, Ichikawa Medical Center, 3-4-32 Todajima, Urayasu-City, Chiba 279-0001. Email: atsuhito.tanaka17@gmail.com

Conflicts of Interest: By the *CPC-EM* article submission agreement, all authors are required to disclose all affiliations, funding sources and financial or management relationships that could be perceived as potential sources of bias. The authors disclosed none.

Copyright: © 2026 Tanaka et al. This is an open access article distributed in accordance with the terms of the Creative Commons Attribution ([CC BY 4.0](http://creativecommons.org/licenses/by/4.0/)) License. See: <http://creativecommons.org/licenses/by/4.0/>

REFERENCES

1. Munoz-Munoz M, Torres-Mansur R, Torres-Ramirez MA. The rarity of Petit's hernia: a case report on diagnosis and treatment. *Int J Surg Case Rep.* 2023;111:108886.
2. Yahya Z, Al-Habbal Y, Hassen S. Ureteral inguinal hernia: an uncommon trap for general surgeons. *BMJ Case Rep.* 2017;2017:bcr2017219288
3. Zandrino F, Di Guardia G, Gallesio C. Inferior lumbar (Petit's) hernia with ureteral incarceration treated with percutaneous repair. *J Radiol Rev.* 2022;9(3):158-60.
4. Ben Ghezala H, Feriani N. Hernia of the Jean Louis Petit triangle in the emergency department: a rare image. *Pan Afr Med J.* 2020;37:166.
5. Strange CD, Birkemeier KL, Sinclair ST. Atypical abdominal hernias in the emergency department: acute and non-acute. *Emerg Radiol.* 2009;16(2):121-8.