

CPC Emergency Medicine

Volume III, Number 1, February 2019

Open Access at www.cpcem.org

ISSN: 2474-252X

Clinical Practice and Cases in Emergency Medicine

In Collaboration with the *Western Journal of Emergency Medicine*

Clinicopathological Cases from the University of Maryland

- 1 **38-year-old Woman with a Cough and a Rash**
Donahue MP, Clayborne EP, ZDW Dezman, Bontempo LJ

Case Series

- 6 **Occipital Nerve Blocks in the Emergency Department for Initial Medication-Refractory Acute Occipital Migraines: A Case Series**
Yanuck J, Shah S, Jen M, Dayal R

Case Reports

- 11 **Point-of-Care Ultrasound Diagnosis of Pulmonary Embolism with Thrombus in Transit**
Kahl N, Gabriel C, Lahham S, Thompson M, Hoonpongsimanont W
- 13 **Early Identification of Central Retinal Artery Occlusion Using Point-of-care Ultrasound**
Stoner-Duncan B, Morris SC
- 16 **Emergent Treatment of Neuroleptic Malignant Syndrome Induced by Antipsychotic Monotherapy Using Dantrolene**
Ngo V, Guerrero A, Lanum D, Burgett-Moreno M, Fenati G, Barr S, Neeki MM
- 24 **Kratom (Mitragynine) Ingestion Requiring Naloxone Reversal**
Overbeek DL, Abraham J, Munzer BW
- 27 **A Single-session Crisis Intervention Therapy Model for Emergency Psychiatry**
Simpson SA
- 33 **Late Presentation of Transfusion-related Acute Lung Injury in the Emergency Department**
Peak DK, Davis WT, Walton SB
- 36 **Point-of-care Ultrasound Diagnosis of Tennis Leg**
Monseau AJ, Balcik BJ, Denne N, Sharon MJ, Minardi JJ
- 40 **No Sweat! Bilateral Shoulder Reduction Using a Modified Davos Technique**
Joseph J, Nguyen N, Olson D, Boutin A, Olson D

Contents continued on page iii



UC Irvine Health



ACOEP's
SPRING SEMINAR

Save the Date!

❁ April 8-12, 2019 ❁

Join us at the 2019 Spring Seminar
in beautiful Bonita Springs, Florida!

Featuring three incredible keynote speakers:



Richard Cantor, MD



Amal Mattu, MD



Tarlan Hedayati, MD

The American College of Osteopathic Emergency Physicians (ACOEP) is accredited by the Accreditation Council for Continuing Medical Education (ACCME) to provide continuing medical education for physicians. ACOEP is accredited by the AOA to provide osteopathic continuing medical education for physicians.

**ACOEP IS NOW DUALY
ACCREDITED!**

ACOEP is now accredited by the American Osteopathic Association (AOA) and the Accreditation Council for Continuing Medical Education (ACCME) to provide CME credits to physicians!

Clinical Practice and Cases in Emergency Medicine

Indexed in PubMed and full text in PubMed Central

In Collaboration with the *Western Journal of Emergency Medicine*

Rick A. McPheeters, DO, Editor-in-Chief
Kern Medical/UCLA- Bakersfield, California

Manish Amin, DO, Associate Editor
Kern Medical/UCLA- Bakersfield, California

Mark I. Langdorf, MD, MHPE, Associate Editor
University of California, Irvine School of Medicine- Irvine, California

Shadi Lahham, MD, MS, Associate Editor
University of California, Irvine School of Medicine- Irvine, California

Shahram Lotfipour, MD, MPH, Managing Associate Editor
University of California, Irvine School of Medicine- Irvine, California

Anna McFarlin, MD, Section Editor
Louisiana State University Health Science Center- New Orleans, Louisiana

Christopher Sampson, MD, Section Editor
University of Missouri- Columbia, Missouri

Joel Moll, MD, Section Editor
Virginia Commonwealth University School of Medicine- Richmond, Virginia

Scott Goldstein, DO, Section Editor
Sidney Kimmel College of Medicine- Philadelphia, Pennsylvania

Steven Walsh, MD, Section Editor
Einstein Medical Center Philadelphia-Philadelphia, Pennsylvania

John Ashurst, DO, Section Editor
Kingman Regional Health Network, Arizona

Editorial Board

Amin A. Kazzi, MD, MAAEM
The American University of Beirut, Beirut, Lebanon

Anwar Al-Awadhi, MD
Mubarak Al-Kabeer Hospital, Jabriya, Kuwait

Arif A. Cevik, MD
*United Arab Emirates University
College of Medicine and Health Sciences, Al Ain, United Arab Emirates*

Abhinandan A. Desai, MD
University of Bombay Grant Medical College, Bombay, India

Bandr Mzahim, MD
King Fahad Medical City, Riyadh, Saudi Arabia

Barry E. Brenner, MD, MPH
Case Western Reserve University

Brent King, MD, MMM
University of Texas, Houston

Daniel J. Dire, MD
University of Texas Health Sciences Center San Antonio

David F.M. Brown, MD
Massachusetts General Hospital/Harvard Medical School

Edward Michelson, MD
Texas Tech University

Edward Panacek, MD, MPH
University of South Alabama

Erik D. Barton, MD, MBA
Icahn School of Medicine, Mount Sinai, New York

Francesco Dellacorte, MD
Azienda Ospedaliera Universitaria "Maggiore della Carità," Novara, Italy

Francis Counselman, MD
Eastern Virginia Medical School

Gayle Galletta, MD
Sørlandet Sykehus HF, Akershus Universitetssykehus, Lorenskog, Norway

Hjalte Björnsson, MD
Icelandic Society of Emergency Medicine

Jacob (Kobi) Peleg, PhD, MPH
Tel-Aviv University, Tel-Aviv, Israel

Jonathan Olshaker, MD
Boston University

Katsuhiko Kanemaru, MD
University of Miyazaki Hospital, Miyazaki, Japan

Khrongwong Musikatavorn, MD
King Chulalongkorn Memorial Hospital, Chulalongkorn University, Bangkok, Thailand

Leslie Zun, MD, MBA
Chicago Medical School

Linda S. Murphy, MLIS
University of California, Irvine School of Medicine Librarian

Nadeem Qureshi, MD
*St. Louis University, USA
Emirates Society of Emergency Medicine, United Arab Emirates*

Niels K. Rathlev, MD
Tufts University School of Medicine

Pablo Aguilera Fuenzalida, MD
Pontificia Universidad Católica de Chile, Región Metropolitana, Chile

Peter A. Bell, DO, MBA
*Liberty University
College of Osteopathic Medicine*

Peter Sokolove, MD
University of California, San Francisco

Robert M. Rodriguez, MD
University of California, San Francisco

Robert Suter, DO, MHA
UT Southwestern Medical Center

Robert W. Derlet, MD
University of California, Davis

Rosidah Ibrahim, MD
Hospital Serdang, Selangor, Malaysia

Samuel J. Stratton, MD, MPH
Orange County, CA, EMS Agency

Scott Rudkin, MD, MBA
University of California, Irvine

Scott Zeller, MD
University of California, Riverside

Steven Gabaeff, MD
Clinical Forensic Medicine

Steven H. Lim, MD
Changi General Hospital, Simei, Singapore

Terry Mulligan, DO, MPH, FIFEM
ACEP Ambassador to the Netherlands Society of Emergency Physicians

Vijay Gautam, MBBS
University of London, London, England

Wirachin Hoonpongsimanont, MD, MSBATS
Siriraj Hospital, Mahidol University, Bangkok, Thailand

Advisory Board

Amal Khalil, MBA
UC Irvine Health School of Medicine

Elena Lopez-Gusman, JD
*California ACEP
American College of Emergency Physicians*

Janice Wachtler, BAE, CBA
American College of Osteopathic Emergency Physicians

John B. Christensen, MD
California Chapter Division of AAEM

Lori Winston, MD
*California ACEP
American College of Emergency Physicians
Kaweah Delta Healthcare District*

Mark I. Langdorf, MD, MHPE
UC Irvine Health School of Medicine

Nicholas T. Sawyer, MD, MBA
*California ACEP
American College of Emergency Physicians
University of California, Davis*

Peter A. Bell, DO, MBA
*American College of Osteopathic Emergency Physicians
Liberty University, College of Osteopathic Medicine*

Robert Suter, DO, MHA
*American College of Osteopathic Emergency Physicians
UT Southwestern Medical Center*

Shahram Lotfipour, MD, MPH
UC Irvine Health School of Medicine

Trevor Mills, MD, MPH
*California Chapter Division of AAEM
Northern California VA Health Care*

Jimmy To, BS
Editorial Director

Leila Danishgar, BS
Associate Editorial Director

Tushank Chadha, BS
Marketing Director to Media and Communications Director

Nancy G. Hernandez, BA
Executive Publishing Director

Dana Le, BS
WestJEM Publishing Director

Shashank Somasundaram, BS
CPC-EM Publishing Director

Cassandra Saucedo, BS
Associate Publishing Director

June Casey, BA
Copy Editor

Alissa Fiorentino, BA
WestJEM Staff Liaison

Editorial Staff

Official Journal of the California Chapter of the American College of Emergency Physicians, the American College of Osteopathic Emergency Physicians, and the California Chapter of the American Academy of Emergency Medicine



Available in MEDLINE, PubMed, PubMed Central, Google Scholar, eScholarship, DOAJ, and OASPA.

Editorial and Publishing Office: *WestJEM*/Department of Emergency Medicine, UC Irvine Health, 333 City Blvd, West, Rt 128-01, Orange, CA 92866, USA

Office: 1-714-456-6389; Email: Editor@westjem.org

Clinical Practice and Cases in Emergency Medicine

Indexed in PubMed and full text in PubMed Central

In Collaboration with the *Western Journal of Emergency Medicine*

This open access publication would not be possible without the generous and continual financial support of our society sponsors, department and chapter subscribers.

Professional Society Sponsors

AMERICAN COLLEGE OF OSTEOPATHIC EMERGENCY PHYSICIANS
CALIFORNIA ACEP

CALIFORNIA CHAPTER DIVISION OF
AMERICAN ACADEMY OF EMERGENCY MEDICINE

Academic Department of Emergency Medicine Subscriber

Albany Medical College Albany, NY	INTEGRIS Health Oklahoma City, OK	Robert Wood Johnson University Hospital New Brunswick, NJ	University of Florida, Jacksonville Jacksonville, FL
American University of Beirut Beirut, Lebanon	Kaweah Delta Health Care District Visalia, CA	Rush University Medical Center Chicago, IL	University of Illinois at Chicago Chicago, IL
Arrowhead Regional Medical Center Colton, CA	Kennedy University Hospitals Turnersville, NJ	Southern Illinois University Carbondale, IL	University of Illinois College of Medicine Peoria, IL
Augusta University Augusta GA	Kern Medical Bakersfield, CA	St. Luke's University Health Network Bethlehem, PA	University of Iowa Iowa City, IA
Baystate Medical Center Springfield, MA	Lakeland HealthCare St. Joseph, MI	Stanford/Kaiser Emergency Medicine Residency Program Stanford, CA	University of Louisville Louisville, KY
Beaumont Hospital Royal Oak, MI	Lehigh Valley Hospital and Health Network Allentown, PA	Staten Island University Hospital Staten Island, NY	University of Maryland Baltimore, MD
Beth Israel Deaconess Medical Center Boston, MA	Loma Linda University Medical Center Loma Linda, CA	SUNY Upstate Medical University Syracuse, NY	University of Michigan Ann Arbor, MI
Boston Medical Center Boston, MA	Louisiana State University Health Sciences Center New Orleans, LA	Temple University Philadelphia, PA	University of Missouri, Columbia Columbia, MO
Brigham and Women's Hospital Boston, MA	Madigan Army Medical Center Tacoma, WA	Texas Tech University Health Sciences Center El Paso, TX	University of Nebraska Medical Center Omaha, NE
Brown University Providence, RI	Maimonides Medical Center Brooklyn, NY	University of Alabama, Birmingham Birmingham, AL	University of South Alabama Mobile, AL
Carl R. Darnall Army Medical Center Fort Hood, TX	Maricopa Medical Center Phoenix, AZ	University of Arkansas for Medical Sciences Little Rock, AR	University of Southern California/Keck School of Medicine Los Angeles, CA
Conemaugh Memorial Medical Center Johnstown, PA	Massachusetts General Hospital Boston, MA	University of California, Davis Medical Center Sacramento, CA	University of Tennessee, Memphis Memphis, TN
Desert Regional Medical Center Palm Springs, CA	Mayo Clinic College of Medicine Rochester, MN	University of California Irvine Orange, CA	University of Texas, Houston Houston, TX
Doctors Hospital/Ohio Health Columbus, OH	Mt. Sinai Medical Center Miami Beach, FL	University of California, Los Angeles Los Angeles, CA	University of Texas Health San Antonio, TX
Eastern Virginia Medical School Norfolk, VA	North Shore University Hospital Manhasset, NY	University of California, San Diego La Jolla, CA	University of Warwick Library Coventry, United Kingdom
Einstein Healthcare Network Philadelphia, PA	Northwestern Medical Group Chicago, IL	University of California, San Francisco San Francisco, CA	University of Washington Seattle, WA
Emory University Atlanta, GA	Ohio State University Medical Center Columbus, OH	UCSF Fresno Center Fresno, CA	University of Wisconsin Hospitals and Clinics Madison, WI
Genesys Regional Medical Center Grand Blanc, Michigan	Ohio Valley Medical Center Wheeling, WV	University of Chicago, Chicago, IL	Wake Forest University Winston-Salem, NC
Hartford Hospital Hartford, CT	Oregon Health and Science University Portland, OR	University of Colorado, Denver Denver, CO	Wright State University Dayton, OH
Hennepin County Medical Center Minneapolis, MN	Penn State Milton S. Hershey Medical Center Hershey, PA	University of Florida Gainesville, FL	
Henry Ford Hospital Detroit, MI	Presence Resurrection Medical Center Chicago, IL		

State Chapter Subscriber

ARIZONA CHAPTER DIVISION OF THE
AMERICAN ACADEMY OF EMERGENCY MEDICINE
CALIFORNIA CHAPTER DIVISION OF THE
AMERICAN ACADEMY OF EMERGENCY MEDICINE
FLORIDA CHAPTER DIVISION OF THE
AMERICAN ACADEMY OF EMERGENCY MEDICINE

GREAT LAKES CHAPTER DIVISION OF THE
AMERICAN ACADEMY OF EMERGENCY MEDICINE
TENNESSEE CHAPTER DIVISION OF THE
AMERICAN ACADEMY OF EMERGENCY MEDICINE

UNIFORMED SERVICES CHAPTER DIVISION OF THE
AMERICAN ACADEMY OF EMERGENCY MEDICINE
VIRGINIA CHAPTER DIVISION OF THE
AMERICAN ACADEMY OF EMERGENCY MEDICINE

International Society Partners

EMERGENCY MEDICINE ASSOCIATION OF TURKEY
LEBANESE ACADEMY OF EMERGENCY MEDICINE
MEDITERRANEAN SOCIETY OF EMERGENCY MEDICINE

NORWEGIAN SOCIETY FOR EMERGENCY MEDICINE
SOCIEDAD ARGENTINA DE EMERGENCIAS

SOCIEDAD CHILENO MEDICINA URGENCIA
THAI ASSOCIATION FOR EMERGENCY MEDICINE

To become a *WestJEM* departmental sponsor, waive article processing fee, receive print and copies for all faculty and electronic for faculty/residents, and free CME and faculty/fellow position advertisement space, please go to <http://westjem.com/subscribe> or contact:

Alissa Fiorentino
WestJEM Staff Liaison
Phone: 1-800-884-2236
Email: sales@westjem.org

Clinical Practice and Cases in Emergency Medicine

Indexed in PubMed and full text in PubMed Central

In Collaboration with the *Western Journal of Emergency Medicine*

JOURNAL FOCUS

Clinical Practice and Cases in Emergency Medicine (CPC-EM) is a MEDLINE-indexed internationally recognized journal affiliated with the *Western Journal of Emergency Medicine* (WestJEM). It will offer the latest in patient care case reports, images in the field of emergency medicine and state of the art clinicopathological and medicolegal cases. CPC-EM is fully open-access, peer reviewed, well indexed and available anywhere with an internet connection. CPC-EM encourages submissions from junior authors, established faculty, and residents of established and developing emergency medicine programs throughout the world.

Table of Contents *continued*

- 43 **Abdominal Cerebrospinal Fluid Pseudocyst Diagnosed with Point-of-care Ultrasound**
BJ Guest, MH Merjanian, Emily F. Chiu, Caleb P. Canders
- 47 **The Use of Emergency Department Extracorporeal Membrane Oxygenation for Treatment of Acute Necrotizing Myocarditis**
CA Loner, PW Crane
- 51 **Ruptured Ectopic Pregnancy in the Presence of an Intrauterine Device**
MR Neth, MA Thompson, CB Gibson, JP Gullett, DC Pigott
- 55 **The Quick and Dirty: A Tetanus Case Report**
P Mcelaney, M Iyanaga, S Monks, E Michelson
- 59 **Acute Lymphoblastic Leukemia Presenting Solely as Low Back Pain**
J Goodwin, B Das
- 62 **Ruptured Tubal Ectopic Pregnancy at 15 Weeks Gestational Age: A Case Report**
JK Stremick

Images in Emergency Medicine

- 65 **Left Ventricular Thrombus in a 34-year-old Female Seen on Point-of-care Ultrasound**
F Khan, S Lahham
- 67 **Detection of Inferior Vena Cava Thrombosis Extending into the Right Atrium Using Point-of-care Ultrasound**
J Yanuck, G Ghanem, S Lahham
- 69 **Young Male with Seizures**
SM Ayyan, BX Kaliparrambil, SG Nair
- 71 **Multiple Carpometacarpal Dislocations**
A Davies, K Smith, W Eilbert
- 73 **Dyspnea in a Patient with Melanoma**
LJ Bontempo, N Seyoum
- 75 **A Benign Case of Hepatic Gas**
LK Hou, SLC Diaz, DL Kimball
- 77 **Superficial Temporal Artery Pseudoaneurysm Diagnosed by Point-of-Care Ultrasound**
SL Burluson, FN Cirillo, CB Gibson, JP Gullett, DC Pigott

Policies for peer review, author instructions, conflicts of interest and human and animal subjects protections can be found online at www.cpcem.org.

Clinical Practice and Cases in Emergency Medicine

Indexed in PubMed and full text in PubMed Central

In Collaboration with the *Western Journal of Emergency Medicine*

Table of Contents *continued*

- 79 **Pemphigoid Gestationis**
RM Kukkamalla, P Bayless
- 81 **Point-of-Care Ultrasound Diagnosis of Slipped Capital Femoral Epiphysis**
I Asad, MS Lee
- 83 **Diagnosis of Brachial Artery Thromboembolism with Point-of-care Ultrasound**
V Ceretto, M Lu
- 85 **Point-of-Care Ultrasound Diagnosis of Right Ventricular Rupture Post Cardiac Arrest After Thrombolysis in Myocardial Infarction**
J Miller, L Swarbrick, B Abdelhameed, T Carter
- 87 **Patient with Swollen Neck**
A Elegandhala, R Liu, H Wang

Clinical Practice and Cases in Emergency Medicine (CPC-EM) is a open-access Medline-indexed internationally recognized journal affiliated with the *Western Journal of Emergency Medicine* (WestJEM). CPC-EM is distributed electronically to 19,000 emergency medicine scholars. This includes our sponsors California ACEP, the American College of Osteopathic Emergency Physicians, California Chapter of AAEM, and over 83 academic department of emergency medicine subscribers and 8 AAEM State Chapters.

Western Journal of Emergency Medicine Call for Papers:



- **Social Emergency Medicine**
- **Systematic Review**



CALL FOR SECTION EDITORS!

WestJEM Integrating Emergency Care
with Population Health

- Behavioral Health
- Cardiac Care
- Clinical Practice
- International Medicine
- Pediatric Emergencies
- Public Health
- Trauma Care
- Ultrasound

Send your CV and letter of interest to
editor@westjem.org

Learn more at **WestJEM.org**

CPCEM Clinical
Practice
& Cases

- Case Reports
- Images in Emergency
Medicine
- Medical-Legal Case
Reports

**INDEXED in
PUBMED/PUBMED CENTRAL**

Send your CV and letter of interest to
editor@cpcem.org

Learn more at **CPCEM.org**

WestJEM Integrating Emergency Care
with Population Health

CPCEM Clinical
Practice
& Cases

Call for Reviewers!

Please send your CV and letter of interest to
editor@westjem.org

CPCEM Clinical
Practice
& Cases

CALL FOR SUBMISSIONS

- Patient Care Case Reports
- Images in Emergency Medicine
- Indexed in PubMed and PubMed Central

Fully open-access, peer reviewed: CPC-EM is available anywhere with an internet connection at **CPCEM.org**

Clinical Practice and Cases in Emergency Medicine is an internationally recognized companioned journal with the MEDLINE-indexed ***Western Journal of Emergency Medicine***

CPC-EM encourages submissions from junior authors and countries with developing emergency medicine programs

38-year-old Woman with a Cough and a Rash

Megan P. Donohue, MD, MPH*

Elizabeth P. Clayborne, MD, MA†

Zachary D.W. Dezman, MD, MS, MS†

Laura J. Bontempo, MD, MEd†

*University of Maryland Medical Center, Department of Emergency Medicine, Baltimore, Maryland

†University of Maryland School of Medicine, Department of Emergency Medicine, Baltimore, Maryland

Section Editor: Rick A. McPheeters, DO

Submission history: Submitted August 10, 2018; Revision received October 11, 2018; Accepted November 7, 2018

Electronically published January 4, 2019

Full text available through open access at http://escholarship.org/uc/uciem_cpccm

DOI: 10.5811/cpcem.2018.11.40591

[Clin Pract Cases Emerg Med. 2019;3(1):1–5.]

CASE PRESENTATION (Dr. Donohue)

A 38-year-old female presented to the emergency department (ED) with rash, dyspnea, odynophagia, and nasal congestion for the prior two weeks. During that time, she sought medical care twice. The first physician to evaluate the patient started her on antibiotics for a presumed upper respiratory infection (URI). Her symptoms did not improve after completing a 10-day course of amoxicillin; then a second medical provider prescribed her ciprofloxacin. She was on her eighth day of ciprofloxacin (i.e., total 18th day of treatment) when she presented to our ED with rash and dyspnea. She decided to come to the ED because her cough had worsened and become productive of sputum. She also complained of one month of fevers, chills, night sweats, and malaise. She denied any complaints of headaches, chest pain, palpitations, abdominal pain, genitourinary or neurologic symptoms.

Her past medical history was significant for adult-onset asthma and allergic rhinitis. Medications included fluticasone, ipratropium, and her recent courses of amoxicillin and ciprofloxacin. She had no known medication allergies but reported gastrointestinal intolerance to fish oil. Her family history was significant for a sister with multiple sclerosis. She was an Iranian immigrant who had moved to Baltimore six months prior to presenting in our ED. She was married with no children and denied ever using tobacco, alcohol or illicit drugs.

On physical exam, she was alert but appeared uncomfortable as she hobbled into triage that night. She was afebrile (36.7° Celsius) and mildly tachycardic (heart rate of 110 beats per minute). Her blood pressure was 102/68 millimeters of mercury, she was mildly tachypneic with a respiratory rate of 20 breaths per minute, and her oxygen saturation was 97% while breathing room air. She was well developed and well nourished, with an estimated body mass index of 22. Her head was normocephalic and atraumatic. Her oropharynx was clear; her neck was supple and no lymphadenopathy was detected. On auscultation, she was

tachycardic with a normal S1 and S2, without any murmurs, gallops or rubs. She was mildly tachypneic without any accessory muscle use, retractions, or increased work of breathing. She was able to speak in full sentences without difficulty. The patient's lungs were clear to auscultation bilaterally without wheezes, rhonchi, or rales. Her abdomen was soft and non-tender, and no lower extremity edema was present. She was alert, oriented and appropriately interactive.

On closer examination of the patient's skin, her rash appeared to have three different morphologies. The first was located on her forehead and consisted of sub-centimeter papulovesicular eruptions with petechiae that were pruritic but not tender (Image 1). The second rash consisted of scattered hemorrhagic vesicles with purpuric macules and was located on her distal upper and lower extremities (Image 2). The third rash was an erythematous and indurated plaque at the base of the left foot, which was tender and made it painful for her to walk.

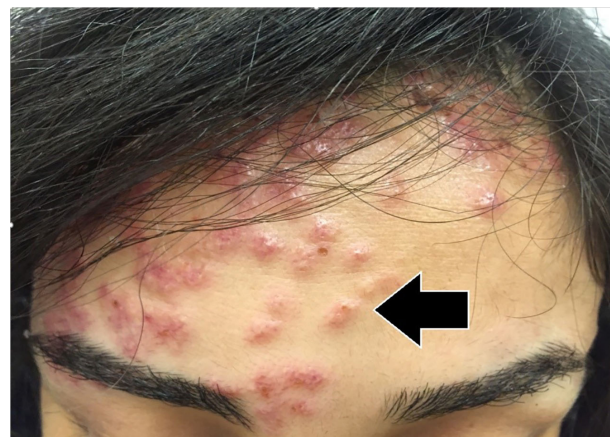

Image 1. Papulovesicular eruptions with petechiae on the forehead of the patient (arrow).

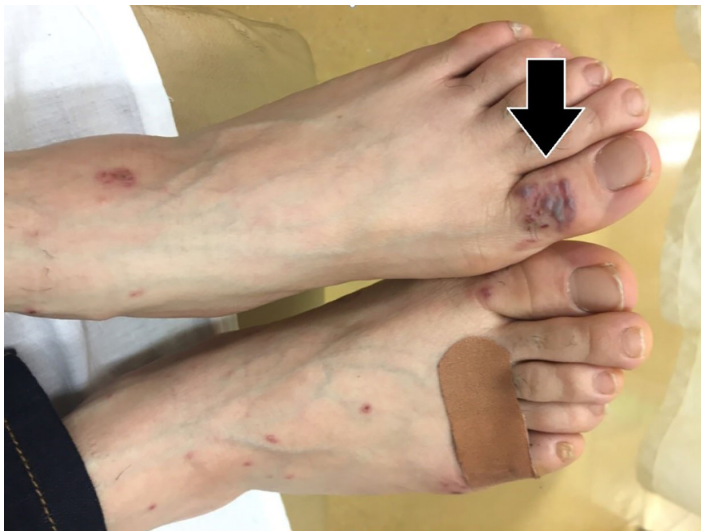

Image 2. Scattered hemorrhagic vesicles (arrow) with purpuric macules on the patient's feet.

Initial laboratory results are shown in Tables 1-3. The patient's electrocardiogram showed sinus tachycardia with normal intervals and without ST-segment or T-wave abnormalities. Bilateral multilobar infiltrates were revealed on chest radiograph (Image 3). A computed tomography (CT) of her chest confirmed the presence of bilateral multilobar infiltrates and a CT of her sinuses showed mucosal thickening throughout. An echocardiogram revealed a normal ejection fraction and no valvular pathology. No vegetations were seen. The patient was admitted to the hospital for further evaluation. A test then was performed, which confirmed the diagnosis.

CASE DISCUSSION (Dr. Clayborne)

My approach to cases that contain a lot of non-specific information is to first look at the big picture. I like to identify highlights from the history of present illness (HPI), past medical history, social history, review of symptoms (ROS) and physical examination to isolate what stands out most and may give insight into the differential. First impressions of the HPI were the story of a young female with a history of asthma and allergic rhinitis, who recently had a URI that was unresponsive to two different antibiotics. That patient then presented to the ED with a rash after taking ciprofloxacin. First impressions of the ROS highlighted that she had one month of constitutional symptoms and fatigue, nasal congestion, sore throat, a cough that was productive without hemoptysis and a new rash with pruritis. First impressions of social history included her status as an Iranian immigrant who did not drink, smoke or use drugs. Finally, first impressions from her physical examination included an afebrile, stable-appearing patient with tachycardia and tachypnea whose lungs were clear to auscultation bilaterally, who also had rashes of three different morphologies on her face, extremities, and the sole of one foot.

Table 1. Initial laboratory results of a 38-year-old female patient presenting with a rash and dyspnea.

	Values
Complete blood cell count	
White blood cell count (K/ μ L)	12.1
Hemoglobin (g/dL)	11.5
Hematocrit (%)	33
Platelets (K/ μ L)	237
Differential	
Granulocytes (%)	64.4
Lymphocytes (%)	15.3
Monocytes (%)	8.3
Eosinophils (%)	10.6
Serum chemistries	
Sodium (mmol/L)	141
Potassium (mmol/L)	3.5
Chloride (mmol/L)	100
Bicarbonate (mmol/L)	26
Blood urea nitrogen (mg/dL)	6
Creatinine (mg/dL)	0.54
Total protein (g/dL)	8.4
Albumin (g/dL)	3.8
Aspartate aminotransferase (u/L)	26
Alanine aminotransferase (u/L)	21
Alkaline phosphatase (u/L)	58

K, kilo; μ L, microliter; g, grams, dL, deciliter; mmol, millimoles; L, liter; mg, milligrams; u, units.

Immediately after my first impressions, the item that raised my concern the most was the rash. I find that many emergency physicians can be uncomfortable with rashes since we often find them difficult to properly describe, breaking the link between identifying a rash and making the diagnosis. In this case, the rash's location and characteristics were not specific to an etiology with which I was familiar. But I was able to combine the description of the rash with my first impressions to generate a preliminary differential diagnosis.

I subdivided my differential diagnosis into the three broad areas: infectious (bacterial, viral, or fungal); allergic; and autoimmune. Based on these three categories I began to use the data collected in the ED to help narrow my focus.

Pertinent positives from the lab work included a mild leukocytosis of 12.1 kilo/microliter with eosinophilia of 10.6%, urinalysis with trace blood, erythrocyte sedimentation rate of 70 millimeters per hour, a C-reactive protein of 3.3 milligrams per liter, and her screen for acquired human immunodeficiency virus was nonreactive. These are the labs that I would expect to result during the patient's ED visit. In

Table 2. Additional laboratory results of 38-year-old patient presenting with a rash and dyspnea.

Additional labs	Values
Human immunodeficiency virus screen	Non-reactive
Erythrocyte sedimentation rate (mm/hr)	70
C-reactive protein (mg/L)	3.3
Immunoglobulin E (KU/L)	6,266

Mm, millimeters; *hr*, hour; *mg*, milligrams; *L*, liter; *KU*, kilounits.

the ED I would also see her chest radiograph and CT chest showing bilateral multilobar infiltrates. With this information, if I were the treating physician, I would order antibiotics and admit the patient for an inpatient workup.

The results that would more likely be done during the inpatient stay demonstrated sinusitis, a normal cardiac ejection fraction, and an elevated Immunoglobulin E (IgE) of 6,266 kilounits per liter. Based on this additional data, I went back to my broad differential diagnosis to see what fit and did not fit each category. Allergic etiologies would include a rash, respiratory symptoms, and perhaps mild elevation of inflammatory markers but do not account for the constitutional symptoms or positive findings on radiograph and CT. Autoimmune etiologies would account for the constitutional symptoms, rash, and infiltrates but I would question why only a few of the inflammatory markers were elevated. Infectious etiologies, especially fungal infections, could account for the constitutional symptoms, pulmonary disease, eosinophilia, and elevated IgE.

My top two diagnoses based on the patient's presentation coupled with her laboratory results are eosinophilic granulomatous polyangiitis (EGPA), also known as Churg-Strauss syndrome, and aspergillosis. Invasive pulmonary aspergillosis starts when the patient becomes colonized by inhaling fungal spores. The patient's symptoms are often constitutional (weakness, fatigue, and low-grade fevers) and non-specific (shortness of breath and cough that is productive but not responsive to antibiotics). Patients often present with hemoptysis, which did not occur in this case. The infection can spread from the lower respiratory tree to multiple organs, most often the brain. These patients will then develop abnormalities on head CT (infarcts, ring-enhancing lesions, hemorrhage, abscess) and begin to suffer from seizures.

Patients with aspergillosis will often present with eosinophilia, elevated IgE levels, abnormal chest radiographs and CTs, sinusitis, and a characteristic rash. The rash begins as either solitary or multiple erythematous or violaceous, indurated papules or plaques. It can be tender and evolve rapidly into pustules, hemorrhagic vesicles, or eschars.¹ However, this patient does not

Table 3. Urinalysis of 38-year-old patient presenting with a rash and dyspnea.

Urinalysis	Values
pH	7
Specific gravity	1.003
Glucose	Negative
Ketones	Negative
Protein	Negative
Nitrile	Negative
Leukocyte esterase	Negative
White blood cells	None
Red blood cells	Trace

have any of the risk factors for aspergillosis (prolonged neutropenia, transplant [especially lung], prolonged high-dose corticosteroid therapy, hematological malignancy, cytotoxic therapy, or advanced acquired immune deficiency syndrome). This patient has sinusitis and no hemoptysis, both of which are inconsistent with aspergillosis.

EGPA was first described in 1951 by Churg and Strauss. They described a syndrome in 13 patients who had asthma, eosinophilia, granulomatous inflammation, necrotizing systemic vasculitis, and necrotizing glomerulonephritis. In 1990 the American College of Rheumatology (ACR) proposed the following six criteria for the diagnosis of EGPA:²

- Asthma (wheezing, expiratory rhonchi)
- Eosinophilia of more than 10% in peripheral blood
- Paranasal sinusitis
- Pulmonary infiltrates (may be transient)
- Histological proof of vasculitis with extravascular eosinophils
- Mononeuritis multiplex or polyneuropathy

This patient met four of these criteria (asthma, eosinophilia, sinusitis and pulmonary infiltrates), which is consistent with a diagnosis of EGPA (sensitivity of 85%, specificity of 99.7%).

If I were the treating physician, I would empirically treat with antifungals due to the concern for aspergillosis. For this case exercise, however, I believe a punch biopsy would confirm a diagnosis of EGPA.

CASE OUTCOME (Dr. Donohue)

The diagnostic study performed was a punch biopsy of a hemorrhagic vesicle on the right foot. It revealed two key findings: 1) eosinophils surrounding a central granuloma; and 2) the cross-section of a blood vessel with central necrosis. These findings confirmed the diagnosis of EGPA, also known as Churg-Strauss syndrome.

Our patient was admitted to an inpatient medical service, but the diagnostic punch biopsy was actually performed

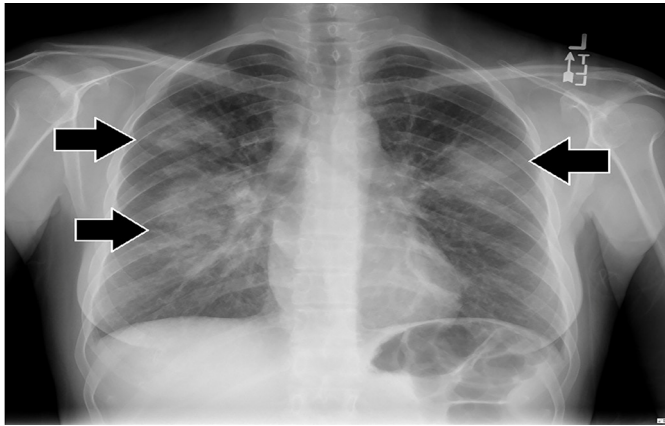


Image 3. Chest radiograph of a 38-year-old patient with rash and dyspnea, showing bilateral multi-lobe infiltrates (arrows).

in the ED prior to admission. While on the inpatient service, numerous consultants participated in her care including dermatology, rheumatology, pulmonology, and infectious disease. She underwent bronchoscopy, bronchoalveolar lavage and lung biopsy. Ultimately, based on the ACR EGPA criteria, she was diagnosed with EGPA and started on high-dose prednisone 60 milligrams (mg) daily.² On outpatient follow-up, she was transitioned to azathioprine and at one year follow-up was doing well.

RESIDENT DISCUSSION

EGPA is a rare vasculitis with an estimated incidence of one to three cases per million people. Early in the history of its recognition, reliable data on incidence were unavailable due to its similarities with other heterogeneous disease processes and lack of diagnostic criteria.³ EGPA was first described in 1951 by two young pathologists in New York City who were studying vasculitis. As pathologists, their case study data was obtained from autopsies in which they recognized “the occurrence of a clinical syndrome of severe asthma, fever and hypereosinophilia.”⁴ Keep in mind, this was in addition to the fact that these patients already had known vasculitis and were already deceased. However, it was “the finding of granulomatous lesions, both within vessel walls and in connective tissue” that made it distinct from other allergic syndromes and vasculitides.⁵ Churg and Strauss theorized that 11 of the 13 sentinel cases had died due to this syndrome to which they applied their eponym.

Since 1951 the underlying pathology and pathogenesis of EGPA has become better understood. As a result, the name was changed from Churg-Strauss syndrome to EGPA, which better describes the underlying disease process and the phases of its clinical manifestations. EGPA has three distinct clinical phases. The first, or prodromic, is characterized by onset of asthma in the second or third decade of life. It often is associated with allergic rhinitis and recurrent sinusitis. The second, eosinophilic, phase

is marked by peripheral eosinophilia with organ infiltration. Peripheral eosinophilia may be masked by steroid therapy.⁵ Eosinophilic organ infiltration occurs most commonly in the lungs, peripheral nerves and skin, but can occur in any organ system,⁶ creating an array of clinical presentations.⁷ This phase of the disease is difficult to distinguish from other hypereosinophilic conditions. The third phase of EGPA is vasculitic; this phase, which is unique to EGPA, makes it fatal if untreated.

Patients with pulmonary EGPA can develop pulmonary infarcts, nodules or diffuse alveolar hemorrhage. The most common CT findings include bilateral ground-glass opacities, airspace consolidation, centrilobular nodules and bronchial wall thickening.^{8,9} Infiltration of the heart can cause myocardial infarction, pericarditis or congestive heart failure. Central nervous system involvement may result in neuropathy, mononeuritis, seizure, stroke or coma. One study found that mononeuritis was the second most common presentation of EGPA, second only to asthma.⁸ In the gastrointestinal system EGPA can cause cholecystitis, pancreatitis or gastroenteritis. Vasculitic involvement of the renal system may result in proteinuria, hematuria, glomerulonephritis or renal insufficiency. Any of these complications may be a patient’s presenting symptoms; the case we highlighted is the most common presentation of EGPA. Organ system involvement is important due to its prognostic value as calculated by the five-factor score. If two or more of the following organ systems are involved, cardiac, gastrointestinal, nervous system or kidneys, five-year mortality is 50% untreated.⁹

Diagnostic criteria have changed over time. Churg and Strauss initially described a disease that only was diagnosed on biopsy. It was felt that an emphasis on biopsy and pathological findings led to the disease being underdiagnosed.¹⁰ The ACR revised the diagnostic criteria in 1990 to include more common features: the presence of asthma; eosinophilia >10% on white blood cell count differential; mononeuropathy or polyneuropathy; non-fixed pulmonary infiltrates on imaging; parasinus abnormality; or a characteristic biopsy. If four or more criteria were present, sensitivity was 85% and specificity 99.7%. Alternatively, if a patient had asthma, eosinophilia and history of allergy or drug sensitivity, sensitivity was 95% and specificity 99.2%.² Now that biopsy is no longer needed to confirm the diagnosis, a provider’s clinical index of suspicion portends significant impact in recognition and diagnosis of EGPA.

It has been suggested that anti-leukotriene medications may play a role in the development of EGPA, but this is controversial.¹¹⁻¹⁴ The current understanding is that prolonged survival of eosinophils due to inhibition of CD95-mediated apoptosis plays a role in EGPA pathogenesis. Recent data suggest that cytokine release from T-lymphocyte may be an important step.¹⁵ Even though the exact cause of EGPA has yet to be fully elucidated, treatment guidelines are available. High-dose glucocorticoids (1 mg/kg/day prednisone) for at least two to three weeks is the cornerstone for treatment to obtain remission.

EGPA responds well to first-line treatments, but relapse has been shown to occur in up to 25% of patients.¹⁰ Cyclophosphamide is the main pharmacotherapy for remission induction. Azothioprine and methotrexate are used for maintenance therapy for patients with life- or organ-threatening disease involvement. Intravenous immunoglobulin is considered second-line treatment for refractory disease. New treatment modalities currently being studied include plasma exchange and use of monoclonal antibodies.¹⁶ Treatment of EGPA should always include a multidisciplinary team, including rheumatology.

FINAL DIAGNOSIS

Eosinophilic granulomatous polyangiitis, also known as Churg-Strauss syndrome

KEY TEACHING POINTS

1. EGPA is a rare but deadly vasculitis.
2. Typical features of EGPA are asthma with allergic rhinitis and recurrent sinusitis, peripheral eosinophilia and vasculitis.
3. High clinical suspicion is paramount as it is a clinical diagnosis.
4. Differential diagnosis should be broadened when a patient has bounced back and already failed initial medical therapy.
5. Diagnostic momentum in the ED can play a pivotal role in making the correct diagnosis.

Documented patient informed consent and/or Institutional Review Board approval has been obtained and filed for publication of this case report.

Address for Correspondence: Zachary D.W. Dezman, MD, MS, MS, Department of Emergency Medicine, University of Maryland, 110 S Poca Street, 6th Floor, Suite 200, Baltimore, MD 21201. Email: zdezman@som.umaryland.edu.

Conflicts of Interest: By the CPC-EM article submission agreement, all authors are required to disclose all affiliations, funding sources and financial or management relationships that could be perceived as potential sources of bias. The authors disclosed none.

Copyright: © 2019 Donohue et al. This is an open access article distributed in accordance with the terms of the Creative Commons Attribution (CC BY 4.0) License. See: <http://creativecommons.org/licenses/by/4.0/>

REFERENCES

1. Kosmidis C and Denning DW. Republished: the clinical spectrum of pulmonary aspergillosis. *Postgrad Med J.* 2015;91(1077):403-10.
2. Masi AT, Hunder GG, Lie JT, et al. The American College of Rheumatology 1990 criteria for the classification of Churg-Strauss syndrome. *Arthritis Rheumatol.* 1990;33(8):1094-100.
3. Watts RA, Carruthers DM, Scott DG. Epidemiology of systemic vasculitis: changing incidence or definition? *Semin Arthritis Rheum.* 1995;25(1):28-34.
4. Churg J and Strauss L. Allergic granulomatosis, allergic angiitis and periarteritis nodosa. *Am J Pathol.* 1951;27(2):277-301.
5. Churg, A. Recent advances in the diagnosis of Churg-Struass syndrome. *Mod Pathol.* 2001;14(12):1284-93.
6. Chumbley LC, Harrison EG Jr, De Remeé RE. Allergic granulomatosis and angiitis (Churg-Strauss syndrome). *Mayo Clin Proc.* 1977;52(8):477-84.
7. Churg A, Brallas M, Stephen R, et al. Formes frustes of Churg-Strauss syndrome. *Chest.* 1995;108(2):320-3.
8. Guillevin L, Cohen P, Gayraud M, et al. Churg-Strauss syndrome: clinical study and long-term follow-up of 96 patients. *Medicine (Baltimore).* 1999;78(1):26-37.
9. Guillevin L, Lhote F, Gayraud M, et al. Prognostic factors in polyarteritis nodosa and Churg-Strauss syndrome. *Medicine (Baltimore).* 1996;75(1):17-28.
10. Lanham JG, Elkon KB, Pusey CD, et al. Systemic vasculitis with asthma and eosinophilia: A clinical approach to the Churg-Strauss syndrome. *Medicine (Baltimore).* 1984;63(2):65-81.
11. Noth I, Streck ME, Leff AR. Churg-Strauss syndrome. *Lancet.* 2003;361(9357):587-94.
12. Bili A, Condemi JJ, Bottone SM, et al. Seven cases of complete and incomplete forms of Churg-Strauss syndrome not related to leukotriene receptor antagonists. *J Allergy Clin Immunol.* 1999;104(5):1060-5.
13. Wechsler ME, Garpestad E, Flier SR, et al. Pulmonary infiltrates, eosinophilia, and cardiomyopathy following corticosteroid withdrawal in patients with asthma receiving zafirlukast. *JAMA.* 1998;279(6):455-7.
14. Churg A and Churg J. Steroids and Churg-Strauss. *Lancet.* 1998;352(9121):32-3.
15. Hellmich B, Ehlers S, Csernok E, et al. Update on the pathogenesis of Churg-Strauss syndrome. *Clin Exp Rheumatol.* 2003;21(6 Suppl 32):S69-77.
16. Navarro-Mendoza EP and Tobon GJ. Eosinophilic granulomatosis with polyangiitis: newer therapies. *Curr Rheumatol Rep.* 2018;20(5):23.

Occipital Nerve Blocks in the Emergency Department for Initial Medication-Refractory Acute Occipital Migraines

Justin Yanuck, MD, MS*
Sagar Shah, BS*
Maxwell Jen, MD, MBA*
Rakhi Dayal, MD†

*University of California, Irvine, Department of Emergency Medicine, Orange, California
†University of California, Irvine, Department of Anesthesiology, Orange, California

Section Editor: Rick A. McPheeters, DO

Submission history: Submitted July 18, 2018; Revision received December 6, 2018; Accepted January 1, 2019

Electronically published January 22, 2019

Full text available through open access at http://escholarship.org/uc/uciem_cpccem

DOI: 10.5811/cpcem.2019.1.39910

Migraines are consistently among the top 20 primary coded diagnoses in emergency departments, constituting 4.5% of all chief complaints. In a significant subset of these, pain arises from the occipital region innervated by the greater (GON) and lesser occipital nerve. In this case series, we present three patients with occipital migraines who received GON blockade with 1% lidocaine. The blockade was performed only after first-line treatment with metoclopramide and possibly additional medications as ordered by triage physician, failed to adequately alleviate pain by 40 minutes after medication administration. Patients were contacted a minimum of seven days following treatment. All three patients experienced significant analgesia and relief of symptoms within 15 minutes of blockade and sustained relief through a seven-day follow-up period. [Clin Pract Cases Emerg Med. 2019;3(1):6–10.]

INTRODUCTION

Up to 4.5% of emergency department (ED) visits carry a chief complaint of non-traumatic headache.¹ A subset of these headaches arise from the occipital region and are diagnosed as occipital migraines. The occipital nerve (of which the greater and lesser occipital nerves make up the primary sensory fibers) innervates the posterior aspect of the head to the vertex.²⁻⁴ While the etiology of an occipital migraine is unclear, there is evidence that local nerve blocks of the greater occipital nerve (GON) and the lesser occipital nerve (LON) contributes to analgesia by interrupting the facilitatory effect of GON stimulation on central pain sensitization of second-order neurons.^{5,6} Although there are currently multiple treatment options for occipital migraines, there is vast heterogeneity in treatment patterns among emergency physicians.⁷ While a majority of patients still receive opioids and non-steroidal anti-inflammatory medications for acute migraines, there is data to support that anti-dopaminergics (such as metoclopramide) offer superior therapeutic benefit with the most benign side-effect profile.^{8,9} However, further treatment modalities remain desirable given that even with metoclopramide, there is incomplete pain relief and high

recurrence of migraines within one month.¹⁰ In this case series, we describe three distinct patient cases who presented to the ED with occipital migraines that had incomplete resolution of pain following initial home abortive medications and then a 10 mg dose of metoclopramide, who subsequently underwent bedside occipital nerve block which achieved significant improvement in pain. We subsequently followed-up with these patients one week after the ED visit to evaluate their post-treatment symptom course.

CASE SERIES

Case 1

A 17-year-old female with history significant for twice-weekly migraines presented to the ED with 12 hours of a persistent right-sided occipital migraine described as constant, sharp, and 10/10 in severity. The patient had associated nausea, with no other neurologic symptoms, and no recent fever or head trauma. The patient took acetaminophen and sumatriptan at home, which helped for two hours, before subsequent recurrence. On exam, the patient had mild right occipital tenderness to palpation, with no midline spinal tenderness and no neurologic deficits. The patient received

metoclopramide 10 mg in triage and one liter of normal saline. Approximately 40 minutes after initial treatment, the patient noted her pain had improved from 10/10 to 8/10 severity. The patient then received one milliliter (mL) injection of 1% lidocaine 1cm to the right GON. Approximately 60 minutes after medications had been given, and ten minutes after occipital nerve block, the patient noted her pain improved to 2/10. During follow-up phone interview at seven days, the patient noted her symptoms completely resolved one hour after discharge, and that over last seven days she had not had any further migraines.

Case 2

A 48-year-old female presented to the ED with three days of persistent bilateral occipital pain that was constant, sharp in quality, and was 8/10 in severity. The patient had past medical history only significant for hyperlipidemia and migraines. The patient usually suffered one to two migraines per month. In addition to her headache, the patient also endorsed nausea and three episodes of emesis. She took sumatriptan, acetaminophen, and ibuprofen in the 48 hours prior to arrival with minimal relief. The patient denied any other symptoms. On exam, the patient was noted to have mild bilateral occipital tenderness to palpation and no neurological deficits or midline tenderness. In ED triage, the patient received metoclopramide 10 mg and ketoralac 15 mg intravenously. Approximately 60 minutes after the patient received these medications she was re-assessed and found to have persistent head pain rated at a 7/10 in severity. Bilateral GON blocks were administered with a total of one mL of 1% lidocaine to each site. At 15 minutes and 1.5 hours post-procedure, the patient reported pain improvement to 3/10. During follow-up phone interview at nine days post-emergency department visit, patient noted her pain had resolved over the course of 24 hours, with no recurrence of a migraine.

Case 3

A 37-year-old male presented to the ED with past medical history significant for anxiety and once monthly migraines. The patient described the pain as originating from the back of his head and radiating forward. The pain was located only to the right side, was constant and sharp in nature, and rated at a 10/10 in severity. The patient had the pain for 12 hours. The patient noted that the pain was typical for his migraine; however, his typical home abortive medication, ibuprofen, did not work for him on this occasion. The patient also tried one hydrocodone/acetaminophen 5/325 three hours prior to arrival (which he had obtained during previous emergency department visits for the same head pain) but without improvement. The patient denied any recent head trauma, fevers, or neurological deficits. On exam, the patient had no midline spinal tenderness, no motor/sensory deficits, or cranial nerve abnormalities. The patient was noted to have right occipital tenderness to

CPC-EM Capsule

What do we already know about this clinical entity?

Migraines are among the top 20 coded diagnoses in emergency departments, constituting 4.5% of all chief complaints.

What makes this presentation of disease reportable?

These cases present a simple bedside procedure that is not well known or practiced in the emergency department.

What is the major learning point?

Occipital nerve blocks are a possible treatment modality for occipital migraines.

How might this improve emergency medicine practice?

This report provides an additional tool to treat refractory migraines which is critical to improving outcomes, reducing costs, and providing quality care for patients.

palpation. The patient was given metoclopramide 10 mg, one liter of normal saline, and diphenhydramine 25 mg by the ED triage physician. Approximately 45 minutes after the medications were given, the patient was re-assessed and stated his pain had improved from a 10/10 to an 8/10. The patient then received one mL of 1% lidocaine to the right GON. Approximately 60 minutes after the patient received the initial medications, and three minutes after the patient received the occipital nerve block, the patient reported the pain had improved to 2/10. Follow-up phone call interview conducted at day eight revealed that the patient's migraine never recurred. The patient noted that his symptoms had completely resolved following the injection and that if he had a migraine again, he would preferentially seek out an occipital nerve block.

DISCUSSION

In this case series, we highlight three patients who presented to the emergency department with occipital migraines who failed to receive adequate relief of symptoms from initial conventional therapy. We demonstrate that a simple bedside procedure that can be performed by all emergency physicians can easily and safely provide patients with significant relief from treatment-refractory occipital migraines and with

sustained relief during a seven-day follow-up period. The above three patients all had migraines or probable migraines without aura as defined by the International Headache Society's International Classification of Headache Disorders (ICHD) with a self-reported majority of pain in the occipital region.¹¹ It is this subset of occipital migraine patients for whom we sought to elucidate whether occipital nerve blocks could provide relief of symptoms to initial treatment refractory pain.

Anesthetic nerve blockade for an occipital migraine is thought to exert its effects via modulation of cervical nociceptive signals that converge on the spinal trigeminal nucleus caudalis and subsequently travel to higher cortical structures. Both the GON and LON travel back through the second cervical vertebrae (C2) spinal nerve through the dorsal ramus (greater) and ventral ramus (lesser.) Nerve block studies for cervicogenic headaches found GON blockade to be as effective as complete C2 spinal nerve blockade¹², suggesting it makes little difference as to whether the pain is mediated by the GON or the LON. Given the relative ease of a single GON injection, we suggest GON blockade alone is sufficient for initial treatment of an occipital migraine in the ED.

While multiple techniques exist for the performance of the occipital nerve block, many involve a fanning technique and addition of some form of a steroid; there is no consensus as to what provides the most effective immediate and long-term relief of symptoms.¹³⁻¹⁶ For this case series, we chose to use a simple technique that requires only one needle insertion and does not include steroid. Either the left, right, or bilateral sides were prepped with a sterile alcohol pad. Utilizing a 27 gauge 1-3/8 inch needle, 1 milliliter of 1% lidocaine was injected at 90-degree angle to skin immediately medial to the occipital artery with care taken to target the occiput above the intermastoid line (the imaginary line between the external occipital protuberance and the mastoid process). The needle is inserted until it hits bone, which is usually about 1 centimeter and then withdrawn slightly off of the bone before infiltration with the lidocaine. This anesthetizes the GON.¹⁷ If the occipital artery could not be detected by palpation, the injection was made 1-2 cm lateral to external occipital protuberance given that the GON typically lies 1-2 cm lateral to the external occipital protuberance (Figure, Video).

Migraines are consistently among the top 20 primary coded diagnoses in emergency departments.¹⁸ Furthermore, the 2007 Centers for Disease Control and Prevention ambulatory medical utilization estimates found that 18% of all migraine care occurs in an emergency department setting.¹⁸ Given migraines are just one of many clinical diagnoses for which opioids might be indicated, ED physicians are the most frequent "first-prescribers" of opioids.¹⁹ While in this case series no ED provider prescribed opioids as initial therapy for these patients' occipital migraines, it is our experience that for many patients who experience initial treatment-refractory migraines, many ED providers will utilize opioids as the next

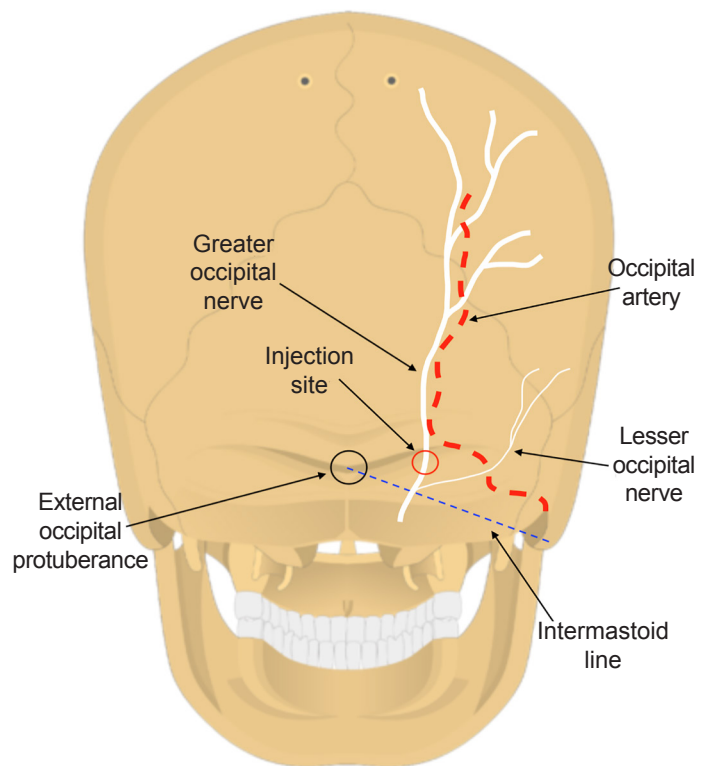


Figure. The diagram demonstrates the location of the intermastoid line, external occipital protuberance, greater occipital nerve, and lesser occipital nerve. The injection site is located just medial to the occipital artery and should be targeted above the intermastoid line. The needle is inserted until it hits bone and retracted slightly off of the surface.

treatment modality. In fact, a 2017 study found that opioids were prescribed in 36% of migraine diagnoses in three diverse emergency departments. In 30% of those cases, those opioids were given as first-line treatment. Alternatively, in 49% of those cases, opioids were given as rescue therapy (within 60 minutes of initial diagnoses) when initial treatment was ineffective.²⁰ Although there is variation in opioid prescription rates by practice setting, these findings are not reflective of the guidelines recommending against opioids for migraines. Providing emergency physicians with an additional tool to effectively treat refractory migraines without opioid therapy is critical to improving outcomes, reducing costs, and providing quality care for patients.

The use of triptans, beta-blockers, anticonvulsants, antidepressants, and opioids for the treatment of migraines may have unsatisfactory efficacy or undesirable systemic effects.^{10,21-22} In the three cases presented here, the patients came to the ED because abortive therapy was ineffective. Beyond failing to reduce the pain during initial presentation, these medications may be poorly tolerated long-term; furthermore, noncompliance or misuse may lead to the chronification of

migraines. Prior data indicates that one in five patients will discontinue preventative medications for tolerability or safety concerns.²¹ Less than a quarter of patients prescribed oral preventative medications will remain compliant for more than 12 months following initial treatment.²² The management of treatment-refractory migraine challenges emergency physicians to provide adequate pain relief, minimize time spent in the ED, prevent repeat ED visits, and minimize the risk of substance abuse. As shown here, occipital nerve blocks possibly provide a tool that could address some of these concerns.

CONCLUSION

The three cases presented here suggest occipital nerve blocks could potentially be used to alleviate treatment-refractory migraines in the ED. Often times, when a first-line therapy, such as metoclopramide which was given to these patients, fails to alleviate migraine pain, many emergency departments use opioids as rescue therapy.¹⁸ Although this small case series does nothing to formally establish the efficacy of occipital nerve blocks for initial treatment refractory occipital migraines, it does highlight a useful tool that could be tried by an emergency physician. Current evidence for the effectiveness of occipital nerve blocks in the management of chronic migraines justifies the additional study of occipital nerve block use for acute occipital migraines that present to the ED. Future direction includes a prospective randomized controlled study to assess the role of this technique in patients presenting to the ED with a refractory occipital migraine.

Video. Demonstration of occipital nerve block for the treatment of refractory occipital migraine.

Documented patient informed consent and/or Institutional Review Board approval has been obtained and filed for publication of this case report.

Address for Correspondence: Justin Yanuck, MD, MS, University of California, Irvine, Department of Emergency Medicine, 333 City Blvd West, Suite 640, Orange, CA 92868. Email: jyanuck@uci.edu.

Conflicts of Interest: By the CPC-EM article submission agreement, all authors are required to disclose all affiliations, funding sources and financial or management relationships that could be perceived as potential sources of bias. The authors disclosed none.

Copyright: © 2019 Yanuck et al. This is an open access article distributed in accordance with the terms of the Creative Commons Attribution (CC BY 4.0) License. See: <http://creativecommons.org/licenses/by/4.0/>

REFERENCES

1. Torelli P, Campana V, Cervellin G, et al. Management of primary headaches in adult Emergency Departments: a literature review, the Parma ED experience and a therapy flow-chart proposal. *Neurol Sci.* 2010;31(5):545-53.
2. Güvençer M, Akyer P, Sayhan S, et al. The importance of the greater occipital nerve in the occipital and the suboccipital region for nerve blockade and surgical approaches—An anatomic study on cadavers. *Clin Neurol Neurosurg.* 2011;113(4):289-94.
3. Gilroy AM, MacPherson BR, Ross LM, et al. Neurovasculature of the Skull & Face. In: Atlas of anatomy. New York, New York: Thieme; 2008;488-504.
4. Fujimaki T, Son JH, Takanashi S, et al. Preservation of the lesser occipital nerve during microvascular decompression for hemifacial spasm. *J Neurosurg.* 2007;107(6):1235-7.
5. Bartsch T and Goadsby, PJ. Stimulation of the greater occipital nerve induces increased central excitability of dural afferent input. *Brain.* 2002;125(7):1496-509.
6. Ossipov MH, Dussor GO, Porreca F. Central modulation of pain. *J Clin Invest.* 2010;120(11):3779-87.
7. Vinson DR. Treatment patterns of isolated benign headache in US emergency departments. *Ann Emerg Med.* 2002;39(3):215-22.
8. Friedman BW, West J, Vinson DR, et al. Current management of migraine in US emergency departments: An analysis of the National Hospital Ambulatory Medical Care Survey. *Cephalalgia.* 2015;35(4):301-9.
9. Orr SL, Friedman BW, Christie S, et al. Management of Adults With Acute Migraine in the Emergency Department: The American Headache Society Evidence Assessment of Parenteral Pharmacotherapies. *Headache.* 2016;56(6):911-40.
10. Colman I, Brown MD, Innes GD et al. Parenteral metoclopramide for acute migraine: meta-analysis of randomised controlled trials. *BMJ.* 2004;329(7479):1369-73.
11. Headache Classification Committee of the International Headache Society (IHS). The international classification of headache disorders, (beta version). *Cephalalgia.* 2013;33(9):629-808.
12. Bovim G, Berg R, Dale LG. Cervicogenic headache: anesthetic blockades of cervical nerves (C2-C5) and facet joint (C2/C3). *Pain.* 1992;49(3):315-20.
13. Anthony, M. Cervicogenic headache: prevalence and response to local steroid therapy. *Clin Exp Rheumatol.* 2000;18(2 Suppl 19):S59-64.
14. Inan N, Ceyhan A, Inan L, et al. C2/C3 Nerve blocks and greater occipital nerve block in cervicogenic headache treatment. *Funct Neurol.* 2001;16(3):239-43.
15. Naja ZM, El-Rajab M, Al-Tannir MA, et al. Occipital nerve blockade for cervicogenic headache: a double-blind randomized controlled clinical trial. *Pain Pract.* 2006;6(2):89-95.
16. Young WB, Marmura M, Ashkenazi A, et al. Expert opinion: greater occipital nerve and other anesthetic injections for primary headache disorders. *Headache.* 2008;48(7):1122-5.
17. Ward JB. Greater occipital nerve block. *Semin Neurol.* 2003;23(1):59-62.

18. Schappert SM and Rechsteiner EA. Ambulatory medical care utilization estimates for 2007. *CDC Stacks*. 2011;169:1-38.
19. Minen MT, Lindberg K, Wells RE, et al. Survey of opioid and barbiturate prescriptions in patients attending a tertiary care headache center. *Headache*. 2015;55(9):1183-91.
20. Young N, Silverman D, Bradford H, et al. Multicenter prevalence of opioid medication use as abortive therapy in the ED treatment of migraine headaches. *Am J Emerg Med*. 2017;35(12):1845-9.
21. Gracia-Naya M, Santos-Lasaosa S, Rios-Gomez C, et al. Predisposing factors affecting drop-out rates in preventive treatment in a series of patients with migraine. *Rev Neurol*. 2011;53(4):201-8.
22. Hepp Z, Dodick DW, Varon SF, et al. Adherence to oral migraine-preventive medications among patients with chronic migraine. *Cephalalgia*. 2015;35(6):478-88.

Point-of-care Ultrasound Diagnosis of Pulmonary Embolism with Thrombus in Transit

Nicolas Kahl, BS
Christopher Gabriel, BS
Shadi Lahham, MD, MS
Maxwell Thompson, MD
Wirachin Hoonpongsimanont, MD, MS

University of California, Irvine, Department of Emergency Medicine,
Orange, California

Section Editor: Manish Amin, DO

Submission history: Submitted July 31, 2018; Revision received October 25, 2018; Accepted November 7, 2018

Electronically published January 4, 2019

Full text available through open access at http://escholarship.org/uc/uciem_cpchem

DOI: 10.5811/cpchem.2018.11.40377

A 95-year-old female with a history of dementia and atrial fibrillation (not on anticoagulation) presented to the emergency department (ED) by ambulance from her skilled nursing facility due to hypoxia. Point-of-care ultrasound was performed, and showed evidence of a large mobile thrombus in the right ventricle on apical four-chamber view. Further evidence of associated right heart strain was seen on the corresponding parasternal short-axis view. These ultrasound findings in combination with the patient's clinical presentation are diagnostic of acute pulmonary embolism with right heart strain. Point-of-care transthoracic cardiac ultrasound in the ED is an effective tool to promptly diagnose acute pulmonary embolism with right heart strain and thrombus in transit and guide further treatment. [Clin Pract Cases Emerg Med. 2019;3(1):11–12.]

INTRODUCTION

Deep venous thrombosis (DVT) and pulmonary embolism (PE) are dangerous conditions frequently encountered in the emergency department (ED). Clinical presentation along with diagnostic modalities, including computed tomography (CT), ultrasound and laboratory testing, may be used to arrive at the diagnosis. Thrombus in transit is defined on ultrasound as mobile echogenic material temporarily present in the right heart chambers on its way to the pulmonary circulation, and it is diagnostic of PE.⁷ We present a case report of an elderly female who was brought by ambulance to the ED in acute respiratory distress, and was immediately evaluated with point-of-care ultrasound (POCUS).

CASE REPORT

A 95-year-old female with a history of dementia and atrial fibrillation (not on anticoagulation) presented to the ED by ambulance from her skilled nursing facility due to hypoxia. The patient had been requiring 2-4 liters of oxygen via nasal cannula at her nursing facility; however, in the ED the patient's oxygen saturation was 80% on a non-rebreather face mask. Physical exam was notable for tachycardia, tachypnea, use of accessory muscles for respiration, and somnolence. The patient did not have clinical signs of DVT such as unilateral leg swelling or

calf tenderness. Of note, the patient had an allergy to iodinated contrast. POCUS was performed and showed evidence of a large mobile thrombus in the right ventricle on apical four-chamber view (Video). Further evidence of associated right heart strain was seen in the corresponding parasternal short-axis view. There was no evidence of a pericardial effusion. These ultrasound findings in combination with the patient's clinical presentation were diagnostic of acute PE with right heart strain.^{1,2} The patient's family arrived in the ED, and her code status was established as "do not resuscitate" with comfort measures only. Further imaging, fibrinolysis and thrombectomy were not attempted in accordance with the patient's wishes.

DISCUSSION

DVT and associated PE is a potentially devastating problem encountered in the ED. The gold standard for diagnosis is CT angiogram. However, in order to undergo CT angiography patients must have adequate renal function and cannot have contrast allergies.⁶ A visible right heart thrombus on ultrasound is a rare finding in acute PE and is associated with a poor prognosis.³ The high mortality rate of 44.7% is due to the potential for imminent embolization to the pulmonary arteries, which can cause obstructive shock.³ Other evidence of right heart strain on ultrasound includes

bowing of the intraventricular septum into the left ventricle, right ventricular systolic dysfunction, and McConnell's sign. McConnell's sign is the most specific finding at 94% and is defined as right ventricular free wall akinesis with sparing of the apex.⁴ POCUS allows for rapid diagnostic assessment that can guide therapy for time-sensitive, critically ill patients. Furthermore, in patients with contraindications to iodinated contrast, ultrasound is an acceptable alternative to CT angiogram. Our patient's allergy to iodine made ultrasound preferable to CT angiogram. Immediate thrombolysis or surgical embolectomy to prevent circulatory collapse should be considered in these high-risk patients with signs of right ventricular dysfunction and visible thrombi in transit.⁵

CONCLUSION

Point-of-care transthoracic cardiac ultrasound in the ED is an effective tool to promptly diagnose acute pulmonary embolism with right heart strain and thrombus in transit and guide further treatment. Our patient was 95 years old and wanted comfort measures only, but the use of cardiac ultrasound could have expedited potentially life-saving fibrinolysis or thrombectomy if she had wanted it. The risk of delaying medical decision-making and treatment of acute pulmonary embolism with right heart strain makes the consideration of using rapid point-of-care transthoracic cardiac ultrasound in this setting critically important for emergency physicians.

Video. Apical four-chamber view of the heart shows mobile thrombus in transit between the right atrium and right ventricle. There is right atrial dilation and evidence of McConnell's sign.

Documented patient informed consent and/or Institutional Review Board approval has been obtained and filed for publication of this case report.

Address for Correspondence: Shadi Lahham, MD, MS, University of California, Irvine, Department of Emergency Medicine, 333 The City Boulevard West, Suite 640, Orange, CA, 92868. Email: slahham@uci.edu.

Conflicts of Interest: By the CPC-EM article submission agreement, all authors are required to disclose all affiliations, funding sources and financial or management relationships that could be perceived as potential sources of bias. The authors disclosed none.

Copyright: © 2019 Kahl et al. This is an open access article distributed in accordance with the terms of the Creative Commons Attribution (CC BY 4.0) License. See: <http://creativecommons.org/licenses/by/4.0/>

CPC-EM Capsule

What do we already know about this clinical entity?
Pulmonary embolism (PE) is frequently encountered in the emergency department. Clinical presentation and various diagnostic modalities are used to arrive at the diagnosis.

What makes this presentation of disease reportable?
Thrombus in transit is a rare finding on ultrasound, and has important diagnostic and therapeutic implications in management of PE.

What is the major learning point?
Point-of-care ultrasound (POCUS) can be used to rapidly diagnose pulmonary embolism and guide management and intervention prior to computed tomography angiogram or further diagnostic testing.

How might this improve emergency medicine practice?
Emergency physicians can consider POCUS as a first-line diagnostic modality in a patient who presents with clinical concern for PE.

REFERENCES

1. Mousavi N, Jassal DS, Moon MC, et al. Thrombus in transit. *Can J Cardiol.* 2010;26(3):e133.
2. Alraies M, Blake D, Browning J. Multimodality imaging of thrombus in transit. *Eur Heart J.* 2014;35(43):3000.
3. Chartier L, Béra J, Delomez M, et al. Free-floating thrombi in the right heart: diagnosis, management, and prognostic indexes in 38 consecutive patients. *Circulation.* 1999;99(21):2779–83.
4. McConnell MV, Solomon SD, Rayan ME, et al. Regional right ventricular dysfunction detected by echocardiography in acute pulmonary embolism. *Am J Cardiol.* 1996;78(4):469–73.
5. Puls M, Hünlich M, Schillinger W. Free-floating right heart thrombi in pulmonary embolism: therapeutic options and differential diagnosis. *Dtsch Med Wochenschr.* 2014;139(17):887–91.
6. Remy-Jardin M, Pistolesi M, Goodman L, et al. "Management of Suspected Acute Pulmonary Embolism in the Era of CT Angiography: A Statement from the Fleischner Society." *Radiology.* 2007;245(2):315–29.
7. Arboine-Aguirre L, Figueroa-Calderón E, Ramírez-Rivera A, et al. Thrombus in transit and submassive pulmonary thromboembolism successfully treated with tenecteplase. *Gac Med Mex.* 2017;153(1):129–33.

Early Identification of Central Retinal Artery Occlusion Using Point-of-care Ultrasound

Ben Stoner-Duncan, MD
Stephen C. Morris, MD, MPH

University of Washington School of Medicine, Department of Emergency Medicine,
Seattle, Washington

Section Editor: Shadi Lahham, MD, MS

Submission history: Submitted June 15, 2018; Revision received October 27, 2018; Accepted November 7, 2018

Electronically published January 4, 2019

Full text available through open access at http://escholarship.org/uc/uciem_cpem

DOI: 10.5811/cpem.2018.11.39406

A 69-year-old woman with a history of untreated hypertension presented with acute-onset monocular vision loss. Initial workup was delayed due to lack of immediate specialty consultation and dilated fundoscopic exam. Point-of-care ultrasound in the emergency department identified a small hyperechoic structure within the distal area of the central retinal artery; in conjunction with specialty ophthalmologic evaluation in a tertiary care center, the diagnosis of central retinal artery occlusion was made. The patient was admitted to the neurology service for stroke risk stratification and was discharged in stable condition with re-initiation of her antihypertensive medication regimen. [Clin Pract Cases Emerg Med. 2019;3(1):13–15.]

INTRODUCTION

Painless vision loss represents a small proportion of emergency department (ED) visits but can portend not only an acute threat to vision, but also significant systemic pathology. Thromboembolic disease related to cardiovascular or stroke risk factors,¹ rheumatologic disease such as giant cell arteritis, or pathology localized to the eye can all present in a similar fashion.² For many causes of acute painless vision loss, dilated fundoscopic exam is considered the gold standard for diagnosis; however, this can be a challenging exam in some patients, especially in resource-limited settings without expert consultation available. It has previously been shown that point-of-care ultrasound (POCUS) can be used to reliably evaluate arterial and venous flow in cases of retinal vessel compromise using color Doppler imaging,³ and to directly visualize retinal artery thrombus.⁴ Here we present a case of central retinal artery occlusion (CRAO) identified by POCUS, with evidence of edematous optic nerve, a previously undescribed ocular ultrasound finding in the evaluation of CRAO.

CASE REPORT

A 69-year-old woman presented to the ED with painless vision loss in her left eye. She stated that over the course of minutes, she completely lost vision in that eye, with onset approximately six hours prior to evaluation. Initially, there was concern for posterior circulation arterial stroke, as the patient had elected to stop taking her antihypertensive medications one

year prior. A computed tomography (CT) of the head showed no evidence of intracranial hemorrhage, and a magnetic resonance imaging (MRI) evaluation of the brain showed no evidence of acute stroke. The patient's fundoscopic exam was limited by constricted pupils, and she was transferred to a tertiary care academic medical center for ophthalmologic evaluation.

On arrival to the tertiary care center, the ED team performed a POCUS, linear probe, 12 MegaHertz (MHz) of the patient's eye to evaluate for retinal detachment. No evidence of retinal detachment, vitreous detachment, or massive vitreous hemorrhage was found. However, the study demonstrated a widened and irregular optic nerve sheath, which measured over the normal limit of five millimeters (mm).⁵ Additionally, an area of hyperechoic signal was noted in the distal aspect of the optic nerve, raising concern for embolic event (Image). Additional radiologist review of the patient's MRI showed no evidence of embolism in that area. Ophthalmology was consulted and performed a dilated fundoscopic exam, with direct visualization of a pale, occlusive object within the central retinal artery.

The patient was admitted to the neurology service for monitoring of permissive hypertension initially, and then resumption of an antihypertensive medication regimen. The timing of symptom onset was a contraindication for thrombolytic treatment. Rapid stroke-risk stratification demonstrated no echocardiographic evidence of cardiac source of her embolus, no right-to-left cardiac shunt, and no significant carotid stenosis on CT angiography. She was re-initiated on her outpatient

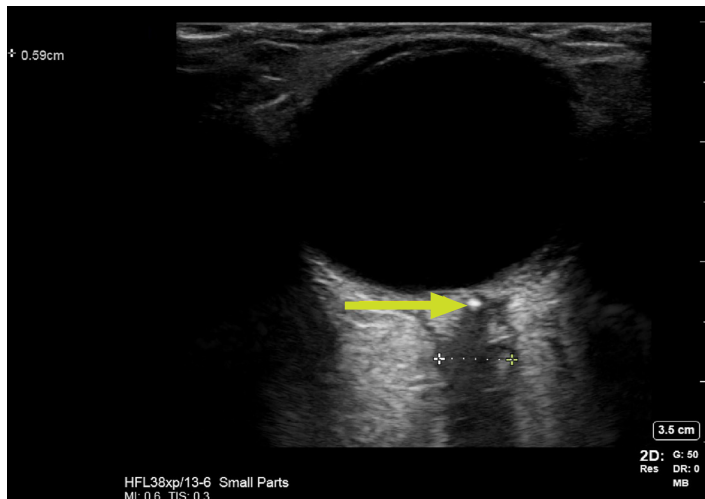


Image. Point-of-care ultrasound of left eye with linear probe small-parts setting, demonstrating likely clot (yellow arrow) and edematous optic nerve (measured at 3.5cm).

antihypertensive medications, and on two-month follow-up she had no significant return of vision in her left eye and had no evidence of further embolic events.

DISCUSSION

POCUS is of increasing utility to the emergency physician. The optic globe, as a superficial fluid-filled object, lends itself to reliable ultrasound imaging with potential diagnostic utility in a number of acute ophthalmologic emergencies.⁶ Here we present an instance of CRAO identified rapidly on POCUS. Multiple prior studies have reported on ultrasonographic findings related to CRAO. A prior study of 29 patients diagnosed with CRAO, but without evidence of retinal plaque on funduscopy, revealed that 31% showed retrobulbar hyperechoic foci on orbital color Doppler imaging.³

In another study, 59% of patients with CRAO were found to have an “intra-arterial spot sign,” which was associated with lack of response to thrombolytic therapy. This lack of response is thought to be primarily due to calcific components of likely carotid thromboembolic plaque, which is not amenable to thrombolysis.⁷ Elucidating cardiovascular risk factors associated with retinal artery occlusions, 79.8% of patients with CRAO had hypertension, as did our patient. Although dilated funduscopy exam reveals pale macula and a “cherry red spot” in the vast majority of cases, only 11% of CRAO thrombi were directly visualized funduscopically.¹ Given the possibility of diagnostic uncertainty and delay in specialty consultation, this indicates that POCUS may offer a more rapid diagnosis of this important entity and could also aid in diagnostic reliability.

The finding of edematous optic nerve may provide another reproducible finding, though this has not been well described in the literature. A measurement pattern has been established to have a sensitivity of 88% and specificity of 93% for optic

CPC-EM Capsule

What do we already know about this clinical entity?
These findings have been well documented in other imaging sources, particularly magnetic resonance imaging. Use of ultrasound has been reported and quantified but is not widely disseminated in the literature.

What makes this presentation of disease reportable?
The image gives a guide to practicing physicians as to appearance of the edematous optic nerve.

What is the major learning point?
Incorporating ultrasound in the evaluation and management of patients presenting with vision loss could potentially speed the diagnosis of central retinal artery occlusion.

How might this improve emergency medicine practice?
Emergency physicians reading this article would be able to incorporate ultrasound in evaluation and management of patients presenting with vision loss, potentially speeding the diagnosis of central retinal artery occlusion.

nerve sheath edema due to intracranial pressure of greater than 20 centimeters water based on an optic nerve sheath diameter of greater than 5mm.⁵ In our reported case, it is biologically plausible that this finding was related to time after occlusion, and may be able to provide some evidence of the timing of occlusion onset in cases with an unclear “last known normal.” This measurement, combined with previously described Doppler studies may also offer increased sensitivity for rapid POCUS diagnosis. More rapid diagnosis in cases of CRAO allows for possible interventions such as ocular massage, thrombolysis, surgical intervention to lower intra-ocular pressure and earlier initiation of stroke workup in order to reduce patient risk. Future studies should focus on reliability of optic sheath measurement in reaction to CRAO, and occurrence of ultrasound-evident occlusive emboli in these cases.

CONCLUSION

Central retinal artery occlusion is a rare presentation to the ED; however, it represents significant pathology, with concerns for long-term disability (vision loss) and possible life-threatening associated conditions (stroke.) Use of point-of-care ultrasound represents an opportunity to make a rapid and accurate diagnosis of CRAO.

Documented patient informed consent and/or Institutional Review Board approval has been obtained and filed for publication of this case report.

Address for Correspondence: Stephen C. Morris, MD, MPH, University of Washington School of Medicine, Department of Emergency Medicine, 325 9th Ave Seattle, WA 98104. Email: stephenmorrismd@gmail.com.

Conflicts of Interest: By the *CPC-EM* article submission agreement, all authors are required to disclose all affiliations, funding sources and financial or management relationships that could be perceived as potential sources of bias. The authors disclosed none.

Copyright: © 2019 Stoner-Duncan et al. This is an open access article distributed in accordance with the terms of the Creative Commons Attribution ([CC BY 4.0](https://creativecommons.org/licenses/by/4.0/)) License. See: <http://creativecommons.org/licenses/by/4.0/>

REFERENCES

1. Schmidt D, Hetzel A, Geibel-Zehender A, et al. Systemic diseases in non-inflammatory branch and central retinal artery occlusion-an overview of 416 patients. *Eur J Med Res.* 2007;12(12):595-603.
2. Beran DI and Murphy-Lavoie H. Acute, painless vision loss. *J La State Med Soc.* 2009;161(4):214-26.
3. Foroozan R, Savino PJ, Sergott RC. Embolic central retinal artery occlusion detected by orbital color Doppler imaging. *Ophthalmology.* 2002;109(4):744-7.
4. Riccardi A, Siniscalchi C, Lerza R. Embolic central retinal artery occlusion detected with point-of-care ultrasonography in the emergency department. *J Emerg Med.* 2016;50(4):e183-5.
5. Kimberly HH, Shah S, Marill K, et al. Correlation of optic nerve sheath diameter with direct measurement of intracranial pressure. *Acad Emerg Med.* 2008;15(2):201-4.
6. Blaivas M, Theodoro D, Sierzenski PR. A study of bedside ocular ultrasonography in the emergency department. *Acad Emerg Med.* 2002;9(8):791-9.
7. Rudkin AK, Lee AW, Chen CS. Vascular risk factors for central retinal artery occlusion. *Eye (Lond).* 2010;24(4):678-81.

Emergent Treatment of Neuroleptic Malignant Syndrome Induced by Antipsychotic Monotherapy Using Dantrolene

Vivian Ngo, MD*
Alfredo Guerrero, BA†
David Lanum, MD*‡
Michelle Burgett-Moreno, BA†
Gregory Fenati, DO†‡
Steven Barr, MD§
Michael M. Neeki, DO, MS†‡

*Arrowhead Regional Medical Center, Department of Family Medicine, Colton, California
†Arrowhead Regional Medical Center, Department of Emergency Medicine, Colton, California
‡California University of Sciences and Medicine, Department of Emergency Medicine, Colton, California
§Arrowhead Regional Medical Center, Department of Anesthesia, Colton, California

Section Editor: Steve Walsh, MD

Submission history: Submitted July 10, 2018; Revision received October 11, 2018; Accepted November 7, 2018

Electronically published January 4, 2019

Full text available through open access at http://escholarship.org/uc/uciem_cpccem

DOI: 10.5811/cpccem.2018.11.39667

Neuroleptic malignant syndrome (NMS) is a rare but potentially fatal complication resulting from neuroleptic drug therapy. Presentation of NMS can vary, and diagnosis relies primarily upon medical history and symptomatology. Due to the potential delay in diagnosis, emergency physicians should remain vigilant in recognizing the symptoms of NMS and be prepared to initiate immediate treatment following diagnosis. Dantrolene, which has been used for spasticity and malignant hyperthermia, has been reported as a potential treatment for NMS and led to off-label use for NMS. We report two cases of NMS induced by antipsychotic monotherapy for which dantrolene was administered. [Clin Pract Cases Emerg Med. 2019;3(1):16–23.]

INTRODUCTION

Neuroleptic malignant syndrome (NMS) is a rare but potentially fatal complication of antipsychotic drug therapy.^{1,2} It occurs in 0.002-3% of patients taking neuroleptic drugs, including patients of both genders and all age groups.^{3,4} It is characterized by hyperthermia, blood pressure fluctuation, muscle rigidity, altered mental status, and tachycardia.³ Lab values typically show leukocytosis, elevated transaminases, metabolic acidosis, myoglobinuria, elevated creatine and blood urea nitrogen levels. Electrocardiogram (ECG) changes can reveal prolonged PR, QRS, and QT intervals as well as ST and T-wave abnormalities.³ The presentation of NMS is varied and may include some or all of these criteria.

Although formal diagnostic criteria have been proposed (Table 1), there is no universally-accepted criteria; the diagnosis of NMS is one that relies heavily on history and symptomatology rather than laboratory and diagnostic testing.⁴⁻⁶ Once the diagnosis of NMS has been suspected, treatment should be immediately initiated following current available guidelines to reduce morbidity and mortality associated with delays in treatment.⁷ However, while removal of the causative agent and supportive

care are widely accepted steps in the management of NMS, the efficacy of specific medical treatments remains controversial.^{8,9} Most of the current guidelines are supported by clinical experience and case reports of patients treated for NMS due to the rarity of NMS presentation.^{8,10}

There are a growing number of case reports on NMS, likely in relation to the ongoing use of antipsychotic monotherapy (Table 2).^{1,7,11-17} We present two cases of NMS induced by antipsychotic monotherapy treated with dantrolene in the emergency department (ED). Both cases were approved by the Arrowhead Regional Medical Center Institutional Review Board. The goal of this case report is to increase awareness of NMS among emergency physicians and to add to the growing body of knowledge surrounding NMS presentation and treatment options.

CASE REPORT

Case One

A 48-year-old male with past medical history of hypertension, diabetes, and schizophrenia was brought to the ED for acute altered mental status and combative behavior at

home. Family reported a history of hallucinations and a recent medication change to haloperidol (Table 3). In the ED the patient presented lethargic with a Glasgow Coma Scale (GCS) of 4, foaming from the oropharynx, and rigid. Vitals included an intravesical temperature of 109.6°F, blood pressure of 143/129 millimeters mercury (mmHg), pulse of 133 beats per minute (bpm), respiratory rate of 12 breaths per minute and irregular, and 100% saturation on high oxygen flow via nasal cannula. The patient's total creatine kinase was 28.482 units per liter (U/L) and troponin of 0.75 nanogram per milliliter (ng/mL) with ECG revealing lateral depressions.

The patient was intubated for airway protection and immediately cooled with evaporative cooling measures. Additionally, the patient's rhabdomyolysis was managed with vigorous hydration. The cardiology team determined the patient was not stable enough for urgent cardiac catheterization, and heparin drip was started. Given the patient's hyperthermia and muscle rigidity, NMS was suspected and an intravenous one milligram per kilogram (mg/kg) bolus dantrolene was administered in the ED. He was admitted to the intensive care unit (ICU) with a diagnosis of NMS, rhabdomyolysis, respiratory failure, and non-ST-elevation myocardial infarction. The ICU treatment team began bromocriptine at a dose of 2.5mg per nasal gastric tube every six hours per neurology recommendations and cooling through Arctic Sun 5000 Temperature Management System™.

He also experienced multi-organ insult including hepatic shock and acute renal failure. Furthermore, he continued to experience labile temperatures with episodic fevers (Figure 1). However, blood and urine cultures and cerebrospinal fluid (CSF) analysis were unremarkable. Additionally, he had acute loss of consciousness with wavering mentation, likely secondary to toxic metabolic encephalopathy, with GCS ranging from 4-11. After several failed multiple attempts for extubation, the patient subsequently required tracheostomy. He was discharged to an extended care facility for tracheostomy care after four weeks of inpatient management.

Case Two

A 21-year-old male with past medical history of autism and psychiatric disorder on risperidone was brought to the ED by his family with concern of altered mental status. The family reported that the patient had been somnolent, nonverbal, febrile, and had developed an unsteady gait. The patient was presenting one-week post treatment with a depot dose of risperidone (Table 4). In the ED, the patient was nonverbal with a GCS of 11, rigid, somnolent but able to follow basic commands, and displayed masked facies. Vitals included a temporal temperature of 99.3°F, blood pressure of 146/97 mmHg, pulse of 125 bpm, respiratory rate of 20 breaths per minute and oxygen saturation of 98% at ambient air. Laboratory examination was significant for creatine kinase 1092 U/L. Urine drug screen, comprehensive metabolic

CPC-EM Capsule

What do we already know about this clinical entity?

Neuroleptic malignant syndrome (NMS) is a rare but potentially fatal disorder with a variable onset following neuroleptic treatment.

What makes this presentation of disease reportable?

Patients suffering from NMS often present to emergency departments for treatment. Unfortunately, NMS is widely variable both in presentation and patient outcomes.

What is the major learning point?

Timely treatment of acute onset of NMS is essential to counteract the potential deleterious side effects of NMS. Dantrolene may also present an additional tool to improve long-term outcomes.

How might this improve emergency medicine practice?

Emergency physicians can reduce the long-term health impacts following NMS by rapidly recognizing its symptoms and expediting treatment, which may include dantrolene in appropriate cases.

panel, hematology, and CSF analysis were unremarkable. The patient's ECG revealed sinus tachycardia with a heart rate of 102 bpm but was otherwise normal.

The patient was started on an intravenous 1mg/kg bolus of dantrolene, followed by 1mg/kg intravenously every six hours in the ED. He was admitted to the ICU for close monitoring. On hospital day two, he began to show improvement in alertness and cognition but remained mostly somnolent with no improvement in muscle rigidity, and he spiked a fever of greater than 102.3°F (Figure 2). After four days, the intensive care team and neurology adjusted the dantrolene regimen to 40mg intravenously every six hours. Dantrolene was discontinued after 15 days and he was started on a 2.5mg dose of bromocriptine twice per day, which was subsequently adjusted to 5mg every eight hours.

By hospital day six, he was following basic commands and showing progressive symptomatic improvement. The patient continued to improve and by hospital day 10 demonstrated significant improvement in both gross and fine motor skills. He

Table 1. Diagnostic criteria via Diagnostic and Statistical Manual of Mental Disorders (DSM-5),⁵ Levenson,⁴ and Caroff and Mann.⁶

Source	Presentation features	Diagnostic criteria
Diagnostic and Statistical Manual of Mental Disorders (DSM-5) ⁵	<ul style="list-style-type: none"> •Exposure to dopamine antagonist within 72 hours prior to symptom development •Hyperthermia (>100.4°F or >38°C on at least two occasions) •Generalized rigidity •Creatine kinase elevation (at least four times upper limit of normal) •Changes in mental status •Autonomic instability (tachycardia, diaphoresis, blood pressure elevation or fluctuation, urinary incontinence, pallor) <p>Major:</p> <ul style="list-style-type: none"> •Fever •Rigidity •Elevated creatine phosphokinase concentration <p>Minor:</p> <ul style="list-style-type: none"> •Tachycardia •Abnormal arterial pressure •Tachypnea •Altered consciousness •Diaphoresis •Leukocytosis 	<p>Presence of these cardinal features are suggestive of diagnosis</p> <p>Presence of all three major, or two major and four minor features</p>
Caroff, Mann 1936	<p>Major:</p> <ul style="list-style-type: none"> •Treatment of neuroleptics within seven days of onset (2-4 weeks for depot) •Hyperthermia •Muscle rigidity •Exclusion of other drug-induced, systemic, or neuropsychiatric illnesses <p>Minor:</p> <ul style="list-style-type: none"> •Change in mental status •Tachycardia, hypertension or hypotension, tachypnea or silorrhoea •Tremors •Incontinence •Creatine phosphokinase elevation or myoglobinuria, leukocytosis, metabolic acidosis 	<p>Presence of all four major items and five minor features</p>

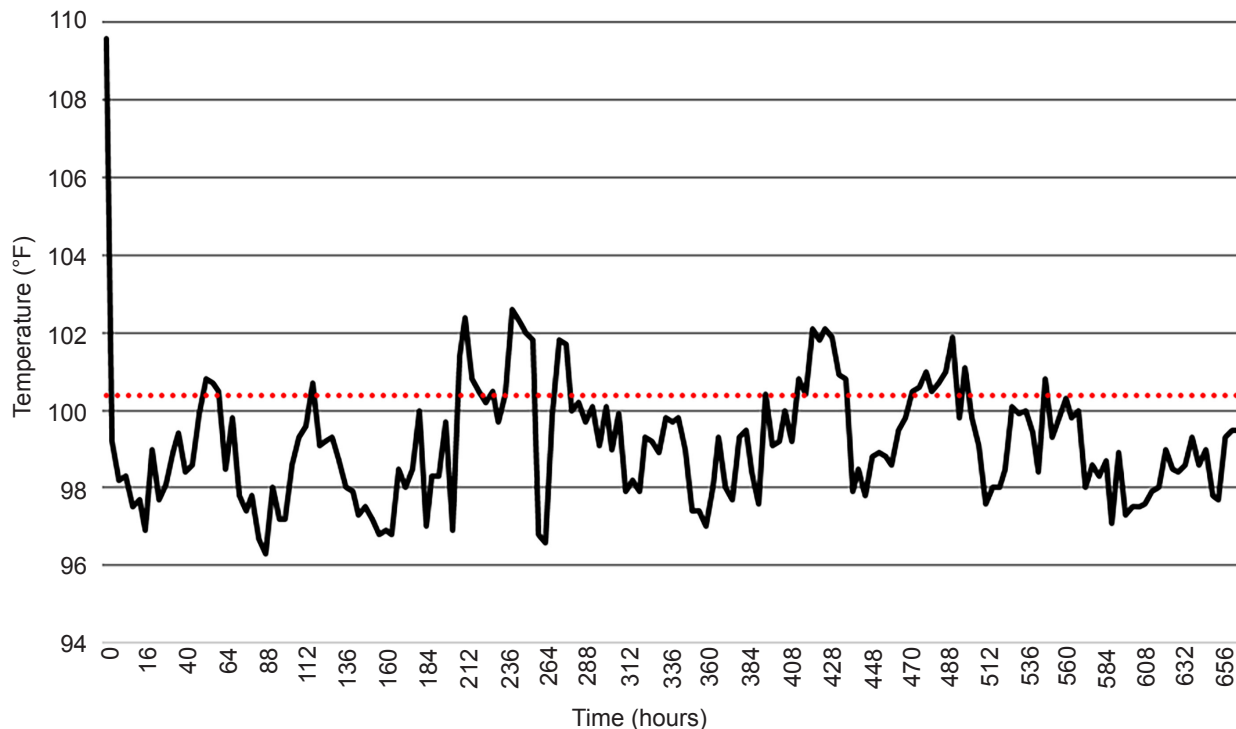


Figure 1. Patient one temperature vs. time.

Table 2. Previously published case reports detailing subject's age and gender, offending agent, neuroleptic malignant syndrome presentation and treatment, and patient outcome.

Source	Subject	Offending agent	Presentation	Treatment	Outcome
Al Danaf et al. 2015 ¹	60M	Risperidone	Shortness of breath, confusion, symmetrical rigidity in extremities, 37.1°C, BP 83/60 mmHg, HR 106 bpm, CPK 8450-12000	Dantrolene (initial dose 120 mg IV, 100 mg per NG tube every eight hours), Bromocriptine (5 mg per NG tube every eight hours, 10 mg per NG tube every eight hours). For fever reduction, cooling methods and low-dose lorazepam as needed.	Discharged day 17
Drews et al. 2017 ¹¹	54M	Quetiapine and haloperidol	GCS 13 declining, diffuse lead-pipe rigidity, 102.2°F–104.7°F, CK 247 IU/L	Cooling measures, offending agents were discontinued, IV dantrolene 2.5 mg/kg tapering dose, bromocriptine 2.5 to 5 mg every eight hours.	Discharged day 29.
Saha et al. 2017 ¹²	19M	Olanzapine	Mutism, rigidity in extremities, high-grade fever, CPK 2467 IU/L	Fluids, offending agent was stopped, bromocriptine 5 mg/day to 15 mg/day, lorazepam 4 mg/day.	Discharged day 23 with quetiapine at low dose and gradually increased to 200 mg/day.
Ahmad et al. 2013 ¹³	22M	Flupentixol decanoate and Clozapine	GCS 6, increased muscular tone and joint rigidity, fever, BP 70/40, HR 168 bpm, CK 31010 units	Supportive therapy including ventilation, paralysis, intravenous fluids, antipyretics, passive cooling and sedation.	Patient developed compartment syndrome of the right forearm. Fasciotomy with debridement along with a skin harvest and was finally discharged to the psychiatric unit. Brachial plexus injury was also identified and gradually resolved in six months.
Leenhardt et al. 2017 ⁷	49M	Clozapine and loxapine	Confusion, muscle rigidity, 39.5–40.8°C, BP 163/90 mmHg, HR 139 bpm	Withdrawal of offending agent.	Discharged day 11.
Leenhardt et al. 2017 ⁷	71M	Loxapine	Recent muscle rigidity, 41.2°C/106.2°F, CK 562-6760 U/L	Transferred to the intensive care unit, no NMS treatment started.	Developed multiple organ failure with secondary acute renal insufficiency requiring dialysis, metabolic acidosis, rhabdomyolysis, nosocomial pneumonia, and cardiopulmonary arrest with severe hypoxia. Died 22 days after onset.
Kuchibatta et al. 2009 ¹⁴	32M	Haloperidol depot and zuclopenthixol decanoate depot, and clozapine	Dizziness upon standing, 37.9°C to 38.5°C, BP 69/59 mmHg and 144/93 mmHg, HR 120 bpm, CK 216-521 IU/L	Offending agent stopped, vital signs normalized over four days, CK down to 152 IU/L by day 10.	Restarted on zuclopenthixol depot after an initial test dose of 100 mg intramuscularly, discharged to day hospital for monitoring, reviewed in outpatient clinic with zuclopenthixol decanoate depot, 200 mg intramuscularly weekly.

M, male; BP, blood pressure; mmHg, millimeters of mercury; HR, heart rate; bpm, beats per minute; CPK, creatine phosphokinase; IV, intravenous; NG, nasogastric; GCS, Glasgow Coma Scale; IU, international units; L, liter; hrs, hours; U/L, units per liter; CK, creatine kinase; NMS, neuroleptic malignant syndrome; ICU, intensive care unit.

Table 2. Continued.

Source	Subject	Offending agent	Presentation	Treatment	Outcome
Rajamani et al. 2016 ¹⁵	43M	Risperidone	Altered sensorium, muscle rigidity, high-grade fever, CPK 1543 IU/L	Offending agent was stopped immediately, and he was treated with lorazepam, trihexyphenidyl, paracetamol, and intravenous fluids.	Discharged day 3 with monitoring of glycemic control and no antipsychotics.
Chandran et al. 2003 ¹⁶	81M	Loxapine and methotrimeprazine	Some cognitive impairment, tremor, rigidity and unsteady gait, 38.3-39.3°C, BP 124/84 mmHg, HR 128 bpm, CK 1145-2574 U/L	Offending agent was stopped, dantrolene (70 mg intravenously), after 24 hours changed to bromocriptine (2.5 mg three times daily).	Discharged five weeks, on olanzapine (2.5 mg once daily) and sertraline (25 mg once daily).
Sagud et al. 2016 ¹⁷	30F	Risperidone and haloperidol	Altered consciousness, muscular rigidity and tremor, 38.6°C, HR 123 bpm, CK 3486 U/L	Offending agents were discontinued, and she was transferred to the ICU, where she stayed for two weeks. Despite normal temp and CK, patient developed catatonia, presenting with negativism, mutism, and occasional episodes of uncontrolled motor restlessness. Electroconvulsive therapy, where she received 12 applications and her condition improved.	The patient was discharged and restarted on clozapine.

M, male; F, female; CPK, creatine phosphokinase; CK, creatine kinase; HR, heart rate; BP, blood pressure; IU/L, international units/liter; U/L, units per liter; bpm, beats per minute; ICU, intensive care unit.

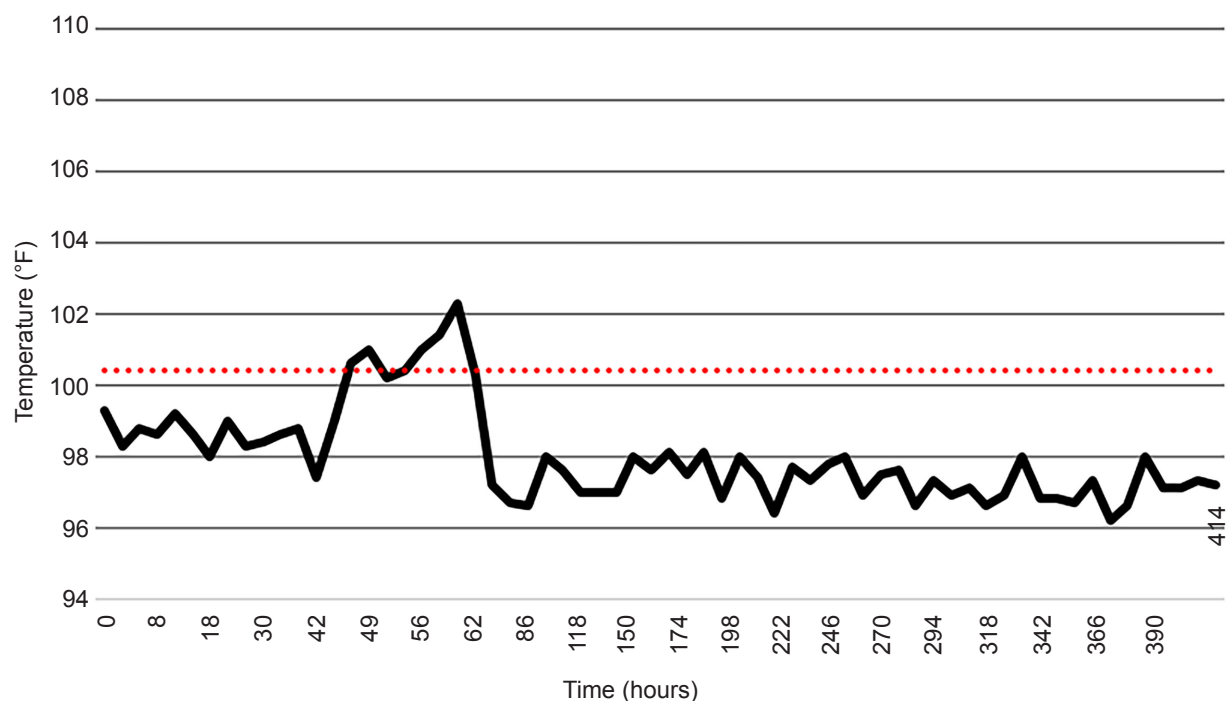
**Figure 2.** Patient two temperature vs. time.

Table 3. Patient one outpatient medications prior to neuroleptic malignant syndrome presentation.

Drug	Dose
Haloperidol	5 mg taken orally, daily
Clonidine	0.3 mg patch, weekly
Clonidine	0.2 mg taken orally, every 8 hours
Topiramate	50 mg taken orally, daily
Diphenhydramine	50 mg taken orally, daily
Hydroxyzine	25 mg taken orally, daily
Metoprolol succinate	100 mg taken orally, daily
Aripiprazole	5 mg taken orally, daily
Desvenlafaxine	100 mg taken orally, daily
Phenytoin	400 mg taken orally, twice daily
Amlodipine	5 mg taken orally, daily
Tamsulosin hydrochloride	0.4 mg taken orally, daily
Rosuvastatin	10 mg taken orally, daily
Cyclobenzaprine hydrochloride	10 mg taken orally, three times daily
Metoclopramide	10 mg taken orally, before meals
Eszopiclone	3 mg taken orally, before bed
Tramadol	50 mg taken orally, twice daily
Sitagliptin	100 mg taken orally, daily
Losartan-hydrochlorothiazide	100 / 25 mg taken orally, daily
Insulin aspart	25 units subcutaneous injection, before meals
Insulin detemir	50 units subcutaneous injection, twice daily

mg, milligrams.

Table 4. Patient two outpatient medications prior to neuroleptic malignant syndrome presentation.

Drug	Dose
Risperidone	2 mg taken orally, daily
Risperidone	25 mg intramuscular injection, every two weeks

mg, milligrams.

was subsequently discharged on hospital day 18 with continued bromocriptine treatment and close follow-up.

DISCUSSION

Recent literature suggests that both diagnosis and treatment of NMS remain challenging.^{11,18} While NMS is primarily recognized by hyperthermia and peripheral muscle rigidity, presentation can often vary. Additional symptoms may include altered mental state, irregular blood pressure,

tachycardia, metabolic acidosis, elevated creatine kinase, etc.¹⁰ In our case series, one patient presented with the most frequently reported NMS symptoms, hyperthermia and rigidity, while the second patient presented with only a mild fever and rigidity but also had an altered mental state, elevated blood pressure and elevated creatinine kinase, which led to the NMS diagnosis. Therapeutic approaches tend to vary as they are often implemented in a trial fashion rather than evidence-based practice.¹⁰

Primary treatment consists of withdrawal of the neuroleptic and supportive therapy such as hydration and cooling measures (Table 5).⁸ Medical therapy using dantrolene was first used for NMS in 1981 and has been cited in several reports as a useful treatment for NMS, particularly if the neuroleptic was a monotherapy.¹⁰ However, some studies have reported that dantrolene offers no significant benefit when compared to supportive therapy alone. Due to the low incidence rate of NMS, a randomized, controlled trial has not been feasible leading to a continued lack of consistency in treatment.¹⁰

There are several differences between our two cases that reveal firsthand the lack of consistency in treatment guidelines. The first patient received a bolus of dantrolene before being transferred immediately to the ICU for further management. Within the ICU setting, neurology and the intensive care team discontinued dantrolene and started bromocriptine. In contrast, the second patient remained in the ED for 12 hours and received two doses of dantrolene before being transferred to the ICU where dantrolene was continued until hospital day 15. He then was switched to bromocriptine. The differences in medical therapy seem to result from general practice differences between departments and specialists. Whereas dantrolene is commonly used for spasticity and malignant hyperthermia by ED providers, neurologists and intensivists favor bromocriptine as the medical therapy for management of NMS. This change in medical therapies used for NMS management during a hospital course has been reported previously.^{1,11}

The common theory of pathogenesis of NMS is dopamine blockade with subsequent disruption of the hypothalamus and corpus striatum, leading to temperature deregulation and muscle contractions.¹⁹ Dopamine pathways play a crucial role in hypothalamus function and temperature regulation, which can be disrupted by dopamine receptor antagonists such as haloperidol and risperidone.²⁰ Derangement of hypothalamic function can cause hyperthermia, arrhythmias, and irregular blood pressure and respiration. Additionally, dopamine blockade in the corpus striatum can lead to increased muscular rigidity and may lead to the occurrence of non-traumatic rhabdomyolysis. A recent study found that rhabdomyolysis and acute kidney injury were the most common complications in NMS – 30.1% and 16.1%, respectively.²¹ Additionally, acute kidney injury was associated with 2.3 times increased odds of death.²¹

Table 5. Standard treatment pathway for neuroleptic malignant syndrome.⁸

	Treatment
Stop causative agent	Remove causative agent and any other contributing psychotropic. If NMS was due to discontinuation of dopaminergic therapy, then it should be reinstated.
Supportive care	Maintain cardiorespiratory stability, maintain fluid balance, lower fever, lower blood pressure if elevated, prescribe heparin for prevention of venous thromboembolism, use of benzodiazepines to control agitation as necessary.
Medical therapy	
Lorazepam	1 to 2 mg IM or IV every four to six hours or diazepam 10 mg IV every eight hours.
Dantrolene	1 to 2.5 mg/kg IV are typically used in adults and can be repeated to a maximum dose of 10 mg/kg/day.
Bromocriptine	2.5 mg (through nasogastric tube) every six to eight hours are titrated up to a maximum dose of 40 mg/day
Amantadine	Initial dose is 100 mg orally or via gastric tube and is titrated upward as needed to a maximum dose of 200 mg every 12 hours.
Levodopa, apomorphine, carbamazepine, benzodiazepines	Have been used with some anecdotal success
Electroconvulsive therapy	Efficacy in treating malignant catatonia and reports of parkinsonism improving with ECT. ECT is generally reserved for patients not responding to other treatments or in whom nonpharmacologic psychotropic treatment is needed.

NMS, neuroleptic malignant syndrome; mg, milligram; IM, intramuscularly; IV, intravenously; kg, kilogram(s); ECT, electroconvulsive therapy.

Although the use of dantrolene in the setting of NMS is widely reported due to its effectiveness in spasticity and malignant hyperthermia, its pathophysiological effects are unclear. It is known that dantrolene directly relaxes skeletal muscle by inhibiting both ryanodine receptor binding and calcium release from intracellular storage in the sarcoplasmic reticulum. As an inhibitor of calcium release, it is suggested that dantrolene may also treat or prevent neuronal injury.²² The binding of dantrolene to ryanodine receptors in the brain protects neurons from the disruptions in calcium that occur in NMS. There is evidence that dantrolene may have effects in the thermoregulation areas of the brain to thereby reduce hyperthermia.²³ Additionally, dantrolene promptly reduces muscular rigidity, which in turn decreases hyperthermia in NMS patients and prevents myoglobinuric acute kidney injury secondary to spontaneous rhabdomyolysis common in NMS patients.^{9,24}

Despite the inconsistencies in NMS presentation and treatment, emergency physicians need to be prepared to rapidly assess and treat patients presenting with NMS symptomatology to avoid poor outcomes. Unfortunately, previous studies lack consistency in neuroleptic dosage, scales for reporting rigidity, and a temporal sequence of NMS symptomatology, further complicating an accurate NMS diagnosis (Table 2).¹⁰ As our case series shows, the first patient presented with hyperthermia and rigidity typical of NMS and went on to develop serious complications, which greatly lengthened his recovery time. Complications secondary to NMS include acute kidney injury, respiratory failure, myocardial infarction, and toxic

encephalopathy. Furthermore, such serious complications predict a poor prognosis. Therefore, prompt treatment should follow high suspicion for NMS and is imperative to avoid increased morbidity and mortality.

Our case series demonstrates that dantrolene may be effective in treating NMS because it affects both muscular and central nervous systems, especially if NMS was caused by neuroleptic monotherapy. Fortunately, in our case series both patients were brought in by family members who reported recent doses of neuroleptic monotherapy, which led to a faster diagnosis of NMS and treatment strategies including the use of dantrolene.

CONCLUSION

Our case series provides emergency physicians with critical examples of NMS symptomatology that presented in an ED and the potential benefit of using dantrolene for NMS resulting from neuroleptic monotherapy. Additionally, it is our hope that our case series will contribute to the growing body of knowledge regarding NMS presentation and treatment and encourage future studies to further explore NMS diagnostic criteria and appropriate treatment regimens.

Documented patient informed consent and/or Institutional Review Board approval has been obtained and filed for publication of this case report.

Address for Correspondence: Michelle Burgett-Moreno, BA, Arrowhead Regional Medical Center, Department of Emergency Medicine, 400 N Pepper Ave, Colton, CA 92324. Email: mburgett@gmail.com.

Conflicts of Interest: By the CPC-EM article submission agreement, all authors are required to disclose all affiliations, funding sources and financial or management relationships that could be perceived as potential sources of bias. The authors disclosed none.

Copyright: © 2019 Ngo et al. This is an open access article distributed in accordance with the terms of the Creative Commons Attribution (CC BY 4.0) License. See: <http://creativecommons.org/licenses/by/4.0/>

REFERENCES

- Al Danaf J, Madara J, Dietsche C. Neuroleptic malignant syndrome: a case aimed at raising clinical awareness. *Case Rep Med*. 2015;2015:769576.
- Berman BD. Neuroleptic malignant syndrome: a review for neurohospitalists. *Neurohospitalist*. 2011;1(1):41-7.
- Strawn JR, Keck PE Jr, Caroff SN, et al. Neuroleptic malignant syndrome. *Am J Psychiatry*. 2007;164(6):870-6.
- Levenson JL. Neuroleptic malignant syndrome. *Am J Psychiatry*. 1985;142(10):1137-45.
- American Psychiatric Association. (2013). *Diagnostic and Statistical Manual of Mental Disorders* (5th ed.). Arlington, VA: American Psychiatric Association Publishing.
- Caroff SN and Mann SC. Neuroleptic malignant syndrome. *Med Clin North Am*. 1993;77(1):185-202.
- Leenhardt F, Perier D, Pinzani V, et al. Pharmacist intervention to detect drug adverse events on admission to the emergency department: Two case reports of neuroleptic malignant syndrome. *J Clin Pharm Ther*. 2017;42(4):502-5.
- Wijdicks EF. Neuroleptic malignant syndrome. Available at: <https://www.uptodate.com/contents/neuroleptic-malignant-syndrome>. Accessed March 10, 2017.
- Grossman RA, Hamilton RW, Morse BM, et al. Nontraumatic rhabdomyolysis and acute renal failure. *N Engl J Med*. 1974;291(16):807-11.
- Reulbach U, Dütsch C, Biermann T, et al. Managing an effective treatment for neuroleptic malignant syndrome. *Crit Care*. 2007;11(1):R4.
- Drews JD, Christopher A, Evans DC. Neuroleptic malignant syndrome in the trauma intensive care unit: Diagnosis and management of a rare disease in a challenging population. *Int J Crit Illn Inj Sci*. 2017;7(2):119-21.
- Saha PK, Chakraborty A, Layek AK, et al. Olanzapine-induced neuroleptic malignant syndrome. *Indian J Psychol Med*. 2017;39(3):364-5.
- Ahmad A, Harrison CA, Davies HG. Two unusual complications of neuroleptic malignant syndrome. *Indian J Crit Care Med*. 2013;17(2):116-8.
- Kuchibatla SS, Cheema SA, Chakravarthy KS, et al. A case report of neuroleptic malignant syndrome. *BMJ Case Rep*. 2009;2009:bcr0720080429.
- Rajamani B, Kumar Y, Rahman SM. Neuroleptic malignant syndrome. *J Family Med Prim Care*. 2016;5(1):178-80.
- Chandran GJ, Mikler JR, Keegan DL. Neuroleptic malignant syndrome: case report and discussion. *CMAJ*. 2003;169(5):439-42.
- Šagud M, Vuksan-Cusa B, Božina N, et al. Olanzapine long-acting injections after neuroleptic malignant syndrome: two case reports. *J Clin Psychopharmacol*. 2016;36(6):733-5.
- Ambulkar RP, Patil VP, Moiyadi AV. Neuroleptic malignant syndrome: a diagnostic challenge. *J Anaesthesiol Clin Pharmacol*. 2012;28(4):517-9.
- Bottoni TN. Neuroleptic malignant syndrome: a brief review. *Hosp Physician*. 2002;38(3):58-63.
- Yamawaki S, Yanagawa K, Morio M, et al. Possible central effect of dantrolene sodium in neuroleptic malignant syndrome. *J Clin Psychopharmacol*. 1986;6(6):378-9.
- Modi S, Dharaiya D, Schultz L, et al. Neuroleptic malignant syndrome: complications, outcomes, and mortality. *Neurocrit Care*. 2016;24(1):97-103.
- Muehlschlegel S and Sims JR. Dantrolene: mechanisms of neuroprotection and possible clinical applications in the neurointensive care unit. *Neurocrit Care*. 2009;10(1):103-15.
- Oyamada T, Hayashi T, Kagaya A, et al. Effect of dantrolene on K⁺- and caffeine-induced dopamine release in rat striatum assessed by in vivo microdialysis. *Neurochem Int*. 1998;32(2):171-6.
- Brvar M and Bunc M. Video of dantrolene effectiveness on neuroleptic malignant syndrome-associated muscular rigidity and tremor. *Crit Care*. 2007;11(3):415.

Kratom (Mitragnine) Ingestion Requiring Naloxone Reversal

Daniel L. Overbeek, MD
Jonathan Abraham, MD
Brendan W. Munzer, MD

University of Michigan, Department of Emergency Medicine, Ann Arbor, Michigan

Section Editor: Steven Walsh, MD

Submission history: Submitted August 10, 2018; Revision received October 26, 2018; Accepted November 7, 2018

Electronically published January 4, 2019

Full text available through open access at http://escholarship.org/uc/uciem_cpccm

DOI: 10.5811/cpcem.2018.11.40588

Kratom (mitragynine) is a naturally occurring opioid agonist whose use has been escalating. Its suppliers advertise it as a safe alternative for opioids and a safe treatment for opioid-withdrawal symptoms. There has been controversy in the past two years regarding the legal status and lack of regulation surrounding kratom. Currently, kratom is legal and unregulated, leaving users at risk from unpredictable potencies and effects. We present the first case of successful naloxone reversal of opioid toxidrome from recreationally used kratom. We advocate further research and regulation to ensure standardized dosing to protect patients. [Clin Pract Cases Emerg Med. 2019;3(1):24–26.]

INTRODUCTION

Kratom (also called mitragynine) is an opioid receptor agonist, which is a naturally-occurring compound. It is produced by *Mitragyna speciosa* and has been advertised as a safe treatment for opioid dependence as well as opiate withdrawal symptoms.¹ Kratom is currently not a scheduled drug in the United States (U.S.) and can be legally acquired and consumed in most states.² In 2016, the Drug Enforcement Administration (DEA) announced that they intended to classify kratom as a Schedule I drug; however, this decision was withdrawn after an advocacy effort by the drug's proponents based on claims that kratom is a safe alternative to prescription opioids and for weaning opioid dependence.³ There have been multiple cases documenting risks of kratom.^{4,5} We present a unique case of kratom overdose and treatment using naloxone.

CASE REPORT

A 38-year-old female with a history significant for depression and polysubstance abuse presented to the emergency department (ED) for altered mental status and decreased respiratory rate. She was placed in a resuscitation bay, where she was noted to be obtunded with minimal responsiveness to painful stimuli. She was also experiencing respiratory depression with bradypnea. Given clinical presentation and concern for opioid toxidrome with respiratory depression, the patient received two doses of 0.4 mg of naloxone.

Following administration, the patient's depressed mental status resolved and respiratory rate increased. She subsequently became acutely agitated, requiring haloperidol for sedation. She was monitored in the ED, receiving supportive care and intravenous fluids. After she received haloperidol, she experienced altered mental status, which persisted for the next 12 hours. She did not have any respiratory depression during the monitoring after haloperidol administration, likely suggesting the altered mental status was related to the administration of the haloperidol.

Chart review revealed prior hospitalization for altered mental status, likely polysubstance overdose, with gas chromatography / mass spectrometry (GC/MS) during that admission positive for bupropion, venlafaxine, and kratom. During previous hospitalization, she did confirm that she had consumed kratom and otherwise denied current drug use. She was admitted to the hospital for continued altered mental status, which improved with supportive care over the next 24 hours. GC/MS analysis of her urine during this visit was positive only for the presence of kratom and did not show other opioids. The patient admitted to using kratom upon discharge, though she denied intentional overdose.

DISCUSSION

Mitragynine is an alkaloid compound naturally produced by *Mitragyna speciosa*; it is sold as kratom in multiple different preparations.^{5,6} The effects vary from stimulating effects at low doses to sedating effects at high doses. Kratom

has been documented to have mu-receptor agonism in humans and in vitro in mice, which would be consistent with the clinical findings in this case.⁷⁻⁹ Review articles currently recommend the administration of naloxone in the case of kratom overdose, mainly based on the excellent safety profile of naloxone; however, they also note that the clinical effectiveness of naloxone in reversing the effects of kratom overdose has not been proven.^{10,11} Prior to this case, there does not appear to have been any documented case of naloxone reversal of opioid toxidrome from kratom in humans. In this case, the patient required two doses of naloxone prior to improvement in obtundation.

One viable alternative explanation is that the patient may have consumed an opioid in addition to the kratom. We considered this to be unlikely, as the GC/MS did not identify other opioids, and the patient also endorsed kratom use and denied other drug use.

Recently there has been a surge in demand for products marketed to be an alternative for opioids as pain control and to treat opioid dependence and withdrawal. Kratom is one of the most widely known, and its use has been increasing.^{12,13} Recreational use has also increased, and kratom is regularly advertised as a “legal high.” Multiple online sites, including reddit.com and bluelight.org, have forums discussing its recreational use and contribute to pro-kratom advocacy.^{14,15} Our patient in this case had a prior history of kratom use and appeared to be using it as a recreational drug.

The increased use of kratom has been enough to draw the attention of federal agencies. In 2016, the DEA announced that they were planning to classify mitragynine as a Schedule I substance. This would have banned its sale and use in the U.S. This announcement caused an outcry from advocates for the drug, claiming that it was a safe alternative to other therapies for chronic pain. Shortly thereafter, a strong lobbying effort was undertaken to influence the DEA’s decision, and the DEA withdrew their notice shortly after the initial announcement.^{3,16} In November 2017, the U.S. Food and Drug Administration (FDA) released a warning against using kratom for opioid dependence and withdrawal. They identified 36 deaths associated with kratom, and refuted the claim that the drug is safe, identifying seizures and liver disease as known risks. However, the FDA did not make any statements comparing the safety of kratom to other opioids or treatments for opioid dependence.^{12,17}

Research is not yet available to determine the relative safety of kratom for the treatment of chronic pain or opioid dependence. With the current opioid epidemic, we are in a situation where we should work to ensure the availability of safe alternatives. We call for safety studies, followed by a clear regulation of these products to ensure standardized dosing. These patients who are looking for safe alternatives are put at risk by the current unregulated plethora of products with a wide variety of dosing and preparation. The alternate is

CPC-EM Capsule

What do we already know about this clinical entity?

Kratom (mitragynine) is a drug used as an alternative to opioids and as a complement to opioids. It has previously been shown to have opioid mu-agonist properties.

What makes this presentation of disease reportable?

Most toxicology resources recommend the use of naloxone to reverse kratom overdose; however, there are no previously reported cases of successful reversal with naloxone.

What is the major learning point?

Opioid toxidrome including respiratory depression should be treated with naloxone regardless of the specific opioid used.

How might this improve emergency medicine practice?

Providers should be aware of alternative opioids used by patients and the risks they face from those substances.

a continuation of the current system of unpredictable effects from inconsistent dosing.

CONCLUSION

The effects of the opioid epidemic have expanded significantly in recent years. Many are looking for alternative safe treatments, and the use of kratom is also increasing. Kratom is often advertised as a safe, legal substance available as an alternative to other opioids. This case identifies the risk of kratom overdose and provides evidence that naloxone may be an effective treatment for respiratory depression from kratom use. Prior work has established the good safety profile of naloxone, and we would recommend its use in the setting of respiratory depression from kratom overdose. We call for further research and reasonable regulation of kratom to protect patients from the risks of kratom overdose.

Documented patient informed consent and/or Institutional Review Board approval has been obtained and filed for publication of this case report.

Address for Correspondence: Daniel Overbeek, MD, University of Michigan, Department of Emergency Medicine, 1500 E Medical Center Dr, Ann Arbor, MI 48109. Email: overbeek@med.umich.edu.

Conflicts of Interest: By the CPC-EM article submission agreement, all authors are required to disclose all affiliations, funding sources and financial or management relationships that could be perceived as potential sources of bias. The authors disclosed none.

Copyright: © 2019 Overbeek et al. This is an open access article distributed in accordance with the terms of the Creative Commons Attribution (CC BY 4.0) License. See: <http://creativecommons.org/licenses/by/4.0/>

REFERENCES

- Rook W. The Addictions Coach: Kratom for Opiate Withdrawal. What is it and How Does it Work? Guest blog from author, Wendi Rook. 2015. Available at: <https://theaddictionscoach.com/the-addictions-coach-kratom-for-opiate-withdrawal-what-is-it-and-how-does-it-work-guest-blog-from-author-wendi-rook/>. Accessed April 4, 2018.
- Stetzel K. The FDA Is Still Trying to Ban Kratom, a Potential Solution to the Opioid Epidemic. Reason. 2018. Available at: <https://reason.com/blog/2018/02/12/fda-declares-kratom-an-opioid>. Accessed June 24, 2018.
- Gianutsos GPJ. The DEA changes its mind on kratom. *US Pharmacist*. 2017. Available at: <https://www.uspharmacist.com/article/the-dea-changes-its-mind-on-kratom>. Accessed April 4, 2018.
- Cumpston KL, Carter M, Wills BK. Clinical outcomes after kratom exposures: A poison center case series. *Am J Emerg Med*. 2018;36(1):166-8.
- McIntyre IM, Trochta A, Stolberg S, et al. Mitragynine 'kratom' related fatality: a case report with postmortem concentrations. *J Anal Toxicol*. 2015;39(2):152-5.
- Drug and Chemical Evaluation Secretary. DEA Solicitation for Information on Kratom. Soc Forensic Toxicol Tox Talk. 2013. Available at: http://www.soft-tox.org/files/toxtalk/SOFT_ToxTalk_v37-3.pdf. Accessed June 24, 2018.
- Matsumoto K, Mizowaki M, Suchitra T, et al. Antinociceptive action of mitragynine in mice: Evidence for the involvement of supraspinal opioid receptors. *Life Sci*. 1996;59(14):1149-55.
- Matsumoto K, Horie S, Ishikawa H, et al. Antinociceptive effect of 7-hydroxymitragynine in mice: discovery of an orally active opioid analgesic from the Thai medicinal herb *Mitragyna speciosa*. *Life Sci*. 2004;74(17):2143-55.
- Hassan Z, Muzaimi M, Navaratnam V, et al. From kratom to mitragynine and its derivatives: physiological and behavioural effects related to use, abuse, and addiction. *Neurosci Biobehav Rev*. 2013;37(2):138-51.
- Rech MA, Donahey E, Cappiello Dziedzic JM, et al. New drugs of abuse. *Pharmacotherapy*. 2015;35(2):189-97.
- Rosenbaum CD, Carreiro SP, Babu KM. Here today, gone tomorrow. and back again? A review of herbal marijuana alternatives (K2, Spice), synthetic cathinones (bath salts), kratom, *Salvia divinorum*, methoxetamine, and piperazines. *J Med Toxicol*. 2012;8(1):15-32.
- Gottlieb SM. Statement from FDA commissioner Scott Gottlieb, M.D. on FDA advisory about deadly risks associated with kratom. 2017. Available at: <https://www.fda.gov/NewsEvents/Newsroom/PressAnnouncements/ucm584970.htm>. Accessed January 10, 2018.
- Anwar M, Law R, Schier J. Notes from the field: kratom (*Mitragyna speciosa*) exposures reported to poison centers — United States, 2010–2015. *MMWR Morb Mortal Wkly Rep*. 2016;65(29):748-9.
- Kratom. Reddit.com. Available at: <https://www.reddit.com/r/kratom/>. Accessed June 24, 2018.
- Kratom Mega Thread. Bluelight.org. Available at: <http://www.bluelight.org/vb/threads/793447-Kratom-Mega-Thread-v-5>. Accessed June 24, 2018.
- Silverman L. Kratom gets reprieve from DEA's Schedule I drug list - CNN. CNN. 2016. Available at: <http://www.cnn.com/2016/10/17/health/kratom-dea-schedule-i-comments/index.html>. Accessed January 10, 2018.
- Reuters. FDA warns against using kratom for opioid addiction. 2017. Available at: <https://www.reuters.com/article/us-fda-kratom/fda-warns-against-using-kratom-for-opioid-addiction-idUSKBN1DE1ZJ>. Accessed January 10, 2018.

A Single-session Crisis Intervention Therapy Model for Emergency Psychiatry

Scott A. Simpson, MD, MPH

Denver Health Medical Center, Psychiatric Emergency Services, Department of Behavioral Health, Denver, Colorado

Section Editor: Shadi Lahham, MD

Submission history: Submitted August 1, 2018; Revision received September 23, 2018; Accepted October 9, 2018

Electronically published January 10, 2019

Full text available through open access at http://escholarship.org/uc/uciem_cpccem

DOI: 10.5811/cpcem.2018.10.40443

Presentations for anxiety and depression constitute the fastest growing category of mental health diagnoses seen in emergency departments (EDs). Even non-psychiatric clinicians must be prepared to provide psychotherapeutic interventions for these patients, just as they might provide motivational interviewing for a patient with substance use disorders. This case report of an 18-year-old woman with suicidal ideation illustrates the practicality and utility of a brief, single-session, crisis intervention model that facilitated discharge from the ED. This report will help practitioners to apply this model in their own practice and identify patients who may require psychiatric hospitalization. [Clin Pract Cases Emerg Med. 2019;3(1):27–32.]

INTRODUCTION

Symptoms of anxiety and depression are the most common reasons to present for emergency psychiatric care.¹ The broad differential for depressive and anxiety symptoms includes major depressive, post-traumatic stress, adjustment, substance-induced, and personality disorders.² Because medications are not indicated for some of these conditions, all emergency department (ED) clinicians must be prepared to provide brief, non-pharmacologic treatment. This case report demonstrates a single-session, crisis intervention model for ED patients presenting with anxiety and depression.

CASE REPORT

An 18-year-old woman was brought to the ED by ambulance. Paramedics reported that the patient was on the phone with her mother and said she wanted to be dead. Her mother lives in another country and called emergency services. The patient was tearful and “very stressed” on arrival. Vital signs, a routine urine toxicology screen, and pregnancy test were unremarkable. She reported suicidal thoughts for about a week attributed to poor grades in college, family conflict, and financial obligations. She had missed several appointments with her therapist and prescriber and had recently run out of sertraline (Zoloft). She declined to provide her mother’s phone number.

The patient described a history of abuse at a young age. She had one prior psychiatric hospitalization after walking into traffic in a suicide attempt at age 15. Other episodes of self-harm started at age 10 and were non-suicidal in nature. Her biological father had minimal contact with the patient. Her grandmother had been diagnosed with schizophrenia. The patient denied access to firearms.

Concerned about multiple suicide safety risk factors, the emergency psychiatrist began a structured, single-session psychotherapy. The psychiatrist and patient wrote a timeline of events preceding the presentation (Figure 1). In so doing, she provided more details of her history. Ten months prior, she had to leave her apartment due to conflicts with roommates. Beginning college, she worried about tuition and found two jobs. Despite several attempts to re-schedule her therapy appointments around her work schedule, the therapist’s office did not return her calls. The patient also revealed that a supportive stepfather lived nearby. The morning of her ED visit, she received another reminder about her tuition bill. She was talking with a roommate about this bill; however, she felt her roommate did not fully appreciate her challenges, and she then called her mother.

The psychiatrist and patient agreed all this would be stressful for anyone. Her affect evolved from tearful to more composed, and she identified some immediate goals: find a new therapist; talk with her school about a tuition grant; identify a

tutor; and spend more time doing things she enjoys (Supplemental Figure). She agreed to let the resident call her mother who could help complete these tasks. The patient's mother corroborated the patient's history. In fact, the mother had already spoken with the school about help with tuition and had begun searching for new outpatient providers.

To complete discharge planning, a nurse made an appointment for the patient with a new outpatient provider. The patient completed a written safety plan and was offered a follow-up call. The family was apprised of local crisis resources. Within an hour, the evaluating psychiatrist felt that this patient's acute risk was significantly mitigated through safety planning, mobilization of social supports, connection to treatment, and acute de-escalation to justify discharge. After six months, she had persistent resolution of suicidal thoughts without recurrent self-harm or inpatient hospitalization.

DISCUSSION

This brief psychotherapy emphasizes active problem-solving and is adapted from a multi-session model built for integrated care settings.³ Specialized single-session psychotherapies have been described for other psychiatric conditions including insomnia,⁴ gambling,⁵ agitation,⁶ and suicidal ideation.⁷ Therapy models described for ED settings are often applied by non-psychiatric staff, for example, motivational interviewing for substance use⁸ and safety planning for suicidality.^{9,10}

This model uses the concept of crisis as a framework for assessment and treatment. A crisis occurs when a person's usual coping skills are inadequate to a life stressor.¹¹ A crisis may be precipitated by medical illness or interpersonal conflicts. A patient's ability to cope with stressors arises from individual temperament, life experiences, personal skills, and social network. When a crisis develops, individuals are unable to access these strengths to resolve the crisis. Anxiety, depression, a sense of feeling overwhelmed, or suicidal ideation ensues in a patient with perhaps little psychiatric treatment history and a high level of functioning that includes stable employment and relationships. Some patients manifest primitive coping skills such as somatization that precipitate an ED visit. A crisis may also relate to worsening symptoms in patients with chronic psychiatric illness, for example, increased suicidal ideation in a patient with borderline personality disorder. Crisis does not fit neatly into the *Diagnostic and Statistical Manual of Mental Disorders*, 5th edition, (DSM-5) but is most closely related to the diagnosis of adjustment disorder.¹²

Single-session therapy leverages the crisis model to help patients and providers understand the origins of the ED visit and begin actively resolving the crisis. This intervention may be delivered by emergency physicians or ED behavioral health consultants including social workers or nurses. Patients most likely to benefit from this therapy present in the context of a discrete life stressor and have a history of better psychological functioning and insight.

CPC-EM Capsule

What do we already know about this clinical entity?

Anxiety, depression, and adjustment reactions represent the fastest-growing category of reasons for psychiatric presentations to the emergency department (ED).

What makes this presentation of disease reportable?

This case demonstrates how a single-session crisis therapy in the ED may avert hospitalization for a depressed, suicidal patient.

What is the major learning point?

ED clinicians should be prepared to recommend or deliver brief psychotherapy for these common psychiatric presentations.

How might this improve emergency medicine practice?

Most suicidal ED patients are hospitalized. However, most patients with depression or suicidality can be safely treated in the ED and discharged.

One-Session Crisis Intervention Psychotherapy

The goals of this intervention include ameliorating anxiety and depressive symptoms, initiating treatment, and identifying patients who may need referral for more intensive psychiatric treatment. These steps and their therapeutic benefits are summarized in Table.

1. Recognize the Crisis and Identify the Precipitant

Patients in crisis present to the ED with a range of psychiatric symptoms including anxiety, depression, fatigue, or poor sleep. After excluding a somatic etiology of psychiatric symptoms and ensuring acute safety, the clinician must elucidate the onset of the patient's psychiatric symptoms. In the ED it is important to keep in mind that suicidality is often a symptom of underlying distress, does not necessarily indicate the presence of a severe psychiatric disorder, and can be treated in outpatient settings.¹³

Writing a timeline with the patient helps identify life stressors driving the crisis. This technique is helpful for several reasons. First, many patients in crisis feel overwhelmed and are challenged to recall and reconstruct a helpful history. A

Table. Summary of working steps and therapeutic processes for one-session crisis intervention therapy.

Stage	Working steps	Therapeutic process
1. Recognize the crisis and identify the precipitant(s)	<ul style="list-style-type: none"> Assemble history Write timeline (Figure 1) 	<ul style="list-style-type: none"> Ascertain more replete history Inform DSM-5 diagnosis Demonstrate active exploration of crisis Build rapport
2. Characterize the patient's response	<ul style="list-style-type: none"> Describe emotional response Describe behavioral response: immobility, avoidance, or adaptation Immobile patients benefit from naming the precipitant; avoidant patients benefit from identifying solutions 	<ul style="list-style-type: none"> Validate emotional state Validate therapeutic relationship Consider whether lack of adaptive posture requires higher level treatment Support evolution towards adaptive response in course of session
3. Formulate together	<ul style="list-style-type: none"> Discuss what is going on: What are the precipitants? How does the patient feel? What does the patient need? What choices are available? What's going well despite the crisis? Agree on an explanation for symptoms and the ED visit 	<ul style="list-style-type: none"> Validate the work done in prior steps Align with patient on identifying the problem Begin problem-solving
4. Identify behavioral goals and offer concrete support	<ul style="list-style-type: none"> Write a list of goals (Supplemental figure) For easy "to-do's," provide concrete support (e.g., make appointments, help with phone calls) For more aspirational goals (e.g., "feel better"), identify intermediate, actionable steps Safety plan Restrict access to lethal means Arrange follow-up call if possible 	<ul style="list-style-type: none"> Demonstrate adaptive problem-solving Begin envisioning discharge and anticipating challenges Reduce safety risks
5. Engage social supports	<ul style="list-style-type: none"> Write hub-and-spoke diagram of social supports (Figure 2) Call social supports for collateral information Enlist supports in discharge planning 	<ul style="list-style-type: none"> Enhance social connectedness Improve concrete support for discharge plan Increase likelihood of other persons referring patient to treatment should crisis worsen

DSM-5, Diagnostic and Statistical Manual for Mental Disorders, 5th ed.; ED, emergency department.

structured framework focuses the interview on the acute presentation. A timeline is easy for both clinicians and patients to interpret. And, in the act of writing a timeline together, the clinician and patient build therapeutic rapport that itself is part of the healing process. Finally, the resulting product can be used to later formulate the crisis state with the patient.

2. Characterize the Patient's Response

The patient's emotional and behavioral responses to the crisis state should be considered in guiding treatment.¹⁴

Validate the patient's emotional response to the crisis. The emotional response is often readily described by the patient: stressed, overwhelmed, anxious, or alone. The clinician may validate the emotional state by noting it to be an understandable response to the clear stressors described in the timeline. A patient's endorsement of depression is not synonymous with major depressive disorder (a specific diagnosis with precise diagnostic criteria).

Behavioral responses are characterized by immobility, avoidance, or adaptation. Immobility is a sense of feeling stuck and persistently unable to problem-solve, as this patient

felt initially. Some patients avoid their problems entirely, thereby prolonging the crisis and exacerbating its consequences. Immobile and avoidant patients need help identifying the precipitant of the crisis and brainstorming possible solutions. Immobile or avoidant patients who cannot demonstrate more adaptive skills may require referral to specialty psychiatric care.

Patients who demonstrate adaptive responses to crisis are positioned to grow from their crisis and manage their lives more effectively. In this case, the patient moved from a more immobile stance to one characterized by greater initiative and adaptation.

3. Formulate Together

With a timeline of precipitants and a sense of the patient's response styles, the clinician formulates the acute crisis aloud with the patient. What are the precipitants? How do these make the patient feel? What does the patient need to address the crisis? What choices are available?

The resulting conversation is both diagnostic and therapeutic. This patient experienced relief from an expert's explanation of why she did not feel well. The clinician

validated the severity of the patient's stressors while offering optimism and active problem-solving.

A broad psychiatric differential should always be considered. Cognitive impairment related to severe depression or disorganization due to psychosis may be recognized in the course of therapy. Such symptoms complicate less-restrictive outpatient treatment and may alter disposition planning. Antidepressant discontinuation syndrome was considered less likely here given the timing and quality of her depressive symptoms.

4. Identify Behavioral Goals and Offer Concrete Support

The clinician helps the patient generate a to-do list of goals to resolve the crisis. This patient's list is included as Supplemental Figure. Goals should be specific, realistic, and accomplishable in the near future.¹⁵ Patients with more aspirational goals (e.g., feel better) should identify intermediate steps that are specific and accomplishable. Solutions-focused thinking can be introduced by asking, "If things were going well in your life, how would things look four weeks from now?" This conversation invites the patient to anticipate potential obstacles to resolution of the crisis—and also begin envisioning discharge from the ED.

Clinicians need to provide practical support for patients. For example, this patient needed help making an international phone call. Making an appointment for an outpatient provider improves outpatient adherence and reduces ED return rates.^{16,17} Identifying triggers for suicidal thoughts, coping skills, and supportive contacts through a safety plan reduces the risk of subsequent self-harm and improves symptom burden.^{9,18,19}

5. Engage Social Supports

Patients in crisis are quick to say they have nobody to help them when, in fact, supportive friends or family are indeed available. This social network should be mobilized while the patient is in the ED.

A hub-and-spoke diagram helps the patient recognize persons who can help resolve the crisis (Figure 2). The patient is in the middle hub. As many other persons as possible are written around the spokes of the wheel. Supportive persons are connected to the hub with a solid line, and less-supportive contacts are connected with a dashed line. The most important one or two persons are starred.

The clinician should contact these supportive persons. Collateral information provides a stronger diagnostic and suicide safety assessment.²⁰ In this instance, that the patient's mother described so many supportive actions already underway illustrates how the crisis state induces a perception of isolation and hopelessness. Social supports should be enlisted to help in treatment planning. For example, family may take the patient to a follow-up appointment. When collateral information introduces new data worrying for safety risk or a social network is truly unavailable, the clinician may more strongly consider more intensive treatment including hospitalization.

CONCLUSION

Most ED visits for suicidal ideation still result in hospitalization.²¹ This single-session, crisis intervention complements the traditional expectations of emergency psychiatric evaluations by providing clinicians a way to treat symptoms of

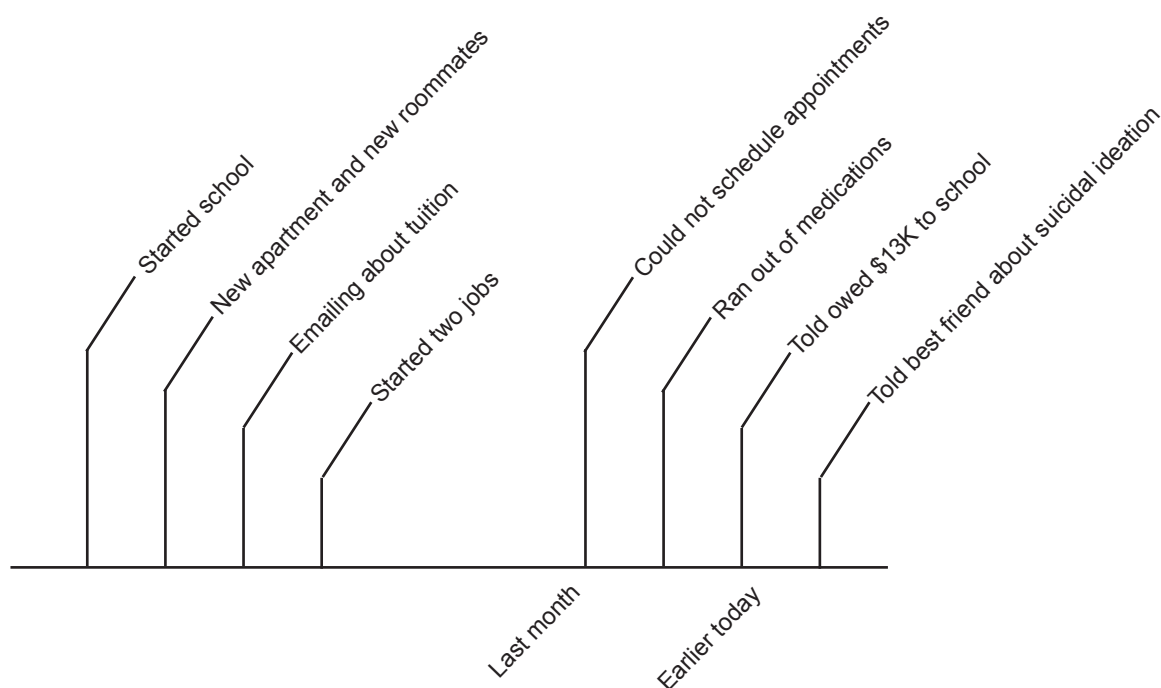


Figure 1. A timeline of stressors preceding the patient's emergency department visit.

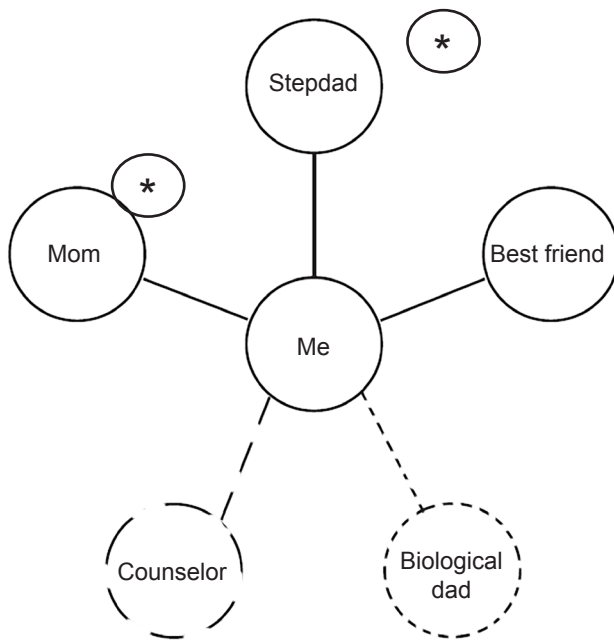


Figure 2. A hub-and-spoke diagram of the patient's social supports.

anxiety and depression in the ED. This model may also assist in the treatment of boarding psychiatric patients and encourage further studies of psychotherapy in the emergency setting.

ACKNOWLEDGMENTS

The author would like to thank Dr. Robert Feinstein, MD, for his mentorship and intellectual contributions to this model. Also, Dr. Jack Gende, DO, deserves thanks for his superb care of this patient. Dr. Simpson presented an earlier iteration of this model at the Academy of Psychosomatic Medicine Annual Meeting, November 9-12, 2016, in Austin, TX.

Documented patient informed consent and/or Institutional Review Board approval has been obtained and filed for publication of this case report.

Address for Correspondence: Scott A. Simpson, MD, MPH, Denver Health Medical Center, Psychiatric Emergency Services, Department of Behavioral Health, 777 Bannock St, MC 0116, Denver, CO 80204. Email: scott.simpson@dhha.org.

Conflicts of Interest: By the CPC-EM article submission agreement, all authors are required to disclose all affiliations, funding sources and financial or management relationships that could be perceived as potential sources of bias. The authors disclosed none.

Copyright: © 2019 Simpson et al. This is an open access article distributed in accordance with the terms of the Creative Commons Attribution (CC BY 4.0) License. See: <http://creativecommons.org/licenses/by/4.0/>

REFERENCES

- Weiss J, Barrett ML, Heslin KC, et al. Agency for Healthcare Research and Quality. Trends in Emergency Department Visits Involving Mental and Substance Use Disorders, 2006-2013. 2016. Available at: <https://www.hcup-us.ahrq.gov/reports/statbriefs/sb216-Mental-Substance-Use-Disorder-ED-Visit-Trends.jsp>. Accessed August 17, 2017.
- Bentley SM, Pagalilauan GL, Simpson SA. Major depression. *Med Clin North Am.* 2014;98(5):981-1005.
- Simpson SA & Feinstein RE. (2017). Crisis intervention in integrated care. In Feinstein RE, Connelly JV & Feinstein MS (Eds.), *Integrating Behavioral Health and Primary Care* (pp. 497-513). New York, NY: Oxford University Press.
- Ellis JG, Cushing T, Germain A. Treating acute insomnia: a randomized controlled trial of a "single-shot" of cognitive behavioral therapy for insomnia. *Sleep.* 2015;38(6):971-8.
- Toneatto T. Single-session interventions for problem gambling may be as effective as longer treatments: Results of a randomized control trial. *Addict Behav.* 2016;52:58-65.
- Cadwalader A, Orellano S, Tanguay C, et al. The effects of a single session of music therapy on the agitated behaviors of patients receiving hospice care. *J Palliat Med.* 2016;19(8):870-3.
- Ward-Ciesielski EF, Jones CB, Wielgus MD, et al. Single-session dialectical behavior therapy skills training versus relaxation training for non-treatment-engaged suicidal adults: a randomized controlled trial. *BMC Psychol.* 2016;4:13.
- Kohler S and Hofmann A. Can motivational interviewing in emergency care reduce alcohol consumption in young people? A systematic review and meta-analysis. *Alcohol Alcohol.* 2015;50(2):107-17.
- Miller IW, Camargo CA Jr, Arias SA, et al. Suicide prevention in an emergency department population: The ED-SAFE Study. *JAMA psychiatry.* 2017;74(6):563-70.
- Stanley B, Brown GK, Brenner LA, et al. Comparison of the safety planning intervention with follow-up vs usual care of suicidal patients treated in the emergency department. *JAMA Psychiatry.* 2018;75(9):894-900.
- Hobbs M. Crisis intervention in theory and practice: a selective review. *Br J Med Psychol.* 1984;57(Pt 1):23-34.
- American Psychiatric Association. (2013). *Diagnostic and Statistical Manual of Mental Disorders.* (Fifth ed.). Arlington, VA: American Psychiatric Association.
- Norris D and Clark MS. Evaluation and treatment of the suicidal patient. *Am Fam Physician.* 2012;85(6):602-5.
- Myer RA and Conte C. Assessment for crisis intervention. *J Clin Psychol.* 2006;62(8):959-70.
- Doran GT. There's a S.M.A.R.T. way to write managements's goals and objectives. *Manage Rev.* 1981;70(11):35-6.
- Magnusson AR, Hedges JR, Vanko M, et al. Follow-up compliance after emergency department evaluation. *Ann Emerg Med.* 1993;22(3):560-7.

17. McCullumsmith C, Clark B, Blair C, et al. Rapid follow-up for patients after psychiatric crisis. *Community Ment Health J*. 2015;51(2):139-44.
18. Stanley B, Brown GK, Currier GW, et al. Brief intervention and follow-up for suicidal patients with repeat emergency department visits enhances treatment engagement. *Am J Public Health*. 2015;105(8):e1-e3.
19. Bryan CJ, Mintz J, Clemans TA, et al. Effect of crisis response planning vs. contracts for safety on suicide risk in U.S. Army soldiers: A randomized clinical trial. *J Affect Disord*. 2017;212:64-72.
20. American Psychiatric Association Work Group on Suicidal Behaviors. Practice guideline for the assessment and treatment of patients with suicidal behaviors. *Am J Psychiatry*. 2003;160(11 Suppl):1-60.
21. Owens PL, Fingar KR, Heslin KC, et al (2017). Emergency Department Visits Related to Suicidal Ideation, 2006-2013: Statistical Brief #220. In *Healthcare Cost and Utilization Project (HCUP) Statistical Briefs*. Rockville, MD: Agency for Healthcare Research and Quality.

Late Presentation of Transfusion-related Acute Lung Injury in the Emergency Department

David K. Peak, MD
William T. Davis, MD
Steven B. Walton, MD

San Antonio Uniformed Services Health Education Consortium, Department of Emergency Medicine, San Antonio, Texas

Section Editor: John Ashurst, DO

Submission history: Submitted August 10, 2018; Revision received October 29, 2018; Accepted November 8, 2018

Electronically published January 7, 2019

Full text available through open access at http://escholarship.org/uc/uciem_cpccem

DOI: 10.5811/cpcem.2018.11.40592

Transfusion-related acute lung injury (TRALI) is a complication of blood product transfusion characterized by respiratory distress with bilateral lung infiltrates and non-cardiogenic pulmonary edema developing within six hours of transfusion. TRALI is believed to result from an immunological response to transfused blood products. TRALI is a clinical diagnosis that requires the exclusion of other etiologies of pulmonary edema and acute lung injury. Here we report a case of a female who presented to the emergency department in acute respiratory distress two days after receiving a transfusion of packed red blood cells for post-operative anemia following a hysterectomy. [Clin Pract Cases Emerg Med. 2019;3(1):33–35.]

INTRODUCTION

Transfusion of blood products throughout calendar year 2015 was comprised of 11.3 million whole blood and red blood cells, 2.1 million apheresis platelets, and 3.6 million plasma transfusions. Complications arising from blood transfusions range from allergic reactions to hemolytic transfusion reactions, febrile transfusion reaction, transfusion-associated circulatory overload, and transfusion-related acute lung injury (TRALI).¹ TRALI is a complex clinical syndrome that arises after transfusion of fresh frozen plasma, platelets, or packed red blood cells.² TRALI occurs approximately once in every 5,000 transfusions.³ Although TRALI is usually a self-limiting process requiring minimal support, it can be fatal if not identified and treated early.⁴ Here we present a case of a 52-year-old female who developed TRALI after receiving two units of packed red blood cells for symptomatic post-operative anemia.

CASE REPORT

A 52-year-old female with hypertension and no other past history of cardiopulmonary disease presented to the emergency department (ED) in acute respiratory distress. Two days prior to arrival, the patient underwent a total laparoscopic hysterectomy, which was complicated by a prolonged surgical course of six hours and an estimated blood loss of 1,500 milliliters. The patient suffered from symptomatic post-operative anemia and was given two units of packed red blood cells on post-operative day one. The patient experienced mild shortness of breath shortly after the transfusion but was cleared by pulmonology for discharge after maintaining normal vital signs during a trial of ambulation and

lacking the appropriate clinical evidence to support a diagnosis of TRALI. The patient endorsed progressively worsening dyspnea at home, which prompted her to return to the ED less than 24 hours after being discharged.

Initial vital signs were notable for tachypnea to 30 breaths per minute, an oxygen saturation of 77% on room air, tachycardia to 107 beats per minute, blood pressure of 177/94 millimeters of mercury, and an oral temperature of 101.8° Fahrenheit. The patient was in moderate respiratory distress with suprasternal retractions, accessory muscle use, diffuse rales, anxiety, diaphoresis, and speaking in short phrases. Her electrocardiogram showed sinus tachycardia without evidence of acute ischemia or infarction.

Chest radiography (Image 1) and a computed tomography (CT)-pulmonary angiography (Image 2) revealed bilateral pulmonary edema, which was not present on prior imaging. No pulmonary embolism was seen. The patient remained hypoxic to 90% oxygen saturation despite receiving eight liters of oxygen by non-rebreather mask. The patient was given 40 milligrams (mg) intravenous (IV) furosemide, 0.4 mg sublingual nitroglycerin, and one gram IV acetaminophen. Her respiratory status remained unchanged with these interventions, so noninvasive ventilation was initiated with continuous positive airway pressure at five centimeters water.

The patient was admitted to the medical intensive care unit given her need for noninvasive ventilatory support. She underwent diuresis and weaning of her respiratory support. On hospital day three, the patient was discharged following complete resolution of her respiratory symptoms.

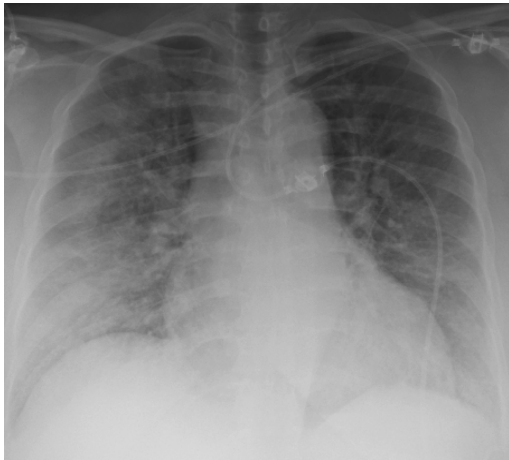

Image 1. Anteroposterior chest radiograph in the emergency department showed bilateral pulmonary edema.

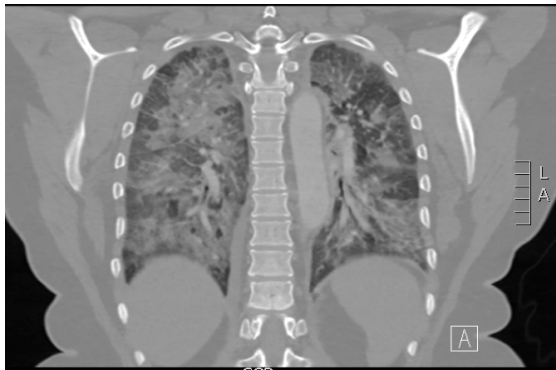


Image 2. Coronal chest computed tomography demonstrated bilateral pulmonary edema.

DISCUSSION

TRALI is defined by the National Heart, Lung, and Blood Institute as acute lung injury within six hours of a blood product transfusion that cannot be explained by another cardiopulmonary process.⁵ TRALI occurs in approximately one in 5,000 patients receiving transfusions.⁵ The risk of TRALI varies depending on the blood product transfused.⁶ According to one study, one episode of TRALI occurred per 15,924 transfusions of fresh frozen plasma, 44,092 transfusions of red blood cells, 40,452 transfusions of whole blood platelet pools, and 47,000 transfusions of apheresis platelets.⁷ Patients receiving a greater number of units of blood products are at higher risk of developing TRALI.² TRALI is now considered the leading cause of transfusion-related mortality in developed countries.²

There are two competing hypotheses as to the cause of TRALI. The “antigen-antibody hypothesis” postulates that alloantibodies in the donor blood product activate the recipient’s neutrophils, monocytes, or tissue macrophages. This immune system activation initiates an inflammatory cascade, damages

CPC-EM Capsule

What do we already know about this clinical entity?
Transfusion-related acute lung injury (TRALI) is characterized by respiratory distress and noncardiogenic pulmonary edema developing within six hours of receiving a blood transfusion.

What makes this presentation of disease reportable?
This patient presented to the emergency department (ED) more than 24 hours post-transfusion due to a progressive worsening of respiratory symptoms.

What is the major learning point?
TRALI is a possible etiology of respiratory distress even when the ED presentation is greater than six hours after a blood transfusion.

How might this improve emergency medicine practice?
A recent blood product transfusion is important history to consider for any patient presenting with respiratory distress.

the pulmonary endothelium, and increases the permeability of endothelial cells.⁸ The “two-event hypothesis” proposes that an initial event, such as surgery or underlying inflammation, increases the patient’s risk of TRALI. Then, lipids and cytokines from the transfused blood products act as the second event by activating neutrophils and causing pulmonary damage.⁹

TRALI is a clinical diagnosis that can only be made after ruling out other causes of acute lung injury. Signs and symptoms associated with TRALI include hypoxemia, fulminant pulmonary edema, fever, tachycardia, and hypotension or hypertension.² The clinical diagnosis of TRALI is made based on a history of recent blood product transfusion followed by signs and symptoms of acute lung injury. Echocardiography and B-type natriuretic peptide measurements may help in differentiating between hydrostatic causes of pulmonary edema such as transfusion-associated circulatory overload and the non-cardiogenic pulmonary edema seen in TRALI. Invasive techniques such as right heart catheterization and sampling of alveolar fluid protein may further help to classify the cause of acute pulmonary edema.¹⁰

Management of TRALI involves supportive care with oxygen supplementation and ventilatory assistance when appropriate.¹¹ If mechanical ventilation is required, a low-tidal volume strategy is important to minimize additional ventilator-

induced lung injury.¹² There is currently not sufficient literature to support either the use of corticosteroids or statins. Conservative fluid practices are appropriate, as long as appropriate steps are made to avoid hypotension. Preventative strategies, such as conservative transfusion practices, avoiding high-plasma component donors, using fresh, un-stored red blood cells, and excluding plasma from female donors, have helped reduce the incidence of TRALI.¹³

CONCLUSION

Our patient presented with respiratory distress from acute lung injury two days after receiving a blood transfusion. Although TRALI is defined as occurring within six hours of blood product transfusion, this case highlights the possibility of a delayed presentation of TRALI to the ED if the initial respiratory symptoms are not recognized. Emergency providers must keep TRALI on the differential for patients presenting with dyspnea after recently receiving any blood product transfusions.

Documented patient informed consent and/or Institutional Review Board approval has been obtained and filed for publication of this case report.

Address for Correspondence: Address for Correspondence: David K. Peak, MD, San Antonio Military Medical Center, Department of Emergency Medicine, 3841 Roger Brooke Dr, Fort Sam Houston, TX 78234. Email: kramer.peak@yahoo.com.

Conflicts of Interest: By the CPC-EM article submission agreement, all authors are required to disclose all affiliations, funding sources and financial or management relationships that could be perceived as potential sources of bias. The authors disclosed none. The view(s) expressed herein are those of the author(s) and do not reflect the official policy or position of Brooke Army Medical Center, the U.S. Army Medical Department, the U.S. Army Office of the Surgeon General, the Department of the Army, the Department of the Air Force and Department of Defense or the U.S. Government.

Copyright: © 2019 Peak et al. This is an open access article distributed in accordance with the terms of the Creative Commons Attribution (CC BY 4.0) License. See: <http://creativecommons.org/licenses/by/4.0/>

REFERENCES

1. U.S. Food and Drug Administration. Fatalities Reported to FDA Following Blood Collection and Transfusion Annual Summary for FY2016. Food and Drug Administration Center for Biologics Evaluation and Research. Available at: <https://www.fda.gov/downloads/BiologicsBloodVaccines/SafetyAvailability/ReportaProblem/TransfusionDonationFatalities/UCM598243.pdf>. Accessed October 29, 2018.
2. Sayah DM, Looney MR, Toy P. Transfusion reactions: newer concepts on the pathophysiology, incidence, treatment, and prevention of transfusion-related acute lung injury. *Crit Care Clin*. 2012;28(3):363-72.
3. Popovsky MA. Transfusion-related acute lung injury: incidence, pathogenesis and the role of multicomponent apheresis in its prevention. *Transfus Med Hemother*. 2008;35(2):76-9.
4. Sokolovic M and Pastores SM. Transfusion therapy and acute lung injury. *Expert Rev Respir Med*. 2010;4(3):387-93.
5. Toy P and Lowell C. TRALI - Definition, mechanisms, incidence and clinical relevance. *Best Pract Res Clin Anaesthesiol*. 2007;21(2):183-93.
6. Triulzi DJ. Transfusion-related acute lung injury: current concepts for the clinician. *Anesth Analg*. 2009;108(3):770-6.
7. Robillard P, Hyson C, McCombie N. TRALI, possible TRALI and respiratory complications of transfusion reported to the Canadian Transfusion Transmitted Injuries Surveillance System. 60th Annual Meeting of the American Association of Blood Banks. 2007.
8. Kopko PM, Paglieroni TG, Popovsky MA, et al. TRALI: correlation of antigen-antibody and monocyte activation in donor-recipient pairs. *Transfusion*. 2003;43(2):177-84.
9. Sachs UJ. Recent insights into the mechanism of transfusion-related acute lung injury. *Curr Opin Hematol*. 2011;18(6):436-42.
10. Gajic O, Gropper MA, Hubmayr RD. Pulmonary edema after transfusion: how to differentiate transfusion-associated circulatory overload from transfusion-related acute lung injury. *Crit Care Med*. 2006;34(5 Suppl):S109-13.
11. Goldberg AD and Kor DJ. State of the art management of transfusion-related acute lung injury (TRALI). *Curr Pharm Des*. 2012;18(22):3273-84.
12. Cho MS and Sharma S. Transfusion-related acute lung injury (TRALI). *StatPearls*. Available at: <https://www.ncbi.nlm.nih.gov/books/NBK507846/>. Accessed October 29, 2018.
13. Vlaar AP, Schultz MJ, Juffermans NP. Transfusion-related acute lung injury: a change of perspective. *Neth J Med*. 2009;67(10):320-6.

Point-of-care Ultrasound Diagnosis of Tennis Leg

Aaron J. Monseau, MD*
Brenden J. Balcik, MD*
Nicolas Denne, MD*
Melinda J. Sharon, MPH*
Joseph J. Minardi, MD*†

*West Virginia University School of Medicine, Department of Emergency Medicine, Morgantown, West Virginia
†West Virginia University School of Medicine, Department of Medical Education, Morgantown, West Virginia

Section Editor: Steven Walsh, MD

Submission history: Submitted September 21, 2018; Revision received November 8, 2018; Accepted November 14, 2018

Electronically published January 7, 2019

Full text available through open access at http://escholarship.org/uc/uciem_cpccem

DOI: 10.5811/cpcem.2018.11.41022

A 38-year-old male presented with left calf pain after a fall while skiing. Physical examination revealed tenderness over the gastrocnemius with a palpable mass and pain with resisted plantar flexion. Point-of care-ultrasound (POCUS) of the gastrocnemius was consistent with a muscle rupture, and we made a diagnosis of tennis leg. The patient was instructed to rest for two weeks, followed by a home rehabilitation program, and he was able to return to his normal activities. Here we present a case of tennis leg quickly and accurately diagnosed with POCUS, negating the need for additional advanced imaging. [Clin Pract Cases Emerg Med. 2019;3(1):36–39.]

INTRODUCTION

Patients frequently present to the emergency department (ED) with musculoskeletal injuries. The majority of the workup in the ED has long centered on evaluation for fracture with plain radiographs. Once significant fractures have been effectively ruled out, most physicians will send these patients to follow-up with their primary care physician, a physician of sports medicine, or an orthopedist. Tendon ruptures have been evaluated with ultrasound in the ED when clinically appropriate, which should speed up diagnosis and thus improve patient outcomes. Muscular injuries such as full tears, partial tears, or even large contusions can be well diagnosed with point-of-care ultrasound (POCUS), which should ensure correct and prompt treatment. We present one such case of a muscular tear.

CASE REPORT

A 38-year-old white male who is an avid skier presented with left calf pain described as sharp on the medial aspect that started after he fell while skiing about two weeks prior. During the fall, his left ankle was forced into extreme dorsiflexion. He had immediate onset of severe pain and had to stop skiing that day. He noticed swelling in the medial calf along with bruising of the area over the next few days. After about a week, he was able to ski again but had pain

aggravated by active plantar flexion.

On physical examination of his left leg, his knee and ankle both appeared normal and had normal strength and range of motion with no tenderness. Sensation and pulses were normal. There was tenderness over the medial head of his gastrocnemius with a palpable, firm, four-centimeter ovoid mass. Pain was elicited during resisted plantar flexion. His right leg was completely normal.

Radiographs of the lower leg obtained in the ED were normal. A POCUS was then performed in the ED with specific focus over the mass in the medial head of the gastrocnemius, revealing a swollen, heterogeneous, disorganized mass in the medial head of the gastrocnemius, as demonstrated in Images 1-3. Comparison views to the unaffected extremity, as seen in Image 3, further clarified the findings. We made a diagnosis of muscle tear in the medial head of the gastrocnemius.

The patient was instructed on exercises for strengthening and range of motion of the calf and ankle and specifically eccentric exercises that he should complete after an initial rest period of two weeks. On follow-up two months after the initial visit, his symptoms had nearly completely resolved. He reported mountain biking several times per week with only minimal pain after a long ride. The mass in the calf resolved, and he relayed no concerns about his leg for the upcoming ski season.

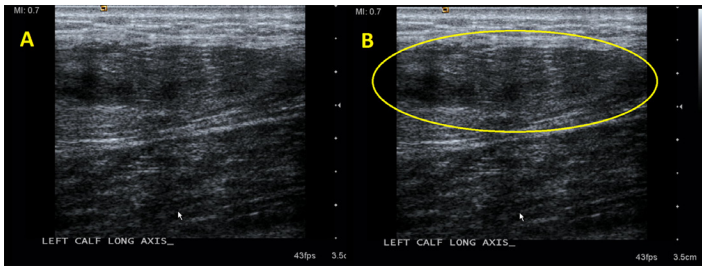


Image 1. In frame A, the enlarged, disorganized, heterogeneous tissue of a muscle tear is seen in long axis. These findings are circled in frame B.

DISCUSSION

Tennis leg, which previously indicated a plantaris tendon rupture, is now more commonly a term used to describe rupture of the medial head of the gastrocnemius muscle.¹ Tennis leg is a common injury seen in middle-aged athletes with a male predominance.² Mechanism of injury typically involves knee extension with concomitant forced dorsiflexion of the ankle or active plantar flexion of the foot during simultaneous knee extension.^{3,4} These mechanisms are commonly encountered in patients playing tennis, running, or jumping, but may occur with more routine activities such as walking up stairs, and has even been reported to occur during Namaz prayer.^{1,2,5} Patients will typically hear an audible “pop” and feel a pulling or tearing sensation within the calf at the time of injury.^{1,6} Clinical findings include calf swelling and tenderness, and pain with weight bearing.⁴ Patients will frequently hold the foot in plantar flexion, which avoids placing tension on the gastrocnemius.⁶

With the initial history and physical, the differential diagnosis would include muscle strain, muscle tear, Achilles tear, Achilles tendinosis, symptomatic Baker’s cyst, and deep venous thrombosis. While magnetic resonance imaging can be used to evaluate gastrocnemius muscle injury, high cost in addition to availability issues, limit its utility.⁴ We propose the use of POCUS to aid with the diagnosis of tennis leg and other acute musculoskeletal disorders. Point-of-care ultrasonography

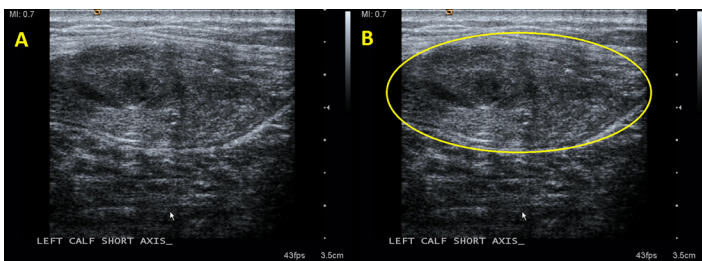


Image 2. In frame A, the enlarged, disorganized, heterogeneous tissue of a muscle tear is seen in short axis. These findings are circled in frame B.

CPC-EM Capsule

What do we already know about this clinical entity?

Tears of the medial head of the gastrocnemius can be common, especially in active individuals. Previously, magnetic resonance imaging (MRI) was frequently used for diagnosis.

What makes this presentation of disease reportable?

With point-of-care ultrasound (POCUS) for diagnosis, the patient can avoid a long stay in the emergency department and the higher cost associated with MRI.

What is the major learning point?

POCUS for muscle tears is a relatively simple skill to learn, especially for emergency physicians who are already adept at using POCUS.

How might this improve emergency medicine practice?

Using POCUS instead of MRI can significantly decrease both length of stay for patients and overall healthcare costs.

is a rapid, repeatable, noninvasive, and low-cost method of evaluating muscle injury, which can also be used to evaluate the full differential diagnosis with a high degree of accuracy in these cases.⁴ Data on the use of ultrasound in the diagnosis of tennis leg comes largely from case literature and reports by imaging specialists. There are few reports documenting the use of ultrasound at the point of care by clinicians to make the diagnosis.

Muscle ultrasonography is typically accomplished with high-frequency linear array transducers (7.5-13 MegaHertz). The most important sonographic finding is interruption of the normally uniform, homogeneous, linear appearance of the muscle, which can typically be identified at the patient’s point of maximal pain. Typically, an enlarged, heterogeneous, and disorganized mass is seen at the area of muscle injury. Other findings may include hematomas and fluid collections, which are more common with more severe tears and correspond with prolonged recovery time. Comparison views to the contralateral extremity are useful.⁷ The muscle lesions become more hypoechoic later in the course, decreasing in size with eventual

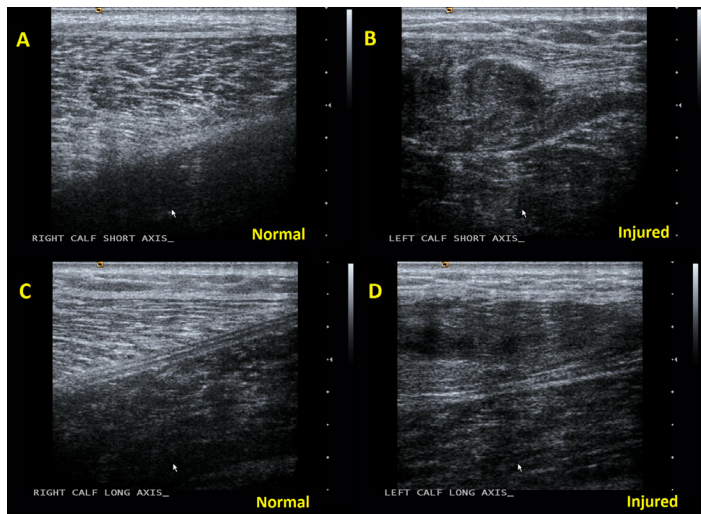


Image 3. Frame A is a comparison view of the unaffected gastrocnemius muscle in the same patient. Here the organized regular appearance of alternating dark muscle and bright connective tissue characteristic of normal muscle belly in short axis is appreciated, in comparison to the injured gastrocnemius muscle in frame B where the regular pattern is disrupted by the swollen, heterogeneous, and disorganized appearance of a muscle tear. Frame C shows the normal appearing, linearly arranged alternating dark muscle and bright connective tissue in the unaffected gastrocnemius in long axis. Frame D shows the disrupted, irregular, and heterogeneous appearance of muscle tear in the injured gastrocnemius.

formation of scar tissue at six-month to one-year follow-up.^{3,7}

Ultrasound has proven to be very useful to make the diagnosis, provide prognostic information, and evaluate other differential considerations.⁷ Bianchi et al. retrospectively reviewed sonographic images of 65 patients with clinically suspected tennis leg and described the typical sonographic features and sonographic progression of the diagnosis.⁴ Flecca et al. prospectively performed ultrasound examinations of 35 consecutive patients with clinical features of tennis leg and described the findings. Interestingly, other diagnoses such as phlebitis and a ruptured Baker's cyst were discovered in six patients.²

Treatment for a rupture of the medial head of the gastrocnemius is typically non-operative with surgery reserved for refractory cases.⁸ In the acute period, treatment revolves around rest, ice, compression and elevation. Crutches may be needed due to pain. Once the patient is able to bear weight a rehabilitation protocol can be developed where the patient gradually increases resistance against movement of the ankle progressing from resistance bands to calf-raises with body weight or more. As with many muscle tears, the patient may see a significant improvement in the first few weeks, but most will not feel back to normal for six to eight weeks or more. The available literature suggests that the severity of findings on ultrasound may correlate with the course.³

CONCLUSION

While a few studies have investigated the usefulness of ultrasound by imaging specialists, POCUS is an ideal modality for the diagnosis of a tear of the medial head of the gastrocnemius, also known as “tennis leg,” due to its bedside availability, low cost, accuracy, and utility in investigating alternate diagnoses. In addition, making the diagnosis at the bedside may decrease the need for subsequent imaging and clinic visits related to injury. Finally, during the literature review for this article, we found no other cases where a tear of a medial head of the gastrocnemius resulted from skiing as the ski boot likely protects against this injury.

Documented patient informed consent and/or Institutional Review Board approval has been obtained and filed for publication of this case report.

Address for Correspondence: Aaron J. Monseau, MD, West Virginia University School of Medicine, Department of Emergency Medicine, 1 Medical Center Dr., Morgantown, WV, 26506. Email: amonseau@hsc.wvu.edu.

Conflicts of Interest: By the CPC-EM article submission agreement, all authors are required to disclose all affiliations, funding sources and financial or management relationships that could be perceived as potential sources of bias. The authors disclosed none.

Copyright: © 2019 Monseau et al. This is an open access article distributed in accordance with the terms of the Creative Commons Attribution (CC BY 4.0) License. See: <http://creativecommons.org/licenses/by/4.0/>

REFERENCES

1. Pachecho RA and Stock H. Tennis leg: mechanism of injury and radiographic presentation. *Conn Med.* 2013;77(7):427-30.
2. Flecca D, Tomei A, Ravazzolo N, et al. US evaluation and diagnosis of rupture of the medial head of the gastrocnemius (tennis leg). *J Ultrasound.* 2007;10(4):194-8.
3. Shah JR, Shah BR, Shah AB. Pictorial essay: Ultrasonography in 'tennis leg'. *Indian J Radiol Imaging.* 2010;20(4):269-73.
4. Bianchi S, Martinoli C, Abdelwahab IF, et al. Sonographic evaluation of tears of the gastrocnemius medial head (“tennis leg”). *J Ultrasound Med.* 1998;17(3):157-62.
5. Yilmaz C, Orgenc Y, Ergenc R, et al. Rupture of the medial gastrocnemius muscle during namaz praying: An unusual cause of tennis leg. *Comput Med Imaging Graph.* 2008;32(8):728-31.
6. Sarwark JF. (2010). *Essentials of Musculoskeletal Care.* (4th ed.)

(680-681). American Academy of Orthopaedic Surgeons.

7. Kwak HS, Han YM, Lee SY, et al. Diagnosis and follow-up US evaluation of ruptures of the medial head of the gastrocnemius

("tennis leg"). *Korean J Radiol.* 2006;7(3):193-8.

8. Cheng Y, Yang HL, Sun ZY, et al. Surgical treatment of gastrocnemius muscle ruptures. *Orthop Surg.* 2012;4(4):253-7.

No Sweat! Bilateral Shoulder Reduction Using a Modified Davos Technique

Jijoe Joseph, DO, MBA
Nancy Nguyen, DO
Daniel Gruzman, DO
Anthony Boutin, MD
Dean Olsen, DO

Nassau University Medical Center, Department of Emergency Medicine, East Meadow, New York

Section Editor: Rick A. McPheeters, DO

Submission history: Submitted June 21, 2018; Revision received November 11, 2018; Accepted November 14, 2018

Electronically published January 22, 2019

Full text available through open access at http://escholarship.org/uc/uciem_cpccem

DOI: 10.5811/cpcem.2018.11.39445

Shoulder dislocations are a common entity seen and treated in the everyday practice of emergency physicians. Bilateral simultaneous shoulder dislocations, however, are rare and are only described in the literature through case reports with no consensus about how to effectively and efficiently reduce them. We present a case of a 21-year-old male who sustained bilateral simultaneous anterior shoulder dislocations after a suspected seizure. Following confirmation with radiographs, the patient's dislocations were reduced successfully and in a timely manner using a novel method: the modified Davos technique. [Clin Pract Cases Emerg Med. 2019;3(1):40–42.]

INTRODUCTION

Anterior shoulder dislocation is a well-known injury encountered in the emergency department (ED). Bilateral shoulder dislocations, however, are rare and may present as both posterior and anterior types. Of the two, bilateral posterior shoulder dislocations are far more prevalent than bilateral anterior shoulder dislocations.¹ Bilateral posterior dislocations are traditionally caused by sports injuries, seizures, electrical shock or electroconvulsive therapy. Simultaneous bilateral anterior shoulder dislocations on the other hand are usually of traumatic origin with only a few cases described in the literature.¹ After a thorough literature search, we found select cases that reported simultaneous bilateral anterior shoulder dislocations following seizures.⁵⁻⁷

CASE REPORT

A 21-year-old incarcerated male was brought by ambulance to the ED for evaluation of bilateral shoulder pain. Prior to arrival the patient had suffered a witnessed, generalized tonic-clonic seizure at the penitentiary. He was stabilized by on-site medical personnel at the institution. During examination in the ED, the patient was lucid and oriented despite transitioning out from a postictal state. Upon questioning, he reported shoulder pain that he described as similar bilaterally – moderate to severe

in intensity, sharp in nature with generalized radiation to adjacent joint structures and apprehensive to movement secondary to discomfort. He denied numbness, tingling and presence of stingers of the affected upper extremities. On physical exam, the patient was in mild distress, both shoulders resting in slight abduction and external rotation.

Both humeral heads were palpated along the anterior aspect of each glenohumeral joint with global, painful restriction of range of motion bilaterally without any evidence of peripheral motor, sensory or vascular deficit.

Plain radiographs confirmed bilateral subcoracoid dislocations, with the humeral heads lying anteriorly, medially and inferiorly in respect to the glenoid fossae (Image 1). We performed prompt reduction using modified Davos technique without anesthesia or analgesia, followed by sling immobilization and subsequent rehabilitation (Image 2).

DISCUSSION

Simultaneous bilateral glenohumeral joint dislocations, with or without fractures, in all planes are rare. The force necessary to produce a dislocation must act in synchrony in both joints.² Bilateral shoulder dislocations were first described in 1902 in a patient with excessive muscle contractions that occurred as a result of camphor overdose.² Evidence from the

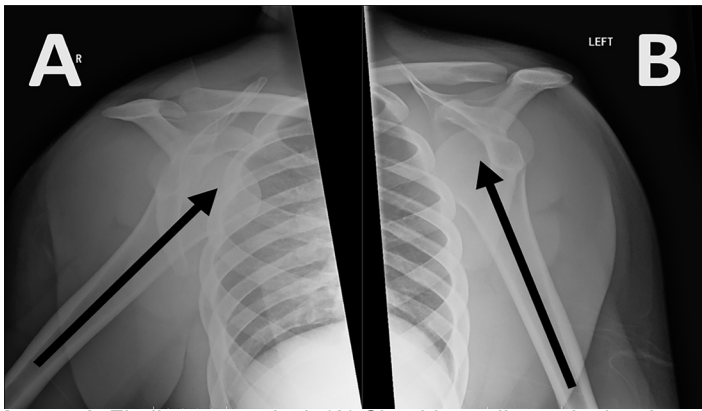


Image 1. Findings on arrival. (A) Shoulder radiograph showing anterior dislocation of the right shoulder joint (arrow). (B) Shoulder radiograph showing anterior dislocation of the left shoulder joint (arrow).

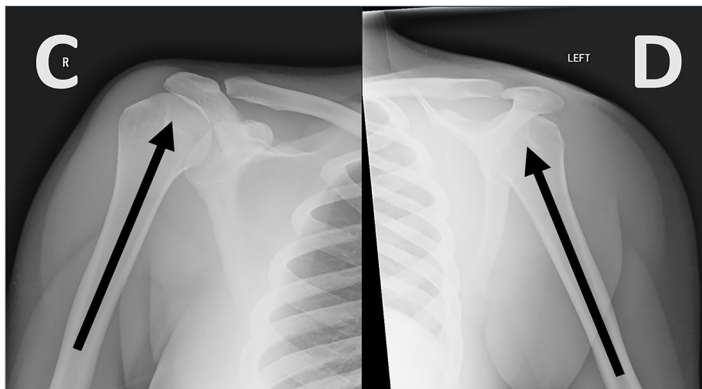


Image 2. Post-reduction films of the right (C) and left (D) shoulders following the modified Davos procedure. There is anatomic alignment of both glenohumeral joints, and no fractures are identified.

literature suggests that most bilateral dislocations are posterior.⁴⁻⁵ Bilateral anterior dislocations are rare. In 1999, Dinopoulos et al. found only 28 reported cases since 1966.³

Numerous techniques are employed by emergency physicians to reduce anterior shoulder dislocations. Most involve traction and/or rotation of the glenohumeral joint in some capacity that may result in excessive pain, sometimes requiring procedural sedation. In response to this, Boss, Holzach and Matter in 1993, working at Davos hospital in Switzerland, introduced an alternative that was later coined the Davos technique, a non-traumatic, patient-controlled and auto-reduction method that would obviate the need for pain medications or anesthesia and the associated risks. Boss et al. demonstrated a 60% success rate with the Davos technique.⁸⁻⁹

Over the past three decades, this technique has been

CPC-EM Capsule

What do we already know about this clinical entity?

Bilateral anterior shoulder dislocations are rare and usually the result of trauma. The Davos technique is a patient-controlled method of anterior shoulder dislocation reduction.

What makes this presentation of disease reportable?

This was the first case found in literature in which a simultaneous bilateral anterior shoulder dislocation was reduced using a modified version of the Davos technique.

What is the major learning point?

The Davos technique can be modified to treat bilateral simultaneous anterior shoulder dislocations successfully without the risks of procedural sedation.

How might this improve emergency medicine practice?

This case, despite being rare, represents a safe and cost-effective way to treat an entity with no clear consensus regarding management which could prove useful to clinicians who encounter it.

gaining popularity. Reports were published by Ceroni et al. in 1997, Stafylakis et al. in 2016, and Marcano-Fernández et al. in 2018. This technique has consistently been found to have an improving success rate with the most recent being 77%.¹⁰⁻¹² This is comparable to other reduction methods (notably the Milch technique, 82-89%).¹¹ The only requirements are a conscious patient, an elastic bandage, and an assistant. The Davos technique can be performed safely by trained personnel; this technique decreases the time to reduction in addition to reducing the patients' pain and anxiety levels. It can be particularly useful to those patients with a risk of recurrence or in remote locations with no immediate access to a hospital.¹² A caveat to the implementation of this technique is that it requires a high degree of communication between practitioner and patient as well as compliance from the patient.¹¹ Below are the steps to perform the Davos technique as originally described by Boss et al.

The Standard Davos Reduction Procedure

Proper positioning for the procedure includes the patient sitting on the bed holding the injured extremity with their non-injured hand with their ipsilateral knee flexed as much as possible. The physician then ties both hands together using an elastic band or tape sparing the fingers with elbows kept close to thigh (patient should avoid crossing fingers as this can lead to an increased muscle tension). The physician or an assistant sits on the patient's foot to help stabilize the wrist against the anterior tibia and instructs the patient to lean his head back and let his shoulders roll forward (shrug) as he slowly tries to lie back in bed. This neck extension exerts traction on the injured shoulder. A successful reduction should be followed by standard post-reduction intervention.⁸⁻⁹

As our patient had bilateral anterior shoulder dislocations, we modified our approach to this technique to adapt to his situation, which we describe below. To the best of our knowledge, this is the first reported use of such a technique to treat bilateral anterior shoulder dislocations caused by a seizure.

Modified Davos Procedure

1. The patient was instructed to sit with his back resting on the back of the stretcher and the bed at 90- 100 degrees. Each of the patient's arms was individually tied to a sheet.
2. One physician held gentle traction to the sheet so that the patient's arms were lifted parallel to the ground while another physician slowly lowered the head of the bed, asking the patient to extend his head backward and keep his back resting against the stretcher.
3. Dislocation is then promptly reduced, and standard post-reduction intervention should follow.

CONCLUSION

In summary, because bilateral anterior shoulder dislocations are rare there is uncertainty regarding their management. Employing the modified Davos-reduction procedure described in this case report to treat this entity yielded multiple benefits: the patient was able to control his reduction by using his own weight; no sedation or analgesia was necessary; and the provider performing the procedure did not need to exert any physical effort other than to hold traction on a sheet to keep the patient's arms elevated. Although limited in its scope of use and requiring further study, we are optimistic about the utility of this novel procedure to treat bilateral anterior shoulder dislocations as it exposes the patient to virtually no risk and potentially major benefit.

Documented patient informed consent and/or Institutional Review Board approval has been obtained and filed for publication of this case report.

Address for Correspondence: Jijoe Joseph, DO, MBA, Nassu University Medical Center, Department of Emergency Medicine, 2201 Hempstead Turnpike, East Meadow, New York 11554. Email: jjoseph9@numc.edu.

Conflicts of Interest: By the CPC-EM article submission agreement, all authors are required to disclose all affiliations, funding sources and financial or management relationships that could be perceived as potential sources of bias. The authors disclosed none.

Copyright: © 2019 Joseph et al. This is an open access article distributed in accordance with the terms of the Creative Commons Attribution (CC BY 4.0) License. See: <http://creativecommons.org/licenses/by/4.0/>

REFERENCES

1. Page AE, Meinhard BP, Schulz E, et al. Bilateral posterior fracture-dislocation of the shoulders: Management by bilateral shoulder hemiarthroplasties. *J Orthop Trauma*. 1995;9(6):526-9.
2. Dinopoulos HT, Giannoudis PV, Smith RM, et al. Bilateral anterior shoulder fracture-dislocation. *Int Orthop*. 1999;23(2):128-30.
3. Dunlop CC. Bilateral anterior shoulder dislocation: a case report and review of the literature. *Acta Orthop Belg*. 2002;68(2):168-70.
4. Tripathy SK, Sen RK, Aggarwal S, et al. Simultaneous bilateral anterior shoulder dislocation: report of two cases and review of the literature. *Chin J Traumatol*. 2011;14(5):312-5.
5. Auerbach B, Bitterman A, Mathew C, et al. Bilateral shoulder dislocation presenting as a unilateral shoulder dislocation: case report. *J Am Osteopath Assoc*. 2015;115(8):514-7.
6. Lasanianos NG and Mouzopoulos G. An undiagnosed bilateral anterior shoulder dislocation after a seizure: a case report. *Cases J*. 2008;1(1):342.
7. Marty B, Simmen HP, Käch K, et al. Bilateral anterior shoulder dislocation fracture after an epileptic seizure. A case report. *Unfallchirurg*. 1994;97(7):382-4.
8. Boss A, Holzach P, Matter P. Analgesic-free self-reduction of acute shoulder dislocation. *Z Unfallchir Versicherungsmed*. 1993;Suppl 1:215-20.
9. Boss A, Holzach P, Matter P. A new self-repositioning technique for fresh, anterior-lower shoulder dislocation. *Helv Chir Acta*. 1993;60(1-2):263-5.
10. Ceroni D, Sadri H, Leuenberger A. Anteroinferior shoulder dislocation: an auto-reduction method without analgesia. *J Orthop Trauma*. 1997;11(6):399-404.
11. Stafylakis D, Abrassart S, Hoffmeyer P. Reducing a shoulder dislocation without sweating. The Davos technique and its results. Evaluation of a nontraumatic, safe, and simple technique for reducing anterior shoulder dislocations. *J Emerg Med*. 2016;50(4):656-9.
12. Marcano-Fernández FA, Balaguer-Castro M, Fillat-Gomà F, et al. Teaching patients how to reduce a shoulder dislocation: a randomized clinical trial comparing the Boss-Holzach-Matter self-assisted technique and the Spaso method. *J Bone Joint Surg Am*. 2018;100(5):375-80.

Abdominal Cerebrospinal Fluid Pseudocyst Diagnosed with Point-of-care Ultrasound

Brittany J. Guest, DO
Michael H. Merjanian, MD
Emily F. Chiu, BS
Caleb P. Canders, MD

David Geffen School of Medicine at University of California, Los Angeles, Department of Emergency Medicine, Los Angeles, California

Section Editor: Shadi Lahham, MD, MS

Submission history: Submitted August 25, 2018; Revision received November 6, 2018; Accepted November 14, 2018

Electronically published January 7, 2019

Full text available through open access at http://escholarship.org/uc/uciem_cpchem

DOI: 10.5811/cpcem.2018.11.40780

Abdominal pseudocysts are rare complications of ventriculoperitoneal (VP) shunts characterized by accumulations of cerebrospinal fluid surrounded by fibrous layers in the intra-abdominal cavity or abdominal wall. We present a woman with bilateral VP shunts who presented with right-sided abdominal distension, pain, and tenderness and who was found to have an abdominal pseudocyst on point-of-care ultrasound and computed tomography. Given the potential to develop a secondary infection or VP shunt malfunction, it is important for emergency providers to consider intra-abdominal complications of VP shunts, including rare ones such as abdominal pseudocysts, in these patients who present with vague abdominal complaints. [Clin Pract Cases Emerg Med. 2019;3(1):43–46.]

INTRODUCTION

Placement of a ventriculoperitoneal (VP) shunt, which diverts cerebrospinal fluid (CSF) from the ventricles of the brain to the intra-abdominal cavity, is the most common neurosurgical procedure performed to relieve high intracranial pressure in patients with hydrocephalus. Common complications of VP shunts include shunt infection or obstruction, tube disconnection, and over-drainage of CSF.^{1,2} Rarely, patients with VP shunts can develop accumulations of CSF at the terminating end of the shunt, within the intra-abdominal cavity or adjacent abdominal wall. These accumulations, known as abdominal pseudocysts or “CSFomas,” can cause abdominal distension or pain, obstruction of the VP shunt, or become secondarily infected. We describe the case of a middle-aged woman with a history of bilateral VP shunt placement, who presented with weeks of abdominal distension, pain, and tenderness. She was found to have an abdominal pseudocyst on point-of-care ultrasound (POCUS) and computed tomography (CT). Neurosurgery was consulted and arranged for urgent, outpatient VP shunt revision.

CASE REPORT

A 48-year-old woman with history of congenital hydrocephalus and bilateral VP shunt placement presented to the emergency department (ED) with three weeks of

progressively worsening, right-sided abdominal distension and pain. The pain was dull, constant, non-radiating, and unrelated to meals. She reported passing flatus and denied fevers, chills, nausea, vomiting, headache, visual changes, changes in urination, constipation, melena, or bright red blood in her stools. Her past surgical history was notable for placement of a right VP shunt terminating in her right lower abdomen (last revised 10 years prior) and a left VP shunt terminating in her left lower abdomen (last revised two years prior). She denied a history of other abdominal surgeries.

On examination, the patient appeared comfortable, was afebrile, and had a heart rate of 84 beats per minute, respiratory rate of 16 breaths per minute, blood pressure of 150/80 mmHg, and oxygen saturation of 99% on room air. Her abdominal exam was notable for morbid obesity and distension of the right upper and lower abdomen, which was dull to percussion. Her abdomen was minimally tender in the right upper and lower quadrants, but not rigid or tense. There was no erythema or other skin changes overlying her VP shunt reservoirs. Fundoscopic and neurologic exams, including gait, were unremarkable. A complete blood count, comprehensive metabolic panel, lipase, and urinalysis were normal. POCUS revealed a large fluid collection with septations in the soft tissue of the right abdominal wall as seen in Image 1 and Video. Neurosurgery was consulted and requested a

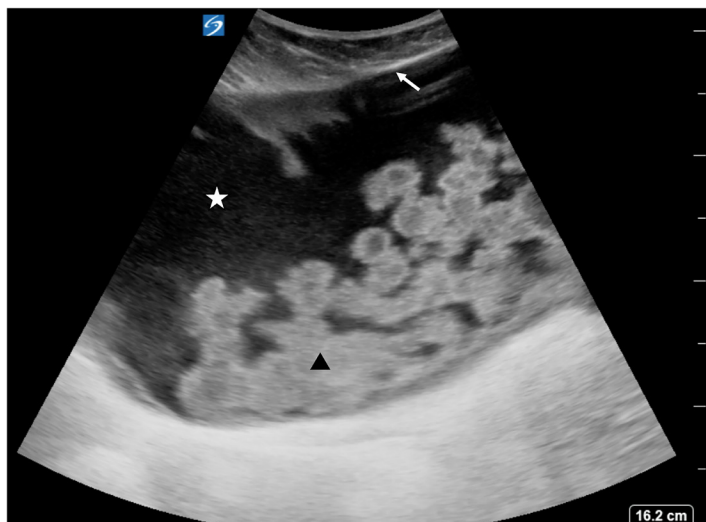


Image 1. Point-of-care ultrasound performed with a curvilinear probe in the right lower quadrant shows a large, anechoic (black) collection of cerebrospinal fluid (white star) encapsulated by a fibrous layer (white arrow) and containing echogenic debris and hyperechoic (white) septations (black arrowhead).

CT of the abdomen and pelvis with intravenous contrast, which confirmed a diagnosis of an abdominal pseudocyst as seen in Image 2. Given that the patient had no infectious symptoms or signs of VP shunt malfunction, she was scheduled for an urgent, outpatient revision of her right VP shunt.

DISCUSSION

Hydrocephalus, caused by abnormal accumulation of CSF in the ventricles of the brain, is commonly managed by placing a VP shunt, which diverts CSF to the intra-abdominal cavity. Complications of VP shunts are common: up to 30% fail within one year, and 60% fail within 10 years of placement.^{1,3} Common complications of VP shunts include shunt infection, peritonitis, shunt obstruction, and over-drainage of CSF. Formation of an abdominal pseudocyst, also known as a “CSFoma,” is a rare complication of VP shunts, with a reported incidence of <5%.^{2,4,5}

An abdominal pseudocyst is defined as an accumulation of CSF at the distal tip of the VP shunt within the abdominal cavity or, if the VP shunt has migrated, within the adjacent abdominal wall.⁶ It is referred to as a “pseudocyst” because it is encapsulated by a fibrous, peritoneal membrane, which does not contain an epithelium.⁷ Abdominal pseudocysts occur more commonly in children than adults and typically develop within five years of shunt placement or revision.⁸ The exact pathophysiology of abdominal pseudocyst formation is unclear, although risk factors include low-grade shunt infection, increased CSF protein concentration, chronic inflammation of the peritoneum (either infectious or sterile), post-operative peritoneal adhesions, and a history of multiple shunt revisions.^{5,6}

Symptoms of abdominal pseudocysts are often vague. Patients most commonly present with abdominal complaints,

CPC-EM Capsule

What do we already know about this clinical entity?
Abdominal pseudocysts are rare complications of ventriculoperitoneal (VP) shunts that can lead to abdominal pain, VP shunt obstruction, or become secondarily infected.

What makes this presentation of disease reportable?
We describe a woman with bilateral VP shunts who presented with right-sided abdominal pain and was diagnosed with an abdominal pseudocyst using point-of-care ultrasound (POCUS) in the emergency department.

What is the major learning point?
POCUS can assist emergency providers in diagnosing complications of VP shunts, including abdominal pseudocysts.

How might this improve emergency medicine practice?
Patients with abdominal pseudocysts often present with vague symptoms. This case demonstrates how POCUS can be used to diagnose an abdominal pseudocyst at the bedside, potentially reducing healthcare resource utilization and avoiding a missed diagnosis.

including pain and distension.^{9,10} Children are more likely than adults to present with symptoms related to elevated intracranial pressure, such as nausea, vomiting, and headache, secondary to shunt obstruction.^{9,11} Bacterial cultures from abdominal pseudocyst fluid are positive in 30–60% of patients; *Staphylococcus epidermidis* and *Staphylococcus aureus* are the most commonly isolated pathogens.^{5,12,13} No statistically significant link has been demonstrated between the size of the pseudocyst and the risk of infection.¹⁴ Reported complications of abdominal pseudocysts include hyponatremic seizures and inferior vena caval, ureteral, and intestinal obstructions, secondary to mass effect from the pseudocyst.^{15,16}

POCUS is a fast, non-invasive, and radiation-free imaging modality that can be used to diagnose abdominal pseudocysts at the bedside.^{17,18} On ultrasound, abdominal pseudocysts appear as anechoic (black) fluid collections with well-defined, hyperechoic (bright) margins.^{11,19} In some cases, the terminating end of the VP shunt may be visualized as two hyperechoic (bright) lines. In contrast to ascites, which surrounds the normal structures of the abdomen, the fluid within an abdominal pseudocyst is walled off from adjacent structures. CT, although useful to delineate the extent of large abdominal pseudocysts and to rule out other

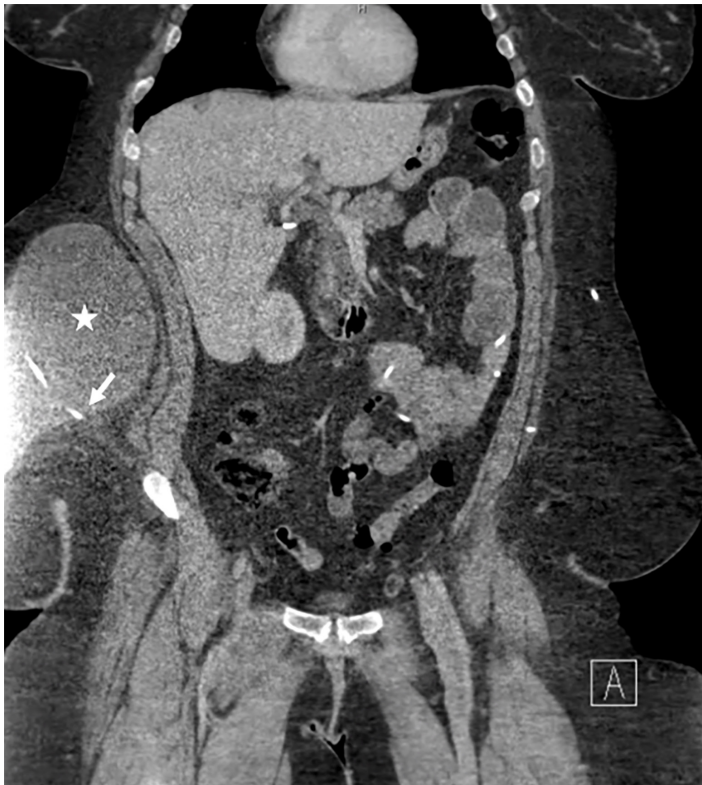


Image 2. Computed tomography of the abdomen and pelvis with intravenous contrast demonstrates a right ventriculoperitoneal shunt terminating in the soft tissue of the right lower abdominal wall (white arrow). There is an associated 22 x 20 x 11 cm collection of cerebrospinal fluid at the tip of the shunt (white star).

etiologies such as peritonitis, abscess, or pancreatic pseudocyst, is costlier than ultrasound and carries radiation risks.⁵

Treatment of abdominal pseudocysts related to VP shunts is variable and often depends on whether a secondary infection is suspected. CSF from the shunt or abdominal pseudocyst is often obtained pre-operatively to guide antibiotic selection.⁵ Often, the abdominal pseudocyst resolves spontaneously after laparoscopic or open repositioning of the catheter tip, typically to the opposite quadrant or a non-peritoneal space.^{5,20} In cases of large abdominal pseudocysts or those that do not resolve spontaneously, management options of the pseudocyst itself include percutaneous drainage, laparoscopic intra-abdominal drainage, or laparotomy with wide excision of cystic walls.^{21,22} Approximately 20% of abdominal pseudocysts recur.⁵ Neurosurgical consultation is recommended in all cases of abdominal pseudocysts diagnosed in the ED to determine if antibiotics are warranted and to schedule VP shunt revision.

CONCLUSION

We describe a woman with a history of bilateral VP shunt placement who presented with three weeks of abdominal distension, pain, and tenderness, who was found to have an

abdominal pseudocyst on POCUS and CT. In addition to common intra-abdominal complications of VP shunts, such as peritonitis, it is important to consider abdominal pseudocysts in patients presenting with vague abdominal complaints, given that up to 60% of patients will develop infection and almost all will require shunt revision. POCUS is a readily available tool in most EDs that can be used to quickly evaluate for abdominal pseudocysts in patients with VP shunts.

Video. Point-of-care ultrasound performed with a curvilinear probe in the right lower quadrant reveals a large, anechoic fluid collection (white star) that is encapsulated by a hyperechoic fibrous layer (white arrow) and contains echogenic debris (black triangle), consistent with an abdominal pseudocyst.

Documented patient informed consent and/or Institutional Review Board approval has been obtained and filed for publication of this case report.

Address for Correspondence: Caleb P. Canders, MD, David Geffen School of Medicine at University of California, Los Angeles, Department of Emergency Medicine, 924 Westwood Boulevard, Suite 300, Box 951777, Los Angeles, CA 90095. Email: ccanders@mednet.ucla.edu.

Conflicts of Interest: By the CPC-EM article submission agreement, all authors are required to disclose all affiliations, funding sources and financial or management relationships that could be perceived as potential sources of bias. The authors disclosed none.

Copyright: © 2019 Guest et al. This is an open access article distributed in accordance with the terms of the Creative Commons Attribution (CC BY 4.0) License. See: <http://creativecommons.org/licenses/by/4.0/>

REFERENCES

- Stein SC and Guo W. Have we made progress in preventing shunt failure? A critical analysis. *J Neurosurg Pediatr.* 2008;1(1):40-7.
- Chung JJ, Yu JS, Kim JH, et al. Intraabdominal complications secondary to ventriculoperitoneal shunts: CT findings and review of the literature. *AMJ Am J Roentgenol.* 2009;193(5):1311-7.
- Tuli S, Tuli J, Drake J, et al. Predictors of death in pediatric patients requiring cerebrospinal fluid shunts. *J Neurosurg.* 2004;100(5 Suppl Pediatrics):442-6.
- Aparici-Robles F and Molina-Fabrega R. Abdominal cerebrospinal

- fluid pseudocyst: a complication of ventriculoperitoneal shunts in adults. *J Med Imaging Radiat Oncol*. 2008;52(1):40-3.
5. Dabdoub CB, Dabdoub CF, Chavez M, et al. Abdominal cerebrospinal fluid pseudocyst: a comparative analysis between children and adults. *Childs Nerv Syst*. 2014;30(4):579-89.
 6. Tamura A, Shida D, Tsutsuimi K. Abdominal cerebrospinal fluid pseudocyst occurring 21 years after ventriculoperitoneal shunt placement: a case report. *BMC Surg*. 2013;13:27.
 7. Mobley LW III, Doran SE, Hellbusch LC, et al. Abdominal pseudocysts: predisposing factor and treatment algorithm. *Pediatr Neurosurg*. 2005;41(2):77-83.
 8. Pahwa S, Sherwani P, Anand R. CSF pseudocyst: an unusual cause of abdominal distension in a child. *Trop Doct*. 2014;44(2):112-3.
 9. Rainov N, Schobess A, Heidecke V, et al. Abdominal CSF pseudocysts in patients with ventriculo-peritoneal shunts. Report of fourteen cases and review of the literature. *Acta Neurochir (Wien)*. 1994;127(1-2):73-8.
 10. Ohba S, Kinoshita Y, Tsutsui M, et al. Formation of abdominal cerebrospinal fluid pseudocyst—case report. *Neurol Med Chir (Tokyo)*. 2012;52(11):838-42.
 11. Briggs JR, Hendry GM, Minns RA. Abdominal ultrasound in the diagnosis of cerebrospinal fluid pseudocysts complicating ventriculoperitoneal shunts. *Arch Dis Child*. 1984;59(7):661-4.
 12. Ersahin Y, Mutluer S, Tekeli G. Abdominal cerebrospinal fluid pseudocysts. *Childs Nerv Syst*. 1996;12(12):755-8.
 13. Salomão JF and Leibinger RD. Abdominal pseudocysts complicating CSF shunting in infants and children. Report of 18 cases. *Pediatr Neurosurg*. 1999;31(5):274-8.
 14. Roitberg BZ, Tomita T, McLone DG. Abdominal cerebrospinal fluid pseudocyst. *Pediatr Neurosurg*. 1998;29(5):267-73.
 15. Leung GK. Abdominal cerebrospinal fluid (CSF) pseudocyst presented with inferior vena caval obstruction and hydronephrosis. *Childs Nerv Syst*. 2010;26(9):1243-5.
 16. Buyukyavuz BI, Duman L, Karaaslan T, et al. Hyponatremic seizure due to huge abdominal cerebrospinal fluid pseudocyst in a child with ventriculoperitoneal shunt: a case report. *Turk Neurosurg*. 2012;22(5):656-8.
 17. Ivan Y, Hauptman J, Marin JR. Abdominal cerebrospinal fluid pseudocyst diagnosed by point-of-care ultrasound. *Pediatr Emerg Care*. 2016;32(6):408-9.
 18. Stetson RC, Goyal KA, Sandefur BJ. Abdominal cerebrospinal fluid pseudocyst masquerading as ascites in an adolescent girl. *J Emerg Med*. 2017;52(4):e159-61.
 19. Egelhoff J, Babcock DS, McLaurin R. Cerebrospinal fluid pseudocysts: sonographic appearance and clinical management. *Pediatr Neurosci*. 1985-1986;12(2):80-6.
 20. Oh A, Wildbrett P, Golub R, et al. Laparoscopic repositioning of a ventriculo-peritoneal catheter tip for a sterile abdominal cerebrospinal fluid (CSF) pseudocyst: a case report and review of the literature. *Surg Endosc*. 2001;15(5):518.
 21. Coley BD, Shiels WE II, Elton S, et al. Sonographically guided aspiration of cerebrospinal fluid pseudocysts in children and adolescent. *AJR Am J Roentgenol*. 2004;183(5):1507-10.
 22. Nfonsam V, Chand B, Rosenblatt S, et al. Laparoscopic management of distal ventriculoperitoneal shunt complications. *Surg Endosc*. 2008;22(8):1866-70.

Use of Emergency Department Extracorporeal Membrane Oxygenation for Treatment of Acute Necrotizing Myocarditis

Carly A. Loner, MD
Peter W. Crane, MD, MBA

University of Rochester Medical Center, Department of Emergency Medicine,
Rochester, New York

Section Editor: Christopher Sampson, MD

Submission history: Submitted August 15, 2018; Revision received October 9, 2018; Accepted November 7, 2018

Electronically published January 4, 2019

Full text available through open access at http://escholarship.org/uc/uciem_cpccem

DOI: 10.5811/cpccem.2018.11.40569

We report a case of acute necrotizing eosinophilic myocarditis (ANEM) secondary to drug rash with eosinophilia and systemic symptoms (DRESS) related to administration of minocycline. Myocarditis is a rare complication of DRESS and can manifest as either a self-limited hypersensitivity myocarditis or as the frequently fatal ANEM. Due to the high morbidity and mortality caused by this disease, emergency physicians should be aware of the potential of ANEM in patients with history of DRESS and new-onset cardiac dysfunction. This case reviews the clinical presentation and management of ANEM and the potential role of extracorporeal membrane oxygenation use in the emergency department. [Clin Pract Cases Emerg Med. 2019;3(1):47-50.]

INTRODUCTION

Drug rash with eosinophilia and systemic symptoms (DRESS) is a rare, drug-induced hypersensitivity syndrome most commonly associated with use of aromatic anticonvulsants and sulfonamides, but it can also occur with use of tetracyclines.¹ Treatment of DRESS involves discontinuation of the offending drug and initiation of steroid therapy. Complications of DRESS include end organ dysfunction due to eosinophilic infiltration, including hepatic, renal, and cardiac dysfunction.² The incidence of DRESS is one in 1,000-10,000 exposures with mortality estimated to be 10-20%, mainly caused by myocarditis and hepatic failure.^{3,4} The presentation of DRESS-associated myocarditis is delayed, presenting weeks to months after discontinuation of the causal drug.⁵ Most episodes of eosinophilic myocarditis are self-limited and will resolve with supportive therapy. However, some patients may develop a more severe form of myocarditis that involves eosinophilia and eventual necrosis of cardiomyocytes: acute necrotizing eosinophilic myocarditis (ANEM).⁶ This form of myocarditis can present with onset of rapidly deteriorating systolic dysfunction and hemodynamic instability.⁵

Emergency physicians should be aware of the potential of ANEM in patients previously diagnosed with DRESS. ANEM has a mortality rate of greater than 50% and a mean survival of three to four days.⁵ Precipitating factors include viral reactivation (human herpesvirus 6) and lack of detoxifying enzymes,

permitting accumulation of toxic drug metabolites.^{7,8} Age may be a less important factor with ANEM occurring in patients ranging in age from 2-83 years old.⁹

Timely recognition of the potential diagnosis of ANEM is critical to starting appropriate therapy in these critically ill patients. The most common presenting symptoms are cardiogenic shock, hypotension, and chest pain.¹⁰ Few case reports in the emergency medicine literature depict the presentation of ANEM within the emergency department (ED), and even fewer detail the potential role of mechanical assist devices such as extracorporeal membrane oxygenation (ECMO) which are becoming increasingly prevalent within the ED.^{3,5,11} We present a case of ANEM secondary to DRESS after minocycline use, which required ECMO support due to cardiovascular collapse.

CASE REPORT

A 21-year-old woman presented to the ED with complaint of chest pain and shortness of breath. Prior to arrival to the ED she had an episode of near syncope. Her previous medical history included development of diffuse erythematous rash following a course of minocycline prescribed for acne three months prior to ED presentation. The minocycline was discontinued, and she was treated with 30 milligrams (mg) daily oral prednisone with improvement of the rash. Initial vitals included blood pressure of 81/68 millimeters of mercury (mmHg), heart rate of 121 beats per minute (bpm), and

respiratory rate of 18 breaths per minute. She was afebrile (36.7°C oral temperature) and had pulse oximetry (SpO₂) of 100% on room air. Physical exam was within normal limits. Electrocardiogram (ECG) showed right bundle branch block and normal ST-T segments, but no previous ECG was available.

While in the ED the patient had an episode of syncope during peripheral venous catheter placement, and intravenous (IV) fluids were administered due to concern of vasovagal event. She was also administered 5 mg IV dexamethasone due to possibility of adrenal suppression from steroid use. Her systolic pressure improved. However, the patient complained of worsening chest pain and then became unresponsive with pulseless electrical activity arrest (PEA). Cardiopulmonary resuscitation (CPR) and Advanced Cardiac Life Support were initiated. She received two doses of 1 mg IV epinephrine with return of spontaneous circulation (ROSC) in normal sinus rhythm of 70 bpm and blood pressure of 72/48 mmHg. Due to persistent hypotension, norepinephrine infusion was administered with improvement of blood pressure to 88/56 mmHg. She was intubated for airway protection.

Due to concern for massive pulmonary embolus, computed tomography chest angiography was performed but was unremarkable. Point-of-care echocardiogram demonstrated no right heart strain and grossly reduced heart function. Telemetry demonstrated QRS widening and increasing bradycardia to 41 bpm. The patient then developed a second PEA arrest with ROSC after CPR and one dose of 1 mg IV epinephrine. She remained hypotensive with blood pressure of 60/40 mmHg despite norepinephrine infusion. Initial troponin-T measured was 8.56 nanograms/milliliter (ng/mL) (reference range 0.0-0.02 ng/mL) and complete blood count with differential showed leukocytosis of 17.5 x 10³ cells/mL (reference range 4.0-10.0 x 10³ cells/mL) and eosinophilia of 1.6 x 10³ cells/mL (reference range 0.0-0.4 x 10³ cells/mL). The cardiology service was consulted and a formal echocardiogram demonstrated a severely reduced ejection fraction of 15% (normal range 55-70%).

The dermatology service was also consulted at bedside in the ED; concern for ANEM in setting of DRESS given the rapidity of onset of her cardiac dysfunction was discussed. Also, the differential diagnoses included coronary vasculitis, viral myocarditis, infiltrative cardiomyopathy, and sepsis. (She was administered 4.5 g piperacillin/tazobactam and 20 milligrams/kilogram (mg/kg) vancomycin, and 500 mg azithromycin IV.)

While in the ED the patient developed further hypotension with blood pressure of 61/40 mmHg despite multiple vasopressors (IV vasopressin and norepinephrine infusions) and had severe acidemia and hypoxemia despite high ventilator support. Ventilator settings were tidal volume of 360mL, positive end-expiratory pressure of 20 centimeters of water (cmH₂O), and fraction of inspired oxygen of 100%, and respiratory rate of 28 breaths per minute. Arterial blood gas (ABG) revealed respiratory acidosis with pH of 7.06, carbon dioxide partial pressure (pCO₂) of 78 mmHg (reference range 33-43 mmHg), low arterial oxygen

CPC-EM Capsule

What do we already know about this clinical entity?
Acute necrotizing eosinophilic myocarditis (ANEM) is a rare complication of drug rash with eosinophilia and systemic symptoms. Presenting symptoms are cardiogenic shock, hypotension, and chest pain.

What makes this presentation of disease reportable?
Few case reports depict the presentation of ANEM in the emergency department (ED). We review the potential role of mechanical assist devices such as extracorporeal membrane oxygenation (ECMO) to manage ANEM.

What is the major learning point?
ECMO is a potential therapy for cardiogenic shock resulting from ANEM. Early use of ECMO can preserve cardiac function and improve survival in these critically ill patients.

How might this improve emergency medicine practice?
This case highlights the presentation and management of ANEM, an emergent cause of cardiovascular compromise, and the use of ECMO in the ED.

(PaO₂) of 61 mmHg (reference range 80-100 mmHg), and normal bicarbonate. Basal metabolic panel was within normal limits. Due to continued decline, she received cannulation for veno-arterial extracorporeal membrane oxygenation (VA-ECMO) within the ED. ECMO cannulation occurred within three hours of initial cardiac arrest. Once placed on ECMO she had significant improvement in her acidosis and hypoxemia on repeat ABG (pH 7.39, pCO₂ 41 mmHg, PaO₂ 135 mmHg) and was rapidly weaned from her vasopressors.

The patient was admitted to the cardiac intensive care unit (ICU) for further management. Due to concern of DRESS-induced myocarditis, dexamethasone with a dose of 1 mg/kg/day was administered intravenously. On hospital day (HD) eight, cardiac biopsy demonstrated diffuse active myocarditis with coagulative myocyte necrosis and mixed infiltrate including eosinophils consistent with DRESS myocarditis. She was decannulated from ECMO on HD 16. She was eventually discharged after 20 days in the ICU and 62 total days in the hospital with a life vest and continued cardiac follow-up. An echocardiogram performed three months later demonstrated improved ejection fraction of 34%.

DISCUSSION

This patient had cardiovascular collapse soon after presentation to the ED due to ANEM from minocycline-induced DRESS. This was caused by eosinophilic infiltration of the myocardium and eosinophilic degranulation, which caused necrosis and apoptosis of cardiomyocytes.⁶ Histology confirmed the diagnosis of ANEM with diffuse eosinophilic myocarditis with lymphocytic infiltrate and liquefactive necrosis.⁵ Patients may present with chest pain and hemodynamic instability. Additional findings include ST-T segment elevation on ECG, elevated troponin, normal coronary arteries on angiogram, and rapidly deteriorating systolic function.^{5,11} Cardiac echocardiogram will typically show increased wall thickness, severe biventricular failure and pericardial effusion.⁵ DRESS-induced myocarditis, especially ANEM, is an emergent diagnosis that can cause refractory cardiovascular shock and may require mechanical cardiac support if less-invasive measures are unsuccessful.

Treatments commonly used in the treatment of DRESS-induced myocarditis include high dose systemic steroids (from 1 mg/kg to 1 gram IV daily), IV immunoglobulin, and mycophenolate mofetil.⁵ These treatments will limit eosinophilic infiltration into myocyte tissue and prevent degranulation.⁶ Plasmapheresis and immune suppressive agents such as mycophenolate mofetil, rituximab, and azathioprine can be used in conjunction with systemic steroids.⁶ These methods of treatment may be more appropriate in the setting of non-necrotizing hypersensitivity myocarditis, which often presents as slow-onset heart failure with improved hemodynamic stability in comparison to ANEM.⁶ In these cases, fluid restriction, angiotensin-converting enzyme inhibitors, beta blockers and diuretics can be used to prevent further decompensation.⁶

In the setting of cardiovascular shock, ECMO is an alternative therapy that can bypass the lungs and heart to support gas exchange and circulatory perfusion.¹² There are two classifications of ECMO with different indications for initiation. VA-ECMO is used in cases of treatment-refractory cardiac failure or combined heart and lung failure to maintain systemic perfusion.¹² In VA-ECMO, the venously drained blood is oxygenated extracorporeally, bypasses pulmonary circulation, and is returned to the aorta. Indications for VA-ECMO include ventricular dysrhythmias, pulmonary embolism, right and left ventricular failure, sepsis, and cardiac arrest.^{12,13} In contrast, venovenous ECMO (VV-ECMO) is indicated in severe hypoxemic respiratory distress. Venously drained blood is oxygenated and decarboxylated extracorporeally and returned to the right atrium. Indications for VV-ECMO include acute respiratory distress syndrome and hypercapnic failure.^{12,13}

The time of initiation to ECMO is dependent on the rapidity of onset of systolic dysfunction, and earlier initiation may be associated with improved outcomes. The CHEER trial (mechanical CPR, hypothermia, ECMO, and early reperfusion) promotes the early use of ECMO in the setting of refractory

cardiac arrest and cardiovascular shock. In this study, selected patients presenting with out-of-hospital or in-hospital cardiac arrest were started on ECMO with CPR if they had refractory cardiac arrest for greater than 30 minutes.¹⁴ ROSC was achieved in 92% (25/26) of patients, and the difference in median time of collapse to initiation of ECMO between survivors and non-survivors was 40 minutes compared to 78 minutes.¹⁴ Another study showed that ECMO use in pediatric patients with hemodynamic compromise from dysrhythmias of acute fulminant myocarditis had shorter times to recovering sinus rhythm (median time: 1.7 days vs. 7.35 days).¹⁵ ECMO has an important role in the treatment of refractory cardiovascular shock in patients with fulminant myocarditis.^{14,16,17} Early use of ECMO can preserve cardiac function and improve survival and morbidity.^{14,15,17} A multicenter, retrospective chart review would be beneficial to better quantify the benefits of ECMO use in DRESS-induced myocarditis in comparison to other therapies.

CONCLUSION

Emergency physicians should be aware of the potential of ANEM in patients with new-onset cardiac dysfunction and history concerning for DRESS. ECMO is becoming increasingly prevalent, with studies showing reduced morbidity and mortality with earlier ECMO initiation. In some Level I trauma settings cannulation for ECMO may occur within the resuscitation bay of the ED. It is important for ED providers to be aware of the generalized types of ECMO and their indications. Timely recognition of the potential diagnosis of ANEM is critical to starting appropriate therapy. Early use of ECMO can preserve cardiac function and improve survival in these critically ill patients.

Documented patient informed consent and/or Institutional Review Board approval has been obtained and filed for publication of this case report.

Address for Correspondence: Carly A. Loner, MD, University of Rochester Medical Center, Department of Emergency Medicine, 601 Elmwood Ave, Rochester, NY 14642. Email: carly_loner@urmc.rochester.edu.

Conflicts of Interest: By the CPC-EM article submission agreement, all authors are required to disclose all affiliations, funding sources and financial or management relationships that could be perceived as potential sources of bias. The authors disclosed none.

Copyright: © 2019 Loner et al. This is an open access article distributed in accordance with the terms of the Creative Commons Attribution (CC BY 4.0) License. See: <http://creativecommons.org/licenses/by/4.0/>

REFERENCES

1. Kanno K, Sakai H, Yamada Y, et al. Drug-induced hypersensitivity due to minocycline complicated by severe myocarditis. *J Dermatol*. 2014;41(2):160-2.
2. Tas S and Simonart T. Drug rash with eosinophilia and systemic symptoms (DRESS syndrome). *Acta Clin Belg*. 1999;54(4):197-200.
3. James J, Sammour YM, Virata AR, et al. Drug reaction with eosinophilia and systemic symptoms (DRESS) syndrome secondary to furosemide: case report and review of literature. *Am J Case Rep*. 2018;19:163-70.
4. Lopez-Rocha E, Blancas K, Rodriguez-Mireles A, et al. Prevalence of DRESS syndrome. *Rev Alerg Mex*. 2014;61(1):14-23.
5. Bourgeois GP, Cafadi JA, Groysman SV, et al. Fulminant myocarditis as a late sequela of DRESS: two cases. *J Am Acad Dermatol*. 2011;65(4):889-90.
6. Thongsri L, Chularojanamantri L, Pichler WJ, et al. Cardiac involvement in DRESS syndrome. *Asian Pac J Allerg Immunol*. 2017;35(1):3-10.
7. Descamps V, Valance A, Edlinger C, et al. Association of herpesvirus 6 infection with drug reaction with eosinophilia and systemic symptoms. *Arch Dermatol*. 2001;137(3):301-4.
8. Parrillo JE. Heart Disease and the eosinophil. *New Engl J Med*. 1990;323(22):1560-1.
9. Kawano S, Kato J, Kawano Y. Clinical features and outcomes of eosinophilic myocarditis patients treated with prednisolone at a single institutional over a 27-year period. *Intern Med*. 2011;50(9):975-81.
10. Tsyrlunik A and Landman A. Drug rash with eosinophilia and systemic symptoms: two emergency department cases. *West J Emerg Med*. 2011;12(4):559-62.
11. Bourgeois GP, Cafardi JA, Groysman V, et al. A review of DRESS-associated myocarditis. *J Am Acad Dermatol*. 2012;66(6):229-36.
12. Beck L, Burg MC, Heindel W. Extracorporeal membrane oxygenation in adults- variants, complications during therapy, and role of radiological imaging. *Rofa*. 2017;189(2):119-27.
13. Makdisi G and Weng I. Extra corporeal membrane oxygenation (ECMO) review of a lifesaving technology. *J Thorac Dis*. 2015;7(7):E166-176.
14. Stub D, Bernard S, Pellegrino V, et al. Refractory cardiac arrest treated with mechanical CPR, hypothermia, ECMO and early reperfusion (the CHEER trial). *Resuscitation*. 2015;86:88-94.
15. Lin KM, Li MH, Hsieh KS, et al. Impact of extracorporeal membrane oxygenation on acute fulminant myocarditis-related hemodynamic compromise arrhythmia in children. *Pediatr Neonatol*. 2016;57(6):480-7.
16. Lo MH, Huang LS, Chang HC, et al. Drug reaction with eosinophilia and systemic symptoms syndrome associated myocarditis: a survival experience after extracorporeal membrane oxygenation support. *J Clin Pharm Ther*. 2013;38(2):172-4.
17. Jentzer JC, Clements CM, Wright RS. Improving survival from cardiac arrest; a review of contemporary practice and challenges. *Ann Emerg Med*. 2016;68(6):678-9.

Ruptured Ectopic Pregnancy in the Presence of an Intrauterine Device

Matthew R. Neth, MD
Maxwell A. Thompson, MD
Courtney Blayke Gibson, MD
John P. Gullett, MD
David C. Pigott, MD

University of Alabama at Birmingham, Department of Emergency Medicine,
Birmingham, Alabama

Section Editor: Rick A. McPheeters, DO

Submission history: Submitted October 21, 2018; Revision received December 11, 2018; Accepted January 4, 2019

Electronically published January 22, 2019

Full text available through open access at http://escholarship.org/uc/uciem_cpccem

DOI: 10.5811/cpcem.2019.1.41345

Ruptured ectopic pregnancy is the leading cause of first trimester maternal mortality. The diagnosis of ectopic pregnancy should always be suspected in patients with abdominal pain, vaginal bleeding or syncope. While the use of an intrauterine device (IUD) markedly reduces the incidence of intrauterine pregnancy, it does not confer equal protection from the risk of ectopic pregnancy. In this report we discuss the case of a female patient who presented with a ruptured ectopic pregnancy and hemoperitoneum despite a correctly positioned IUD. [Clin Pract Cases Emerg Med. 2019;3(1):51–54.]

INTRODUCTION

Although many forms of contraception are available worldwide, including oral hormonal contraceptives, barrier devices and others, the intrauterine device (IUD) remains a popular choice. By 2015 estimates, IUD use reached greater than 100 million women worldwide, and IUDs are used by approximately 7% of reproductive-age women in the United States (U.S.).^{1,2} The two major types currently available here are the T-shaped copper IUD introduced in the late 1980s and the similarly-shaped levonorgestrel-releasing IUD introduced in the early 2000s.² While it is clear that IUD use reduces the overall rate of pregnancy (including ectopic gestation), for patients with IUD failure (i.e., unintended pregnancy), the presence of an IUD markedly increases the risk that such a pregnancy will be extrauterine. A recent multicenter study from China demonstrated that pregnancies during IUD use were highly likely to be ectopic (adjusted odds ratio +16.4) and accounted for ~10% of ectopic pregnancies in the studied population.³

Although the overall incidence of ectopic pregnancy is approximately 2%,⁴ the incidence of ectopic pregnancy in emergency department (ED) patients has been shown to be significantly higher. Among patients presenting to the ED with either abdominal pain or vaginal bleeding, or both complaints, ectopic pregnancy rates has been reported as high as 6-16%.⁵

Ectopic pregnancy continues to be associated with significant maternal risk, with mortality estimates ranging from 3-6%, with the majority of deaths resulting from hemorrhage.^{6,7}

We report a case of ruptured ectopic pregnancy in a patient with an IUD. Rapid use of point-of-care ultrasonography (POCUS) enabled a timely diagnosis and potentially life-saving treatment of a patient in whom the diagnosis of pregnancy was thought to be extremely unlikely.

CASE REPORT

A 34-year-old woman with no significant past medical history presented to our ED with acute onset of suprapubic pain two hours prior to arrival. Pain was sharp, constant and non-radiating with associated nausea and vomiting. She denied any fever, vaginal bleeding, vaginal discharge, dark or bloody stools, flank pain, dyspnea, or syncope. The patient reported no history of pelvic inflammatory disease (PID) or ectopic pregnancy. She stated that she had a copper IUD placed approximately three years prior. Her initial vital signs included a blood pressure of 140/81 millimeters of mercury, pulse of 96 beats per minute, respiratory rate of 20 breaths per minute, and temperature of 98.1° Fahrenheit. Physical examination was remarkable for moderate to severe lower abdominal tenderness to palpation with associated rebound and guarding.

Although a urine pregnancy test was ordered shortly after the patient arrived, while walking to the restroom, the patient sustained an episode of lightheadedness and near-syncope. Immediately following this episode, point-of-care transabdominal pelvic sonography was performed to further evaluate the etiology for the patient's presentation.

A focused assessment with sonography in trauma (FAST) protocol revealed free fluid in Morison's pouch and the splenorenal space, as well as in the pelvis. Transabdominal pelvic sonography also showed evidence of an IUD within the uterus without evidence of an intrauterine pregnancy. Extensive pelvic hematoma was noted surrounding the uterus (Image 1, Video 1). Transabdominal ultrasound examination of the adnexa showed a thick-walled circular structure in the left adnexa (Image 2) demonstrating marked hypervascularity ("ring of fire" sign) (Image 3, Video 2) as well as fetal cardiac activity consistent with a live ectopic pregnancy. Given these findings, emergent gynecology consultation was obtained. Initial laboratory studies showed mild anemia and leukocytosis (hemoglobin 10.9 grams per deciliter, white blood cell count 12.4×10^9 per liter). Serum beta-human chorionic gonadotropin was 24,976 milli-international units per milliliter. The patient was taken emergently to the operating room where a ruptured left tubal ectopic pregnancy with one liter hemoperitoneum was noted, and salpingectomy was performed. The patient remained hemodynamically stable, and was subsequently discharged in good condition.

CPC-EM Capsule

What do we already know about this clinical entity?

Factors affecting fallopian tube or uterine function, such as prior surgery, infection, or instrumentation, may increase risk for ectopic pregnancy.

What makes this presentation of disease reportable?

This case illustrates the utility of point-of-care ultrasound in the diagnosis of ectopic pregnancy in a setting where pregnancy was thought to be very unlikely.

What is the major learning point?

In this case, a ruptured ectopic pregnancy was diagnosed in a patient with an intrauterine device, an important risk factor for ectopic pregnancy.

How might this improve emergency medicine practice?

This case reinforces the importance of a high clinical suspicion for ectopic pregnancy in reproductive-age women, despite the use of highly effective contraception.

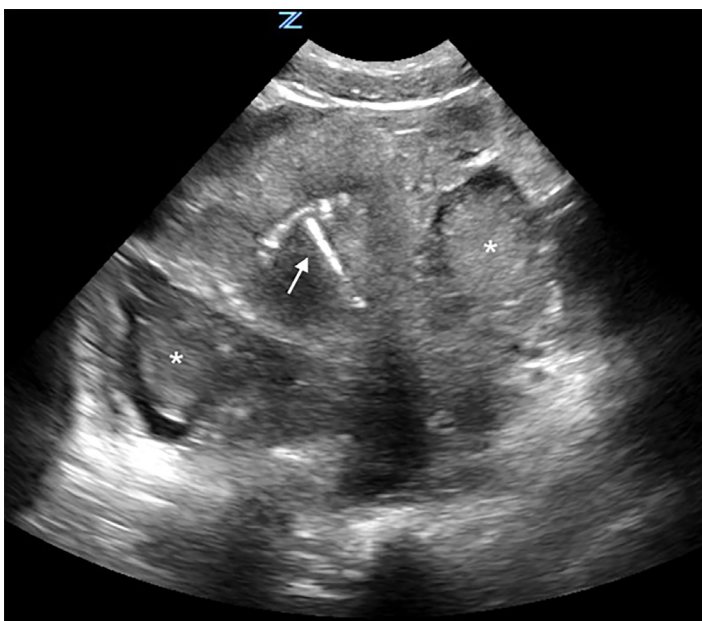


Image 1. Transabdominal transverse ultrasound view of the pelvis. Note presence of intrauterine device within uterus (arrow) and pelvic hematoma (asterisks).

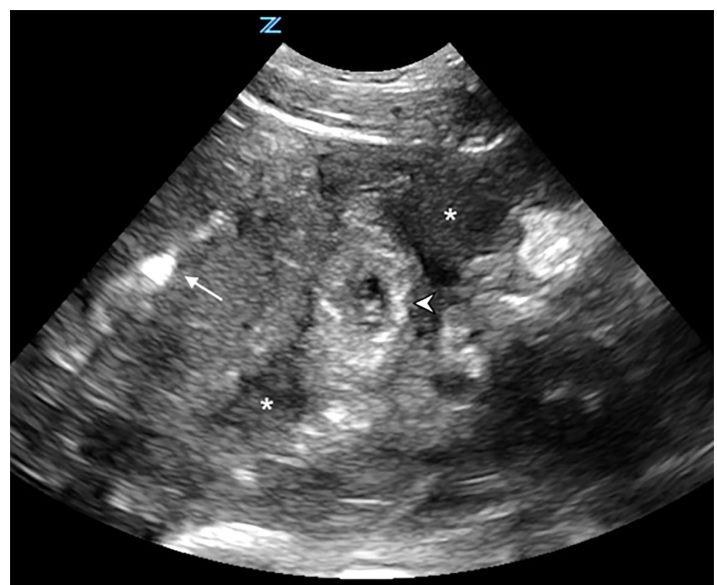


Image 2. Transabdominal transverse ultrasound view of the pelvis. Note presence of intrauterine device within uterus (arrow) and adjacent ectopic pregnancy in left adnexa (arrowhead). Hypoechoic fluid (asterisks) surrounds the uterus and adnexa.

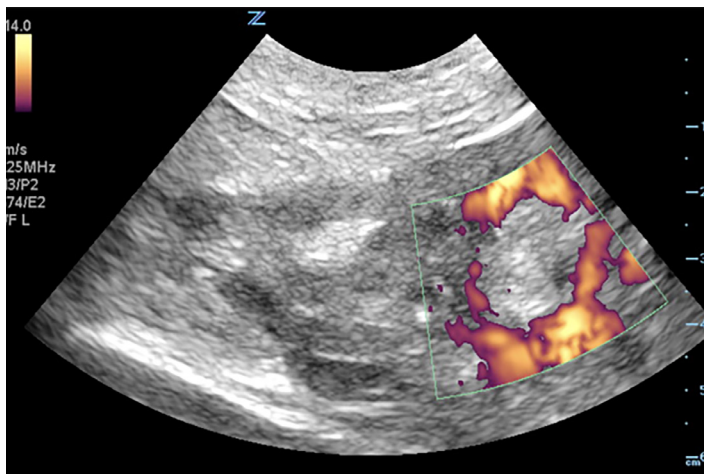


Image 3. Transabdominal power Doppler ultrasound of the left adnexa. Note ectopic pregnancy with “ring of fire” sign reflecting peripheral hypervascularity.

DISCUSSION

POCUS has long been shown to be a valuable tool for the emergency physician, particularly in the evaluation of patients with early pregnancy. This case demonstrates the utility of POCUS in the rapid, accurate diagnosis of ruptured ectopic pregnancy leading to definitive treatment in a patient on highly effective contraceptive therapy. The presence of ruptured ectopic pregnancy with concurrent IUD use is notable, as this complication has rarely been reported.

One of the most attractive features of the IUD is its proven efficacy in preventing pregnancy. The one-year failure rate for the copper and the levonorgestrel-releasing IUD has been reported at 0.8 and 0.1 unintended pregnancies per 100 women, respectively.⁸ Although IUD use markedly reduces the overall rate of pregnancy (including ectopic pregnancy) compared to patients not on contraception, in patients with IUD failure (i.e., unintended pregnancy during IUD use), the risk of ectopic pregnancy ranges from 15-27%.⁹ As previously noted, the incidence of ectopic pregnancy in the U.S. is approximately 2%.⁴

While it is clear that IUD use can reduce the overall rate of pregnancy, for patients with IUD failure the presence of an IUD markedly increases the risk that such a pregnancy will be extrauterine. Intrauterine pregnancy in the setting of reported IUD use is rare, and is three times more likely in patients with a malpositioned or inadvertently missing IUD.¹⁰ While IUDs are clearly effective in the prevention of intrauterine pregnancy, they are not necessarily designed to prevent extrauterine gestation. Although the overall incidence of ectopic pregnancy in IUD patients is very low, it is clear that those who become pregnant in the setting of IUD use are at increased risk for ectopic pregnancy.^{3,8,11,12}

Ectopic pregnancy is defined as the implantation of a fertilized ovum outside the endometrial cavity.¹³ Multiple risk

factors for ectopic pregnancy have been identified, including age, history of PID, smoking, previous ectopic pregnancy, and in vitro fertilization.^{14,15} POCUS is a valuable tool in the evaluation of the patient with suspected ectopic pregnancy. While transabdominal ultrasound can rapidly demonstrate the presence of significant intraperitoneal hemorrhage, transvaginal ultrasound (TVUS) is considered the imaging modality of choice for the definitive diagnosis of ectopic pregnancy, allowing for earlier visualization and diagnosis.¹⁶ The sensitivity of TVUS for ectopic pregnancy has been reported at greater than 90%.¹⁷ The accuracy and utility of TVUS, however, may vary depending on operator experience, maternal body mass index, fibroids, and ovarian pathology.¹⁶ In patients where a clear ectopic pregnancy can be visualized, as in our case, transabdominal ultrasound may also provide a definitive diagnosis.

Apart from direct visualization of an ectopic pregnancy, the POCUS evaluation of the patient with suspected ectopic pregnancy may also yield additional evidence suggestive of ectopic pregnancy. Other helpful signs include an empty uterus, adnexal mass, free fluid, or the pseudogestational sac of ectopic pregnancy. While useful, these signs alone do not have reported sensitivities high enough to effectively rule out ectopic pregnancy based on current literature.¹⁸ The most concerning ultrasound finding in this setting, the presence of free intraperitoneal fluid in Morison’s pouch, has been found to be predictive of the need for operative intervention.¹⁹ With this finding, the emergency physician can use ultrasound as a means to expedite patient care and reduce the risk for hemodynamic compromise due to ongoing intraperitoneal hemorrhage.

Pregnant patients with an empty uterus on ultrasound, but without clear signs of ectopic pregnancy such as an extrauterine gestational sac, adnexal mass or free fluid, are classified as having a pregnancy of unknown location. These patients will require follow-up until their pregnancy location is confirmed. Ultimately, approximately 7-20% of women with an initial pregnancy of unknown location will eventually receive a diagnosis of an ectopic pregnancy.^{13,16}

This case report is unique in that it demonstrates the rapid identification of an ectopic pregnancy in a patient with a concurrent IUD using POCUS by EPs. Although the patient’s history of current IUD use initially suggested that pregnancy was unlikely, this case clearly demonstrates that a standard ultrasound-based approach to the ED evaluation of the patient with early pregnancy provided a rapid definitive diagnosis of an emergent medical condition.

CONCLUSION

Although the use of POCUS in the evaluation of a woman presenting with acute pelvic pain has been well-described, the complicating factor of IUD use in the setting of early pregnancy makes this case notable. Point-of-care transabdominal pelvic ultrasound demonstrated an IUD in place without an

intrauterine pregnancy, as well as a clearly visualized ectopic pregnancy and free intraperitoneal fluid. Combined with a positive pregnancy test, these findings were diagnostic for ruptured ectopic pregnancy.

While there is some controversy regarding IUD use and subsequent risk for ectopic pregnancy, it is reasonable to conclude that IUD use is associated with increased risk for ectopic pregnancy, particularly in patients with a positive pregnancy test. Because the IUD was designed explicitly to prevent the implantation of intrauterine pregnancy, the diagnosis of ectopic pregnancy in this setting should be highly suspected. Our case confirms that clinicians should always consider the possibility of ectopic pregnancy in reproductive-age females even with a history of contraceptive use.

Video 1. Transabdominal ultrasound of the pelvis. Note presence of intrauterine device within uterus and extensive pelvic hematoma (arrows).

Video 2. Transabdominal power Doppler ultrasound of the left adnexa. Note ectopic pregnancy with “ring of fire” sign reflecting peripheral hypervascularity.

Documented patient informed consent and/or Institutional Review Board approval has been obtained and filed for publication of this case report.

Address for Correspondence: David C. Pigott, MD, University of Alabama at Birmingham, Department of Emergency Medicine, 619 South 19th St., OHB 251, Birmingham, AL 35249. Email: dpigott@uabmc.edu.

Conflicts of Interest: By the CPC-EM article submission agreement, all authors are required to disclose all affiliations, funding sources and financial or management relationships that could be perceived as potential sources of bias. The authors disclosed none.

Copyright: © 2019 Pigott et al. This is an open access article distributed in accordance with the terms of the Creative Commons Attribution (CC BY 4.0) License. See: <http://creativecommons.org/licenses/by/4.0/>

REFERENCES

- United Nations, Department of Economic and Social Affairs, Population Division. Trends in Contraceptive Use Worldwide 2015 (ST/ESA/SER.A/349). 2015. Available at: <http://www.un.org/en/development/desa/population/publications/pdf/family/trendsContraceptiveUse2015Report.pdf>. Accessed October 20, 2018.
- Centers for Disease Control and Prevention. National Survey of Family Growth: Current use of contraceptive methods. 2018. Available at: www.cdc.gov/nchs/nsfg/key_statistics/c.htm#currentuse. Accessed on December 5, 2018.
- Li C, Zhao WH, Zhu Q, et al. Risk factors for ectopic pregnancy: a multi-center case-control study. *BMC Pregnancy Childbirth*. 2015;15:187.
- Centers for Disease Control and Prevention (CDC). Ectopic pregnancy—United States, 1990-1992. *MMWR Morb Mortal Wkly Rep*. 1995;44(3):46-8.
- Murray H, Baakdah H, Bardell T, et al. Diagnosis and treatment of ectopic pregnancy. *CMAJ*. 2005;173(8):905-12.
- Sivin I and Batar I. State-of-the-art of non-hormonal methods of contraception: III. Intrauterine devices. *Eur J Contracept Reprod Health Care*. 2010;15(2):96-112.
- Callahan R, Yacobson I, Halpern V, et al. Ectopic pregnancy with use of progestin-only injectables and contraceptive implants: a systematic review. *Contraception*. 2015;92(6):514-22.
- Hatcher RA, Nelson AL, Trussell J, et al. (2018). *Contraceptive Technology* (pp. 884). (21st ed.). New York, NY: Ardent Media.
- Heinemann K, Reed S, Moehner S, et al. Comparative contraceptive effectiveness of levonorgestrel-releasing and copper intrauterine devices: the European Active Surveillance Study for Intrauterine Devices. *Contraception*. 2015;91(4):280-3.
- Moschos E and Twickler DM. Intrauterine devices in early pregnancy: findings on ultrasound and clinical outcomes. *Am J Obstet Gynecol*. 2011;204(5):427.e1-6.
- Lehfeldt H, Tietze C, Gorstein F. Ovarian pregnancy and the intrauterine device. *Am J Obstet Gynecol*. 1970;108(7):1005-9.
- Xiong X, Buekens P, Wollast E. IUD use and the risk of ectopic pregnancy: a meta-analysis of case-control studies. *Contraception*. 1995;52(1):23-34.
- Barnhart KT. Clinical practice. Ectopic pregnancy. *New Engl J Med*. 2009;361(4):379-87.
- Farquhar CM. Ectopic pregnancy. *Lancet*. 2005;366(9485):583-91.
- Bouyer J, Coste J, Shojaei T, et al. Risk factors for ectopic pregnancy: a comprehensive analysis based on a large case-control, population-based study in France. *Am J Epidemiol*. 2003;157(3):185-94.
- Kirk E. Ultrasound in the diagnosis of ectopic pregnancy. *Clin Obstet Gynecol*. 2012;55(2):395-401.
- Winder S, Reid S, Condous G. Ultrasound diagnosis of ectopic pregnancy. *Australas J Ultrasound Med*. 2011;14(2):29-33.
- Richardson A, Gallos I, Dobson S, et al. Accuracy of first-trimester ultrasound in diagnosis of tubal ectopic pregnancy in the absence of an obvious extrauterine embryo: systematic review and meta-analysis. *Ultrasound Obstet Gynecol*. 2016;47(1):28-37.
- Moore C, Todd WM, O'Brien E, et al. Free fluid in Morison's pouch on bedside ultrasound predicts need for operative intervention in suspected ectopic pregnancy. *Acad Emerg Med*. 2007;14(8):755-8.

The Quick and Dirty: A Tetanus Case Report

Patrick Mcelaney, MD
Masayuki Iyanaga, MD
Stormy Monks, PhD, MPH
Edward Michelson, MD

Texas Tech University Health Sciences Center El Paso, Department of Emergency Medicine, El Paso, Texas

Section Editor: Rick A. McPheeters, DO

Submission history: Submitted October 16, 2018; Revision received December 13, 2018; Accepted January 3, 2019

Electronically published January 22, 2019

Full text available through open access at http://escholarship.org/uc/uciem_cpsem

DOI: 10.5811/cpsem.2019.1.41301

Tetanus is an increasingly rare diagnosis in the post-vaccination era, although it continues to have significant morbidity and mortality worldwide. In the United States (U.S.), the incidence of tetanus has declined dramatically due to the widespread use of the vaccine. High-risk populations for tetanus in the U.S. include the elderly, diabetics, injection drug users, and unvaccinated individuals. This is a report of a 78-year-old male with an incomplete immunization history who presented to an emergency department with jaw pain and who was ultimately diagnosed with tetanus. This report highlights the importance of prompt diagnosis, treatment, and prevention of tetanus. [Clin Pract Cases Emerg Med. 2019;3(1):55–58.]

INTRODUCTION

Tetanus is a life-threatening disease caused by a toxin produced by *Clostridium tetani*, an anaerobic gram-positive, spore-forming bacillus found in soil and animal excrement.¹ Tetanus is an acute illness diagnosed clinically with features of hypertonia and muscle spasm in the absence of a more likely diagnosis.² Tetanus occurs when bacterial spores enter the body through breaks in the skin and then germinate under anaerobic conditions. The bacteria produce an exotoxin – tetanospasmin – which binds at the neuromuscular junction and results in painful muscle contractions.²

There are three different clinical forms in which tetanus can be classified: generalized; localized; and cephalic.³ Generalized tetanus is the most common presentation with patients initially experiencing spasms of the masseter muscle or trismus. This progresses to painful, generalized spasms of muscles in the neck, abdomen, or extremities and potential abdominal rigidity.³ Patients may also develop autonomic instability, which may contribute to cardiac arrest. Localized tetanus occurs with spasm to a certain muscle group, typically near the wound.³ Cephalic tetanus, the most rare form, is associated with wounds to the head or face. It presents differently from the other forms with cranial nerve palsies resulting in flaccid paralysis rather than spasm. Both localized and cephalic tetanus can progress to the generalized

form.³ Upon recognition of tetanus, prompt treatment is recommended with tetanus immunoglobulin, tetanus toxoid, aggressive wound care, and antibiotics with coverage for anaerobes. Medications for treatment of muscle spasm should be used, with benzodiazepines being the preferred agent.³

Since 1947 when the disease was first tracked by the Centers for Disease Control and Prevention (CDC), the number of tetanus cases has declined by more than 95% and deaths have declined by greater than 99%.¹ Only 29 cases of tetanus were reported in the United States (U.S.) in 2015, yet it continues to be a morbid disease, with a case-fatality rate of 13.2%.¹ Populations at an increased risk for infection include unvaccinated individuals, the elderly, diabetics and illicit-injection drug users.¹ Knowing how to identify and treat at-risk wounds and cases of suspected tetanus is essential for emergency physicians.

CASE REPORT

A 78-year-old Hispanic male, a resident of Mexico, presented to the emergency department (ED) of a level I county trauma center with a complaint of jaw pain for the prior three days. On review of systems, the patient also complained of abdominal bloating. His medical history was only significant for hypertension, although he did not take any medications. The patient did not report having allergies, and

he denied the use of tobacco, alcohol, or drugs. His vital signs were as follows: temperature 36.9° Celsius, blood pressure 165/109 millimeters of mercury, pulse 88 beats per minute, and respiratory rate 18 breaths per minute.

The patient appeared to have difficulty opening his mouth and exhibited dysphonia as a result. He had no reproducible pain on exam, but was uncomfortable when we attempted to open his mouth by force. While the oral exam was limited secondary to poor mouth opening, no caries or abscesses were appreciated. No lymph nodes were palpable and the remainder of the ear, nose, and throat exam was unremarkable. The patient's abdomen was rigid and mildly distended, but non-tender. On examination, the medial aspect of the right forearm revealed a healing laceration, approximately 5 x 2 centimeters. When questioned about the wound, the patient stated he had received it at work two weeks prior when he fell off a tractor and into muddy water. He stated he had been seen by a doctor in Mexico for the wound and was given a topical medication, which he had been applying. When asked about immunization status, the patient denied receiving tetanus prophylaxis for the wound and stated that as far as he could remember he had never received any childhood or adult vaccinations.

The patient's blood tests and computed tomography of the head and neck were within normal limits. Based on exam and history, the likely diagnosis of tetanus was made. His wound was debrided. Based on CDC guidelines, we administered tetanus immunoglobulin, tetanus diphtheria and pertussis vaccine, and intravenous metronidazole. The patient was admitted to the medical intensive care unit (MICU) for further treatment.

In the MICU, the patient was treated symptomatically with two milligrams of lorazepam as needed for muscle spasms. On hospital day four, he had an apneic event and subsequent cardiac arrest. He was intubated with return of spontaneous circulation. He was unable to be weaned from the ventilator due to continued trismus. On hospital day 11, the patient had a tracheostomy and percutaneous gastrostomy tube placed, given concern for prolonged course on the ventilator. He had continued improvement in mental status along with fewer episodes of tetany. On hospital day 16, the tracheostomy became dislodged without respiratory compromise, and so was discontinued. On hospital day 18, the patient was transferred to the general medical ward. He was started on a clear liquid diet and was able to advance to full liquids during his stay. He was discharged to home on hospital day 22 with the formal diagnosis of tetanus.

DISCUSSION

Tetanus is a clinical diagnosis defined by hypertonia with painful muscle contractions or spasm. Generalized tetanus is a disease characterized as a progression from trismus to stiffness of neck muscles with difficulty swallowing. Patients may develop generalized muscle spasms including spasms of the abdominal musculature that can present as a rigid

CPC-EM Capsule

What do we already know about this clinical entity?

Tetanus is a well-known life threatening disease.

What makes this presentation of disease reportable?

This case reports on a classic presentation on what is becoming an increasingly rare disease since widespread use of the vaccine.

What is the major learning point?

Certain groups remain high risk for tetanus, especially when unvaccinated or under-vaccinated.

How might this improve emergency medicine practice?

Readers will understand the presenting features, the treatment, and prevention of tetanus.

abdomen.² The differential diagnosis for those presenting with trismus and muscle spasm as seen in tetanus includes dystonia, strychnine poisoning, dental infection, seizure, or hypocalcemic tetany.⁴ Patients with tetanus may also initially present with non-specific symptoms including weakness, dysphagia, facial pain, and trismus.

Laboratory tests and imaging may aid in evaluating for other diagnoses, but do not assist in confirmation of tetanus.¹ Given that the diagnosis of tetanus is purely clinical and patients commonly present with non-specific features, the diagnosis on initial presentation may be difficult. However, patients with tetanus should all be admitted for monitoring.³ Multiple case reports have described patients who presented with tetanus-like symptoms, but were initially diagnosed and treated for otitis media or sinusitis.^{5,6} In patients who present with symptoms associated with tetanus, obtaining a vaccination history and a history of recent wounds is warranted in order to risk stratify.

Prior to the advent and implementation of a widespread vaccination program in the 1940s there were an average of 500-600 cases per year in the U.S. Since then, the incidence of tetanus has greatly decreased. During the most recent CDC report from 2001-2008 there was a total of 233 cases during that eight-year time period.¹ Despite the decline in cases, there remains a significant population who are at increased risk of the disease. According to the CDC, populations at increased

risk include individuals over 65 years old, diabetics, and illicit-injection drug abusers.¹ In addition, foreign-born individuals have an increased incidence.¹ This disparity is likely secondary to decreased vaccination rates among minorities and foreign-born individuals.⁷⁻⁹ The increasing numbers of immigrants to the U.S. from countries with lower immunization rates may result in more cases of tetanus presenting in coming years.¹⁰

While a diagnosis of tetanus is rare, the treatment of wounds that are at risk of having tetanus contamination remains a common occurrence in EDs in the U.S. In a prospective observational study at five university-affiliated hospitals, researchers found that emergency physicians greatly undertreat at-risk patients who may have inadequate primary immunizations. Specifically, this study reported that 504 patients were identified as having inadequate primary immunizations, and none of the patients received appropriate tetanus prophylaxis.¹¹

The CDC recommends tetanus vaccine alone for patients who have clean, minor wounds and unknown or fewer than the three-shot series. However, if the patient presents with a wound that is neither clean nor minor, tetanus immunoglobulin should be administered in addition to the tetanus vaccine (Table).¹² Furthermore, major and/or dirty wounds require aggressive local wound care and possibly antibiotics. Major wounds include avulsions, punctures, burns, and/or crush injuries. Dirty wounds include those contaminated with dirt, soil, feces, or saliva.² Those with up-to-date tetanus vaccination do not require vaccination for clean or dirty wounds.¹²

CONCLUSION

Many patients presenting to the ED for wound care will be unimmunized for tetanus or under-immunized with non-protective antibody titers. At-risk patients include individuals over 50 years old and immigrants who may not have been

fully immunized.^{13,14} As pointed out by Sanchez-Gonzalez et al., the latter group includes “all foreign-born, irrespective of their birthplace, citizenship, language and years of residence in the United States.”⁸ According to the 2010 U.S. census, 12.9% or 40 million people in the U.S. are foreign born⁷ and as of 2016, 49.2 million Americans are 65 years or older.¹⁵ It is imperative to scrutinize the immunization history in these high-risk populations and administer immunoglobulin and tetanus vaccine as recommended. The possibility of tetanus, though rare, should be included in the differential diagnosis of patients from high-risk groups presenting with the typical pattern of muscular rigidity.

Documented patient informed consent and/or Institutional Review Board approval has been obtained and filed for publication of this case report.

Address for Correspondence: Stormy Monks, PhD, Texas Tech University Health Sciences Center El Paso, Department of Emergency Medicine, 210 N Rick Francis Suite 302C, El Paso TX, 79905. Email: stormy.monks@ttuhsc.edu.

Conflicts of Interest: By the CPC-EM article submission agreement, all authors are required to disclose all affiliations, funding sources and financial or management relationships that could be perceived as potential sources of bias. The authors disclosed none.

Copyright: © 2019 Mcelaney et al. This is an open access article distributed in accordance with the terms of the Creative Commons Attribution (CC BY 4.0) License. See: <http://creativecommons.org/licenses/by/4.0/>

Table. Centers for Disease Control and Prevention guide to tetanus prophylaxis with tetanus immunoglobulin in routine wound management.

History of absorbed tetanus toxoid-containing vaccines (doses)	Clean, minor wound		All other wounds*	
	DTaP, Tdap, or Td [†]	TIG [‡]	DTaP, Tdap, or Td [†]	TIG [‡]
Unknown or <3	Yes	No	Yes	Yes
≥3	No [§]	No	No [¶]	No

DTaP, diphtheria and tetanus toxoids and acellular pertussis vaccine; Tdap, tetanus toxoid, reduced diphtheria toxoid, and acellular pertussis; Td, tetanus and diphtheria toxoids; TIG, tetanus immune globulin.

*Such as, but not limited to, wounds contaminated with dirt, feces, soil, and saliva; puncture wounds; and wounds resulting from missiles, crushing, burns, and frostbite.

[†]DTaP is recommended for children <7 years of age. Tdap is preferred to Td for persons aged 11 years or older who have not previously received Tdap. Persons 7 years or older who are not fully immunized against pertussis, tetanus or diphtheria should receive one dose of Tdap for wound management and as part of the catch-up series.

[‡]People with HIV infection or severe immunodeficiency who have contaminated wounds (including minor wounds) should also receive TIG, regardless of their history of tetanus immunizations.

[§]Yes, if ≥10 years since the last tetanus toxoid-containing vaccine dose.

[¶]Yes, if ≥5 years since the last tetanus toxoid-containing vaccine dose.

REFERENCES

1. Tetanus Surveillance --- United States, 2001--2008. Centers for Disease Control and Prevention website. Available at: <http://www.cdc.gov/mmwr/preview/mmwrhtml/mm6012a1.htm>. 2011. Accessed August 1, 2018.
2. Manual for the Surveillance of Vaccine-Preventable Diseases. Centers for Disease Control and Prevention website. Available at: <http://www.cdc.gov/vaccines/pubs/surv-manual/chpt16-tetanus.html>. 2017. Accessed August 3, 2018.
3. Tetanus. Manual for the Surveillance of Vaccine-Preventable Diseases. Centers for Disease Control and Prevention website. Available at: <https://www.cdc.gov/tetanus/clinicians.html#symptoms>. 2018. Accessed November 30, 2018.
4. Nickson, C. Tetanus. Life in the Fast Lane - Medical Blog. Available at: <https://lifeinthefastlane.com/cc/tetanus/>. 2014. Accessed November 30, 2018.
5. Tetanus -- Rutland County, Vermont, 1992. MMWR. Centers for Disease Control and Prevention website. Available at: <https://www.cdc.gov/mmwr/preview/mmwrhtml/00017686.htm>. 1992. Accessed September 1, 2018.
6. Tetanus --- Puerto Rico, 2002. MMWR. Center for Disease Control and Prevention website. Available at: <https://www.cdc.gov/mmwr/preview/mmwrhtml/mm5128a1.htm>. 2002. Accessed September 1, 2018.
7. Lu P-J, Rodriguez-Lainz A, O'Halloran A, et al. Adult vaccination disparities among foreign-born populations in the U.S., 2012. *Am J Prev Med*. 2014;47(6):722-33.
8. Sánchez-González L, Rodriguez-Lainz A, O'Halloran A, et al. Factors related to pertussis and tetanus vaccination status among foreign-born adults living in the United States. *J Community Health*. 2016;42(3):573-82.
9. Varan AK, Rodriguez-Lainz A, Hill HA, et al. Vaccination Coverage Disparities Between Foreign-Born and U.S.-Born Children Aged 19--35 Months, United States, 2010--2012. *J Immigr Minor Health*. 2016;19(4):779-89.
10. United States Census Bureau. The foreign-born population in the United States. Census.gov website. Available at: www.census.gov/newsroom/pdf/cspan_fb_slides.pdf. 2011. Accessed August 3, 2018.
11. Talan DA, Abrahamian FM, Moran GJ, et al. Tetanus immunity and physician compliance with tetanus prophylaxis practices among emergency department patients presenting with wounds. *Ann Emerg Med*. 2004;43(3):305-14.
12. Centers for Disease Control and Prevention. (2015) "Tetanus." In Hamborsky J, Kroger A & Wolfe S (Eds.), *Epidemiology and Prevention of Vaccine-Preventable Diseases (13th ed.)*. Washington, District of Columbia: Public Health Foundation.
13. Alagappan K, Donohue B, Guzik H, et al. Seroprevalence of tetanus antibodies among immigrants over age 50: a comparison to an aged matched US-born population. *Ann Emerg Med*. 2004;44(4):S126-7.
14. AdultVaxView. Centers for Disease Control and Prevention website. Available at: <http://www.cdc.gov/vaccines/imz-managers/coverage/adultvaxview/pubs-resources/NHIS-2016.html>. 2018. Accessed August 1, 2018.
15. United States Census Bureau. The nation's older population is still growing, Census Bureau Reports. Census.gov website. Available at: <https://census.gov/newsroom/press-releases/2017/cb17-100.html>. 2017. Accessed August 17, 2018.

Acute Lymphoblastic Leukemia Presenting Solely as Low Back Pain

Joshua Goodwin, BSc
Bijon Das, MD

Dalhousie University, Department of Emergency Medicine, Halifax, Nova Scotia

Section Editor: Rick A. McPheeters, DO

Submission history: Submitted August 21, 2018; Revision received October 22, 2018; Accepted January 1, 2019

Electronically published January 29, 2019

Full text available through open access at http://escholarship.org/uc/uciem_cpccem

DOI: 10.5811/cpccem.2019.1.40699

A 23-year-old man with acute lymphoblastic leukemia presented to the emergency department without any history of constitutional symptoms (fatigue, anorexia, or weight loss), dyspnea, bruising, or bleeding. Presentation of acute leukemia solely as musculoskeletal pathology is common in pediatric populations but rare among adult patients. Recognizing this presentation of acute leukemia in adult patients could help prevent delayed diagnoses. [Clin Pract Cases Emerg Med. 2019;3(1):59–61.]

INTRODUCTION

Acute lymphoblastic leukemia (ALL) is the second most common acute leukemia in the United States, with more than 6,500 new cases annually.¹ The majority (80%) of ALL cases are diagnosed in children.¹ In Canada, an estimated 5,900 patients were diagnosed with leukemia in 2016, with rates of 24% for acute myeloid leukemia (AML), and 5% for ALL.² Both AML and ALL typically present with constitutional symptoms such as fatigue, anorexia, weight loss, and sequelae of bone marrow failure, which include increased bleeding, easy bruising, infection, and dyspnea.^{1,3} Patients with ALL also commonly present with fever, night sweats, lymphadenopathy, splenomegaly, or hepatomegaly; in some cases, central nervous system involvement is seen.² Musculoskeletal symptoms are uncommon in cases of acute leukemia in adults.⁴⁻⁶ In some rare cases, acute leukemia can present solely as bone pain, although this presentation is more commonly seen in children.^{7,8} This case report demonstrates the importance of keeping leukemia on the differential for patients presenting solely with lower back pain in order to prevent a delayed diagnosis.

CASE REPORT

A 23-year-old male presented to the emergency department (ED) with pain in his lower back radiating down his left leg. He had awoken from sleep five days prior with lower back pain radiating into both legs. He went to a hospital in another city where he was prescribed morphine, cyclobenzaprine, and naproxen. His pain was initially

controlled enough that he could return to work while taking naproxen. The pain continued to progressively worsen and had begun to cause difficulty walking. He went to a family physician who suspected sciatic nerve pain and sent him to the ED for imaging of his spine.

On presentation to the ED, his pain was 7 to 8.5 out of 10. There was no history of trauma, and he had no bowel incontinence, urinary retention, or saddle anesthesia. He had no recent fevers, chills, or weight loss. His appetite was decreased due to his pain, and he had not had a bowel movement in three days. He had no significant past medical history and usually took no medications. He had consumed seven to nine alcoholic drinks and used cocaine the night before the pain began.

On examination, his temperature was 37.3°C, his heart rate was 96 beats per minute, his respiratory rate was 16 breaths per minute, his blood pressure was 124/60 millimeters of mercury, and his oxygen saturation was 100%. His abdomen was soft and non-tender. Testicular and rectal exams were normal. Palpation of the left sacroiliac joint revealed exquisite tenderness, identifying the more precise location of the lower back pain. Neurologic exam revealed normal tone, strength, and coordination in all extremities. Radiographs of the pelvis and sacroiliac joints were normal.

On laboratory workup, white cell count was $6.89 \times 10^9/\text{liter}$ (L) (normal range, 4.5-11), serum hemoglobin was 100 grams (g)/L (normal range, 140-180), platelet count was $143 \times 10^9/\text{L}$ (normal range, 150-350), and C-reactive protein (CRP) was

227 milligrams/L (normal range, <8). Peripheral blood smear showed increased polychromasia, some poikilocytosis with occasional teardrop cells, mature neutrophils, roughly 20% circulating blasts, and rare giant platelets, all consistent with acute leukemia. In the ED he was administered two milligrams (mg) of hydromorphone and 600 mg of ibuprofen orally. He was later admitted to the hematology service. He was diagnosed with precursor B-cell ALL and initiated on the Dana-Farber chemotherapy protocol. Two years post-diagnosis, his leukemia was in remission and he had recently completed his final cycle of chemotherapy.

DISCUSSION

This otherwise-healthy, 23-year-old male patient was diagnosed with leukemia after presenting solely with lower back pain. Initial differential diagnoses considered for this patient by the attending emergency physician (EP) included cauda equina syndrome, sciatic nerve pathology, trauma to the lower back, spinal metastases, rheumatological disorders, and infection. Given that the patient stated he had used alcohol and cocaine the night before the pain began, rhabdomyolysis was also considered. In an otherwise-healthy young patient with recent recreational drug use on history, one might also keep drug-seeking behaviour on the differential.

Physical examination and history ruled out the possibility of a cauda equina syndrome, trauma, or a previously diagnosed malignancy. The exquisite tenderness of the patient's sacroiliac joint on palpation suggested pathology of the sacroiliac joint or associated bones rather than sciatic nerve pathology. This was a distinguishing feature of this patient's presentation, likely precipitated by cellular proliferation in bone of the left sacroiliac joint.

The possibility of bone marrow proliferation from leukemia being the cause of the lower back pain was considered by the attending EP once the patient's peripheral blood smear was found to contain circulating blasts. Acute leukemia is not known to typically present as pain in the large joints such as the sacroiliac,⁴ and in this case none of the typical signs of leukemia such as fatigue, bruising, or easy bleeding were present to aid in a clinical diagnosis.^{1,2} To our knowledge, no cases of leukemia presenting solely with back pain are present in the emergency medicine literature. There have been cases where adult patients' acute leukemia has presented as pain in joints involving the back, but these were accompanied by pain in the long bones that is more typical of leukemia.^{4,5} Results of the peripheral blood smear aside, an undiagnosed rheumatological disorder might also have been considered as a potential etiology. If blood tests had not been ordered in the case of this healthy young patient, his diagnosis could have been missed while his leukemia continued to progress undetected.

An otherwise-healthy young patient presenting to the ED with a sole complaint of lower back pain in the absence of

CPC-EM Capsule

What do we already know about this clinical entity?

Leukemia can present solely as musculoskeletal pain, but this presentation is typically seen in children.

What makes this presentation of disease reportable?

There are no previously reported cases of a leukemia presenting solely as low back pain.

What is the major learning point?

Leukemia could be considered in the differential diagnosis of new-onset, low back pain in an otherwise-healthy young adult with no history of physical trauma.

How might this improve emergency medicine practice?

Considering leukemia in the differential diagnosis for these patients could prevent a missed diagnosis of leukemia.

trauma could raise suspicion for leukemia and prompt the EP to order a complete blood count and peripheral blood smear. Both a strong opioid and a non-steroidal anti-inflammatory (or acetaminophen) are suggested for cancer pain rated by the patient to be greater than 6 out of 10 on a numerical rating scale,⁹ and both hydromorphone and ibuprofen were required for effective pain management in this case.

CONCLUSION

In this case, acute leukemia was diagnosed in a patient presenting with a sole clinical feature of lower back pain. This diagnosis would typically be much lower on the differential for a purely musculoskeletal complaint. To prevent delay in diagnosis and appropriate treatment, it is important to recognize leukemia as a potential cause of severe lower back pain in an otherwise-healthy patient presenting to the ED.

Documented patient informed consent and/or Institutional Review Board approval has been obtained and filed for publication of this case report.

Address for Correspondence: Joshua Goodwin, BSc, Dalhousie University, Department of Emergency Medicine, Halifax Infirmary, 1796 Summer Street, Suite 355, Halifax, Nova Scotia, Canada, B3H 3A7. Email: Joshua.goodwin@dal.ca.

Conflicts of Interest: By the CPC-EM article submission agreement, all authors are required to disclose all affiliations, funding sources and financial or management relationships that could be perceived as potential sources of bias. The authors disclosed none.

Copyright: © 2019 Goodwin et al. This is an open access article distributed in accordance with the terms of the Creative Commons Attribution (CC BY 4.0) License. See: <http://creativecommons.org/licenses/by/4.0/>

REFERENCES

1. Terwilliger T and Abdul-Hay M. Acute lymphoblastic leukemia: a comprehensive review and 2017 update. *Blood Cancer J.* 2017;7(6):e577.
2. Hodgson CS and Associates. Blood Cancer in Canada Facts & Stats 2016. Available at: http://www.llscanada.org/sites/default/files/National/CANADA/Pdf/InfoBooklets/Blood_Cancer_in_Canada_Facts_%26_Stats_2016.pdf. Accessed on April 28, 2018.
3. De Kouchkovsky I and Abdul-Hay M. Acute myeloid leukemia: a comprehensive review and 2016 update. *Blood Cancer J.* 2016;6(7):e441.
4. Sakata H, Nakao A, Matsuda K, et al. Acute leukemia presenting as bone pain with normal white blood cell count. *Acute Med Surg.* 2014;1(4):249.
5. Mohanty PK, Patel DK, Majhi CD, et al. Aleukemic acute lymphoblastic leukemia in adult presenting with rheumatic manifestations and osteolytic vertebral lesions. *J Indian Rheumatol Assoc.* 2004;12:150-2.
6. Shapiro FD and Leval LD. Case records of the Massachusetts General Hospital (Case 32 – 2000); A boy with vertebral compression fracture. *N Eng J Med.* 2000;343(16):1168-76.
7. Brix N, Rosthøj S, Herlin T, et al. Arthritis as presenting manifestation of acute lymphoblastic leukaemia in children. *Arch Dis Child.* 2015;100(9):821-5.
8. Chell J, Fernandes JA, Bell MJ. The orthopaedic presentation of acute leukaemia in childhood. *Ann R Coll Surg Engl.* 2001;83(3):186-9.
9. Ripamonti CI, Bandieri E, Roila F, et al. Management of cancer pain: ESMO clinical practice guidelines. *Ann Oncol.* 2011;22 Suppl 6:vi69-77.

Ruptured Tubal Ectopic Pregnancy at Fifteen Weeks Gestational Age

Justine K. Stremick, MD, MPH&TM*
Kyle Couperus, MD†
Simeon W. Ashworth, DO†

*Fort Belvoir Community Hospital, Department of Emergency Medicine, Fort Belvoir, Virginia
†Madigan Army Medical Center, Department of Emergency Medicine, Joint Base Lewis-McChord, Washington

Section Editor: Rick A. McPheeters, DO

Submission history: Submitted September 7, 2018; Revision received December 2, 2018; Accepted January 1, 2019

Electronically published January 29, 2019

Full text available through open access at http://escholarship.org/uc/uciem_cpccem

DOI: 10.5811/cpcem.2019.1.40860

Tubal ectopic pregnancies are commonly diagnosed during the first trimester. Here we present a second-trimester tubal ectopic pregnancy that was previously misdiagnosed as an intrauterine pregnancy on a first-trimester ultrasound. A 39-year-old gravida 1 para 0 woman at 15 weeks gestation presented with 10 days of progressive, severe abdominal pain, along with vaginal bleeding and intermittent vomiting for two months. She was ultimately found to have a ruptured left tubal ectopic pregnancy. Second-trimester ectopic pregnancies carry a significant maternal mortality risk. Even with the use of ultrasound, they are difficult to diagnose and present unique diagnostic challenges. [Clin Pract Cases Emerg Med. 2019;3(1):62–64.]

INTRODUCTION

While ectopic pregnancies account for only 1.3-2.4% of all pregnancies, they are the leading cause of first-trimester maternal pregnancy-related mortality and account for 10% of maternal pregnancy-related deaths.^{1,2} Ninety-five percent of ectopic pregnancies occur in the fallopian tubes, and these are most often discovered in the first trimester. There are only a handful of cases of second-trimester tubal ectopic pregnancies published in the literature.³ Most ectopic pregnancies are diagnosed between six and nine weeks of gestation when the patient becomes symptomatic.¹ They often present with complaints of vaginal bleeding, pelvic pain and occasionally syncope.³ Tubal rupture is common with as many as 16% of tubal ectopic pregnancies showing signs of rupture by six weeks of gestational age.¹ Here we present a rare case of a tubal ectopic pregnancy that progressed to 15 weeks after being misdiagnosed as an intrauterine pregnancy during a first-trimester ultrasound.

CASE REPORT

A 39-year-old gravida one para zero woman at an estimated 15 weeks four days gestation presented to the emergency department (ED) with 10 days of progressive, severe abdominal pain. She also reported moderate vaginal

bleeding for the prior several months along with intermittent nausea and vomiting. Six weeks prior to presentation, she was seen in clinic where her obstetrician performed a point-of-care ultrasound (POCUS). It was documented that the patient had an intrauterine pregnancy with an estimated gestational age of nine weeks and zero days.

In the ED she was tachycardic to 131 beats per minute and normotensive at 116/84 millimeters of mercury. Her exam was significant for tenderness to palpation of her entire abdomen with rebound and guarding present. Her labs were significant for a moderate anemia with a hemoglobin of 9.2 grams per deciliter along with a leukocytosis of 13,200 white blood count per millimeter cubed, and mild elevations of her alanine aminotransferase and aspartate aminotransferase at 76 units per liter (u/L) and 53 u/L, respectively. Limited POCUS identified a fetus measuring 16 weeks one day by biparietal diameter with a heart rate of 163 bpm. Oligohydramnios was noted. Obstetrics was consulted at that time. Shortly afterwards, the patient was taken for a formal ultrasound. This showed free fluid and clotted blood throughout her abdomen and was initially concerning for uterine rupture (Image 1).

The patient was taken to the operating room for an exploratory laparotomy and was found to have a ruptured left tubal ectopic pregnancy. She underwent a left-sided salpingo-

oophorectomy and required four units of packed red blood cells. She did well post-operatively and was discharged home on post-operative day two.

DISCUSSION

Vaginal bleeding, pelvic and abdominal pain occurring in the first 20 weeks of pregnancy are common ED complaints. The differential is broad, including both obstetric and non-obstetric causes, and diagnosis can often be complicated by displacement of intra-abdominal organs. During the work-up of these patients, one must maintain a high clinical suspicion for ruptured ectopic pregnancy, even in the setting of prior imaging showing an intrauterine pregnancy. This can either be due to a heterotopic pregnancy or, as in this case, an initial misdiagnosis of an ectopic pregnancy as an intrauterine pregnancy.

Ultrasound plays a critical role in the work-up and diagnosis of ectopic pregnancy. Typical ultrasound features used to diagnose ectopic pregnancies in the first trimester include the presence of a pseudo-gestational sac, thickened endometrium, fluid in the posterior cul-de-sac and the tubal ring sign. The tubal ring sign is the most specific finding for a tubal ectopic pregnancy but may become less reliable as the pregnancy advances and the tubal wall thins.³

The most common type of ectopic pregnancy that is mistaken for an intrauterine pregnancy during first trimester ultrasound is an interstitial pregnancy. Interstitial ectopic pregnancies are located in the fallopian tube just as it meets the uterine cavity, with most of the gestational sac located outside of the uterus. Ultrasound findings that are suggestive of interstitial pregnancy include a gestational sac covered by an asymmetric or incomplete myometrial mantle, an empty uterine cavity with a central linear echo,

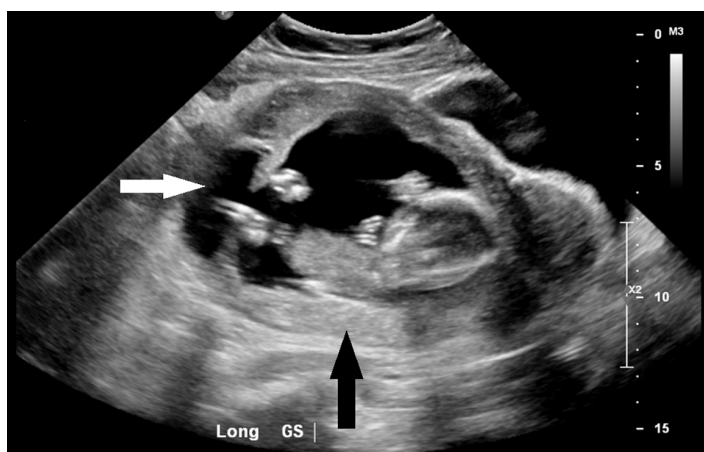

Image 1. Longitudinal image of the gestational sac (GS) depicted by the black arrow. A communication between the gestational sac and peritoneum is depicted by the white arrow.

CPC-EM Capsule

What do we already know about this clinical entity?

Ectopic pregnancies are a leading cause of maternal morbidity and mortality that rarely progress to the second trimester.

What makes this presentation of disease reportable?

This is a rare case of a tubal ectopic pregnancy that progressed to 15 weeks gestational age after being initially misdiagnosed as an intrauterine pregnancy during a first-trimester ultrasound.

What is the major learning point?

Although ultrasound has revolutionized the diagnosis of ectopic pregnancy, its use can sometimes mislead practitioners and in general present unique diagnostic challenges.

How might this improve emergency medicine practice?

This article reviews common ultrasound findings that can help distinguish later-term ectopic pregnancies from normal intra-uterine pregnancies, aiding in quicker recognition and diagnosis.

an eccentrically located gestational sac, myometrium located between the gestational sac and uterine cavity, and a gestational sac seen high in the uterine fundus.⁴

Unfortunately, images from this patient's initial in-office ultrasound were not saved and therefore not available for review. However, the surgical report does not indicate that this was an interstitial pregnancy. For other types of tubal ectopic pregnancies, transvaginal sonography has a 99.9% specificity in diagnosing ectopic pregnancies in the first trimester; so it is likely that human error played a role in her misdiagnosis.³

Later-term ectopic pregnancies can present unique challenges and are often misdiagnosed. Common ultrasound findings suggestive of an ectopic pregnancy are an abnormal fetal lie, displaced cervix, oligohydramnios, and maternal intraperitoneal fluid.⁵ On further review of the

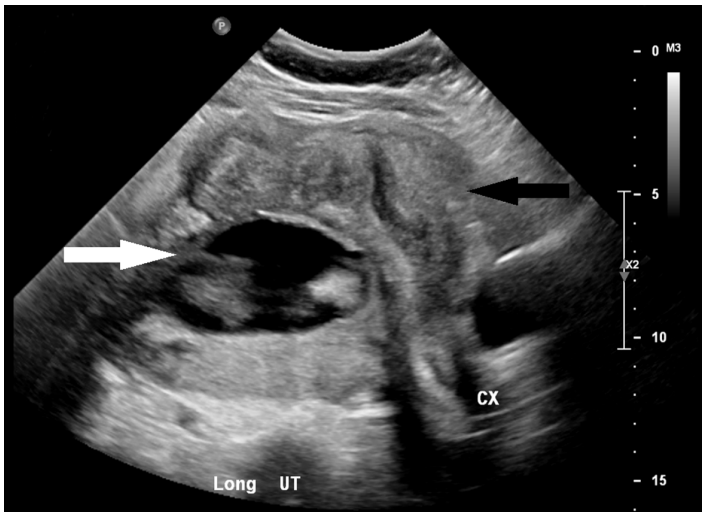


Image 2. Longitudinal image of the uterus (UT) is depicted by the black arrow. The gestational sac is seen sitting posterior to the uterus and is depicted by the white arrow. CX, cervix.

formal ultrasound imaging in this case, the gestational sac can be seen lying posterior to the uterus (Image 2). Echogenic fluid may not be seen in the posterior cul-de-sac in up to two-thirds of tubal pregnancies, as was true in this case. It is therefore prudent to check for either non-echogenic fluid, representing clotted blood in the posterior cul-de-sac, or fluid in the right upper quadrant.¹

CONCLUSION

Second trimester tubal ectopic pregnancies are rare but carry a significant maternal mortality risk. Tubal ectopic pregnancies that progress beyond the first trimester are even more rare especially after receiving prenatal care. Despite being difficult to diagnose it should be considered and investigated regardless of prior ultrasound documentation in a pregnant female presenting with severe abdominal pain.

Documented patient informed consent and/or Institutional Review Board approval has been obtained and filed for publication of this case report.

Address for Correspondence: Justine Stremick, MD, MPH&TM, Fort Belvoir Community Hospital, Department of Emergency Medicine, 9300 DeWitt Loop, Fort Belvoir, VA 22060. Email: jstremic@gmail.com.

Conflicts of Interest: By the CPC-EM article submission agreement, all authors are required to disclose all affiliations, funding sources and financial or management relationships that could be perceived as potential sources of bias. The authors disclosed none. The views expressed are those of the author(s) and do not reflect the official policy or position of the U.S. Army Medical Department, Department of the Army, Department of Defense or the U.S. Government.

Copyright: © 2019 Stremick et al. This is an open access article distributed in accordance with the terms of the Creative Commons Attribution (CC BY 4.0) License. See: <http://creativecommons.org/licenses/by/4.0/>

REFERENCES

1. Taran F, Kagan K, Hübner M et al. The diagnosis and treatment of ectopic pregnancy. *Dtsch Arztebl Int.* 2015;112(41):693-703.
2. Corrigan KJ and Kowalzyk DR. Ectopic ovarian pregnancy in a second-trimester patient. *Am J Emerg Med.* 2007;25(9):185.e3-4.
3. Liu J, Khan A, Johnson S, et al. The usefulness of gestational sac and placental sonographic morphology in differentiating between second-trimester tubal and abdominal pregnancy: case report and a review of literature. *J Clin Ultrasound.* 2014;42(3):162-8.
4. DeWitt C and Abbott J. Interstitial Pregnancy: A potential for misdiagnosis of ectopic pregnancy with emergency department ultrasonography. *Ann Emerg Med.* 2002;40(1):106-9.
5. Worley KC, Hnat MD, Cunningham FG. Advanced extrauterine pregnancy: diagnostic and therapeutic challenges. *Am J Obstet Gynecol.* 2008;198(3):297.e1-7.

Left Ventricular Thrombus in a 34-year-old Female Seen on Point-of-care Ultrasound

Faraz Khan, MS*
Shadi Lahham, MD, MS†

*University of California, Irvine School of Medicine, Irvine, California
†University of California, Irvine, Department of Emergency Medicine, Orange, California

Section Editor: Christopher Sampson, MD

Submission history: Submitted August 29, 2018; Revision received November 26, 2018; Accepted January 1, 2019

Electronically published January 22, 2019

Full text available through open access at http://escholarship.org/uc/uciem_cpchem

DOI: 10.5811/cpcem.2019.1.40801

[Clin Pract Cases Emerg Med. 2019;3(1):65–66.]

CASE PRESENTATION

A 34-year-old female with a history of methamphetamine-associated cardiomyopathy presented to the emergency department (ED) with generalized weakness, altered mental status, and chest pain. She reported a recent placement of an automatic implantable cardioverter-defibrillator at an outside hospital three months prior to current presentation and had a documented ejection fraction of 15%. Upon arrival to the ED, she was hypotensive with a systolic blood pressure ranging in the 40s to 70s millimeters of mercury and was hypothermic at 33.6 degrees Celsius. She appeared cachectic and had a 3/6 systolic ejection murmur at the left upper sternal border. We performed a point-of-care ultrasound (POCUS) to assess the patient's cardiac function and found a large left ventricular (LV) thrombus measuring 5.8 x 2.8 centimeters (Image). Further views of the thrombus seen in the video reveal a large hyperechoic density in the left ventricle. The patient was admitted to the intensive care unit for vasopressor support and thrombolytic therapy.

DISCUSSION

Cardiovascular disease is the leading cause of death in patients with methamphetamine use, and cardiomyopathy is a rare complication that can occur.¹ This can lead to systolic dysfunction and reduced ejection fraction, which is an important risk factor for the formation of LV thrombi.² In patients with methamphetamine-associated cardiomyopathy with an ejection fraction less than 40%, up to 33% can develop a LV thrombus.³ POCUS can be used to help diagnose patients with an LV thrombus.⁴ Patients found to have a thrombus should be started on anticoagulation therapy.⁵

Documented patient informed consent and/or Institutional Review Board approval has been obtained and filed for publication of this case report.

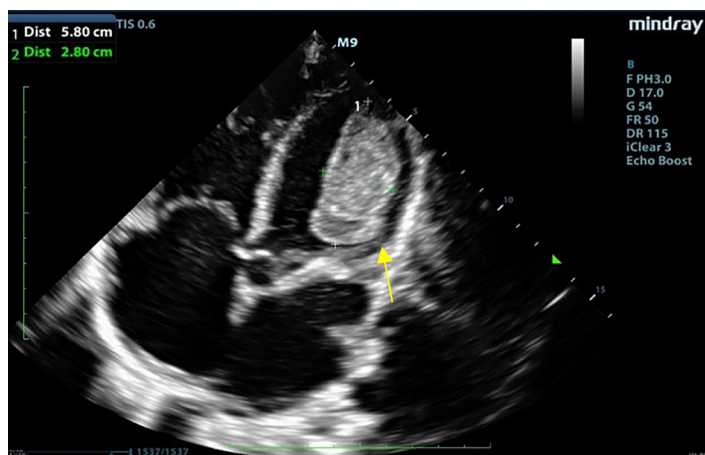


Image. Apical four-chamber view of the heart showing a thrombus in the left ventricle measuring 5.8 x 2.8 centimeters (arrow).

Video. A hyperechoic mobile structure within the left ventricle is seen using point-of-care ultrasound through the parasternal long axis, parasternal short axis, and apical four-chamber views of the heart.

Address for Correspondence: Shadi Lahham, MD, MS, University of California, Irvine, Department of Emergency Medicine, 333 City Blvd. West, Suite 640, Orange, CA 92868. Email: slahham@uci.edu.

Conflicts of Interest: By the CPC-EM article submission agreement, all authors are required to disclose all affiliations, funding sources and financial or management relationships that could be perceived as potential sources of bias. The authors disclosed none.

Copyright: © 2019 Khan et al. This is an open access article distributed in accordance with the terms of the Creative Commons Attribution (CC BY 4.0) License. See: <http://creativecommons.org/licenses/by/4.0/>

REFERENCES

1. Paulus M. Methamphetamine use disorder: Epidemiology, clinical manifestations, course, assessment, and diagnosis. Hermann R. UpToDate. Available at: <https://www.uptodate.com/contents/methamphetamine-use-disorder-epidemiology-clinical-manifestations-course-assessment-and-diagnosis>. Accessed July 30, 2018.
2. Kalaria VG, Passannante MR, Shah T. Effect of mitral regurgitation on left ventricular thrombus formation in dilated cardiomyopathy. *Am Heart J*. 1998;135(2 Pt 1):215-20.
3. Schürer S, Klingel K, Sandri M, et al. Clinical characteristics, histopathological features, and clinical outcome of methamphetamine-associated cardiomyopathy. *JACC Heart Fail*. 2017;5(6):435-45.
4. Ünüer EE, Payza U, Bayata S, et al. Left ventricular thrombus diagnosed by point-of-care ultrasonography. *J Emerg Trauma Shock*. 2016;9(1):42-3.
5. Colucci WS and Lip GYH. Antithrombotic therapy in patients with heart failure. Yeon SB. UpToDate. Available at: <https://www.uptodate.com/contents/antithrombotic-therapy-in-patients-with-heart-failure>. Accessed July 30, 2018.

CPC-EM Capsule

What do we already know about this clinical entity?

Left ventricular thrombus is a complication of cardiomyopathy and can present with shortness of breath and fatigue.

What is the major impact of the image(s)?

These images depict a left ventricular thrombus as seen on point-of-care ultrasound (POCUS).

How might this improve emergency medicine practice?

Emergency physicians can use POCUS to quickly identify a left ventricular thrombus.

Detection of Inferior Vena Cava Thrombosis Extending into the Right Atrium Using Point-of-care Ultrasound

Justin Yanuck, MD, MS
Ghadi Ghanem
Shadi Lahham, MD, MS

University of California, Irvine, Department of Emergency Medicine, Irvine, California

Section Editor: Scott Goldstein, DO

Submission history: Submitted September 23, 2018; Revision received November 23, 2018; Accepted January 1, 2019

Electronically published January 23, 2019

Full text available through open access at http://escholarship.org/uc/uciem_cpem

DOI: 10.5811/cpem.2019.1.41041

[Clin Pract Cases Emerg Med. 2019;3(1):67–68.]

CASE PRESENTATION

A 74-year-old male with a history of metastatic prostate cancer presented to the emergency department with hypotension and shortness of breath. We assessed volume status using point-of-care ultrasound (POCUS) with a phased array probe in the subxiphoid orientation. This revealed a large inferior vena cava (IVC) thrombus extending from above the IVC bifurcation into the right atrium (Image, Video). The patient was started on

intravenous heparin and fluids. Computed tomography (CT) pulmonary angiogram revealed an occlusive pulmonary embolism (PE) in the right lower lobe.

DISCUSSION

Venous thromboembolisms are estimated to occur in 0.1% of patients; 1.5% of patients hospitalized with deep vein thrombosis (DVT) were diagnosed with vena cava thrombosis, of whom 12% had a pulmonary embolism.^{1,2} The mortality rate for IVC thrombosis patients is nearly double that of DVT patients.^{1,3} These patients can present with lower limb swelling or pain, lower back pain, fever, or elevated inflammatory markers.³ CT or magnetic resonance imaging is often used to make the diagnosis.^{4,5}

Recently, ultrasound has shown promise for quick identification of IVC thrombus.⁶ The rapid ultrasound for shock and hypotension (RUSH) protocol, which incorporates assessment of IVC intravascular volume status, can be used for these undifferentiated patients to diagnose conditions not apparent with the standard physical exam.^{7,8} The RUSH examination led to the definitive diagnosis and etiology of this patient's hypotension and dyspnea.

Once diagnosed, confirmation using CT imaging and admission to the hospital for anticoagulation and hemodynamic monitoring is recommended.⁹ Invasive treatments include angioplasty or local thrombolysis.³

Our case highlights the use of POCUS to quickly identify etiologies of hypotensive and dyspneic patients. Further imaging should be obtained in IVC thrombosis patients to rule out PE or additional clots.

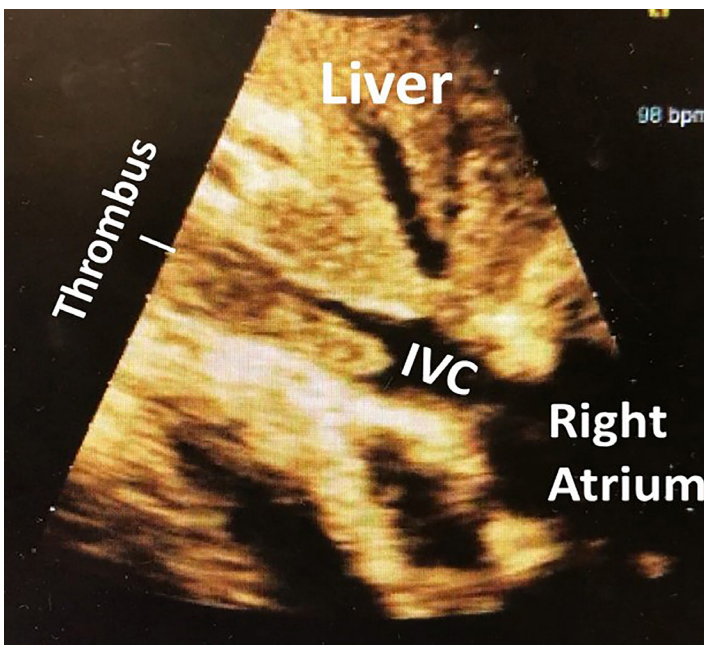


Image. Point-of-care ultrasound phased array probe in the subxiphoid orientation revealed a thrombus situated in the inferior vena cava (IVC).

Video. Rapid ultrasound for shock and hypotension protocol using the phased array probe in the subxiphoid orientation revealed a large thrombus situated in the inferior vena cava.

Documented patient informed consent and/or Institutional Review Board approval has been obtained and filed for publication of this case report.

Address for Correspondence: Justin Yanuck, MD, MS, University of California, Irvine, Department of Emergency Medicine, 333 City Blvd. West, Suite 640, Orange, CA 92868. Email: jyanuck@uci.edu.

Conflicts of Interest: By the CPC-EM article submission agreement, all authors are required to disclose all affiliations, funding sources and financial or management relationships that could be perceived as potential sources of bias. The authors disclosed none.

Copyright: © 2019 Yanuck et al. This is an open access article distributed in accordance with the terms of the Creative Commons Attribution (CC BY 4.0) License. See: <http://creativecommons.org/licenses/by/4.0/>

REFERENCES

1. White RH. The epidemiology of venous thromboembolism. *Circulation*. 2003;107(23 Suppl 1):I4-8.
2. Stein PD, Matta F, Yaekoub AY. Incidence of vena cava thrombosis in the United States. *Am J Cardiol*. 2008;102(7):927-9.
3. McAree B, O'Donnell M, Fitzmaurice G, et al. Inferior vena cava thrombosis: a review of current practice. *Vasc Med*. 2013;18(1):32-43.
4. Soler R, Rodríguez E, López MF, et al. MR imaging in inferior vena cava thrombosis. *Eur J Radiol*. 1995;19(2):101-7.
5. Giordano P, Weber K, Davis M, et al. Acute thrombosis of the inferior vena cava. *Am J Emerg Med*. 2006;24(5):640-2.
6. Lahham S, Tsai L, Wilson SP, et al. Thrombosis of inferior vena cava diagnosed using point-of-care ultrasound after pediatric near-syncope. *J Emerg Med*. 2016;51(4):e89-91
7. Jones AE, Tayal VS, Sullivan DM, et al. Randomized, controlled trial of immediate versus delayed goal-directed ultrasound to identify the cause of nontraumatic hypotension in emergency department patients. *Crit Care Med*. 2004;32(8):1703-8.
8. Perera P, Mailhot T, Riley D, et al. The RUSH exam: rapid ultrasound in shock in the evaluation of the critically ill. *Emerg Med Clin North Am*. 2010;28(1):29-56.
9. Kearon C, Akl EA, Comerota AJ, et al. Antithrombotic therapy for VTE disease: antithrombotic therapy and prevention of thrombosis, 9th ed: American College of Chest Physicians Evidence-Based Clinical Practice Guidelines. *Chest*. 2012;141(2):e419S-96S.

CPC-EM Capsule

What do we already know about this clinical entity?

Inferior vena cava thrombosis is a rare, life-threatening condition that usually requires advanced imaging techniques to diagnose.

What is the major impact of the image(s)?

This image highlights the utility of the rapid ultrasound for shock and hypotension protocol for finding both obvious and less-obvious pathologies.

How might this improve emergency medicine practice?

Rapid diagnosis of undifferentiated hypotensive patients using point-of-care ultrasound expedites care and medical intervention.

Young Male with Seizures

S. Manu Ayyan, MD
Binoy X. Kaliparrambil, MD
Suresh G. Nair, MS, DGO, MCh

Academy of Medical Sciences, Department of Emergency Medicine,
Pariyaram, Kerala, India

Section Editor: Rick A. McPheeters, DO

Submission history: Submitted September 4, 2018; Revision received September 21, 2018; Accepted October 4, 2018

Electronically published January 4, 2019

Full text available through open access at http://escholarship.org/uc/uciem_cpchem

DOI: 10.5811/cpchem.2018.10.40840

[Clin Pract Cases Emerg Med. 2019;3(1):69–70.]

CASE PRESENTATION

A 30-year-old Asian male presented with a history of generalized tonic-clonic seizures an hour before presenting to emergency department. He had a similar episode three years prior for which he had not sought any medical evaluation. He was conscious and oriented on presentation, and physical examination was unremarkable. Non-contrast computed tomography (CT) of the head revealed multiple cystic lesions on both cerebral hemispheres in different stages (Images 1-3).

DIAGNOSIS

Neurocysticercosis (NCC), is the most common parasitic disease of the central nervous system and is caused by the larval form (cysticercus) of the tapeworm *Taenia solium*. It is the most

common cause of acquired epilepsy worldwide. Seizures are the most common manifestation, present in 70-90% of symptomatic patients.¹ NCC has primarily been a disease that remains endemic in less economically developed countries; however, because of globalization, NCC is now being diagnosed more frequently in high-income countries.²

A set of diagnostic criteria for NCC has been proposed and revisited. These criteria are useful for maintaining uniformity, particularly for research.^{3,4} Absolute criteria include direct visualization of parasite, histological demonstration of parasite or evidence of cystic lesion with scolex on CT or magnetic resonance imaging. The disease can be parenchymal, occurring in the brain substance, or extraparenchymal, occurring in the ventricles, basilar cisterns, or subarachnoid space of the brain or

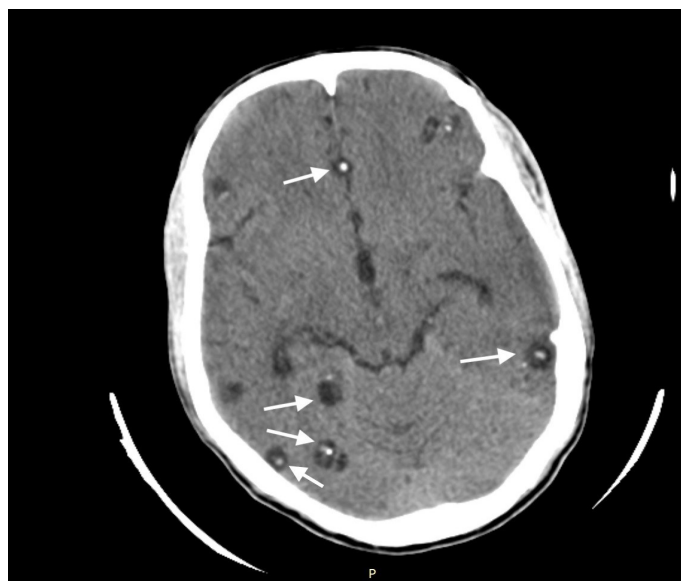


Image 1. Computed tomography of the brain showing multiple cystic lesions and cyst with dot sign in patient with neurocysticercosis (arrows).

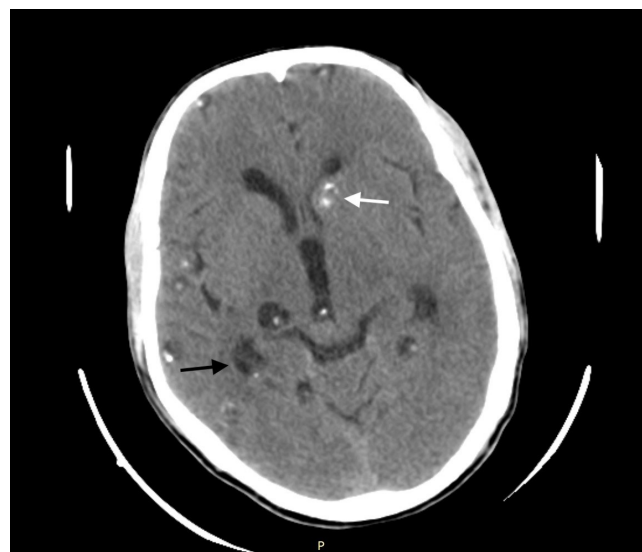


Image 2. Computed tomography of the brain showing multiple cystic lesions in different stages: vesicular (black arrow) and nodular calcific stage with lesion in left cerebral hemisphere near basal ganglion showing calcification (white arrow).

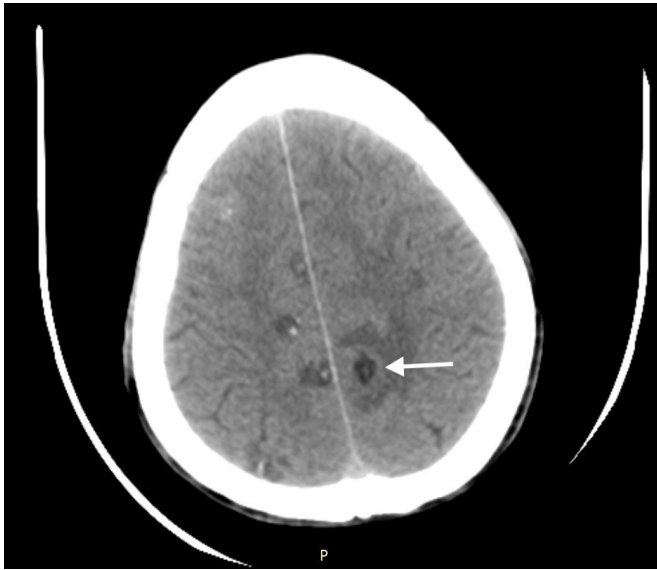


Image 3. Computed tomography of the brain showing multiple cystic lesions in vesicular and colloid-vesicular stage with lesion in left cerebral hemisphere demonstrating surrounding edema (arrow).

in the spinal cord. The scolex is visualized as a bright, extramural nodule within the cyst (hole with dot appearance). Parenchymal NCC has four stages: vesicular; colloidal vesicular; granular nodular; and nodular calcified. When multiple cysts in different stages of evolution are visible it gives rise to the “starry-sky” appearance, which is typical of NCC.

Emergency therapeutic interventions are aimed at managing the neurological complications, which include anticonvulsant therapy, corticosteroids, neurosurgical intervention and/or treatment of increased intracranial pressure. Cysticidal therapy is indicated with antihelminthics (albendazole or praziquantel), but

must be administered with caution because larval death provokes an inflammatory response that may increase symptoms. Concomitant steroids are usually indicated. Treatment with cysticidal therapy leads to reduction in seizure frequency and a faster resolution of lesions.

Documented patient informed consent and/or Institutional Review Board approval has been obtained and filed for publication of this case report.

Address for Correspondence: S. Manu Ayyan, MD, Academy of Medical Sciences, Department of Emergency Medicine, NH 66 Pariyaram MC Campus Road, Pariyaram, Kannur, Kerala 670503, India. Email: manuayyan@hotmail.com.

Conflicts of Interest: By the CPC-EM article submission agreement, all authors are required to disclose all affiliations, funding sources and financial or management relationships that could be perceived as potential sources of bias. The authors disclosed none.

Copyright: © 2019 Ayyan et al. This is an open access article distributed in accordance with the terms of the Creative Commons Attribution (CC BY 4.0) License. See: <http://creativecommons.org/licenses/by/4.0/>

REFERENCES

1. Carabin H, Ndimubanzi PC, Budke CM, et al. Clinical manifestations associated with neurocysticercosis: A systematic review. *PLoS Negl Trop Dis.* 2011;5(5):e1152.
2. Cantey PT, Coyle CM, Sorvillo FJ, et al. Neglected parasitic infections in the United States: cysticercosis. *Am J Trop Med Hyg.* 2014;90(5):805-9.
3. Del Brutto OH, Wadia NH, Dumas M, et al. Proposal of diagnostic criteria for human cysticercosis and neurocysticercosis. *J Neurol Sci.* 1996;142(1-2):1-6.
4. Del Brutto OH, Rajshekhar V, White AC Jr, et al. Proposed diagnostic criteria for neurocysticercosis. *Neurology.* 2001;57(2):177-83.

Multiple Carpometacarpal Dislocations

Alexander Davies, MD
Kevin Smith, BA
Wesley Eilbert, MD

University of Illinois College of Medicine, Department of Emergency Medicine, Chicago, Illinois

Section Editor: Rick A. McPheeters, DO

Submission history: Submitted October 8, 2018; Revision received October 9, 2018; Accepted November 19, 2018

Electronically published January 4, 2019

Full text available through open access at http://escholarship.org/uc/uciem_cpцем

DOI: 10.5811/cpцем.2018.11.41185

[Clin Pract Cases Emerg Med. 2019;3(1):71–72.]

CASE PRESENTATION

A 30-year-old man presented to the emergency department (ED) complaining of right-hand pain after punching a wall in anger approximately one hour prior to arrival. On examination, there was obvious deformity of the dorsal aspect of the hand with a palpable bony step-off extending across the distal aspect of the wrist. Neurovascular examination of the hand and digits was normal. We obtained standard posterior-anterior (Image 1) and lateral (Image 2) radiographs of the wrist.

DIAGNOSIS

Carpometacarpal (CMC) dislocations not involving the thumb are rare, accounting for <1% of all hand trauma.¹ These are typically high-energy injuries occurring in the dominant hand of young men, often as a result of an axial load applied to the metacarpals as occurs with punching.² The diagnosis is frequently missed on initial examination since swelling may obscure the characteristic deformity of the hand dorsum, and routine radiographs may not show the bony displacement clearly.² Left untreated, CMC dislocations frequently result in pain and reduced grip strength.³ Most CMC dislocations are dorsal and frequently occur with fractures of the metacarpal base or carpal bones.⁴ Simultaneous dislocation of multiple CMC joints occurs more often than solitary dislocations.⁴

On radiographs, the usual 1-2 millimeter CMC joint space seen on the posterior-anterior view is obliterated by bony overlap, and displacement of the proximal ends of the metacarpals is seen on the lateral view. Closed reduction by applying longitudinal traction to the involved digits with direct pressure over the bases of the dislocated metacarpals should be performed in the ED since delayed reduction is less likely to be successful.^{5,6} Operative intervention is indicated if closed reduction is unsuccessful.⁵ This patient had successful closed reduction in the ED using procedural sedation and was discharged with a sugar-tong splint for immobilization.

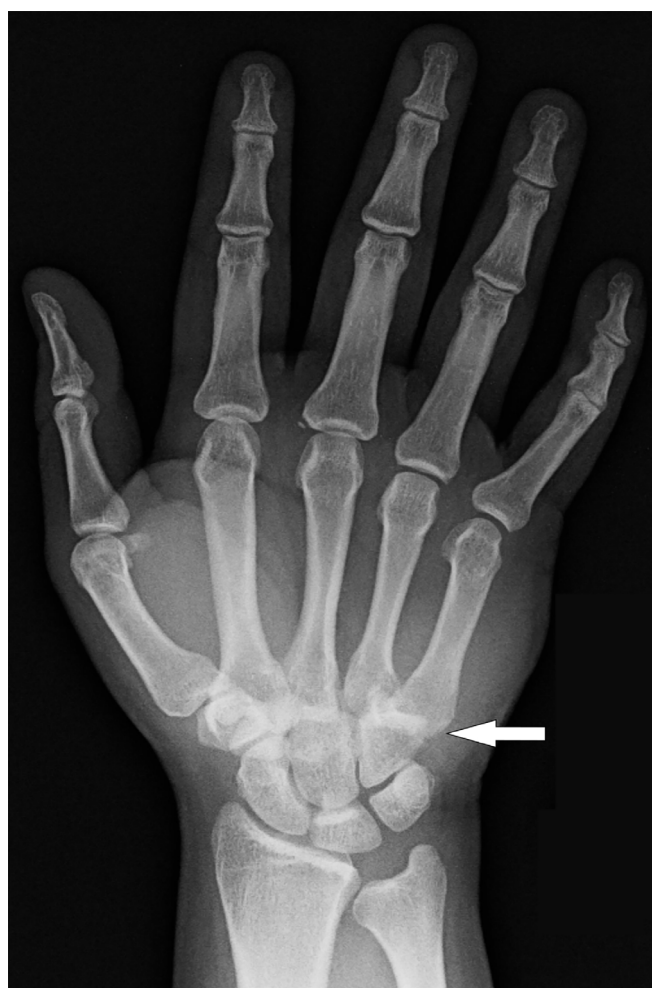

Image 1. Posterior-anterior view of the right hand showing an obscuring of the second through fifth carpometacarpal joints due to bony overlap (arrow).

Documented patient informed consent and/or Institutional Review Board approval has been obtained and filed for publication of this case report.

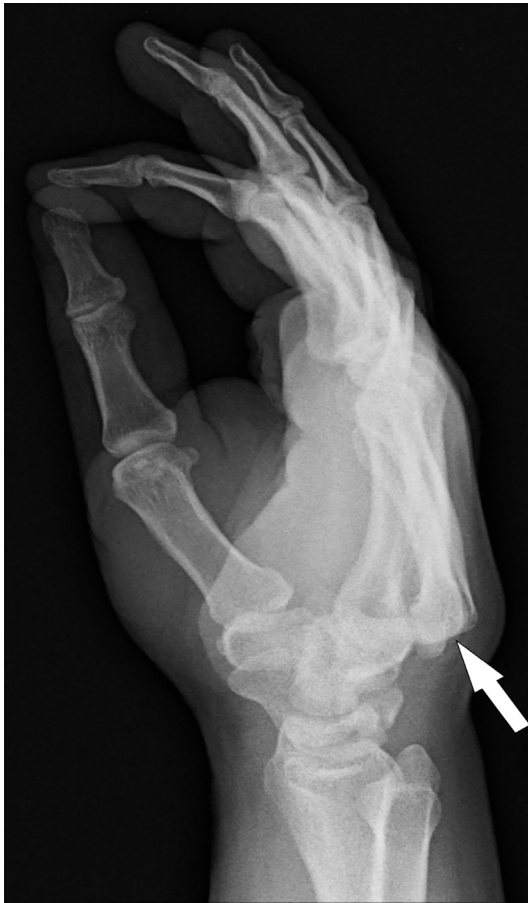

Image 2. Lateral view of the left wrist showing dorsal displacement of the proximal ends of the second through fifth metacarpals (arrow).

Address for Correspondence: Wesley Eilbert, MD, University of Illinois College of Medicine, Department of Emergency Medicine, 1819 West Polk St., Room 469, Chicago, IL 60612. Email: weilbert@uic.edu.

Conflicts of Interest: By the CPC-EM article submission agreement, all authors are required to disclose all affiliations, funding sources and financial or management relationships that could be perceived as potential sources of bias. The authors disclosed none.

Copyright: © 2019 Eilbert et al. This is an open access article distributed in accordance with the terms of the Creative Commons Attribution (CC BY 4.0) License. See: <http://creativecommons.org/licenses/by/4.0/>

CPC-EM Capsule

What do we already know about this clinical entity?

Carpometacarpal dislocations not involving the thumb are rare. The diagnosis is frequently missed on initial examination, resulting in significant morbidity.

What is the major impact of the image(s)?

It identifies the characteristic obscurement of the carpometacarpal joints on the posterior-anterior view and displacement of the proximal ends of the metacarpals on the lateral view radiographs.

How might this improve emergency medicine practice?

Identification of this rare, though commonly missed, injury in the emergency department will prevent long-term hand morbidity.

REFERENCES

1. Storken G, Bogie R, Jansen EJ. Acute ulnar carpometacarpal dislocations. Can it be treated conservatively? A review of four cases. *Hand (NY)*. 2011;6(4):420-3.
2. Henderson JJ and Arafa MA. Carpometacarpal dislocation. An easily missed diagnosis. *J Bone Joint Surg Br*. 1987;69(2):212-4.
3. Imbriglia JE. Chronic dorsal carpometacarpal dislocation of the index, middle, ring and little fingers: a case report. *J Hand Surg*. 1979;4(4):343-5.
4. Fisher MR, Rogers LF, Hendrix RW. Systematic approach to identifying fourth and fifth carpometacarpal joint dislocations. *AJR Am J Roentgenol*. 1983;140(2):319-24.
5. Enejat M, de Boer L, Smit JM. A dislocation of the carpal-metacarpal joints of the index, middle and ring finger. *Am J Emerg Med*. 2009;27(2):e1-2.
6. Kumar A and Olney DB. Multiple carpometacarpal dislocations. *J Accid Emerg Med*. 1994;11(4):257-8.

Dyspnea in a Patient with Melanoma

Laura J. Bontempo, MD, MEd*
Nubia Seyoum, MD†

*University of Maryland School of Medicine, Department of Emergency Medicine,
Baltimore, Maryland

†University of Maryland Medical Center, Department of Emergency Medicine,
Baltimore, Maryland

Section Editor: Rick A. McPheeters, DO

Submission history: Submitted September 27, 2018; Revision received November 16, 2018; Accepted November 26, 2018

Electronically published January 7, 2019

Full text available through open access at http://escholarship.org/uc/uciem_cpccem

DOI: 10.5811/cpcem.2018.11.41064

[Clin Pract Cases Emerg Med. 2019;3(1):73–74.]

CASE PRESENTATION

A 50-year-old woman with widely metastatic melanoma presented to the emergency department with dyspnea. She was found to be tachypneic, hypoxic, tachycardic, and hypotensive. A non-rebreather oxygen mask was placed and her oxygen saturation improved mildly. We obtained a semi-erect chest radiograph (CXR) followed by chest computed tomography angiography (CTA) (Images 1-3), due to concerns for a pulmonary embolism. The CXR revealed a depressed left hemidiaphragm and a left pleural effusion. The CTA revealed a massive left pleural effusion causing left lung atelectasis, rightward mediastinal shift, and depression of the left hemidiaphragm.

DISCUSSION

The diagnosis was a tension hydrothorax due to a massive, malignant pleural effusion causing hemodynamic compromise. The hemodynamic effects of a tension hydrothorax are analogous to those of a tension pneumothorax. Elevated intrathoracic pressure caused by the effusion impairs venous return and compresses the left ventricle, causing reduced stroke volume and subsequent hypotension.¹⁻³ Although pleural effusions are common, occurring in more than half of all cancer patients, a tension hydrothorax due to a massive pleural effusion is a rare event.^{4,5} It has been reported in cancer patients and as an iatrogenic complication of surgery.^{1,4-6}

A CXR will show a large pleural effusion.^{2-6,8} However, as

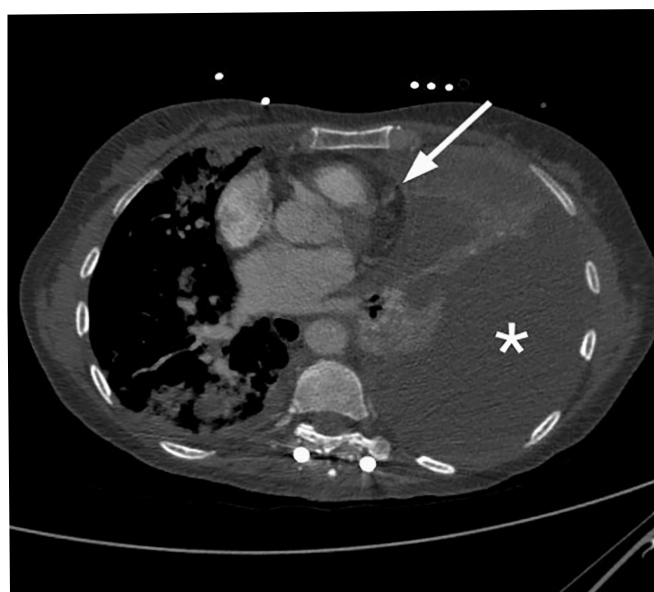

Image 1. Thoracic computed tomography angiography axial view with large left pleural effusion (*) and rightward displacement of the heart (white arrow).

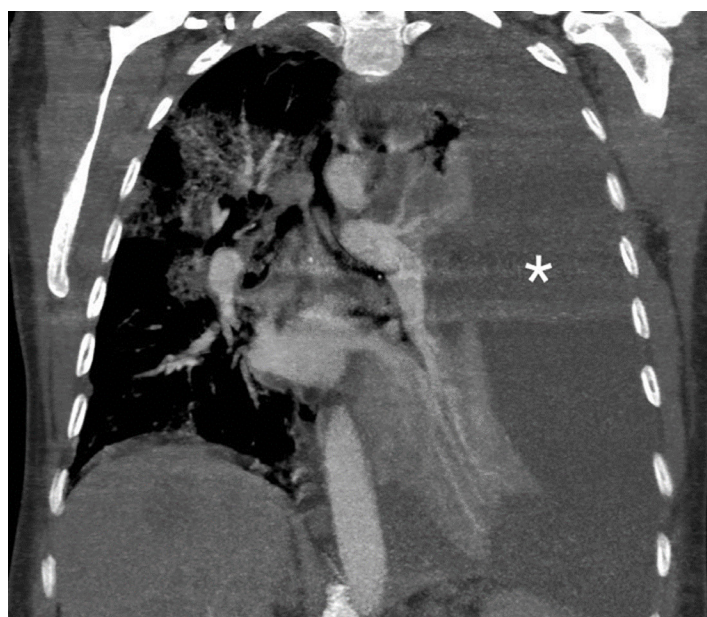


Image 2. Thoracic computed tomography angiography coronal view with complete left hemithorax pleural effusion (*).

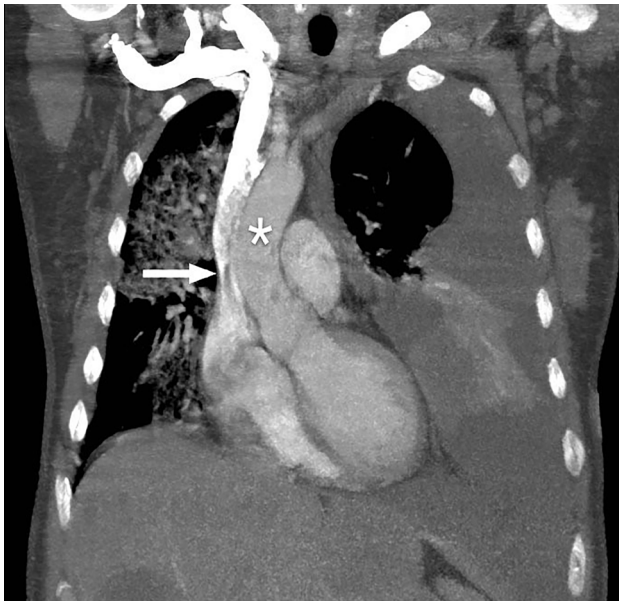

Image 3. Thoracic computed tomography angiography coronal view with rightward mediastinal shift (*) and compression of superior vena cava (white arrow).

in our patient and in a previous case report,⁶ the CXR might indicate no, or only subtle, findings of intrathoracic tension. Tension findings are revealed by CTA. Emergent intervention is necessary to reduce intrathoracic pressure and allow venous return.^{4,6,8} In the management of our patient, we performed a left thoracentesis following intubation, allowing drainage of more than one liter of serosanguineous fluid. Her hemodynamics immediately improved. The patient eventually required thoracostomy tube placement for persistent hypoxia and risk of recurrent tension physiology.

The emergency physician must be aware of this entity when a hemodynamically-compromised patient arrives with a pleural effusion, even if mediastinal shift is not evident on the CXR.

Address for Correspondence: Laura J. Bontempo, MD, MEd, University of Maryland School of Medicine, Department of Emergency Medicine, 110 S. Paca Street, 6th Floor, Suite 200, Baltimore, MD 21201. Email: lbontempo@som.umaryland.edu.

Conflicts of Interest: By the CPC-EM article submission agreement, all authors are required to disclose all affiliations, funding sources and financial or management relationships that could be perceived as potential sources of bias. The authors disclosed none.

Copyright: © 2019 Bontempo et al. This is an open access article distributed in accordance with the terms of the Creative Commons Attribution (CC BY 4.0) License. See: <http://creativecommons.org/licenses/by/4.0/>

CPC-EM Capsule

What do we already know about this clinical entity?

A tension hydrothorax due to a massive pleural effusion is a rare event that can cause hemodynamic instability due to compromised thoracic venous return.

What is the major impact of the image(s)?

The images demonstrate how increased intrathoracic pressure can cause mediastinal shift and vena cava compression.

How might this improve emergency medicine practice?

In a hemodynamically compromised patient with a large pleural effusion, emergent thoracentesis should be considered due to possible tension physiology.

Documented patient informed consent and/or Institutional Review Board approval has been obtained and filed for publication of this case report.

REFERENCES

1. Gouze VA and Breslow MJ. Hydrothorax as a complication of percutaneous access to the renal pelvis. *Anesth Analg.* 1996;83(3):652–3.
2. Chattranukulchai P, Sattitthummanid S, Puwanant S, et al. A rare cause of pulsus paradoxus: acute tension hydrothorax. *BMJ Case Rep.* 2013;2013.
3. Deal A, Evans D, Counselman FL. Tension hydrothorax from disseminated endometriosis. *West J Emerg Med.* 2016;17(1):88–90.
4. Negus RA, Chachkes JS, Wrenn K. Tension hydrothorax and shock in a patient with a malignant pleural effusion. *Am J Emerg Med.* 1990;(3)8:205–7.
5. Dixit R, Agarwal KC, Gokhroo A, et al. Diagnosis and management options in malignant pleural effusions. *Lung India.* 2017;34(2):160–6.
6. Dagrosa RL, Martin JF, Bebartá VS. Tension hydrothorax. *J Emerg Med.* 2009;36(1):78–9.
7. Surani SR, Mendez Y, Anjum H, et al. Pulmonary complications of hepatic diseases. *World J Gastroenterol.* 2016;22(26):6008–15.
8. Azim A, Sahoo JN, Baronia AK, et al. Severe dengue with massive pleural effusion requiring urgent intercostal chest tube drainage: a case report. *Am J Emerg Med.* 2012;30(2):389.e1–2.

A Benign Case of Hepatic Gas

Lawrence K. Hou, MS*
Sheryl L.C. Diaz, MS*
Deborah L. Kimball, MD†

*Touro College of Osteopathic Medicine, Middletown, New York
†Stanford University School of Medicine, Department of Emergency Medicine,
Palo Alto, California

Section Editor: Shadi Lahham, MD, MS

Submission history: Submitted August 30, 2018; Revision received November 13, 2018; Accepted November 26, 2018

Electronically published January 7, 2019

Full text available through open access at http://escholarship.org/uc/uciem_cpccem

DOI: 10.5811/cpcem.2018.11.40815

[Clin Pract Cases Emerg Med. 2019;3(1):75–76.]

CASE PRESENTATION

A 33-year-old obese male with a history of well-controlled type II diabetes and hyperlipidemia presented to the emergency department with a one-day history of recurrent non-bloody diarrhea and abdominal pain in the morning progressing to significant nausea, increased non-radiating abdominal pain, and multiple episodes of non-bilious, non-bloody emesis in the evening. The patient reported 8/10 non-radiating, sharp, epigastric abdominal pain upon arrival. Physical examination findings revealed tenderness and rigidity in the right lower quadrant. The patient had an initial white blood cell count of 22.9 cells/millimeter³ (mm³) anion gap of 16 milliequivalents per liter (L), glucose level of 203 millimoles per liter (mmol/L), and a lactate of 3.01 mmol/L. A computed tomography (CT) of abdomen and pelvis with intravenous contrast showed a mild wall thickening of the terminal ileum with multiple reactive mesenteric lymph nodes in the right lower quadrant indicative of inflammation, and a small volume of hepatic gas in the left hepatic lobe (Image). Point-of-care ultrasound of the abdomen confirmed the presence of hepatic gas in the left hepatic lobe (Video). The patient received two L of normal saline and was reevaluated showing significant pain relief. Ciprofloxacin, metronidazole, and vancomycin were given to treat an infectious etiology causing terminal ileum inflammation and diarrhea. The patient was admitted with gastroenteritis and subsequently discharged.

DISCUSSION

Hepatic portal venous gas is commonly associated with mesenteric ischemia with a mortality rate of 75%.^{1,2} Mirmanesh et al. described a similar presentation and management in an older patient with type II diabetes mellitus diagnosed with viral gastroenteritis.³ Modern advancements in high-resolution CT and ultrasound are leading to increased recognition of benign cases of hepatic portal venous gas.⁴ This information should

prompt emergency physicians to be more aware of benign etiologies that can cause hepatic gas.

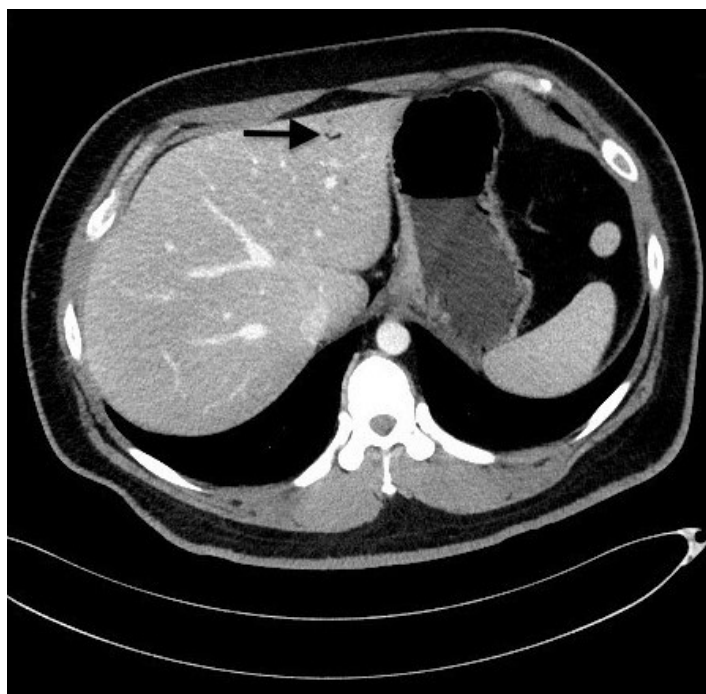


Image. Computed tomography with contrast of abdomen shows hepatic portal venous gas in the anterior portion of the left hepatic lobe (arrow).

Video. Ultrasound clip showing hyperechoic regions indicative of hepatic portal venous gas (arrows).

Documented patient informed consent and/or Institutional Review Board approval has been obtained and filed for publication of this case report.

Address for Correspondence: Deborah L. Kimball, MD, Stanford University, Department of Emergency Medicine, 900 Welch Road Suite 350, Palo Alto, CA 94305. Email: drdeb@stanford.edu.

Conflicts of Interest: By the *CPC-EM* article submission agreement, all authors are required to disclose all affiliations, funding sources and financial or management relationships that could be perceived as potential sources of bias. The authors disclosed none.

Copyright: © 2019 Hou et al. This is an open access article distributed in accordance with the terms of the Creative Commons Attribution (CC BY 4.0) License. See: <http://creativecommons.org/licenses/by/4.0/>

REFERENCES

1. Liebman PR, Patten MT, Manny J, et al. Hepatic-portal venous gas in adults: etiology, pathophysiology and clinical significance. *Ann Surg.* 1978;187(3):281-7.
2. Kinoshita H, Shinozaki M, Tanimura H, et al. Clinical features and management of hepatic portal venous gas: four case reports and cumulative review of the literature. *Arch Surg.* 2001;136(12):1410-4.
3. Mirmanesh M, Nguyen QS, Markelov A. A case of hepatic portal venous gas due to viral gastroenteritis. *Hepat Med.* 2013;5:63-5.
4. Shah PA, Cunningham SC, Morgan TA, et al. Hepatic gas: widening spectrum of causes detected at CT and US in the interventional era. *Radiographics.* 2011;31(5):1403-13.

CPC-EM Capsule

What do we already know about this clinical entity?
The presence of hepatic gas is a serious clinical finding associated with diseases of a high mortality rate. Benign causes of hepatic gas remain rare in literature.

What is the major impact of the image(s)?
Hepatic gas associated with a benign diagnosis of gastroenteritis was found using point-of-care ultrasound and computed tomography in the emergency department setting.

How might this improve emergency medicine practice?
Emergency physicians may now be more aware of benign etiologies causing hepatic gas, using routinely practiced emergency medicine imaging modalities.

Superficial Temporal Artery Pseudoaneurysm Diagnosed by Point-of-Care Ultrasound

Samuel L. Burluson, MD
Francesca N. Cirillo, MD
Courtney B. Gibson, MD
John P. Gullett, MD
David C. Pigott, MD

University of Alabama, Department of Emergency Medicine, Birmingham, Alabama

Section Editor: Rick A. McPheeters, DO

Submission history: Submitted September 15, 2018; Revision received November 20, 2018; Accepted November 26, 2018

Electronically published January 7, 2019

Full text available through open access at http://escholarship.org/uc/uciem_cpem

DOI: 10.5811/cpcem.2018.11.40958

[Clin Pract Cases Emerg Med. 2019;3(1):77–78.]

CASE PRESENTATION

A 55-year-old female presented to the emergency department with an enlarging forehead mass after a fall with head injury two weeks prior. She reported focal, tender swelling to her right forehead and headache. Physical examination revealed a two-centimeter, soft, pulsatile mass to her right frontotemporal region (Image 1). Point-of-care ultrasound (POCUS) with color Doppler revealed a dilated vascular structure with pulsatile, bidirectional flow – the “yin-yang” sign (Image 2). The diagnosis of traumatic superficial temporal artery (STA) pseudoaneurysm was confirmed by computed tomography (CT) angiography with three-dimensional reconstruction (Image 3). The patient’s pseudoaneurysm was surgically ligated and she recovered uneventfully.

DISCUSSION

Traumatic pseudoaneurysm of the STA is a rare complication of minor head trauma, usually presenting as a painless pulsatile mass following blunt trauma.¹ Pseudoaneurysms are contained only by the external adventitial layer of the vessel wall, and are more likely to rupture than true aneurysms.² Complications may include persistent headache, continued enlargement, dizziness, vision changes and, rarely, life-threatening hemorrhage.³ Diagnosis is typically made by history and physical examination, and confirmed by Doppler ultrasonography² or CT angiography, although diagnosis by POCUS has been reported.^{2,4,5}

POCUS can differentiate common causes of focal, superficial swelling such as skin and soft tissue infection from underlying vascular pathology, preventing potentially disastrous attempts at

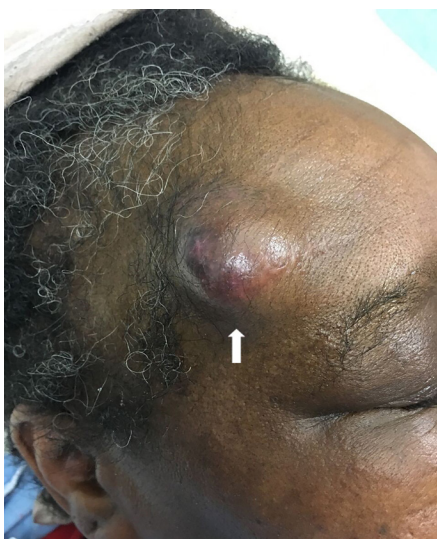

Image 1. Photograph of right superficial temporal arterial pseudoaneurysm (arrow).

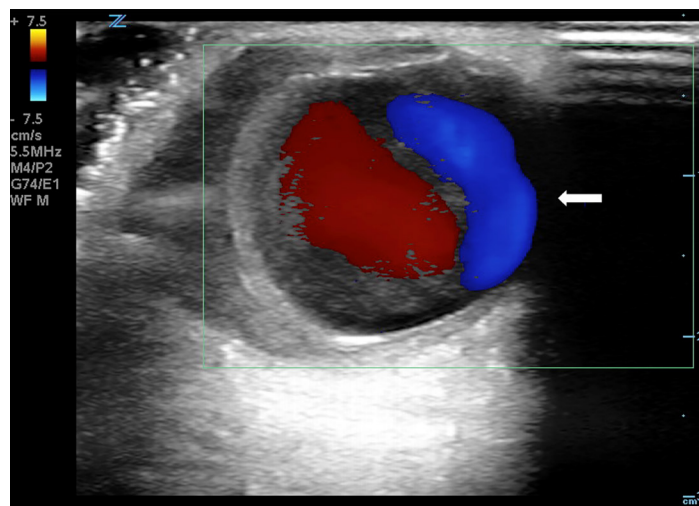


Image 2. Point-of-care Doppler ultrasound demonstrating the classic “yin-yang” sign (arrow), indicating bidirectional blood flow within the pseudoaneurysm.

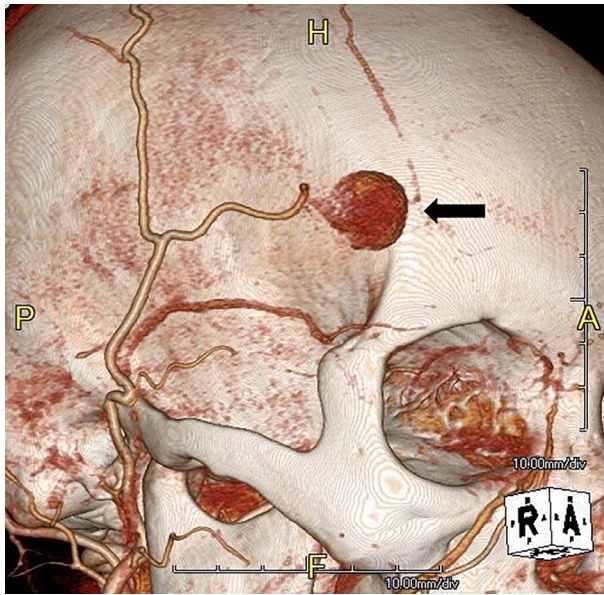


Image 3. Three-dimensional computed tomography angiogram demonstrating a large superficial temporal arterial pseudoaneurysm (arrow).

bedside drainage and expediting referral for definitive therapy.^{5,6} Color Doppler indicates blood flow velocity and direction relative to the probe, although high velocities may show an apparent reversal of color flow due to aliasing. The red-blue, “yin-yang” pattern seen here is due to the continuously changing angle of insonation caused by swirling blood flow.

In summary, we report a case in which POCUS provided a rapid, accurate diagnosis of an uncommon complication following minor head trauma requiring surgical intervention. An “ultrasound-first” approach to focal swelling, particularly with recent head trauma, can expedite appropriate care and avoid unnecessary or potentially harmful interventions.

Address for Correspondence: Samuel L. Burleson, MD, University of Alabama, Department of Emergency Medicine, 619 19th St S, Old Hillman Building Suite 251, Birmingham, AL 35249. Email: slburleson@uabmc.edu.

Conflicts of Interest: By the CPC-EM article submission agreement, all authors are required to disclose all affiliations, funding sources and financial or management relationships that could be perceived as potential sources of bias. The authors disclosed none.

Copyright: © 2019 Burleson et al. This is an open access article distributed in accordance with the terms of the Creative Commons Attribution (CC BY 4.0) License. See: <http://creativecommons.org/licenses/by/4.0/>

CPC-EM Capsule

What do we already know about this clinical entity?
Superficial temporal artery (STA) pseudoaneurysm is a rare complication of minor head trauma. Diagnosis is typically made via color Doppler ultrasound or computed tomography angiography.

What is the major impact of the images?
Point-of-care ultrasound (POCUS) with color Doppler assists in the diagnosis of STA pseudoaneurysm, as well as in undifferentiated soft tissue swelling.

How might this improve emergency medicine practice?
POCUS can expedite diagnosis and definitive therapy of STA pseudoaneurysm and help avoid harmful bedside interventions.

Documented patient informed consent and/or Institutional Review Board approval has been obtained and filed for publication of this case report.

REFERENCES

1. Stapleton CJ, Fusco MR, Thomas AJ, et al. Traumatic pseudoaneurysms of the superficial temporal artery: case series, anatomy, and multidisciplinary treatment considerations. *J Clin Neurosci*. 2014;21(9):1529-32.
2. Nelson M, Szustkiewicz K, Stankard B. Diagnosis of traumatic temporal artery pseudoaneurysm by ultrasound in the emergency department. *J Emerg Med*. 2016;51(5):572-5.
3. Park IH, Kim HSK, Park SK, et al. Traumatic pseudoaneurysm of the superficial temporal artery diagnosed by 3-dimensional CT angiography. *J Korean Neurosurg Soc*. 2008;43(4):209-11.
4. Goksu E, Senay E, Alimoglu E, et al. Superficial temporal artery pseudoaneurysm: ultrasonographic diagnosis in the ED. *Am J Emerg Med*. 2009;27(5):627.e1-3.
5. Blaivas M, and Adhikari S. Unexpected findings on point-of-care superficial ultrasound imaging before incision and drainage. *J Ultrasound Med*. 2011;30(10):1425-30.
6. Rood LK. Superficial temporal artery pseudoaneurysm presenting as a suspected sebaceous cyst. *J Emerg Med*. 2016;51(6):e149-50.

Pemphigoid Gestationis

Rene M. Kukkamalla, MD*
Patricia Bayless, MD*†

* Maricopa Medical Center, Department of Emergency Medicine, Phoenix, Arizona
† University of Arizona College of Medicine-Phoenix, Department of Emergency Medicine, Phoenix, Arizona

Section Editor: Scott Goldstein, DO

Submission history: Submitted June 7, 2018; Revision received October 28, 2018; Accepted November 7, 2018

Electronically published January 7, 2019

Full text available through open access at http://escholarship.org/uc/uciem_cpem

DOI: 10.5811/cpcem.2018.11.39258

[Clin Pract Cases Emerg Med. 2019;3(1):79-80.]

CASE PRESENTATION

A 32-year-old female gravida 3 para 2 presented to the emergency department (ED) with two weeks of hyperpigmented macular and blistering rash involving bilateral upper and lower extremities (Image 1) and trunk (Image 2). The patient was

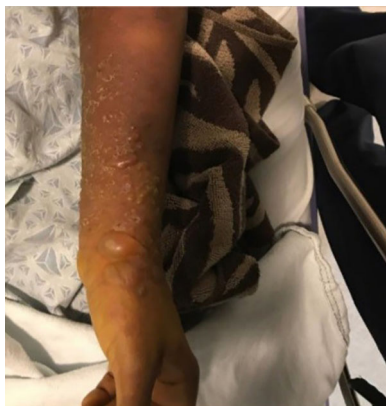

Image 1. Upper extremity with vesiculobullous lesions in a patient with pemphigoid gestationis.

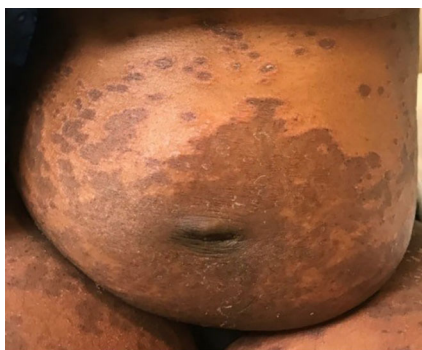


Image 2. Abdomen with macular lesions in a patient with pemphigoid gestationis.

approximately 16 weeks pregnant at time of presentation. The rash was significantly pruritic. She denied constitutional symptoms or mucous membrane involvement. The patient was seen by obstetrics/gynecology consult who deemed her rash consistent with pemphigoid gestationis (PG). She was started on high-dose steroid therapy with improvement in the rash. ELISA (an enzyme-linked immunosorbent assay that measures autoantibody reactions to the bullous pemphigoid antigen [BP180] with 96% sensitivity and specificity for PG) showed our patient's values elevated at 30.59 units (reference range less than 9.0 units).¹ By the 35th week of pregnancy, her rash had resolved while on a stringent steroid regimen. She developed gestational diabetes that is being managed by her prenatal care provider.

DISCUSSION

PG is considered a rare disease with estimated incidence approximately 1 in 50,000 pregnancies.² The disease shows a worldwide distribution and no differences in ethnicity. General population studies on the epidemiology of PG are small.⁴ The rash is characterized by pruritic papular and vesiculobullous eruptions that typically involve the abdomen and extremities. The face is classically spared.² It is thought to be an autoimmune phenomenon caused by immunoglobulin G antibody to a 180-kilodalton antigen in the basement membrane.¹ Onset of the rash is typically in the second or third trimester and can occur immediately post-partum.³

It is important to distinguish this disease from other pregnancy-associated dermatoses because of the high rate of recurrence with more severe symptoms in later pregnancies.^{1,4} Typically fetuses are unaffected; however, in less than 5% of cases they can contract transient skin lesions. While fetal outcome is generally good, there is increased risk for intrauterine growth restriction as well as preterm labor.^{2,4} Diagnosis is made either clinically, by skin biopsy with direct immunofluorescence (showing linear deposits of complement along the basement membrane), or elevated BP180 antibody levels. Treatment includes topical steroids. For more severe cases systemic steroids are appropriate.^{3,4}

Documented patient informed consent and/or Institutional Review Board approval has been obtained and filed for publication of this case report.

Address for Correspondence: Rene M. Kukkamalla, MD, Maricopa Medical Center, Department of Emergency Medicine, 2601 East Roosevelt Street, Phoenix, AZ 85008. Email: meghanakukks@gmail.com.

Conflicts of Interest: By the CPC-EM article submission agreement, all authors are required to disclose all affiliations, funding sources and financial or management relationships that could be perceived as potential sources of bias. The authors disclosed none.

Copyright: © 2019 Kukkamalla et al. This is an open access article distributed in accordance with the terms of the Creative Commons Attribution (CC BY 4.0) License. See: <http://creativecommons.org/licenses/by/4.0/>

CPC-EM Capsule

What do we already know about this clinical entity?

Pemphigoid gestationis (PG) is well described but rarely encountered.

What is the major impact of the image(s)?

The images demonstrate a true "pemphigoid" rash.

How might this improve emergency medicine practice?

Recognition of PG impacts referral and management of the current and future pregnancies.

REFERENCES

1. Powell AM, Sakuma-Oyama Y, Oyama N, et al. Usefulness of BP180 NC16a enzyme-linked immunosorbent assay in the serodiagnosis of pemphigoid gestationis and in differentiating between pemphigoid gestationis and pruritic urticarial papules and plaques of pregnancy. *Arch Dermatol.* 2005;141(6):705-10.
2. Dulay AT. "Pemphigoid Gestationis." In: *Merck Manual Professional Version.* Available at: <https://www.merckmanuals.com/professional/gynecology-and-obstetrics/abnormalities-of-pregnancy/pemphigoid-gestationis>. 2017. Accessed May 25, 2018.
3. Flangini Cobo M, Giuli Santi C, Wakisaka Maruta C, et al. Pemphigoid gestationis: clinical and laboratory evaluation. *Clinics (Sao Paulo).* 2009;64(11):1043-7.
4. Saverall C, Sand FL, Thomsen SF. Pemphigoid gestationis: current perspectives. *Clin Cosmet Investig Dermatol.* 2017;10:441-9.

Point-of-care Ultrasound Diagnosis of Slipped Capital Femoral Epiphysis

Imran Asad, MD
Michelle Sin Lee, MDCM

University of Toronto, Hospital for Sick Children, Division of Pediatric Emergency Medicine, Department of Pediatrics, Toronto, Canada

Section Editor: Rick A. McPheeters, DO

Submission history: Submitted October 21, 2018; Revision received November 28, 2018; Accepted January 1, 2019

Electronically published January 22, 2019

Full text available through open access at http://escholarship.org/uc/uciem_cpem

DOI: 10.5811/cpcem.2019.1.41357

[Clin Pract Cases Emerg Med. 2019;3(1):81–82.]

CASE PRESENTATION

An 11-year-old female was brought to the emergency department with left hip and knee pain as well as limping for three weeks. There was no fever or recent trauma. Physical examination revealed restricted range of movement due to pain on hip flexion, internal and external rotation. A point-of-care ultrasound (POCUS) performed by an emergency physician (Image 1) raised the suspicion for her diagnosis when compared with right side (Image

2), which prompted expedited immobilization and pain control. POCUS was performed using a linear, high-frequency probe (14-5 MegaHertz) aligned parallel to the femoral neck. Subsequently, her pelvic radiograph (Image 3) confirmed the diagnosis.

DISCUSSION

Slipped capital femoral epiphysis (SCFE) is an important hip disorder of adolescence commonly occurring

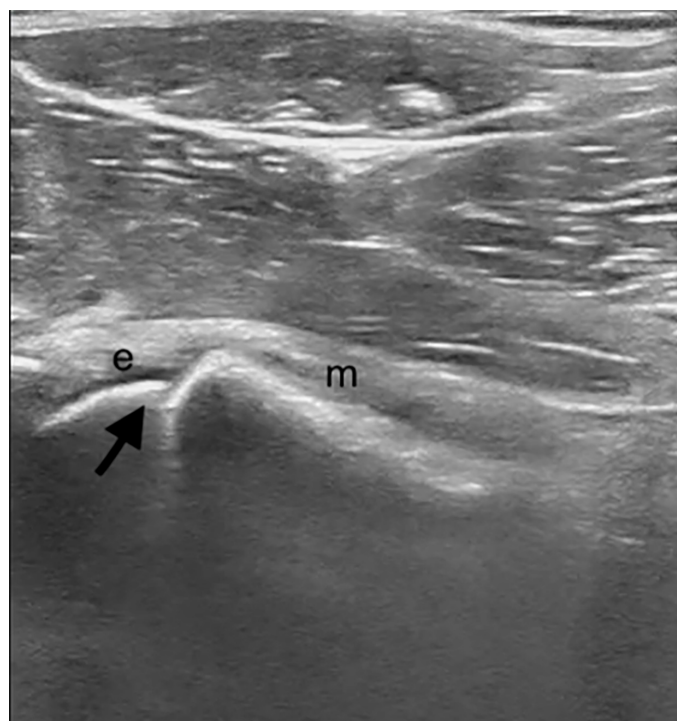


Image 1. Point-of-care ultrasound image of left hip showing displacement of epiphysis(e) from metaphysis (m) – the physal step (arrow).

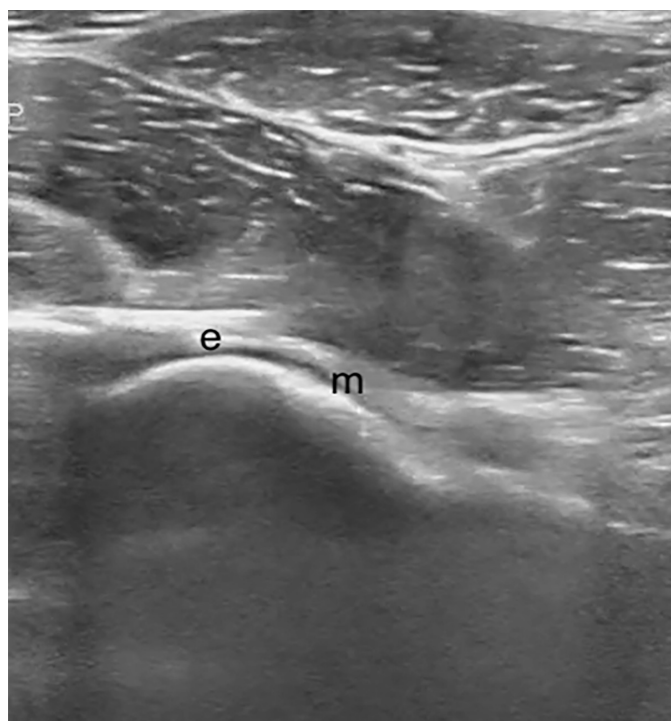


Image 2. Point-of-care ultrasound image of right hip showing normal contour of metaphysis (m) and epiphysis (e) with no displacement.

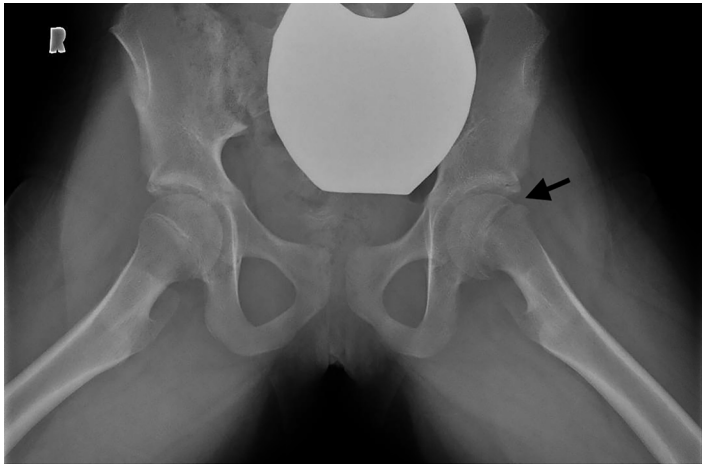


Image 3. Radiograph of pelvis showing medially displaced left femoral epiphysis (arrow).

between the ages of 8-15 years. SCFE is characterized by a displacement of the capital femoral epiphysis from the metaphysis (femoral neck), through the growth plate.¹ SCFE usually presents with sudden or progressive limping with hip, groin, thigh or even knee pain.¹ Delayed diagnosis has been associated with increased severity of slip and complications, including avascular necrosis of the femoral head, chondrolysis and osteoarthritis.²

Although plain radiographs are the primary modality used to diagnose SCFE, ultrasound has also been used for diagnosis, staging and follow-up management of SCFE.³ Key ultrasound findings include posterior displacement of epiphysis with a physeal step, reduced distance between the anterior rim of the acetabulum and the metaphysis, remodeling of the metaphysis and, occasionally, joint effusion.⁴ Ultrasound sensitivity in diagnosis of SCFE is as high as 95%³. Its point-of-care use by emergency physicians can be a useful adjunct as a non-radiating, readily available bedside modality for assessing the limping child – especially in low-resource or rural settings where radiography may not be readily available or would require subsequent transfer to a different facility.

The patient underwent open reduction and internal fixation with uneventful recovery.

Documented patient informed consent and/or Institutional Review Board approval has been obtained and filed for publication of this case report.

CPC-EM Capsule

What do we already know about this clinical entity?
Slipped capital femoral epiphysis (SCFE) is a disorder of older children and adolescents presenting with progressive unilateral pain and limp.

What is the major impact of the image(s)?
These images demonstrate sonographic findings of SCFE, particularly epiphyseal displacement from metaphysis of femur when compared with unaffected side.

How might this improve emergency medicine practice?
Point-of-care ultrasound provides a rapid, non-ionizing bedside method to diagnose SCFE, allowing early immobilization, pain control and expedited management in the emergency department.

Address for Correspondence: Imran Asad, MD, University of Toronto, Hospital for Sick Children, Division of Pediatric Emergency Medicine, Department of Pediatrics, 555 University Avenue, Toronto, ON, Canada M5G1X8. Email: Imran.asad@sickkids.ca.

Conflicts of Interest: By the CPC-EM article submission agreement, all authors are required to disclose all affiliations, funding sources and financial or management relationships that could be perceived as potential sources of bias. The authors disclosed none.

Copyright: © 2019 Asad et al. This is an open access article distributed in accordance with the terms of the Creative Commons Attribution (CC BY 4.0) License. See: <http://creativecommons.org/licenses/by/4.0/>

REFERENCES

1. Peck DM, Voss LM, Voss TT. Slipped capital femoral epiphysis: diagnosis and management. *Am Fam Physician*. 2017;95(12):779-84.
2. Rahme D, Comley A, Foster B, et al. Consequences of diagnostic delays in slipped capital femoral epiphysis. *J Pediatr Orthop B*. 2006;15(2):93-7.
3. Magnano GM, Lucigrai G, De Filippi C, et al. Diagnostic imaging of the early slipped capital femoral epiphysis. *Radiol Med*. 1998;95(1-2):16-20.
4. Palaniappan M, Indiran V, Maduraimuthu P. Ultrasonographic diagnosis of slipped capital femoral epiphysis. *Pol J Radiol*. 2017;82:149-51.

Diagnosis of Brachial Artery Thromboembolism with Point-of-care Ultrasound

Vincent Ceretto, DO, MS
Michael Lu, MD

University of Rochester Medical Center, Department of Emergency Medicine,
Rochester, New York

Section Editor: Rick A. McPheeters, DO

Submission history: Submitted October 7, 2018; Revision received November 20, 2018; Accepted January 1, 2019

Electronically published January 22, 2019

Full text available through open access at http://escholarship.org/uc/uciem_cpem

DOI: 10.5811/cpcem.2019.1.41181

[Clin Pract Cases Emerg Med. 2019;3(1):83–84.]

CASE PRESENTATION

A 77-year-old male with a history of ventricular bigeminy presented to the emergency department complaining of arm tingling, pain, and poikilothermia. This occurred immediately after the patient reached to use the television remote control device. His right forearm and hand were dusky, cold, pulseless, and had delayed capillary refill compared to the left arm. Strength was intact but light touch sensation was decreased. The emergency physician (EP) performed a point-of-care ultrasound, which showed an occlusive distal brachial, proximal ulnar, and proximal radial artery thrombus (Image, Video). Vascular surgery was consulted and within two hours of arrival the patient was in the operating room without any additional vessel imaging. An embolectomy was performed using a Fogarty catheter. Arterial flow was restored, the hand was revascularized, and the patient's symptoms resolved. A transesophageal echocardiogram was performed postoperatively, which showed a left atrial appendage thrombus. He was started on lifelong anticoagulation and discharged from the hospital.

DISCUSSION

Acute upper limb ischemia (AULI) is a rare condition that results from sudden loss of blood flow to an extremity. An EP must rapidly diagnose this condition to prevent limb loss and death. Emboli most commonly originate in the heart as a result of atrial fibrillation, and predominantly embed in the brachial artery (68%).^{1,2} Overall, the incidence of thromboembolism as a result of AULI was 3.3 per 100,000 person-years among men and 5.2 per 100,000 person-years among women.¹ Although the diagnosis is made clinically by a detailed history and physical exam (six Ps: paresthesia, pain, pallor, pulselessness, poikilothermia, and paralysis), preoperative imaging is usually sought out. In a study of 182 patients with peripheral artery emboli, surgical and survival outcomes were equivalent

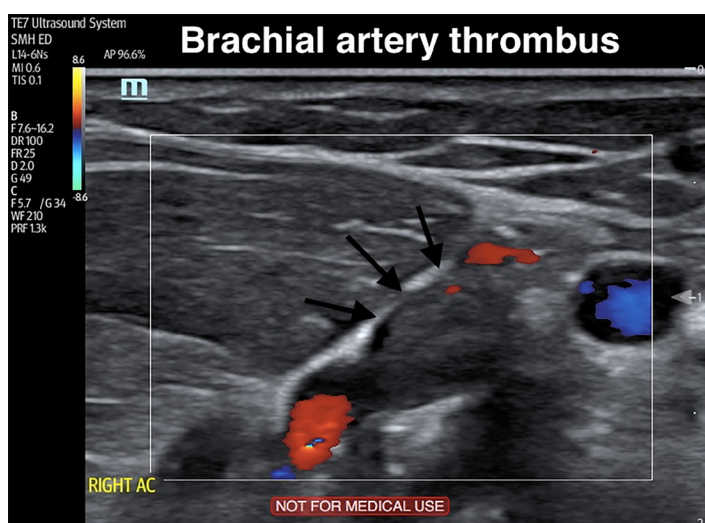


Image. Still image of a duplex ultrasound demonstrating a brachial artery thrombus (arrows).

when comparing duplex ultrasonography alone to contrast angiography or computed tomography angiography.³ Ultrasound offers the advantage of being noninvasive, inexpensive, radiation-free, readily available to EPs, and provides dynamic information about perfusion.

Video. Point-of-care duplex ultrasound demonstrating an upper extremity brachial artery thrombus.

Documented patient informed consent and/or Institutional Review Board approval has been obtained and filed for publication of this case report.

Address for Correspondence: Vincent Ceretto, DO, MS, University of Rochester Medical Center, Department of Emergency Medicine, 601 Elmwood Ave, Box 655, Rochester, NY 14642. Email: vceretto@gmail.com.

Conflicts of Interest: By the CPC-EM article submission agreement, all authors are required to disclose all affiliations, funding sources and financial or management relationships that could be perceived as potential sources of bias. The authors disclosed none.

Copyright: © 2019 Ceretto et al. This is an open access article distributed in accordance with the terms of the Creative Commons Attribution (CC BY 4.0) License. See: <http://creativecommons.org/licenses/by/4.0/>

REFERENCES

1. Andersen LV, Lip GY, Lindholt JS, et al. Upper limb arterial thromboembolism: a systematic review on incidence, risk factors, and prognosis, including a meta-analysis of risk-modifying drugs. *J Thromb Haemost.* 2013;11(5): 836-44.
2. Haimovici H. Cardiogenic embolism of the upper extremity. *J Cardiovasc Surg (Torino).* 1982;23(3):209-13.
3. Crawford JD, Perrone KH, Jung E, et al. Arterial duplex for diagnosis of peripheral arterial emboli. *J Vasc Surg.* 2016;64(5):1351-6.

CPC-EM Capsule

What do we already know about this clinical entity?

Acute upper limb ischemia is a rare condition that results from sudden loss of blood flow. Emergency physicians (EPs) must rapidly diagnose this condition to prevent limb loss and death.

What is the major impact of the image(s)?

Point-of-care ultrasonography can easily be used by EPs to expedite diagnosis and management.

How might this improve emergency medicine practice?

The images provided demonstrate how to identify a brachial artery thrombus.

Point-of-Care Ultrasound Diagnosis of Right Ventricular Rupture Post Cardiac Arrest After Thrombolysis in Myocardial Infarction

Jonathan Miller, MBCHB*

Lorna Swarbrick, MBCHB*

Butheyana Abdelhameed, MBCHB*†

Thomas Carter, DO**

* Palmerston North Hospital, Department of Emergency Medicine, Roslyn, Palmerston North, New Zealand

† University of Otago, Department of Surgery and Anesthesia, Dunedin, New Zealand

** Ohio University Heritage College of Osteopathic Medicine, Department of Emergency Medicine, Athens, Ohio

Section Editor: Rick A. McPheeters, DO

Submission history: Submitted August 19, 2018; Revision received November 27, 2018; Accepted January 1, 2019

Electronically published January 28, 2019

Full text available through open access at http://escholarship.org/uc/uciem_cpem

DOI: 10.5811/cpcem.2019.1.40664

[Clin Pract Cases Emerg Med. 2019;3(1):85–86.]

CASE PRESENTATION

An 81-year-old male was referred by his general practitioner with a troponin-T of 153 nanograms per liter (ng/L) (reference range <5 ng/L) and chest pain ongoing for 13 hours on arrival. Initial electrocardiogram showed 7-millimeter anterior ST elevation in leads V2-5. The case was discussed with cardiology at the nearest tertiary care center and plans were arranged for the patient's transfer for percutaneous coronary intervention. Thrombolysis was withheld due to a known abdominal aortic aneurysm and a suspicious renal mass under investigation. While awaiting transfer, the patient suffered a ventricular tachycardia arrest, and cardiopulmonary resuscitation (CPR) was commenced. Point-of-care echocardiogram was performed, showing a hypokinetic myocardium. After four rounds of CPR, thrombolysis was given as a last resort. Repeat point-of-care echocardiography demonstrated irrecoverable injury; therefore, CPR was discontinued (Video).

DISCUSSION

Right ventricle (RV) free wall rupture is a dangerous complication of myocardial infarction (MI) with a high mortality rate. Overall, cardiac rupture complicates approximately 5% of cases of acute MI,¹ with left ventricular rupture accounting for the majority. RV rupture is comparatively rare and its identification via echocardiography rarer still. Over 10% of cases of free wall rupture occur in patients who subsequently died from ST-segment elevation myocardial infarction (STEMI).² This case was likely a type I rupture: an abrupt, slit-like tear occurring in acute infarcts of less than 24 hours duration.³ Type II ruptures occur where the infarcted myocardium erodes before rupture and is covered by thrombus. Type III represents the perforation of a previously formed aneurysm.³ Examination and history findings are non-specific, but ultrasound for diagnosing ventricular rupture is greater than or equal to 70% sensitive and 90% specific.⁴

It has previously been shown that thrombolytic therapy is independently associated with increased incidence of cardiac rupture and this risk is elevated with prolonged time to administration of thrombolysis.⁵⁻⁷ Other risk factors include advanced age, female sex, previous cerebrovascular disease, chronic kidney disease, and congestive heart failure.⁸⁻⁹ Our patient fulfilled only one of these risk criteria. This case demonstrates the value of echocardiography in the diagnosis of RV free wall rupture, along with the risks of thrombolysis and the need for further research around RV rupture post-STEMI.

Video. Point-of-care echocardiogram demonstrating right ventricle free wall rupture.

Documented patient informed consent and/or Institutional Review Board approval has been obtained and filed for publication of this case report.

Address for Correspondence: Thomas Carter, DO, Palmerston North Hospital, Department of Emergency Medicine, 44 Ruahine St, Roslyn, Palmerston North 4414, New Zealand. Email: thomasecarter@gmail.com.

Conflicts of Interest: By the CPC-EM article submission agreement, all authors are required to disclose all affiliations, funding sources and financial or management relationships that could be perceived as potential sources of bias. The authors disclosed none.

Copyright: © 2019 Miller et al. This is an open access article distributed in accordance with the terms of the Creative Commons Attribution (CC BY 4.0) License. See: <http://creativecommons.org/licenses/by/4.0/>

REFERENCES

1. Depukat R, Chyrchel M, Dudek D. Left ventricular free wall rupture as a mechanical complication in ST-segment elevation acute myocardial infarction. *Kardiol Pol.* 2012;70(12):1309-12.
2. Sugiura T, Nagahama Y, Nakamura S, et al. Left ventricular free wall rupture after reperfusion therapy for acute myocardial infarction. *Am J Cardiol.* 2003;92(3):282-4.
3. Becker AE and van Mantgem JP. Cardiac tamponade. A study of 50 hearts. *Eur J Cardiol.* 1975;3:349-58).
4. Gulalp B, Karagun O, Tekin A et al. Cardiac Rupture. *J Emerg Med.* 2013. 44(1):58-60.
5. Akcay M, Senkaya EB, Bilge M, et al. Rare mechanical complication of myocardial infarction: isolated right ventricle free wall rupture. *Singapore Med J.* 2011;52(1):e7-9.
6. Solodky A, Behar S, Herz I, et al. Comparison of incidence of cardiac rupture among patients with acute myocardial infarction treated by thrombolysis versus percutaneous transluminal coronary angioplasty. *Am J Cardiol.* 2001;87(9):1105-8.
7. Honan MB, Harrell FE Jr., Reimer KA, et al. Cardiac rupture, mortality and timing of thrombolytic therapy: a meta -analysis. *J Am Coll Cardiol.* 1990;16:359-67.
8. Moreyra AE, Huang MS, Wilson AC, et al. Trends in incidence and mortality rates of ventricular septal rupture during acute myocardial infarction. *Am J Cardiol.* 2010;106(8):1095-100
9. Lopez-Sendon J, Gurfinkel EP, Lopez de Sa E, et al. Factors related to heart rupture in acute coronary syndromes in the Global Registry of Acute Coronary Events. *Eur Heart J.* 2010;31(12):1449-56.
10. Menon V, Webb JG, Hillis LD, et al. Outcome and profile of ventricular septal rupture with cardiogenic shock after myocardial infarction: a report from the SHOCK Trial Registry. Should we emergently revascularize occluded coronaries in cardiogenic shock? *J Am Coll Cardiol.* 2000;36(3 Suppl A):1110-16.

CPC-EM Capsule

What do we already know about this clinical entity?

Most literature describing ventricular rupture discusses the left ventricle or the septum. There is minimal literature describing right ventricular free wall rupture.

What is the major impact of the image(s)?

Emergency clinicians may be faced with this rare complication and be able to direct treatment quickly with point-of-care ultrasound images.

How might this improve emergency medicine practice?

The treating group of clinicians felt it may be difficult to interpret a free wall rupture and act appropriately if it was not quickly identified.

Patient with Swollen Neck

Akshay K. Elagandhala, MD
Robert Liu, MD
Henry E. Wang, MD, MS

University of Texas Health Science Center at Houston, Department of Emergency Medicine, Houston, Texas

Section Editor: Rick A. McPheeters, DO

Submission history: Submitted October 16, 2018; Revision received December 13, 2018; Accepted January 3, 2019

Electronically published January 29, 2019

Full text available through open access at http://escholarship.org/uc/uciem_cpccem

DOI: 10.5811/cpcem.2019.1.41294

[Clin Pract Cases Emerg Med. 2019;3(1):87–88.]

CASE PRESENTATION

A 25-year-old female with a history of sickle cell disease (on prophylactic penicillin VK) and venous thromboembolic disease (on oral anticoagulation with apixaban) presented to the emergency department with one week of right-sided neck pain and subjective fevers, and a one day history of trismus. Physical examination revealed warmth, swelling and tenderness to the right lateral neck near the angle of the mandible, with associated mild trismus (Image 1). Additional history revealed the presence of bilateral, subclavian, implanted venous access ports. We ordered a computed tomography (CT) of the neck with intravenous (IV) contrast (Image 2).

DISCUSSION

The CT revealed complete occlusion of the right internal jugular vein consistent with Lemierre's syndrome.^{1,2} Lemierre's syndrome is acute thrombophlebitis of the internal jugular vein,

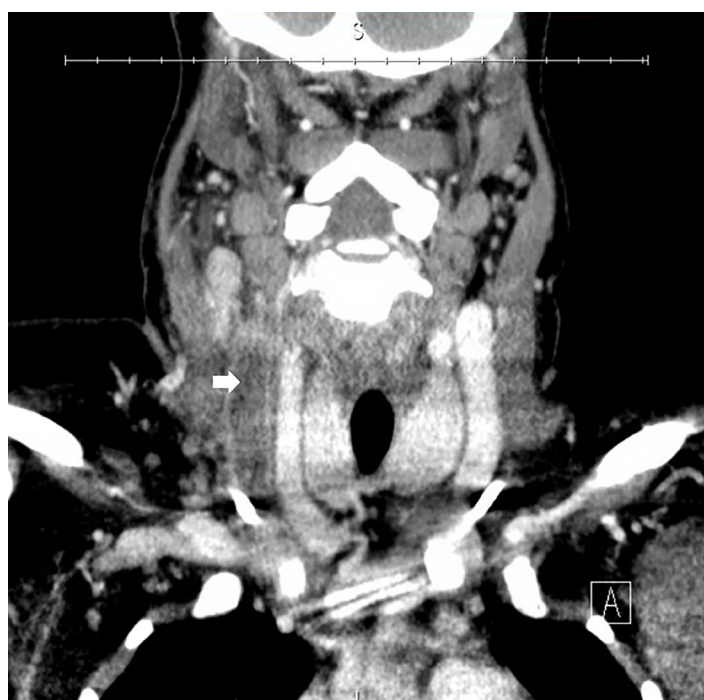

Image 2. Coronal view of a computed tomography of the neck with contrast. Arrow indicates thrombus in the right internal jugular vein with complete occlusion.

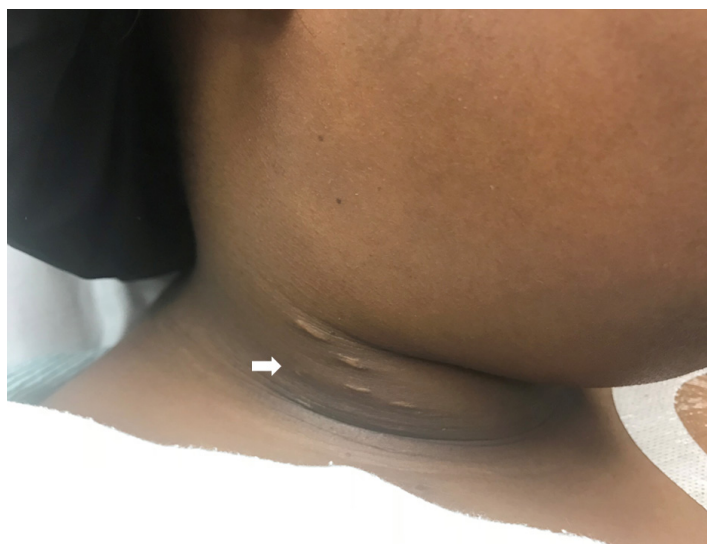

Image 1. External view of the right neck swelling. Arrow indicates area of swelling.

usually associated with direct spread of adjacent odontogenic or oropharyngeal bacterial infections. The most common microbial source is the gram-negative, anaerobic *fusobacterium* species, a part of the oropharyngeal flora. Conditions that should be considered in the work-up of neck swelling may include retropharyngeal abscess, Ludwig's angina, subcutaneous abscess, suppurative parotitis, odontogenic infection (e.g., periodontal abscess, submandibular osteomyelitis), peritonsillar abscess, pharyngitis with reactive cervical lymphadenopathy, malignancy (e.g., lymphoma), and carotid/vertebral artery dissection.

Management of Lemierre's syndrome includes antibiotic therapy and selective use of anticoagulation. Initial antibiotic coverage should include a beta-lactamase resistant antibiotic with anaerobic coverage (e.g., ampicillin and sulbactam, or piperacillin and tazobactam) to cover for oropharyngeal flora. Coverage for methicillin-resistant gram-positive species should also be considered (e.g., vancomycin and fluoroquinolones), especially in catheter-associated infections.^{3,4} In select cases, surgical abscess drainage or jugular vein ligation may be necessary.

In this case, blood cultures drawn from both ports indicated the presence of methicillin-resistant *staphylococcus epidermidis*, presumptively from colonization of the venous access ports. No additional microbial source was identified. The patient's history of sickle cell disease, venous thromboembolic disease, and the presence of venous access ports likely potentiated the risk of internal jugular vein thrombus formation despite concurrent long-term anticoagulation. The patient was hospitalized, received antibiotic therapy with vancomycin and cefepime (later changed to ampicillin-sulbactam) and anticoagulation with IV heparin, and underwent surgical removal of both internal jugular venous access ports.

Documented patient informed consent and/or Institutional Review Board approval has been obtained and filed for publication of this case report.

Address for Correspondence: Henry E. Wang, MD, MS, University of Texas Health Science Center at Houston, Department of Emergency Medicine, 64312 Fannin St., J14 434, Houston, TX 77030. Email: henry.e.wang@uth.tmc.edu.

Conflicts of Interest: By the CPC-EM article submission agreement, all authors are required to disclose all affiliations, funding sources and financial or management relationships that could be perceived as potential sources of bias. The authors disclosed none.

Copyright: © 2019 Elagandhala et al. This is an open access article distributed in accordance with the terms of the Creative Commons Attribution (CC BY 4.0) License. See: <http://creativecommons.org/licenses/by/4.0/>

CPC-EM Capsule

What do we already know about this clinical entity?

Odontogenic and oropharyngeal infections may cause thrombophlebitis of the jugular vein (Lemierre's syndrome).

What is the major impact of the image(s)?

This image depicts complete internal jugular vein occlusion consistent with Lemierre's syndrome.

How might this improve emergency medicine practice?

Clinicians should consider Lemierre's syndrome in individuals presenting with neck pain and fever. The risk may be heightened in those with a history of hematologic or venothromboembolic disease or an indwelling vascular catheter.

REFERENCES

1. Shook J and Trigger C. Lemierre's syndrome. *West J Emerg Med.* 2014;15(2):125-6.
2. Noy D, Rachmiel A, Levy-Faber D, et al. Lemierre's syndrome from odontogenic infection: review of the literature and case description. *Ann Maxillofac Surg.* 2015;5(2):219-25.
3. Lundin MS, Bastakoti S, Havlichek D, et al. Lemierre's syndrome and 2016 American College of Physician guidelines for pharyngitis: no to empiric coverage for bacterial pharyngitis. While no role for routine Fusobacterium PCR, keep suspicion for this pathogen. *BMJ Case Rep.* 2018; pii: bcr-2018-225149.
4. Seidenfeld SM, Sutker WL, Luby JP. Fusobacterium necrophorum septicemia following oropharyngeal infection. *JAMA.* 1982;248(11):1348-50.



20th


Stanford Symposium on **EMERGENCY MEDICINE**

Hawaii

#STANFORDALOHA

APRIL 15-19, 2019 | WAILEA BEACH RESORT, MAUI

Earn up to 27.5 CME credits



Course Topics

- Trauma
- Critical Care
- Disaster Medicine
- Pediatric Emergency Medicine
- Cardiology
- Wilderness Medicine
- Population Health
- Physician Wellness
- Point-of-Care Ultrasound
- & a full day of hands-on workshops!

Learn from our world-class faculty

Course Directors: Phillip Harter, Michael Bresler & Viveta Lobo. Stanford faculty: Kenton Anderson, Paul Auerbach, Milana Boukhman, Peter D'Souza, Bernard Dannenberg, Andrea Fang, Marc Gautreau, Laleh Gharahbaghian, Zhara Ghazi-Askar, Michael Gisondi, Moon Lee, Donald Schreiber, Sam Shen, Rebecca Smith-Coggins, Matthew Strehlow, Ewan Wang, Jenny Wilson



Headquarter Hotel: The Marriott Wailea Beach Resort
Set in the family-friendly Marriott Wailea Beach area, it couldn't be easier to earn quality CME with the family along. Register early to assure your spot!

Visit cme.stanford.edu/emed for more information.

ACCREDITATION

The Stanford University School of Medicine is accredited by the Accreditation Council for Continuing Medical Education (ACCME) to provide continuing medical education for physicians.

CREDIT DESIGNATION

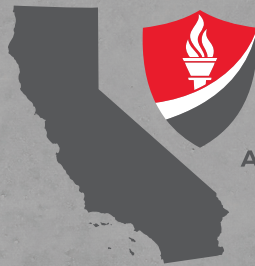The Stanford University School of Medicine designates this live activity for a maximum of 27.5 AMA PRA Category 1 Credits™. Physicians should claim only the credit commensurate with the extent of their participation in the activity.

Four-Day 20th Stanford Symposium on Emergency Medicine: Maximum of 21.5 AMA PRA Category 1 Credits™

One-Day Optional Skills Development Workshops – Each workshop offers 2.00 AMA PRA Category 1 Credits™. Learners may choose up to 3 workshops for a maximum of 6.00 AMA PRA Category 1 Credits™

The American Nurses Credentialing Center (ANCC) accepts AMA PRA Category 1 Credit™ from organizations accredited by the ACCME. Please check with your state's credentialing board for their requirements.

**JOIN
CAL/AAEM!**



CALAAEM

CALIFORNIA CHAPTER DIVISION OF THE
AMERICAN ACADEMY OF EMERGENCY MEDICINE

*Championing
individual physician rights
and workplace fairness*

BENEFITS

- *Western Journal of Emergency Medicine* Subscription
- CAL/AAEM News Service email updates
- Discounted AAEM pre-conference fees
- And more!

CAL/AAEM NEWS SERVICE

- Healthcare industry news
- Public policy
- Government issues
- Legal cases and court decisions

In collaboration with our official journal

WestJEM

Integrating Emergency Care
with Population Health



[FACEBOOK.COM/CALAAEM](https://www.facebook.com/CALAAEM)



FOLLOW US @CALAAEM

[HTTP://WWW.CALAAEM.ORG](http://www.calaaem.org)



CALIFORNIA ACEP
AMERICAN COLLEGE OF EMERGENCY PHYSICIANS

30TH ANNUAL

**LEGISLATIVE
LEADERSHIP
CONFERENCE**

**APRIL 23, 2019
SACRAMENTO, CA**