

# CPC Emergency Medicine

Volume III, Number 3, August 2019

Open Access at [www.cpcem.org](http://www.cpcem.org)

ISSN: 2474-252X

## *Clinical Practice and Cases in Emergency Medicine*

In Collaboration with the *Western Journal of Emergency Medicine*

### Clinicopathological Cases from the University of Maryland

- 178 **75-year-old Woman with a Fever and Rash**  
*Kuhn D, Strong J, Bontempo LJ, ZDW Dezman*

### Clinicopathological Cases

- 185 **Beware of the Zebra: Nine-year-old with Fever**  
*Lupez K, Allen B, Fox S, Lewis M*

### Astonishing Cases and Images in Emergency Medicine

- 191 **Your Automated Implantable Cardioverter Defibrillator Is Not a Bulletproof Vest but It Might Save Your Life**  
*Perahia T, Kleinman DS, Habre WG*

### Medical Legal Case Reports

- 194 **To tPA or Not to tPA: Two Medical-Legal Misadventures of Diagnosing a Cerebrovascular Accident as a Stroke Mimic**  
*Moore MJ, Stuart J, Humphreys A, Pfaff JA*

### Case Reports

- 199 **Symptomatic Pericardial Cyst: An Atypical Case of Pleuritic Chest Pain**  
*Sallade TD, Kraus CK, Hoffman L*
- 202 **Detection of Type B Aortic Dissection in the Emergency Department with Point-of-Care Ultrasound**  
*Earl-Royal E, Nguyen PD, Alvarez A, Gharahbghian L*
- 208 **Head of the Bed Down: Paradoxical Management for Paradoxical Herniation**  
*Bender PD, Brown AEC*
- 211 **A Case of Thiazide-induced Hypokalemic Paralysis**  
*Schell E, Pathman J, Pescatore R, Bianchi PW*
- 215 **Ventricular Tachycardia Storm Presenting as Vague Complaints to the Emergency Department**  
*Kamboj R, Bunch AC, Bernstein RC, Counselman FL*

*Contents continued on page iii*



UC Irvine Health





Austin

— ACOEP's 2019 —

# SCIENTIFIC ASSEMBLY

## SAVE THE DATE

★ NOVEMBER 2 - 6, 2019 ★

JW MARRIOTT • AUSTIN, TX



Stay tuned at [acoep.org](http://acoep.org) for more information.

# Clinical Practice and Cases in Emergency Medicine

Indexed in PubMed and full text in PubMed Central

In Collaboration with the *Western Journal of Emergency Medicine*

**Rick A. McPheeters, DO, Editor-in-Chief**  
*Kern Medical/UCLA- Bakersfield, California*

**Manish Amin, DO, Associate Editor**  
*Kern Medical/UCLA- Bakersfield, California*

**Mark I. Langdorf, MD, MHPE, Associate Editor**  
*University of California, Irvine School of Medicine- Irvine, California*

**Shadi Lahham, MD, MS, Associate Editor**  
*University of California, Irvine School of Medicine- Irvine, California*

**Shahram Lotfipour, MD, MPH, Managing Associate Editor**  
*University of California, Irvine School of Medicine- Irvine, California*

**Anna McFarlin, MD, Section Editor**  
*Louisiana State University Health Science Center- New Orleans, Louisiana*

**Austin Smith, MD, Section Editor**  
*Vanderbilt University Medical Center-Nashville, Tennessee*

**Christopher Sampson, MD, Section Editor**  
*University of Missouri- Columbia, Missouri*

**Joel Moll, MD, Section Editor**  
*Virginia Commonwealth University School of Medicine- Richmond, Virginia*

**Scott Goldstein, DO, Section Editor**  
*Sidney Kimmel College of Medicine- Philadelphia, Pennsylvania*

**Steven Walsh, MD, Section Editor**  
*Einstein Medical Center Philadelphia-Philadelphia, Pennsylvania*

**John Ashurst, DO, Section Editor**  
*Kingman Regional Health Network, Arizona*

## Editorial Board

Amin A. Kazzi, MD, MAAEM  
*The American University of Beirut, Beirut, Lebanon*

Anwar Al-Awadhi, MD  
*Mubarak Al-Kabeer Hospital, Jabriya, Kuwait*

Arif A. Cevik, MD  
*United Arab Emirates University  
College of Medicine and Health Sciences, Al Ain, United Arab Emirates*

Abhinandan A. Desai, MD  
*University of Bombay Grant Medical College, Bombay, India*

Bandr Mzahim, MD  
*King Fahad Medical City, Riyadh, Saudi Arabia*

Barry E. Brenner, MD, MPH  
*Case Western Reserve University*

Brent King, MD, MMM  
*University of Texas, Houston*

Daniel J. Dire, MD  
*University of Texas Health Sciences Center San Antonio*

David F.M. Brown, MD  
*Massachusetts General Hospital/Harvard Medical School*

Edward Michelson, MD  
*Texas Tech University*

Edward Panacek, MD, MPH  
*University of South Alabama*

Erik D. Barton, MD, MBA  
*Icahn School of Medicine, Mount Sinai, New York*

Francesco Dellacorte, MD  
*Azienda Ospedaliera Universitaria "Maggiore della Carità," Novara, Italy*

Francis Counselman, MD  
*Eastern Virginia Medical School*

Gayle Galletta, MD  
*Sørlandet Sykehus HF, Akershus Universitetssykehus, Lorenskog, Norway*

Hjalte Björnsson, MD  
*Icelandic Society of Emergency Medicine*

Jacob (Kobi) Peleg, PhD, MPH  
*Tel-Aviv University, Tel-Aviv, Israel*

Jonathan Olshaker, MD  
*Boston University*

Katsuhiko Kanemaru, MD  
*University of Miyazaki Hospital, Miyazaki, Japan*

Khrongwong Musikatavorn, MD  
*King Chulalongkorn Memorial Hospital, Chulalongkorn University, Bangkok, Thailand*

Leslie Zun, MD, MBA  
*Chicago Medical School*

Linda S. Murphy, MLIS  
*University of California, Irvine School of Medicine Librarian*

Nadeem Qureshi, MD  
*St. Louis University, USA  
Emirates Society of Emergency Medicine, United Arab Emirates*

Niels K. Rathlev, MD  
*Tufts University School of Medicine*

Pablo Aguilera Fuenzalida, MD  
*Pontificia Universidad Católica de Chile, Región Metropolitana, Chile*

Peter A. Bell, DO, MBA  
*Liberty University  
College of Osteopathic Medicine*

Peter Sokolove, MD  
*University of California, San Francisco*

Robert M. Rodriguez, MD  
*University of California, San Francisco*

Robert Suter, DO, MHA  
*UT Southwestern Medical Center*

Robert W. Derlet, MD  
*University of California, Davis*

Rosidah Ibrahim, MD  
*Hospital Serdang, Selangor, Malaysia*

Samuel J. Stratton, MD, MPH  
*Orange County, CA, EMS Agency*

Scott Rudkin, MD, MBA  
*University of California, Irvine*

Scott Zeller, MD  
*University of California, Riverside*

Steven Gabaeff, MD  
*Clinical Forensic Medicine*

Steven H. Lim, MD  
*Changi General Hospital, Simei, Singapore*

Terry Mulligan, DO, MPH, FIFEM  
*ACEP Ambassador to the Netherlands Society of Emergency Physicians*

Vijay Gautam, MBBS  
*University of London, London, England*

Wirachin Hoonpongsimanont, MD, MSBATS  
*Siriraj Hospital, Mahidol University, Bangkok, Thailand*

## Advisory Board

Amal Khalil, MBA  
*UC Irvine Health School of Medicine*

Elena Lopez-Gusman, JD  
*California ACEP  
American College of Emergency Physicians*

Janice Wachtler, BAE, CBA  
*American College of Osteopathic Emergency Physicians*

John B. Christensen, MD  
*California Chapter Division of AAEM*

Lori Winston, MD  
*California ACEP  
American College of Emergency Physicians  
Kaweah Delta Healthcare District*

Mark I. Langdorf, MD, MHPE  
*UC Irvine Health School of Medicine*

Nicholas T. Sawyer, MD, MBA  
*California ACEP  
American College of Emergency Physicians  
University of California, Davis*

Peter A. Bell, DO, MBA  
*American College of Osteopathic Emergency Physicians  
Liberty University, College of Osteopathic Medicine*

Robert Suter, DO, MHA  
*American College of Osteopathic Emergency Physicians  
UT Southwestern Medical Center*

Shahram Lotfipour, MD, MPH  
*UC Irvine Health School of Medicine*

Trevor Mills, MD, MPH  
*California Chapter Division of AAEM  
Northern California VA Health Care*

Leila Danishgar, BS  
*Editorial Director*

Joseph Bui, BS  
*CPC-EM Associate Editorial Director*

Maria Nguyen, BS  
*WestJEM Associate Editorial Director*

Tushank Chadha, BS  
*Marketing Director to Media and Communications Director*

Alissa Fiorentino, BA  
*WestJEM Staff Liaison*

Cassandra Saucedo, BS  
*CPC-EM Publishing Director*

Argineh Shahbandari, BS  
*CPC-EM Associate Publishing Director*

Dana Le, BS  
*WestJEM Publishing Director*

Christine Louis, BS  
*WestJEM Associate Publishing Director*

June Casey, BA  
*Copy Editor*

Official Journal of the California Chapter of the American College of Emergency Physicians, the American College of Osteopathic Emergency Physicians, and the California Chapter of the American Academy of Emergency Medicine



Available in MEDLINE, PubMed, PubMed Central, Google Scholar, eScholarship, DOAJ, and OASPA.

Editorial and Publishing Office: WestJEM/Department of Emergency Medicine, UC Irvine Health, 333 City Blvd, West, Rt 128-01, Orange, CA 92866, USA

Office: 1-714-456-6389; Email: Editor@westjem.org

# Clinical Practice and Cases in Emergency Medicine

Indexed in PubMed and full text in PubMed Central

In Collaboration with the *Western Journal of Emergency Medicine*

This open access publication would not be possible without the generous and continual financial support of our society sponsors, department and chapter subscribers.

## Professional Society Sponsors

AMERICAN COLLEGE OF OSTEOPATHIC EMERGENCY PHYSICIANS  
CALIFORNIA ACEP

CALIFORNIA CHAPTER DIVISION OF  
AMERICAN ACADEMY OF EMERGENCY MEDICINE

## Academic Department of Emergency Medicine Subscriber

Albany Medical College Albany, NY	INTEGRIS Health Oklahoma City, OK	Robert Wood Johnson University Hospital New Brunswick, NJ	University of Florida, Jacksonville Jacksonville, FL
American University of Beirut Beirut, Lebanon	Kaweah Delta Health Care District Visalia, CA	Rush University Medical Center Chicago, IL	University of Illinois at Chicago Chicago, IL
Arrowhead Regional Medical Center Colton, CA	Kennedy University Hospitals Turnersville, NJ	Southern Illinois University Carbondale, IL	University of Illinois College of Medicine Peoria, IL
Augusta University Augusta GA	Kern Medical Bakersfield, CA	St. Luke's University Health Network Bethlehem, PA	University of Iowa Iowa City, IA
Baystate Medical Center Springfield, MA	Lakeland HealthCare St. Joseph, MI	Stanford/Kaiser Emergency Medicine Residency Program Stanford, CA	University of Louisville Louisville, KY
Beaumont Hospital Royal Oak, MI	Lehigh Valley Hospital and Health Network Allentown, PA	Staten Island University Hospital Staten Island, NY	University of Maryland Baltimore, MD
Beth Israel Deaconess Medical Center Boston, MA	Loma Linda University Medical Center Loma Linda, CA	SUNY Upstate Medical University Syracuse, NY	University of Michigan Ann Arbor, MI
Boston Medical Center Boston, MA	Louisiana State University Health Sciences Center New Orleans, LA	Temple University Philadelphia, PA	University of Missouri, Columbia Columbia, MO
Brigham and Women's Hospital Boston, MA	Madigan Army Medical Center Tacoma, WA	Texas Tech University Health Sciences Center El Paso, TX	University of Nebraska Medical Center Omaha, NE
Brown University Providence, RI	Maimonides Medical Center Brooklyn, NY	University of Alabama, Birmingham Birmingham, AL	University of South Alabama Mobile, AL
Carl R. Darnall Army Medical Center Fort Hood, TX	Maricopa Medical Center Phoenix, AZ	University of Arkansas for Medical Sciences Little Rock, AR	University of Southern California/Keck School of Medicine Los Angeles, CA
Conemaugh Memorial Medical Center Johnstown, PA	Massachusetts General Hospital Boston, MA	University of California, Davis Medical Center Sacramento, CA	University of Tennessee, Memphis Memphis, TN
Desert Regional Medical Center Palm Springs, CA	Mayo Clinic College of Medicine Rochester, MN	University of California Irvine Orange, CA	University of Texas, Houston Houston, TX
Doctors Hospital/Ohio Health Columbus, OH	Mt. Sinai Medical Center Miami Beach, FL	University of California, Los Angeles Los Angeles, CA	University of Texas Health San Antonio, TX
Eastern Virginia Medical School Norfolk, VA	North Shore University Hospital Manhasset, NY	University of California, San Diego La Jolla, CA	University of Warwick Library Coventry, United Kingdom
Einstein Healthcare Network Philadelphia, PA	Northwestern Medical Group Chicago, IL	University of California, San Francisco San Francisco, CA	University of Washington Seattle, WA
Emory University Atlanta, GA	Ohio State University Medical Center Columbus, OH	UCSF Fresno Center Fresno, CA	University of Wisconsin Hospitals and Clinics Madison, WI
Genesys Regional Medical Center Grand Blanc, Michigan	Ohio Valley Medical Center Wheeling, WV	University of Chicago, Chicago, IL	Wake Forest University Winston-Salem, NC
Hartford Hospital Hartford, CT	Oregon Health and Science University Portland, OR	University of Colorado, Denver Denver, CO	Wright State University Dayton, OH
Hennepin County Medical Center Minneapolis, MN	Penn State Milton S. Hershey Medical Center Hershey, PA	University of Florida Gainesville, FL	
Henry Ford Hospital Detroit, MI	Presence Resurrection Medical Center Chicago, IL		

## State Chapter Subscriber

ARIZONA CHAPTER DIVISION OF THE  
AMERICAN ACADEMY OF EMERGENCY MEDICINE  
CALIFORNIA CHAPTER DIVISION OF THE  
AMERICAN ACADEMY OF EMERGENCY MEDICINE  
FLORIDA CHAPTER DIVISION OF THE  
AMERICAN ACADEMY OF EMERGENCY MEDICINE

GREAT LAKES CHAPTER DIVISION OF THE  
AMERICAN ACADEMY OF EMERGENCY MEDICINE  
TENNESSEE CHAPTER DIVISION OF THE  
AMERICAN ACADEMY OF EMERGENCY MEDICINE

UNIFORMED SERVICES CHAPTER DIVISION OF THE  
AMERICAN ACADEMY OF EMERGENCY MEDICINE  
VIRGINIA CHAPTER DIVISION OF THE  
AMERICAN ACADEMY OF EMERGENCY MEDICINE

## International Society Partners

EMERGENCY MEDICINE ASSOCIATION OF TURKEY  
LEBANESE ACADEMY OF EMERGENCY MEDICINE  
MEDITERRANEAN ACADEMY OF EMERGENCY MEDICINE

NORWEGIAN SOCIETY FOR EMERGENCY MEDICINE  
SOCIEDAD ARGENTINA DE EMERGENCIAS

SOCIEDAD CHILENO MEDICINA URGENCIA  
THAI ASSOCIATION FOR EMERGENCY MEDICINE

To become a *WestJEM* departmental sponsor, waive article processing fee, receive print and copies for all faculty and electronic for faculty/residents, and free CME and faculty/fellow position advertisement space, please go to <http://westjem.com/subscribe> or contact:

Alissa Fiorentino  
*WestJEM* Staff Liaison  
Phone: 1-800-884-2236  
Email: [sales@westjem.org](mailto:sales@westjem.org)

# *Clinical Practice and Cases in Emergency Medicine*

Indexed in PubMed and full text in PubMed Central

In Collaboration with the *Western Journal of Emergency Medicine*

## JOURNAL FOCUS

*Clinical Practice and Cases in Emergency Medicine* (CPC-EM) is a MEDLINE-indexed internationally recognized journal affiliated with the *Western Journal of Emergency Medicine* (WestJEM). It offers the latest in patient care case reports, images in the field of emergency medicine and state of the art clinicopathological and medicolegal cases. CPC-EM is fully open-access, peer reviewed, well indexed and available anywhere with an internet connection. CPC-EM encourages submissions from junior authors, established faculty, and residents of established and developing emergency medicine programs throughout the world.

## Table of Contents *continued*

- 219 Capsaicin: An Uncommon Exposure and Unusual Treatment**  
*OM Yenigun, M Thanassi*
- 222 Severe Cutaneous Findings in a Woman with Dermatomyositis**  
*S Wang, R Keaton, Z Kendrick*
- 226 Polymethylmethacrylate Pulmonary Embolism Following Kyphoplasty**  
*O Morris, J Mathai, K Weller*
- 229 An Unusual Presentation of Postpartum Spontaneous Coronary Artery Dissection**  
*J Alterie, F Villanueva, M Arekat, A Brill*
- 233 Central Retinal Artery Occlusion Associated with Carotid Artery Occlusion**  
*W Weymouth, C Pedersen*
- 237 Superficial Thrombosis of Pelvic Congestion Syndrome Mimicking Pelvic Abscess**  
*A Romero, J Hohbein, SEN Ross*
- 240 Incomplete Stevens-Johnson Syndrome Caused by Sulfonamide Antimicrobial Exposure**  
*NB Canter, LM Smith*
- 243 Novel Application of Balloon Tamponade in Management of Acute Lower Gastrointestinal Hemorrhage**  
*MM Neeki, V Raj, B Archambeau, S Arabian, F Hussain*
- 248 A Novel Technique to Reduce Reliance on Opioids for Analgesia from Acute Appendicitis: The Ultrasound-guided Erector Spinae Plane Block**  
*D Mantuani, J Luftig, A Herring, A Dreyfuss, A Nagdev*
- 252 Operative Hysteroscopy Intravascular Absorption Syndrome Causing Hyponatremia with Associated Cerebral and Pulmonary Edema**  
*MF Elegante, JA Hamera, J Xiao, DA Berger*
- 256 Misdiagnosed Spontaneous Carotid Cavernous Sinus Fistula**  
*M Canellas, N Cheema*
- 259 Atraumatic Back Pain Due to Quadratus Lumborum Spasm Treated by Physical Therapy with Manual Trigger Point Therapy in the Emergency Department**  
*C Grover, K Christoffersen, L Clark, R Close, S Layhe*

Policies for peer review, author instructions, conflicts of interest and human and animal subjects protections can be found online at [www.cpcem.org](http://www.cpcem.org).

# *Clinical Practice and Cases in Emergency Medicine*

Indexed in PubMed and full text in PubMed Central

In Collaboration with the *Western Journal of Emergency Medicine*

## Table of Contents *continued*

- 262 **Left Ventricular Regional Wall Motion Abnormality in the Setting of Acute Loperamide Overdose**  
*K Bornstein, T Montrief, M Anwar Parris*
- 267 **Life-threatening Development of Cardiac Tamponade in the Span of 24 Hours**  
*P Kishi, T Ahmad, KW Dodd*
- 271 **Dyspnea in an Otherwise Healthy 18-year-old: The Importance of Point-of-care Ultrasonography**  
*EC Cleveland Manchanda, SJ Kharasch, AS Liteplo*
- 275 **Abdominal Pain in the Elderly: An Unusual Case of Chronic Mesenteric Ischemia in the Emergency Department**  
*JL Lacey, RM Hughes, V Noble*
- 278 **Sonographic Detection of a Torsed Meckel's Diverticulum Misinterpreted as Acute Appendicitis**  
*J Choi, N Dorinzi, J Pagenhardt, A Steratore, M Sharon, J Minardi*
- 282 **Trimethoprim/Sulfamethoxazole-Induced Bradycardia, Renal Failure, AV-Node Blockers, Shock and Hyperkalemia Syndrome**  
*N Diribe, J Le*
- 286 **Point-of-Care Ultrasound-Directed Evaluation of Elbow Effusion**  
*P Patitsas, R Davis, R Strony*
- 289 **Homicide Using an Air Weapon**  
*B Mogni, S Maines*

### Images in Emergency Medicine

- 295 **Steal Phenomenon with Tonsillar Arteriovenous Malformation**  
*M Amin, K Chaddha, P Aguiñiga-Navarrete, S Challa, MB Garrett*
- 297 **Tethered Cord Syndrome**  
*S Catmull, J Ashurst*
- 299 **Twiddler's Syndrome**  
*JA Lesnick, BL Cooper, PB Doshi*
- 301 **The Dangers of Barbecuing: An Interesting Case of a Foreign Body in the Throat**  
*VR Sicari, J Pepe, AC Cardenas, C Zabbo*
- 303 **Extravasation from a Misplaced Intraosseous Catheter**  
*CS Sampson*
- 305 **An Unusual Presentation of Cholecystoduodenal Fistula: Abdominal Pain out of Proportion to Exam**  
*R McCreery, M Meigh*
- 307 **Situs Inversus: Inferior-Lateral ST-Elevation Myocardial Infarction on Right-Sided Electrocardiogram**  
*MS Hamam, H Klausner*

*Clinical Practice and Cases in Emergency Medicine* (CPC-EM) is a open-access Medline-indexed internationally recognized journal affiliated with the *Western Journal of Emergency Medicine* (WestJEM). CPC-EM is distributed electronically to 19,000 emergency medicine scholars. This includes our sponsors California ACEP, the American College of Osteopathic Emergency Physicians, California Chapter of AAEM, and over 83 academic department of emergency medicine subscribers and 8 AAEM State Chapters.

# *Clinical Practice and Cases in Emergency Medicine*

Indexed in PubMed and full text in PubMed Central

In Collaboration with the *Western Journal of Emergency Medicine*

## Table of Contents *continued*

- 310 **Teenage Curiosity: Magnetic Attraction Gone Wrong**  
*M Hysell, SE Harris-Kober*
- 312 **Munson's Sign: An Obvious Finding to Explain Acute Vision Loss**  
*J Gold, V Chauhan, S Rojanasthien, J Fitzgerald*
- 314 **An Unusual Case of Stridor: Severe Tracheal Narrowing Secondary to Esophageal Food Impaction**  
*R McCreery, M Meigh*
- 316 **Computed Tomography Imaging in Aortic Dissection**  
*AH Westfall, JS Garrett*
- 318 **Asteroid Hyalosis Seen on Ocular Point-of-Care Ultrasound**  
*B Arthurs, R Connor-Schuler, W Kreifels, J Suszanski, S Baliga, D Amponsah*

*Clinical Practice and Cases in Emergency Medicine* (CPC-EM) is a open-access Medline-indexed internationally recognized journal affiliated with the *Western Journal of Emergency Medicine* (WestJEM). CPC-EM is distributed electronically to 19,000 emergency medicine scholars. This includes our sponsors California ACEP, the American College of Osteopathic Emergency Physicians, California Chapter of AAEM, and over 83 academic department of emergency medicine subscribers and 8 AAEM State Chapters.

# CPC**EM** Clinical Practice & Cases

## CALL FOR SUBMISSIONS

- Patient Care Case Reports
- Images in Emergency Medicine

Fully open-access, peer reviewed,  
well indexed: CPC-EM is available  
anywhere with an internet  
connection at **CPCEM.org**

***Clinical  
Practice and  
Cases in  
Emergency  
Medicine*** is an  
internationally  
recognized  
journal  
affiliated with  
the MEDLINE-  
indexed  
***Western  
Journal of  
Emergency  
Medicine***

CPC-EM encourages submissions from junior authors and  
countries with developing emergency medicine programs

# CPC**EM** Clinical Practice & Cases

## **CALL FOR CPC-EM SECTION EDITORS!**

- Medical-Legal Case Reports
- Case Reports/Images in  
Emergency Medicine

Send your CV and letter of interest to  
[editor@cpcem.org](mailto:editor@cpcem.org)

**WestJEM** Integrating Emergency Care  
with Population Health

**CPCEM** Clinical  
Practice  
& Cases

# Call for Reviewers!

Please send your CV and letter of interest to  
[editor@westjem.org](mailto:editor@westjem.org)

## SEVENTH WORLD CONGRESS ULTRASOUND IN MEDICAL EDUCATION



**UCI** School of Medicine  
Department of Emergency Medicine  
Irvine, California

SEPTEMBER 12 - 15, 2019

[WWW.WCUME2019.ORG](http://WWW.WCUME2019.ORG)

## 75-year-old Woman with a Fever and Rash

Diane Kuhn, MD, PhD\*

Jonathan Strong, MD†

Laura J. Bontempo, MD, MEd†

Zachary D.W. Dezman, MD, MS, MS†

\*University of Maryland Medical Center, Department of Emergency Medicine, Baltimore, Maryland

†University of Maryland School of Medicine, Department of Emergency Medicine, Baltimore, Maryland

Section Editor: Joel Moll, MD

Submission history: Submitted June 10, 2019; Revision received June 19, 2019; Accepted July 4, 2019

Electronically published July 22, 2019

Full text available through open access at [http://escholarship.org/uc/uciem\\_cpccem](http://escholarship.org/uc/uciem_cpccem)

DOI: 10.5811/cpcem.2019.7.44064

[Clin Pract Cases Emerg Med. 2019;3(3):178-184.]

**CASE PRESENTATION (Resident Presentation)**

A 75-year-old woman with a history of multiple myeloma presents to the emergency department (ED) with her daughter for chief complaints of fevers and a rash. Much of the history was provided by the patient's daughter, her primary caregiver. The patient has had intermittent fevers for three days. The fevers occur once or twice a day, last several hours, with defervescence between episodes. The highest temperature recorded at home was an axillary temperature of 38.6 degrees Celsius (C). The patient developed a rash on her left wrist two days ago, and yesterday her lip became discolored. The patient reports that she has numbness and tingling on both her right and left forearms.

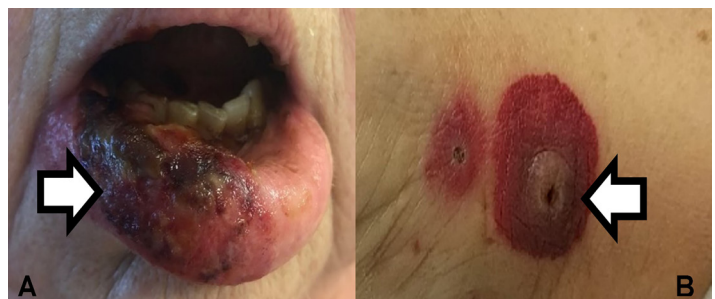The patient was recently hospitalized for pneumonia. She was treated with intravenous (IV) antibiotics, after which the hospital team changed the patient to an oral antibiotic. The daughter believes the name of the oral antibiotic was "something with an ox."

The patient was diagnosed with IgG lambda multiple myeloma in 2004 and treated with an autologous stem cell transplant in 2005. She has had multiple relapses but at the time of presentation was in partial remission. In addition, she has a history of therapy-related myelodysplastic syndrome, diabetes mellitus, hyperlipidemia, and stage III chronic kidney disease. Her home medications are daratumumab, bortezomib, lenalidomide, pomalidomide, dexamethasone, acyclovir, trimethoprim-sulfamethoxazole, azacitidine, glimepiride, insulin, simvastatin, magnesium, calcium carbonate, erythropoietin, and vitamin D. She is allergic to penicillins. She has a 30 pack-year smoking history but quit more than 25 years ago.

Physical examination revealed an overweight (body mass index was 27) white woman sitting up in a stretcher. Her temperature was 38.1°C, her blood pressure was 146/78 millimeters of mercury, her pulse was 86 beats per minute, and she was breathing 22 breaths per minute (bpm) with an oxygenation saturation of 95% on room air. Her head was atraumatic and normocephalic. Her extraocular movements

were intact and her pupils were three millimeters in diameter, round, equal, and reactive to light. Her oral mucosal membranes were moist, with purpura of the lip (Image 1A). Her heart had a normal rate and regular rhythm without audible murmurs, rubs or gallops. She was mildly tachypneic without clear accessory muscle use. Her lungs had diffuse rhonchorous breath sounds bilaterally. She had an implanted vascular access port in her chest wall and the site was without erythema or induration. Her abdomen was soft with normal bowel sounds. She had a few small areas of ecchymoses over the abdomen. All four extremities were warm and well perfused. Her forearms were tender to palpation with some decreased sensation to light touch. She had a well circumscribed purpuric lesion on the left forearm as shown in Image 1B. Neurologically she was oriented to self, place, and time without cranial nerve deficits except decreased sensation in the right V3 region in the area of the purpuric lip lesion.

The patient's initial laboratory results are shown in Table 1. These were significant for severe leukopenia, anemia, and thrombocytopenia consistent with known hematologic malignancy. Her chemistry showed mildly impaired renal function and elevated glucose. Table 2 shows the results of the cultures that were drawn from the patient in the ED. Her



**Images 1A and 1B.** Purpura of the lip (A) and forearm lesion (B) of a woman with fever and rash.

**Table 1.** Initial laboratory results for a 75-year-old woman presenting with fever and rash.

Complete blood cell count		Coagulation profile	
White blood cell count	1.4 K/ $\mu$ L	Prothrombin time	16.7 seconds
Hemoglobin	6.3 g/dL	Partial thromboplastin time	44.0 seconds
Hematocrit	19.10%	International normalized ratio	1.3
Platelets	14 K/ $\mu$ L	Urinalysis	
Serum chemistries		Appearance	Cloudy
Sodium	145 mmol/L	pH	5.0
Potassium	5.4 mmol/L	Ketones	Negative
Chloride	109 mmol/L	Bilirubin	Negative
Bicarbonate	24 mmol/L	Protein	Negative
Blood urea nitrogen (BUN)	91 mg/dL	Nitrite	Negative
Creatinine	2.1 mg/dL	Red blood cells	3-5 cells per high-powered field
Glucose	303 mg/dL	White blood cells	6-10 cells per high-powered field
Calcium	8 mg/dL	Venous blood gas	
Magnesium	2 mg/dL	FiO <sub>2</sub>	21%
Phosphorous	7 mg/dL	Respiratory rate	22 per minute
Total protein	4.7 g/dL	pH	7.39
Albumin	2.4 g/dL	pCO <sub>2</sub>	42 mmHg
Aspartate aminotransferase	63 $\mu$ /L	pO <sub>2</sub>	26 mmHg
Alanine aminotransferase	78 $\mu$ /L	HCO <sub>3</sub>	42 mEq/L
Alkaline phosphatase	206 $\mu$ /L	HbO <sub>2</sub>	43.70%
Total bilirubin	0.5 mg/dL	Base	-0.4 mmol/L

FiO<sub>2</sub>, fraction of inspired air; pH, potential of hydrogen; pCO<sub>2</sub>, partial pressure of carbon dioxide; pO<sub>2</sub>, partial pressure of oxygen; HCO<sub>3</sub>, bicarbonate; HbO<sub>2</sub>, oxyhemoglobin; K/ $\mu$ L, kilos per microliter; mg/dL, milligrams per deciliter; g/dL, grams per deciliter; mEq/L, milliequivalents per liter; mmol/L, millimoles per liter; mmHg, millimeters mercury.

electrocardiogram (ECG) (Image 2) was unchanged from her baseline ECG. Her chest radiograph (CXR) is shown in Image 3. The patient received antipyretics and was started on broad-spectrum antibiotics before being admitted to the hospital for further workup. An additional test revealed the diagnosis.

### CASE DISCUSSION (Attending Discussion)

When presented with a complex case, I find it helpful to succinctly frame the patient presentation: I have a 75-year-old female with a past medical history of multiple myeloma and stem cell transplant, currently on a complex medication regimen including immunomodulators and chemotherapy, who presents with fever, pancytopenia (likely neutropenia), persistent respiratory symptoms despite antibiotics, and a rapidly progressive scattered purpuric and necrotic rash.

My immediate concern after reading this case is neutropenic fever, which is defined by a neutropenic patient experiencing a single oral temperature of  $\geq 38.3^{\circ}\text{C}$  or a temperature of  $\geq 38.0^{\circ}\text{C}$  sustained over a one-hour period.<sup>1</sup> The description of the patient's fever meets these criteria. Neutropenia is defined as an absolute neutrophil count (ANC)  $< 1500$  cells per microliter

( $\mu$ /L).<sup>2</sup> While the white blood cell (WBC) differential is not provided, the total WBC count is 1400 cells/ $\mu$ L, so the patient has at least mild neutropenia. This places the patient at risk for a broad range of infectious organisms including opportunistic bacterial, fungal, and viral infections. Neutropenic patients may not develop symptoms of an infection due to a blunted immune and inflammatory response, leading to atypical presentations of infections. Per the American Society of Clinical Oncology and the Infectious Diseases Society of America guidelines, "in the absence of an alternative explanation, clinicians should assume that fever in a patient with neutropenia from cancer therapy is the result of an infection."<sup>3</sup>

Now that the medical emergency has been addressed, we can examine the rash. Describing a rash using dermatologic terminology helps me narrow the differential diagnosis. This patient has several round, umbilicated purpuric papules and plaques on her left wrist and right forearm with central necrosis that appear in various stages of evolution. The distribution of the lesions is asymmetric and may correspond to where peripheral IV catheters were placed during her recent hospitalization. The patient also has a purpuric and necrotic rash on her right

**Table 2.** Culture results of woman with fever and rash.

Source	Result
Blood #1	No growth
Blood #2	No growth
Urine	No growth
Sputum	No growth

lower lip, with the purpura extending beyond the vermilion border. There appear to be pustules or a honey-colored / white crust present. Note that there is no mention of any lesions involving the oral mucosa. The physical exam describes small areas of ecchymoses on the abdomen. This may be part of the patient's purpuric rash or heparin injections during her recent hospitalization. Now that I've described the rash, I will consider the broad categories of causes: bacterial, fungal, and viral infections, as well as non-infectious etiologies.

Bacterial infections are the most frequent cause of infection in patients with neutropenic fever.<sup>3</sup> More than half are due to gram-positive organisms such as *Staphylococcus* or *Streptococcus* species (especially *Staphylococcus Epidermiditis*).<sup>3</sup> She was recently hospitalized, raising suspicion for hospital-acquired and drug resistant organisms. I suspect the patient was discharged on levofloxacin ("something with an ox"), an antibiotic appropriate for treating community-acquired pneumonia and the empiric treatment of neutropenic fever.<sup>1,3</sup> Purpura fulminans can occur in immunosuppressed patients and is described as petechiae that rapidly progress to purpura and necrotic lesions within hours. *Neisseria meningitidis* or varicella are the most common causes, but pneumococcus, *Staphylococcus*, and streptococci are also implicated. But patients with purpura fulminans are often critically ill, suffering from septic shock and disseminated intravascular coagulation, which does not fit with this patient's presentation.

Our patient's blood cultures did not grow any bacterial pathogens and her symptoms progressed despite antibiotics, so we have to consider fungal infections, especially since they can cause persistent or recurrent fevers. Our patient has a number of risk factors for fungal disease (a central venous catheter, hematologic malignancy, stem cell transplant, diabetes, and glucocorticoid treatment) and she is not on fluconazole prophylaxis.

Disseminated candidiasis can be seen in neutropenic patients after a disruption of the gastrointestinal mucosa (common in chemotherapy) or from central venous catheters. It presents as a scattered, diffuse, maculopapular or pustular rash; rarely the rash may be purpuric. Endophthalmitis may be seen, but lung involvement is rare, making this an atypical case and therefore disseminated candidiasis is unlikely in this patient.

Patients with disseminated aspergillus infections typically present with cough, fever, and hemoptysis. CXR may show single or multiple nodules with or without cavitation, but neutropenic patients may present with segmental consolidation as seen in our patient. Hematologic dissemination can rarely lead to skin lesions that typically manifest as subcutaneous nodules or pustules that evolve into purpuric and necrotic lesions with an ecthyma gangrenosum-like appearance.

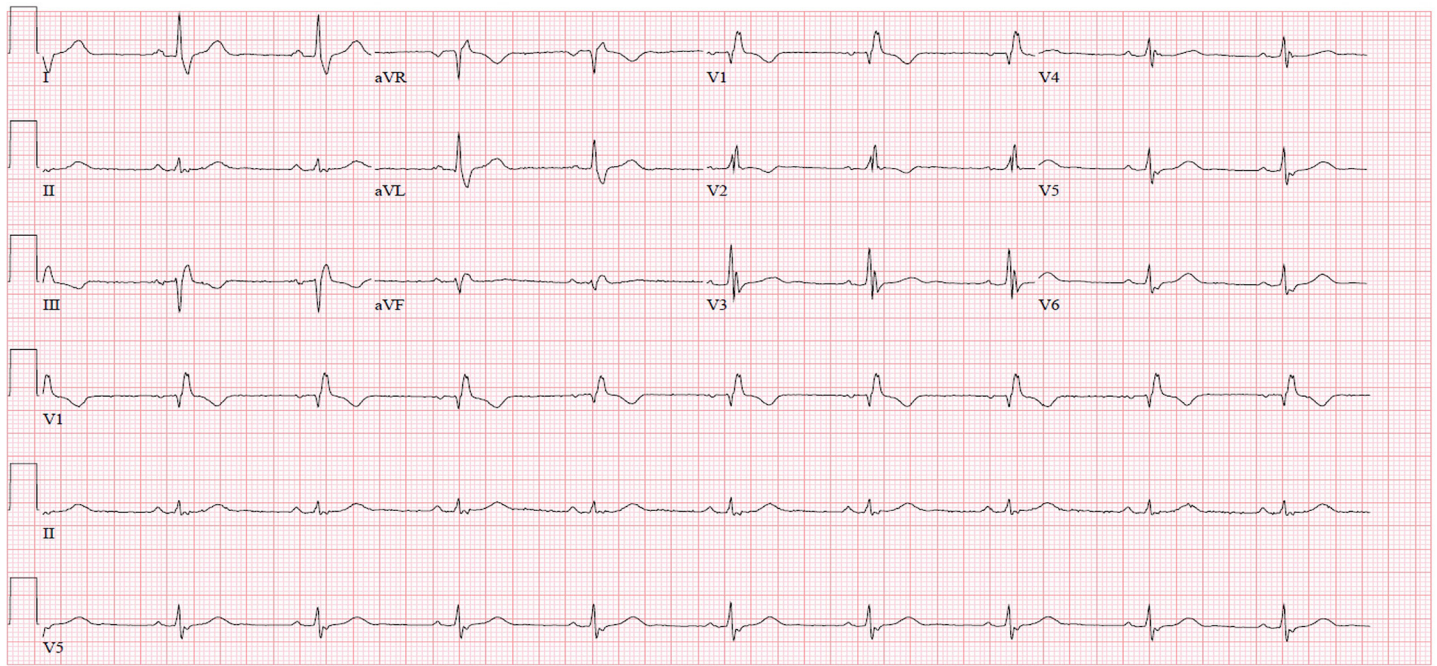
Patients with diabetes and immunosuppression are at risk for mucormycosis. The most common form is rhino-orbital-cerebral mucormycosis, which presents as erythema and swelling in the skin overlying the sinuses or orbits. The patient's skin lesion is located on her lower lip, and she does not appear to have any sinus involvement making mucormycosis less likely. Cutaneous mucormycosis is rarer and is associated with trauma or wounds, appearing as a single painful ecythma-like lesion.

Endemic fungi such as *Histoplasma capsulatum*, *Blastomyces dermatitidis*, and *Coccidioides* spp are also possibilities. However, blastomyces and coccidioides are not endemic to the Mid-Atlantic, and *Histoplasma* is uncommon.<sup>4</sup> The rash of disseminated histoplasmosis is described as diffusely scattered erythematous papules and nodules which may be umbilicated or crusted, inconsistent with this patient's rash.

Reactivation of herpes simplex-1 (HSV-1), herpes simplex-2 (HSV-2), and varicella zoster virus are also important infections to consider in neutropenic patients or those taking medications such as bortezomib.<sup>5</sup> However, the patient's rash is not typical for herpes or zoster and the patient is taking acyclovir for prophylaxis.

Stevens-Johnson syndrome / toxic epidermal necrolysis (SJS/TEN) is a non-infectious cause of rash that presents with fever and muco-cutaneous lesions. The rash typically begins on the face and trunk as coalescing macules with purpuric centers before spreading to the extremities in a symmetric distribution.<sup>6</sup> Over hours to days bullae form, and the skin may begin to slough off. The oral mucosa and vermilion border are almost always involved, with hemorrhagic erosions covered by crusting or a grayish-white membrane. Patients with active malignancy are at increased risk and our patient is on multiple medications that have been implicated in SJS / TEN: lenalidomide, pomalidomide, and trimethoprim-sulfamethoxazole.<sup>7</sup> However, the risk of SJS / TEN is thought to be limited to the first eight weeks of taking a medication. Further, our patient's rash is not symmetric, making SJS / TEN less likely.

Thrombotic thrombocytopenic purpura (TTP) is worth considering. The classic pentad of TTP includes fever, thrombocytopenic purpura, microangiopathic hemolytic anemia, renal dysfunction, and neurologic symptoms. Our patient has fever, thrombocytopenic purpura, anemia, and renal dysfunction. The PLASMIC scoring system can be used to identify patients with severe ADAMS13 deficiency who would benefit from plasma exchange.<sup>8</sup> While the patient has thrombocytopenia,



**Image 2.** Electrocardiogram of febrile cancer patient showing sinus rhythm and known bifascicular block.

her active cancer and her stem-cell transplant history, her low bilirubin, and high creatinine make it unlikely that she has TTP.

Multiple myeloma itself can very rarely present with fever and skin lesions. The skin lesions can occur due to infiltration of plasma cells into the skin (plasmacytomas), deposition of protein (amyloid, cryoglobulins), or secondary to cytopenias (i.e. thrombocytopenia). Plasmacytomas are typically not purpuric or necrotic, and the lesions do not arise over the course of hours to days. Amyloidosis secondary to multiple myeloma can present with purpuric lesions on the face and extremities, classically on the eyelids and periorbital area. The lesions often have a linear or geometric shape occurring due to minor trauma (“pinch purpura”). The patient’s lesions do not have this classic appearance or distribution. Further, the patient is also lacking other features of amyloidosis such as proteinuria and/or restrictive cardiomyopathy.

Cutaneous vasculitis can present with petechiae and purpura. If the vasculitis results in vascular occlusion the lesions can become necrotic and ulcerate. There is a long list of causes for cutaneous vasculitis including drug reactions, infections, malignancy, and rheumatologic causes. One potential cause of cutaneous vasculitis worth considering in this patient is cryoglobulinemia due to multiple myeloma. In cryoglobulinemia, cold causes high circulating levels of immunoglobulins to precipitate resulting in obstruction of distal small blood vessels and rarely an inflammatory vasculitis. Lesions have a predilection for the extremities, particularly acral areas with Raynaud phenomenon and digital ischemia sometimes occurring. Cryoglobulinemia is unlikely in this case given the distribution

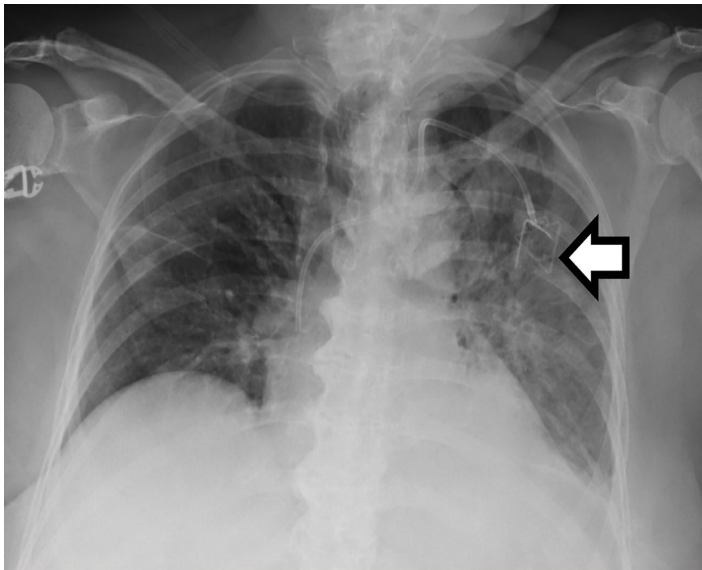
of the lesions, lack of reported cold intolerance, and lack of other organ involvement (i.e., glomerulonephritis).

One more non-infectious entity to consider are the neutrophilic dermatoses (ND) such as Sweet’s syndrome or pyoderma gangrenosum. There is an association between ND and hematologic malignancies, active chemotherapy, and being over the age of 65.<sup>9</sup> In these conditions, inflammatory papules or pustules progress to ulcerations with a necrotic base and a bluish or violaceous margin. As in our case, the rash can present where a patient has had a recent procedure or injury. The diagnosis is made by meeting two minor criteria (recent respiratory illness, fevers, hematologic malignancy, recent vaccination, response to steroids, and elevated erythrocyte sedimentation rate) and two major criteria (classic rash and a biopsy showing neutrophilic infiltrate).<sup>10</sup> While rare, this patient meets one of the major criteria and many of the minor criteria for ND. The one missing criterion is a *diagnostic test*.

If I were the first physician to care for this patient when they presented to the ED, my chief concern would be presumed sepsis in the neutropenic and febrile patient. Once the patient’s medical emergency is managed, I would consider other causes of their fever. In this case, I believe they have a ND, and a skin biopsy would be the diagnostic test of choice.

#### **CASE OUTCOME (Resident Presentation)**

The diagnostic test ordered was a punch biopsy of the skin. The pathology report demonstrated sheets of neutrophils in the upper dermis with less involvement in the deeper dermis, consistent with acute neutrophilic dermatosis



**Image 3.** Chest radiograph of febrile cancer patient with left-sided chemotherapy port in place.

(Sweet's syndrome). The leukemia service recommended starting the patient on one milligram per kilogram (mg/kg) of methylprednisone and the patient quickly defervesced. Steroids were tapered slowly over the following month with the lesions on the lip and upper extremities treated with local wound care. The patient was discharged shortly thereafter.

### RESIDENT DISCUSSION

Sweet's syndrome was first described by Robert Sweet in 1964 as a constellation of symptoms including fever, leukocytosis, and tender erythematous papules and plaques, and a mature neutrophilic infiltrate.<sup>11</sup> Sweet's syndrome has since been linked to hematologic malignancies immune disorders, such as pyoderma gangrenosum, leading researchers to conclude that these diseases might be grouped as "a continuous pathologic spectrum" known as neutrophilic dermatoses ND.<sup>12</sup>

ND are characterized by a cutaneous neutrophilic infiltrate without evidence of infection. Patients with ND may have extracutaneous neutrophilic infiltrates, which will present as systemic diseases such as inflammatory bowel disease and rheumatoid arthritis. Traditionally, ND have transitional and overlap forms, or manifestations that either progress from one ND to another or represent an intersection of more than one ND.<sup>12</sup>

Sweet's syndrome can be broken into classical, malignancy-associated, and drug-induced. Classical Sweet represents approximately half of all cases, typically affecting women 30-50 years old. The disease has no clear geographical or ethnic predisposition. The classical form most commonly involves the upper extremities and it may be preceded by a gastrointestinal or respiratory infection.

Fifteen to twenty percent of Sweet's syndrome cases are associated with a malignancy, most commonly hematologic cancer.<sup>13</sup> Acute myelogenous leukemia is the most common cancer, followed by myeloproliferative diseases such as that of our patient. Sweet's syndrome can occur before, during, or after a malignancy, though the development of Sweet's syndrome while in remission may signal disease recurrence.<sup>1</sup>

Drug-induced Sweet's syndrome has been associated with immunomodulating drugs (granulocyte macrophage colony stimulating factor, filgrastim and lenograstim, ipilimumab, bortezomib, and azathioprine,) and chemotherapy agents.<sup>14</sup> Surprisingly, azathioprine has been identified as both a possible cause and treatment for Sweet's syndrome. Antibiotics (trimethoprim-sulfamethoxazole and minocycline), and anti-hypertensives (hydralazine) have been shown to induce Sweet's syndrome. Our patient was taking three of these medications.

The pathophysiology of Sweet's syndrome is uncertain. Marzano et al. (2014) performed protein arrays of patients with both pyoderma gangrenosum and Sweet syndrome, noting an increase in pro-inflammatory cytokines interleukin-1 $\beta$ , interleukin-6, and interleukin-8, and tumor necrosis factor- $\alpha$ .<sup>15</sup> Increased levels of granulocyte-colony stimulating factor have also been associated with both acute myelogenous leukemia and Sweet's syndrome.<sup>16</sup> Recent research has found mutations in the isocitrate dehydrogenase protein, which activates oncogenes and inactivates tumor suppressor genes, in individuals with myelodysplastic syndrome and Sweet's syndrome.<sup>17</sup>

The major criteria for classical or malignancy-associated Sweet's syndrome include 1) an abrupt onset of painful erythematous plaques or nodules, and 2) histology of skin lesions showing a neutrophilic infiltrate in the absence of infection or vasculitis.<sup>18</sup> Minor criteria include 1) fever greater than 38°C, 2) an association with malignancy, inflammatory or infectious disease, or vaccination, and 3) elevation of inflammatory markers such as erythrocyte sedimentation rate (ESR), C-reactive protein (CRP), white cell count or percentage of neutrophils. Patients with underlying hematologic malignancies may present with neutropenia rather than neutrophilia. Both major criteria and two out of four minor criteria are required for diagnosis. The diagnostic criteria of drug-induced Sweet's syndrome also requires a temporal relationship between the offending agent and the course of symptoms.<sup>19</sup> In the case presented, our patient met diagnostic clinical criteria and had features that were consistent with all three forms of Sweet's syndrome.

The clinical course of Sweet's syndrome is highly variable, with fever being the most common presenting symptom. Intermittent fevers may occur for days to weeks prior to development of cutaneous findings. Symmetric lesions on the upper extremities or head and neck are the most common cutaneous features. Although the cutaneous eruptions may begin as papules or nodules, they can enlarge and form into irregular plaques. It is not unusual for these lesions to occur in areas of cutaneous trauma, such as

venipuncture sites. Patients often have hyperalgesia in the areas of skin findings, which resolves over the course of days to weeks with treatment.

Unfortunately, even characteristic clinical and historical disease features are inadequate to rule out other possible etiologies of fever, particularly in cancer patients who are immunocompromised. Malignancy-associated Sweet's syndrome presents a unique diagnostic challenge as it is most commonly associated with hematologic cancers. Although the cyclic or intermittent fevers and dermatologic findings may be a diagnostic clue, a high level of suspicion must be maintained for other sources of fever. Thus, these patients should undergo a standard fever workup, including urinalysis, blood cultures, and CXR. In addition to complete blood count and chemistries of renal and liver function, inflammatory markers such as CRP and ESR may help to differentiate between sources of fever. Empiric antibiotic treatment while awaiting cultures is important in patients who present with febrile neutropenia of uncertain etiology. It is important to consider early involvement of dermatology for a skin biopsy in patients who have intermittent fevers and characteristic dermatologic findings.

First-line treatment of Sweet's syndrome is 0.5-1.0 mg/kg continued for four to six weeks of systemic glucocorticoids.<sup>20</sup> Symptoms generally improve or resolve within the first one to two weeks. Local corticosteroids may be used in cases of few lesions with no systemic symptoms. Potassium iodide has some efficacy and can be given as a 300 mg tablet three times daily or a solution dosed at 1000 mg/day. In the case of drug-induced Sweet's syndrome, the offending agent should also be discontinued. There are literature reports of malignancy-associated Sweet's syndrome resolving with treatment of the cancer.<sup>19,20</sup> Similarly, an unknown malignancy must be considered when a diagnosis of Sweet's syndrome is made.<sup>20</sup>

Since the episode, the patient has not had a recurrence of Sweet's syndrome, although she has had progression of her multiple myeloma and myelodysplastic syndrome with poor prognosis.

## FINAL DIAGNOSIS

Sweet syndrome secondary to multiple myeloma and myelodysplastic syndrome.

## KEY TEACHING POINTS

- Consider non-infectious causes of fever in immunocompromised patients, particularly patients with known malignancies.
- Sweet's syndrome should be considered in patients with a rash and fever, especially when there is associated malignancy, inflammatory or infectious disease, or vaccination.

- Chemotherapy patients are often on complicated regimens of medications with numerous and clinically relevant side effects; maintain a high degree of suspicion for the role of immunomodulators in disease processes.
- If an apparently healthy patient without recent medication changes or viral illness is diagnosed with Sweet's syndrome, that patient should undergo a workup for underlying malignancy.
- Assume that neutropenic patients presenting with fever are septic and resuscitate them aggressively, even though they may appear clinically to be well.

Documented patient informed consent and/or Institutional Review Board approval has been obtained and filed for publication of this case report.

---

*Address for Correspondence:* Laura Bontempo, MD, MEd, University of Maryland, Department of Emergency Medicine, 110 S. Poca Street, 6th Floor, Suite 200, Baltimore, MD 21201. Email: [Lbontempo@som.umaryland.edu](mailto:Lbontempo@som.umaryland.edu).

*Conflicts of Interest:* By the *CPC-EM* article submission agreement, all authors are required to disclose all affiliations, funding sources and financial or management relationships that could be perceived as potential sources of bias. The authors disclosed none.

*Copyright:* © 2019 Kuhn et al. This is an open access article distributed in accordance with the terms of the Creative Commons Attribution ([CC BY 4.0](http://creativecommons.org/licenses/by/4.0/)) License. See: <http://creativecommons.org/licenses/by/4.0/>

---

## REFERENCES

1. Freifeld AG, Bow EJ, Sepkowitz KA, et.al. Clinical practice guideline for the use of antimicrobial agents in neutropenic patients with cancer: 2010 update by the Infectious Diseases Society of America. *Clin Infect Dis*. 2011;52(4):427-31.
2. Boxer LA. How to approach neutropenia. *Hematology Am Soc Hematol Educ Program*. 2012;2012:174-82.
3. Mikulska M, Viscoli C, Orasch C, et al. Aetiology and resistance in bacteraemias among adult and paediatric haematology and cancer patients. *J Infect*. 2014;68(4):321-31.
4. Baddley JW, Winthrop KL, Patkar NM, et.al. Geographic distribution of endemic fungal infections among older persons, United States. *Emerg Infect Dis*. 2011;17(9):1664-9.

5. Roujeau JC, Guillaume JC, Fabre JP, et al. Toxic epidermal necrolysis (Lyell syndrome): Incidence and drug etiology in France, 1981-1985. *Arch Dermatol*. 1990;126(1):37-42.
6. Chanan-Khan A, Sonneveld P, Schuster MW, et al. Analysis of herpes zoster events among bortezomib-treated patients in the phase III APEX study. *J Clin Oncol*. 2008;26(29):4784-90.
7. Gravante G, Delogu D, Marianetti M, et al. Toxic epidermal necrolysis and Stevens-Johnson syndrome in oncologic patients. *Euro Rev Med Pharmacol Sci*. 2007;11(4):269-74.
8. Bendapudi PK, Hurwitz S, Fry A, et al. Derivation and external validation of the PLASMIC score for rapid assessment of adults with thrombotic microangiopathies: a cohort study. *Lancet Haematol*. 2017;4(4):e157-64.
9. Walker DC and Cohen PR. Trimethoprim-sulfamethoxazole-associated acute febrile neutrophilic dermatosis: case report and review of drug-induced Sweet's syndrome. *J Am Acad Dermatol*. 1996;34(5 Pt 2):918-23.
10. Cohen PR. Sweet's syndrome—a comprehensive review of an acute febrile neutrophilic dermatosis. *Orphanet J Rare Dis*. 2007;2(1):34.
11. Reuss-Borst MA, Pawelec G, Saal JG, et al. Sweet's syndrome associated with myelodysplasia: possible role of cytokines in the pathogenesis of the disease. *Br J Haematol*. 1993;84(2):356-8.
12. Wallach D and Vignon-Pennamen MD. From acute febrile neutrophilic dermatosis to neutrophilic disease: forty years of clinical research. *J Am Acad Dermatol*. 2006;55(6):1066-71.
13. Cohen PR and Kurzrock R. Sweet's syndrome. *Am J Clin Dermatol*. 2002;3(2):117-31.
14. Villarreal-Villarreal CD, Ocampo-Candiani J, Villarreal-Martínez A. Sweet syndrome: a review and update. *Actas Dermosifiliogr*. 2016;107(5):369-78.
15. Marzano AV, Fanoni D, Antiga E, et al. Expression of cytokines, chemokines and other effector molecules in two prototypic autoinflammatory skin diseases, pyoderma gangrenosum and Sweet's syndrome. *Clin Exp Immunol*. 2014;178(1):48-56.
16. Loraas A, Waage A, Lamvik J. Cytokine response pattern in Sweet's syndrome associated with myelodysplasia. *Br J Haematol*. 1994;87(3):669.
17. Im AP, Sehgal AR, Carroll MP, et al. DNMT3A and IDH mutations in acute myeloid leukemia and other myeloid malignancies: associations with prognosis and potential treatment strategies. *Leukemia*. 2014;28(9):1774-83.
18. von den Driesch P. Sweet's syndrome (acute febrile neutrophilic dermatosis). *J Amer Acad Derm*. 1994;31(4):535-56.
19. Rochet NM, Chavan RN, Cappel MA, et al. Sweet syndrome: clinical presentation, associations, and response to treatment in 77 patients. *J Am Acad Dermatol*. 2013;69(4):557-64.
20. O'Connor Reina C, Garcia Iriarte MD, Rodriguez Diaz A, et al. Tonsil cancer and Sweet's syndrome. *Otolaryngol Head Neck Surg*. 1998;119(6):709-10.

## Beware of the Zebra: Nine-year-old with Fever

**Kathryn Lupez, MD**  
**Bryant Allen, MD**  
**Sean Fox, MD**  
**Margaret Lewis, MD**

Carolinas Medical Center, Department of Emergency Medicine, Charlotte, North Carolina

Section Editor: Joel Moll, MD

Submission history: Submitted December 31, 2018; Revision received April 29, 2019; Accepted May 16, 2019

Electronically published July 1, 2019

Full text available through open access at [http://escholarship.org/uc/uciem\\_cpem](http://escholarship.org/uc/uciem_cpem)

DOI: 10.5811/cpcem.2019.5.42119

An otherwise healthy nine-year-old female who spoke only French presented with abdominal pain, vomiting, intermittent fevers, fatigue, and headache. She then quickly became febrile and altered requiring intubation. When treating a healthy child, the physician may initially develop a differential that includes common illnesses. Yet, as emergency medicine providers, we must be thinking about the “zebras” in order to not miss potentially deadly, curable diseases. [Clin Pract Cases Emerg Med. 2019;3(3):185-190.]

### CASE PRESENTATION

A nine-year-old female arrived to the emergency department (ED) with her parents who described a chief complaint for their daughter of “fever and vomiting.” They elaborated on the case and described that the patient had been experiencing diffuse abdominal pain, vomiting, intermittent subjective fevers, and decreased energy, with development of a mild headache earlier that day. She had normal bowel movements, no hematemesis, no bilious emesis, and no known sick contacts. Review of systems was negative for rash, ear pain, cough, chest pain, dysuria, and extremity pain. The patient had no past medical or surgical history, and she was current on her vaccinations. She was not on any daily medications and had no allergies to medications. Of note, the patient and her family members spoke only French and an interpreter was used throughout the examination.

Physical exam revealed an overall ill-appearing child. The vital signs were as follows: temperature of 98.5° Fahrenheit (F), heart rate of 140 beats per minute (bpm), blood pressure of 97/54 millimeters of mercury (mmHg), respiratory rate of 22 breaths per minute (BPM), and SPO<sub>2</sub> of 100% on room air. In general, she was sleepy but arousable. She had dry mucous membranes. Her tympanic membranes were clear bilaterally. She had normal S1 and S2 heart sounds with no murmurs, rubs, or gallops. Her lungs were clear to auscultation bilaterally. Her abdomen was soft yet tender to palpation in all quadrants with noted splenomegaly.

She was moving all four extremities equally. There was no rash noted on exam. Initial workup included a complete blood count, venous blood gas, complete metabolic panel, and urinalysis as documented in Table 1.

On re-examination, the patient had become completely unresponsive. Repeat vital signs revealed the following: a temperature of 102.5° F, heart rate of 160 bpm, blood pressure of 75/40 mm hg, respiratory rate of 30 BPM, and SPO<sub>2</sub> of 92% on room air. She was subsequently resuscitated with an intravenous (IV) fluid bolus. We obtained central access and initiated vasopressors. The patient was then intubated for airway protection given her severely altered mental status.

A head computed tomography (CT) was obtained (Image). The radiologist read it as “No acute intracranial findings.” An abdominal and pelvic CT was obtained (Image), which the radiologist read as “Mild splenomegaly for age. Small volume ascites. No other acute intra-abdominal processes.” We performed a lumbar puncture and obtained a cerebral spinal fluid (CSF) sample as documented in Table 2. A confirmatory test was then sent from the ED and a diagnosis was made.

### Faculty Approach

This case describes an otherwise healthy nine-year-old female who presented to the pediatric ED with subjective fevers and abdominal pain for approximately one week. When treating a healthy child without significant medical history, one may initially apply the common adage “when hearing hoofbeats think horses” and develop a differential that

**Table 1.** Laboratory evaluation of child presenting with fever, abdominal pain, and vomiting.

Comprehensive metabolic panel	
Sodium	128 mmol/L
Potassium	3.7 mmol/L
Chloride	97 mmol/L
Bicarbonate	11 mmol/L
Glucose	75 mg/dL
Blood urine nitrogen	51 mg/dL
Creatine	1.4 mg/dL
Aspartate aminotransferase	34 IU/L
Alanine aminotransferase	130 IU/L
Complete blood count	
White blood cells	1.2 Thousand/uL
Hemoglobin	3.7 g/dL
Platelets	95 Thousand/uL
Venous blood gas	
pH	7.1
Partial pressure carbon dioxide	29 mm Hg
Lactate	13.9 mmol/L
Urinalysis	
Leukocyte Esterase	Negative
Nitrates	Negative
White blood cells	0

mmol, millimole; L, liter; mg, milligram; dL, deciliter; IU, international unit; uL, microliter; mmHg, millimeters of mercury.

includes common illnesses such as urinary tract infection or pyelonephritis, appendicitis or ruptured appendicitis, infectious gastroenteritis, flu-like illness or viral infection not otherwise specified, or even streptococcal pharyngitis. Fever and abdominal pain are extremely common complaints in the ED.

However, our patient had had no specific symptoms of dysuria or flank pain to suggest a urinary tract infection. Nor did she have sore throat or exudates to support strep pharyngitis. Also, the patient had normal bowel movements. Although an infectious gastroenteritis with dehydration was certainly possible, it was less likely given the presentation. Appendicitis was not supported by the timeline or physical exam. Ruptured appendicitis was considered given the duration of symptoms and diffuse abdominal pain; however, the CT abdomen and pelvis revealed splenomegaly and ascites, but no signs of ruptured appendicitis.

Further history and a thorough physical exam became critical. Further history indicated that in addition to a one-week time course the patient had begun to develop headaches. The physical exam was significant in that she was noted to be ill-appearing and sleepy, with an abdominal exam that was

### CPC-EM Capsule

What do we already know about this clinical entity?

*Malaria is known as one of the deadliest diseases in human history and still today, there are over 200 million cases and over 500,000 deaths annually, predominately in children.<sup>7</sup>*

What makes this presentation of disease reportable?

*General illness and fever are common “hoof beats” heard in the pediatric emergency department yet as we become more interconnected than ever before, we need to “beware of the zebras”.*

What is the major learning point?

*There are three general phases of malaria including the incubation phase, “uncomplicated” malaria phase, and the “complicated” malaria phase.*

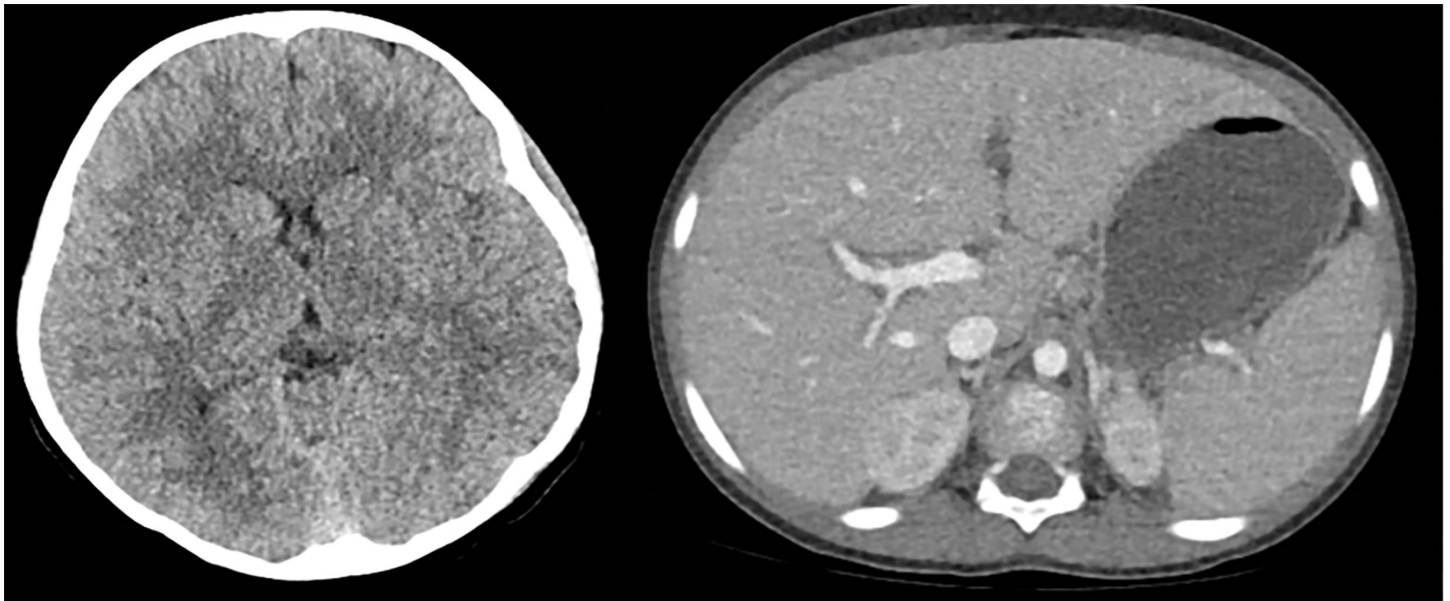
How might this improve emergency medicine practice?

*Review of the presentation of severe malaria is crucial in aiding emergency medicine providers in identifying an uncommon yet treatable deadly disease.*

diffusely tender but not peritoneal and with splenomegaly present. Because fevers, headaches, and abdominal pain are all vague and common complaints, one must keep a broad differential and consider a rather expansive workup. In addition, the patient appeared to be falling off the proverbial cliff and becoming more critically ill in the ED.

Common causes of fever and abdominal pain need to be evaluated as well as fever and headache. Fever itself can lead to headaches, but fever and headache in an ill-appearing child should make one consider possible tick-borne illness depending on location and time of year, meningitis, encephalitis, and even possibly intracranial abscess. Despite the fully immunized status of the patient, this presentation would warrant neurologic imaging and a lumbar puncture.

A comprehensive metabolic panel and complete blood count along with urinalysis and venous blood gas were initially ordered given the initially stated complaint of abdominal pain, vomiting and fever. Normal urinalysis



**Image.** Computed tomography of the head (left) and abdomen and pelvis (right).

effectively ruled out urologic etiology of her symptoms. However, the remainder of the labs were remarkable for hyponatremia, increasing blood urine nitrogen and creatinine, pH of 7.1 with a remarkably elevated lactate, and pancytopenia with white blood count of 1.2, hemoglobin of 7.7, and platelets of 95.

As a patient rapidly declines in the ED, the astute physician will continue to listen to hoofbeats and think horses; at the same time, he or she must now pause and consider zebras, as well as prioritize resuscitative measures. Our patient was intubated, had central access established, and underwent head and abdominal CT imaging (Image). Abdominal CT imaging noted splenomegaly and small ascites, but no definitive causes of the patient's symptoms. Normal head CT served to eliminate intracranial abscess, but meningitis and encephalitis were still potential causes and a lumbar puncture was performed. CSF was notable for clear fluid, slightly elevated opening pressure, high glucose, normal protein, and lymphocyte predominance. The white cells in the CSF were elevated at 17 per microliter but not reflective of a bacterial infection. The white cells, lymphocyte predominance, elevated glucose, and normal protein in the CSF analysis did not reflect a bacterial cause of the patient's symptoms (Table 2).

Following appropriate resuscitation and attempted stabilization, it was critical to reflect back to the presenting symptom, physical exam findings, and known laboratory values. The patient presented with abdominal pain and splenomegaly, fevers and headaches, became acutely and severely ill, and had pancytopenia as well a profound elevation in lactate.

Sepsis, leukemia, and megaloblastic anemia all can cause a pancytopenia. Sepsis was certainly high on the differential

given that the patient had fevers and became severely ill requiring the use of vasopressors. The patient herself never had any cough or shortness of breath to suggest pneumonia as cause of sepsis, nor any urologic complaints and had a normal pulmonary exam, no costovertebral angle tenderness, and a normal urinalysis. She also had a lumbar puncture performed with results that did not reflect bacterial meningitis. Other causes of sepsis, cholecystitis and bacteremia were less likely given that the patient was fully immunized and had no prior medical problems and no indwelling IV lines.

Acute cholecystitis in the pediatric population is rare. Risk factors for acute acalculous cholecystitis (more common in children) include trauma, burns, surgery, and severe systemic infection,<sup>1</sup> of which this patient had none. Leukemia was also certainly on the differential as well in this patient with pancytopenia, unexplained fevers, and splenomegaly. She also had fatigue, which certainly fit the presentation of acute leukemia. Childhood leukemia is one of the most common childhood malignancies, and the patient had many signs and symptoms that supported this diagnosis – fevers, fatigue, splenomegaly, and pancytopenia. However, other symptoms that would have supported a diagnosis of acute leukemia – shoddy lymphadenopathy, easy bruising, recurrent infections, limb pain, and weight loss – were not present in this case.<sup>2</sup> The patient's mother gave no history of recurrent infections, bruising, anorexia, or any other vague symptoms prior to onset of illness; the patient was healthy and well. With megaloblastic anemia, one would expect a more chronic picture of fatigue, pallor, shortness of breath, and light-headedness, none of which correlated with the patient presentation.

**Table 2.** Cerebral spinal fluid findings.

Cerebral spinal fluid	
Opening pressure	31cm H <sub>2</sub> O
Color	Clear
Protein	57 mg/dL
Red blood cells	1 count/mm <sup>3</sup>
White blood cells	15 count/mm <sup>3</sup>
Monocytes	25%
Lymphocytes	75%
Blasts	0%
No Xanthochromia	

cm, centimeter; H<sub>2</sub>O, water; mg, milligram; dL, deciliter; mm, millimeter.

Other causes of pancytopenia include immunosuppressive medications, meningitis, and familial causes. The patient had no history of receiving any immunosuppressive medications, no known family history, and the CSF results did not clearly support meningitis.

Pancytopenia can also be caused by a variety of other viral infections and even parasitic infections. A clear history of present illness and thorough physical exam should help include or exclude different infections. Viral causes may include parvovirus, human herpes virus 8, cytomegalovirus and Epstein-Barr virus. Common symptoms will include fevers, fatigue, headache, and throat pain. Although several of these symptoms corresponded to the patient's symptoms, they did not offer a perfect fit. Finally, one must also consider systemic parasitic infections as the cause of the patient's pancytopenia, and a clear history of potential exposures is critical.

As the patient and family spoke only French, all history was obtained through an interpreter. Although the French language is typically associated with France (and Bordeaux, brie, la Cote D'Azur, Paris, and Notre Dame), there are 29 countries in the world that identify as francophone, or French-speaking. France is the largest francophone country in terms of native speakers, followed by Canada. Interestingly, approximately half of the global French-speaking population lives in Africa, in countries including Congo, Cote d'Ivoire, Madagascar, Cameroon, Senegal, Burkina Faso, Mali, and Niger.<sup>3</sup>

Pancytopenia has a broad and potentially very serious differential including sepsis, acute leukemia, megaloblastic anemia, drug-induced, meningitis, viral, and parasitic causes. The patient herself was an otherwise healthy, French-speaking, young female with fever, abdominal pain and headaches now with an acute and severe deterioration in clinical condition with pancytopenia and a significant elevation in lactate.

Which diseases become "horses," or common diseases, as opposed to "zebras," or rare diseases, is relative to where the patient resides or travels. So, what if the "zebra" in this case were really a French-speaking horse from Africa? It would explain the patient's vague symptoms and severe disease progression. We needed one final laboratory test to make this diagnosis.

## FINAL DIAGNOSIS

As the patient continued to decompensate in the ED, the providers knew further investigation was necessary to help save this child's life given the lack of a definitive diagnosis. Due to concern for incomplete communication, despite use of a French interpreter, further history was gathered on re-examination. It was revealed that the patient and her family were from the Congo and had just arrived in the United States a few weeks earlier. The Centers for Disease Control and Prevention (CDC) malaria guidelines note that an estimated 216 million cases of malaria occurred in 2016 globally, with most cases in sub-Saharan Africa. Malaria itself can present with vague symptoms including fevers, abdominal pain, and fevers, and may progress to severe disease and even death if caused by *Plasmodium falciparum*.<sup>4</sup>

The conglomeration of symptoms including her fever, vomiting, altered mental status, splenomegaly, pancytopenia, multiple organ failure, and increased intracranial pressure led the providers to send one confirmatory test to make their diagnosis. This test was a peripheral blood smear, specifically a thick and thin smear, which revealed *P. falciparum* leading to a final diagnosis of cerebral malaria. From the ED, we contacted the 24-hour CDC hotline,<sup>5</sup> which helped allocate the appropriate anti-malarial medication. The patient was started on a quinine drip and admitted to the pediatric intensive care unit. Remarkably, within four weeks she made a full recovery and returned home with her family.

## Beware of the Zebra

Many of us were taught the common aphorism in medical school: "when you hear hoofbeats, think horses not zebras." When approaching a nine-year-old with fever, we hear these hoofbeat symptoms and tend to think of the typical diagnoses that are commonly seen in our pediatric population. Yet if we are not thinking about the zebras, we will miss this common presentation of a disease that is uncommon north of the equator, which could lead to high morbidity and possibly even mortality for patients

Malaria is known as one of the deadliest diseases in human history with speculations that it has contributed to the death of over half of all people who have ever lived.<sup>6</sup> Still today, there are over 200 million cases and over 500,000 deaths annually, predominantly in children.<sup>7</sup> Endemic regions of tropical and subtropical climates form a ring around our globe that is commonly referred to as the "malaria belt."<sup>8</sup> While most of our

EDs are not located within this “malaria belt,” we have to be prepared. We are more interconnected than we have ever been with thousands of people traveling all over the world every day. Last year alone, our world tourism data was the highest yet with an annual traveler increase of 7%.<sup>9</sup> Malaria, one of the deadliest diseases in human history, will inevitably be arriving soon to an ED near you.

Although there are many different *Plasmodium* species, each with its own nuances, there are three overarching phases that can help us understand the presentation of a patient with malaria.<sup>10</sup> Phase 1 is the incubation phase. This is the time from disease exposure to symptom onset. This typically occurs when one is located in a geographical area at risk; surrounding female *Anopheles* mosquitos can flood malarial sporozoites throughout the blood stream with just one bite. From the time of the bite forward, one can be completely asymptomatic for any time between 7-30 days depending on the *Plasmodium* species.<sup>10</sup> This long incubation period is dangerous given that our patients do not often think to tell us what they were doing a week ago, much less a month ago. We must beware of the zebra and collect a detailed travel history to make this “can’t miss” diagnosis in our patients.

Phase 2 is the “uncomplicated” malaria phase. The sporozoites mature in the liver to schizonts, which then mature to merozoites that readily infect red blood cells. Merozoites rapidly reproduce within the red blood cell until they rupture the red blood cell open, releasing even more merozoites to start the cycle all over again. Each time the merozoites rupture a red blood cell, an intense inflammatory reaction occurs including fever, chills, diffuse muscle aches, lethargy, gastrointestinal upset, and headaches.<sup>10</sup> The reproduction and rupture of the red blood cell is typically cyclical in nature with the length between the reaction varying widely between each *Plasmodium* species. This may lead to a cyclical presentation of clinical symptoms. Yet because patients rarely follow textbook presentation, this can lead to a diagnostic dilemma, particularly in the months of December and January when these inflammatory symptoms can mimic common viral syndromes such as influenza. Yet we must remember to keep our differential broad and beware of the zebra.

Phase 3 is the “complicated” malaria phase. This occurs when the merozoites have replicated to the point of infiltrating just about every organ system. Merozoites can invade the central nervous system, leading to altered mental status, seizures, and extremely high intracranial pressures, also known as cerebral malaria. It can lead to liver failure and renal failure. Although rare, it can lead to a secondary hemophagocytic lymphohistiocytosis presenting as complete pancytopenia as seen in our patient.<sup>11</sup> Systemically, it can present with profound hypotension, fever, and hypoglycemia. If you heard the hoofbeats of these systemic symptoms on any typical day in the ED, you would probably call this sepsis. The hoofbeats of fever with altered mental status may be mistaken as meningitis. The intra-abdominal organ failure might be pinned as some intra-abdominal

catastrophe, or the pancytopenia as a new-onset malignancy, but beware of the zebra. If you weren’t thinking of this zebra, the complicated malaria phase has close to a 100% mortality without treatment.<sup>12</sup>

Thinking of zebras may afford clinicians the ability to pick up on some of the important clues and spur them to order that one crucial diagnostic test the peripheral blood smear. The thick peripheral blood smear will identify the parasitemia load and the thin smear will identify the *Plasmodium* species.<sup>13</sup> Once a diagnosis is made, the 24-hour CDC malaria<sup>5</sup> hotline should be contacted to ensure proper management as well as to expedite any appropriate antimalarials.

Remember that the world we live in is more interconnected than it has ever been. Malaria, one of the deadliest diseases in human history, is coming to your ED, perhaps as soon as your next shift. When you hear those hoofbeats, beware of the zebra.

Documented patient informed consent and/or Institutional Review Board approval has been obtained and filed for publication of this case report.

---

*Address for Correspondence:* Bryant Allen, MD, Carolinas Medical Center, Department of Emergency Medicine, 1000 Blythe Blvd, Charlotte, NC 28203. Email: Bryant.allen@atriumhealth.org.

*Conflicts of Interest:* By the CPC-EM article submission agreement, all authors are required to disclose all affiliations, funding sources and financial or management relationships that could be perceived as potential sources of bias. The authors disclosed none.

*Copyright:* © 2019 Lupez et al. This is an open access article distributed in accordance with the terms of the Creative Commons Attribution (CC BY 4.0) License. See: <http://creativecommons.org/licenses/by/4.0/>

---

## REFERENCES

1. Poddighe D, Tresoldi M, Licari A, et al. Acalculous acute cholecystitis in previously healthy children: general overview and analysis of pediatric infectious cases. *Int J Hepatol.* 2015;2015:459608.
2. Clarke RT, Van den Bruel A, Bankhead C, et al. Clinical presentation of childhood leukaemia: a systematic review and meta-analysis. *Arch Dis Child.* 2016;101(10):894-901.
3. Lingoda. French speaking countries. 2019. Available at: <https://www.lingoda.com/en/french-speaking-countries>. Accessed

- December 22, 2018.
4. Centers for Disease Control and Prevention. Parasites - malaria. Available at: <https://www.cdc.gov/parasites/malaria/index.html>. Accessed December 22, 2018.
  5. Centers for Disease Control and Prevention. Malaria - diagnosis and treatment (United States). 2018. Available at: [https://www.cdc.gov/malaria/diagnosis\\_treatment/index.html](https://www.cdc.gov/malaria/diagnosis_treatment/index.html). Accessed December 19, 2018.
  6. Whitfield J. Portrait of a serial killer. *Nature*. 2002. [In Press].
  7. World Health Organization. World Malaria Report. 2018. Available at: [https://www.who.int/malaria/publications/world\\_malaria\\_report/en/](https://www.who.int/malaria/publications/world_malaria_report/en/). Accessed December 19, 2018.
  8. Centers for Disease Control and Prevention. Where malaria occurs. 2017. Available at: <https://www.cdc.gov/malaria/about/distribution.html>. Accessed December 19, 2018.
  9. World Tourism Organization. 2017 international tourism results: the highest in seven years. 2018. Available at: <http://media.unwto.org/press-release/2018-01-15/2017-international-tourism-results-highest-seven-years>. Accessed December 20, 2018.
  10. Crutcher JM, Hoffman SL. Malaria. 1996. Available at: <http://www.ncbi.nlm.nih.gov/pubmed/21413352>. Accessed December 19, 2018.
  11. Muthu V, Dhooia S, Sehgal IS, et al. Malaria-associated secondary haemophagocytic lymphohistiocytosis: report of two cases & a review of literature. *Indian J Med Res*. 2017;145(3):399-404.
  12. Kyriacou DN, Spira AM, Talan DA, et al. Emergency department presentation and misdiagnosis of imported falciparum malaria. *Ann Emerg Med*. 1996;27(6):696-9.
  13. Trampuz A, Jereb M, Muzlovic I, et al. Clinical review: severe malaria. *Crit Care*. 2003;7(4):315-23.

# Your Automated Implantable Cardioverter Defibrillator Is Not a Bulletproof Vest but It Might Save Your Life

Tzliil Perahia, MD\*

David S. Kleinman, MD†

Wassim G. Habre, MD‡

\*Crozer Chester Medical Center, Department of Emergency Medicine, Upland, Pennsylvania

†Crozer Chester Medical Center, Department of Cardiology, Upland, Pennsylvania

‡Crozer Chester Medical Center, Department of Acute Care Surgery, Upland, Pennsylvania

Section Editor: Rick A. McPheeters, DO

Submission history: Submitted December 25, 2019; Revision received April 4, 2019; Accepted April 22, 2019

Electronically published July 1, 2019

Full text available through open access at [http://escholarship.org/uc/uciem\\_cpccem](http://escholarship.org/uc/uciem_cpccem)

DOI: 10.5811/cpcem.2019.4.42086

A 43-year-old male was brought to the emergency department as the highest level trauma activation with complaints of chest and arm pain after sustaining gunshot wounds (GSW). Initial workup was notable for superficial GSWs to the left chest and upper extremity with direct impact to the patient's automated implantable cardioverter defibrillator. The patient underwent replacement of the device without rewiring and was discharged home without complications. [Clin Pract Cases Emerg Med. 2019;3(3):191-193.]

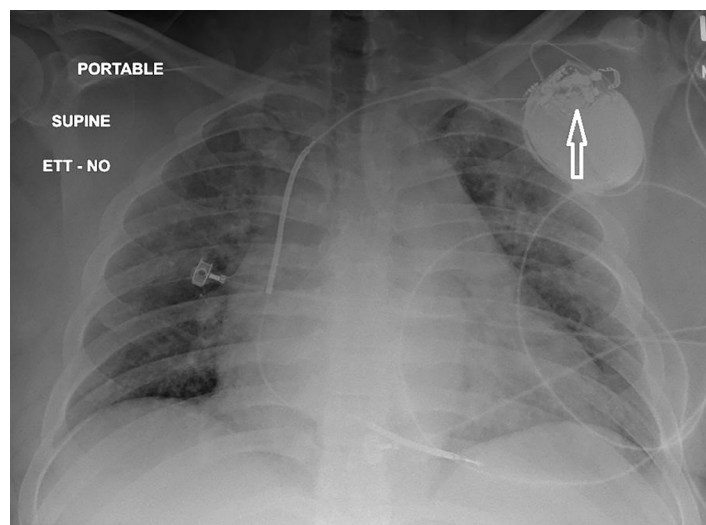
## INTRODUCTION

Automated implantable cardioverter defibrillator (AICD) placement is indicated in a variety of cardiac disease processes ranging from non-ischemic cardiomyopathy with reduced ejection fraction (EF) to recurrent ventricular arrhythmias, with a primary objective of reducing the risk of sudden cardiac death.<sup>1</sup> A typical AICD is primarily composed of a header, containing the control circuitry, a power source, and the leads, which transmit an electrical impulse to the heart. The power source is commonly encased in a titanium alloy shell.<sup>2</sup> On rare occasions an AICD has been reported to have altered a bullet's trajectory and saved a patient's life.<sup>3</sup>

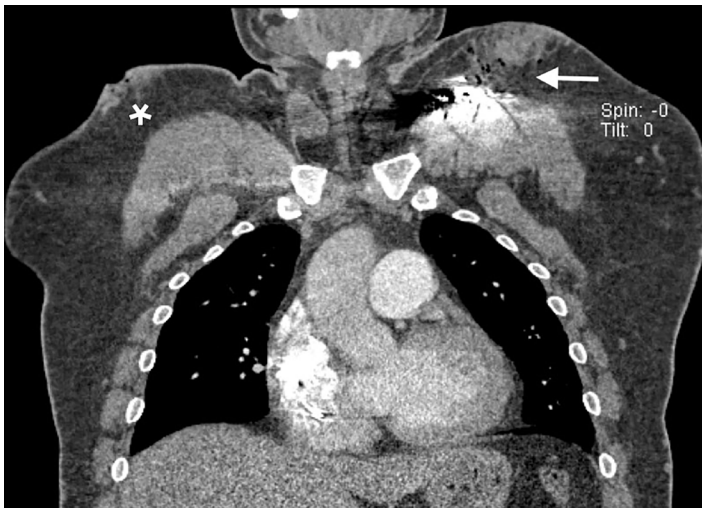
## CASE REPORT

A 43-year-old male was brought by emergency medical services to the emergency department (ED) as a prehospital trauma activation, having sustained multiple gunshot wounds (GSW) to the torso and right upper extremity. One of the GSWs was located overlying the patient's AICD, which had been placed several years previously. The patient had additional GSWs, seemingly in a linear trajectory, across bilateral pectoralis muscles and right bicep. His past medical history was notable for dilated cardiomyopathy with EF less than 35%, paroxysmal atrial fibrillation, hypertension, diabetes mellitus, and history of pulmonary embolism currently on rivaroxaban. The trauma evaluation was negative for intrathoracic injury, and the patient was admitted for pain control and AICD

interrogation. The initial chest radiograph demonstrated a grossly intact AICD. However, upon closer inspection the damaged circuitry of the header was visualized (Image 1). A representative slice of his chest computed tomography shows the damaged AICD with surrounding subcutaneous air, as well



**Image 1.** Anterior posterior chest radiograph showing cardiomegaly and damaged header of the automated implantable cardioverter defibrillator (arrow).



**Image 2.** Representative computed tomography slice showing damaged automated implantable cardioverter defibrillator with surrounding subcutaneous air (arrow) as well as an additional gunshot wound to the right thorax (star).



**Image 3.** Explanted automated implantable cardioverter defibrillator showing damage to the pulse generator (arrow) and separation of the header.

as an additional soft tissue deformity demonstrating an additional GSW (Image 2).

The patient's AICD was unable to be interrogated given the extent of the damage. During the operative exchange the header was found to be completely separated from the pulse generator, which had sustained direct damage from the bullet (Image 3). The leads remained intact. After an antibiotic rinse, the right ventricular coil and superior vena cava coil were reconnected and successfully tested with the new pulse

### *CPC-EM Capsule*

What do we already know about this clinical entity?

*There has been only one reported case of Automated Implantable cardioverter defibrillator (AICD) absorbing the impact of a gun shot wound (GSW) and preventing fatal injury.*

What makes this presentation of disease reportable?

*This case represents a rare complication of a common injury pathway, given increasing incidence of AICD implantations.*

What is the major learning point?

*Penetrating injuries to patients with AICD's merit pacer interrogation during initial resuscitation to reduce risk of arrhythmia during periods of increased physiologic stress.*

How might this improve emergency medicine practice?

*This case raises awareness of a rare complication from GSW to the chest in patients with AICD and should hasten AICD interrogation in this select group of patients.*

generator. The patient recovered and was discharged to home with cardiology follow-up.

### **DISCUSSION**

From 2006-2012 over 300,000 patients underwent implantation of devices used to treat life-threatening cardiac conditions.<sup>4</sup> The primary purpose of these devices is to administer an electrical impulse to the cardiac tissue with the goal of restoring a normal perfusing rhythm. These ICD devices have many modes of failure; however, the leads that conduct the electrical impulse are the most vulnerable component of the system.<sup>5</sup> In the case described, the pulse generator and header suffered damage from the projectile impact while the leads remained unharmed. The failure of the AICD placed the patient at increased risk of developing a fatal arrhythmia given the increased cardiac stress from his chest wall trauma and the patient's innate risk from his dilated cardiomyopathy. Thankfully the patient did not decompensate or require any defibrillation/cardioversion during his hospitalization. His AICD was replaced without requiring rewiring of the leads, and he was discharged to home with cardiology follow-up.

## CONCLUSION

This case describes the second reported incidence of an AICD successfully deflecting a bullet in a patient presenting for multiple GSWs as well as successful pulse generator replacement without rewiring of the leads. Given the increasing implantation rates of cardioverter defibrillator devices, this case also demonstrates the importance of incorporating device interrogation early on in patients sustaining penetrating chest wall trauma.

Documented patient informed consent and/or Institutional Review Board approval has been obtained and filed for publication of this case report.

## REFERENCES

1. Russo AM, Stainback RF, Bailey SR, et al. ACCF/HRS/AHA/ASE/HFSA/SCAI/SCCT/SCMR 2013 appropriate use criteria for implantable cardioverter-defibrillators and cardiac resynchronization therapy: a report of the American College of Cardiology Foundation appropriate use criteria task force, Heart Rhythm Society, American Heart Association, American Society of Echocardiography, Heart Failure Society of America, Society for Cardiovascular Angiography and Interventions, Society of Cardiovascular Computed Tomography, and Society for Cardiovascular Magnetic Resonance. *J Am Coll Cardiol*. 2013;61(12):1318-68.
2. van Welsenes GH, Borleffs CJ, van Rees JB, et al. Improvements in 25 years of implantable cardioverter defibrillator therapy. *Neth Heart J*. 2011;19(1):24-30.
3. Sheppard RC, Levine JC, Rovin J, et al. A novel way an implantable cardioverter-defibrillator prevents death: protection from a gunshot. *Heart Rhythm*. 2009;6(9):1390.
4. Lindvall C, Chatterjee NA, Chang Y, et al. National trends in the use of cardiac resynchronization therapy with or without implantable cardioverter-defibrillator. *Circulation*. 2016;133(3):273-81.
5. Swerdlow CD, Kalahasty G, Ellenbogen KA. Implantable cardiac defibrillator lead failure and management. *J Am Coll Cardiol*. 2016;67(11):1358-68.

*Address for Correspondence:* Tzlil Perahia, MD, Crozer Chester Medical Center, Department of Emergency Medicine, 1 Medical Center Blvd, Upland, PA 19013. Email: [tzlil.perahia@crozer.org](mailto:tzlil.perahia@crozer.org).

*Conflicts of Interest:* By the CPC-EM article submission agreement, all authors are required to disclose all affiliations, funding sources and financial or management relationships that could be perceived as potential sources of bias. The authors disclosed none.

*Copyright:* © 2019 Perahia et al. This is an open access article distributed in accordance with the terms of the Creative Commons Attribution (CC BY 4.0) License. See: <http://creativecommons.org/licenses/by/4.0/>

# To tPA or Not to tPA: Two Medical-Legal Misadventures of Diagnosing a Cerebrovascular Accident as a Stroke Mimic

Malia J. Moore, MD\*  
Jonathan Stuart, DO, MS†  
Alexandra Humphreys, Esq.‡  
James A. Pfaff, MD§

\*Carl R. Darnall Army Medical Center, Department of Emergency Medicine, Fort Hood, Texas  
†Madigan Army Medical Center, Department of Emergency Medicine, Tacoma, Washington  
‡Wharton Aldhizer & Weaver, Harrisonburg, Virginia  
§San Antonio Military Medical Center, Department of Emergency Medicine, San Antonio, Texas

Section Editor: Rick A. McPheeters, DO

Submission History: Submitted January 5, 2019; Revision Received April 3, 2019; Accepted April 22, 2019

Electronically published July 8, 2019

Full text available through open access at [http://escholarship.org/uc/uciem\\_cpem](http://escholarship.org/uc/uciem_cpem)

DOI: 10.5811/cpem.2019.4.42186

We present two recent successfully litigated malpractice cases in which patients with cerebrovascular accidents were misdiagnosed as stroke mimics. The first was diagnosed as a hemiplegic migraine, which occurs in only 0.01% of the population. The second was diagnosed as a conversion disorder, which ultimately has a neurologic etiology in 4% of cases. In both cases, issues of poor patient communication and poor documentation were paramount in the legal outcome. We discuss caveats of stroke mimics, tissue plasminogen activator administration liability, and pitfalls in patient and family interactions. [Clin Pract Cases Emerg Med. 2019;3(3):194-198.]

## CASE REPORT

### *Case 1: Estate of Smith versus Baca, Turner, and Augusta Emergency Physicians – Virginia<sup>1</sup>*

A 40-year-old female was visiting her family when she had sudden onset of severe headache, with associated slurred speech, right-sided weakness, dizziness, nausea and vomiting. Her mother called emergency medical services (EMS) within five minutes and told the dispatcher she was concerned her daughter was having a stroke. EMS arrived at the home 40 minutes later, and the patient arrived at the hospital two hours and twenty minutes after onset of her symptoms. Transport was lengthy because the patient lived in a remote location. Although EMS initially considered flying her from the scene, they were forced to use ground transport due to poor weather; however, the paramedic on scene stated she complained only of headache and right-sided tingling. He performed a Cincinnati Prehospital Stroke Scale nine times during transfer, all of which were documented as normal.

On emergency department (ED) arrival, the patient was accepted from EMS by a nurse and the supervising emergency physician (EP), and was evaluated shortly afterward. Prochlorperazine, diphenhydramine, and

dexamethasone were ordered to treat the patient's headache, and a non-contrast computed tomography (CT) of the head was obtained. The EP diagnosed the patient with a complex migraine headache. It was documented but later disputed that her headache improved; however, while in the ED her symptoms changed. Her paresthesia moved to the left side, and five hours and ten minutes after onset of symptoms, a neurologist was consulted by phone and recommended magnetic resonance imaging (MRI), with a plan to see the patient in the hospital the next day. The MRI revealed an ischemic cerebrovascular accident (CVA). The patient died of complications three days later.

The plaintiff alleged that the EP should have initiated a stroke alert and consulted a neurologist immediately on arrival due to the patient's history of symptoms at home, which could have been consistent with CVA. The hospital is a primary stroke center and had a tele-neurologist available. It was asserted that if the CVA had been identified and tissue plasminogen activator (tPA) administered within the accepted 4.5-hour window, Ms. Smith would have survived. The plaintiff also claimed that failure to identify and treat CVA was a departure from standard of care. Another EP who

participated briefly the next morning and the neurologist were dropped from the case, as they were only involved after the tPA window had expired.

Furthermore, the family of the decedent asserted that they were concerned for stroke and requested multiple times that the patient be evaluated for stroke. Her mother was quoted in testimony as saying, “I want [the EP] to give her ‘that shot’” during the patient’s ED stay.

The EP and his defense team asserted that the decedent had a normal neurologic exam, with the exception of headache and arm tingling, which is not consistent with CVA. Her neurologic symptoms resolved rapidly and were associated with headache, which is consistent with the diagnosis of complex migraine. Furthermore, they alleged that even if CVA were thought to be the cause, the decedent would not have qualified for treatment with tPA based on accepted inclusion criteria. In fact, the experts testified that tPA is a potentially dangerous drug that has no scientific evidence of decreasing mortality; however, at least one jury member stated that the discussion of several, well-publicized tPA studies by the defense had the opposite intended effect, leading the juror to conclude that tPA would have helped the patient.

A major feature of the trial was discussion of the EP’s documentation. Several points were examined. A review of systems was documented, but the EP was unable to recall at trial which questions he would have included. A National Institutes of Health Stroke Scale (NIHSS) was never documented, despite the hospital being a primary stroke center. The physician documented only that the patient had “normal movement and coordination,” but the family disputed that he had ever examined the patient. Similarly, when the patient’s symptoms changed, the EP documented “normal strength and sensation,” however, the family stated there was also slurred speech, which was neither confirmed nor denied by the EP’s chart.

Most importantly, the initial chart presented in discovery for the trial was later found to have been altered by the EP once he learned the patient’s MRI results. The chart in question was an electronic medical record, in which the EP later overwrote his original chart to include the differential of CVA and state why he thought the presentation was more likely consistent with complex migraine. He did not address the potential use of tPA in either chart. He did not annotate that this was a change to the record being entered after the fact, when he had more information.

The family specifically testified that they felt the EP was dismissive, did not examine or care about the patient, and did not discuss options with them.

The jury returned a \$3.5 million verdict for the plaintiff, which is currently under appeal.

#### *Case 2: Anonymous versus Anonymous – Kentucky*

In a recently settled Kentucky case, a 43-year-old woman was celebrating on Christmas Eve with her family. There was

#### *CPC-EM Capsule*

What do we already know about this clinical entity?

*Conversion disorder and hemiplegic migraine are diagnoses of exclusion after cerebrovascular accident has been ruled out.*

What is the major learning point?

*Tissue plasminogen activator (tPA) malpractice cases more often arise from not using it for stroke mimics, rather than complications from using it. Documenting is key.*

How might this improve emergency medicine practice?

*Litigation is less likely when there has been full consideration of diagnoses, and discussion with patients and families of the risks and benefits of administering tPA.*

no family discord or stress. She was witnessed to suddenly fall to the ground. The family noted that at approximately 9:30 PM she could not speak and was unable to use her right arm. They brought her immediately to the ED. Upon arrival, she was evaluated by the EP at 10 PM. A CT of the brain was performed and read by the radiologist as normal at 10:48 PM. Nursing notes commented on the patient’s “unwillingness” to communicate and also that she moved her extremities when the family was not present. The EP failed to document a neurologic exam on the chart. The family repeatedly implored the EP to be concerned about the patient’s condition. The family testified that the EP stated, “Your daughter is having a nervous breakdown because of how you raised her.” The patient was admitted to the hospital with a diagnosis of conversion disorder. No neurologist was consulted, and administration of tPA was not considered. The next morning, the patient was seen by the admitting physician, who suspected that she had suffered a CVA. A repeat CT revealed a large, left middle cerebral artery infarct. The patient was immediately transferred to a tertiary care facility but unfortunately was left with dense motor and speech deficits. She was unable to return to work and the burden of her care led to divorce. The case was settled for an undisclosed sum.<sup>2</sup>

#### **DISCUSSION**

Dr. Moore: The time-sensitive administration of tPA is a “hot button” issue for many EPs. Controversy exists over the efficacy of the treatment, while providing treatment may

directly cause acute decompensation and poor outcomes. Furthermore, several well-known societies support the use of tPA, including the American Heart Association and American Stroke Association, which have deemed its administration “definitely recommended.”<sup>3</sup> Subsequently, several societies including the American Academy of Emergency Medicine have decried this claim.<sup>4</sup> This leaves EPs in a position of fearing complications and medicolegal litigation whether from action or inaction.

In one retrospective cohort of 61,698 patients with acute ischemic stroke who presented within two hours of symptom onset, 25% of eligible patients failed to receive tPA treatment.<sup>5</sup> The reason for this finding is likely multifactorial and thought to be a combination of patient factors such as dementia or other underlying comorbid disorders, hospital factors such as ability to quickly rule out hemorrhagic stroke and initiate therapy with tPA, and lastly EP decision-making. “By far the most common reason cited, reported in more than half of the patients, was mild or rapidly improving symptoms. Among patients without a documented reason for not receiving tPA, mild stroke symptoms, defined as a NIHSS score less than five, were strongly associated with a lower likelihood of being treated. Prior studies have found that this is the most common reason given for not treating otherwise eligible patients with intravenous (IV) tPA, yet multiple cohorts have found that up to one-third of patients with mild stroke symptoms at presentation will have poor long-term outcomes.”<sup>5</sup>

It can be easily extrapolated that EPs fear causing harm to a patient with mild symptoms; however, the risks associated with tPA are primarily applicable to patients who have already had an insult to brain tissue. In a study reviewing the effects of tPA in stroke mimics, 14% of their 521 patient cohort were ultimately diagnosed as stroke mimics after receiving tPA within three hours of symptom onset. None of these patients experienced intracranial hemorrhage. The most common stroke mimics were seizure, complex migraine, and conversion disorder.<sup>6</sup>

In addition to causing harm to a patient, EPs dread the outcome of litigation. In one study reviewing verdicts involving tPA, 33 cases were reviewed. The majority (N21; 63.6%) decided in favor of the defendant providers. Of the remaining, nine (27.3%) resulted in plaintiff verdicts, two (6.1%) resulted in settlements, and one (3.0%) was an arbitration favorable to the plaintiff. Compensation for plaintiffs ranged from \$100,000 to \$30 million. The most common claim plaintiffs made was a failure of the treating physician to provide tPA (N29; 87.9%), with only three cases (9.1%) in which patients sued the providers and claimed that the use of tPA caused their injury. In general, plaintiffs also claimed failure or delay in stroke diagnosis (N22; 66.7%). Based on this review, it appears that most successful litigation resulted from EP delay in stroke diagnosis and/or failure to administer tPA.<sup>7</sup>

A subsequent review confirmed these findings, where out of 40 applicable cases with available verdicts, the most frequent plaintiff claim was related to failure to administer IV tPA (38, 95%), and only two (5.0%) claims involved complications of treatment with tPA.<sup>8</sup>

As with many studies reviewing medicolegal verdicts, juries typically find in favor of the defendant physician, and this trend is also demonstrated with regard to tPA verdicts. Yet it appears that the number of cases is increasing. During the five years after tPA was approved by the United States Food and Drug Administration (1996 to 2001), there were only five cases, whereas from years six to ten (2002 to 2007), 28 cases were reported.<sup>7</sup>

Another issue that becomes critical in regard to administration of tPA is informed consent. A possible explanation for the preponderance of plaintiffs’ success with “failure to treat” cases is that most often when patients receive tPA they have also given informed consent, whereas when tPA was withheld, patients have often not received the same guidance and opportunity to choose. In these cases, either the stroke was not identified, or the physician unilaterally chose for other reasons (contraindications, patient comorbidities, personal concerns about efficacy) not to administer tPA. In other words, informed consent is critical, and in cases where tPA was not given, the physician was more likely not to have obtained or documented informed consent regarding the decision.

“Regardless of one’s personal view regarding the efficacy and safety of tPA, it is essential to discuss and document with patient and family (surrogate) all treatment options. Maintaining legible, detailed and timely documentation as to time of onset, examination findings and informed consent why patients should or should not receive tPA should substantially reduce the threat of legal action.”<sup>9</sup>

Despite the medical concerns involved in the case, lessons apparent for EPs are to listen to the patient and his or her family, validate and discuss their concerns, ensure they are provided informed consent and that they understand the major decision points in the patient’s care. Subsequently, all care should be documented completely and accurately. Occasionally, the situation may occur where the EP knows more at the time of charting than he or she did at the time of the patient’s care, and it is the opinion of the authors that this is best approached with transparency. For example, a statement such as, “I am adding to the chart and am at this point aware the patient had X outcome. I want to record additional thoughts, exam, and findings performed and considered, but not fully documented at the time of care,” may be an appropriate introduction.

Dr. Stuart: Conversion disorder is characterized by neurologic symptoms causing distress but inconsistent with a specific medical or neurologic disease process. The diagnosis requires the following: altered motor or sensory function;

clinical findings demonstrating incompatibility between the symptom and recognized neurological and medical conditions; an explanation for the symptom that is not better explained by another medical or mental disorder; and, finally, the condition must cause clinically significant distress or impairment.<sup>10</sup> There is no requirement to identify psychological factors associated with the symptoms.

A 2005 review of 27 studies found 4% of patients diagnosed were subsequently found to have a neurologic disorder.<sup>11</sup> More recent studies demonstrate a lower incidence of misdiagnosis. Nonetheless, a diagnosis of conversion disorder introduces etiologic assumptions that often cannot be proven and should be made with extreme caution, if at all, in the ED.<sup>12</sup> Patients may also be frightened by the effects of neurologic symptoms and exaggerate symptoms to convince a physician of their problem, creating a presentation suggestive of a conversion disorder. Patients with conversion disorder may also have an underlying neurologic disease similar to patients with psychogenic, non-epileptic seizures also having a concurrent seizure disorder in some cases.

Hemiplegic migraine describes a migraine headache accompanied by motor weakness during the aura phase. Motor weakness never occurs in isolation and is often accompanied by other forms of aura leading to impairment.<sup>13</sup> Most patients with hemiplegic migraine have headaches of varying severity and some will have more severe attacks accompanied by encephalopathy or coma.<sup>14</sup> It is a rare disorder with clinically indistinguishable familial and sporadic forms, which together occur in only 0.01% of the population.<sup>15</sup> Motor and sensory findings more often involve the upper extremities, and upper motor findings such as a Babinski sign or unilateral hyper-reflexia may be present during attacks.<sup>16</sup>

Attacks typically last hours followed by normalization of the neurologic exam, but some patients with familial forms may also have cerebellar findings between attacks.<sup>14</sup> The diagnosis is clinical, and the occurrence of episodic, reversible motor weakness as a manifestation of migraine aura in conjunction with at least one other kind of aura is required. This diagnosis of a rare disease with features indistinguishable on acute presentation from a CVA is further complicated because up to 27% of stroke patients have headache at onset.<sup>17</sup>

Several additional stroke mimics exist and comprise 5-30% of patients initially diagnosed with stroke in the ED.<sup>18,19</sup> Ictal and post-ictal deficits are the most common mimic (13-20%) followed by toxic and metabolic disorders (18%, primarily hypoglycemia), syncope (8-15%), and sepsis (10%).<sup>19</sup> Vertigo and nystagmus, although common neurologic symptoms encountered in the ED, are caused by a stroke 3-10% of the time. Numerous additional stroke mimics exist with varying frequencies including, but not limited to, encephalopathies, mitochondrial disorders, multiple sclerosis, intracranial hemorrhage, reversible constriction syndromes, and transient global amnesia.<sup>20</sup>

Dr. Pfaff: Multiple studies have defined reasons that patients will initiate a malpractice action. One survey of 227 patients who were initiating claims for medical malpractice noted the actions were not only for the injury but also because of poor communication and insensitive handling. Only 15% of explanations were deemed satisfactory. The four main reasons given for litigation were the following: 1) Concerns about competence and prevention of other patients being harmed; 2) to obtain an understanding and explanation of what happened; 3) to obtain compensation to handle further medical care and permanent injury; and 4) to hold parties accountable for their actions.<sup>21</sup> Another representative study linked the relationship of patient satisfaction to the likelihood of litigation. It reported on 353 physicians who had patient satisfaction surveys and ranked them into thirds. The middle third had a 26% higher chance of a malpractice action, while the lowest third had 110% higher risk.<sup>22</sup>

The importance of documentation can't be emphasized enough in order to prevent and defend a malpractice action. Prosecuting attorneys use charting deficiencies to show carelessness, sloppiness, and dishonesty. Physicians should realize they themselves have the ability to control and create the evidence and facts with proper documentation.<sup>23</sup>

In a recent illustrative case of CVA in Louisiana, in which a physician was accused of failing to give tPA, the jury stated it did not feel tPA was indicated. The physician claimed he discussed the issue with the patient's wife, but there was no discussion documented on the chart. The jury in an interview later stated the \$300,000 award was solely based on the lack of documentation of informed decision-making.<sup>24</sup>

Humphreys JD: The axiom "if it's not charted, it's not done" rings especially true in medical malpractice litigation, where the patient's medical records are often the only way for a physician to prove that a patient's treatment was carried out properly. A physician's failure to document the completion of certain tests or assessments can serve as persuasive evidence in showing the physician failed to perform a complete workup. Additionally, a physician's alteration of records can also help a plaintiff's case, especially if the changes were made after the physician learned or should have learned of an adverse patient outcome, by suggesting the physician's acknowledgment of an earlier medical error. These general truisms came into play in both of these cases.

## CONCLUSION

When facing the possibility of a neurologic emergency in the ED, serious and debilitating possibilities should be considered, and rare conditions as well as those that can't be confirmed with certainty should be less emphasized. It is imperative to both make a timely diagnosis and provide treatment for patients with a CVA. Physicians must also effectively communicate concerns and options to patients and their families (with documentation) to minimize subsequent litigation.

Documented patient informed consent and/or Institutional Review Board approval has been obtained and filed for publication of this case report.

*Address for Correspondence:* Malia J. Moore, MD, Carl R. Darnall Army Medical Center, Department of Emergency Medicine, 36065 Santa Fe Drive, Fort Hood, TX 76544. Email: majmoore@gmail.com.

*Conflicts of Interest:* By the CPC-EM article submission agreement, all authors are required to disclose all affiliations, funding sources and financial or management relationships that could be perceived as potential sources of bias. The views expressed here are those of the authors and do not reflect the official policy of the Department of the Army, the Department of Defense, or the U.S. Government.

*Copyright:* © 2019 Moore et al. This is an open access article distributed in accordance with the terms of the Creative Commons Attribution (CC BY 4.0) License. See: <http://creativecommons.org/licenses/by/4.0/>

## REFERENCES

- Estate of Smith v. Baca, Turner, and Augusta Emergency Physicians. Augusta County (VA) Circuit Court No. CL-17894-002.
- Anonymous v Anonymous. Commonwealth of Kentucky Grayson Circuit Court Civil Action No. 07-CI-00343.
- Guidelines 2000 for Cardiopulmonary Resuscitation and Emergency Cardiovascular Care. Part 7: the era of reperfusion: section 2: acute stroke. The American Heart Association in collaboration with the International Liaison Committee on Resuscitation. American Heart Association with collaboration with the International Liaison Committee on Resuscitation. *Circulation*. 2000;102(8 suppl):1204-16.
- AAEM work group on Thrombolytic Therapy in Stroke. Position statement of the American Academy of Emergency Medicine on the use of intravenous therapy in the treatment of stroke. Available at: [www.aaem.org/positionstatements/thrombolytictherapy.html](http://www.aaem.org/positionstatements/thrombolytictherapy.html). Accessed June 29, 2018.
- Messé SR, Khatri P, Reeves MJ, et al. Why are acute ischemic stroke patients not receiving IV tPA? Results from a national registry. *Neurology*. 2016;87(15):1565-74.
- Chernyshev OY, Martin-Schild S, Albright KC, et al. Safety of tPA in stroke mimics and neuroimaging-negative cerebral ischemia. *Neurology*. 2010;74(17):1340-5.
- Liang BA and Zivin JA. Empirical characteristics of litigation involving tissue plasminogen activator and Ischemic Stroke. *Ann Emerg Med*, 2008;5(2):160-4.
- Bhatt A, Safdar A, Chaudhari D, et al., Medicolegal considerations with intravenous tissue plasminogen activator in stroke: a systematic review. *Stroke Res Treat*. 2013;2013:562564.
- Weintraub MI. Thrombolysis (tissue plasminogen activator) in stroke: a medicolegal quagmire." *Stroke*. 2006;37(7):1917-22.
- American Psychiatric Association. (2013). Diagnostic and Statistical Manual of Mental Disorders. Washington, D.C.: American Psychiatric Association.
- Yutzy SH, Parish BS (2008). "Somatoform disorders." *The American Psychiatric Publishing Textbook of Psychiatry* (pg. 609). Washington, D.C.: American Psychiatric Publishing.
- Stone J, Smyth R, Carson A, et al. Systematic review of misdiagnosis of conversion symptoms and "hysteria". *BMJ*. 2005;331(7523):989.
- Thomsen LL and Olesen J. Sporadic hemiplegic migraine. *Cephalalgia*, 2004;24(12):1016-23.
- Russell MB and Ducros A. Sporadic and familial hemiplegic migraine: pathophysiological mechanisms, clinical characteristics, diagnosis, and management. *Lancet Neurol*. 2011;10(5):457-70.
- Lykke TL, Kirchmann EM, Faerch RS, et al. An epidemiological survey of hemiplegic migraine. *Cephalalgia*. 2002;22(5):361-75.
- Thomsen LL, Eriksen MK, Roemer SF, et al. A population-based study of familial hemiplegic migraine suggests revised diagnostic criteria. *Brain*. 2002;125(Pt 6):1379-91.
- Tentschert S, Wimmer R, Greisenegger S, et al. Transient ischemic attacks: mimics and chameleons. *Stroke*. 2005;36:e1.
- Onder H. Todd's paralysis: a crucial entity masquerading stroke in the emergency department. *J Emerg Med*. 2017;52(4):e153-5.
- Valle J, Lopera E, Guillian M, et al. Stroke mimics: a challenge for the emergency physician. *An Sist Sanit Navar*. 2014;37(1):117-28.
- Kerber K, Brown D, Lisabeth L, et al. Stroke among patients with dizziness, vertigo, and imbalance in the emergency department. *Stroke*. 2006;37(10):2484-7.
- Vincent C, Young M, Phillips A. Why do people sue doctors? A study of patients and relatives taking legal action. *Lancet*. 1994;343(8913):1609-13.
- Stelfox HT, Gandhi TK, Oray EJ et al. The relation of patient satisfaction with complaints against physicians and malpractice lawsuits. *Am J Med*. 2005;118(10):1126-33.
- American Medical News. Medical charting errors can drive patient liability suits. 2013. Available at: <https://amednews.com/article/20130325/profession/130329979/5/>. Accessed June 29, 2018.
- Coulon v. Creel. Jefferson (LA) Parish Court Case No. 664-42.

# Symptomatic Pericardial Cyst: An Atypical Case of Pleuritic Chest Pain

T. Douglas Sallade, DO  
Chadd K. Kraus, DO, DrPH, MPH  
Lisa Hoffman, DO

Geisinger Medical Center, Department of Emergency Medicine, Danville, Pennsylvania

Section Editor: Rick A. McPheeters, DO

Submission history: Submitted January 31, 2019; Revision received April 19, 2019; Accepted May 16, 2019

Electronically published July 1, 2019

Full text available through open access at [http://escholarship.org/uc/uciem\\_cpem](http://escholarship.org/uc/uciem_cpem)

DOI: 10.5811/cpcem.2019.5.42601

Pericardial cysts were first described in 1837 as diverticula extending from the pericardium. They are rare and frequently asymptomatic. Symptomatic presentations may be similar to more common causes of chest pain or dyspnea such as acute coronary syndrome or pulmonary embolism. Emergency physicians should consider mediastinal mass, and in this case pericardial cyst, in the differential diagnosis of chest pain because of the risk for tamponade, sudden cardiac death, or other life-threatening complications. Here, we describe a novel presentation of a pericardial cyst presenting as atypical chest pain. [Clin Pract Cases Emerg Med. 2019;3(3):199-201.]

---

## INTRODUCTION

Pericardial cysts were first described in 1837 as diverticula extending from the pericardium.<sup>1</sup> They are usually asymptomatic and are incidentally found on chest radiograph (CXR) as a well-circumscribed opacity over the right heart border.<sup>2</sup> One large study using CXRs suggested a prevalence of pericardial cysts as one in 100,000 people.<sup>3</sup> We describe a case of a pericardial cyst causing pleuritic chest pain in a patient presenting to an emergency department (ED).

## CASE REPORT

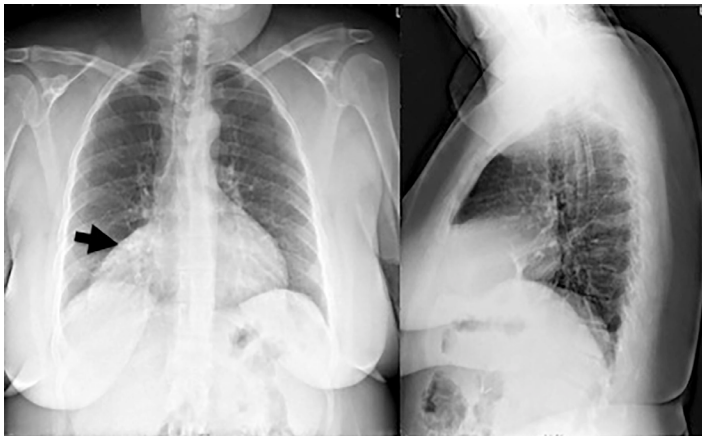A 43-year-old female presented to the ED of an academic medical center for sudden onset chest pain. The pain was severe and pleuritic, radiating over her anterior chest and through to her shoulder blades. The pain worsened when lying flat, making her dyspneic. Associated symptoms included irregular, pounding heartbeats and occasionally a “whooshing” sensation in her chest. Review of systems was otherwise negative.

For approximately six months prior to ED presentation, she had presented to several urgent care centers for respiratory symptoms including “not getting air” and cough. Her symptoms were attributed to bronchitis or asthma and treated with azithromycin and prednisone with variable relief. Her past medical history included asthma, gastroesophageal reflux, and migraine headaches.

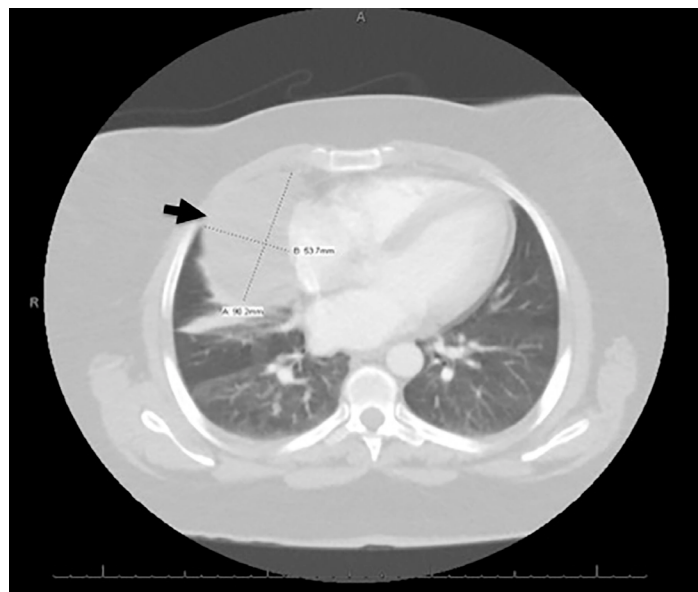
On arrival to the ED, vital signs included a blood pressure of 142/77 millimeters of mercury, heart rate of 89 beats per minute, respiratory rate of 16 breaths per minute, oxygen saturation of 98% on room air, and temperature of 36.7 degrees Celsius. Physical exam revealed an anxious-appearing female of stated age. Cardiac exam revealed regular rhythm, with first and second heart sounds present, and no murmurs, rubs, or gallops. Pulmonary exam revealed clear lungs, normal effort, and was significant for pain on deep inspiration. The remainder of the physical exam was unremarkable.

The complete blood count, basic metabolic panel, and high-sensitivity troponin were unremarkable. D-dimer was elevated (0.86 micrograms per milliliters (ug/ml) fibrinogen equivalent units, normal <0.50 ug/ml fibrinogen equivalent units). Electrocardiogram showed normal sinus rhythm with a non-specific T-wave inversion in lead III. CXR was significant for a large opacity over the right mediastinal border (Image 1). C-reactive protein (15 milligrams per liter (mg/L), normal 0-5 mg/L) and erythrocyte sedimentation rate (31 millimeters per hour (mm/h), normal 0-20 mm/h) were ordered following evidence of opacity on CXR.

The elevated D-dimer prompted computed tomography (CT) to evaluate for pulmonary embolism and to better define the opacity seen on chest radiograph. The CT was negative for pulmonary embolism but revealed a large pericardial cyst (Image 2).



**Image 1.** Chest radiograph: Anterior-posterior and lateral films demonstrating anterior mediastinal opacity over the right heart border (arrow).



**Image 2.** Axial slice of computed tomography (CT) of the chest (pulmonary embolism protocol): CT showing pericardial cyst (arrow).

Transthoracic echocardiogram was negative for tamponade physiology. The patient was hospitalized and two days later taken for thoracoscopy and cyst excision. Pathology interpreted the tissue sample as a mesothelial-lined cyst with marked acute and chronic inflammation consistent with infected pericardial cyst containing purulent exudate. Fluid gram stain and cultures were negative. Blood cultures were not obtained and the patient did not receive antibiotics. Cytology was benign and noted intense acute inflammation of unknown etiology. The patient required no further treatment, had no further symptoms, and had no complications at her postoperative follow-up one month later.

### *CPC-EM Capsule*

What do we already know about this clinical entity?

*Pericardial cysts are rare mediastinal masses that are usually asymptomatic but can be complicated by arrhythmia, tamponade, and sudden cardiac death.*

What makes this presentation of disease reportable?

*Among symptomatic pericardial cysts, pleuritic pain is not a common presenting symptom. This cyst was found to be infected.*

What is the major learning point?

*Symptomatic pericardial cysts are uncommon presentations of a rare condition. Urgent echocardiography and surgical excision may be necessary in their management.*

How might this improve emergency medicine practice?

*It is important to consider mediastinal mass and, more specifically, pericardial cyst in the differential diagnosis of chest pain.*

## DISCUSSION

This is a novel presentation of a rare condition. Most pericardial cysts are asymptomatic. Ranging in size from 1-15 centimeters, 70% appear as a round opacity at the right cardiophrenic angle, while approximately 20% are found on the left heart border, and the remaining 10% are found either in the superior or posterior chest.<sup>2,4</sup> Chest pain, dyspnea, or cough are common presentations of symptomatic cysts. More uncommon presentations are documented and include complications such as atrial fibrillation, sudden cardiac death, right heart failure, cyst rupture, airway obstruction, or cardiac tamponade.<sup>5</sup> After identifying a cyst, further diagnostic evaluation includes serial transthoracic echocardiograms for asymptomatic patients. Symptomatic patients may require aspiration or surgical resection of the cyst.<sup>5</sup>

This patient's presentation of pericardial cyst was atypical for several reasons. First, she presented with pleuritic chest pain, an uncommon symptom of pericardial cysts. Second, the pathology analysis of the cyst and purulent fluid was consistent with infection. Pericardial

cysts are classically described as “spring water” cysts because they usually contain clear fluid.<sup>1</sup> Lastly, the large size of this cyst may have contributed to the pleuritic nature of the patient’s chest pain. It is reasonable to consider that further enlargement or rupture of the cyst could have put her at risk for complications such as tamponade or intrathoracic infection. Excision of this large, symptomatic, and inflamed cyst resolved the patient’s symptoms in-hospital and at her one-month follow-up appointment.

## CONCLUSION

Symptomatic pericardial cysts are uncommon. They may masquerade as more common causes of chest pain, pleuritic chest pain, or dyspnea such as acute coronary syndrome or pulmonary embolism. Emergency physicians should include pericardial cysts in the differential diagnosis of pleuritic and other chest pain presentations. Careful exclusion of more common etiologies is necessary; however, consideration of mediastinal mass and more specifically pericardial cyst in the differential diagnosis is important because of the risk for tamponade, sudden cardiac death, or other life-threatening complications. Our patient had a definitive diagnosis and surgical excision with no complications from the pericardial cyst.

Documented patient informed consent and/or Institutional Review Board approval has been obtained and filed for publication of this case report.

*Address for Correspondence:* T. Douglas Sallade, DO, Geisinger Medical Center, Department of Emergency Medicine, 100 North Academy Avenue, Dansville, PA 17822. Email: tdsallade1@geisinger.edu.

*Conflicts of Interest:* By the *CPC-EM* article submission agreement, all authors are required to disclose all affiliations, funding sources and financial or management relationships that could be perceived as potential sources of bias. Dr. Kraus serves as an Associate Editor of the *Western Journal of Emergency Medicine*.

*Copyright:* © 2019 Sallade et al. This is an open access article distributed in accordance with the terms of the Creative Commons Attribution ([CC BY 4.0](http://creativecommons.org/licenses/by/4.0/)) License. See: <http://creativecommons.org/licenses/by/4.0/>

## REFERENCES

1. Schweigert M, Dubecz A, Beron M, et al. The tale of spring water cysts: a historical outline of surgery for congenital pericardial diverticula and cysts. *Tex Heart Inst J*. 2012;39(3):330-4.
2. Borges AC, Gellert K, Dietel M, et al. Acute right-sided heart failure due to hemorrhage into a pericardial cyst. *Ann Thorac Surg*. 1997;63(3):845-7.
3. Le Roux BT. Pericardial coelomic cysts. *Thorax*. 1959;14(1):27-35.
4. Feigin DS, Fenoglio JJ, McAllister HA, et al. Pericardial cysts. A radiologic-pathologic correlation and review. *Radiology*. 1977;125(1):15-20.
5. Najib MQ, Chaliki HP, Raizada A, et al. “Symptomatic pericardial cyst: a case series.” *Eur Heart J Cardiovasc Imaging*. 2011;12(11):E43.

# Detection of Type B Aortic Dissection in the Emergency Department with Point-of-Care Ultrasound

Emily Earl-Royal, MD\*

Phi D. Nguyen, MD†

Al'ai Alvarez, MD\*

Laleh Gharahbaghian, MD\*

\*Stanford School of Medicine, Department of Emergency Medicine, Palo Alto, California

†Kaiser Permanente Sacramento Medical Center, Department of Emergency Medicine, Sacramento, California

Section Editor: Shadi Lahham, MD, MS

Submission history: Submitted March 1, 2019; Revision received May 8, 2019; Accepted May 16, 2019

Electronically published July 8, 2019

Full text available through open access at [http://escholarship.org/uc/uciem\\_cpem](http://escholarship.org/uc/uciem_cpem)

DOI: 10.5811/cpcem.2019.5.42928

Aortic dissection (AD) is a rare, time-sensitive, and potentially fatal condition that can present with subtle signs requiring timely diagnosis and intervention. Although definitive diagnosis is most accurately made through computed tomography angiography, this can be a time-consuming study and the patient may be unstable, thus preventing the study's completion. Chest radiography (CXR) signs of AD are classically taught yet have poor diagnostic reliability. Point-of-care ultrasound (POCUS) is increasingly used by emergency physicians for the rapid diagnosis of emergent conditions, with multiple case reports illustrating the sonographic signs of AD. We present a case of Stanford type B AD diagnosed by POCUS in the emergency department in a patient with vague symptoms, normal CXR, and without aorta dilation. A subsequent review of CXR versus sonographic signs of AD is described. [Clin Pract Cases Emerg Med. 2019;3(3):202-207.]

---

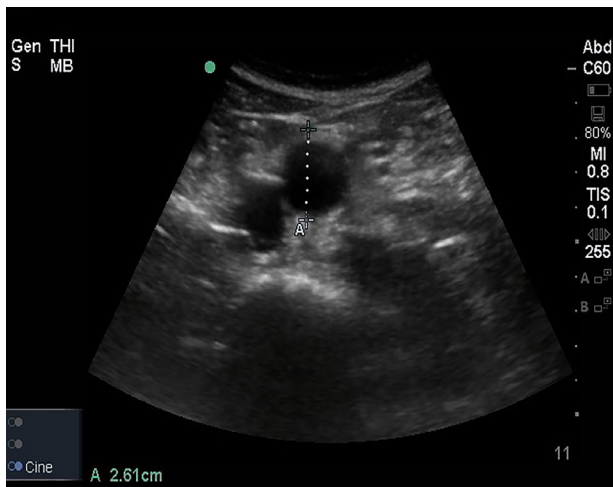
## INTRODUCTION

Aortic dissection (AD) is a rare and potentially fatal condition that can have delayed diagnosis in the emergency department (ED). Atypical signs and symptoms,<sup>1</sup> patient instability that prevents transport to radiology, and a long turn-around time for computed tomography angiography (CTA) imaging and its results all contribute to diagnostic limitations.<sup>2</sup> Clinically, AD may present with chest, abdominal or back pain, syncope or near-syncope, weakness, shortness of breath, or a sense of impending doom with pulse deficits, blood pressure differentials, neurologic deficits, or signs of cardiogenic or hypovolemic shock. For every hour delay in AD diagnosis, there is an estimated 1% increased risk in mortality, and AD continues to have a mortality of 25-30%.<sup>2</sup> The International Registry of Acute Aortic Dissection (IRAD) holds the largest database for AD presentation, imaging, and management. IRAD demonstrates that although clinical features haven't changed in 20 years, imaging has been optimized, including that of echocardiography.<sup>3-5</sup> Emergency physicians must maintain a high index of suspicion and use available resources, including point-of-care ultrasound (POCUS).

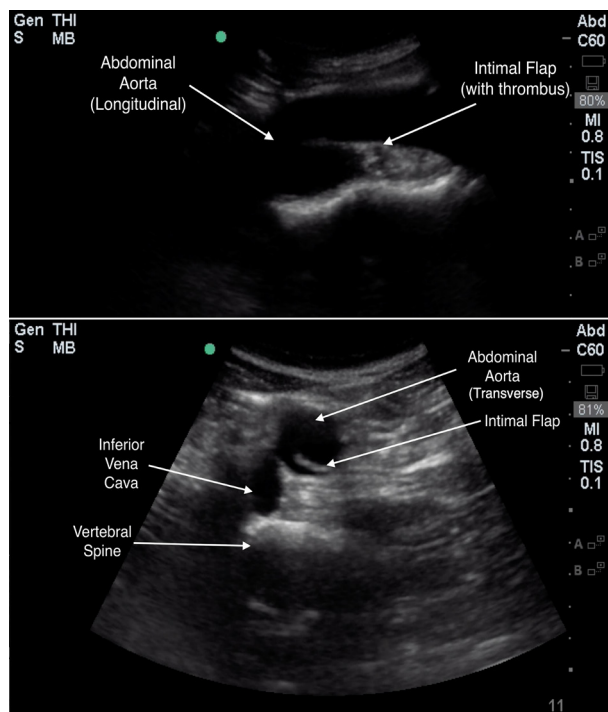
## CASE REPORT

A 49-year-old male with a new diagnosis of hypertension presented to the ED after leaving against medical advice from an outside hospital due to waiting multiple hours for CTA imaging. He reported two days of sudden onset back pain associated with discomfort while swallowing, without blood pressure control at the prior hospital. Initial vital signs included a heart rate of 97 beats per minute, blood pressure of 184/100 millimeters of mercury, respiratory rate of 16 breaths per minute, oxygen saturation of 95% on room air, and temperature of 98.2 degrees Fahrenheit. Physical exam revealed a patient in no acute distress, clear lung sounds, no murmur, and a soft, non-distended, non-tender abdomen with no palpable masses and symmetric distal pulses. Electrocardiogram showed normal sinus rhythm without ischemic changes.

POCUS of the abdominal aorta and a transthoracic echocardiogram with lung views using a Sonosite Edge 5-2 Megahertz (MHz) curvilinear and 5-1MHz phased array transducer, respectively, showed an abdominal aorta intimal flap with color Doppler differential between the true and false lumen (Images 1-4 and Video), normal cardiac contractility



**Image 1.** Transverse view of abdominal aorta at its widest point measures 2.61 centimeters.



**Image 2.** Transverse (bottom) and longitudinal (top) views of abdominal aortic dissection with intimal flap floating in true lumen.

and ascending aorta size without pericardial effusion with poor visualization of the descending aorta, and a left-sided pleural effusion. A rapid diagnosis of AD was made, continuous blood pressure monitoring and control measures were implemented, and the vascular surgery service was consulted within minutes after ED arrival. Chest radiography (CXR) showed no acute cardiopulmonary disease. A stat CTA chest/abdomen/pelvis

### *CPC-EM Capsule*

What do we already know about this clinical entity?

*Aortic dissection (AD) is a potentially fatal clinical emergency with diagnostic limitations. A high clinical suspicion is required.*

What makes this presentation of disease reportable?

*Point-of-care ultrasound (POCUS) adds to the diagnostic process with both direct and indirect data, and can illustrate the definitive diagnostic sign for the diagnosis of AD.*

What is the major learning point?

*POCUS can help identify AD with higher accuracy than chest radiograph, as well evaluate for other causes of chest pain.*

How might this improve emergency medicine practice?

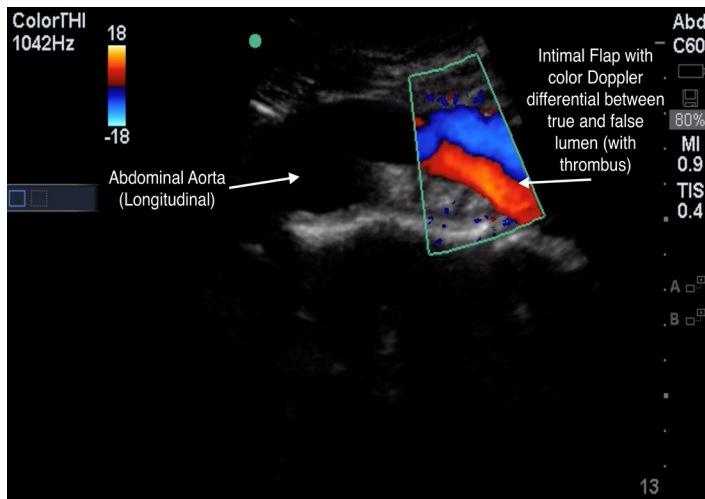
*POCUS can aid the emergency physician in the evaluation of patients suspected of having an AD.*

confirmed a Stanford type B AD originating between the left common carotid and the left subclavian artery extending through the chest and abdomen to the proximal bilateral common iliac arteries. He underwent medical management with stable repeat CTA on hospital day seven and was subsequently discharged.

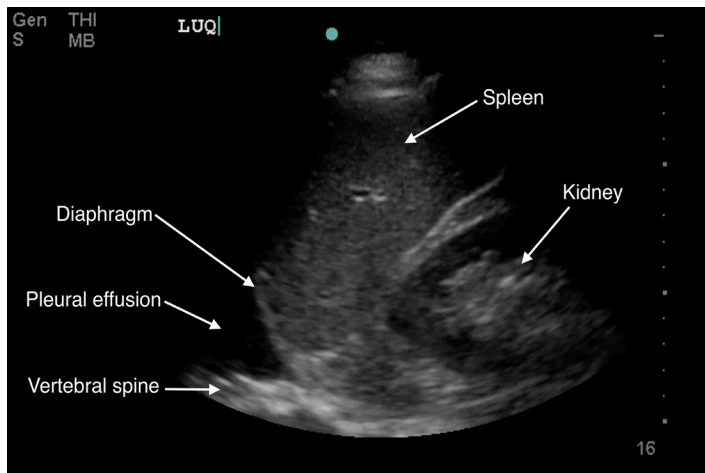
### DISCUSSION

Violation of the intimal layer of the aorta, allowing blood to dissect between the intimal and adventitial layers, defines AD. Further classification of AD includes which portions of the aorta are involved, with Stanford type A involving the ascending aorta and Stanford type B involving the descending aorta.<sup>6</sup> It is a rare condition with a reported incidence of 2.9 per 100,000 persons per year.<sup>7</sup> Untreated AD mortality rates approach 25% at 24 hours and 75% by two weeks. Type B dissection treated medically carries a mortality of 10.7% while the mortality rate of those treated surgically being higher at 31.4%, mainly due to aortic rupture and visceral ischemia.<sup>3</sup>

AD is a clinical diagnostic challenge. The presentation can vary from no deficits from organ damage to myocardial infarction and stroke. Approximately 6-15% of patients have no pain; however, they carry an increased mortality compared



**Image 3.** Longitudinal view of abdominal aortic dissection with true lumen, intimal flap, and echogenic false lumen. Superimposed color Doppler demonstrating flow differences in true and false lumen of abdominal aortic dissection.



**Image 4.** Left coronal view of thoracic cavity showing anechoic (black) fluid above the diaphragm, indicative of pleural effusion.

with painful AD.<sup>7,8</sup> The most common presenting complaint is severe, sharp chest pain and is more common with type A dissection; back and abdominal pain occurs more with type B dissection.<sup>3,8</sup> Hypertension, present in up to 72% of patients with AD, is the most important risk factor and causes increased shear forces that propagate the dissection.<sup>3</sup> Clinical variability contributes to emergency physicians' suspicion for AD in confirmed cases being at only 43%.<sup>9</sup> Our patient presented with new hypertension, back pain, and odynophagia, a rare clinical manifestation of AD discussed in only a few case reports.<sup>10-12</sup>

Timely lab and imaging tests for AD evaluation have limitations. Some evidence shows that D-dimer may help

when matched with the AD detection risk score,<sup>13,14</sup> while troponin can be an indirect marker for patients with resultant myocardial ischemia. Advanced imaging would still be required.<sup>3,14</sup> As with our patient, the absence of aortic dilation does not exclude AD diagnosis, with a normal CXR occurring in 12.4% of patients with AD and mostly in those who have a normal aorta size.<sup>3,15,16</sup> However, pleural effusion on CXR is an independent predictor of mortality in type B dissection.<sup>17</sup> While there was no pleural effusion seen on our patient's CXR, we did see a pleural effusion on POCUS.

The largest database of AD patients, IRAD, bases the diagnosis on medical history, imaging study, direct visualization at surgery, or post-mortem examination. It reviews patient presentation, lab testing, imaging studies, and AD management.<sup>3,18</sup> Although CTA is the gold standard for AD diagnosis, emergency physicians order a CXR to screen for other causes while knowing there are specific CXR signs of AD. However, CXR for AD has limitations, including an inability to exclude AD and the absence of the classic CXR sign for AD, mediastinal widening, in 37.4% of patients with AD.<sup>3,19,20</sup> With imaging advances, there has been increased utilization of CTA (used as the initial imaging modality in 61% of patients), magnetic resonance imaging (MRI), and echocardiography (transesophageal [TEE] and/or transthoracic [TTE]), used as the initial imaging modality in 33% of patients.<sup>3,8,20</sup> CTA and MRI imaging may not be readily available, while TEE requires mobilizing resources and sedation and cannot assess the abdominal aorta. Ultimately, IRAD shows that most patients required more than one imaging study.<sup>3,18</sup>

POCUS is readily available, provides rapid evaluation and dynamic imaging for emergency physicians, and lacks the need for contrast or ionizing radiation. It is most critical in patients with undifferentiated shock where a protocol exists that includes an evaluation of the heart, lung, and aorta.<sup>21</sup> TTE, lung, and transabdominal aorta POCUS views can show the following sonographic findings diagnostic of, or as a consequence of, AD: intimal flap separating the true and false lumens (sensitivity 67-79%; specificity 99-100%); aorta dilation (sensitivity 95%); intra-aorta thrombus; pericardial effusion (sensitivity 96%, specificity 98%); aortic regurgitation; wall motion abnormalities; and left pleural effusion (accuracy 93%) (Table).<sup>22-28</sup> TTE has a sensitivity of 77-80% and a specificity of 93-96% for identifying proximal AD, while the sensitivity for distal AD is slightly lower.<sup>20</sup> Abdominal aorta POCUS assessment for aneurysm has a sensitivity and specificity of over 98%, with abdominal AD assessment described in case reports.<sup>29-33</sup> As seen in our patient, POCUS demonstrates the extent of the dissection, with color Doppler showing differences of blood flow between the true and false lumen, further increasing diagnostic sensitivity.<sup>34</sup>

As opposed to CXR, POCUS is distinctly able to visualize an intimal flap, which is required for the definitive diagnosis of AD. The dynamic nature of POCUS allows for

**Table.** Summary of chest radiography versus point-of-care ultrasound (POCUS) signs of non-traumatic aortic dissection.<sup>3,20,29,32,36-40</sup>

Imaging sign	Chest radiograph	POCUS (views)
Intimal flap (definitive diagnosis of AD)	No	Yes (PSL [aortic root and ascending aorta], PSL and AP4 [portions of descending aorta], suprasternal aortic arch, abdominal descending aorta) (sensitivity 88-99%)
Intramural hematoma/thrombus (definitive diagnosis of AD)	Yes (sensitivity 49-63%)	Yes (PSL [aortic root and ascending aorta], suprasternal aortic arch, abdominal descending aorta) (sensitivity 88%)
Left-sided pleural effusion	Yes (sensitivity 19%)	Yes (lung) (sensitivity 94%)
Pericardial effusion/tamponade (enlarged cardiac silhouette)	Yes (sensitivity 26%)	Yes (SX, PSL) (sensitivity 96%)
Wall motion abnormality	No	Yes (SX, PSL, AP4)
Thoracic aorta size/contour (wide mediastinum)	Yes (sensitivity 49-67%)	Yes (PSL, suprasternal aortic arch) (sensitivity 93%)
Abdominal aorta size	No	Yes (abdominal aorta) (sensitivity 99-100%)

AD, aortic dissection; PSL, parasternal long; AP4, apical four chamber; SX, subxiphoid.

flap assessment in several angles and locations to ensure that flap motion is independent of surrounding structures, is pulsatile, and is contained within the aorta. Characterization of the false lumen of AD by POCUS involves visualization of a wedge-like angle where the flap meets the aortic wall (“beak sign”) and strand-like structures in the lumen (“cobwebs”).<sup>20</sup> All of the above findings are seen in our patient, with case reports and case series that describe intimal flap visualization (Images 1-4 and Video).<sup>23-28</sup> POCUS applications, including those needed for AD evaluation, are part of the list of ultrasound applications expected for emergency physician training and privileging under the American College of Emergency Physicians.<sup>35</sup>

There are inherent limitations to POCUS, particularly with regard to sonographer skill and experience, sonographic artifacts, and patient-centered challenges such as body habitus, bowel gas, and overall cooperation.<sup>20,27</sup> Also, portions of the thoracic aorta cannot be visualized by POCUS and evaluation of intimal flap extension into smaller arteries is limited. Further investigation is needed to determine the true accuracy of POCUS with Type B AD diagnosis especially when it involves the abdominal aorta. Whether the list of direct and indirect sonographic signs independently or collectively should be used to increase diagnostic sensitivity requires further investigation.

## CONCLUSION

AD is a rare, potentially fatal, and clinically difficult diagnosis. Subtle signs and symptoms, diagnostic challenges and limitations of CXR, and difficulties in obtaining timely definitive diagnosis using CTA, all contribute to

diagnostic delays. As described in this case report, POCUS can accurately diagnose AD rapidly when multiple views are obtained that include the heart, lung, and thoracic and abdominal aorta in order to assess for the various sonographic signs for AD.

**Video.** Transverse view of abdominal aortic dissection with intimal flap.

Documented patient informed consent and/or Institutional Review Board approval has been obtained and filed for publication of this case report.

*Address for Correspondence:* Laleh Gharahbaghian, MD, Stanford University, Department of Emergency Medicine, 900 Welch Rd, Suite 350, Palo Alto, CA 94304. Email: lalehg@stanford.edu.

*Conflicts of Interest:* By the *CPC-EM* article submission agreement, all authors are required to disclose all affiliations, funding sources and financial or management relationships that could be perceived as potential sources of bias. The authors disclosed none.

*Copyright:* © 2019 Earl-Royal et al. This is an open access article distributed in accordance with the terms of the Creative Commons Attribution (CC BY 4.0) License. See: <http://creativecommons.org/licenses/by/4.0/>

## REFERENCES

1. Strayer RJ, Shearer PL, Hermann LK. Screening, evaluation, and early management of acute aortic dissection in the ED. *Curr Cardiol Rev.* 2012;8(2):152-7.
2. Klompas M. Does this patient have an acute thoracic aortic dissection? *JAMA.* 2002;287(17):2262-72.
3. Hagan PG, Nienaber CA, Isselbacher EM, et al. The International Registry of Acute Aortic Dissection (IRAD): new insights into an old disease. *JAMA.* 2000;283(7):897-903.
4. Yuan X, Mitsis A, Tang Y, et al. The IRAD and beyond: what have we unravelled so far? *Gen Thorac Cardiovasc Surg.* 2019;67(1):146-53.
5. Pape LA, Awais M, Woznicki EM, et al. Presentation, diagnosis, and outcomes of acute aortic dissection: 17-year trends from the International Registry of Acute Aortic Dissection. *J Am Coll Cardiol.* 2015;66(4):350-8.
6. Daily PO, Trueblood HW, Stinson EB, et al. Management of acute aortic dissections. *Ann Thorac Surg.* 1970;10(3):237-47.
7. Mészáros I, Mórocz J, Szlávi J. Epidemiology and clinicopathology of aortic dissection. *Chest.* 2000;117(5):1271-8.
8. Park SW, Hutchison S, Mehta RH, et al. Association of painless acute aortic dissection with increased mortality. *Mayo Clin Proc.* 2004;79(10):1252-7.
9. Sullivan PR, Wolfson AB, Leckey RD, et al. Diagnosis of acute thoracic aortic dissection in the emergency department. *Am J Emerg Med.* 2000;18(1):46-50.
10. Abad C, Castellano C, Guerra M. [Neck pain and odynophagia as first clinical manifestation in aortic dissection]. *An Med Interna.* 2000;17(7):390-1.
11. Elloway RS, Mezwa DG, Alexander T. Foregut ischemia and odynophagia in a patient with a type III aortic dissection. *Am J Gastroenterol.* 1992;87(6):790-3.
12. Minatoya K, Okita Y, Tagusari O, et al. Transmural necrosis of the esophagus secondary to acute aortic dissection. *Ann Thorac Surg.* 2000;69(5):1584-6.
13. Nazerian P, Mueller C, Soeiro AM, et al. Diagnostic accuracy of the aortic dissection detection risk score plus D-dimer for acute aortic syndromes: The ADvISED Prospective Multicenter Study. *Circulation.* 2018;137(3):250-8.
14. Suzuki T, Distante A, Zizza A, et al. Diagnosis of acute aortic dissection by D-dimer: the International Registry of Acute Aortic Dissection Substudy on Biomarkers (IRAD-Bio) experience. *Circulation.* 2009;119(20):2702-7.
15. Trimarchi S, Jonker FH, Froehlich JB, et al. Acute type B aortic dissection in the absence of aortic dilatation. *J Vasc Surg.* 2012;56(2):311-6.
16. Pape LA, Tsai TT, Isselbacher EM, et al. Aortic diameter > or =5.5 cm is not a good predictor of type A aortic dissection: observations from the International Registry of Acute Aortic Dissection (IRAD). *Circulation.* 2007;116(10):1120-7.
17. Tsai TT, Fattori R, Trimarchi S, et al. Long-term survival in patients presenting with type B acute aortic dissection: insights from the International Registry of Acute Aortic Dissection. *Circulation.* 2006;114(21):2226-31.
18. Moore AG, Eagle KA, Bruckman D, et al. Choice of computed tomography, transesophageal echocardiography, magnetic resonance imaging, and aortography in acute aortic dissection: International Registry of Acute Aortic Dissection (IRAD). *Am J Cardiol.* 2002;89(10):1235-8.
19. Chawla A, Rajendran S, Yung WH, et al. Chest radiography in acute aortic syndrome: pearls and pitfalls. *Emerg Radiol.* 2016;23(4):405-12.
20. Hiratzka LF, Bakris GL, Beckman JA, et al. 2010 ACCF/AHA/AAATS/ACR/ASA/SCA/SCAI/SIR/STS/SVM guidelines for the diagnosis and management of patients with thoracic aortic disease: a report of the American College of Cardiology Foundation/American Heart Association Task Force on Practice Guidelines, American Association for Thoracic Surgery, American College of Radiology, American Stroke Association, Society of Cardiovascular Anesthesiologists, Society for Cardiovascular Angiography and Interventions, Society of Interventional Radiology, Society of Thoracic Surgeons, and Society for Vascular Medicine. *Circulation.* 2010;121(13):e266-369.
21. Perera P, Mailhot T, Riley D, et al. The RUSH exam: Rapid Ultrasound in SHock in the evaluation of the critically ill. *Emerg Med Clin North Am.* 2010;28(1):29-56.
22. von Kodolitsch Y, Schwartz AG, Nienaber CA. Clinical prediction of acute aortic dissection. *Arch Intern Med.* 2000;160(19):2977-82.
23. Khandheria BK, Tajik AJ, Taylor CL, et al. Aortic dissection: review of value and limitations of two-dimensional echocardiography in a six-year experience. *J Am Soc Echocardiogr.* 1989;2(1):17-24.
24. Roudaut RP, Billes MA, Gosse P, et al. Accuracy of M-mode and two-dimensional echocardiography in the diagnosis of aortic dissection: an experience with 128 cases. *Clin Cardiol.* 1988;11(8):553-62.
25. Williams J, Heiner JD, Perreault MD, et al. Aortic dissection diagnosed by ultrasound. *West J Emerg Med.* 2010;11(1):98-9.
26. Evangelista A, Flachskampf FA, Erbel R, et al. Echocardiography in aortic diseases: EAE recommendations for clinical practice. *Eur J Echocardiogr.* 2010;11(8):645-58.
27. Fojtik JP, Costantino TG, Dean AJ. The diagnosis of aortic dissection by emergency medicine ultrasound. *J Emerg Med.* 2007;32(2):191-6.
28. Blaivas M, and Sierzenski P.R. Dissection of the proximal thoracic aorta: a new ultrasonographic sign in the subxiphoid view. *Am J Emerg Med.* 2002;20(4):344-8.
29. Rubano E, Mehta N, Caputo W, et al. Systematic review: emergency department bedside ultrasonography for diagnosing suspected abdominal aortic aneurysm. *Acad Emerg Med.* 2013;20(2):128-38.
30. Thomas EA and Dubbins PA. Duplex ultrasound of the abdominal aorta—a neglected tool in aortic dissection. *Clin Radiol.* 1990;42(5):330-4.
31. Kuhn M, Bonnin RL, Davey MJ, et al. Emergency department ultrasound scanning for abdominal aortic aneurysm: accessible, accurate, and advantageous. *Ann Emerg Med.* 2000;36(3):219-23.
32. Tayal V, Graf CD, Gibbs M. Prospective study of accuracy and outcome of emergency ultrasound for abdominal aortic aneurysm

- over two years. *Acad Emerg Med*. 2003;10(8):867-71.
33. Kaban J and Raio C. Emergency department diagnosis of aortic dissection by bedside transabdominal ultrasound. *Acad Emerg Med*. 2009;16(8):809-10.
34. Sentz A. The role of CTA, MRA, and sonography in aortic dissection. *J Diagn Med Sonogr*. 2015;31(4):235-40.
35. American College of Emergency Physicians. ACEP emergency ultrasound guidelines-2001. *Ann Emerg Med*. 2001;38(4):470-81.
36. Mandavia DP, Hoffner RJ, Mahaney K, et al. Bedside echocardiography by emergency physicians. *Ann Emerg Med*. 2001;38(4):377-82.
37. Lichtenstein D, Goldstein I, Mourgeon E, et al. Comparative diagnostic performances of auscultation, chest radiography, and lung ultrasonography in acute respiratory distress syndrome. *Anesthesiology*. 2004;100(1):9-15.
38. Nazerian P, Vanni S, Castelli M, et al. Diagnostic performance of emergency transthoracic focus cardiac ultrasound in suspected acute type A aortic dissection. *Intern Emerg Med*. 2014;9(6):665-70.
39. Youseffard M, Baikpour M, Ghelichkhani P, et al. Screening performance characteristic of ultrasonography and radiography in detection of pleural effusion; a meta-analysis. *Emerg (Tehran)*. 2016;4(1):1-10.
40. von Kodolitsch Y, Nienaber CA, Dieckmann C, et al. Chest radiography for the diagnosis of acute aortic syndrome. *Am J Med* 2004;116(2):73-7.

# Head of the Bed Down: Paradoxical Management for Paradoxical Herniation

Patrick D. Bender, MD  
Alisha E.C. Brown, MD

University of Washington, Harborview Medical Center, Department of  
Emergency Medicine, Seattle, Washington

Section Editor: Rick A. McPheeters, DO

Submission history: Submitted October 19, 2018; Revision received March 20, 2019; Accepted April 1, 2019

Electronically published May 29, 2019

Full text available through open access at [http://escholarship.org/uc/uciem\\_cpem](http://escholarship.org/uc/uciem_cpem)

DOI: 10.5811/cpem.2019.4.41331

Emergency physicians are well versed in cerebral herniation, pathology that typically results from increased intracranial pressure; however, paradoxical herniation is less common and requires opposing treatments. We describe a case of paradoxical herniation following lumbar puncture in a patient with previous hemicraniectomy. The symptomatology was similar to cerebral herniation from intracranial hypertension and included lethargy, bradycardia, headache, and compression of brain structures on non-contrast head computed tomography. However, contrary to treatment modalities for intracranial hypertension, our management strategy aimed to reverse intracerebral hypotension. Treatment for paradoxical herniation involved increasing intracranial pressure using fluid resuscitation and Trendelenburg positioning. In the intensive care unit our patient received an epidural blood patch and hydration with resolution of his symptoms. [Clin Pract Cases Emerg Med. 2019;3(3):208-210.]

---

## INTRODUCTION

The trajectory of elevated intracranial pressure and impending brain herniation is a disease process in which emergency physicians (EP) are trained and prepared to manage. Usual management strategies aim to reduce intracranial hypertension and include hypertonic osmotic agents, patient positioning with an elevated head of bed, manipulation of cerebral arterial blood flow through hyperventilation and surgical intervention. However, the process of paradoxical herniation is a lesser-known pathology for which the treatment is the contrary to standard therapies for cerebral herniation. Traditional treatments aimed at lowering intracerebral hypertension will worsen paradoxical herniation,<sup>1</sup> making this a critical condition for EPs to understand. We present a case of paradoxical brain herniation presenting as a post-lumbar puncture (LP) headache in a hemicraniectomy patient. We highlight the underlying pathophysiology, risk factors, presentation, and emergency department (ED) management.

## CASE REPORT

A 19-year-old man presented to the ED with a persistent headache one week after a LP. His past medical history was significant for a stab wound to his left middle cerebral artery one year prior to presentation with surgical management of his injury requiring a left hemicraniectomy. His post-surgical course was complicated by synthetic skull infection and cranioplasty

revision, and he was ultimately discharged without a bone flap. One month after discharge, he underwent LP in neurosurgery outpatient clinic for monitoring of previous fungal meningitis and evaluation of flap swelling. In the days following his LP, the patient began to develop a dull, holocephalic headache associated with photophobia, nausea, and vomiting. His headache was worse with sitting and standing. He denied fevers, weakness, or numbness. His caretaker noted he was more lethargic than usual, and the flap overlying his craniectomy site now appeared sunken. There was no new trauma reported. A week into his symptoms, he was referred to the ED for evaluation of post-LP headache.

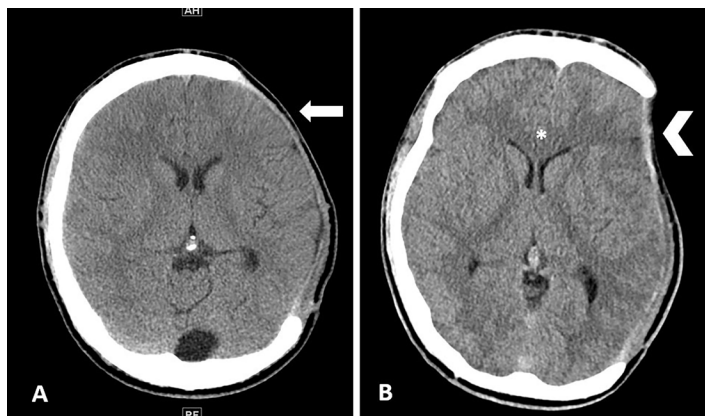
Vital signs on presentation to the ED were as follows: heart rate of 45 beats per minute, blood pressure of 93/73 millimeters of mercury, respiratory rate of 14 breaths per minute, and a temperature 37 degrees Celsius. He was drowsy but arousable and could answer simple questions. His presenting Glasgow Coma Scale was 14. Head examination revealed a sunken scalp flap overlaying the left anterior temporal craniectomy site without erythema, drainage or fluctuance. There was no evidence of new cranial trauma. His cranial nerve examination revealed no deficits, with symmetric and reactive pupils. He had full and symmetric strength in his upper and lower extremities with no obvious sensory changes. His cardiac exam was notable for bradycardia. His LP site was well appearing without leakage, erythema, bruising, or tenderness. The remainder of his examination was normal. Cerebrospinal fluid studies from

earlier in the week were reviewed and showed zero white blood cells and zero red blood cells.

In the ED, the patient underwent a non-contrast head computed tomography (CT), which demonstrated a 5 millimeter (mm) left-to-right midline shift with subfalcine herniation (Image 1), sulcal effacement (Image 2), and soft tissue sinking consistent with paradoxical herniation. We placed the patient's head of bed down, gave him one liter normal saline, metoclopramide for nausea, and acetaminophen and hydromorphone for pain control. Neurosurgery was emergently consulted and the patient was admitted to the intensive care unit (ICU). He underwent an epidural blood patch with anesthesia the next morning. Repeat non-contrast head CT one day later showed decreased midline shift from 5 mm to 3mm and improved sunken appearance of the left cerebral hemisphere. On hospital day two, his headache had improved and he was discharged in stable condition with plans for outpatient cranioplasty. Follow-up of his cerebrospinal fluid cultures revealed no fungal or bacterial growth.

## DISCUSSION

Decompressive craniectomy is a neurosurgical procedure in which part of the skull is removed in an effort to prevent brain herniation in the setting of severely elevated intracranial pressure. It is typically performed in patients with life-threatening traumatic brain injury,<sup>2,3</sup> or extensive stroke.<sup>4</sup> Once the primary neurologic insult has improved or resolved, most patients will undergo a cranioplasty in which the defect is closed either with the original bone or a prosthetic device. Cranioplasties typically occur days to weeks after the original craniectomy. In some patients, however, cranioplasty is not immediately possible.



**Image 1.** Non-contrast axial head computed tomography (CT) image demonstrating sunken flap and midline shift. Image A is from seven weeks prior to patient's emergency department (ED) presentation. He is status post left hemicraniectomy. His CT demonstrates a normal-appearing cranioplasty flap (arrow). In comparison, image B is from the day of patient's ED presentation demonstrating flattening and depression at the area of skull defect (arrowhead) with a corresponding 5 millimeter left-to-right midline shift (star) concerning for paradoxical herniation.

### *CPC-EM Capsule*

What do we already know about this clinical entity?

*Paradoxical herniation occurs in the setting of a cranioplasty when atmospheric pressure exceeds intracranial pressure, resulting in compression of critical brain structures.*

What makes this presentation of disease reportable?

*This is a rare disease entity in cranioplasty patients resulting in cerebral herniation. However, interventions are opposite that of herniation syndromes more commonly encountered in intracranial hypertension.*

What is the major learning point?

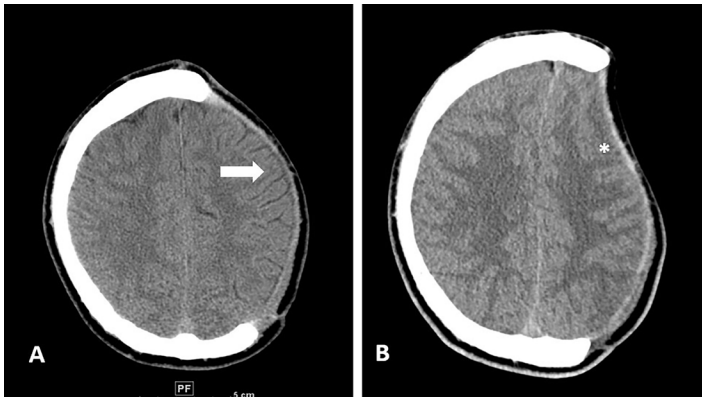
*Forces generating herniation in paradoxical herniation originate from a low pressure system. Management should be aimed at increasing intracranial pressure.*

How might this improve emergency medicine practice?

*Recognition of important physical exam findings such as a sunken flap may provide early clues to this diagnosis, facilitating timely treatment and appropriate disposition.*

Without the rigid structure of the skull, these patients are at risk for developing a pressure gradient across the soft tissues of the head with respect to atmospheric pressure. Consequently, the soft tissues of the brain are susceptible to movement with relation to the falx, tentorium, and foramen magnum. When the supporting hydrostatic column of cerebrospinal fluid is altered (i.e., during a LP), brain tissue can shift as atmospheric pressure exceeds intracranial pressure. This is known as paradoxical herniation. The driving force is intracranial hypotension as opposed to intracranial hypertension. It is referred to as the "syndrome of the trephinated" or "sinking skin flap syndrome."<sup>5</sup>

Some cases are provoked (i.e., in the setting of a LP or shunt placement); while others are spontaneous. Paradoxical herniation is typically encountered in the weeks to months after original craniectomy<sup>6</sup> making this a potential complication seen by EPs. Paradoxical herniation results in physical compression of critical brain structures leading to headache, autonomic instability (including bradycardia), altered mental status, pupillary changes, and focal neurologic



**Image 2.** Non-contrast axial head computed tomography (CT) image demonstrating sulcal effacement. Image A is from seven weeks prior to patient's emergency department (ED) presentation. He is status post left hemicraniectomy. His CT demonstrates a normal-appearing cranioplasty flap (arrow). In comparison, image B is from the day of patient's ED presentation and demonstrates sulcal effacement (star).

deficits. Unique physical exam findings include sinking of the skin overlying the craniectomy defect; however, not all cases will have a sunken flap.<sup>6</sup>

As the forces generating herniation in paradoxical herniation originate from a low pressure system, management is focused on increasing intracranial pressure. This involves positioning the patient with the head of the bed down (Trendelenburg position), hydration with crystalloid, and discontinuing diuretics or hypertonic solutions.<sup>1</sup> The patient should receive supportive care for nausea and pain. Intubation and advanced airway management may be necessary in severe cases. There have been reports of cases successfully treated with addition of a blood patch, a therapeutic used in our patient. In extreme situations, patients have had to return emergently to the operating room for cranioplasty.<sup>7</sup>

Patients with paradoxical herniation should be admitted to the ICU and neurologic status closely monitored. Highly symptomatic patients with evidence of brainstem compression should be transferred to centers with neurosurgery consultation.<sup>3</sup>

## CONCLUSION

Our case highlights a rare disease entity in craniectomy patients. Unlike herniation from elevated intracerebral pressures, paradoxical herniation is due to a low-pressure intracerebral state, resulting in compression of vital brain structures. It is important to inspect the contour and shape of craniectomy flaps. Management should be aimed at increasing the intracerebral pressure.

## ACKNOWLEDGMENTS

Dr. Alan Leung, MD, University of Washington Department of Radiology, for his assistance in image acquisition and interpretation.

Documented patient informed consent and/or Institutional Review Board approval has been obtained and filed for publication of this case report.

*Address for Correspondence:* Patrick D. Bender, MD, University of Washington, Harborview Medical Center, Department of Emergency Medicine, 325 9<sup>th</sup> Ave, Seattle, WA 98104. Email: patdb@uw.edu.

*Conflicts of Interest:* By the CPC-EM article submission agreement, all authors are required to disclose all affiliations, funding sources and financial or management relationships that could be perceived as potential sources of bias. The authors disclosed none.

*Copyright:* © 2019 Bender et al. This is an open access article distributed in accordance with the terms of the Creative Commons Attribution (CC BY 4.0) License. See: <http://creativecommons.org/licenses/by/4.0/>

## REFERENCES

1. Akins PT and Guppy KH. Sinking skin flaps, paradoxical herniation, and external brain tamponade: a review of decompressive craniectomy management. *Neurocrit Care.* 2007;9(2):269-76.
2. Rosenfeld JV, Maas AI, Bragge P, et al. Early management of severe traumatic brain injury. *Lancet.* 2012;380(9847):1088-98.
3. Stocchetti N, Zoerle T, Carbonara M. Intracranial pressure management in patients with traumatic brain injury: an update. *Curr Opin Crit Care.* 2017;23(2):110-4.
4. Dasenbrock HH, Robertson FC, Vaitkevicius H, et al. Timing of decompressive hemicraniectomy for stroke: a nationwide inpatient sample analysis. *Stroke.* 2017;48(3):704-11.
5. Annan M, De Toffol B, Hommet C, et al. Sinking skin flap syndrome (or syndrome of the trephined): a review. *Br J Neurosurg.* 2015;29(3):314-8.
6. Creutzfeldt CJ, Vilela MD, Longstreth WT. Paradoxical herniation after decompressive craniectomy provoked by lumbar puncture or ventriculoperitoneal shunting. *J Neurosurg.* 2015;123(5):1170-5.
7. Díaz-Romero R, Avendaño P, Coloma G. Life-threatening paradoxical brain herniation rapidly reversed by emergency cranioplasty repair: a case report. *Acta Neurochir.* 2015;157(11):2031-2.

# A Case of Thiazide-induced Hypokalemic Paralysis

Elizabeth Schell, BS\*  
Joshua Pathman, MD†  
Richard Pescatore, DO†  
Pollianne W. Bianchi, MD†

\*Drexel University College of Medicine, Philadelphia, Pennsylvania  
†Crozer-Keystone Health System, Department of Emergency Medicine,  
Upland, Pennsylvania

Section Editor: Rick A. McPheeters, DO

Submission history: Submitted December 20, 2018; Revision received February 22, 2019; Accepted March 28, 2019

Electronically published May 20, 2019

Full text available through open access at [http://escholarship.org/uc/uciem\\_cpem](http://escholarship.org/uc/uciem_cpem)

DOI: 10.5811/cpsem.2019.3.42062

We describe the case of a patient presenting with odd neurologic symptoms initially thought to represent somatization who was found to have critical hypokalemia manifesting as hypokalemic non-periodic paralysis. It was determined that the patient had baseline hypokalemia as a function of alcohol abuse, exacerbated by self overmedication with hydrochlorothiazide for elevated blood pressure readings at home. The diagnosis was suspected when an electrocardiogram was obtained demonstrating a pseudo-prolonged QT interval with ST depression, consistent with T-U wave fusion and a QU interval with an absent T wave.<sup>1</sup> The patient received oral and intravenous potassium and magnesium supplementation with resolution of symptoms. [Clin Pract Cases Emerg Med. 2019;3(3):211-214.]

---

## INTRODUCTION

We report a rare and unusual case of hypokalemic non-periodic paralysis (HNPP) precipitated by thiazide diuretic overuse in the setting of alcoholic malnutrition. HNPP associated with thiazide diuretics is extremely rare and reported only sparingly in the literature. Unique features of this case include the patient's non-specific presentation, pathognomonic electrocardiogram (ECG) changes, and the severity of the patient's hypokalemia and associated hypomagnesemia. The patient had complete resolution of symptoms with electrolyte repletion in the emergency department (ED). We discuss the incidence and mechanism of hypokalemic paralysis and a detailed description of the patient's presentation as a reminder for emergency physicians to consider HNPP in the differential diagnosis of patients treated with thiazide diuretics presenting with neurologic symptoms.

## CASE REPORT

A 53-year old female with a history of alcohol abuse, anxiety, and hypertension presented to the ED with a chief complaint of "I think I'm having a stroke." The patient reported inability to move her face or hands since awaking that morning, about 30 minutes prior to arrival. She was immediately assessed by physician and nursing staff after triage personnel initiated a rapid stroke evaluation.

On physical exam, the patient held her mouth immobile and partly open, even while talking. On neurologic exam, the patient's hands and wrists appeared to be flaccid, with

wrists held in passive flexion. Passive range of motion of all extremities was normal with no spasticity. Muscle strength was assessed at 1/5 in wrist flexion and extension, and 4/5 throughout the remainder of the bilateral extremities. She was unable to comply with cerebellar testing due to weakness. There was no clonus. The rest of the physical exam was unremarkable, including vital signs, which demonstrated a heart rate of 96 beats per minute, blood pressure of 136/88 millimeters of mercury, respirations of 16 breaths per minute, and pulse oximetry of 99% on room air. The patient was afebrile with an oral temperature of 97.6 degrees Fahrenheit.

On further history, the patient reported daily moderate alcohol abuse of 2-3 glasses of wine, with her last drink the evening prior. She had been poorly compliant with outpatient primary care follow-up and had not seen her primary care physician (PCP) in nine months. However, she had received multiple refills of her prescribed hydrochlorothiazide (HCTZ) 25 milligrams (mg) twice daily, as well as sertraline 100mg daily, her only medications. The patient admitted to intermittent medication compliance, but stated that she had been taking extra doses of HCTZ recently due to elevated blood pressures noted on home sphygmomanometry, with an estimated daily dose of 50 – 75 mg of HCTZ.

The differential diagnosis was considered to be broad, including an anxiety reaction, somatization, intoxication, extrapyramidal side effects due to sertraline, or other metabolic derangements. Given her neurologic examination, a cerebral vascular accident was thought to be unlikely. Believing

anxiety, somatization, and extrapyramidal side effects to be more likely, the treating physician administered 25mg of intramuscular diphenhydramine to the patient without any significant improvement. Laboratory studies were drawn and sent and an ECG obtained (Image).

The patient's ECG was thought to be concerning for hypokalemia, which was confirmed when serum chemistry revealed a potassium level of 1.8 milliequivalents per liter (mEq/L) (normal 3.5-5.0 mEq/L). Additionally, the patient's magnesium level was found to be critically low at 0.8 mEq/L (normal 1.5-2.5 mEq/L). Serum calcium level was 8.1 mg/deciliter (dL) with an albumin level of 2.9 grams (g)/dL (normal 3.4 – 5.4 g/dL). Corrected serum calcium was calculated to be 9.0 mg/dL (normal 8.5 – 10.2 mg/dL). Serum ethanol was undetectable and urine drug screen was negative. The patient's sodium level was 134 mEq/L (normal 135-145 mEq/L). Her complete blood count, thyroid stimulating hormone, and creatine kinase were within normal limits. She had normal renal function. A presumptive diagnosis of HNPP was made and potassium and magnesium correction started through oral and intravenous (IV) routes.

Following administration of 40 mEq of oral potassium chloride, 20 mEq of IV potassium chloride, 800 mg of oral magnesium oxide, and 2 grams of IV magnesium sulfate, the patient had complete resolution of her symptoms and narrowing of corrected QT interval. Potassium and magnesium supplementation was continued and the patient was admitted for evaluation by internal medicine and nephrology.

The patient received additional magnesium and potassium supplementation, and subsequent serum chemistries demonstrated resolution of hypokalemia and hypomagnesemia. She was evaluated by nephrology, who felt that the cause of the patient's electrolyte abnormalities was likely multifactorial, a function of diuretic abuse and alcoholic malnutrition. While congenital channelopathies were considered and thought to be possible, genetic testing was deferred. The patient's HCTZ was discontinued in lieu of amlodipine 10mg daily and the patient started on 20 mEq daily potassium chloride supplementation. She was discharged to home and advised to obtain repeat laboratory testing with her PCP.

## DISCUSSION

Hypertension is a major cause of morbidity and mortality in the United States. Thiazide diuretics are the most commonly prescribed anti-hypertensive medication. Thiazides are typically very safe and effectively lower blood pressure with few side effects or adverse events.<sup>2</sup> Potential side effects do exist, however, including renal potassium wasting leading to hypokalemia. Thiazides work via disruption of sodium/chloride co-transporters in the distal tubule leading to increased sodium infiltrate. This increase leads to a surge in sodium resorption distally via sodium-potassium/hydrogen counter transporters and a subsequent urinary loss of potassium. This loss of potassium and hydrogen ions can

### *CPC-EM Capsule*

What do we already know about this clinical entity?  
*Hypokalemic paralysis is associated with genetic channelopathy or thyrotoxicosis. Symptoms of weakness or paralysis lead to respiratory failure and cardiac arrhythmias.*

What makes this presentation of disease reportable?  
*We present an unusual case of hypokalemic non-periodic paralysis caused by potassium depletion that was related to drug side effects and compounded by malnutrition.*

What is the major learning point?  
*An electrocardiogram may give insight into the cause of vague weakness of unclear etiology, such as that caused by otherwise-benign thiazide diuretics.*

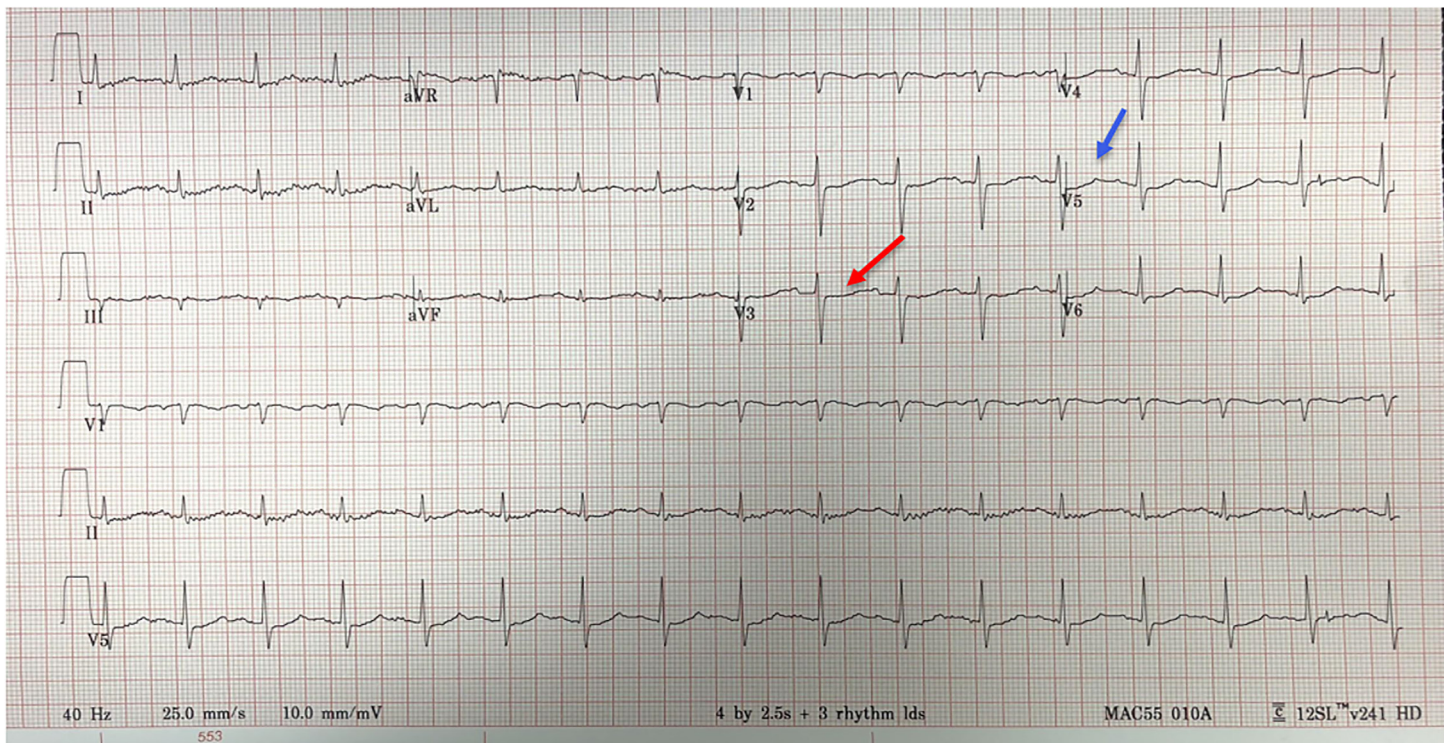
How might this improve emergency medicine practice?  
*This case reinforces the need for a high index of suspicion for electrolyte abnormalities in patients with alcohol use disorder or who present with vague weakness.*

potentially lead to hypokalemia and metabolic alkalosis, a common co-occurrence.<sup>3</sup>

Given their mechanism of action, it is well-documented that non-potassium sparing diuretics, including thiazides, can cause hypokalemia. The first case of hypokalemic paralysis caused by thiazides was documented in 1958 in a man instructed to take 250 mg HCTZ twice daily for hypertension.<sup>4</sup> Potassium wasting has since been found to be dose-dependent, and current guidelines do not recommend a patient take more than a total of 100 mg HCTZ per day.

Even with reduction in dosing, hypokalemia is a potential side effect in certain patients taking thiazides, and it is associated with increased mortality in hospitalized patients. Mild hypokalemia (between 3.5 and 3.0 mEq/L) is typically asymptomatic. Below 3.0 mEq/L, patients may experience muscle cramping, muscle weakness, myalgias, and malaise. In severe hypokalemia (less than 2.5 mEq/L), symptoms can include ECG changes, arrhythmias, and paralysis.<sup>5</sup> If left untreated, severe hypokalemia can lead to respiratory failure and fatal dysrhythmias. However, even in severe cases, up to 50% of patients are asymptomatic.<sup>6</sup>

In the presented case, the patient presented with paralysis and ECG changes due to hypokalemia from potassium wasting



**Image.** Electrocardiogram demonstrating a pseudo-prolonged corrected QT interval (522 milliseconds) with ST depression (red arrow), consistent with T-U wave fusion and a QU interval with an absent T wave (blue arrow).

due to medication-induced renal wasting in the presumed setting of alcoholic malnutrition. Hypokalemia as well as hypomagnesemia are frequently present in the alcoholic patient with prevalence of 12% and 30%, respectively.<sup>7</sup> Hypokalemic paralysis caused by loss of total body potassium is typically referred to as hypokalemic non-periodic paralysis. Another type of hypokalemic paralysis, caused by inherited channelopathies, is called hypokalemic periodic paralysis. In contrast to potassium wasting, the channelopathy causes a rapid shift of potassium into cells and subsequent paralysis.<sup>8</sup> Genetic channelopathy testing was considered in our patient, but was ultimately declined because of the other likely causes of hypokalemia including diuretic use and alcoholism.

As stated above, the overwhelming majority of patients taking thiazides do not develop clinically significant hypokalemia. It is not completely understood why some patients are more sensitive to the potassium lowering effects of thiazides, but gastrointestinal absorption likely plays a role. Differences in dietary potassium intake and other factors affecting potassium absorption, such as chronic alcohol use, laxative use, and bulimia nervosa put a patient at higher risk for developing hypokalemia.<sup>9</sup>

It was the ECG obtained in this case that sparked initial concern for hypokalemia in this patient. Several classic hypokalemia ECG findings are noted in this case including diffuse ST depressions, as well as diffuse flattening of the T waves with the beginnings of T wave inversions in some lateral leads. Prominent U waves are seen following the flattened T

waves in the precordial and lateral leads. The flattening of the T wave in conjunction with the prominent U wave can give the impression of an isolated prolonged QT, which should not be confused with the ECG manifestations of hypocalcemia. Not well visualized in this case is the increase in length and amplitude of the P wave or the significant T wave inversions which give a biphasic appearance to the TU segment.

As outlined previously, thiazide-induced HNPP is driven primarily by whole body depletion of potassium. Successful treatment in this case (and severe hypokalemia in general) focuses on rapid repletion of potassium in addition to magnesium. Oral formulations of potassium chloride are generally preferred to their IV counterparts; however, the IV route should be used in patients unable to tolerate oral medication or with cardiac arrhythmias or acute respiratory failure.<sup>10</sup> This patient received rapid IV infusion due to ECG changes concerning for a developing cardiac arrhythmia.

Equally important to potassium administration is the requirement for magnesium coadministration to correct the hypomagnesemia that frequently accompanies hypokalemia. Potassium chloride administration is futile in the untreated hypomagnesemic patient as magnesium is critical in maintaining intracellular potassium levels.<sup>11</sup> Recommendations on repletion vary; however, administration of 2g IV magnesium sulfate, as was done in this case, is an accepted initial regimen. Further repletion will often be required over the following 24 hours.<sup>12</sup>

## CONCLUSION

While hypokalemic periodic paralysis associated with an inherited genetic mutation or thyrotoxicosis is an infrequent but well-documented entity, hypokalemic paralysis associated with thiazide use – termed hypokalemic non-periodic paralysis – has little discussion in the literature. This case report demonstrates how a patient presentation that could have been dismissed as somatization was actually caused by a severe electrolyte abnormality, which can be associated with cardiac arrhythmia and respiratory failure. Hypokalemic non-periodic paralysis should be considered in the differential diagnosis for patients presenting with paralysis who are prescribed thiazide diuretics or other potassium-lowering medications. Clinicians should have a low threshold to investigate for hypokalemia in patients presenting with symptoms suggestive of paralysis.

Documented patient informed consent and/or Institutional Review Board approval has been obtained and filed for publication of this case report.

---

*Address for Correspondence:* Polliane W. Bianchi, MD, Crozer Chester Medical Center, Department of Emergency Medicine, One Medical Blvd, Upland, PA 19013. Email: pollianne.ward@crozer.org.

*Conflicts of Interest:* By the CPC-EM article submission agreement, all authors are required to disclose all affiliations, funding sources and financial or management relationships that could be perceived as potential sources of bias. The authors disclosed none.

*Copyright:* © 2019 Schell et al. This is an open access article distributed in accordance with the terms of the Creative Commons Attribution (CC BY 4.0) License. See: <http://creativecommons.org/licenses/by/4.0/>

---

## REFERENCES

1. Levis JT. ECG diagnosis: hypokalemia. *Perm J.* 2012;16(2):57.
2. Kantor ED, Rehm CD, Haas JS, et al. Trends in prescription drug use among adults in the United States from 1999-2012. *JAMA.* 2015;314(17):1818-30.
3. Tannen RL. Diuretic-induced hypokalemia. *Kidney Int.* 1985;28(6):988-1000.
4. Cohen T. Hypokalemic muscle paralysis associated with administration of chlorothiazide. *JAMA.* 1959;170(17):2083-5.
5. Veltri KT and Mason C. Medication-induced hypokalemia. *PT.* 2015;40(3):185-90.
6. Marti G, Schwarz C, Leichtle AB, et al. Etiology and symptoms of severe hypokalemia in emergency department patients. *Eur J Emerg Med.* 2014;21(1):46-51.
7. Moses E and Rigas K. Metabolic abnormalities in alcoholic patients: focus on acid base and electrolyte disorders. *J Alcohol Drug Depend.* 2015;2(185):2.
8. Lee TW, Bae E, Hwang K, et al. Severe hypokalemic paralysis and rhabdomyolysis occurring after binge eating in a young bodybuilder: Case report. *Medicine (Baltimore).* 2017;96(40):e8251.
9. Sung CC, Cheng CJ, Chiang WF, et al. Etiologic and therapeutic analysis in patients with hypokalemic nonperiodic paralysis. *Am J Med.* 2015;128(3):289-96.
10. Levitt JO. Practical aspects in the management of hypokalemic periodic paralysis. *J Transl Med.* 2008;6(1):18.
11. Cohn JN, Kowey PR, Whelton PK, et al. New guidelines for potassium replacement in clinical practice: a contemporary review by the National Council on Potassium in Clinical Practice. *Arch Intern Med.* 2000;160(16):2429-36.
12. Hamill-Ruth RJ and McGory R. Magnesium repletion and its effect on potassium homeostasis in critically ill adults: results of a double-blind, randomized, controlled trial. *Crit Care Med.* 1996;24(1):38-45.

# Ventricular Tachycardia Storm Presenting as Vague Complaints to the Emergency Department

Ravneet Kamboj, MS-IV\*  
Andy C. Bunch, MD\*  
Robert C. Bernstein, MD†  
Francis L. Counselman, MD\*‡

\*Eastern Virginia Medical School, Department of Emergency Medicine, Norfolk, Virginia  
†Sentara Cardiology Specialists, Department of Cardiology, Norfolk, Virginia  
‡Emergency Physicians of Tidewater, Norfolk, Virginia

Section Editor: Rick A. McPheeters, DO

Submission history: Submitted March 11, 2019; Revision received April 22, 2019; Accepted May 16, 2019

Electronically published July 8, 2019

Full text available through open access at [http://escholarship.org/uc/uciem\\_cpccm](http://escholarship.org/uc/uciem_cpccm)

DOI: 10.5811/cpcem.2019.5.43052

We present the case of a 75-year-old man with vague symptoms and hypotension found to be in electrical storm secondary to sustained ventricular tachycardia. The patient did not respond to intravenous amiodarone, magnesium, lidocaine, or four cardioversion attempts. This case illustrates the challenges in managing patients with electrical storm presenting to the emergency department. [Clin Pract Cases Emerg Med. 2019;3(3):215-218.]

---

## INTRODUCTION

We present the case of a 75-year-old man who presented to the emergency department (ED) with the primary complaints of lightheadedness and blurred vision. The patient was found to be hypotensive and in ventricular tachycardia (VT) storm. Despite optimal medical therapy with intravenous amiodarone, magnesium, lidocaine, and a total of four cardioversions, the patient remained in sustained VT or electrical storm. This is defined as three or more sustained episodes of VT, ventricular fibrillation (VF), or appropriate implantable cardioverter-defibrillator (ICD) shocks within a 24-hour period.<sup>1,2,3</sup> VT, as in this case, is usually the abnormal rhythm, but VF can occur as well. Emergency physicians need to consider electrical storm in the setting of sustained VT, VF, or appropriate ICD shocks.

## CASE REPORT

A 75-year-old man presented to the ED complaining of lightheadedness and blurred vision. The patient had a history of myocardial infarction, deep venous thrombosis, and hyperlipidemia. He stated he had taken a sildenafil pill earlier in the day. A few minutes after taking it, he became dizzy, lightheaded and experienced blurred vision. The patient denied chest pain, shortness of breath, palpitations, or nausea and vomiting. He denied extremity numbness, weakness, or change in speech. The patient's medications included warfarin 2.5 milligrams (mg) daily, simvastatin 20 mg daily, and sildenafil 100 mg as needed.

Physical exam revealed a pulse of 141 beats per minute, respiratory rate of 18 breaths per minute, blood pressure 84/48 millimeters of mercury (mmHg), 96% oxygen saturation on room air, and that he was afebrile. The cardiac monitor revealed a wide complex tachycardia consistent with VT. He appeared comfortable and was able to converse without any problem. The head, eyes, ears, nose, and throat exam was normal. Examination of the heart revealed a tachycardic, regular rhythm without murmurs, rubs, or gallop. Auscultation of the lungs revealed clear, bilateral breath sounds. The abdomen was soft, nontender, and without guarding or rebound. The neurologic exam was completely normal.

A stat electrocardiogram (ECG) was obtained, blood drawn, an intravenous (IV) line established, and a portable chest radiograph (CXR) ordered. The ECG showed VT (Image). The patient was given amiodarone 150 mg IV and two grams of magnesium IV, without any change in the rhythm or blood pressure. Given his hemodynamic instability, the patient was given midazolam one mg IV in preparation for synchronized biphasic cardioversion. The pads were placed in the anterolateral position, and the patient was cardioverted with 100 joules (J), followed by 200 J, without any change in condition. The patient was cardioverted again at 360 J, without any change in rhythm or blood pressure. Finally, the pads were changed to an anterior/posterior placement and the patient cardioverted at 360 J, again without change. A one-liter bolus of Ringers lactate solution IV was administered.

At this point, cardiology was consulted; they recommended giving amiodarone 300 mg IV (in addition to the initial 150 mg given). This was administered without any change in the patient's condition. The cardiologist then evaluated the patient in the ED and gave adenosine six mg IV, followed by 12 mg IV, without effect. Cardiology then ordered lidocaine 100 mg IV bolus, again without any change in the patient's status.

The basic metabolic profile and troponin I and T were normal. The patient was adequately anticoagulated with an international normalized ratio of 3.5 seconds. The complete blood count, hepatic panel, and magnesium level were all normal. The CXR showed streaky opacities in the right midlung zone, representing atelectasis, along with emphysematous changes.

The patient was admitted to the cardiac care unit with a diagnosis of VT refractory to amiodarone and cardioversion. He was continued on an amiodarone, lidocaine, and heparin IV drip. He was also started on a phenylephrine IV drip to keep the mean arterial pressure above 65 mmHg. Review of his most recent echocardiogram (ie, six months prior) showed a large area of thinning and akinesis involving the distal septum, apical and inferoapical walls, with an ejection fraction of 40%. Serial cardiac troponins were elevated, but were thought to be secondary to the multiple cardioversions in the ED.

The patient remained in VT, requiring IV pressor support for hypotension, but was otherwise asymptomatic. An electrophysiologist was consulted and recommended VT ablation with Impella support. The next morning, the patient was taken to the electrophysiology suite and intubated. Synchronized biphasic cardioversion at 125 J was performed, resulting in asystole. Atrial and ventricular pacing was immediately performed and capture obtained; the Impella device was placed and proper positioning confirmed. The

*CPC-EM Capsule*

What do we already know about this clinical entity?

*Electrical storm is defined as three or more sustained episodes of ventricular tachycardia (VT), ventricular fibrillation (VF), or appropriate implantable cardioverter - defibrillator shocks within a 24-hour period.*

What makes this presentation of disease reportable?

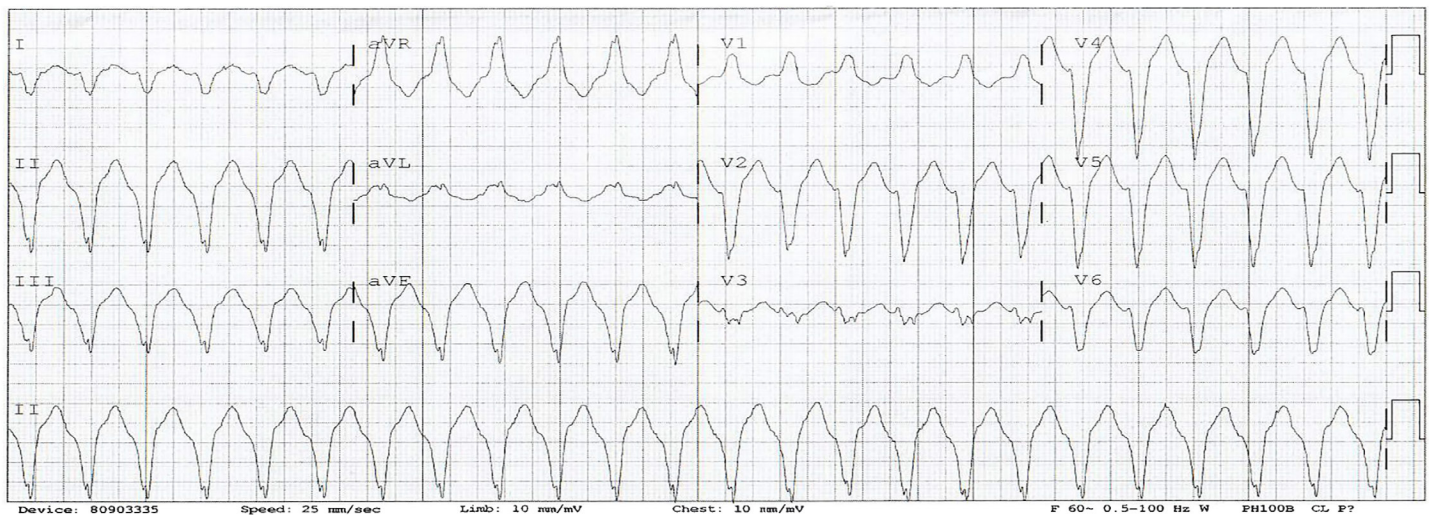
*Despite the fact this patient was hypotensive and in sustained ventricular tachycardia, he only complained of lightheadedness and blurred vision.*

What is the major learning point?

*Electrical storm can present with only vague symptoms and be resistant to traditional medical and electrical therapy, and must be considered in the differential diagnosis of sustained VT or VF.*

How might this improve emergency medicine practice?

*Emergency physicians must be aware of this uncommon, but life-threatening presentation of VT or VF, and how to manage appropriately.*



**Image.** Electrocardiogram demonstrating monomorphic ventricular tachycardia in a patient with electrical storm.

patient developed VT, which was terminated with a single biphasic cardioversion. The decision was made to abandon the ablation procedure due to the development of severe biventricular failure with low cardiac output. The patient was started on IV dobutamine and norepinephrine for the low cardiac output and weaned off the phenylephrine.

Cardiothoracic surgery was consulted for possible surgical options. After careful review, given his condition and past medical history, they felt the patient was not an appropriate candidate for a durable mechanical assist device (i.e., ventricular assist device). Similarly, they did not think he was a candidate for extracorporeal membrane oxygenation, as he would have no exit strategy. The family made the decision to provide comfort care only. The Impella device was turned off and the patient extubated; he died shortly afterwards.

## DISCUSSION

This patient suffered from the electrophysiological phenomenon known as electrical storm. It is defined as three or more sustained episodes of VT, VF, or appropriate ICD shocks within a 24-hour period.<sup>1,2,3</sup> Ventricular tachycardia is the culprit arrhythmia in the majority of cases, but VF can also be seen. In one study examining the causative arrhythmia in patients with electrical storm by interrogation of their ICD, VT was identified as the causative arrhythmia in 52% of cases, and VF in the remaining 48%.<sup>4</sup> Interestingly, previous smaller studies had identified VF as the cause in only 14-40% of cases.<sup>5,6,7</sup> Sustained VT presenting as electrical storm is usually monomorphic and associated with structural heart disease. It is typically due to electrical wave front re-entry around a fixed anatomic barrier, such as scar tissue following a myocardial infarction.<sup>3</sup> In this situation, the abnormal re-entrant circuit is initiated and maintained due to the abnormal conduction present in scarred myocardium.<sup>8</sup> The severity of the presentation and degree of hemodynamic compromise depends on several factors, including the ventricular rate, left ventricular function, the presence and degree of heart failure, and any loss of atrioventricular synchrony.<sup>3,9</sup>

In contrast, polymorphic VT is most often associated with acute ischemia, but can occur in its absence. Other risk factors for polymorphic VT include a prolonged QT interval, myocarditis and hypertrophic cardiomyopathy. If the electrical storm is secondary to polymorphic VT with a long QT interval, acquired causes must be considered, including electrolyte imbalance (i.e., hypokalemia, hypomagnesemia), hypothyroidism, and medications that prolong the QT interval (i.e., erythromycin).<sup>3</sup> Similar to polymorphic VT storm, VF storm can occur, with ischemia as the primary cause. In general, in the setting of an acute coronary syndrome, the electrical storm most likely involves polymorphic VT or VF, as opposed to monomorphic VT. Additional risk factors for polymorphic VT/VF storm include history of hypertension, prior myocardial

infarction, ST-segment changes at presentation, and chronic obstructive pulmonary disease.<sup>1</sup>

One of the diagnostic challenges of electrical storm is its ability to present with a wide variety and severity of symptoms, ranging from lightheadedness and palpitations, to chest pain and cardiac arrest. In our case, the patient presented with vague, nonspecific complaints. Our patient specifically denied chest pain, shortness of breath, or palpitations. He also did not appear to be in any acute distress and was oriented, calm, and conversant throughout his ED visit, despite being tachycardic and hypotensive.

The first step in successfully managing these patients is correctly diagnosing the causative arrhythmia. In addition to the three ventricular arrhythmias previously discussed, the emergency physician must be able to distinguish supraventricular tachycardia (SVT) with aberrancy from VT. This most often occurs in patients with a bundle branch block, a ventricular preexcitation syndrome (i.e., Wolff-Parkinson-White), or a rate-related aberrancy.<sup>3</sup> It is critical the clinician not use the patient's hemodynamic status to distinguish between the two. Patients with VT storm can present hemodynamically stable and with only vague, nonspecific complaints. It is much safer to assume that a patient presenting with an ambiguous, wide-complex tachycardia has VT, especially if they have a history of structural heart disease.<sup>3</sup> Treating SVT with aberrancy with a calcium-channel blocker in a patient actually experiencing VT can result in cardiac arrest and death.

Next, the clinician needs to determine if the patient is hemodynamically stable. For hemodynamically unstable patients with VT or VF, cardioversion or defibrillation is the initial treatment. If the patient is awake and mentating, consider administering a short-acting benzodiazepine (i.e., midazolam) prior to cardioversion. One case report found the use of propofol for sedation prior to cardioversion was associated with both the conversion and suppression of VT in a patient with electrical storm.<sup>8</sup> The initial shock should be with 200 J on a biphasic defibrillator, or 360 J for a monophasic. The usual advanced cardiac life support (ACLS) algorithm is followed, including high-quality cardiopulmonary resuscitation, airway management, epinephrine, and amiodarone. If the patient is hemodynamically stable, it is important to distinguish monomorphic VT from polymorphic VT. While the initial treatment for the two can be the same (i.e., IV amiodarone), if polymorphic VT is the causative rhythm, then the provider needs to simultaneously consider (and treat if present) reversible causes, such as electrolyte abnormality or ischemia.

Given the infrequency of electrical storm, early cardiology consultation is recommended. Increased sympathetic activation has been implicated in the generation of electrical storm, whereas sympathetic blockade has been shown to prevent VF and sudden cardiac death.<sup>8</sup> One study comparing sympathetic blockade for the treatment of VT storm to standard ACLS therapy found that sympathetic blockade with left stellate ganglion blockade,

esmolol or propranolol significantly reduced both the number of VT/VF episodes and the mortality rate.<sup>8,10</sup>

After initial stabilization, patients should undergo catheter ablation of the arrhythmogenic foci of their electrical storm. They should be continued on antiarrhythmic medication, given the risk of recurrence of ventricular tachydysrhythmias. Unfortunately, patients who survive electrical storm are at much higher risk of recurrent ventricular tachydysrhythmias and death.

## CONCLUSION

Electrical storm is an electrophysiologic condition consisting of three or more sustained episodes of VT, VF or appropriate ICD shocks within a 24-hour period.<sup>1,2</sup> It can present with a wide variety of clinical complaints, from mild to life-threatening, and these patients are at high risk for acute decompensation and death. Emergency physicians must be able to recognize and appropriately treat electrical storm. Initial therapy is guided by the patient's presenting arrhythmia, hemodynamic status, standard ACLS therapy, and early cardiology involvement.

Documented patient informed consent and/or Institutional Review Board approval has been obtained and filed for publication of this case report.

---

*Address for Correspondence:* Francis L. Counselman, MD, Eastern Virginia Medical School, Department of Emergency Medicine, 600 Greshman Dr. Raleigh Building, Room 304, Norfolk, Virginia 23507. Email: [counselfl@evms.edu](mailto:counselfl@evms.edu).

*Conflicts of Interest:* By the CPC-EM article submission agreement, all authors are required to disclose all affiliations, funding sources and financial or management relationships that could be perceived as potential sources of bias. The authors disclosed none.

*Copyright:* © 2019 Kamboj et al. This is an open access article distributed in accordance with the terms of the Creative Commons Attribution (CC BY 4.0) License. See: <http://creativecommons.org/licenses/by/4.0/>

---

## REFERENCES

- 2017 AHA/ACC/HRS Guideline for Management of Patients with Ventricular Arrhythmias and the Prevention of Sudden Cardiac Death: Executive summary: A Report of the American College of Cardiology/American Heart Association Task Force on Clinical Practice Guidelines and the Heart Rhythm Society. *Circulation*. 2018;15(10):e190-252.
- European Heart Rhythm Association; Heart Rhythm Society, Zipes DP, Camm AJ, Borggrefe M, et al. ACC/AHA/ESC 2006 Guidelines for Management of Patients with Ventricular Arrhythmias and the Prevention of Sudden Cardiac Death; a report of the American College of Cardiology/American Heart Association Task Force and the European Society of Cardiology Committee for Practice Guidelines (Writing Committee to Develop Guidelines for Management of Patients with Ventricular Arrhythmias and the Prevention of Sudden Cardiac Death). *J Am Coll Cardiol* 2006;48(5):e247-346.
- Eifling M, Razavi M, Massumi A. The evaluation and management of electrical storm. *Tex Heart Inst J*. 2011;38(2):111-21.
- Verma A, Kilicaslin F, Marrouche NF, et al. Prevalence, predictors, and mortality significance of the causative arrhythmia in patients with electrical storm. *J Cardiovasc Electrophysiol*. 2004;15(11):1265-70.
- Credner SC, Klingenheben T, Mauss O, et al. Electrical storm in patients with transvenous implantable cardioverter-defibrillators: incidence, management and prognostic implications. *J Am Coll Cardiol*. 1998;32(7):1909-15.
- Villacastin J, Almendral J, Arenal A, et al. Incidence and clinical significance of multiple consecutive, appropriate, high-energy discharges in patients with implanted cardioverter-defibrillators. *Circulation*. 1996;93(4):753-62.
- Exner DV, Pinski SL, Wyse DG, et al. Electrical storm presages nonsudden death; the antiarrhythmics versus implantable defibrillators (AVID) trial. *Circulation*. 2001;103(16):2066-71.
- Burjorjee JE and Milne B. Propofol for electrical storm; a case report of cardioversion and suppression of ventricular tachycardia by propofol. *Can J Anesth*. 2002;49(9):973-7.
- Saksena S, Ciccone JM, Craelius W, et al. Studies on left ventricular function during sustained ventricular tachycardia. *J Am Coll Cardiol*. 1984;4(3):501-8.
- Nademanee K, Taylor R, Bailey WE, et al. Treating electrical storm: sympathetic blockade versus advanced cardiac life support-guided therapy. *Circulation*. 2000;102(7):742-7.

# Capsaicin: An Uncommon Exposure and Unusual Treatment

Onur M. Yenigun, MD\*<sup>†</sup>  
Mark Thanassi, MD<sup>†</sup>

\*Stanford University Medical Center, Department of Emergency Medicine,  
Palo Alto, California

<sup>†</sup>Kaiser Permanente Medical Center, Department of Emergency Medicine,  
Santa Clara, California

Section Editor: Rick A. McPheeters, DO

Submission history: Submitted October 11, 2018; Revision received March 11, 2019; Accepted March 28, 2019

Electronically published May 20, 2019

Full text available through open access at [http://escholarship.org/uc/uciem\\_cpem](http://escholarship.org/uc/uciem_cpem)

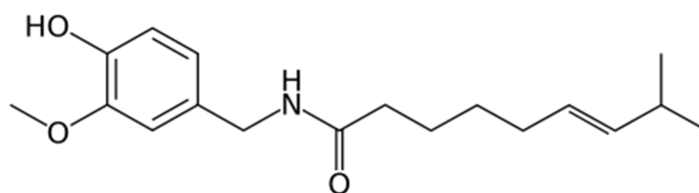
DOI: 10.5811/cpcem.2019.3.41231

Capsaicin, the active component of chili peppers, is an alkaloid that causes tissue irritation and burning especially upon contact with mucous membranes. While favored in certain cuisines around the world, it has also been weaponized in the form of pepper sprays and bear repellents. When significant capsaicin exposures occur, patients may present to the emergency department; thus, providers should be prepared to manage these cases effectively. In this case report we discuss an unusual exposure of capsaicin to the vaginal mucosa with successful treatment. [Clin Pract Cases Emerg Med. 2019;3(3):219-221.]

## INTRODUCTION

In 2017 the American Association of Poison Control Centers reported 2,229 exposures to capsicum-containing peppers, 215 of which were treated in a healthcare facility. An additional 3,320 exposures to capsicum defense sprays were reported, and 833 of these sought medical care.<sup>1</sup> Pepper sprays are prevalent and commercially available in the United States. They contain the active ingredient oleoresin capsicum, which is an oily extract composed primarily of capsaicinoids. These hydrophobic, fat-soluble phenols are produced by chili peppers and elicit significant pain and burning upon tissue and mucous-membrane exposure.<sup>2</sup> Capsaicinoids act as a direct irritant, in addition to causing secondary neurogenic inflammation elicited by capsaicin's (Figure) interaction with sensory neurons via the vanillin receptor subtype 1 (TRPV).<sup>3</sup> The hydrophobic nature of these compounds explains why water and other hydrophilic solvents are minimally effective in alleviating their noxious effects.<sup>4</sup>

While oral mucosal exposures to capsaicin are fairly common, other body areas can be affected in situations such as military training, police actions, and self-defense where non-lethal means of subduing individuals is required. Effects vary based on the anatomic site involved. Dermatological exposures induce burning, hyperalgesia and erythema. Ophthalmic effects include blepharospasm, conjunctivitis, corneal erosions, and periorbital edema, whereas inhalation often results in dyspnea and a burning sensation in the chest.<sup>5,6</sup>



**Figure.** Capsaicin molecular structure, C<sub>18</sub>H<sub>27</sub>NO<sub>3</sub>. C, carbon; H, hydrogen; N, nitrogen; O, oxygen.

Various strategies for neutralizing the pain and burning of capsaicin exposure have been explored including baby shampoo, mixtures of detergent solutions, milk, topical anesthetics, and antacid solutions such as calcium carbonate.<sup>7</sup> Specialized decontaminants such as Sudecon wipes have been developed, as well as SABRE Decon and BioShield sprays commonly used by law enforcement. These methods use detergents, surfactants, or other hydrophobic molecules with the ability to displace and neutralize the compound. The following case report describes an unusual capsaicin exposure and subsequent effective treatment in the emergency department (ED).

## CASE REPORT

A 22-year-old female presented to the ED with the chief complaint of severe vaginal pain and burning. The patient reported that she was a security guard who routinely carried

pepper spray in her bag. She was not aware that the canister had discharged into the bag containing personal items including tampons. When the patient subsequently inserted the tampon she immediately experienced severe vaginal mucosal burning that was not relieved after removal of the tampon; so she sought medical care. The time of exposure to ED arrival was approximately 20 minutes.

Initial presentation revealed a patient in significant distress, crying out in pain. Vital signs were notable for mild tachycardia and otherwise within normal limits. Pertinent exam findings included labial and vaginal erythema and extreme sensitivity. The pepper spray canister was analyzed and found to contain capsaicin without other significant irritant or corrosive additives.

Analgesia was attempted with four milligrams (mg) of intravenous (IV) morphine, which had no observed effect over a 15-minute period. Management was then directed towards neutralizing and displacing the capsaicin from the mucosa. A medium-sized, disposable plastic speculum was obtained and lubricated with 2% lidocaine jelly while two tampons were presoaked in cold, pasteurized 2% skim milk. After patient consent, a standard speculum exam was performed, which was notable for vaginal mucosal erythema without ulcerations or bleeding. The saturated tampons were then placed in-line within the vaginal canal and the speculum was removed leaving the tampons in place with the strings externalized to permit easy removal. An icepack and milk-soaked towel were then placed over the groin.

The patient rapidly achieved significant pain relief within 5-7 minutes with a reported reduction in her pain scale from 10/10 to 3/10. After an approximately 15-minute dwell time the tampons were removed; the patient was observed for a brief period and then discharged to home in stable condition.

## DISCUSSION

Pain management in the ED commonly involves IV and oral medications. This case, however, highlights the fact that topical irritants can be more effectively managed via direct anesthesia and displacement of the offending compound. Topical anesthetics such as lidocaine alleviate pain through inhibition of sensory neurons via sodium channel blockade. Viscous preparations more effectively adhere to the involved tissue, but will be absorbed by mucosal tissue so it is important to keep in mind the toxic dose based on patient weight. Furthermore, lidocaine uptake will be increased in abraded tissue and should be kept in mind. Toxicity can occur at doses over 5-7 mg per kilogram and may result in cardiac arrhythmias or seizures.

Strategies to directly displace an irritant must take into account the nature of the compound. Hydrophilic substances such as water will have little to no efficacy in displacing hydrophobic molecules such as capsaicin from sensory

### *CPC-EM Capsule*

What do we already know about this clinical entity?

*Capsaicin is a hydrophobic, fat-soluble compound that acts as a direct irritant to mucosal surfaces, causing significant pain and burning upon exposure.*

What makes this presentation of disease reportable?

*This is an unusual exposure of capsaicin to the vaginal mucosa with a unique and effective means of management.*

What is the major learning point?

*Capsaicinoids are best displaced by hydrophobic solutes. Furthermore, topical anesthetics such as lidocaine are effective in temporarily alleviating pain via inhibition of sensory neurons.*

How might this improve emergency medicine practice?

*This report adds to the emergency physician's toolbox by providing a quick and effective means of managing an exposure to capsaicin with frequently available products.*

receptors. Milk, on the other hand, is readily available in the hospital setting and contains the hydrophobic protein casein, which effectively displaces capsaicin, quickly relieving pain. Ten percent glucose solutions, also readily available in the ED, have additionally been shown to decrease the pain associated with capsaicin exposure; however, this has only been studied in the oral cavity and may not be generalizable to other areas of the body.<sup>8</sup>

As with all patient chemical exposures, measures should be taken to limit healthcare worker contamination. Appropriate personal protective equipment such as gloves, gowns, and face shields should be used.

## CONCLUSION

While capsaicin exposure is not uncommon and typically involves the face, this case illustrates a novel approach to managing an unusual case of vaginal mucosal involvement and presents effective strategies for pain management using readily available therapies. As emergency physicians we must be prepared to quickly adapt to challenging cases and think

outside the box. The ideal or most accessible treatment may not always be in your department's medical cabinet.

Documented patient informed consent and/or Institutional Review Board approval has been obtained and filed for publication of this case report.

---

*Address for Correspondence:* Onur M. Yenigun, MD, Stanford University Medical Center, Department of Emergency Medicine, 900 Welch Road, Suite 350, Palo Alto, CA 94304. Email: onury@stanford.edu.

*Conflicts of Interest:* By the CPC-EM article submission agreement, all authors are required to disclose all affiliations, funding sources and financial or management relationships that could be perceived as potential sources of bias. The authors disclosed none.

*Copyright:* © 2019 Yenigun et al. This is an open access article distributed in accordance with the terms of the Creative Commons Attribution (CC BY 4.0) License. See: <http://creativecommons.org/licenses/by/4.0/>

---

## REFERENCES

1. Gummin DD, Mowry JB, Spyker DA, et al. 2017 Annual Report of the American Association of Poison Control Centers' National Poison Data System (NPDS): 35th Annual Report. *Clin Toxicol (Phila)*. 2018;56(12):1213-415.
2. Smith J and Greaves I. The use of chemical incapacitant sprays: a review. *J Trauma*. 2002;52(3):595-600.
3. Tominaga M and Julius D. Capsaicin receptor in the pain pathway. *Jpn J Pharmacol*. 2000;83(1):20-4.
4. O'Neill J, Brock C, Olesen AE, et al. Unravelling the mystery of capsaicin: a tool to understand and treat pain. *Pharmacol Rev*. 2012;64(4):939-71.
5. Zollman TM, Bragg RM, Harrison DA. Clinical effects of oleoresin capsicum (pepper spray) on the human cornea and conjunctiva. *Ophthalmology*. 2000;107(12):2186-9.
6. Yeung MF and Tang WY. Clinicopathological effects of pepper (oleoresin capsicum) spray. *Hong Kong Med J*. 2015;21(6):542-52.
7. Kim-Katz SY, Anderson IB, Kearney TE, et al. Topical antacid therapy for capsaicin-induced dermal pain: a poison center telephone-directed study. *Am J Emerg Med*. 2010;28(5):596-602.
8. Nasrawi CW and Pangborn RM. Temporal effectiveness of mouth-rinsing on capsaicin mouth-burn. *Physiol Behav*. 1990;47(4):617-23.

# Severe Cutaneous Findings in a Woman with Dermatomyositis

Sean Wang, MD  
Rachel Keaton, MD  
Zachary Kendrick, MD

University of Texas Health Science Center at San Antonio, Department of  
Emergency Medicine, San Antonio, Texas

Section Editor: Christopher Sampson, MD

Submission history: Submitted September 26, 2018; Revision received March 8, 2019; Accepted March 28, 2019

Electronically published May 20, 2019

Full text available through open access at [http://escholarship.org/uc/uciem\\_cpccem](http://escholarship.org/uc/uciem_cpccem)

DOI: 10.5811/cpccem.2019.3.41058

Dermatomyositis is an inflammatory condition characterized by proximal muscle weakness and classic skin manifestations. The severity of these symptoms, however, can vary greatly. Here we present the case of a woman with a particularly severe form of the cutaneous signs. It is important to recognize the potential severity of this condition as the uncontrolled progression of this disease can lead to respiratory compromise and cardiac involvement. [Clin Pract Cases Emerg Med. 2019;3(3):222-225.]

## INTRODUCTION

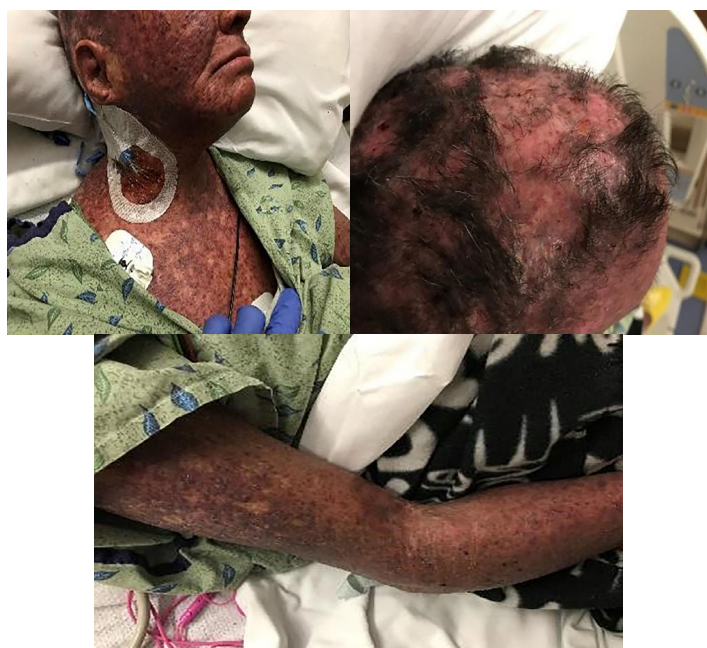Dermatomyositis is an idiopathic, inflammatory condition characterized most commonly by proximal muscle weakness and a variety of skin manifestations.<sup>1</sup> The hallmark dermatologic findings are Gottron's papules and heliotrope eruptions, but the presence and severity of these findings can vary greatly and do not always correlate with other systemic symptoms.<sup>2-3</sup> Described below is the case of a woman with a particularly severe exacerbation in the setting of recent medication cessation.

## CASE REPORT

A 53-year-old female with a history of heart failure, chronic obstructive pulmonary disease, and biopsy-proven diagnosis of dermatomyositis presented to the emergency department (ED) with a one-week history of worsening shortness of breath, periorbital edema, diffuse pain, and intensely pruritic rash. She reported recent abrupt cessation of her prednisone due to concern for complications related to long-term steroid use to include lumbar spine fracture, as well as methicillin-resistant *Staphylococcus aureus* cellulitis that required intravenous (IV) antibiotics. Regarding her rash, she reported that it had been present since diagnosis of dermatomyositis in 2011; however, the rash had varied in intensity depending on medication regimen and compliance.

On arrival, the patient was in moderate distress secondary to pain but was speaking in full sentences. On presentation her vital signs were as follows: afebrile at 98.4 degrees Fahrenheit, tachycardic to 108 beats per minute, respiratory rate 18 beats per minute, oxygen saturation 100% on room air, blood pressure 138/73 millimeters of mercury, and reported 10/10

pain diffusely, but worse on face and scalp. Physical exam was significant for severe rash with erythematous and violaceous macules and patches of excoriation and lichenification over her scalp, face, neck, chest, abdomen, back, and on dorsal surface of arms, with the worst areas on her scalp (Image). Her exam was notable for severe excoriations of the scalp resulting in serosanguinous drainage. There was significant periorbital



**Image.** Severe excoriations and rash over upper chest, scalp, and arm respectively.

edema resulting in difficulty opening her eyes voluntarily. The skin on her arms was sclerosed, making it difficult to obtain dependable vascular access, eventually necessitating placement of a central venous catheter in her right internal jugular. She had mild contractures at both elbows bilaterally and was unable to fully extend her arms. Her lower extremities were notable for 1+ non-pitting edema to her knees. Her abdomen was soft and non-tender, and although the rash was present on her abdomen, the skin was not as sclerosed as the scalp, face, and extremities. The rest of her physical exam was relatively normal with clear lung sounds, no abnormal heart sounds, and an unremarkable neurological exam.

The patient was given 125 milligrams IV methylprednisolone, one liter (L) bolus of normal saline, and pain control medication. Laboratory results revealed alkaline phosphatase 246 international units per liter (IU/L), B-type natriuretic peptide 585 picogram/milliliter, hemoglobin 7.8 grams per deciliter, hematocrit 26.9%, and erythrocyte sedimentation rate 54 millimeters per hour. The remaining laboratory values were as detailed in the Table.

The patient was admitted and remained in the hospital for seven days. She received a course of IV steroids, and we obtained repeat punch biopsies. The biopsies demonstrated thickening of the basement membrane with dermal fibrosis, superficial vascular ectasia, and underlying septal-predominant panniculitis – features consistent with dermatomyositis. Dermatology and rheumatology follow-up appointments were made for the patient prior to discharge, but as of writing this report the patient had not kept her appointments and was not answering phone calls. Attempts are still being made to contact this patient for follow-up and continuation of treatment.

## DISCUSSION

According to a database review study out of Ontario, Canada, only 3.3% of ED visits over a five-year period presented with a primary dermatologic complaint – approximately half of which were for a soft tissue infection rather than autoimmune pathologies. Of that 3.3%, only 4% required inpatient admission, making severe dermatologic conditions a relatively rare occurrence in the ED.<sup>4</sup>

When evaluating patients who present to the ED with a diffuse rash such as found in this case, many other conditions must be considered. Patients with systemic lupus erythematosus (SLE) can also present with facial erythema and photosensitive eruptions. SLE, however, will often spare the nasolabial folds and lacks the pronounced muscular involvement classically seen with dermatomyositis.<sup>5</sup> Scalp dermatomyositis can also appear similar to cutaneous findings seen in psoriasis. However, psoriasis does not exhibit the poikilodermatous changes typically present in dermatomyositis, a characteristic exemplified in the case presented here.<sup>6</sup> One must also consider infectious etiologies or, of more concern,

### *CPC-EM Capsule*

What do we already know about this clinical entity?  
*Dermatomyositis is an autoimmune condition with a wide spectrum of severity. Most treatments only manage symptoms, attempt to slow the progression, and prevent complications.*

What makes this presentation of disease reportable?  
*We present a case of dermatomyositis of particular severity that demonstrates the importance of helping patients overcome obstacles to compliance.*

What is the major learning point?  
*Dermatomyositis, in severe cases, can produce significant scarring, pain, and risk of infection.*

How might this improve emergency medicine practice?  
*Providers need to recognize the spectrum of presentations, enabling us to both treat exacerbations and provide education and follow-up to help patients long-term.*

a bacterial infection superimposed on a pre-existing autoimmune rash. In this case, while it was impossible to differentiate erythema caused by her chronic skin condition from erythema that could indicate infection, there were no other findings concerning for a concurrent infection (i.e., leukocytosis, fever, hypotension).

Dermatomyositis is a rare condition that affects an estimated two in 100,000 annually in the general population and has a 2:1 female predominance.<sup>7</sup> The exact pathogenesis is not fully understood, but much of the literature demonstrates type 1 interferons and/or antibody and complement mediated damage to myofibrils and capillaries.<sup>8-10</sup> Research into the development of the condition is made difficult by the low incidence of the disease. The paucity of large, randomized control studies makes standardized, targeted therapy especially difficult; most treatment regimens still focus on high-dose glucocorticoids and immunosuppressants.

Contributing to the confusion surrounding the disease is the variable expression of symptoms among patients. The severity of the rash will vary from Gottron's papules to a generalized erythroderma with variation presumably attributed to protective factors, genetic allotypes, and how quickly treatment was initiated after diagnosis.<sup>11-12</sup> Clinical features that have been associated with a worse outcome include the following: delay in initiation of treatment for

**Table.** Initial laboratory results for patient with dermatomyositis.

Lab	Result
Complete blood count	
White blood cell	7.35 K/mcL
Hemoglobin	7.8 g/dL
Hematocrit	26.9 %
Platelets	469 K/mcL
Complete metabolic panel	
Sodium	137 mmol/L
Potassium	3.2 mmol/L
Chloride	102 mmol/L
Carbon dioxide	30 mmol/L
Blood urea nitrogen	7 mg/dL
Creatinine	0.38 mg/dL
Glucose	132 mg/dL
Liver	
Aspartate aminotransferase	48 U/L
Alanine aminotransferase	19 U/L
Alkaline phosphatase	246 U/L
Bilirubin (total)	0.6 mg/dL
Albumin	2.0 g/dL
Cardiac	
B-type natriuretic peptide	585 pg/ml
Troponin	<0.030 ng/ml
Other	
Creatine kinase	53 U/L
Lactic acid	1.6 mmol/L
Lipase	259 U/L
Erythrocyte sedimentation rate	54 mm/hr

*K/mcL*, thousands per microliter; *g/dL*, grams per deciliter; *mmol/L*, millimoles per liter; *mg/dL*, milligram per deciliter; *U/L*, units per liter; *pg/ml*, picograms per milliliter; *ng/ml*, nanograms per milliliter; *mm/hr*, millimeter per hour.

more than six months after onset of symptoms; significant muscular weakness at presentation; dysphagia; respiratory muscle weakness; interstitial lung disease; cardiac involvement; and associated malignancy.<sup>13-17</sup> Despite the need for more information and the variable presentation, increased recognition and rapid initiation of treatment has led to an increased rate of remission and an improved five-year mortality for these patients. From 1971 to 1985, the five-year survival rate for inflammatory myopathies was 52-65%, but improved to 75-95% in studies from 2001 to 2006. Among the causes of death in this population, the most common are malignancies, infection, respiratory failure, and cardiovascular disease.<sup>18</sup>

The case of the patient presented here was a particularly serious one. Of the known features associated with poor prognosis, our patient demonstrated almost all of them. While she seemed to have been started on treatment soon after diagnosis in 2011, she had, at best, intermittent treatment due to long periods of non-compliance. Muscular weakness was not a predominant feature at the time of this presentation, but the presence of contractures in her bilateral upper extremities and a documented history of proximal upper extremity weakness were concerning for a poor prognosis. She also had a documented history of dysphagia with repeated neurologic evaluation. These factors combined with her existing comorbidities placed her at significant risk for poor outcome.

## CONCLUSION

Dermatomyositis is a rare, incompletely-understood condition that presents with characteristic cutaneous findings. The patient discussed here presented with a severe form of the rash. It is likely that the severity of her condition was due in significant part to poor compliance and other social issues that prevented her from participating in treatment. Given the wide spectrum of severity seen in dermatomyositis, there remains much work to discover effective, affordable treatment. While not a common occurrence in the ED, it is still of vital importance for emergency physicians to recognize dermatomyositis exacerbations when they present. Given that it is a progressive disease, delays in treatment or misdiagnosis can lead to devastating changes that affect quality of life (scarring, expensive therapies, etc.), and can increase risk of death.

Documented patient informed consent and/or Institutional Review Board approval has been obtained and filed for publication of this case report.

*Address for Correspondence:* Zachary Kendrick, MD, University of Texas Health Science Center at San Antonio, Department of Emergency Medicine, 7703 Floyd Curl Drive, San Antonio, TX 78229. Email: kendrickz@uthscsa.edu.

*Conflicts of Interest:* By the CPC-EM article submission agreement, all authors are required to disclose all affiliations, funding sources and financial or management relationships that could be perceived as potential sources of bias. The authors disclosed none.

*Copyright:* © 2019 Wang et al. This is an open access article distributed in accordance with the terms of the Creative Commons Attribution (CC BY 4.0) License. See: <http://creativecommons.org/licenses/by/4.0/>

## REFERENCES

1. Dalakas MC and Hohlfeld R. Polymyositis and dermatomyositis. *Lancet*. 2003;362(9388):971-82.
2. Dugan EM, Huber AM, Miller FW, et al. Photoessay of the cutaneous manifestations of idiopathic inflammatory myopathies. *Dermatol Online J*. 2009;15(2):1.
3. Auriemma M, Capo A, Meogrossi G, et al. Cutaneous signs of classical dermatomyositis. *G Ital Dermatol Venereol*. 2014;149(5):505-17.
4. Baibergenova A and Shear NH. Skin conditions that bring patients to emergency departments. *Arch Dermatol*. 2011;147:118-9.
5. Lee HJ and Sinha AA. Cutaneous lupus erythematosus: understanding of clinical features, genetic basis, and pathobiology of disease guides therapeutic strategies. *Autoimmunity*. 2006;39(6):433-44.
6. Meglio PD, Villanova F, Nestle FO. Psoriasis. *Cold Spring Harb Perspect Med*. 2014;4(8):a015354.
7. Jacobson DL, Gange SJ, Rose NR, et al. Epidemiology and estimated population burden of selected autoimmune diseases in the United States. *Clin Immunol Immunopathol*. 1997;84(3):223-43.
8. Greenberg SA. Type 1 interferons and myositis. *Arthritis Res Ther*. 2010;12 (Suppl 1):S4.
9. Greenberg SA. Dermatomyositis and type 1 interferons. *Curr Rheumatol Rep*. 2010;12(3):198-203.
10. Greenberg SA. Proposed immunologic models of the inflammatory myopathies and potential therapeutic implications. *Neurology*. 2007;69(21):2008.
11. Shamim EA, Rider LG, Pandey JP, et al. Differences in idiopathic inflammatory myopathy phenotypes and genotypes between Mesoamerican Mestizos and North American Caucasians: ethnogeographic influences in the genetics and clinical expression of myositis. *Arthritis Rheum*. 2002;46(7):1885-93.
12. O'Hanlon TP, Carrick DM, Targoff IN, et al. Immunogenetic risk and protective factors for the idiopathic inflammatory myopathies: distinct HLA-A, -B, -Cw, -DRB1, and -DQA1 allelic profiles distinguish European American patients with different myositis autoantibodies. *Medicine (Baltimore)*. 2006;85(2):111-27.
13. Joffe MM, Love LA, Leff RL, et al. Drug therapy of the idiopathic inflammatory myopathies: predictors of response to prednisone, azathioprine, and methotrexate and a comparison of their efficacy. *Am J Med*. 1993;94(4):379-87.
14. Fafalrak RG, Peterson MG, Kagen LJ. Strength in polymyositis and dermatomyositis: best outcome in patients treated early. *J Rheumatol*. 1994;21(4):643-8.
15. Carpenter JR, Bunch TW, Engel AG, et al. Survival in polymyositis: corticosteroids and risk factors. *J Rheumatol*. 1977;4(2):207-14.
16. Dankó K, Ponyi A, Constantin T, et al. Long-term survival of patients with idiopathic inflammatory myopathies according to clinical features: a longitudinal study of 162 cases. *Medicine (Baltimore)*. 2004;83(1):35-42.
17. Maugars YM, Berthelot JM, Abbas AA, et al. Long-term prognosis of 69 patients with dermatomyositis or polymyositis. *Clin Exp Rheumatol*. 1996;14(3):263-74.
18. Lundberg IE and Forbess CJ. Mortality in idiopathic inflammatory myopathies. *Clin Exp Rheumatol*. 2008;26(5 Suppl 51):S109-14.

# Polymethylmethacrylate Pulmonary Embolism Following Kyphoplasty

Oliver Morris, DO  
Josephin Mathai, DO  
Karl Weller, DO

St. Lucie Medical Center, Department of Emergency Medicine, Port St. Lucie, Florida

Section Editor: Christopher Sampson, MD

Submission history: Submitted January 13, 2019; Revision received March 22, 2019; Accepted April 2, 2019

Electronically published May 20, 2019

Full text available through open access at [http://escholarship.org/uc/uciem\\_cpchem](http://escholarship.org/uc/uciem_cpchem)

DOI: 10.5811/cpcem.2019.4.42324

We report a case of polymethylmethacrylate cement pulmonary embolism (PE) that occurred two days following a minimally invasive kyphoplasty procedure. Our patient developed non-specific rib pain postoperatively followed by dyspnea, prompting presentation to the emergency department. The polymethylmethacrylate cement was visualized on initial chest radiograph and further characterized using computed tomography. The patient was admitted and anticoagulation started, later having an uncomplicated hospital course. The polymethylmethacrylate cement has a well-documented history of leakage and other postoperative complications. Cement PE, while rare, can present similarly to a thrombotic PE and requires adequate long-term anticoagulation with close follow-up. [Clin Pract Cases Emerg Med. 2019;3(3):226-228.]

---

## INTRODUCTION

Vertebral compression fractures make up approximately one half of all osteoporotic fractures in the United States (U.S.), affecting over 700,000 people per year.<sup>1</sup> Patients with compression fractures often experience severe pain that may limit mobility, increase morbidity, and can be a significant source of healthcare resource utilization. Multiple treatment modalities have been used including medical management, pain management, physical therapy, bracing, and surgery. The surgical therapies consist of minimally invasive techniques such as percutaneous balloon kyphoplasty and vertebroplasty, where a cement polymer is injected into the vertebrae to stabilize the osseous structure. There are estimated to be over 25,000 kyphoplasty and vertebroplasty procedures performed in the U.S. each year, and they can be associated with severe intra- and postoperative complications.<sup>2</sup> This case report highlights one of the rarer but often more severe complications, polymethylmethacrylate (PMMA) pulmonary embolism (PE).

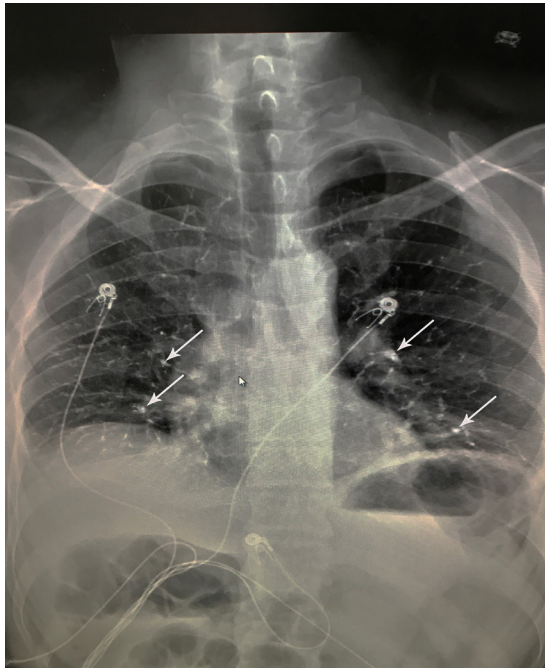
## CASE REPORT

A 43-year-old male construction worker with a history of chronic back pain and recent kyphoplasty two days prior, presented to the emergency department (ED) for the second time that day for dyspnea. The patient had been seen in the ED earlier in the day by another provider for nonspecific lower back and flank pain that was medically treated with improvement of

symptoms. A few hours after arriving home, the patient became dyspneic and returned to the ED for evaluation.

On physical examination, he appeared to be mildly tachypneic. His blood pressure was 105/71 millimeters of mercury, pulse 86 beats per minute (BPM), respiratory rate 20 breaths per minute, and oxygen saturation of 95% on room air. He did not appear to be in respiratory distress with no accessory muscle use. Lungs were clear to auscultation but mildly diminished. He exhibited no wheezing, rhonchi, or rales. The heart sounds were regular, with no audible murmur. Abdomen was soft and nontender, with positive bowel sounds. There was no midline spinal tenderness. He had several well-healing, non-erythematous paraspinal puncture wounds from the kyphoplasty procedure two days prior. The rest of his physical exam was unremarkable.

Initial workup consisted of basic metabolic panel, complete blood count, troponin, electrocardiogram (ECG) and a chest radiograph (CXR). When we applied the Wells criteria for PE, the patient scored 1.5 for having had a surgery in the previous four weeks. This score put him in the low-risk group with a 1.3% chance of PE.<sup>1</sup> The ECG showed a normal sinus rhythm at 85 BPM. The CXR revealed pulmonary cement embolism with mild vascular crowding and atelectasis at the lung bases (Image 1). With this finding, a computed tomography angiography of the chest was ordered, which revealed cement in distal pulmonary arteries consistent with cement emboli along with patchy,



**Image 1.** Chest radiograph of a 43-year-old male depicting multiple hyperdense opacities (arrows) with vascular crowding and atelectasis at lung bases.

ground-glass opacity worrisome for infiltrate (Image 2). The patient was immediately treated with heparin and admitted to the hospital for continued management. While there, he was treated according to guidelines for thrombotic PEs and started on six-month warfarin therapy. He was discharged home two days later.

## DISCUSSION

Kyphoplasty and vertebroplasty are two common surgical techniques used in stabilization and repair of vertebral compression fractures. The procedures are similar in that they use a cement, such as PMMA, which is injected into the vertebral body and allowed to harden. Kyphoplasty differs by first employing a balloon that is inflated in the vertebral body prior to the cement injection. This allows for height restoration of the affected vertebrae. The procedures themselves are minimally invasive, but the efficacy of kyphoplasty and vertebroplasty in osteoporotic vertebral fractures continues to be controversial. Two randomized, placebo-controlled trials found no significant benefit over conservative management.<sup>2,3,4,5</sup> In 2010, as part of its clinical practice guidelines, the American Academy of Orthopaedic Surgeons strongly recommended against vertebroplasty for patients who present with an osteoporotic spinal compression. Since taking that stance, there have been several newer, unblinded trials and meta-analyses published that contradict the initial findings.<sup>6,7,8</sup>

Cement extravasation is the most common and well-known complication of both vertebroplasty and kyphoplasty

### *CPC-EM Capsule*

What do we already know about this clinical entity?

*Polymethylmethacrylate pulmonary embolism is a rare but known complication of kyphoplasty. It has been reported in orthopaedic literature but rarely in emergency medicine.*

What makes this presentation of disease reportable?

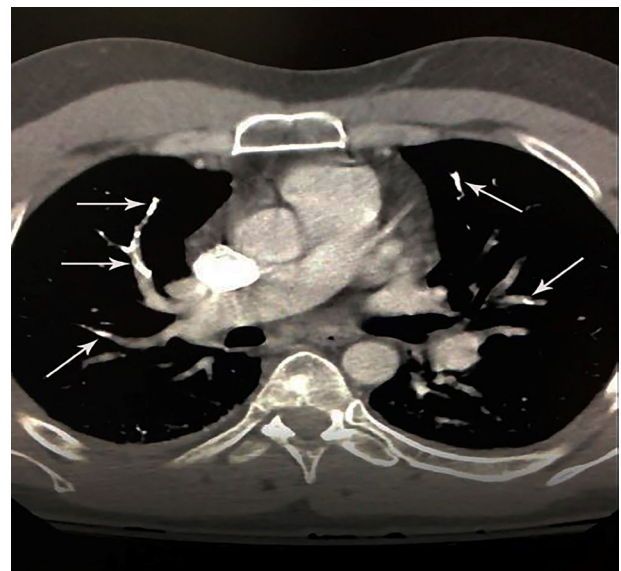
*There have been very few reports of this disease entity in emergency medicine literature, so increasing awareness of post-kyphoplasty complications is essential.*

What is the major learning point?

*The novelty of this disease, along with the morbidity and mortality if left untreated, makes early recognition important.*

How might this improve emergency medicine practice?

*Early recognition of polymethylmethacrylate pulmonary embolism can lead to better patient outcomes.*



**Image 2.** Computed tomographic angiogram of the chest of a 43-year-old male depicting hyperdense material in distal pulmonary arteries (arrows) consistent with cement emboli.

with rates as high as 41% and 18%, respectively.<sup>9,10</sup> This leakage can cause damage to surrounding nerve and tissues, irritation of nerve roots, PE, and even reports of cardiac tamponade. The literature research revealed that the risk of PE ranges from 3.5-23%, with vertebroplasty leakages being more common and more significant.<sup>11</sup> Treatment in these cases has not been well defined, but the consensus is to proceed according to guidelines of thrombotic PEs. Initial heparinization and six months of continuous warfarin therapy is recommended in symptomatic peripheral and asymptomatic central PE along with admission for clinical observation and close follow-up. In rare instances of central symptomatic PE, surgical embolectomy may be considered.<sup>11</sup>

## CONCLUSION

This report highlights the importance of recognizing cement PE in a postoperative kyphoplasty patient presenting for non-specific chest complaints in an otherwise healthy individual and minimal PE risk factors.

Documented patient informed consent and/or Institutional Review Board approval has been obtained and filed for publication of this case report.

---

*Address for Correspondence:* Oliver J. Morris, DO, St. Lucie Medical Center, Department of Emergency Medicine, 1800 SE Tiffany Ave, Port St. Lucie, FL 34652. Email: [oliver.morris@hcahealthcare.com](mailto:oliver.morris@hcahealthcare.com).

*Conflicts of Interest:* By the CPC-EM article submission agreement, all authors are required to disclose all affiliations, funding sources and financial or management relationships that could be perceived as potential sources of bias. The authors disclosed none.

*Copyright:* © 2019 Morris et al. This is an open access article distributed in accordance with the terms of the Creative Commons Attribution (CC BY 4.0) License. See: <http://creativecommons.org/licenses/by/4.0/>

---

## REFERENCES

1. McCall T, Cole C, Dailey A. Vertebroplasty and kyphoplasty: a comparative review of efficacy and adverse events. *Curr Rev Musculoskelet Med*. 2008;1(1):17-23.
2. Laratta JL, Shillingford JN, Lombardi JM, et al. Utilization of vertebroplasty and kyphoplasty procedures throughout the United States over a recent decade: an analysis of the Nationwide Inpatient Sample. *J Spine Surg*. 2017;3(3):364-70.
3. Buchbinder R, Golmohammadi K, Johnston RV, et al. Percutaneous vertebroplasty for osteoporotic vertebral compression fracture. *Cochrane Database Syst Rev*. 2015;(4):CD006349.
4. Savage JW, Schroeder GD, Anderson PA. Vertebroplasty and kyphoplasty for the treatment of osteoporotic vertebral compression fractures. *J Am Acad Orthop Surg*. 2014;22(10):653-64.
5. Klazen CA, Lohle PN, Vries J, et al. Vertebroplasty versus conservative treatment in acute osteoporotic vertebral compression fractures (VERTOS II): an open-label randomised trial. *The Lancet*. 2010;376(9746):1085-92.
6. Guarnieri G, Masala S, Muto M. Update of vertebral cementoplasty in porotic patients. *Interv Neuroradiol*. 2015;21(3):372-80.
7. Yuan WH, Hsu HC, Lai KL. Vertebroplasty and balloon kyphoplasty versus conservative treatment for osteoporotic vertebral compression fractures: A meta-analysis. *Medicine (Baltimore)*. 2016;95(31):e4491.
8. Yaltirik K, Ashour AM, Reis CR, et al. Vertebral augmentation by kyphoplasty and vertebroplasty: 8 years experience outcomes and complications. *J Craniovertebr Junction Spine*. 2016;7(3):153-60.
9. Papanastassiou ID, Filis A, Gerochristou MA, et al. Controversial issues in kyphoplasty and vertebroplasty in osteoporotic vertebral fractures. *Biomed Res Int*. 2014;2014:934206.
10. Papanastassiou P, Phillips FM, Van Meirhaeghe J, et al. Comparing effects of kyphoplasty, vertebroplasty, and non-surgical management in a systematic review of randomized and non-randomized controlled studies. *Eur Spine J*. 2012;21(9):1826-43.
11. Krueger A, Bliemel C, Zettl R, et al. Management of pulmonary cement embolism after percutaneous vertebroplasty and kyphoplasty: a systematic review of the literature. *Eur Spine J*. 2009;18(9):1257-65.

# An Unusual Presentation of Postpartum Spontaneous Coronary Artery Dissection

**Jonathan Alterie, DO\***  
**Francis Villanueva, OMS-IV†**  
**Mohamed Arekat, DO‡**  
**April Brill, DO\***

\*Chicago College of Osteopathic Medicine, Department of Emergency Medicine, Downers Grove, Illinois  
†Chicago College of Osteopathic Medicine, Downers Grove, Illinois  
‡Franciscan Health, Department of Cardiology, Olympia Fields, Illinois

Section Editor: Rick A. McPheeters, DO

Submission history: Submitted October 17, 2018; Revision received March 20, 2019; Accepted April 1, 2019

Electronically published May 20, 2019

Full text available through open access at [http://escholarship.org/uc/uciem\\_cpccem](http://escholarship.org/uc/uciem_cpccem)

DOI: 10.5811/cpcem.2019.4.41305

The postpartum population is one with a unique physiologic profile that predisposes these patients to rare and often life-threatening conditions. Herein, we discuss a case of a 37-year-old, multiparous female who presented to the emergency department with vague chest discomfort 14 days after delivering her sixth child via vaginal delivery. The patient was found to have elevated cardiac biomarkers and was ultimately diagnosed with pregnancy-related spontaneous coronary artery dissection (P-SCAD). This case report discusses the evaluation, pathophysiology, workup, and management of P-SCAD. [Clin Pract Cases Emerg Med. 2019;3(3):229-232.]

---

## INTRODUCTION

Pregnancy-related spontaneous coronary artery dissection (P-SCAD) is a rare complication in the postpartum patient, but it is the most common cause of acute coronary syndrome (ACS) in young females without coronary artery disease.<sup>1,2</sup> Those suffering from P-SCAD typically present with signs and symptoms similar to ACS.<sup>2,3</sup> We report a case of a postpartum female who presented to our emergency department (ED) with atypical signs of ACS and ultimately was diagnosed with P-SCAD. This case exemplifies the need for the emergency physician to keep a broad differential diagnosis for the postpartum patient as these patients comprise a unique population and may not always present in a typical manner.

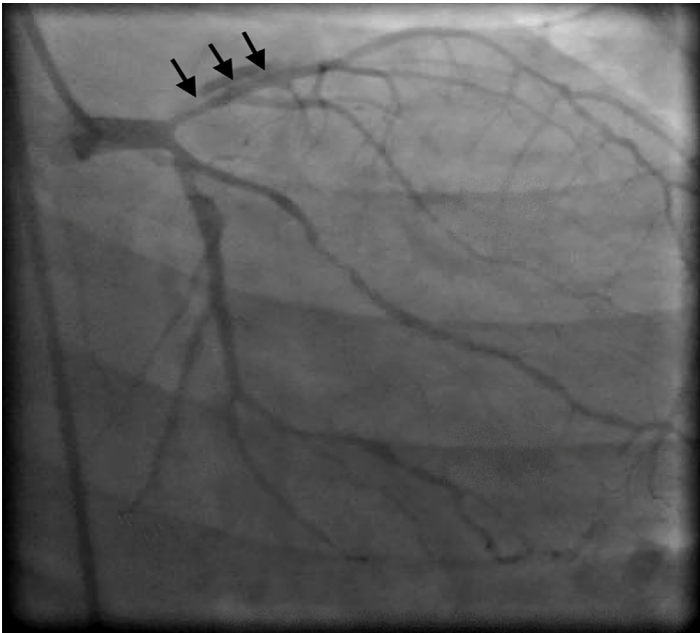## CASE REPORT

A gravida 6, para 6, 37-year-old, well-appearing female presented to our ED approximately two weeks postpartum after a term, singleton vaginal delivery with a chief complaint of non-specific chest pain for one week. Her chest pain was substernal, intermittent, sharp, and non-radiating. It was exacerbated with certain movements and positions such as picking up her children and lying supine. Associated symptoms were shortness of breath and palpitations. Her pregnancy was complicated by gestational diabetes requiring

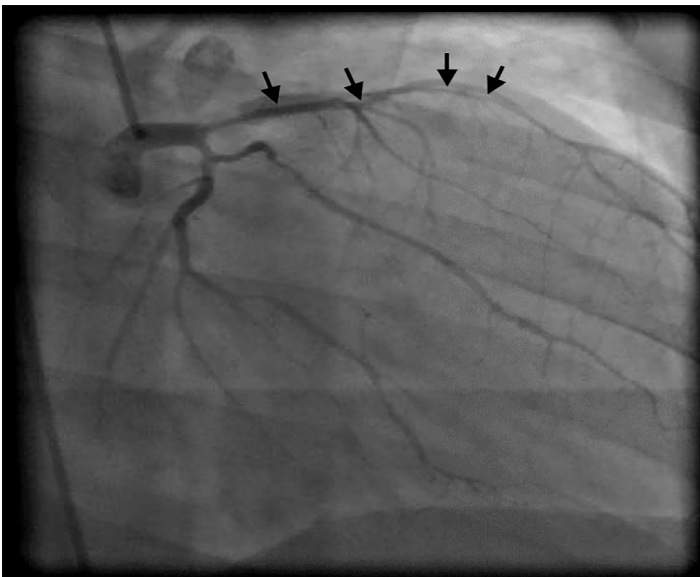
subcutaneous insulin therapy and iron deficiency anemia requiring transfusion of one unit of packed red blood cells.

The patient's family history was significant for a brother who required a cardiac stent for coronary artery disease at the age of 40 and her mother who developed cardiovascular disease later in life. The patient's physical exam and vital signs were unremarkable. However, given her family history of early onset of coronary artery disease and being 14 days postpartum, we pursued a cardiopulmonary workup. The initial workup was notable for an electrocardiogram (ECG) that demonstrated normal sinus rhythm with left axis deviation and a chest radiograph that revealed trace pleural effusions with an enlarged cardiac silhouette. Labs were significant for microcytic anemia: hemoglobin 10.5 grams per deciliter (g/dL) (12.1-15.1 g/dL) and hematocrit 33% (34.9-44.5%) and an initial troponin I elevated at 0.92 nanograms per milliliter (ng/mL) (<0.03 ng/mL). A repeat troponin I was 2.81 ng/mL. A chest computed tomography angiography (CTA) did not reveal pulmonary embolism but confirmed pleural effusions. Cardiology was consulted and elected to take the patient for angiogram due to the rising troponin and negative CTA.

Coronary angiogram revealed a spontaneous dissection extending to the junction of the distal third left anterior descending artery (Images 1 and 2). Due to the extensive nature of the dissection, the interventional cardiology team



**Image 1.** Selective left coronary angiogram in the right anterior coronary oblique caudal projection showing the proximal portion of a spontaneous dissection in the left anterior descending artery (arrows).



**Image 2.** Right anterior oblique caudal projection showing the proximal portion of a spontaneous dissection in the left anterior descending artery extending to the junction of the middle and distal thirds of the left anterior descending artery (arrows).

consulted cardiothoracic surgery, which deemed it more appropriate that the patient undergo coronary artery bypass grafting (CABG). It was intraoperatively that she was found to have bilateral spontaneous coronary dissections

### *CPC-EM Capsule*

What do we already know about this clinical entity?

*Increased cardiovascular risk and anomalies are linked to the pregnant and postpartum states due to the hormonal and hemodynamic demands of pregnancy.*

What makes this presentation of disease reportable?

*This presentation is reportable as the patient presented with rather vague symptoms, worse with movement, as opposed to an acute onset with “tearing” chest pain.*

What is the major learning point?

*Pregnant and post-partm spontaneous coronary dissection may present variably and with vague symptoms. It is important to understand this unique population.*

How might this improve emergency medicine practice?

*This may result in faster identification of the disease process and lead to quicker intervention and better outcomes for pregnant or postpartum patients.*

from the ostia of both the left main and the right main coronary arteries all the way to the distal end of all of the coronary tree. A five-vessel CABG was performed successfully and the patient was discharged postoperative day six.

### **DISCUSSION**

The term dissection refers to the separation of the arterial wall layers, creating an additional channel for blood to flow, which is called a false lumen. This false lumen can collapse upon the true lumen causing occlusion.<sup>2-5</sup> Coronary artery dissection can be characterized as primary (spontaneous) or secondary, the latter being more common.<sup>4</sup> It has been cited that SCAD has a strong association with pregnancy and those suffering from connective tissue disorders.<sup>2,4,5,6</sup> Although the exact cause of P-SCAD is still under investigation, studies postulate that the physiological cardiac demands of pregnancy, hormonal changes in

estrogen and progesterone, and the hemodynamic strains of labor and delivery contribute to the development of intimal wall tears and degeneration within coronary artery walls. Despite having some cardioprotective effects, estrogen may play a role in upregulating the release of matrix metalloproteinases and contributing to the loss of structural support. Increased progesterone levels weaken the arterial wall by disrupting the normal corrugation of elastic fibers and degradation of medial wall collagen. Recurrent exposures to high levels of estrogen and progesterone, as seen in multiparity, can have additive effects to the degeneration of the arterial wall.<sup>2,3,4,7</sup>

Although P-SCAD can affect women considered peripartum, the highest incidence occurs during the postpartum period. According to a retrospective review of the Mayo Clinic's SCAD registry by Tweet et al., nearly all of the women diagnosed with P-SCAD presented within the 12 weeks following delivery, and the greater majority within one week postpartum.<sup>1,7</sup> When compared to other women of childbearing age in the United States population, those who developed P-SCAD were more likely to have suffered from pre-eclampsia and had undergone treatment for infertility. They were also more likely to be multiparous; however, there was no significant difference between these two groups in terms of number of childbirths. Only a small percentage of those suffering from P-SCAD showed risk factors or predisposing health conditions that are typical of non-pregnancy related SCAD, such as fibromuscular dysplasia, antiphospholipid syndrome, Marfan syndrome, connective tissue dysplasia, and Ehlers-Danlos syndrome.<sup>1,3</sup>

The most common signs and symptom are those similar to ACS.<sup>1-3</sup> According to one study, which compiled data from the three largest literature reviews of P-SCAD, the most common presentations included chest pain, dyspnea, acute myocardial infarction, congestive heart failure, ventricular arrhythmia, sudden cardiac death, and cardiogenic shock.<sup>3</sup> Eliciting a medical history will often show no other predisposing risk factors for cardiovascular disease other than the patient being postpartum.<sup>8</sup>

Findings consistent with P-SCAD are ST-segment elevation myocardial infarction (STEMI), non-STEMI, left main or multivessel SCAD, or a left ventricular dysfunction of less than 35%.<sup>3</sup> Workup may demonstrate ischemic changes on ECG, pericardial tamponade, or elevated cardiac biomarkers.<sup>3,6</sup> In a majority of cases, ECG will show ST-segment changes in a left coronary artery system distribution.<sup>1,8</sup> Diagnosis is confirmed with coronary angiography as CTA has inadequate spatial resolution to visualize SCAD in smaller coronary arteries.

Current management of P-SCAD is controversial and without clear guidelines.<sup>1,2</sup> P-SCAD may be treated with conservative therapy, percutaneous coronary intervention (PCI), temporizing measures such as extracorporeal membrane oxygenation or CABG surgery for the most severe cases.<sup>7-12</sup> Conservative management may be considered in patients who have no evidence of ongoing ischemia and no significant stenosis

on cardiac catheterization. This management includes the use of heparin, beta blockers, calcium channel blockers, nitrates, and antiplatelet therapy. However, these therapies are often only short-term solutions. PCI is often the treatment of choice for involvement of a single vessel and CABG is preferred in a patient with multi-vessel dissection, complex lesions, or failed PCI.<sup>3</sup> Treatment is chosen on a case by case basis depending on severity of the dissection(s), amount of salvageable myocardium, and the overall clinical presentation.

This case report brings to light a postpartum female with multiple risk factors for P-SCAD who presented with vague and poorly explained chest pains. We pursued a workup due to her risk factors, which placed her into a higher risk subpopulation. The purpose of this case report is to highlight the need for recognition of risk factors for a certain condition such as P-SCAD as these factors may sometimes (as in our case) be the only heralding findings of a case that spurs a workup in a certain direction.

## CONCLUSION

P-SCAD is a rare condition that is under-represented in the emergency medicine literature. The patient discussed in our case represents a novel presentation of P-SCAD. Without obtaining a thorough and complete history, a clinician may have easily misdiagnosed her with reflux or postpartum musculoskeletal pain. This case demonstrates that not all patients with P-SCAD present with obvious signs and symptoms of ACS. The threshold to work up a postpartum female presenting with poorly explained symptoms of acute coronary syndrome should be low, and P-SCAD should be on the differential no matter how innocuous the presentation.

Documented patient informed consent and/or Institutional Review Board approval has been obtained and filed for publication of this case report.

---

*Address for Correspondence:* Jonathan D. Alterie, DO, Midwestern University Chicago College of Osteopathic Medicine, Department of Emergency Medicine, 555 31st Street Cardinal Hall, Suite 530, Downers Grove, IL, 60515. Email: [jalterie66@midwestern.edu](mailto:jalterie66@midwestern.edu).

*Conflicts of Interest:* By the *CPC-EM* article submission agreement, all authors are required to disclose all affiliations, funding sources and financial or management relationships that could be perceived as potential sources of bias. The authors disclosed none.

*Copyright:* © 2019 Alterie et al. This is an open access article distributed in accordance with the terms of the Creative Commons Attribution ([CC BY 4.0](http://creativecommons.org/licenses/by/4.0/)) License. See: <http://creativecommons.org/licenses/by/4.0/>

---

## REFERENCES

1. Tweet MS, Hayes SN, Codsi E, et al. Spontaneous coronary artery dissection associated with pregnancy. *J Am Coll Cardiol*. 2017;70(4):426-35.
2. Vijayaraghavan R, Verma S, Gupta N, et al. Pregnancy-related spontaneous coronary artery dissection. *Circulation*. 2014;130(21):1915-20.
3. Sheikh AS and O'Sullivan M. Pregnancy-related spontaneous coronary artery dissection: two case reports and a comprehensive review of literature. *Heart Views : The Official Journal of the Gulf Heart Association*. 2012;13(2),53-65.
4. Winchester DE and Pepine CJ. (2017). Nonobstructive atherosclerotic and nonatherosclerotic coronary artery disease. In Fuster V, Harrington RA, Narula J, Eapen ZJ (Eds.). *Hurst's The Heart*, 14e. New York, NY: McGraw-Hill. Available at: <http://accessmedicine.mhmedical.com.mwu.idm.oclc.org/content.aspx?bookid=2046&sectionid=176555511>. Accessed on September 14, 2017.
5. Bashore TM, Granger CB, Jackson KP, et al. (2018). Heart disease. In Papadakis MA, McPhee SJ, Rabow MW (Eds.). *Current Medical Diagnosis & Treatment*. New York, NY: McGraw-Hill. Available at: <http://accessmedicine.mhmedical.com.mwu.idm.oclc.org/content.aspx?bookid=2192&sectionid=168190671>. Accessed on September 14, 2017.
6. Saw J, Aymong E, Sedlak T, et al. Spontaneous coronary artery dissection: association with predisposing arteriopathies and precipitating stressors and cardiovascular outcomes. *Circ Cardiovasc Interv*. 2014;7(5):645-55.
7. Almeda FQ, Barkatullah S, Kavinsky CJ. Spontaneous coronary artery dissection. *Clin Cardiol*. 2004;27:377-80.
8. Higgins III GL, Borofsky JS, Irish CB, et al. Spontaneous peripartum coronary artery dissection presentation and outcome. *J Am Board Fam Med*. 2010;26(1):82-9.
9. Martins JL, Afreixo V, Santos L, et al. Medical treatment or revascularisation as the best approach for spontaneous coronary artery dissection: a systematic review and meta-analysis. *Eur Heart J Acute Cardiovasc Care*. 2018;7(7):614-23.
10. Evans R. Postpartum spontaneous coronary artery dissection and the use of veno-arterial extra-corporeal membrane oxygenation. *Nurs Crit Care*. 2014;19(6):304-9.
11. Behrooz Shamloo BK, Chintala RS, Nasur A, et al. Spontaneous coronary artery dissection: aggressive vs. conservative therapy. *J Invasive Cardiol*. 2010;22(5):222-8.
12. Vanzetto G, Berger-Coz E, Barone-Rochette G, et al. Prevalence, therapeutic management and medium-term prognosis of spontaneous coronary artery dissection: results from a database of 11,605 patients. *Eur J Cardiothorac Surg*. 2009;35(2):250-4.

# Central Retinal Artery Occlusion Associated with Carotid Artery Occlusion

Wells Weymouth, MD  
Craig Pedersen, MD

San Antonio Military Medical Center, Department of Emergency Medicine, Fort Sam Houston, Texas

Section Editor: Rick A. McPheeters, DO

Submission history: Submitted September 5, 2018; Revision received March 26, 2019; Accepted April 1, 2019

Electronically published May 21, 2019

Full text available through open access at [http://escholarship.org/uc/uciem\\_cpccem](http://escholarship.org/uc/uciem_cpccem)

DOI: 10.5811/cpcem.2019.4.40847

Sudden, painless vision loss in patients with stroke risk factors is suspect for central retinal artery occlusion (CRAO), an ophthalmic emergency that in addition to ocular treatment warrants a thorough neurologic and vascular evaluation. In addition to the high risk of concurrent stroke, carotid artery stenosis and occlusion is often overlooked during the initial evaluation. Here we report a case of CRAO with concurrent ipsilateral complete left internal carotid artery (ICA) occlusion and right ICA critical narrowing, dissection and pseudoaneurysm, which subsequently improved with prompt hyperbaric oxygen therapy. [Clin Pract Cases Emerg Med. 2019;3(3):233-236.]

## INTRODUCTION

Known commonly as a “stroke of the eye,” central retinal artery occlusion (CRAO) presents with sudden, severe, painless monocular visual loss, and is an ophthalmic emergency. While the presentation is rare (the incidence of CRAO is estimated around 1.9/100,000 in the United States) the consequences can be dire.<sup>1</sup> The strong association between CRAO and stroke is well known, and prompt evaluation of the carotid arteries is paramount in order to expedite definitive treatment, especially since ipsilateral carotid artery disease is known to occur in 50% of these patients.<sup>2,3</sup>

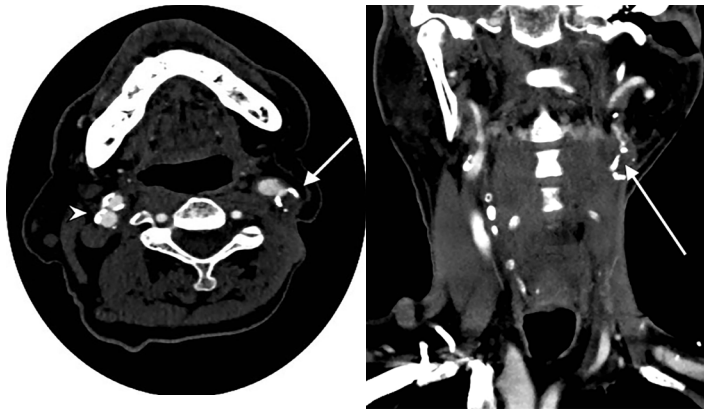
## CASE REPORT

A 66-year-old male with known history of hypertension and hypothyroidism presented to the emergency department (ED) with sudden, painless loss of vision in his left eye of two hours duration. The patient reported that he had sneezed four times in rapid succession and then stated he lost vision in his left eye, but experienced no eye pain. The patient then drove himself to the ED. He denied any other accompanying symptoms on extensive review of systems. Examination revealed 20/30 vision in his right eye with corrective lenses (eyeglasses), but no light perception in his left. The left pupil did not have any direct light response but had preserved consensual response. Consensual light response was absent in the right pupil, but direct response was preserved. Point-of-care ocular ultrasound was performed but did not reveal

any apparent abnormality. The patient had no other focal neurological deficits and was found to be in normal sinus rhythm on electrocardiogram. Tonometry was not available at this facility nor were ophthalmologic services. A head computed tomography (CT) without contrast showed no acute hemorrhage or apparent infarct and he was sent emergently to the ophthalmology clinic at the tertiary care hospital several miles away in consultation with the receiving ophthalmologist.

In the ophthalmology clinic, the patient was confirmed to have multiple arterial thrombi with characteristic cherry-red spot on exam consistent with CRAO. He was then transferred directly from the ophthalmology clinic to the hyperbaric chamber for hyperbaric oxygen therapy. Upon the initial dive at 33 feet of therapy he began seeing letters and his vision continued to improve after one hour at 60 feet. Vision in the affected eye improved from solely light perception to 20/50 at 24 hours, with subsequent resolution of symptoms. Shortly thereafter, while inpatient he received CT angiography of the neck and head (Image), which revealed complete left internal carotid artery (ICA) occlusion at its origin with retrograde filling of the distal cervical and intracranial portions. The right ICA showed regions concerning for dissection with associated pseudoaneurysm formation, with another region just distal with critical narrowing of the cervical internal carotid artery to approximately one millimeter.

Several days later the patient underwent successful transcarotid artery revascularization in the operating room.



**Image.** Computed tomography angiography of the head and neck in coronal (right) and axial (left) views demonstrating complete occlusion of the left internal carotid artery (ICA) (arrows) and critical narrowing of the right ICA (arrowhead), in a patient with right central retinal artery occlusion.

## DISCUSSION

In the setting of sudden, painless vision loss, the diagnosis of CRAO must be at the top of the differential, as it portends the most vision- and life-threatening underlying diagnosis and with associated high mortality. Typical patients have severe monocular visual loss, with 80% of patients having a visual acuity of 20/400 or worse as a result of loss of blood supply to the inner retinal layers.<sup>4</sup> Analogous to ischemic cerebral stroke, the pathology is thromboembolic and the majority are due to carotid artery disease, primarily due to atherosclerotic plaques. As demonstrated in this case, one cannot neglect carotid stenosis (and the heart) as other potential sources of emboli.

Risk factors mimic those of cerebral stroke and include hypertension, diabetes mellitus, carotid artery disease, coronary artery disease, a history of transient ischemic attacks or cerebral vascular accidents, and smoking tobacco, among others.<sup>5</sup> In fact, atherosclerotic disease is the leading cause of CRAO in patients aged 40-60 years.<sup>6</sup> There have also been several case series of CRAO during and post angiography and stenting.<sup>7,8</sup> Patients typically present with crippling monocular vision loss, and clinicians should focus on detailed ophthalmic and neurologic exams. As in this case, the classic “cattle trucking” or “box-carring,” which is a discontinuous appearance of the vessels due to segmentation of the blood column in the arteries, and the cherry-red spot in the macula, may be difficult to see without a dilated fundoscopic exam.<sup>8</sup>

Given the emergent nature of the condition, swift imaging and treatment is critical. It is suspected that irreversible retinal damage occurs without recovery of vision within six and a half hours, although animal models show partial recovery only up to 240 minutes.<sup>9,10</sup> Given these constraints, it is critical to obtain an expeditious CT to assess for intracranial infarct

### *CPC-EM Capsule*

What do we already know about this clinical entity?

*Central retinal artery occlusion is an ophthalmic emergency which requires both prompt neurologic and ophthalmic evaluation and advanced imaging.*

What makes this presentation of disease reportable?

*Data on treatment efficacy for tissue plasminogen activator, hyperbaric treatment, and anterior chamber paracentesis is limited.*

What is the major learning point?

*Hyperbaric oxygen therapy is an underutilized treatment, and if available, should be strongly considered within eight hours.*

How might this improve emergency medicine practice?

*After central retinal artery occlusion is recognized, perform advanced imaging, and in conjunction with ophthalmic consultation, consider hyperbaric oxygen.*

as soon as possible. In at least one study, 32% had acute or subacute brain infarct seen on imaging.<sup>11</sup> Given the propensity for arterial occlusion and severe carotid stenosis (up to 40% of patients), we would recommend CT angiography of the neck and head be done as well, which is consistent with current guidelines.<sup>12</sup> One study demonstrated that nine of nine patients with CRAO had angiographically demonstrable ipsilateral carotid artery disease.<sup>13</sup> As magnetic resonance imaging is more time consuming, it was this team’s opinion that it could be done while inpatient.

Treatment for CRAO targets acute reperfusion of the central retinal artery; however, the exact choice of treatment is still a matter of debate. In this case, the physicians chose hyperbaric treatment and achieved vision recovery. The use of this modality is relatively rare; it is offered only 7% of the time, even though based on the American Heart Association classification of evidence, treatment of CRAO with hyperbaric oxygen therapy is Level IIb.<sup>14,15</sup> Literature review demonstrates that overall 65% of cases have shown improvement when treated with hyperbaric oxygen, although it is apparent that a significant portion of patients will benefit from oxygen alone. Given the relative ubiquity of supplemental oxygen and relatively low risk,

it seems logical to place the patient on 100% oxygen by nasal cannula or non-rebreather upon presentation. However, if there is no significant improvement with normobaric oxygen within 15 minutes, one algorithm proposes to proceed immediately to hyperbaric oxygen at two atmospheres of pressure.<sup>16</sup>

As with most instances of ischemia, the colloquialism “time is vision” may apply here as well. Best outcomes likely result when applied within the first eight hours from the onset of visual impairment.<sup>17</sup> The most widely studied treatment is tissue plasminogen activator, which binds to the site of the thrombus and facilitates the conversion of plasminogen to plasmin to dissolve the clot. Given the similarities between ischemic stroke and CRAO, it does seem biologically plausible it would be effective. It would appear, however, that data on the subject are mixed, with at least two large reviews demonstrating improvement of visual acuity as well as relative safety, and two other large multicenter randomized controlled trials failing to show the same but demonstrating severe side effects including the feared complication of intracranial hemorrhage.<sup>9,18-22</sup> Another treatment that is well described and commonly used although its efficacy is unproven, is anterior chamber paracentesis. It functions to lower intraocular pressure to increase dilatation of the retinal arteries due to vascular tortuosity produced from distortion of the globe.<sup>23</sup> Unfortunately, a 2009 Cochrane review found no treatment modality is more effective than placebo.<sup>24</sup>

Even after treatment, if any, these patients remain at high risk for ischemic stroke, with the incident rate ratio peaking at one to seven days after CRAO and remaining elevated for the first 30 days.<sup>25</sup>

## CONCLUSION

Prompt recognition of CRAO symptoms should be followed by a detailed neurologic and vascular evaluation for concurrent stroke and carotid artery stenosis or occlusion. These patients are also at risk for ischemic events after treatment, largely because atherosclerotic disease is the primary underlying diagnosis for both conditions. Hyperbaric oxygen is an underused treatment modality with promising results. Patients presenting to the ED within eight hours of symptom onset should be considered for this therapy. This case highlights the high risk to these patients, which requires intensive workup and admission from the ED and while inpatient, as well as provides further evidence for the successful use of hyperbaric oxygen treatment.

Documented patient informed consent and/or Institutional Review Board approval has been obtained and filed for publication of this case report.

*Address for Correspondence:* Wells Weymouth, MD, San Antonio Military Medical Center, Department of Emergency Medicine, 3551 Roger Brooke Dr., Fort Sam Houston, Texas 78234. Email: weymouthmd@gmail.com.

*Conflicts of Interest:* By the CPC-EM article submission agreement, all authors are required to disclose all affiliations, funding sources and financial or management relationships that could be perceived as potential sources of bias. The views expressed here are those of the authors and do not reflect the official policy of the Department of the Army, the Department of Defense, or the US Government.

*Copyright:* © 2019 Weymouth et al. This is an open access article distributed in accordance with the terms of the Creative Commons Attribution (CC BY 4.0) License. See: <http://creativecommons.org/licenses/by/4.0/>

## REFERENCES

1. Leavitt JA, Larson TA, Hodge DO, et al. The incidence of central retinal artery occlusion in Olmsted County, Minnesota. *Am J Ophthalmol.* 2011;152(5):820-3.e2.
2. Merchut MP, Gupta SR, Naheedy MH. The relation of retinal artery occlusion and carotid artery stenosis. *Stroke.* 1988;19(10):1239-42.
3. Zhang LY, Zhang J, Kim RK, et al. Risk of acute ischemic stroke in patients with monocular vision loss of vascular etiology. *J Neuroophthalmol.* 2018;38(3):328-33.
4. Hayreh SS and Zimmerman MB. Central retinal artery occlusion: visual outcome. *Am J Ophthalmol.* 2005;140(3):376-91.
5. Hayreh SS, Podhajsky PA, Zimmerman MB. Retinal artery occlusion: associated systemic and ophthalmic abnormalities. *Ophthalmology.* 2009;116(10):1928-36.
6. Georgalas I, Pagoulatos D, Koutsandrea C, et al. Sudden unilateral painless loss of vision. *BMJ.* 2014;349:g4117.
7. Sun R, Peng XY, You QS, et al. Branch retinal artery occlusion following carotid stenting: a case report. *Exp Ther Med.* 2016;12(4):2183-6.
8. Tomsak RL, Hanson M, Gutman FA. Carotid artery disease and central retinal artery occlusion. *Cleve Clin Q.* 1979;46(1):7-11.
9. Chen CS, Lee AW, Campbell B, et al. Efficacy of intravenous tissue-type plasminogen activator in central retinal artery occlusion: report from a randomized, controlled trial. *Stroke.* 2011;42(8):2229-34.
10. Hattenbach LO, Kuhl-Hattenbach C, Scharrer I, et al. Intravenous thrombolysis with low-dose recombinant tissue plasminogen activator in central retinal artery occlusion. *Am J Ophthalmol.* 2008;146(5):700-6.
11. Wagner B, Lindenbaum E, Logue C, et al. 265 Rethinking the standard of care for patients with central retinal artery occlusion. *Ann Emerg Med.* 2017;70(4):S105.
12. Olsen TW, Pulido JS, Folk JC, et al. Retinal and ophthalmic artery occlusions preferred practice pattern. *Ophthalmology.* 2017;124(2):P120-P143.
13. Kollarits CR, Lubow M, Hissong SL. Retinal strokes: I. Incidence of

- carotid atheromata. *JAMA*. 1972;222(10):1273-5.
14. Youn TS, Lavin P, Patrylo M, et al. Current treatment of central retinal artery occlusion: a national survey. *J Neurol*. 2018;265(2):330-5.
  15. Gibbons RJ, Smith S, Antman E. American College of Cardiology/ American Heart Association clinical practice guidelines: Part I: where do they come from? *Circulation*. 2003;107(23):2979-86.
  16. Murphy-Lavoie H, Butler F, Hagan C. Central retinal artery occlusion treated with oxygen: a literature review and treatment algorithm. *Undersea Hyperb Med*. 2012;39(5):943-53.
  17. Hadanny A, Maliar A, Fishlev G, et al. Reversibility of retinal ischemia due to central retinal artery occlusion by hyperbaric oxygen. *Clin Ophthalmol*. 2016;11:115-25.
  18. Schumacher M, Schmidt D, Jurklics B, et al. Central retinal artery occlusion: local intra-arterial fibrinolysis versus conservative treatment, a multicenter randomized trial. *Ophthalmology*. 2010;117(7):1367-75.e1.
  19. Zhang X, Ji X, Luo Y, et al. Intra-arterial thrombolysis for acute central retinal artery occlusion. *Neurol Res*. 2009;31(4):385-9.
  20. Aldrich EM, Lee AW, Chen CS, et al. Local intra-arterial fibrinolysis administered in aliquots for the treatment of central retinal artery occlusion: the Johns Hopkins Hospital experience. *Stroke*. 2008;39(6):1746-50.
  21. Noble J, Weizblit N, Baerlocher M, et al. Intra-arterial thrombolysis for central retinal artery occlusion: a systematic review. *Br J Ophthalmol*. 2008;92(5):588-93.
  22. Biousse V, Calvetti O, Bruce BB, et al. Thrombolysis for central retinal artery occlusion. *J Neuroophthalmol*. 2007;27(3):215-30.
  23. Beatty S and Eong KA. Acute occlusion of the retinal arteries: current concepts and recent advances in diagnosis and management. *J Accid Emerg Med*. 2000;17(5):324-9.
  24. Varma D, Cugati S, Lee A, et al. A review of central retinal artery occlusion: clinical presentation and management. *Eye (Lond)*. 2013;27(6):688-97.
  25. Park SJ, Choi N-K, Yang BR, et al. Risk and risk periods for stroke and acute myocardial infarction in patients with central retinal artery occlusion. *Ophthalmology*. 2015;122(11):2336-43.e2.

# Superficial Thrombosis of Pelvic Congestion Syndrome Mimicking Pelvic Abscess

Adrian Romero, MD\*  
 Janae Hohbein, DO†  
 Shana E.N. Ross, DO, MSc‡

\*University of Illinois at Chicago, Department of Emergency Medicine, Chicago, Illinois  
 †Newark Beth Israel Medical Center, Department of Emergency Medicine, Newark, New Jersey  
 ‡University of Illinois Hospital & Health Science Systems, Department of Emergency Medicine, Chicago, Illinois

Section Editor: Shadi Lahham, MD, MS

Submission history: Submitted January 25, 2019; Revision received March 27, 2019; Accepted April 2, 2019

Electronically published May 29, 2019

Full text available through open access at [http://escholarship.org/uc/uciem\\_cpccm](http://escholarship.org/uc/uciem_cpccm)

DOI: 10.5811/cpcem.2019.4.42527

Pelvic congestion syndrome (PCS) is an uncommon illness that is typically diagnosed after chronic pelvic pain. We present a case of superficial thrombosis of pelvic veins from PCS that presented to the emergency department (ED) as a previous diagnosis of pelvic abscess with cellulitis. PCS was diagnosed in the ED by computed tomography after an abnormal point-of-care ultrasound. Here we describe this unusual presentation and our approach to the diagnosis. [Clin Pract Cases Emerg Med. 2019;3(3):237-239.]

## INTRODUCTION

Pelvic congestion syndrome (PCS) has been estimated to account for 33% of chronic pelvic pain.<sup>1</sup> The diagnosis of PCS is typically defined as chronic pelvic pain lasting greater than six months with visible congestion of pelvic veins.<sup>2</sup> PCS usually affects multiparous women in the reproductive age group. There have been no reported cases in menopausal women, which may be related to the decline in estrogen that leads to venous dilation.<sup>3</sup>

While the pathology is unclear, multiple cases of PCS have been described in patients with gross dilatation, incompetence, and reflux of the ovarian veins. Pregnancy can be associated with up to a 50% increase in venous capacity, resulting in venous incompetence.<sup>4</sup> Thus, it stands to reason that PCS is related to these venous changes, supporting the potential link between multiparity and PCS. However, as all women with venous congestion do not have pelvic pain, a causal relationship has not been established.

## CASE REPORT

A 52-year-old woman with a history of chronic deep vein thrombosis (DVT) on warfarin, presented to the emergency department (ED) for expedited incision and drainage (I&D) of a mons pubis abscess. She complained of progressively worsening mons pubis pain, redness, and swelling for the prior week. The patient had been seen by her primary care physician

at the onset of symptoms and diagnosed with a mons pubis abscess. She was prescribed oral antibiotics (sulfamethoxazole/trimethoprim) and scheduled for an I&D later that day with a general surgeon. However, due to intractable pain after sexual intercourse the previous night, she presented to the ED to have it drained sooner. She denied any systemic symptoms including fevers, chills, nausea, vomiting, dysuria, hematuria, vaginal bleeding, or unusual vaginal discharge. In addition, the patient reported intermittent lower abdominal pain for years, which had not recently changed. On further questioning she admitted to not being compliant with warfarin on multiple episodes in the past, but was compliant at the time of presentation.

Physical exam revealed a middle-aged obese female in no acute distress. Vital signs on presentation were significant for a temperature of 36.1 degrees Celsius, pulse rate of 66 beats per minute, and a blood pressure of 166/82 millimeters of mercury. Evaluation of the genitalia revealed a warm, indurated, fluctuant, 5 centimeter (cm) x 5cm x 4 cm left mons pubis area of swelling with moderate tenderness to palpation, and overlying induration. Point-of-care ultrasound (POCUS) revealed multiple fluid-filled tubular structures tracking into the abdomen and left femoral vein with intermittent areas of color flow.

Given the unusual ultrasound appearance, a computed tomography (CT) of the abdomen and pelvis with intravenous contrast was ordered along with laboratory studies. White blood

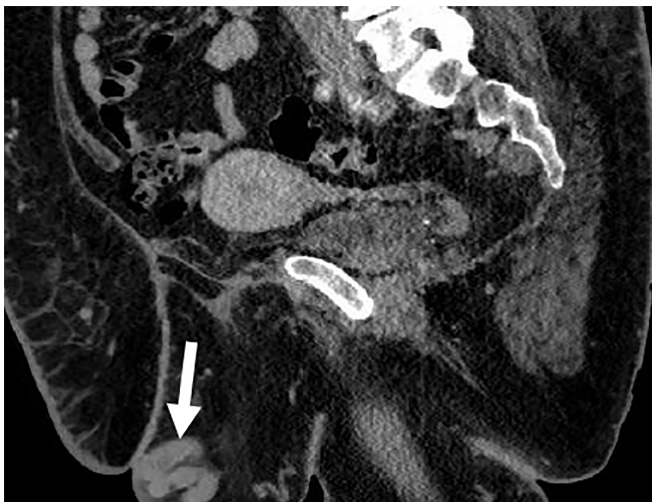
cell count and international normalized ratio were  $8.8 \times 10^3$ /microliters and 2.9 respectively. CT revealed multiple prominent collateral venous vessels over the mons pubis and lower abdominal wall consistent with PCS (Image 1 and 2). I&D was not performed and vascular surgery was consulted. Vascular surgery noted a superficial venous thrombosis within the collection of the mons pubis vessels resulting in a clinical picture similar to a mons pubis abscess.

The patient was provided outpatient follow-up with vascular surgery for monitoring and potential thrombectomy. She was also counseled on medication compliance. At follow-up, the pain and swelling had resolved with hot compresses and continuation of anticoagulation therapy.

## DISCUSSION

In the ED it can be easy to anchor on a diagnosis made by an outpatient provider and continue the treatment without being critical of the proposed plan. This patient presented to the ED with a diagnosis and a treatment plan already in motion. A POCUS and thorough history were enough to raise our suspicion and we ordered further studies. This practice should be applied to all suspected abscesses but especially those in the pelvic area of female patients.

In venous congestion of the pelvis, two closely related entities may present as chronic pelvic pain: PCS and vulvovaginal varicosities.<sup>5</sup> While the pathophysiology of these two conditions is not fully understood the end result is vascular insufficiency of the pelvic venous system. The etiology for vulvovaginal varicosities is multifactorial. Some of the factors linked to vulvovaginal varicosities are proximal venous obstruction, lack of valves in the vulvovaginal veins, and a relative hyperestrogenic state during pregnancy.<sup>6,7</sup> These factors lead to venodilation and



**Image 1.** Sagittal cross-section of computed tomography of abdomen and pelvis with intravenous contrast demonstrating dilated pelvic veins (arrow) near the mons pubis.

### CPC-EM Capsule

What do we already know about this clinical entity?

*Pelvic congestion syndrome (PCS) is a diagnosis of exclusion for chronic pelvic pain thought to be associated with dilation of venous system.*

What makes this presentation of disease reportable?

*Inflammatory changes may confuse the provider into treating as an infectious etiology rather than a purely vascular one.*

What is the major learning point?

*The use of point-of-care ultrasound can help correctly guide care in cases such as this one where the differential includes such different etiologies.*

How might this improve emergency medicine practice?

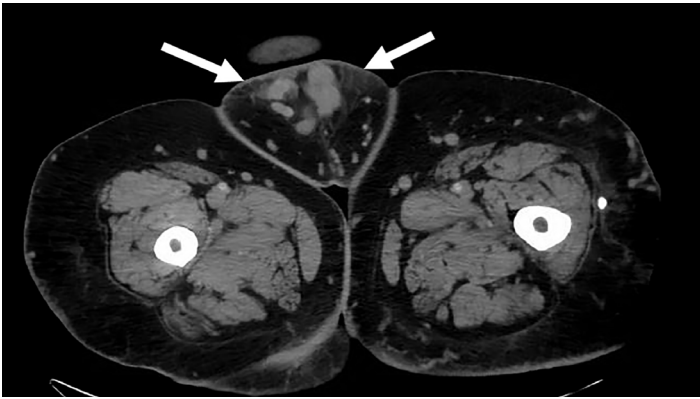
*This case presentation may spur providers to think of PCS as an alternative to pelvic abscess.*

venous insufficiency seen on vulvovaginal varicosities. Similarly, PCS is associated with dilation and incompetence of the ovarian veins. No specific causative mechanism has been identified; however, factors similar to the ones seen on vulvovaginal varicosities are believed to play a role.<sup>7</sup>

Although there could have been an infectious component to our patient's presentation, as would be the case with cellulitis, abscess, or suppurative thrombophlebitis, the etiology was primarily vascular. It was important to differentiate these two entities since the management varies. This becomes even more critical if the patient is anticoagulated as our patient was, given her history of chronic DVTs.

## CONCLUSION

This case demonstrates the unusual presentation of PCS with the appearance of mons pubis abscess. While the treatment for PCS is not one normally started in the ED, the patient can be counseled on treatment and directed to the correct specialist once the diagnosis is made. The utility of POCUS in PCS is not yet known, but as in our case it completely changed the diagnostic and therapeutic plan.



**Image 2.** Axial view of computed tomography of abdomen and pelvis with intravenous contrast demonstrating fat stranding (arrows) caused by inflammation from thrombophlebitis.

Documented patient informed consent and/or Institutional Review Board approval has been obtained and filed for publication of this case report.

## REFERENCES

1. Ignacio EA, Dua R, Sarin S, et al. Pelvic congestion syndrome: diagnosis and treatment. *Semin Intervent Radiol.* 2008;25(4):361-8.
2. Beard RW, Highman JH, Pearce S, et al. Diagnosis of pelvic varicosities in women with chronic pelvic pain. *Lancet.* 1984;2(8409):946-9.
3. Phillips D, Deipolyi A, Hesketh R, et al. Pelvic congestion syndrome: etiology of pain, diagnosis, and clinical management. *J Vasc Interv Radiol.* 2014;25(5):725-33.
4. Hobbs JT. The pelvic congestion syndrome. *Br J Hosp Med.* 1990;43(3):200-6.
5. Marrocco-Trischitta M, Nicodemi E, Nater C, et al. Management of congenital venous malformations of the vulva. *J Obstet Gynaecol.* 2001;98(5 Pt 1):789-93.
6. Kondo T, Uehara T, Noda K, et al. Vulvar varicosity. *BMJ.* 2017;356:i6332.
7. Lepage PA, Villavicencio JL, Gomez ER, et al. The valvular anatomy of the iliac vein venous system and its clinical implications. *J Vasc Surg.* 1991;14(5):678-83.

*Address for Correspondence:* Adrian Romero, MD, University of Illinois at Chicago, Department of Emergency Medicine, 808 South Wood Street, 469A CME, M/C 724, Chicago, IL 60612. Email: adrian.romero.em@gmail.com

*Conflicts of Interest:* By the CPC-EM article submission agreement, all authors are required to disclose all affiliations, funding sources and financial or management relationships that could be perceived as potential sources of bias. The authors disclosed none.

*Copyright:* © 2019 Romero et al. This is an open access article distributed in accordance with the terms of the Creative Commons Attribution (CC BY 4.0) License. See: <http://creativecommons.org/licenses/by/4.0/>

# Incomplete Stevens-Johnson Syndrome Caused by Sulfonamide Antimicrobial Exposure

Nikki B. Canter, PA-C  
Lane M. Smith, MD, PhD

Wake Forest School of Medicine, Department of Emergency Medicine, Winston-Salem, North Carolina

Section Editor: Scott Goldstein, DO

Submission history: Submitted January 29, 2019; Revision received March 18, 2019; Accepted April 2, 2019

Electronically published May 29, 2019

Full text available through open access at [http://escholarship.org/uc/uciem\\_westjem](http://escholarship.org/uc/uciem_westjem)

DOI: 10.5811/westjem.2019.4.42551

Stevens-Johnson syndrome (SJS) is a mucocutaneous reaction typically brought on by medications or infections. The diagnosis of SJS is typically made when patients present with a variable appearing rash and involvement of the oral, ocular, or genital mucosa. However, there are rare reports of atypical or incomplete SJS. These cases are usually associated with children infected with *Mycoplasma pneumoniae*, which presents with severe mucositis but no rash. Herein, we report the first case of adult incomplete SJS brought on by sulfonamide antimicrobial use without clinical or laboratory evidence of *M. pneumoniae* infection. [Clin Pract Cases Emerg Med. 2019;3(3):240-242.]

## INTRODUCTION

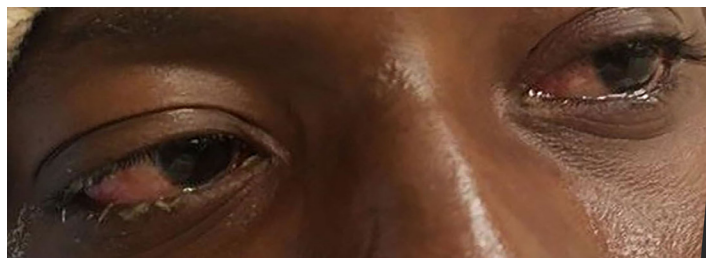
Stevens-Johnson syndrome (SJS) is a rare, mucocutaneous reaction that affects two to seven per million people per year and is often precipitated by medications and infections.<sup>1</sup> Women, human immunodeficiency virus-infected patients, and those with cancer are disproportionately affected.<sup>2,3</sup> It is characterized by skin rash and the involvement of the oral mucosa, genitals, or conjunctivae, but rare presentations of incomplete SJS are reported in children after *Mycoplasma pneumoniae* infection.<sup>4</sup> Here, we report the first case of oral and ocular SJS without skin lesions in a healthy adult after exposure to an antibacterial sulfonamide without *M. pneumoniae* infection.

## CASE REPORT

A 25-year-old African-American male with a history of diabetes presented to our emergency department (ED) with eye irritation, painful mouth sores, and difficulty swallowing. Three weeks prior to this visit, he was seen at a local ED for a small abscess on the posterior neck and treated with a 10-day course of trimethoprim/sulfamethoxazole (TMP-SMX). He did not begin this antibiotic for three days and took it intermittently over the next three weeks. He returned to the local ED two weeks after the first visit for symptoms of sore throat and lip swelling. This was attributed to a food allergy, and he was discharged with a five-day course of prednisone. He returned to the same institution two days later with worsening lip swelling and new mouth sores. He was prescribed nystatin suspension for presumed oral candidiasis

that he took with the prednisone and remaining TMP-SMX for two days prior to arriving at our ED.

He arrived at our institution with two remaining tablets of TMP-SMX and complaining of worsening lip swelling, mouth sores, eye irritation, and difficulty swallowing over the two days since his last visit to the local ED. Vital signs on presentation were a temperature of 38.6 degrees Celsius, blood pressure 132/73 millimeters of mercury, heart rate 115 beats per minute, respiratory rate 16 breaths per minute, and pulse oximetry 99% on room air. His review of systems was positive for odynophagia, sore throat, and eye irritation; negative for cough, rash, joint pain, or genital irritation. Physical examination showed injected conjunctiva bilaterally with sloughing (Image 1); visual acuity was intact. The mouth



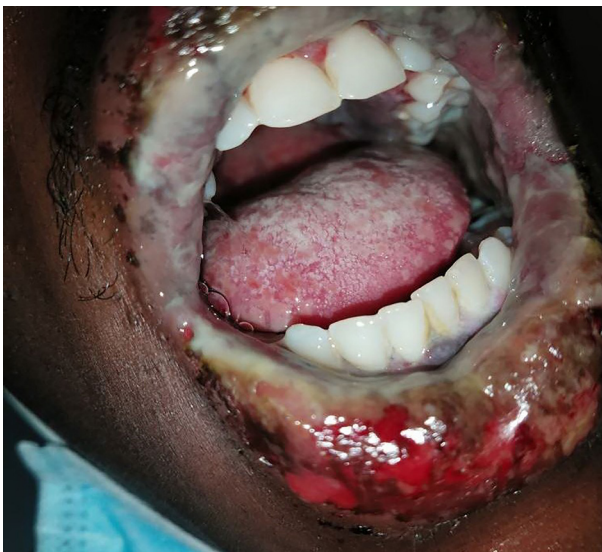**Image 1.** Injected conjunctiva with epithelial sloughing. Patient consent was given to use this photo.

and pharynx had severe stomatitis with ulcers involving the lips, tongue, buccal mucosa, and oropharyngeal mucosa (Image 2). There were no skin rashes and the lesion on his neck was well healed. All images were taken and published with the express, written consent of the patient.

Laboratory investigation revealed negative gonococcus/chlamydia polymerase chain reaction and negative *M. pneumoniae* immunoglobulin M on immunofluorescence assay. He was treated with intravenous (IV) fluids and admitted to the hospital for ophthalmologic and dermatologic consultations. The previously prescribed TMP-SMX was discontinued. He received IV methylprednisolone and mixed medication mouthwash for his stomatitis. The mild conjunctival sloughing was treated with erythromycin ophthalmic ointment, prednisolone acetate ophthalmic drops, and artificial tears, but did not require amniotic membrane graft. He was discharged after two days on a prednisone taper, prednisolone ophthalmic drops, and erythromycin ophthalmic ointment.

## DISCUSSION

SJS is part of a spectrum of mucocutaneous diseases affecting the skin and mucous membranes, which include erythema multiforme minor, SJS (erythema multiforme major), and toxic epidermal necrolysis.<sup>5</sup> Skin involvement occurs in more than 90% of patients, but the appearance of skin lesions can vary from targetoid to diffuse erythema.<sup>6</sup> Mucosal lesions typically occur at multiple sites such as the mouth, eyes, or genitalia. In adults, medications such as aromatic antiepileptics, allopurinol, sulfonamides, and nonsteroidal anti-inflammatory drugs are the most common precipitants.<sup>5,6</sup> Bacterial and viral infections are the most commonly identified cause in children,



**Image 2.** Severe stomatitis with diffuse ulcerations.

### *CPC-EM Capsule*

What do we already know about this clinical entity?

*Rare cases of incomplete Stevens-Johnson syndrome having only mucositis without rash occur in children infected with Mycoplasma pneumoniae.*

What makes this presentation of disease reportable?

*We report the first case of oral and ocular SJS without skin lesions in a healthy adult after exposure to an antibacterial sulfonamide and without Mycoplasma pneumoniae infection.*

What is the major learning point?

*Pay careful attention to new or recently completed medications in patients complaining of skin or isolated mucous membrane complaints.*

How might this improve emergency medicine practice?

*Awareness that incomplete Stevens-Johnson syndrome can occur in adults as well as children will help clinicians identify precipitating agents and avoid delays in diagnosis.*

with *M. pneumoniae* being the most common infectious agent associated with SJS among all age groups.<sup>5</sup>

Mucositis without skin involvement is an extremely rare variation of SJS most often seen in children infected by *M. pneumoniae*.<sup>4,7</sup> Isolated mucositis is also a rare complication associated with combining TMP-SMX and methotrexate.<sup>8</sup> However, our case is the first reported instance of isolated mucositis in an adult, brought on by a single medication known to cause SJS without clinical or laboratory evidence of *M. pneumoniae* infection. While some authors feel these atypical or incomplete presentations of SJS represent a distinct clinical entity, a common immunologic mechanism involving interleukin-15 and cluster of differentiation 8+ cytotoxic T cell-induced apoptosis of keratinocytes is likely common to all forms of SJS.<sup>9</sup>

Multiple outpatient visits were required in this case to establish the correct diagnosis. Additionally, we

were assisted by obvious vital sign abnormalities and symptoms that precluded discharge. Careful attention to new or recently completed medications will often provide diagnostic clues to help make such a difficult diagnosis. In this case, the diagnosis was made when the provider found the bottle of TMP-SMX in the patient's medication bag.

Treatment of SJS is largely supportive and includes removal of any offending medications. Corticosteroids, cyclosporine, IV immunoglobulin, plasmapheresis, and tumor necrosis factor inhibitors have all been used.<sup>10,11</sup> There is no clear benefit to any pharmacologic strategy, and treatments should be individualized based on severity and timing of the symptoms. Patients with severe conjunctival sloughing should receive amniotic membrane grafting early in their disease to preserve visual acuity.<sup>12</sup> Our patient improved with removal of the offending antibiotic and steroids. He was advised to avoid other antimicrobial sulfonamides.

Documented patient informed consent and/or Institutional Review Board approval has been obtained and filed for publication of this case report.

---

*Address for Correspondence:* Lane M. Smith, MD, PhD, Wake Forest School of Medicine, Department of Emergency Medicine, Meads Hall 2nd floor, Medical Center Blvd., Winston-Salem, NC 27157. Email: [lmsmith@wakehealth.edu](mailto:lmsmith@wakehealth.edu)

*Conflicts of Interest:* By the CPC-EM article submission agreement, all authors are required to disclose all affiliations, funding sources and financial or management relationships that could be perceived as potential sources of bias. The authors disclosed none.

*Copyright:* © 2019 Canter et al. This is an open access article distributed in accordance with the terms of the Creative Commons Attribution (CC BY 4.0) License. See: <http://creativecommons.org/licenses/by/4.0/>

---

## REFERENCES

1. Frey N, Jossi J, Bodmer M, et al. The epidemiology of Stevens-Johnson syndrome and toxic epidermal necrolysis in the UK. *J Invest Dermatol.* 2017;137(6):1240-7.
2. Mittmann N, Knowles SR, Koo M, et al. Incidence of toxic epidermal necrolysis and Stevens-Johnson syndrome in an HIV cohort: an observational, retrospective case series study. *Am J Clin Dermatol.* 2012;13(1):49-54.
3. Gillis NK, Hicks JK, Bell GC, et al. Incidence and Triggers of Stevens-Johnson syndrome and toxic epidermal necrolysis in a large cancer patient cohort. *J Invest Dermatol.* 2017;137(9):2021-3.
4. Ravin KA, Rappaport LD, Zuckerbraun NS, et al. Mycoplasma pneumoniae and atypical Stevens-Johnson syndrome: a case series. *Pediatrics.* 2007;119(4):e1002-5.
5. Letko E, Papaliodis DN, Papaliodis GN, et al. Stevens-Johnson syndrome and toxic epidermal necrolysis: a review of the literature. *Ann Allergy Asthma Immunol.* 2005;94(4):419-36.
6. Chatproedprai S, Wutticharoenwong V, Tempark T, et al. Clinical features and treatment outcomes among children with Stevens-Johnson syndrome and toxic epidermal necrolysis: a 20-year study in a tertiary referral hospital. *Dermatol Res Pract.* 2018;2018:3061084.
7. Schallock PC and Dinulos JG. Mycoplasma pneumoniae-induced cutaneous disease. *Int J Dermatol.* 2009;48(7):673-80.
8. Cudmore J, Seftel M, Sisler J, et al. Methotrexate and trimethoprim-sulfamethoxazole: toxicity from this combination continues to occur. *Can Fam Physician.* 2014;60(1):53-6.
9. Stern RS and Divito SJ. Stevens-Johnson syndrome and toxic epidermal necrolysis: associations, outcomes, and pathobiology—thirty years of progress but still much to be done. *J Invest Dermatol.* 2017;137(5):1004-8.
10. Ng QX, De Deyn MLZQ, Venkatanarayanan N, et al. A meta-analysis of cyclosporine treatment for Stevens-Johnson syndrome/toxic epidermal necrolysis. *J Inflamm Res.* 2018;11:135-42.
11. Wang CW, Yang LY, Chen CB, et al. Randomized, controlled trial of TNF-antagonist in CTL-mediated severe cutaneous adverse reactions. *J Clin Invest.* 2018;128(3):985-96.
12. Sharma N, Thenarasun SA, Kaur M, et al. Adjuvant role of amniotic membrane transplantation in acute ocular Stevens-Johnson syndrome: a randomized control trial. *Ophthalmology.* 2016;123(3):484-91.

# Novel Application of Balloon Tamponade in Management of Acute Lower Gastrointestinal Hemorrhage

Michael M. Neeki, DO, MS\*  
Vikram Raj, DO\*  
Benjamin Archambeau, DO\*  
Sarkis Arabian, DO†  
Farabi Hussain, MD‡

\*Arrowhead Regional Medical Center, Department of Emergency Medicine, Colton, California  
†Arrowhead Regional Medical Center, Department of Internal Medicine, Colton, California  
‡Arrowhead Regional Medical Center, Department of Surgery, Colton, California

Section Editor: Steve Walsh, MD

Submission history: Submitted November 28, 2018; Revision received February 12, 2019; Accepted March 4, 2019

Electronically published April 22, 2019

Full text available through open access at [http://escholarship.org/uc/uciem\\_cpccem](http://escholarship.org/uc/uciem_cpccem)

DOI: 10.5811/cpcem.2019.3.41772

We present a case of acute lower gastrointestinal (GI) bleeding in the emergency department, in which specialists were not emergently available to render their support. A quick intervention using balloon tamponade technique with a Minnesota tube helped stabilize the patient until intensive care, gastroenterology, and surgical specialists could intervene. We also review previous cases from the literature in which a balloon tamponade method was used to control GI hemorrhage. Our novel application of the Minnesota tube is important for emergency physicians to consider for cases of acute lower GI bleeding, particularly in emergent presentations when specialists are not readily available in-hospital. [Clin Pract Cases Emerg Med. 2019;3(2):243-247.]

---

## INTRODUCTION

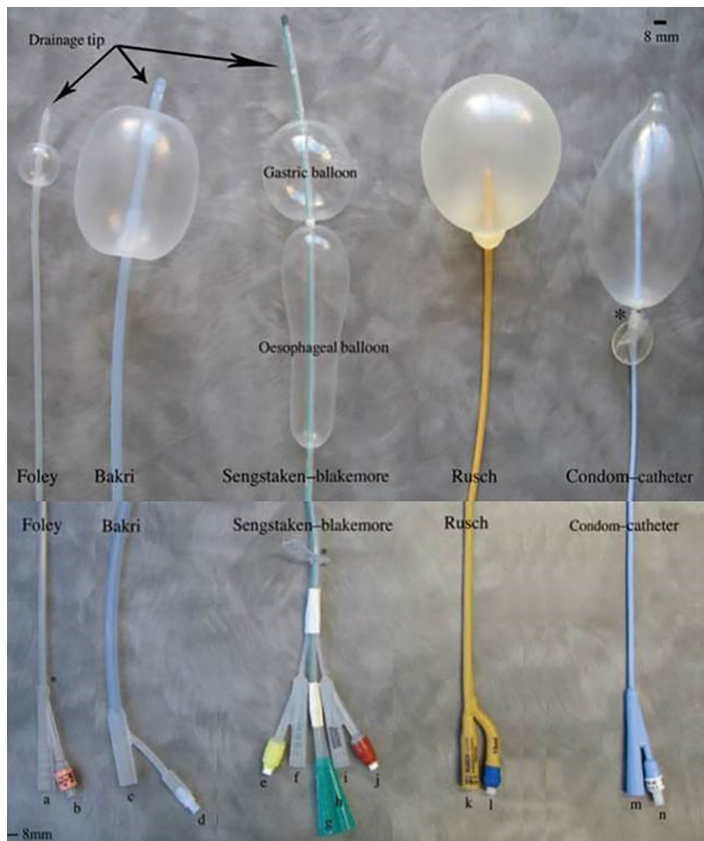
Lower gastrointestinal (GI) hemorrhage is defined as bleeding that arises from the GI tract at any site distal to the ligament of Treitz, which connects at the duodenojejunal flexure.<sup>1</sup> The incidence of lower GI bleeding is reported to be from 20-36 per 100,000 persons.<sup>2,3</sup> This pathology accounts for approximately 1-2% of all acute hospital admissions with 5-12% of cases resulting in mortality.<sup>1</sup> Of these cases, nearly 95% are due to bleeding from the colon, whereas other reports estimate that 10-25% of cases are due to small bowel bleeding.<sup>4-6</sup> Due to challenges in emergent localization of the sources of lower GI hemorrhage and effective treatment, acute lower GI hemorrhage remains a frustrating problem for both the treatment team and patient, especially when standard treatments fail to achieve hemostasis.<sup>1</sup>

Acute lower GI hemorrhage can become life threatening if not diagnosed quickly and properly managed. Previous studies have explored the use of balloon tamponades in treatment of acute hemorrhage in fields such as obstetrics and gynecology, prehospital traumatic injury, and upper GI hemorrhage.<sup>7-16</sup> Investigators have used various balloon tamponade devices (Image 1) for a range of conditions, including penetrating neck trauma, postoperative rectal hemorrhage, postpartum

hemorrhage, and various variceal bleeds.<sup>7-16</sup>

In particular, several balloon tamponade devices were specifically designed as temporary measures for upper GI hemorrhage, particularly in patients with shock indices greater than 1.3.<sup>17,18</sup> For example, studies involving Sengstaken-Blakemore tube utilization in upper GI hemorrhage demonstrated successful hemostasis of variceal hemorrhage in up to 94% of cases, although 38% of patients experienced rebleeding and 10% suffered major complications such as pressure ulceration and necrosis.<sup>8</sup> Similarly, the Minnesota tube (Image 2), which is the Sengstaken-Blakemore tube's successor, is a 4-lumen esophagogastric balloon tamponade device indicated for the treatment of gastric and esophageal variceal exsanguination.<sup>19</sup> Previous studies have demonstrated the utility of the Minnesota tube in upper GI bleeding with a case series of 100 patients showing that balloon tamponade was successful in achieving hemostasis in 61% of cases, while other studies have indicated a success rate of approximately 50%.<sup>1,20,21</sup> As these studies suggest, balloon tamponade devices are viable tools in a wide range of situations involving hemorrhage, acting as a bridge until definitive interventions are available.

We present a unique case of acute massive lower GI hemorrhage in the emergency department (ED), where a balloon



**Image 1.** A variety of balloon tamponade devices showing the distal end with maximal inflation (top) and the proximal end (bottom).<sup>10</sup>

tamponade technique using a Minnesota tube was successful in achieving hemostasis at a critical time when no definitive intervention was available. The goal of this case report is to alert emergency physicians to the unique utility of balloon tamponade in the treatment of non-localized, lower GI hemorrhage.

## CASE REPORT

A 76-year-old, wheelchair-bound male with history of hypertension, chronic kidney disease, and a prior thoracic and abdominal aortic repair, presented to the ED with an altered level of consciousness and was assessed with a Glasgow Coma Scale of nine (Eye 2, Verbal 3, Motor 4) and generalized weakness after examination. Emergency medical services noted bright red blood during the transfer, and upon arrival to the ED the patient presented hypotensive at 74/45 milligrams of mercury (mmHg), a heart rate of 102 beats per minute, a shock index of 1.4, a temperature of 97° Fahrenheit, 94% saturation breathing room air, and a respiratory rate of 18 breaths per minute. Given the patient's hypotensive status, we suspected the altered level of consciousness to be due to the acute hemorrhage.

Initially, the bleeding seemed to be minimal, although his hemoglobin, hematocrit, and platelet counts were notably

### *CPC-EM Capsule*

What do we already know about this clinical entity?

*Emergent lower gastrointestinal (GI) hemorrhage is a potentially fatal event with a variable presentation.*

What makes this presentation of disease reportable?

*Patients with lower GI hemorrhage often present to emergency departments. Unfortunately, access to tools and specialists is widely variable and may affect patient outcomes.*

What is the major learning point?

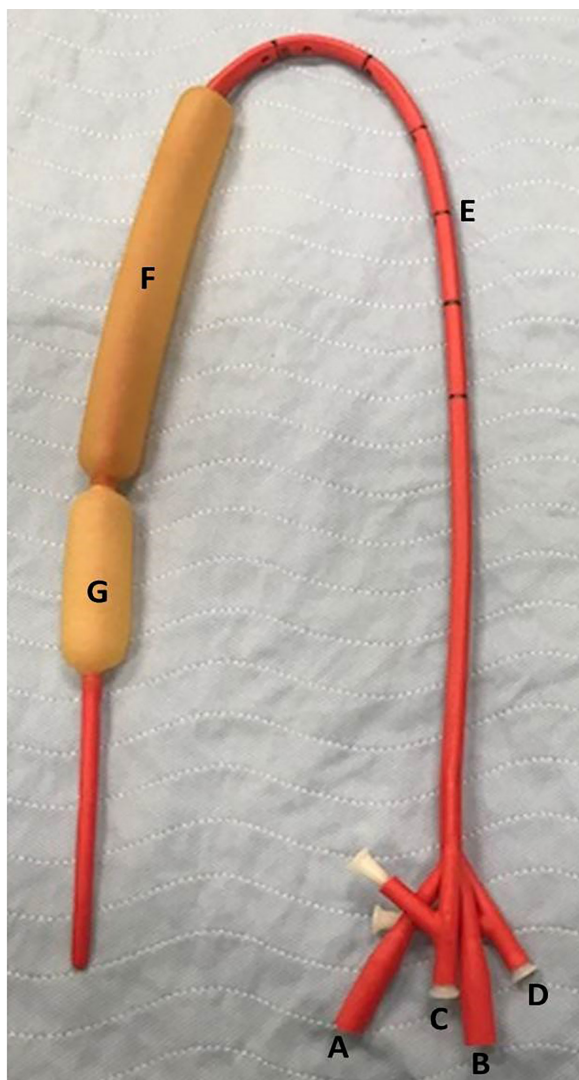
*Timely treatment of acute onset of lower GI hemorrhage is essential. Balloon tamponade devices may present an additional tool to improve mortality and morbidity outcomes.*

How might this improve emergency medicine practice?

*Balloon tamponade devices may present an opportunity to control bleeding and stabilize the patient until definitive treatment, but only in appropriate cases and with close observation.*

low, with hemoglobin at 6.6 grams per deciliter, hematocrit at 20.7%, and platelet count of 104,000 units per liter. The patient was intubated using rapid sequence intubation to protect his airway, and two large antecubital intravenous (IV) lines and later a right internal jugular vein central venous catheter were placed to administer blood products and medications. Subsequently, the massive transfusion protocol was activated with immediate transfusion with two units of packed red blood cells (PRBCs) in addition to one gram IV tranexamic acid over 10 minutes and an additional one gram infused over the next eight hours. As the patient presented at late evening hours, specialists such as GI and interventional radiology teams were unavailable in-house. However, the gastroenterology and interventional radiology specialist teams were remotely consulted by telephone in the management of the patient. In addition, the patient's condition was too unstable to allow him to be transferred for imaging studies.

As the initial transfusion started, the patient began to bleed profusely via his rectum. The treatment team was unable to localize the source of bleeding, and direct visualization using an



**Image 2.** Minnesota tube with labeled components: A) gastric aspiration port; B) esophagus aspiration port; C) gastric balloon port; D) esophagus balloon port; E) length marks for placement; F) esophageal balloon; G) gastric balloon.

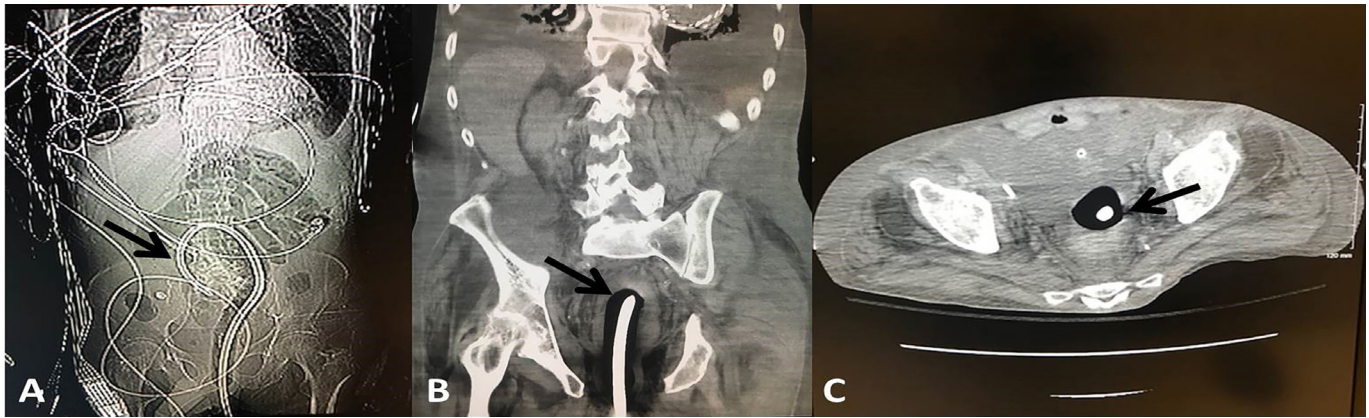
anoscope was not feasible due to acute profuse hemorrhaging from the rectum. Attempts at applying direct, intrarectal pressure with gauze were unsuccessful. Subsequently, a Foley balloon accompanied with direct pressure to the site also proved ineffective. Based on the patient's past history of constipation along with abdominal aortic aneurysm repair, a colonic tear along with a possible aortoenteric fistula was suspected to be the cause of the profuse bright red bleeding. Since other standard and alternative interventions were exhausted, a decision was made to use a Minnesota tube, a balloon tamponade device traditionally used for upper GI bleeding, transrectally in an attempt to control the bleeding. The gastric balloon was initially inflated with 200 milliliters (mL) of air without resolution of bleeding, at which point the esophageal port was inflated with 300 mL of air to a

pressure of 40 mmHg, which ultimately resulted in adequate hemostasis. The patient was then resuscitated with continuous transfusion of blood products and stabilized in the ED prior to undergoing a diagnostic computed tomography (CT) of abdomen and pelvis in an attempt to localize the source of the hemorrhage (Image 3). Following the CT, which showed no evidence of acute aortoenteric pathology or acute bleeding within colonic mucosa, the patient was transported to the intensive care unit, where he did not experience any further episodes of rectal bleeding. Over the course of the night, he received an additional six units of PRBCs, two units of plasma, two units of platelets, and two units of cryoprecipitate. The following morning, the gastroenterology team removed the Minnesota tube prior to performing a flexible sigmoidoscopy. During the flexible sigmoidoscopy, a circumferential, ulcerated mucosa at the dentate line was identified as the source of the profuse bleeding and was cauterized. The patient was then extubated, observed overnight without complications, and finally discharged 48 hours post-arrival to an extended care facility in a stable condition.

## DISCUSSION

In treating cases of GI hemorrhage with balloon tamponade, differences in upper and lower GI tissue should be considered. Upper GI mucosa epithelium is keratinized and possesses protective mechanisms that contribute to its ability to withstand harsh, acidic environments.<sup>22</sup> As a result, conditions that compromise the protective mucous layer, such as peptic ulcer disease, may result in bleeding.<sup>23,24</sup> In contrast, the anal canal tissue is composed of columnar epithelial cells, which thinly overlie the hemorrhoidal venous plexuses, contributing to the risk of massive hemorrhage.<sup>25</sup> Etiology for lower GI hemorrhage is predominately caused by colonic diverticulosis, followed by internal hemorrhoids, with ischemic colitis and post-polypectomy being an increasing minority of causes.<sup>3</sup> These structural differences of lower GI mucosa and the increased risk of mechanical iatrogenic complications may warrant additional caution when considering balloon tamponade in treating lower GI hemorrhage.

Potential complications from the use of balloon tamponade may include ulceration and pressure necrosis resulting from compression of the visceral wall via increased pressure of the balloon tamponade device, which may ultimately cause perforation, especially in cases of excessive or prolonged inflation.<sup>7,26</sup> To avoid potential complications, the following recommendations should be considered: sub-maximal balloon inflation for a maximum of 12 hours, careful monitoring, and gradual deflation in the case of visceral pain.<sup>7</sup> In our case we used a Minnesota tube, originally designed for esophageal bleeds, in a situation involving a lower GI bleed. Given the structural differences between upper and lower GI mucosal structure, these aforementioned precautions may require more conservative adjustment. The propensity for lower GI bleeds to result from physical factors may warrant



**Image 3.** Radiologic images of balloon tamponade placement with arrows indicating the inflated Minnesota tube: A) radiograph showing the full placement; B) computed tomography (CT) of coronal plane showing placement in the descending colon; C) CT of axial plane showing placement in the colon.

**Table.** Previously published case reports detailing subject's age and gender, location of the hemorrhage, presentation/case details, type of balloon tamponade used, and patient outcome.

Author	Subject	Location	Presentation / case details	Type of balloon	Outcome
Brale y et al. 2002 <sup>14</sup>	54M	Lower GI (presacral)	Lower GI bleeding after removal of GI stromal tumor	Breast implant sized	Adequate hemostasis until surgery performed
McGuinness et al. 2004 <sup>7</sup>	65M	Lower GI (transanal)	Lower GI bleeding after removal of rectal adenoma	Minnesota tube w/ gauze	No further bleeding
Marshall et al. 2007 <sup>9</sup>	54M	Lower GI (iliorectal anastomosis)	Bleeding after formation of a ileorectal anastomosis following a blood transfusion	Minnesota tube	No complications
Su Min Cho, 2006 <sup>28</sup>	51M	Lower GI (rectal varices)	Bleeding 24 hours after polypectomy, and then rebleed after laparotomy	Minnesota tube	No further bleeding

M, Male; GI, gastrointestinal.

lower levels of inflation than the maximal recommended pressure of 45 mmHg for esophageal bleeds.<sup>27</sup> Other precautions should include a reduced maximum duration of balloon inflation and a more gradual deflation.

Balloon tamponade has rarely been employed for lower GI hemorrhage, and previous successful cases have mostly been anecdotal via case reports (Table). Our use of a Minnesota tube in a case of lower GI hemorrhage provides additional evidence that balloon tamponade may be an effective and accessible alternative to establish hemostasis in a variety of hemorrhagic situations and provide necessary stabilization during the initial phase of resuscitation prior to definitive intervention.

## CONCLUSION

Our case provides emergency physicians with a critical example of an alternative method of stabilization of a non-localized, massive lower GI hemorrhage using balloon tamponade when all other alternative methods failed to achieve

hemostasis. This novel case may provide a basis for both further research and support for ED providers in the future to consider non-standard utilization of readily available resources for emergent cases of bleeding. It is also important to consider the possible complications of such a procedure, although none occurred in this case. While there is precedent for this treatment modality, the risks and benefits of its use should be weighed, and all avenues of standard treatment should first be exhausted.

## ACKNOWLEDGMENT

The authors would like to thank Nima Khoshab, Michelle Burgett-Moreno, and Thomas Dang, for their participation in drafting the manuscript and final approval.

Documented patient informed consent and/or Institutional Review Board approval has been obtained and filed for publication of this case report.

**Address for Correspondence:** Michael M Neeki, DO, MS, Arrowhead Regional Medical Center, Department of Emergency Medicine, 400 N Pepper Ave, Colton, CA 92324. Email: armcemresearch@gmail.com.

**Conflicts of Interest:** By the CPC-EM article submission agreement, all authors are required to disclose all affiliations, funding sources and financial or management relationships that could be perceived as potential sources of bias. The authors disclosed none.

**Copyright:** © 2019 Neeki et al. This is an open access article distributed in accordance with the terms of the Creative Commons Attribution (CC BY 4.0) License. See: <http://creativecommons.org/licenses/by/4.0/>

## REFERENCES

- Hoedema RE and Luchtefeld MA. The management of lower gastrointestinal hemorrhage. *Dis Colon Rectum*. 2005;48(11):2010-24.
- Qayed E, Dagar G, Nanchal RS. Lower gastrointestinal hemorrhage. *Crit Care Clin*. 2016;32(2):241-54.
- Ghassemi KA and Jensen DM. Lower GI bleeding: epidemiology and management. *Curr Gastroenterol Rep*. 2013;15(7):333.
- Farrands P and Taylor I. Management of acute lower gastrointestinal haemorrhage in a surgical unit over a 4-year period. *J R Soc Med*. 1987;80(2):79-82.
- Leitman IM, Paull DE, Shires GT 3rd. Evaluation and management of massive lower gastrointestinal hemorrhage. *Ann Surg*. 1989;209(2):175-80.
- Wagner HE, Stain SC, Gilg M, et al. Systematic assessment of massive bleeding of the lower part of the gastrointestinal tract. *Surg Gynecol Obstet*. 1992;175(5):445-9.
- McGuinness J, Winter DC, O'Connell PR. Balloon tamponade to control haemorrhage following transanal rectal surgery. *Int J Colorectal Dis*. 2004;19(4):395-6.
- Pasquale MD and Cerra FB. Sengstaken-Blakemore tube placement: use of balloon tamponade to control bleeding varices. *Crit Care Clin*. 1992;8(4):743-53.
- Marshall BJ, Seow CH, Levitt MD. Use of a Minnesota tube to tamponade bleeding from an ileorectal anastomosis. *ANZ J Surg*. 2007;77(10):916-7.
- Georgiou C. Balloon tamponade in the management of postpartum haemorrhage: a review. *BJOG*. 2009;116(6):748-57.
- Weppner J. Improved mortality from penetrating neck and maxillofacial trauma using Foley catheter balloon tamponade in combat. *J Trauma Acute Care Surg*. 2013;75(2):220-4.
- Dabelea V, Schultze PM, McDuffie RS Jr. Intrauterine balloon tamponade in the management of postpartum hemorrhage. *Am J Perinatol*. 2007;24(6):359-64.
- Ball CG, Wyrzykowski AD, Nicholas JM, et al. A decade's experience with balloon catheter tamponade for the emergency control of hemorrhage. *J Trauma*. 2011;70(2):330-3.
- Bralely SC, Schneider PD, Bold RJ, et al. Controlled tamponade of severe presacral venous hemorrhage. *Dis Colon Rectum*. 2002;45(1):140-2.
- Brown H, Okeyo S, Mabeya H, et al. The Bakri tamponade balloon as an adjunct treatment for refractory postpartum hemorrhage. *Int J Gynaecol Obstet*. 2016;135(3):276-80.
- Gelsthorpe A, Patodi N, Ahmed M. PMO-185 Duodenal tamponade: a case series and fourth modality in gastrointestinal bleed control. *Gut*. 2012;61(2):A149.
- Nadler J, Stankovic N, Uber A, et al. Outcomes in variceal hemorrhage following the use of a balloon tamponade device. *Am J Emerg Med*. 2017;35(10):1500-2.
- TAMING THE SRU. Air Care Series: Balloon tamponade of variceal hemorrhage. 2018. Available at: <http://www.tamingthesru.com/blog/air-care-series/balloon-tamponade-of-variceal-hemorrhage>. Accessed November 27, 2018.
- Parkes BM, Obeid FN, Sorensen VJ, et al. The management of massive lower gastrointestinal bleeding. *Am Surg*. 1993;59(10):676-8.
- Greenwald B. The Minnesota tube: its use and care in bleeding esophageal and gastric varices. *Gastroenterol Nurs*. 2004;27(5):2127; quiz 8-9.
- Sorbi D, Gostout CJ, Peura D, et al. An assessment of the management of acute bleeding varices: a multicenter prospective member-based study. *Am J Gastroenterol*. 2003;98(11):2424-34.
- Orlando RC. Esophageal mucosal defense mechanisms. *GI Motility Online*. 2006. Available at: <https://www.nature.com/gimo/contents/pt1/full/gimo15.html>. Accessed December 14, 2018.
- Cook D and Guyatt G. Prophylaxis against upper gastrointestinal bleeding in hospitalized patients. *N Engl J Med*. 2018;378(26):2506-16.
- Loperfido S, Baldo V, Piovesana E, et al. Changing trends in acute upper-GI bleeding: a population-based study. *Gastrointest Endosc*. 2009;70(2):212-24.
- Morgan CN and Thompson HR. Surgical anatomy of the anal canal with special reference to the surgical importance of the internal sphincter and conjoint longitudinal muscle. *Ann R Coll Surg Engl*. 1956;19(2):88-114.
- Chahla E, Cheesman A, Taylor JR. Esophageal perforation caused by misplaced Minnesota tube. *Clin Gastroenterol Hepatol*. 2016;14(1):A33-4.
- Roberts JR and Hedges JR. (2013). *Roberts and Hedges' Clinical Procedures in Emergency Medicine*, 6<sup>th</sup> edition: Philadelphia, Pennsylvania: Saunders Publishing.
- Cho SM, Al-Khafaji A, Ahmad J. Minnesota Tube for Bleeding Rectal Varices. *Am J Gastroenterol*. 2006;101(Suppl 2):S284-5.

# A Novel Technique to Reduce Reliance on Opioids for Analgesia from Acute Appendicitis: The Ultrasound-guided Erector Spinae Plane Block

Daniel Mantuani, MD, MPH  
Josh Luftig, PA  
Andrew Herring, MD  
Andrea Dreyfuss, MD  
Arun Nagdev, MD

Highland General Hospital, Alameda Health System, Department of Emergency Medicine, Oakland, California

Section Editor: Scott Goldstein, MD

Submission history: Submitted December 29, 2018; Revision received March 18, 2019; Accepted April 22, 2019

Electronically published May 29, 2019

Full text available through open access at [http://escholarship.org/uc/uciem\\_cpccem](http://escholarship.org/uc/uciem_cpccem)

DOI: 10.5811/cpcem.2019.4.42117

Single injection, ultrasound-guided nerve blocks have drastically changed the multimodal approach to pain management of the acutely injured patient in the emergency department (ED). Ultrasound-guided femoral nerve blocks in the ED have become standard aspects of multiple, hospital system pain management protocols, with early evidence demonstrating improved patient outcomes. Developing a multimodal pain management strategy can improve analgesia while reducing reliance on opioids in this era of opioid addiction.<sup>1</sup> The single injection, ultrasound-guided erector spinae plane (ESP) block is a technique safely used for pain control for rib fractures that can be easily performed at the bedside and integrated into optimal emergency care. A more inferiorly located ultrasound-guided ESP block has been recently described in the anesthesia literature for perioperative pain control for various abdominal surgeries but has not yet been described for patients with acute appendicitis. Here we describe a single injection, lower ESP block performed by emergency physicians that successfully alleviated pain from acute appendicitis in an ED patient awaiting definitive surgical treatment. Along with allowing clinicians to actively manage pain without reliance on opioids, this novel ED technique may improve patient care outcomes. [Clin Pract Cases Emerg Med. 2019;3(3):248-251.]

## INTRODUCTION

Acute appendicitis is commonly diagnosed in the emergency department (ED), where intravenous (IV) opioids are the primary analgesic used to control pain while patients await definitive surgical care.<sup>2</sup> Increasingly, data support the benefits of opioid-sparing multimodal analgesia for intra-abdominal surgery as part of enhanced recovery after surgery protocols.<sup>3</sup> However, little has been studied in the preoperative period, specifically while patients are in the ED. Ultrasound-guided nerve blocks have become standard practice for many emergency physicians (EP) for acute traumatic injury such as hip fracture. The ultrasound-guided erector spinae plane (ESP) block, developed for both chronic and surgical thoracic pain and later adopted by EPs for management of acute rib fractures, is thought to provide relief for both somatic and visceral pain.<sup>4-6</sup>

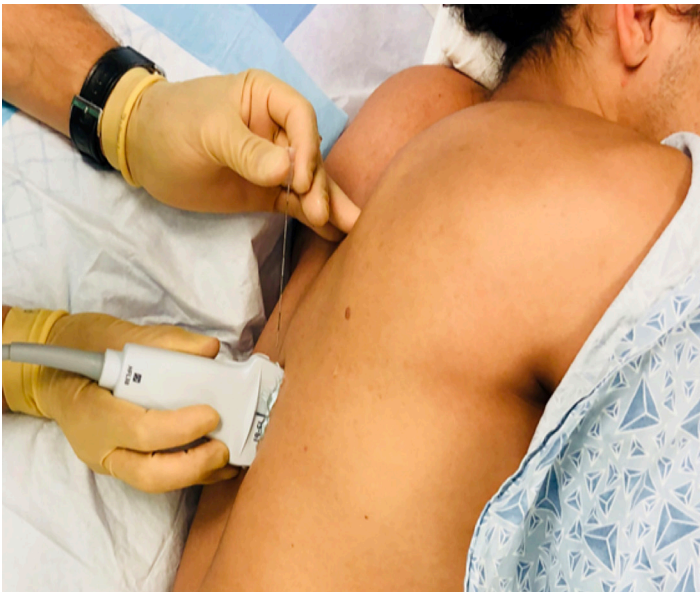Recently, several reports suggest benefit of the ESP block for the pain associated with major open abdominal surgery, bariatric surgery, ventral hernia repair, abdominal zoster, laparoscopic cholecystectomy, inguinal hernia repair, and cesarean section.<sup>6-11</sup> This single injection, interfascial plane block could be an ideal pain-control intervention for the ED patient awaiting definitive surgical intervention. Along with offering effective localized pain management, the ESP block could potentially reduce or even obviate the need for opioids for acute appendicitis. Herein, we present the first description of a successful, ultrasound-guided ESP block for pain control in preoperative acute appendicitis.

## CASE REPORT

A 24-year-old male presented to the ED after seven hours of sharp mid-abdominal pain migrating to the right lower

quadrant (RLQ), associated with nausea and vomiting. Vital signs were within normal limits except for mild hypertension (149/68 millimeters of mercury). Laboratory results showed a leukocytosis, white blood cells  $14.5 \times 10^9/\text{liters (L)}$  ( $4.5\text{-}11.5 \times 10^9/\text{L}$ ). A contrast-enhanced computed tomography of the abdomen and pelvis revealed a 10-millimeter (mm) dilated, fluid-filled appendix with appendicolith suggestive of acute appendicitis. The patient was given IV cefoxitin and admitted to the department of surgery for planned appendectomy later that day. For analgesia, the patient received 0.5 milligrams (mg) IV hydromorphone, 30 mg IV ketorolac, and 1000 mg IV acetaminophen but was still reporting 7/10 pain. Palpation of the RLQ produced 10/10 sharp localized pain with rebound and guarding. Operative management was to be delayed for four hours; thus, after discussion with the surgical team, the patient was offered a single injection, ultrasound-guided ESP (block) for pain control.

After the patient gave verbal consent he was placed on a cardiac monitor and rolled into the left lateral decubitus position. The physician stood at head of the bed facing the patient's feet with the ultrasound monitor in direct line of sight (Image 1). The first lumbar (L1) spinous process was identified using surface landmarks and ultrasound imaging and the skin cleansed with chlorhexidine. A high-frequency 10-5 megahertz linear ultrasound probe was placed in the parasagittal plane approximately three centimeters (cm) lateral to the spinous process at the right L1 transverse process. Under ultrasound-guidance, a 20 gram (g)-3.5 inch Touhy needle was advanced in-plane, cranial to caudal, until



**Image 1.** In preparation for administration of erector spinae plane block, the patient is positioned in either lateral decubitus with the affected side up or prone with the provider at the head of the bed. The needle trajectory is from cranial to caudal.

### *CPC-EM Capsule*

What do we already know about this clinical entity?

*Traditional pain control for acute appendicitis relies on intravenous opiates.*

What makes this presentation of disease reportable?

*Regional anesthesia has not been described for analgesia in acute appendicitis.*

What is the major learning point?

*A single injection, ultrasound-guided erector spinae plane block can provide complete analgesia for appendicitis.*

How might this improve emergency medicine practice?

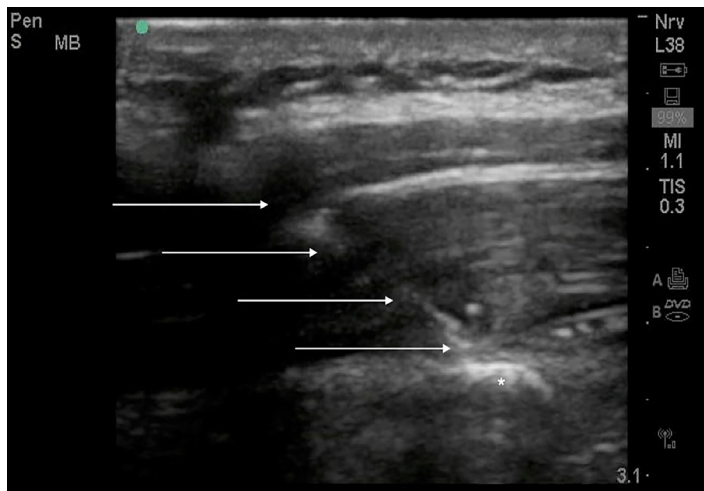*Emergency physicians can now incorporate regional anesthesia for pain control in acute appendicitis.*

the needle tip was in contact with the posterior surface of the transverse process (Image 2). Hydrodissection with 10 milliliters (mL) of normal saline with direct visualization confirmed needle tip placement in the fascial plane adjacent to the posterior surface of the transverse process. After negative aspiration, 20 mL of 1% lidocaine with epinephrine was injected in aliquots of 2-4 mL.

Thirty minutes after the procedure the patient reported 0/10 pain at rest. With deep palpation to the RLQ, the patient reported mild, dull, pressure-like pain (3/10); the abdomen remained soft without guarding, rebound or localized pain. Sensory testing to cold with ethyl chloride spray revealed right-sided decreased sensation in the tenth thoracic (T10) to L2 distribution (from approximately two cm inferior to the umbilicus to the mid-anterior right thigh). Two hours later, nursing documentation indicated that the patient's pain remained well controlled. During the remaining 5.5 hours of his ED stay the patient reported his pain was well controlled and required no additional analgesic medications. He had an uncomplicated laparoscopic appendectomy, with appendicitis later confirmed by pathology.

### **DISCUSSION**

Currently, pain control for acute surgical abdominal pain is often limited to IV opioids, sometimes combined with nonsteroidal anti-inflammatory drugs or acetaminophen.



**Image 2.** In-plane approach: advancing the needle tip (arrows) through the erector spinae muscle to the posterior surface of the transverse process of the first lumbar vertebra (\*).

With operating room crowding, abdominal surgical patients often board in the ED for many hours, relying on repeated dosing of opioid medications that risk side effects while often failing to provide adequate pain relief. In the last quarter of 2018 at our institution, patients admitted for appendicitis boarded an average of 320 minutes before leaving the ED. Ultrasound-guided regional blocks for abdominal surgeries performed by anesthesiologists have been shown to be effective in the perioperative and postoperative period.<sup>8,10,11</sup> This is the first report of an ESP block for acute appendicitis performed by EPs on a patient boarding in the ED whose pain was unrelieved by IV hydromorphone, acetaminophen, and ketorolac. This technique can be incorporated into an opioid-sparing, multimodal pain control strategy for patients with confirmed appendicitis who are boarding in the ED, and it may apply to other painful surgical abdominal pathologies.

Communication with surgical consultants with regard to performing the ESP block before the procedure should be routine. Clear documentation in both the chart and on the patient (we commonly place the time and block type) should also be part of the workflow when incorporating ultrasound-guided nerve blocks in the ED. Surgical consultants should also be aware that peritoneal blocks may significantly reduce the pain from acute appendicitis; thus, using the abdominal examination as a marker of progression of illness may not be possible.

Technical considerations include adhering to block safety standards to prevent local anesthetic systemic toxicity. Because this was a novel, lower-targeted ESP block, we used a shorter acting anesthetic (1% lidocaine with epinephrine) as an additional precaution in case of adverse effects. However, a longer-acting anesthetic (such as bupivacaine or ropivacaine) would likely be optimal and consistent with prior

published reports of ESP block.<sup>13</sup> In the thorax, injecting into the erector spinae fascial plane spreads multiple vertebral levels superiorly and inferiorly.<sup>5,6</sup> Additional study is needed to determine the ideal vertebral level needed to cover the lower abdomen. Previous case reports in the anesthesiology literature indicate that ESP block placed at the T8-T9 level may be preferred as it is less likely to cause excessive lower lumbar blockade, and it is easier to target since the transverse process is located more superficially at that level.<sup>7-9,11,12</sup>

## CONCLUSION

Given our experience managing pain for rib fractures, we consider the ESP block to be technically feasible and highly effective. By moving the location of the single injection ESP block more caudally, we can expand the range of this block to include pain control for acute appendicitis as part of an opioid-sparing, multimodal pain control strategy for patients in the ED. We suspect that further study of this novel technique may show improved pain control for patients with acute appendicitis when compared to standard opioid-based pain regimens with fewer side effects and improved patient outcomes.

Documented patient informed consent and/or Institutional Review Board approval has been obtained and filed for publication of this case report.

*Address for Correspondence:* Daniel Mantuani, MD, Highland General Hospital, Department of Emergency Medicine, 1411 East 31st Street, Oakland, CA 94105. Email: [dmantuani@alamedahealthsystem.org](mailto:dmantuani@alamedahealthsystem.org).

*Conflicts of Interest:* By the *CPC-EM* article submission agreement, all authors are required to disclose all affiliations, funding sources and financial or management relationships that could be perceived as potential sources of bias. The authors disclosed none.

*Copyright:* © 2019 Mantuani et al. This is an open access article distributed in accordance with the terms of the Creative Commons Attribution ([CC BY 4.0](http://creativecommons.org/licenses/by/4.0/)) License. See: <http://creativecommons.org/licenses/by/4.0/>

## REFERENCES

- Casey SD, Stevenson DE, Mumma BE, et al. Emergency department management following implementation of a geriatric hip fracture program. *West J Emerg Med.* 2017;18(4):585-91.
- Manterola C, Vial M, Moraga J, et al. Analgesia in patients with acute abdominal pain. *Cochrane Database Syst Rev.* 2011;(1):CD005660.
- de Boer HD, Detriche O, Forget P. Opiate-related side effects: postoperative ileus, urinary retention, nausea and vomiting, and

- shivering. A review of the literature. *Best Pract Res Clin Anaesthesiol*. 2017;31(4):499-504.
4. Forero M, Adhikary SD, Lopez H, et al. The erector spinae plane block: a novel analgesic technique in thoracic neuropathic pain. *Reg Anesth Pain Med*. 2016;41(5):621-7.
  5. Chin KJ, Adhikary S, Sarwani N, et al. The analgesic efficacy of pre-operative bilateral erector spinae plane (ESP) blocks in patients having ventral hernia repair. *Anaesthesia*. 2017;72(4):452-60.
  6. Luftig J, Mantuani D, Herring AA, et al. Successful emergency pain control for posterior rib fractures with ultrasound-guided erector spinae plane block. *Am J Emerg Med*. 2018;36(8):1391-6.
  7. Restrepo-Garces CE, Chin KJ, Suarez P, et al. Bilateral continuous erector spinae plane block contributes to effective postoperative analgesia after major open abdominal surgery: a case report. *AA Case Rep*. 2017;9(11):319-21.
  8. Chin KJ, Adhikary S, Sarwani N, et al. The analgesic efficacy of pre-operative bilateral erector spinae plane (ESP) blocks in patients having ventral hernia repair. *Anaesthesia*. 2017;72(4):452-60.
  9. Chin KJ, Malhas L, Perlas A. The erector spinae plane block provides visceral abdominal analgesia in bariatric surgery: a report of 3 cases. *Reg Anesth Pain Med*. 2017;42(3):372-6.
  10. Ahiskalioglu A, Alici HA, Ari MA. Ultrasound guided low thoracic erector spinae plane block for management of acute herpes zoster. *J Clin Anesth*. 2018;45:60-1.
  11. Yamak EA, García DS, Fajardo-Pérez M. Erector spinae plane block for analgesia after lower segment caesarean section. *Rev Esp Anesthesiol Reanim*. 2018;65(5):284-6.
  12. Tulgar S, Selvi O, Kapakli MS. Erector spinae plane block for different laparoscopic abdominal surgeries: case series. *Case Rep Anesthesiol*. 2018;2018:3947281.
  13. Luftig J, Mantuani D, Herring AA, et al.. The authors reply to the optimal dose and volume of local anesthetic for erector spinae plane blockade for posterior rib fractures. *Am J Emerg Med*. 2018;36(6):1103-4.

# Operative Hysteroscopy Intravascular Absorption Syndrome Causing Hyponatremia with Associated Cerebral and Pulmonary Edema

Marco F. Elegante, MD\*  
Joseph A. Hamera, MD\*  
Jane Xiao, MD†  
David A. Berger, MD\*

\*Oakland University William Beaumont School of Medicine, Department of Emergency  
Medicine, Royal Oak, Michigan  
†Oregon Health Sciences University, Department of Emergency Medicine,  
Portland, Oregon

Section Editor: John Ashurst, MD

Submission history: Submitted December 3, 2018; Revision received April 2, 2019; Accepted April 22, 2019

Electronically published June 4, 2019

Full text available through open access at [http://escholarship.org/uc/uciem\\_cpccem](http://escholarship.org/uc/uciem_cpccem)

DOI: 10.5811/cpcem.2019.4.41878

Operative hysteroscopy intravascular absorption syndrome is an iatrogenic syndrome caused by absorption of hypo-osmolar distension medium during hysteroscopy, which can lead to rapid hyponatremia with resulting cerebral and pulmonary edema. We present a case of a 47-year-old female who underwent hysteroscopic myomectomy at an outpatient ambulatory surgical center who was brought to the emergency department with dyspnea, hypoxia, and altered mental status. Workup showed hyponatremia with cerebral edema on computed tomography of the head and pulmonary edema on chest radiograph. The patient improved after resuscitation with intravenous saline and supplemental oxygen, and she was discharged home the next day. [Clin Pract Cases Emerg Med.2019;3(3):252-255.]

---

## INTRODUCTION

Hysteroscopy has been increasingly common since the 1990s. As this procedure becomes more commonplace in ambulatory surgical centers there will be an increased need for postoperative complications to be evaluated and initially managed in emergency departments (ED). Operative hysteroscopy intravascular absorption (OHIA) syndrome was first described in 1993 and is considered the gynecological equivalent of transurethral resection syndrome.<sup>1</sup> OHIA occurs by absorption of the fluid distension medium used during operative hysteroscopy in an exposed vascular bed. A commonly used distension medium in hysteroscopy is 1.5% glycine solution due to its favorable optical and conductive properties. However, 1.5% glycine is hypo-osmolar (200 milliosmole [mOsm]) per kilogram [kg] of water), and absorption of volumes greater than 500 milliliters (mL) have been associated with hyponatremia and cerebral edema.<sup>2</sup>

## CASE REPORT

A 47-year-old female presented by ambulance from an outpatient ambulatory surgical center to the ED secondary to hypoxia, coughing up pink, frothy sputum and with

mental status changes. The patient was noted to have a medical history of recurrent uterine fibroids despite two prior hysteroscopic myomectomies over the previous year. She underwent a hysteroscopic myomectomy in an outpatient ambulatory surgical setting, with 1.5% glycine used as distension medium. Intraoperative monitoring of inflow volume of glycine distension medium and collected fluid showed an initial calculated fluid deficit of 600 mL. Repeat measurement 15 minutes later showed the calculated fluid deficit was 2700 mL, at which time the procedure was stopped due to concern for rapid intravascular absorption and the patient was taken to the recovery area. The entire procedure was reported to have lasted less than 30 minutes.

After being brought to the recovery area the patient was given two milligrams (mg) morphine intravenously. She became more and more dyspneic over the next several minutes and began coughing up pink, frothy sputum. She was not complaining of nausea, vomiting or headache. Lung auscultation showed decreased breath sounds in all fields, most prominently at the bases. She was noted to be hypoxic with an oxygen saturation of 82% and was placed on 15 liters per minute (L/min) oxygen by nonrebreather with improvement

in oxygen saturation to 98%. She was also treated with two puffs of an albuterol inhaler, intravenous (IV) furosemide 40 milligrams (mg), hydrocortisone 50 mg, and 600 mL of 0.9% saline. She was then transported by ambulance to the ED.

Vital signs on arrival showed blood pressure 99/49 millimeters mercury, respiratory rate 17 breaths/ min, heart rate 72 beats/min with oxygen saturation 97% on 15 L/min supplemental oxygen by non-rebreather mask. Attempt at weaning oxygen to 12 L/min was accompanied by oxygen desaturation. Auscultation of the chest on arrival was notable for decreased breath sounds in the lower lung fields bilaterally. The patient was noted to be somewhat somnolent and confused but was easily roused and oriented to person, place and time, with a Glasgow Coma Scale (GCS) score of 12. She had received an additional 100 mL of 0.9% saline during transport for a total of 700 mL prior to arrival. Workup in the ED was significant for serum sodium level of 125 micromoles (mmol)/L (135-145 mmol/L).

Other mild electrolyte abnormalities included serum chloride level of 96 mmol/L (98-110 mmol/L), serum bicarbonate level of 20 (22-32 mmol/L) and serum calcium level of 8.2 mmol/L (8.4-10.4 mmol/L). Chest radiograph showed pulmonary edema, vascular congestion, and bilateral small pleural effusions (Image 1). Computed tomography (CT) of the head was consistent with mild cerebral edema (Image 2). The patient received another 150 mL of 0.9% saline in the ED. Repeat electrolyte measurement two hours after arrival showed serum sodium of 130 mmol/L at which point the IV fluids were stopped. Her mental status had significantly improved to a GCS score of 15, and she was able to maintain an oxygen saturation of 99% on 5 L/min supplemental oxygen by nasal cannula.

She was admitted to the surgical intensive care unit where

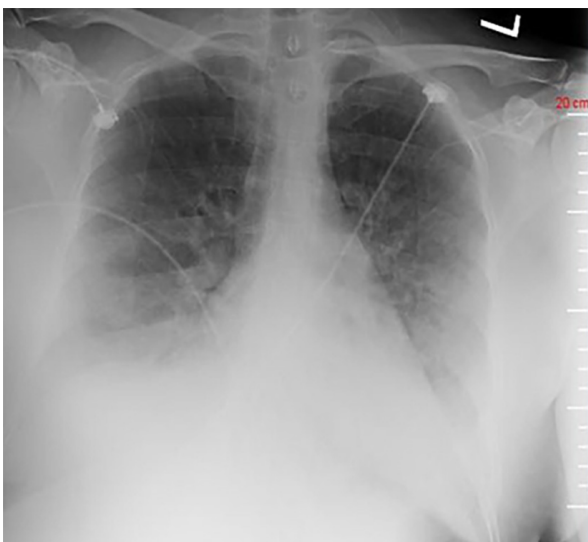


Image 1. Anterior-posterior chest radiograph demonstrating findings consistent with fluid overload.

### *CPC-EM Capsule*

What do we already know about this clinical entity?

*This is an iatrogenic condition where large-volume, rapid intravascular absorption of operative distension fluid causes acute hyponatremia and fluid overload.*

What makes this presentation of disease reportable?

*This case highlights a severe presentation of an iatrogenic disease state not commonly treated by emergency physicians (EP).*

What is the major learning point?

*As ambulatory surgical centers grow in number, EPs will more often care for patients presenting with critical illness related to perioperative complications.*

How might this improve emergency medicine practice?

*EPs should have a high suspicion for acute hyponatremia with volume overload in patients presenting with altered mental status and respiratory distress after hysteroscopy.*

she was monitored overnight and had electrolyte checks every four hours. A repeat chest radiograph the next morning showed complete resolution of the pulmonary edema and she was saturating 100% on room air. Her serum sodium continued to trend upward and was noted to be 141 mmol/L in the afternoon of the day after arrival. She was discharged from the hospital on postoperative day one.

### **DISCUSSION**

During operative hysteroscopy the use of a fluid medium is used to distend the uterine tissue to allow for optimal visualization. Resectoscopes used in these procedures were initially developed using monopolar current, which necessitated the use of non-electrolyte containing solutions such as 1.5% glycine, 5% dextrose with water, 3% sorbitol, 5% mannitol and 32% Dextran 70 solution. With the development of resectoscopes using bipolar current the use of isotonic electrolyte solutions such as Ringer's lactate or 0.9% saline may be used as distension media.<sup>3</sup> Systemic absorption of some of the distension fluid medium is expected,

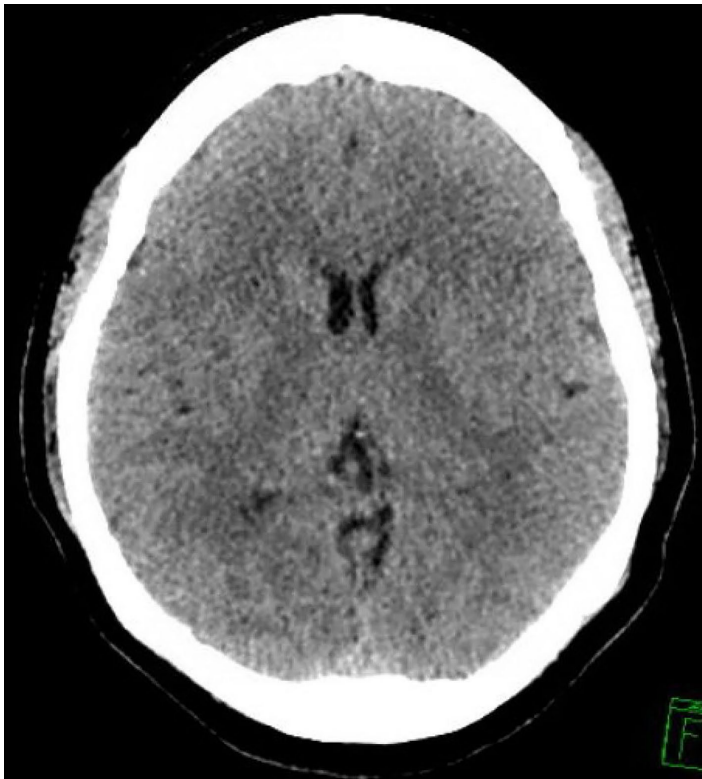


Figure 2. Computed tomography axial image demonstrating mild cerebral edema.

with the average amount of fluid absorbed during operative hysteroscopy cases being approximately 400-600 mL.<sup>4</sup> Intravascular absorption of fluid is driven by (1) increasing the hydrostatic pressure gradient between the distension fluid and the vasculature, and (2) increasing the surface area of vascular beds exposed to the distension fluid. Increased operative time increases the risk of absorbing larger amounts of fluid. Among hysteroscopic procedures, myomectomies and resections of uterine septa are at higher risk for increased fluid absorption.<sup>5</sup>

Some of the commonly used distension media with monopolar resectoscopy, such as 1.5% glycine solution or 3% sorbitol solution, are hypotonic in addition to being electrolyte free. Intravascular absorption of large amounts of these solutions leads to hypervolemia with dilutional hyponatremia. Using 0.9% saline as distension medium during hysteroscopy with a bipolar resectoscope is not associated with hyponatremia, although there have been reported cases of fluid overload and pulmonary edema.<sup>6,7</sup> There is no exact amount of fluid at which point patients will develop symptoms. Professional society recommendations state that surgeries should be halted once the calculated fluid deficit shows absorption of 1000 mL of hypotonic distension medium in healthy patients or 750 mL in patients with cardiac disease or renal insufficiency. One small study found that nine out of ten patients who experienced intravascular absorption of 1000 mL of 1.5% glycine solution had findings of cerebral edema on

head CT. This was accompanied by a 10 mmol/L or more drop in serum sodium levels.<sup>2,3</sup>

OHIA syndrome can present with myriad signs and symptoms. Manifestations may include nausea, vomiting, headache, weakness, pulmonary edema, acute respiratory distress syndrome, laryngeal edema, cerebral edema, hyponatremia, hypocalcemia, diffuse intravascular coagulation and rhabdomyolysis.<sup>1,2,4,8,9</sup> This condition is not uncommon and is usually transient and mild in severity; however, it can be life-threatening.<sup>10</sup> Additionally, premenopausal women who develop postoperative hyponatremic encephalopathy were found in one study to be 25 times more likely to die or develop permanent neurologic sequelae when compared to men and postmenopausal women with hyponatremic encephalopathy. This is attributed to differences in sex hormone influence on sodium pump function in the central nervous system.<sup>11</sup>

Treatment will vary based on symptoms and severity. If an electrolyte-containing isotonic solution such as 0.9% saline was used then the patient will most likely present with symptoms consistent with volume overload, and treatment will center on optimization of respiratory status with supplemental oxygen, non-invasive positive pressure ventilation or intubation as needed and correction of hypervolemia with loop diuretics. If the distension medium was an electrolyte-free hypotonic solution, as was reported in this case, then patients will likely present with electrolyte disturbances in addition to the hypervolemia. As hyponatremia is the most common electrolyte abnormality seen, clinicians should maintain a high degree of suspicion if a patient presents after operative hysteroscopy with neurologic symptoms. Symptomatic and/or severe acute hyponatremia (serum sodium <120 mmol/L) may be treated with 3% hypertonic saline as a 100 mL bolus infused over 10 minutes. This may be repeated up to three times as needed to increase the serum sodium by 4-6 mmol/L to prevent herniation. Patients with less severe presentations may be treated with a slow infusion of 3% hypertonic saline (0.5-2 mL/kg/hour).<sup>12</sup> Alternatively, these patients may be treated with 0.9% saline and loop diuretics. Consultation with a nephrologist or a critical care specialist is recommended. Monitoring of electrolytes every two to four hours is also advised.

Ambulatory surgical centers performed an increasing percentage of all outpatient surgeries in the United States between 2001-2010.<sup>13</sup> The case presented here highlights some of the challenges with diagnosing and managing these uncommon but severe postoperative syndromes. When symptoms began to manifest in the postoperative period the patient was given supplemental oxygen as well as a dose of furosemide. However, as she was in an ambulatory surgical center, access to diagnostic and therapeutic capabilities was limited. She was started on an infusion of 0.9% saline in a timely manner in the postoperative period. However, a serum sodium level was not measured until she arrived at the ED at which point she had already received 700 mL of 0.9% saline.

This delay in measuring serum sodium does not appear to have adversely influenced the outcome for this patient, but it is unclear whether she would have met criteria for the initiation of hypertonic saline infusion that are outlined in the treatment guidelines.<sup>3,12</sup> Hypertonic saline may have also been helpful in this patient as her severe pulmonary edema could have worsened with higher volumes of 0.9% saline compared to lower volumes of 3% saline that could have been used to correct her hyponatremia if the circumstances were more ideal. Regardless, with limited data the patient was given therapeutic interventions prior to arrival at the ED and she recovered well.

## CONCLUSION

This report highlights a not uncommon entity with an uncommon severity that is familiar to gynecologists and anesthesiologists but is not frequently encountered by emergency providers. Emergency providers should recognize the need to rapidly correct underlying hyponatremia as this can have devastating consequences for patients, in particular premenopausal women.

Documented patient informed consent and/or Institutional Review Board approval has been obtained and filed for publication of this case report.

---

*Address for Correspondence:* Marco F. Elegante, MD, William Beaumont Hospital Royal Oak, Department of Emergency Medicine, 3601 W. 13 Mile Rd. Royal Oak, MI, USA, 48073. Email: Marco.Elegante@beaumont.org

*Conflicts of Interest:* By the CPC-EM article submission agreement, all authors are required to disclose all affiliations, funding sources and financial or management relationships that could be perceived as potential sources of bias. The authors disclosed none.

*Copyright:* © 2019 Elegante et al. This is an open access article distributed in accordance with the terms of the Creative Commons Attribution (CC BY 4.0) License. See: <http://creativecommons.org/licenses/by/4.0/>

---

## REFERENCES

1. Arieff AI and Ayus JC. Endometrial ablation complicated by fatal hyponatremic encephalopathy. *JAMA*. 1993;270(10):1230-2.
2. Istre O, Bjoennes J, Naess R, et al. Postoperative cerebral oedema after transcervical endometrial resection and uterine irrigation with 1.5% glycine. *Lancet*. 1994;344(8931):1187-9.
3. Umranikar S, Clark TJ, Saridogan E, et al. BSGE/ESGE guideline on management of fluid distension media in operative hysteroscopy. *Gynecol Surg*. 2016;13(4):289-303.
4. Wegmüller B, Hug K, Meier Buenzli C, et al. Life-threatening laryngeal edema and hyponatremia during hysteroscopy. *Crit Care Res Pract*. 2011;2011:140381.
5. Propst AM, Liberman RF, Harlow BL, et al. Complications of hysteroscopic surgery: predicting patients at risk. *Obstet Gynecol*. 2000;96(4):517-20.
6. Darwish AM, Hassan ZZ, Attia AM, et al. Biological effects of distension media in bipolar versus monopolar resectoscopic myomectomy: a randomized trial. *J Obstet Gynaecol Res*. 2010;36(4):810-7.
7. Kim J-Y, Chae M, Lee J. Operative hysteroscopy intravascular absorption syndrome caused by massive absorption of 0.9% saline as the distention/irrigation medium. *Korean J Anesthesiol*. 2013;65(6 Suppl):S44-6.
8. Lee GY, Han JI, Heo HJ. Severe hypocalcemia caused by absorption of sorbitol-mannitol solution during hysteroscopy. *J Korean Med Sci*. 2009;24(3):532-4.
9. Brandt RR, Dunn WF, Ory SJ. Dextran 70 embolization. Another cause of pulmonary hemorrhage, coagulopathy, and rhabdomyolysis. *Chest*. 1993;104(2):631-3.
10. Pasini A and Belloni C. [Intraoperative complications of 697 consecutive operative hysteroscopies]. *Minerva Ginecol*. 2001;53(1):13-20.
11. Ayus JC, Wheeler JM, Arieff AI. Postoperative hyponatremic encephalopathy in menstruant women. *Ann Intern Med*. 1992;117(11):891-7.
12. Verbalis JG, Goldsmith SR, Greenberg A, et al. Diagnosis, evaluation and treatment of hyponatremia: expert panel recommendations. *Am J Med*. 2013;126(10 suppl 1):S1-42.
13. Hollenbeck BK, Dunn RL, Suskind AM, et al. Ambulatory surgery centers and outpatient procedure use among Medicare beneficiaries. *Med Care*. 2014;52(10):926-31.

# Misdiagnosed Spontaneous Carotid Cavernous Sinus Fistula

Maureen Canellas, MD  
Navneet Cheema, MD

University of Chicago, Department of Emergency Medicine, Chicago, Illinois

Section Editor: Anna McFarlin, MD

Submission history: Submitted January 8, 2019; Revision received April 23, 2019; Accepted April 22, 2019

Electronically published May 29, 2019

Full text available through open access at [http://escholarship.org/uc/uciem\\_cpem](http://escholarship.org/uc/uciem_cpem)

DOI: 10.5811/cpem.2019.4.42247

A 63-year-old female presented to the emergency department with worsening left-sided blurry vision and diplopia. She had previously seen several physicians and had been diagnosed with common ocular conditions – keratoconus and dry eye. However, despite treatment her symptoms were worsening. By the time her true underlying diagnosis was treated, she was left with permanent vision loss. This case report discusses the presentation, diagnosis, and treatment of her rare condition. [Clin Pract Cases Emerg Med. 2019;3(3):256-258.]

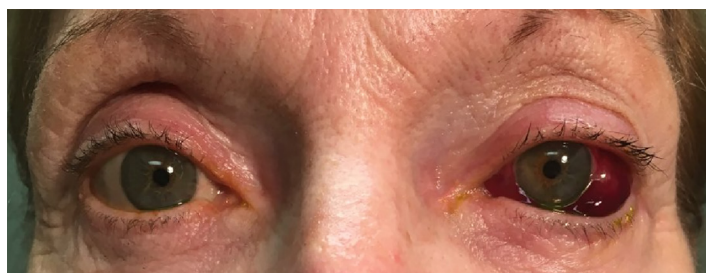## INTRODUCTION

A carotid cavernous fistula (CCF) is a rare connection between the carotid artery and cavernous system. It can occur spontaneously or traumatically.<sup>1</sup> Spontaneous CCFs are more commonly insidious and misdiagnosed.<sup>2</sup> They frequently present with ophthalmoplegia and changes in vision.<sup>3</sup> When left untreated, the damage to cranial nerves and vision loss can become permanent.<sup>2</sup> In this case, we present the diagnosis, treatment, and outcome of a patient with a spontaneous CCF that had been misdiagnosed for months.

## CASE REPORT

A 63-year-old female without past medical history presented with left eye pain and headaches for five months. These symptoms acutely worsened over the prior three days with associated blurry vision and diplopia. The vision changes started gradually and without preceding trauma or an inciting event. They were associated with an intermittent left ear whooshing sound. Over the previous five months, she had one primary care visit, two neurology visits, five emergency department (ED) visits, and seven ophthalmology visits for these symptoms. At her previous visits, she was diagnosed with dry eye and keratoconus, an abnormal bulging of the cornea leading to vision changes, eye redness and pain, and headaches. In the ED her eye exam revealed a left large subconjunctival hemorrhage and chemosis (Image 1).

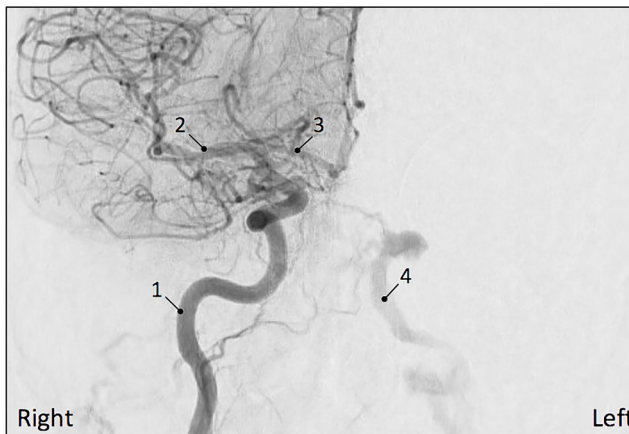Her neurologic exam revealed partial left cranial nerve III, IV, and VI palsies. Laboratory testing and computed tomography (CT) of the head were inconclusive. During the previous five months of visits, she had negative imaging including two CTs



**Image 1.** Physical exam revealing a large, left-sided subconjunctival hemorrhage, proptosis, and chemosis. Patient consent was obtained to use this Image.

of her head without contrast, magnetic resonance imaging (MRI) of her brain with and without contrast, MR angiogram and venogram of her brain, MRI of her orbits with and without contrast, and an ophthalmic ultrasound of her left eye. The emergency team contacted the patient's ophthalmologist given her worsening symptoms despite negative imaging. Her ophthalmologist reported a concern about an ongoing CCF despite continued negative imaging and recommended consulting neurosurgery. Given her cranial nerve deficits and acute worsening of symptoms, the neurosurgery team immediately consented and prepped the patient for diagnostic and therapeutic angiography. Subsequent digital subtraction angiogram was performed with direct localization of the fistula between the internal carotid artery and the cavernous sinus (Image 2). The fistula was coiled with complete closure of the fistula (Image 3).

Overall, this patient had a four-month delay between initial symptoms and definitive treatment. At the time of



**Image 2.** Right carotid system angiogram revealing cross-filling into the left carotid system and left inferior petrosal sinus fistula. (1) Right internal carotid artery; (2) middle cerebral artery; (3) anterior cerebral artery; (4) left internal carotid artery.

discharge, her cranial nerve III and VI palsies resolved and cranial nerve IV palsy partially improved; however, her diplopia and blurry vision remained. These symptoms remained at the patient's one-year follow-up.

## DISCUSSION

This patient was suffering from a rare spontaneous CCF. It is an uncommon condition that can easily be misdiagnosed as conjunctivitis or common ocular problems. CCF is important for the emergency physician to recognize given its potential for morbidity. All CCFs can be classified as direct or dural. Direct fistulas, denoted as high flow, connect the cavernous sinus directly with the intracavernous carotid artery. Dural fistulas, denoted as low flow, connect the cavernous sinus with a branch of the intracavernous carotid artery. Our patient's angiogram findings indicated a dural CCF. Direct fistulas are commonly due to traumatic or spontaneous intimal tears in the artery, while dural fistulas are idiopathic and theorized to be related to genetic predisposition or hypertension.<sup>1,4,5</sup>

Both forms present with primarily ocular and neurologic signs and symptoms, ranging from subjective or ocular bruit (80%), blurry vision (32%), headache (84%), diplopia (88%), proptosis (72%), chemosis (55%), and conjunctival injection (44%).<sup>3,6</sup> In terms of ophthalmoplegia, cranial nerve VI is the most common palsy, followed by cranial nerves III and IV.<sup>3</sup> When a fistula is suspected, advanced imaging such as CT, CT angiography or MRI of the head is required for diagnosis. These images may only show proptosis and expansion of the cavernous sinus and ophthalmic drainage systems and do not reliably localize the fistula.<sup>7</sup> Thus, digital subtraction angiography remains the gold standard for diagnosis. This modality allows for simultaneous treatment via embolization.

### *CPC-EM Capsule*

What do we already know about this clinical entity?

*A carotid cavernous fistula (CCF) is a rare connection between the carotid artery and cavernous system that can occur spontaneously or post trauma.*

What makes this presentation of disease reportable?

*Spontaneous CCFs are not frequently described in the literature and have higher rates of morbidity due to their insidious nature.*

What is the major learning point?

*Emergency physicians should be aware of the diagnosis of CCF as it can masquerade as non-emergent ocular conditions, resulting in delayed diagnosis and vision loss.*

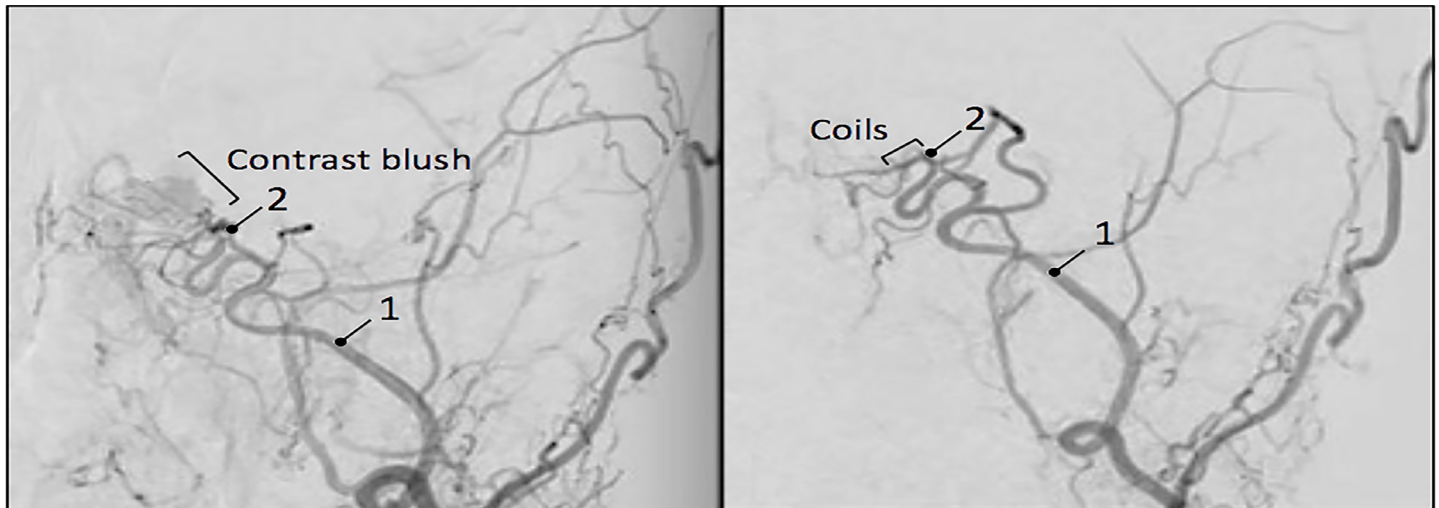
How might this improve emergency medicine practice?

*This case is an important reminder to consider CCF as a cause of spontaneous monocular ophthalmoplegia or vision changes in patients with negative imaging.*

A minority but not insignificant number of patients with direct fistulas sustain intracranial bleeds and life-threatening epistaxis when left untreated.<sup>2,6</sup> However, rates of permanent ophthalmoplegia and vision loss are lower than that of dural fistulas.<sup>8</sup> The high-flow nature of the fistula can lead to the continued tearing of intracerebral vessels, but also allows for an acute onset of symptoms leading to prompt diagnosis and early definitive management.<sup>3</sup> Since low-flow fistulas have a more subacute presentation, they are commonly misdiagnosed as conjunctivitis or other common ocular conditions by multiple providers prior to appropriate management. This delay in treatment correlates to a 20-30% prevalence of permanent vision loss for dural fistulas.<sup>2</sup>

## CONCLUSION

While direct CCFs present clearly, dural CCFs commonly masquerade as a non-emergent ocular condition. This patient had a several-month delay in diagnosis and definitive treatment, leading to permanent vision loss. Emergency physicians should not underestimate this condition's noteworthy, sight-robbing potential.



**Image 3.** (Left) Internal carotid artery angiogram with blush at the site of the fistula, and (right) subsequent closure post-coiling. (1) Cavernous segment of left internal carotid artery; (2) ophthalmologic segment of left internal carotid artery.

Documented patient informed consent and/or Institutional Review Board approval has been obtained and filed for publication of this case report.

**Address for Correspondence:** Maureen Canellas, MD, UMass Memorial Medical Center, Department of Emergency Medicine, 55 Lake Avenue North, Worcester, MA 01655. Email: maureen.canellas@uchospitals.edu

**Conflicts of Interest:** By the CPC-EM article submission agreement, all authors are required to disclose all affiliations, funding sources and financial or management relationships that could be perceived as potential sources of bias. The authors disclosed none.

**Copyright:** © 2019 Canellas et al. This is an open access article distributed in accordance with the terms of the Creative Commons Attribution (CC BY 4.0) License. See: <http://creativecommons.org/licenses/by/4.0/>

## REFERENCES

1. Ringer AJ, Salud L, Tomsick TA. Carotid cavernous fistulas: anatomy, classification, and treatment. *Neurosurg Clin N Am.* 2005;16(2):279-95, viii.
2. Jiamsripong P, Mookadam M, Mookadam F. An uncommon cause of epistaxis: carotid cavernous fistula. *Emerg Med J.* 2007;24(5):e28.
3. Lewis AI, Tomsick TA, Tew JM. Management of 100 consecutive direct carotid-cavernous fistula: results of treatment with detachable balloons. *Neurosurgery.* 1995;36(2):239-44.
4. Helmke K, Krüger O, Laas R. The direct carotid cavernous fistula: a clinical, pathoanatomical, and physical study. *Acta Neurochir (Wien).* 1994;127(1-2):1-5.
5. Van Rooij WJ, Sluzewski M, Beute GN. Ruptured cavernous sinus aneurysms causing carotid cavernous fistula: incidence, clinical presentation, treatment, and outcome. *AJNR Am J Neuroradiol.* 2006;27(1):185-9.
6. Gupta AK, Purkayastha S, Krishnamoorthy T, et al. Endovascular treatment of direct carotid cavernous fistulae: a pictorial review. *Neuroradiology.* 2006;48(11):831-9.
7. Acierno MD, Trobe JD, Cornblath WT, et al. Painful oculomotor palsy caused by posterior-draining dural carotid cavernous fistulas. *Arc Ophthalmol.* 1995;113(8):1045-9. Review.
8. Miller NR. Diagnosis and management of dural carotid-cavernous sinus fistulas. *Neurosurg Focus.* 2007;23(5):E13. Review.

# Atraumatic Back Pain Due to Quadratus Lumborum Spasm Treated by Physical Therapy with Manual Trigger Point Therapy in the Emergency Department

Casey Grover, MD  
Kory Christoffersen, BS  
Lindsay Clark, DPT, PT  
Reb Close, MD  
Stephanie Layhe, PT

Community Hospital of Monterey, Department of Emergency Medicine,  
Monterey, California

Section Editor: Rick A. McPheeters, DO

Submission history: Submitted February 18, 2019; Revision received April 9, 2019; Accepted April 22, 2019

Electronically published May 29, 2019

Full text available through open access at [http://escholarship.org/uc/uciem\\_cpem](http://escholarship.org/uc/uciem_cpem)

DOI: 10.5811/cpcem.2019.4.42788

Manual trigger point therapy is effective for treating myofascial pain, yet it is not frequently used in emergency department (ED) settings. A 42-year-old female presented to the ED with atraumatic back pain. Her pain was thought to be myofascial, and we obtained a physical therapy consultation. Diagnosing the patient with quadratus lumborum spasm, the physical therapist treated her in the ED using manual trigger point therapy, and completely relieved her pain without requiring any medications. Manual trigger point therapy can provide non-opioid pain relief in ED patients, and physical therapists can apply this technique effectively in the ED. [Clin Pract Cases Emerg Med. 2019;3(3):259-261.]

---

## INTRODUCTION

Given the current epidemic of opiate use, addiction, and death from overdose in the United States,<sup>1-3</sup> non-opioid therapies to treat pain are needed to avoid exposing patients to the risk of opioid dependence. We discuss the use of manual trigger point therapy by emergency providers and physical therapists in the emergency department (ED), as an underused non-opioid treatment for pain management in the ED.

## CASE REPORT

A 42-year-old female presented to the ED with left-sided back pain upon waking up in the morning. She reported that the pain was located in the left posterior lower ribs, about the inferior portion of the left scapula. The patient denied associated fevers, trauma, or rashes. She stated that her pain was worse with movement and taking a deep breath, and when reaching her left arm across the right side of the body. She denied any associated numbness or weakness. Her past medical history was notable for hypertension, but she could not recall the name of her anti-hypertensive medication. She

had no allergies and had no other significant past medical or social history, although she did smoke e-cigarettes.

On examination, her vital signs were within normal limits. There was no hypoxia, tachypnea, or tachycardia. Pertinent physical exam findings revealed that the patient was experiencing moderate distress secondary to pain. She had a normal cardiac and pulmonary auscultation, and her skin was normal. Neurologically, her strength and sensation were intact in the upper and lower extremities. On musculoskeletal examination, the provider noted pain with forced adduction of the left arm across the body, and back exam was notable for tenderness in the left paravertebral muscles of the thoracic spine. The provider initially reported concern for pulmonary embolism, which was excluded with the Pulmonary Embolism Rule-out Criteria, as well as concern for pneumothorax and occult rib injury. A chest radiograph with dedicated left-sided rib views revealed no acute abnormality.

Given that the patient's pain appeared to be myofascial in origin, a physical therapy consultation was obtained. The physical therapist was specifically trained in myofascial

manipulation and trigger point release. The patient was diagnosed by the physical therapist with muscular spasm of the left quadratus lumborum muscle, and was treated with manual trigger point therapy, which completely released the spasm in the muscle. Upon re-assessment by the emergency physician (EP), the patient was pain free and had not required any medication while in the ED. She was discharged with topical diclofenac to be used in case the spasm re-occurred.

## DISCUSSION

Manual trigger point therapy is a technique that can be used by healthcare providers from multiple training backgrounds. It involves assessment of a patient in pain for myofascial trigger points, followed by the use of manual techniques to de-activate the trigger point, which results in a decrease in, or resolution of the patient's pain. A myofascial trigger point is a hard, palpable nodule in a tight band of muscle that is hyperirritable and painful. Such trigger points often have multiple contraction knots within the muscle, and are tender on examination.<sup>4</sup> While several therapies are available for management of myofascial trigger points, manual therapy may be used; it involves the use of a provider's hands to provide treatment.

Manual therapy can be defined as application of an accurately determined and specifically directed force to the body to address dysfunction in joints, connective tissue, or muscle. Techniques may include trigger point pressure release, or trigger point compression.<sup>5-6</sup> At our institution, physical therapists have been trained in manual trigger point therapy (course: Myopain Seminars, Bethesda, Maryland), and are available to evaluate and treat ED patients with myofascial pain. An important detail is that manual trigger point therapy involves providing treatment with the provider's hands alone, as opposed to a technique such as trigger point injection or trigger point needling, both of which involve the use of a needle.

While trigger point injections may be used by EPs,<sup>7</sup> they may not be aware of the technique or know how to perform it. Additionally, many patients express a phobia of needles and are not willing to receive an injection; however, they are open to other treatments, which, in the case of severe muscle spasm, may lead to the use of oral opioids or benzodiazepines. Manual trigger point therapy is an effective means of treating muscle spasm without using needles or potentially addictive medications, and therefore represents a novel option for non-opioid ED pain management.

Manual trigger point therapy may be performed by healthcare providers from a variety of training backgrounds, including physical or occupational therapists as well as physicians. As EPs are often busy with multiple critical patients, physical therapists are an excellent option to provide treatment with this technique in the ED. At our institution, manual trigger point therapy has been performed by physical therapy in the ED since March 2018. Physical therapists are available to provide this treatment between 8 AM and 4 PM,

### *CPC-EM Capsule*

What do we already know about this clinical entity?

*Pain is a common presentation to the emergency department (ED), and non-opioid treatments are desirable. Trigger point therapy can provide non-opioid relief.*

What makes this presentation of disease reportable?

*This is the first report of a physical therapist successfully providing manual trigger point therapy in the ED to relieve pain.*

What is the major learning point?

*Emergency providers should consider trigger point therapy to provide non-opioid pain relief.*

How might this improve emergency medicine practice?

*Using trigger point therapy in the ED, including when provided by physical therapists, can improve pain relief without opioids.*

seven days per week. When this service is needed outside of these hours, the EP can provide a trigger point injection (if the patient is willing), use medication, or use a transcutaneous electrical nerve stimulation unit to provide relief. Two osteopathic physicians in our department provide treatment similar to manual trigger point therapy with osteopathic manipulation. In one case, a patient who presented to the ED in the late evening had severe muscle spasm and pain that could not be controlled in the ED with medication. The patient was admitted to the observation unit for physical therapy consultation and treatment with manual trigger point release the next morning, which provided good relief of her pain and spasm.

An informal survey of our EPs (n = 12) revealed that 100% of them agreed the treatment was useful for treating pain, and 100% felt that the technique was an effective intervention to reduce the use of opioids in the ED. A similar informal survey of the physical therapists trained in the technique at our hospital (n = 9) revealed that 100% of them also felt that the treatment was useful for treating pain.

To the best of our knowledge, this is the first report of using manual trigger point therapy to treat muscle spasm by physical therapists in the ED. While this intervention may have been performed in this way at other institutions, we

chose to report our case as it was so successful at relieving pain without the use of medication, and may encourage further use of this technique and future research on the topic.

## CONCLUSION

Manual trigger point therapy is an inexpensive and effective way to treat myofascial pain and can be used in the ED, particularly when it is advisable to avoid opioids or other sedating medications. If EPs are unable to perform the treatment, physical therapists can be easily trained in the technique and are effective in using it to treat pain in ED patients.

## REFERENCES

1. Gwira Baumblatt JA, Wiedeman C, Dunn JR, et al. High-risk use by patients prescribed opioids for pain and its role in overdose deaths. *JAMA Intern Med.* 2014;174(5):796-801.
2. Paulozzi LJ, Strickler GK, Kreiner PW, et al. Controlled substance prescribing patterns – prescription behavior surveillance system, eight states, 2013. *MMWR Surveill Summ.* 2015;64(9):1-14.
3. Guy GP Jr, Zhang K, Bohm MK, et al. Vital signs: changes in opioid prescribing in the United States, 2006-2015. *MMWR Morb Mortal Wkly Rep.* 2017;66(26):697-704.
4. Shah JP, Thaker N, Heimur J, et al. Myofascial trigger points then and now: a historical and scientific perspective. *PM R.* 2015;7(7):746-61.
5. Morikawa Y, Takamoto K, Nishimaru H, et al. Compression at myofascial trigger point on chronic neck pain provides pain relief through the prefrontal cortex and autonomic nervous system: a pilot study. *Front Neurosci.* 2017;11:186.
6. Travell JG and Simons DG. Myofascial Pain and Dysfunction: The Trigger Point Manual. Vol 2. Baltimore MD. Williams and Wilkins, 1992.
7. Roldan C and Hu N. Myofascial pain syndromes in the emergency department: What are we missing? *J Emerg Med.* 2015;49(6):1004-10.

Documented patient informed consent and/or Institutional Review Board approval has been obtained and filed for publication of this case report.

---

*Address for Correspondence:* Casey A Grover, MD, Community Hospital of the Monterey Peninsula, Department of Emergency Medicine, 23625 Homan Highway, Monterey, CA, 93940. Email: caseygrover@gmail.com

*Conflicts of Interest:* By the CPC-EM article submission agreement, all authors are required to disclose all affiliations, funding sources and financial or management relationships that could be perceived as potential sources of bias. The authors disclosed none.

*Copyright:* © 2019 Grover et al. This is an open access article distributed in accordance with the terms of the Creative Commons Attribution (CC BY 4.0) License. See: <http://creativecommons.org/licenses/by/4.0/>

---

# Left Ventricular Regional Wall Motion Abnormality in the Setting of Acute Loperamide Overdose

**Kasha Bornstein, MSc\***  
**Timothy Montrief, MD, MPH†**  
**Mehruba Anwar Parris, MD†**

\*University of Miami Miller School of Medicine, Miami, Florida  
†Jackson Memorial Hospital, Department of Emergency Medicine, Miami, Florida

Section Editor: Rick A. McPheeters, DO

Submission history: Submitted January 23, 2019; Revision received April 8, 2019; Accepted April 22, 2019

Electronically published July 1, 2019

Full text available through open access at [http://escholarship.org/uc/uciem\\_cpem](http://escholarship.org/uc/uciem_cpem)

DOI: 10.5811/cpcem.2019.4.42510

Loperamide is an inexpensive, over-the-counter antidiarrheal agent with emerging reports of overdose due to its opioid properties. Although it is considered by many patients to be safe, cardiotoxicity has been reported, prompting the United States Food and Drug Administration to release a warning regarding the arrhythmogenic potential of loperamide. We present a case of a 32-year-old male presenting in acute loperamide overdose and subsequent cardiac dysrhythmia with focal wall motion abnormalities on echocardiogram. This finding has not been previously reported in the literature and is unique in this clinical presentation. We also highlight the potential mechanisms for loperamide cardiotoxicity and its challenging management. [Clin Pract Cases Emerg Med. 2019;3(3):262-266.]

---

## INTRODUCTION

Loperamide is an inexpensive, widely used, nonprescription antidiarrheal. Its mechanism of action involves inhibition of intestinal peristalsis through  $\mu$ -opioid receptor agonism, calcium channel blockade, calmodulin inhibition, and by decreasing paracellular permeability.<sup>1</sup> Loperamide is sold under the trade name Imodium in the United States (U.S.). When initially introduced in the 1970s, loperamide was listed as a Schedule II drug, due to concerns over its opioid properties. Loperamide was transferred to Schedule V in 1977, and then decontrolled in 1982 following multiple volunteer studies showing low risk of dependence at therapeutic doses secondary to its poor oral systemic bioavailability and limited central nervous system penetration.<sup>2-4</sup> However, reports of loperamide misuse are increasing, more commonly at very high doses of 70-100 milligrams (mg) per day, either to attenuate the effects of opioid withdrawal or for its euphoric effects.<sup>5</sup>

As loperamide misuse has become more widespread in the past decade, descriptions of significant cardiac dysrhythmias in the overdose setting have emerged. These include ventricular tachycardia and torsades de pointes secondary to the drug's ability to block cardiac sodium and potassium channels at high doses.<sup>6-7</sup> The U.S. faces an increasing population of opioid-

addicted patients with escalating opioid overdose mortality. In the setting of efforts to regulate prescription opioid medication misuse through new legislation, many patients are turning to loperamide as an accessible and inexpensive alternative. An added benefit is the lack of social stigma associated with its use.<sup>8</sup> It is imperative that healthcare providers be made aware of this emerging trend of loperamide use and its under-recognized cardiac toxicity. We describe one case of loperamide overdose presenting with cardiac dysrhythmia and focal wall motion abnormalities discovered on echocardiogram.

## CASE REPORT

A 32-year-old man with a history of polysubstance use including heroin was found combative and delirious in his room by staff at his sober living facility. Multiple empty boxes of loperamide were found in his backpack at the scene by emergency medical services. He was given intravenous (IV) fluids and transported to the emergency department (ED). In the ED, he was notably agitated. On physical exam, he was noted to be tachycardic with a regular pulse of 128 beats per minute and a blood pressure of 123/77 millimeters of mercury (mmHg). He was tachypneic with mild respiratory distress, diaphoretic, and oriented to person only.

He was intubated for airway protection using etomidate and succinylcholine. An initial electrocardiogram (ECG) showed a regular, wide-complex tachycardia with a prolonged QTc of 473 milliseconds (ms) and QRS of 140 ms, with an RSR' pattern in lead aVR. This was determined to be sinus tachycardia with a left bundle branch block by the consulting cardiologist and electrophysiologist (Image 1). The patient's electrolyte levels were within normal limits.

Acutely, in conjunction with poison control the decision was made to manage the patient with 0.4 milligram (mg) IV naloxone, 400 mg IV lidocaine, and one gram IV magnesium. The patient also received 50 milliequivalent (mEq) IV sodium bicarbonate for presumed sodium channel toxicity from the high-dose loperamide. An initial troponin I was elevated to 0.084 nanograms (ng) per milliliter (mL) (reference 0.000-0.045 ng/mL). A point-of-care ultrasound (POCUS) demonstrated left ventricular anterior wall hypokinesis. He underwent emergent cardiac catheterization, which revealed left ventricular anterior wall hypokinesis, angiographically normal cardiac arteries with a left ventricle ejection fraction (LVEF) of 45%, and an elevated left ventricular filling pressure of 23 mmHg.

During his hospitalization, the patient's QT peaked one day after admission to 616 ms with a QTc 573 ms and a QRS of 120 ms (Image 2). At that time the patient admitted to taking over 100 mg of loperamide as well as an unknown amount of gabapentin as an alternative to opioids on the day of admission. His dysrhythmia resolved and QTc normalized within four days of admission with no further exposure to loperamide. A subsequent transthoracic ECG showed a LVEF of 55% and no evidence of diastolic dysfunction or hypokinesis of the anterior wall. At discharge, his ECG

### CPC-EM Capsule

What do we already know about this clinical entity?

*Loperamide is a widely used, nonprescription opioid antidiarrheal typically understood to have low risk of dependence given its low bioavailability and limited central nervous system activity.*

What makes this presentation of disease reportable?

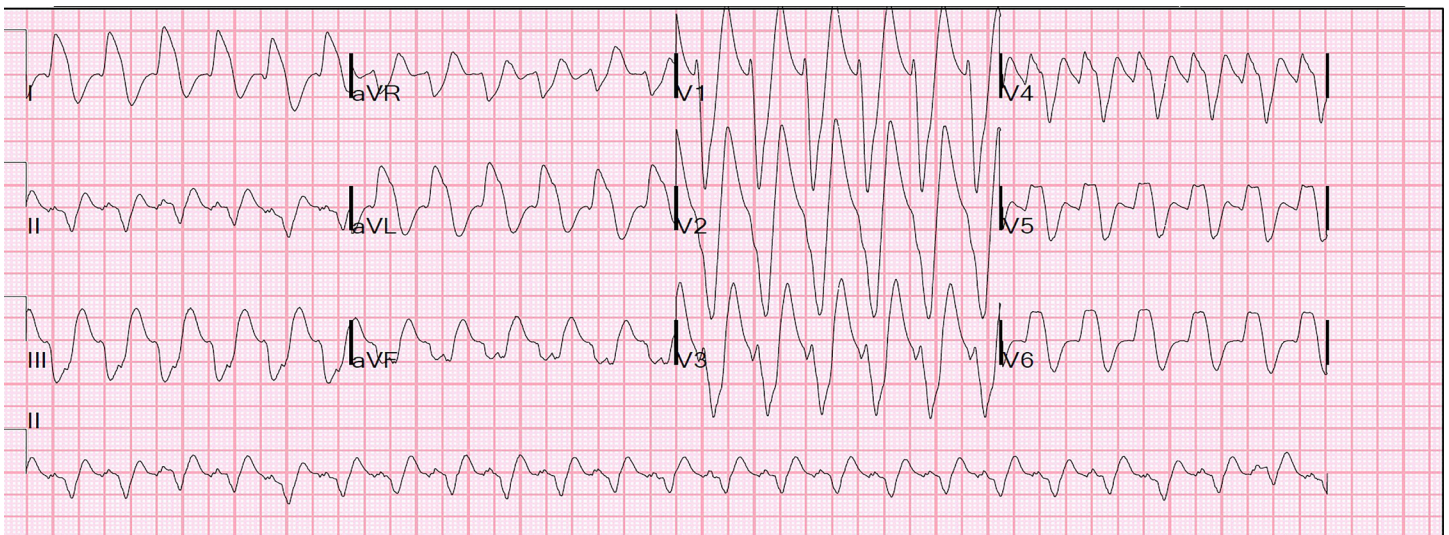
*Prior to this case, there were no reported instances of cardiac angiography confirming loperamide as a primary pharmacological cause of depressed myocardial function.*

What is the major learning point?

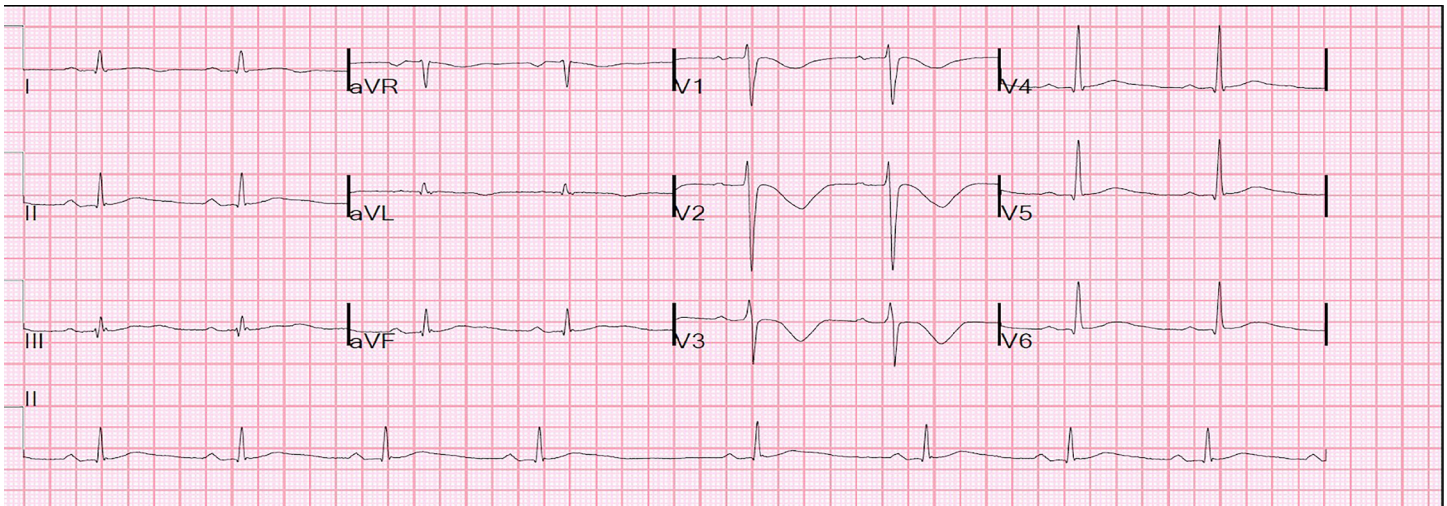
*Loperamide toxicity can present with elevated cardiac injury markers. Resuscitation should be guided by treatment of factors that may induce electrolyte abnormalities.*

How might this improve emergency medicine practice?

*This case contributes to awareness of the toxidrome as a unique clinical entity. Management to guide resuscitation should be based on pharmacologic principles.*



**Image 1.** Patient's initial electrocardiogram showing sinus tachycardia with a left bundle branch block and prolonged QT interval of 328 milliseconds (ms), QTc of 470 ms, and QRS of 140 ms.



**Image 2.** Patient's electrocardiogram one day after admission showing first degree atrioventricular block, and loperamide-induced QT prolongation, with a QT interval of 616 milliseconds (ms), QTc of 573 ms, and QRS of 120 ms.

showed a QTc of 442 ms and a QRS of 98 ms (Image 3). A loperamide serum concentration was not measured during hospitalization. Urine toxicology screen on admission was negative for opiates as loperamide is not included in the standard panel of drugs screened.

## DISCUSSION

This is a novel case of acute loperamide overdose with subsequent cardiac dysrhythmia with focal wall motion abnormalities on ECG. We do not think gabapentin contributed to his cardiac toxicity as the mechanism of action, nor would toxicity of gabapentin explain the clinical presentation or the laboratory abnormalities. Furthermore, there have been no prior reports of arrhythmias with gabapentin, although both hypertension and hypotension have been reported. The management of loperamide toxicity is largely supportive, although some recommendations can be extrapolated from case reports, pharmacologic principals, and anecdotal experience. In the setting of an acute ingestion, loperamide should adsorb to activated charcoal. Activated charcoal can be administered within two to four hours after a large overdose, provided the patient is not an aspiration risk, in contrast to our case.<sup>9</sup>

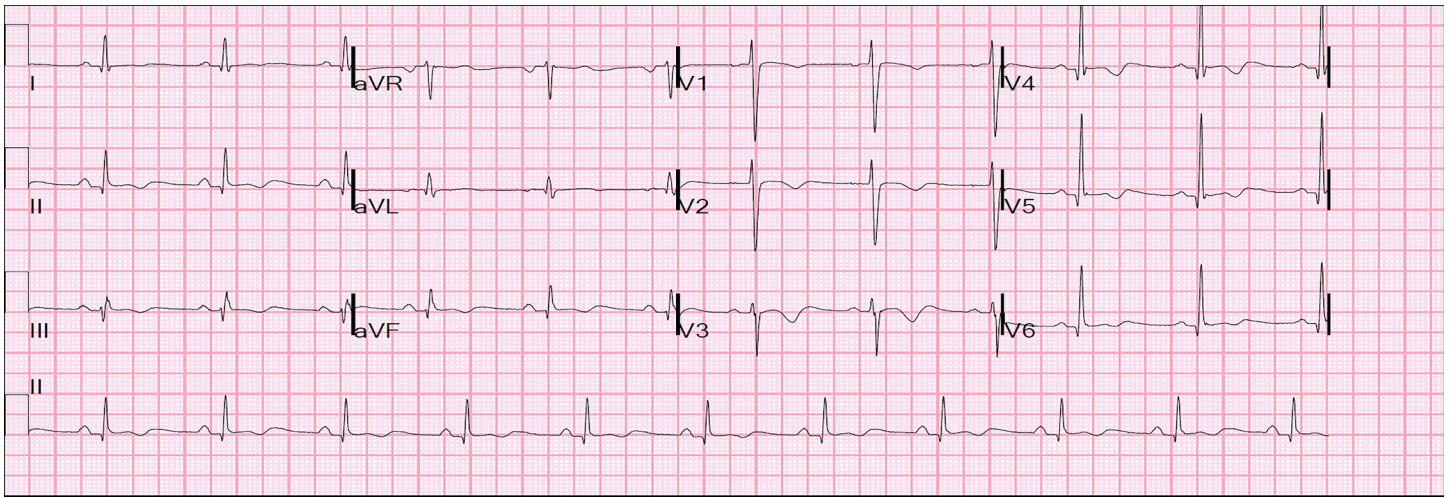
For patients with decreased responsiveness or respiratory depression, naloxone can be considered as an adjunct to appropriate airway management. This modality showed benefit in one adult case<sup>10</sup> and a series of pediatric cases.<sup>11,12</sup> In one pediatric case, a four-month-old girl inadvertently ingested approximately two mg/kg of loperamide liquid and subsequently became comatose with respiratory depression. She recovered after three injections of 0.01 mg IV naloxone over 24 hours.<sup>12</sup> While naloxone should reverse the respiratory depression induced by

loperamide's  $\mu$ -opioid agonism, it would not be expected to affect the cardiotoxicity associated with loperamide. However, little data exists to guide naloxone use in acute loperamide toxicity, including dosing. Given loperamide's long half-life, repeated doses of naloxone may be warranted.<sup>12</sup>

ECG abnormalities are characteristic of loperamide toxicity, particularly prolonged QT and QRS intervals. Again, little data exists to guide cardiac resuscitation in the setting of loperamide ingestion. It is therefore reasonable to treat factors that may induce ECG interval prolongation such as electrolyte abnormalities and other medications. This may be attempted with antiarrhythmic medications such as amiodarone, sotalol, lidocaine, or procainamide,<sup>13-15</sup> as well as sodium bicarbonate to overcome loperamide's sodium channel blockade. Class 1b antiarrhythmic agents such as lidocaine may be preferable in loperamide toxicity as they have weak sodium channel blocking effects and decrease the effective refractory period in comparison to other class one agents.

## CONCLUSION

Within the literature, the majority of case reports regarding loperamide overdose describe a constellation of symptoms including decreased levels of consciousness, unheralded syncope, markedly increased QTc and QRS intervals, and dysrhythmias including ventricular tachycardia and torsades de pointes. Only one case is reported in which a long-time loperamide user presented with severely depressed global left ventricular function measured by ECG but normal coronary angiography.<sup>16</sup> Additionally, two case reports of loperamide overdose described mild global hypokinesis of the left ventricle as measured by ECG without corresponding coronary



**Image 3.** Patient's electrocardiogram upon discharge, showing a sinus rhythm with a QT interval of 434 milliseconds (ms), QTc of 442 ms, and QRS of 98 ms.

angiography.<sup>15,17</sup> The literature includes only one case report of acute loperamide overdose involving a patient who received both an ECG and coronary angiography. In that case, investigations revealed normal ventricular function and no angiographic abnormalities.<sup>18</sup> This case provides an opportunity to describe a novel presentation of acute loperamide toxicity, with an elevated cardiac injury marker and confirmed focal left ventricular anterior wall hypokinesia that subsequently resolved after clearance of the drug.

Documented patient informed consent and/or Institutional Review Board approval has been obtained and filed for publication of this case report.

**Address for Correspondence:** Kasha Bornstein, MSc, University of Miami Miller School of Medicine, 1600 NW 10th Avenue, Miami, FL 33136. Email: kashabornstein@med.miami.edu.

**Conflicts of Interest:** By the CPC-EM article submission agreement, all authors are required to disclose all affiliations, funding sources and financial or management relationships that could be perceived as potential sources of bias. The authors disclosed none.

**Copyright:** © 2019 Bornstein et al. This is an open access article distributed in accordance with the terms of the Creative Commons Attribution (CC BY 4.0) License. See: <http://creativecommons.org/licenses/by/4.0/>

## REFERENCES

- Baker DE. Loperamide: a pharmacological review. *Rev Gastroenterol Disord.* 2007;7(suppl 3):S11-8.
- DEA Office of Diversion Control. DEA Orange Book Lists of Scheduling Actions. 2016. Available at: <http://www.deadiversion.usdoj.gov/schedules/orangebook/orangebook.pdf>. Accessed April 6, 2019.
- Jaffe JH, Kanzler M, Green J. Abuse potential of loperamide. *Clin Pharmacol Ther.* 1980;28(6):812-9.
- Korey A, Zilm DH, Sellers EM. Dependence liability of two antidiarrheals, nufenoxole and loperamide. *Clin Pharmacol Ther.* 1980;27(5):659-64.
- Juurink DN. Activated charcoal for acute overdose: a reappraisal. *Br J Clin Pharmacol.* 2016;81(3):482-7.
- Kang J, Compton DR, Vaz RJ, et al. Proarrhythmic mechanisms of the common anti-diarrheal medication loperamide: revelations from the opioid abuse epidemic. *Naunyn Schmiedebergs Arch Pharmacol.* 2016;389(10):1133-7.
- Harmer AR, Valentin JP, Pollard CE. On the relationship between block of the cardiac Na channel and drug-induced prolongation of the QRS complex. *Br J Pharmacol.* 2011;164(2):260-73.
- Lasoff DR, Koh CH, Corbett B, et al. Loperamide trends in abuse and misuse over 13 years: 2002-2015. *Pharmacotherapy.* 2017;37(2):249-53.
- Daniulaityte R, Carlson R, Falck R, et al. 'I just wanted to tell you that loperamide WILL WORK': a web-based study of extra-medical use of loperamide. *Drug Alcohol Depend.* 2013;130(1-3):241-4.
- Bhatti Z, Norsworthy J, Szombathy T. Loperamide metabolite-induced cardiomyopathy and QTc prolongation. *Clin Toxicol (Phila).* 2017;55(7):659-61.
- Minton NA and Smith PG. Loperamide toxicity in a child after a single dose. *Br Med J (Clin Res Ed).* 1987;294(6584):1383.
- Friedli G and Haenggeli CA. Loperamide overdose managed by

- naloxone. *Lancet*. 1980;1(8183):1413.
13. Lasoff DR and Schneir A. Ventricular dysrhythmias from loperamide misuse. *J Emerg Med*. 2016;50(3):508-9.
  14. Upadhyay A, Bodar V, Malekzadegan M, et al. Loperamide induced life threatening ventricular arrhythmia. *Case Rep Cardiol*. 2016:5040176.
  15. Spinner HL, Lonardo NW, Mulamalla R, et al. Ventricular tachycardia associated with high-dose chronic loperamide use. *Pharmacotherapy*. 2015;35(2):234-8.
  16. Mirza M, Attakamvelly S, Dillon A, et al. Potential life threatening cardiac toxicity from an easily accessible over the counter drug. *J Am Coll Cardiol*. 2017;69(11):2375.
  17. Patel KM, Shah S, Subedi D. Takotsubo-like cardiomyopathy after loperamide overdose. *Am J Ther*. 2018;25(5):e548-50.
  18. Salama A, Levin Y, Jha P, et al. Ventricular fibrillation due to overdose of loperamide, the "poor man's methadone." *J Community Hosp Intern Med Perspect*. 2017;7(4):222-6.

# Life-threatening Development of Cardiac Tamponade in the Span of 24 Hours

Patrick Kishi, MD  
Thaer Ahmad, MD  
Kenneth W. Dodd, MD

Advocate Christ Medical Center, Department of Emergency Medicine, Oak Lawn, Illinois

Section Editor: Rick A. McPheeters, DO

Submission history: Submitted February 13, 2019; Revision received April 17, 2019; Accepted April 22, 2019

Electronically published July 1, 2019

Full text available through open access at [http://escholarship.org/uc/uciem\\_cpem](http://escholarship.org/uc/uciem_cpem)

DOI: 10.5811/cpcem.2019.4.42741

Cardiac tamponade is a medical emergency that requires immediate treatment. Caused by the development of fluid in the pericardial space, it can result in a severe decrease in cardiac output. When encountering patients with severe hypotension and tachycardia, emergency physicians must always consider the diagnosis of tamponade to facilitate prompt and effective treatment and stabilization. We report our experience with a patient who developed life-threatening cardiac tamponade within a span of less than 24 hours. [Clin Pract Cases Emerg Med. 2019;3(3):267-270.]

---

## INTRODUCTION

Cardiac tamponade is a medical emergency that is caused by compression of the cardiac chambers due to an accumulation of fluid in the pericardial space.<sup>1,2</sup> Approximately 15-30 milliliters (mL) of fluid lies between the parietal pericardium and visceral pericardium in normal physiologic states.<sup>3,4</sup> If fluid accumulation surpasses a critical threshold, cardiac output and blood pressure drop precipitously.<sup>4,5</sup> However, due to the adaptive and elastic properties of the pericardium, the amount of pericardial fluid that can be tolerated is related to the rate of the accumulation of fluid.<sup>1</sup> Chronic accumulation of fluid gives the pericardium time to gradually increase its compliance; thus, tamponade may not be seen until a large amount of fluid has developed in the pericardial sac. In acute settings, the pericardium does not have time to increase its compliance, leading to a rapid decline in cardiac output.

Several causes of cardiac tamponade have been identified, including idiopathic, infectious, autoimmune, malignancy, trauma, and metabolic etiologies.<sup>6-8</sup> One study identified the most common diagnoses of patients with pericardial effusions as follows: acute idiopathic pericarditis (20%), iatrogenic cause (16%), malignancy (13%), chronic idiopathic effusion (9%), acute myocardial infarction (8%), end stage renal disease (6%), and tuberculosis or bacterial infection (4%).<sup>4,9</sup>

The clinical presentation of cardiac tamponade can vary widely. Acute presentations of tamponade can occur

within minutes or hours, as is typically seen in trauma, aortic rupture, or iatrogenic result from an invasive procedure. Acute presentations frequently result in life-threatening hypotension necessitating immediate interventions to decrease the pericardial pressure.<sup>10</sup> In contrast, the subacute presentations can occur over days to weeks and hypotension is relatively uncommon.<sup>4,11</sup> One study demonstrated that 27-43% of patients presenting with subacute cardiac tamponade are actually hypertensive, with systolic blood pressures ranging from 127 millimeter of mercury (mmHg) to 144 mmHg, likely secondary to increased activity of the sympathetic nervous system.<sup>11,12</sup> Clinical findings of tamponade can vary, and no sensitive or specific signs have been identified.<sup>13</sup> Findings may include tachycardia, jugular venous distension, pulsus paradoxus, tachypnea, hypotension, hypertension, and pericardial rub. The classic presentation of Beck's triad, characterized by hypotension, increased jugular venous pressure, and muffled heart sounds, is seen only in a small number of acute cardiac tamponade cases.<sup>14</sup>

When considering cardiac tamponade in patients, the diagnostic workup should include an electrocardiogram, chest radiograph, and echocardiogram. While tamponade is mostly a clinical diagnosis, echocardiography is highly recommended by multiple task forces and societies.<sup>13,15</sup> If available in the emergency department (ED), point-of-care ultrasound should be used by emergency physicians to help identify and possibly treat acute cardiac tamponade.

Our report describes a life-threatening presentation of cardiac tamponade that developed over the span of one day in a young, female patient.

## CASE REPORT

A 23-year-old African-American female presented to our ED with one day of sharp, midline chest pain that radiated to her jaw and left arm. She reported mild associated shortness of breath but no exertional symptoms. The review of systems was otherwise unremarkable. Her past medical history was significant for adrenal insufficiency on daily hydrocortisone, hypothyroidism, and two prior episodes of pericardial effusion with previous drainage procedures. Vital signs included a blood pressure of 129/96 mmHg, heart rate 99 beats per minute, and oxygen saturation 100% on room air. The patient was afebrile. Initial laboratory workup was unremarkable with a negative troponin. Due to the patient's history of pericardial effusions, a formal transthoracic echocardiogram was performed, which demonstrated normal systolic function with an ejection fraction of 50-55% and no evidence of a pericardial effusion (Video 1). The patient was then discharged home.

The following day, the patient presented to our ED with similar symptoms, including chest pain and shortness of breath. Upon evaluation, her vital signs demonstrated severe hypotension with a blood pressure of 71/52 mmHg, heart rate 121 beats per minute, respiratory rate 16 breaths per minute, oxygen saturation 100% on room air, and temperature 36.8°C. Her exam was now significant for depressed mental status and lethargy. A point-of-care cardiac ultrasound was performed, which demonstrated a large amount of pericardial fluid and right ventricular collapse. Immediate transthoracic echocardiogram confirmed these findings (Videos 2 and 3).

Interventional cardiology and cardiovascular surgery were consulted, and a decision was made to take the patient to the operating room emergent pericardiectomy. In the operating room, approximately 300 mL of turbid, yellow fluid was evacuated from the underlying pericardium. A 24 French Blake drain was placed in the pericardium and the patient was admitted to the intensive care unit.

With the patient's previous pericardial effusion, past laboratory workup demonstrated high titers for coxsackie B virus. Upon this admission, a viral panel was negative, including hepatitis B panel, influenza, respiratory syncytial virus, corona virus, metapneumovirus, parainfluenza virus types 1,3, and 4, Epstein-Barr virus, cytomegalovirus, human immunodeficiency virus, coxsackie, influenza A, mycoplasma pneumonia, *Chlamydia pneumoniae*, buccal virus, and rhinovirus. Rheumatologic workup was also negative, including antinuclear antibody, anti-double stranded deoxyribonucleic acid, antimicrosomal antibody, anticentromere antibody, Sjogren's syndrome A and B, Smith antibody, celiac

### *CPC-EM Capsule*

What do we already know about this clinical entity?

*Cardiac tamponade is a life-threatening illness that requires emergent recognition and treatment.*

What makes this presentation of disease reportable?

*We present a unique case of a patient who developed severe, life-threatening cardiac tamponade in under 24 hours that necessitated immediate intervention.*

What is the major learning point?

*Cardiac tamponade can develop rapidly, and recent negative imaging does not rule it out. Point-of-care ultrasound can help rapidly identify this disease process.*

How might this improve emergency medicine practice?

*Emergency physicians must always consider cardiac tamponade in hypotensive, tachycardic patients.*

screen, anti-Jo 1 antibody, and anti-SCL-70 antibody (anti-topoisomerase I). Further testing for anti-21 alpha hydroxylase and anti-TPO antibodies were also negative.

Pericardial fluid analysis demonstrated predominantly acute inflammatory cells without any evidence of malignancy. Pericardial biopsy results were unrevealing. Repeat echocardiogram demonstrated normal left ventricular ejection fraction of 50-55% and no significant pericardial effusion. The patient was discharged 10 days following initial presentation and has not had any subsequent episodes of cardiac tamponade or pericardial effusions diagnosed at our institution.

## DISCUSSION

Our report highlights a unique presentation of life-threatening, atraumatic cardiac tamponade that developed over the span of 24 hours in a young female with a history of pericardial effusion.

Echocardiography has a class I recommendation to evaluate most pericardial diseases as it can identify anatomic, physiologic, and hemodynamic abnormalities of the heart.<sup>15</sup> When evaluating for pericardial effusions, this

imaging modality can estimate the size and location of the effusion. Effusions can be classified based on quantitative measurements: small <10 mm, moderate 10-20 mm, and large >20 mm in size.<sup>13</sup> Echocardiographic signs of tamponade include collapsing cardiac chambers, changes in chamber volumes and flows with respiration, and inferior venous cava dilation.<sup>13</sup> While any heart chambers may collapse in tamponade, the most common findings are right-sided atrial and ventricular collapse, and studies have demonstrated that right atrial collapse is highly sensitive and specific for tamponade if it persists for longer than one-third of the cardiac cycle.<sup>15</sup> Collapse of the right ventricle is less sensitive than right atrial collapse, but very specific for tamponade.<sup>16</sup>

This patient was treated by a cardiothoracic surgeon who performed a pericardial window to remove the pericardial fluid. Most patients with cardiac tamponade require drainage of the effusion to improve symptoms. The two methods of removal include percutaneous drainage by a pericardiocentesis and surgical drainage by creating a pericardial window (pericardiectomy). While each method has its advantages, our patient underwent surgical pericardiectomy. This procedure allows the clinician to obtain pericardial biopsies for further evaluation, which was an important consideration in this patient given her history of recurrent effusions. For our patient, analysis of the fluid and subsequent rheumatologic and malignant workups were negative. Interestingly, the patient tested negative for the most common etiologies of tamponade. Upon discharge, a repeat echocardiogram demonstrated no evidence of re-accumulation of a pericardial effusion.

## CONCLUSION

Despite the acute, life-threatening presentation of cardiac tamponade, this patient was successfully treated by surgical pericardiectomy to remove pericardial fluid. While there are many known causes of cardiac tamponade, our patient had a completely negative workup. This case illustrates the importance for emergency physicians to always consider the diagnosis of cardiac tamponade when encountering patients with severe hypotension and tachycardia. Without prompt and proper identification of this diagnosis, patients have a high likelihood of experiencing severe morbidity and possibly mortality. Immediate point-of-care cardiac ultrasound and transthoracic echocardiography can aid in the diagnosis. In conclusion, we report a unique presentation of severe cardiac tamponade that developed within a 24-hour interval period and was successfully treated with a pericardial window.

**Video 1.** A formal parasternal long-axis view of the heart in the patient when she initially presented to the emergency department. No significant pericardial effusion is seen.

**Video 2.** A formal parasternal long-axis view of the heart of the patient when she re-presented the following day. A large pericardial effusion can be seen. (Arrows indicate surrounding fluid).

**Video 3.** A formal apical four-chamber view of the heart demonstrating a large pericardial effusion (Top arrow demonstrates fluid, bottom arrow demonstrates right atrial collapse).

Documented patient informed consent and/or Institutional Review Board approval has been obtained and filed for publication of this case report.

---

*Address for Correspondence:* Patrick Kishi, MD, Advocate Christ Medical Center, Department of Emergency Medicine, 4440 95th St, Oak Lawn, IL 60453. Email: Patrick.kishi@advocatehealth.com.

*Conflicts of Interest:* By the CPC-EM article submission agreement, all authors are required to disclose all affiliations, funding sources and financial or management relationships that could be perceived as potential sources of bias. The authors disclosed none.

*Copyright:* © 2019 Kishi et al. This is an open access article distributed in accordance with the terms of the Creative Commons Attribution (CC BY 4.0) License. See: <http://creativecommons.org/licenses/by/4.0/>

---

## REFERENCES

1. Spodick DH. Acute cardiac tamponade. *N Engl J Med*. 2003;349(7):684-90.
2. Troughton RW, Asher CR, Klein AL. Pericarditis. *Lancet*. 2004;363(9410):717-27.
3. Spodick DH. Pericarditis, pericardial effusion, cardiac tamponade, and constriction. *Crit Care Clin*. 1989;5(3):455-76.
4. Roy CL, Minor MA, Brookhart MA, et al. Does this patient with a pericardial effusion have cardiac tamponade? *JAMA*. 2007;297(16):1810-8.
5. Fowler NO. Physiology of cardiac tamponade and pulsus paradoxus, II: physiological, circulatory, and pharmacological responses in cardiac tamponade. *Mod Concepts Cardiovasc Dis*. 1978;47(12):115-8.
6. LeWinter MM. Clinical practice. Acute pericarditis. *N Engl J Med*. 2014;371(25):2410-6.
7. Imazio M and Gaita F. Diagnosis and treatment of pericarditis. *Heart*. 2015;101(14):1159-68.
8. Imazio M. Contemporary management of pericardial diseases. *Curr*

- Opin Cardiol.* 2012;27(3):308-17.
9. Sagristà-Sauleda J, Merce J, Permanyer-Miralda G, et al. Clinical clues to the causes of large pericardial effusions. *Am J Med.* 2000;109(2):95-101.
  10. Reddy PS, Curtiss EI, Uretsky BF. Spectrum of hemodynamic changes in cardiac tamponade. *Am J Cardiol.* 1990;66(20):1487-91.
  11. Argulian E and Messerti F. Misconceptions and facts about pericardial effusion and tamponade. *Am J Med.* 2013;126(10):858-61.
  12. Argulian E, Herzog E, Halpern DG, et al. Paradoxical hypertension with cardiac tamponade. *Am J Cardiol.* 2012;110(7):1066-9.
  13. Adler Y, Charron P, Imazio M, et al. 2015 ESC Guidelines for the diagnosis and management of pericardial diseases: The Task Force for the Diagnosis and Management of Pericardial Diseases of the European Society of Cardiology (ESC) Endorsed by: The European Association for Cardio-Thoracic Surgery (EACTS). *Eur Heart J.* 2015;36(42):2921-64.
  14. Beck CS. Two cardiac compression triads. *JAMA.* 1935;104(9):714-6.
  15. Cheitlin MD, Armstrong WF, Aurigemma GP, et al. ACC/AHA/ASE 2003 guideline for the clinical application of echocardiography: summary article. *J Am Soc Echocardiogr.* 2003;16(10):1091-110.
  16. Kerber RE, Gascho JA, Litchfield R, et al. Hemodynamic effects of volume expansion and nitroprusside compared with pericardiocentesis in patients with acute cardiac tamponade. *N Engl J Med.* 1982;307(15):929-31.

# Dyspnea in an Otherwise Healthy 18-year-old: The Importance of Point-of-care Ultrasonography

Emily C. Cleveland Manchanda, MD, MMPH  
Sigmund J. Kharasch, MD  
Andrew S. Liteplo, MD, RDMS

Massachusetts General Hospital, Department of Emergency  
Medicine, Boston, Massachusetts

Section Editor: Anna Mcfarlin, MD and Rick A. McPheeters, DO

Submission history: Submitted May 30, 2018; Revision received August 23, 2018; Accepted September 6, 2018

Electronically published July 1, 2019

Full text available through open access at [http://escholarship.org/uc/uciem\\_cpchem](http://escholarship.org/uc/uciem_cpchem)

DOI: 10.5811/cpcem.2018.9.39218

A healthy 18-year-old male presented to the emergency department with chest pain, palpitations, and dyspnea. His exam was unremarkable; however, point-of-care ultrasound (POCUS) revealed right ventricular strain with a D-sign and enlarged right ventricle. He subsequently reported a history of factor V Leiden. His D-dimer was markedly elevated, and a computed tomography angiogram of the chest demonstrated submassive pulmonary embolism (PE). He was taken to the catheterization lab for directed thrombolysis and was discharged in good condition two days later. Factor V Leiden is the most common genetic cause of venous thromboembolism. POCUS can facilitate rapid diagnosis and risk stratification of patients with acute PE. [Clin Pract Cases Emerg Med. 2019;3(3):271-274.]

---

## INTRODUCTION

Within the field of emergency medicine, point-of-care ultrasound (POCUS) has become a widely accepted tool in the emergency physician's (EP) arsenal for both diagnosing and exonerating pathology. Nevertheless, consulting services are often skeptical of the EP's ultrasound findings, and at our institution frequently request confirmatory, comprehensive ultrasonography before proceeding with invasive procedures or other interventions. This case highlights the utility of expedited POCUS in the rapid diagnosis and subsequent treatment of this life-threatening condition.

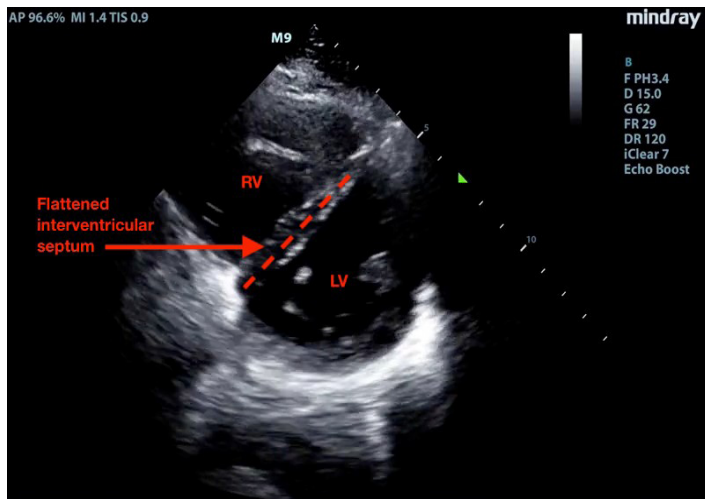
## CASE REPORT

An 18-year-old male who reported no past medical history presented to the pediatric emergency department (ED) complaining of mild substernal chest pain, intermittent palpitations, and dyspnea with minimal exertion over the prior week. He endorsed decreased oral intake of fluids and solids over the prior week and occasional non-productive cough. He endorsed some caffeine intake (1-2 caffeinated sodas per day), but no recent increase in caffeine consumption. He denied any fevers, drug use including cocaine, and reported no significant familial history of hyperthyroidism, cardiac disease, or sudden death. There was no history of recent upper respiratory infections, muscle pain, back pain, joint stiffness, nausea,

vomiting, diarrhea, rash, dizziness, syncope, leg swelling, or history of trauma. There were no known ill contacts.

Initial exam revealed a very well-appearing young man in no distress, speaking in full sentences, and sitting on the stretcher playing with his 9-month-old child. Initial vital signs included a temperature of 96.7 degrees Fahrenheit, pulse of 116 beats per minute (bpm), blood pressure of 126/81 millimeters of mercury (mmHg), respiratory rate of 18 breaths per minute, and an oxygen saturation of 95% on room air. There were no murmurs on cardiac exam. His pulmonary exam was normal with no wheezes or accessory muscle use. The abdomen was soft with no tenderness, and his extremity and neurologic exams were unremarkable. No lower extremity edema, calf cords, or leg tenderness was noted.

The patient had an intravenous line placed, and initial labs included a complete blood count and electrolytes, which were normal. He was given one liter of normal saline and his heart rate improved to 92 bpm. A point-of-care cardiac ultrasound was performed. He had a normal ejection fraction on the parasternal long view with no pericardial effusion. However, the parasternal short-axis view demonstrated a "D-sign," wherein bowing of the interventricular septum into the left ventricle (LV) caused it to take on the shape of a capital letter D, indicative of right ventricular (RV) strain (Image 1 and Video 1). The apical four-chamber axis view demonstrated



**Image 1.** Parasternal short view of the heart, demonstrating bowing of the interventricular septum away from the right ventricle (RV) into the left ventricle (LV) (the “D-sign”).

an enlarged RV, although the team did not observe akinesis of the mid-free wall of the RV (“McConnell’s sign”) (Image 2 and Video 2). A D-dimer was sent, as the identification of RV strain on POCUS increased the team’s suspicion for pulmonary embolism (PE). Ultrasound of the lower extremity veins identified a non-compressible right popliteal vein, indicative of an occlusive thrombus.

On further questioning regarding family history, the patient called his mother and subsequently reported that he carried a diagnosis of factor V Leiden mutation, which had been identified after his mother developed an unprovoked PE several years prior. He also recalled twisting his right ankle one week prior to presentation, although he had no significant swelling or difficulty walking thereafter.

The patient’s D-dimer subsequently came back at greater than 6,000, with a N-terminal pro b-type natriuretic peptide (NT-proBNP) elevated at 1096. Troponin was negative. Computed tomography (CT) angiography of the chest identified a saddle PE, with near-occlusive clot in the right pulmonary artery, signs of right heart strain, and pulmonary arterial enlargement (Image 3). The patient was taken to the cardiac catheterization suite for ultrasound-assisted, catheter-directed, low-dose thrombolysis using the EkoSonic Endovascular System (EKOS catheters). He was admitted to the medical intensive care unit thereafter and recovered without complications. He was discharged two days later on rivaroxaban, with the plan for lifelong anticoagulation.

## DISCUSSION

POCUS is a useful tool for expediting the diagnosis of venous thromboembolism (VTE) in the ED.<sup>1</sup> Emergency physicians may obtain reasonable competency in POCUS

### CPC-EM Capsule

What do we already know about this clinical entity?

*Pulmonary embolism (PE) can cause significant morbidity and mortality. Point-of-care ultrasonography (POCUS) can rapidly identify right heart strain, which may predict clinical outcomes following PE.*

What makes this presentation of disease reportable?

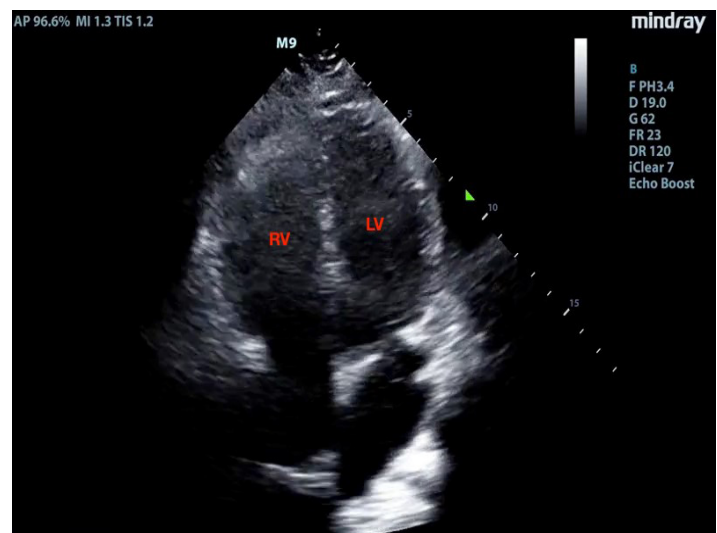
*Despite having a submassive PE with a large clot burden, the patient was only mildly symptomatic. Without POCUS, his PE could have been missed, leading to long-term cardiopulmonary sequelae.*

What is the major learning point?

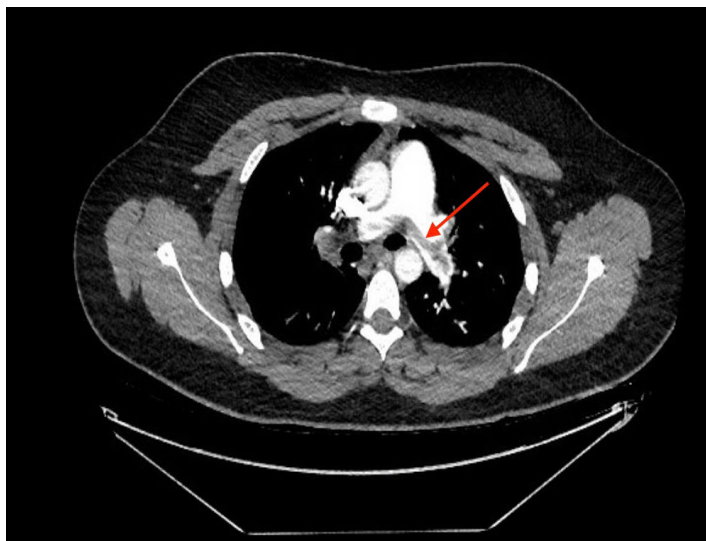*Use POCUS to evaluate patients with cardiopulmonary symptoms in the emergency department. Signs of right heart strain may lead to more rapid diagnosis and treatment of potentially fatal PEs.*

How might this improve emergency medicine practice?

*Early use of POCUS to evaluate patients with cardiopulmonary symptoms in the emergency department can critically alter their care.*



**Image 2.** Apical four-chamber view of the heart, demonstrating an enlarged right ventricle (RV), greater in size than the left (LV).



**Image 3.** Axial view of the chest on computed tomography for pulmonary angiogram, demonstrating a saddle pulmonary embolism (arrow), with near-occlusive clot in the right pulmonary artery.

diagnosis with even limited training.<sup>2</sup> The parasternal long-axis view is most useful for observing global LV function, as well as for identifying a pericardial effusion. The parasternal short-axis view is useful for identifying wall motion abnormalities in the LV, as well as for comparing the relative pressures between the LV and RV. When right-sided pressures are elevated, as seen in this case, the interventricular septum bows toward the left during diastole, distorting the LV from its usual rounded appearance into a D-shape. In the apical four-chamber axis view, the RV diameter is usually no more than 70% that of the LV measured at the level of the tips of the valves at end-diastole. An RV that is *greater* in size than the LV in the apical four view is pathologic and indicates elevated RV pressures.<sup>3</sup> McConnell's sign – akinesis of the mid-free wall of the RV with normal motion at the apex, best seen in the apical four-chamber axis view – was initially described to have a relatively low sensitivity (77%) but high specificity (94%) for acute PE.<sup>4</sup> A subsequent study, however, showed that acute RV infarction has a similar incidence of McConnell's sign as PE, suggesting that perhaps it is more indicative of an acute process rather than RV failure due to PE in particular.<sup>5</sup>

Even in the era of CT angiography, ultrasound continues to play an important role in risk stratification.<sup>6</sup> In a prospective study of patients with acute PE, Grifoni et al. demonstrated that among initially normotensive patients, RV dysfunction on ultrasound was associated with a 10% rate of subsequent PE-related shock and 5% in-hospital mortality, while patients without RV dysfunction had benign inpatient courses.<sup>7</sup> Patients with intermediate-risk PEs, defined as PE with evidence of RV dysfunction and/or myocardial injury without

hypotension or shock,<sup>8</sup> have a mortality rate of 3%, nearly the same as patients who present with acute myocardial infarction.<sup>9</sup> Retrospective studies have shown that 80% of patients with saddle PEs demonstrate RV dysfunction, and have a mortality of between 5-6%.<sup>6,10,11</sup> These patients may be candidates for catheter-directed thrombolysis in addition to systemic anticoagulation.<sup>12</sup> Some data suggests that patients such as the one in this case have improved outcomes after ultrasound-assisted, catheter-directed thrombolysis compared to systemic anticoagulation alone, without an increased rate of bleeding complications.<sup>13</sup>

Factor V Leiden is the most common genetic risk factor for VTE.<sup>14</sup> Approximately 3-8% of the general United States and European populations are heterozygous carriers of the modified allele. It is characterized by poor response to activated protein C and leads to increased risk of deep vein thrombosis and PE. Individuals with factor V Leiden mutations are at a 50-fold increased risk for VTE after a minor lower extremity injury compared with individuals without this mutation,<sup>15</sup> and heterozygous carriers have been shown to have a lifetime VTE risk of 10% in population studies.<sup>16</sup>

## CONCLUSION

This case highlights the power of POCUS in the early evaluation of patients with cardiopulmonary complaints. The recognition of right heart strain early in this patient's course led the clinical team to obtain an urgent CT angiogram, which facilitated the timely diagnosis for his submassive PE. Despite his large clot burden, the patient was only mildly symptomatic. Without POCUS, his PE could have been missed as his heart rate normalized and some of his symptoms improved following administration of intravenous fluids. In this case, the EP's ultrasound, in conjunction with the clot burden seen on CT, were conclusive evidence of significant RV dysfunction, and prompted the cardiac surgery team to take the patient directly to the catheterization laboratory for thrombolysis without a comprehensive transthoracic echocardiogram. His expedited diagnosis in the ED led to rapid intervention and treatment by the appropriate specialist team and may have avoided long-term cardiopulmonary sequelae.

**Video 1.** Ultrasound video clip of parasternal short view of the heart, demonstrating bowing of the interventricular septum away from the right ventricle (RV) into the left ventricle (LV) (the "D-sign").

**Video 2.** Ultrasound video clip of apical four-chamber view of the heart, demonstrating an enlarged right ventricle (RV), greater in size than the left (LV).

Documented patient informed consent and/or Institutional Review Board approval has been obtained and filed for publication of this case report.

---

*Address for Correspondence:* Emily C. Cleveland Manchanda, MD, MPH, Massachusetts General Hospital, Department of Emergency Medicine, 5 Emerson Place, Suite 101, Boston, MA 02114. Email: [eclevelandmanchanda@partners.org](mailto:eclevelandmanchanda@partners.org).

*Conflicts of Interest:* By the CPC-EM article submission agreement, all authors are required to disclose all affiliations, funding sources and financial or management relationships that could be perceived as potential sources of bias. The authors disclosed none.

*Copyright:* © 2019 Cleveland Manchanda et al. This is an open access article distributed in accordance with the terms of the Creative Commons Attribution (CC BY 4.0) License. See: <http://creativecommons.org/licenses/by/4.0/>

---

## REFERENCES

- Theodoro D, Blaivas M, Duggal S, et al. Real-time B-mode ultrasound in the ED saves time in the diagnosis of deep vein thrombosis (DVT). *Am J Emerg Med.* 2004;22(3):197-200.
- Torres-Macho J, Antón-Santos JM, García-Gutierrez I, et al. Initial accuracy of bedside ultrasound performed by emergency physicians for multiple indications after a short training period. *Am J Emerg Med.* 2012;30(9):1943-9.
- Noble V, Nelson B. *Manual of Emergency and Critical Care Ultrasound.* 2nd ed. New York: Cambridge University Press; 2011.
- McConnell MV, Solomon SD, Rayan ME, et al. Regional right ventricular dysfunction detected by echocardiography in acute pulmonary embolism. *Am J Cardiol.* 1996;78(4):469-73.
- Casazza F, Bongarzone A, Capozzi A, et al. Regional right ventricular dysfunction in acute pulmonary embolism and right ventricular infarction. *Eur J Echocardiogr.* 2005;6(1):11-4.
- Goldhaber SZ. Echocardiography in the management of pulmonary embolism. *Ann Intern Med.* 2002;136(9):691-700.
- Grifoni S, Olivetto I, Cecchini P, et al. Short-term clinical outcome of patients with acute pulmonary embolism, normal blood pressure, and echocardiographic right ventricular dysfunction. *Circulation.* 2000;101(24):2817-22.
- Torbicki A, Perrier A, Konstantinides S, et al. Guidelines on the diagnosis and management of acute pulmonary embolism: The Task Force for the Diagnosis and Management of Acute Pulmonary Embolism of the European Society of Cardiology (ESC). *Eur Heart J.* 2008;29(18):2276-315.
- Meyer G, Vicaut E, Danays T, et al. Fibrinolysis for patients with intermediate-risk pulmonary embolism. *N Engl J Med.* 2014;370(15):1402-11.
- Ryu JH, Pellikka PA, Froehling DA, et al. Saddle pulmonary embolism diagnosed by CT angiography: frequency, clinical features and outcome. *Respir Med.* 2007;101(7):1537-42.
- Sardi A, Gluskin J, Guttentag A, et al. Saddle pulmonary embolism: is it as bad as it looks? A community hospital experience. *Crit Care Med.* 2011;39(11):2413-8.
- Zarghouni M, Charles HW, Maldonado TS, et al. Catheter-directed interventions for pulmonary embolism. *Cardiovasc Diagn Ther.* 2016;6(6):651-61.
- Kucher N, Boekstegers P, Müller O, et al. Randomized controlled trial of ultrasound-assisted catheter-directed thrombolysis for acute intermediate-risk pulmonary embolism. 2013. Available at: <http://circ.ahajournals.org/content/early/2013/11/13/CIRCULATIONAHA.113.005544.short>. Accessed August 17, 2017.
- Kujovich JL. Factor V Leiden thrombophilia. *Genet Med.* 2011;13(1):1-16.
- van Stralen KJ, Rosendaal FR, Doggen CJ. Minor injuries as a risk factor for venous thrombosis. *Arch Intern Med.* 2008;168(1):21-6.
- Heit JA, Sobell JL, Li H, et al. The incidence of venous thromboembolism among factor V Leiden carriers: a community-based cohort study. *J Thromb Haemost.* 2005;3(2):305-11.

# Abdominal Pain in the Elderly: An Unusual Case of Chronic Mesenteric Ischemia in the Emergency Department

Julietta I. Lacey, MD  
Robert M. Hughes, DO  
Vicki Noble, MD

University Hospitals Cleveland Medical Center, Department of Emergency Medicine,  
Cleveland, Ohio

Section Editor: Rick A. McPheeters, DO

Submission history: Submitted December 3, 2018; Revision received May 2, 2019; Accepted May 16, 2019

Electronically published July 1, 2019

Full text available through open access at [http://escholarship.org/uc/uciem\\_cpchem](http://escholarship.org/uc/uciem_cpchem)

DOI: 10.5811/cpcem.2019.5.41886

Chronic mesenteric ischemia (CMI) is a rare cause of abdominal pain with the potential for significant morbidity and mortality. An infrequently described complication of CMI is acalculous cholecystitis. Historically, acalculous cholecystitis is thought to be multifactorial and usually occurs in the setting of severe illness. In CMI, the etiology is more likely chronic ischemia to the gallbladder leading to inflammation. We present a case of acalculous cholecystitis that presented insidiously in a patient with CMI. [Clin Pract Cases Emerg Med. 2019;3(3):275-277.]

---

## INTRODUCTION

Chronic mesenteric ischemia (CMI) is a rare, but potentially fatal, cause of abdominal pain. CMI refers to splanchnic hypoperfusion involving at least two of the following: the celiac artery, superior mesenteric artery, and inferior mesenteric artery.<sup>2</sup> In a recent study, the prevalence of symptomatic CMI was reported to be as low as 0.03% despite the growing prevalence of mesenteric artery stenosis.<sup>3</sup> CMI is typically secondary to atherosclerosis and most commonly involves the celiac artery.<sup>1,3</sup> A usual presentation consists of intestinal angina and progressive weight loss.

One study shows that significant stenosis, especially greater than 70%, within the splanchnic vessels can lead to the development of collateral vessels in order to prevent ischemia to the bowels.<sup>4</sup> This angiogenesis, along with the body's intrinsic collateral vessels, serves to protect the remainder of the splanchnic organs from significant ischemia as well. One notable exception is the gallbladder, which receives its blood supply primarily from the cystic artery, a terminal branch of the celiac artery.<sup>6</sup> To our knowledge, there is no evidence to support the formation of collaterals to the gallbladder in CMI.

Acalculous cholecystitis, an infrequently described complication of CMI, may present with the typical symptoms of CMI and should be considered, especially in the setting of right upper quadrant pain, leukocytosis and elevated inflammatory markers in patients with risk factors for vascular disease. While acute acalculous cholecystitis is most often described in the

critically ill, we describe a case of acute acalculous cholecystitis that presented with marked leukocytosis and hypotension in an otherwise well appearing, elderly female with underlying CMI.

## CASE REPORT

A 76-year-old Caucasian female with a past medical history significant for hyperlipidemia and poorly controlled hypertension was sent to the emergency department (ED) by her outpatient cardiologist due to abnormal labs. Her labs were most significant for a severe leukocytosis and hypokalemia. On her arrival to the ED, she was grossly asymptomatic but reported a two-week history of generalized fatigue and intermittent lightheadedness. On review of systems, she also endorsed a 10-pound weight loss over the prior six months and episodic generalized abdominal pain associated with nausea and vomiting over the prior year.

On exam, she was hypotensive to 83/42 millimeters of mercury with otherwise normal vital signs. She was awake, alert, in no acute distress, and in general was very comfortable and well appearing. She did not demonstrate any evidence of hypoperfusion on exam such as altered mental status, dizziness, or cold extremities. Her abdomen was soft and non-distended with only mild tenderness to palpation in the suprapubic region but no guarding or rebound. Her exam was otherwise notable for a diminished left radial pulse and bilaterally diminished dorsalis pedis pulses.

Routine investigations revealed a white cell count of 49.1/ liters (L) ( $4.4-11.3 \times 10^9/L$ ) with a left shift and neutrophil

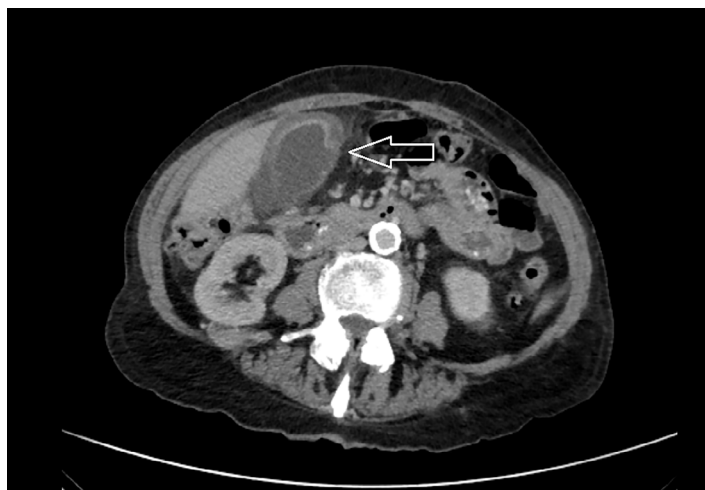predominance, potassium of 2.5 millimoles (mmol)/L (3.5-5.3mmol/L), sodium of 127 mmol/L (136-145mmol/L), blood urea nitrogen of 31 milligrams per deciliter (mg/dL) (6-23 mg/dL), creatinine of 1.53 mg/dL (0.50-1.05 mg/dL), C reactive protein of 31.44 mg/dL (<1.00) and lactate of 3.7 mmol/L (0.4-2.0 mmol/L). Her liver function tests were within normal limits. Urinalysis and chest radiograph were obtained for an infectious workup and were both unremarkable.

After a period of observation, an abdominal computed tomography (CT) was obtained given her history of chronic abdominal pain and persistent concern for infectious process with no clear source. The CT showed gallbladder wall thickening and edema with pericholecystic edema and a contained perforation of the gallbladder wall near the fundus (Image).

Interval CT angiogram showed severe atherosclerotic changes of the abdominal aorta and its branches with complete occlusion of the celiac artery origin and diminutive flow in its distal branches from collateral vessels, severe stenosis of the superior mesenteric artery, and mild stenosis of the inferior mesenteric artery. There was mild wall thickening of the ascending colon and transverse colon.

## DISCUSSION

Acalculous cholecystitis is an infrequent, acute inflammatory disease of the gallbladder, thought to be multifactorial in etiology, which most often occurs in critically ill patients.<sup>6</sup> Acalculous cholecystitis as a result of CMI is an especially rare complication with only a handful of reported cases in the literature. Melo et al. reported a case of acute acalculous cholecystitis in a patient with severe atherosclerosis



**Image.** Abdominal computed tomography scan with contrast showing cholecystitis with evidence of gallbladder wall perforation (white arrow). Gallbladder wall appears thickened and edematous and there is a moderate amount of pericholecystic fluid and inflammatory stranding. In addition, there is an apparent discontinuity in the gallbladder wall.

### CPC-EM Capsule

What do we already know about this clinical entity?

*A rare complication of chronic mesenteric ischemia (CMI), acalculous cholecystitis, is most often seen in critically ill patients.*

What makes this presentation of disease reportable?

*Acalculous cholecystitis in the setting of mesenteric ischemia is a rare cause of chronic abdominal pain, a common chief complaint in the emergency department.*

What is the major learning point?

*Acalculous cholecystitis is a rare complication of CMI that should be considered in elderly patients with abdominal pain and risk factors for vascular disease.*

How might this improve emergency medicine practice?

*Early recognition and diagnosis of acalculous cholecystitis in patients with post-prandial abdominal pain may expedite treatment and improve outcomes.*

and CMI. This patient's presentation consisted of acute onset, right upper quadrant pain while admitted to the hospital for a planned revascularization. He underwent a simultaneous cholecystectomy and elective revascularization of his aortic and visceral occlusive disease. Other case reports present instances of acute acalculous cholecystitis in patients with critical illness causing systemic inflammation such as a severe infection, systemic lupus erythematosus, or burns.<sup>7,8,9</sup> Our case contrasts with the above case reports in that our patient's abdominal pain was chronic and not present on the day of her presentation. A high index of suspicion is required to consider acalculous cholecystitis as a cause of her severe leukocytosis in this otherwise well-appearing female with a benign abdominal exam.

Although it is understood that the pathogenesis of acalculous cholecystitis is multifactorial, ischemia has been more recently recognized as an important risk factor for its development.<sup>6</sup> Our case demonstrates the development of acalculous cholecystitis in a patient with no identified risk factors other than peripheral vascular disease as demonstrated by unequal and diminished peripheral pulses on exam and by

areas of severe stenoses on her subsequent CT angiogram. Her history of poorly controlled hypertension was also suggestive of renal artery stenosis. She had not had any other acute illness in the weeks prior to predispose her to systemic inflammation and to the acute irritation and subsequent perforation of her gallbladder in the absence of cholelithiasis.

It is clear that acalculous cholecystitis can develop in an array of clinical settings. Systemic illness has been established, and frequently cited, as a known risk factor. However, given the gallbladder's terminal blood flow and susceptibility to ischemia, acalculous cholecystitis should be recognized as a possible complication of mesenteric atherosclerosis and specifically CMI.

## CONCLUSION

The patient was treated prophylactically with piperacillin/tazobactam and admitted to the surgical service for a laparoscopic cholecystectomy. She underwent the procedure without complications and was discharged home. She then followed up with her cardiologist to discuss the findings on her CT angiogram and her CMI. She was feeling well after her cholecystectomy, and because of her lack of symptoms they decided to pursue conservative management of her CMI rather than revascularization.

Documented patient informed consent and/or Institutional Review Board approval has been obtained and filed for publication of this case report.

## REFERENCES

1. Heiss C. [Chronic Mesenteric Ischemia]. *Dtsch Med Wochenschr.* 2018;143(20):1426-9.
2. Sreenarasimhaiah J. Chronic mesenteric ischemia. *Best Pract Res*

*Address for Correspondence:* Vicki Noble, MD, University Hospitals Cleveland Medical Center, Department of Emergency Medicine, 11100 Euclid Ave, Cleveland, OH 44106. Email: julieta.lacey@uhhospitals.org.

*Conflicts of Interest:* By the CPC-EM article submission agreement, all authors are required to disclose all affiliations, funding sources and financial or management relationships that could be perceived as potential sources of bias. The authors disclosed none.

*Copyright:* © 2019 Lacey et al. This is an open access article distributed in accordance with the terms of the Creative Commons Attribution (CC BY 4.0) License. See: <http://creativecommons.org/licenses/by/4.0/>

*Clin Gastroenterol.* 2005;19(2):283-95.

3. Kolkman JJ and Geelkerken RH. Diagnosis and treatment of chronic mesenteric ischemia: An update. *Best Pract Res Clin Gastroenterol.* 2017;31(1):49-57.
4. van Petersen AS, Kolkman JJ, Meerwaldt R, et al. Mesenteric stenosis, collaterals, and compensatory blood flow. *J Vasc Surg.* 2014;60(1):111-9.
5. Hakala T, Nuutinen PJ, Ruokonen ET, et al. Microangiopathy in acute acalculous cholecystitis. *Br J Surg.* 1997;84(9):1249-52.
6. Melo R, M Pedro L, Silvestre L, et al. Acute acalculous cholecystitis as a rare manifestation of chronic mesenteric ischemia. A case report. *Int J Surg Case Rep.* 2016;25:207-11.
7. Araki H, Shimizu S, Hayashi K, et al. Acute acalculous cholecystitis caused by *Giardia lamblia*. *Intern Med.* 2017;56(13):1657-62.
8. Yang H, Bian S, Xu D, et al. Acute acalculous cholecystitis in patients with systemic lupus erythematosus: a unique form of disease flare. *Lupus.* 2017;26(10):1101-5.
9. Hermiz SJ, Diegidio P, Garimella R, et al. Acalculous cholecystitis in burn patients: is there a role for percutaneous cholecystostomy? *Clin Plast Surg.* 2017;44(3):567-71.

# Sonographic Detection of a Torsed Meckel's Diverticulum Misinterpreted as Acute Appendicitis

Justin Choi, MSIII  
Nicole Dorinzi, MD  
Justine Pagenhardt, MD  
Anthony Steratore, MD  
Melinda Sharon, MPH  
Joseph Minardi, MD

West Virginia University, Department of Emergency Medicine, Morgantown, West Virginia

Section Editor: Austin Smith, MD

Submission history: Submitted March 5, 2019; Revision received May 4, 2019; Accepted May 16, 2019

Electronically published July 22, 2019

Full text available through open access at [http://escholarship.org/uc/uciem\\_cpccem](http://escholarship.org/uc/uciem_cpccem)

DOI: 10.5811/cpcem.2019.5.42976

A 38-year-old female presented to the emergency department (ED) with acute-onset right lower quadrant abdominal pain following two days of nausea and vomiting. Physical examination revealed right lower quadrant tenderness to palpation, rebound tenderness, and guarding. Point-of-care ultrasound (POCUS) of the right lower abdomen was performed and interpreted as probable appendicitis. However, upon laparoscopic examination of the abdomen, a benign-appearing appendix was visualized. Further investigation revealed the source of the patient's pain to be a torsed Meckel's diverticulum. Although rare, a torsed and inflamed Meckel's diverticulum can be visualized by POCUS in the ED without the need for further imaging or delay. [Clin Pract Cases Emerg Med. 2019;3(3):278-281.]

---

## INTRODUCTION

Acute abdominal pain is a common presentation in the emergency department (ED). Pain localized to the right lower quadrant (RLQ) warrants a workup for appendicitis, a diagnosis commonly made in the ED and a prevalent cause of urgent abdominal surgery.<sup>1</sup> Imaging of the abdomen in suspected appendicitis is important for distinguishing true appendicitis from appendicitis mimics in order to prevent negative appendectomies and unnecessary surgical risks. However, certain mimics warrant surgical treatment. One example is an inflamed or torsed Meckel's diverticulum that is symptomatic.<sup>2</sup> While the imaging modality of choice for RLQ pain suggestive of acute appendicitis has been computed tomography (CT) of the abdomen and pelvis, many ED providers are moving towards abdominal ultrasound (US) as the initial imaging study, as it can identify both appendicitis and, as in this case, a torsed Meckel's diverticulum at the bedside without the need for radiation exposure.<sup>3</sup>

## CASE REPORT

A 38-year-old white female with no significant past medical history presented to the ED with acute onset RLQ

abdominal pain that began earlier that day. The pain was described as being sharp, stabbing, radiating to the right flank, and greatly exacerbated by movement. She reported decreased appetite, nausea, and vomiting two days prior to presentation with only nausea on the day of admission. On physical examination, the RLQ of her abdomen was tender to palpation with guarding and rebound tenderness. Other examination findings included a blood pressure of 90/60 millimeters of mercury, a heart rate of 97 beats per minute, and a temperature of 36.8 degrees Celsius. Pertinent laboratory findings included leukocytosis, with a white blood cell count of  $17.6 \times 10^3$ /microliter, a normal hepatic and pancreatic function panel, a normal basic metabolic panel, and a negative pregnancy test.

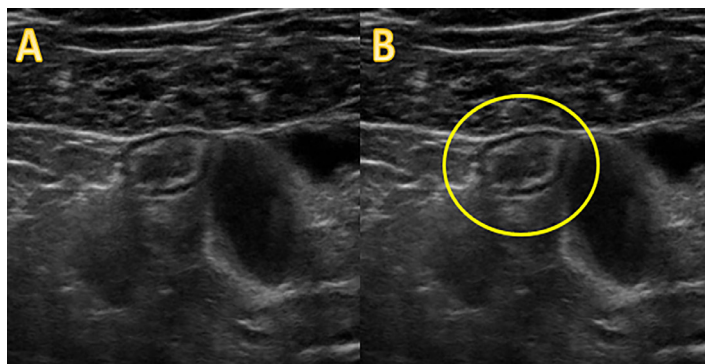
Based on the patient's presenting symptoms and workup, a point-of-care ultrasound (POCUS) of the abdomen focused on the RLQ was performed to assess for suspected appendicitis. A linear probe was used on the RLQ to first obtain a short-axis view, and then rotated 90° to obtain a long-axis view. The bedside US interpreted by the emergency physician showed a tubular, non-peristalsing structure

superficial to the iliac vessels 0.9 centimeters in diameter with edematous walls consistent with appendicitis (Image, Video). Further increasing the likelihood of appendicitis was the structure's "target" appearance on short-axis, associated with the gut signature of bowel wall (Image, Video).

Surgery was promptly consulted for acute abdomen with a preoperative diagnosis of appendicitis. The patient was consented for a laparoscopic appendectomy and taken into the operating room. Upon initial laparoscopic examination of the lower abdomen, the patient's appendix appeared normal, with no signs of appendiceal inflammation, induration, or injection. The appendix was removed despite its normal appearance, and the lower abdomen was again examined for another source of the patient's pain. An area of torsed, dark tissue was identified on the antimesenteric portion of the small bowel and subsequently detorsed, revealing an ischemic Meckel's diverticulum that appeared to be the cause of the patient's symptoms. The transected tissue was sent to pathology, which confirmed both a normal appendix and a Meckel's diverticulum. The patient recovered and was discharged two days later with weight restrictions and home rest for two weeks.

## DISCUSSION

Meckel's diverticulum is the most common congenital anomaly of the gastrointestinal tract, with a prevalence of 2-4%.<sup>4</sup> Meckel's diverticulitis and torsion of a Meckel's diverticulum is often clinically, and in many cases, radiologically difficult to distinguish from appendicitis. Meckel's diverticulitis is accurately diagnosed preoperatively in fewer than 10% of patients, with acute appendicitis being the most common preoperative diagnosis.<sup>5-6</sup>



**Image.** Frame A is a short-axis view of a point-of-care ultrasound showing an edematous, non-compressible tubular structure in the right lower quadrant of the abdomen with adjacent normal-appearing, compressible loops of small bowel. Clearly visible is the "gut signature" associated with the different layers of the bowel wall; serosa (echogenic), muscularis externa (hypoechoic), submucosa (echogenic), muscularis mucosa (hypoechoic), and mucosa (echogenic). This structure is circled in Frame B.

### *CPC-EM Capsule*

What do we already know about this clinical entity?

*Meckel's diverticulum is the most common congenital gastrointestinal anomaly. When torsed or inflamed, it can clinically and radiologically mimic acute appendicitis.*

What makes this presentation of disease reportable?

*A rare, torsed Meckel's diverticulum was thought to be appendicitis but properly treated after visualization via point-of-care ultrasound.*

What is the major learning point?

*Visualization of the pathological process is more crucial to patient care than distinguishing an inflamed Meckel's diverticulum from appendicitis.*

How might this improve emergency medicine practice?

*Point-of-care sonography can save time and resources as well as reduce radiation exposure without negatively affecting outcomes in right lower quadrant pain.*

Many factors contribute to the difficulty in correctly distinguishing between a torsed or inflamed Meckel's and an inflamed appendix. Both can present with a similar history of acute onset right lower abdominal pain with variable abdominal distention, nausea and vomiting, especially in the case of bowel obstruction with Meckel's diverticulum.<sup>7</sup> Laboratory findings are also relatively nonspecific, with both appendicitis and any diverticulitis commonly presenting with leukocytosis and fever.<sup>8</sup> Physical examination findings commonly show RLQ tenderness on palpation as well as guarding, rigidity, and rebound tenderness. While pain from Meckel's diverticulum can be located more toward the midline, periumbilical pain is common due to peritoneal irritation with early acute appendicitis as well, rendering this finding nonspecific.

Regarding imaging findings, torsion of a Meckel's diverticulum is an extremely rare complication and thus there are limited studies of optimal imaging modalities.<sup>6</sup> In the ED, the most likely scenario is high suspicion of acute

appendicitis, with a torsed Meckel's diverticulum being near the bottom of the differential diagnosis if even considered. Thus, it is fitting to deliberate over imaging options in the context of acute appendicitis. Historically, the initial imaging modality of choice for suspected appendicitis has been CT, with alternative modalities such as magnetic resonance imaging or US reserved for children and pregnant women due to concern for radiation exposure.<sup>9</sup> However, many emergency physicians are moving toward abdominal US as the initial imaging modality for suspected acute appendicitis, typically via the high-frequency linear probe, with sensitivity and specificity reaching values above 90%.<sup>3,10</sup>

US can also visualize a torsed Meckel's diverticulum, as shown in this case; however, it is often misdiagnosed as acute appendicitis due to similar location, features, and anatomy. Anatomically, Meckel's diverticulum is classically found within 100 centimeters of the ileocecal valve, placing it in the RLQ or near the midline, analogous to the appendix. US findings are also similar between the two diagnoses. Both are true diverticula meaning they contain all gut wall layers, resulting in the classic gut signature or "target" appearance on ultrasonography, and both show non-compressible, blind-ending, tubular, non-peristaltic structures with edematous walls (Image).

While it is possible to correctly identify a Meckel's diverticulum on ultrasonography by its lack of association with the cecum, this case shows that from an ED perspective, the visualization of a pathological process that is likely the source of the patient's pain is much more crucial and meaningful than accurately diagnosing a Meckel's diverticulum at the bedside. The aforementioned sonographic findings coupled with the patient's presenting symptoms would warrant surgical consultation in either case. Whether the findings are indicative of appendicitis or a torsed Meckel's diverticulum can be demonstrated intraoperatively, as both of these etiologies would require surgery.

Here, we see that US is a valuable study for RLQ pain even in the setting of bowel ischemia secondary to axial torsion of a Meckel's diverticulum. In this particular case, a torsed Meckel's diverticulum was mistakenly identified as appendicitis, but the patient's treatment course and outcome were not affected. On the contrary, the patient was quickly consented for laparoscopic surgery without the need for further imaging, interpretation by a radiologist, or exposure to unnecessary radiation.

## CONCLUSION

Few studies have investigated the utility of ultrasonography in the setting of an axially torsed Meckel's diverticulum. Here, we have shown that POCUS in the ED is a capable and appropriate tool for investigating acute RLQ abdominal pain even in the setting of a Meckel's diverticulum. Although US is relatively operator-dependent, in the right hands it is a readily available and quickly interpreted imaging modality, making it an important skill for emergency physicians.

## ACKNOWLEDGMENT

The authors would like to give special thanks to Ashley McDonald for her contributions to the manuscript.

**Video.** A linear probe is being used on the right lower quadrant of the abdomen in this video clip. An edematous, fluid-filled, non-compressible structure is seen just below the abdominal wall musculature in short-axis view and is circled in yellow. The structure displays a "targetoid" gut signature and is shown adjacent to normal loops of small bowel, making it suspicious for acute appendicitis. It was later found to be an inflamed Meckel's diverticulum.

Documented patient informed consent and/or Institutional Review Board approval has been obtained and filed for publication of this case report.

*Address for Correspondence:* Nicole Dorinzi, MD, West Virginia University, Department of Emergency Medicine, 1 Medical Center Drive, Morgantown, WV 26506. Email: nldorinzi@hsc.wvu.edu.

*Conflicts of Interest:* By the CPC-EM article submission agreement, all authors are required to disclose all affiliations, funding sources and financial or management relationships that could be perceived as potential sources of bias. The authors disclosed none.

*Copyright:* © 2019 Choi et al. This is an open access article distributed in accordance with the terms of the Creative Commons Attribution (CC BY 4.0) License. See: <http://creativecommons.org/licenses/by/4.0/>

## REFERENCES

1. Cole MA and Maldonado N. Evidence-based management of suspected appendicitis in the emergency department. *Emerg Med Pract.* 2011;13(10):1-29.
2. Park JJ, Wolff BG, Tollefson MK, et al. Meckel diverticulum: the Mayo Clinic experience with 1476 patients (1950-2002). *Ann Surg.* 2005;241(3):529-33.
3. Sartelli M, Baiocchi GL, Di Saverio S, et al. Prospective Observational Study on Acute Appendicitis Worldwide (POSAW). *World J Emerg Surg.* 2018;13:19.
4. Sagar J, Kumar V, Shah DK. Meckel's diverticulum: a systematic review. *J R Soc Med.* 2006;99(10):501-5.
5. Aarnio P and Salonen IS. Abdominal disorders arising from 71 Meckel's diverticulum. *Ann Chir Gynaecol.* 2000;89(4):281-4.
6. Turgeon DK and Barnett JL. Meckel's diverticulum. *Am J Gastroenterol.* 1990;85(7):777-81.
7. Hadeed AA, Azar RR, Azar NN, et al. Meckel's diverticulum

- complicated by axial torsion and gangrene. *J Surg Case Rep*. 2015;2015(3).pii:rjv008.
8. Tehrani HY, Petros JG, Kumar RR, et al. Markers of severe appendicitis. *Am Surg*. 1999;65(5):453-5.
9. Garcia EM, Camacho MA, Karolyi DR, et al. ACR Appropriateness Criteria right lower quadrant pain-suspected appendicitis. *J Am Coll Radiol*. 2018;15(11S):S373-87.
10. Dirks K, Calabrese E, Dietrich CF, et al. EFSUMB Position Paper: Recommendations for Gastrointestinal Ultrasound (GIUS) in Acute Appendicitis and Diverticulitis. *Ultraschall Med*. 2019;40(2):163-75.

# Trimethoprim/Sulfamethoxazole-Induced Bradycardia, Renal Failure, AV-Node Blockers, Shock and Hyperkalemia Syndrome

Nnaemeka Diribe, DO  
Jacqueline Le, MD

Desert Regional Medical Center, Department of Emergency Medicine, Palm Springs, California

Section Editors: Joel Moll, MD and Rick A. McPheeters, DO

Submission history: Submitted March 17, 2019; Revision received May 6, 2019; Accepted May 20, 2019

Electronically published July 22, 2019

Full text available through open access at [http://escholarship.org/uc/uciem\\_cpem](http://escholarship.org/uc/uciem_cpem)

DOI: 10.5811/cpcem.2019.5.43118

BRASH (bradycardia, renal failure, atrioventricular-node blockers, shock, and hyperkalemia) syndrome is a recently coined term for a condition that describes the severe bradycardia and shock associated with hyperkalemia in patients on atrioventricular (AV)-node blocking agents. The proposed pathophysiology involves a precipitating event that exacerbates renal dysfunction with resulting AV-node blocker and potassium accumulation that act synergistically to precipitate bradycardia and hypotension. This syndrome may be refractory to the usual management of bradycardia. This case describes BRASH syndrome precipitated by trimethoprim/sulfamethoxazole. [Clin Pract Cases Emerg Med. 2019;3(3):282-285.]

## INTRODUCTION

Severe hyperkalemia can present as reversible bradycardia that mimics atrioventricular (AV) block.<sup>1</sup> However, hyperkalemia in the setting of concomitant AV-node blocker usage can precipitate refractory bradycardia and hemodynamic instability even without a critically elevated potassium level or sizeable ingestion of AV-node blocking agents. This syndrome termed BRASH – bradycardia, renal failure, AV-node blockers, shock and hyperkalemia – is a cycle of synergy between hyperkalemia and AV-blockade that can result in cardiovascular collapse.<sup>2</sup> It would generally be expected that the prevalence of such a condition be higher among the elderly who may be more likely to be on AV-node blocking medications and have a greater likelihood of events that precipitate renal failure.<sup>3</sup> We report a case of BRASH syndrome occurring in a relatively young patient following a course of trimethoprim/sulfamethoxazole (TMP/SMX).

## CASE REPORT

A 51-year-old male with past medical history of pituitary carcinoma with resection, metastasis to the liver, Cushing's syndrome, hypertension, hyperlipidemia, hypothyroidism, insulin dependent diabetes mellitus, and renal insufficiency presented to the emergency department (ED) after a syncopal episode at the office of his primary care physician (PCP). He was found to have a pulse of 20 beats per minute (bpm) and

blood pressure of 60/30 millimeters of mercury (mmHg) by paramedics who immediately initiated transcutaneous pacing and transported him to the ED. On arrival, the patient was somnolent but arousable, paced at 90 bpm at 70 milliamps, and persistently hypotensive with blood pressure of 80/60 mm Hg. Pacer capture was poor. His electrocardiogram (ECG) revealed third-degree AV block and marked bradycardia with heart rate of 39 bpm, peaked T waves, and widened QRS of 173 milliseconds (Image). The patient's bradycardia was refractory to atropine, and pacing was resumed. Initial laboratory data was significant for elevated serum potassium of 8.6 millimoles per liter (mmol/L) (reference range 3.5 – 4.9 mmol/L), blood urea nitrogen (BUN) of 51 milligrams per deciliter (mg/dL) (reference range 8 – 26 mg/dL), and creatinine of 3.3 mg/dL (reference range 0.6 – 1.3 mg/dL).

According to his PCP, his baseline creatinine level was 1.7 mg/dL. Sodium was low at 130 mmol/L (reference range 138 – 146 mmol/L), and troponin I was normal at 0.010 ng/mL (reference range 0.000 – 0.080ng/mL). Intravenous (IV) calcium chloride, insulin with dextrose, and albuterol were administered to treat his hyperkalemia. IV hydrocortisone was additionally given for potential adrenal crisis. With treatment, his heart rate and blood pressure improved to 97 bpm and 140/52 mmHg, respectively. His level of consciousness likewise was restored. Nephrology was

contacted for possible dialysis, and the patient was admitted to the intensive care unit.

It was later discovered that the patient's medications included the beta-blocker carvedilol (6.25 mg twice daily) and eplerenone (25 mg daily), a potassium-sparing diuretic. He denied any recent dosage changes or attempted overdose. Interestingly, he had been started on TMP/SMX for otitis media a week prior to presentation and had developed progressive weakness and fatigue three days after his first dose. He was being evaluated on an outpatient basis for said weakness when he had the syncopal episode. His hospital course consisted of continued therapy with additional diuresis and sodium polystyrene sulfonate, resulting in the down trending of serum potassium levels and improvement of his renal function and urine output. Within 24 hours, his potassium level corrected to 5.0 mmol/L, and therefore dialysis was not initiated. Upon discharge three days later, his potassium was 4.1 mmol/L, BUN 31 mg/dL, and creatinine 1.4 mg/dL. He was instructed to stop taking his eplerenone and was discharged in stable condition with scheduled outpatient follow-up.

## DISCUSSION

Hyperkalemia is a well-known reversible cause of heart block, arrhythmia, and syncope.<sup>3</sup> It can be precipitated and worsened by multiple factors including medications, renal failure, mineralocorticoid deficiency, tissue necrosis, metabolic derangement and exogenous intake.<sup>4</sup> Risk factors for medication-induced hyperkalemia include

### *CPC-EM Capsule*

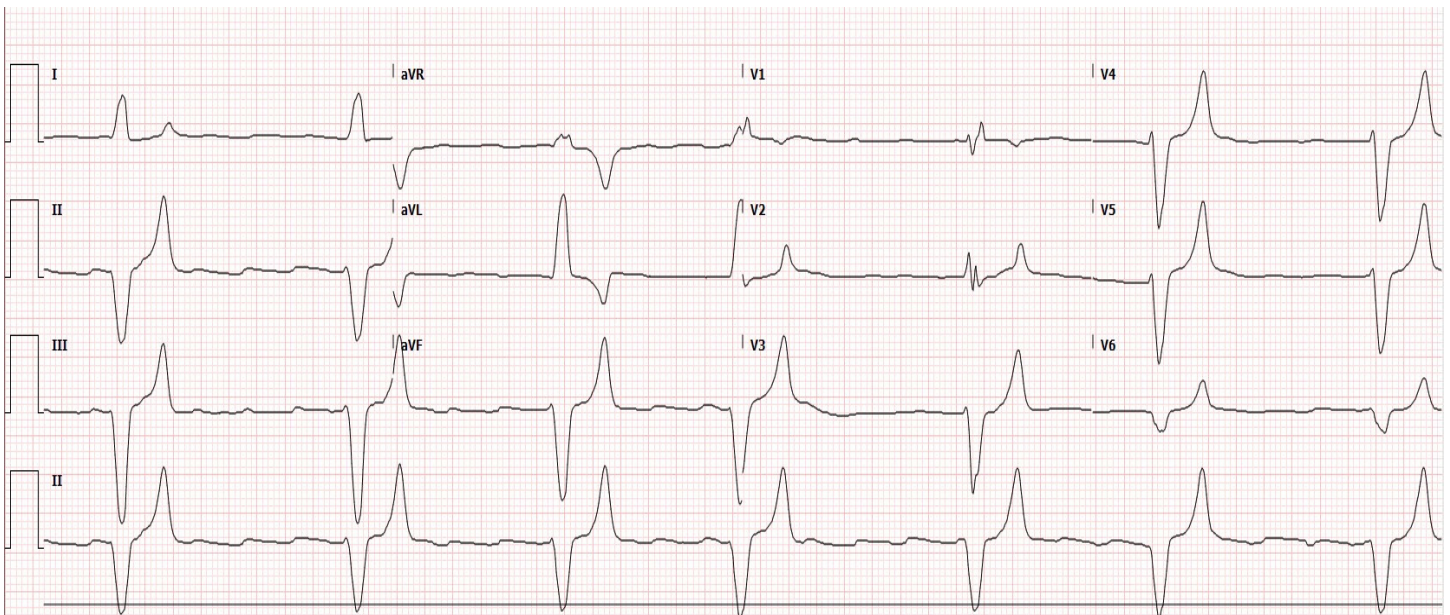
What do we already know about this clinical entity?  
*Atrioventricular-node blockers and hyperkalemia may act in synergy to precipitate bradycardia and shock that may be refractory to usual individual therapy.*

What makes this presentation of disease reportable?  
*This case highlights bradycardia, renal failure, AV-node blockers, shock and hyperkalemia (BRASH) syndrome and the potentially grave risk associated with prescribing medications that can cause hyperkalemia.*

What is the major learning point?  
*Bradycardia and shock from BRASH syndrome require intervention at multiple physiologic fronts that individually may not be grossly abnormal.*

How might this improve emergency medicine practice?

*Algorithmic and heuristic recognition of this syndrome could aid rapid intervention by the emergency physician and improve potential morbidity and mortality.*



**Image.** Initial electrocardiogram of 51-year-old male showing third-degree atrioventricular block with a ventricular escape rhythm. There is marked bradycardia (39 beats/minute), peaked T waves, and widened QRS (173 milliseconds).

diabetes mellitus, renal insufficiency, hypoaldosteronism, and age greater than 60 years.<sup>5</sup> There have been multiple documented cases of hyperkalemia precipitated by TMP/SMX as sole therapy<sup>6,7</sup> or in combination with other medications.<sup>8</sup> In fact, hyperkalemia and acute renal dysfunction have been documented with onset after therapy initiation in as quickly as 24 hours, particularly in patients with baseline renal insufficiency.<sup>9</sup> This is due to the direct activity of the trimethoprim component of TMP/SMX in inhibiting potassium excretion by reversibly disrupting sodium reabsorption by cells in the distal nephron.<sup>10</sup>

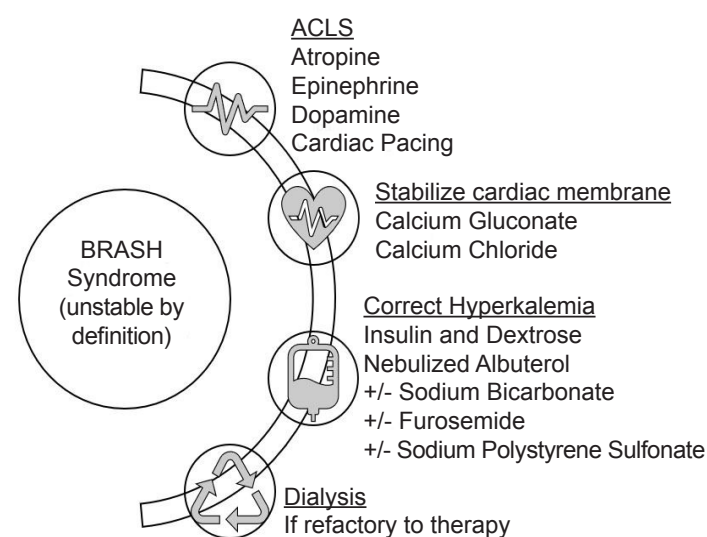
There may also be elements of renal toxicity driven by sulfamethoxazole crystal deposition.<sup>11</sup> Moreover, eplerenone is an aldosterone antagonist that inhibits renal secretion of potassium and sodium reabsorption, whereas carvedilol is a beta blocker that suppresses catecholamine-driven renin release while impairing cellular potassium uptake.<sup>4</sup> Our patient was therefore on several prescribed medications with the potential to drive and worsen hyperkalemia. Particularly interesting is the notion that beta blockers can act in synergy with hyperkalemia to induce bradycardia even with only mild hyperkalemia present.<sup>3</sup> This is achieved by the dual role beta blockers play as direct AV-node blockers in addition to maintaining higher serum potassium levels by reducing potassium excretion and impairing cellular uptake of serum potassium.<sup>4</sup> This cycle is propagated as bradycardia worsens renal perfusion leading to a spiral of worsening hyperkalemia, renal failure and bradycardic shock, which can sometimes be refractory to usual therapy.<sup>2</sup>

Given the pathophysiology described above, it is reasonable to expect that the population most susceptible to this syndrome would include the elderly who are often on multiple medications with potential to block the AV node or depress renal function, as well as patients with baseline renal insufficiency or heart block.<sup>3,4</sup> It is important to note that patients presenting with BRASH syndrome may be adherent to the prescribed doses of the AV-node blocker and have not ingested additional significant quantities of the medication. There may be, however, a precipitating event such as the addition of a new medication with the potential to cause hypovolemia or exacerbate baseline renal insufficiency. In this case, the initiation of antibiotic therapy with TMP/SMX worsened our patient's already-known renal insufficiency and on top of the eplerenone and carvedilol he was taking, contributed to his overall marked hyperkalemia and bradycardia. Furthermore, a stress corticosteroid was not used during the treatment of his ear infection.

Management of BRASH syndrome involves supportive care, treatment of shock, and expeditious correction of electrolyte abnormalities (Figure). As is standard with severe symptomatic hyperkalemia, membrane stabilization must be initiated with IV administration of calcium, insulin and dextrose, beta-agonist therapy and diuresis or dialysis as needed. Volume status must be evaluated carefully and addressed since acutely anuric patients can experience fluid overload while others may be fluid depleted. Patients may require support with vasopressors if shock remains despite other therapies, in which case epinephrine and isoproterenol could be reasonable choices given their beta-receptor activity.<sup>2</sup>

## CONCLUSION

BRASH – bradycardia, renal failure, AV-node blockers, shock and hyperkalemia – is a syndrome of severe bradycardic shock that is likely propagated by a synergy between AV-node blockade and hyperkalemia. The patients are generally on only prescribed doses of the AV-node blocker and present with severe bradycardia and hypotension after a precipitating event that worsens renal function. In some cases, such as the one presented here, the shock is severe enough to cause syncope. Mindfulness of the populations most likely to develop BRASH syndrome is recommended to help avoid prescribing medications that can potentially worsen renal function and predispose an already vulnerable patient to this syndrome. Immediate recognition of BRASH syndrome is likewise imperative to ensure prompt and aggressive management.



**Figure.** Management considerations for BRASH – bradycardia, renal failure, atrioventricular-node blockers, shock, and hyperkalemia – syndrome.

Documented patient informed consent and/or Institutional Review Board approval has been obtained and filed for publication of this case report.

*Address for Correspondence:* Nnaemeka Diribe, DO, Desert Regional Medical Center, Department of Emergency Medicine, 1180 N. Indian Canyon Dr. Suite E418, Palm Springs, CA 92262. Email: nnaemeka.diribe@tenethealth.com.

*Conflicts of Interest:* By the CPC-EM article submission agreement, all authors are required to disclose all affiliations, funding sources and financial or management relationships that could be perceived as potential sources of bias. The authors disclosed none.

*Copyright:* © 2019 Diribe et al. This is an open access article distributed in accordance with the terms of the Creative Commons Attribution (CC BY 4.0) License. See: <http://creativecommons.org/licenses/by/4.0/>

## REFERENCES

1. Unterman A and Moscovitch SD. The silence of the atria. *Isr Med Assoc J.* 2008;10(7):556.
2. Farkas J. BRASH syndrome: bradycardia, renal failure, AV blocker, shock, hyperkalemia. Available at: <https://emcrit.org/pulmcrit/brash-syndrome-bradycardia-renal-failure-av-blocker-shock-hyperkalemia/>. Accessed July 15, 2018.
3. Ahmad NH and Tan TL. Correlation of iatrogenic mild hyperkalaemia and bradyarrhythmia: a problem of polypharmacy in elderly. *Med & Health.* 2017;12(2):329-34.
4. Aziz EF, Javed F, Korniyenko A, et al. Mild hyperkalemia and low eGFR a tedious recipe for cardiac disaster in the elderly: an unusual reversible cause of syncope and heart block. *Heart Int.* 2011;6(2):e12.
5. Ponce SP, Jennings AE, Madias NE, et al. Drug-induced hyperkalemia. *Medicine (Baltimore).* 1985;64(6):357-70.
6. Velazquez H, Perazella MA, Wright FS, et al. Renal mechanism of trimethoprim-induced hyperkalemia. *Ann Intern Med.* 1993;119(4):296-301.
7. Greenberg S, Reiser IW, Chou SY, et al. Trimethoprim-sulfamethoxazole induces reversible hyperkalemia. *Ann Intern Med.* 1993;119(4):291-5.
8. Antoniou T, Gomes T, Juurlink DN, et al. Trimethoprim-sulfamethoxazole-induced hyperkalemia in patients receiving inhibitors of the renin-angiotensin system: a population-based study. *Arch Intern Med.* 2010;170(12):1045-9.
9. Nucera G, Raffaelli V, Caliri L, et al. Trimethoprim/sulfamethoxazole-induced acute renal failure: a case report. 2017. Available at: [http://journalhss.com/wp-content/uploads/jhhs22\\_215-220.pdf](http://journalhss.com/wp-content/uploads/jhhs22_215-220.pdf). Accessed July 15, 2018.
10. Choi MJ, Fernandez PC, Patnaik A, et al. Brief report: trimethoprim-induced hyperkalemia in a patient with AIDS. *N Engl J Med.* 1993;328(10):703-6.
11. Shrishrima K and Wesson J. Sulfamethoxazole crystalluria. *Am J Kidney Dis.* 2011;58(3):492-3.

# Point-of-Care Ultrasound-Directed Evaluation of Elbow Effusion

Peter Patitsas, MD, MBA  
Richard Davis, DO  
Robert Strony, DO, MBA

Geisinger Medical Center, Department of Emergency Medicine, Danville, Pennsylvania

Section Editor: Shadi Lahham, MD, MS

Submission history: Submitted November 16, 2019; Revision received May 21, 2019; Accepted May 28, 2019

Electronically published July 22, 2019

Full text available through open access at [http://escholarship.org/uc/uciem\\_cpem](http://escholarship.org/uc/uciem_cpem)

DOI: 10.5811/cpem.2019.5.41674

A 53-year-old male presented with pain in the right elbow that was sudden in onset and progressively worsening over approximately eight hours. The pain was exacerbated with any movement of the elbow. Of note, he had been recently admitted for robotic prostatectomy and had a prolonged hospital stay requiring a course of antibiotics. This case report details the emergency department evaluation of septic arthritis of the elbow with a focus on best practices for ultrasound-guided elbow arthrocentesis. [Clin Pract Cases Emerg Med. 2019;3(3):286-288.]

## INTRODUCTION

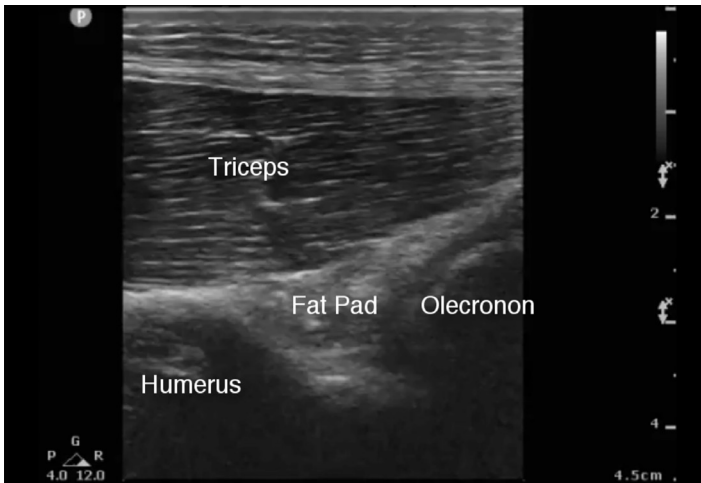
Septic arthritis results from an infection in a joint space from bacteria, fungus, virus, or even parasite. Delay in diagnosis of septic arthritis can have significant morbidity and even lead to death.<sup>1</sup> While physical exam is critical to the diagnosis and evaluation of a septic joint, joint aspiration and culture is definitive.<sup>2</sup> Because joint aspiration can be uncomfortable for a patient already presenting with joint pain, it is helpful to use ultrasound to evaluate whether there is an effusion. In the emergency department (ED), ultrasound is a critical diagnostic tool in the evaluation of patients in whom septic joint is clinically suspected. Ultrasound imaging can provide diagnostic information that expedites definitive diagnosis and treatment.

## CASE REPORT

A 53-year-old man presented to the ED with pain in his right elbow. The onset of this pain was sudden, was without a clear injury or event, and had been worsening for approximately eight hours prior to presentation to the ED. He denied trauma to the area recently or historically and had no prior surgeries to the right elbow. Of note, he did have a recent hospitalization for robotic-assisted prostatectomy due to prostate cancer and had been on a course of antibiotics during that hospitalization. The patient reported that the pain was exacerbated by any movement of the elbow, particularly with flexion to 90 degrees. There was mild associated swelling, but no significant redness or warmth. He denied fevers, chills, weakness, numbness, or paresthesia.

The patient's vital signs on presentation to the ED were within normal limits. He was well appearing and in no distress. On exam, we noted mild associated swelling of the right elbow, but no significant erythema or increased warmth. There was severe pain with any palpation of the right elbow. The right extremity was neurovascularly intact. Additionally, the patient was able to extend the affected wrist, abduct all fingers, and oppose the thumb. The differential diagnosis included hemarthrosis, elbow strain, septic arthritis, or crystalline disease. Complete blood count and basic metabolic panel were unremarkable. C-reactive protein was less than one milligram per liter and erythrocyte sedimentation rate was five millimeters per hour. Three radiographs of the right elbow were unremarkable without sail sign or posterior fat pad observed. We used a posterior oblique ultrasound approach of the right elbow to look specifically at the olecranon fossa. For the purposes of comparison, a normal sonographic appearance of the elbow (posterior approach) is depicted in Image 1. A joint effusion (Image 2) was identified between the olecranon fossa and its associated fat pad. We again used a posterior oblique approach to identify the joint effusion. Using an 18-gauge spinal needle with sterile technique, we aspirated the joint effusion under dynamic ultrasound guidance (Image 3). Six milliliters (ml) of cloudy, purulent fluid was aspirated.

Ultrasound helped to rapidly identify the effusion and guide the aspiration. Orthopedics was then consulted and expeditiously admitted the patient for suspected septic joint. He was treated with ceftriaxone and vancomycin. Studies of the joint aspirate showed white blood cell count (WBC) of 53,100 cells per



**Image 1.** Posterior long-axis view of the elbow using a high-frequency linear transducer. The transducer indicator (p) is positioned superiorly and proximally. Note the normal elbow sonoanatomy and the position of the posterior fat pad to the elbow joint.

cubic millimeter ( $\text{mm}^3$ ) and red cloudy fluid. There were no synovial crystals identified in the fluid.

In this case, ED point-of-care ultrasound (POCUS) quickly identified a right elbow joint effusion and was used for dynamically guided arthrocentesis of the right elbow joint.<sup>3</sup> POCUS additionally allowed for exclusion of other etiologies for the patient's symptoms such as tendon injury, muscle injury, or fracture, and these were not seen surrounding the elbow.<sup>4</sup> Of note, while the initial analysis of the synovial fluid was suggestive of septic arthritis,<sup>5</sup> given  $\text{WBC} > 50,000$  cells/ $\text{mm}^3$ , cultures did not grow any bacteria. This was likely due to recent antibiotic use after prostatectomy, suggesting partially treated septic arthritis.

## DISCUSSION

This case is unique and relevant to the emergency physician (EP) because joint complaints are a common presentation that has a wide differential to consider. POCUS was essential because it allowed identification of an abnormal joint effusion and guided the elbow aspiration, which is difficult to do by landmark-only technique. Using POCUS, the EP can use three areas surrounding the elbow to evaluate a swollen elbow. These three areas are the olecranon fossa, coronoid fossa, and the radial fossa. Each of these has an associated fat pad. Normally, a fat pad fills these potential spaces, but if there is an effusion present (Image 2), the effusion displaces the fat pad. The posterior recess or olecranon fossa is the fastest and easiest area to explore. One can use either a long-axis or short-axis orientation of the ultrasound probe. It is also one of the easier approaches for aspirating a joint effusion.

The elbow arthrocentesis (Image 3) should be performed with the patient sitting upright and at the appropriate height as to allow the sonographer comfort and to identify

### *CPC-EM Capsule*

What do we already know about this clinical entity?

*Septic joint is a well-characterized disease that usually occurs secondary to blood-borne infection.*

What makes this presentation of disease reportable?

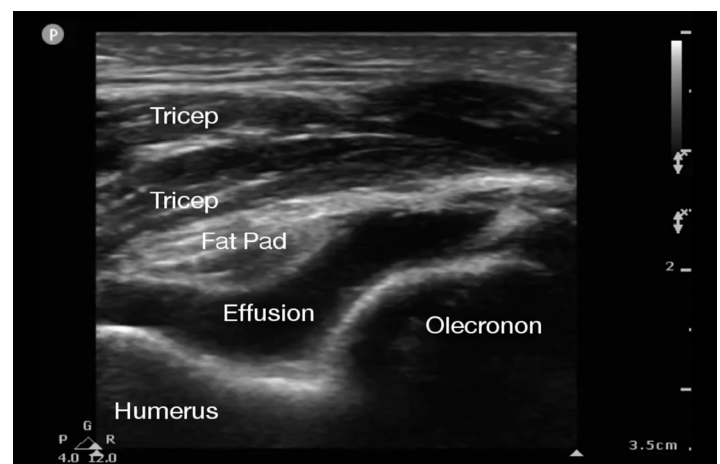
*This patient had recently undergone prostatectomy and a course of antibiotics, with physical exam findings of elbow tenderness, mild swelling, and pain with movement of the joint.*

What is the major learning point?

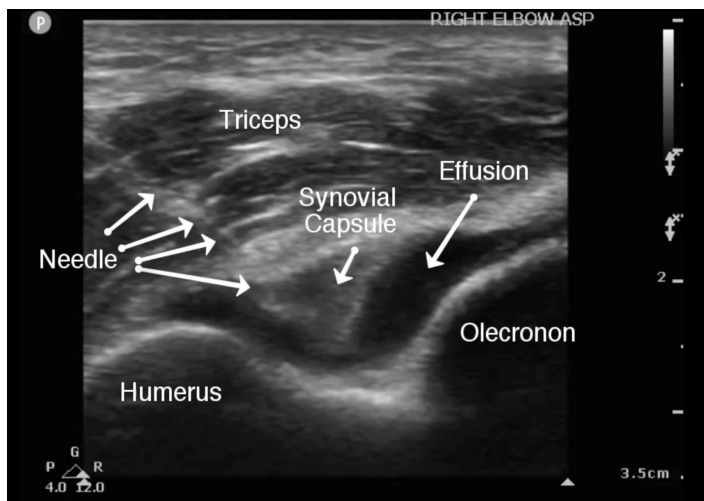
*Ultrasound can be used to identify an effusion even when there is no erythema, warmth, or significant swelling over the elbow joint.*

How might this improve emergency medicine practice?

*Bedside ultrasound can supplement clinical suspicion for septic joint, aid in efficacy of joint aspiration, and expedite treatment at little associated risk and cost.*



**Image 2.** Posterior long-axis view of the elbow using a high-frequency linear transducer. The transducer indicator (p) is positioned superiorly and proximally. A large elbow joint effusion is labeled along with relevant anatomy. Note the posterior displacement of the fat pad.



**Image 3.** Posterior long-axis dynamic guided elbow aspiration using the high-frequency linear transducer and 18-gauge spinal needle. The transducer indicator (p) is again positioned superiorly and proximally. Note the posterior displacement of the synovial joint capsule into the effusion during aspiration.

landmarks. A high-frequency linear transducer should be used and placed on the posterior aspect of the elbow with the indicator superior and proximally (toward the triceps body). Place the elbow in 90 degrees, arm abducted, with the patient's forearm pronated using a side table to rest the hand. There are specific landmarks of the elbow that should be identified and palpated. Given that we used the posterior oblique approach and olecranon fossa for arthrocentesis, imagine a triangle formed by the lateral olecranon, the head of the radius, and the lateral epicondyle.

The skin should be prepared and cleaned with chlorhexidine. Next, using 1% lidocaine and a small needle (25 or 27 gauge), inject a wheal of local anesthesia into the dermis. With consistent pressure, identify the needle tip and advance the needle under sonographic dynamic guidance until the joint capsule is penetrated and joint fluid is aspirated. Collect synovial fluid, 5 ml to 10 ml, and remove the needle. Apply pressure with gauze for any bleeding observed and dress the puncture site. Send the specimen for testing.<sup>6</sup>

EPs can easily examine for the presence of elbow effusion with POCUS to aid in the diagnostic evaluation. The technique has little associated risk and cost. This bedside test can supplement clinical suspicion for septic joint, aid in efficacy of joint aspiration, and expedite treatment.

## CONCLUSION

A high index of suspicion for septic joint/arthritis is an important consideration for a patient presenting with joint pain significant enough to prevent decreased ability to move the affected joint. This case highlights that the classic

symptoms of infection, including erythema, warmth, and swelling are not always present on physical exam especially when the patient has been on a recent course of antibiotics. POCUS is an excellent modality to identify and safely aspirate joint effusions. This patient proceeded to incision and drainage of the right elbow with orthopedics, and cultures continued to be negative. He made a full recovery. Using POCUS for workup and diagnosis of septic joint can improve efficacy of workup and time to treatment.

Documented patient informed consent and/or Institutional Review Board approval has been obtained and filed for publication of this case report.

*Address for Correspondence:* Robert Strony, DO, MBA, Geisinger Emergency Medicine, 100 N. Academy Ave MC 20-05, Danville, PA 17822. Email: rjstrony@geisinger.edu.

*Conflicts of Interest:* By the CPC-EM article submission agreement, all authors are required to disclose all affiliations, funding sources and financial or management relationships that could be perceived as potential sources of bias. The authors disclosed none.

*Copyright:* © 2019 Patitsas et al. This is an open access article distributed in accordance with the terms of the Creative Commons Attribution (CC BY 4.0) License. See: <http://creativecommons.org/licenses/by/4.0/>

## REFERENCES

1. Lin HM, Learch TJ, White EA, et al. Emergency joint aspiration: a guide for radiologists on call. *Radiographics*. 2009;29(4):1139-58.
2. Boniface KS, Ajmera K, Cohen JS, et al. Ultrasound-guided arthrocentesis of the elbow: a posterior approach. *J Emerg Med*. 2013;45(5):698-701.
3. Springer BL and Pennington BM. Joint arthrocentesis in the emergency department. 2017. Available at: <https://www.reliasmedia.com/articles/141511-joint-arthrocentesis-in-the-emergency-department>. Accessed October 28, 2018.
4. Boss SE, Mehta A, Maddow C, et al. Critical orthopedic skills and procedures. *Emerg Med Clin North Am*. 2013;31(1):261-90.
5. Carpenter CR, Schuur JD, Everett WW, et al. Evidence-based diagnostics: adult septic arthritis. *Acad Emerg Med*. 2011;18(8):781-96.
6. Jacobson JA. (2013). *Fundamentals of Musculoskeletal Ultrasound*. Philadelphia, PA: Elsevier/Saunders.

# Homicide Using an Air Weapon

Benjamin Mogni, MD\*  
Sarah Maines, MD†

\*Rush University Medical Center, Department of Emergency Medicine, Chicago, Illinois  
†Kentucky State Medical Examiner's Office, Frankfort, Kentucky

Section Editor: Scott Goldstein, MD

Submission history: Submitted March 5, 2019; Revision received June 3, 2019; Accepted June 10, 2019

Electronically published July 22, 2019

Full text available through open access at [http://escholarship.org/uc/uciem\\_cpccem](http://escholarship.org/uc/uciem_cpccem)

DOI: 10.5811/cpcem.2019.6.42982

The debate over the lethality and ownership of modern, high-powered weapons has recently grabbed the headlines. High-velocity air weapons, advertised as starter guns for children, can cause lethal injuries despite non-lethal appearing wounds. Presented is a rare case of a modern, high-powered air weapon used in a homicide. A literature search yielded reports of only three previous murders by air weapon in the United States and only one involving injury to the thorax. In the current case, the killer used a diabolo pellet to penetrate the chest. The pathway tracked through the sternum, piercing the anterior pericardial sac and perforating the right ventricle, which led to a pericardial effusion. The pellet embolized to the left pulmonary artery and eventually the vasculature of the left lung. Cause of death was a penetrating gunshot wound of the chest most likely leading to cardiac tamponade. This case exemplifies several important characteristics of penetrating chest trauma from air guns: first, air rifles, with exit velocities up to 1200 feet per second, can kill and have been used in accidental deaths, homicides and suicides; secondly, diabolo pellets may embolize just as bullets can; and lastly, minor external damage may mask major internal destruction. [Clin Pract Cases Emerg Med. 2019;3(3):289-294.]

## INTRODUCTION

An air-powered gun is defined as a weapon that uses the expanding forces of compressed air or gas to propel a projectile.<sup>1</sup> Retail stores advertise air weapons, shown in Image 1, as starter or recreational guns for children, but fail to warn citizens about the lethal threat they pose. While these injuries may appear non-lethal, they can cause deadly end organ damage. The literature on air weapon deaths yielded only three murders in the United States (U.S.), and only one of these described a gunshot wound to the chest. Case reports involving accidental deaths usually describe children with injuries to the head, neck and eyes.<sup>1-8</sup> In reported cases involving penetration of the thorax, death resulted from laceration of the pulmonary artery, aorta or right ventricle.<sup>9-11</sup> We discuss the homicide of a 31-year-old male killed by a penetrating injury of the right ventricle via air weapon, which led to pericardial tamponade. In addition, we review the literature.

## CASE REPORT

Emergency medical technicians arrived to find a man lying on the sidewalk for an unknown period of time. They provided Advanced Cardiac Life Support care, intubated the man, and placed him on a cardiac monitor. The reading



Image 1. Example of an air rifle.

showed asystole. He was transported to a local area hospital and pronounced dead after a resuscitation attempt. Medical staff noted a small, possible bullet wound over the patient's sternum. The county coroner requested an autopsy.

On autopsy, the patient was a 68.5 inches (1.74 meters [m]) tall male weighing 174 pounds (lbs) (78.9 kilograms [kg]) with a penetrating gunshot wound of the midline chest, 0.19 inch (4.76 millimeters [mm]) in diameter and located 18.25 inches (46.4 centimeters [cm]) from the top of his head. Black cutaneous discoloration surrounded the wound and did not wipe away. From 11 o'clock to 6 o'clock the discoloration's thickness was 0.13 inch (3.18 mm) wide, and from 6 o'clock to 11 o'clock it was 0.19 inch (1.59 mm).


The forensic pathologist tracked the pathway of the projectile through the sternum; it pierced the anterior pericardial sac and penetrated the right ventricle of the heart, eventually entering the vasculature of the left lung. A diabolo air-rifle pellet, shown in Image 2 and described as hourglass or mushroom shaped with a hollow base, was recovered from the left pulmonary artery. The trajectory of the projectile was front to back, with minimal left to right or up-down deviation. Injuries outside of the heart included emphysema of the mediastinal soft tissue, hemorrhage of the mediastinal soft tissues and the left hilar soft tissues, and hemoaspiration. The pathologist also noted a 500 milliliter (mL) hemopericardium and a 250 mL left hemothorax. Cause of death was a penetrating gunshot wound of the chest most likely leading to cardiac tamponade.

The police investigation revealed that a Game Big Cat 1200 air rifle had been used in the shooting. This gun can shoot at a top speed of 1200 feet per second (ft/s). It can only shoot a 0.18-inch (4.57 mm) air pellet.

## DISCUSSION

The danger of air weapons was evident as far back as the early 1800s when they were used in the Napoleonic wars.<sup>4</sup> In their earliest days, air rifles held several advantages over powder firearms. These weapons were quieter, did not produce a flash or smoke, and a soldier could discharge 20 rounds in the same time it took him to reload a musket. However, the air weapon's delicate nature did not hold up in combat.<sup>11</sup> While today's air rifles feature increased accuracy, automatic capability, and the power of modern firearms, they are no longer a weapon of war; rather they are advertised to children as a recreational device.<sup>9,11</sup>

In the late 1960s, the U.S. and the United Kingdom (UK) both adopted gun control laws. The U.S. excluded air weapons, including those using carbon dioxide, from being classified as firearms.<sup>9</sup> (It is important to note that manufacturers did not introduce high-powered air rifles until the early 1970s.<sup>6,12</sup>) Currently, only 28 states have



**Image 2.** Diabolo pellet used in the homicide.

### *CPC-EM Capsule*

What do we already know about this clinical entity?

*Ocular trauma is the most common presentation of air weapon injury in the emergency department. Most deaths from an air weapon injury are caused by intracranial penetration by the pellet.*

What makes this presentation of disease reportable?

*Penetration of the myocardium with an air rifle rarely occurs. Most deaths happen after the pellet enters the cranium. Furthermore, homicides are seldom committed with air weapons.*

What is the major learning point?

*Physicians should not underestimate the injury caused by an air weapon. A small external wound is often misleading. Furthermore, physicians should counsel patients on the dangers of these guns.*

How might this improve emergency medicine practice?

*This case report hopes to teach physicians to completely investigate air weapon wounds. Furthermore, we hope physicians will counsel patients on the dangers these weapons pose to children.*

laws regulating air rifles; some states classify them as firearms while others exclude air rifles from this classification.<sup>5</sup> In 1980, U.S. retailers sold over three million air weapons.<sup>6</sup>

The Firearms (Dangerous Air Weapons) Rules of 1969 in the UK specified the maximum kinetic energy that an air pistol and air rifle could eject their projectile as follows: at six feet per pound (ft/lb) (8.1 joules [J]) for an air pistol and 12 ft/lb (16.3 J) for an air rifle. Any greater energy categorized the gun as a firearm and required a certificate for possession. Use of carbon dioxide classified the air weapon as a firearm.<sup>4</sup> In Scotland, the total number of injuries due to air weapons decreased from 2377 in 2002/2003 to 299 in 2014/2015. Of these reported injuries,

authorities reported zero to three fatalities per year. In 2017, Scottish authorities began requiring licenses for possession of an air weapon.<sup>13</sup> No data has been published yet on whether this requirement has further decreased air weapon-induced injuries or deaths.

Physicians have long been aware of the ophthalmologic dangers of air weapons.<sup>7,14-22</sup> Bowen in 1973 showed that out of 105 cases of eye injury due to air weapon, 43% of children had significant residual visual deficits and 20% of children with a globe rupture from an air weapon required removal of the eye.<sup>15</sup> However, these weapons also cause injuries outside of the eye and even death.

The greatest factor in any death by projectile is the kinetic energy of the projectile. The equation for kinetic energy is  $KE = \frac{1}{2}mv^2$ . Therefore, impact velocity of the pellet claims the largest component involved in pellet gun deaths.<sup>23</sup> The farther the shooter stands from the victim, the lower the impact velocity and the lower the kinetic energy. Diabolo pellets consist of light material and their speed deteriorates quickly. Therefore, the pellets' exit velocity, distance traveled, and which tissue they hit determine the damage done.<sup>11,24</sup> In the early 1960s, the U.S. Army determined that a projectile requires 58 ft/lb (78.6 J) of force to create a casualty.<sup>16</sup> With a force between one and 10.9 ft/lb (1.4 J and 14.8 J), air weapons fail to satisfy this criterion; however, they could cause injury or death if the pellets were to strike certain anatomical locations.<sup>1</sup>

The most recent data from 2000 showed 21,840 injuries from air weapons in the U.S. Unfortunately, children prove most vulnerable to injury and death from air rifles, especially when unsupervised.<sup>24,25</sup> In 1995, the Centers for Disease Control and Prevention (CDC) reported air weapon injuries over a two-year time span. They reported that children and teenagers, 18 and younger, suffered 81% of the injuries.<sup>15,16</sup> Percentages on anatomic location of injury vary by series. However, the CDC report stated that 6% occurred to the eye, 25% to the head and neck not including the eye, 54% to the extremities, and 15% to the trunk.<sup>16</sup> In 1997, Scribano reported that minor injuries comprised 74% of injuries related to air weapons presenting to the emergency department (ED).<sup>18</sup>

The ammunition used in these weapons varies depending on the gun. The classic Daisy BB Gun will fire a pellet 0.18 inch (4.57 mm) in diameter and weighing 0.013 ounce (0.36 grams [g]). An air rifle will fire a diabolo pellet, a mushroom-shaped, gray projectile with a hollow bottom shown in Image 2. Air rifles typically fire two calibers of diabolo pellets: a 0.18-inch (4.57 mm), 0.53-g (0.019 ounce) pellet, or a 0.22-inch (5.59 mm), 0.97-g (0.034 ounce) pellet. These weapons can use several mechanisms to fire the pellets.<sup>1</sup>

Air weapons use three main propulsion arrangements to propel their pellets: spring-piston, pneumatic, and carbon dioxide. In a spring-piston weapon, a spring moves the piston and compresses air in a chamber. When released, the spring expels the

air from the chamber and the pellet exits the barrel. The pellet travels approximately 1000 ft per second (/s) (305 m/s).<sup>1</sup> A pneumatic air gun employs a system of pumps, with more pumps imparting a greater velocity, to deploy the projectile up to 770 ft/s (235 m/s).<sup>26</sup> A carbon dioxide-powered gun exploits compressed carbon dioxide. This scheme maintains approximately the same speed as a spring-piston air gun but varies with temperature.<sup>1</sup>

A process known as "dieseling" increases the velocities of all these weapons. Dieseling occurs when regular greasing of the barrel leaves excess oil, which the pellet ignites as it hurtles through the barrel.<sup>4,27</sup> Older versions of these guns, such as the classic Daisy BB Gun, discharged a projectile between 275 ft/s and 350 ft/s (84 m/s to 107 m/s). The literature reports that newer versions can fire a projectile as fast as 1200 ft/s (366 m/s) but most reach a velocity of 900 ft/s (274 m/s).<sup>1,11</sup> A trip to a department store by this author found several air weapons that could fire 1300 ft/s and 1400 ft/s as shown in Image 3. This surpasses the velocity of several, low-power handguns including a 9-mm, which Dimaio reported as 1140 ft/s (347 m/s).<sup>1,5,6,9,11</sup> With a velocity this high, these bullets may cause damage to any part of the body.

By firing pellets at pig eyes, the authors of one study determined that corneal perforation and globe rupture occurs 50% of the time at a velocity of 246 ft/s to 249 ft/s (75 m/s to 76 m/s) using a 0.18-inch (4.50 mm), 0.013 ounce (0.36 g) BB.<sup>1,17</sup> Dimaio established skin penetration of human lower extremities results at 331 ft/s (101 m/s) for a 0.18-inch (4.57 mm), 0.01-ounce (0.54-g) pellet and 245 ft/s (75 m/s) for a 0.038-ounce (1.07 g), 0.22-inch (5.59 mm) pellet.<sup>28</sup> Other reports place bone penetration around 350 ft/s (107 m/s).<sup>1</sup> However, the damage depends on the kinetic energy and, therefore, the weight as well. The lighter the projectile, the greater the velocity needed for penetration. Skin thickness and subcutaneous tissue will also affect the degree of penetration. Children tend to have thinner skin than adults and, therefore, a lower velocity will be needed to break the skin.<sup>1</sup>

Smedra-Kazmiriska et al. studied the velocity air pellets maintain for a certain distance and their force on impact. The highest velocity came from the "BMK 19"-0.18 inch (4.5 mm) air rifle with a velocity of 886 ft/s (270 m/s) and carrying an initial kinetic energy of 12.19 ft-lb (16.58 J). Depending on pellet type used, this led to penetration of a pellet into ballistics gelatin between 1.97 inches and 3.7 inches (50 mm and 94 mm) when fired from 65.6 ft (20 m). The study showed that several air rifle models available in 2013, including the "BMK 19"-0.18 inch (4.5 mm), could penetrate the pericardium from a distance of 65.6 ft (20 m).<sup>29</sup>

From 1982 to 1996, 33 deaths from air weapons occurred in the U.S.<sup>6</sup> From 1990 to 2000, American authors reported 39 deaths involving air weapons, 32 of which were children younger than 15 years old.<sup>12</sup> Cranial damage resulted in death most often.

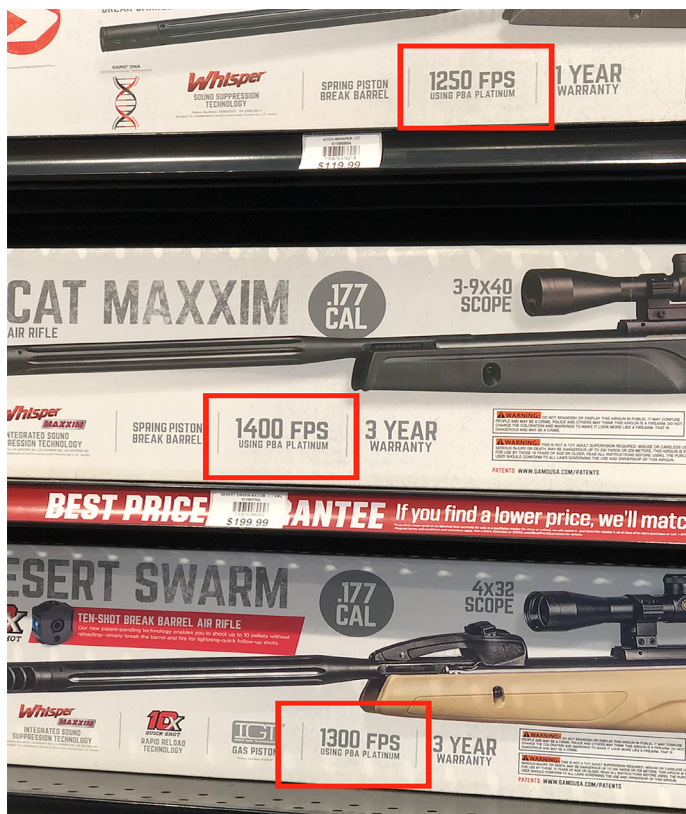

Image 3. Example of maximum velocity.

The pellet typically entered transnasally, transocularly or transtemporally, where the bone is the thinnest.<sup>11,30,31</sup> Several authors warn that children with these penetrating head injuries appear fine and maintain consciousness but may rapidly deteriorate.<sup>25,32</sup> However, injuries to the abdomen and thorax may result in fatality as well.

Penetrating wounds to the chest and abdomen carry significant morbidity and mortality. Chest injuries classically involve damage of the myocardium, aorta, or pulmonary vessels leading to cardiac tamponade or hemothorax.<sup>1,4,6-9,11,18,24,33-36</sup> While perforating injuries from air weapons to the abdomen commonly result in visceral injury, they can also injure the abdominal aorta.<sup>5,6,18,37,38</sup> Furthermore, physicians often underestimate the injury potential of air weapon gunshot wounds to the chest and abdomen.<sup>37</sup> Physicians must understand that air-weapon pellets carry a propensity to embolize once in the bloodstream.<sup>34,39</sup> (The old fear of lead poisoning from a retained air-weapon pellet appears obsolete, as the modern alloy composition of the ammunition does not elevate serum lead levels.<sup>19</sup>) Accidental trauma, suicide, or homicide may precipitate these injuries and deaths.

Although uncommon, suicide attempts typically involve penetrating injuries to the head, but also may involve the abdomen and chest.<sup>30,33,40-42</sup> The CDC reported in 1995 that 0.1% of ED visits for air-weapon injuries were from suicide

attempts.<sup>16</sup> Campbell-Hewson et al. presented a series of nine attempted suicides by air weapon and three completed suicides. The authors proposed that the availability of high-power firearms in the U.S. precludes air weapons as common weapons for suicide and murder.<sup>41</sup>

In the U.S., only three authors reported homicides with an air rifle since 1975. Dimaio described the first murder by air rifle portraying two teenage boys involved in a heated argument.<sup>43</sup> The younger of the two grabbed an air rifle and fired from only a few feet away, striking the older boy in the medial half of the right upper eyelid. The pellet travelled through the soft tissue of the orbit superiorly to the globe and entered the cranial cavity. The pellet caused damage to both hemispheres of the brain. The 17-year-old only survived for an hour and a half following the shot. Green in 1980 reported a case in which a gunshot wound to the head killed a man.<sup>44</sup> It appears two pellets were loaded into the chamber in a technique called “piggybacking.” Piggybacking occurs when two projectiles are loaded in the chamber. When fired, the increased mass augments the momentum of the pellets and thus intensifies the impact energy.<sup>4,6</sup>

In 2010, Bligh-Glover reported a drive-by shooting where an air-rifle bullet struck the victim’s left chest. The projectile perforated the pulmonary vasculature leading to a hemothorax. The bullet further struck the left ventricle but did not penetrate the myocardium. In 2001 in Japan, Ng’walali reported that a 0.03-ounce (0.9 g) and 0.22-inch (5.59 mm) diameter pellet perforated an elderly woman’s myocardium leading to cardiac tamponade and death. The pellet embolized to the left subclavian artery.<sup>35</sup>

## CONCLUSION

Most emergency physicians (EP) do not observe homicides or any other manner of death caused by air weapons because these events are rare. This case portrays only the fourth homicide using an air weapon that has been reported in the U.S. Although decreasing in popularity, air weapons still pose a threat that physicians should be prepared to treat and counsel patients about. Adults must supervise children using air weapons. Furthermore, any weapon that can penetrate the pericardium from 20 m away should not be viewed as a toy. When these injuries present to the ED, the EP should treat them as penetrating trauma.<sup>9</sup> Likewise, an EP should not underestimate an air-weapon injury, as the outside trauma may appear minimal despite extensive internal damage.<sup>18,37</sup> Without any soot around the wound the EP cannot distinguish between a wound inflicted from a short distance or long range.<sup>16</sup>

Several cultural factors enhance the dangers of these weapons. The physician must consider these aspects when counseling. First, many people view air guns as toys. Their low cost reinforces this perception. Also, lack of regulations and restrictions allow their simple acquisition in stores or online.<sup>16,37,40</sup> Our online search found dozens of air rifles on sale for as little as \$70.

Felons execute homicides with these guns; and in their lowest moments people commit suicide with these weapons. Physicians have debated the need for this legislation in the past with no clear consensus.<sup>8,20</sup> Perhaps it is time to revisit the topic, as gun-control legislation specifically addressing air weapons would increase public awareness of the danger.

Documented patient informed consent and/or Institutional Review Board approval has been obtained and filed for publication of this case report.

**Address for Correspondence:** Benjamin Mogni, MD, Rush University Medical Center, Department of Emergency Medicine, 1750 W. Harrison St. Suite 108 Kellogg, Chicago IL 60612-3833. Email: benjamin.mogni@uky.edu.

**Conflicts of Interest:** By the CPC-EM article submission agreement, all authors are required to disclose all affiliations, funding sources and financial or management relationships that could be perceived as potential sources of bias. The authors disclosed none.

**Copyright:** © 2019 Mogni et al. This is an open access article distributed in accordance with the terms of the Creative Commons Attribution (CC BY 4.0) License. See: <http://creativecommons.org/licenses/by/4.0/>

## REFERENCES

- DiMaio VJM. (2016). *Gunshot Wounds: Practical Aspects of Firearms, Ballistics, and Forensic Techniques* (3 ed). CRC Press; Boca Raton, Florida.
- Miner ME, Cabrera JA, Ford E, et al. Intracranial penetration due to BB air rifle injuries. *Neurosurgery*. 1986;19(6):952-4.
- Lawrence HS. Fatal nonpowder firearm wounds: case report and review of the literature. *Pediatrics*. 1990;85(2):177-81.
- Milroy CM, Clark JC, Carter N, et al. Air weapon fatalities. *J Clin Pathol*. 1998;51(7):525-9.
- Naude GP and Bongard FS. From deadly weapon to toy and back again: the danger of air rifles. *J Trauma*. 1996;41(6):1039-43.
- Bond SJ, Schnier GC, Miller FB. Air-powered guns: too much firepower to be a toy. *J Trauma*. 1996;41(4):674-8.
- Reeves B. Danger of airguns. *Br Med J*. 1968;1(5591):577-8.
- Christoffel KK, Tanz R, Sagerman S, et al. Childhood injuries caused by nonpowder firearms. *Am J Dis Child*. 1984;138(6):557-61.
- DeCou JM, Abrams RS, Miller RS, et al. Life-threatening air rifle injuries to the heart in three boys. *J Pediatr Surg*. 2000;35(5):785-7.
- Wascher RA and Gwinn BC, 2nd. Air rifle pellet injury to the heart with retrograde caval migration. *J Trauma*. 1995;38(3):379-81.
- Bligh-Glover WZ. One-in-a-million shot: a homicidal thoracic air rifle wound, a case report, and a review of the literature. *Am J Forensic Med Pathol*. 2012;33(1):98-101.
- Laraque D. Injury risk of nonpowder guns. *Pediatrics*. 2004;114(5):1357-61.
- Brown J, Sturge, G., Pratt A. . Air Weapons. *House of Commons Library*. 2018. 2018(Number 3641).
- Usher A and Webster JH. Aftermath of the Battle of Wagram. *Med Sci Law*. 1964;4:264-6.
- Bowen DI and Magauran DM. Ocular injuries caused by airgun pellets: an analysis of 105 cases. *Br Med J*. 1973;1(5849):333-7.
- BB and pellet gun-related injuries—United States, June 1992-May 1994. *MMWR Morb Mortal Wkly Rep*. 1995;44(49):909-13.
- Powley KD, Dahlstrom DB, Atkins VJ, et al. Velocity necessary for a BB to penetrate the eye: an experimental study using pig eyes. *Am J Forensic Med Pathol*. 2004;25(4):273-5.
- Scribano PV, Nance M, Reilly P, et al. Pediatric nonpowder firearm injuries: outcomes in an urban pediatric setting. *Pediatrics*. 1997;100(4):E5.
- Jacobs NA and Morgan LH. On the management of retained airgun pellets: a survey of 11 orbital cases. *Br J Ophthalmol*. 1988;72(2):97-100.
- Colby WD. Serious childhood injuries caused by air guns. *CMAJ*. 1991;145(10):1200-2.
- LaRoche GR, McIntyre L, Schertzer RM. Epidemiology of severe eye injuries in childhood. *Ophthalmology*. 1988;95(12):1603-7.
- Sharif KW, McGhee CN, Tomlinson RC. Ocular trauma caused by air-gun pellets: a ten year survey. *Eye (Lond)*. 1990;4(Pt 6):855-60.
- Barnes FC and Helson RA. A death from an air gun. *J Forensic Sci*. 1976;21(3):653-8.
- Fernandez LG, Radhakrishnan J, Gordon RT, et al. Thoracic BB injuries in pediatric patients. *J Trauma*. 1995;38(3):384-9.
- James W. A fatal air rifle pellet wound of the brain. *Med Sci Law*. 1962;2(2):153-4.
- Steindler RA. Air gun pellet penetration. *Med Sci Law*. 1980;20(2):93-8.
- Buchanan JD. "Dieseling" - a potentially lethal phenomenon in air weapons. *Med Sci Law*. 1982;22(2):107-10.
- DiMaio VJ, Copeland AR, Besant-Matthews PE, et al. Minimal velocities necessary for perforation of skin by air gun pellets and bullets. *J Forensic Sci*. 1982;27(4):894-8.
- Smedra-Kazmirska A, Barzdo M, Kedzierski M, et al. Experimental effect of shots caused by projectiles fired from air guns with kinetic energy below 17 J. *J Forensic Sci*. 2013;58(5):1200-9.
- Jacob B, Huckenbeck W, Daldrup T, et al. Suicides by starter's pistols and air guns. *Am J Forensic Med Pathol*. 1990;11(4):285-90.
- Ford EG, Senac MO, Jr., McGrath N. It may be more significant than you think: BB air rifle injury to a child's head. *Pediatr Emerg Care*. 1990;6(4):278-9.
- Shaw MD and Galbraith S. Penetrating airgun injuries of the head. *Br J Surg*. 1977;64(3):221-4.

33. Bakovic M, Petrovecki V, Strinovic D, et al. Shot through the heart-firepower and potential lethality of air weapons. *J Forensic Sci.* 2014;59(6):1658-61.
34. Isik O, Engin C, Daylan A, et al. Air gun pellet: cardiac penetration and peripheral embolization. *Ulus Travma Acil Cerrahi Derg.* 2016;22(3):301-3.
35. Ng'walali PM, Ohtsu Y, Muraoka N, et al. Unusual homicide by air gun with pellet embolisation. *Forensic Sci Int.* 2001;124(1):17-21.
36. Keten A, Avsar, A., Karanfil, R., et al. Accidental death by air rifle: a case report. *The Bulletin of Legal Medicine.* 2016;21(1).
37. DiGiulio GA, Kulick RM, Garcia VF. Penetrating abdominal air gun injuries: pitfalls in recognition and management. *Ann Emerg Med.* 1995;26(2):224-8.
38. Mejia A, Myers JG, Stewart RM, et al. Air gun injuries to the abdominal aorta: report of two cases and review of the literature. *J Trauma.* 2003;54(6):1235-8.
39. Colquhoun IW, Jamieson MP, Pollock JC. Venous bullet embolism: a complication of airgun pellet injuries. *Scott Med J.* 1991;36(1):16-7.
40. Pottker TI, Dowd MD, Howard J, et al. Suicide with an air rifle. *Ann Emerg Med.* 1997;29(6):818-20.
41. Campbell-Hewson G, Egleston CV, Busuttill A. The use of air weapons in attempted suicide. *Injury.* 1997;28(2):153-8.
42. Hollerhage HG and Dorfmueller G. [Extensive brain injury caused by attempted suicide with an airgun and ultrasound controlled removal of the deep intracranial projectile]. *Nervenarzt.* 1992;63(10):641-3.
43. DiMaio VJ. Homicidal death by air rifle. *J Trauma.* 1975;15(11):1034-7.
44. Green GS and Good R. Homicide by use of a pellet gun. *Am J Forensic Med Pathol.* 1982;3(4):361-5.

## Steal Phenomenon with Tonsillar Arteriovenous Malformation

Manish Amin, DO  
 Krishan Chaddha, DO  
 Phillip Aguiñiga-Navarrete, RA  
 Sudha Challa, MD  
 Madison B. Garrett, RA

Kern Medical, Department of Emergency Medicine, Bakersfield, California

Section Editor: Christopher Sampson, MD

Submission history: Submitted February 27, 2019; Revision received May 1, 2019; Accepted May 16, 2019

Electronically published July 1, 2019

Full text available through open access at [http://escholarship.org/uc/uciem\\_cpem](http://escholarship.org/uc/uciem_cpem)

DOI: 10.5811/cpcem.2019.5.42882

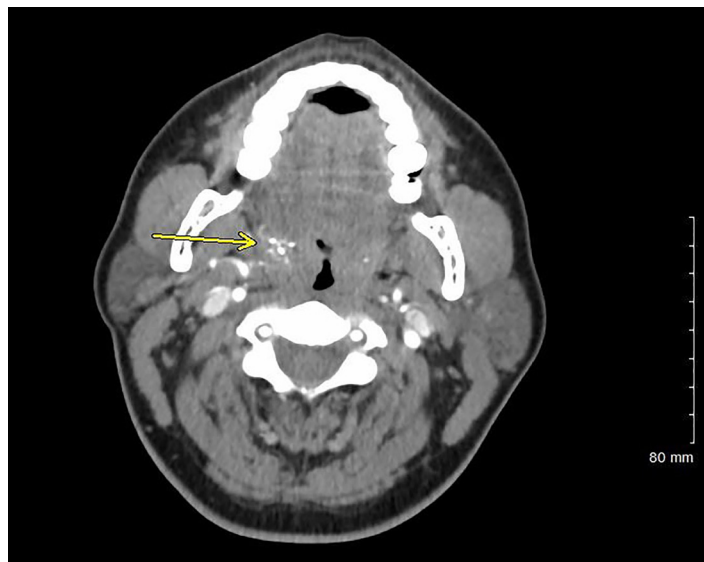
Cranial vascular malformations can cause symptoms of headache, stroke, transient ischemic attack, or other cerebrovascular disorders due to steal phenomenon. Subclavian steal phenomenon is a localized change in cerebral perfusion from a cranial arteriovenous malformation (AVM). We present the only recorded case of a tonsillar AVM causing a transient ischemic attack due to steal phenomenon. [Clin Pract Cases Emerg Med. 2019;3(3):295-296.]

### CASE PRESENTATION

A 35-year-old female presented to the ED with left arm and leg weakness. The patient had normal vital signs. Symptoms started 90 minutes before arrival. Past medical history included a questionable transient ischemic attack (TIA) two years prior. Physical examination noted enlargement of the right tonsillar region. The patient had four of five strength of the left upper and lower extremities with decreased light touch and pain sensation. Her National Institutes of Health Stroke Scale was one. Computed tomography (CT) of the brain was normal. CT angiogram of the brain and neck noted asymmetrical enlargement of the right pharyngeal tonsil associated with vessels and calcifications within the right tonsillar region (Image). Magnetic resonance imaging of the brain was normal. Neurology was consulted and the diagnosis of TIA from tonsillar arteriovenous malformation (AVM) was made.

### DISCUSSION

This is the only reported case of tonsillar AVM with an associated TIA. Venous malformations are common types of vascular malformations that present in infancy and expand throughout a patient's lifespan. They typically present in a focal region, with 40% of them occurring in the head and neck.<sup>1</sup> Vascular malformations noted within the cranium can contribute to symptoms of headache, stroke, TIA, or other cerebrovascular disorders.<sup>2</sup> Intracranial AVMs are known to cause TIA symptoms due to steal phenomenon, which is a localized change



**Image.** Axial computed tomographic angiography of the head showing palatine tonsillar arteriovenous malformation.

in perfusion from an AVM. Use of antiplatelet agents in TIAs is evidence-based and reduces the possibility of recurrence of neurologic deficits in patients who have had TIAs. However, this poses a problem in patients known to have AVMs, as these agents can cause a higher rate of complications and rupture with AVMs.<sup>3</sup>

The steal phenomenon noted with intracranial AVMs has not been known to be associated with AVMs that are located outside the cranium. This may be an area of research for the future.

Documented patient informed consent and/or Institutional Review Board approval has been obtained and filed for publication of this case report.

---

*Address for Correspondence:* Manish Amin, DO, Kern Medical Center, Department of Emergency Medicine, 1700 Mount Vernon Ave, Bakersfield, CA 93306. Email: manish.amin@kernmedical.com.

*Conflicts of Interest:* By the CPC-EM article submission agreement, all authors are required to disclose all affiliations, funding sources and financial or management relationships that could be perceived as potential sources of bias. Dr. Amin serves as an Associate Editor for CPC-EM.

*Copyright:* © 2019 Amin et al. This is an open access article distributed in accordance with the terms of the Creative Commons Attribution (CC BY 4.0) License. See: <http://creativecommons.org/licenses/by/4.0/>

---

## REFERENCES

1. Amato MV, Patel NA, Hu S, et al. Sporadic multifocal venous malformations of the head and neck. *Case Rep in Otolaryngol.* 2015;2015:508149.
2. Carolei A and Sacco S. Headache attributed to stroke, TIA, intracerebral haemorrhage, or vascular malformation. *Handb Clin Neurol.* 2010;97:517-28.
3. Jabbari E, Sethuraman S, Sekaran L. The clinical dilemma of treating transient ischaemic attack-like symptoms in patients with coexisting arteriovenous malformation. *BMJ Case Rep.* 2014;2014. pii: bcr2013201315.

### CPC-EM Capsule

What do we already know about this clinical entity?

*It is understood that vascular malformations within the cranium can result in steal phenomenon, transient ischemic attack (TIA) and stroke-like symptoms.*

What is the major impact of the image(s)?

*This atypical case shows arteriovenous malformation in the palatine tonsillar region, where a correlation to steal phenomenon causing TIA symptoms is not well studied.*

How might this improve emergency medicine practice?

*This case adds to the differential diagnosis for stroke-type presentations.*

## Tethered Cord Syndrome

Shawn Catmull, DO  
John Ashurst, DO, MSc

Kingman Regional Medical Center, Department of Emergency Medicine, Kingman, Arizona

Section Editor: Shadi Lahham, MD

Submission history: Submitted January 27, 2019; Revision received April 10, 2019; Accepted April 22, 2019

Electronically published July 3, 2019

Full text available through open access at [http://escholarship.org/uc/uciem\\_cpem](http://escholarship.org/uc/uciem_cpem)

DOI: 10.5811/cpcem.2019.4.42536

Tethered spinal cord syndrome refers to signs and symptoms of motor and sensory dysfunction related to increased tension on the spinal cord due to its abnormal attachment; it has classically been associated with a low-lying conus medullaris. Treatment is primarily surgical and has varying degrees of results. Although rarely diagnosed in the emergency department, the emergency physician must be aware of the disease in patients presenting with signs and symptoms concerning for cauda equina syndrome. [Clin Pract Cases Emerg Med.2019;3(3):297-298.]

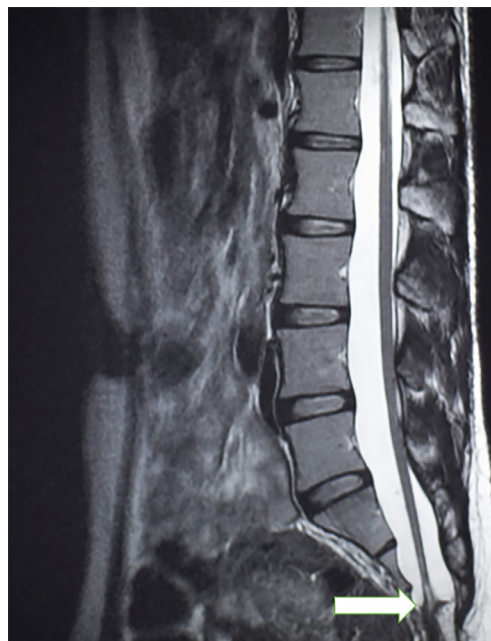### CASE PRESENTATION

A 30-year-old male presented to the emergency department with a three-day history of low back pain associated with urinary incontinence. His past medical history was significant for numerous urinary tract infections and bilateral hydronephrosis with associated mega-ureters status post ureteral stenting. Physical examination revealed tenderness to palpation along the paravertebral musculature of the lower back, normal muscle strength and tone, normal sphincter tone and no paresthesia along any dermatome. Magnetic resonance imaging (MRI) of the lumbar spine was obtained and depicted a dorsally positioned spinal cord segment within the spinal canal that continued to the position of the fifth lumbar and first sacral vertebrae (Images 1 and 2). The patient's case was discussed with the neurosurgical services and he underwent surgical decompression as an outpatient. The patient had complete resolution of his urinary symptoms following the procedure.

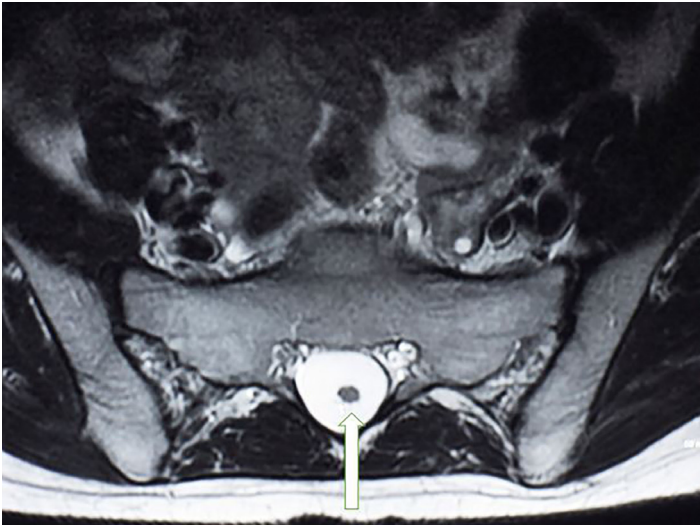
### DIAGNOSIS

Tethered spinal cord syndrome (TCS), first described in 1857, is a neurological disorder caused by an abnormal attachment of the spinal cord to surrounding tissues.<sup>1,2</sup> TCS can be caused by congenital (primary) or acquired (secondary) disorders.<sup>1,2</sup> Congenital disorders can occur anytime during embryologic development.<sup>1,2</sup> Acquired TCS can occur from lipomas, abnormal dural tracts, infections, or trauma.<sup>1,2</sup> The most common physical exam finding in adult patients with TCS is low back pain with flexion, but other neurologic findings including weakness, paresthesia, gait abnormalities, and

incontinence may occur.<sup>1-3</sup> In those suspected of TCS, the spine should be examined for any signs of spina bifida and scoliotic deformities and the feet should be examined for any signs of clubbing.<sup>1,2</sup> MRI is currently the gold standard for diagnosis, and neurosurgical intervention is the treatment of choice.<sup>1,2</sup>



**Image 1.** Sagittal view of a T2-weighted magnetic resonance image of the lumbar spine showing the conus medullaris of the tethered cord reaching to inferior edge of the second sacral vertebrae (arrow).



**Image 2.** Axial view of the T2-weighted magnetic resonance image showing the continuation of the spinal cord into the sacral region (arrow).

Documented patient informed consent and/or Institutional Review Board approval has been obtained and filed for publication of this case report.

*Address for Correspondence:* John Ashurst, DO, MSc, Kingman Regional Medical Center, Department of Emergency Medicine, 3269 Stockton Hill Road, Kingman, AZ 86409. Email: ashurst.john.32.research@gmail.com.

*Conflicts of Interest:* By the CPC-EM article submission agreement, all authors are required to disclose all affiliations, funding sources and financial or management relationships that could be perceived as potential sources of bias. Dr. Ashurst serves as a Section Editor for CPC-EM.

*Copyright:* © 2019 Catmull et al. This is an open access article distributed in accordance with the terms of the Creative Commons Attribution (CC BY 4.0) License. See: <http://creativecommons.org/licenses/by/4.0/>

### *CPC-EM Capsule*

What do we already know about this clinical entity?

*Tethered cord syndrome is a rare cause of back pain that is caused by an abnormal attachment of the spinal cord to surrounding tissues.*

What is the major impact of the image(s)?

*The image depicts the conus medullaris below the typical anatomical location that is expected by the emergency physician (EP). The EP should be aware of anatomical variants for the future treatment of patients.*

How might this improve emergency medicine practice?

*The EP should keep a broad differential when faced with a patient with back pain and frequent urinary tract infections.*

### REFERENCES

1. Agarwalla PK, Dunn IF, Scott RM, et al. Tethered cord syndrome. *Neurosurg Clin N Am.* 2007;18(3):531-47.
2. Hertzler DA 2nd, DePowell JJ, Stevenson CB, et al. Tethered cord syndrome: a review of the literature from embryology to adult presentation. *Neurosurg Focus.* 2010;29(1):E1.
3. Akay KM, Ersahin Y, Cakir Y. Tethered cord syndrome in adults. *Acta Neurochir (Wien).* 2000;142(10):1111-5.

## Twiddler's Syndrome

Jason A. Lesnick, MD  
Benjamin L. Cooper, MD  
Pratik B. Doshi, MD

McGovern Medical School at the University of Texas Health Science Center in Houston (UTHealth), Department of Emergency Medicine, Houston, Texas

Section Editor: Christopher Sampson, MD

Submission history: Submitted December 31, 2018; Revision received February 6, 2019; Accepted April 1, 2019

Electronically published May 20, 2019

Full text available through open access at [http://escholarship.org/uc/uciem\\_cpccem](http://escholarship.org/uc/uciem_cpccem)

DOI: 10.5811/cpcem.2019.4.42123

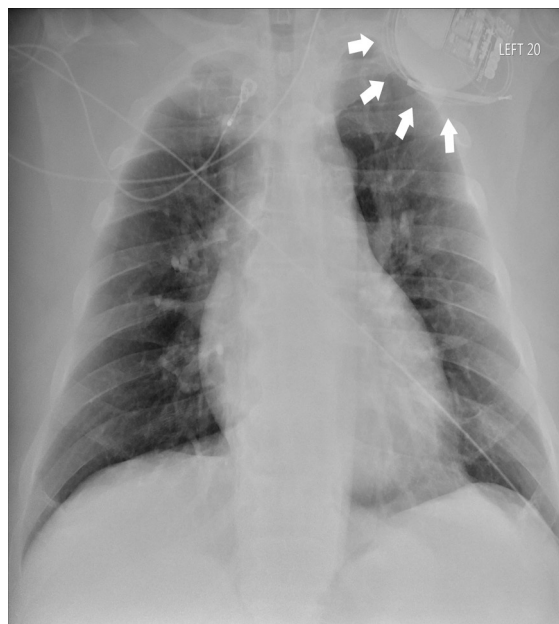
Twiddler's syndrome refers to a rare condition in which a pacemaker or automatic implantable cardioverter-defibrillator (AICD) malfunctions due to coiling of the device in the skin pocket and resultant lead displacement. This image is the chest radiograph (CXR) of a 54-year-old male who presented to the emergency department with chest pain five months after his AICD was placed. The CXR shows AICD leads coiled around the device and the absence of leads in the ventricle consistent with Twiddler's syndrome. Patients with twiddler's syndrome should be admitted for operative intervention. [Clin Pract Cases Emerg Med. 2019;3(3):299-300.]

### CASE PRESENTATION

A 54-year-old male with an automatic implantable cardioverter-defibrillator (AICD) placed five months prior to arrival presented with sharp, left-sided chest pain for one day. He stated that his "pacemaker is moving." On physical exam, the vital signs were within normal limits, the patient was in no distress, and the left superolateral chest wall was tender to palpation. The electrocardiogram showed a normal sinus rhythm without ischemic changes. Chest radiograph revealed AICD leads wrapped around the device and absence of leads in the ventricle (Image).

### DIAGNOSIS

Twiddler's syndrome refers to pacemaker or AICD malfunction due to coiling of the device in the skin pocket and resultant lead displacement. It is rare, estimated to occur in 0.07 – 7% of implanted devices, and almost always occurs within the first year of implantation.<sup>1</sup> It requires urgent attention as patients with malfunctioning AICDs are at risk for ventricular dysrhythmias and death,<sup>2,3</sup> and patients who rely on pacemakers lose extrinsic pacemaking activity. Patients with twiddler's syndrome should be admitted to a telemetry bed for operative repair. Twiddler's syndrome is classically associated with the patient twiddling or twisting his pacemaker causing lead dislodgement. While our patient denied intentionally manipulating the device, he did mention that he felt like his pacemaker moved when he changed positions.



**Image.** Anteroposterior chest radiograph revealing automatic implantable cardioverter-defibrillator leads wrapped around the device (white arrows) and absence of leads in the ventricle.

As implantable devices increase in popularity, emergency physicians should be aware of this potentially life-threatening condition.

Documented patient informed consent and/or Institutional Review Board approval has been obtained and filed for publication of this case report.

---

*Address for Correspondence:* Benjamin L. Cooper, MD, McGovern Medical School at the University of Texas Health Science Center in Houston (UTHealth), Department of Emergency Medicine, 6431 Fannin Street, JLL 434, Houston, Texas 77030. Email: benjamin.l.cooper@uth.tmc.edu

*Conflicts of Interest:* By the CPC-EM article submission agreement, all authors are required to disclose all affiliations, funding sources and financial or management relationships that could be perceived as potential sources of bias. The authors disclosed none.

*Copyright:* © 2019 Lesnick et al. This is an open access article distributed in accordance with the terms of the Creative Commons Attribution (CC BY 4.0) License. See: <http://creativecommons.org/licenses/by/4.0/>

---

### *CPC-EM Capsule*

What do we already know about this clinical entity?

*Twiddler's syndrome is a rare condition in which a pacemaker malfunctions due to coiling of the device in the skin pocket and resultant lead displacement.*

What is the major impact of the image(s)?

*The chest radiograph shows AICD leads coiled around the device and the absence of leads in the ventricle consistent with twiddler's syndrome.*

How might this improve emergency medicine practice?

*Patients with twiddler's syndrome should be admitted for operative intervention.*

## REFERENCES

1. Salahuddin M, Cader FA, Nasrin S, et al. The pacemaker-twiddler's syndrome: an infrequent cause of pacemaker failure. *BMC Res Notes*. 2016;9:32.
2. Bardy GH, Lee KL, Mark DB, et al. Amiodarone or an implantable cardioverter-defibrillator for congestive heart failure. *N Engl J Med*. 2005;352(3):225-37.
3. Moss AJ, Hall WJ, Cannom DS, et al. Improved survival with an implanted defibrillator in patients with coronary disease at high risk for ventricular arrhythmia. *N Engl J Med*. 1996;335(26):1933-40.

# The Dangers of Barbecuing: An Interesting Case of a Foreign Body in the Throat

Vincent R. Sicari, DO  
Joseph Pepe, DO  
Alfonso C. Cardenas Jr., MD  
Christopher Zabbo, DO

Kent Hospital, Department of Emergency Medicine, Warwick, Rhode Island

Section Editor: Scott Goldstein, DO

Submission history: Submitted December 28, 2018; Revision received March 24, 2019; Accepted April 1, 2019

Electronically published May 29, 2019

Full text available through open access at [http://escholarship.org/uc/uciem\\_cpem](http://escholarship.org/uc/uciem_cpem)

DOI: 10.5811/cpcem.2019.4.42105

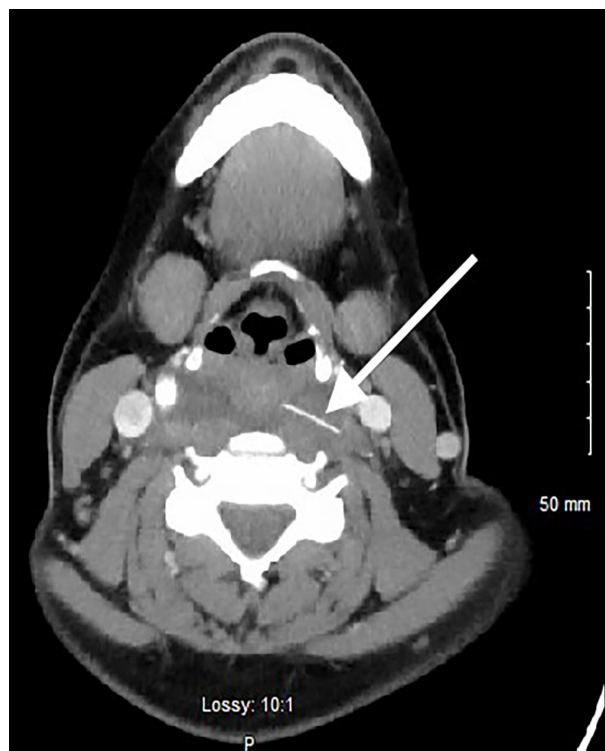Swallowing of foreign bodies (FB), and sensation of such in the throat, is a common complaint in the emergency department setting, with roughly 80,000 visits in 2010 for FB ingestion.<sup>1</sup> Grill wire brushes are a rarely reported, accidental FB ingestion, although recent literature suggests that it is more common than initially thought.<sup>2</sup> This is a report of a female with acute onset odynophagia after a meal, with a normal laryngoscopic exam that used flexible fiberoptics. Evidence of a metallic linear density was present in the retropharynx on computed tomography imaging, most consistent with a wire from a grill wire brush. [Clin Pract Cases Emerg Med. 2019;3(3):301-302.]

## CASE PRESENTATION

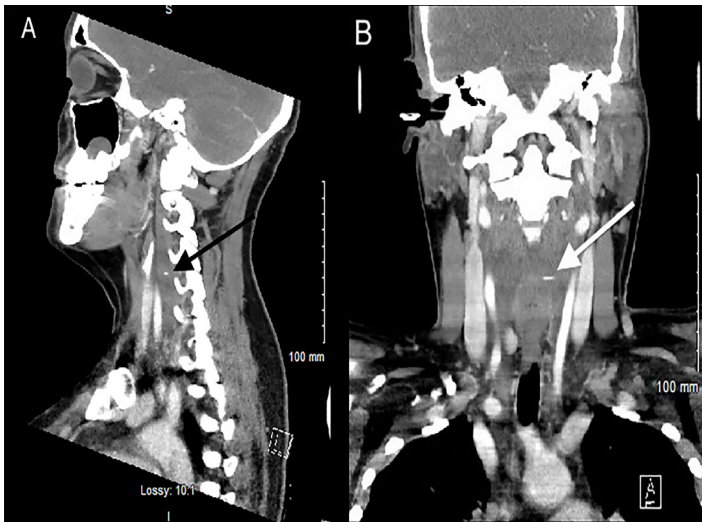
A 36-year-old-female presented to the emergency department with a one-day history of sharp pain in her throat that began immediately after swallowing food. Her vital signs, chest radiograph, and physical exam were unremarkable. She was discharged home after flexible fiberoptic visualization of her posterior oropharynx was normal. Her symptoms had subsided after treatment with viscous lidocaine. After she returned four days later with odynophagia, neck computed tomography (CT) was performed that showed a two-centimeter linear, radiopaque metallic density within the retropharyngeal soft tissues with effusion (Images 1 and 2).

## DISCUSSION

The patient was diagnosed with a retropharyngeal effusion caused by a retained foreign body (FB). She was taken to the operating room by otolaryngology; however, an attempt at retrieval was unsuccessful. She was subsequently transferred to a facility with head and neck surgery for the retrieval. On her first day of symptoms she did recall using a grill-wire brush prior to placing the food she had eaten on the grill, and therefore the FB was thought to be a wire from the brush. Grill wire brushes are a rarely reported, accidental FB ingestion, although recent literature suggests that it is more common than once thought.<sup>1</sup> Recently there have been increasing, albeit few,



**Image 1.** Computed tomography of the neck soft tissue with intravenous contrast in axial view, showing a linear metallic density with surrounding retropharyngeal effusion (white arrow).



**Image 2.** Computed tomography of the neck soft tissue with intravenous contrast in sagittal (A) and coronal (B) views. A linear metallic density with surrounding retropharyngeal effusion is visible: (A) (black arrow) and (B) (white arrow).

case reports describing grill-wire brush ingestion and their potential complications, which include esophageal perforation, effusion, abscess, and death.<sup>2,3,4</sup> This case demonstrates that patients with a clinical history suggestive of grill-wire brush FB should be considered for CT imaging, even in the absence of other physical findings.

Documented patient informed consent and/or Institutional Review Board approval has been obtained and filed for publication of this case report.

## REFERENCES

1. Marx JA and Rosen P. (2014). *Rosen's Emergency Medicine: Concepts and Clinical Practice*. 8th ed. Philadelphia, Pennsylvania: Elsevier/Saunders.
2. Grand DJ, Cloutier DR, Beland MD, et al. Inadvertent ingestion of wire bristles from a grill cleaning brush: radiologic detection of unsuspected foreign bodies. *AJR Am J Roentgenol*. 2012;198(4):836-9.
3. Campisi P, Setwart C, Forte V. Penetrating esophageal injury by ingestion of a wire bristle. *J Pediatr Surg*. 2005;40(10):e15-6.
4. Arganbright JM, Bruegger DE, Sykes KJ, et al. Wire grill brush bristle as an unusual foreign body: Report of two pediatric cases. *Laryngoscope*. 2012;122(3):685-7.

### *CPC-EM Capsule*

What do we already know about this clinical entity?

*Foreign body (FB) sensation in the throat is typically a benign condition. Grill wire brush ingestions are a rarely reported accidental FB ingestion but more common than once thought.*

What is the major impact of the image(s)?

*An accurate patient history and a high index of suspicion for this rare ingestion will decrease the delay in diagnosing this potentially life-threatening condition.*

How might this improve emergency medicine practice?

*Probing further into patient history, and adding contrast-enhanced imaging to plain radiographs, would help delineate this condition and its associated complications.*

*Address for Correspondence:* Vincent R. Sicari, DO, Kent Hospital, Department of Emergency Medicine, 455 Toll Gate Rd, Warwick, RI 02886. Email: vsicari@kentri.org.

*Conflicts of Interest:* By the CPC-EM article submission agreement, all authors are required to disclose all affiliations, funding sources and financial or management relationships that could be perceived as potential sources of bias. The authors disclosed none.

*Copyright:* © 2019 Sicari et al. This is an open access article distributed in accordance with the terms of the Creative Commons Attribution (CC BY 4.0) License. See: <http://creativecommons.org/licenses/by/4.0/>

## Extravasation from a Misplaced Intraosseous Catheter

Christopher S. Sampson, MD

University of Missouri School of Medicine, Department of Emergency Medicine,  
Columbia, Missouri

Section Editor: Rick A. McPheeters, DO

Submission history: Submitted January 29, 2019; Revision received April 4, 2019; Accepted April 22, 2019

Electronically published May 29, 2019

Full text available through open access at [http://escholarship.org/uc/uciem\\_cpem](http://escholarship.org/uc/uciem_cpem)

DOI: 10.5811/cpcem.2019.4.42561

A 75-year old female presented in cardiac arrest with a right tibial intraosseous (IO) catheter through which prehospital medications were administered. The catheter, which had been placed by emergency medical services, was noted in the emergency department to be misplaced and was removed. Due to extravasation of the medications, the patient suffered localized tissue necrosis and eventually required skin grafting. This case illustrates the importance of confirming appropriate IO placement. [Clin Pract Cases Emerg Med. 2019;3(3):303-304.]

### CASE PRESENTATION

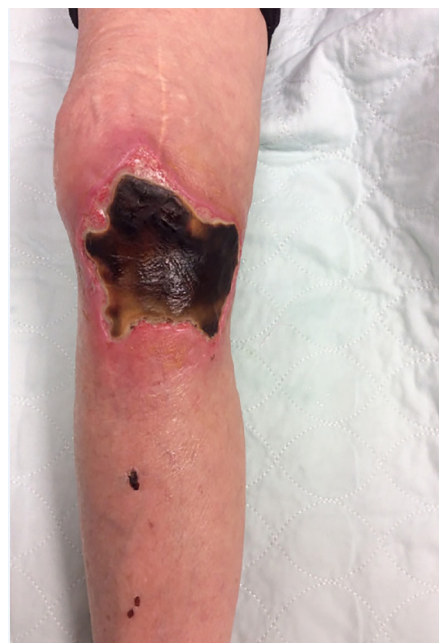A 75-year-old female arrived to the emergency department (ED) via emergency medical services (EMS) with a chief complaint of cardiac arrest. The patient had been shopping at a local store and collapsed. Bystanders started cardiopulmonary resuscitation. On EMS arrival her rhythm was found to be ventricular fibrillation. Multiple defibrillations were attempted with return of spontaneous circulation by EMS. During resuscitation an intraosseous (IO) catheter was placed in the right proximal tibia using an EZ-IO (Arrow) device prior to ED arrival. Medications given through the IO catheter by EMS included epinephrine, magnesium, amiodarone, and calcium chloride. On ED arrival, the IO catheter was found to not flush; it was deemed not functional, and new intravenous access was obtained. The IO catheter was removed. On hospital day three, ecchymosis was noted at the IO site. The patient was discharged from the hospital four days after admission and presented to the wound clinic three weeks later (Images 1 and 2).

After close follow-up (Image 3), skin grafting was performed on the patient's right leg at three months post event with good healing obtained.

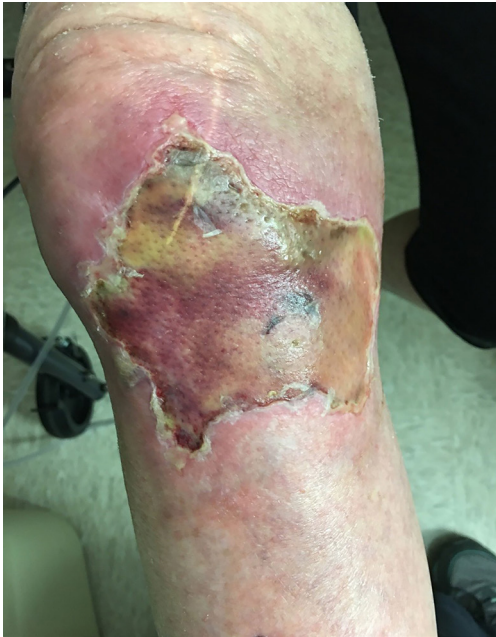### DISCUSSION

Extravasation of IO catheter infusions is a serious complication due to possible development of tissue necrosis or compartment syndrome. Complications reports are rare but serious and include tissue necrosis, osteomyelitis, fracture, and compartment syndrome.<sup>1</sup>

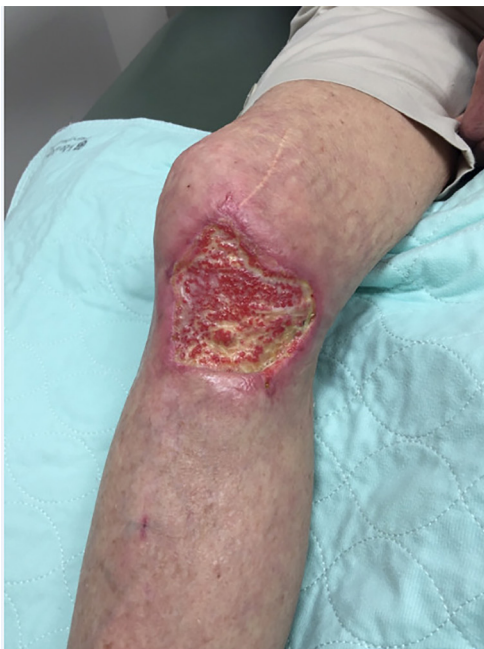Emergency providers must ensure proper technique is used for placement, as well as appropriate location. The anteromedial surface of the proximal tibia is the preferred location. After needle placement, aspiration of blood or marrow helps to confirm placement.<sup>2</sup>



**Image 1.** Intraosseous (IO) site, prior to debridement, three weeks after incorrect placement of IO catheter.



**Image 2.** Intraosseous site following debridement.



**Image 3.** Intraosseous site two months after placement.

Documented patient informed consent and/or Institutional Review Board approval has been obtained and filed for publication of this case report.

### *CPC-EM Capsule*

What do we already know about this clinical entity?

*Intraosseous (IO) access is a common method used to quickly obtain vascular access when traditional methods fail.*

What is the major impact of the image(s)?

*Misplaced IO catheters can lead to devastating consequences that can cause long-term morbidity.*

How might this improve emergency medicine practice?

*The emergency provider should confirm placement of an IO catheter and stay vigilant for signs of extravasation.*

*Address for Correspondence:* Christopher S. Sampson, MD, University of Missouri School of Medicine, Department of Emergency Medicine, 1 Hospital Drive DC029.1 Columbia, MO 65212. Email: sampsoncs@health.missouri.edu

*Conflicts of Interest:* By the *CPC-EM* article submission agreement, all authors are required to disclose all affiliations, funding sources and financial or management relationships that could be perceived as potential sources of bias. The authors disclosed none.

*Copyright:* © 2019 Sampson et al. This is an open access article distributed in accordance with the terms of the Creative Commons Attribution ([CC BY 4.0](http://creativecommons.org/licenses/by/4.0/)) License. See: <http://creativecommons.org/licenses/by/4.0/>

### REFERENCES

1. Simmons CM, Johnson NE, Perkin RM, et al.. Intraosseous extravasation complication reports. *Ann Emerg Med.* 1994;23(2):363-6.
2. Dev SP, Stefan RA, Saun T, et al. Videos in clinical medicine. Insertion of an intraosseous needle in adults. *N Engl J Med.* 2014;370(24):e35.

# An Unusual Presentation of Cholecystoduodenal Fistula: Abdominal Pain out of Proportion to Exam

Ryan McCreery, DO  
Matthew Meigh, DO

Orange Regional Medical Center, Department of Emergency Medicine, Middletown, New York

Section Editor: Rick A McPheeters, DO

Submission history: Submitted February 7, 2019; Revision received April 11, 2019; Accepted April 22, 2019

Electronically published May 29, 2019

Full text available through open access at [http://escholarship.org/uc/uciem\\_cpccem](http://escholarship.org/uc/uciem_cpccem)

DOI: 10.5811/cpcem.2019.4.42686

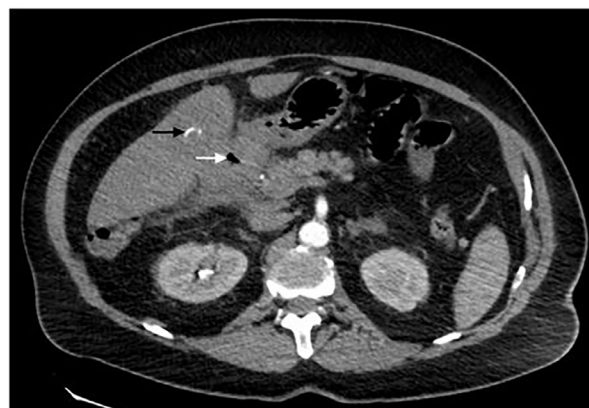Cholecystoduodenal fistula (CDF) is a rare complication of gallbladder disease. Clinical presentation is variable, and preoperative diagnosis is challenging due to the non-specific symptoms of CDF. We discuss a 61-year-old male with a history of atrial fibrillation who presented with severe abdominal pain out of proportion to exam. The patient was diagnosed promptly and successfully managed non-operatively. This case presentation emphasizes the need to maintain a broad differential diagnosis for abdominal pain out of proportion to exam, with the possibility of a biliary-enteric fistula as a possible cause. It also stresses the importance of a multimodality imaging approach to arrive at a final diagnosis. [Clin Pract Cases Emerg Med. 2019;3(3):305-306.]

## CASE PRESENTATION

A 61-year-old male with a history of atrial fibrillation presented to our emergency department with intermittent, post-prandial abdominal pain over the prior week. The patient localized the pain to the epigastric region and reported associated diarrhea. On examination, he was afebrile but appeared markedly distressed with an irregularly irregular rhythm at 108 beats per minute. Abdominal exam revealed mild generalized tenderness without guarding or rebound. Laboratory study results were unremarkable. Right upper quadrant ultrasound revealed gallstones with gallbladder wall thickening measuring up to 9.0 millimeters. In conjunction with the ultrasound findings, computed tomography (CT) angiography of the abdomen and pelvis revealed acute cholecystitis with gallbladder adherence to the right hepatic lobe and a fistula between the inflamed gallbladder and proximal duodenum (Images 1 and 2). Multiple, rim-calcified gallstones were visualized within the proximal jejunum (Image 3). No evidence of thromboembolic disease within the visceral arterial bed was identified. The patient was managed non-operatively with repeat CT imaging showing decreased inflammation over his one-week hospital stay.

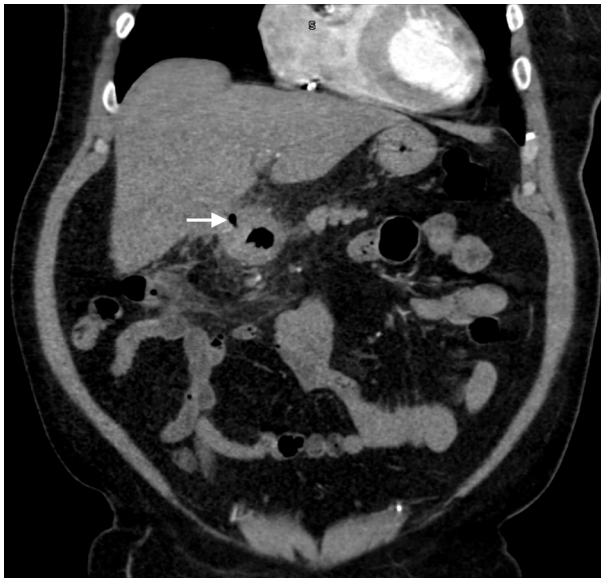## DISCUSSION

Cholecystoenteric fistula (CF) is defined as a spontaneous tract between an inflamed gallbladder and one or more parts of the adjacent gastrointestinal tract. Cholecystoduodenal fistula accounts for approximately 75-80% of all such fistulas.<sup>1,3</sup> It is an uncommon complication

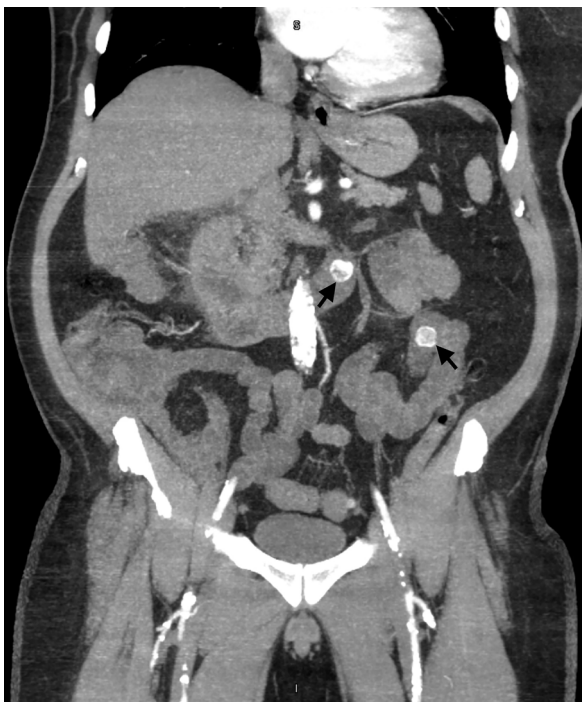

**Image 1.** Computed tomography angiography (axial view) demonstrating a wide soft tissue tract between the gallbladder and proximal duodenum (white arrow). Calcified gallstones seen entering the proximal duodenum and along the undersurface of the right hepatic lobe (black arrow).

of cholelithiasis with reported incidences ranging from 0.5-0.9%.<sup>2</sup> Chronic cholecystitis is the primary etiology for as many as 75% of CF patients.<sup>3</sup> Preoperative diagnosis is challenging due to the non-specific symptoms of CF when compared with cholecystitis. Initial management should focus on symptomatic treatment, antibiotics for concurrent cholecystitis, and surgical consultation. Gallstone ileus is a potential serious complication requiring surgical evaluation.<sup>4</sup>



**Image 2.** Computed tomography angiography (coronal view) demonstrating a wide, soft tissue tract between the gallbladder and proximal duodenum, containing a small amount of air (white arrow).



**Image 3.** Computed tomography angiography (coronal view) demonstrating two rim-calcified gallstones within the proximal jejunum (black arrows).

Documented patient informed consent and/or Institutional Review Board approval has been obtained and filed for publication of this case report

### *CPC-EM Capsule*

What do we already know about this clinical entity?

*Cholecystoduodenal fistula (CDF) is a rare complication of gallbladder disease with chronic cholecystitis as the primary etiology.*

What is the major impact of the image(s)?  
*These images clearly characterize CDF and will help raise awareness for this particular disease.*

How might this improve emergency medicine practice?

*This presentation emphasizes the need to maintain a broad differential diagnosis for abdominal pain out of proportion to exam, with CDF as a possible cause.*

*Address for Correspondence:* Ryan McCreery, DO, Orange Regional Medical Center, Department of Emergency Medicine, 707 E. Main St. Middletown, NY 10940. Email: [rmccreery@ghvhs.org](mailto:rmccreery@ghvhs.org).

*Conflicts of Interest:* By the CPC-EM article submission agreement, all authors are required to disclose all affiliations, funding sources and financial or management relationships that could be perceived as potential sources of bias. The authors disclosed none.

*Copyright:* © 2019 McCreery et al. This is an open access article distributed in accordance with the terms of the Creative Commons Attribution (CC BY 4.0) License. See: <http://creativecommons.org/licenses/by/4.0/>

### REFERENCES

1. Glenn F, Reed C, Grafe WR. Biliary enteric fistula. *Surg Gynecol Obstet.* 1981;153(4):527–31.
2. Chowbey PK, Bandyopadhyay SK, Sharma A, et al. Laparoscopic management of cholecystoenteric fistulas. *J Laparosc Adv Surg Tech A.* 2006;16(5):467–72.
3. Sharma A, Sullivan M, English H, et al. Laparoscopic repair of cholecystoduodenal fistulae. *Surg Laparosc Endosc.* 1994;4(6):433–5.
4. Abou-Saif A and Al-Kawas FH. Complications of gallstone disease: Mirizzi syndrome, cholecystocholedochal fistula, and gallstone ileus. *Am J Gastroenterol.* 2002;97(2):249–54.

# Situs Inversus: Inferior-Lateral ST-Elevation Myocardial Infarction on Right-Sided Electrocardiogram

Mohamed S. Hamam, MD, MSc\*†  
Howard Klausner, MD\*

\*Henry Ford Health System, Department of Emergency Medicine, Detroit, Michigan  
†Henry Ford Health System, Department of Internal Medicine, Detroit, Michigan

Section Editor: Shadi Lahham, MD

Submission history: Submitted February 28, 2019; Revision received May 10, 2019; Accepted May 16, 2019

Electronically published July 1, 2019

Full text available through open access at [http://escholarship.org/uc/uciem\\_cpem](http://escholarship.org/uc/uciem_cpem)

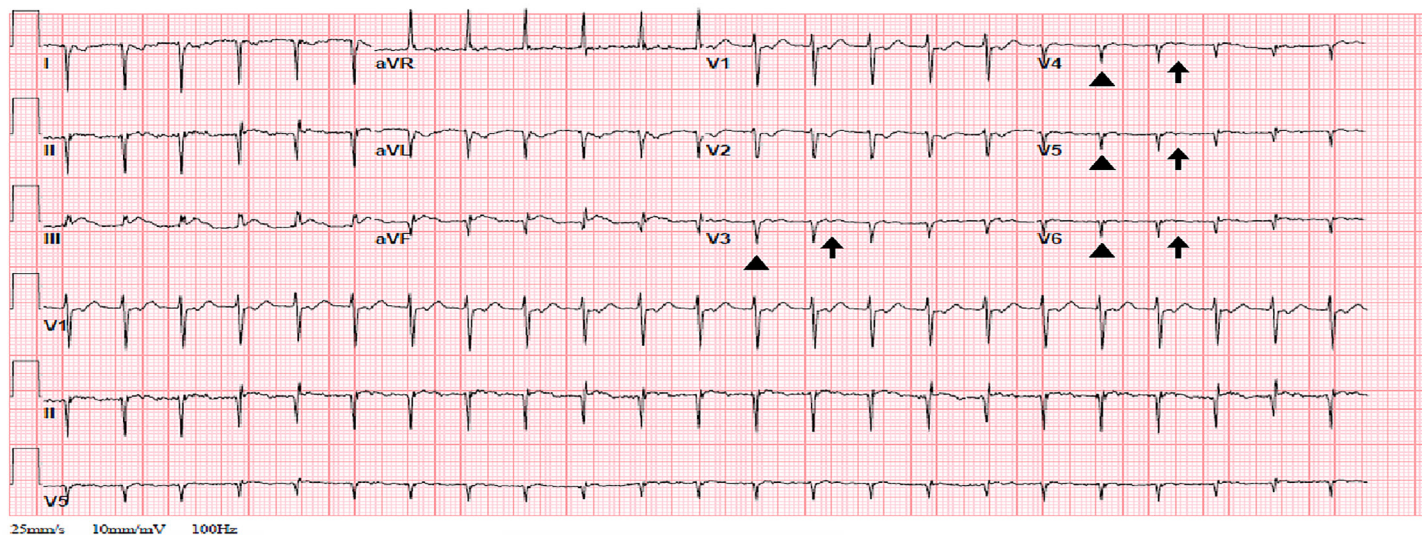
DOI: 10.5811/cpcem.2019.5.42912

Dextrocardia is a rare anatomical anomaly in which the heart is located in the patient's right hemithorax with its apex directed to the right. Although it usually does not pose any serious health risks, patients with undiagnosed dextrocardia present a diagnostic challenge especially in those presenting with chest pain. Traditional left-sided electrocardiograms (ECG) inadequately capture the electrical activity of a heart positioned in the right hemithorax, which if unnoticed could delay or even miss an acute coronary syndrome diagnosis. Here, we present a case of a patient with dextrocardia presenting with chest pain and diagnosed with ST-elevation myocardial infarction using a right-sided ECG. [Clin Pract Cases Emerg Med. 2019;3(3):307-309.]

## CASE PRESENTATION

A 52-year-old man presented to the emergency department with two days of intermittent, substernal, crushing chest pain radiating to his right shoulder that woke him from sleep. His medical history included Evan's syndrome, hypertension, beta-thalassemia, and

situs inversus. On physical examination, the patient had a heart rate of 138 beats per minute and a blood pressure of 141/96 millimeters of mercury (mmHg). Initial 12-lead electrocardiogram (ECG) obtained showed poor R-wave progression and flat T-waves in the precordial leads and ST-elevation in inferior leads (Image 1). Given these ECG



**Image 1.** A traditional electrocardiogram in a patient with dextrocardia with poor R-wave progression (arrowheads) and flattened T-waves (arrows). Heart rate: 138 beats per minute. PR interval: 96 milliseconds (ms). QRS interval: 72 ms. QT/QTc: 304/460 ms.

abnormalities, further history was obtained from the patient who said that a doctor had once told him his heart “faces the wrong way.” Therefore, a right-sided 12-lead ECG was obtained showing ST elevations in V4R, V5R, V6R, III and aVF suggestive of inferior-lateral ischemia (Image 2). The patient was treated with aspirin, heparin and ticagrelor, and cardiac catheterization lab was activated. The patient was found to have an occluded right coronary artery and underwent right coronary artery stenting for obstructive disease. The right-sided 12-lead ECG was essential in detecting lateral ischemia in this patient with dextrocardia.

## DISCUSSION

Dextrocardia describes an anatomical anomaly in which the heart is located in the right hemithorax with its apex directed to the right. However, the anatomical location of the atria, ventricles and great vessels vary depending on the embryological development of the heart.<sup>1</sup> In situs inversus, also called mirror-image dextrocardia, the great vessels and chambers are positioned as a mirror image of a left-sided heart.<sup>1</sup> This malpositioning produces interesting abnormalities that can be seen on a traditional ECG with poor R-wave progression and lack of T-waves.<sup>1</sup> Without noticing these details, a devastating diagnosis such as ST-elevation myocardial infarction could potentially be missed. It is, therefore, always important to scrutinize all ECGs and address any abnormality that could not be explained anatomically. Quick changes to the positioning

### CPC-EM Capsule

What do we already know about this clinical entity?

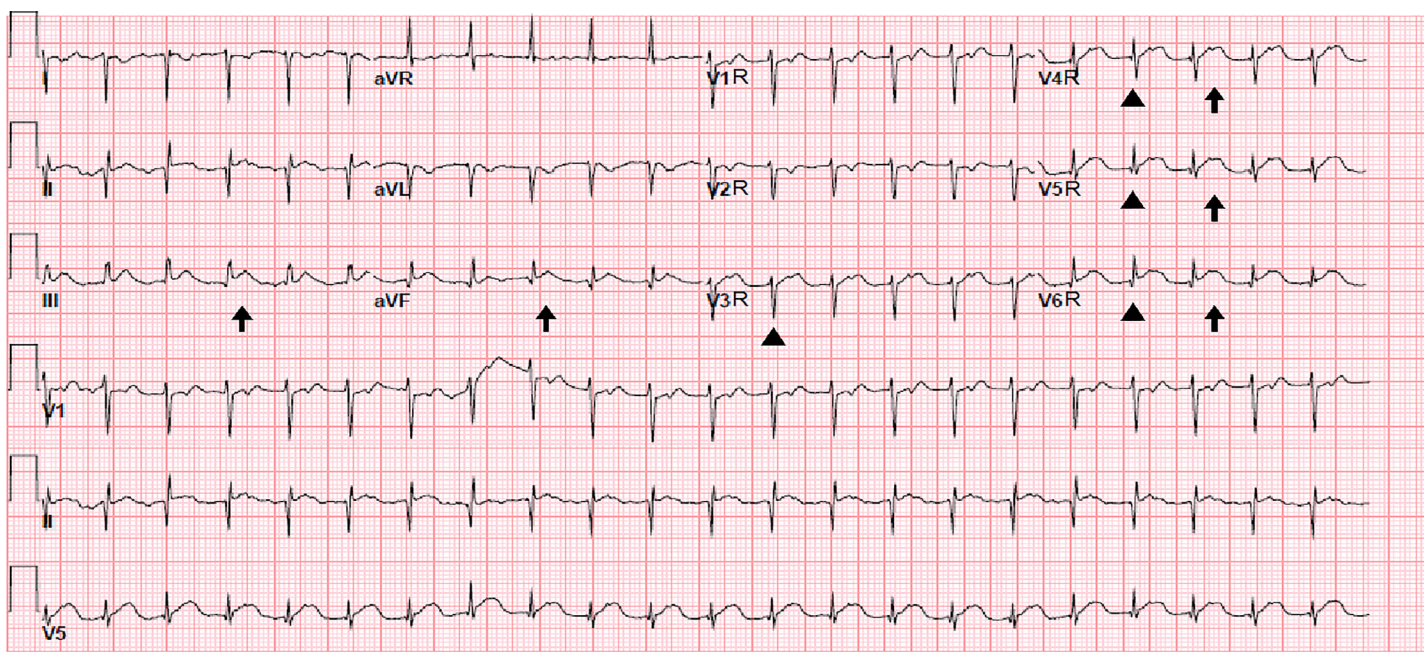
*Dextrocardia is the abnormal location of the heart in the thorax that can cause irregularities in traditional left-sided electrocardiograms (ECG).*

What is the major impact of the image(s)?

*The images show a left-sided ECG with unclear ST changes and a right-sided ECG showing the full extent of an ST-elevation myocardial infarction in a patient with dextrocardia.*

How might this improve emergency medicine practice?

*Thorough evaluation of ECGs for appropriate lead placement is important to accurately interpret pathology and life-threatening disease in the emergency department.*



**Image 2.** A right-sided electrocardiogram in the same patient with appropriate R-wave progression (arrowheads) and ST elevations (arrows) in the precordial leads. Heart rate: 132 beats per minute. PR interval: 96 milliseconds (ms). QRS interval: 66 ms. QT/QTc: 286/423 ms.

of the ECG leads provide a depth of information that could have otherwise been missed.

Documented patient informed consent and/or Institutional Review Board approval has been obtained and filed for publication of this case report.

## REFERENCE

1. Maldjian PD and Saric M. Approach to dextrocardia in adults: review. *AJR Am J Roentgenol.* 2007;188(6 suppl):S39-49.

---

*Address for Correspondence:* Mohamed S. Hamam, MD, MSc, Henry Ford Health System, Department of Emergency Medicine, 2799 W. Grand Blvd, Detroit, MI 48202. Email: mhamam1@hfhs.org.

*Conflicts of Interest:* By the *CPC-EM* article submission agreement, all authors are required to disclose all affiliations, funding sources and financial or management relationships that could be perceived as potential sources of bias. The authors disclosed none.

*Copyright:* © 2019 Hamam et al. This is an open access article distributed in accordance with the terms of the Creative Commons Attribution ([CC BY 4.0](http://creativecommons.org/licenses/by/4.0/)) License. See: <http://creativecommons.org/licenses/by/4.0/>

---

## Teenage Curiosity: Magnetic Attraction Gone Wrong

Matthew Hysell, MD  
Sarah E. Harris-Kober, OMS III

Michigan State University College of Osteopathic Medicine, Spectrum Health-  
Lakeland, Department of Emergency Medicine, St. Joseph, Michigan

Section Editor: Austin Smith, MD

Submission history: Submitted March 4, 2019; Revision received April 26, 2019; Accepted May 16, 2019

Electronically published July 1, 2019

Full text available through open access at [http://escholarship.org/uc/uciem\\_cpccem](http://escholarship.org/uc/uciem_cpccem)

DOI: 10.5811/cpccem.2019.5.42879

A 13-year-old male presented with suprapubic pain, hesitancy, and dysuria beginning seven hours prior to arrival. After initial evasiveness, the patient admitted to inserting small, magnetic ball bearings into his penis. Vital signs and physical exam were unremarkable aside from mild suprapubic tenderness to palpation. Pelvic radiograph demonstrated about 45 radiopaque beads within the urethra and bladder. While urethral foreign body (FB) is an uncommon diagnosis, it is essential to identify quickly as lifelong complications can arise. Magnetic FBs are particularly concerning due to possible ischemia from compression injury and difficulty of removal. Safety concerns led to temporary market removal of neodymium magnetic toys, but sales resumed in 2016. [Clin Pract Cases Emerg Med. 2019;3(3):310-311.]

### CASE PRESENTATION

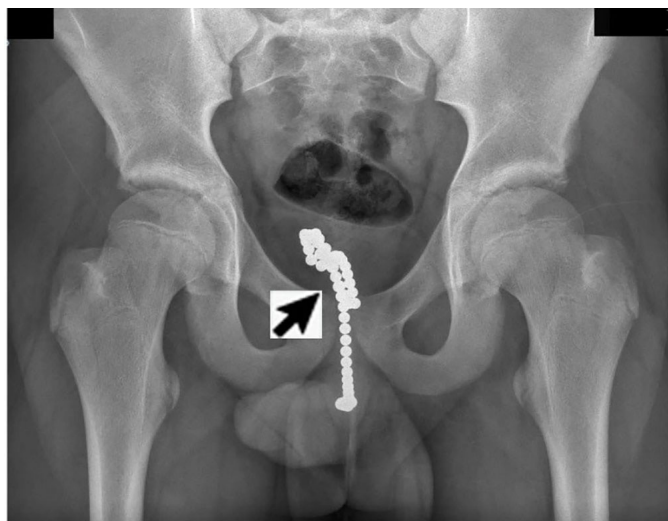A healthy 13-year-old male presented with suprapubic pain, hesitancy, and dysuria beginning seven hours prior to arrival. After initial hesitancy, the patient admitted to inserting small, magnetic ball bearings into his penis over the prior month, stating "I never lost any until today." Vital signs and physical exam were largely unremarkable aside from mild suprapubic tenderness to palpation. Urinalysis demonstrated 31-50 leukocytes per high powered field (HPF) and too numerous to count red blood cells/HPF. Complete blood count and comprehensive metabolic panels were within normal limits.

Due to concern for retained foreign body (FB), pelvic radiograph was obtained. This demonstrated about 45 small, round, radiopaque beads within the urethra and bladder consistent with those brought in by the boy's father (Images 1 and 2). Post-void residual bladder scan revealed 69 milliliters of urine prior to patient reporting complete bladder emptying in the ED. Outpatient urologic surgery was arranged for the next day with prescription for prophylactic cephalexin. Our community urologist was unable to remove the magnetic bearings, and the patient was referred to pediatric urology at a tertiary location.

### DISCUSSION

Diagnosis of urethral FBs is challenging given patients' hesitance to report insertion of a FB. Delayed presentation and diagnosis increases complication rates.<sup>1</sup>

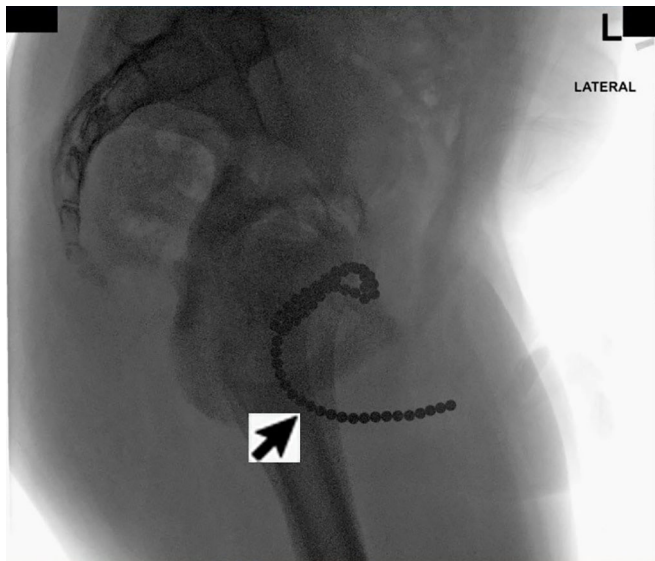
Polyembolokoilamania, or insertion of an object into a bodily orifice for sexual gratification, is the most common



**Image 1.** An anterior posterior plain film radiograph of the pelvis showing magnetic ball bearings in bladder and urethra.

cause of urethral FBs.<sup>2</sup> Other motivations for insertion include curiosity or as a voiding aide.<sup>3</sup>

Urethral FB presentation is similar to infection or stricture. Complications include chronic cystitis, hydronephrosis, secondary stone formation, and renal failure.<sup>1,4</sup> It is essential, especially in populations with low rates of voiding difficulty or infection, such as children and teenagers, to consider urethral FB.



**Image 2.** A lateral plain film radiograph of the pelvis demonstrating magnetic ball bearings in bladder and urethra.

Magnetic FBs are particularly concerning due to possible urethral or bladder wall compression resulting in ischemia.<sup>3</sup> Removal of these objects is difficult due to their magnetic adhesion. While neodymium magnetic toys were temporarily removed from the market, retail sales resumed in 2016 and they continue to pose a risk in the community.

Documented patient informed consent and/or Institutional Review Board approval has been obtained and filed for publication of this case report.

## REFERENCES

1. Hegde AV, Choubey S, Kanagali RS, et al. Listening to his inner voice? An unusual urethral foreign body: a review of literature and few learning points. *Asian J Urol.* 2018;5(2):131-2.
2. Naidu K, Chung A, Mulcahy M. An unusual urethral foreign body. *Int J Surg Case Rep.* 2013;4(11):1052-4.
3. Robey TE, Kaimakliotis HZ, Hittelma AB, et al. An unusual destination for magnetic foreign bodies. *Pediatr Emerg Care.* 2014;30(9):643-5.
4. Sharma D, Pandey S, Garg G, et al. Foreign body urethra misdiagnosed as stricture leading to inadequate management and

### *CPC-EM Capsule*

What do we already know about this clinical entity?

*The most common cause of urethral foreign body (FB) is polyembolokoilamania. This often leads to delayed presentation and failure to report insertion.*

What is the major impact of the image(s)?

*Magnet urethral FBs are particularly concerning due to possible serious complications. Neodymium beads were temporarily removed from the market but returned in 2016.*

How might this improve emergency medicine practice?

*It is important to consider urethral FB in populations with low risk of voiding difficulty. Early detection is essential as serious, life-long complications can occur.*

*Address for Correspondence:* Matthew Hysell, MD, Spectrum Health-Lakeland, Department of Emergency Medicine, 1234 Napier, St Joseph, MI 49085. Email: mhysell@lakelandhealth.org.

*Conflicts of Interest:* By the *CPC-EM* article submission agreement, all authors are required to disclose all affiliations, funding sources and financial or management relationships that could be perceived as potential sources of bias. The authors disclosed none.

*Copyright:* © 2019 Hysell et al. This is an open access article distributed in accordance with the terms of the Creative Commons Attribution ([CC BY 4.0](http://creativecommons.org/licenses/by/4.0/)) License. See: <http://creativecommons.org/licenses/by/4.0/>

prolonged treatment duration: a lesson to learn. *BMJ Case Rep.* 2018;2018.

5. Chung PH, Traylor J, Baker LA. Urethral foreign body: removal of degraded magnetic spheres using Hartmann ear forceps. *Urology.* 2014;84(5):1214-6.

# Munson's Sign: An Obvious Finding to Explain Acute Vision Loss

Jake Gold, MD\*  
Vijai Chauhan, MD\*  
Siripong Rojanasthien, MD†  
Jennifer Fitzgerald, BS\*

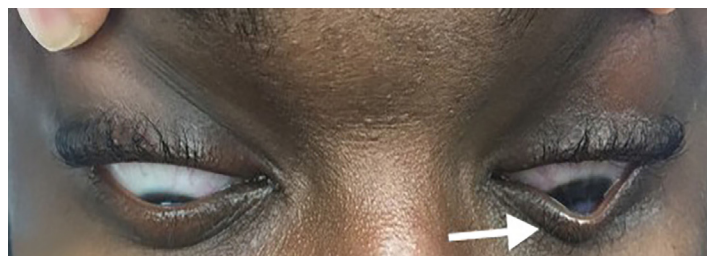\*Saint Louis University, Department of Emergency Medicine, St. Louis, Missouri  
†Saint Louis University Eye Institute, Department of Ophthalmology, St. Louis, Missouri

Section Editor: Rick A. McPheeters, DO and Shadi Lahham, MD, MS  
Submission history: Submitted February 19, 2019; Revision received February 27, 2019; Accepted May 20, 2019  
Electronically published July 8, 2019  
Full text available through open access at [http://escholarship.org/uc/uciem\\_cpccem](http://escholarship.org/uc/uciem_cpccem)  
DOI: 10.5811/cpcem.2019.5.42793

Keratoconus is a progressive disorder affecting the cornea, which causes the cornea to become weakened and conical in appearance. The resultant decrease in structural integrity of the cornea predisposes affected individuals to acute corneal hydrops, a break in Descemet's membrane, the deepest layer of the cornea, resulting in pain and acute vision loss. We present here a case of this little-known cause of acute vision loss, and an example of Munson's sign, which is a v-shaped protrusion of the lower eyelid on downward gaze that is characteristic of advanced keratoconus. We hope to highlight Munson's sign as a simple identifier of keratoconus in an otherwise undiagnosed individual suspected of having acute corneal hydrops. [Clin Pract Cases Emerg Med. 2019;3(3):312-313.]

## CASE PRESENTATION

A 28-year-old male with a history of keratoconus was transferred to our emergency department from an outside hospital for possible corneal ulcer. The patient suddenly lost vision in his left eye the night prior to presentation and had associated left eye pain and epiphora (watery eyes). The physical exam performed by ophthalmology noted opacification of the left cornea (Image 1) with a positive Munson's sign (Image 2), central corneal edema, and oculus sinister ("left eye") visual acuity decreased to hand motion at one foot. The remainder of the complete ophthalmologic exam revealed no additional abnormalities. The patient was diagnosed with acute corneal hydrops (ACH). He was given an eye shield without patching, started on cyclopentolate drops, erythromycin ointment, sodium chloride 5% drops,

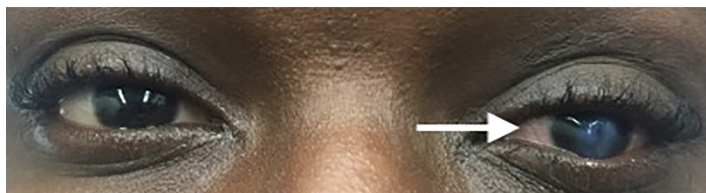

**Image 2.** Positive Munson's sign of patient's left eye. Note the V-shaped protrusion of the left lower eyelid as the patient gazes downward (arrow).

brimonidine drops, and instructed to avoid rubbing his eyes and to follow up with an ophthalmologist in one week.

## DISCUSSION

Keratoconus is a non-inflammatory disease characterized by progressive stromal thinning and cone-like bulging (ectasia) of the cornea leading to vision loss.<sup>1</sup> It is the most common corneal ectatic disorder (CED).<sup>1</sup> ACH, a complication of CEDs, is a break in Descemet's membrane and the endothelium, the deepest layers of the cornea, resulting in corneal edema and a sudden, painful decrease in visual acuity.<sup>2</sup> When



**Image 1.** Obvious opacification of patient's left cornea (arrow).

ACH is suspected but there is no history of CED, a positive Munson's sign can be used to make a diagnosis of keratoconus and subsequently ACH.<sup>3</sup> Munson's sign is pathognomonic for keratoconus.<sup>3</sup> However, providers should be aware that Munson's sign is typically seen in cases of advanced keratoconus, and its absence does not exclude CED or ACH.<sup>3</sup>

Documented patient informed consent and/or Institutional Review Board approval has been obtained and filed for publication of this case report.

---

*Address for Correspondence:* Jennifer Fitzgerald, BS, Saint Louis University, Department of Emergency Medicine, 3635 Vista Ave. Desloge Towers, 1st floor, St. Louis, MO 63110. Email: Jenn.fitzgerald@health.slu.edu.

*Conflicts of Interest:* By the CPC-EM article submission agreement, all authors are required to disclose all affiliations, funding sources and financial or management relationships that could be perceived as potential sources of bias. The authors disclosed none.

*Copyright:* © 2019 Gold et al. This is an open access article distributed in accordance with the terms of the Creative Commons Attribution (CC BY 4.0) License. See: <http://creativecommons.org/licenses/by/4.0/>

---

## REFERENCES

1. Gomes JA, Tan D, Rapuano CJ, et al. Global consensus on

*CPC-EM Capsule*

What do we already know about this clinical entity?  
*Acute corneal hydrops (ACH) is a complication of keratoconus and other corneal ectatic disorders. Munson's sign signifies advanced keratoconus.*

What is the major impact of the image(s)?  
*The images presented demonstrate a couple of the simple ophthalmologic exam findings, particularly Munson's sign, that can help emergency physicians identify keratoconus and ACH.*

How might this improve emergency medicine practice?  
*When present, Munson's sign can help easily identify an individual with keratoconus without an ophthalmology consult.<sup>3</sup>*

- keratoconus and ectatic diseases. *Cornea*. 2015;34(4):359-69.
2. Fan Gaskin JC, Patel DV, McGhee CN. Acute corneal hydrops in keratoconus – new perspectives. *Am J Ophthalmol*. 2014;157(5):921-8.
3. Romero-Jiménez M, Santodomingo-Rubido J, Wolffsohn JS. Keratoconus: a review. *Cont Lens Anterior Eye*. 2010;33(4):157-66.

## An Unusual Case of Stridor: Severe Tracheal Narrowing Secondary to Esophageal Food Impaction

Ryan McCreery, DO\*†  
Matthew Meigh, DO\*†

\*Orange Regional Medical Center, Department of Emergency Medicine, Middletown, New York  
†New York Colleges Osteopathic Medicine Educational Consortium, Department of Emergency Medicine, Middletown, New York

Section Editor: Rick A. McPheeters, DO

Submission history: Submitted March 9, 2019; Revision received May 29, 2019; Accepted May 29, 2019

Electronically published July 22, 2019

Full text available through open access at [http://escholarship.org/uc/uciem\\_cpccem](http://escholarship.org/uc/uciem_cpccem)

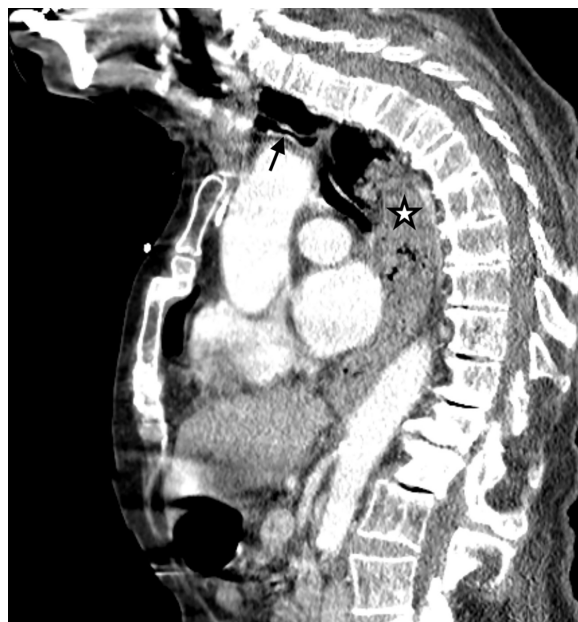DOI: 10.5811/cpcem.2019.5.43027

Foreign body impaction (FBI) in the esophagus has the potential to be a serious condition with a high mortality rate. Although the majority of foreign bodies trapped within the esophagus pass spontaneously, some do require endoscopic intervention. This case discusses a 95-year-old-female with a history of cerebral vascular accident who presented with acute onset respiratory distress with inspiratory stridor. The patient denied any episodes of choking or foreign body sensation. Further imaging revealed a large food bolus within the esophagus with extensive tracheal narrowing. The patient was diagnosed promptly and successfully managed endoscopically. This case presentation emphasizes the need to maintain a high index of clinical suspicion for FBI in high-risk populations, especially when the patient's history makes it unlikely. In the setting of respiratory complications, airway protection remains a priority, but an accurate diagnosis with timely intervention is paramount. [Clin Pract Cases Emerg Med. 2019;3(3):314-315.]

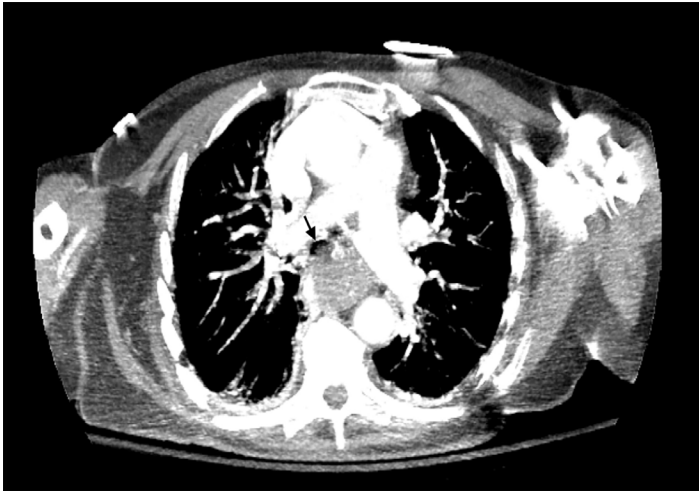### CASE PRESENTATION

A 95-year-old female with history of cerebral vascular accident presented to our emergency department for acute onset respiratory distress with inspiratory stridor. Vital signs revealed the patient to be hypertensive, tachycardic and tachypneic with intermittent episodes of mild hypoxia. On physical exam, she was unable to phonate with audible stridor but without drooling or trismus. Lung sounds were clear to auscultation bilaterally. She denied any choking or foreign body sensation. Radiography of the soft tissue of the neck and chest were unremarkable. Bedside transnasal flexible laryngobronchoscopy was normal to the level of the cords.

Contrast-enhanced computed tomography (CT) chest revealed significant tracheal compromise from marked distention of the esophagus (Images 1 and 2). The patient was intubated and underwent an emergent therapeutic bronchoscopy and esophagogastroduodenoscopy (EGD). While bronchoscopy was unremarkable, EGD showed a large food bolus extending from the upper to lower esophageal sphincters. Food bolus removal resolved her respiratory symptoms, and subsequent esophagram showed marked esophageal dysmotility.



**Image 1.** Computed tomography (sagittal view) demonstrating luminal narrowing of the trachea (black arrow) with marked distention of the esophagus. Significant inspissated material noted throughout the distended esophagus (white star).



**Image 2.** Computed tomography (axial view) demonstrating near obliteration of the trachea at the level of the manubrium secondary to esophageal distention (black arrow).

## DISCUSSION

Esophageal foreign body impaction (FBI) can be a serious condition carrying high mortality when not properly diagnosed or if management is delayed. While 80-90% of FBIs spontaneously pass from the esophagus to the stomach, an estimated 10-20% require endoscopic intervention.<sup>1</sup> Life-threatening complications include airway compromise and esophageal wall perforation, which can lead to mediastinitis, fistula, abscess, empyema, or death.<sup>2</sup> In adults, stridor due to esophageal FBI is a rare complication that not only requires airway protection but an accurate diagnosis with timely intervention.<sup>3</sup>

Documented patient informed consent and/or Institutional Review Board approval has been obtained and filed for publication of this case report.

## REFERENCES

1. Heger P, Weber TF, Rehm J, et al. Cervical esophagotomy for foreign body extraction: case report and comprehensive review of the literature. *Ann Med Surg (Lond)*. 2016;7:87–91.
2. Loh KS, Tan LK, Smith JD, et al. Complications of foreign bodies in the esophagus. *Otolaryngol Head Neck Surg*. 2000;123(5):613-6.
3. Muthucumar M and Clarnette T. Oesophageal foreign body causing stridor in an infant: Is a rare forgotten cause. *J Pediatr Surg Case Rep*. 2014;2(6):284-6.

### *CPC-EM Capsule*

What do we already know about this clinical entity?

*In the setting of respiratory compromise, an accurate diagnosis of esophageal foreign body impaction with timely intervention is paramount to reduce mortality.*

What is the major impact of the image(s)?

*These images clearly depict severe tracheal narrowing from esophageal food impaction and help raise awareness for this particular process.*

How might this improve emergency medicine practice?

*Consider esophageal food impaction in the differential diagnosis for stridor in the awake, adult patient without localizing signs or symptoms of dysphagia.*

*Address for Correspondence:* Ryan McCreery, DO, Orange Regional Medical Center, Department of Emergency Medicine, 707 East Main Street, Middletown, NY 10940. Email: [rmccreery@ghvhs.org](mailto:rmccreery@ghvhs.org).

*Conflicts of Interest:* By the *CPC-EM* article submission agreement, all authors are required to disclose all affiliations, funding sources and financial or management relationships that could be perceived as potential sources of bias. The authors disclosed none.

*Copyright:* © 2019 McCreery et al. This is an open access article distributed in accordance with the terms of the Creative Commons Attribution ([CC BY 4.0](http://creativecommons.org/licenses/by/4.0/)) License. See: <http://creativecommons.org/licenses/by/4.0/>

# Computed Tomography Imaging in Aortic Dissection

Amanda H. Westfall, MD  
John S. Garrett, MD

Baylor University Medical Center, Department of Emergency Medicine, Dallas, Texas

Section Editor: Steven Walsh, MD

Submission history: Submitted January 26, 2019; Revision received May 21, 2019; Accepted May 28, 2019

Electronically published July 22, 2019

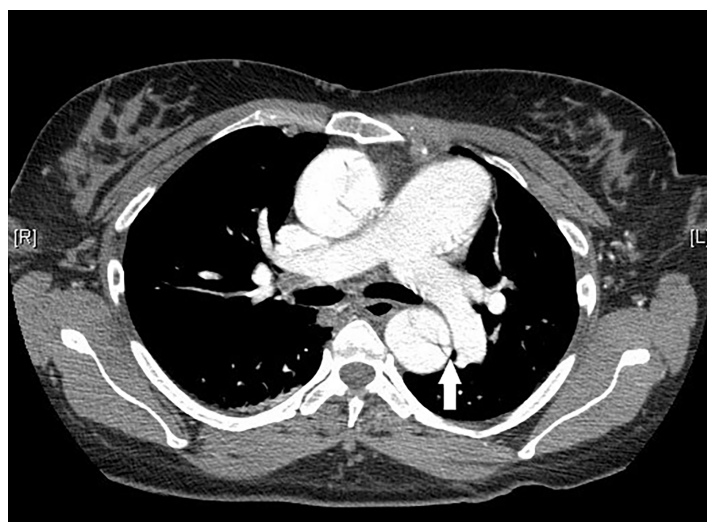
Full text available through open access at [http://escholarship.org/uc/uciem\\_cpccem](http://escholarship.org/uc/uciem_cpccem)

DOI: 10.5811/cpcem.2019.5.42531

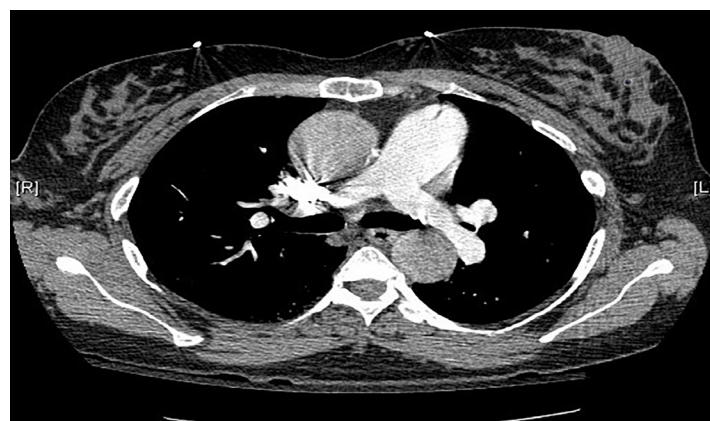Emergency physicians often rely on a “triple-rule-out” computed tomography (CT) where image acquisition is timed to obtain image quality equivalent to dedicated coronary CT angiography, pulmonary CT angiography, and thoracic aorta CT angiography. This case highlights the importance of obtaining CT angiography dedicated to the aorta in the setting of high clinical suspicion for aortic disease if initial CT pulmonary angiogram is negative for aortic disease. [Clin Pract Cases Emerg Med. 2019;3(3):316-317.]

## CASE PRESENTATION

A 39-year-old woman with twin gestation at 25 weeks presented to the emergency department with syncope. Her past medical history was significant for Marfan’s syndrome. Physical exam demonstrated confusion, hypotension, and a normal cardiopulmonary exam with equal pulses in all extremities. The patient denied chest pain. Differential diagnosis included aortic dissection and, given her pregnant state, pulmonary embolism. To minimize radiation exposure, a computed tomography (CT) pulmonary angiogram (PA) was obtained to evaluate for pulmonary embolism and aortic dissection (Image 1). Due to a negative CTPA and high suspicion for aortic disease, CT of the thoracic aorta was obtained (Image 2).



**Image 2.** Computed tomography thoracic aorta showing aortic dissection (arrow).

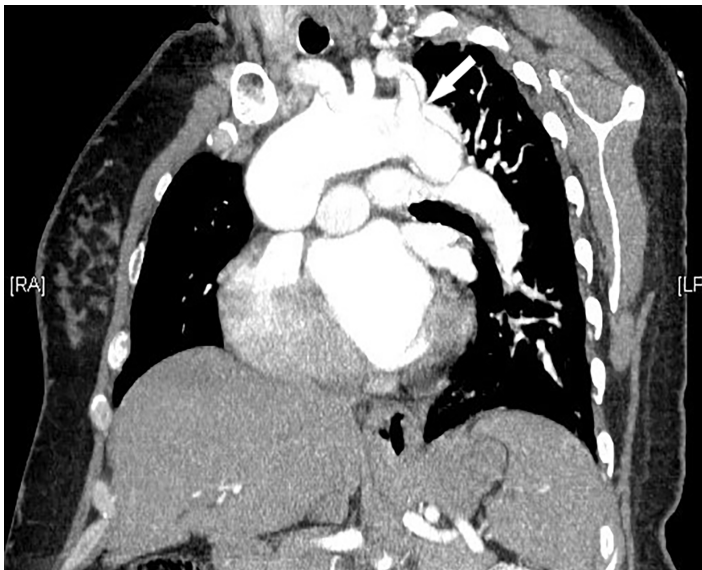


**Image 1.** Unremarkable computed tomography pulmonary angiogram.

## DISCUSSION

### Type A Aortic Dissection

CT of the thoracic aorta revealed a dissection from the aortic root to the abdominal aorta and involving the left common carotid (Image 3). The patient was sent to the operating room for fenestration of the thoracoabdominal aorta and subsequent replacement of the ascending aorta and hemiarch. Her twins were delivered by emergent cesarean section at 28 weeks gestation. Mother was discharged to a rehabilitation facility and then home.



**Image 3.** Computed tomography thoracic aorta showing aortic dissection involving left common carotid artery (arrow).

Thoracic CT imaging may evaluate for pulmonary embolism, aortic disease, and coronary artery disease. This can be accomplished through a “triple-rule-out” CT, where image acquisition is timed to obtain image quality equivalent to dedicated coronary, pulmonary and thoracic aorta CT angiography with high sensitivity and specificity.<sup>1</sup> Emergency physicians should be aware of the significant limitations related to the contrast bolus timing, especially if a CTPA is used to screen for aortic pathology. If intravenous contrast is not within the aorta at the time of image acquisition, false negative results can occur, making aortic dissection invisible.<sup>2</sup>

Documented patient informed consent and/or Institutional Review Board approval has been obtained and filed for publication of this case report.

## REFERENCES

1. McMahon MA and Squirrell CA. Multidetector CT of the aortic dissection: a pictorial review. *Radiographics*. 2010;30(2):445-60.

2. Dähnert W. (2003). Cardiovascular disorders: aortic dissection. In W. Dähnert (5<sup>th</sup> Eds.), *Radiology Review Manual* (607-9). Philadelphia, Pa: Lippincott Williams & Wilkins.

### *CPC-EM Capsule*

What do we already know about this clinical entity?

*Type A Aortic dissection is a life-threatening disease with high morbidity and mortality. It requires early diagnosis, most often accomplished via computed tomography (CT) imaging.*

What is the major impact of the image(s)?

*These comparison images demonstrate the importance of obtaining CT angiography dedicated to the aorta, even if initial CT pulmonary angiogram is negative for aortic disease.*

How might this improve emergency medicine practice?

*These comparison images demonstrate the importance of obtaining CT angiography dedicated to the aorta, even if initial CT pulmonary angiogram is negative for aortic disease.*

---

*Address for Correspondence:* Amanda H. Westfall, MD, Baylor University Medical Center, Department of Emergency Medicine, 3500 Gaston Avenue, Dallas, TX 75214. Email: amanda.westfall@bswhealth.org.

*Conflicts of Interest:* By the CPC-EM article submission agreement, all authors are required to disclose all affiliations, funding sources and financial or management relationships that could be perceived as potential sources of bias. The authors disclosed none.

*Copyright:* © 2019 Westfall et al. This is an open access article distributed in accordance with the terms of the Creative Commons Attribution (CC BY 4.0) License. See: <http://creativecommons.org/licenses/by/4.0/>

---

# Asteroid Hyalosis Seen on Ocular Point-of-Care Ultrasound

Blake Arthurs, BS\*<sup>o</sup>

Randi Connor-Schuler, MD<sup>†o</sup>

Wendelin Kreifels, MD<sup>†</sup>

Julian Suszanski, MD<sup>†</sup>

Sudhir Baliga, MD<sup>†</sup>

David Amponsah, MD<sup>†</sup>

\*Wayne State University School of Medicine, Detroit, Michigan

<sup>†</sup>Henry Ford Hospital, Department of Emergency Medicine, Detroit, Michigan

<sup>o</sup>Co-first authors

Section Editor: Anna McFarlin, MD

Submission history: Submitted March 2, 2019; Revision received June 14, 2019; Accepted June 11, 2019

Electronically published July 22, 2019

Full text available through open access at [http://escholarship.org/uc/uciem\\_cpem](http://escholarship.org/uc/uciem_cpem)

DOI: 10.5811/cpem.2019.6.42935

We present a case of a patient who underwent ultrasound evaluation for potential blunt ocular trauma. She was found to have multiple, freely mobile, scintillating hyperechoic opacities within the vitreous that was diagnosed as asteroid hyalosis, a rare but benign condition easily confused with vitreous hemorrhage, retinal detachment, lens dislocation, or foreign body on ocular ultrasound. [Clin Pract Cases Emerg Med. 2019;3(3):318-320.]

## CASE PRESENTATION

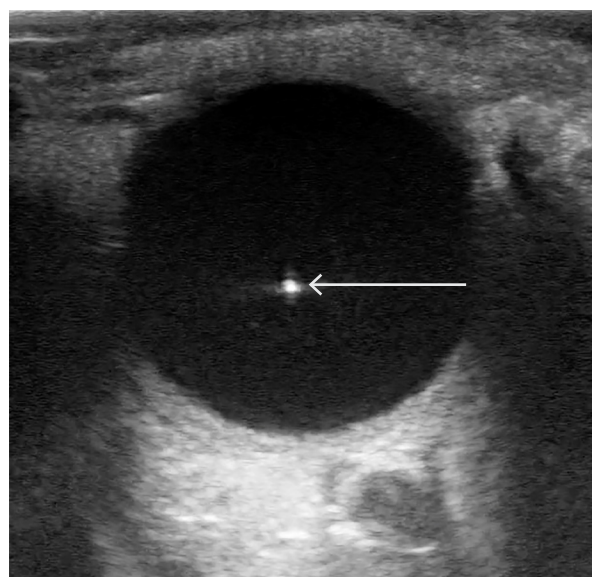
An 86-year-old woman with a history of hyperlipidemia presented to the emergency department after a fall. Exam was significant for altered mental status and signs of head trauma with left periorbital swelling and ecchymosis. Ocular ultrasound was performed using an ocular preset and with a Sonosite 10-MHz linear transducer to further assess for potential traumatic eye pathology. Ultrasound of the left eye was unremarkable, however the right eye demonstrated discrete, freely mobile, scintillating, hyperechoic opacities scattered throughout the vitreous (Images 1 and 2; Video).

## DIAGNOSIS

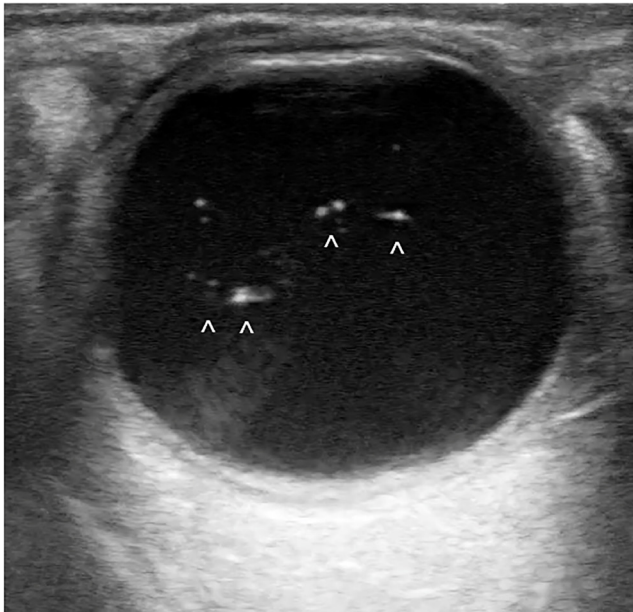
Asteroid hyalosis (AH) is a benign, degenerative condition of fatty calcium soap deposits in the vitreous that usually occurs unilaterally and typically occurs in men ages 75-86.<sup>1-4</sup> Previous research has shown that these spherical asteroid bodies are composed of calcium and phosphate complexed with lipids and are usually asymptomatic.<sup>1,5</sup> Asteroid bodies can be visualized by ophthalmoscope examination as well as B-mode ultrasonography, as this case demonstrates, with a shimmering, starry-night appearance to the vitreous. While rare, it is important to be aware of AH as it is a benign condition that can be confused with other ocular pathologies typically seen on ultrasound, including vitreous hemorrhage, foreign body, and retinal detachment.

AH can be most easily confused with vitreous hemorrhage.<sup>6,7</sup> While vitreous hemorrhage may have an echogenic appearance,

particularly when the gain is increased, it will also have a fluid, heterogenous appearance that ebbs and flows with eye movements and typically layers posterior in the eye. In contrast, AH will have discrete, scintillating particles of more



**Image 1.** B-mode sonogram showing an echogenic particle (arrow) floating within the body of the vitreous in a patient with asteroid hyalosis.



**Image 2.** B-mode sonogram demonstrating several discrete, free-floating, echogenic particles (^) consistent with asteroid hyalosis.

variable echogenicity scattered throughout the vitreous.<sup>7</sup> It is important to differentiate the two conditions in the point-of-care setting as vitreous hemorrhage is often an acute pathology while AH is a benign condition that does not require urgent ophthalmology consultation or evaluation.

#### KEY ISSUES

- Point-of-care ocular ultrasound is performed using a high-frequency linear probe.
- Point-of-care ultrasound can be used to diagnose ocular disorders such as lens dislocation, foreign body, retinal detachment, and vitreous hemorrhage.
- AH can be confused with vitreous hemorrhage as both involve echogenic debris floating in the vitreous.
- Vitreous hemorrhage has an “oil in water” appearance with more fluid echogenic material that will ebb and flow with ocular movements, in contrast to AH, which involves individual echogenic particles that will undergo small movements in the vitreous with ocular movement.
- It is important to differentiate between vitreous hemorrhage and AH given the clinical implications. While vitreous hemorrhage is pathologic and requires ophthalmology consultation, AH is a benign condition that does not require ophthalmologic evaluation.

#### *CPC-EM Capsule*

What do we already know about this clinical entity?

*Asteroid hyalosis (AH) is a benign condition more familiar to ophthalmologists and less well known to emergency physicians.*

What is the major impact of the image(s)?

*These images highlight the appearance of AH on ultrasound with scintillating echogenic particles seen within the vitreous body vs alternative diagnoses such as vitreous hemorrhage.*

How might this improve emergency medicine practice?

*With the increasing use of point-of-care ultrasound, it is important to distinguish normal, benign conditions from pathology that requires specialist intervention.*

**Video.** B-mode ultrasound clip showing multiple scintillating hyperechoic foci consistent with a diagnosis of asteroid hyalosis.

Documented patient informed consent and/or Institutional Review Board approval has been obtained and filed for publication of this case report.

*Address for Correspondence:* Randi Connor-Schuler, MD, Emory University, Department of Emergency Medicine, 615 Michael Street, NE Suite 205, Atlanta, GA 30322. Email: randi.schuler@gmail.com

*Conflicts of Interest:* By the CPC-EM article submission agreement, all authors are required to disclose all affiliations, funding sources and financial or management relationships that could be perceived as potential sources of bias. The authors disclosed none.

*Copyright:* © 2019 Arthurs et al. This is an open access article distributed in accordance with the terms of the Creative Commons Attribution (CC BY 4.0) License. See: <http://creativecommons.org/licenses/by/4.0/>

**REFERENCES**

1. Tripathy K. Asteroid hyalosis. *N Engl J Med*. 2018;379(8):e12.
2. Kim JH, Roh MI, Byeon SH, et al. Prevalence of and risk factors for asteroid hyalosis in Seoul, Korea. *Retina*. 2008;28(10):1515-21.
3. Fawzi AA, Vo B, Kriwanek R, et al. Asteroid hyalosis in an autopsy population: the University of California at Los Angeles (UCLA) experience. *Arch Ophthalmol*. 2005;123(4):486-90.
4. Moss SE, Klein R, Klein BE. Asteroid hyalosis in a population: the Beaver Dam eye study. *Am J Ophthalmol*. 2001;132(1):70-5.
5. Khoshnevis M, Rosen S, Sebag J. Asteroid hyalosis: a comprehensive review. *Surv Ophthalmol*. 2019. pii:S0039-6257(18)30205-4.
6. Stringer CEA, Ahn JS, Kim DJ. Asteroid hyalosis: a mimic of vitreous hemorrhage on point of care ultrasound. *CJEM*. 2017;19(4):317-20.
7. Lema PC, Mantuani D, Nagdex A, et al. Asteroid hyalosis masquerading as vitreous hemorrhage on point-of-care sonography. *J Ultrasound Med*. 2018;37(1):281-4.

# X<sup>th</sup> MEDITERRANEAN EMERGENCY MEDICINE CONGRESS



**JOIN US!**  
**REGISTER TODAY**

MEMC19 embraces a true multinational collaboration of teaching and learning, based on the belief that every emergency care practitioner has knowledge and experience that will benefit all of us.

Our focus is to move away from a uni-centric practice model towards a model of best practices that embraces genuine cultural competency, diversity, and respect for the variety of resource availability that characterizes the true practice of emergency medicine on a global scale.

You may count on a diverse and stimulating curriculum which will prove to be impactful to both new and seasoned physicians, residents and medical students; as well as nurses, researchers and scientists, pharmacists, nutritionists, and anyone involved in the delivery of emergency care.

We invite you to explore all that this historic city, located on the Adriatic Sea, and its surrounding areas have to offer.

**Abstract Submissions  
Now Open!**

**Visit the website to learn more.**

**MEMC19**

[www.aaem.org/MEMC19](http://www.aaem.org/MEMC19)  
#MEMC19

**Dubrovnik CROATIA**

**22-25 SEPTEMBER 2019**

**JOIN  
CAL/AAEM!**



**CALAAEM**

CALIFORNIA CHAPTER DIVISION OF THE  
AMERICAN ACADEMY OF EMERGENCY MEDICINE

*Championing  
individual physician rights  
and workplace fairness*

## **BENEFITS**

- *Western Journal of Emergency Medicine* Subscription
- CAL/AAEM News Service email updates
- Discounted AAEM pre-conference fees
- And more!

## **CAL/AAEM NEWS SERVICE**

- Healthcare industry news
- Public policy
- Government issues
- Legal cases and court decisions

In collaboration with our official journal

**WestJEM** Integrating Emergency Care  
with Population Health



[FACEBOOK.COM/CALAAEM](https://www.facebook.com/CALAAEM)



FOLLOW US @CALAAEM

[HTTP://WWW.CALAAEM.ORG](http://www.calaaem.org)



# ADVANCED >

## YOUR LIFE IN EMERGENCY MEDICINE

### > CALIFORNIA ACEP'S ANNUAL CONFERENCE 2019

Education is targeted to Medical Students and Residents, but all are welcome to attend.

**Friday, September 20, 2019**

Hyatt Regency, Orange County, CA



**CALIFORNIA ACEP**  
AMERICAN COLLEGE OF EMERGENCY PHYSICIANS