

CPC Emergency Medicine

Volume IV, Number 1, February 2020

Open Access at www.cpcem.org

ISSN: 2474-252X

Clinical Practice and Cases in Emergency Medicine

In Collaboration with the *Western Journal of Emergency Medicine*

Clinicopathological Cases

- 1 **Fitting a Square Peg in a Round Hole: A Simple Case of Chest Pain**
McLean ME, Beck-Esmay J

Astonishing Cases and Images in Emergency Medicine

- 8 **Removal of an Impaled Intraocular Hair Comb Following Self-inflicted Trauma**
Markovitz M, Hamburger J, Fromm BS, Carr B, Zhang XC

Medical Legal Case Reports

- 12 **Beware of Reversal of an Anticoagulated Patient With Factor IX in the Emergency Department: Case Report of a Medical-Legal Misadventure**
Gannon S, Bell D, Jackmiczyk K, Moore G

Case Series

- 16 **Administration of Nebulized Ketamine for Managing Acute Pain in the Emergency Department: A Case Series**
Drapkin J, Masoudi A, Butt M, Hossain R, Likourezos A, Motov S
- 21 **Serratus Anterior Plane Block in the Emergency Department: A Case Series**
Lin J, Hoffman T, Badashova K, Motov S, Haines L

Case Reports

- 26 **Euglycemic Diabetic Ketoacidosis in Pregnancy**
Garcia de Alencar JCG, Weibelling da Silva G, Correa da Costa Ribeiro S, Marchini JFM, Brandao Neto RA, Possolo de Souza H
- 29 **Point-of-care Ultrasound Diagnosis of Bilateral Patellar Tendon Rupture**
Ogle K, Mandoorah S, Fellin M, Shokoohi H, Probasco W, Boniface K
- 32 **Pediatric Herpes Zoster**
Quesada D, Morsky L, Aguiñiga-Navarrete P, Garrett MB
- 35 **Endometriosis: An Unusual Cause of Bilateral Pneumothoraces**
Sampson CS, White K

Contents continued on page iii



UC Irvine Health



A Peer-Reviewed, International Professional Journal



— ACOEP's 2020 —
SPRING SEMINAR



SAVE THE DATE

APRIL 14-17, 2020

**WESTIN KIERLAND RESORT & SPA
SCOTTSDALE, AZ**



Clinical Practice and Cases in Emergency Medicine

Indexed in PubMed and full text in PubMed Central

Rick A. McPheeters, DO, Editor-in-Chief
Kern Medical/UCLA- Bakersfield, California

Manish Amin, DO, Associate Editor
Kern Medical/UCLA- Bakersfield, California

Mark I. Langdorf, MD, MHPE, Associate Editor
University of California, Irvine School of Medicine- Irvine, California

Shadi Lahham, MD, MS, Associate Editor
University of California, Irvine School of Medicine- Irvine, California

Shahram Lotfipour, MD, MPH, Managing Associate Editor
University of California, Irvine School of Medicine- Irvine, California

Anna McFarlin, MD, Section Editor
Louisiana State University Health Science Center- New Orleans, Louisiana

Austin Smith, MD, Section Editor
Vanderbilt University Medical Center-Nashville, Tennessee

Christopher Sampson, MD, Section Editor
University of Missouri- Columbia, Missouri

Joel Moll, MD, Section Editor
Virginia Commonwealth University School of Medicine- Richmond, Virginia

Scott Goldstein, DO, Section Editor
Sidney Kimmel College of Medicine- Philadelphia, Pennsylvania

Steven Walsh, MD, Section Editor
Einstein Medical Center Philadelphia-Philadelphia, Pennsylvania

John Ashurst, DO, Section Editor
Kingman Regional Health Network, Arizona

Melanie Heniff, MD, Section Editor
University of Indiana School of Medicine- Indianapolis, Indiana

Editorial Board

Amin A. Kazzi, MD, MAAEM
The American University of Beirut, Beirut,
Lebanon

Anwar Al-Awadhi, MD
Mubarak Al-Kabeer Hospital, Jabriya,
Kuwait

Arif A. Cevik, MD
United Arab Emirates University
College of Medicine and Health Sciences, Al
Ain, United Arab Emirates

Abhinandan A. Desai, MD
University of Bombay Grant Medical
College, Bombay, India

Bandr Mzahim, MD
King Fahad Medical City, Riyadh, Saudi
Arabia

Barry E. Brenner, MD, MPH
Case Western Reserve University

Brent King, MD, MMM
University of Texas, Houston

Daniel J. Dire, MD
University of Texas Health Sciences Center
San Antonio

David F.M. Brown, MD
Massachusetts General Hospital/Harvard
Medical School

Edward Michelson, MD
Texas Tech University

Edward Panacek, MD, MPH
University of South Alabama

Erik D. Barton, MD, MBA
Icahn School of Medicine, Mount Sinai,
New York

Francesco Dellacorte, MD
Azienda Ospedaliera Universitaria "Maggiore
della Carità," Novara, Italy

Francis Counselman, MD
Eastern Virginia Medical School

Gayle Galletta, MD
Sorlandet Sykehus HF, Akershus
Universitetssykehus, Lorenskog, Norway

Hjalte Björnsson, MD
Icelandic Society of Emergency Medicine

Jacob (Kobi) Peleg, PhD, MPH
Tel-Aviv University, Tel-Aviv, Israel

Jonathan Olshaker, MD
Boston University

Katsuhiko Kanemaru, MD
University of Miyazaki Hospital, Miyazaki, Japan

Khrongwong Musikatavorn, MD
King Chulalongkorn Memorial Hospital,
Chulalongkorn University, Bangkok, Thailand

Leslie Zun, MD, MBA
Chicago Medical School

Linda S. Murphy, MLIS
University of California, Irvine School of
Medicine Librarian

Nadeem Qureshi, MD
St. Louis University, USA
Emirates Society of Emergency Medicine,
United Arab Emirates

Niels K. Rathlev, MD
Tufts University School of Medicine

Pablo Aguilera Fuenzalida, MD
Pontificia Universidad Católica de Chile,
Región Metropolitana, Chile

Peter A. Bell, DO, MBA
Liberty University
College of Osteopathic Medicine

Peter Sokolove, MD
University of California, San Francisco

Robert M. Rodriguez, MD
University of California, San Francisco

Robert Suter, DO, MHA
UT Southwestern Medical Center

Robert W. Derlet, MD
University of California, Davis

Rosidah Ibrahim, MD
Hospital Serdang, Selangor, Malaysia

Samuel J. Stratton, MD, MPH
Orange County, CA, EMS Agency

Scott Rudkin, MD, MBA
University of California, Irvine

Scott Zeller, MD
University of California, Riverside

Steven Gabaeff, MD
Clinical Forensic Medicine

Steven H. Lim, MD
Changi General Hospital, Simei, Singapore

Terry Mulligan, DO, MPH, FIFEM
ACEP Ambassador to the Netherlands Society of
Emergency Physicians

Vijay Gautam, MBBS
University of London, London, England

Wirachin Hoonpongmanont, MD, MSBATS
Siriraj Hospital, Mahidol University, Bangkok,
Thailand

Advisory Board

Amal Khalil, MBA
UC Irvine Health School of Medicine

Elena Lopez-Gusman, JD
California ACEP
American College of Emergency Physicians

Adam Levy, BS
American College of Osteopathic Emergency
Physicians

John B. Christensen, MD
California Chapter Division of AAEM

Lori Winston, MD
California ACEP
American College of Emergency Physicians
Kaweah Delta Healthcare District

Mark I. Langdorf, MD, MHPE
UC Irvine Health School of Medicine

Jorge Fernandez, MD
California ACEP
American College of Emergency Physicians
University of California, San Diego

Peter A. Bell, DO, MBA
American College of Osteopathic Emergency
Physicians
Liberty University, College of Osteopathic Medicine

Robert Suter, DO, MHA
American College of Osteopathic Emergency
Physicians
UT Southwestern Medical Center

Shahram Lotfipour, MD, MPH
UC Irvine Health School of Medicine

Brian Potts, MD, MBA
California Chapter Division of AAEM
Alta Bates Summit-Berkeley Campus

Editorial Staff

Leila Danishgar, BS
Editorial Director

Joseph Bui, BS
CPC-EM Associate Editorial Director

Maria Nguyen, BS
WestJEM Associate Editorial Director

Tushank Chadha, BS
Marketing Director to Media and
Communications Director

Alissa Fiorentino, BA
WestJEM Staff Liaison

Cassandra Saucedo, BS
CPC-EM Publishing Director

Argineh Shahbandari, BS
CPC-EM Associate Publishing Director

Dana Le, BS
WestJEM Publishing Director

Christine Louis, BS
WestJEM Associate Publishing Director

June Casey, BA
Copy Editor

Official Journal of the California Chapter of the American College of Emergency Physicians, the American College of Osteopathic Emergency Physicians, and the California Chapter of the American Academy of Emergency Medicine



Available in MEDLINE, PubMed, PubMed Central, Google Scholar, eScholarship, DOAJ, and OASPA.

Editorial and Publishing Office: WestJEM/Department of Emergency Medicine, UC Irvine Health, 333 City Blvd, West, Rt 128-01, Orange, CA 92866, USA

Office: 1-714-456-6389; Email: Editor@westjem.org

Clinical Practice and Cases in Emergency Medicine

Indexed in PubMed and full text in PubMed Central

This open access publication would not be possible without the generous and continual financial support of our society sponsors, department and chapter subscribers.

Professional Society Sponsors

AMERICAN COLLEGE OF OSTEOPATHIC EMERGENCY PHYSICIANS
CALIFORNIA ACEP

CALIFORNIA CHAPTER DIVISION OF
AMERICAN ACADEMY OF EMERGENCY MEDICINE

Academic Department of Emergency Medicine Subscribers

Albany Medical College Albany, NY	INTEGRIS Health Oklahoma City, OK	Robert Wood Johnson University Hospital New Brunswick, NJ	University of Florida, Jacksonville Jacksonville, FL
American University of Beirut Beirut, Lebanon	Kaweah Delta Health Care District Visalia, CA	Rush University Medical Center Chicago, IL	University of Illinois at Chicago Chicago, IL
Arrowhead Regional Medical Center Colton, CA	Kennedy University Hospitals Turnersville, NJ	Southern Illinois University Carbondale, IL	University of Illinois College of Medicine Peoria, IL
Augusta University Augusta GA	Kern Medical Bakersfield, CA	St. Luke's University Health Network Bethlehem, PA	University of Iowa Iowa City, IA
Baystate Medical Center Springfield, MA	Lakeland HealthCare St. Joseph, MI	Stanford/Kaiser Emergency Medicine Residency Program Stanford, CA	University of Louisville Louisville, KY
Beaumont Hospital Royal Oak, MI	Lehigh Valley Hospital and Health Network Allentown, PA	Staten Island University Hospital Staten Island, NY	University of Maryland Baltimore, MD
Beth Israel Deaconess Medical Center Boston, MA	Loma Linda University Medical Center Loma Linda, CA	SUNY Upstate Medical University Syracuse, NY	University of Michigan Ann Arbor, MI
Boston Medical Center Boston, MA	Louisiana State University Health Sciences Center New Orleans, LA	Temple University Philadelphia, PA	University of Missouri, Columbia Columbia, MO
Brigham and Women's Hospital Boston, MA	Madigan Army Medical Center Tacoma, WA	Texas Tech University Health Sciences Center El Paso, TX	University of Nebraska Medical Center Omaha, NE
Brown University Providence, RI	Maimonides Medical Center Brooklyn, NY	University of Alabama, Birmingham Birmingham, AL	University of South Alabama Mobile, AL
Carl R. Darnall Army Medical Center Fort Hood, TX	Maricopa Medical Center Phoenix, AZ	University of Arkansas for Medical Sciences Little Rock, AR	University of Southern California/Keck School of Medicine Los Angeles, CA
Conemaugh Memorial Medical Center Johnstown, PA	Massachusetts General Hospital Boston, MA	University of California, Davis Medical Center Sacramento, CA	University of Tennessee, Memphis Memphis, TN
Desert Regional Medical Center Palm Springs, CA	Mayo Clinic College of Medicine Rochester, MN	University of California Irvine Orange, CA	University of Texas, Houston Houston, TX
Doctors Hospital/Ohio Health Columbus, OH	Mt. Sinai Medical Center Miami Beach, FL	University of California, Los Angeles Los Angeles, CA	University of Texas Health San Antonio, TX
Eastern Virginia Medical School Norfolk, VA	North Shore University Hospital Manhasset, NY	University of California, San Diego La Jolla, CA	University of Warwick Library Coventry, United Kingdom
Einstein Healthcare Network Philadelphia, PA	Northwestern Medical Group Chicago, IL	University of California, San Francisco San Francisco, CA	University of Washington Seattle, WA
Emory University Atlanta, GA	Ohio State University Medical Center Columbus, OH	UCSF Fresno Center Fresno, CA	University of Wisconsin Hospitals and Clinics Madison, WI
Genesys Regional Medical Center Grand Blanc, Michigan	Ohio Valley Medical Center Wheeling, WV	University of Chicago, Chicago, IL	Wake Forest University Winston-Salem, NC
Hartford Hospital Hartford, CT	Oregon Health and Science University Portland, OR	University of Colorado, Denver Denver, CO	Wright State University Dayton, OH
Hennepin County Medical Center Minneapolis, MN	Penn State Milton S. Hershey Medical Center Hershey, PA	University of Florida Gainesville, FL	
Henry Ford Hospital Detroit, MI	Presence Resurrection Medical Center Chicago, IL		

State Chapter Subscribers

ARIZONA CHAPTER DIVISION OF THE
AMERICAN ACADEMY OF EMERGENCY MEDICINE
CALIFORNIA CHAPTER DIVISION OF THE
AMERICAN ACADEMY OF EMERGENCY MEDICINE
FLORIDA CHAPTER DIVISION OF THE
AMERICAN ACADEMY OF EMERGENCY MEDICINE

GREAT LAKES CHAPTER DIVISION OF THE
AMERICAN ACADEMY OF EMERGENCY MEDICINE
TENNESSEE CHAPTER DIVISION OF THE
AMERICAN ACADEMY OF EMERGENCY MEDICINE

UNIFORMED SERVICES CHAPTER DIVISION OF THE
AMERICAN ACADEMY OF EMERGENCY MEDICINE
VIRGINIA CHAPTER DIVISION OF THE
AMERICAN ACADEMY OF EMERGENCY MEDICINE

International Society Partners

EMERGENCY MEDICINE ASSOCIATION OF TURKEY
LEBANESE ACADEMY OF EMERGENCY MEDICINE
MEDITERRANEAN ACADEMY OF EMERGENCY MEDICINE

NORWEGIAN SOCIETY FOR EMERGENCY MEDICINE
SOCIEDAD ARGENTINA DE EMERGENCIAS

SOCIEDAD CHILENO MEDICINA URGENCIA
THAI ASSOCIATION FOR EMERGENCY MEDICINE

To become a *WestJEM* departmental sponsor, waive article processing fee, receive print and copies for all faculty and electronic for faculty/residents, and free CME and faculty/fellow position advertisement space, please go to <http://westjem.com/subscribe> or contact:

Alissa Fiorentino
WestJEM Staff Liaison
Phone: 1-800-884-2236
Email: sales@westjem.org

JOURNAL FOCUS

Clinical Practice and Cases in Emergency Medicine (CPC-EM) is a MEDLINE-indexed internationally recognized journal affiliated with the *Western Journal of Emergency Medicine* (WestJEM). It offers the latest in patient care case reports, images in the field of emergency medicine and state of the art clinicopathological and medicolegal cases. CPC-EM is fully open-access, peer reviewed, well indexed and available anywhere with an internet connection. CPC-EM encourages submissions from junior authors, established faculty, and residents of established and developing emergency medicine programs throughout the world.

Table of Contents *continued*

- 38 **Bilateral Luxatio Erecta Humeri With Acute Anterior-inferior Re-dislocation**
A Kessler, J Hinkley, Houserman D, Lytle J, Sorscher M
- 42 **Carbon Monoxide Poisoning Effectively Treated with High-flow Nasal Cannula Oxygen**
P Lee, SD Salhanick
- 46 **Neurosyphilis: Old Disease, New Implications for Emergency Physicians**
L Mercurio, LE Taylor, AF Jarman
- 51 **An Unusual Case of Carbon Monoxide Poisoning from Formic and Sulfuric Acid Mixture**
M Ershad, A Meliosiotis, Z Gaskill, M Kelly, R Hamilton
- 55 **Pericardial Tamponade After Systemic Alteplase in Stroke and Emergent Reversal With Tranexamic Acid**
C Romero, S Shartar, MJ Carr
- 59 **Paraspinal Abscess in a Two-year-old Female**
R O'Donnell, S Sayani, P Aguiñiga-Navarrete, D Quesada, K Barkataki, MB Garrett
- 62 **Bisphosphonate-related Femoral Shaft Fracture**
J Kellar, A Givertz, J Mathias, J Cohen
- 65 **Cesarean Scar Ectopic Pregnancy: Diagnosis With Ultrasound**
T Hoffman, J Lin
- 69 **Epstein-Barr Virus-induced Jaundice**
J Herold, F Grimaldo
- 72 **Break up the band: Laparoscopic Adjustable Gastric Banding-associated Discitis and Osteomyelitis**
S Meester, C Hogrefe
- 75 **Stroke Mimic: A Case of Unilateral Thyrotoxic Hypokalemic Periodic Paralysis**
M Lajeunesse, S Young
- 79 **Point-of-care Ultrasound Diagnosis of Acute Abdominal Aortic Occlusion**
B Bloom, R Gibbons, D Brandis, TG Costantino
- Images in Emergency Medicine**
- 83 **Disseminated Gonorrhoea**
J Estrada, S Sergent, J Ashurst
- 85 **Acute Finger Ischemia in an Elderly Male without Risk Factors for Hypercoagulability**
M Amin, A Torres, P Aguiñiga-Navarrete, D Quesada, JP Jerome, A Jones

Policies for peer review, author instructions, conflicts of interest and human and animal subjects protections can be found online at www.cpcem.org.

Table of Contents *continued*

- 88 **A Full Uterus: Hematometra from Cervical Scarring**
CS Sampson, KA Arnold
- 90 **A Hidden Complication of Pigtail Catheter Insertion**
JC Garcia de Alencar, MG Pinheiro Costa, RA Brandao Neto, H Possolo de Souza
- 92 **Hydronephrosis Due to Bilateral Tubo-ovarian Abscess**
E Fite, J Fitzgerald, Q Kistenfeger
- 94 **Renal Infarct After Endovascular Abdominal Aortic Aneurysm Repair: Consider in Back Pain Differential**
SY Liu, A Hackett
- 96 **Endotracheal Metastasis Causing Airway Obstruction**
Y Yano, T Fujiwara, M Mizuta
- 99 **Diabetic Muscle Infarction**
S Ahmed, R Fairley
- 101 **Idiopathic Bilateral Internal Jugular Vein Thrombosis Diagnosed by Point-of-Care Ultrasound**
VM Aquino-Jose, J Johnson, T Dulani
- 103 **Pseudo-duplication of the Gallbladder**
J Adamski, D Mohan, C Waasdorp
- 105 **New Reduction Technique for Traumatic Posterior Glenohumeral Joint Dislocations**
M Khodae
- 107 **Point-of-care Ultrasound Diagnosis of Emphysematous Cholecystitis**
DF Al Hammadi, R Buhmaid
- 109 **Pseudoatrial Flutter: When the Problem Lies Outside the Heart**
S Ceruti, M Spagnoletti, R Mauri

Clinical Practice and Cases in Emergency Medicine (CPC-EM) is a open-access Medline-indexed internationally recognized journal affiliated with the *Western Journal of Emergency Medicine* (WestJEM). CPC-EM is distributed electronically to 19,000 emergency medicine scholars. This includes our sponsors California ACEP, the American College of Osteopathic Emergency Physicians, California Chapter of AAEM, and over 83 academic department of emergency medicine subscribers and 8 AAEM State Chapters.

CPC**EM** Clinical Practice & Cases

CALL FOR SUBMISSIONS

- Patient Care Case Reports
- Images in Emergency Medicine

Fully open-access, peer reviewed,
well indexed: CPC-EM is available
anywhere with an internet
connection at **CPCEM.org**

***Clinical
Practice and
Cases in
Emergency
Medicine*** is an
internationally
recognized
journal
affiliated with
the MEDLINE-
indexed
***Western
Journal of
Emergency
Medicine***

**CPC-EM encourages submissions from junior authors and
countries with developing emergency medicine programs**

CPC**EM** Clinical Practice & Cases

CALL FOR CPC-EM SECTION EDITORS!

- Medical-Legal Case Reports
- Case Reports/Images in
Emergency Medicine

**Send your CV and letter of interest to
editor@cpcem.org**

WestJEM Integrating Emergency Care
with Population Health

CPCEM Clinical
Practice
& Cases

Call for Reviewers!

Please send your CV and letter of interest to
editor@westjem.org

CALL FOR SUBMISSIONS

Team Based Learning ▪ Podcasts ▪ Lectures ▪
Small Group Learning and Workshops ▪ Oral
Boards ▪ Simulation ▪ Curricula ▪ Innovations

CALL FOR REVIEWERS

JETem is an online,
open access, peer-
reviewed journal-
repository for EM
educators.

VISIT JETem.org
to learn more about
submissions or if
you're interested
in being a JETem
reviewer.



Journal of Education & Teaching in Emergency Medicine

A Journal of CORD

Fitting a Square Peg in a Round Hole: A Simple Case of Chest Pain

Mary E. McLean, MD*
Jennifer Beck-Esmay, MD†

*St. John's Riverside Hospital, Department of Emergency Medicine, Yonkers, New York
†Mount Sinai St. Luke's-Mt Sinai West, Department of Emergency Medicine, New York, New York

Section Editor: Rick A. McPheeters, DO and Joel Moll, MD

Submission history: Submitted June 15, 2019; Revision received September 13, 2019; Accepted October 2, 2019

Electronically published January 6, 2020

Full text available through open access at http://escholarship.org/uc/uciem_cpccm

DOI: 10.5811/cpcem.2019.10.44141

A 39-year-old female presents to the emergency department with chest pain and shortness of breath. Her electrocardiogram suggests ST-elevation myocardial infarction, but she has no atherosclerotic risk factors. She is gravida 4, para 4, and four weeks postpartum from uncomplicated vaginal delivery. She is diaphoretic and anxious, but otherwise her exam is unremarkable. Cardiac enzymes are markedly elevated and point-of-care echocardiogram shows inferolateral hypokinesis and ejection fraction of 50%. In this clinicopathological case, we explore a classically underappreciated cause of acute coronary syndrome in healthy young women. [Clin Pract Cases Emerg Med. 2020;4(1):1–7.]

CASE PRESENTATION (Resident Presentation)

Paramedics place a call to the emergency department (ED). They are en route with lights and sirens! The patient is a 39-year-old female with 10/10 crushing left chest pain radiating to the left arm. Her field electrocardiogram (ECG) is suggestive of inferior ST-elevation myocardial infarction (STEMI). She receives full-dose aspirin and sublingual nitroglycerin in the ambulance with slight improvement in symptoms.

On arrival to the ED, the patient still has pain and associated diaphoresis, shortness of breath, cough, palpitations, headache, nausea, anxiety, and a feeling of impending doom. The ED ECG (Image 1) shows subtle ST elevations in II, III, and aVF, and a reciprocal T-wave inversion in aVL.

Peripheral intravenous access is obtained and the patient is placed on the cardiac monitor. Her systolic blood pressure is 128 millimeters of mercury (mmHg), diastolic blood pressure is 72 mmHg, heart rate is 88 beats per minute, respiratory rate is 20 breaths per minute, pulse oximetry is 98% on room air, and temperature is 36.8 degrees Celsius. Her body mass index is estimated at 25. She appears uncomfortable, diaphoretic, and anxious. There are no other abnormal cardiovascular, respiratory, abdominal, or neurologic findings on exam. There is no calf swelling, tenderness, or palpable cords. There are no sequelae of hyperlipidemia, diabetes mellitus, or other chronic illness. History is completed after critical stabilization actions.

The patient was resting at home when the symptoms began. She denies leg pain/swelling, hemoptysis, immobilization,

surgery, exogenous hormone use, orthopnea, paroxysmal nocturnal dyspnea, syncope, or lightheadedness.

She receives regular medical care, and has never been diagnosed with any chronic illness or had surgery. She denies family history of coronary artery disease, sudden unexplained death, blood clotting disorders, or other chronic diagnosis. She has never used tobacco, alcohol, or drugs. She lives at home with her loving husband and four children, and denies psychiatric illness.

In fact, the only notable findings on history are regarding reproductive history. She is gravida 4, para 4 (G4P4), and four weeks postpartum. Pregnancy and vaginal delivery were uncomplicated and she has been breastfeeding without issue. She has help from multiple supportive family members, and she does not feel stressed.

Point-of-care echocardiogram reveals inferolateral hypokinesis and left ventricular ejection fraction (EF) of 50%, but no pericardial effusion, valvular abnormalities, or right heart strain. The chest radiograph (CXR) shows nothing acute. The total creatine kinase is 1344 units per liter and troponin I is 2.42 nanograms per milliliter, but remaining labs are normal (Table 1).

CASE DISCUSSION (Attending Discussion)

I like to start thinking through any case with a little review. This patient was brought in by ambulance with chest pain, shortness of breath, and diaphoresis. Her vitals were

stable and she received nitroglycerin and aspirin, but ECG showed persistent inferior ST elevation and reciprocal changes. At this point, the case seems quite simple: the STEMI code should have been activated, and the patient should have had immediate coronary angiography. But that's not what happened for this patient. Instead, she had a CXR, echocardiogram, and lab work prior to diagnosis. Why didn't she get a speedy door-to-balloon time? Maybe because the patient is a woman? Studies have shown that women are less likely than men to undergo coronary angiography or revascularization and, specifically, they are less likely to receive timely revascularization.¹

Implicit gender bias may have played a role in this case and there are probably some very good reasons why. So let's step back and review the most significant details. This patient was a previously healthy 39-year-old female, whose chest pain presentation was complicated by the fact that she was G4P4 and just four weeks postpartum. Usually when a postpartum woman presents with chest pain or shortness of breath, there are two obvious diagnoses to consider: pulmonary embolism (PE) and postpartum cardiomyopathy.

PE is a leading cause of pregnancy-related death in the developed world.² The incidence of venous thromboembolism (VTE) is about 13 in 10,000 pregnancies, with half occurring before delivery and half in the postpartum period. The increased risk of VTE continues for 6-12 weeks postpartum. Whether a patient is recently pregnant or not, this diagnosis is always on my differential for chest pain and/or shortness of breath in a patient with lungs that are clear to auscultation. However, this patient has no clinical signs or symptoms of deep venous thrombosis, and she has normal vital signs. Healthy young patients may have good cardiovascular reserve and may not show any abnormalities until later in the course of their illness, so I would keep PE on the differential for now.

No thought exercise on pregnancy and chest pain would be complete without mentioning amniotic fluid embolism. This is similar to a pulmonary VTE, but it is due to amniotic fluid entering the maternal pulmonary circulation. This presents with a classic triad of hypoxia, hypotension, and coagulopathy. Most of these occur during labor; but about one third happen during the immediate postpartum period.³ This patient has no hypoxia, hypotension, or coagulopathy and is outside the expected time frame for amniotic fluid embolism, meaning we can likely remove it from the differential.

Next, let's think about peripartum cardiomyopathy. This typically occurs in the postpartum period and is marked by left ventricular dysfunction and heart failure. Research has suggested that peripartum cardiomyopathy is caused by vascular dysfunction, triggered by late-gestational maternal hormones.⁴ According to the definition from the European Society of Cardiology, these patients have a reduced EF, usually less than 45%, toward the end of pregnancy or in the months after delivery. Clinically, this patient does not look like she has heart failure. On exam she has clear lungs and no peripheral edema, and on CXR there is no pulmonary edema; so this makes heart failure less likely.

We have another clue in the case that can help us think about both PE and cardiomyopathy: the echocardiogram. There was no right heart strain, and a 50% EF. It seems unlikely to have a PE large enough to cause an elevated troponin without signs of right heart strain, and the 50% EF isn't quite low enough for cardiomyopathy. The combination of her clinical picture and the echocardiogram allows us to remove PE and cardiomyopathy from our differential.

Because neither of these likely diagnoses fit in this patient, we turn again to the ECG, which shows a STEMI. On top of that, the inferolateral hypokinesia on her

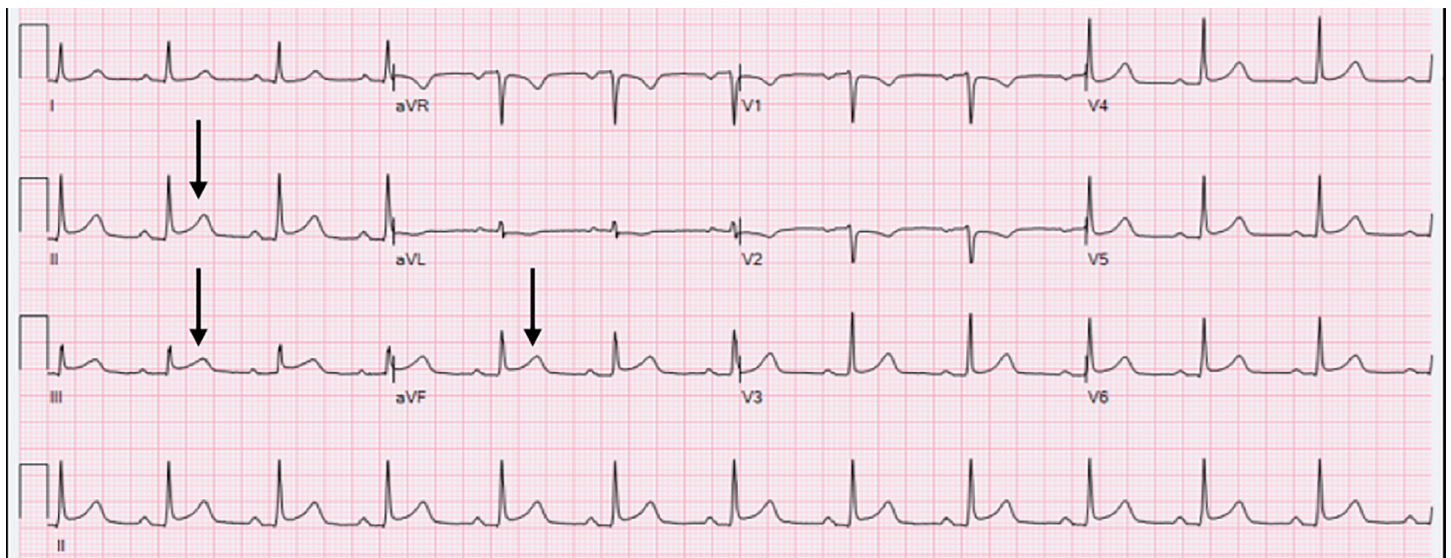


Image 1. Initial emergency department electrocardiogram. Black arrows indicate ST elevations.

Table 1. Emergency department laboratory results. Abnormal values are flagged with (H).

Test	Value	Reference
Hematology (serum)		
White blood cell count	9.9 K/mm ³	4.0-10.0 K/mm ³
Red blood cell count	4.78 million/uL	3.6-5.2 million/uL
Hemoglobin	13.8 g/dL	10.7-15.3 g/dL
Hematocrit	41.9%	32.4-45.2%
Mean cell volume	87.7 fL/cell	80-96 fL/cell
Mean corpuscular hemoglobin	28.9 pg	25.7-33.7 pg
Mean corpuscular hemoglobin concentration	33 g/dL	32.0-36.0 g/dL
Red blood cell distribution width	13.6%	11.6-15.6%
Platelet volume	238 K/mL	134-434 K/mL
Mean platelet volume	10 fL	7.5-11.1 fL
Chemistry (serum)		
Sodium	139 mmol/L	136-145 mmol/L
Potassium	3.9 mmol/L	3.5-5.1 mmol/L
Chloride	103 mmol/L	98-107 mmol/L
Carbon dioxide	22 mmol/L	21-32 mmol/L
Anion gap	14 mmol/L	8-16 mmol/L
Blood urea nitrogen	12 mg/dL	7-18 mg/dL
Creatinine	0.7 mg/dL	0.55-1.3 mg/dL
Glucose	106 mg/dL	74-106 mg/dL
Calcium	8.5 mg/dL	8.5-10.1 mg/dL
Total bilirubin	0.4 mg/dL	0.2-1.0 mg/dL
Aspartate aminotransferase	35 U/L	15-37 U/L
Alanine transaminase	39 U/L	13-61 U/L
Alkaline phosphatase	83 U/L	45-117 U/L
Total protein	6.9 g/dL	6.4-8.2 g/L
Albumin	3.7 g/dL	3.4-5.0 g/L
Total creatine kinase	1,344 U/L (H)	30-170 U/L
Troponin	2.42 ng/mL (H)	0.00-0.05 ng/mL
Thyroid function		
Free thyroxine	1.1 ng/dL	0.9-2.4 ng/dL
Thyroid stimulating hormone	2.24 mIU/L	0.83-1.09 mIU/L
Coagulation		
Prothrombin time	12.1 s	9.7-13.0 s
International normalized ratio	1.07	0.83-1.09
Urinalysis		
Color	Yellow	None
Appearance	Clear	None
Potential hydrogen	6	5.0-8.0
Specific gravity	1.019	1.010-1.035
Protein	Negative	Negative
Glucose	Negative	Negative
Ketones	Negative	Negative

K, thousand; *mm*³, cubic millimeter; *uL*, microliter; *g*, gram; *dL*, deciliter; *fL*, femtoliters; *pg*, picograms; *mmoles*, millimoles; *L*, liter; *mg*, milligram; *U*, units; *ng*, nanogram; *mL*, milliliter; *mIU*, milli-international unit; *s*, second.

Table 1. Continued.

Test	Value	Reference
Blood	Negative	Negative
Nitrite	Negative	Negative
Bilirubin	Negative	Negative
Urobilinogen	Negative	0.2-1.0 mg/dL
Leukocyte esterase	Negative	Negative

mg, milligram; dL, deciliter.

echocardiogram is a wall motion abnormality that fits the ST-elevation distribution on her ECG. This got me thinking: why would a healthy young postpartum woman have a STEMI? Pregnancy-related acute myocardial infarction (MI) is super rare! It complicates only 6.2 of 100,000 pregnancies.⁵ Wait, is there a differential diagnosis for STEMI?

The *Fourth Universal Definition of Myocardial Infarction* Task Force provided an international consensus on the classification of myocardial injury and infarction in 2018.⁶ They defined five types of MI.

MI types 4 and 5 are those associated with revascularization procedures, either percutaneous coronary intervention (PCI) or coronary artery bypass grafting (CABG), respectively. This patient had no recent procedure, so she couldn't have a type 4 or 5 MI.

Type 3 MI occurs when a patient suffers cardiac death, with symptoms or ECG changes that suggest MI, but who die before we can obtain biomarkers. This scenario clearly doesn't fit our alive patient.

Type 2 MI is due to an imbalance between myocardial oxygen supply and demand, unrelated to coronary artery disease. This is what we think of clinically as "demand ischemia." Supply and demand imbalance causes MI in a variety of ways, and some of these are worth exploring (Table 2).

This patient does not have hypertension, respiratory failure or shock; so we can immediately remove those from our differential. Her ECG shows normal sinus rhythm, so we can rule out the tachy- or brady-dysrhythmias. According to her blood work, she is not anemic. Her CXR shows a normal mediastinum, and while that does not entirely rule out aortic dissection, it certainly makes it less likely. That leaves coronary vasospasm (Prinzmetal's angina) and coronary artery dissection (CAD).

Coronary spasm was first reported by Prinzmetal et al. in the 1950s when they demonstrated reversible myocardial ischemia accompanied by ST-segment elevation on the ECG. Coronary artery spasm is defined as "dynamic, transient reduction in the luminal diameter of the epicardial coronary arteries due to increased vasomotor tone leading to myocardial ischemia." It causes only 1.8% of pregnancy-related MIs,⁷ which is pretty rare but not impossible in this patient.

Next, let's turn to CAD. Spontaneous coronary artery

dissection (SCAD) is a non-traumatic, non-iatrogenic epicardial CAD. While the cause of pregnancy-associated SCAD is not fully understood, we think the hormonal changes of pregnancy may compromise the arterial wall architecture. Importantly, SCAD isn't limited to the peripartum woman; it's a major cause of MI overall in women ≤ 50 years of age.⁸

The last type of MI (type I) is caused by plaque rupture or erosion leading to thrombus formation in a patient with atherosclerotic coronary artery disease. Our patient has no known atherosclerotic risk factors, making type 1 MI less likely.

We now have three causes of STEMI that remain on this patient's differential: coronary artery vasospasm, CAD, and classic plaque rupture with thrombus formation. The diagnostic test in each case is the same: the patient needs coronary angiography. To diagnose this patient without that study, as asked to do for a clinicopathological case, then becomes about numbers and odds. Pregnancy-associated SCAD is the most common cause of MI among patients who are pregnant or postpartum, accounting for 43% of acute MI in the peripartum population,⁹ making this the most likely cause of her MI.

Clinical Diagnosis:

Acute ST-elevation myocardial infarction due to pregnancy-associated spontaneous coronary artery dissection.

CASE OUTCOME (Resident Presentation)

Given this patient's STEMI in the setting of multiparity and recent postpartum status, a provisional diagnosis of SCAD was made by the ED provider. The patient was further managed in the ED with a heparin bolus and drip, and metoprolol. Cardiology was called for immediate consultation. Over the following four hours, the ST elevations improved on repeat ECG and the troponin climbed slightly but thereafter plateaued. The patient was admitted to the cardiac care unit (CCU) and was prepared for cardiac catheterization.

Coronary angiography (Image 2) revealed a long but subtle lesion in a large branch of the right coronary artery. To better characterize this lesion, the adjunctive intravascular ultrasound imaging modality optical coherence tomography (OCT) was used during cardiac catheterization. The OCT of

Table 2. Causes of type 2 myocardial infarction.

Anemia
Aortic Dissection
Aortic Valve Dissection
Arrhythmias
Coronary Artery Dissection
Coronary Vasospasm
Hypertension
Left Ventricular Hypertrophy
Respiratory Failure
Shock

the lesion demonstrated a large intramural hematoma with intimal disruption. There was 75% obstruction of the true lumen at the time of catheterization.

The patient stayed in the CCU for several days on the heparin drip and metoprolol. Her symptoms resolved, and her lab values and ST elevations normalized. Her ECG on discharge from the hospital showed a persistent T-wave inversion in aVL. She continued daily metoprolol and baby aspirin, and declined the option of clopidogrel because she was breastfeeding. She had a negative outpatient workup for fibromuscular dysplasia, and has had no recurrence of symptoms.

RESIDENT DISCUSSION

Pathophysiology

SCAD is defined as “separation of the coronary arterial wall by intramural hemorrhage creating a false lumen, with or without an intimal tear.”¹⁰ It develops in much the same way as aortic dissection; an intimal tear often results in high-pressure accumulation of hematoma between the vessel layers. Alternatively, the vasa vasorum can bleed between weakened vessel layers to create intramural hematoma. If this hematoma compresses the true lumen, it can cause complete or near-complete coronary vessel occlusion, resulting in STEMI or non-STEMI, respectively. There is an atherosclerotic variant of SCAD that tends to be self-limited by medial scarring and atrophy, but non-atherosclerotic SCAD is the real killer; it results in more extensive and severe dissection and has an acute mortality rate of 28-82%.^{11,12}

In 2018, *Circulation* published an American Heart Association (AHA) scientific statement noting that SCAD is more common than previously believed. Typical SCAD patients are healthy young women without conventional atherosclerotic risk factors. The AHA also expressed that SCAD must be evaluated and treated differently from atherosclerotic acute coronary syndrome (ACS).⁸ These statements drive home three important points:

- Epidemiology: SCAD is more common than previously thought
- Demographics: SCAD and type 1 MI patients differ markedly in age and risk factors.
- Management: SCAD and type 1 MI clinical management differs markedly.

Epidemiology

SCAD is more common than previously thought. According to recent literature, it accounts for up to 4% of ACS overall, and for up to 35% of ACS occurring in women aged 50 and younger.⁸ A retrospective review of an 32,869-patient angiography database found that women constituted 77% of SCAD cases, and all of these women had undergone at least one prior pregnancy.¹³ Historical underdiagnosis of SCAD is likely due to the subtle coronary angiography findings of long and diffusely narrowed coronary vessel segments. This triggered the need for OCT, which came into use in the mid-1990s. The true incidence and prevalence of SCAD remain unknown.¹⁴

Demographics

Although patients with SCAD present with the same symptoms as those with atherosclerotic ACS, the demographics differ markedly. In the ED, this means we have a different population of chest pain patients to be worried about: healthy young women.

SCAD is associated with fibromuscular dysplasia and other predisposing arteriopathies. Aside from genetic and structural abnormalities, the mechanism for vessel wall weakening is poorly understood. A widely accepted theory is that chronically elevated circulating hormone levels increase the risk of SCAD in multiparous (≥ 4 births), pregnant, and/or postpartum women. Interestingly, postpartum status was the sole risk factor in 18% of women, with a mean postpartum period of 38 days at the time of SCAD diagnosis.¹⁵

Management

Although SCAD is managed differently from atherosclerotic ACS, the initial ED workup is the same. The ECG for these patients often shows STEMI (25-50% of cases) or non-STEMI. The left anterior descending coronary artery is most commonly involved, and multivessel disease is not rare.¹³ Cardiac enzymes may be elevated, echocardiogram can reveal left ventricular dysfunction, and up to 14% of cases are complicated by ventricular dysrhythmias.¹⁶

Medical management is strongly preferred for SCAD. While in the ED, SCAD patients should still get aspirin, nitroglycerin, and heparin whenever applicable. They *should not* routinely get thrombolytics; there are prior descriptions of thrombolysis-precipitated extension of the dissection or even rupture leading to cardiac tamponade.¹⁷ SCAD patients should undergo coronary angiography with OCT for definitive diagnosis. Stenting is

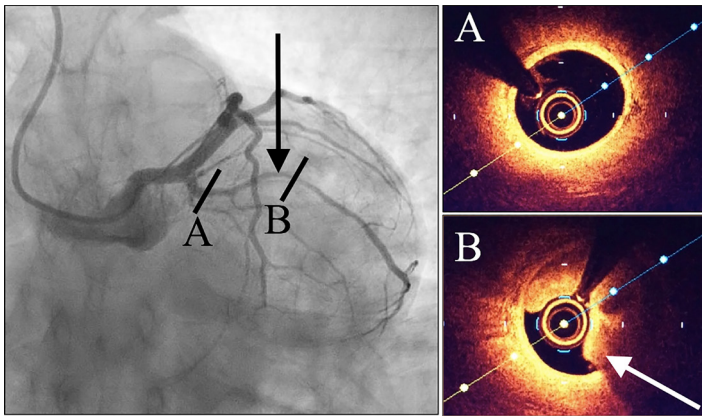


Image 2. Coronary catheterization images. Fluoroscopy is shown on the left, and intracoronary optical coherence tomography (OCT) is shown on the right. The black arrow indicates the lesion on angiography. The white arrow indicates intramural hematoma on OCT. Letters A and B signify locations along the lesion.

Documented patient informed consent and/or Institutional Review Board approval has been obtained and filed for publication of this case report.

Address for Correspondence: Mary E. McLean, MD, St. John's Riverside Hospital, Department of Emergency Medicine, 967 North Broadway, Yonkers, NY 10701. Email: mmclean@riversidehealth.org.

Conflicts of Interest: By the CPC-EM article submission agreement, all authors are required to disclose all affiliations, funding sources and financial or management relationships that could be perceived as potential sources of bias. The authors disclosed none.

Copyright: © 2020 McLean et al. This is an open access article distributed in accordance with the terms of the Creative Commons Attribution (CC BY 4.0) License. See: <http://creativecommons.org/licenses/by/4.0/>

reserved for severe cases. Balloon angioplasty can rupture the compromised vessel wall or cause hematoma propagation. A Mayo Clinic case series of 189 patients showed technical failure in 53% of patients initially managed with percutaneous coronary intervention (PCI).¹⁸ CABG may be reasonable for persistent STEMI, severe symptoms, or cardiogenic shock.

Beyond the acute phase, SCAD patients are typically worked up for fibromuscular dysplasia, connective tissue disorders, and systemic inflammatory conditions. Long-term management includes a beta blocker, statin, and daily baby aspirin and/or clopidogrel. As for long-term prognosis, the 10-year rate of major adverse cardiac events (death, heart failure, MI, and SCAD recurrence) was found to be 47%.¹⁶

FINAL DIAGNOSIS

Pregnancy-related spontaneous coronary artery dissection.

KEY TEACHING POINTS

- SCAD is historically underdiagnosed and accounts for up to 35% of MI in women aged ≤ 50 years, especially multiparous and peripartum women
- Medical management is strongly preferred (aspirin, heparin, and metoprolol), but do not thrombolysse these patients
- SCAD patients need coronary angiography for definitive diagnosis; but reserve stents and CABG for unstable patients or persistent STEMI, and do not perform balloon angioplasty
- Treat cardiogenic shock the same as all other cardiogenic shock (PCI, CABG, intra-aortic balloon pump, extracorporeal membrane oxygenation, left ventricular assist device, and implantable cardioverter-defibrillator)

REFERENCES

1. Khan E, Brieger D, Amarena J, et al. Differences in management and outcomes for men and women with ST-elevation myocardial infarction. *Med J Aust.* 2018;209(3):118-23.
2. Dado C, Levinson A, Bourjeily G. Pregnancy and pulmonary embolism. *Clin Chest Med.* 2018;39(3):525-37.
3. Sundin C and Mazac L. Amniotic fluid embolism. *MCN Am J Matern Child Nurs.* 2017;42(1):29-35.
4. Arany Z and Elkayam U. Peripartum cardiomyopathy. *Circulation.* 2016;133(14):1397-409.
5. James A, Jamison M, Biswas M, et al. Acute myocardial infarction in pregnancy: a United States population-based study. *Circulation.* 2006;113:1564-71.
6. Thygesen K, Alpert J, Jaffe A, et al. Fourth Universal Definition of Myocardial Infarction (2018). *Circulation.* 2018;138:e618-51.
7. Koneru J, Cholankeril M, Patel K, et al. Postpartum coronary vasospasm with literature review. *Case Rep Cardiol.* 2014;2014:523023.
8. Hayes S, Kim E, Saw J, et al. Spontaneous Coronary Artery Dissection: Current State of the Science: a scientific statement from the American Heart Association. *Circulation.* 2018;137:e523-57.
9. Elkayam U, Jalnapurkar S, Barakkat M, et al. Pregnancy-associated acute myocardial infarction: a review of contemporary experience in 150 cases between 2006 and 2011. *Circulation.* 2014-04;129(16):1695-702.
10. Saw J. Spontaneous coronary artery dissection. *Can J Cardiol.* 2013;29:1027-33.
11. Kearney P, Singh H, Hutter J, et al. Spontaneous coronary artery dissection: a report of three cases and review of the literature. *Postgrad Med J.* 1993;69:940-5.
12. Koller P, Cliffe C, Ridley D. Immunosuppressive therapy for

- peripartum-type spontaneous coronary artery dissection: case report and review. *Clin Cardiol.* 1998;21(1):40-6.
13. Mortensen K, Thuesen L, Kristensen I, et al. Spontaneous coronary artery dissection: a Western Denmark Heart Registry study. *Catheter Cardiovasc Interv.* 2009;74(5):710-7.
14. Lebrun S and Bond R. Spontaneous coronary artery dissection (SCAD): the underdiagnosed cardiac condition that plagues women. *Trends Cardiovasc Med.* 2018;28(5):340-5.
15. Tweet M, Hayes S, Pitta S, et al. Clinical features, management, and prognosis of spontaneous coronary artery dissection. *Circulation.* 2012;126(5):579-88.
16. Yip A and Saw J. Spontaneous coronary artery dissection: a review. *Cardiovasc Diagn Ther.* 2015;5(1):37-48.
17. Al-Hussaini A and Adlam D. Spontaneous coronary artery dissection. *Heart.* 2017;103(13):1043-51.
18. Tweet M, Eleid M, Best P, et al. Spontaneous coronary artery dissection: revascularization versus conservative therapy. *Circ Cardiovasc Interv.* 2014;7(6):777-86.

Removal of an Impaled Intraocular Hair Comb Following Self-inflicted Trauma

Michele Markovitz, MD*
Jordan Hamburger, BS†
Brian S. Fromm, MD‡
Brendan Carr, MD, MS‡
Xiao Chi Zhang, MD, MS‡

*Wills Eye Hospital, Department of Ophthalmology, Philadelphia, Pennsylvania
†Sidney Kimmel Medical School, Philadelphia, Pennsylvania
‡Thomas Jefferson University, Department of Emergency Medicine, Philadelphia, Pennsylvania

Section Editor: Rick A. McPheeters, DO

Submission history: Submitted July 13, 2019; Revision received October 9, 2019; Accepted October 17, 2019

Electronically published January 2, 2020

Full text available through open access at http://escholarship.org/uc/uciem_cpchem

DOI: 10.5811/cpchem.2019.10.44460

Ocular trauma is one of the most common and vision-threatening ophthalmic presentations with a wide spectrum of complications, such as bleeding, infection, vision loss, and enucleation. A 64-year-old-male presented to the emergency department (ED) with a self-inflicted orbital penetrating injury with a hair comb. Computed tomography showed the comb traversed the medial orbit inferior to the medial rectus but did not damage the optic nerve; there were no globe or orbital wall fractures. His ocular exam was significant for a right eye afferent pupillary defect and decreased visual acuity 20/800, consistent with optic neuropathy. Primary concerns were stabilizing and removing the foreign body without causing further damage in the setting of an uncooperative patient. The comb was removed with the aid of local and systemic analgesia using gentle traction and normal saline irrigation. The patient was admitted for systemic and topical antibiotics and showed improvement in visual acuity and resolution of his optic neuropathy. This case illustrates the importance of rapid ED assessment and management of complex penetrating ocular trauma. Examination should specifically look for signs of globe rupture and optic nerve injury. Expedited foreign body removal should be managed together with an ophthalmologist with procedural sedation and broad-spectrum antibiotics to avoid further visual and infectious complications. [Clin Pract Cases Emerg Med. 2020;4(1):8–11.]

INTRODUCTION

Ocular trauma is one of the most common, vision-threatening presentations seen by emergency physicians (EP).^{1,2} Complications include bleeding, infection, vision loss, loss of the eye and, rarely, sympathetic ophthalmia.¹ Emergency management strategies differ depending on the type, size, and site of penetration; however, timely imaging, adequate sedation, proper antibiotic, and early anti-inflammatory treatment can reduce morbidity and permanent vision loss.

CASE REPORT

A 64-year-old-male with a medical history of alcohol dependence with end-stage liver disease, and unknown baseline visual acuity, presented to the emergency department (ED) for a foreign body (FB) in his right eye. The patient

was receiving treatment at an outside hospital for hepatic encephalopathy when he forcibly impaled the handle of a plastic comb into his right eye without provocation. The patient was transferred to our ED due to its affiliation with an independent eye hospital and for complex ophthalmic intervention. Prior to arrival, the patient had received intravenous (IV) fentanyl for pain control and agitation, undergone a computed tomography (CT), and was immediately transferred with the comb secured in place with bulky dressing.

On arrival, the patient was sedated, jaundiced, and intermittently following simple commands. His vital signs were blood pressure 138/66 millimeters of mercury (mmHg), pulse rate 68 beats per minute, temperature 98° Fahrenheit, and saturating 97% on room air. External examination revealed an intact plastic hair comb handle embedded into the

inferomedial right orbit with a right conjunctival laceration at the nasal limbus extending inferonasally with associated subconjunctival hemorrhage (Image 1).

Ophthalmology was consulted immediately on patient arrival and was at bedside within 30 minutes. While all aspects of the eye exam were limited by cooperation and sedation, the patient was able to perceive light in both eyes and cooperated enough to determine a visual acuity in the right eye of 20/800 and a full left eye extraocular movement. Pupillary exam showed equally round and reactive pupils with a 1+ afferent pupillary defect (APD) in the right eye. Despite his encephalopathy, the patient was cooperative and directable and allowed for rapid intraocular pressures (IOP) measurement using gentle eyelid traction and tonopen tonometry with IOP measuring 13 mmHg and 10 mmHg (reference range 8–21 mm Hg). The CT from the transferring hospital demonstrated the comb was localized in the medial orbit adjacent to the medial rectus, extending toward the orbital apex and abutting the optic nerve, but it did not penetrate through the orbital wall and the globe was intact (Image 2).

To avoid further ocular damage, the decision was made to emergently remove the comb at the bedside with topical proparacaine and IV fentanyl. The ophthalmologist gently removed the comb using steady traction after sterilizing the surgical field with topical betadine. The patient was admitted for further management of his hepatic disease and psychiatric evaluation. He was continued on topical erythromycin ointment and neomycin-polymyxin-dexamethasone drops, IV piperacillin/tazobactam, and IV levofloxacin. He also received three days of IV dexamethasone for optic neuropathy. His afferent pupillary defect resolved by hospital day 2 and his visual acuity improved to 20/70 in both eyes. On discharge (hospital day 13), he had regained full extraocular motility, and his conjunctival laceration and subconjunctival hemorrhage were healing well and did not require further

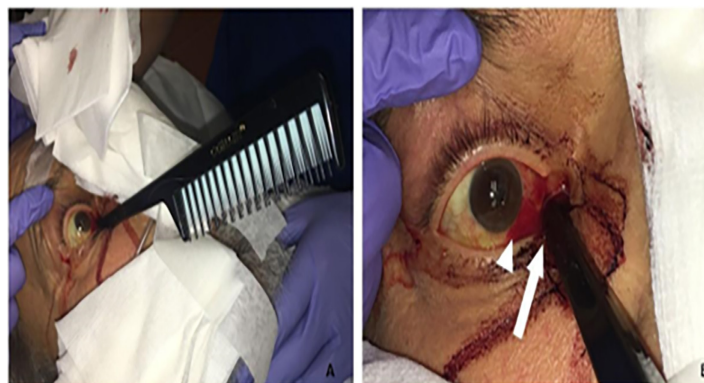

Image 1. Hair comb impaled into the right inferomedial orbit (A) with higher magnification (B) of the foreign body with right conjunctival laceration at the nasal limbus extending inferonasally (arrow) with associated subconjunctival hemorrhage (arrowhead).

CPC-EM Capsule

What do we already know about this clinical entity?

Intraorbital penetrating trauma can lead to infection, vision loss, and many other medical problems.

What makes this presentation of disease reportable?

This is a novel presentation of rare disease in which a penetrating intraorbital foreign body (FB) resulted in vision impairment without globe damage.

What is the major learning point?

Unstable, penetrating intraorbital FB without globe rupture or intracranial extension may be removed in the ED with appropriate imaging, sedation, and ophthalmology consultation.

How might this improve emergency medicine practice?

This case highlights the sedatives, antibiotics, anti-inflammatories, and procedural techniques needed in the removal of foreign bodies in unpredictable patients.

procedural intervention. He was discharged with erythromycin ointment and neomycin-polymyxin-dexamethasone drops.

DISCUSSION

Penetrating ocular trauma is a main cause of unilateral blindness.³ Management strategies depend on the type, size of the FB, site of penetration, and hemostasis.⁴⁻⁷ Ocular imaging of radiolucent FBs remains difficult: plain films detect only metallic FBs⁸ and magnetic resonance imaging poses risk associated with unrecognized metal.⁹ Inert FBs carry a lower risk of infection than organic FBs such as wood,⁴ but still warrant broad-spectrum antibiotics to prevent infections.^{10,11}

Intraorbital trauma should be explored for globe rupture and optic nerve injuries.¹²⁻¹⁴ Classic signs of optic nerve compromise include decreased visual acuity, APD, and dyschromatopsia.¹⁵ In our patient the imaging demonstrated an intact globe and the presence of a transient optic neuropathy, as evidenced by initial presence of APD, likely attributable to perineural inflammation from the adjacent FB

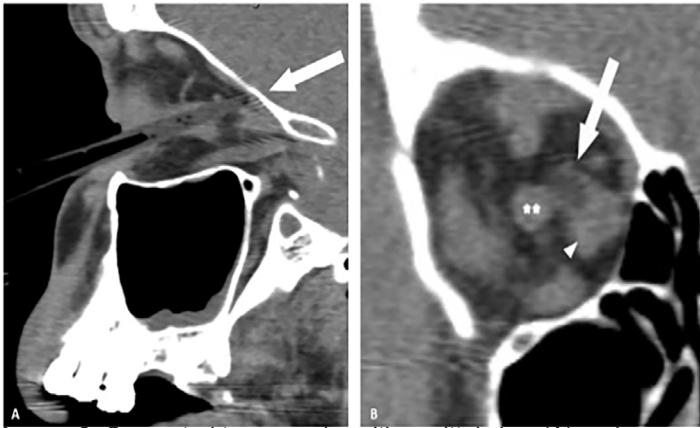


Image 2. Computed tomography with sagittal view (A) and coronal view (B) showing the foreign body (arrow) entering the orbit, adjacent to the right medial rectus muscle (arrowhead) and abutting the optic nerve sheath (white asterisks in middle of figure) and terminating at the posterior superior orbital wall with no evidence of orbital wall fracture.

rather than an irreversible traumatic optic neuropathy due to improvement after FB removal.

In many cases, delayed removal of the FB has shown no negative impact on the final visual outcome.^{16,17} Some intraorbital FBs such as glass, plastic, graphite, aluminum, and gold can be left in the eye if they pose no danger to intraocular structures, while iron, lead, and copper necessitate immediate removal due to retinal toxicity, chalcosis, and siderosis risks.¹⁸ Immediate removal of an intraorbital FB may result in incomplete retrieval or fragmented pieces left in the orbit, necessitating immediate transfer to a tertiary center with ophthalmology for emergent globe exploration. Further potential complications include bleeding and compartment syndrome, requiring surgical decompression with lateral canthotomy and cantholysis.

In our case, there was a high concern that instability of the comb and patient agitation could dislodge it and cause permanent optic nerve damage or even penetration into the intracranial cavity. Procedural sedation with medications such as ketamine or propofol may be considered for reducing agitation and preventing further intraocular injuries.¹⁹ While ketamine may be associated with increased IOP, our patient did not demonstrate ocular compartment syndrome or elevated IOP that would have limited the use of this chemical sedative for a time-sensitive and vision-saving procedure. Ophthalmic anesthetic drops should also be used for removal of any FB involving the cornea or conjunctiva; the need for additional medications should be at the discretion of the treating physician based on the individual situation. Fortunately, the FB was removed with limited analgesia and his APD improved shortly after FB removal and systemic steroids.

CONCLUSION

This case highlighted the risks and benefits in removing an unstable, intraorbital foreign body in an unpredictable

patient in a time-sensitive and vision-threatening situation. Examination should assess for globe rupture and optic nerve injury. CT imaging can guide both prognosis and management. Early ED management should include aggressive pain control, careful chemical sedation and early broad-spectrum antibiotics to avoid further traumatic, visual, and infectious complications. Cases requiring expedited foreign body removal should be managed together with an ophthalmologist.

ACKNOWLEDGMENTS

The authors would like to thank the Department of Emergency Medicine at Thomas Jefferson University and the Wills Eye Hospital for their support.

Documented patient informed consent and/or Institutional Review Board approval has been obtained and filed for publication of this case report.

Address for Correspondence: Xiao Chi Zhang, MD, MS, Thomas Jefferson University, Department of Emergency Medicine, 1020 Sansom St., Thompson Bldg, Suite 1651, Philadelphia, PA 19107. Email: xiao.chi.zhang@jefferson.edu.

Conflicts of Interest: By the CPC-EM article submission agreement, all authors are required to disclose all affiliations, funding sources and financial or management relationships that could be perceived as potential sources of bias. The authors disclosed none.

Copyright: © 2020 Markovitz et al. This is an open access article distributed in accordance with the terms of the Creative Commons Attribution (CC BY 4.0) License. See: <http://creativecommons.org/licenses/by/4.0/>

REFERENCES

1. Young ML, Sabti K, Kapusta MA. Traumatic optic neuropathy secondary to an intraoptic nerve foreign body. *Can J Ophthalmol.* 2003;38(4):289-91.
2. Chang IT, Prendes MA, Tarbet KJ, et al. Ocular injuries from fireworks: the 11-year experience of a US level I trauma center. *Eye (Lond).* 2016;30(10):1324-30.
3. Chen KC, Yang CS, Hsieh MC, et al. Successful management of double penetrating ocular trauma with retinal detachment and traumatic endophthalmitis in a child. *J Chin Med Assoc.* 2008;71(3):159-62.
4. Bhaduri G, Chattopadhyay SS, Ghosh RP, et al. An unusual case of penetrating ocular trauma with metallic spoon. *Indian J Ophthalmol.* 2010;58(4):330-1.
5. Islam S, Walton GM, Dean F, et al. Multidisciplinary management of a

- complicated orbital injury inflicted by a horse. *Ophthalmic Plast Reconstr Surg*. 2007;23(6):486-8.
6. Lee MH and Van Heerden A. Woman with facial trauma. *Ann Emerg Med*. 2016;67(6):e19-20.
 7. Carral-Santander IE, Acón-Ramírez D, Soberón-Ventura V, et al. Conservative management of penetrating ocular trauma caused by a nail gun. *Am J Ophthalmol Case Rep*. 2018;11:115-8.
 8. Pokhraj PS, Jigar JP, Mehta C, et al. Intraocular metallic foreign body: role of computed tomography. *J Clin Diagn Res*. 2014;8(12):RD01-3.
 9. Shellock FG and Kanal E. Re: Metallic foreign bodies in the orbits of patients undergoing MR imaging: prevalence and value of radiography and CT before MR. *Am J Roentgenol*. 1994;162(4):985-6.
 10. Fulcher TP, McNab AA, Sullivan TJ. Clinical features and management of intraorbital foreign bodies. *Ophthalmology*. 2002;109(3):494-500.
 11. Dolar Bilge A, Yilmaz H, Yazici B, et al. Intraorbital foreign bodies: clinical features and outcomes of surgical removal. *Ulus Travma Acil Cerrahi Derg*. 2016;22(5):432-6.
 12. Cherry PM. Standardized classification of ocular trauma. *Ophthalmology*. 1997;104(3):344-5.
 13. Mcdermott MW, Durity FA, Rootman J, et al. Combined frontotemporal-orbitozygomatic approach for tumors of the sphenoid wing and orbit. *Neurosurgery*. 1990;26(1):107-16.
 14. Chandran SR, Balakrishnan RK, Umakanthan K, et al. Neurocysticercosis presenting as isolated wall-eyed monocular internuclear ophthalmoplegia with contraversive ocular tilt reaction. *Journal of Neurosciences in Rural Practice*. 2012;3(01):84-6.
 15. Zhang XC, Statler B, Suner S, et al. Man with a swollen eye: nonspecific orbital inflammation in an adult in the emergency department. *J Emerg Med*. 2018;55(1):110-3.
 16. Colyer MH, Weber ED, Weichel ED, et al. Delayed intraocular foreign body removal without endophthalmitis during operations Iraqi Freedom and Enduring Freedom. *Ophthalmology*. 2007;114(8):1439-47.
 17. Gill E, Shulman M, Schechet S, et al. Open globe injury with an interesting intra-ocular foreign body. *GMS Ophthalmol Cases*. 2017;7:Doc17.
 18. Kuriyan A and Rachitskaya A. Update on the management of intraocular foreign bodies. *Retinal Physician*. 2017;14:48-52.
 19. Drayna PC, Estrada C, Wang W, et al. Ketamine sedation is not associated with clinically meaningful elevation of intraocular pressure. *Am J Emerg Med*. 2012;30(7):1215-8.

Beware of Reversal of an Anticoagulated Patient with Factor IX in the Emergency Department: Case Report of a Medical-Legal Misadventure

Steven Gannon, MD*
David Bell, MD, PhD†‡
Kenneth Jackmiczyk, MD†‡
Gregory Moore, MD, JD§

*Baylor University Medical Center, Pulmonary and Critical Care Medicine, Dallas, Texas
†Maricopa Medical Center, Department of Emergency Medicine, Phoenix, Arizona
‡University of Arizona College of Medicine-Phoenix, Department of Emergency Medicine, Phoenix, Arizona
§Mayo Clinic, Department of Emergency Medicine, Rochester, Minnesota

Section Editor: Melanie Heniff, MD

Submission history: Submitted May, 2019; Revision received October 23, 2019; Accepted December 17, 2019

Electronically published January 24, 2020

Full text available through open access at http://escholarship.org/uc/uciem_cpem

DOI: 10.5811/cpcem.2019.12.43675

In this article we present a case of a patient who received reversal of anticoagulation therapy with factor IX in violation of hospital guidelines. As a direct result, myocardial infarction and ischemic stroke occurred, leaving the patient neurologically debilitated. Factor IX is indicated in the setting of warfarin-induced, life-threatening bleeding. The patient's care was provided by an intern with attending physician supervision. Delayed charting and questionable shared decision-making were present in the care. We discuss usage of factor IX, liability for supervision of physicians in training, and factors that can lead to plaintiff awards. [Clin Pract Cases Emerg Med. 2020;4(1):12–15]

CASE PRESENTATION

A 54-year-old woman presented to her primary care physician complaining of epistaxis, hematochezia, headache, and a seizure. She had a prior history of seizures. The patient was on warfarin for an unknown reason. Her physician ordered an international normalized ratio (INR), which returned with a result of 13.4 after the patient had gone home. She had been told to hold her warfarin during her office visit. The patient was directed to go immediately to the emergency department (ED) but did not present until the next day. She had a history of very labile INRs in the past, with and without compliance. Multiple prior ED visits with extremely high levels in the past had been treated successfully with vitamin K and fresh frozen plasma (FFP) without complications.

On presentation to the ED the patient complained of a headache. She had no epistaxis or evidence of nasal bleeding. Her skin exam was normal. A neurologic exam was normal. A rectal exam was heme negative and the stool was normal color. The patient had right lower abdominal pain and tenderness. The emergency physician (EP) attending who was board certified in emergency medicine (EM) (seven years experience) supervised an intern (who had just begun

residency training) in rendering patient care. A computed tomography (CT) of the brain was done with normal results. An INR lab test returned with a result of greater than 10. Due to abdominal tenderness, the possibility of appendicitis was entertained. A CT of the abdomen was ordered and the surgical service consulted.

The attending EP then discussed the case with the intern and a decision was made to give Proflinone (factor IX). There was no documentation of medical decision-making or discussion with the patient. The decision to administer factor IX was made prior to completion of the surgical consultation or CT result. Subsequently the EP attending left for home before the patient's consultation or care was completed. He had never administered the drug before and instructed the intern to look up the dose on the Internet and order it. A hospital guideline specifically discussed indications for use of the drug: The patient must have either (1) a serious or life-threatening bleed; or (2) require emergency surgery.

Three hours after administration of the medication the patient developed signs and symptoms of an acute myocardial infarction (MI). An electrocardiogram showed marked ST elevations, which resolved after the administration of tPA.

Troponin was elevated as well. Cardiac catheterization performed after resolution of the ST-segment elevation revealed no thrombosis. The patient suffered a cardiac arrest and was subsequently resuscitated. Experts opined that a stroke had also occurred.¹ She was left in a minimally conscious state with a seven-year life expectancy. A jury rendered a plaintiff verdict for \$15 million.

DISCUSSION

Dr. Gannon: Caveats when Using Profilnine

Profilnine is the brand name for factor IX complex composed of factors II, IX, X. It has notably low or even nontherapeutic levels of factor VII and thus should not be confused with prothrombin complex concentrate. The primary indications for use are in patients diagnosed with a factor IX deficiency, also known as hemophilia B or Christmas disease. It is indicated in these patients when they present with acute hemorrhage, prophylaxis for bleeding, or in preparation for planned surgical or dental procedures.² Dosing is based both on weight and goal of factor IX level, which in turn is dependent on the severity and/or risk of further bleeding. The cost of factor IX complex is per unit and current available pricing is \$1.57 per unit. In a typical 70 kilogram (kg) patient receiving the 75-90 units/kg recommended for treatment of major bleeding, the price for factor IX complex would amount to \$8,242.50–\$9,891.00.³

Known adverse effects from factor IX complex include antibody formation to factor IX, hypersensitivity reactions, thrombotic events, and disseminated intravascular coagulation. While there are no contraindications listed in the manufacturer's labeling, caution is advised when using factor IX complex in patients with liver disease, history of coronary artery disease, and disseminated intravascular coagulation due to the risk of thromboembolic complications. Factor IX complex has also been used in the treatment of life-threatening hemorrhage associated with warfarin. It is important to note that this use is off-label, and evidence regarding its use for reversal of supratherapeutic INR is poor and heavily expert-opinion based.⁴

Current consensus guidelines do not recommend use of prothrombin complex concentrates outside of the setting of warfarin-associated major bleeding. When it is used for this purpose, the concomitant use of FFP or factor VIIa can be considered as factor IX complex contains nontherapeutic levels of factor VII.⁵ It has been shown, in a small study, to be effective in the treatment of warfarin-associated intracranial hemorrhage without a significantly increased risk of thromboembolic complications when compared to FFP. However, this study did note that reversal with 3-factor prothrombin complex concentrate was accompanied by thrombotic complications (venous thromboembolism, ischemic stroke or MI) in 12.5% of patients.⁶

Dr. Bell: Medical-Legal Liability of Residents

Between 2009-2013, EM residents were named in 13.4% of malpractice lawsuits.⁷ In a malpractice lawsuit, four elements must be present: duty; breach of duty; causation; and damages. This standard holds true for both residents and attending physicians who are named in the suit. Malpractice cases with residents named were statistically more likely to involve cardiac cases and procedures.⁷

The vexing issue regarding residents is this: What standard of care ought they be held to? Historically, from the 1950s-1980s, residents were held to a lower standard of care than attendings.⁸ However, this has changed over the years in subsequent court rulings. While there is some court variation, in general, medical interns, even though they are unlicensed, are held to the standard of care of a general practitioner who is practicing in a similar setting.⁸ Residents beyond their intern year who are training in a specialty have consistently been found to be held to the higher standard of care of an attending physician in that specialty.^{9,10} In part, this is argued because such residents are licensed and are also presenting themselves to the patients as specialists in a particular field. While there is some possibility that as specialist training progresses, residents are held to increasing stricter standards, there is some variation in the courts regarding this.

Although it can occur that EM residents are the sole practitioners named in malpractice lawsuits, practically speaking this is rare, occurring in only 5.3% of cases between 2009-2013.¹¹ Hospitals, training institutions, and attendings are almost always named in malpractice suits as well.¹¹ With some minor variations, the courts have consistently found that attending physicians are liable for the residents they are supervising, whether that supervision is in person or at a distance (direct or indirect).¹²

As a malpractice lawsuit progresses it sometimes occurs that those named in the suit with greater financial assets ("deeper pockets"), such as hospitals and attending physicians, are pursued for damages, while residents who may have smaller limits on their malpractice insurance are dropped. However, residency programs should be encouraged and expected to provide appropriate levels of location- and specialty-specific malpractice coverage for their trainees. While it is possible for a resident to argue that they were poorly trained by their program and thus not liable for their malpractice errors, in general such arguments have not succeeded.⁹

Dr. Jackimczyk: Attending Physician Medical-Legal Liability for Residents

Two classic legal cases give insight into liability when attending physicians supervise residents. In *Landry v Leonard*, a 22-year-old woman was referred by her obstetrician to a teaching hospital for induction of labor. Upon her arrival a fetal stress test was performed by the obstetrical (OB) resident on duty and was interpreted as being normal. The test actually demonstrated

fetal distress. The baby was subsequently born neurologically impaired. The supervising attending OB physician was not present at the hospital during the resident's care of the patient but was named in the lawsuit. It was argued that his lack of appropriate supervision resulted in the child's brain damage. Both at trial and on appeal the attending obstetrician was dismissed because he never came into contact with the patient. Ultimately, the case went to the Ohio Supreme Court.

The patient had signed consent at the teaching hospital allowing students to administer treatment but the consent also stated that there would be an attending physician delivering general instructions. The Ohio Supreme Court ruled that it was the attending physician's duty to be present for the birth rather than waiting for the resident to call for help. The Court concluded that a physician-patient relationship arises whenever a physician consents to act for a patient's benefit. In teaching hospitals a physician-patient relationship may be present when a physician agrees to provide supervision in the care of a patient even if they have no direct or indirect contact with the patient.¹³

In *Lownsbury v VanBuren*, a 23-year-old woman presented to the ED with a severe headache. She was examined by a resident who ordered a CT of the head. He interpreted the CT as normal and performed a lumbar puncture, which was normal. The patient was admitted to the hospital and was discharged the next day with a diagnosis of muscle tension headache. She was never seen and her case was never reviewed by the attending physician. She returned to the ED the following day with a worsening headache and vomiting. She was examined by an attending physician who noted decreased vision in her left eye. He reviewed the previous day's CT and noted several small infarcts that the resident hadn't seen. He repeated the head CT and it showed a "massive cerebral infarct." She was admitted to the intensive care unit and died three days later.

A lawsuit was filed and the plaintiffs received damages of \$500,000, the highest award possible under Louisiana's malpractice law. The plaintiff's expert witness noted that the hospital's bylaws "bar the medical staff from delegating diagnosis and care of patients to practitioners who are not qualified to undertake responsibility and who are not adequately supervised." The plaintiff's verdict was upheld on appeal. The attending physician claimed that his lack of involvement in the case eliminated his liability. The court decided that the attending physician, as supervisor of the resident, had accepted a duty to care for the patient and should be held responsible for the error in the resident's judgment. The court stated that this is the very reason the attending should be present.¹⁴

Dr. Moore MD JD: Physician Medical-Legal Mistakes

Plaintiff attorneys, in the setting of possible malpractice, feel very confident in successful litigation when hospital guidelines are violated. Guidelines represent

a consensus opinion and result from a variety of authorities agreeing on standard practice. While a physician may disagree with the guidelines, and deviate from them in certain situations, there should be clear documentation of the reasoning behind the deviation. Conversely, when a guideline is followed, plaintiffs admit they have great difficulty proving negligence.

The chart in this case was generated three days later by the attending and seven days later by the intern. In these cases of delayed documentation, when a poor patient outcome occurs, juries can be very skeptical of the truthfulness of the chart. They recognize the documentation may have self-serving and litigation-avoiding purposes.

Recently, plaintiff attorneys have begun to point to a failure of shared decision-making or lack of informed consent when patient outcomes are poor. This is especially true when significant and risky treatment decisions are undertaken without actual or documented involvement of the patient and/or family. A recent randomized controlled simulation using clinical vignettes explored the magnitude of this issue using no/brief/thorough shared decision-making. Of 804 participants, patients who received brief or thorough shared decision-making were 80% less likely to contact a lawyer and expressed higher trust and acceptance of adverse outcomes when compared to patients who received no decision-making.¹⁵

Ignorance of hospital guidelines, delayed charting, and lack of shared decision-making all played a significant part in this plaintiff outcome of \$15 million.

CONCLUSION

Administration of factor IX is a significant medical decision, which can lead to severe morbidity or mortality. It is also very expensive. It behooves providers to be certain that it is indicated before prescribing this therapy. When supervising others who are using this medication, providers must be aware of their responsibility and liability for others. Optimal charting and information-sharing with patients will reduce liability. Approved guidelines that are in place should be respected and the chart should reflect specific reasons for deviation.

Take Home Points:

1. Use of factor IX can lead to severe morbidity and mortality as well as liability and thus should be given only if specifically indicated.
2. When supervising physicians in training, it should be realized that although those in training may be held liable, the courts have clearly stated that the supervising physician has greatest responsibility and liability.
3. Deviation from accepted clinical guidelines exposes great liability unless there is clear documentation for the thought process and justification that led to the deviation.
4. Delayed charting, when there are bad clinical outcomes,

leads to questions of physician honesty by juries when trial occurs.

5. Shared decision-making with patients, when there are significant clinical decisions to be made, reduces liability in resultant negative patient outcomes

ACKNOWLEDGMENT

The authors appreciate the support of attorney Brian Snyder of the plaintiff firm Snyder and Wenner in supplying public court documents on this case.

Documented patient informed consent and/or Institutional Review Board approval has been obtained and filed for publication of this case report.

Address for Correspondence: Gregory Moore, MD, JD, Maricopa Medical Center, Department of Emergency Medicine, 1507 Nisqually Street, Steilacoom, WA 98388. Email: gmoore4408@aol.com.

Conflicts of Interest: By the CPC-EM article submission agreement, all authors are required to disclose all affiliations, funding sources and financial or management relationships that could be perceived as potential sources of bias. The authors disclosed none.

Copyright: © 2020 Gannon et al. This is an open access article distributed in accordance with the terms of the Creative Commons Attribution (CC BY 4.0) License. See: <http://creativecommons.org/licenses/by/4.0/>

REFERENCES

1. *Tripp vs The Arizona Board of Regents*, Case No. C20144811. (Superior Court of Arizona-Pima County)
2. Frontera JA, Gordon E, Zach V, et al. Reversal of coagulopathy using prothrombin complex concentrates is associated with improved outcome compared to fresh frozen plasma in warfarin-associated intracranial hemorrhage. *Neurocrit Care*. 2014;21(3):397-406.
3. Baker RI, Coughlin PB, Gallus AS, et al. Warfarin reversal: consensus guidelines, on behalf of the Australasian Society of Thrombosis and Haemostasis. *Med J Aust*. 2004;181(9):492-7.
4. Holland L, Warkentin TE, Refaai M, et al. Suboptimal effect of a three-factor prothrombin complex concentrate (Profilnine-SD) in correcting supratherapeutic international normalized ratio due to warfarin overdose. *Transfusion*. 2009;49(6):1171-7.
5. Guyatt GH, Akl EA, Crowther M, et al. *Executive Summary: Antithrombotic Therapy and Prevention of Thrombosis*, 9th ed: American College of Chest Physicians Evidence-Based Clinical Practice Guidelines. *Chest*. 2012;141(2 Suppl):7S-47.
6. Masotti L, Di Napoli M, Godoy DA, et al. The practical management of intracerebral hemorrhage associated with oral anticoagulant therapy. *Int J Stroke*. 2011;6(3):228-40.
7. Gurley KR, Grossman SA, Janes M, et al. Comparison of emergency medicine malpractice cases involving residents to nonresident cases. *Acad Emerg Med*. 2018;25(9):980-6.
8. Wegman B, Stannard JP, Sonny Ball B. Medical liability of the physician in training. *Clin Orthop Relat Res*. 2012;470(5):1379-85.
9. Bailey RA. Resident liability in medical malpractice. *Ann Emerg Med*. 2013;61(1):114-7.
10. Teo WZW, Brenner LH, Ball BS. Medicolegal sidebar: resident physician liability. *Clin Orthop Relat Res*. 2017;475(8):1963-5.
11. Kachalia A and Studdert DM. Professional liability issues in graduate medical education. *JAMA*. 2004;292(9):1051-6.
12. Ott CJ and Houry DE. Medical malpractice and the emergency medicine resident. *Ann Emerg Med*. 2000;36(6):631-33.
13. *Landry v. Leonard J. Chabert Medical Center*, No. 2002 CA 1559 (May 14, 2003).
14. *Lownsbury v. VanBuren*, No. 00-1655, (Ohio Supreme Court, Feb. 20, 2002).
15. Schoenfeld EM, Mader S, Houghton C. The effect of shared decision making on patients' likelihood of filing a complaint or lawsuit: a simulation study. *Ann Emerg Med*. 2019;74(1):126-36.

Administration of Nebulized Ketamine for Managing Acute Pain in the Emergency Department: A Case Series

Jefferson Drapkin, BS
 Aidin Masoudi, MD
 Mahlaqa Butt, MPH
 Rukhsana Hossain, MPH
 Antonios Likourezos, MA, MPH
 Sergey Motov, MD

Maimonides Medical Center, Department of Emergency Medicine, Brooklyn, New York

Section Editor: Rick A. McPheeters, DO

Submission history: Submitted July 18, 2019; Revision received November 1, 2019; Accepted October 17, 2019

Electronically published January 2, 2020

Full text available through open access at http://escholarship.org/uc/uciem_cpchem

DOI: 10.5811/cpchem.2019.10.44582

Ketamine administration in sub-dissociative doses in the emergency department (ED) results in effective pain relief in patients with acute traumatic and non-traumatic pain, chronic pain, and opioid-tolerant pain. This case series describes five adult ED patients who received nebulized ketamine for predominantly acute traumatic pain. Three patients received nebulized ketamine at 1.5 milligrams per kilogram (mg /kg) dose, one patient at 0.75 mg/kg, and one patient at 1 mg/kg. All five patients experienced a decrease in pain from the baseline up to 120 minutes. The inhalation route of ketamine delivery via breath-actuated nebulizer may have utility for managing pain in the ED. [Clin Pract Cases Emerg Med. 2020;4(1):16–20.]

INTRODUCTION

Ketamine is a non-competitive N-methyl-D-aspartate/ glutamate receptor complex antagonist that decreases pain by diminishing central sensitization, hyperalgesia, and “wind-up” phenomenon at the level of the spinal cord (dorsal ganglion) and central nervous system.¹ Ketamine administration in sub-dissociative (SDK) dose (0.1–0.3 milligrams per kilogram (mg/kg)) in the emergency department (ED) results in effective pain relief in patients with acute traumatic and non-traumatic pain, chronic non-cancer and cancer pain, and opioid-tolerant pain by virtue of providing anti-hyperalgesia, anti-allodynia, and anti-tolerance.^{2,3} Two commonly employed administration strategies of SDK administration in the ED include an intravenous (IV) route (push-dose, short infusion, or continuous infusion), and intranasal route.^{4,5} However, in situations when IV access is unobtainable and /or mucosal atomization device is not readily available, nebulized routes of analgesic administration can be used. The nebulization of analgesics in the ED provides rapid, effective, and titratable analgesic delivery. It also results in less painful methods of analgesic delivery, minimizes analgesic toxicity and side effects (for example-opioids), and improves overall management of a variety of painful conditions in the ED.⁶

Nebulized administration of ketamine has been studied in the areas of palliative care, therapy for asthma, and acute postoperative management of sore throat.⁷⁻⁹ To our knowledge, there is no literature regarding analgesic efficacy and safety of nebulized ketamine’s role in managing acute painful conditions in the ED. The following cases describe five patients presenting to the ED of a tertiary medical center between May-June 2019 with acute painful conditions and receiving nebulized ketamine at three different dosing regimens of 0.75 mg/kg, 1 mg/kg, and 1.5 mg/kg via breath-actuated nebulizer.

CASE SERIES

We describe five patients, ages 30-54, who presented to the ED with acute painful conditions: four patients with traumatic musculoskeletal pain, and one with abdominal pain (Table 1).

Case #1

A 44-year-old man without prior medical history presented to the ED with one-day history of traumatic injury to his right wrist and hand with severe 8/10 pain and moderate swelling along the dorsal aspect of the right hand and wrist.

Radiographs were negative for acute fracture or dislocation. The patient received only two doses of nebulized ketamine at 0.75 mg/kg with change in pain score from eight at the baseline to one at 120 minutes (min) (Table 2). The patient was discharged with a final diagnosis of wrist strain.

Case #2

A 43-year-old woman without prior medical history presented to the ED with a chief complaint of 8/10 severe bilateral knee pain over the prior six months with pain radiating to both of her calf muscles and associated with stiffness. On physical examination the patient had moderate right patellar tenderness, no appreciable joint effusion, and no evidence of infectious/inflammatory processes. She received a single dose of nebulized ketamine at 1 mg/kg with a change in pain score from eight at baseline to zero at 120 min (Table 2). The patient was discharged with a final diagnosis of traumatic knee pain.

Case #3

A 30-year-old man without prior medical history presented to the ED with severe, 8/10 pain to his left hand after slamming it with a car door. On examination, the patient was noted to have swelling and tenderness to palpation at the dorsal aspect of the left hand/metacarpal region with decreased range of motion at the second through fifth metacarpal joints and intact neurovascular status. He received nebulized ketamine at 1.5 mg/kg with change in pain score from eight at the baseline to two at 120 min (Table 2). The patient was discharged with a final diagnosis of hand contusion.

Case #4

A 54-year-old man without prior medical history presented to the ED with severe, 9/10 acute lower back pain after a fall at home that resulted in the patient landing on his back and

subsequently sliding down 10 steps. On examination, he had prominent paraspinal tenderness at the lumbar region without

CPC-EM Capsule

What do we already know about this clinical entity?
Ketamine is used in the emergency department (ED) via intravenous, subcutaneous, and intranasal routes for managing acute painful conditions.

What makes this presentation of disease reportable?
This is the first description of the use of ketamine analgesia via breath-actuated nebulizer for adult ED patients presenting with acute painful conditions.

What is the major learning point?
Nebulized ketamine at doses of 0.75 milligrams per kilogram (mg/kg), 1 mg/kg, and 1.5 mg/kg alleviates acute pain in adult ED patients.

How might this improve emergency medicine practice?
Ketamine administration via breath-actuated nebulizer may serve as an additional non-invasive route for delivering analgesia in the ED.

Table 1. Characteristics of patients given nebulized ketamine.

Patient number	Age/sex	Chief complaint	Weight	Dosing mg/kg - actual dose ^a	Doses given	Total dose received ^b	Baseline vital signs			
							HR	BP	RR	SpO ₂
1	44M	Traumatic arm pain	70 kg	0.75 mg/kg – 55mg	2	55 mg	88	140/93	20	99
2	43F	Traumatic knee pain	67 kg	1.0 mg/kg – 65 mg	1	19.5 mg	78	112/58	16	100
3	30M	Traumatic arm pain	90 kg	1.5 mg/kg – 135 mg	1	108 mg	83	131/98	13	100
4	54M	Traumatic back pain	70 kg	1.5 mg/kg – 105 mg	1	105 mg	61	121/71	14	98
5	38F	Abdominal pain	65 kg	1.5 mg/kg – 100 mg	2	140 mg	72	116/72	15	97

^a Actual dose: Indicates the per dose concentration the patient was meant to receive.

^b Total dose received: Indicates the total amount a patient consumed after wastage.

M, male; F, female; kg, kilogram; mg, milligram; HR, heart rate; BP, blood pressure; RR, respiratory rate; SpO₂, peripheral capillary oxygen saturation.

Table 2. Numerical pain scores.

Patient number	NRS pain over time					
	Baseline	15 min	30 min	60 min	90 min	120 min
1	8	6	5	5	1	1
2	8	5	3	2	0	0
3	8	5	4	2	2	2
4	9	6	4	0	0	0
5	9	2	2	1	1	0

NRS, numeric pain-rating scale; *min*, minutes.

swelling, ecchymosis, or laceration. He received nebulized ketamine at 1.5 mg/kg with change in pain score from nine at the baseline to zero at 120 min (Table 2). The patient was discharged with a final diagnosis of traumatic back pain.

Case #5

A 38-year-old woman without prior medical history presented to the ED with chief complaint of severe 9/10 crampy abdominal pain and nausea and single episode of loose stool. On examination, the patient had prominent epigastric and periumbilical tenderness without rebound and guarding. She received IV famotidine and ketorolac without appreciable pain relief and subsequently received two doses of nebulized ketamine at 1.5 mg/kg with change in pain score from nine at the baseline to zero at 120 min (Table 2). The patient was discharged with a final diagnosis of viral gastroenteritis.

Three patients were male and two were female. None of the patients had absolute contraindications to ketamine such as allergy to ketamine, pregnancy, or history of schizophrenia. We used a standard verbal numeric pain-rating scale to evaluate patients' pain scores at the baseline and at 15, 30, 60, 90, and 120 min.¹⁰ We used the Side-effects Rating Scale of Dissociative Anesthetics to describe side effects related to ketamine administration from baseline to 120 min.¹¹

Three patients received nebulized ketamine via breath-actuated nebulizer at 1.5 mg/kg dose, one patient at 0.75 mg/kg, and one patient at 1 mg/kg. Two patients requested and received a second dose of nebulized ketamine. The dosages of nebulized ketamine (ordered and received) as well as baseline vital signs are presented in Tables 1 and 2. All five patients experienced a decrease in pain from baseline to 15 min, 30 min, 60 min, 90 min, and 120 min post medication administration (Table 2).

One patient experienced dizziness of modest intensity that was self-limited after 60 min and felt fatigued at 90 min. Another patient experienced a mood change, self-described as feeling "relaxed and happy," at 15 min (Table 3). No patient experienced elevated heart rate and/or blood pressure during the observational period.

DISCUSSION

In situations when intravenous access and /or mucosal atomization devices are not readily available, inhalation (nebulization) route might be considered for provision of timely and effective analgesia in the ED. However, safety and efficacy of ketamine in a nebulized form as an analgesic in the ED setting has yet to be shown.

Nebulized administration of ketamine has been studied in the areas of palliative care, asthma therapy, and acute postoperative management of sore throat.^{7-9,12,13} Five randomized trials have compared nebulized ketamine either in a fixed-dosing regimen (50 mg) or weight-based dosing (0.5 mg/kg, 1mg/kg, or 1.5 mg/kg) to placebo in reducing post-intubational sore throat. The average decrease of postoperative throat pain decreased by 44-50% without any major side effects.^{7-9,12,13} Similarly, ketamine inhalation in healthy volunteers was easily tolerated and was not associated with oropharyngeal irritation, hypersalivation, stridor, laryngospasm, cough, dry mouth, hoarseness, dyspnea, tachypnea, aspiration, cardiac dysrhythmias, or desaturations.^{14,15}

Pharmacokinetic properties of inhaled ketamine have not been studied broadly, but a single observational study evaluated pharmacokinetics of S-ketamine administered via nebulization to 12 healthy volunteers at doses of 0.35, 0.5, and 0.7mg/kg and inhalation duration of 20–40 min. The study demonstrated a time to maximum concentration of 15-22 min and a maximum concentration of 128ng/ml.¹⁵

In addition, based on the bioavailability of intranasal ketamine (25-50%) and oral ketamine (16-24%), the bioavailability to nebulized ketamine ranges between 20-40% of IV route.^{16,17} To date, this case series is the first to describe the use of nebulized ketamine via breath-actuated nebulizer at three different dosing regimens, with titration as needed for patients presenting to the ED with acute traumatic and non-traumatic painful conditions. The breath-actuated nebulizer (BAN) (AeroEclipse, Trudell Medical International, London, Ontario, Canada) provides smaller particles and greater dose delivery efficiency than continuous jet nebulizers. In addition, BAN possesses dual modes of action: 1) continuous aerosol generation; and 2) breath-actuated (in response to the patient's

Table 3. Severity of side effects using rating scale of dissociative anesthetics by patient and time.

Adverse effect	Time point	Level of severity			
		1-Weak	2-Modest	3-Bothersome	4-Very bothersome
Dizziness	15 min	--	Patient 2	--	--
	30 min	--	Patient 2	--	--
	60 min	--	Patient 2	--	--
	90 min	--	--	--	--
	120 min	--	--	--	--
Fatigue	15 min	--	--	--	--
	30 min	--	--	--	--
	60 min	--	--	--	--
	90 min	--	Patient 2	--	--
	120 min	--	--	--	--
Mood change	15 min	Patient 3	--	--	--
	30 min	--	--	--	--
	60 min	--	--	--	--
	90 min	--	--	--	--
	120 min	--	--	--	--

min, minutes.

inspiratory flow), ensuring that virtually no drug is lost to the environment.^{18,19} Furthermore, BAN has a potential to provide greater compliance and safer patient environment that may impact overall pain management, patients satisfaction, and length of stay in the ED.

All five patients had a decrease in pain from the baseline to 120 min with average change in pain score of 3.6 at 15 min, 4.6 at 30 min, 6.4 at 60 min, 7.6 at 90 min, and 7.8 at 120 min. Furthermore, only one patient experienced dizziness of modest intensity. While the descriptive nature of this report cannot be used to make any conclusion of safety and efficacy of nebulized ketamine in managing pain in the ED, the non-invasive route, titratability, and self-administration (by the patient) make this analgesic modality an attractive choice, especially when IV access is not readily available or unobtainable. There is a need for larger, dose-finding studies in a prospective, randomized fashion to fully evaluate the safety and efficacy of nebulized ketamine for analgesia in the ED.

CONCLUSION

The inhalation route of ketamine delivery via breath-actuated nebulizer for managing pain in the ED may add an additional modality to the analgesic armamentarium of ED clinicians in providing rapid, effective, and non-invasive pain relief.

Documented patient informed consent and/or Institutional Review Board approval has been obtained and filed for publication of this case report.

Address for Correspondence: Jefferson Drapkin, BS, Maimonides Medical Center, Department of Emergency Medicine, 4802 10th Avenue, Brooklyn, NY 11219. Email: jdrapkin@maimonidesmed.org.

Conflicts of Interest: By the *CPC-EM* article submission agreement, all authors are required to disclose all affiliations, funding sources and financial or management relationships that could be perceived as potential sources of bias. The authors disclosed none.

Copyright: © 2020 Drapkin et al. This is an open access article distributed in accordance with the terms of the Creative Commons Attribution ([CC BY 4.0](https://creativecommons.org/licenses/by/4.0/)) License. See: <http://creativecommons.org/licenses/by/4.0/>

REFERENCES

1. Gao M, Rejaei D, Liu H. Ketamine use in current clinical practice. *Acta Pharmacol Sin.* 2016;37(7):865-72.
2. Ahern TL, Herring AA, Anderson ES, et al. The first 500: initial

- experience with widespread use of low-dose ketamine for acute pain management in the ED. *Am J Emerg Med.* 2015;33(2):197-201.
3. Motov S, Drapkin J, Likourezos A, et al. Sub-dissociative dose ketamine administration for managing pain in the emergency department. *World J Emerg Med.* 2018;9(4):249-55.
 4. Motov S, Mai M, Pushkar I, et al. A prospective randomized, double-dummy trial comparing intravenous push dose of low dose ketamine to short infusion of low dose ketamine for treatment of moderate to severe pain in the emergency department. *Am J Emerg Med.* 2017;35(8):1095-1100.
 5. Quinn K, Kriss S, Drapkin J, et al. (Print) Analgesic efficacy of intranasal ketamine versus intranasal fentanyl for moderate to severe pain in children: a prospective, randomized, double-blind study. *Pediatr Emerg Care.* 2018.
 6. Thompson JP and Thompson DF. Nebulized fentanyl in acute pain: a systematic review. *Ann Pharmacother.* 2016;50(10):882-91.
 7. Ahuja V, Mitra S, Sama R. Nebulized ketamine decreases incidence and severity of postoperative sore throat. *Indian J Anaesth.* 2015;59(1):37-42.
 8. Goyal S and Agrawal A. Ketamine in status asthmaticus: A review. *Indian J Crit Care Med.* 2013;17(3):154-61.
 9. Thomas D, Bejoy R, Zabrin N, et al. Preoperative ketamine nebulization attenuates the incidence and severity of postoperative sore throat: A randomized controlled clinical trial. *Saudi J Anaesth.* 2018;12(3):440-5.
 10. Bijur PE, Latimer CT, Gallagher EJ. Validation of a verbally administered numerical rating scale of acute pain for use in the emergency department. *Acad Emerg Med.* 2003;10(4):390-2.
 11. Eide K, Stubhaug A, Oye I, et al. Continuous subcutaneous administration of the N-methyl-D-aspartic acid (NMDA) receptor antagonist ketamine in the treatment of post-herpetic neuralgia. *Pain.* 1995;61(2):221-8.
 12. Segaran S, Bacthavasalame AT, Venkatesh RR, et al. Comparison of nebulized ketamine with nebulized magnesium sulfate on the incidence of postoperative sore throat. *Anesth Essays Res.* 2018;12(4):885-90.
 13. Charan SD, Khilji MY, Jain R, et al. Inhalation of ketamine in different doses to decrease the severity of postoperative sore throat in surgeries under general anesthesia patients. *Anesth Essays Res.* 2018;12(3):625-9.
 14. Jonkman K, Duma A, Velzen M, et al. Ketamine inhalation. *Br J Anaesth.* 2017;118(2):268-9.
 15. Jonkman K, Duma A, Olofsen E, et al. Pharmacokinetics and Bioavailability of Inhaled Esketamine in Healthy Volunteers. *Anesthesiology.* 2017;127(4):675-83.
 16. Mathew SJ, Shah A, Lapidus K, et al. Ketamine for treatment-resistant unipolar depression: current evidence. *CNS Drugs.* 2012;26(3):189-204.
 17. Yanagihara Y, Ohtani M, Kariya S, et al. Plasma concentration profiles of ketamine and norketamine after administration of various ketamine preparations to healthy Japanese volunteers. *Biopharm Drug Dispos.* 2003;24(1):37-43.
 18. Monaghan. AeroEclipse Breath Actuated Nebulizer. 2019. Available at: <https://www.monaghanmed.com/AeroEclipse-II-BAN>. Accessed on July 18, 2019.
 19. Ari A and Fink JB. Breath-actuated nebulizer versus small-volume nebulizer: efficacy, safety, and satisfaction. *Respir Care.* 2012;57(8):1351-3.

Serratus Anterior Plane Block in the Emergency Department: A Case Series

Judy Lin, MD
Taryn Hoffman, MD
Ksenya Badashova, MD
Sergey Motov, MD
Lawrence Haines, MD

Maimonides Medical Center, Department of Emergency Medicine, Brooklyn, New York

Section Editor: Rick A. McPheeters, DO

Submission history: Submitted August 22, 2019; Revision received October 30, 2019; Accepted November 11, 2019

Electronically published January 21, 2020

Full text available through open access at http://escholarship.org/uc/uciem_cpem

DOI: 10.5811/cpcem.2019.11.44946

This is a case series of six emergency department (ED) patients who received an ultrasound-guided serratus anterior plane block (SAPB) for a variety of painful conditions. Our cases illustrate the feasibility and analgesic efficacy of the SAPB in providing pain management in ED patients with a variety of painful syndromes, including those with severe pain from multiple rib fractures, herpes zoster, and tube thoracostomy placement. In addition, we found no adverse events in our case series. [Clin Pract Cases Emerg Med. 2020;4(1):21–25.]

INTRODUCTION

The serratus anterior plane block (SAPB) is a relatively new compartment block described in the anesthesia literature for the treatment of thoracic wall pain.¹⁻⁴ Numerous studies have demonstrated the efficacy of SAPB for post-thoracotomy and post-mastectomy pain.^{3,5,6} However, of greater interest to emergency physicians (EP) is its use in patients with severe thoracic wall pain for whom opioids or non-steroidal anti-inflammatory drugs may not be an ideal treatment modality.

The SAPB is a sensory nerve block that provides analgesia to the hemithorax from second thoracic (T2) to T9 dermatomes. Anesthetic, usually 25-30 milliliters (mL), is injected under ultrasound-guidance into the serratus anterior plane, either superficial or deep to the serratus anterior muscle (SAM). Within this fascial plane are the lateral cutaneous branches of the thoracic intercostal nerves.^{1,3} Image 1 depicts the external landmarks used to identify the proper injection site for the nerve block. Image 2 reveals the sono-anatomy of the serratus anterior plane and surrounding structures. The video demonstrates the SAPB being performed.

The most common indication for SAPB in the emergency department (ED) is for treatment of rib fracture pain. However, we also report a novel ED indication including

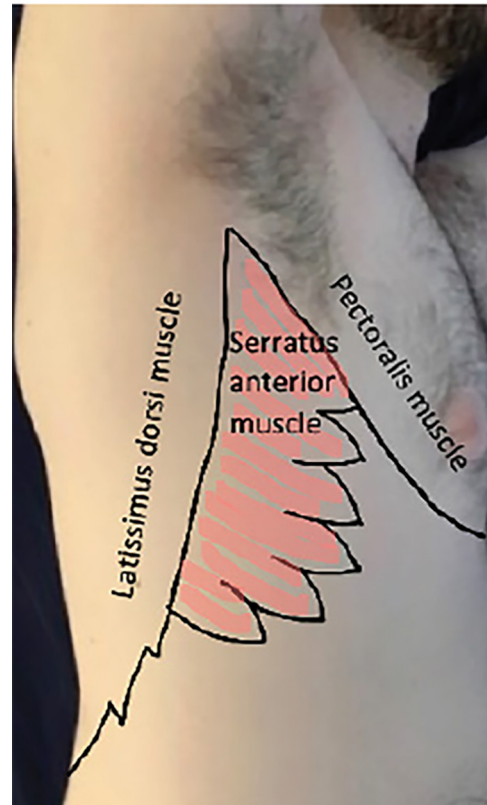


Image 1. Serratus anterior plane block external landmarks.

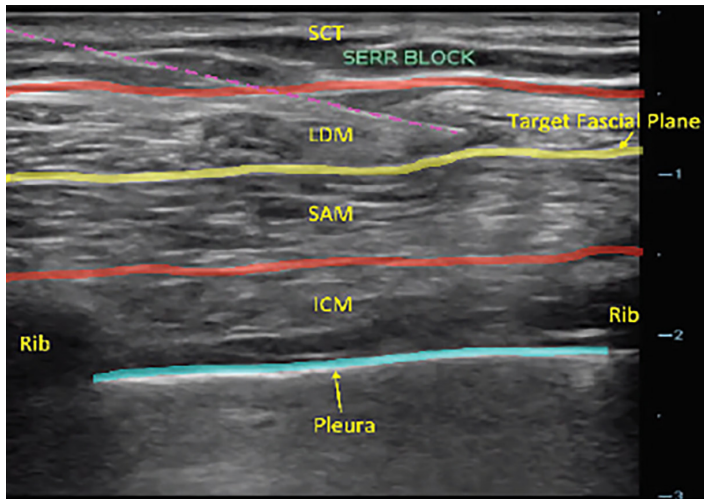


Image 2. Serratus anterior plane block sono-anatomy. Yellow line, target plane; purple-dotted line, needle; blue line, pleura. SCT, subcutaneous tissue; SAM, serratus anterior muscle; LDM, latissimus dorsi muscle; ICM, Intercostal muscle.

treatment of herpes zoster pain and periprocedural pain from tube thoracostomy. Contraindications include local infection or allergy to the local anesthetic. Complications may result in local anesthetic toxicity, pneumothorax, and block failure.^{1,7}

Patients with rib fractures have an increased risk of developing pneumonia, respiratory failure, and death, with mortality ranging from 4–20%.^{8–10} Treatment of such pain with opioids, especially in the elderly population, can lead to delirium and respiratory depression.¹¹ Epidural and paravertebral blocks have been shown to decrease the risk of delirium and opioid requirements in patients with rib fractures, but require a patient to be sitting, lateral recumbent, or in a prone position.^{11,12} The SAPB can be performed in a supine patient and is, therefore, a more feasible alternative in the traumatic ED patient.

The evidence supporting the use of SAPB in the ED is limited to one prior case report in two ED patients for rib fracture pain.¹³ Additionally, there are no case reports describing EP-performed SAPB for tube thoracostomy and thoracic herpes zoster pain, although a few reports exist in the anesthesia literature.^{14,15} Here we present a case series of ED patients who received an EP-performed SAPB, and describe the extent of their injuries, the indication for the SAPB, the efficacy of the nerve block, and whether any adverse events due to the SAPB occurred during their hospital stay.

CASE SERIES

Case 1

An 85-year-old female with a medical history of meningioma, seizures, and hypertension, presented to the ED after a ground-level fall. On physical examination, the patient was

CPC-EM Capsule

What do we already know about this clinical entity?

One prior case series found that emergency physician (EP)-performed serratus anterior plane block (SAPB) can provide analgesia for rib fracture pain.

What makes this presentation of disease reportable?

There is limited literature describing the effects of EP-performed SAPB on a range of different, painful thoracic processes.

What is the major learning point?

SAPB can be an effective analgesic modality for thoracic diseases and injuries including rib fractures, herpes zoster, and thoracostomy placement.

How might this improve emergency medicine practice?

EPs may decide to use SAPB as a method for pain control, especially in patients for whom nonsteroidal anti-inflammatory drugs or opioids may have suboptimal side effects.

uncomfortable and tender to her right flank. Chest radiography (CXR) and computed tomography (CT) demonstrated six posterior rib fractures (T4 to T9). The patient had pain with an intensity rating of 10/10, and reported minimal improvement despite administration of intravenous (IV) morphine sulfate at 8 milligrams (mg). The SAPB was performed using 30 mL of 0.25% bupivacaine deposited superficial to the SAM, with complete relief of pain 10 minutes after the block. The patient did not require any further pain medication in the ED, and received only acetaminophen during her inpatient stay. She was discharged without any use of opioids.

Case 2

A 72-year-old male with medical history of diabetes and hypertension, and daily use of ticagrelor presented to the ED after a fall from standing that day. On physical examination, he was not in any respiratory distress and had tenderness to the left lateral chest wall. CXR showed displaced overriding, left-sided posterolateral fractures of ribs 8 to 11 that was confirmed on CT. SAPB was performed using 30 mL of 0.25% bupivacaine

deposited superficial to the SAM. No other analgesics besides the SAPB were given. The patient reported complete pain relief after the procedure, required no further pain medication in the ED, and was admitted to the trauma service.

Case 3

A 78-year-old female with a history of diabetes and hypertension presented to the ED with six days of “pimples” to her right chest with pain intensity rating of 10/10. On physical examination she had a classic zoster rash localized to lateral chest within the distribution of T5 to T8 dermatomes. The patient had a SAPB performed with 20 mL of 0.5% bupivacaine mixed with 60 mg of solumedrol deposited superficial to the SAM. The patient did not require any other pain medicine during her ED stay and reported significant pain relief. She was discharged on gabapentin 100 mg three times per day upon discharge, and did not have any return visits to the ED.

Case 4

An 89-year-old female with history of atrial fibrillation on aspirin, hypertension, congestive heart failure (CHF), and chronic obstructive pulmonary disease presented to the ED, after being found on the floor by family, complaining of left-sided chest wall pain. On physical examination, the patient was tachypneic with a respiratory rate of 25 breaths per minute, and had left lateral chest wall tenderness. She was placed on bi-level positive airway pressure (BIPAP). Her CXR demonstrated left-sided rib fractures of indeterminate age with prominence of interstitial lung markings bilaterally. Her CT was remarkable for left-sided rib fractures 2 to 11 with a segmental fracture of rib seven and trace left-pleural effusion. Her venous blood gas showed a pH of 7.29 (7.320-7.430) and PCO₂ of 71 millimeters of mercury (mm Hg) (38-50 mm Hg).

She and the family did not want intubation. Despite administration of 650 mg of oral acetaminophen, 10 mg of IV ketorolac, and 25 micrograms of IV fentanyl, the patient continued to complain of severe pain. There was concern that more opioids would worsen her sedation, hypercarbia and respiratory acidosis. Thus, the SAPB was performed with 30 mL of 0.25% bupivacaine with epinephrine deposited deep to the SAM. After the procedure, the patient reported numbness to her left chest wall and complete relief of her pain. She was discharged two days later with a prescription for acetaminophen and lidocaine patch.

Case 5

A 94-year-old female with history of CHF and atrial fibrillation not on anticoagulation presented to the ED in respiratory distress. On arrival, her respiratory rate was 32 breaths per minute and oxygen saturation was 94% on non-rebreather. Her physical examination was significant for a chronically ill-appearing female in respiratory distress with decreased bibasilar breath sounds and poor

air movement. Her B-type natriuretic peptide was 1180 picograms (pg) per mL (<100 pg/mL) and CXR showed new bilateral moderate-sized pleural effusions. She was placed on BIPAP without improvement. The patient and family did not want intubation, so the decision was made to insert a pigtail catheter for drainage of the pleural effusion. Pre-procedurally, a SAPB was performed using 30 mL of 0.25% bupivacaine deposited deep to the SAM. The patient tolerated the procedure well and did not require any pain medication besides the SAPB in the ED.

Case 6

A 60-year-old female with no past medical history presented to the ED with severe, left-sided chest pain two days after a mechanical fall down a flight of stairs. She went to an urgent care center and had a CXR showing five displaced rib fractures and was sent to the ED. On arrival to the ED, the patient was tachypneic with a respiratory rate of 25 breaths per minute. On physical examination, she was uncomfortable appearing with tenderness to palpation over the left lateral ribs. In the ED she was given 4 mg of IV morphine but still could not tolerate lying flat for a chest CT due to worsening pain. A SAPB was performed with 20 mL of 0.25% bupivacaine deposited superficial to the SAM. The patient had significant relief of pain and was able to lie flat almost immediately after the block, which allowed her to tolerate lying supine for a CT that showed anterior rib fractures T5 to T9 and posterior rib fractures T8 to T10. The patient was admitted to the trauma service.

DISCUSSION

Our case series reports on the positive efficacy of the SAPB performed in a series of six patients in the ED either as an alternative or as an adjunct to opioid and non-opioid analgesia. There was no evidence of SAPB-related adverse events.

SAPB was most commonly performed for rib fractures in our case series. Effective analgesia in patients with rib fractures is necessary for the prevention of reduced inspiratory volume and pneumonia.^{9,12} As illustrated in our descriptions, several patients could not achieve adequate pain control with parenteral opioids, but had pain relief with the block. A case series by Durant et al. also found similar improvement in rib fracture pain with the SAPB.¹³

SAPB was also performed for pain control in the treatment of acute herpes zoster pain as well as for procedural pain, ie, from tube thoracostomy, which has not been previously reported in the ED literature, although a few case reports in the anesthesiology literature exist.^{14,15} In our case series, patients had significant pain relief from the EP performed SAPB for both tube thoracostomy and acute herpes zoster. Our study included patients with anesthetic directed both superficial and deep to the SAM. Blanco et al. described similar spread of anesthesia as evidenced on

magnetic resonance imaging for both locations relative to the SAM.¹ Volunteers in Blanco's study also showed similar distribution of chest wall analgesia whether they received superficial or deep injections.¹ Our report indicates that both superficial and deep locations of anesthetic injections can result in effective analgesia.

This case series is limited due to its small size, and as this was not a retrospective chart review, data was not systematically collected. There is the possibility that the physician may not have documented all side effects. These findings do not evaluate the efficacy of the nerve block for all patients and does not identify instances of failed SAPB. In addition, the findings from this case series may not be generalizable. The dosing of parenteral pain medication was not standardized prior to the administration of the SAPB and, therefore, patients may have been underdosed, which could have exaggerated the impact of the nerve block on pain relief. All patients, except those from Cases 2 and 5, received an SAPB that was performed by an ultrasound fellowship-trained EP. The extra training and skill level required for performing this nerve block may limit the generalizability of this case series.

While this case series highlights the benefits of using SAPB in the patients described, further investigation must be pursued to determine the efficacy of and indications for all ED patients receiving a SAPB. Prospective studies evaluating the effectiveness of SAPB compared to traditional treatment for rib fracture pain, thoracostomy pain, and herpes zoster-related pain may further support the use of SAPB in these conditions.

CONCLUSION

This case series found that SAPB was an effective treatment of pain secondary to rib fractures, herpes zoster, and tube thoracostomy with no adverse events. Based on our report, we believe that the SAPB can be an effective tool for the treatment of the aforementioned painful conditions and has several advantages over opioids that may make it an ideal treatment for specific patient populations. Further investigation is still needed to determine the role of SAPB in the management of a variety of patients with acutely painful conditions.

Video. Serratus anterior plane block video. Yellow line = target plane; Purple-dotted line = needle.
SAM, serratus anterior muscle; LDM, latissimus dorsi muscle; ICM, intercostal muscle.

Documented patient informed consent and/or Institutional Review Board approval has been obtained and filed for publication of this case report.

Address for Correspondence: Judy Lin, MD, Maimonides Medical Center, Department of Emergency Medicine, 4802 Tenth Avenue, Brooklyn, NY 11219. Email: julin@maimonidesmed.org.

Conflicts of Interest: By the CPC-EM article submission agreement, all authors are required to disclose all affiliations, funding sources and financial or management relationships that could be perceived as potential sources of bias. The authors disclosed none.

Copyright: © 2020 Lin et al. This is an open access article distributed in accordance with the terms of the Creative Commons Attribution (CC BY 4.0) License. See: <http://creativecommons.org/licenses/by/4.0/>

REFERENCES

1. Blanco R, Parras T, McDonnell JG, et al. Serratus plane block: a novel ultrasound-guided thoracic wall nerve block. *Anaesthesia*. 2013;68:1107-13.
2. Hetta DF and Rezk KM. Pectoralis-serratus interfascial plane block vs thoracic paravertebral block for unilateral radical mastectomy with axillary evacuation. *J Clin Anesth*. 2016;34:91-7.
3. Khalil AE, Abdallah NM, Bashandy GM, et al. Ultrasound-guided serratus anterior plane block versus thoracic epidural analgesia for thoracotomy pain. *J Cardiothorac Vasc Anesth*. 2017;31(1):152-8.
4. Künzli N, Ackermann-Liebrich U, Keller R, et al. Variability of FVC and FEV1 due to technician, team, device and subject in an eight centre study: three quality control studies in SAPALDIA. Swiss Study on Air Pollution and Lung Disease in Adults. *Eur Respir J*. 1995;8(3):371-6.
5. Rahimzadeh P, Imani F, Faiz SHR, et al. Impact of the ultrasound-guided serratus anterior plane block on post-mastectomy pain: a randomised clinical study. *Turk J Anaesthesiol Reanim*. 2018;46(5):388-92.
6. Madabushi R, Tewari S, Gautam SKS, et al. Serratus anterior plane block: a new analgesic technique for post-thoracotomy pain. *Pain Physician*. 2015;18(3):E421-4.
7. May L, Hillermann C, Patil S. Rib fracture management. *BJA Education*. 2016;16(1):26-32.
8. Fligel BT, Luchette FA, Reed RL, et al. Half-a-dozen ribs: the breakpoint for mortality. *Surgery*. 2005;138(4):717-23; discussion 723-5.
9. Sirmali M, Türüt H, Topçu S, et al. A comprehensive analysis of traumatic rib fractures: morbidity, mortality and management. *Eur J Cardiothorac Surg*. 2003;24(1):133-8.
10. Quaday KA. Morbidity and mortality of rib fractures. *J Trauma*. 1995;39(3):617.
11. O'Connell KM, Quistberg A, Tessler R, et al. Decreased risk of delirium with use of regional analgesia in geriatric trauma patients with multiple rib fractures. *Ann Surg*. 2018;268(3):534-40.
12. Mackersie RC, Karagianes TG, Hoyt DB, et al. Prospective evaluation of epidural and intravenous administration of fentanyl for pain control and restoration of ventilatory function following multiple

- rib fractures. *J Trauma*. 1991;31(4):443-51.
13. Durant E, Dixon B, Luftig J, et al. Ultrasound-guided serratus plane block for ED rib fracture pain control. *Am J Emerg Med*. 2017;35(1):197.e3-6.
14. Chu GM and Jarvis GC. Serratus Anterior Plane Block to Address Postthoracotomy and Chest Tube-Related Pain: A Report on 3 Cases. *AA Case Rep*. 2017;8(12):322-5.
15. Ahiskalioglu A, Alici HA, Yayik AM, et al. Ultrasound-guided serratus plane block for management of acute thoracic herpes zoster. *Anaesth Crit Care Pain Med*. 2017;36(5):323-4.

Euglycemic Diabetic Ketoacidosis in Pregnancy

Júlio César Garcia de Alencar, MD
Geovane Wiebelling da Silva, MD
Sabrina Correa da Costa Ribeiro, PhD
Júlio Flavio Meirelles Marchini, PhD
Rodrigo Antonio Brandao Neto, PhD
Heraldo Possolo de Souza, PhD

São Paulo University, Department of Emergency Medicine, São Paulo, Brazil

Section Editor: John Ashurst, DO

Submission history: Submitted May 1, 2019; Revision received July 12, 2019; Accepted September 6, 2019

Electronically published November 15, 2019

Full text available through open access at http://escholarship.org/uc/uciem_cpem

DOI: 10.5811/cpcem.2019.9.43624

The clinical presentation of diabetic ketoacidosis in pregnancy (DKP) is similar to that observed in nonpregnant women, although reports suggest the presenting blood glucose level may not be as high. It is hypothesized that lower, maternal fasting glucose levels are a result of both the fetus and the placenta consuming glucose. We report the case of a 38-year-old woman gravida 2, para 0, abortion 1 with type 1 diabetes who had euglycemic diabetic ketoacidosis and review the literature on DKP, with a focus on diagnosis, treatment, and monitoring of the mother and fetus. [Clin Pract Cases Emerg Med. 2020;4(1):26–28.]

INTRODUCTION

Diabetic ketoacidosis in pregnancy (DKP) is a serious complication that develops because of relative or absolute insulin deficiency and a simultaneous increase in counter-regulatory hormones.¹ DKP is usually observed in patients with type 1 diabetes, but it can also occur in those with type 2 and gestational diabetes.² It is likely to be precipitated by specific factors, such as hyperemesis gravidarum, starvation, infections, nonadherence to insulin therapy, and certain medications (e.g., steroids).^{2,3}

Euglycemic DKP is a rare situation where the patient presents with diabetic ketoacidosis and normal or subnormal blood glucose levels. The putative mechanisms are a combination of glucose consumption by the fetoplacental unit, increased renal glucose losses, increased maternal usage of blood glucose, or a dilutional effect.⁴⁻⁶

CASE REPORT

A 38-year-old woman (gravida 2, para 0, abortus 1) was admitted to the emergency department at 34 weeks of pregnancy with nausea and vomiting. The patient had type 1 diabetes (diagnosed at age seven) treated with insulin glargine and lispro. She had a history of nonadherence to insulin therapy and one previous intensive care unit admission due to DKP at 22 weeks of the same gestation.

The patient sought care complaining of nausea, vomiting, anorexia, and abdominal pain of three days' duration. She had not administered any insulin in the prior seven days. She presented drowsy and dehydrated, with a stable blood pressure of 100/70 millimeters of mercury (mmHg) although tachycardic (140 beats per minute) and tachypneic (32 breaths per minute). The capillary glucose level was 82 milligrams per deciliter (mg/dL) (reference range, <200 mg/dL). Laboratory results showed pH 7.25 (reference range 7.35-7.45), bicarbonate 10 milliequivalent per liter (mEq/L) (reference range 21-27 mEq/L), base excess -14.9 (reference range -2 to +2), blood glucose 80 mg/dL, and urine strongly positive for ketones. She had no signs of infectious processes. Point-of-care abdominal ultrasound showed a single fetus in cephalic presentation with limb movements, a fetal heart rate of 160 beats per minute, and normal amniotic fluid index.

The patient was rehydrated with 5% dextrose and 0.9% sodium chloride solution administered at 500 milliliters per hour (mL/h) for the first hour, followed by 250 mL/h in the succeeding four hours, and then tapered to 125 and 75 mL/h until resolution of diabetic ketoacidosis. Hydration was titrated to ensure a urine output of 0.5 mL/kilogram (kg)/h (measured via indwelling catheter). Potassium was administered at 20 millimoles (mmol)/L/h until the fourth hour of resuscitation. A continuous intravenous (IV) infusion of regular insulin was started at 7 units (U)/h.

Clinical condition and laboratory data were monitored continuously. After 24 hours, laboratory results showed pH 7.44, bicarbonate 21 mEq/L, and blood glucose levels in the normal range. Nevertheless, fetal monitoring showed sustained bradycardia after 22 hours in the ED and the obstetrics team opted for an emergency cesarean section, which was performed uneventfully. The patient was discharged 48 hours after cesarean section with a new insulin prescription. The neonate was discharged 14 days later.

DISCUSSION

The Joint British Diabetes Societies Inpatient Care Group requires laboratory data to confirm the diagnosis of DKP. The diagnostic criteria are as follows: 1) blood ketone level ≥ 3.0 mmol/L or urine ketone level $>2+$; 2) blood glucose level >200 mg/dL or known diabetes mellitus; and 3) bicarbonate level <15.0 mEq/L and/or venous pH < 7.3 .³

The emergency physician must be able to recognize and treat DKP even when the patient is normoglycemic. Nausea, vomiting, and decreased caloric intake in an otherwise healthy pregnant diabetic woman should prompt evaluation to rule out ketosis.⁷ The patient should receive large-bore IV access and continuous monitoring of echocardiogram and pulse oximetry.⁸ Treatment consists of fluid replacement with isotonic saline at 10–15 mL/kg/h for the first hour,¹ after which the rate should be adjusted according to the hemodynamic status of the patient, blood pressure, and urine output. The goals are a systolic blood pressure ≥ 90 mmHg and a urine output 0.5 mL/kg/h, monitored using an indwelling catheter.³

Management of euglycemic DKP follows the same principles as that of regular DKP.³ Insulin should not be delayed except for hypokalemia (see below). Therefore, in euglycemic ketoacidosis, 5% dextrose is necessary from the start of treatment.⁹ At our facility, we start a regular insulin infusion at an initial rate of 0.1 U/kg/h (to a maximum of 15 U/h).³ A priming bolus is not required.³ If metabolic targets are not achieved, the insulin infusion is increased by 1 U/h until ketones reach the desired level.³ Once DKP is resolved, we administer a first dose of subcutaneous rapid-acting insulin and a meal, and discontinue the insulin infusion 30–60 minutes later.³

If the serum potassium is below 3.3 mEq/L, we start potassium chloride replacement before starting the insulin infusion.³ Patients with a normal urine output and serum potassium level <5.5 mEq/L should receive potassium chloride in order to maintain their potassium level in the range of 4–5 mEq/L.³ Although whole-body phosphate is decreased, replacement is not necessary unless the serum level is <1 mg/dL or the patient develops cardiopulmonary effects of hypophosphatemia.³ Administration of bicarbonate is not recommended, as there is no evidence of a beneficial effect and it may be harmful to the patient and the fetus.³

Capillary glucose should be monitored hourly to avoid hypoglycemia. Blood ketones should be monitored hourly for

CPC-EM Capsule

What do we already know about this clinical entity?

Diabetic ketoacidosis in pregnancy (DKP) develops because of relative or absolute insulin deficiency and a simultaneous increase in counter-regulatory hormones.

What makes this presentation of disease reportable?

We report the case and review literature regarding DKP in terms of diagnosis, treatment, and maternal and fetal monitoring.

What is the major learning point?

On suspicion of DKP, the physician must confirm the diagnosis, immediately start treatment, and continuously monitor the mother and fetus.

How might this improve emergency medicine practice?

The emergency physician should be able to recognize and treat diabetic ketoacidosis in pregnant women even if they are normoglycemic.

the first six hours; the goal is to decrease rate ketones by at least 0.5 mmol/L every hour. Other biochemical parameters, such as pH, bicarbonate, and serum potassium, can be monitored every two hours. The goal for bicarbonate levels is an increase of 3 mEq/L every hour.³

The fetal effects of DKP stem from a combination of severe maternal dehydration and acidosis, and may reduce uteroplacental perfusion. Maternal electrolyte imbalances may result in fetal cardiac arrhythmias.¹⁰ The necessary frequency of fetal monitoring is unknown, and no definite recommendations are currently available.¹⁰ Therefore, individualized care with a multidisciplinary approach is recommended. The decision to deliver should be individualized and based on evaluation of the maternal clinical status, laboratory results, fetal gestational age, cardiotocography, and ultrasound.¹¹

CONCLUSION

DKP is a medical emergency. The emergency physician should be able to recognize and treat it even when the patient

is normoglycemic (euglycemic DKP). On suspicion of DKP, the diagnosis should be confirmed with laboratory tests. In addition to basic measures such as airway maintenance and hemodynamic stabilization, treatment consists of large-bore IV access, glucose and insulin infusion, correction of electrolytic imbalances, and continuous maternal and fetal monitoring.

Documented patient informed consent and/or Institutional Review Board approval has been obtained and filed for publication of this case report.

Address for Correspondence: Júlio César Garcia de Alencar, MD, São Paulo University, Department of Emergency Medicine, 225 Eneas de Carvalho Aguiar, 05403-000. Email: julio.alencar@hc.fm.usp.br.

Conflicts of Interest: By the CPC-EM article submission agreement, all authors are required to disclose all affiliations, funding sources and financial or management relationships that could be perceived as potential sources of bias. The authors disclosed none.

Copyright: © 2020 Garcia de Alencar et al. This is an open access article distributed in accordance with the terms of the Creative Commons Attribution (CC BY 4.0) License. See: <http://creativecommons.org/licenses/by/4.0/>

REFERENCES

1. Kitabchi AE, Umpierrez GE, Miles JM, et al. Hyperglycemic crises in adult patients with diabetes. *Diabetes Care*. 2009;32(7):1335-43.
2. Sibai BM and Viteri OA. Diabetic ketoacidosis in pregnancy. *Obstet Gynecol*. 2014;123(1):167-78.
3. Joint British Diabetes Societies Inpatient Care Group. The Management of Diabetic Ketoacidosis in Adults. 2013. Available at: http://www.diabetologists-abcd.org.uk/JBDS/JBDS_IP_DKA_Adults_Revised.pdf. Accessed on July 10, 2019.
4. Munro JF, Campbell IW, McCuish AC, et al. Euglycaemic diabetic ketoacidosis. *Br Med J*. 1973;9(2):578-80.
5. Guo RX, Yang LZ, Li LX, et al. Diabetic ketoacidosis in pregnancy tends to occur at lower blood glucose levels: case-control study and a case report of euglycemic diabetic ketoacidosis in pregnancy. *J Obstet Gynaecol Res*. 2008;34(3):324-30.
6. Chico M, Levine SN, Lewis DF. Normoglycemic diabetic ketoacidosis in pregnancy. *J Perinatol*. 2008;28(4):310-2.
7. Barski L, Eshkoli T, Brandstaetter E, et al. Euglycemic diabetic ketoacidosis. *Eur J Inter Med*. 2019;63:9-14.
8. Wass J and Owen K. (2014). Diabetic hyperglycaemic emergencies. *Oxford Handbook of Endocrinology and Diabetes*, 3rd ed. Oxford, United Kingdom: Oxford University Press.
9. Montoro MN, Myers VP, Mestman JH, et al. Outcome of pregnancy in diabetic ketoacidosis. *Am J Perinatol*. 1993;10(1):17-20.
10. de Veciana M. Diabetes ketoacidosis in pregnancy. *Semin Perinatol*. 2013;37(4):267-73.
11. Mohan M, Baagar KAM, Lindow, S. Management of diabetic ketoacidosis in pregnancy. *Obstet Gynaecol*. 2017;19:55-62.

Point-of-care Ultrasound Diagnosis of Bilateral Patellar Tendon Rupture

Kathleen Ogle, MD*
Sohaib Mandoorah, MBBS*
Matthew Fellin, MD*
Hamid Shokoohi, MD, MPH*
William Probasco, MD†
Keith Boniface, MD*

*George Washington University, Department of Emergency Medicine, Washington, District of Columbia

†George Washington University, Department of Orthopedics, Washington, District of Columbia

Section Editor: Rick A. McPheeters, DO

Submission history: Submitted June 21, 2019; Revision received September 19, 2019; Accepted October 2, 2019

Electronically published January 24, 2020

Full text available through open access at http://escholarship.org/uc/uciem_cpem

DOI: 10.5811/cpcem.2019.10.44194

Musculoskeletal complaints are one cornerstone of urgent issues for which orthopedic and emergency physicians provide care. Ultrasound can be a useful diagnostic tool to help identify musculoskeletal injuries. We describe a case of bilateral patellar tendon rupture that presented after minor trauma, and had the diagnosis confirmed at the bedside by point-of-care ultrasound. Physicians caring for patients with orthopedic injuries should be familiar with the use of ultrasound to diagnose tendon ruptures. [Clin Pract Cases Emerg Med. 2020;4(1):29–31.]

INTRODUCTION

Musculoskeletal complaints are common in emergency medicine.¹ On initial evaluation in the emergency department (ED), clinical assessment of musculoskeletal problems is comprised of history, physical examination, and plain radiography (which is limited in ability to evaluate soft tissue injuries). An alternative to plain radiography includes magnetic resonance imaging (MRI), a costly, time-consuming, and much less readily available modality. MRI provides excellent anatomic detail but only provides static images, and can be challenging to obtain from the ED. Ultrasound has been used to evaluate musculoskeletal structures and offers bedside static and dynamic imaging of musculoskeletal structures that is rapid and inexpensive.² The American College of Emergency Physicians (ACEP) Emergency Ultrasound Guidelines address the use of ultrasound for a wide range of indications, both diagnostic and therapeutic, including musculoskeletal injuries.³ This article discusses a case in which point-of-care ultrasound (POCUS) led to the diagnosis of bilateral patellar tendon rupture following minor trauma.

CASE REPORT

A 38-year-old man presented to the ED complaining of bilateral knee pain and inability to ambulate after hopping off

a ledge that was a foot or two off the ground. Upon landing, he immediately felt knee pain bilaterally, and was unable to walk. In the ED he denied any prior episodes of knee injury or pain, or any past medical history or medications – specifically no connective tissue disease or steroid use. On examination, he had swelling and a palpable defect inferior to the patella bilaterally. His neurovascular exam was normal; however, he was unable to actively extend either of his legs at the knees or lift his lower legs off the stretcher. POCUS using a high-frequency linear probe (15-8 megahertz, Sonosite XPorte, Bothell, WA) revealed bilateral patellar tendon ruptures with proximal retraction of the patella (Image 1; Video 1 and 2). Both videos are oriented in the longitudinal plane images, as the ones captured in the transverse plane did not add diagnostic value in this case and the defects were well visualized in the longitudinal plane.

He was then evaluated by orthopedics and noted to have visible deformity of bilateral knees suggestive of bilateral patella alta. He was able to contract his quadriceps bilaterally but unable to perform straight leg raise bilaterally. He was otherwise neurovascularly intact. Plain radiographs were significant for bilateral patella alta (Image 2).

The patient was subsequently admitted to the orthopedics service and underwent successful operative repair of bilateral ruptured patellar tendons.

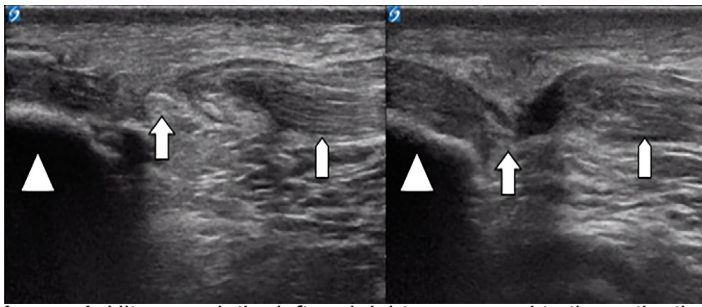





Image 1. Ultrasound: the left and right correspond to the patient's left and right patellar tendons. Orientation marker is directed toward the patient's head and the probe is placed just at the inferior edge of the patella in a sagittal plane.

-  Hyperchoic cortex of the patella with resulting anechoic shadow behind
-  Disruption of the patellar tendon fibers on the left and right patellar tendons
-  Normal fibrillar appearance of patellar tendons on the patient's left and right knees

DISCUSSION

The extensor mechanism of the knee is essential to the ability to walk. This extensor mechanism can be disrupted by a rupture of the patellar or quadriceps tendon, or by a fracture of the patella itself with rupture of the capsule. In patients under the age of 40, patellar tendon rupture is most common in athletic adults and most often unilateral.⁴ Bilateral patellar tendon ruptures are exceedingly rare, especially in patients without underlying disease. Most cases of patellar tendon ruptures occur in patients with a predisposition towards tendinopathy due to diabetes, renal failure, lupus, rheumatoid arthritis, or corticosteroids.^{4,5,6}

In the urgent setting, the use of ultrasound can expedite diagnosis and mobilize consultants to facilitate excellent patient care. Ultrasound is ideal due to its portability, low cost, and lack of ionizing radiation. Extremity and tendon injuries are especially amenable to ultrasound due to the superficial location of these structures.^{7,8} To ultrasound the extensor tendons of the knee, a high-frequency linear probe is used to scan in longitudinal and transverse planes. In a patient with a unilateral injury, the asymptomatic extremity may be examined for comparison.

Tendons visualized by ultrasound have a bright fibrillar structure and normally exhibit the property of anisotropy, which means their echogenicity varies depending on the angle of the ultrasound beam in relation to the tendon. Tendinous fibers will appear more echogenic or brighter if the ultrasound is perpendicular but will become less echogenic as the angle decreases. This is important in the evaluation of tendons because a ruptured tendon will appear hypoechoic or in some cases anechoic. In a ruptured tendon, hypoechoic or anechoic areas and discontinuity of the fibrillar lines with frayed appearance may be

CPC-EM Capsule

What do we already know about this clinical entity?

Bilateral patellar tendon rupture is rare in the absence of predisposing conditions for tendinous injury such as lupus, rheumatoid arthritis, diabetes, renal disease, or chronic steroid use.

What makes this presentation of disease reportable?

This atypical presentation of disease with minimal mechanism is unexpected in a young, healthy male patient. Immediate visualization of the tendon rupture facilitates proper specialty care.

What is the major learning point?

Systematic use of point-of-care ultrasound for musculoskeletal injuries is fast, cost-effective, and allows for dynamic assessment of the tendon mechanism.

How might this improve emergency medicine practice?

Given its low cost and ease of use, point-of-care ultrasonography for musculoskeletal injury may expedite specialty consultation and treatment, particularly in resource limited locations.

appreciated. Hypoechoic surrounding edema and hematoma may also be seen. Dynamic ultrasound of tendons during contraction of the attached muscle may aid in demonstrating partial and complete rupture by magnifying the defect.⁹

While there is a learning curve to performing this examination, the ACEP Guidelines for Point-of-Care and Clinical Ultrasound suggest emergency physicians should be able to recognize tendon rupture and laceration.³ According to Li et al., "Despite its benefits and widespread adoption in general medicine and other specialties, however, ultrasonography is not as well adapted as a diagnostic and research tool in orthopedic surgery."¹⁰ This suggests a potential symbiotic relationship that is likely to improve patient care when experienced sonographer clinicians identify pathology in collaboration with specialist colleagues. In this case, POCUS combined with history, physical exam, and plain radiographs demonstrated bilateral patellar tendon ruptures in a patient without predisposing factors, expediting orthopedic evaluation and surgical repair.

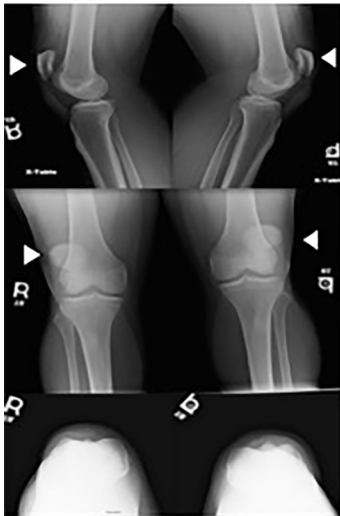

Image 2. Radiograph of bilateral knees demonstrating patella alta (arrows).

CONCLUSION

Extensor mechanism ruptures are high-risk events that require surgical intervention. We describe a case of a 38-year-old healthy man with bilateral patellar tendon rupture diagnosed at the bedside using point-of-care ultrasound. This case highlights the importance of POCUS for musculoskeletal indications, illustrating how physicians can collaborate in the use of ultrasound to complement other traditional musculoskeletal examination modalities to expedite the diagnosis and treatment of this orthopedic surgical urgency.

Video 1. Right patellar tendon video demonstrating rupture.

Video 2. Left patellar tendon video demonstrating rupture.

Documented patient informed consent and/or Institutional Review Board approval has been obtained and filed for publication of this case report.

Address for Correspondence: Kathleen Ogle, MD, George Washington University, Department of Emergency Medicine, 2120 L Street NW, Suite 450, Washington, DC 20037. Email: kogle@mfa.gwu.edu.

Conflicts of Interest: By the CPC-EM article submission agreement, all authors are required to disclose all affiliations, funding sources and financial or management relationships that could be perceived as potential sources of bias. The authors disclosed none.

Copyright: © 2020 Ogle et al. This is an open access article distributed in accordance with the terms of the Creative Commons Attribution (CC BY 4.0) License. See: <http://creativecommons.org/licenses/by/4.0/>

REFERENCES

1. Gaieski DF, Mehta S, Hollander JE, et al. Low-severity musculoskeletal complaints evaluated in the emergency department. *Clin Orthop Relat Res.* 2008;466(8):1987-95.
2. Warden SJ, Kiss ZS, Malara FA, et al. Comparative accuracy of magnetic resonance imaging and ultrasonography in confirming clinically diagnosed patellar tendinopathy. *Am J Sports Med.* 2007;35(3):427-36.
3. Ultrasound guidelines: Emergency, point-of-care and clinical ultrasound guidelines in medicine. *Ann Emerg Med.* 2017;69(5):e27-54.
4. Pengas IP, Assiotis A, Khan W, et al. Adult native knee extensor mechanism ruptures. *Injury.* 2016;47(10):2065-70.
5. Mencia M, Edwards A, Ali T. Spontaneous bilateral patellar tendon ruptures in a patient with chronic renal failure: a case report. *Internet J Emerg Med.* 2012;7(2).
6. Enad JG. Patellar tendon ruptures. *South Med J.* 1999;92(6):563-6.
7. Berg K, Peck J, Boulger C, et al. Patellar tendon rupture: an ultrasound case report. *BMJ Case Rep.* 2013;2013. pii:bcr2012008189.
8. Hall BT and McArthur T. Ultrasound diagnosis of a patellar tendon rupture. *Mil Med.* 2010;175(12):1037-8.
9. Griffin MJ, Olson K, Heckmann N, et al. Realtime Achilles Ultrasound Thompson (RAUT) test for the evaluation and diagnosis of acute Achilles tendon ruptures. *Foot Ankle Int.* 2017;38(1):36-40.
10. Li X, Yi PH, Curry EJ, et al. Ultrasonography as a diagnostic, therapeutic, and research tool in orthopaedic surgery. *J Am Acad Orthop Surg.* 2018;26(6):187-96.

Pediatric Herpes Zoster

Daniel Quesada, MD*†

Larissa Morsky, MD†

Phillip Aguiñiga-Navarrete, RA†

Madison B. Garrett, RA†

*LAC+USC Medical Center, Department of Emergency Medicine, Los Angeles, California

†Kern Medical, Department of Emergency Medicine, Bakersfield, California

Section Editor: Rick A. McPheeters, DO

Submission history: Submitted July 1, 2019; Revision received September 25, 2019; Accepted October 2, 2019

Electronically published December 17, 2019

Full text available through open access at http://escholarship.org/uc/uciem_cpchem

DOI: 10.5811/cpchem.2019.10.44301

A 10-year-old male vaccinated against varicella had developed left-sided rashes on his thoracic region in single dermatomal distribution, which is consistent with herpes zoster. Although herpes zoster is uncommon in children, especially with the current vaccination regimen, this case report serves as a reminder to consider it in one's differential diagnoses, even in the immunocompetent, fully immunized pediatric patient. This is a case report of a previously healthy, fully vaccinated child who developed herpes zoster. [Clin Pract Cases Emerg Med. 2020;4(1):32–34.]

INTRODUCTION

The varicella vaccination was introduced in 1995 as a one-time shot to be given at 12-18 months.¹ The current Centers for Disease Control and Prevention recommendations are a two-shot series given between 12-15 months and again at four-six years.² The duration of immune-protection ranges from 6-20 years.² One study demonstrated a decrease in risk of four to 12 times in vaccinated children under 10.¹ The vaccine has been proven beneficial in largely preventing herpes zoster (HZ) and blunting the course of the infection. It was reported that children who were vaccinated and presented with HZ were likely to be less than 10, have lower associated pain, and a zoster rash in the lumbosacral region with fewer vesicles that were smaller in size.¹

There has been a reported higher incidence of HZ in children vaccinated after the age of five as compared to those vaccinated between 12-18 months.³ A retrospective study demonstrated a 2.1-year average incidence of HZ after vaccination.³ Prior to vaccination, the incidence of HZ was 46 per 100,000 cases for children under 14.³ With the increase in the number of shots from 1995 to today, there has been a decreased incidence of HZ from 2003 to 2014, 74 per 100,000 person years for unvaccinated children and 38 per 100,000 person years for children who are vaccinated.⁴

One case-control study identified race as a risk factor for vaccinated children developing HZ. Black children were at a lower risk than White or Asian.⁵ Incidents were found to be highest in White non-Hispanic children followed by Hispanic

children.¹ Retrospective studies also demonstrated that children vaccinated at one to two years had an increased chance of HZ when compared to their unvaccinated counterparts.⁴ Although there have been cases of HZ caused by wild-type virus and vaccine-strain virus in children who have been vaccinated, there is still consistently strong clinical support for the routine use of the varicella vaccine. Even in vaccinated children, wild-type virus was more likely to be isolated than the vaccine strain.^{3,5-11} With the changes in the shot series, there has been a decrease in the risk of wild-type virus causing HZ.³

CASE REPORT

A previously healthy 10-year-old Hispanic male presented with a chief complaint of a rash on his left chest and back for three days. The rash began gradually, which was described as both itching and burning in sensation. Prior to the onset of the rash, the patient stated that he had felt a burning sensation to the area where the rash eventually developed. According to his parents, the patient was fully vaccinated, including the varicella vaccine, and had never contracted chicken pox. They denied any sick contacts at home. The patient had no other known risk factors such as trauma, family history of HZ, autoimmune diseases, or other malignancies that would have predisposed him to HZ. All reviews of systems were negative.

Physical examination was remarkable for grouped vesicles noted on the left anterior chest and healing vesicles with eschars noted on the left upper back (Image). The rash appeared along the sixth thoracic dermatome. The rash was

painful, blanched with palpation, and was without induration or discharge. Vital signs and the remainder of the physical examination were unremarkable. Diagnosis of HZ was clinical, given the classic unilateral dermatomal distribution and vesicular appearance of the rash. The patient remained stable during his emergency department (ED) visit and was discharged home with a prescription for acyclovir and acetaminophen for anticipated neuropathic pain, generally associated with HZ. Patient was advised to follow up with his pediatrician in one week.

The patient's mother was contacted approximately three weeks after his ED visit using a Spanish-speaking phone translator. The mother informed the author that the rash had lasted approximately eight days and the lesions were completely healed the following week. She reported that he no longer had any pain at the site of the rash. Of note, his younger sister, who was 10 months old, developed a rash all over her body, including back, buttocks, and legs, and was diagnosed with varicella.

DISCUSSION

Herpes zoster, also known as shingles, is a condition caused by reactivation of the varicella zoster virus, which causes varicella or chicken pox, the result of primary infection by the virus. Although HZ incidence has significantly fallen since the introduction of the live-attenuated varicella vaccination in 1995 to prevent primary infection, varicella primarily affects children and is self-limited. While vaccinated children do not present with varicella, both vaccine-type and wild-type viruses remain dormant in sensory ganglia and can be reactivated, usually during times of stress, such as in trauma or malignancy.

HZ is typically seen in older individuals or those with decreased cell-mediated immunity. When infection occurs in younger age groups, it tends to be less severe. The reactivation typically presents initially with a prodrome of pain and paresthesia, followed by a macular rash. After approximately 24 hours, a painful vesicular rash erupts, confines to one dermatome, and eventually ruptures, crusts, and then resolves. Itching, pain and paresthesia persist throughout the disease course and can be described as having a burning, sharp and lancinating sensation.

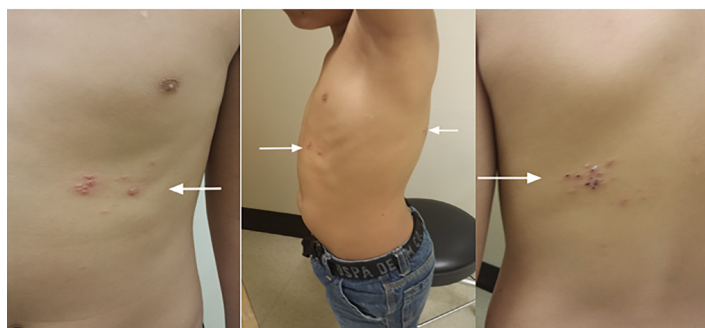


Image. Vesicular rash in the left thoracic region distributed in single dermatome consistent with herpes zoster (arrows).

CPC-EM Capsule

What do we already know about this clinical entity?

Herpes Zoster is uncommon in children after the advent of the Varicella vaccine in 1995 and current CDC prevention recommendations of a two-vaccine series.

What makes this presentation of disease reportable?

Despite being fully vaccinated and otherwise healthy with no prior history of primary varicella infection, a child may develop Herpes Zoster secondary to Varicella-zoster virus reactivation.

What is the major learning point?

It is important for the clinician to keep the differential broad when evaluating pediatric rashes despite vaccine history, age, or absence of history of primary varicella infection.

How might this improve emergency medicine practice?

The ability to diagnose this disease process in a timely manner facilitates the implementation of immediate treatment which may shorten the course of illness and reduce post herpetic sequelae.

There can also be associated hyperesthesia and hyperalgesia. Post-herpetic neuralgia can follow after a resolved outbreak and can persist from a few months to indefinitely.¹² Ocular complications can also occur in patients with involvement of the ophthalmic division of the trigeminal nerve.

Treatment typically consists of antiviral agents such as oral acyclovir if received within 72 hours after the onset of a rash, which decrease the duration of the rash and severity of pain.¹³ The utility of antiviral therapy on patients presenting beyond the 72-hour period has not been amply studied. However, despite insufficient evidence, antiviral therapy is recommended for patients presenting 72 hours after the onset of rashes, including new vesicle formation, ocular, neurologic or cutaneous complications, and immunocompromise.¹⁴ While famciclovir and valacyclovir are preferred due to simpler dosing schedules and pharmacokinetic characteristics, patients should be treated with acyclovir if neither are available.¹⁴

CONCLUSION

Herpes zoster incidence has become increasingly uncommon in EDs of developed nations with the advent of the varicella vaccine, but it can still occur and should be considered in an emergency physician's differential even in immunocompetent, fully vaccinated children.

Documented patient informed consent and/or Institutional Review Board approval has been obtained and filed for publication of this case report.

Address for Correspondence: Daniel Quesada, MD, Kern Medical, Department of Emergency Medicine, 1700 Mount Vernon, Bakersfield, CA 93306 Email: Daniel.queada@kernmedical.com.

Conflicts of Interest: By the CPC-EM article submission agreement, all authors are required to disclose all affiliations, funding sources and financial or management relationships that could be perceived as potential sources of bias. The authors disclosed none.

Copyright: © 2020 Quesada et al. This is an open access article distributed in accordance with the terms of the Creative Commons Attribution (CC BY 4.0) License. See: <http://creativecommons.org/licenses/by/4.0/>

REFERENCES

1. Civen R, Marin M, Zhang J, et al. The incidence and clinical characteristics of herpes zoster among children and adolescents after implementation of varicella vaccination. *Pediatr Infect Dis J*. 2009;28(11):954-9.
2. Centers for Disease Control and Prevention. Chicken Pox | Vaccination | Varicella. Available at: <https://www.cdc.gov/chickenpox/vaccination.html>. Accessed June 20, 2019.
3. Goldman GS and King PG. Review of the United States universal varicella vaccination program: herpes zoster, incidence rates, cost-effectiveness, and vaccine efficacy based primarily on the Antelope Valley Varicella Active Surveillance Project data. *Vaccine*. 2013;31(13):1680-94.
4. Weinmann S, Naleway AL, Koppolu P, et al. Incidence of Herpes Zoster Among Children: 2003–2014. *Pediatrics*. 2019;144(1):e2018917.
5. Silver B and Zhu H. Varicella zoster virus vaccines: potential complications and possible improvements. *Virology*. 2014;29(5):265-73.
6. Tseng HF, Smith N, Marcy SM, et al. Incidence of herpes zoster among children vaccinated with varicella vaccine in a prepaid health care plan in the United States, 2002-2008. *Pediatr Infect Dis J*. 2009;28(12):1069-72.
7. Tseng HF, Smith N, Marcy SM, et al. Risk factors of herpes zoster among children immunized with varicella vaccine: results from a nested case-control study. *Pediatr Infect Dis J*. 2010;29(3):205-8.
8. Ulman CA, Trevino JJ, Gandhi RK. Herpes zoster in a 2-year-old vaccinated against varicella. *Dermatol Online J*. 2014;20(1):21259.
9. Vázquez M, LaRussa PS, Gershon AA, et al. The effectiveness of the varicella vaccine in clinical practice. *N Engl J Med*. 2001;344(13):955-60.
10. Weinmann S, Chun C, Schmid DS, et al. Incidence and clinical characteristics of herpes zoster among children in the varicella vaccine era, 2005-2009. *J Infect Dis*. 2013;208(11):1859-68.
11. Wen SY and Liu WL. Epidemiology of pediatric herpes zoster after varicella infection: a population based study. *Pediatrics*. 2015;135(3):e565-71.
12. Nurmikko T. Clinical features and pathophysiologic mechanisms of postherpetic neuralgia. *Neurology*. 1995;45:S54-5.
13. Stankus SJ, Dlugopolski M, Packer D. Management of herpes zoster (shingles) and postherpetic neuralgia. *Am Fam Physician*. 2000;61(8):2437-44.
14. Schmader K. Herpes zoster. *Ann Intern Med*. 2018;169(3):ITC19-31.

Endometriosis: An Unusual Cause of Bilateral Pneumothoraces

Christopher S. Sampson, MD*
Kathleen White, MD†

*University of Missouri-Columbia, Department of Emergency Medicine, Columbia, Missouri
†University of Missouri-Columbia, Department of Surgery, Columbia, Missouri

Section Editor: Anna McFarlin, MD

Submission history: Submitted September 9, 2019; Revision received November 6, 2019; Accepted November 11, 2019

Electronically published January 24, 2020

Full text available through open access at http://escholarship.org/uc/uciem_cpchem

DOI: 10.5811/cpcem.2019.11.45061

A 27-year-old female presented to the emergency department with sudden onset shortness of breath. A diagnosis of bilateral catamenial pneumothoraces was made following chest radiograph. Catamenial pneumothorax is a recurrent spontaneous pneumothorax that occurs in 90% of affected women 24-48 hours after the onset of their menstruation; 30-50% of cases have associated pelvic endometriosis. Symptoms can be as simple as chest pain or as severe as the presentation of this patient who was initially found to be in significant respiratory distress. [Clin Pract Cases Emerg Med. 2020;4(1):35–37.]

INTRODUCTION

Catamenial pneumothorax is a recurrent spontaneous pneumothorax that occurs in 90% of affected women 24-48 hours after the onset of their menstruation. Thirty to fifty percent of cases have associated pelvic endometriosis. Symptoms can be as simple as chest pain or as severe as the symptoms with which this patient presented.¹ The number of known episodes of catamenial pneumothorax prior to treatment average between two and eight.² We describe a rare presentation of catamenial pneumothorax given the bilateral presentation.

CASE REPORT

A 27-year-old female presented to the emergency department (ED) by emergency medical services with a complaint of sudden-onset shortness of breath. She was working as a housekeeper when she had a sudden onset of severe chest pain and dyspnea. She reported being unable to take deep breaths since symptom onset. The patient had similar episodes in the past with a negative workup when she saw her doctor. Vital signs were notable for a respiratory rate of 28 breaths per minute and a pulse oximetry 95% on room air. Pulse rate and blood pressure were normal. On presentation, the patient was bent over in a chair in obvious distress. Lung sounds were diminished bilaterally when examined in a noisy hallway. A chest radiograph (CXR) was obtained (Image 1). Following CXR review, the patient was moved to a stretcher and placed on 100% oxygen via non-rebreather mask.

Upon further questioning a history of endometriosis was obtained along with a temporal relationship noted between

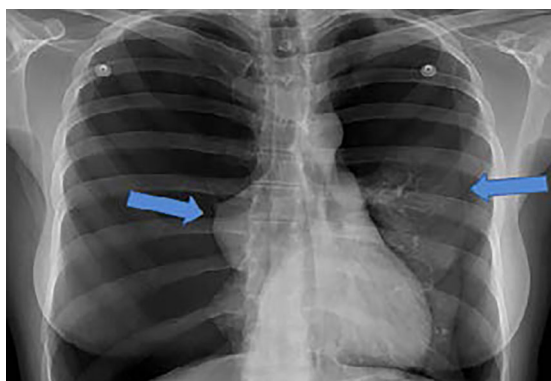


Image 1. Posterior-anterior chest radiograph with bilateral pneumothoraces. Lung marking indicated by arrows.

her previous symptoms and her menstrual cycle. She was diagnosed with bilateral catamenial pneumothoraces, and bilateral chest tubes were placed without difficulty (Image 2). The patient was admitted to the medical inpatient service with pulmonary consultation. Thoracic endometriosis was confirmed following video-assisted thoracic surgery (VATS) with talc pleurodesis on hospital day nine.

DISCUSSION

Catamenial pneumothorax (CP) is a rare disease with a poorly understood etiology that is commonly misdiagnosed as a spontaneous pneumothorax. Theories exist to explain its development but without any consensus. The disease is characterized by recurrent spontaneous pneumothorax that occurs

24 hours preceding or 72 hours following the onset of menses.^{3,4} Thus, it should be considered in the differential diagnosis of any menstruating female with recurrent pneumothorax.

CP was first characterized in the literature in 1958 by Maurer et al. as a recurrent, right-sided pneumothorax related to menstruation.⁵ In 1972 Lillington et al. termed the condition catamenial pneumothorax. Their report described a set of common clinical features among the cases including right-sided pneumothorax, close temporal relationship with onset of menses, and later onset closer to the fourth decade of life.⁶ In 2011 Haga et al. created a scoring system to help better distinguish CP from a spontaneous pneumothorax. This system included four clinical variables: side of pneumothorax; history of pelvic endometriosis; patient age; and smoking history. Right-sided pneumothorax had the highest odds ratio for CP.⁷

Previous literature has suggested that 3-6% of spontaneous pneumothoraces in women met the definition of CP; however, more recent studies have suggested that the actual rate is much higher and could be as high as 35%, although many of these studies were done on patients undergoing surgery.^{4,7-9} The vast majority of cases of CP described in the literature have been unilateral with an estimated 85-95% being exclusively right sided. Left-sided CP is possible but rare, with bilateral CP being even more rare.⁹

Given the patient's reported previous symptoms in relation to her menstrual cycle, it would be possible she had recurrent small pneumothoraces that spontaneously resolved. Her workup also occurred in the outpatient setting, and it was unknown whether any imaging had ever been obtained prior to the ED visit. VATS is the preferred procedure in these patients with attention not only given to lungs and thoracic cavity, but to the diaphragm as well. The diaphragm can develop defects or perforations from damage caused by the endometrial tissue.¹¹

CONCLUSION

Although catamenial pneumothorax is a rare cause of spontaneous pneumothorax in women, it should be an important consideration. Often with good history taking, including temporal relation to menstrual cycle, the diagnosis

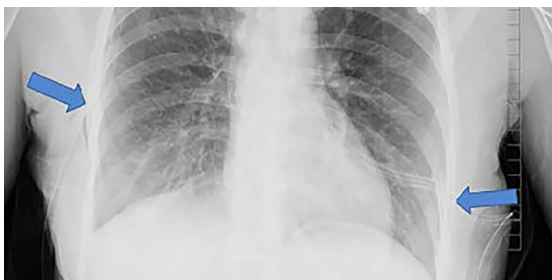

Image 2. Chest radiograph following bilateral chest tube placement for bilateral pneumothoraces. Arrows mark chest tube insertion sites.

CPC-EM Capsule

What do we already know about this clinical entity?

Endometriosis is a rare cause of pneumothorax in young women when there is pulmonary and diaphragmatic involvement.

What makes this presentation of disease reportable?

Bilateral catamenial pneumothoraces is an extremely unusual presentation of this disease.

What is the major learning point?

In any menstruating female with recurrent chest pain that is temporally related to her menstrual cycle who develops a pneumothorax, consider endometriosis as a cause.

How might this improve emergency medicine practice?

Recognition of catamenial pneumothorax can help patients obtain appropriate consultation for definitive care.

may become more apparent. Initial management is similar to any other pneumothorax, but may include surgical management to prevent recurrence.

Documented patient informed consent and/or Institutional Review Board approval has been obtained and filed for publication of this case report.

Address for Correspondence: Christopher Sampson, MD, University of Missouri-Columbia, Department of Emergency Medicine, 1 Hospital Drive DC029.1, Columbia, MO 65212. Email: sampsoncs@health.missouri.edu.

Conflicts of Interest: By the CPC-EM article submission agreement, all authors are required to disclose all affiliations, funding sources and financial or management relationships that could be perceived as potential sources of bias. The authors disclosed none.

Copyright: © 2020 Sampson et al. This is an open access article distributed in accordance with the terms of the Creative Commons Attribution (CC BY 4.0) License. See: <http://creativecommons.org/licenses/by/4.0/>

REFERENCES

1. Aissa S, Benzarti W, Alimi F, et al. Catamenial pneumothorax revealing diaphragmatic endometriosis: a case report and revue of literature. *Pan Afr Med J*. 2017;27:112.
2. Tulandi T, Sirois C, Sabban H, et al. Relationship between catamenial pneumothorax or noncatamenial pneumothorax and endometriosis. *J Minim Invasive Gynecol*. 2018;25(3):480-3.
3. Rousset-Jablonski C, Alifano M, Plu-Bureau G, et al. Catamenial pneumothorax and endometriosis-related pneumothorax: clinical features and risk factors. *Hum Reprod*. 2011;26(9):2322-9.
4. Alifano M, Jablonski C, Kadiri H, et al. Catamenial and noncatamenial, endometriosis-related or nonendometriosis-related pneumothorax referred for surgery. *Am J Respir Crit Care Med*. 2007;176(10):1048-53.
5. Maurer ER, Schaal JA, Mendez FL Jr. Chronic recurring spontaneous pneumothorax due to endometriosis of the diaphragm. *J Am Med Assoc*. 1958;168(15):2013-4.
6. Lillington GA, Mitchell SP, Wood GA. Catamenial pneumothorax. *JAMA*. 1972;219(10):1328-32.
7. Haga T, Kataoka H, Ebana H, et al. Thoracic endometriosis-related pneumothorax distinguished from primary spontaneous pneumothorax in females. *Lung*. 2014;192(4):583-7.
8. Shrestha B, Shrestha S, Peters P, et al. Catamenial pneumothorax, a commonly misdiagnosed thoracic condition: Multicentre experience and audit of a small case series with review of the literature. *Heart Lung Circ*. 2019;28(6):850-7.
9. Marshall MB, Ahmed Z, Kucharczuk JC, et al. Catamenial pneumothorax: optimal hormonal and surgical management. *Eur J Cardiothorac Surg*. 2005;27(4):662-6.
10. AlAqeel S, Al Jehani Y, AlMuhaiish M. Bilateral catamenial hemopneumothorax: diagnostic & management challenges. *Int J Surg Case Rep*. 2019;61:271-4.
11. Marjanski T, Sowa K, Czapl A, et al. Catamenial pneumothorax: a review of the literature. *Kardiochir Torakochirurgia Pol*. 2016;13(2):117-21.

Bilateral Luxatio Erecta Humeri With Acute Anterior-inferior Re-dislocation

Adam Kessler, DO*
Jacob Hinkley, DO*
David Houserman, BS†
Jacob Lytle, DO*
Michael Sorscher, MD*

*Ascension Genesys Hospital, Department of Orthopedics, Grand Blanc, Michigan
†Des Moines University, Des Moines, Iowa

Section Editor: Rick A. McPheeters, DO

Submission history: Submitted June 22, 2019; Revision received September 8, 2019; Accepted September 13, 2019

Electronically published November 19, 2019

Full text available through open access at http://escholarship.org/uc/uciem_cpem

DOI: 10.5811/cpem.2019.9.44205

Luxatio erecta is a description for a specific and rare type of shoulder dislocation where the humeral head dislocates directly inferior. This rare form of glenohumeral dislocation accounts for only 0.5% of shoulder dislocations. It is even less common for both shoulders to be bilaterally dislocated inferiorly with the characteristic “hands up” posture. A limited number of these bilateral occurrences are described in the literature to date and most have been from higher energy trauma. We have described a low energy case of bilateral luxatio erecta and the reduction method used and the continued instability following successful reduction under procedural anesthesia. [Clin Pract Cases Emerg Med. 2020;4(1):38–41.]

INTRODUCTION

Luxatio erecta, meaning “to place upward” in Latin, is a term coined by Dr. Middeldorpf and Dr. Scharm in 1859 to describe the unique presentation of traumatic inferior dislocation of the glenohumeral joint.¹ Patients classically present with the affected extremity held overhead in fixed abduction, with slight flexion of the elbow and pronation of the forearm, creating a so-called “hands up” posture.² This is a rare diagnosis, accounting for 0.5% of shoulder dislocations, with only a total of 30 cases of bilateral luxatio erecta humeri (LEH) reported in the literature to date.³

The shoulder is inherently an unstable joint, with the large humeral head articulating with the smaller glenoid fossa. A combination of static and dynamic stabilizers contributes to the location of the humeral head in the glenoid socket. Injuries to either the static or dynamic stabilizers of the joint predispose to dislocation.⁴ By far, shoulder dislocations most commonly occur anteriorly, accounting for 95-97% of shoulder dislocations.⁴ Here, we present one such patient who presented with bilateral LEH after a ground-level fall.

CASE REPORT

We present a case of a 67-year-old female who was recently treated with a decompression and 10th thoracic to second lumbar fusion secondary to formation of an epidural hematoma from

a 12th thoracic vertebra fracture (type unknown). While in a physical therapy session the patient suffered a fall forward, trying to break her fall with her arms outstretched above her head. After the fall the patient’s arms were stuck in full abduction and pronation and she was in significant pain. The patient’s presenting position is displayed in Image 1. She arrived in the emergency department where X-rays were taken and demonstrated bilateral inferior shoulder dislocations, LEH (Image 2).

Orthopedics was consulted to evaluate and treat. Upon evaluation, the patient was distally neurovascularly intact with

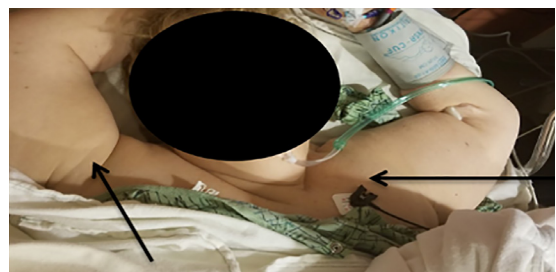

Image 1. Clinical photograph of patient’s bilateral humeri held in abduction with forearms in pronation. Black arrows pointing to shoulders that are abducted and externally rotated.

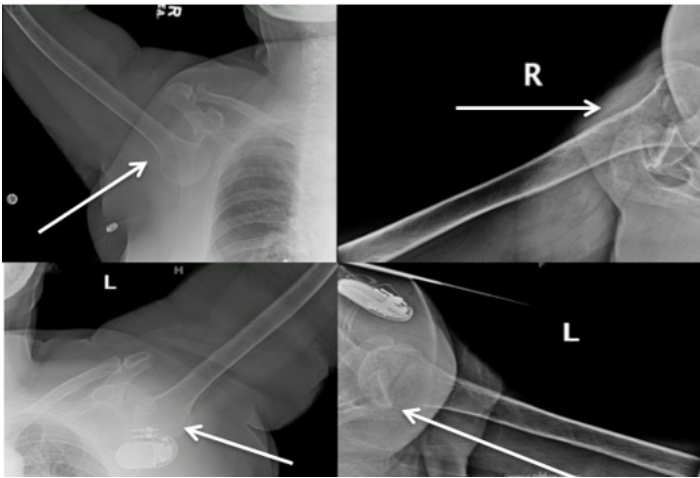


Image 2. Radiographs demonstrating bilateral inferior shoulder dislocations without fracture. White arrows pointing to humeral head of bilateral shoulders, which is directly inferior to the glenoid.

2/4 radial pulses bilaterally, sensation intact to light touch about the fifth cervical to first thoracic dermatomes, and motor function was intact in all peripheral motor groups of the upper extremities. The emergency physician provided sedation with closed reduction performed by the orthopedic service. The right shoulder was reduced using traction through the humerus through a flexed elbow to control the limb, and the opposite hand was used to place superior pressure on the humeral head through the axilla to guide the head into the glenoid. Slight external rotation and adduction was added as the head cleared the glenoid. Attention was then turned to the left shoulder, which was reduced, in a similar fashion; however, this shoulder was converted from an inferior to anterior dislocation using pressure in the axilla and slight external rotation.

Following this, traction through the humerus external rotation, and lateral pressure on the humeral head yielded a successful relocation of the glenohumeral joint. After reduction the patient remained neurovascularly intact bilaterally. The patient was placed into bilateral shoulder slings, advised to avoid active shoulder range of motion, and admitted to the hospital for placement. Three days after the patient's admission she adjusted a continuous positive airway pressure (CPAP) mask with her right arm dislocating anteroinferiorly (Image 3).

She was again noted to be distally neurovascularly intact. Sedation was performed by the anesthesia department, and the orthopedic service then performed closed reduction. The patient remained neurovascularly intact after reduction. She has not had another instability event to date.

DISCUSSION

LEH is an extremely uncommon diagnosis, making it worthwhile to report. Our case is unique in that the patient experienced a subsequent unilateral non-traumatic

CPC-EM Capsule

What do we already know about this clinical entity?

Luxatio erecta is a direct inferior shoulder dislocation accounting for only 0.5% of all shoulder dislocations and associated with higher rates of neurovascular injury.

What makes this presentation of disease reportable?

The presentation is a bilateral occurrence with a low energy mechanism followed by repeat instability which is rare in dislocations occurring in this age group.

What is the major learning point?

Despite low energy mechanism there was repeat instability. It is important to distinguish this presentation from routine simple shoulder dislocations.

How might this improve emergency medicine practice?

Recognizing this rare presentation may prompt earlier orthopedic consultation and follow-up. This may expedite treatment for continued instability.

anteroinferior shoulder dislocation within 48 hours of bilateral LEH reduction, which, to our knowledge, has never been described before in the literature on LEH.

The shoulder is inherently an unstable joint, with the large humeral head articulating with the smaller glenoid fossa. At any given moment only 25-30% of the humeral head surface is in direct contact with the glenoid surface.⁵ Joint congruity is maintained by both static and dynamic stabilizers. The glenoid labrum is a cartilaginous ring that acts as a static stabilizer to the joint, deepening the glenoid by 50%.⁶ Other static joint stabilizers include the glenohumeral ligaments, the articular congruity and version of the glenohumeral interface, and the negative intra-articular pressure created at the joint surface. The labrum combines with the joint capsule and ligaments to provide the remainder of static stability, deepening the articulation and serving as a capsuloligamentous attachment site.

These structures tighten with motion of the arm and are most functional at the extremes of motion. The coracohumeral and superior glenohumeral ligament act to prevent inferior translation with the arm adducted and posterior translation when

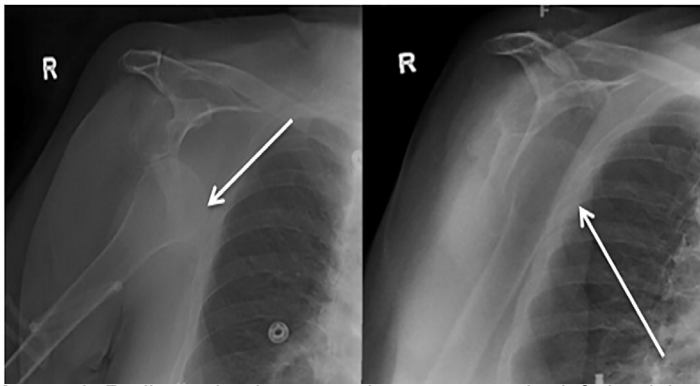


Image 3. Radiographs demonstrating acute anterior-inferior right shoulder dislocation. White arrows pointing to the humeral head, which is anterior and inferior to the glenoid.

forward flexed and internally rotated. The middle glenohumeral ligament is absent in 8-30% of people. Traveling from the supraglenoid tubercle and superior labrum to the medial aspect of the lesser tuberosity it prevents anterior translation in 60-90° of abduction and from inferior translation in adduction. The inferior glenohumeral ligament (IGHL) is the thickest and most consistent. Originating from the anterior inferior portions of the labrum to the lesser tuberosity of the humerus. The IGHL is mainly responsible for preventing anterior translation in abduction and external rotation.⁵ The rotator cuff musculature, long head of the biceps, and periscapular muscles act as dynamic stabilizers, providing stability throughout range of motion of the joint. Injuries to either the static or dynamic stabilizers of the joint predispose to dislocation, the most common direction being anterior in 95-97% of cases.⁴

Two main mechanisms of injury account for LEH, which are exclusively traumatic in nature.⁷ Commonly, an inferior force vector is applied on a fully abducted extremity, which disrupts the weaker inferior ligamentous complex allowing the humeral head to disengage the glenoid and dislocate inferiorly. Alternatively, hyperabduction injury can cause levering of the proximal humerus off of the acromion causing an inferior dislocation, usually from grasping an immobile object while falling to the ground. Our patient fell forward from a standing height while using her four-wheeled walker. It is unclear if she tried to catch herself on the walker with both hands while falling. However, the likely cause was bilateral hyperabduction moment leading to her dislocation. Nambiar et al. evaluated all of the published case reports regarding unilateral or bilateral LEH, and found that falls accounted for 45% of all cases, where falls from standing height accounted for 12% of all cases.⁸

Reduction techniques for LEH have been described in the literature with the most common reduction technique being overhead traction.^{7,9} This method involves bringing the patient's arm into full abduction and, with an assistant to provide counter

traction, physician applies upward directed force. Traction is maintained as the arm is slowly brought down into adduction. This method requires significant force to overwhelm the shoulder musculature and often requires conscious sedation.^{7,9,10}

Nho and colleagues have described a separate two-part reduction maneuver that they successfully used in two patients described in their case report. In this technique the patient is placed supine and the physician stands on the affected side next to the head of the patient. The pushing hand should be placed on the lateral aspect of the midshaft humerus while the pulling hand is positioned over the medial epicondyle. The push hand manipulates the humeral head to an anterior position relative to the glenoid while the pull hand gives gentle superior directed force moving the head to anterior. The second step can be various methods for reduction of anterior dislocations including traction counter traction, or Nho's preferred external rotation method. With patients arm completely adducted the push hand gives constant adduction force while the pull hand is relocated to the forearm to produce external rotation of the humerus until reduction is palpated.⁹

The surgeon should be aware of the well-known complications of LEH, which include associated fractures of the proximal humerus, acromion and clavicle, avulsion of the greater tuberosity, ligament and soft tissue injury such as rotator cuff tear and, less frequently, neurovascular injury. Ngam et al. performed a systematic review of five publications describing the magnetic resonance imaging features of LEH, and found that up to 75% of patients with traumatic LEH had concomitant rotator cuff tears. They observed that patients never sustained both a rotator cuff tear and a greater tuberosity avulsion, suggesting that avulsing the greater tuberosity spares the rotator cuff and vice-versa.³

Mallon et al. reviewed 80 cases of LEH and found that either a fracture of the greater tuberosity or rotator cuff tear were present in 80% of patients.¹¹ Another characteristic finding in traumatic LEH is a Hill-Sachs-like impaction fracture at the posterosuperior humeral head, located more superior and lateral than classic Hill-Sachs lesions, from impacting the humeral head against the inferior glenoid.⁷ Computed tomography (CT) is the best imaging modality to evaluate for this Hill-Sachs-like lesion, or for radiographically occult fracture. CT was not obtained in our patient's case because there was no clinical suspicion or radiographic evidence of fracture.

A lesser-reported complication of LEH is recurrent instability, and there is a paucity of literature reporting rates of re-dislocation with no reports of *anterior* instability and dislocation. Olds et al. performed a meta-analysis quantifying the recurrence rate and risk factors predicting re-dislocation after primary anterior shoulder dislocation. The study found that factors leading to increased risk of dislocation included age <40 years old had an odds ratio (OR) [13.46], male sex (OR [3.18]), and hyperlaxity in >1 joints (OR [2.68]).¹² Our patient had none of the predictive risk factors for recurrent dislocation; there was no history of

shoulder instability, hyperlaxity, and she was a female >40 years old. There was no radiographic evidence of acute fracture, bony Bankart lesion or Hill-Sachs-like deformity.

Given the bilateral nature of her injury and need to conduct activities of daily living, the patient was put in simple slings with strict instructions to avoid forward flexion and abduction as an alternative to bilateral shoulder immobilizers. Her re-dislocation occurred while she was reaching her hand over her mouth to remove a CPAP machine. The position of her arm was approximately forward flexed and abducted to 90 degrees with 45 degrees of external rotation normally within the physiologic range. However, it resulted in an anteroinferior dislocation in our patient showing the degree of instability she developed due to her initial LEH insult.

CONCLUSION

LEH is an uncommon presentation for glenohumeral dislocation. This case is even more rare as it is bilateral with an unusual mechanism. We describe techniques for reduction as well as the inherent instability present in the geriatric population once the rotator cuff is disrupted. The instability is demonstrated in the limited inpatient follow-up we have with a subsequent anterior dislocation.

Documented patient informed consent and/or Institutional Review Board approval has been obtained and filed for publication of this case report.

REFERENCES

1. Middeldorpf M and Scharm B. De nova humeri luxationis specie. *Clin Eur*. 1859;2:12-6.
2. Kumar KS, O'Rourke S, Pillary JG. Hands up: a case of bilateral inferior shoulder dislocation. *Emerg Med J*. 2001;18(5):404-5.
3. Ngam PI, Hallinan JT, Sia DSY. Sequelae of bilateral luxatio erecta in the acute post-reduction period demonstrated by MRI: a case report and literature review. *Skeletal Radiol*. 2018;48(3):467-73.
4. Simon RR, Sherman SC, Koenigsnecht SJ. (2006). Emergency Orthopedics: The Extremities (5th ed.). New York, NY: McGraw-Hill.
5. Terry GC and Chopp TM. Functional anatomy of the shoulder. *J Athl Train*. 2000;35(3):248-55.
6. Howell SM and Galinat BJ. The glenoid-labral socket. A constrained articular surface. *Clin Orthop Relat Res*. 1989;(243):122-5.
7. Davids JR and Talbott RD. Luxatio erect humeri: a case report. *Clin Orthop Relat Res*. 1990;(252):144-9.
8. Nambiar M, Owen D, Moore P, et al. Traumatic inferior shoulder dislocation: a review of management and outcome. *Eur J Trauma Emerg S*. 2018;44(1):45-51.
9. Nho SJ, Dodson CC, Bardzik KF, et al. The two-step maneuver for closed reduction of inferior glenohumeral dislocation (luxatio erecta to anterior dislocation to reduction). *J Orthop Trauma*. 2006;20(5):354-7.
10. Stimson LA. (1912). Fractures and Dislocations. Philadelphia, PA: Lea and Febiger.
11. Mallon WJ, Basset FH 3rd, Goldner RD. Luxatio erecta: the inferior glenohumeral dislocation. *J Orthop Trauma*. 1990;4(1):19-24.
12. Olds M, Ellis R, Donaldson K, et al. Risk factors which predispose first-time traumatic anterior shoulder dislocations to recurrent instability in adults: a systematic review and meta-analysis. *Br J Sports Med*. 2015;49(14):913-22.

Address for Correspondence: Jacob Lytle, DO, Ascension Genesys Hospital, Department of Orthopedics, 1 Genesys Parkway, Grand Blanc, MI 48439. Email: Jacob.lytle@ascension.org.

Conflicts of Interest: By the CPC-EM article submission agreement, all authors are required to disclose all affiliations, funding sources and financial or management relationships that could be perceived as potential sources of bias. The authors disclosed none.

Copyright: © 2020 Kessler et al. This is an open access article distributed in accordance with the terms of the Creative Commons Attribution (CC BY 4.0) License. See: <http://creativecommons.org/licenses/by/4.0/>

Carbon Monoxide Poisoning Effectively Treated with High-flow Nasal Cannula

Patrick Lee, MD*
Steven D. Salhanick, MD†

*Southern New Hampshire Medical Center, Department of Emergency Medicine, Nashua, New Hampshire

†Massachusetts/Rhode Island Center for Poison Control and Information, Staff Toxicologist, Boston, Massachusetts

Section Editor: Rick A. McPheeters, DO

Submission history: Submitted May 1, 2019; Revision received September 6, 2019; Accepted September 13, 2019

Electronically published November 19, 2019

Full text available through open access at http://escholarship.org/uc/uciem_cpccem

DOI: 10.5811/cpcem.2019.9.43618

Carbon monoxide (CO) poisoning is typically treated by administration of oxygen via non-rebreather mask (NRB). High-flow nasal cannula (HFNC) is an alternative to NRB in a variety of disease states. We report a case of the novel use of HFNC in the treatment of acute CO poisoning. A 29-year-old man presented with a carboxyhemoglobin (COHb) level of 29.8%. He was treated with HFNC, and COHb levels declined to 5.4% in 230 minutes. Given several theoretical advantages of HFNC relative to NRB, HFNC is a potential option for use in the treatment of CO poisoning. [Clin Pract Cases Emerg Med. 2020;4(1):42–45.]

INTRODUCTION

Carbon monoxide (CO) poisoning is a significant cause of morbidity and mortality causing approximately 500 deaths annually, and as many as 25,000 hospitalizations per year.^{1,2} The treatment of CO poisoning is primarily aimed at removing CO through competitive binding of hemoglobin by administration of supplemental oxygen. In the majority of cases this is done using a non-rebreather mask (NRB). Alternatively, hyperbaric oxygen may be used in cases of more severe toxicity based on very high levels of carboxyhemoglobin (COHb) or signs or symptoms of severe toxicity.

Delivery of supplemental oxygen via high-flow nasal cannula (HFNC) has been used with increasing frequency. HFNC allows for delivery of a higher flow rate of oxygen as well as positive pressure and administration of warmed, humidified oxygen. Proponents suggest that it can be advantageous over other forms of supplemental oxygen delivery as it is often better tolerated than a NRB, can provide some degree of positive pressure, is useful in washing out anatomic dead space, and allows for up to 60 liters per minute (LPM) of oxygen administration.³ High flow rate of oxygen reduces the dilution of inspired oxygen that occurs when the volume of inspired gas exceeds the flow rate of the NRB. As such, HFNC provides some theoretical advantages over NRB for the treatment of CO poisoning. To date we find two

recent reports of HFNC used to treat CO poisoning; however, widespread use has not been reported.^{4,5} Our case is submitted to support recent earlier findings and therefore support the novel use of HFNC following CO poisoning.

CASE REPORT

A 29-year-old man presented to the emergency department (ED) after being found in an idling car parked in an enclosed space. The patient had last been seen approximately four hours prior to being found in the car. He was awake and alert upon arrival. He had significant nausea but no vomiting. He denied loss of consciousness, confusion, seizure, chest pain, shortness of breath or headache, or any concomitant ingestion. He had no significant medical or surgical history other than depression, but reported being a pack per day smoker. The patient had been transported from home via ambulance and administered 100% oxygen via NRB at a flow rate of 15 LPM for approximately 15 minutes during transport.

On arrival, the patient's blood pressure was 130/63 millimeters of mercury (mmHg), pulse rate was 73 beats per minute, respiratory rate was 18 breaths per minute, oxygen saturation (SaO₂) was 99% on NRB, and temperature was 36.6 degrees Celsius. He was awake and had normal mentation, and was in no apparent distress. Cardiovascular exam showed normal heart sounds, normal rhythm, no murmurs, rubs or

gallops. Respiratory exam revealed no respiratory distress, equal and clear breath sounds bilaterally. Neurologically, he was oriented to name, place, time, and purpose. He had normal speech, Glasgow Coma Scale of 15, normal memory, cranial nerves II-XII, and motor and sensory exams were completely normal. His gait was normal. He had no nystagmus. His psychiatric exam revealed that he was feeling suicidal. Otherwise, he had an unremarkable physical exam.

Initial arterial blood gas (ABG) on room air shortly after arrival revealed a pH 7.369 [7.35-7.45], partial pressure of carbon dioxide ($p\text{CO}_2$) of 41.9 mmHg (35-45 mmHg), partial pressure of oxygen ($p\text{O}_2$) of 93.3 mmHg (75-100 mmHg), and COHb level of 29.8% (0-2%). His electrocardiogram, serum electrolytes, liver function tests, creatinine kinase, and complete blood count were within normal range, excepting a potassium level of 3.1 milliequivalents per liter (mEq/L) (3.5-5.1 mEq/L). Salicylate, troponin I, ethanol, and acetaminophen levels were below the assay limits of detection.

Immediately after obtaining the ABG results the patient was started on 100% oxygen via HFNC at 30 LPM due to concerns that he would not tolerate the NRB and could vomit due to complaints of severe nausea. His nausea resolved within the first hour of HFNC treatment. After 112 minutes of therapy via HFNC, a repeat ABG revealed the following: pH 7.403, COHb 11.5%, $p\text{CO}_2$ 42.1 mmHg, and $p\text{O}_2$ of 462.4 mmHg. It was felt that the patient was responding to HFNC therapy as evidenced by the decline in COHb and the increase in $p\text{O}_2$. HFNC therapy at the same settings was continued for a total of approximately 230 minutes when a repeat ABG was obtained revealing a COHb of 5.4%. At this point the patient was asymptomatic and therapy was discontinued. Of note the patient did not receive antiemetic medication. Following administration of supplemental oral potassium he was transferred to the psychiatric service.

DISCUSSION

HFNC is a promising treatment option for hypoxic respiratory failure in the ED due to the ability to more comfortably deliver oxygen at a high rate as well as deliver positive pressure and wash out anatomic dead space. HFNC delivers warmed, humidified oxygen at flow rates of up to 60 LPM and with positive pressure of 2-5 mmHg.⁶⁻⁹ The ability to warm the oxygen to core temperature and humidify at high flow rates also helps remove airway secretions, decreases work of breathing, and avoids drying out the airway, reducing epithelial injury.¹⁰ Current indications for HFNC in children include use for premature infants with respiratory distress syndrome and infants with bronchiolitis.¹¹ The indications for HFNC in adults include non-hypercapnic hypoxemic respiratory failure requiring relatively high concentrations of inspired oxygen. Other applicable settings for HFNC include post-extubation support, postoperative respiratory failure, intubation support, tracheostomy weaning, and support of hypoxemic patients during fiberoptic bronchoscopy.¹²

CPC-EM Capsule

What do we already know about this clinical entity?

Carbon monoxide (CO) poisoning is effectively treated with supplemental oxygen, typically via a non-rebreather mask (NRB). In some clinical situations, however, patients may have difficulty tolerating the NRB.

What makes this presentation of disease reportable?

There are no prior reports of the use of high flow nasal cannula (HFNC) in the literature outside those reported using a strict study protocol. Our report supports effectiveness in clinical practice.

What is the major learning point?

HFNC is a likely effective option for the administration of supplemental oxygen when treating CO poisoning.

How might this improve emergency medicine practice?

Our report supports the use of HFNC which has distinct advantages over use of a NRB when administering supplemental oxygen to patients with elevated CO levels.

CO poisoning is treated with high levels of supplemental oxygen in an effort to displace CO from hemoglobin, other heme-containing molecules, and other sites of CO binding.^{13,14} This is typically realized clinically by the decrease in time that it takes to eliminate CO from hemoglobin in the peripheral circulation. At baseline CO is eliminated with a half-life of approximately 300 minutes.¹⁵ This can be reduced by oxygen administration via NRB to between 37-120 minutes.¹⁶ Given the proposed mechanism of elimination, it stands to reason that HFNC could be of similar or greater efficacy as it allows for higher oxygen flow rates than NRB.

There are several theoretical advantages to the use of HFNC in treating CO poisoning. HFNC can produce a higher partial pressure of oxygen than NRB when applied to patients who are tachypneic, potentially resulting in increased rate of elimination of CO relative to NRB. This is due to the phenomenon of mixing of ambient air into inspired air when the volume of air inspired exceeds the flow rate of

oxygen delivered by a mask, typically 15 LPM. Given that HFNC can provide flow rates exceeding 60 LPM, the extent to which ambient air is mixed with supplemental oxygen is low; consequently, pO_2 may be higher. HFNC is better tolerated than NRB due to improved comfort and warming and humidification of inspired gas, which may allow for better compliance with non-invasive oxygen therapy, particularly when administering to patients who may be agitated. Lastly, should vomiting occur, patients may be less likely to aspirate using HFNC as opposed to the NRB.

Previously, Tomruk et al. reported the use of HFNC routinely in a single academic medical center with an increase in the decline of absolute COHb levels in one hour compared to historical controls that received standard treatment with NRB. Mean levels of COHb were 22% in the HFNC group and 18.6% in the NRB group prior to treatment.⁵ Ozturan et al. reported a mean half-life of 36.8 minutes calculated from 33 patients enrolled with elevated COHb levels (mean 22.5% COHb prior to treatment) treated with HFNC.⁴ Neither study included any clinical outcome as endpoints. Our patient showed a decrease in COHb levels comparable to those described for NRB, indicating that HFNC delivered oxygen in a manner of comparable efficacy. Further, we were able to achieve a high pO_2 with HFNC. Consequently, we would anticipate increased elimination of CO based on the pO_2 achieved using HFNC.

While we did not have adequate data to calculate a half-life, our estimate based on the rate of decline of COHb between the first and second ABG suggests a half-life of approximately 81 minutes, and an estimate between the first and third COHb level suggests a half life of 92 minutes.¹⁷ These are consistent with reported half-lives using NRB and are exceeded more than four fold by the half-life generally reported with ambient air.^{16,18} The estimated half-life for our patient, however, was substantially less than that reported in prior studies using HFNC, suggesting that previous reports of half-life may not mirror effects in a uncontrolled clinical setting. Further, kinetics of elimination may vary as the initial COHb level in our patient was approximately 25% higher than the mean levels reported in the previous studies. Lastly, our patient reported a marked improvement in clinical symptoms following HFNC. Neither of the prior reports noted any clinical outcome. This is significant as early and late clinical findings may not correlate with COHb levels.¹⁹

There are several limitations to the data. First, we did not measure clearance directly and thus cannot state unequivocally that our half-life estimates are correct. However, given the substantial difference between our estimate of half-life and the half-life expected on room air, as well as the directly measured increase in arterial pO_2 , we feel confident that HFNC had a therapeutic effect. Another issue may be that we measured an artificially high initial level of COHb as there is an initial distribution phase of CO. We think this is unlikely as the

time lapse between removal from the exposure and obtaining blood gas was greater than 30 minutes. Given that the initial rate of distribution is rapid we think that our initial COHb level likely represents a steady state level.^{19,20} Also, while our patient's nausea resolved, we have no information regarding any long-term clinical issues or whether HFNC administration may have any effect on these given the limitations of COHb levels in predicting clinical outcome. Further, we cannot say this approach would have better outcome than use in NRB and antiemetics. Lastly, our patient was a chronic tobacco smoker, affecting his baseline levels of COHb and possibly his tolerance for elevated COHb levels.

CONCLUSION

In a patient with a CO poisoning, as evidenced by symptoms and COHb level, use of HFNC resulted in an apparent increase in the rate of elimination of COHb similar to that seen with administration of oxygen via NRB. HFNC was well tolerated and may be a good option for treatment of CO poisoning.

Documented patient informed consent and/or Institutional Review Board approval has been obtained and filed for publication of this case report.

Address for Correspondence: Steven D. Salhanick, MD, Massachusetts/Rhode Island Center for Poison Control and Information, Department of Toxicology, 300 Longwood Ave., Boston, MA 02115. Email: steven.salhanick@childrens.harvard.edu.

Conflicts of Interest: By the CPC-EM article submission agreement, all authors are required to disclose all affiliations, funding sources and financial or management relationships that could be perceived as potential sources of bias. The authors disclosed none.

Copyright: © 2020 Lee et al. This is an open access article distributed in accordance with the terms of the Creative Commons Attribution (CC BY 4.0) License. See: <http://creativecommons.org/licenses/by/4.0/>

REFERENCES

1. Carbon monoxide exposures--United States, 2000-2009. *MMWR*. 2011;60(30):1014-7.
2. Hampson NB. U.S. Mortality due to carbon monoxide poisoning, 1999-2014. accidental and intentional deaths. *Ann Am Thorac Soc*. 2016;13(10):1768-74.
3. Zhu Y, Yin H, Zhang R, et al. High-flow nasal cannula oxygen therapy versus conventional oxygen therapy in patients with acute

- respiratory failure: a systematic review and meta-analysis of randomized controlled trials. *BMC Pulm Med*. 2017;17(1):201.
4. Ozturan IU, Yaka E, Suner S, et al. Determination of carboxyhemoglobin half-life in patients with carbon monoxide toxicity treated with high flow nasal cannula oxygen therapy. *Clin Tox (Phila)*. 2019;57(7):617-23.
 5. Tomruk O, Karaman K, Erdur B, et al. A New promising treatment strategy for carbon monoxide poisoning: high flow nasal cannula oxygen therapy. *Med Sci Monit*. 2019;25:605-9.
 6. Lenglet H, Sztrymf B, Leroy C, et al. Humidified high flow nasal oxygen during respiratory failure in the emergency department: feasibility and efficacy. *Respir Care*. 2012;57(11):1873-8.
 7. Parke RL, Eccleston ML, McGuinness SP. The effects of flow on airway pressure during nasal high-flow oxygen therapy. *Respir Care*. 2011;56(8):1151-5.
 8. Parke RL and McGuinness SP. Pressures delivered by nasal high flow oxygen during all phases of the respiratory cycle. *Respir Care*. 2013;58(10):1621-4.
 9. Sztrymf B, Messika J, Bertrand F, et al. Beneficial effects of humidified high flow nasal oxygen in critical care patients: a prospective pilot study. *Intensive Care Med*. 2011;37(11):1780-6.
 10. Williams R, Rankin N, Smith T, et al. Relationship between the humidity and temperature of inspired gas and the function of the airway mucosa. *Crit Care Med*. 1996;24(11):1920-9.
 11. Franklin D, Babl FE, Schlapbach LJ, et al. A randomized trial of high-flow oxygen therapy in infants with bronchiolitis. *N Engl J Med*. 2018;378(12):1121-31.
 12. Helviz Y and Einav S. A systematic review of the high-flow nasal cannula for adult patients. *Crit Care*. 2018;22(1):71.
 13. Hardy KR and Thom SR. Pathophysiology and treatment of carbon monoxide poisoning. *J Toxicol Clin Toxicol*. 1994;32(6):613-29.
 14. Rose JJ, Wang L, Xu Q, et al. Carbon monoxide poisoning: pathogenesis, management, and future directions of therapy. *Am J Respir Crit Care Med*. 2017;195(5):596-606.
 15. Peterson JE and Stewart RD. Absorption and elimination of carbon monoxide by inactive young men. *Arch Environ Health*. 1970;21(2):165-71.
 16. Weaver LK, Howe S, Hopkins R, et al. Carboxyhemoglobin half-life in carbon monoxide-poisoned patients treated with 100% oxygen at atmospheric pressure. *Chest*. 2000;117(3):801-8.
 17. Weill Medical College of Cornell University. Critical care pediatrics drug half life. 2000. Available at: <http://www-users.med.cornell.edu/~spon/picu/calc/halfcalc.htm>. Accessed March 25, 2019.
 18. Hampson NB, Piantadosi CA, Thom SR, et al. Practice recommendations in the diagnosis, management, and prevention of carbon monoxide poisoning. *Am J Respir Crit Care Med*. 2012;186(11):1095-101.
 19. Hampson NB and Hauff NM. Carboxyhemoglobin levels in carbon monoxide poisoning: do they correlate with the clinical picture? *Am J Emerg Med*. 2008;26(6):665-9.
 20. Goldbaum LR, Orellano T, Dergal E. Mechanism of the toxic action of carbon monoxide. *Ann Clin Lab Sci*. 1976;6(4):372-6.

Neurosyphilis: Old Disease, New Implications for Emergency Physicians

Laura Mercurio, MD**
Lynn E. Taylor, MD†
Angela F. Jarman, MD, MPH*

*Alpert Medical School of Brown University, Department of Emergency Medicine, Providence, Rhode Island

†University of Rhode Island Providence Campus, CODAC Behavioral Health, Providence, Rhode Island

‡Alpert Medical School of Brown University, Department of Pediatrics, Providence, Rhode Island

Section Editor: Rick A. McPheeters, DO

Submission history: Submitted June 2, 2019; Revision received September 28, 2019; Accepted September 26, 2019

Electronically published November 19, 2019

Full text available through open access at http://escholarship.org/uc/uciem_cpchem

DOI: 10.5811/cpcem.2019.9.43871

Recent epidemiologic data demonstrate increasing rates of neurosyphilis, particularly among those in the community of men who have sex with men and those coinfecting with the human immunodeficiency virus (HIV). Here we discuss a case of early neurosyphilis and new HIV diagnosis in a 27-year-old previously-healthy trans woman presenting for the second time with progressive, ascending weakness and cranial nerve VI palsy. Emergency physicians should consider this rare but highly morbid diagnosis, given the rising prevalence of neurosyphilis among at-risk patients and those with new neurologic deficits. [Clin Pract Cases Emerg Med. 2020;4(1):46–50.]

INTRODUCTION

Neurosyphilis, an invasion of the central nervous system (CNS) by the spirochete *Treponema pallidum* (*T pallidum*), can affect the brain parenchyma, meninges, and spinal cord. This disease has been commonly understood as the consequence of chronic, untreated syphilis. Now early neurosyphilis is resurging among at-risk populations in the United States (U.S.) and abroad. During 2015-2016, the U.S. national syphilis rate increased by 17.6% to 8.7 cases per 100,000 population – the highest rate reported since 1993.¹ The ratio of biologically male to female individuals with syphilis also increased from 1.2 (1996) to 5.7 (2005) per 100,000²; this increase was disproportionately seen among those in the community of men who have sex with men.³

By some estimates, up to 75% of new syphilis cases were among the men who have sex with men population, and approximately half of these individuals were coinfecting with human immunodeficiency virus (HIV).^{4,5} The prevalence of neurosyphilis among HIV-infected individuals with untreated syphilis has been reported as high as 23.5-40%, as compared to approximately 10% in HIV-uninfected individuals.⁶ Here we present a case of neurosyphilis in a reportedly previously-healthy trans

woman presenting with progressive, ascending weakness and new HIV diagnosis.

CASE REPORT

A 27-year-old male-to-female transgender patient with no significant medical history presented to the emergency department (ED) with three weeks of worsening lower extremity weakness and pain that progressed to include bilateral upper extremity weakness. She described her left leg “giving way” while at work several weeks prior; this episode caused a fall, but she was able to continue working and did not seek medical attention at that time. Within a week, her lower extremity weakness progressed to the point of requiring assistance to ambulate to the bathroom. She also developed worsening, diffuse left leg and low back pain.

The patient initially sought care one week prior to presentation at an outside hospital with the chief complaint of back and leg pain and weakness; she reported that radiographs of the lumbar spine were normal, and she was discharged home with ibuprofen and muscle relaxants. The patient subsequently developed worsening upper extremity weakness such that she could not pull herself up in bed. Review of systems indicated a 10-pound weight loss and intermittent double vision with

rightward gaze; she denied any rash or lesions, fevers, chills, photophobia, headache, neck pain or stiffness, or any recent illnesses or vaccinations. The patient endorsed being sexually active with one male partner and did not use barrier protection during anal intercourse. She denied having prior HIV testing. Social history was notable for daily cigarette use, but no current or past intravenous (IV) drug use. The patient had no family history of multiple sclerosis, amyotrophic lateral sclerosis, or other neurodegenerative diseases.

The patient had normal vital signs on presentation. Initial neurologic examination was notable for an alert, anxious, cooperative patient with fluent speech, loss of right eye abduction with diplopia, leftward tongue deviation, 3/5 strength in right lower extremity, 1/5 strength in left lower extremity, 4/5 strength of bilateral upper extremities, 1+ biceps reflexes with absent patellar reflexes bilaterally. She was unable to walk due to weakness, and required some assistance to move from lying to sitting in bed.

Pertinent findings on serum testing included the following: a normal c-reactive protein of 2.98 milligrams per deciliter (mg/dL) (reference [ref] 0.0-10.0 mg/dL), an elevated erythrocyte sedimentation rate of 123 millimeters per hour (mm/hr) (ref 0.0-20.0 mm/hr), a normal white blood cell count of 6.3×10^9 / liter (L) (ref 4.4-16.0 $\times 10^9$ /L) with a slight neutrophilic predominance, but without bandemia (67.9% neutrophils, 19% lymphocytes 11.2% monocytes 1.4 eosinophils, 0.5 bands); and an elevated creatinine kinase (336 international units [IU]/L, ref 20-210 IU/L). Other studies that were within normal limits included hemoglobin (13.7 grams [G]/dL, ref 11.0-16.3 G/dL); platelet count (231×10^9 /L, ref 150-400 $\times 10^9$ /L); basic metabolic panel; liver function testing; and thyroid stimulating hormone.

A non-contrast computed tomography of the brain was obtained and was notable for a 1.5 centimeter-mass within the central left nasopharynx but did not show any acute cerebral/cerebellar findings. Lumbar puncture was performed and cerebrospinal fluid (CSF) results included the following: normal glucose (56 mg/dL, ref 38-85 mg/dL); elevated protein (792 mg/dL, ref 15-45 mg/dL); and pleiocytosis (94 cells, ref 0-5/cubic millimeters) with 92% lymphocytes (ref 63-99%). Ceftriaxone and vancomycin were initiated based on abnormal CSF preliminary testing.

Given the significant weight loss and new neurologic deficits, we obtained consent for HIV testing, and rapid antibody/antigen testing returned positive. A qualitative serum rapid plasma reagin (RPR) was sent and found to be positive with a titer of 1:16. CSF herpes simplex virus I/II polymerase chain reactions were negative. While in the ED, CSF venereal disease research laboratory (VDRL) testing was positive with a 1:2 titer, at which point 24 million units of IV penicillin G was administered. HIV myositis was also considered, although creatinine kinase level was only 316 IU/L (ref 20-210 IU/L). After a multidisciplinary discussion with neurology and

CPC-EM Capsule

What do we already know about this clinical entity?

Neurosyphilis is an invasion of the central nervous system by the spirochete Treponema pallidum. This disease has been understood as a consequence of chronic, untreated disease, but can present as a primary infection.

What makes this presentation of disease reportable?

This case demonstrates a case of primary neurosyphilis with HIV diagnosis in a previously-healthy trans woman with progressive lower-extremity weakness.

What is the major learning point?

It is important to consider neurosyphilis among HIV-infected patients, as well as those within the men who have sex with men and transgender communities.

How might this improve emergency medicine practice?

Practitioners should consider neurosyphilis in at-risk patients, those with HIV or new, unexplained neuro-psychiatric symptoms.

immunology, neither steroids nor IV immunoglobulin (IG) were administered in the ED pending further imaging and serologic evaluation.

Magnetic resonance imaging with and without contrast of the brain and spine was notable only for diffuse enhancement of cauda equina nerve roots with minimal, associated nerve root thickening, but no definite nodularity or clumping (Image).

The patient completed a 14-day course of IV penicillin G therapy (24 million units) for neurosyphilis. The initial cluster of differentiation 4 (CD4) count was 0.247 K/uL (ref 0.500-1.800 K/uL) with HIV RNA viral load of 37,811 copies/mL (ref 20-10,000,000 copies/mL). She was started on a once-daily antiretroviral regimen of elvitegravir, cobicistat, emtricitabine, and tenofovir alafenamide after resistance testing was sent. She also received five days of IVIG due to concern for Guillain-Barré syndrome (GBS). It was ultimately unable to be determined whether her weakness stemmed from neurosyphilis alone, GBS, HIV-related neuropathy, critical illness myopathy, or a combination of these. Blood cultures and CSF cultures

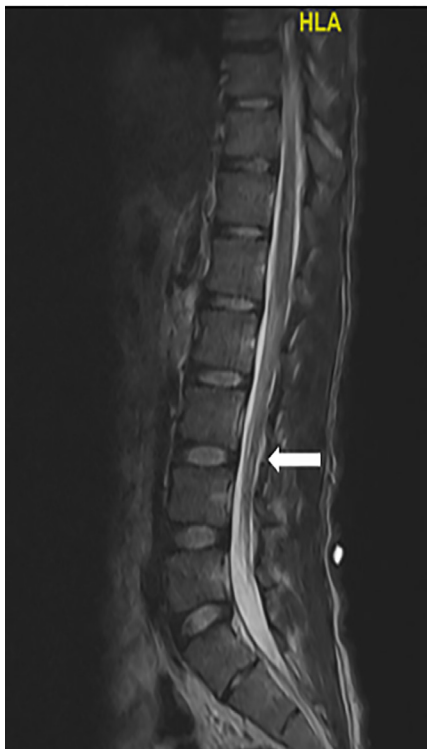

Image. T2-weighted magnetic resonance imaging of the spine. Lower spinal sagittal windows demonstrate diffuse enhancement of the cauda equina (white arrow).

remained negative. Cryptococcal, human T-lymphotrophic virus 1, and herpes simplex virus testing were negative.

After hospital discharge, the patient required 15 days of inpatient physical rehabilitation, but ultimately signed out against medical advice. She reported improvement in diplopia but continued to have lower extremity weakness requiring a walker for mobility and assistance with activities of daily living. A three-month follow-up lumbar puncture was planned to reassess CSF pleiocytosis and VDRL testing, but was not completed. Bloodwork obtained 10 months after initial diagnosis included reactive RPR with a titer of 1:4; negative hepatitis B panel; negative mycobacterium tuberculosis testing; and an undetectable HIV RNA viral load. Currently, the patient remains lost to in-person follow-up due to ambulation and transportation difficulties.

DISCUSSION

Progressive, lower extremity weakness has a wide differential diagnosis ranging from isolated neuropathies, spinal cord compression syndromes, and inflammatory or autoimmune disease (e.g., multiple sclerosis, GBS), to CNS infection and oncologic processes. This case highlights the importance of considering neurosyphilis among HIV-infected patients, as well as those within the men who have sex with men and transgender communities.

Estimates report 20-50% of men who have sex with men with syphilis living in major cities have concurrent HIV infection.² Prior or concurrent HIV infection increases risk of CNS invasion in early syphilis – a 2004 study demonstrated that 2.1% of HIV-infected individuals presented with neurosyphilis as their early disease manifestation, while only 0.6% of HIV-uninfected individuals presented in this manner.⁷ The four sub-types of neurosyphilis (Figure) are based on natural history of syphilis infection: symptomatic meningitis; meningovascular disease; general paresis; and tabes dorsalis. CNS infection can present with a broad range of neurologic concerns including psychiatric symptoms, dementia, headache, stroke-like symptoms, meningismus, progressive weakness, and encephalopathy.^{4,8-10}

The diagnostic approach to suspected neurosyphilis includes lumbar puncture and serum studies to test for the presence of *T pallidum* in the blood and CSF.^{4,10} Syphilis diagnostic testing can be divided into two categories: non-treponemal testing – RPR and VDRL; and treponemal testing – most commonly, the fluorescent treponemal antibody absorption (FTA-ABS) test. Non-treponemal testing detects the presence of antibody/antigen to *T pallidum* proteins, while the FTA-ABS tests for the whole organism.⁴ Nontreponemal tests can be falsely non-reactive in late syphilis, while treponemal tests remain reactive for life in patients with all forms of syphilis, even after treatment.⁴

Initial evaluation typically includes serum FTA-ABS and CSF VDRL testing (qualitative, then quantitative), as well as CSF culture and cell counts. *T pallidum* antibodies (immunoglobulin-G, immunoglobulin-M) can also be obtained to evaluate chronicity of syphilis infection.¹¹ Since this case, revised U.S. Centers for Disease Control and Prevention guidelines recommend starting with treponemal testing.¹² HIV testing should also be performed if the patient's status is not already established. HIV-infected patients with neurosyphilis can present with unique clinical manifestations including initial false negative serologic testing due to the prozone phenomenon; rapid progression to meningovascular disease; and inconsistent CSF leukocytosis. However, CSF testing should reveal an elevated protein, and this population is more likely to have a Jarisch–Herxheimer reaction – a systemic inflammatory response to treatment caused by the rapid lysis of treponemal organisms. Individuals with a new HIV diagnosis should also undergo appropriate CSF testing for opportunistic infections including tuberculosis, herpes simplex viruses and, depending on clinical presentation, human polyoma virus 2.

Standard treatment for neurosyphilis includes 18-24 million units/day of IV penicillin G therapy for 10-14 days.⁶ Our patient required a 14-day course of penicillin as well as antiretroviral therapy. Repeat CSF testing should be performed approximately three months¹³ after treatment to confirm clearance of the *T pallidum* infection from the CNS. Of note,

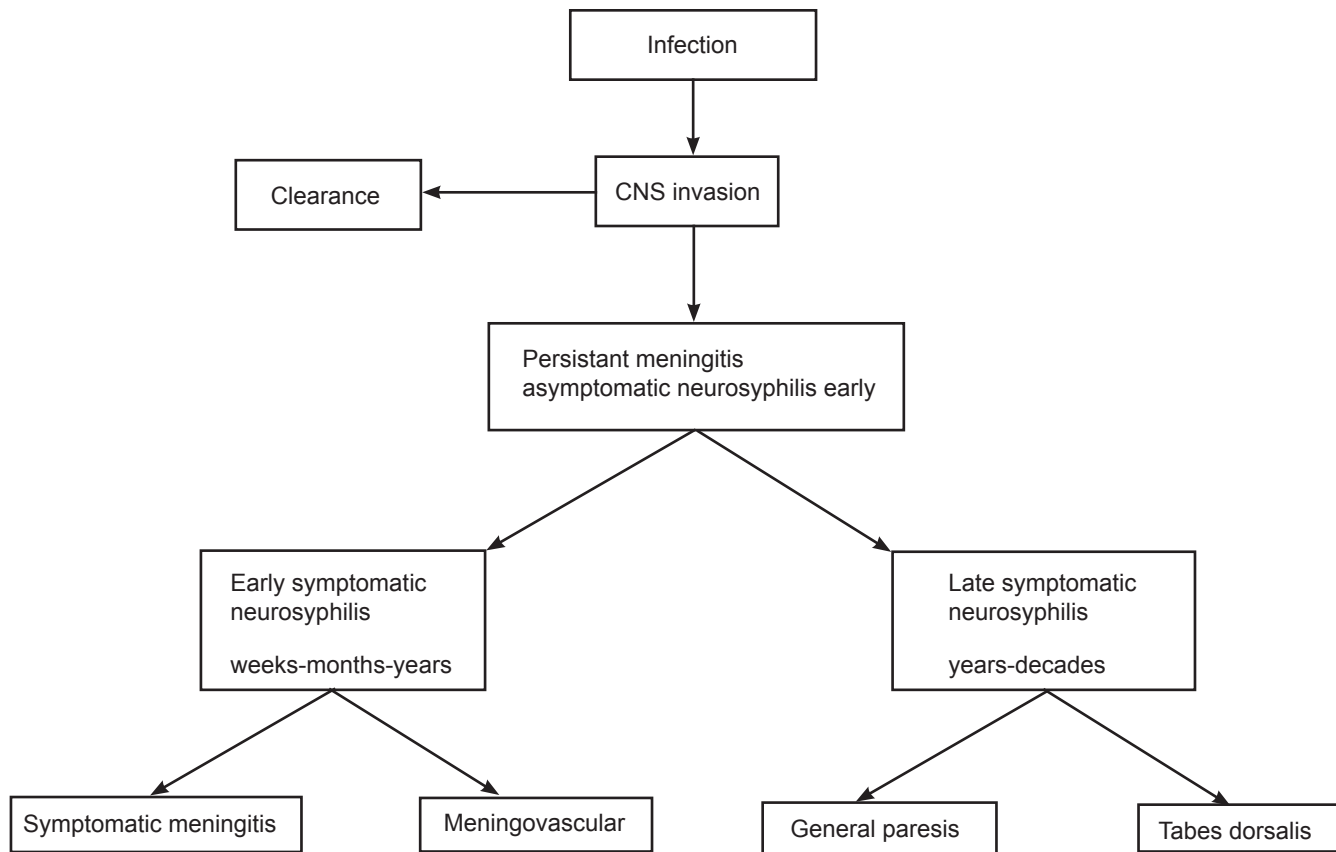


Figure. Natural history of neurosyphilis. Neuro-invasion occurs in at least 40% of individuals. Clearance occurs in about 70% of individuals. The remaining 30% of patients have persistent central nervous system (CNS) infection, also called asymptomatic neurosyphilis. In the pre-penicillin era, about 20% of individuals with asymptomatic neurosyphilis developed one of the symptomatic forms of neurosyphilis. In the penicillin era, the early forms (eg, symptomatic meningitis, meningovascularitis) are more common than the late forms (e.g., dementia and tabes dorsalis). Reprinted with permission from Marra CM.⁴

HIV-infected individuals may fail to clear the anti-treponemal antibodies after therapy, but there should be a significant decrease in levels as measured by CSF VDRL and plasma RPR testing.^{6,10} Patients also often report persistent neurologic symptoms six months after initial diagnosis and treatment.¹⁴

CONCLUSION

Given the rising prevalence of neurosyphilis, emergency physicians should consider this “cannot-miss” diagnosis, particularly among patients presenting with progressive weakness, unexplained psychiatric symptoms, new-onset dementia, or focal neurologic findings. These patients should also receive HIV testing given the rate of co-infection, unique clinical manifestations, and response to treatment.

Documented patient informed consent and/or Institutional Review Board approval has been obtained and filed for publication of this case report.

Address for Correspondence: Laura Mercurio, MD, Alpert Medical School of Brown University, Department of Emergency Medicine, 55 Claverick St., Providence, RI 02903. Email: lauraymercurio@gmail.com.

Conflicts of Interest: By the CPC-EM article submission agreement, all authors are required to disclose all affiliations, funding sources and financial or management relationships that could be perceived as potential sources of bias. The authors disclosed none.

Copyright: © 2020 Mercurio et al. This is an open access article distributed in accordance with the terms of the Creative Commons Attribution (CC BY 4.0) License. See: <http://creativecommons.org/licenses/by/4.0/>

REFERENCES

- Centers for Disease Control and Prevention. Syphilis. 2017. Available at: <https://www.cdc.gov/std/syphilis/stats.htm>. Accessed March 16, 2017.

2. Zetola NM and Klausner JD. Syphilis and HIV infection: an update. *Clin Infect Dis*. 2007;44(9):1222-8.
3. Chesson HW, Heffelfinger JD, Voigt RF, et al. Estimates of primary and secondary syphilis rates in persons with HIV in the United States, 2002. *Sex Transm Dis*. 2005;32(5):265-9.
4. Marra CM. Neurosyphilis. *Continuum (Minneap Minn)*. 2015;21(6 Neuroinfectious Disease):1714-28.
5. Solomon MM and Mayer KH. Evolution of the syphilis epidemic among men who have sex with men. *Sex Health*. 2015;12(2):96-102.
6. Pialoux G, Vimont S, Moulignier A, et al. Effect of HIV infection on the course of syphilis. *AIDS Rev*. 2008;10(2):85-92.
7. Taylor MM, Aynalem G, Olea LM, et al. A consequence of the syphilis epidemic among men who have sex with men (MSM): neurosyphilis in Los Angeles, 2001-2004. *Sex Transm Dis*. 2008;35(5):430-4.
8. Chrzaszcz-Wlodarczyk A, Wlodarczyk A, Szarmach J. Diverse clinical presentations of neurosyphilis: focus on differential diagnosis. *Neurol Sci*. 2018;39(4):803-4.
9. Marks M, Jarvis JN, Howlett W, et al. Neurosyphilis in Africa: a systematic review. *PLoS Negl Trop Dis*. 2017;11(8):e0005880.
10. Chang CC, Leslie DE, Spelman D, et al. Symptomatic and asymptomatic early neurosyphilis in HIV-infected men who have sex with men: a retrospective case series from 2000 to 2007. *Sex Health*. 2011;8(2):207-13.
11. Young H. Guidelines for serological testing for syphilis. *Sex Transm Infect*. 2000;76(5):403-5.
12. Peng J, Lu Y, Yu H, et al. Analysis of 2 Reverse syphilis testing algorithms in diagnosis of syphilis: a large-cohort prospective study. *Clin Infect Dis*. 2018;67(6):947-53.
13. de Voux A, Bernstein K, Bradley H, et al. Syphilis testing among sexually active men who have sex with men and who are receiving medical care for HIV in the United States-Medical Monitoring Project, 2013-2014. *Clin Infect Dis*. 2019;68(6):934-9.
14. Centers for Disease Control and Prevention. Symptomatic early neurosyphilis among HIV-positive men who have sex with men --- four cities, United States, January 2002--June 2004. *MMWR Morb Mortal Wkly Rep*. 2007;56(25):625-8.

An Unusual Case of Carbon Monoxide Poisoning from Formic and Sulfuric Acid Mixture

Muhammed Ershad, MD*
Athanasios Melisiotis, MD†
Zachary Gaskill, DO‡
Matthew Kelly, MD‡
Richard Hamilton, MD†

*Drexel University College of Medicine, Department of Emergency Medicine, Division of Medical Toxicology, Philadelphia, Pennsylvania

†Drexel University College of Medicine, Department of Emergency Medicine, Philadelphia, Pennsylvania

‡Penn Medicine, Division of Hyperbaric Medicine, Philadelphia, Pennsylvania

Section Editor: Rick A. McPheeters, DO

Submission history: Submitted June 27, 2019; Revision received September 19, 2019; Accepted October 2, 2019

Electronically published December 17, 2019

Full text available through open access at http://escholarship.org/uc/uciem_cpem

DOI: 10.5811/cpcem.2019.10.44265

Formic acid, when combined with sulfuric acid, gets dehydrated to form carbon monoxide (CO). A 27-year-old female was found unconscious inside a car, next to a container with a mixture of sulfuric acid and formic acid. Concentrations of up to 400 parts per million of CO were measured inside the car post ventilation. Serum carboxyhemoglobin level was 15% after receiving 100% oxygen for two hours. The patient received hyperbaric oxygen therapy after which she was extubated with normal mental status. On follow-up after three months, she demonstrated neurocognitive abnormalities suggestive of delayed neurological sequelae from CO exposure. [Clin Pract Cases Emerg Med. 2020;4(1):51–54.]

INTRODUCTION

Carbon monoxide (CO) toxicity is usually seen following exposure to smoke from house fires, heating system emissions, and exhaust fumes from motor vehicles. There are, however, various reported instances where CO produced through specific chemical reactions has been used by individuals to end their own lives. One such method involves combining formic acid with sulfuric acid, which produces CO.¹ A total of 11 such reported cases were found in the literature, one of which was an outdoor occupational exposure.²⁻¹⁰ All the other cases were acts of suicide in enclosed surroundings including home spaces and, in one particular case, inside a car. We report a patient who generated CO from a sulfuric and formic acid mixture in her car in an attempt to commit suicide.

CASE REPORT

A 27-year-old female was found unconscious in the front seat of her car. On the car floor was a five-gallon (18.9 liter [L]) plastic drum containing a funnel and hose. The drum contained a green oily fluid assumed to be a mixture of sulfuric acid and formic acid because empty containers of the same were found in the vicinity of the scene. First responders measured CO levels of 400 parts per million (ppm) inside the car, which was measured after adequate ventilation. On-scene

assessment documented that the patient was minimally responsive to pain with occasional tonic-clonic movements of her extremities. Initial vitals were a blood pressure of 192/125 millimeters mercury, heart rate of 135 beats per minute, respiratory rate of 24 breaths per minute and a Glasgow Coma Scale of 8/15 (best eye response 2, best verbal response 2, best motor response 4). She was started on 100% oxygen via a non-rebreather mask and transferred to the emergency department (ED).

In the ED, she was noted to be minimally responsive with tonic clonic movements of her distal extremities. This was followed by decerebrate rigidity. Her pupils were symmetric and reactive to light bilaterally. The remainder of her neurological exam was unremarkable. She remained tachycardic. The patient was eventually intubated for airway protection because of her depressed mental status. Her initial labs revealed an elevated carboxyhemoglobin (COHB) level of 15% (0-3%), lactate of 2 millimoles (mmol)/L (0.5-2.2 mmol/L) and a troponin level of 3.066 nanograms per milliliters (ng/ml) (0-0.03 ng/ml). The electrocardiogram was normal.

The patient was transferred to a hyperbaric center around four hours after being found on the scene and almost immediately underwent three sessions of hyperbaric oxygen therapy over 24 hours. The first session was at 2.8 ATA (atmospheres absolute) for 45 minutes, 2.0 ATA for

60 minutes, and a five-minute air break. The second two cycles were at 2.0 ATA for 90 minutes. She was extubated the next day with normal mentation and neurological exam. Around four weeks after discharge, her neurologic evaluation demonstrated an anterograde amnesia beginning with the suicide event. In addition, she demonstrated other neurocognitive abnormalities suggestive of delayed neurological sequelae (DNS). Brain magnetic resonance imaging (MRI) showed abnormal restricted diffusion with associated fluid-attenuated inversion recovery (FLAIR) signal abnormalities in the white matter of the right temporal lobe, bilateral globus pallidi, bilateral mesial temporal lobes, hippocampus and scattered foci within the bilateral cerebellar hemispheres suggestive of anoxic-ischemic brain injury.

DISCUSSION

Formic acid, when combined with sulfuric acid, gets dehydrated to produce CO. This method is used in the commercial production of CO in laboratories. In the past few years, this method has been used to commit suicide. One possible explanation could be the availability of a considerable number of books, webpages, and online forums that provide information on the production of CO for the purpose of suicide.¹¹⁻¹⁶ Interestingly, another chemical reaction that has been recommended is heating calcium carbonate and zinc to produce calcium oxide, zinc oxide, and CO.¹⁶ It is important that first responders and emergency physicians be aware of such chemical reactions so that they can deploy appropriate on-scene and personal protection precautions.

Because CO is a colorless and odorless gas, it can be hazardous to first responders on the scene. A previous case report describes how a first responder developed CO poisoning in similar circumstances requiring several days of intensive critical care to recover.⁹ In most of the reported cases, the victims had displayed warning signs outside their enclosures, warning the first responders against CO exposure. In our case, the first responders were initially unaware of a potential hazardous materials (HAZMAT) situation on the scene and hence were not adequately protected with personal protective equipment. They reported a “chemical smell” when they initially got into the car. There were, however, no reported injuries among them on later assessment. The HAZMAT team was later deployed on the scene, and after ventilating the car they identified the chemicals and measured the CO levels. Considering the CO levels were measured after appropriate ventilation of the car, the levels measured (400 ppm) were most likely an underestimation of the maximum CO concentration.

The patient was not decontaminated on the scene due to the initial lack of information about the HAZMAT involved. The ED was alerted that the patient originated in an unknown HAZMAT scene prior to patient arrival and hence the patient was decontaminated with tepid water

CPC-EM Capsule

What do we already know about this clinical entity?

Formic acid when combined with sulfuric acid generates carbon monoxide (CO) as a byproduct which has been reported as a method of suicide in various case reports.

What makes this presentation of disease reportable?

This is the first case reported where hyperbaric oxygen (HBO) therapy was used to treat such a unique form of CO poisoning. In spite of timely initiation with HBO therapy, the patient still developed delayed neurological sequelae.

What is the major learning point?

Delayed neurological sequelae can occur despite timely intervention with HBO therapy. Combining formic acid with any strong acid can potentially generate dangerous concentrations of CO, especially in enclosed spaces.

How might this improve emergency medicine practice?

Emergency physicians can be made more aware of this chemical reaction, which may help in earlier identification of potential CO toxicity and appropriate allocation of triage resources especially in a mass casualty incident.

and soap in a stand-alone decontamination room prior to entering the ED.

The initial serum COHB level measured in the ED was 15.1%, more than two hours after the patient was started on 100% oxygen. Considering that the half-life of COHB is around 75 minutes on 100% oxygen at atmospheric pressure,¹⁷ it is possible that the patient had a COHB level in the range of 45% when she was found in the car, assuming zero order kinetics.¹⁸ Use of a simplified version of the Coburn-Forster-Kane model predicts that the patient had a COHB level of 38.3 % $[(\text{COHB}(\%) = 100/[1 + R(643/\text{ppm CO})])]$.¹⁹ Previous studies have interestingly indicated poor correlation between initial COHB levels,

clinical manifestations, and the risk of delayed neurological sequelae. This patient would serve as an example to this fact, considering that the initial COHB levels were only moderately elevated despite the remarkable clinical presentation and noteworthy delayed neurological sequelae. It is also not clear how long the patient was exposed to CO inside the car before being evacuated, because the patient herself had poor recall of the events.

After resolution of the acute clinical course, the patient was admitted to psychiatry where she underwent treatment for depression. Four weeks after the exposure, she developed retrograde amnesia. She had no awareness of the suicide event or the events leading up to the suicide and demonstrated euthymia, inappropriate laughter, incongruent affect, childlike behavior, and impaired short- and long-term memory. She endorsed to having been treated for drug-resistant depression with ketamine infusions in the past but could not recall suicidality or plans of suicide around the time of the suicide attempt. She reported having no feelings of being suicidal a month after the event. At three months follow-up, many of her cognitive deficits had improved but her amnesia remained.

Delayed neurological sequelae following CO poisoning can present with a multitude of neurological and cognitive symptoms and signs. DNS may develop in up to 40% of the survivors of acute CO poisoning within 2-40 days.²⁰ A Cochrane systematic review analysis concluded that there is insufficient evidence to support the use of hyperbaric oxygen (HBO) to prevent DNS from CO poisoning.²¹ Similarly, the American College of Emergency Physicians has noted that there remains lack of clarity over whether HBO is superior to normobaric oxygen for improving long-term neurocognitive outcomes in CO exposure.²² Our patient developed DNS despite timely HBO therapy. This is the first case report of poisoning from chemical production of CO where long-term follow-up revealed delayed neurocognitive manifestations and distinct MRI findings in the face of expedient HBO therapy.

CONCLUSION

The case presented here demonstrates an unusual way of attempting suicide by combining formic acid with sulfuric acid to generate CO inside an enclosed car. The patient was treated with hyperbaric oxygen and survived the event but developed delayed neurological sequelae. Emergency physicians and first responders need to be aware of such chemical reactions to avoid injury to first responders and to guide appropriate treatment.

Documented patient informed consent and/or Institutional Review Board approval has been obtained and filed for publication of this case report.

Address for Correspondence: Muhammed Ershad, MD, Drexel University College of Medicine, Department of Emergency Medicine, Division of Medical Toxicology, 230 N. Broad St., Philadelphia, PA 19102. Email: me539@drexel.edu.

Conflicts of Interest: By the CPC-EM article submission agreement, all authors are required to disclose all affiliations, funding sources and financial or management relationships that could be perceived as potential sources of bias. The authors disclosed none.

Copyright: © 2020 Ershad et al. This is an open access article distributed in accordance with the terms of the Creative Commons Attribution (CC BY 4.0) License. See: <http://creativecommons.org/licenses/by/4.0/>

REFERENCES

- Schierz ER. The decomposition of formic acid by sulfuric acid. *J Am Chem Soc.* 1923;45(2):447-55.
- Prahlow JA and Doyle BW. A suicide using a homemade carbon monoxide "death machine." *Am J Forensic Med Pathol.* 2005;26(2):177-80.
- Wehr K, Schäfer A. [An unusual case of suicidal carbon monoxide poisoning]. *Arch Kriminol.* 1987;180(5-6):155-60.
- Schneir A, Rentmeester L. Carbon monoxide poisoning and pulmonary injury from the mixture of formic and sulfuric acids. *Clin Toxicol.* 2016;54(5):450-3.
- Bakovic M, Nestic M, Mayer D. Suicidal chemistry: combined intoxication with carbon monoxide and formic acid. *Int J Legal Med.* 2016;130(3):723-9.
- Lin PT and Dunn WA. Suicidal carbon monoxide poisoning by combining formic acid and sulfuric acid within a confined space. *J Forensic Sci.* 2014;59(1):271-3.
- Zelený M, Pivnička J, Šindler M, et al. Unusual way of suicide by carbon monoxide. Case Report. *Neuro Endocrinol Lett.* 2015;36 Suppl 1:147-9.
- Djafari G, Rosenthal I, Ingemann-Hansen O. Fatal carbon monoxide poisoning: an outdoor occupational accident case. *Inj Prev.* 2010;16(1).
- Yang CC, Ger J, Li CF. Formic acid: a rare but deadly source of carbon monoxide poisoning. *Clin Toxicol.* 2008;46(4):287-9.
- Santamaria M, Erker CG, Wilp M, et al. Kohlenmonoxidintoxikation in suizidaler Absicht durch ein Gemisch aus Schwefelsäure und Ameisensäure. *Notfall.* 2013;16(6):457-9.
- Humphry D. (2002). *Final Exit* (third edition). New York, NY: Delta Publishing.
- Kevorkian J and Kurtz P. *Medicide: the goodness of planned death.* *Free Inq.* 1991;11(4):14-8.
- Humphry D. (1995). *Dying with Dignity.* Secaucus, NJ: Random House Value Publishing.
- Hunt J. *How to kill yourself using the inhalation of carbon monoxide*

- gas. Available at: <http://www.jerryjunt.org/JerryHunt/kill.asp>. August 24, 2019.
15. Nitschke to unveil death machine. Available at: <https://www.canberratimes.com.au/story/6114720/nitschke-to-unveil-high-tech-death-pod/?cs=14231>. August 25, 2019.
 16. How can carbon monoxide be produced at home? Available at: <https://www.quora.com/How-can-carbon-monoxide-be-produced-at-home>. August 25, 2019.
 17. Weaver LK, Howe S, Hopkins R, et al. Carboxyhemoglobin half-life in carbon monoxide-poisoned patients treated with 100% oxygen at atmospheric pressure. *Chest*. 2000;117(3):801-8.
 18. Jay GD and McKindley DS. Alterations in pharmacokinetics of carboxyhemoglobin produced by oxygen under pressure. *Undersea Hyperb Med*. 1997;24(3):165-73.
 19. Touger M, Birnbaum A, Wang J, et al. Performance of the RAD-57 pulse CO-oximeter compared with standard laboratory carboxyhemoglobin measurement. *Ann Emerg Med*. 2010;56(4):382-8.
 20. Krantz T, Thisted B, Strom J, et al. Acute carbon monoxide poisoning. *Acta Anaesthesiol Scand*. 1988;32(4):278-82.
 21. Buckley NA, Juurlink DN, Isbister G, et al. Hyperbaric oxygen for carbon monoxide poisoning. *Cochrane Database Syst Rev*. 2011;(4):CD002041.
 22. Wolf SJ, Maloney GE, Shih RD, et al. Clinical policy: critical issues in the evaluation and management of adult patients presenting to the emergency department with acute carbon monoxide poisoning. *Ann Emerg Med*. 2017;69(1):98-107.e6.

Pericardial Tamponade After Systemic Alteplase in Stroke and Emergent Reversal With Tranexamic Acid

Cynthia Romero, MD*

*Emory University Hospital, Department of Emergency Medicine, Atlanta, Georgia

Samuel Shartar, MSN*†

†Emory University Hospital, Office of Critical Event Preparedness and Response, Atlanta, Georgia

Michael J. Carr, MD*

Section Editor: Rick A. McPheeters, DO

Submission history: Submitted July 7, 2019; Revision received September 28, 2019; Accepted October 9, 2019

Electronically published December 17, 2019

Full text available through open access at http://escholarship.org/uc/uciem_cpem

DOI: 10.5811/cpcem.2019.10.44369

Alteplase, or tissue plasminogen activator (tPA), lyses clots by enhancing activation of plasminogen to plasmin. Conversely, tranexamic acid (TXA) functions by inhibiting the conversion of plasminogen to plasmin, which inhibits fibrinolysis. TXA has proven safe and effective in major bleeding with various etiologies. A 76-year-old male developed acute ischemic stroke symptoms. Systemic alteplase was administered and he showed clinical improvement. Shortly thereafter, the patient became hypotensive and lost pulses. Point-of-care ultrasound revealed cardiac tamponade. TXA was immediately given to inhibit fibrinolysis since cryoprecipitate and blood products were not immediately available. Pericardiocentesis was performed and successfully removed 200 milliliters of blood with return of pulses. Clinicians must consider TXA as a rapidly accessible antagonist of tPA's fibrinolytic effects. [Clin Pract Cases Emerg Med. 2020;4(1):55–58.]

INTRODUCTION

The current treatment for acute ischemic stroke is to restore blood flow to the brain using reperfusion therapy. Several options have proven effective in reperfusion therapy including systemic or local tissue plasminogen activator (tPA or alteplase), or mechanical thrombectomy.¹ Thrombolytic therapy with tPA is considered the mainstay of treatment of acute ischemic stroke. Alteplase acts as a thrombolytic by binding to fibrin in the thrombus and enhancing the activation of plasminogen to plasmin. Plasmin lyses the thrombus into fibrin degradation products, thus initiating local fibrinolysis.¹

In the United States, approximately 795,000 strokes occur each year, of which 692,000 are ischemic strokes.² Of these, it is estimated that 3.4%–5.2% of ischemic stroke patients receive tPA, which is between 24,000 and 36,000 stroke patients yearly.¹ Thrombolytics have many risks, of which the most feared complication is intracranial hemorrhage or major bleeding elsewhere in the body.³ Pericardial tamponade is a rare adverse effect of tPA with only a few cases reported, usually associated with recent myocardial infarction.^{3–5}

Tranexamic acid (TXA) has been safely used as an antifibrinolytic in a full spectrum of clinical settings. Its on- and off-label use has rapidly expanded over the past

few decades.⁶ TXA works by blocking the conversion of plasminogen to plasmin and prevents plasmin from binding to fibrin, inhibiting clot breakdown and abating hemorrhage.⁷ There is no data regarding the efficacy or safety of the routine use of TXA to reverse tPA-induced fibrinolysis. Given its molecular mechanism of action, however, TXA is the perfect antagonist to tPA and should be considered in cases of life-threatening hemorrhage secondary to tPA administration.

CASE PRESENTATION

A 76-year-old male with past medical history of hypertension presented to the emergency department (ED) by ambulance as a stroke alert. History was obtained from the patient's family and emergency medical services (EMS). The patient was in his usual state of health, speaking to his daughter on the phone, when he abruptly stopped talking and was no longer responding to her. This prompted her to call 9-1-1. On EMS arrival, the patient appeared to be convulsing, which quickly resolved, and he was then nonverbal but remained interactive. He was noted to have left-sided hemiparesis and was expressively aphasic. The patient was not on anticoagulants and family denied any recent trauma, bleeding, or surgery.

Initial physical examination revealed a nonverbal, elderly gentleman in mild distress. He was aphasic. Vital signs were as follows: blood pressure 98/62 millimeters of mercury (mmHg), pulse 76 beats per minute, respirations 19 breaths per minute, oral temperature 36 degree Celsius ($^{\circ}\text{C}$) (96.8°F), and pulse oximetry 99% on room air. Neurologic examination was notable for pupils equally round and reactive to light, left visual field loss with right gaze preference, left facial droop, and localization of painful stimuli on the right with absence of painful withdrawal on the left upper and lower extremities. He demonstrated left upper and lower extremity hemiparesis. National Institutes of Health Stroke Scale was 18. Pulmonary examination revealed lungs clear to auscultation, and cardiac examination revealed a regular rate and rhythm with no murmurs, gallops, or rubs. There was normal peripheral perfusion in all extremities.

Labs were notable for point-of-care (POC) glucose 114 milligrams per deciliter (mg/dL) (reference range: 65 - 110 mg/dL), POC creatinine 0.66 mg/dL (reference range: 0.8 - 1.3 mg/dL), POC international normalized ratio (INR) 1.0 (reference range: 0.9 - 1.2), troponin-I < 0.03 nanograms per milliliter (ng/mL) (reference range: 0 - 0.4 ng/mL) and complete blood count notable for platelet count 143×10^9 per liter (L) (reference range: $150 - 400 \times 10^9/\text{L}$). Non-contrasted computed tomography (CT) of the head was grossly within normal limits. CT angiogram (CTA) of the head and neck did not demonstrate dissection or a large vessel occlusion, and the patient was not a candidate for thrombectomy. Evaluation of the aorta was markedly suboptimal, with mild aortic wall thickening. The heart was not visualized in the CTA head and neck study. As the patient was within the treatment window, tPA was administered one hour after symptom onset for his right middle cerebral artery syndrome acute ischemic stroke.

On re-examination 20 minutes after tPA administration, the patient was returning to his mental baseline with improving neurologic exam. He was noted to be awake, alert, and talking to his family. Approximately 45 minutes after tPA administration, the patient had an acute change in mental status, acute onset vomiting, and was noted to be hypotensive to 61/46 mmHg. Focused assessment with sonography in trauma (FAST) exam using point-of-care ultrasound revealed a large pericardial effusion with tamponade physiology, specifically right ventricular diastolic collapse (Image). He then lost pulses and cardiopulmonary resuscitation (CPR) was initiated. TXA was immediately given to inhibit tPA-induced fibrinolysis and bleeding.

Compressions were halted and pericardiocentesis was performed with 200mL of dark blood removed using a triple lumen catheter (TLC) kit. An ultrasound-guided approach with Seldinger technique was used to insert the TLC into the pericardial space. The patient subsequently regained strong pulses and began to wake up and respond to commands. Two units of uncrossed blood were then given

CPC-EM Capsule

What do we already know about this clinical entity?

Alteplase (tPA) causes lysis of fibrin clots by enhancing the activation of plasminogen to plasmin. A feared adverse effect of this medication is major hemorrhage.

What makes this presentation of disease reportable?

We report a rare, adverse effect of tPA administration causing cardiac tamponade and profound hypoperfusion, temporarily abated with tranexamic acid (TXA) and pericardiocentesis.

What is the major learning point?

TXA should be considered as an adjunct therapy for ongoing hemorrhage. Its molecular mechanism of action makes it the ideal antagonist to tPA's fibrinolytic effects.

How might this improve emergency medicine practice?

It is imperative to evaluate patients who become hypotensive after tPA with point-of-care ultrasound, including echocardiography. Consider TXA to abate hemorrhage.

to him. Cryoprecipitate was ordered but not immediately available. His blood pressure recovered to 179/117 mmHg. No epinephrine or other Advanced Cardiovascular Life Support medications were given during the period of cardiac arrest. Repeat point-of-care cardiac ultrasound showed resolution of tamponade physiology.

Cardiothoracic surgery was consulted, and they exchanged the TLC catheter for a pericardial drain over a wire in the ED. No additional blood was noted to drain from the new pericardial drain. The patient was admitted to the intensive care unit (ICU) and was awaiting transport out of the ED. During this time his family was bedside, talking with the patient. Over the next hour, he was treated with 10 units of cryoprecipitate. Approximately 3.5 hours after arrival to the ED, the patient again became unresponsive and was noted to be hypotensive and bradycardic. Point-of-care ultrasound showed re-accumulation of pericardial effusion and worsening tamponade physiology.

Unfortunately, the existing pericardial drain was not functioning even after flushing the catheter. The patient again

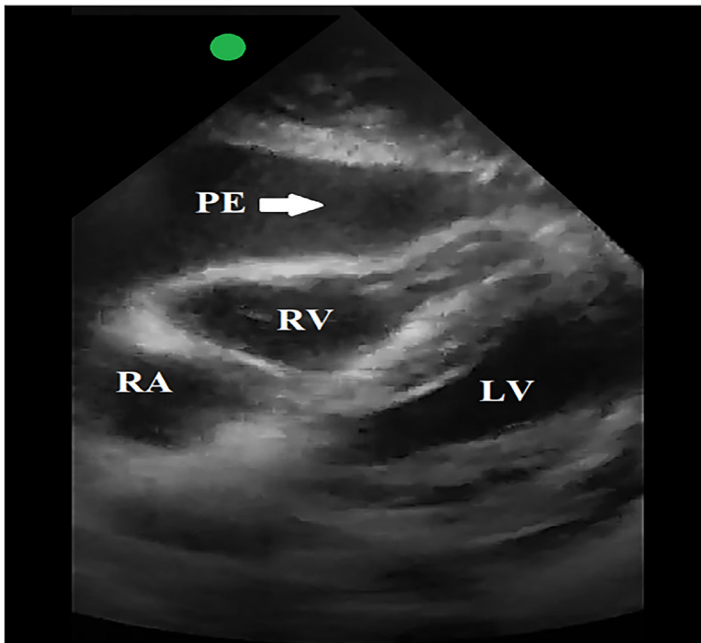


Image. In this subxiphoid view obtained with a phased array, point-of-care ultrasound probe, there is obvious pericardial effusion with right ventricular wall collapse. This demonstrates pericardial tamponade physiology in combination with the patient's vital signs and physical exam findings.

RV, right ventricle; *LV*, left ventricle; *RA*, right atrium; *PE*, pericardial effusion.

lost pulses and CPR was initiated. A second pericardiocentesis was performed by cardiothoracic surgery with removal of 800 mL of bright red blood. Despite removing the blood, the tamponade was not resolving as the re-accumulation was too great. After discussion with the patient's family, care was withdrawn and CPR discontinued, in line with their wishes. The patient expired shortly after termination of resuscitative efforts.

DISCUSSION

The treatment of acute ischemic stroke focuses on tPA administration to improve neurologic outcomes. This treatment has many well-documented complications, including intracerebral hemorrhage, systemic bleeding, angioedema, spontaneous hemothorax, and spontaneous pericardial tamponade in the setting of recent myocardial infarction.^{3,4,8} The incidence of fatal hemopericardium after tPA administration in stroke treatment is unknown.

Currently there are no approved alternatives to blood products for the reversal of tPA-induced fibrinolysis.⁹ Treatment options for intracranial hemorrhage related to tPA administration are unproven, but include platelets, cryoprecipitate, and consideration of prothrombin complex concentrate and fresh frozen plasma.¹⁰ As our patient's condition was life threatening and there was not enough time to wait for blood products to be prepared, he was immediately treated with

TXA and pericardiocentesis. There was no re-accumulation of blood in the pericardial space on repeat point-of-care ultrasound. This is the first case, to our knowledge, of cardiac tamponade with cardiac arrest after systemic tPA administration for acute ischemic stroke successfully temporized with TXA, in addition to emergent pericardiocentesis. Even though the patient ultimately died, the TXA seemed to halt the re-accumulation of blood, giving the patient time to wake up and speak to his family, which is invaluable for critically ill patients with life-threatening injuries.

TXA is an antifibrinolytic and a lysine analog that occupies binding sites on plasminogen, thus preventing its binding to fibrin and inhibiting plasminogen activation to plasmin. The blockade of lysine-binding sites on plasmin prevents binding to fibrin and thus inhibits clot breakdown.⁶ TXA causes a delay in the body's normal physiologic breakdown of platelet aggregation and ensures existing clots remain viable, lessening hemorrhage.⁷ Given its mechanism of action at the molecular level, TXA is a logical antidote for reversing the thrombolytic effects of tPA.

Most major studies of TXA use have been in the setting of traumatic hemorrhage. The largest study of TXA is the Clinical Randomization of an Antifibrinolytic in Significant Hemorrhage 2 (CRASH-2) trial, which revealed that TXA decreased the risk of death in bleeding trauma patients.¹¹ Literature review of TXA's safety and efficacy shows its wide applicability outside of the trauma setting. It has been safely used in coagulopathies, to control heavy menstrual cycle bleeding, to reduce death due to bleeding in post-partum hemorrhage, perioperatively to reduce bleeding in adult patients having elective posterior thoracic/lumbar spinal fusion surgery, and in patients undergoing cardiac surgery.^{6,7,12-14} Numerous studies and Cochran Review concluded that TXA has a good safety profile when administered within three hours of injury and demonstrated no evidence that TXA has an effect on the risk of vascular occlusive events.^{7,11,15,16}

Based on all available multidisciplinary data, TXA appears safe when used in the right timeframe without increasing risk of thrombotic events. While traditionally used in the setting of traumatic hemorrhage, it should be considered to counteract acute hemorrhage secondary to tPA administration. Again, at the molecular level, it directly counteracts the mechanism of action of tPA and can therefore be lifesaving or temporize life-threatening injuries while definitive treatment is provided. In the case of our patient, it is unclear what led to the spontaneous hemopericardium. His initial aphasia secondary to acute stroke complicated our ability to obtain a full history in order to determine if he had any recent symptoms suggesting myocardial infarction. There was also no cardiac imaging completed prior to the initial point-of-care ultrasound during the patient's resuscitation. It is not known whether there was a pre-existing pericardial effusion. Clinically, we must also consider the possibility

that the stroke and cardiac tamponade were due to an aortic dissection. No autopsy was performed to confirm this. Regardless of the exact etiology of the pericardial tamponade, it is feasible that patients with hemopericardium after tPA administration may benefit from TXA.

CONCLUSION

This case report describes the occurrence of a rare adverse effect of tPA administration, bleeding into the pericardium causing cardiac tamponade and profound hypoperfusion, temporarily abated with TXA and pericardiocentesis. This rare complication may be missed if clinicians do not maintain a high index of suspicion. Pericardiocentesis is the definitive treatment for acute pericardial tamponade. While this will serve to evacuate the existing pericardial effusion, it will not stop any further bleeding into the pericardial space and, thus, TXA should be considered as an adjunct therapy to impede ongoing hemorrhage. While traditionally used in the setting of traumatic hemorrhage, its molecular mechanism of action makes it the ideal antagonist to tPA's fibrinolytic effects. The bottom line is to consider TXA as soon as possible in the setting of massive or life-threatening hemorrhage secondary to tPA thrombolysis.

Documented patient informed consent and/or Institutional Review Board approval has been obtained and filed for publication of this case report.

Address for Correspondence: Michael J. Carr, MD, Emory University Hospital, Department of Emergency Medicine, 531 Asbury Circle, Annex Suite N340, Atlanta, GA 30322. Email: michael.j.carr@emory.edu.

Conflicts of Interest: By the CPC-EM article submission agreement, all authors are required to disclose all affiliations, funding sources and financial or management relationships that could be perceived as potential sources of bias. The authors disclosed none.

Copyright: © 2020 Romero et al. This is an open access article distributed in accordance with the terms of the Creative Commons Attribution (CC BY 4.0) License. See: <http://creativecommons.org/licenses/by/4.0/>

REFERENCES

1. Adeoye O, Hormung R, Khatro P, et al. Recombinant tissue-type plasminogen activator use for ischemic stroke in the United States: a doubling of treatment rates over the course of 5 years. *Stroke*. 2011;42(7):1952-5.
2. Benjamin EJ, Mutner P, Alonso A, et al. Heart Disease and Stroke Statistics-2019 Update: A Report from the American Heart Association. *Circulation*. 2019;139:e227.
3. Hensen H, Spaander F, Bax M, et al. Fatal hemopericardium after intravenous recombinant transplasminogen activator (rt-PA) for acute ischemic stroke. *Am J Emerg Med*. 2016;34(12):2462.e5-6.
4. Dhand A, Nakagawa K, Nagpal S, et al. Cardiac rupture after intravenous t-PA administration in acute ischemic stroke. *Neurocrit Care*. 2010;13(2):261-2.
5. De Silva DA, Manzano JJ, Chang HM, et al. Reconsidering recent myocardial infarction as a contraindication for IV stroke thrombolysis. *Neurology*. 2011;76(21):1838-40.
6. Cap AP, Baer DG, Orman JA, et al. Tranexamic acid for trauma patients: a critical review of the literature. *J Trauma*. 2011;71(1 Suppl):S9-14.
7. Carr MJ, Mell HK, Weingart SD, et al. An interdisciplinary literature review of prehospital use of tranexamic acid (TXA) in major bleeding. *J Emerg Med Services*. 2016;43(1):46-62.
8. Kelmenson DA, Kurche JS, Geraci M. Spontaneous hemothorax resulting from tissue plasminogen activator in a patient with ischemic stroke and unrecognized recent myocardial infarction. *Ann Am Thorac Soc*. 2015;12(7):1105-6.
9. French KF, White J, Hoesch RE. Treatment of intracerebral hemorrhage with tranexamic acid after thrombolysis with tissue plasminogen activator. *Neurocrit Care*. 2012;17(1):107-11.
10. Yaghi S, Boehme AK, Dibu J, et al. Treatment and Outcome of Hemorrhagic Transformation After Intravenous Alteplase in Acute Ischemic Stroke: A Scientific Statement for Healthcare Professionals from the American Heart Association/American Stroke Association. *Stroke*. 2017;48:e343.
11. Shakur H, Roberts I, Bautista R, et al. Effects of tranexamic acid on death, vascular occlusive events, and blood transfusion in trauma patients with significant haemorrhage (CRASH-2): a randomised, placebo-controlled trial. *Lancet*. 2010;376(9734):23-32.
12. Women Trial Collaborators. Effect of early tranexamic acid administration on mortality, hysterectomy, and other morbidities in women with post-partum haemorrhage (WOMAN): an international, randomised, double-blind, placebo-controlled trial. *Lancet*. 2017;389(10084):2105-16.
13. Wong J, El beheiry H, Rampersaud YR, et al. Tranexamic acid reduces perioperative blood loss in adult patients having spinal fusion surgery. *Anesth Analg*. 2008;107(5):1479-86.
14. Myles P, Smith J, Forbes A, et al. Tranexamic acid in patients undergoing coronary-artery surgery. *N Engl J Med*. 2017;376(2):136-48.
15. Gayet-ageron A, Prieto-merino D, Ker K, et al. Effect of treatment delay on the effectiveness and safety of antifibrinolytics in acute severe haemorrhage: a meta-analysis of individual patient-level data from 40 138 bleeding patients. *Lancet*. 2018;391(10116):125-32.
16. Ker K, Roberts I, Shakur H, et al. Antifibrinolytic drugs for acute traumatic injury. *Cochrane Database Syst Rev*. 2015;(5):CD004896.

Paraspinal Abscess in a Two-year-old Female

Rachel O'Donnell, MD*

Sean Sayani, MD*

Phillip Aguiñiga-Navarrete, RA*

Daniel Quesada, MD†

Kieron Barkataki, DO*

Madison Brooke Garrett, RA*

*Kern Medical Center, Department of Emergency Medicine, Bakersfield, California

†LAC + USC Medical Center, Department of Emergency Medicine, Los Angeles, California

Section Editor: Rick A. McPheeters, DO

Submission history: Submitted August 6, 2019; Revision received October 16, 2019; Accepted October 17, 2019

Electronically published December 17, 2019

Full text available through open access at http://escholarship.org/uc/uciem_cpem

DOI: 10.5811/cpcem.2019.10.44857

A paraspinal abscess is an uncommon condition frequently diagnosed late due to equivocal symptoms, which can lead to increased morbidity and mortality. Commonly associated risk factors include prior invasive spinal procedures, diabetes mellitus, trauma, chronic steroid use, malnutrition, intravenous drug use and an immunocompromised state. Pediatric paraspinal abscesses are not well documented in the literature. We report a case of a two-year-old female presenting with fevers, lower back pain, and decreased oral intake ultimately diagnosed with isolated lumbar paraspinal abscess. The patient underwent an ultrasound-guided percutaneous drainage of the abscess, subsequently improving, and was discharged within 48 hours of presentation. [Clin Pract Cases Emerg Med. 2020;4(1):59–61.]

INTRODUCTION

Due to the infrequency of paraspinal abscesses, no reliable figures on prevalence are documented in North America. Within developing nations, the incidence is roughly one in 100,000 – 250,000.^{1,2} The most common etiology is an abscess resulting from an invasive spinal procedure such as a lumbar puncture, epidural anesthesia, or both. Hematogenous, lymphatic and direct spread from adjacent sites have been reported, but are of greater rarity in the literature.^{2,3} Due to non-specific symptoms and unreliable expressions, pediatric patients are commonly diagnosed late in the disease process, which can increase morbidity and mortality.³ We present a rare case of pediatric paraspinal abscess, diagnosis and management.

CASE REPORT

A two-year-old female born at term with no known medical history presented to the emergency department (ED) with her family complaining of fevers, right lower back pain, and abdominal pain for six days. The patient's parents reported decreased oral intake, fussiness, and increased refusal to ambulate. Vitals were significant for a heart rate of 145 beats per minute and temperature of 39.8 degrees Celsius (103.6° Fahrenheit). Physical examination was positive for a fussy,

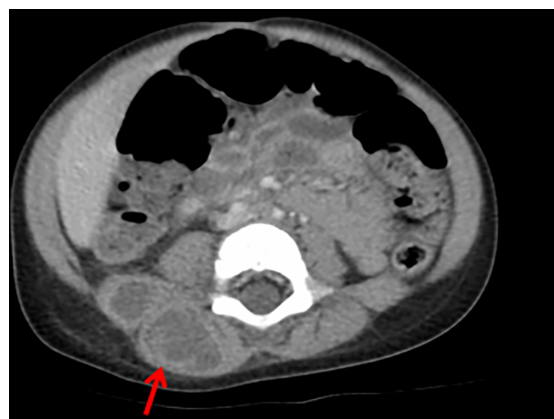

Image 1. Axial computed tomography of the lumbar spine revealing areas of low density with some rim enhancement in the right posterior paraspinal muscles (arrow) consistent with abscess.

difficulty to console child who refused to stand or ambulate. A mild amount of swelling and erythema was observed on the right lower back, which was tender to palpation.

Lab findings were significant for leukocytosis 15.2×10^9 liters (L) (5.0×10^9 – 11.0×10^9 L), Lactic acidosis 4.6 millimoles (mmol) per L (2.0–4.0 mmol/L), elevated CRP (C-reactive

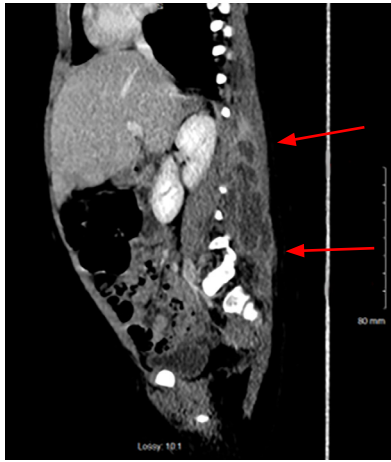

Image 2. Sagittal computed tomography of the lumbar spine revealing a rim-enhancing paraspinal muscle abscess extending from lumbar vertebrae 1 (L1) to L5 (arrows).

protein) 7.4 milligrams per deciliter (mg/dL) (0.0–3.0 mg/dL) and ESR (erythrocyte sedimentation rate) 82 millimeters per hour (mm/hr) (3–13 mm/hr). Due to the clinical presentation and lab findings, a computed tomography (CT) of the abdomen and pelvis was ordered. The imaging was significant for multiloculated fluid collection in the right paraspinal musculature extending from lumbar vertebrae 1 (L1) to L5 without spinal, bony or canal involvement (Images 1 and 2). The patient was given intravenous (IV) fluids, IV vancomycin, and piperacillin/tazobactam; she subsequently had an ultrasound-guided percutaneous drainage of the abscess completed. Cultures of the abscess were positive for methicillin-susceptible *Staphylococcus aureus*. Blood cultures were negative. The patient had no resulting neurological sequelae, and was ambulating and eating within 24 hours. Her symptoms resolved and she was discharged with clindamycin palmitate within 48 hours of initially presenting to the ED.

DISCUSSION

A paraspinal abscess is frequently diagnosed late in the disease process unless a physician has a high index of suspicion. Our patient had no identifiable etiology or risk factors to explain how the abscess might have developed. Paraspinal abscesses commonly occur in the mid-thoracic and lumbar spine, similar to our case.³ *S. aureus* accounts for up to 79% of isolated bacteria in pediatric cases, with Streptococcal and *Escherichia coli* infections also reported.³ Other possible organisms include fungi such as *Candida* and *Cryptococcus* species, although they are rare causes. Risk factors include previous spinal procedures, diabetes mellitus, trauma, immunocompromised state, chronic steroid use, malnutrition and IV drug use.^{4,5} Back pain and fever are common symptoms, seen in 50% of cases, and they were present in our case. Other symptoms

CPC-EM Capsule

What do we already know about this clinical entity?

Paraspinal abscesses are rare in children. Usually these abscesses are due to invasive spinal procedures; less commonly, they are hematogenous or direct spread.

What makes this presentation of disease reportable?

This image demonstrates the rare finding of a paraspinal abscess in a pediatric patient with no identifiable risk factors.

What is the major learning point?

Paraspinal abscesses can present in the pediatric patient population, even without previous instrumentation or risk factors.

How might this improve emergency medicine practice?

Emergency physicians should consider broadening the differential to include paraspinal abscesses in pediatric patients presenting with non-specific symptoms.

include weakness, other neurological deficits, and death late in the disease course.²

CRP and ESR are both sensitive but not specific modalities that aid in diagnosis. A normal white blood cell count does not exclude the diagnosis. Procalcitonin recently has been shown to be helpful in diagnosis, especially when trying to discern if the organism is bacterial, but it has lower sensitivity than a CRP.⁵ Plain radiographs are not commonly used for diagnosis as pathology is difficult to visualize until it is late in the disease course (after 3-4 weeks). Some observable features include soft tissue swelling and eventual bony destruction.² Magnetic resonance imaging is the gold standard for diagnostic imaging due to high sensitivity and specificity rates of 96% and 94%, respectively. CT imaging is used frequently due to cost and accessibility.⁵ Medical management using parenteral antibiotics can be initially attempted for smaller abscesses due to adequate penetration into paraspinal tissues, although larger abscesses may warrant percutaneous drainage. Surgical debridement should follow with failure of conservative management, neurological signs, spinal instability, and spinal lesions.⁵

CONCLUSION

Paraspinal abscesses can be present with nonspecific symptoms. Pediatric patients can be more difficult to diagnose, as the child may be unable to effectively describe abdominal and back complaints, as in the presented patient. This case illustrates the importance of conducting a thorough history and physical examination with a wide differential diagnosis, especially in the pediatric population. Early diagnosis is imperative to prevent further progression of the disease course, and to reduce hospital stay.

Documented patient informed consent and/or Institutional Review Board approval has been obtained and filed for publication of this case report.

REFERENCES

1. Sharma RR, Sethu AU, Mahapatra AK, et al. Neonatal cervical osteomyelitis with paraspinal abscess and Erb's palsy. *Pediatr Neurosurg*. 2000;32(5):230-3.
2. Acharya U. A case of atypical presentation of thoracic osteomyelitis & paraspinal abscess. *McGill J Med*. 2008;11(2):164-7.
3. Kiyamaz N and Demir O. Spontaneous cervical paraspinal and epidural giant abscess in a child—case report. *Neurol Med Chir (Tokyo)*. 2005;45(10):540-2.
4. Chen CT, Lin JC, Chang SY. Cough syncope induced by paraspinal abscess. *Am J Med Sci*. 2014;347(1):86-7.
5. Lener S, Hartmann S, Barbagallo GMV, et al. Management of spinal infection: a review of the literature. *Acta Neurochir (Wien)*. 2018;160(3):487-96.

Address for Correspondence: Rachel O'Donnell, MD, Kern Medical Center, Department of Emergency Medicine, 1700 Mount Vernon Ave., Bakersfield, CA 93306. Email: Rachel.o'donnell@kernmedical.com.

Conflicts of Interest: By the CPC-EM article submission agreement, all authors are required to disclose all affiliations, funding sources and financial or management relationships that could be perceived as potential sources of bias. The authors disclosed none.

Copyright: © 2020 O'Donnell et al. This is an open access article distributed in accordance with the terms of the Creative Commons Attribution (CC BY 4.0) License. See: <http://creativecommons.org/licenses/by/4.0/>

Bisphosphonate-related Femoral Shaft Fracture

Jesse Kellar, MD, MBA

Alan Givertz, MD

Jessica Mathias, BS

Jessica Cohen, MSMHS

Saint Agnes Medical Center, Department of Emergency Medicine, Fresno, California

Section Editor: Rick A. McPheeters, DO

Submission history: Submitted August 30, 2019; Revision received October 14, 2019; Accepted October 17, 2019

Electronically published December 17, 2019

Full text available through open access at http://escholarship.org/uc/uciem_cpchem

DOI: 10.5811/cpchem.2019.10.45007

The efficacy of using bisphosphonate therapy to treat osteoporotic patients is becoming more widely known, but the potential side effects may not be. While this class of drugs is generally safe, concerns have emerged regarding risks of atypical subtrochanteric fractures associated with long-term use. There have been a number of case reports discussing the association of patients on bisphosphonates who suffer a non-traumatic or a low-energy mechanism of injury atypical of subtrochanteric fractures. The purpose of this case report is to raise awareness of this potential side effect and provide increased clinical suspicion for this rare type of fracture. [Clin Pract Cases Emerg Med. 2020;4(1):62–64.]

INTRODUCTION

The risk of fracture in osteoporotic patients is high due to the low bone-mineral density and poor bone quality, which develops as an individual ages. It has been estimated that more than 200 million people worldwide have osteoporosis, including about 75 million in the United States, Europe, and Japan.¹ The condition is especially common in postmenopausal women as approximately half of all women over the age of 50 will experience an osteoporosis-related fracture at some point during their lifetime.² Twenty percent of these patients will die within 12 months after sustaining a fracture.²

The National Institutes for Health and Care Excellence recommends bisphosphonates as the treatment of choice for all patients over the age of 50 who are at risk of a fragility fracture, and for those patients under age 50 with a prior history of fragility fracture. The most commonly prescribed drugs from the bisphosphonate class are alendronate, risedronate, ibandronate, and zoledronic acid. These function to inhibit bone resorption and interfere with the action of bone-resorbing osteoclasts.³ Bisphosphonates can be administered orally or intravenously in a wide range of doses. While bisphosphonates have proven to reduce the occurrence of spinal and hip fractures, long-term users are found to have a higher susceptibility to atypical subtrochanteric fractures.

CASE REPORT

A 79-year-old female with significant past medical history including osteoporosis presented to the emergency department

(ED) with severe, throbbing left hip pain after a ground-level fall. She was walking around a corner when she ran into a doorknob with her left leg. The patient subsequently fell to the ground and was unable to get back up. On the initial paramedic assessment, as well as in the ED, the patient's left hip was rotated with obvious shortening and major deformity at the left mid femur. The left foot was neurovascularly intact. A radiograph of the femur revealed an acute mid femoral-shaft fracture with characteristic lateral cortex breaking consistent with bisphosphonate fracture (Images 1 and 2).

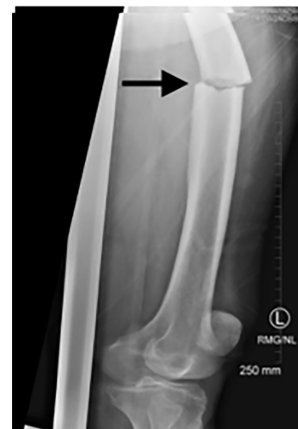

Image 1. Lateral view of left femur reveals acute mid-femoral shaft fracture with characteristic lateral cortex beaking consistent with bisphosphonate fracture (arrow).

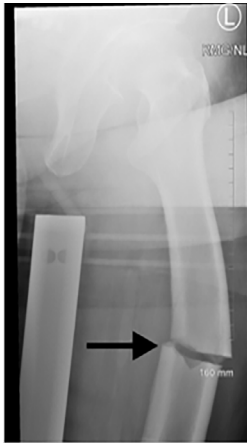

Image 2. Frontal view of the pelvis reveals acute mid-femoral shaft fracture with characteristic lateral cortex beaking consistent with bisphosphonate fracture (arrow).

Her prescription history confirmed that she was on aspirin and a 70 milligram tablet of alendronate every seven days from September 2018 through June 2019. She had an orthopedics consultation and underwent a left hip cephalomedullary nail procedure.

DISCUSSION

In 2005, a report of nine patients on long-term alendronate documented that they had suffered low-energy nonvertebral fractures, with three of the nine patients having an atypical subtrochanteric fracture.³ Low-energy fractures are caused by minimal trauma such as bumping into a door, stepping off a curb, or walking. As described in the case study presented above, the patient suffered a ground-level fall after walking into a doorknob. While this patient had immediate severe pain and an obvious deformity after the fall, some patients can have early pain in the affected region weeks to months before sustaining a spontaneous or low-trauma injury.³ Of patients who have an atypical subtrochanteric fracture, 32-76% present with persistent non-traumatic pain in the groin or hip.⁴ The pain is most commonly presented in the anterior or lateral thigh or in the groin.

If a patient is on long-term bisphosphonates and presents with this pain, it should be a signal to obtain a radiograph of the lower extremity. While the fracture pathogenesis is still unknown, there is evidence suggesting that long-term bisphosphonate use may stop bone metabolism, limiting the repair of microdamage and creating the risk of low-energy fractures.⁵ Radiography is the first step to rule out this type of fracture. An anteroposterior and lateral plain radiograph of the hip, including the full diaphysis of the femur, should be performed.² If images appear normal but clinical suspicion remains high, a technetium bone scan or magnetic resonance imaging (MRI) may be performed. In order to confirm the

CPC-EM Capsule

What do we already know about this clinical entity?

Bisphosphonate therapy is commonly used to treat osteoporosis, and help prevent bone loss and future fractures. A potential side effect is atypical femoral fractures.

What makes this presentation of disease reportable?

This case highlights the need for high clinical suspicion of fracture in patients on bisphosphonate therapy, even those with low mechanism of injury.

What is the major learning point?

Understanding the potential side effects of bisphosphonate therapy, including atypical femoral fractures.

How might this improve emergency medicine practice?

This case will help elevate the suspicion for a fracture in patients on bisphosphonate therapy who come into the emergency department after suffering from a low mechanism of injury.

diagnosis of an atypical subtrochanteric fracture, MRI is required even if initial findings were discovered on a radiograph. Once an atypical fracture is confirmed, the bisphosphonate regimen must be stopped and patients should be administered daily calcium and vitamin D supplementation.

CONCLUSION

The benefits versus risks of patients using bisphosphonates should ultimately be decided by the patient's primary care provider. The purpose of this case report is to raise provider awareness regarding these risks and to have increased clinical suspicion for an atypical subtrochanteric fracture if a patient presents with these signs and symptoms.

ACKNOWLEDGMENT

The authors would like to acknowledge orthopedic surgeon Julia Lee, MD, (Fresno, California) for her expertise and assistance on this case.

Documented patient informed consent and/or Institutional Review Board approval has been obtained and filed for publication of this case report.

REFERENCES

1. Lewiecki ME. Bisphosphonates for the treatment of osteoporosis: Insights for clinicians. *Ther Adv Chronic Dis*. 2010;1(3):115-28.
2. Kharwadkar N, Mayne B, Lawrence JE, et al. Bisphosphonates and atypical subtrochanteric fractures of the femur. *Bone Joint Res*. 2017;6(3):144-53.
3. Russell R. Bisphosphonates: the first 40 years. *Bone*. 2011;49(1):2-19.
4. Silverman S, Kupperman E, Bukata S. Bisphosphonate-related atypical femoral fracture: managing a rare but serious complication. *Cleve Clin J Med*. 2018;85(11):885-93.
5. Neviasser A, Lane J, Lenart B, et al. Low-energy femoral shaft

Address for Correspondence: Jesse Kellar, MD, Saint Agnes Medical Center, Department of Emergency Medicine, 1303 E. Herndon Ave, Fresno, CA 93711. Email: jesse.kellar@vituity.com.

Conflicts of Interest: By the *CPC-EM* article submission agreement, all authors are required to disclose all affiliations, funding sources and financial or management relationships that could be perceived as potential sources of bias. The authors disclosed none.

Copyright: © 2020 Kellar et al. This is an open access article distributed in accordance with the terms of the Creative Commons Attribution ([CC BY 4.0](http://creativecommons.org/licenses/by/4.0/)) License. See: <http://creativecommons.org/licenses/by/4.0/>

fractures associated with alendronate use. *J Orthop Trauma*. 2008;22(5):346-50.

Cesarean Scar Ectopic Pregnancy: Diagnosis With Ultrasound

Taryn Hoffman, MD, MS
Judy Lin, MD

Maimonides Medical Center, Department of Emergency Medicine Brooklyn, New York

Section Editor: Steven Walsh, MD and Rick A. McPheeters, DO

Submission history: Submitted June 6, 2019; Revision received October 14, 2019; Accepted October 17, 2019

Electronically published January 15, 2020

Full text available through open access at http://escholarship.org/uc/uciem_cpchem

DOI: 10.5811/cpchem.2019.10.43988

We present a rare case of cesarean scar ectopic pregnancy as diagnosed by transvaginal ultrasonography. Cases such as this are rare, but they are becoming more commonly detected with the growing frequency of cesarean sections, improving technology, and provider proficiency with point-of-care ultrasound. Quick identification of this dangerous diagnosis can be life saving for the patient, as the outcomes of ruptured cesarean ectopic pregnancy may include significant hemorrhage, uterine rupture, and possibly maternal death. [Clin Pract Cases Emerg Med. 2020;4(1):65–68.]

INTRODUCTION

The rates of cesarean deliveries have shown a steady increase over the past few decades.¹ Given this increase and the improved technology of sonographic imaging, the incidence of detection of cesarean scar ectopic pregnancies has also shown a rise.¹ A cesarean scar pregnancy (CSP) is a developing pregnancy implanted in the myometrium of a previous cesarean delivery scar.² Although CSP is still a rare diagnosis, it is of critical importance for practitioners to be able to quickly identify and intervene on this dangerous condition. Undiagnosed CSP may progress to uterine rupture, hemorrhage, loss of future fertility, and possibly maternal death.

Overall mortality has trended downwards, but unrecognized ectopic pregnancy of any abnormal location remains a significant cause of pregnancy-related death.³ Ectopic pregnancies comprise approximately 2% of all pregnancies.² Treatment for a diagnosed CSP may include both medical and surgical options, with the best option likely being a combination approach.^{4,5} Diagnosis is most rapidly made by ultrasound. We present a rare case of cesarean scar ectopic pregnancy as diagnosed by transvaginal ultrasonography.

CASE REPORT

A 28-year-old female gravida 6 para 3023 with a last menstrual period six weeks prior presented to the emergency department (ED) for vaginal bleeding. She denied any fever, chills, abdominal pain, nausea, vomiting, chest pain, or dizziness. She had a past surgical history of three prior cesarean sections. Her urine beta human chorionic gonadotropin (β -hCG) was positive in the ED, and her serum

quantitative β -hCG was 19,175 milli-international units per milliliter (mIU/mL) (reference < 5 mIU/mL). A transvaginal point-of-care ultrasound (POCUS) was performed, revealing a gestational sac with a yolk sac located on the anterior aspect of the lower uterine segment (Video). The endomyometrial mantle was measured at 0.35 centimeters and therefore concerning for an ectopic pregnancy (Image). Other ultrasound findings of cesarean scar ectopic pregnancy are depicted in the figure and table below.

The obstetrics and gynecology (OB/GYN) team was consulted and their repeat transvaginal ultrasound confirmed

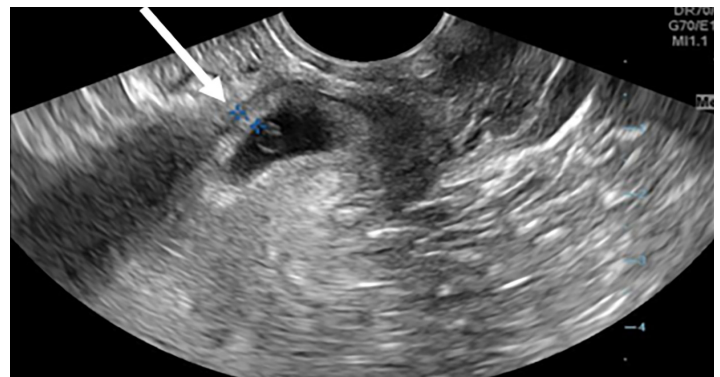


Image. Transvaginal ultrasound view of uterus in sagittal plane showing cesarean scar ectopic pregnancy. Myometrium thickness of anterior uterine segment (arrow) measures 0.35 centimeters, which meets diagnostic criteria for ectopic pregnancy.⁶

the abnormal location of the yolk sac, which was concerning for a CSP. Due to her lack of abdominal pain, the patient was discharged home and instructed to follow up at the OB/GYN clinic the next day. On next day follow-up, she received an ultrasound showing an unruptured CSP and received a dose of intramuscular methotrexate at one milligram per kilogram (mg/kg). She was instructed to return the day after to receive a multi-dose regimen of methotrexate alternating with intramuscular leucovorin at 0.1mg/kg, but did not return for repeat dosing. She was contacted one month later and reported that she no longer had any abdominal pain or vaginal bleeding.

DISCUSSION

Cesarean scar ectopic pregnancies are rare, comprising less than 1% of all pregnancies.² In recent years, the incidence has increased due to the growing frequency of cesarean sections. The Centers for Disease Control and Prevention (CDC) reported a cesarean section rate of 20.7% in 1996, which grew to 32% in 2017 in the United States. This increase in rate of CSP detection may also be due to improvements in image quality of transvaginal ultrasound as well as the increasing use of transvaginal POCUS. This uncommon condition was first described by Larsen and Solomon in 1978, with only 19 additional cases documented until 2001.^{7,8} It now accounts for nearly 5% of all ectopic pregnancies in women with prior cesarean deliveries.⁹

Ultrasound is the initial imaging test of choice for diagnosis of CSP with a sensitivity of 86.4%.⁸ When evaluating a first trimester pregnancy by transvaginal ultrasound, there are multiple criteria used to diagnose CSP (Table).

A CSP is diagnosed when the uterine cavity and cervical canal are empty and the gestational sac is in the anterior portion of the uterine isthmus.⁸ The thickness of the myometrium at the site of implantation is thin; this can be measured at the site between the gestational sac and the bladder, and is abnormal when less than eight millimeters.^{5,11} Approximately two-thirds of cases of CSP have a myometrial thickness less than five millimeters.⁶ This abnormal implantation occurs when the blastocyst implants into the scar tissue from a prior cesarean incision; it invades into the remaining tract from the prior uterine wall disruption.¹² Women who have had multiple cesarean deliveries carry a higher risk of abnormal implantation into the fibrotic scar tissue.⁶

There are two types of CSP, differentiated by the depth of invasion. The first type is implanted deeply into the scar defect, up to the serosal lining and possibly into the bladder or abdominal cavity. This type is very dangerous; it has a high risk of uterine rupture and hemorrhage.¹³ The second type implants in the scar but grows away from the serosal lining and toward the uterine cavity.²

When evaluating a pregnant patient with vaginal bleeding or abdominal pain, it is important to consider ectopic pregnancy, abnormally invasive placenta and

CPC-EM Capsule

What do we already know about this clinical entity?
A developing pregnancy can implant into the preexisting scar from a prior cesarean section delivery. Delayed diagnosis could lead to hemorrhage and maternal death.

What makes this presentation of disease reportable?
We present a rare cause of ectopic pregnancy with abnormal sono-anatomy identified through point-of-care ultrasound (POCUS), leading to expedited consult and diagnosis.

What is the major learning point?
Cesarean scar pregnancy (CSP) should be in the differential diagnosis for any pregnant patient with abdominal pain or bleeding. POCUS findings can raise suspicion for CSP.

How might this improve emergency medicine practice?
Educating providers on POCUS findings consistent with CSP may help to avoid misdiagnosis and expedite obstetrics consultation and appropriate management.

spontaneous abortion.¹⁴ Taking a thorough history including outcomes of all prior pregnancies is crucial. When considering CSP, cervical ectopic pregnancy and abortion in progress should also be included in the differential. A cervical ectopic pregnancy will have the gestational sac implanted in the cervix, with the sac located in the endocervical canal rather than embedded in the anterior lower uterine segment. This may look similar to a CSP, but the anterior myometrium will be of normal thickness. When examining an abortion in progress, the cervical os may be open, the anterior myometrium will also be of normal thickness, and the fetus may be seen within the cervical canal without fetal cardiac activity. The cervical os is closed in a CSP, so the pelvic exam is useful to help further differentiate these diagnoses.^{9, 15}

Currently there are several acceptable methods of treatment for CSP. A retrospective chart review conducted by Riaz, et al. of 20 women with CSPs found that these patients were treated with a combination of intramuscular

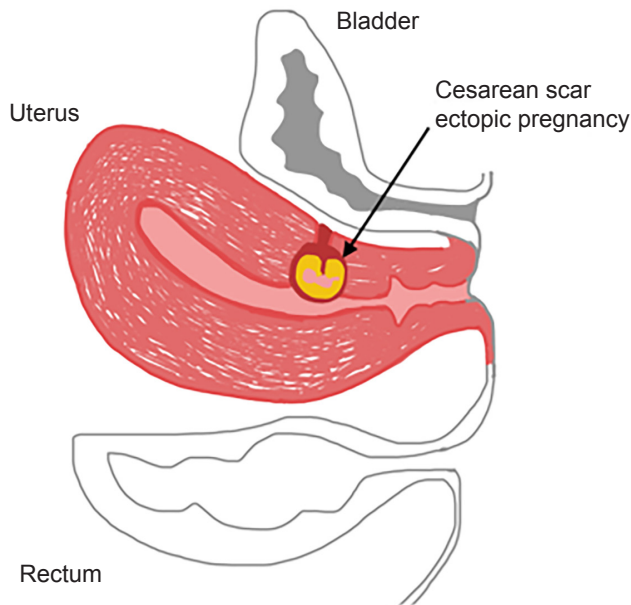


Figure. Anatomic depiction of uterus with cesarean scar ectopic pregnancy. Features of cesarean scar ectopic pregnancy seen here include an empty uterus, gestational sac implanted in lower anterior segment of uterus with thin myometrium and empty cervical canal.¹⁰

Table. Ultrasound criteria for diagnosis of cesarean scar ectopic pregnancy.⁶

1. Empty uterus with clearly visualized endometrium
2. Empty cervical canal
3. Gestational sac implanted in the lower anterior uterine segment at the presumed site of cesarean section incision scar
4. Thin or absent myometrium between the gestational sac and the bladder. (Majority of cases have a myometrium thickness < 5 millimeters)

methotrexate, local embryocidal methotrexate injection, or surgery.¹⁵ Five of the 15 patients who received methotrexate had successful abortions, although three of those patients required additional doses. Although single-dose therapy has been found to be effective in some cases, it is likely that patients will require additional doses or more invasive treatments for successful termination of the ectopic pregnancy. There is no widely accepted consensus on the matter; practice patterns vary based on patient, provider, and facility in which the treatment takes place. The goals of therapy are the same, however, which are to prevent dangerous blood loss or uterine rupture while preserving the woman's fertility for future conceptions.¹⁵ When methotrexate fails or is not an option, the next-line therapy is laparoscopic resection.¹⁶

CONCLUSION

Ultrasonography has become a vital skill in the scope of practice for emergency physicians. It allows for rapid identification of potentially life-threatening conditions. This case report reveals an interesting and rare case of CSP as diagnosed by transvaginal ultrasound. Although diagnosis of CSP on ultrasound may be outside the scope of practice for emergency physicians, it is still important to be aware of CSPs and they should be within the differential of any pregnant patient presenting with abdominal pain or vaginal bleeding with a history of prior cesarean section. Knowledge of the criteria for CSP can help emergency physicians to be familiar with findings of an abnormal pregnancy on ultrasound, which should prompt additional imaging and urgent consultation from an obstetrician.

Video. Ultrasound clip of cesarean scar ectopic pregnancy with narration. Indicator shows relevant anatomy: empty uterus with a clearly visualized endometrium; empty cervical canal; and gestational sac implanted in the anterior lower uterine segment with a thin myometrium measured at 0.35 centimeters.⁶

Documented patient informed consent and/or Institutional Review Board approval has been obtained and filed for publication of this case report.

Address for Correspondence: Taryn Hoffman, MD, MS, Maimonides Medical Center, Department of Emergency Medicine, 4802 Tenth Ave., Brooklyn, NY 11219. Email: thoffman@maimonidesmed.org.

Conflicts of Interest: By the CPC-EM article submission agreement, all authors are required to disclose all affiliations, funding sources and financial or management relationships that could be perceived as potential sources of bias. The authors disclosed none.

Copyright: © 2020 Hoffman et al. This is an open access article distributed in accordance with the terms of the Creative Commons Attribution (CC BY 4.0) License. See: <http://creativecommons.org/licenses/by/4.0/>

REFERENCES

1. Gonzalez N and Tulandi T. Cesarean scar pregnancy: a systematic review. *J Minim Invasive Gynecol.* 2017;24(5):731-8.
2. Abbas A, Ali S, Nagy M, et al. Accidental diagnosis and conservative management of a case of first-trimester cesarean scar ectopic pregnancy. *Int J Reprod Contracept Obstet Gynecol.* 2018;7(4):1628-30.
3. Dibble E and Lourenco A. Imaging unusual pregnancy Implantations:

- rare ectopic pregnancies and more. *AJR Am J Roentgenol*. 2016;207(6):1380-92.
4. Maheux-Lacroix S, Li F, Bujold E, et al. Cesarean scar pregnancies: a systematic review of treatment options. *J Minim Invasive Gynecol*. 2017;24(6):915-25.
 5. Birch Petersen K, Hoffmann E, Ribbjerg Larsen C, et al. Cesarean scar pregnancy: a systematic review of treatment studies. *Fertil Steril*. 2016;105(4):958-67.
 6. Osborn DA, Williams TR, Craig BM. Cesarean scar pregnancy: sonographic and magnetic resonance imaging findings, complications, and treatment. *J Ultrasound Med*. 2012;31(9):1449-56.
 7. Larsen JV and Solomon MH. Pregnancy in a uterine scar sacculus—an unusual cause of postabortal haemorrhage. A case report. *S Afr Med J*. 1978;53(4):142-3.
 8. Ash A, Smith A, Maxwell D. Cesarean scar pregnancy. *BJOG*. 2007;114(3):253-63.
 9. El-badawy Awad ES, Samy El-agwany A, Mahmoud El-habashy A, et al. Lower uterine segment pregnancy (Cesarean scar pregnancy and early placenta accreta): a rising complication from cesarean section with possible and similar early ultrasound diagnoses and management. *Egypt J Radiol Nuc Med*, 2015;46(4):977-80.
 10. Timor-Tritsch IE, Monteagudo A, Bennett T, et al. A new minimally invasive treatment for cesarean scar pregnancy and cervical pregnancy. *Am J Obstet Gynecol*. 2016;215(3):351.e1-8.
 11. Timor-Tritsch IE, Monteagudo A, Cali G, et al. Easy sonographic differential diagnosis between intrauterine pregnancy and cesarean delivery scar pregnancy in the early first trimester. *Am J of Obstet and Gynecol*. 2016;215(2):225.e1-7.
 12. Aich R, Solanki N, Kekadiya K, et al. Ectopic pregnancy in caesarean section scar: a case report. *Radiol Case Rep*. 2015;10(4):68-71.
 13. Godin PA, Bassil S, Donnez J. An ectopic pregnancy developing in a previous caesarian section scar. *Fertil Steril*. 1997;67(2):398-400.
 14. Timor-Tritsch IE, Monteagudo A, Cali G, et al. Cesarean scar pregnancy and early placenta accreta share common histology. *Ultrasound Obstet Gynecol*, 2014;43(4):383-95.
 15. Riaz RM, Williams TR, Craig BM, et al. Cesarean scar ectopic pregnancy: imaging features, current treatment options, and clinical outcomes. *Abdom Imaging*. 2015;40(7):2589-99.
 16. Ades A and Parghi S. Laparoscopic resection of cesarean scar ectopic pregnancy. *J Minim Invasive Gynecol*. 2017;24(4):533-5.

Epstein-Barr Virus-induced Jaundice

Jessica Herold, DO
Felipe Grimaldo, MD

Naval Medical Center San Diego, Department of Emergency Medicine, San Diego, California

Section Editors: Scott Goldstein, MD

Submission history: Submitted September 2, 2019; Revision received October 30, 2019; Accepted October 31, 2019

Electronically published January 21, 2020

Full text available through open access at http://escholarship.org/uc/uciem_cpccem

DOI: 10.5811/cpcem.2019.10.45049

Infectious mononucleosis is primarily caused by Epstein-Barr virus (EBV) and is a common diagnosis made in emergency departments worldwide. Subclinical and transient transaminase elevations are a well-established sequela of EBV. However, acute cholestatic hepatitis is a rare complication. EBV infection should be considered as part of the differential diagnosis in patients with an obstructive pattern on liver function tests without evidence of biliary obstruction demonstrated on advanced imaging. [Clin Pract Cases Emerg Med. 2020;4(1):69–71.]

INTRODUCTION

Epstein-Barr virus (EBV) is a DNA virus that causes infectious mononucleosis. Infections are common in childhood and young adulthood but are usually asymptomatic. The classic triad of fever, tonsillitis, and lymphadenopathy that frequently presents to the emergency department (ED) is more common in adolescents and adults. Elevations in liver transaminases are not uncommon with EBV infection, but are usually transient and rarely progress to fulminant hepatitis.^{1,2} However, significant cholestasis and jaundice are rare complications with an incidence of less than 5%.^{3,4,5}

CASE REPORT

A 23-year-old previously healthy male presented to the ED with complaints of a headache that was gradual in onset and had been present for the prior 24 hours. He noted some lightheadedness and dizziness while standing, which prompted him to present to the ED for evaluation. He was febrile to 100.5 degrees Fahrenheit (F) and tachycardic to 110 beats per minute (bpm). The remainder of his physical exam was grossly unremarkable with no meningeal signs or focal neurologic deficits. He was provided antipyretics and intravenous (IV) fluids with complete resolution of his symptoms and discharged home with a diagnosis of viral syndrome.

Two days later, he returned to the ED with complaints of continued headache and fever. He recalled a “dry, tickling throat,” which was brief and self-limited in the prior two days. He was tachycardic, but afebrile on exam. With the exception of his tachycardia, his physical exam was again unremarkable without an identifiable infectious source. Laboratory

evaluation demonstrated a bandemia of 8% (reference range 0-5) as well as mild transaminitis with alanine aminotransferase (ALT) 177 units per liter (U/L) (reference range 17-63) and aspartate aminotransferase (AST) 171 U/L (reference range 12-39). His rapid heterophile antibody test was positive. He was discharged home with precautions to avoid contact sports and to have repeated liver function tests performed by his primary care provider.

Three days after his second ED visit, he returned with jaundice, dark urine, and with continued fever and fatigue. He denied sore throat, cough, chest pain, abdominal pain, vomiting, diarrhea, hematuria, dysuria, or rash. He was again febrile with a temperature of 100.9° F and a pulse rate of 109 bpm. There was noticeable scleral icterus and diffuse jaundice. He was also noted to have multiple, palpable, posterior cervical lymph nodes.

Laboratory evaluation was notable for a leukocytosis of 14.8×10^3 cells per microliter (mcL) (reference 4.0-10.5) with lymphocytic predominance of 24% and thrombocytopenia of 99×10^3 cells/mcL (reference range 150-450). Comprehensive metabolic panel was notable for mild hyponatremia of 133 millimoles (mmol) per L (reference range 136-145 mmol/L), total bilirubin of 7.93 milligrams per deciliter (mg/dL) (reference 0.15-1.00), direct bilirubin of 6.9 mg/dL (reference range <0.2-0.3), alkaline phosphatase of 198 U/L (reference range 40-129), ALT of 753 U/L (reference range 17-63), and AST 692 U/L (reference range 12-39). Coagulation studies were within normal limits. Acetaminophen level was negative at <1.5 micrograms per milliliter (reference range 10-30). Hepatitis serologies were

notable for a reactive hepatitis B virus core antibody, non-reactive hepatitis B core antibody IgM, positive hepatitis B surface antibody, and negative hepatitis B surface antigen consistent with immunity due to natural infection. Hepatitis C antibody was non-reactive. Human immunodeficiency virus testing was negative. Blood cultures were also negative. EBV heterophile antibodies were positive.

A formal right upper quadrant ultrasound demonstrated a mildly enlarged liver with normal contour. The gallbladder was visualized and noted to be contracted. The gallbladder wall was noted to be mildly thickened with a measurement of 0.34 centimeters. There was no evidence of cholelithiasis.

The patient was admitted to the hospital for supportive care and further laboratory evaluation. He was provided IV fluids, and liver function tests were trended every six hours. Liver enzymes gradually decreased and his jaundice resolved. His thrombocytopenia was thought to be related to acute hepatitis. Coagulation studies remained within normal limits. He was discharged from the hospital with a diagnosis of cholestatic hepatitis secondary to EBV. He followed up with internal medicine and had serial liver function tests over the subsequent weeks.

DISCUSSION

EBV is a member of the herpes virus family and has a seroprevalence of 90-95% worldwide.⁶ EBV is the primary cause of infectious mononucleosis, which can occur at all ages but is most common during adolescence and early adulthood.^{7,8} The likelihood of symptomatic disease is higher in older populations, and the risk of severe symptoms is positively correlated with age.⁷ Classic clinical symptoms of infectious mononucleosis include a triad of fever, pharyngitis, and adenopathy, which usually manifest after an incubation period of four to seven weeks.^{3,7} EBV is transmitted through saliva and infiltrates epithelial cells and resting B-cells, replicating and spreading throughout the body.⁹ After its incubation period, activation of cytotoxic T lymphocytes and natural killer cells occurs, leading to a cell-mediated immune response.^{7,10} Most infections are self-limited with an overall excellent prognosis; however, in some cases EBV infection complications can range from mild hepatitis to lymphoproliferative disorders, hepatosplenomegaly and, rarely, acute liver failure.⁸

The diagnosis of EBV is made based on clinical presentation and laboratory findings. Clinical presentation may include the classic triad of symptoms as well as tonsillar exudates, palatal petechiae, hepatosplenomegaly, and hepatitis.^{9,11} About 5-10% may present with jaundice.⁷ Laboratory analysis may demonstrate an absolute lymphocytosis in which more than 10% of the cells are atypical and positive heterophile antibody titers. Heterophile antibody titers may be falsely negative in the first week and may be consistently negative in approximately 10% of patients. If this is the case, EBV viral capsid antigen IgG and IgM antibody tests as well as EBV nuclear antigen antibodies may be helpful in

CPC-EM Capsule

What do we already know about this clinical entity?

Infectious mononucleosis is primarily caused by Epstein-Barr virus and is a common diagnosis in the emergency department.

What makes this presentation of disease reportable?

Cholestatic hepatitis is a rare presentation of Epstein-Barr virus with only approximately 5% of patients presenting with jaundice.

What is the major learning point?

As emergency providers, it is important that our differential diagnoses include Epstein-Barr virus when evaluating patients with cholestasis.

How might this improve emergency medicine practice?

Keeping Epstein-Barr virus on the differential as a cause of cholestatic hepatitis may save money on further diagnostic imaging and work up.

distinguishing the infection.^{7,8} Serum aminotransferase levels are usually elevated by less than five times the upper limit of normal and rarely reach over 1000 U/L.

Liver tissue injury is common in EBV infection with about 75% of patients exhibiting an increase in aminotransferases.⁷ Cholestatic hepatitis is a rare sequelae of EBV, and jaundice is seldom reported; however, it is more frequent in people aged 35 and older.^{12,13,14} If seen, jaundice may be due to autoimmune hemolytic anemia, cholestasis due to acalculous cholecystitis, biliary duct obstruction due to abdominal lymphadenopathy, or cholestatic hepatitis.^{9,15} The pathogenesis of cholestatic hepatitis due to EBV is unclear. EBV unlikely infects hepatocytes, biliary epithelium or vascular endothelium.³ It has been considered that cholestasis may be related to lipid peroxidation and consequent free radical production.^{9,12}

Once the diagnosis of EBV is made, further workup is generally not warranted.^{1,2} Treatment of uncomplicated infectious mononucleosis usually requires only symptomatic treatment with antipyretics, hydration, and rest.^{1,2,6} Often patients may experience abdominal pain, which may in part be due to splenomegaly.⁶ If splenomegaly is present, it is prudent to warn the patient against

physical activity to prevent splenic rupture; although rare, it has an incidence of 0.1-0.2%.¹⁰ Rare complications of EBV may include upper airway obstruction, peritonsillar abscess, encephalitis, myocarditis, or pleural effusion.^{8,9,10} The patient in this case recovered without serious intervention.

CONCLUSION

EBV infection has a high prevalence throughout the world. Although EBV often leads to self-limited infectious mononucleosis, it should be considered in the diagnosis of cholestatic hepatitis even in the absence of typical infectious mononucleosis clinical signs. It is important for emergency care providers to expand their differential to include EBV when working up a patient with cholestasis. Heterophile antibody testing is widely available and quick to perform and may be useful for rapid indication of EBV hepatitis. Providers should consider the diagnosis of EBV in all patients with unexplained hepatitis regardless of their age or symptomatology.

Documented patient informed consent and/or Institutional Review Board approval has been obtained and filed for publication of this case report.

Address for Correspondence: Jessica Herold, DO, Naval Medical Center San Diego, Department of Emergency Medicine, 34800 Bob Wilson Drive, San Diego, CA 92134. Email: jessica.m.herold.mil@mail.mil.

Conflicts of Interest: By the CPC-EM article submission agreement, all authors are required to disclose all affiliations, funding sources and financial or management relationships that could be perceived as potential sources of bias. I am a military service member or employee of the U.S. Government. This work was prepared as part of my official duties. Title 17, U.S.C. §105 provides that copyright protection under this title is not available for any work of the U.S. Government. Title 17, U.S.C. §101 defines a U.S. Government work as work prepared by a military service member or employee of the U.S. Government as part of that person's official duties. The views expressed in this article are those of the authors and do not necessarily reflect the official policy or position of the Department of the Navy, Department of Defense, nor the U.S. Government.

Copyright: © 2020 Herold et al. This is an open access article distributed in accordance with the terms of the Creative Commons Attribution (CC BY 4.0) License. See: <http://creativecommons.org/licenses/by/4.0/>

REFERENCES

1. Kang SJ, Yoon KH, Hwang JB. Epstein-Barr virus infection with acute pancreatitis associated with cholestatic hepatitis. *Pediatr Gastroenterol Hepatol Nutr*. 2013;16(1):61-4.
2. Yesilbag Z, Kardeniz A, Kaya FO. Acute acalculous cholecystitis: a rare presentation of primary Epstein-Barr virus infection in adults—Case report and review of the literature. *Case Rep Infect Dis*. 2017;2017:5790102.
3. Kimura H, Nagasaka T, Hoshino Y, et al. Severe hepatitis caused by Epstein-Barr virus without infection of hepatocytes. *Hum Pathol*. 2001;32(7):757-62.
4. Salva I, Silva IV, Cunha F. Epstein-Barr virus-associated cholestatic hepatitis. *BMJ Case Rep*. 2013;2013. pii: bcr2013202213.
5. Shaw N and Evans J. Liver failure and Epstein-Barr virus infection. *Arch Dis Child*. 1988;63:432-45.
6. Vine LJ, Shepherd K, Hunter JG, et al. Characteristics of Epstein-Barr virus hepatitis among patients with jaundice or acute hepatitis. *Aliment Pharmacol Ther*. 2012;36(1):16-21.
7. Fugl A and Andersen C. Epstein-Barr virus and its association with disease—a review of relevance to general practice. *BMC Fam Pract*. 2019;20(1):62.
8. Losavio A and Te H. Epstein-Barr virus: an unusual cause of cholestatic hepatitis in older adults. *Gastroenterol Hepatol (N Y)*. 2007;3(2):101-5.
9. Agergaard J and Larsen C. Acute acalculous cholecystitis in a patient with primary Epstein-Barr virus infection: a case report and literature review. *Int J Infect Dis*. 2015;35:67-72.
10. Straus SE, Cohen JI, Tosato G, et al. Epstein-Barr virus infections: biology, pathogenesis and management. *Ann Intern Med*. 1993;118(1):45-58.
11. Yang SI, Geong JH, Kim JY. Clinical characteristics of primary Epstein-Barr virus hepatitis with elevation of alkaline phosphatase and γ -Glutamyltransferase in children. *Yonsei Med J*. 2014;55(1):107-12.
12. Hinedi TB and Koff RS. Cholestatic hepatitis induced by Epstein-Barr virus infection in an adult. *Dig Dis Sci*. 2003;48(3):539-41.
13. Shaukat A, Tsai H, Rutherford R, et al. Epstein-Barr virus induced hepatitis: an important cause of cholestasis. *Hepatol Res*. 2005;33(1):24-6.
14. Shkalim-Zemer V, Shahar-Nissan K, Ashkenazi-Hoffnung L, et al. Cholestatic hepatitis induced by Epstein-Barr virus in a pediatric population. *Clin Pediatr (Phila)*. 2015;54(12):1153-7.
15. Edoute Y, Baruch Y, Lachter J, et al. Severe cholestatic jaundice induced by Epstein-Barr virus infection in the elderly. *J Gastroenterol Hepatol*. 1998;13(8):821-4.

Break up the band: Laparoscopic Adjustable Gastric Banding-associated Discitis and Osteomyelitis

Scott Meester, MD
Christopher Hogrefe, MD

University of Iowa Hospitals and Clinics, Department of Emergency Medicine, Iowa City, Iowa

Section Editor: Rick A. McPheeters, DO

Submission history: Submitted August 11, 2019; Revision received October 31, 2019; Accepted November 11, 2019

Electronically published January 21, 2020

Full text available through open access at http://escholarship.org/uc/uciem_cpem

DOI: 10.5811/cpcem.2019.11.44879

Obesity is an epidemic that adversely affects millions of Americans. In 2017, the Center for Disease Control and Prevention reported that 93.3 million Americans suffer from obesity.¹ Many individuals have undergone laparoscopic adjustable gastric banding (LAGB) procedures in order to lose weight. The procedure is thought to be safe with complication rates reported as low as 1.6% following surgery.² We present a case of LAGB-associated discitis and osteomyelitis 20 years after placement and examine the current literature on the complication rates of bariatric surgery along with the rare injuries following LAGB placement. [*Clin Pract Cases Emerg Med.* 2020;4(1):72–74.]

INTRODUCTION

Morbid obesity is an epidemic affecting 93.3 million individuals in the United States, or almost 40% of the population.¹ Multiple medical and surgical treatment options exist to combat obesity. One such surgical option is the laparoscopic adjustable gastric banding (LAGB) procedure. In 2017 alone, 228,000 individuals underwent bariatric surgery with 2.77% involving an LAGB procedure.² Complications have been reported with this surgery, including infection, bleeding, and erosion of the gastric band through gastric wall. We report a complication that has not been previously detailed in the literature, specifically an LAGB catheter eroding into the spine resulting in discitis and osteomyelitis.

CASE REPORT

The patient is a 55-year-old gentleman with a past medical history remarkable for hypertension, methamphetamine abuse, epidural and paraspinal abscesses in 2018, and an LAGB procedure in 1998 that presented to the Emergency Department with back pain. The patient reported a two month history of back pain that was progressively worsening. He described sharp lower midline back pain with right lower extremity weakness. The patient's initial vital signs revealed a temperature of 36.6°C, heart rate of 62 beats per minute, a blood pressure of 135/82 millimeters of Mercury (mmHg), and an oxygen saturation of 99% on room air. Skin exam was notable for a well-healed 6 centimeters surgical wound to the right side of the lumbar spine.

The patient had full range of motion of his upper and lower extremities. Sensation was intact in the bilateral upper and lower extremities. Strength in his right hip and right knee were 3/5, while strength in the left lower extremity was 5/5. Straight leg raise testing was positive bilaterally, with the right side being more painful than left. At that juncture the working differential diagnosis included epidural abscess, epidural hematoma, lumbar radiculopathy, and/or worsening osteomyelitis. Laboratory studies were significant for hemoglobin of 8.6 gram/deciliter (g/dL) [11.9 - 15.5 g/dL], a white blood cell count of 9.0 thousand/millimeter³ (K/mm³) [3.7-10.5 K/mm³], an erythrocyte sedimentation rate of 122 millimeter/hour (mm/hr) [0-20 mm/hr], and a C-reactive protein of 4.4 milligram/deciliter (mg/dL) [≥ 0.5 mg/dL].

A computed tomography (CT) scan of the abdomen and pelvis was performed given the patient's persistent pain and recent spinal epidural abscess drainage at an outside hospital. CT scan showed concerns for continued abscesses. Given abnormal neurological exam and abscesses, a magnetic resonance imaging (MRI) of the thoracic and lumbar spine was secured (Image). This revealed an LAGB ring component eroding through the gastric wall with localized pneumatosis. The catheter from the LAGB appeared to have passed through the retroperitoneum and the left psoas into the central spinal canal through the second lumbar (L2)-L3 vertebral body resulting in discitis and osteomyelitis with surrounding abscesses. The transferring hospital treated the patient with a 30 milligram/kilogram (mg/kg) fluid bolus and started intravenous metronidazole, vancomycin,

and fluconazole. The patient's pain was treated with intravenous dilaudid. He was subsequently transferred for an orthopaedic spine evaluation, as this was not available locally.

Given the aforementioned imaging, the diagnosis of L2-L3 discitis and osteomyelitis was made along with both spinal canal and iliopsoas foreign bodies consisting of hardware from the LAGB. The patient was admitted to the surgical intensive care unit, after which he underwent laparoscopic and endoscopic removal of the gastric LAGB and spinal fusion of the twelfth thoracic vertebra (T12) to L5 with decompression of the spine. His hospital course was complicated by septicemia treated with intravenous ertapenem and fluconazole. The patient remained in the hospital nineteen days and was discharged home with resolved lower extremity weakness and overall normal neurological status. The patient did, however, continue to experience gradually improving lower back pain following his surgery, which was treated with oral medications.

DISCUSSION

Gastric bypass surgery is a popular procedure for the morbidly obese population to help promote weight loss. The American Society for Metabolic and Bariatric Surgery estimates that approximately 228,000 individuals underwent bariatric surgery in 2017. Of these individuals, 2.77% underwent LAGB placement.³ Multiple studies have examined the revision rates of LAGB and complications from LAGB placement. A study looking at approximately 32,000 perioperative bariatric surgery patients examined the morbidity and complications following this operation. In LAGB procedures specifically, they found the total complication rate to be 1.6%, which included infection, hemorrhage, and/or cardiovascular complications. Bleeding

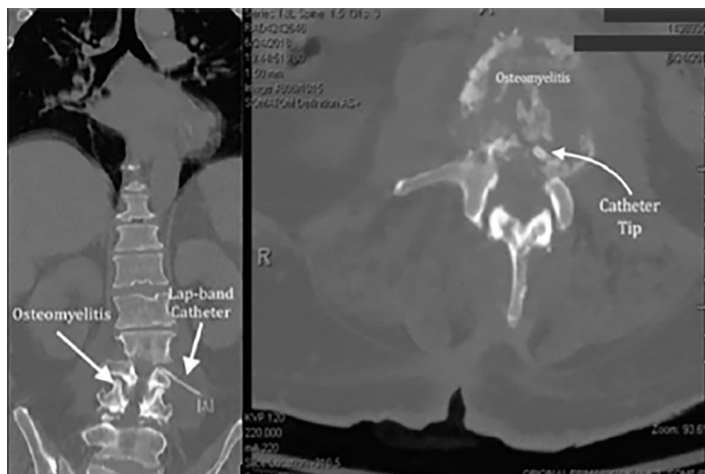


Image. Computed tomography of the lumbar spine, (left) coronal view and (right) axial view demonstrating erosion of the laparoscopic gastric banding catheter into the spinal area and associated osteomyelitis.

CPC-EM Capsule

What do we already know about this clinical entity?
Laparoscopic adjustable gastric banding (LAGB) comes with complications such as infection, bleeding, and erosion of the gastric band through the gastric wall.

What makes this presentation of disease reportable?
LAGB-associated discitis and osteomyelitis is a complication of LAGB placement that has yet to be reported in literature.

What is the major learning point?
LAGB patients with back or abdominal pain may be suffering from further pathology such as discitis or osteomyelitis secondary to hardware migration.

How might this improve emergency medicine practice?
Providers seeing patients with persistent and significant back or abdominal pain should consider further imaging to rule out rare pathology.

during the procedure was the most common complication.² However, multiple studies following patients over time revealed a complication rate of 15.0% - 34.17%.^{4,5} One study in particular found an explant rate secondary to complication of 8.74%.⁶ Most complications were not statistically significant; they included abscess, atelectasis, depression, internal complications, port leak or band removal, displacement, slippage, and numerous other complications.⁴ However, no examined reviews of LAGB complications reported discitis and/or osteomyelitis of the spine.

One of the most commonly mentioned and reviewed complications of the LAGB procedure is erosion. Niville et al. followed 301 patients for two years after an LAGB procedure. A total of 5 patients (1.66%) developed erosions into the stomach wall and required LAGB removal.⁷ This suggests that migration of the LAGB should be considered in anyone presenting with abdominal pain following an LAGB procedure. Although no cases of osteomyelitis of the spine have been reported previously, pericardial effusion after a postoperative infection of an LAGB has been reported in one case.⁸

Based on these studies, it appears that although complication rates of LAGB procedures can be as high as 34%, erosion and migration of LAGB are less commonly seen. However, if a patient presents with back pain in the context of a previous LAGB placement, a rare complication that must be

considered is osteomyelitis secondary to migration of LAGB catheter into the spinal space.

CONCLUSION

Laparoscopic adjustable gastric banding-associated spinal discitis and osteomyelitis are rare complications of LAGB erosion. Symptoms such as back pain, radicular pain, numbness, or tingling, lower extremity motor weakness or loss of reflexes, and disturbed bowel or bladder function should be evaluated further with imaging. An MRI with contrast of the spine should be considered in the setting of neurological exam findings and continued symptoms despite adequate treatment in order to better characterize the spine. Although this is the first reported such case, it is worth remembering that patients with significant back pain and neurological findings warrant further investigation into the etiology of their symptoms.

Documented patient informed consent and/or Institutional Review Board approval has been obtained and filed for publication of this case report.

REFERENCES

1. Centers for Disease Control and Prevention. Adult obesity facts. Available at: <https://www.cdc.gov/obesity/data/adult.html>. Accessed on August 13, 2018.
2. Gould JC, Kent KC, Wan Y, et al. Perioperative safety and volume: outcomes relationships in bariatric surgery: a study of 32,000 patients. *J Am Coll Surg*. 2011;213(6):771-7.

Address for Correspondence: Scott Meester, MD, University of Iowa Hospitals and Clinics, Department of Emergency Medicine, 200 Hawkins Drive, Iowa City, IA 52242. Email: scott-meester@uiowa.edu.

Conflicts of Interest: By the CPC-EM article submission agreement, all authors are required to disclose all affiliations, funding sources and financial or management relationships that could be perceived as potential sources of bias. The authors disclosed none.

Copyright: © 2020 Meester et al. This is an open access article distributed in accordance with the terms of the Creative Commons Attribution (CC BY 4.0) License. See: <http://creativecommons.org/licenses/by/4.0/>

3. American Society for Metabolic and Bariatric Surgery. Estimate of Bariatric Surgery Numbers, 2011-2017. 2018. Available at: <https://asmbs.org/resources/estimate-of-bariatric-surgery-numbers>. Accessed on October 16, 2018.
4. Altieri MS, Yang J, Telem DA, et al. Lap band outcomes from 19,221 patients across centers and over a decade within the state of New York. *Surg Endosc*. 2016;30(5):1725-32.
5. Karasko D. Weight loss in adolescents after bariatric surgery: A systematic review. *J Pediatr Health Care*. 2019;33(1):26-34.
6. Dixon JB, Eaton LL, Curry T, et al. Health outcomes and explant rates after laparoscopic adjustable gastric banding: a phase 4, multicenter study over 5 years. *Obesity (Silver Spring)*. 2018;26(1):45-52.
7. Niville E, Dams A, Vlasselaers J. Lap-Band erosion: incidence and treatment. *Obes Surg*. 2001;11(6):744-7.
8. Bui HT, Kiroff G, Foy S. Massive pericardial effusion following a laparoscopic adjustable gastric banding. *Obes Surg*. 2003;13(6):944-7.

Stroke Mimic: A Case of Unilateral Thyrotoxic Hypokalemic Periodic Paralysis

Michael Lajeunesse, MD
Scott Young, DO

Madigan Army Medical Center, Department of Emergency Medicine, Tacoma, Washington

Section Editor: Rick A. McPheeters, DO

Submission history: Submitted August 30, 2019; Revision received November 19, 2019; Accepted November 25, 2019

Electronically published January 24, 2020

Full text available through open access at http://escholarship.org/uc/uciem_cpem

DOI: 10.5811/cpcem.2019.11.44966

Thyrotoxic hypokalemic periodic paralysis (THPP) is a condition that results in transient skeletal muscle paralysis secondary to intracellular potassium sequestration. Susceptible individuals often have an underlying channelopathy, which may be exacerbated by lifestyle factors or underlying medical comorbidities such as hyperthyroidism or diarrheal illness. Classically, THPP presents with paralysis of proximal extremity musculature. In this case, we present a rare case of unilateral THPP. Such a presentation is relevant to emergency physicians as it mimics a stroke or transient ischemic attack and should be considered on the differential for unilateral neurologic deficits. [Clin Pract Cases Emerg Med. 2020;4(1):75–78.]

INTRODUCTION

Thyrotoxic hypokalemic periodic paralysis (THPP) is an endocrinologic disease that presents with acute episodic paralysis. In THPP, a thyroid-hormone-mediated cascade results in increased sodium/potassium (Na^+/K^+) pump activity leading to K^+ sequestration inside the cell and subsequent muscular paralysis.^{1,2} Underlying electrolyte channel mutations predispose individuals to acquired periodic paralysis syndromes, and the thyrotoxic insult instigates the episodic paralysis.¹ THPP classically presents with proximal muscle weakness, with the lower extremities typically affected to a greater extent than the upper extremities.¹ Atypical findings such as asymmetric paralysis are rare, and there is a paucity of such presentations reported in the literature. We report an atypical case of unilateral weakness secondary to THPP, adding this diagnosis to the long differential that emergency physicians must consider among other stroke mimics.

CASE REPORT

A 48-year-old Caucasian male presented via emergency medical services (EMS) with sudden onset unilateral right-sided weakness. The patient reported a heavy sensation in his muscles on the right side of his body and complained of difficulty manipulating his phone. The peak symptoms lasted about 3-5 minutes, and by the time EMS arrived, gross motor function had returned. The patient reported persisting, mild,

right-sided weakness on arrival to the emergency department (ED), but otherwise remained hemodynamically stable.

He reported a history of Grave's disease controlled by methimazole and propranolol. Further history revealed a similar episode in December 2017 marked by generalized weakness and fasciculations. He had been found to have hyperthyroidism at that time and was started on propranolol, in addition to methimazole. His current medication list included methimazole, propranolol, telmisartan/hydrochlorothiazide, testosterone, albuterol, aspirin, and emtricitabine/tenofovir disoproxil. He also admitted to non-compliance with his high potassium diet and supplementation.

Physical examination demonstrated 4/5 strength in both the right upper and lower extremities, as compared with 5/5 strength on the left. Proximal and distal muscles were affected equally. The patient denied any sensory deficits. The EMS report described near-complete loss of right-sided motor function with rapid improvement en route to the hospital. Relevant laboratory testing demonstrated a K^+ of 3.4 milliequivalents per liter (mEq/L) (reference range 3.5-5.1 mEq/L), normal blood glucose, a thyroid stimulating hormone (TSH) of 0.02 microinternational units per milliliter (uIU/ml) (reference range: 0.270-4.320 uIU/ml) and a free-thyroxine (T4) of 2.34 nanogram per deciliter (ng/dL) (reference range: 0.80-1.80 ng/dL). Computed tomography (CT) of the head with and without angiography demonstrated periventricular

and subcortical white matter densities, which were unchanged from prior imaging, but did not reveal any intracranial hemorrhage or flow-limiting lesions. His electrocardiogram (ECG) showed a right bundle-branch block, which was unchanged from prior ECGs. Subsequent outpatient testing for syphilis was negative.

The diagnosis of THPP was made in consultation with neurology based on past medical history, lab abnormalities, and negative CT/ CT angiography imaging. Given his near-complete recovery after several hours of observation and a near normal K^+ , we withheld K^+ supplementation and propranolol in the ED. Endocrinology advised that he increase his methimazole and restart his high-potassium diet. The patient was discharged with endocrinology and neurology follow-up. Subsequent outpatient electroencephalogram performed by neurology in evaluation of atypical seizures was also negative. With compliance of his medications and high potassium diet, the patient has not had any additional episodes of paralysis.

DISCUSSION

THPP has a 0.1-0.2% prevalence in the United States, typically presenting with transient symmetric skeletal muscle paralysis, which usually affects the lower extremities disproportionately to the upper extremities.^{3,4,5} It occurs more frequently in Asian populations and typically presents in Asian men ages 20 to 40.³ Males are more susceptible than females, with reported ratios ranging from 17:1 to 70:1.⁶ THPP is thought to be mediated through the Na^+/K^+ pump. Studies suggest that androgen-mediated promotion of the Na^+/K^+ pump and a larger muscle-to-body ratio lead to greater risk of THPP episodes.¹ In addition, estrogen decreases Na^+/K^+ pump activity, making females less susceptible to this syndrome. Hyperthyroidism upregulates the Na^+/K^+ pump expression on skeletal muscle in addition to increasing the pump activity.^{1,2,4} As a result, the cell sequesters K^+ intracellularly, leading to the common pathway for many acquired paralysis syndromes: hypokalemia.⁶

Thyrotoxicosis alone, however, does not result in episodic paralysis, nor do free T4 levels correlate to symptoms.⁷ Rather, certain genetic factors in combination with a trigger such as thyrotoxicosis lead to clinical manifestation of the disease.⁸

The potassium inwardly-rectifying channel subfamily J member 2 gene (KCNJ2) and potassium inwardly-rectifying channel subfamily J member 18 gene (KCNJ18) are the two most prominent genes with mutations that predispose individuals to THPP in Asians and Caucasians, respectively.⁶ These genes are inward-rectifying K^+ channels, which counteract the Na^+/K^+ pump by channeling K^+ extracellularly.⁸ In mutated genes, excess thyroid hormone, excess catecholamines or excess insulin may all inhibit efflux of potassium from the cell, further sequestering K^+ and contributing to intravascular hypokalemia.⁸ Other known triggers include large carbohydrate loads (excess insulin),

CPC-EM Capsule

What do we already know about this clinical entity?

Thyrotoxic hypokalemic periodic paralysis (THPP) is marked by transient hypokalemia due to hyperthyroidism resulting in transient symmetric muscular paralysis.

What makes this presentation of disease reportable?

THPP usually manifests as bilateral weakness. However, this case presented with unilateral weakness presenting as a stroke mimic.

What is the major learning point?

THPP is a stroke mimic and should be considered on the differential in patients with thyroid conditions.

How might this improve emergency medicine practice?

Physicians may now better identify this rare stroke mimic and initiate proper treatment while avoiding unnecessary testing.

exercise (excess catecholamines), stress, toxic adenomas, diuretics, fluoroquinolones, aminoglycosides, amiodarone, alcohol, and even licorice.^{2,8,9,10}

Presentations vary widely from mild, transient, self-limited motor dysfunction to total flaccid paralysis including respiratory muscles.^{11,12,13} Bulbar and ocular symptoms have been reported in rare cases; however, it is unclear whether ocular involvement stems from THPP or the thyrotoxicosis.^{1,8} This syndrome may even precipitate various dysrhythmias including ventricular fibrillation, ventricular tachycardia, atrioventricular block, or sinus arrest.¹⁴

Although existence of asymmetric THPP is suggested in the literature, a paucity of unilateral or asymmetric cases has been reported.^{1,15} A small 2012 case series of 11 patients with acquired hypokalemic periodic paralysis reported asymmetric weakness in three patients; however, all of these patients had acquired non-thyrotoxic hypokalemic periodic paralysis, whereas no patients with THPP had asymmetric weakness.¹⁵ Treatment for THPP involves correction of K^+ and returning the patient to a euthyroid state.^{1,2,6,14}

Care must be taken when correcting K^+ as the patient has relative hypokalemia, in which the potassium is merely shifted into the cell instead of being depleted in the body.^{1,2} In

addition, similar to the presented patient who was borderline hypokalemic, one case of THPP with normokalaemia has been reported.² This, however, may represent a redistribution of K⁺ back into the extra-cellular space at the time of the lab draw rather than true normokalemia at the time of symptom onset. Thus, potassium supplementation in the ED must be performed with care as 70-80% of patients treated with potassium have rebound hyperkalemia.^{6,14} Providers must also consider management of associated electrolytes such as magnesium when repleting potassium. Close cardiac monitoring is also essential since patients are at risk of both hypo and hyperkalemic-induced dysrhythmias.

In the ED, a non-selective β -blocker such as propranolol is favored to reduce hyperthyroid symptoms and inhibit intracellular potassium sequestration.^{1,2} Selective β -blockers do not act on skeletal muscle, which makes them less useful in the management of THPP.¹ One study demonstrated resolution of paralysis and normalization of the potassium within two hours of a three milligram per kilogram dose of propranolol administration by mouth.¹⁶ After correction of the emergent episode, maintenance of a euthyroid state and outpatient follow-up is important in preventing recurrent paralytic episodes.⁶ This is critical for long-term management since repeated attacks may cause permanent muscle weakness.¹

CONCLUSION

In this case, we report a rare presentation of THPP associated with transient, self-resolving, unilateral weakness. While non-thyrotoxic hypokalemic periodic paralysis has been associated with asymmetric weakness, only one source cites THPP with asymmetry.¹⁵ Additional pathologies such as familial periodic paralysis, stroke, transient ischemic attack, and neurosyphilis were investigated both in the ED and in follow-up without evidence of another convincing etiology. Unilateral weakness in THPP is a rare stroke mimic. Nevertheless, it is an important diagnosis in the ED given that it requires prompt treatment, astute electrolyte management, and close cardiac monitoring, which sometimes may present a difference in priorities for stroke workups. TSH, rapid electrolyte testing, a history of hyperthyroidism, or a history of past similar episodes can help tip off a physician to this pathology.

For emergency physicians, ensuring proper follow-up is essential since compliance with medications and management of the patient's hyperthyroidism can prevent long-term morbidity such as persistent muscular weakness. No studies have researched the propensity for repeated paralytic episodes or long-term morbidity in populations with disparate degrees of healthcare access; however, special attention should be paid to the disposition and follow-up of THPP patients with poor healthcare access who may not have easy access to medications or a physician to make medication changes. As emergency physicians, we can make a lasting difference for these patients by prompt recognition and proper care

in the ED, and via coordination of appropriate outpatient management for medical comorbidities.

Documented patient informed consent and/or Institutional Review Board approval has been obtained and filed for publication of this case report.

Address for Correspondence: Michael Lajeunesse, MD, Madigan Army Medical Center, Department of Emergency Medicine, CMR 422, Box 450, APO, AE 09067-0005. Email: michael.d.lajeunesse2.mil@mail.mil.

Conflicts of Interest: By the CPC-EM article submission agreement, all authors are required to disclose all affiliations, funding sources and financial or management relationships that could be perceived as potential sources of bias. The authors disclosed none. The views expressed here are those of the authors and do not reflect the official policy of the Department of the Army, the Department of Defense, or the US Government.

Copyright: © 2020 Lajeunesse et al. This is an open access article distributed in accordance with the terms of the Creative Commons Attribution (CC BY 4.0) License. See: <http://creativecommons.org/licenses/by/4.0/>

REFERENCES

1. Meseeha M, Parsamehr B, Kissell K, et al. Thyrotoxic periodic paralysis: a case study and review of the literature. *Community Hosp Intern Med Perspect.* 2017;7(2):103-6.
2. Gragg JI, Federico M, Mellick LB. Normokalemic thyrotoxic periodic paralysis with acute resolution in the emergency department. *Clin Pract Cases Emerg Med.* 2017;1(2):129-31.
3. Kelley DE, Gharib H, Kennedy FP, et al. Thyrotoxic periodic paralysis. Report of 10 cases and review of electromyographic findings. *Arch Intern Med.* 1989;149(11):2597-600.
4. Paul B, Hirudayaraj P, Baig MW, et al. Thyrotoxic periodic paralysis: an unusual presentation of weakness. *Emerg Med J.* 2003;20(5):E7.
5. Lin SH and Huang CL. Mechanism of thyrotoxic periodic paralysis. *J Am Soc Nephrol.* 2012;23(6):985-8.
6. Roh JG, Park KJ, Lee HS, et al. Thyrotoxic hypokalemic periodic paralysis due to Graves' disease in 2 adolescents. *Ann Pediatr Endocrinol Metab.* 2019;24(2):133-6.
7. Salih M, van Kinschot CMJ, Peeters RP, et al. Thyrotoxic periodic paralysis: an unusual presentation of hyperthyroidism. *Neth J Med.* 2017;(75):315-20.
8. Garla VV, Gunturu M, Kovvuru KR, et al. Thyrotoxic periodic paralysis: case report and review of the literature. *Electron Physician.*

- 2018;10(8):7174-9.
9. Lulsegg A, Wlodek C, Rossi M. Thyrotoxic periodic paralysis: case reports and an up-to-date review of the literature. *Case Rep Endocrinol.* 2011;2011:867475.
 10. Sayiner ZA, Abiyev A, Eraydin A, et al. A rare cause of thyrotoxic periodic paralysis: liquorice consumption. *Postgrad Med J.* 2017;93(1099):295-6.
 11. Neki N. Hyperthyroid hypokalemic periodic paralysis. *Pak J Med Sci.* 1969;32(4):1051-2.
 12. Valizadeh N and Zarrin S. A 32-year-old man with normokalemic thyrotoxic periodic paralysis. *Malys J Med Sci.* 2013;20(1):81-3.
 13. Lam L, Nair RJ, Tingle L. Thyrotoxic periodic paralysis. *Proc (Bayl Univ Med Cent).* 2006;9(2):126-9.
 14. Wang PH, Liu KT, Wu YH, et al. Periodic paralysis with normokalemia in a patient with hyperthyroidism. *Medicine.* 2018;97(46):e13256.
 15. Hiraga A, Kamitsukasa I, Kojima K. Clinical features and recovery patterns of acquired non-thyrotoxic hypokalemic paralysis. *J Neurol Sci.* 2012;313(1-2):42-5.
 16. Lin SH and Lin YF. Propranolol rapidly reverses paralysis, hypokalemia, and hypophosphatemia in thyrotoxic periodic paralysis. *Am J Kidney Dis.* 2001;37(3):620-3.

Point-of-care Ultrasound Diagnosis of Acute Abdominal Aortic Occlusion

Benjamin Bloom, MD*
Ryan Gibbons, MD†
Dov Brandis, MD†
Thomas G. Costantino, MD†

*Temple University Hospital, Department of Emergency Medicine, Philadelphia, Pennsylvania
†Lewis Katz School of Medicine at Temple University, Department of Emergency Medicine, Philadelphia, Pennsylvania

Section Editors: Shadi Lahham, MD and Rick A. McPheeters, DO

Submission history: Submitted July 2, 2019; Revision received November 18, 2019; Accepted November 25, 2019

Electronically published January 23, 2020

Full text available through open access at http://escholarship.org/uc/uciem_cpem

DOI: 10.5811/cpcem.2019.11.44311

Acute aortic occlusion is an emergent vascular condition not encountered routinely. Given its varied presentations, including neurovascular deficits and mimicking an acute abdomen, the diagnosis is often delayed causing increased morbidity and mortality. We present a case of acute abdominal aortic occlusion masquerading as sudden onset lower extremity pain and weakness in an 86-year-old female requiring emergent thrombectomy. This is only the second case report to discuss the use of point-of-care ultrasound to expedite diagnosis and management.¹ [Clin Pract Cases Emerg Med. 2020;4(1):79–82.]

INTRODUCTION

Acute aortic occlusion (AAO) is a rare but potentially devastating vascular emergency. It can be secondary to an embolism, thrombus, or aneurysmal disease.²⁻⁵ Given its varied presentations, including neurovascular deficits, the diagnosis is often challenging and delayed, impeding time to revascularization and causing significant morbidity and mortality between 21-74%.²⁻⁵ Traditionally, computed tomography (CT) angiography has been the diagnostic modality of choice. However, issues including patient stability, contrast allergies, kidney function, and time delays, limit its utilization. We report a case of AAO in which point-of-care ultrasound (POCUS) expedited definitive diagnosis and treatment. We will review the current literature regarding the role of POCUS in the diagnosis of aortic pathology as well.

CASE REPORT

An 86-year-old female with a past medical history significant for hypertension, congestive heart failure, aortic and mitral valve regurgitation status post repair, transient ischemic attack without residual neurologic deficits, and atrial fibrillation not on anticoagulation presented to an urban, academic emergency department (ED) with acute onset bilateral lower extremity pain, weakness, and paresthesia. The symptoms began two hours prior to arrival. The patient denied abdominal pain, back pain, fever, and recent trauma.

The patient arrived in moderate distress with an irregularly, irregular pulse of 65 beats per minute and a blood pressure of 187/109 millimeters of mercury. Other vital signs and the patient's blood sugar were within normal limits. During initial triage, physical examination revealed new onset right (4/5) and left (2/5) lower extremity weakness. Neurological exam was otherwise unremarkable. A stroke alert was initiated immediately. CT head revealed no acute pathology. Upon return to the ED, the treating physician noted cool extremities with absent bilateral dorsalis pedis and posterior tibial pulses. Abdominal exam was benign. No rash or signs of trauma were evident. We then considered alternative etiologies of our patient's bilaterally lower extremity weakness, including aortic pathologies.

POCUS of the abdominal aorta demonstrated an occlusive intraluminal echogenicity originating just proximal to the iliac bifurcation (Image 1 and Video). Vascular surgery was consulted immediately for AAO. Emergent CT angiography of the inferior abdomen and bilateral lower extremities confirmed the aortoiliac occlusive thrombus (Image 2). The soft tissues demonstrated no evidence of myonecrosis. Laboratory values were unremarkable.

The patient was taken directly to the operating room where she underwent successful thrombectomy of the aorta, iliac, and femoral arteries. A transesophageal echocardiography did not demonstrate left atrial or ventricular

thrombus. The patient had an unremarkable hospital course. Upon discharge to a skilled nursing facility, distal lower extremity pulses were present on Doppler exam, and the patient was ambulatory with mild residual bilateral lower extremity weakness.

DISCUSSION

Chronic aortic occlusive disease is a consequence of atherosclerotic disease, and has a reported incidence of 1-8%.² The aortoiliac vessels are among the most common sites of chronic atherosclerosis, and risk factors for aortoiliac thrombotic disease are similar to those of other peripheral artery disease, including smoking, hyperlipidemia, hypertension, and diabetes.⁷ Chronic disease often presents with intermittent signs and symptoms of claudication.

Unlike chronic occlusive disease, our patient presented with acute onset lower extremity weakness and pain, consistent with AAO. This is a separate entity from chronic aortic occlusive disease, and has a reported mortality ranging between 21-74%.²⁻⁵ Etiologies include thrombosis (51.5%-91.6%), embolism, or aneurysmal disease.²⁻⁵ The patient did not have an aortic aneurysm or a history of claudication; however, she may have had pre-existing aortoiliac thrombosis. Given the patient's medical history and lack of anticoagulation, the acute occlusion was likely secondary to embolic disease. Furthermore, the lower extremity motor deficits were subsequent to acute anterior spinal artery syndrome due to occlusion of the radicular artery of Adamkiewicz, which originates between the ninth thoracic vertebrae (T9) to T12 to supply the spinal cord, which was the level of the patient's occlusion.⁷

The initial presentation of lower extremity deficits can mislead providers. Several case reports describe the

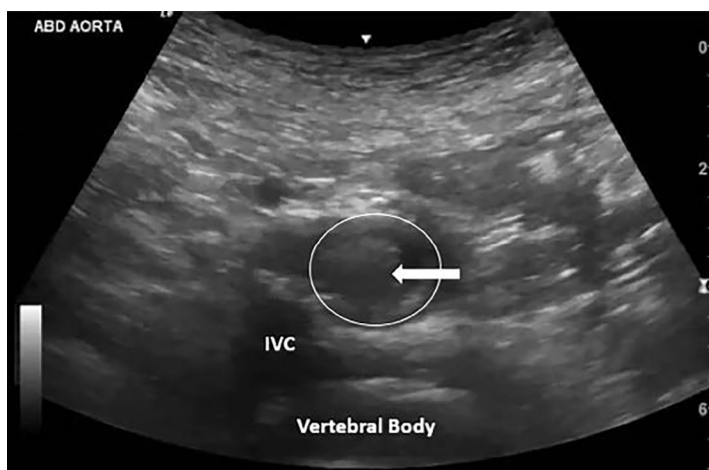


Image 1. Point-of-care ultrasound transverse image of distal aorta (white circle) with hyperechoic intraluminal content (white arrow), representing thrombus.

CPC-EM Capsule

What do we already know about this clinical entity?

Acute aortic occlusion is a rare condition with high morbidity and mortality, varied presentations, and is often challenging to diagnose.

What makes this presentation of disease reportable?

The use of point-of-care ultrasound (POCUS) made the rapid diagnosis of acute aortic pathology masquerading as a neurologic presentation.

What is the major learning point?

Consider aortic pathology in patients with sudden onset lower extremity weakness; POCUS can be used to evaluate for abdominal aortic thrombus.

How might this improve emergency medicine practice?

POCUS can expedite diagnosis of acute aortic pathology and decrease time to definitive management.

mischaracterization of chronic aortic occlusive disease as sciatica, and acute aortic occlusive disease as a cerebrovascular accident or spinal cord myelopathy.⁸⁻¹⁰ Diagnostic uncertainty delays revascularization and increases morbidity and mortality as ischemic complications propagate, including neurologic deficits, amputation, renal failure, and mesenteric ischemia.⁵ In a case series of AAOs, Meagher et al. reported a mean delay of 24 hours from presentation to diagnosis.⁹ Dossa et al. reported 11% of patients had either a neurologic or neurosurgical consultation prior to the final diagnosis of AAO.⁴ Thorough physical examination and early use of POCUS facilitates recognition of vascular occlusion, redirecting diagnostic momentum away from neurogenic etiologies. It is noteworthy that the majority of AAOs occur infrarenal (75.8%-94.8%).²⁻³ The clinician is advised to extend the scan distal to the bifurcation of the aorta to ensure complete visualization of the entire abdominal aorta. Typically, thrombus is best visualized along the anterolateral wall of the abdominal aorta. The use of color flow and pulsed-wave Doppler to aid visualization and to differentiate between the aorta and inferior vena cava is also recommended.

Emergency physicians have been using POCUS for the diagnosis of aortic pathology for over 20 years. In fact, the

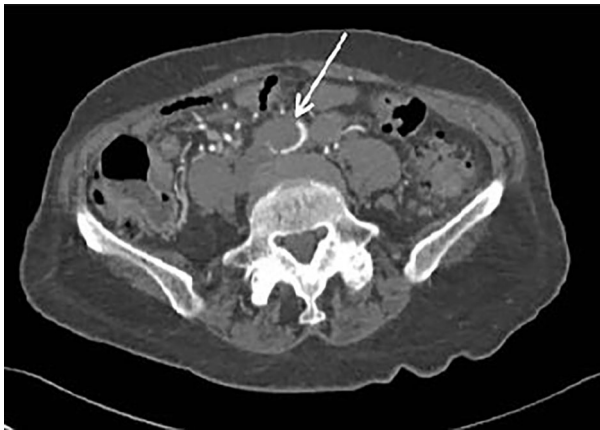

Image 2. Computed tomography angiography axial image demonstrating occlusive thrombus (white arrow) in the distal abdominal aorta just proximal to the aortic bifurcation.

2016 American College of Emergency Physicians policy statement, Ultrasound Guidelines: Emergency, Point-of-care, and Clinical Ultrasound Guidelines in Medicine, mandates the sonographic evaluation of the abdominal aorta as a core emergency medicine (EM) competency.¹¹ Numerous studies have validated sensitivities from 94-100% for the detection of abdominal aortic aneurysms with negative predictive values between 98.6%-100%.¹²⁻¹⁵ Costantino et al. demonstrated that the accuracy of EM resident-performed ultrasound is within 4.4 millimeters of CT evaluation of abdominal aortic aneurysms.¹² More recently, Gibbons et al. established a POCUS aortic dissection protocol with 100% and 93.7% sensitivities for the detection of Stanford type A and Stanford type B aortic dissections, respectively.¹⁶ Furthermore, Pare et al. reported a mean reduction of 146 minutes in time to diagnosis of Stanford type A aortic dissections when implementing a POCUS-first approach.¹⁷

Although no formal studies exist evaluating the diagnostic accuracy of POCUS at identifying aortic occlusions, this case report illustrates a further extension of bedside ultrasound in evaluating emergent aortic pathology.

CONCLUSION

Acute aortic occlusion is a rare but potentially devastating vascular emergency. Emergency physicians should consider this aortic pathology in patients presenting to the ED with acute onset lower extremity neurovascular deficits. Diagnostic delay impedes time to revascularization and portends worse patient outcomes with morbidity and mortality rates between 21-74%.²⁻⁵ POCUS is a rapid, accurate, and non-invasive diagnostic imaging modality for patients presenting with aortic pathology. Given its high sensitivity for identifying aneurysms, dissections, and intraluminal thrombus, POCUS is the ideal screening exam for emergent aortic pathology.¹²⁻¹⁷

Documented patient informed consent and/or Institutional Review Board approval has been obtained and filed for publication of this case report.

Address for Correspondence: Benjamin Bloom, MD, Temple University Hospital, Department of Emergency, 3401 N. Broad St., Philadelphia, PA 19140. Email: Benjamin.bloom@tuhs.temple.edu.

Conflicts of Interest: By the *CPC-EM* article submission agreement, all authors are required to disclose all affiliations, funding sources and financial or management relationships that could be perceived as potential sources of bias. The authors disclosed none.

Copyright: © 2020 Bloom et al. This is an open access article distributed in accordance with the terms of the Creative Commons Attribution ([CC BY 4.0](http://creativecommons.org/licenses/by/4.0/)) License. See: <http://creativecommons.org/licenses/by/4.0/>

REFERENCES

- Roxas R, Gallegos L, Bailitz J. Rapid detection of aortic occlusion with emergency ultrasonography. *Ann Emerg Med.* 2011;58(1):21-3.
- Babu SC, Shah PM, Sharma P, et al. Adequacy of central hemodynamics versus restoration of circulation in the survival of patients with acute aortic thrombosis. *Am J Surg.* 1987;154(2):206-10.
- Crawford JD, Perrone KH, Wong VW, et al. A modern series of acute aortic occlusion. *J Vasc Surg.* 2014;59(4):1044-50.
- Dossa CD, Shepard AD, Reddy DJ, et al. Acute aortic occlusion: a 40-year experience. *Arch Surg.* 1994;129(6):603-7.
- Surowiec SM, Isiklar H, Sreera S, et al. Acute occlusion of the abdominal aorta. *Am J Surg.* 1998;176(6):193-7.
- Brewster DC. (2012). Aortoiliac occlusive disease. In Enrico Acscher (Ed) *Haimovici's Vascular Surgery Edition 6* (pp. 710-35). West Sussex, UK: Wiley-Blackwell.
- Wan IY, Angelini GD, Bryan AJ, et al. Prevention of spinal cord ischaemia during descending thoracic and thoracoabdominal aortic surgery *Eur J Cardiothorac Surg.* 2001;19(2):203-3.
- Lai CH, Wang CH, Wu SY, et al. Aortoiliac occlusive disease presenting as sudden onset paraplegia. *Ann Vasc Surg.* 2014;28(5):1321.e5-7.
- Meagher AP, Lord RS, Graham AR, et al. Acute aortic occlusion presenting with lower limb paralysis. *J Cardiovasc Surg.* 1991;32(5):643-7.
- Wang YC, Chiu YS, Yeh CH. Leriche's syndrome presenting as sciatica. *Ann Vasc Surg.* 2010;24(5):694.e1-3.
- American College of Emergency Physicians. Ultrasound Guidelines: Emergency, Point-of-care, and Clinical Ultrasound Guidelines in Medicine. 2016. Available at <https://www.acep.org/globalassets/new-pdfs/policy-statements/ultrasound-guidelines---emergency-point-of-care-and-clinical-ultrasound-guidelines-in-medicine.pdf>. Accessed June 3, 2019.

12. Costantino TG, Bruno EC, Handy N, et al. Accuracy of emergency medicine ultrasound in the evaluation of abdominal aortic aneurysm. *J Emerg Med.* 2005;29(4):455-60.
13. Dent B, Kendall RJ, Boyle AA, et al. Emergency ultrasound of the abdominal aorta by UK emergency physicians: a prospective cohort study. *Emerg Med J.* 2007;24(8):547-9.
14. Kuhn M, Bonnin RL, Davey MJ, et al. Emergency department ultrasound scanning for abdominal aortic aneurysm: accessible, accurate, and advantageous. *Ann Emerg Med.* 2000;36(3):219-23.
15. Tayal TS, Graf CD, Gibbs MA. Prospective study of accuracy and outcome of emergency ultrasound for abdominal aortic aneurysm over two years. *Acad Emerg Med.* 2003;10(8):867-71.
16. Gibbons RC, Smith D, Mulflur M, et al. Point-of-care ultrasound for the detection of aortic dissections in the emergency department. *Ann Emerg Med.* 2017;70:S143.
17. Pare JR, Liu R, Moore CL, et al. Emergency physician focused cardiac ultrasound improves diagnosis of ascending aortic dissection. *Am J Emerg Med.* 2016;43(3):486-92.

Disseminated Gonorrhea

Janelle Estrada, DO
Shane Sergent, DO
John Ashurst, DO, MSc

Kingman Regional Medical Center, Department of Emergency Medicine,
Kingman, Arizona

Section Editor: Rick A. McPheeters, DO

Submission history: Submitted June 28, 2019; Revision received September 8, 2019; Accepted September 13, 2019

Electronically published November 19, 2019

Full text available through open access at http://escholarship.org/uc/uciem_cpem

DOI: 10.5811/cpem.2019.9.44272

Sexually transmitted infections have risen sharply over the last decade in the United States. The incidence of gonorrhea has risen to 172 reported cases per 100,000 people over the past year. This likely represents an under-representation due to many cases going unreported. Disseminated gonorrhea can present with nonspecific symptoms including arthralgia, cutaneous lesions, or tenosynovitis. Diagnosis is based upon a degree of high clinical suspicion and serology. Emergency department treatment includes ceftriaxone and azithromycin. [Clin Pract Cases Emerg Med. 2020;4(1):83–84.]

CASE PRESENTATION

A 23-year-old male presented to the emergency department (ED) due to a three-day history of a painful, swollen, and erythematous left third digit. He also noted that over the preceding day a black blister had formed on the affected digit. He admitted to a history of intravenous drug use within the prior week but not within the affected digit. He also admitted to unprotected sexual intercourse with multiple partners. He also noted penile discharge one week prior with associated dysuria. Physical examination revealed an erythematous and swollen left third digit with a hemorrhagic bullae (Image). Urine polymerase chain reaction was positive for gonorrhea. The patient was treated with ceftriaxone and azithromycin and admitted for further care. Blood cultures and a wound culture were negative at five days.

DIAGNOSIS

The incidence of sexually transmitted infections in the United States has been on the rise over the last decade. Since 2009, reported cases of gonorrhea have increased by 75.2% and by 18.6% in the last two years.¹ In 2017 alone, a total of 555,608 new cases of gonorrhea were reported to the Centers for Disease Control and Prevention.¹ Although cases of gonorrhea are relatively common for the emergency physician, disseminated gonorrhea occurs in 0.2-1.9% of all patients infected with *Neisseria (N.) gonorrhoeae*.² Cutaneous manifestations are generally nonspecific but can present as herpetiform or non-herpetiform pustules, necrotic

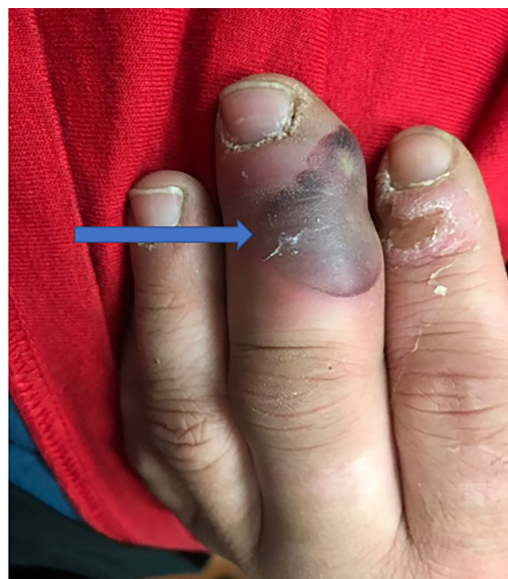

Image. Photograph of the left third digit depicting edema, erythema, and a hemorrhagic bullae (arrow).

vesicles, bullae, or tender purpuric papules.² Diagnosis is confirmed by either identification of *N. gonorrhoeae* in blood, synovial fluid, or tissue.² Presumptive diagnosis can be made in a patient with a clinical presentation consistent with disseminated gonorrhea and microbiologic evidence from the urogenital, rectal, or pharyngeal tract.² ED treatment

should include ceftriaxone one gram intravenously and azithromycin one gram orally, and the patient should be admitted for further management.²

Documented patient informed consent and/or Institutional Review Board approval has been obtained and filed for publication of this case report.

Address for Correspondence: John Ashurst, DO, MSc, Kingman Regional Medical Center, Department of Emergency Medicine, 3269 Stockton Hill Road, Kingman, AZ 86409. Email: Ashurst.john.32.research@gmail.com.

Conflicts of Interest: By the CPC-EM article submission agreement, all authors are required to disclose all affiliations, funding sources and financial or management relationships that could be perceived as potential sources of bias. The authors disclosed none.

Copyright: © 2020 Ashurst et al. This is an open access article distributed in accordance with the terms of the Creative Commons Attribution (CC BY 4.0) License. See: <http://creativecommons.org/licenses/by/4.0/>

REFERENCES

- Centers for Disease Control and Prevention. Sexually transmitted disease surveillance. 2017. Available at: <https://www.cdc.gov/std/stats17/gonorrhea.htm>. Accessed June 14, 2019.
- Beatrous S, Grisoli SB, Riahi RR, et al. Cutaneous manifestations of disseminated gonococemia. *Dermatol Online J*. 2017;23(1):1-6.

CPC-EM Capsule

What do we already know about this clinical entity?

Although a relatively rare entity, cases of disseminated gonorrhea have become more prevalent with the recent increase in sexually transmitted infections in the United States.

What is the major impact of the image(s)?

Cutaneous manifestations of disseminated gonorrhea are varied but can present as hemorrhagic bullae.

How might this improve emergency medicine practice?

When faced with an abnormal skin lesion, the emergency physician should gather further history into the sexual practices of the patient.

Acute Finger Ischemia in an Elderly Male without Risk Factors for Hypercoagulability

Manish Amin, DO*
Angela Torres, MS-IV†
Phillip Aguiñiga-Navarrete*
Daniel Quesada, MD*†
Jason P. Jerome, MD‡
Amber Jones, DO*

*Kern Medical Center, Department of Emergency Medicine, Bakersfield, California
 †LAC+USC Medical Center, Department of Emergency Medicine, Los Angeles, California
 ‡Kern Medical Center, Department of Trauma Surgery, Bakersfield, California

Section Editor: Rick A. McPheeters, DO

Submission history: Submitted September 15, 2019; Revision received November 10, 2019; Accepted November 18, 2019

Electronically published January 23, 2020

Full text available through open access at http://escholarship.org/uc/uciem_cpem

DOI: 10.5811/cpcem.2019.11.45224

Literature on ulnar artery thrombosis and acute finger ischemia is scant and usually related to underlying hypercoagulable or occlusive states, such as atrial fibrillation, thrombangiitis obliterans, vasospasm, trauma, and neurovascular compression at the root of the upper limb. An elderly hypertensive male without an underlying hypercoagulable state, and in otherwise good health, presented to our emergency department with acute multi-finger ischemia, and ulnar artery and palmar arch thromboses. Given his innocuous history, this case demonstrates the importance of maintaining acute arterial thrombosis on the differential for hand pain despite the obvious propensity toward mechanical injuries in the extremities. [Clin Pract Cases Emerg Med. 2020;4(1):85–87.]

CASE PRESENTATION

A 65-year-old male with a past medical history of hypertension presented to the emergency department with sudden-onset distal fourth digit pain and paresthesia in the second through fourth digits of the right hand. His examination revealed mild distal duskiness with proximal pallor of the second through fourth digits, with mottling of his palm. Radial pulses were 2+ with weak ulnar pulses. Capillary refill was greater than two seconds. Allen's test was positive.

His electrocardiogram showed normal sinus rhythm. His coagulation panel, laboratory and inpatient hypercoagulability workup was unremarkable. A computed tomographic angiogram of the right upper extremity displayed an ulnar-artery filling defect (Image 1). A heparin drip was initiated in consultation with vascular surgery. A formal angiogram of his upper extremity revealed a similar filling defect (Image 2A), at which point intra-arterial tissue plasminogen activator (tPA) was initiated. On hospital day two, the patient had a return of a strong ulnar pulse and improved perfusion to the affected digits (Images 2B, 3A, and 3B).

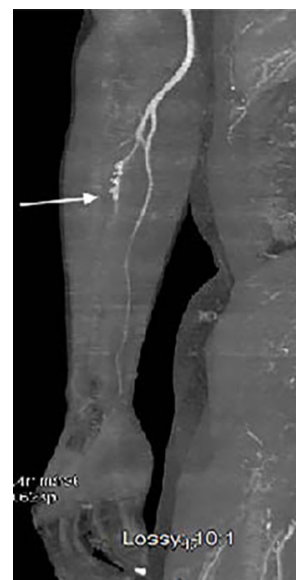

Image 1. Computed tomographic angiography of the right upper extremity revealing abrupt non-opacification of the ulnar artery approximately three centimeters below the takeoff of the interosseous artery (arrow). Non-visualization of the superficial palmar arch and metacarpal arteries.

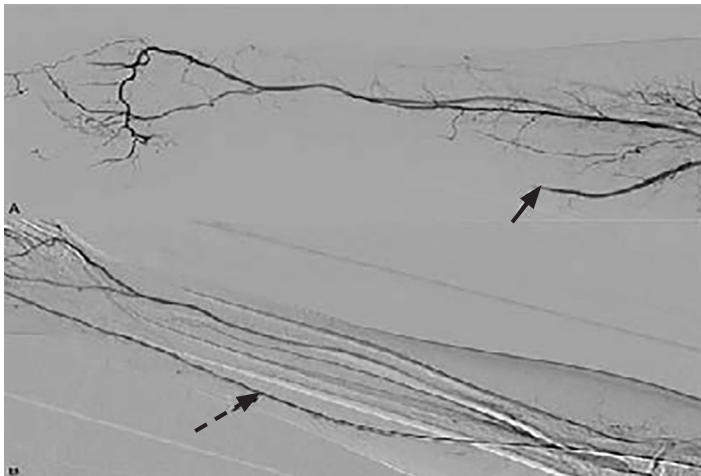


Image 2. Formal angiogram of the right upper extremity (A) revealed ulnar artery flow defect pre-tissue plasminogen activator (tPA) administration (arrow). Formal angiogram of the right upper extremity (B) revealed restoration of ulnar artery flow post-tPA administration (dashed arrow).

DISCUSSION

Common etiologies of acute finger ischemia include but are not limited to hypercoagulable states, atrial fibrillation, thrombangiitis obliterans, vasospasm, trauma, and neurovascular compression at the root of the upper limb.¹ This case demonstrates the importance of physical exam maneuvers such as neurovascular testing, assessment of capillary refill and Allen's test in diagnosing critical limb ischemia where a history of risk factors for arterial thrombi is absent. The

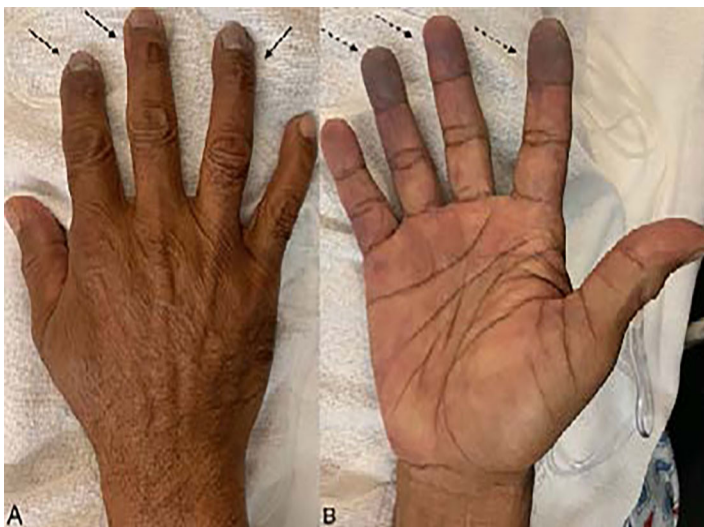

Image 3. Image of the right-hand post-tissue plasminogen activator (tPA) administration. The dorsal aspect of the right hand reveals subungual pallor (A). The palmar aspect of the hand post-tPA administration (pre-tPA not pictured), revealing a significant progression of the mottling and discoloration seen on initial presentation (B).

CPC-EM Capsule

What do we already know about this clinical entity?

Digital ischemia is an uncommon entity that occurs in patients with underlying hypercoagulable states. Treatments include anticoagulation and vascular surgery.

What is the major impact of the image(s)?

The images detail the appearance of acute finger ischemia in a patient lacking risk factors, illustrating that acute finger ischemia must be on the differential diagnosis for hand pain.

How might this improve emergency medicine practice?

In the setting of acute digit pain, even with a relatively benign physical exam, a high index of suspicion for ischemia must be maintained.

management of limb ischemia includes initiating anti-platelet therapy and heparin to prevent further thrombosis.⁵ Restoration of blood flow can be achieved by intra-arterial thrombolytic infusions in conjunction with interventional radiology, surgical revascularization, or thrombectomy.⁵ A retrospective, single-center study revealed a trend toward increased amputation-free survival in patients who underwent thrombolysis after acute finger ischemia; however, the study lacked power.² Further studies are needed to delineate treatment guidelines for patients presenting with acute finger ischemia.

Documented patient informed consent and/or Institutional Review Board approval has been obtained and filed for publication of this case report.

Address for Correspondence: Manish Amin, DO, Kern Medical Center, Department of Emergency Medicine, 1700 Mount Vernon Ave., Bakersfield, CA 93306 Email: Manish.Amin@Kernmedical.com.

Conflicts of Interest: By the CPC-EM article submission agreement, all authors are required to disclose all affiliations, funding sources and financial or management relationships that could be perceived as potential sources of bias. The authors disclosed none.

Copyright: © 2020 Amin et al. This is an open access article distributed in accordance with the terms of the Creative Commons Attribution (CC BY 4.0) License. See: <http://creativecommons.org/licenses/by/4.0/>

REFERENCES

1. Edwards EA. Varieties of digital ischemia and their management. *N Engl J Med.* 1954;250(17):709-16.
2. Islam A, Edgerton C, Stafford JM, et al. Anatomic findings and outcomes associated with upper extremity arteriography and selective thrombolysis for acute finger ischemia. *J Vasc Surg.* 2014;60(2):410-7.
3. Jones NF. Acute and chronic ischemia of the hand: pathophysiology, treatment, and prognosis. *J Hand Surg.* 1991;16(6):1074-83.
4. Thoma A and Ginty M. Spontaneous thrombosis of the ulnar artery from midforearm to common digital arteries: a case report. *J Hand Surg.* 1992;17(2):211-3.
5. Iannuzzi NP and Higgins JP. Acute arterial thrombosis of the hand. *J Hand Surg.* 2015;40(10):2099-106.

A Full Uterus: Hematometra from Cervical Scarring

Christopher S. Sampson, MD
Krysta Arnold, PA-C

University of Missouri School of Medicine, Department of Emergency Medicine,
Columbia, Missouri

Section Editor: Rick A. McPheeters, DO

Submission history: Submitted August 20, 2019; Revision received October 9, 2019; Accepted October 17, 2019

Electronically published January 24, 2020

Full text available through open access at http://escholarship.org/uc/uciem_cpem

DOI: 10.5811/cpem.2019.10.44925

A 29-year-old female presented with abdominal pain, nausea, and vomiting. She reported no menstrual period for one year. She did report monthly episodes of severe cramping. A loop electrosurgical excision procedure was performed approximately 10 months prior. On pelvic exam, a smooth cervix with scarring over the os was visualized with no evidence of cervical opening. A pelvic ultrasound showed an enlarged uterus with contents within the endometrial cavity likely representing hemorrhage of different ages and ongoing bleeding. Gynecology was consulted and performed an incisional opening of the cervix. The patient was diagnosed with hematometra from scarred cervical os. [Clin Pract Cases Emerg Med. 2020;4(1):88–89.]

CASE PRESENTATION

A 29-year-old female presented with abdominal pain, nausea, and vomiting for one day. The pain was in the lower abdomen and described as an achy, constant, fluctuating pain. She had a negative home pregnancy test one week prior and reported no menstrual period for one year due to her current breast feeding. She did report monthly episodes of severe cramping. Vital signs were within normal limits. On exam she was noted to have a soft, non-distended abdomen. Mild, suprapubic tenderness was appreciated. On pelvic exam, a smooth cervix with scarring over the os was visualized with no evidence of cervical opening.

Medical records showed that a loop electrosurgical excision procedure was performed approximately 10 months prior. Labs were notable for white blood cell count of $8.14 \times 10^9/l$ (3.5-10.5), hemoglobin 13.8 grams per deciliter (13.5-17.5), hematocrit 42.2 % (38-50), and platelets $306 \times 10^9/l$ (150-450). A comprehensive metabolic panel and urinalysis were grossly normal. Urine human chorionic gonadotropin was negative. A computed tomography of the abdomen and pelvis was performed, which showed a hypodense mass in lower cervix (Image 1).

A formal pelvic ultrasound was performed and showed an enlarged uterus with mixed echogenic contents within the endometrial cavity likely representing hemorrhage of different ages and ongoing bleeding (Image 2). Gynecology was consulted and performed an incisional opening of the cervix and evacuated dark, mucoid blood and bright red blood. The patient was diagnosed with hematometra from scarred cervical os and was prescribed oral estrogen to prevent reclosure.

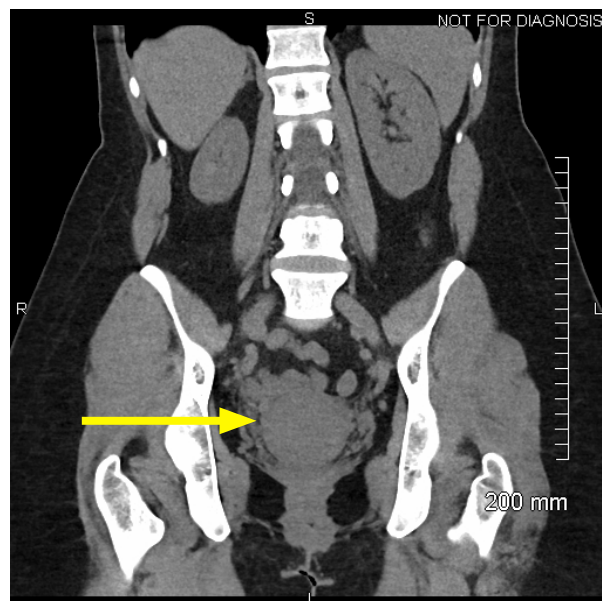


Image 1. Computed tomography of the abdomen and pelvis in coronal view demonstrating a hypodense pelvic mass (arrow).

DISCUSSION

Hematometra is a collection or retention of blood in the uterus most commonly due to an imperforate hymen or transverse vaginal septum.¹ Acquired causes leading to cervical stenosis include radiation treatment, ablation, cervical conization, or

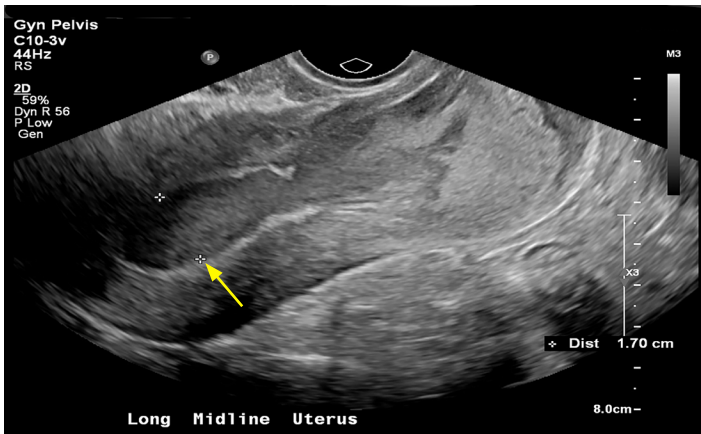


Image 2. Formal pelvic ultrasound showing mixed echogenic contents contained within the uterus (arrow).

malignancies.² Diagnosis can be confirmed with pelvic exam and ultrasound. Treatment is usually done with surgical dilation. This diagnosis should be considered in females of child-bearing age with lower abdominal and pelvic pain.

Documented patient informed consent and/or Institutional Review Board approval has been obtained and filed for publication of this case report.

REFERENCES

1. Dolan MS, Hill C, Valea FA. (2017). Benign gynecological lesions: vulva, vagina, cervix, uterus, oviduct, ovary, ultrasound imaging of pelvic structures. In: Lobo R, Gershenson DM, Letz G Valea F eds. *Comprehensive Gynecology, 7th edition* (pp 370-422.e5). Philadelphia, PA: Elsevier.
2. Hoffman BL, Schorge JO, Bradshaw KD, et al. Pelvic mass. 2016. Available at: <http://accessmedicine.mhmedical.com/content.aspx?bookid=1758§ionid=118168387>. Accessed October 3, 2019.

CPC-EM Capsule

What do we already know about this clinical entity?

Hematometra is a rare but potential cause of pelvic pain in women, especially those who may have undergone cervical procedures leading to scarring.

What is the major impact of the image(s)?

Hematometra can be suspected when pelvic ultrasound shows mixed echogenic contents.

How might this improve emergency medicine practice?

In the patient presenting to the emergency department with pelvic pain, consider hematometra based on previous obstetrical and gynecological history.

Address for Correspondence: Christopher S. Sampson, MD, University of Missouri School of Medicine, Department of Emergency Medicine, One Hospital Drive, Columbia, MO 65212. Email: sampsoncs@health.missouri.edu.

Conflicts of Interest: By the *CPC-EM* article submission agreement, all authors are required to disclose all affiliations, funding sources and financial or management relationships that could be perceived as potential sources of bias. The authors disclosed none.

Copyright: © 2020 Sampson et al. This is an open access article distributed in accordance with the terms of the Creative Commons Attribution ([CC BY 4.0](http://creativecommons.org/licenses/by/4.0/)) License. See: <http://creativecommons.org/licenses/by/4.0/>

A Hidden Complication of Pigtail Catheter Insertion

Júlio C. Garcia de Alencar, MD São Paulo University, Department of Emergency Medicine, São Paulo, Brazil
 Millena G. Pinheiro Costa, MD
 Rodrigo A. Brandao Neto, PhD
 Heraldo Possolo de Souza, PhD

Section Editor: Rick A. McPheeters, DO

Submission history: Submitted August 19, 2019; Revision received October 25, 2019; Accepted November 11, 2019

Electronically published January 21, 2020

Full text available through open access at http://escholarship.org/uc/uciem_cpem

DOI: 10.5811/cpcem.2019.11.44913

Pigtail catheters have emerged as an effective and less morbid alternative to traditional chest tubes for evacuation of pleural air. Rare complications in the literature have been reported. We report a case of a 92-year-old male who presented with dyspnea and shock, noted to have a pneumothorax requiring tube thoracostomy. Computed tomography demonstrated pigtail within the lung parenchyma. We discuss the implications of this occurrence. [*Clin Pract Cases Emerg Med.* 2020;4(1):90–91.]

CASE PRESENTATION

A 92-year-old male presented to the emergency department with a 4-day history of flu-like symptoms and shortness of breath that had progressed to respiratory failure. On admission, he was intubated and on vasopressors due to circulatory shock. Endotracheal intubation had been performed at an outside facility; mechanical ventilation was reportedly difficult. At examination, no breath sounds were audible on the left side, and the jugular veins were distended. Point-of-care ultrasound showed no lung sliding on the left. Tube thoracostomy was performed and a pigtail catheter placed, with positive air drainage. Chest radiograph showed a well-positioned catheter and good lung expansion (Image 1).

On day two, the patient was extubated and transferred to the Intermediate Care Unit. Three days later he had abrupt onset of dyspnea, extensive subcutaneous emphysema, and drainage of serosanguinous fluid through the chest tube instead of air. Chest computerized tomography showed the pigtail within the lung parenchyma and a residual pneumothorax (Image 2).

The decision was to remove the pigtail and place a traditional chest tube. The patient had an uneventful course, with complete resolution of pneumothorax. The chest tube was removed after six days, and the patient was discharged without further complications.

DISCUSSION

Pigtail catheters offer reliable treatment of pneumothoraces, and are a safe and less invasive alternative to tube thoracostomy.¹ Rare complications in the literature such as intraparenchymal insertion, left ventricular penetration, subclavian artery laceration

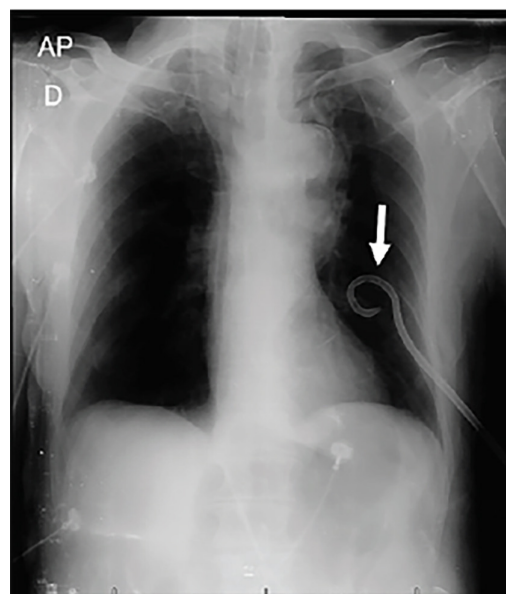


Image 1. Chest radiograph: well-positioned catheter and good lung expansion (arrow).

and cerebral air embolism have been reported.² Image guided technique, ideally ultrasound, should be utilized for pig tail insertion to minimize the risk of complications.³

Documented patient informed consent and/or Institutional Review Board approval has been obtained and filed for publication of this case report.

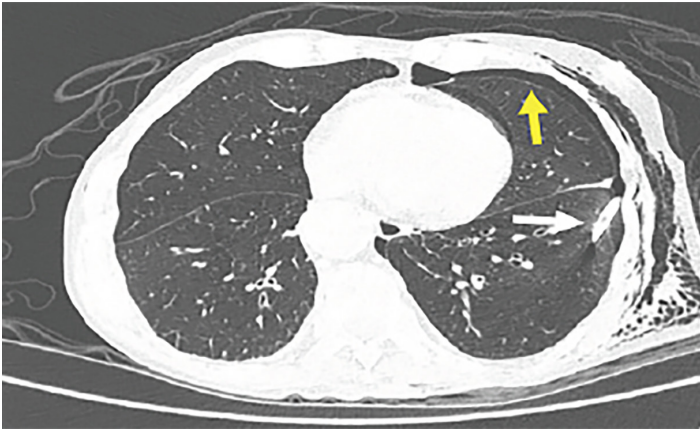


Image 2. Chest computerized tomography: pigtail within the lung parenchyma (white arrow) and a residual pneumothorax (yellow arrow).

Address for Correspondence: Júlio C. Garcia de Alencar, MD, São Paulo University, Department of Emergency Medicine, 255 Eneas de Carvalho Aguir, São Paulo, Brazil 05403-000. Email: julio.alencar@hc.fm.usp.br.

Conflicts of Interest: By the CPC-EM article submission agreement, all authors are required to disclose all affiliations, funding sources and financial or management relationships that could be perceived as potential sources of bias. The authors disclosed none.

Copyright: © 2020 Garcia de Alencar et al. This is an open access article distributed in accordance with the terms of the Creative Commons Attribution (CC BY 4.0) License. See: <http://creativecommons.org/licenses/by/4.0/>

CPC-EM Capsule

What do we already know about this clinical entity?

Pigtail catheters offer reliable treatment of pneumothoraces, and are a safe and less invasive alternative to tube thoracostomy. Rare complications have been reported.

What is the major impact of the image(s)?

We discuss the implications of this occurrence and recommended management based on our experience.

How might this improve emergency medicine practice?

Image guided technique, ideally ultrasound point-of-care, should be utilized for pigtail insertion to minimize the risk of complications.

REFERENCES

1. Gammie JS, Banks MC, Fuhrman CR, et al. The pigtail catheter for pleural drainage: a less invasive alternative to tube thoracostomy. *JSLs*. 1999;3(1):57-61.
2. Saqib A, Ibrahim U, Maroun R. An unusual complication of pigtail catheter insertion. *J Thoracic Dis*. 2018;10(10):5964-7.
3. Laws D, Neville E, Duffy J. Pleural diseases group, standards of care committee, British Thoracic Society: BTS guidelines for the insertion of a chest drain. *Thorax*. 2003;58(suppl 2):53-9.

Hydronephrosis Due to Bilateral Tubo-ovarian Abscess

Emily Fite, MD*
Jennifer Fitzgerald, BS*
Quinn Kistenfeger, BS†

*Saint Louis University School of Medicine, Saint Louis, Missouri
†Saint Louis University School of Medicine, Division of Emergency Medicine, Department of Surgery, Saint Louis, Missouri

Section Editor: Rick A. McPheters, DO

Submission history: Submitted July 16, 2019; Revision received November 1, 2019; Accepted October 17, 2019

Electronically published January 6, 2020

Full text available through open access at http://escholarship.org/uc/uciem_cpchem

DOI: 10.5811/cpchem.2019.10.44568

A 27-year-old female presented to the emergency department with fevers, nausea, chills, and non-specific bilateral lower quadrant abdominal pain. A pregnancy test was negative. Computed tomography demonstrated moderate left hydronephrosis secondary to tubo-ovarian abscess (TOA). The abscess was so large it distorted local anatomy and compressed the ureters. She was prescribed meropenem and admitted for care by obstetrics/gynecology. [Clin Pract Cases Emerg Med. 2020;4(1):92–93.]

CASE PRESENTATION

A 27-year-old female presented to the emergency department with bilateral lower quadrant abdominal pain, fever, nausea, chills, and body aches. She stated she had been ill for three days and was getting worse. She was vomiting all oral intake and had new vaginal discharge. Upon examination, she was febrile to 101.1° Fahrenheit with a heart rate of 160 beats per minute. Her pregnancy test was negative. She had voluntary guarding and generalized tenderness on her abdominal exam while pelvic exam revealed cervical motion tenderness with copious vaginal discharge. Patient was given fluids and pain medication, and we obtained computed tomography (CT) of the abdomen and the pelvis with intravenous contrast (Images 1 and 2).

DISCUSSION

This case demonstrates the complications that can occur when pelvic inflammatory disease goes untreated. Tubo-ovarian abscesses (TOA) can form from an ascending infection of the female genital tract leaking purulent discharge through the fallopian tube and forming a pus-filled mass encompassing the tube and/or ovary.¹ In this case, the abscess was so large that it distorted local anatomy and compressed the ureters, causing hydronephrosis. Ultrasonography or CT can be used to evaluate nonspecific symptoms and look for specific complications associated with pelvic inflammatory disease.² The CT demonstrated findings consistent with the presence of a TOA with hydronephrosis (Image 2).

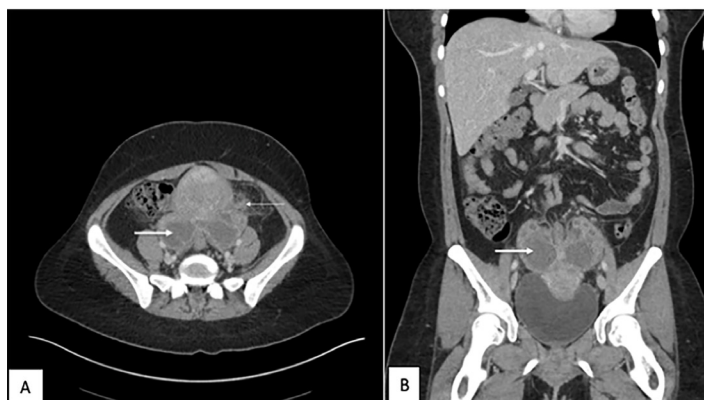

Image 1. Computed tomography of abdomen and pelvis (A) axial view and (B) coronal view. Thick arrow: Bilateral adnexal multilocular septate cystic masses with enhancing septa and loss of normal ovarian parenchyma. Thin arrow: surrounding peritubal fat stranding.

First-line treatment of TOA with broad-spectrum antibiotics should begin immediately after blood cultures are taken.¹ Treatment with antibiotics has been shown to be effective in many patients, but recurrence is likely. Surgical intervention may be considered if it is a recurrence, nonresponsive to antibiotics, or if rupture occurs.^{1,3} Minimally invasive measures should be considered, especially in women of childbearing age, to avoid causing infertility.³ Our patient was prescribed meropenem and she was admitted for care by her obstetrician-gynecologist.

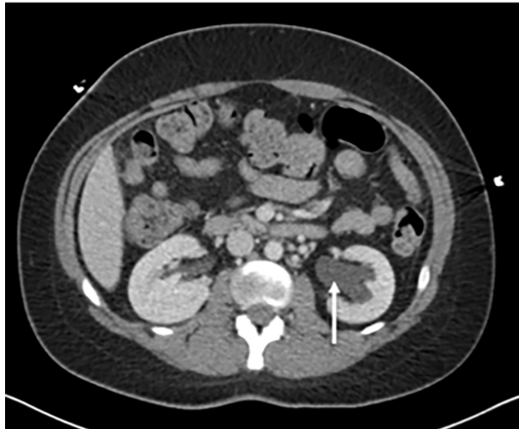

Image 2. Computed tomography of the abdomen and pelvis in axial view demonstrating bilateral hydronephrosis, more prominent on the left (arrow) secondary to tubo-ovarian abscess.

Documented patient informed consent and/or Institutional Review Board approval has been obtained and filed for publication of this case report.

Address for Correspondence: Quinn Kistenfeger, BS, Saint Louis University School of Medicine, Address, Saint Louis, MO 63110. Email: quinn.kistenfeger@health.slu.edu.

Conflicts of Interest: By the *CPC-EM* article submission agreement, all authors are required to disclose all affiliations, funding sources and financial or management relationships that could be perceived as potential sources of bias. The authors disclosed none.

Copyright: © 2020 Fite et al. This is an open access article distributed in accordance with the terms of the Creative Commons Attribution ([CC BY 4.0](http://creativecommons.org/licenses/by/4.0/)) License. See: <http://creativecommons.org/licenses/by/4.0/>

CPC-EM Capsule

What do we already know about this clinical entity?

Untreated tubo-ovarian abscess (TOA) can lead to abscess rupture, sepsis, and infection of nearby organs.

What is the major impact of the image(s)?

In our case, the patient had a TOA so large that it put pressure on the ureters, causing bilateral hydronephrosis.

How might this improve emergency medicine practice?

TOA is a less common diagnosis. Treatment should begin promptly with broad-spectrum antibiotics and may require surgical intervention to prevent abscess rupture and sepsis.

REFERENCES

1. Munro K, Gharaibeh A, Nagabushanam S, et al. Diagnosis and management of tubo-ovarian abscesses. *Obstet Gynecol.* 2018;20(1):11-9.
2. Rezvani M and Shaaban AM. Fallopian tube disease in the nonpregnant patient. *Radiographics.* 2011;31(2):527-48.
3. Tokumaru T, Shima Y, Okabayashi T, et al. Emergency surgery for tubo-ovarian abscess identified extended-spectrum beta-lactamase-producing *Escherichia coli*: the first case presentation revealing causative bacteria. *Surg Case Rep.* 2015;1(1):66.

Renal Infarct After Endovascular Abdominal Aortic Aneurysm Repair: Consider in Back Pain Differential

Sophia Y. Liu, MD
Anthony Hackett, DO

Carl R. Darnall Army Medical Center, Department of Emergency Medicine, Fort Hood, Texas

Section Editors: Scott Goldstein, MD

Submission history: Submitted May 1, 2019; Revision received October 14, 2019; Accepted October 17, 2019

Electronically published January 2, 2020

Full text available through open access at http://escholarship.org/uc/uciem_cpccem

DOI: 10.5811/cpcem.2019.10.43623

As hypertension, obesity, and hyperlipidemia become more widespread, the prevalence of abdominal aortic aneurysms (AAA) has also increased.¹ Traditionally those with multiple comorbidities – also those with greatest AAA mortality – were considered too high risk for operative repair. In recent decades, however, endovascular abdominal aortic aneurysm repair (EVAR) has become a popular option, especially for high-risk patients. Overall, short-term outcomes are comparable to traditional open repair despite higher patient baseline risk. However, EVAR comes with its own risks, which the emergency physician should be aware of. Here, we present a rare complication of EVAR: device thrombosis with subsequent renal infarct. [Clin Pract Cases Emerg Med. 2020;4(1):94–95.]

CASE PRESENTATION

The image shows a left renal infarct two months after an endovascular abdominal aortic aneurysm repair (EVAR). A 50-year-old male with a history of lupus, chronic obstructive pulmonary disease, and coronary artery disease presented with four hours of acute back and groin pain. The patient had no history of coagulopathy or prior thromboembolism. His exam showed diffuse abdominal tenderness and was otherwise non-focal with good distal perfusion. Vitals were within normal limits and stable throughout evaluation. His laboratory values were normal except for a leukocytosis of 12×10^3 per microliter (μL) ($4.5\text{--}11.0 \times 10^3 / \mu\text{L}$) and a serum creatinine of 1.59 milligrams per deciliter (mg/dL) ($0.6\text{--}1.3 \text{ mg/dL}$) with normal coagulation studies. Subsequent computed tomography angiogram of the aorta was performed, demonstrating a thrombosed endoluminal stent and a left kidney with intraparenchymal gas, indicating ischemic changes (Image 1 and 2).

DISCUSSION

EVAR has become more common in recent decades as the technology has improved. This is an especially viable option for high-risk patients with comorbidities who may not tolerate open repair. Overall, EVAR has a lower 30-day mortality, perioperative morbidity, and a shorter recovery period compared to open repair.

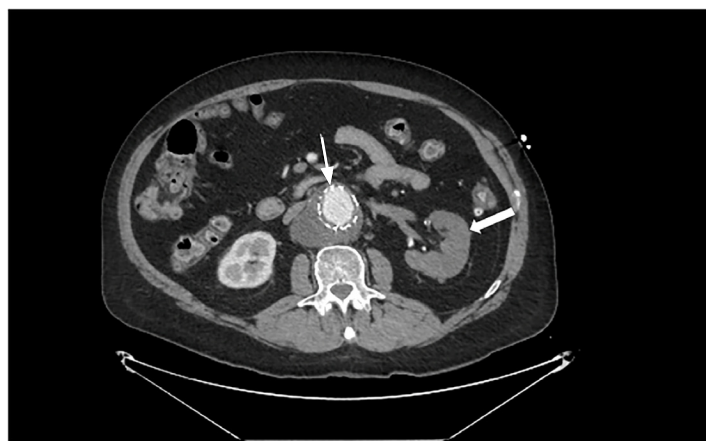

Image 1. Computed tomography with contrast in axial view demonstrating thrombosed endoluminal aortic stent (thin arrow) and infarcted left kidney (thick arrow).

Despite higher-risk patients, endovascular and open repair have similar long-term outcomes and survival.² Known complications of EVAR include the following: device migration; mechanical failures; graft infection; end-organ ischemia; and endoleaks (failure of the graft with continued expansion of the aneurysm from migration, graft porosity, aneurysmal dilation, collateral flow, or improper anchoring of the graft).

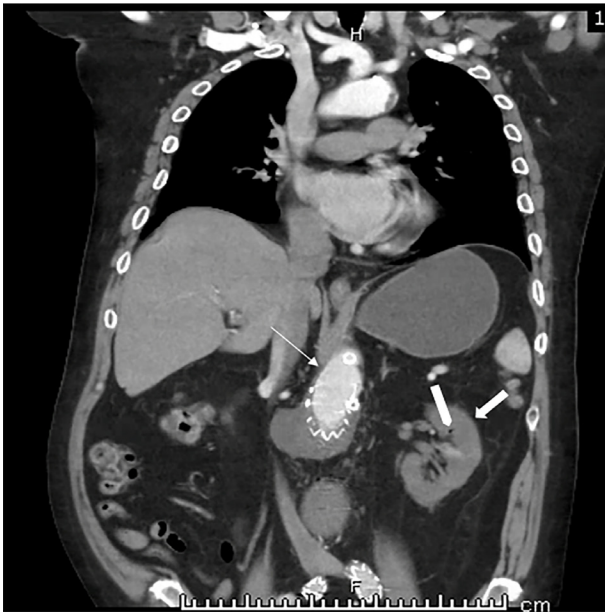


Image 2. Computed tomography with contrast in coronal view demonstrating thrombosed endoluminal aortic stent (thin arrow) and infarcted left kidney (thick arrow) with intraparenchymal air (tab).

Bearing in mind these known complications, patients require lifelong surveillance.³ Renal infarction has been reported with endovascular repair, ranging from 2.5-6.4%, usually from stent occlusion of the accessory renal artery.⁴ Graft occlusion or restenosis is a relatively rare complication, with rates as low as <0.005%.^{5,6} As EVAR becomes more common and patients are surviving longer, emergency physicians should consider these potentially catastrophic complications during their workup of these patients presenting with severe back pain.

Documented patient informed consent and/or Institutional Review Board approval has been obtained and filed for publication of this case report.

REFERENCES

1. Sidloff D, Stather P, Dattani N, et al. Aneurysm Global Epidemiology Study: public health measures can further reduce abdominal aortic aneurysm mortality. *Circulation*. 2014;129:747-53.
2. Moore WS, Kashyap VS, Vescera CL, et al. Abdominal aortic aneurysm: a 6-year comparison of endovascular versus transabdominal repair. *Ann Surg*. 1999;230(3):298-306.
3. Daye D and Walker TG. Complications of endovascular aneurysm repair of the thoracic and abdominal aorta: evaluation and management. *Cardiovasc Diagn Ther*. 2018;8(S1):S138-56.
4. Miller LE, Razavk MK, Lal BK. Suprarenal versus infrarenal stent graft fixation on renal complications after endovascular aneurysm

CPC-EM Capsule

What do we already know about this clinical entity?

Endovascular abdominal aortic aneurysm repair (EVAR) comes with known complications requiring life-long surveillance. Graft restenosis however, is a very rare complication, occurring in <0.005%.

What is the major impact of the image(s)?

Renal infarct in EVAR is usually due to renal artery occlusion by the graft itself. Here, the infarct was secondary to graft thrombosis, highlighting another cause of morbidity and mortality.

How might this improve emergency medicine practice?

This image demonstrates a rare complication of an increasingly used intervention, thereby highlighting the need for caution by emergency physicians in this growing patient population.

Address for Correspondence: Sophia Liu, MD, Carl R. Darnall Army Medical Center, Department of Emergency Medicine, 36065 Santa Fe Drive, Fort Hood, TX 76544. Email: syliu89@gmail.com.

Conflicts of Interest: By the CPC-EM article submission agreement, all authors are required to disclose all affiliations, funding sources and financial or management relationships that could be perceived as potential sources of bias. The authors disclosed none. The views expressed here are those of the authors and do not reflect the official policy of the Department of the Army, the Department of Defense, or the U.S. Government.

Copyright: © 2020 Liu et al. This is an open access article distributed in accordance with the terms of the Creative Commons Attribution (CC BY 4.0) License. See: <http://creativecommons.org/licenses/by/4.0/>

repair. *J Vasc Surg*. 2015;61(5):1340-9.

5. Jacobowitz GR, Lee AM, Riles TS. Immediate and late explantation of endovascular aortic grafts: the endovascular technologies experience. *J Vasc Surg*. 1999;29(2):308-16.
6. NCD Vascular Surgery Data Analysis Team. Vascular Surgery in Japan: 2011 Annual Report by the Japanese Society for Vascular Surgery. *Ann Vasc Dis*. 2018;11(3):377-97.

Endotracheal Metastasis Causing Airway Obstruction

Yudai Yano, MD*
Takashi Fujiwara, MD, PhD†
Masanobu Mizuta, MD, PhD†

*Kurashiki Central Hospital, Department of Emergency and Critical Care Center, Okayama, Japan
†Kurashiki Central Hospital, Department of Otolaryngology Head and Neck Surgery, Okayama, Japan

Section Editor: Rick A. McPheeters, DO

Submission history: Submitted August 24, 2019; Revision received October 17, 2019; Accepted October 30, 2019

Electronically published January 21, 2019

Full text available through open access at http://escholarship.org/uc/uciem_cpem

DOI: 10.5811/cpcem.2019.10.44964

Endotracheal metastasis, a critical complication of primary lung cancer, is an extremely rare lesion. A 73-year-old woman who had previously received treatment for lung cancer presented to our emergency department with dyspnea. A chest computed tomography and nasopharyngolaryngoscopy showed an endotracheal mass below the epiglottis, obstructing the trachea almost completely. The patient had an emergency tracheostomy, and then the mass was removed via median laryngotomy. This lesion was proven to be a recurrent metastasis of lung cancer. Clinicians should recognize endotracheal metastasis as an important differential diagnosis in cancer patients presenting with respiratory symptoms. [Clin Pract Cases Emerg Med. 2020;4(1):96–98.]

CASE PRESENTATION

A 73-year-old woman presented to our emergency department with complaints of dyspnea for one month. She had a history of pulmonary large-cell neuroendocrine carcinoma (LCNEC) and chronic obstructive pulmonary disease. Following surgery for LCNEC, she had also completed chemotherapy and radiation therapy 10 months earlier. Currently she was receiving home oxygen therapy with nasal cannula at two liters per minute.

Her respiratory rate was 19 breaths per minute and oxygen saturation was 96% with nasal cannula at two liters per minute. Lungs were clear to auscultation and there was no stridor. A chest computed tomography (CT) and nasopharyngolaryngoscopy showed an endotracheal mass below the glottis, almost completely obstructing the trachea (Images 1 and 2).

She underwent emergency tracheostomy for airway protection, and then the mass was removed via median laryngotomy (Image 3). Post surgically, her dyspnea improved. On histopathology examination, recurrent metastasis of LCNEC was diagnosed. She was started on chemotherapy and radiation therapy for recurrent metastasis. The postoperative course was uneventful, and the tracheo-cutaneous fistula could be closed two months later.

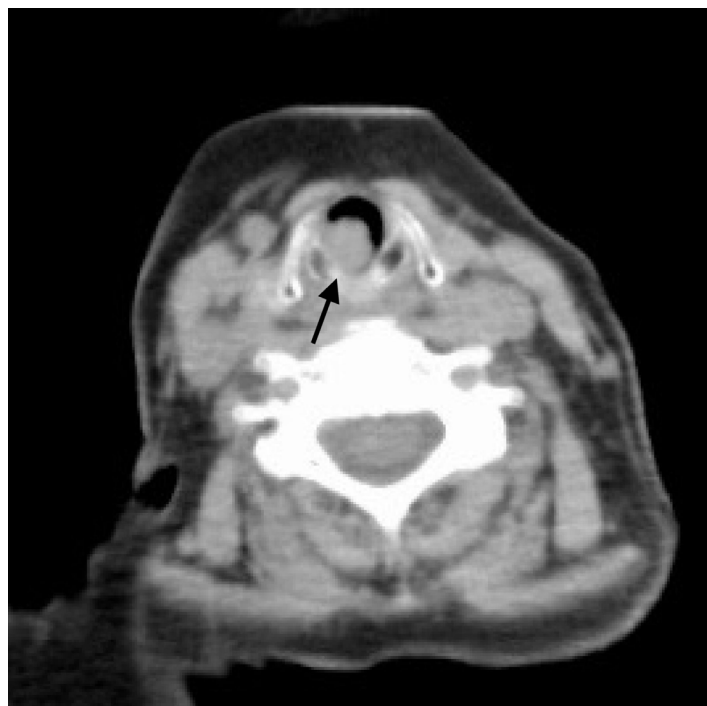

Image 1. A chest computed tomography showing the endotracheal mass (arrow) immediately below the glottis.

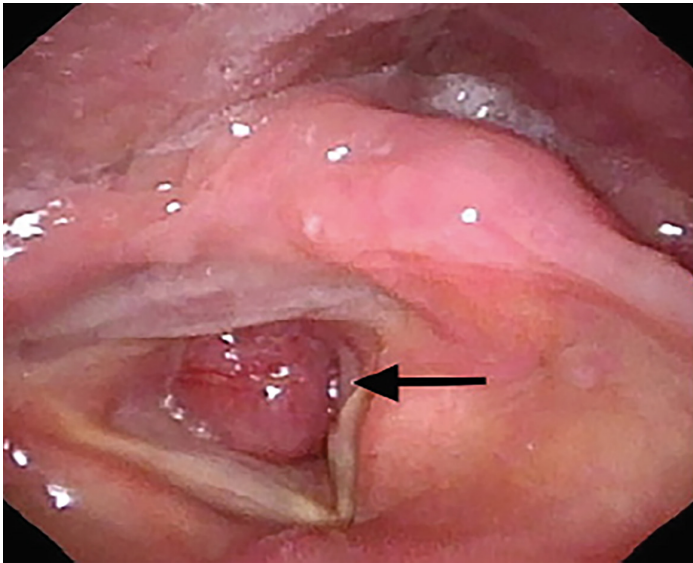


Image 2. Nasopharyngolaryngoscopy showing the mass (arrow) immediately below the glottis, obstructing the patient's airway almost completely.

DISCUSSION

Endotracheal metastasis of primary lung cancer is extremely rare with a reported prevalence of 0.44%.¹ It is a serious complication due to the risk of airway obstruction. Sudden death due to endotracheal metastasis has been reported previously.² A differential diagnosis of airway metastasis should be considered in cancer patients complaining of respiratory symptoms. To avoid missing lesions of the upper airway, a chest CT including the glottis is recommended.

Depending on the patient's general condition and site of metastasis, various treatment modalities such as airway stents,

bronchoscopic extraction, laser ablation, and radiation therapy are available.³ However, the most important management step is to secure the airway. In our case, tracheostomy was performed to safely secure the airway because the endotracheal metastasis was immediately below the glottis. Clinicians should select the best airway management including surgical options.

Documented patient informed consent and/or Institutional Review Board approval has been obtained and filed for publication of this case report.

Address for Correspondence: Yudai Yano, MD, Kurashiki Central Hospital, Department of Emergency Medicine, 1-1-1 Miwa Kurashiki, Okayama 710-8602, Japan. Email: Itq23kt@gmail.com.

Conflicts of Interest: By the CPC-EM article submission agreement, all authors are required to disclose all affiliations, funding sources and financial or management relationships that could be perceived as potential sources of bias. The authors disclosed none.

Copyright: © 2020 Yano et al. This is an open access article distributed in accordance with the terms of the Creative Commons Attribution (CC BY 4.0) License. See: <http://creativecommons.org/licenses/by/4.0/>

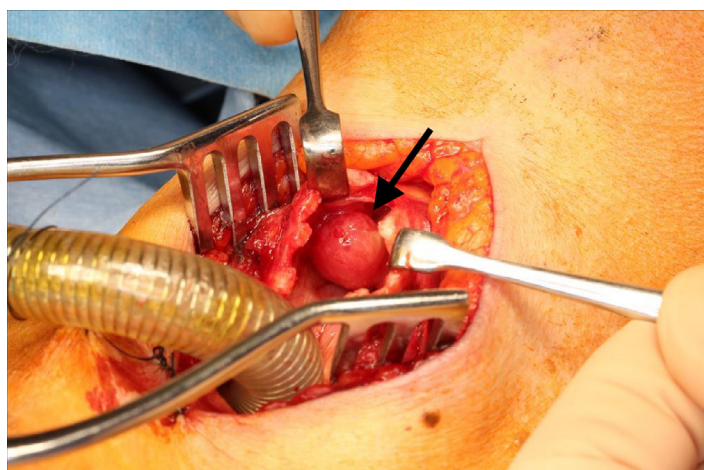


Image 3. The endotracheal mass (arrow) was removed via median laryngotomy after tracheostomy.

CPC-EM Capsule

What do we already know about this clinical entity?

Primary lung cancer can metastasize in the trachea, but this is extremely rare.

What is the major impact of the image(s)?

Endotracheal metastasis of primary lung cancer obstructed the patient's airway almost completely. After emergency tracheostomy, the metastasis was removed via median laryngotomy.

How might this improve emergency medicine practice?

Endotracheal metastasis can lead to airway obstruction. Clinicians should recognize endotracheal metastasis as a differential diagnosis in cancer patients presenting with respiratory symptoms.

REFERENCES

1. Chong S, Kim TS, Han J. Tracheal metastasis of lung cancer: CT findings in six patients. *AJR Am J Roentgenol.* 2006;186(1):220-4.
2. Byard RW. Endobronchial/tracheal metastasis and sudden death. *J Forensic Sci.* 2014;59(4):1139-41.
3. Shavit L, Maly B, Rosenbaum E, et al. Endotracheal metastases in renal cell carcinoma: a life-threatening but treatable complication. *Eur J Intern Med.* 2007;18(2):161-3.

Diabetic Muscle Infarction

Sophia Ahmed, MD
Romeo Fairley, MD

UT Health San Antonio, Department of Emergency Medicine, San Antonio, Texas

Section Editor: Rick McPheeters, DO

Submission history: Submitted October 9, 2019; Revision received October 22, 2019; Accepted October 30, 2019

Electronically published January 21, 2020

Full text available through open access at http://escholarship.org/uc/uciem_cpem

DOI: 10.5811/cpcem.2019.10.45483

A 58-year-old male with past medical history of diabetes mellitus presented with pain to the bilateral groin for six weeks. Magnetic resonance imaging of the patient's lower extremities revealed acute myoedema, and he was diagnosed with myositis secondary to diabetic muscle infarction. [Clin Pract Cases Emerg Med.2020;4(1):99–100.]

CASE PRESENTATION

A 58-year-old male presented after persistent severe pain to the bilateral groin for six weeks. He had no fever, urinary symptoms, incontinence, trauma, weight loss, or saddle anesthesia. He had a history of diabetes mellitus and hypertension. Physical examination showed tenderness to palpation of the suprapubic region, normal testicles, no inguinal hernias, and hyperpigmentation extending from the groin to the left mid-thigh. Laboratory tests revealed an elevated creatinine of 1.56 milligrams per deciliter (mg/dL) (normal 0.60 to 1.30 mg/dL), creatine kinase (CK) of 177 units per liter (U/L) (normal 24 – 223 U/L), C-reactive protein (CRP) of 180 mg/L (normal <10.01 mg/L) and erythrocyte sedimentation rate (ESR) 106 millimeters per hour (mm/hr) (normal 2 – 37 mm/hr). Hemoglobin A1c was 11.4% (normal 4.0 - 6.4%), consistent with his longstanding history of poorly controlled diabetes.

Ultrasound of scrotum and computed tomography of the abdomen/pelvis were both non-diagnostic. Magnetic resonance imaging (MRI) of the bilateral lower extremities (see image), revealed acute myoedema involving the left obturator internus, externus and proximal adductor muscles of the left thigh. Findings were concerning for acute myositis likely secondary to diabetic muscle infarction. The patient was admitted for pain and glucose control. CRP down-trended to 110 mg/L prior to discharge and acute kidney injury resolved.

DISCUSSION

Diabetic muscle infarction is a rare, difficult-to-diagnose disease causing significant pain and morbidity for patients. The mean duration of symptoms before presenting for care is about four weeks, and time to resolution ranges from 2-17 weeks with an average of four weeks.¹ CK, ESR and CRP may be elevated,

but are nonspecific. MRI with intravenous contrast is the most useful diagnostic imaging technique.² Computed tomography and ultrasounds are routinely non-diagnostic. All patients with diabetic muscle infarction should be treated with an antiplatelet agent, most commonly aspirin.³ Use of antiplatelet and/or anti-inflammatory agents decreases mean recovery time by 2.5 weeks.⁴ Recurrence rates exceed 40%, so early recognition and management is pivotal.⁴

Documented patient informed consent and/or Institutional Review Board approval has been obtained and filed for publication of this case report.

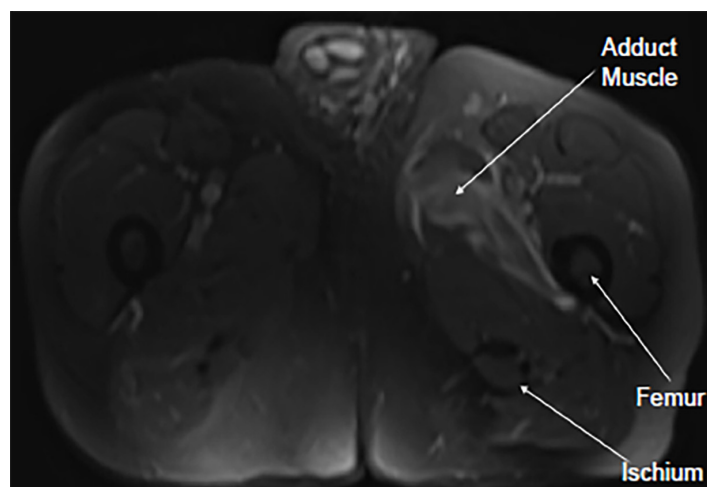


Image. Magnetic resonance imaging demonstrating acute myositis of the left proximal adductor muscles.

Address for Correspondence: Sophia Ahmed, MD, UT Health San Antonio, Department of Emergency Medicine, 7703 Floyd Curl Drive, MC7736, San Antonio, TX 78229. Email: Ahmeds1@uthscsa.edu.

Conflicts of Interest: By the CPC-EM article submission agreement, all authors are required to disclose all affiliations, funding sources and financial or management relationships that could be perceived as potential sources of bias. The authors disclosed none.

Copyright: © 2020 Ahmed et al. This is an open access article distributed in accordance with the terms of the Creative Commons Attribution (CC BY 4.0) License. See: <http://creativecommons.org/licenses/by/4.0/>

REFERENCES

1. Trujillo-Santos AJ. Diabetic Muscle Infarction: An underdiagnosed complication of long-standing diabetes. *Diabetes Care*. 2003;26(1):211-5.
2. Umpierrez GE, Stiles RG, Kleinbart J, et al. Diabetic muscle infarction. *Am J Med*. 1996;101(3):245-50.
3. Horton WB, Taylor JS, Ragland TJ, et al. Diabetic muscle infarction: a systematic review. *BMJ Open Diabetes Res Care*. 2015;3(1):e000082.
4. Kapur S and McKendry RJ. Treatment and outcomes of diabetic muscle infarction. *J Clin Rheumatol*. 2005;11(1):8-12.

CPC-EM Capsule

What do we already know about this clinical entity?

The pathogenesis of myositis is unknown, and it is rarely diagnosed. It causes acute or subacute swelling, pain and tenderness, predominantly in the thigh or calf.

What is the major impact of the image(s)?

Magnetic resonance imaging demonstrates myositis in a typical distribution for diabetic muscle infarction. It may be undetected on other imaging modalities including computed tomography.

How might this improve emergency medicine practice?

Diabetes has increased in prevalence, so physicians should keep the diagnosis in mind. Magnetic resonance imaging is the diagnostic tool of choice.

Idiopathic Bilateral Internal Jugular Vein Thrombosis Diagnosed by Point-of-Care Ultrasound

Victor M. Aquino-Jose, MD*
Jennifer Johnson, BA†
Tina Dulani, MD‡

*Stony Brook University Hospital, Department of Surgery, Division of Trauma, Emergency Surgery, and Critical Care, Stony Brook, New York

†North Shore University Hospital-Northwell Health, Department of Emergency Medicine, Manhasset, New York

‡Donald and Barbara Zucker School of Medicine at Hofstra/Northwell, Department of Emergency Medicine, Manhasset, New York

Section Editor: Rick A. McPheeters, DO

Submission history: Submitted August 6, 2019; Revision received October 2, 2019; Accepted November 11, 2019

Electronically published January 21, 2020

Full text available through open access at http://escholarship.org/uc/uciem_cpchem

DOI: 10.5811/cpchem.2019.11.44855

Internal jugular vein (IJV) thrombosis is an unusual condition, especially when it develops bilaterally. This is a case of bilateral IJV thrombosis in a 77-year old female who presented to the emergency department with neck and arm swelling after discontinuing apixaban and undergoing an oropharyngeal procedure. The diagnosis of bilateral IJV thrombosis was made with the use of point-of-care ultrasound to evaluate bilateral jugular vein distention and bilateral upper extremity pitting edema found on her physical examination. [Clin Pract Cases Emerg Med. 2020;4(1):101–102.]

CASE PRESENTATION

A 77-year-old female with a history of atrial fibrillation currently taking apixaban presented to the emergency department (ED) with swelling of her neck and arms for the past seven days. Two weeks prior, she underwent an embolization of a greater palatine pseudoaneurysm, for which she stopped taking apixaban. After being discharged from the hospital, she continued to experience neck swelling, and had an upper extremity ultrasound evaluation which was negative for thrombus. She returned to the ED for worsening neck swelling. She denied shortness of breath, chest pain, fever, or a history of thromboembolic disease. Her physical exam showed pitting edema on bilateral upper extremities and bilateral jugular vein distention. Point-of-care ultrasound was performed on patient's neck and upper extremities, revealing thrombosis in bilateral internal jugular veins (IJV) as seen in the Image. The patient was started on anticoagulation and admitted to the Intensive Care Unit (ICU) for monitoring due to significant thrombus burden.

DISCUSSION

IJV thrombosis is an uncommon condition and very rare when it occurs bilaterally. Previous studies indicate that it usually occurs in patients with a history of malignancy, oropharyngeal infections, or deep vein thrombosis.^{1,2} In this case, the patient's recent oropharyngeal procedure and cessation of apixaban

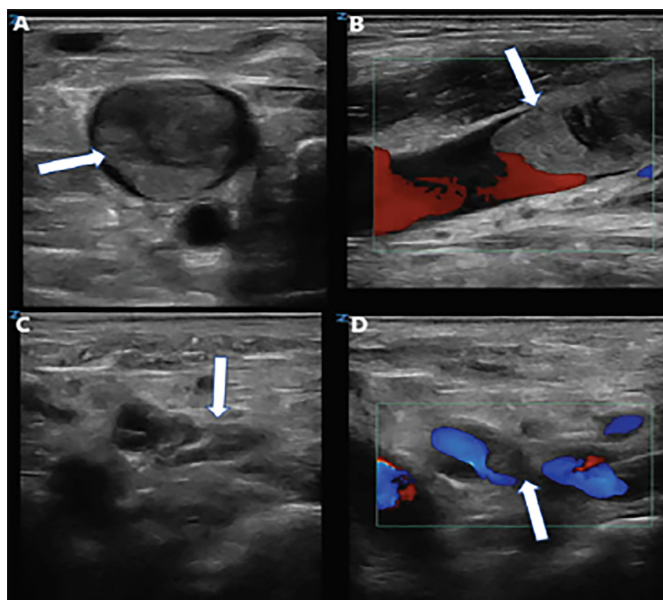


Image. A) Thrombus in the right internal jugular vein (arrow) seen on transverse view. B) Sagittal view of right internal jugular vein thrombus (arrow) with color doppler showing obstruction of venous outflow and turbulence proximal to the thrombus. C) Thrombus in the distal left internal jugular vein (arrow) seen on transverse view. D) Color doppler of the left internal jugular vein thrombus (arrow) showing partial occlusion of the lumen seen on transverse view.

may have led to thrombus formation. IJV thrombosis increases the risk of clot migration and further thrombosis, leading to pulmonary embolism and cerebral vein thrombosis.³ These risks increase when there is bilateral IJV thrombosis due to significant venous outflow obstruction.⁴ Patients with this condition should be started on anticoagulation and monitored for signs of clot migration or worsening thrombosis. The patient was admitted to the ICU for initial monitoring while on anticoagulation due to significant clot burden and was later discharged home on oral anticoagulation without complications.

Video. A) Thrombus in the right internal jugular vein (arrow) seen on transverse view. B) Sagittal view of right internal jugular vein thrombus (arrow) with color doppler showing obstruction of venous outflow and turbulence proximal to the thrombus. C) Thrombus in the distal left internal jugular vein (arrow) seen on transverse view. D) Color doppler of the left internal jugular vein thrombus (arrow) showing partial occlusion of the lumen seen on transverse view.

Documented patient informed consent and/or Institutional Review Board approval has been obtained and filed for publication of this case report.

Address for Correspondence: Tina Dulani, MD, Donald and Barbara Zucker School of Medicine at Hofstra/Northwell, Department of Emergency Medicine, 300 Community Drive, Manhasset, NY 11030. Email: tdulani@northwell.edu.

Conflicts of Interest: By the CPC-EM article submission agreement, all authors are required to disclose all affiliations, funding sources and financial or management relationships that could be perceived as potential sources of bias. The authors disclosed none.

Copyright: © 2020 Aquino-Jose et al. This is an open access article distributed in accordance with the terms of the Creative Commons Attribution (CC BY 4.0) License. See: <http://creativecommons.org/licenses/by/4.0/>

CPC-EM Capsule

What do we already know about this clinical entity?

Internal jugular vein (IJV) thrombosis may develop in patients with malignancy or oropharyngeal infections.

What is the major impact of the image(s)?

IJV thrombosis may develop bilaterally in patients presenting with jugular vein distention without exhibiting the common causes of bilateral thrombosis of the internal jugular veins.

How might this improve emergency medicine practice?

Point-of-care ultrasound is effective at providing a prompt diagnosis of bilateral IJV thrombosis and should be monitored after anticoagulation is provided.

REFERENCES

1. Sheikh MA, Topoulos AP, Deitcher SR. Isolated internal jugular vein thrombosis: Risk factors and natural history. *Vasc Med.* 2002;7(3):177-9.
2. Leci-Tahiri L, Zherka-Saracini H, Tahiri A, et al. Bilateral internal jugular vein thrombosis due to malignant tumor. *J Med Case Rep.* 2018;12(1):42.
3. Boedeker CC, Ridder GJ, Weerda N, et al. Etiology and therapy of the internal jugular vein thrombosis. *Laryngorhinootologie.* 2004;83(11):743-9.
4. Li C, Sun L, Zhao X, et al. Cerebral venous thrombosis originating from internal jugular vein outflow impairment: A case report. *Medicine (Baltimore).* 2017;96(48):e8975.

Pseudo-duplication of the Gallbladder

Jamie Adamski, DO*
 Divya Mohan, DO*†
 Christopher Waasdorp, DO*†

*Jefferson Northeast, Department of Emergency Medicine, Philadelphia, Pennsylvania
 †Jefferson Northeast, Department of Family Medicine, Philadelphia, Pennsylvania

Section Editor: John Ashurst, DO

Submission history: Submitted April 5, 2019; Revision received September 3, 2019; Accepted September 6, 2019

Electronically published November 19, 2019

Full text available through open access at http://escholarship.org/uc/uciem_cpccm

DOI: 10.5811/cpcem.2019.9.43332

Phrygian cap and its rare relative, pseudo-duplication of the gallbladder, are two radiologic findings that may be revealed on ultrasound evaluation. Correct identification of Phrygian cap and pseudo-duplication should trigger a careful survey of the gallbladder in its entirety to rule out pathology. These anatomic variants may lead to partial under-distension of the gallbladder and can cause the gallbladder wall to appear falsely thickened. Asymptomatic patients with this finding may be safely discharged while symptomatic patients may require further surgical consultation. [Clin Pract Cases Emerg Med. 2020;4(1):103–104.]

CASE PRESENTATION

A 30-year-old male with history of cholelithiasis presented with right upper and lower quadrant abdominal pain, nausea, vomiting, and subjective fevers. He denied diarrhea, hematochezia, melena, dysuria, hematuria, urinary frequency, chest pain, or shortness of breath. History raised suspicion for cholecystitis versus appendicitis. Labs revealed a mild leukocytosis. Computed tomography showed gallbladder wall thickening (Image 1), and point-of-care ultrasound (Image 2) demonstrated a Phrygian cap with pseudo-duplication of the

gallbladder. After surgical consultation, cholescintigraphy was negative for cholecystitis. With successful pain control and oral fluid challenge, the patient was discharged with outpatient surgical follow-up.

DISCUSSION

Correct identification of Phrygian cap and its rare relative, pseudo-duplication of the gallbladder, warrants careful survey of the gallbladder to rule out underlying pathology.² The term Phrygian cap refers to a portion of

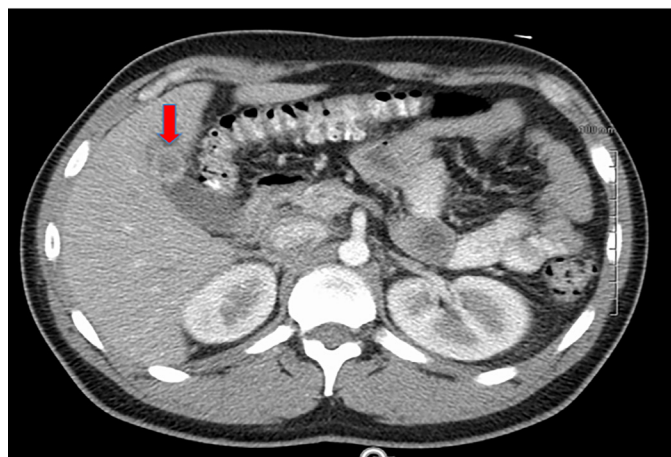

Image 1. Computed tomography demonstrating gallbladder wall thickening (red arrow).

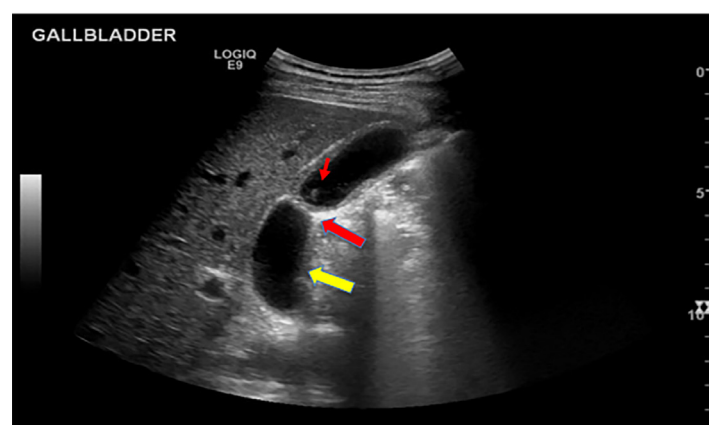


Image 2. Ultrasound showing a Phrygian cap (large red arrow) and pseudo-duplication (large yellow arrow) with mild gallbladder wall thickening (measuring 3.3 millimeters) and gallstones (small arrow).

the gallbladder that contains an outpouching or folded-over portion. Pseudo-duplication of the gallbladder, a congenital abnormality with an incidence of 1:4000, refers to a duplicate appearance of the gallbladder in the presence of a Phrygian cap. Pseudo-duplication of the gallbladder is associated with congenital biliary obstruction and is important to identify, as the distal segment past the “fold” of the Phrygian cap may be relatively under-distended. This under-distension may allow the gallbladder wall to appear falsely thickened. In an asymptomatic patient, Phrygian cap has no pathological significance and prophylactic cholecystectomy is not necessary. However, in symptomatic patients, further evaluation and surgical consultation may be indicated.⁴ Correct identification of these anatomic variants is important to avoid misidentifying a thickened wall as pathologic in an otherwise normal gallbladder.^{3,4}

Documented patient informed consent and/or Institutional Review Board approval has been obtained and filed for publication of this case report.

Address for Correspondence: Divya Mohan, DO, Jefferson Northeast, Department of Emergency Medicine, 108000 Knights Rd, Philadelphia, PA 19114. Email: dxm289@jefferson.edu.

Conflicts of Interest: By the CPC-EM article submission agreement, all authors are required to disclose all affiliations, funding sources and financial or management relationships that could be perceived as potential sources of bias. The authors disclosed none.

Copyright: © 2020 Adamski et al. This is an open access article distributed in accordance with the terms of the Creative Commons Attribution (CC BY 4.0) License. See: <http://creativecommons.org/licenses/by/4.0/>

CPC-EM Capsule

What do we already know about this clinical entity?

In a patient with right upper quadrant pain, it is important to distinguish a diseased gallbladder from a healthy one.

What is the major impact of the image(s)?

Correct identification of two anatomic variants in the gallbladder, Phrygian cap and pseudo-duplication, will help determine whether or not a gallbladder is diseased.

How might this improve emergency medicine practice?

Using ultrasound to identify normal anatomy and anatomic variants aids in distinguishing a diseased versus a healthy gallbladder and determining appropriate treatment.

REFERENCES

1. Kannan N, Kannan U, Ganesh Babu C. Congenital bilobed gallbladder with Phrygian cap presenting as calculus cholecystitis. *J Clin and Diagn Research*. 2014;8(8):ND05-6.
2. Dalal S, Chauhan T, Kumar R, et al. Pseudo-duplication of the gall bladder due to Phrygian cap: a case report. *Internet J Surg*. 2013;29(1):1-3.
3. Meilstrup JW, Hopper KD, Thieme GA. Imaging of gallbladder variants. *AJR Am J Roentgenol*. 1991;157(6):1205-8.
4. Van Kamp MJSV, Bouman DE, Steenvoorde P, et al. A Phrygian cap. *Case Rep in Gastro*. 2013;7(2):347-51.

New Reduction Technique for Traumatic Posterior Glenohumeral Joint Dislocations

Morteza Khodaei, MD, MPH

University of Colorado School of Medicine, Department of Family Medicine and Orthopedics, Division of Sports Medicine, Denver, Colorado

Section Editor: Scott Goldstein, MD

Submission history: Submitted August 1, 2019; Revision received November 16, 2019; Accepted November 17, 2019

Electronically published January 24, 2020

Full text available through open access at http://escholarship.org/uc/uciem_cpccem

DOI: 10.5811/cpcem.2019.11.44790

Traumatic posterior glenohumeral joint (GHJ) dislocation is a rare condition which can be missed if it is not suspected. Clinical presentation may be subtle, but limitation in range of motion in patient with acute trauma should warrant obtaining a thorough history, performing a comprehensive physical examination, and acquiring at least a 3-view plain radiography. Reduction can be achieved with a direct pressure to the posterior aspect of the humeral head. [Clin Pract Cases Emerg Med. 2020;4(1):105–106.]

CASE PRESENTATION

A 44-year-old male presented at a ski clinic shortly after a fall directly onto his right shoulder while skiing. He was unable to move his right arm due to pain. His past medical history was significant for right shoulder dislocation about 25 years earlier. He did not recall the type of dislocation he suffered at that time. He did not undergo any surgeries. He had an active lifestyle and denied experiencing any other shoulder injuries since then. On physical examination, he was holding his right arm in an adducted and internally rotated position. He had a subtle deformity (sulcus sign) in his right shoulder. The patient was unable to tolerate a passive abduction due to the pain. His neurovascular examination was normal. Plain radiography revealed posterior glenohumeral joint (GHJ) dislocation (Image 1). We reduced his posterior GHJ dislocation using direct pressure to the posterior aspect of his humeral head in a sitting position without any analgesics (Image 2 and Video). Reduction was confirmed by post-reduction radiographs (Image 1).

DISCUSSION

Most posterior GHJ dislocations are atraumatic (e.g., seizures and electrocutions).^{1,2} Traumatic posterior GHJ dislocations account for less than 1% of all GHJ dislocations.^{2,3} Due to subtle clinical presentations, particularly among the elderly with atraumatic etiology, and subtle signs on plain radiography, up to 80% of these dislocations are misdiagnosed for months.¹⁻³ If the dislocation is not obvious on AP, AP oblique (Grashey), and lateral (scapular Y) radiography views,

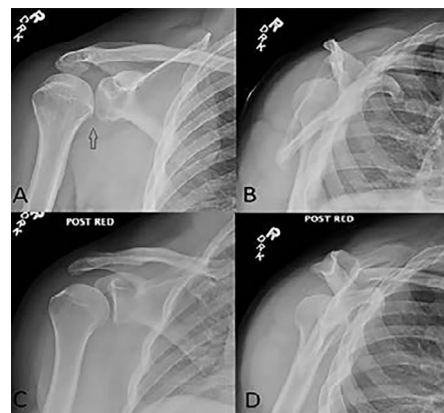


Image 1. Right shoulder plain radiography reveals posterior glenohumeral dislocation (arrow) on AP (A) and scapular Y (B) views. Post-reduction Grashey (C) and scapular Y (D) views confirmed the reduction. No fracture is present on these images.

an axillary (or at least a Velpeau axillary) view should be obtained.^{2,4} As the majority of patients with posterior GHJ dislocation are diagnosed late, reduction usually requires conscious sedation or general anesthesia.¹⁻³

There is a gap in the literature on the management of acute traumatic posterior GHJ dislocations.^{2,3} Similar or modified reduction techniques for anterior GHJ dislocation are recommended for acute traumatic posterior GHJ.^{1,4} Most of these recommended techniques involve longitudinal traction, forward

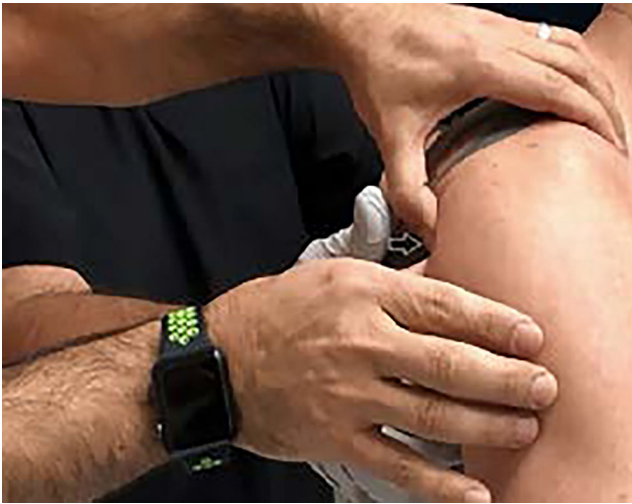

Image 2. Reduction of the posterior glenohumeral dislocation with anteriorly directed pressure to the posterior humeral head (arrow).

flexion, and internal and external rotation of the shoulder.¹⁻⁵ The humeral head is more palpable and more superficial in patients with posterior GHJ dislocations compared to patients with anterior GHJ dislocations. It seems that significant anteriorly directed force can be transferred to the humeral head by applying direct pressure in patients with posterior GHJ dislocations. To the best of our knowledge, this is the first time that direct posterior pressure to the humeral head is applied alone. However, anteriorly directed pressure to the humeral head in conjunction with longitudinal tractions, and internal and external rotations have been recommended previously.^{1,2,5} This technique requires minimum patient cooperation. Large studies are required to evaluate the effectiveness of this technique for patients with acute traumatic posterior GHJ dislocations.

Video. Reduction of the posterior glenohumeral dislocation with anteriorly directed pressure to the posterior humeral head (arrow).

Documented patient informed consent and/or Institutional Review Board approval has been obtained and filed for publication of this case report.

REFERENCES

1. Benninger E and Jost B. (2015). Glenohumeral dislocations. In: Browner BD (5th ed.), *Skeletal Trauma (1454-82)*. Philadelphia, PA: Elsevier Saunders.
2. Rouleau DM, Hebert-Davies J, Robinson CM. Acute traumatic posterior shoulder dislocation. *J Am Acad Orthop Surg*. 2014;22(3):145-52.
3. Cicak N. Posterior dislocation of the shoulder. *J Bone Joint Surg Br*. 2004;86(3):324-32.
4. Khodae M, Vidal A, Gutierrez G. Dimple on the shoulder after a ski injury. *Emerg Med J*. 2017;34(11):740.
5. Kowalsky MS and Levine WN. Traumatic posterior glenohumeral dislocation: classification, pathoanatomy, diagnosis, and treatment. *Orthop Clin North Am*. 2008;39(4):519-33, viii.

CPC-EM Capsule

What do we already know about this clinical entity?

Traumatic posterior glenohumeral joint (GHJ) dislocation is rare. Unless clinically suspected, there may be a significant delay in diagnosis and management of a traumatic posterior GHJ dislocation.

What is the major impact of the image(s)?

The image and the video show how you can attempt this new technique.

How might this improve emergency medicine practice?

The new proposed technique may improve the reduction procedure by decreasing the numbers of the attempts and eliminating the need for pre-procedural sedation.

Address for Correspondence: Morteza Khodae, MD, MPH, University of Colorado School of Medicine, Department of Family Medicine and Orthopedics, Division of Sports Medicine, AFW Clinic, 3055 Roslyn Street, Denver, CO 80238 Email: morteza.khodae@cuanschutz.edu.

Conflicts of Interest: By the CPC-EM article submission agreement, all authors are required to disclose all affiliations, funding sources and financial or management relationships that could be perceived as potential sources of bias. The authors disclosed none.

Copyright: © 2020 Khodae. This is an open access article distributed in accordance with the terms of the Creative Commons Attribution (CC BY 4.0) License. See: <http://creativecommons.org/licenses/by/4.0/>

Point-of-care Ultrasound Diagnosis of Emphysematous Cholecystitis

Fadwa Al Hammadi, MBBS*
Rasha Buhumaid, MBBS†

*Sheikh Khalifa Medical City, Department of Emergency Medicine, Abu Dhabi, United Arab Emirates

†Mohammed Bin Rashid University of Medicine and Health Sciences, Department of Emergency Medicine, Dubai, United Arab Emirates

Section Editor: Rick A. McPheeters, DO

Submission history: Submitted September 26, 2019; Revision received November 3, 2019; Accepted November 18, 2019

Electronically published January 23, 2020

Full text available through open access at http://escholarship.org/uc/uciem_cpem

DOI: 10.5811/cpcem.2019.11.45337

A 49-year-old male presented to the emergency department with abdominal pain and generalized weakness. The physical examination was positive for right upper quadrant tenderness and positive Murphy's sign. Point-of-care biliary ultrasound revealed signs of emphysematous cholecystitis. Emphysematous cholecystitis is a rare biliary pathology with a high mortality rate. It differs from acute cholecystitis in many ways. It has unique ultrasound characteristics. This case highlights the use of point-of-care ultrasound to diagnose a rare biliary condition. [Clin Pract Cases Emerg Med. 2020;4(1):107–108.]

CASE PRESENTATION

A 49-year-old man presented to the emergency department with epigastric abdominal pain. He was known to have multiple myeloma and was on chemotherapy; he also had a mass in the head of the pancreas, which required endoscopic retrograde cholangiopancreatography and stenting one month prior to this presentation. He was hypotensive and tachycardic. Abdominal exam revealed right upper quadrant tenderness and a positive Murphy's sign. Point-of-care biliary ultrasound revealed gallstones, pericholecystic fluid, and punctate hyperechoic foci in the lumen of the gallbladder (Video). Computed tomography revealed a distended gallbladder with intraluminal gas extending into the inferior surface of the liver (Image). The patient underwent percutaneous cholecystostomy. The bile culture grew the gram-negative bacterium *Prevotella buccae*.

DISCUSSION

Emphysematous cholecystitis (EC) is diagnosed by the presence of gas in the lumen or the wall of the gallbladder in the setting of acute cholecystitis. It is a rare biliary pathology with a high mortality rate.¹ EC differs from acute cholecystitis in many ways. It is more common in men and diabetics, and one third of the cases are not associated with cholelithiasis.² It is thought to be due to an ischemic event followed by an infection with gas-forming bacteria.

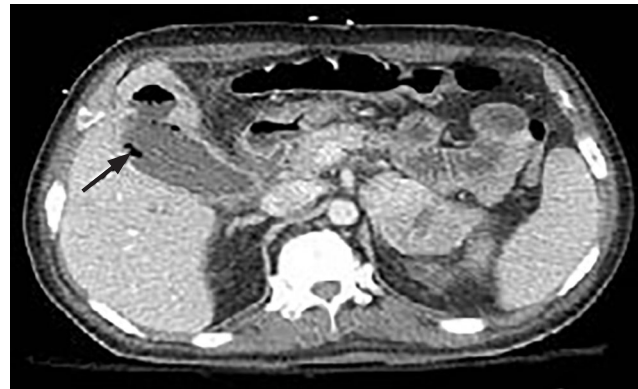


Image. Computerized tomography scan identified distended gallbladder with intraluminal gas (black arrow).

The causative organism identified in this case is rare. The most common bacteria associated with this condition are *Clostridium* species, *Escherichia coli*, *Klebsiella* species, and anaerobic streptococci.¹

The appearance of EC on ultrasound differs depending on the amount of gas in the gallbladder. A small amount of gas will produce echogenic foci with reverberation artifact known as ring-down artifact. However, a large amount of gas will produce a band with posterior dirty shadowing.³⁻⁴

Gas can also form multiple echogenic foci that move from the dependent to the independent area within the lumen of the gallbladder, also known as “effervescent gallbladder” or the “champagne” sign.⁴ Computed tomography is more sensitive and specific for the diagnosis of this condition.⁵ EC is a surgical emergency that is managed with intravenous antibiotics and cholecystectomy. Alternatively, percutaneous cholecystostomy is used in patients who are high risk for surgery.⁵

Video. Point-of-care biliary ultrasound identifying gallstones (white arrow), pericholecystic fluid (red arrow), and gas in the gallbladder lumen (green arrow).

Documented patient informed consent and/or Institutional Review Board approval has been obtained and filed for publication of this case report.

REFERENCES

1. Smith E, Dillman J, Elsayes K, et al. Cross-sectional imaging of acute and chronic gallbladder inflammatory disease. *Am J Roentgenol.* 2009;192(1):188-96.
2. Zippel D, Shapiro R, Goitein O, et al. Emphysematous cholecystitis: Don't be lulled into complacency. *J Emerg Med.* 2011;41(4):400-1.
3. Wexler B and Panebianco N. The effervescent gallbladder: an emergency medicine bedside ultrasound diagnosis of emphysematous cholecystitis. *Cureus.* 2017;9(7):e1520.
4. Safwan M and Penny S. Emphysematous cholecystitis. *J Diagn Med Sonogr.* 2016;32(3):131-7.
5. Huang H, Chuang C, Yang P. Abnormal gas in the gallbladder: emphysematous cholecystitis. *J Emerg Med.* 2013;45(2):254-5.

CPC-EM Capsule

What do we already know about this clinical entity?

Emergency physicians commonly perform biliary point-of-care ultrasound to identify gallstones and acute cholecystitis.

What is the major impact of the image(s)?

This case describes the use of point-of-care ultrasound to diagnose Emphysematous Cholecystitis (EC), highlighting the unique ultrasound characteristic of this condition.

How might this improve emergency medicine practice?

Using point-of-care ultrasound to diagnose EC (a rare condition with high mortality rate) could help accelerate the diagnosis and management.

Address for Correspondence: Rasha Buhumaid, MBBS, Mohammed Bin Rashid University of Medicine and Health Sciences, College of Medicine, Building 14, Dubai Healthcare City, PO Box 505055, Dubai, United Arab Emirates. Email: Rasha.buhumaid@mbru.ac.ae.

Conflicts of Interest: By the CPC-EM article submission agreement, all authors are required to disclose all affiliations, funding sources and financial or management relationships that could be perceived as potential sources of bias. The authors disclosed none.

Copyright: © 2020 Al Hammadi et al. This is an open access article distributed in accordance with the terms of the Creative Commons Attribution (CC BY 4.0) License. See: <http://creativecommons.org/licenses/by/4.0/>

Pseudoatrial Flutter: When the Problem Lies Outside the Heart

Samuele Ceruti, MD*
 Marco Spagnoletti, MD†
 Romano Mauri, MD†

*Hôpitaux Universitaires de Genève, Department of Intensive Care, Genève, Switzerland
 †Clinica Luganese, Via Moncucco, Department of Emergency Medicine, Lugano, Switzerland

Section Editor: Rick A. McPheeters, DO

Submission history: Submitted July 28, 2019; Revision received October 9, 2019; Accepted November 25, 2019

Electronically published January 23, 2020

Full text available through open access at http://escholarship.org/uc/uciem_cpem

DOI: 10.5811/cpcem.2019.11.44665

Electrocardiogram (ECG) artifacts are a common problem in emergency medicine. Generally these artifacts are induced by movement disorders, which generate electrical interference with the ECG recording. If these disorders are not promptly recognized, consequences can lead to hospitalization and execution of unnecessary diagnostic tests, thereby increasing the costs and clinical risks such as nosocomial infections and thromboembolism. We present a pseudoatrial flutter generated by a Parkinson's-like movement. [Clin Pract Cases Emerg Med. 2020;4(1):109–110.]

CASE PRESENTATION

A 72-year-old woman presented to the emergency department with chest pain for several days, not associated with dyspnea or other symptoms. She reported that similar symptoms had occurred in the past. The patient was quickly assessed with the performance of an electrocardiogram (ECG), which demonstrated the following tracing (Image).

After a first suspicion of a paroxysmal atrial flutter, it was noted that precordial “pseudo F” waves were really broad in

amplitude, while a sinus rhythm was maintained in lead three. Moreover, even with the disappearance of the “pseudo F” waves, it was also noted that the QRS complexes remained regular between the suspected “flutter phase” and the “sinus phase,” without any compensatory pauses or changes in heart rate. An artifact ECG was likely: the lack of “pseudo F” waves in lead three increased the probability of artifact involving the right peripheral electrode, thus saving lead three, which analyzes only the electrode of the left foot.

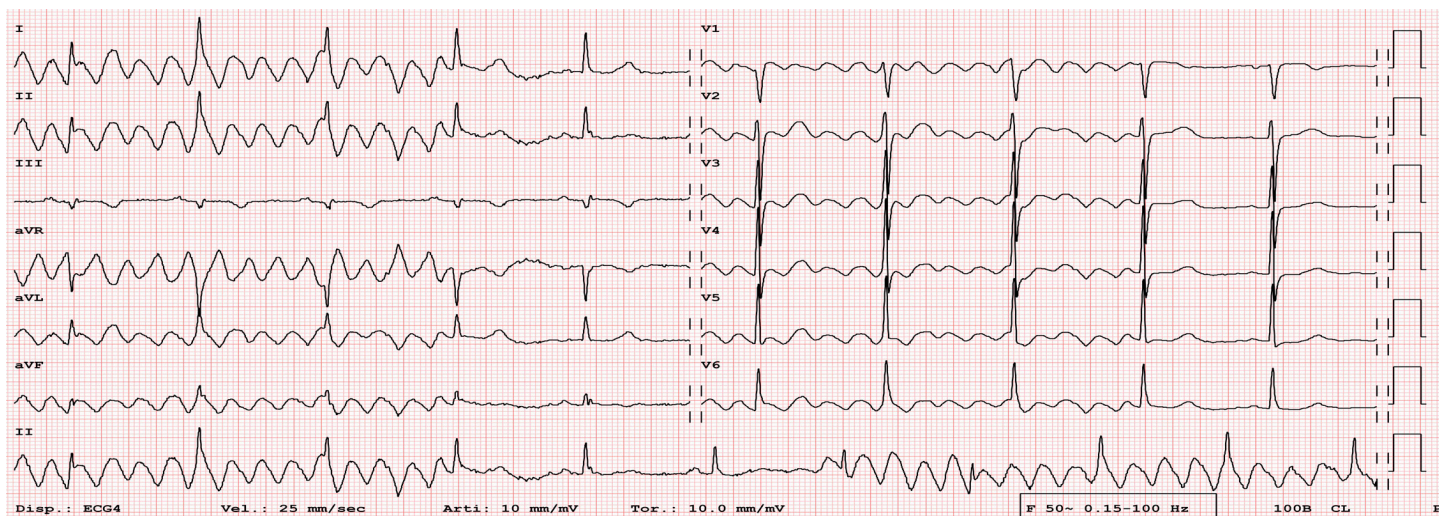


Image. Patient's artifact electrocardiogram showing pseudoatrial flutter. Note regular maintenance of QRS complexes between the suspected “flutter phase” (arrowheads) and the “sinus phase”; moreover, lead three demonstrated continuous sinus rhythm (arrows).

A new ECG recording was performed by the physician verifying electrode placement, and it revealed the appearance of artifacts quite similar to the previous one. Again, pseudo-F waves were noted in all leads except for lead three (not shown), although this signal was larger and not completely identical to the previous one recorded. At the end of this recording, the clinicians noted a slight rhythmic tremor resembling Parkinsonism at 5-6 hertz in the right arm, which was thought to be responsible for the recorded electrical signal (Video).

DISCUSSION

ECG artifacts are common in emergency situations, especially among patients with movement disorders such as Parkinsonism,^{1,2} simulating some arrhythmias such as atrial flutter.^{3,4} The role of a clinician is to identify these anomalies and promptly look for extra-cardiac conditions,⁵⁻⁶ to avoid any inappropriate and potentially dangerous consequences such as hospitalization, risk of infection, use of unnecessary diagnostic tests and procedures, and increased patient anxiety.⁶ The patient's symptoms were ultimately found to be non-cardiac in nature and she was subsequently discharged home in improved clinical status.

Video. Patient's right arm Parkinsonism, noted just after electrocardiographic recording, was responsible for the artifact electrocardiogram.

Documented patient informed consent and/or Institutional Review Board approval has been obtained and filed for publication of this case report.

REFERENCES

1. Nam MC, Best L, Greaves K, et al. Global pseudo-atrial flutter ECG appearance secondary to unilateral parkinsonian tremor. *BMJ Case Rep.* 2016;2016. pii:bcr2015214048.
2. Hwang WJ, Chen JY, Sung PS, et al. Parkinsonian tremor-induced electrocardiographic artifacts mimicking atrial flutter/fibrillation or ventricular tachycardia. *Int J Cardiol.* 2014;173(3):597-600.
3. Barrett CD, Kelly PJ, Halley C, et al. Pseudo atrial flutter. *Eur J Intern Med.* 2007;18(8):603-4.
4. Knight BP, Pelosi F, Michaud GF, et al. Physician interpretation of electrocardiographic artifact that mimics ventricular tachycardia. *Am J Med.* 2001;110(5):335-8.
5. Vanerio G. Tremor as a cause of pseudoatrial flutter. *Am J Geriatr Cardiol.* 2007;16(2):106-8.
6. Nolan NS, Koerber SR, Balla S. Pseudoatrial flutter waves -- when a flutter is not a flutter. *JAMA Intern Med.* 2016;176(3):298-9.

CPC-EM Capsule

What do we already know about this clinical entity?

Electrocardiogram (ECG) artifacts are common in emergency situations, especially among patients with movement disorders.

What is the major impact of the image(s)?

In analyzing the ECG, it is possible to trace the lead affected by the artifact and identify a movement disorder.

How might this improve emergency medicine practice?

The clinician's role is to identify these anomalies in order to avoid dangerous consequences such as hospitalization and unnecessary diagnostic procedures.

Address for Correspondence: Samuele Ceruti, MD, Hôpitaux Universitaires de Genève, Department of Intensive Care, Rue Gabrielle-Perret-Gentil 4, 1205 Genève, CH. Email: samuele.ceruti@me.com.

Conflicts of Interest: By the *CPC-EM* article submission agreement, all authors are required to disclose all affiliations, funding sources and financial or management relationships that could be perceived as potential sources of bias. The authors disclosed none.

Copyright: © 2020 Ceruti et al. This is an open access article distributed in accordance with the terms of the Creative Commons Attribution ([CC BY 4.0](http://creativecommons.org/licenses/by/4.0/)) License. See: <http://creativecommons.org/licenses/by/4.0/>



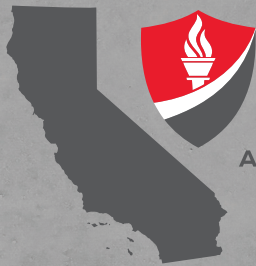39TH ANNUAL
**MAMMOTH MOUNTAIN
EMERGENCY MEDICINE
CONFERENCE**

MARCH 2-5, 2020

www.MammothEM.com

This activity has been approved for *AMA PRA Category 1 Credits*

**JOIN
CAL/AAEM!**



CALAAEM

CALIFORNIA CHAPTER DIVISION OF THE
AMERICAN ACADEMY OF EMERGENCY MEDICINE

*Championing
individual physician rights
and workplace fairness*

BENEFITS

- *Western Journal of Emergency Medicine* Subscription
- CAL/AAEM News Service email updates
- Discounted AAEM pre-conference fees
- And more!

CAL/AAEM NEWS SERVICE

- Healthcare industry news
- Public policy
- Government issues
- Legal cases and court decisions

In collaboration with our official journal

WestJEM Integrating Emergency Care
with Population Health



[FACEBOOK.COM/CALAAEM](https://www.facebook.com/CALAAEM)



FOLLOW US @CALAAEM

[HTTP://WWW.CALAAEM.ORG](http://www.calaaem.org)



2020 LEGISLATIVE LEADERSHIP CONFERENCE

JOIN CALIFORNIA ACEP IN SACRAMENTO
TO ADVOCATE ON BEHALF OF YOUR
PATIENTS AND YOUR PRACTICE!

APRIL 14, 2020

WWW.
CALIFORNIA
ACEP.ORG