

# A Case of COVID-19 Pneumonia in a Young Male with Full Body Rash as a Presenting Symptom

Madison Hunt, MD  
Christian Koziatek, MD

New York University School of Medicine, Department of Emergency Medicine, New York, New York  
Bellevue Hospital Center, Department of Emergency Medicine, New York, New York

Section Editor: Rick A. McPheeters, DO

Submission history: Submitted March 21, 2020; Revision received March 25, 2020; Accepted March 25, 2020

Electronically published March 28, 2020

Full text available through open access at [http://escholarship.org/uc/uciem\\_cpem](http://escholarship.org/uc/uciem_cpem)

DOI: 10.5811/cpem.2020.3.47349

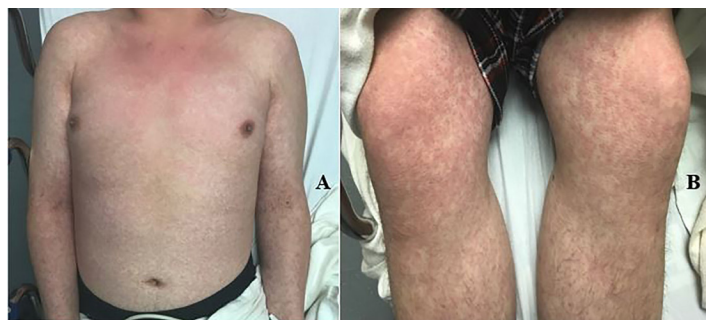**Background:** In December 2019 the coronavirus disease of 2019 (COVID-19), caused by the severe acute respiratory syndrome coronavirus 2, was identified in Wuhan, China. In the ensuing months, the COVID-19 pandemic has spread globally and case load is exponentially increasing across the United States. Emergency departments have adopted screening and triage procedures to identify potential cases and isolate them during evaluation.

**Case Presentation:** We describe a case of COVID-19 pneumonia requiring hospitalization that presented with fever and extensive rash as the primary presenting symptoms. Rash has only been rarely reported in COVID-19 patients, and has not been previously described. [Clin Pract Cases Emerg Med. 2020;4(2):219–221.]

**Keywords:** COVID-19; coronavirus; rash.

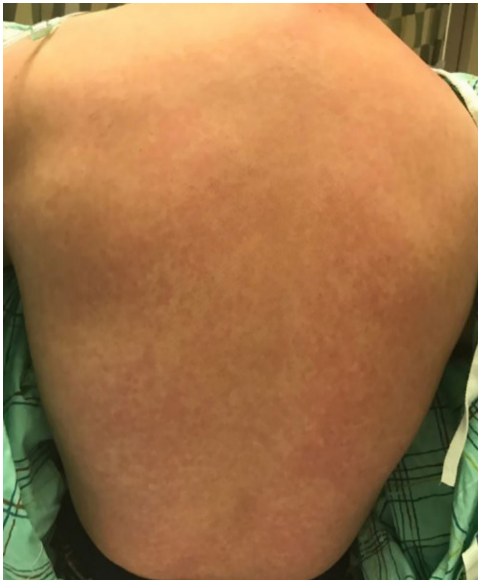## CASE PRESENTATION

A 20-year-old previously healthy male originally presented to an urgent care center with a chief complaint of fever and rash. He was diagnosed with a viral upper respiratory infection and sent home with supportive care. Six days later, the patient presented to the emergency department (ED) with continued fever and rash. Vital signs included a temperature of 103.0° Fahrenheit, heart rate 115 beats per minute, blood pressure 93/54 millimeters of mercury, respiratory rate 24 breaths per minute, and an oxygen saturation of 91%. Physical examination revealed a diffuse, morbilliform rash across the trunk and extremities, sparing the face (Images 1 and 2). There was no mucosal or ocular involvement. Chest radiograph revealed bilateral infiltrates consistent with multifocal pneumonia (Image 3). Labs included a normal leukocyte count (8300 units per liter [uL], reference range 4200-9100/uL) with an absolute lymphocyte count of 800/uL (reference range 1300-3600/uL). A C-reactive protein was elevated at 118.5 milligrams per liter (mg/L) (reference range 0-5 mg/L). A rapid strep test and an human immunodeficiency virus test were both negative, as was a respiratory viral panel. The patient required escalating



**Image 1.** Image of the anterior trunk and upper extremities (A) and anterior lower extremities (B) demonstrating a diffuse, morbilliform, maculopapular rash.

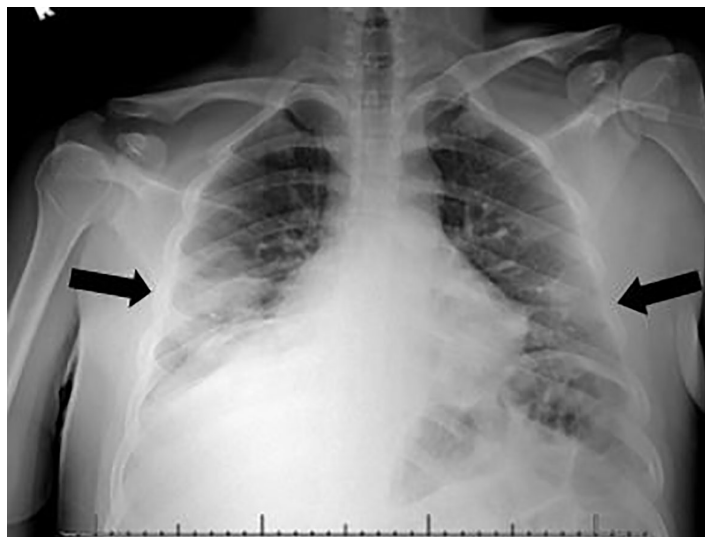
amounts of supplemental oxygen during his ED course and was admitted to the intensive care unit (ICU). A severe acute respiratory syndrome coronavirus 2 (SARS-CoV-2) polymerase chain reaction test resulted positive on hospital day two. The patient remains hospitalized in the ICU on hospital day six.



**Image 2.** Image of the posterior trunk similarly demonstrates a diffuse, maculopapular morbilliform rash.

**DISCUSSION**

We describe a case of COVID-19 pneumonia in a young, healthy male requiring hospitalization, which presented with fever and extensive rash. The rash was morbilliform, maculopapular, and nonpruritic, and appeared consistent with a viral exanthem. The clinical characteristics of COVID-19 have been described in several publications, most thoroughly in a case series of 1099 patients by Guan et al. Fever, cough, congestion, and dyspnea are the most common presenting symptoms. Only 2/1099 patients were noted to have any skin



**Image 3.** A chest radiograph demonstrating bilateral infiltrates consistent with bilateral multifocal pneumonia.

*CPC-EM Capsule*

What do we already know about this clinical entity?

*Coronavirus disease of 2019 (COVID-19) typically initially presents with symptoms similar to other viral respiratory infections, most commonly with fever, cough, fatigue, myalgias, and congestion.*

What is the major impact of the image(s)?

*This case describes a COVID-19 patient who presented with a full body rash, which is a rare presenting symptom in previous studies and has not been described previously in the literature.*

How might this improve emergency medicine practice?

*COVID-19 may rarely present with an associated morbilliform viral eruption and should not be discarded as a diagnostic possibility in patients with viral syndrome and rash.*

rash, and the rash was not described<sup>1</sup>; no other publications have noted or described skin manifestations as a presenting symptom.<sup>1-5</sup> Rash may be a rare presenting symptom of COVID-19 and should be kept in mind by front-line providers.

Documented patient informed consent has been obtained and filed for publication of this image in emergency medicine.

---

*Address for Correspondence:* Christian Koziatek, MD, New York University School of Medicine, Department of Emergency Medicine, 462 First Avenue, Room A340A, New York, NY 10016. Email: ckoziatek@gmail.com.

*Conflicts of Interest:* By the CPC-EM article submission agreement, all authors are required to disclose all affiliations, funding sources and financial or management relationships that could be perceived as potential sources of bias. The authors disclosed none.

*Copyright:* © 2020 Hunt et al. This is an open access article distributed in accordance with the terms of the Creative Commons Attribution (CC BY 4.0) License. See: <http://creativecommons.org/licenses/by/4.0/>

---

**REFERENCES**

1. Guan WJ, Ni ZY, Hu Y, et al. Clinical characteristics of coronavirus disease 2019 in China. *N Engl J Med*. 2020. In Press.
2. Xu XW, Wu XX, Jiang XG, et al. Clinical findings in a group of patients infected with the 2019 novel coronavirus (SARS-Cov-2) outside of Wuhan, China: Retrospective case series. *BMJ*. 2020;368:m606.
3. Shi H, Han X, Jiang N, et al. Radiological findings from 81 patients with COVID-19 pneumonia in Wuhan, China: a descriptive study. *Lancet Infect Dis*. 2020. In Press.
4. Zhou F, Yu T, Du R, et al. Clinical course and risk factors for mortality of adult inpatients with COVID-19 in Wuhan, China: a retrospective cohort study. *Lancet*. 2020;pii:S0140-6736(20)30566-3.
5. Wu Z and McGoogan JM. Characteristics of and important lessons from the coronavirus disease 2019 (COVID-19) outbreak in China: summary of a report of 72 314 cases from the Chinese Center for Disease Control and Prevention. *JAMA*. February 2020. In Press.