

CPC Emergency Medicine

Volume IV, Number 2, May 2020

Open Access at www.cpcem.org

ISSN: 2474-252X

Clinical Practice and Cases in Emergency Medicine

In Collaboration with the *Western Journal of Emergency Medicine*

Clinicopathological Cases from Maryland

- 111 **55-year-old Male with Exertional Dyspnea**
Friedman ER, Gatz JD, Bontempo LJ, ZDW Dezman

Clinicopathological Cases

- 116 **55-year-old Woman with Headache, Vomiting, and Visual Disturbance**
Shaker L, Ripper J, Murano T

Case Series

- 121 **Heroin Adulterated with the Novel Synthetic Cannabinoid 5F-MDMB-PINACA: A Case Series**
Ershad M, Cruz MD, Mostafa A, Khalid MM, Arnold R, Hamilton R

Case Reports

- 126 **Novel, Inexpensive Portable Respiratory Protection Unit (PRPU) for Healthcare Workers**
Sampson CS, Beckett A
- 129 **Early Multi-organ Point-of-Care Ultrasound Evaluation of Respiratory Distress During SARS-CoV-2 Outbreak: Case Report**
Farrow II R, Becherer-Bailey G, Mantuani D, Nagdev A
- 134 **Urethral Calculi**
Lee P, Haber J
- 137 **An Early Holiday Surprise: Cholecystitis Wrapped in Takotsubo Cardiomyopathy**
Gould K, Miller S, Moll J
- 142 **Acute Jaundice in a Six-year-old: An Unusual Presentation of Atypical Kawasaki Disease**
Bylund LCDR W, Zarow GJ, Ponce LCDR DM
- 146 **Topical Tranexamic Acid for Hemostasis of an Oral Bleed in a Patient on a Direct Oral Anticoagulant**
Boccio E, Hultz K, Wong AH
- 150 **The Ultimate Poker Face: A Case Report of Facial Diplegia, a Guillain-Barré Variant**
Lowe J, Pfaff J

Contents continued on page iii



UC Irvine Health





**ACOEP stands with all emergency
physicians and providers on the
front line. We thank you for your
tireless work and effort.**



The American College of
Osteopathic Emergency Physicians

www.acoep.org

Clinical Practice and Cases in Emergency Medicine

Indexed in PubMed and full text in PubMed Central

Rick A. McPheeters, DO, Editor-in-Chief
Kern Medical/UCLA- Bakersfield, California

Manish Amin, DO, Associate Editor
Kern Medical/UCLA- Bakersfield, California

Mark I. Langdorf, MD, MHPE, Associate Editor
University of California, Irvine School of Medicine- Irvine, California

Shadi Lahham, MD, MS, Associate Editor
University of California, Irvine School of Medicine- Irvine, California

Shahram Lotfipour, MD, MPH, Managing Associate Editor
University of California, Irvine School of Medicine- Irvine, California

Anna McFarlin, MD, Section Editor
Louisiana State University Health Science Center- New Orleans, Louisiana

Austin Smith, MD, Section Editor
Vanderbilt University Medical Center-Nashville, Tennessee

Christopher Sampson, MD, Section Editor
University of Missouri- Columbia, Missouri

Joel Moll, MD, Section Editor
Virginia Commonwealth University School of Medicine- Richmond, Virginia

Scott Goldstein, DO, Section Editor
Sidney Kimmel College of Medicine- Philadelphia, Pennsylvania

Steven Walsh, MD, Section Editor
Einstein Medical Center Philadelphia-Philadelphia, Pennsylvania

John Ashurst, DO, Section Editor
Kingman Regional Health Network, Arizona

Melanie Heniff, MD, Section Editor
University of Indiana School of Medicine- Indianapolis, Indiana

Editorial Board

Amin A. Kazzi, MD, MAAEM
The American University of Beirut, Beirut,
Lebanon

Anwar Al-Awadhi, MD
Mubarak Al-Kabeer Hospital, Jabriya,
Kuwait

Arif A. Cevik, MD
United Arab Emirates University
College of Medicine and Health Sciences, Al
Ain, United Arab Emirates

Abhinandan A. Desai, MD
University of Bombay Grant Medical
College, Bombay, India

Bandr Mzahim, MD
King Fahad Medical City, Riyadh, Saudi
Arabia

Barry E. Brenner, MD, MPH
Case Western Reserve University

Brent King, MD, MMM
University of Texas, Houston

Daniel J. Dire, MD
University of Texas Health Sciences Center
San Antonio

David F.M. Brown, MD
Massachusetts General Hospital/Harvard
Medical School

Edward Michelson, MD
Texas Tech University

Edward Panacek, MD, MPH
University of South Alabama

Erik D. Barton, MD, MBA
Icahn School of Medicine, Mount Sinai,
New York

Francesco Dellacorte, MD
Azienda Ospedaliera Universitaria "Maggiore
della Carità," Novara, Italy

Francis Counselman, MD
Eastern Virginia Medical School

Gayle Galleta, MD
Sorlandet Sykehus HF, Akershus
Universitetssykehus, Lorenskog, Norway

Hjalte Björnsson, MD
Icelandic Society of Emergency Medicine

Jacob (Kobi) Peleg, PhD, MPH
Tel-Aviv University, Tel-Aviv, Israel

Jonathan Olshaker, MD
Boston University

Katsuhiko Kanemaru, MD
University of Miyazaki Hospital, Miyazaki, Japan

Khrongwong Musikatavorn, MD
King Chulalongkorn Memorial Hospital,
Chulalongkorn University, Bangkok, Thailand

Leslie Zun, MD, MBA
Chicago Medical School

Linda S. Murphy, MLIS
University of California, Irvine School of
Medicine Librarian

Nadeem Qureshi, MD
St. Louis University, USA
Emirates Society of Emergency Medicine,
United Arab Emirates

Niels K. Rathlev, MD
Tufts University School of Medicine

Pablo Aguilera Fuenzalida, MD
Pontificia Universidad Católica de Chile,
Región Metropolitana, Chile

Peter A. Bell, DO, MBA
Liberty University
College of Osteopathic Medicine

Peter Sokolove, MD
University of California, San Francisco

Robert M. Rodriguez, MD
University of California, San Francisco

Robert Suter, DO, MHA
UT Southwestern Medical Center

Robert W. Derlet, MD
University of California, Davis

Rosidah Ibrahim, MD
Hospital Serdang, Selangor, Malaysia

Samuel J. Stratton, MD, MPH
Orange County, CA, EMS Agency

Scott Rudkin, MD, MBA
University of California, Irvine

Scott Zeller, MD
University of California, Riverside

Steven Gabaeff, MD
Clinical Forensic Medicine

Steven H. Lim, MD
Changi General Hospital, Simei, Singapore

Terry Mulligan, DO, MPH, FIFEM
ACEP Ambassador to the Netherlands Society of
Emergency Physicians

Vijay Gautam, MBBS
University of London, London, England

Wirachin Hoonpongmanont, MD, MSBATS
Siriraj Hospital, Mahidol University, Bangkok,
Thailand

Advisory Board

Amal Khalil, MBA
UC Irvine Health School of Medicine

Elena Lopez-Gusman, JD
California ACEP
American College of Emergency Physicians

Adam Levy, BS
American College of Osteopathic Emergency
Physicians

John B. Christensen, MD
California Chapter Division of AAEM

Lori Winston, MD
California ACEP
American College of Emergency Physicians
Kaweah Delta Healthcare District

Mark I. Langdorf, MD, MHPE
UC Irvine Health School of Medicine

Jorge Fernandez, MD
California ACEP
American College of Emergency Physicians
University of California, San Diego

Peter A. Bell, DO, MBA
American College of Osteopathic Emergency
Physicians
Liberty University, College of Osteopathic Medicine

Robert Suter, DO, MHA
American College of Osteopathic Emergency
Physicians
UT Southwestern Medical Center

Shahram Lotfipour, MD, MPH
UC Irvine Health School of Medicine

Brian Potts, MD, MBA
California Chapter Division of AAEM
Alta Bates Summit-Berkeley Campus

Editorial Staff

Leila Danishgar, BS
Editorial Director

Joseph Bui, BS
CPC-EM Associate Editorial Director

Maria Nguyen, BS
WestJEM Associate Editorial Director

Tushank Chadha, BS
Marketing Director to Media and
Communications Director

Alissa Fiorentino, BA
WestJEM Staff Liaison

Cassandra Saucedo, BS
CPC-EM Publishing Director

Argineh Shahbandari, BS
CPC-EM Associate Publishing Director

Dana Le, BS
WestJEM Publishing Director

Christine Louis, BS
WestJEM Associate Publishing Director

June Casey, BA
Copy Editor

Official Journal of the California Chapter of the American College of Emergency Physicians, the American College of Osteopathic Emergency Physicians, and the California Chapter of the American Academy of Emergency Medicine



Available in MEDLINE, PubMed, PubMed Central, Google Scholar, eScholarship, DOAJ, and OASPA.

Editorial and Publishing Office: WestJEM/Department of Emergency Medicine, UC Irvine Health, 333 City Blvd, West, Rt 128-01, Orange, CA 92866, USA

Office: 1-714-456-6389; Email: Editor@westjem.org

Clinical Practice and Cases in Emergency Medicine

Indexed in PubMed and full text in PubMed Central

This open access publication would not be possible without the generous and continual financial support of our society sponsors, department and chapter subscribers.

Professional Society Sponsors

AMERICAN COLLEGE OF OSTEOPATHIC EMERGENCY PHYSICIANS
CALIFORNIA ACEP

CALIFORNIA CHAPTER DIVISION OF
AMERICAN ACADEMY OF EMERGENCY MEDICINE

Academic Department of Emergency Medicine Subscribers

Albany Medical College Albany, NY	INTEGRIS Health Oklahoma City, OK	Robert Wood Johnson University Hospital New Brunswick, NJ	University of Florida, Jacksonville Jacksonville, FL
American University of Beirut Beirut, Lebanon	Kaweah Delta Health Care District Visalia, CA	Rush University Medical Center Chicago, IL	University of Illinois at Chicago Chicago, IL
Arrowhead Regional Medical Center Colton, CA	Kennedy University Hospitals Turnersville, NJ	Southern Illinois University Carbondale, IL	University of Illinois College of Medicine Peoria, IL
Augusta University Augusta GA	Kern Medical Bakersfield, CA	St. Luke's University Health Network Bethlehem, PA	University of Iowa Iowa City, IA
Baystate Medical Center Springfield, MA	Lakeland HealthCare St. Joseph, MI	Stanford/Kaiser Emergency Medicine Residency Program Stanford, CA	University of Louisville Louisville, KY
Beaumont Hospital Royal Oak, MI	Lehigh Valley Hospital and Health Network Allentown, PA	Staten Island University Hospital Staten Island, NY	University of Maryland Baltimore, MD
Beth Israel Deaconess Medical Center Boston, MA	Loma Linda University Medical Center Loma Linda, CA	SUNY Upstate Medical University Syracuse, NY	University of Michigan Ann Arbor, MI
Boston Medical Center Boston, MA	Louisiana State University Health Sciences Center New Orleans, LA	Temple University Philadelphia, PA	University of Missouri, Columbia Columbia, MO
Brigham and Women's Hospital Boston, MA	Madigan Army Medical Center Tacoma, WA	Texas Tech University Health Sciences Center El Paso, TX	University of Nebraska Medical Center Omaha, NE
Brown University Providence, RI	Maimonides Medical Center Brooklyn, NY	University of Alabama, Birmingham Birmingham, AL	University of South Alabama Mobile, AL
Carl R. Darnall Army Medical Center Fort Hood, TX	Maricopa Medical Center Phoenix, AZ	University of Arkansas for Medical Sciences Little Rock, AR	University of Southern California/Keck School of Medicine Los Angeles, CA
Conemaugh Memorial Medical Center Johnstown, PA	Massachusetts General Hospital Boston, MA	University of California, Davis Medical Center Sacramento, CA	University of Tennessee, Memphis Memphis, TN
Desert Regional Medical Center Palm Springs, CA	Mayo Clinic College of Medicine Rochester, MN	University of California Irvine Orange, CA	University of Texas, Houston Houston, TX
Doctors Hospital/Ohio Health Columbus, OH	Mt. Sinai Medical Center Miami Beach, FL	University of California, Los Angeles Los Angeles, CA	University of Texas Health San Antonio, TX
Eastern Virginia Medical School Norfolk, VA	North Shore University Hospital Manhasset, NY	University of California, San Diego La Jolla, CA	University of Warwick Library Coventry, United Kingdom
Einstein Healthcare Network Philadelphia, PA	Northwestern Medical Group Chicago, IL	University of California, San Francisco San Francisco, CA	University of Washington Seattle, WA
Emory University Atlanta, GA	Ohio State University Medical Center Columbus, OH	UCSF Fresno Center Fresno, CA	University of Wisconsin Hospitals and Clinics Madison, WI
Genesys Regional Medical Center Grand Blanc, Michigan	Ohio Valley Medical Center Wheeling, WV	University of Chicago, Chicago, IL	Wake Forest University Winston-Salem, NC
Hartford Hospital Hartford, CT	Oregon Health and Science University Portland, OR	University of Colorado, Denver Denver, CO	Wright State University Dayton, OH
Hennepin County Medical Center Minneapolis, MN	Penn State Milton S. Hershey Medical Center Hershey, PA	University of Florida Gainesville, FL	
Henry Ford Hospital Detroit, MI	Presence Resurrection Medical Center Chicago, IL		

State Chapter Subscribers

ARIZONA CHAPTER DIVISION OF THE
AMERICAN ACADEMY OF EMERGENCY MEDICINE
CALIFORNIA CHAPTER DIVISION OF THE
AMERICAN ACADEMY OF EMERGENCY MEDICINE
FLORIDA CHAPTER DIVISION OF THE
AMERICAN ACADEMY OF EMERGENCY MEDICINE

GREAT LAKES CHAPTER DIVISION OF THE
AMERICAN ACADEMY OF EMERGENCY MEDICINE
TENNESSEE CHAPTER DIVISION OF THE
AMERICAN ACADEMY OF EMERGENCY MEDICINE

UNIFORMED SERVICES CHAPTER DIVISION OF THE
AMERICAN ACADEMY OF EMERGENCY MEDICINE
VIRGINIA CHAPTER DIVISION OF THE
AMERICAN ACADEMY OF EMERGENCY MEDICINE

International Society Partners

EMERGENCY MEDICINE ASSOCIATION OF TURKEY
LEBANESE ACADEMY OF EMERGENCY MEDICINE
MEDITERRANEAN ACADEMY OF EMERGENCY MEDICINE

NORWEGIAN SOCIETY FOR EMERGENCY MEDICINE
SOCIEDAD ARGENTINA DE EMERGENCIAS

SOCIEDAD CHILENO MEDICINA URGENCIA
THAI ASSOCIATION FOR EMERGENCY MEDICINE

To become a *WestJEM* departmental sponsor, waive article processing fee, receive print and copies for all faculty and electronic for faculty/residents, and free CME and faculty/fellow position advertisement space, please go to <http://westjem.com/subscribe> or contact:

Alissa Fiorentino
WestJEM Staff Liaison
Phone: 1-800-884-2236
Email: sales@westjem.org

JOURNAL FOCUS

Clinical Practice and Cases in Emergency Medicine (CPC-EM) is a MEDLINE-indexed internationally recognized journal affiliated with the *Western Journal of Emergency Medicine* (WestJEM). It offers the latest in patient care case reports, images in the field of emergency medicine and state of the art clinicopathological and medicolegal cases. CPC-EM is fully open-access, peer reviewed, well indexed and available anywhere with an internet connection. CPC-EM encourages submissions from junior authors, established faculty, and residents of established and developing emergency medicine programs throughout the world.

Table of Contents *continued*

- 154 Ruptured Coronary Sinus of Valsalva in the Setting of a Supracristal Ventricular Septal Defect**
A Arrascaeta-Llanes, A Kashyap, D Meyler, R Gupta, Z Tharayil, W Khan
- 158 False Elevation of Volume Determined by Bladder Scanner Secondary to Bowel Obstruction**
S Schowalter, Z Altawil, EM Schechter-Perkins, JR Pare
- 161 Open Dorsal Proximal Interphalangeal Dislocation**
R Derrah, C Wolterstorff
- 164 An Atypical Presentation of Cystic Echinococcosis**
B Tetali, DC Graf, ED Abou Asala, D Axelson
- 167 Intracranial Hemorrhage Due to Secondary Hypertension from Intracranial Large Vessel Occlusion**
A Rawal, A Waldman, O Saeed, AA Khan
- 171 Serotonin Syndrome versus Cannabis Toxicity in the Emergency Department**
JW Blatz, LT Le
- 174 Pyogenic Flexor Tenosynovitis as a Rare Complication of Dyshidrotic Eczema**
WS Nimjareansuk, M Rosselli
- 178 Heterotopic Pregnancy Diagnosed with Point-of-care Ultrasound in the Emergency Department: A Case Report**
IJ Holley, SP Stickle
- 181 Cardiac Memory-induced T-wave Inversions**
SC Polito, JA Giordano, BL Cooper
- 185 Euglycemic Diabetic Ketoacidosis in Concurrent Very Low-carbohydrate Diet and Sodium-glucose Transporter-2 Inhibitor Use: A Case Report**
M Earle, B Ault, C Bonney
- 189 A Case Report of Angioedema and Anaphylactic Shock Induced by Ingestion of Polyethylene Glycol**
A Rossi, Osborn L
- 193 A Case Report of Acute Heart Failure Due to Infective Aortic Endocarditis Diagnosed by Point-of-care Ultrasound**
R Gallagher, M Wilson, P Hite, B Jackson
- 197 Eagle Syndrome: A Rare Case of Atraumatic, Painful Cervical Neck Swelling**
CP Worden, SS Bhandari, BB Cable, DR Kuehl
- 201 Gastric Adenocarcinoma Presenting as Chronic Back Pain: A Case Report**
A Chitty, D Cardriche, TH Matese Jr

Policies for peer review, author instructions, conflicts of interest and human and animal subjects protections can be found online at www.cpcem.org.

Table of Contents *continued*

- 205 Accidental Chlorine Gas Exposure in a Pediatric Patient: A Case Report**
A Antolick, L Ouellette, B Judge, B Riley, JS Jones
- 208 A Case of Hyperkalemia Versus Pseudohyperkalemia in Chronic Lymphocytic Leukemia**
RD Le, SP Geary
- 211 High-Pressure Injection Injury of the Face: A Case Report on Presentation and Management**
E Zitelny, B Briggs, R Little, D Masneri
- 214 Rare External Jugular Vein Pseudoaneurysm**
PJ Wallace, J Haber

Images in Emergency Medicine

- 219 A Case of COVID-19 Pneumonia in a Young Male with Full Body Rash as a Presenting Symptom**
M Hunt, C Koziatek
- 222 Image to Fit the Clinical Picture: Point-of-care Ultrasound Assessment of Ebstein's Anomaly in Peru**
AC Rider, A Dreyfuss, R Inga
- 225 A Rare Case of Hip Pain Secondary to Pigmented Villonodular Synovitis**
G Lai, B Staller, B Ganguly, Q Ta, A Scumpia
- 227 Bowel Perforation in the Emergency Department Related to Bevacizumab Therapy and Recurrent Ovarian Cancer**
SA Ostby, M Olushoga, CA Leath III, SL Burlison
- 230 Ultrasonography of a Helical Left Common Carotid Artery**
BJ Busack, V Tran, CD Busack, CJ Butts
- 232 55-year-old Female with Hematuria**
DA Long, B Long

Fall 2018 and Spring 2019 The American College of Osteopathic Emergency Medicine (ACOEP) FOEM Competition

The Foundation for Osteopathic Emergency Medicine (FOEM) promotes research and graduate medical education to advance the science of patient centric holistic emergency care consistent with the osteopathic philosophy. Each year FOEM hosts a number of research competitions that are presented at the American College of Osteopathic Emergency Physicians (ACOEP) fall scientific assembly and spring seminar. This issue of Clinical Practice and Cases in Emergency Medicine (CPC-EM) highlights FOEM clinical pathological cases and case reports presented at the 2018 ACOEP Scientific Assembly and the 2019 ACOEP Spring Seminar.

John Ashurst, DO, MSc
Kingman Regional Medical Center

- 234 A 45-year-old Female with an Atypical Presentation of Pharyngitis**
A Schander, AA Glickman, N Weber, B Rodgers, MB Carney
- 109 Low Back Pain and Swelling as an Atypical Presentation of IgA Vasculitis**
CT Winkler, RW Dobson, MJ Tranovich
- 244 Fever Unmasked Brugada Syndrome in Pediatric Patient: A Case Report**
O Mirzapolos, P Marshall, A Brill

Clinical Practice and Cases in Emergency Medicine (CPC-EM) is a open-access Medline-indexed internationally recognized journal affiliated with the Western Journal of Emergency Medicine (WestJEM). CPC-EM is distributed electronically to 19,000 emergency medicine scholars. This includes our sponsors California ACEP, the American College of Osteopathic Emergency Physicians, California Chapter of AAEM, and over 83 academic department of emergency medicine subscribers and 8 AAEM State Chapters.

Table of Contents *continued*

- 247 **Unsuspecting Dietary Factors in Hyperkalemia: A Case Report on Why History Matters**
K McLendon, M Wiggins, D Hunt, A Gauthier, D Thoppil
- 251 **Brugada Syndrome: Presentation and Management of the Atypical Patient in the Emergent Setting**
A Nguyen, M Flores, V Tano
- 255 **Spontaneous Carotid Artery Dissection Presenting as Trigeminal Neuralgia in the Emergency Department**
R Look, TJ Terlau, R Misek
- 259 **Diet-induced Ketoacidosis in a Non-diabetic: A Case Report**
S Slade, J Ashurst
- 263 **Portal Venous Thrombosis Associated with Use of Etonogestrel/ethinyl Estradiol Vaginal Ring**
KE Bailey, MJ Tranovich
- 267 **Subacute Presentation of Central Cord Syndrome Resulting from Vertebral Osteomyelitis and Discitis: A Case Report**
T Dang, F Dong, G Fenati, M Rabiei, M Cerda, M Neeki

Clinical Practice and Cases in Emergency Medicine (CPC-EM) is a open-access Medline-indexed internationally recognized journal affiliated with the *Western Journal of Emergency Medicine* (WestJEM). CPC-EM is distributed electronically to 19,000 emergency medicine scholars. This includes our sponsors California ACEP, the American College of Osteopathic Emergency Physicians, California Chapter of AAEM, and over 83 academic department of emergency medicine subscribers and 8 AAEM State Chapters.

CPC**EM** Clinical Practice & Cases

CALL FOR SUBMISSIONS

- Patient Care Case Reports
- Images in Emergency Medicine

Fully open-access, peer reviewed, well indexed: CPC-EM is available anywhere with an internet connection at **CPCEM.org**

Clinical Practice and Cases in Emergency Medicine is an internationally recognized journal affiliated with the MEDLINE-indexed ***Western Journal of Emergency Medicine***

CPC-EM encourages submissions from junior authors and countries with developing emergency medicine programs

CPC**EM** Clinical Practice & Cases

CALL FOR CPC-EM SECTION EDITORS!

- Medical-Legal Case Reports
- Case Reports/Images in Emergency Medicine

Send your CV and letter of interest to editor@cpcem.org

WestJEM Integrating Emergency Care
with Population Health

CPCEM Clinical
Practice
& Cases

Call for Reviewers!

Please send your CV and letter of interest to
editor@westjem.org

CALL FOR SUBMISSIONS

Team Based Learning ▪ Podcasts ▪ Lectures ▪
Small Group Learning and Workshops ▪ Oral
Boards ▪ Simulation ▪ Curricula ▪ Innovations

CALL FOR REVIEWERS

JETem is an online,
open access, peer-
reviewed journal-
repository for EM
educators.

VISIT JETem.org
to learn more about
submissions or if
you're interested
in being a JETem
reviewer.



Journal of Education & Teaching in Emergency Medicine

A Journal of CORD

55-year-old Male with Exertional Dyspnea

Eric R. Friedman, MD*

J. David Gatz, MD†

Zachary D.W. Dezman, MD, MS, MS†

Laura J. Bontempo, MD, MEd†

*University of Maryland Medical Center, Department of Emergency Medicine, Baltimore, Maryland

†University of Maryland School of Medicine, Department of Emergency Medicine, Baltimore, Maryland

Section Editors: Joel Moll, MD

Submission history: Submitted January 3, 2020; Revision received March 9, 2020; Accepted March 13, 2020

Electronically published April 23, 2020

Full text available through open access at http://escholarship.org/uc/uciem_cpchem

DOI: 10.5811/cpchem.2020.3.46393

Introduction: Dyspnea is a common presenting complaint for many patients in the emergency department.

Case Presentation: A 55-year-old man with type I diabetes presented to the emergency department with one month of intermittent palpitations and dyspnea. His lungs were clear to auscultation, and his chest radiograph was normal.

Discussion: This case takes the reader through the differential diagnosis and systematic work-up of dyspnea with discussion of the diagnostic study, which ultimately led to this patient's diagnosis and successful treatment. [Clin Pract Cases Emerg Med. 2020;4(2):111–115.]

Keywords: *Clinicopathological cases; cardiology; epidemiology.*

CASE PRESENTATION (Dr. Eric R. Friedman):

A 55-year-old man presented to the emergency department (ED) of an urban, academic, medical center with intermittent palpitations (fast beats accompanied by a “pounding” sensation in the chest) for the prior month. Palpitations were most noticeable at night but had become more severe and constant over the preceding three days. He also reported shortness of breath while supine in bed and lightheadedness with exertion. The patient is an avid hiker, so he only presented once his dyspnea prevented him from completing a typical family hike. He denied any chest pain, fevers, weight loss, syncope, leg swelling, cough, nausea, vomiting, or rashes.

The patient was diagnosed with type 1 diabetes mellitus when he was 30 and has a history of hypertension. He was taking insulin glargine nightly with sliding-scale insulin aspart during meals and had recently switched from ramipril to losartan 50 milligrams (mg) daily due to nocturnal cough. He denied any drug, alcohol, or tobacco use. His father died suddenly at age 42 due to a heart attack. He denied any allergies.

The patient's vital signs on presentation were as follows: temperature 97.2 degrees Fahrenheit; blood pressure 131/83 millimeters of mercury (mm Hg); pulse 55 beats per minute, respiratory rate 18 breaths per minute; and oxygen saturation

99% on room air, with a body mass index of 28.6 kilograms per meters squared. Physical exam revealed a well-developed and well-nourished male patient in no acute distress. His head was normocephalic and atraumatic. His eye exam was normal with pupils that were equal, round, and reactive to light. No scleral icterus was seen. His neck was supple and had normal range of motion. There was no jugular venous distension seen. The patient's cardiac exam was notable for a bradycardic and irregularly irregular heartbeat without a murmur. His lungs were clear to auscultation bilaterally, and no wheezes or rales were heard. The patient's abdomen was soft, non-tender, and non-distended. His extremities were warm and well perfused, and without edema. The patient's cranial nerves II–XII were intact, and gait and strength assessments were unremarkable. No pronator drift was seen. Skin was normal in appearance, without any lesions or rashes. The patient demonstrated a normal mood and affect throughout the history and exam.

A chest radiograph (CXR) and electrocardiogram (ECG) were obtained (Images 1 and 2, respectively). Laboratory studies (Table) were notable for a white blood cell count of 6.2 thousand per microliter, hemoglobin of 15.1 grams per deciliter, platelets of 190,000 per microliter, glucose 250 milligrams per deciliter, negative troponin, B-type natriuretic peptide (BNP)

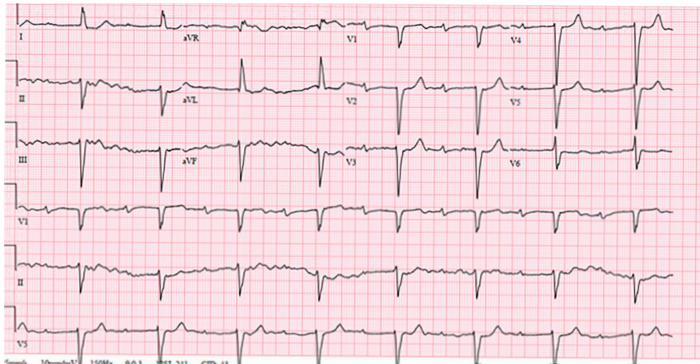


Image 1. Electrocardiogram of a 55-year-old male with palpitations and dyspnea, taken while in the emergency department.

of 502 picograms per deciliter, a thyroid stimulating hormone level of 1.2 milli-international units per liter with free thyroxine of 1.4 nanomoles per liter, and a *Borrelia Burgdorferi* IgM/IgG (immunoglobulin) titer of 0.28, negative antinuclear antibody test. (The latter test resulted after the patient was admitted.) While in the ED the patient experienced an acute episode of palpitations. His rhythm, as recorded by telemetry, is shown in Image 3. An echocardiograph was performed, which showed severe global hypokinesis with a left ventricular ejection fraction (LVEF) of 15%, mild dilation, biatrial enlargement, and no pericardial effusion.

FACULTY DISCUSSION (Dr. J. David Gatz):

I can feel my own heart racing as I work through this case. A passionate hiker myself, I immediately empathize with this patient's concern of diminishing trail endurance. It is all quite alarming for a relatively young gentleman who otherwise seems healthy and active. He goes outdoors frequently and only has two chronic medical problems – insulin-dependent diabetes and hypertension. He did have a recent medication change, from ramipril to losartan, but this seems unlikely to be significant. It is alarming that his father suffered a cardiac-related death at such a young age (only 42 years old!) and raises the question of a potential hereditary component to this presentation. His reported symptoms unfortunately don't give us much additional direction: A month of palpitations with some exertional pre-syncope and orthopnea are rather vague. On exam, the patient's vital signs are frustratingly benign. The respiratory rate of 18 breaths per minute is probably just an estimated number and not directly measured. He is slightly bradycardic at 55 beats per minute, which may be due to his baseline level of athletic activity. He is slightly hypertensive, but this is a known diagnosis. His physical exam appears normal except for an irregular rhythm on cardiac assessment. His labs are mostly benign. Mild hyperglycemia is reasonable in the setting of his diabetes. His Lyme titers are within normal ranges. The patient's BNP, while not drastically

elevated, is certainly higher than what we would expect in an otherwise healthy individual without an existing cardiac or renal diagnosis.

The patient's ECG is abnormal and difficult to interpret. At first glance it appears to show a sinus bradycardia with first-degree atrioventricular (AV) block. There is left ventricular hypertrophy with repolarization abnormalities, and a left anterior fascicular block. Then, as if by premonition, the patient experiences a ventricular tachycardia. Understandably this triggers additional work-up including a CXR and an echocardiogram.

This is a large amount of information to work through, and it becomes essential to not miss the forest for the trees. Combining the patient's initially vague symptoms with the left ventricular hypertrophy on his ECG, elevated BNP, and dilated hypokinetic echo, it is clear that this patient has a cardiomyopathy. The question becomes why? Something has made his cardiac tissue structurally and functionally abnormal, yet in the absence of any known coronary artery disease, valvular disease, or hypertension (currently just on monotherapy with only mildly elevated pressures in the ED). Cardiomyopathy is typically thought of as falling within one of three general categories: hypertrophic, dilated, or restrictive.¹ The patient's ECG does not demonstrate the classic findings we would expect in a septal or apical variant of hypertrophic cardiomyopathy.² While there is an

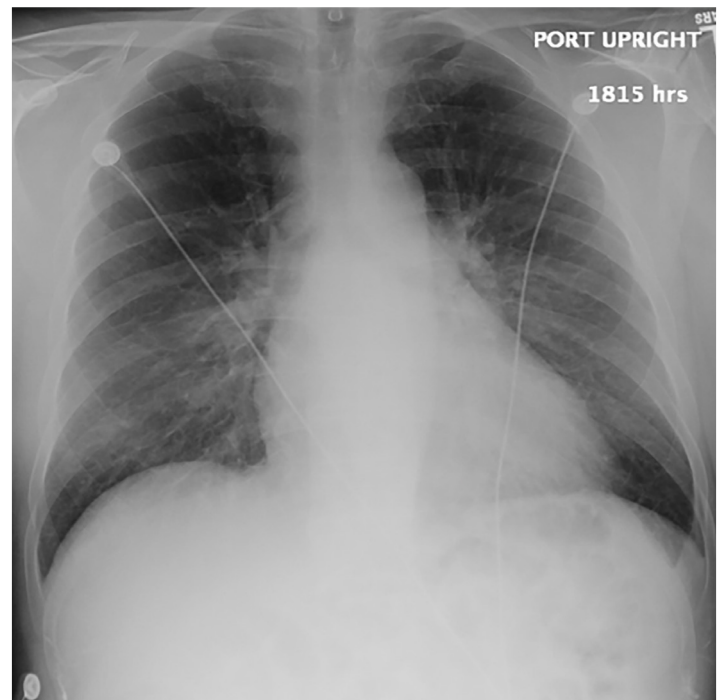


Image 2. Anterior-posterior chest radiograph of a 55-year-old male with palpitations and dyspnea.

Table. Laboratory results of a 55 year-old male with palpitations and dyspnea.

Lab test	Value	Units	Normal range
White blood cell count	6.2	K/mcL	4.5 - 11.0
Hemoglobin	15.1	g/dL	12.6 - 17.4
Hematocrit	43.7	%	37.0 - 50.0
Mean corpuscular volume	85.7	fL	80.0 - 96.0
Mean corpuscular hemoglobin	29.6	pg	28.0 - 33.0
Mean corpuscular hemoglobin concentration	34.6	g/dL	33.0 - 36.0
Platelets	190	K/mcL	153 - 367
Mean platelet volume	11.6	fL	9.4 - 12.4
Red cell distribution width	13.3	%	12.0 - 15.2
Sodium	141	mmol/L	136 - 145
Potassium	4.5	mmol/L	3.5 - 5.1
Chloride	105	mmol/L	98 - 107
Bicarbonate	27	mmol/L	21 - 30
Glucose	250	mg/dL	70 - 99
Creatinine	1.01	mg/dL	0.66 - 1.25
Blood urea nitrogen	16	mg/dL	7-20
Calcium	9.2	mg/dL	8.6 - 10.2
Total protein	6.1	g/dL	6.3 - 8.2
Albumin	3.4	g/dL	3.5 - 5.2
Bilirubin total	0.9	mg/dL	0.3 - 1.2
Alkaline phosphatase	63	units/L	38 - 126
Aspartate aminotransferase	25	units/L	17 - 59
Alanine aminotransferase	40	units/L	21 - 72
Thyroid stimulating hormone	1.2	mIU/L	0.47 - 4.68
T4 free	1.4	ng/dL	0.6 - 2.5
Magnesium	1.8	mg/dL	1.6 - 2.6
Phosphorus	4.2	mg/dL	2.5 - 4.5
<i>Borrelia burgdorferi</i> IgG/IgM Total*	0.28		
Anti-nuclear antibody	Neg		
Brain natriuretic peptide	502	pg/mL	<900
Troponin	<0.02	ng/mL	<0.07

*The amount of immunoglobulin G or M that are reactive to *Borrelia* antigen, results < 0.9 of the laboratory standard are considered negative.

K, thousand; *mcL*, microliter; *g*, grams; *dL*, deciliter; *fL*, femtoliter; *pg*: picogram; *mmol*, millimoles; *L*, liter; *mg*, milligrams; *mIU*, milli-international unit; *ng*, nanograms; *pg*, picograms; *mL*, milliliter; *ng*, nanograms; *Ig*: immunoglobulin; *Neg*, negative.

AV block and widened QRS complexes, the patient's ECG lacks the small voltages typically associated with a restrictive cardiomyopathy. Given that the patient's echo demonstrates global hypokinesis (not apical) and there are no known significant new stressors in his life, his presentation does not seem consistent with a stress (Takotsubo) cardiomyopathy. Given all of this, it seems reasonable to narrow our search to potential causes of dilated cardiomyopathy (DCM).

But the number of etiologies just within DCM is long.³ There are many known infectious causes (bacterial, viral, spirochetal, rickettsial, mycotic, protozoal, helminthic), but the patient has no fevers, antecedent illnesses, or laboratory evidence of infection. Lyme disease is an exciting thought given the patient's outdoor activities, but the patient's Lyme titers are within normal limits. While deposition diseases (hemochromatosis/amyloidosis) can cause DCM, there is no ECG evidence or associated stigmata. Numerous medications (especially chemotherapeutics and antiretrovirals) are known to cause DCM, but the patient is not taking any of them. Similarly, the patient has no history to suggest ingestion or exposure to toxins that could potentially cause DCM. Laboratory results and history exclude DCM secondary to any profound electrolyte, renal, or nutritional abnormalities. Diabetes can cause DCM, and while we don't have a hemoglobin A1c to show whether his diabetes is controlled or not, it would be unlikely for a patient to present with DCM without a history of coronary artery disease, myocardial infarction, or any of the more common complications of diabetes (e.g., peripheral neuropathy, diabetic nephropathy, and retinopathy). There is no evidence of additional endocrine or genetic disorder. This leaves one final major category of potential etiologies – autoimmune processes.

The autoimmune diseases that cause DCM include systemic lupus erythematosus (SLE), dermatomyositis, scleroderma, rheumatoid arthritis, and sarcoidosis. SLE is less likely because the patient doesn't have the classic symptoms, the rash, or nephritis. Similarly, the classic cutaneous findings of dermatomyositis and scleroderma are not present. Sarcoidosis, however, can be much more subtle. With this in mind, the patient's CXR seems to provide an essential clue.

Hilar structures on CXRs can be confusing. This patient's CXR demonstrates additional "lumpy and bumpy" radiodensities in the hilar areas. In contrast to the smooth contours of bilateral pulmonary artery enlargement, these findings are consistent with hilar adenopathy, a finding suggestive of a neoplastic, infectious (tuberculosis, histoplasmosis), and inflammatory processes like sarcoidosis.⁴

And thus, while this has been a long and winding path through the woods, we appear to have finally stumbled into a clearing. Sarcoidosis uniquely unifies our clinical suspicion of a DCM with the patient's CXR. Moreover, the patient is the appropriate age and has experienced many of the typical symptoms including heart failure, AV blocks, and arrhythmias.

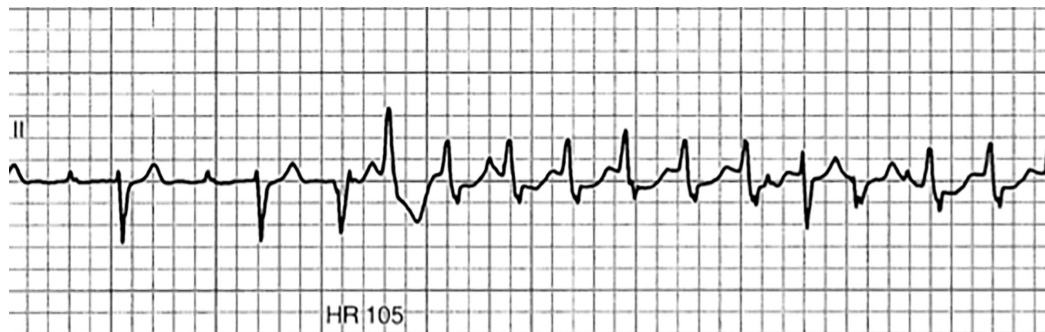


Image 3. Patient's cardiac rhythm during an episode of palpitations that occurred while he was in the emergency department. "HR 105" refers to the patient's heart rate.

Confirming the diagnosis can be attempted by cardiac biopsy, the classic diagnostic test, but this seems excessively invasive. Cardiac magnetic resonance imaging (MRI), however, has reasonable accuracy and is therefore my preferred diagnostic test. Hopefully a correct diagnosis and treatment will let this patient return to the trail for, as astutely noted by Hippocrates, "Walking is man's best medicine."

CASE OUTCOME (Dr. Friedman):

The patient was admitted to the cardiology service. Cardiac catheterization was considered, but the patient instead received a cardiac MRI that showed DCM with extensive enhancement involving inferoseptal, inferior, and inferolateral segments from base to apex and mediastinal lymphadenopathy, with a severely decreased ventricular function and a LVEF of 21%. The patient had multiple runs of ventricular tachycardia while admitted and consequently received an automated implantable cardioverter-defibrillator (AICD). A hilar lymph node biopsy showed non-caseating granulomatous inflammation and multinucleated giant cells, consistent with sarcoidosis. The patient was originally started on prednisone 40 milligrams (mg) for the sarcoidosis and alprazolam 1 mg as needed due to post-traumatic stress disorder from his recurrent AICD shocks. He has since transitioned to 1 gram of mycophenolate mofetil and prednisone 35 mg daily. He is doing well and has not experienced any recent shocks from his AICD.

RESIDENT DISCUSSION:

Sarcoidosis has a protean presentation, and the incidence of the disease varies widely among different cultural and racial groups: 1-2 persons per 100,000 of Japanese descent are affected, while 35-80 per 100,000 African-American persons are affected.⁵ Cardiac sarcoidosis is relatively rare, occurring in less than 5% of all cases.⁵ Untreated cardiac sarcoidosis can result in sudden cardiac death from ventricular tachyarrhythmias or atrioventricular blocks, and should be considered in patients with unexplained low LVEF, unexplained

sustained ventricular tachycardia, and new AV block (usually Mobitz type II second degree or third degree).⁶ Endomyocardial biopsy has the highest specificity for the diagnosis of cardiac sarcoidosis but is rarely performed given the comparative ease and lack of complications associated with cardiac MRI.⁷ Cardiac MRI has an acceptably high sensitivity and specificity of 89% and 78%, respectively.⁷ Cardiac MRI will usually show multiple areas of enhancement in a non-infarct pattern and will show direct enhancement from the left ventricle, across the interventricular segment, into the right ventricle.⁸

Early treatment with immunosuppressants such as steroids can help treat cardiac sarcoidosis. In one case, a 32-year-old man with cardiac sarcoidosis had complete resolution of his AV block and ventricular tachycardia within two weeks of initiating steroid treatment. Follow-up cardiac MRI showed no further uptake, consistent with resolution of his cardiac sarcoidosis.⁹ This case illustrates a rare, deadly disease that was fortunately recognized early. The correct treatment was started, which resolved his symptoms and dysrhythmias.

FINAL DIAGNOSIS:

Cardiac sarcoidosis.

KEY TEACHING POINTS:

1. Consider cardiac sarcoidosis in younger patients presenting with symptoms of heart failure, arrhythmias, or syncope.
2. Up to a quarter of cardiac sarcoidosis cases may occur in the absence of any extracardiac involvement.
3. The most typical radiographic features of thoracic sarcoidosis include symmetric hilar and mediastinal lymphadenopathy.

The authors attest that their institution requires neither Institutional Review Board approval, nor patient consent for publication of this case report. Documentation on file.

Address for Correspondence: Laura Bontempo, MD, MEd, University of Maryland, Department of Emergency Medicine, 110 S. Paca St., 6th floor, Suite 200, Baltimore, MD 21201. Email: Lbontempo@som.umaryland.edu.

Conflicts of Interest: By the CPC-EM article submission agreement, all authors are required to disclose all affiliations, funding sources and financial or management relationships that could be perceived as potential sources of bias. The authors disclosed none.

Copyright: © 2020 Friedman et al. This is an open access article distributed in accordance with the terms of the Creative Commons Attribution (CC BY 4.0) License. See: <http://creativecommons.org/licenses/by/4.0/>

REFERENCES

- Brieler J, Breeden MA, Tucker J. Cardiomyopathy: an overview. *Am Fam Physician*. 2017;96(10):640-6.
- Pelto H, Owens D, Drezner J. Electrocardiographic findings suggestive of cardiomyopathy: what to look for and what to do next. *Curr Sports Med Rep*. 2013;12(2):77-85.
- Jefferies JL and Towbin JA. Dilated cardiomyopathy. *Lancet*. 2010;375(9716):752-62.
- Silva M, Nunes H, Valeyre D, et al. Imaging of sarcoidosis. *Clin Rev Allergy Immunol*. 2015;49(1):45-53.
- Rybicki, Benjamin A., and Michael C. Iannuzzi. "Epidemiology of sarcoidosis: recent advances and future prospects." *Seminars in Respiratory and Critical Care Medicine*. Vol. 28. No. 01. Copyright 2007 by Thieme Medical Publishers, Inc.
- Birnie DH, Sauer WH, Bogun F, et al. HRS expert consensus statement on the diagnosis and management of arrhythmias associated with cardiac sarcoidosis. *Heart Rhythm*. 2014;11(7):1305-23.
- Langah R, Spicer K, Gebregziabher, et al. Effectiveness of prolonged fasting 18f-FDG PET-CT in the detection of cardiac sarcoidosis. *J Nucl Cardiol*. 2009;16(5):801-10.
- Sharma S. Cardiac imaging in myocardial sarcoidosis and other cardiomyopathies. *Curr Opin Pulm Med*. 2009;15(5):507-12.
- Okabe T, Yakushiji T, Hiroe M, et al. Steroid pulse therapy was effective for cardiac sarcoidosis with ventricular tachycardia and systolic dysfunction. *ESC Heart Fail*. 2016; 3(4): 288-92.

55-year-old Woman with Headache, Vomiting, and Visual Disturbance

Lana Shaker, MD
Jill Ripper, MD
Tiffany Murano, MD

Rutgers New Jersey Medical School, Department of Emergency Medicine, Newark,
New Jersey

Section Editor: Joel Moll, MD

Submission history: Submitted October 14, 2019; Revision received November 26, 2019; Accepted December 17, 2019

Electronically published April 17, 2020

Full text available through open access at http://escholarship.org/uc/uciem_cpccem

DOI: 10.5811/cpcem.2019.12.45546

Case Presentation: A 55-year-old woman with a past medical history of hypertension, hyperlipidemia, and iron deficiency anemia presented to the emergency department with three days of headache, nausea, vomiting, and visual changes. Her vital signs were within normal limits. She was noted to have a left cranial nerve six palsy on exam.

Results: Her laboratory testing revealed leukocytosis, hyponatremia, and hypokalemia. A non-contrast computed tomography scan of the head revealed an enlarged sella turcica and pituitary gland with hemorrhage and deviation of the optic chiasm.

Conclusion: Her symptoms improved and she was discharged from the hospital in stable condition. [Clin Pract Cases Emerg Med. 2020;4(2):116–120.]

Keywords: *headache; pituitary apoplexy; pituitary adenoma.*

CASE PRESENTATION (Lana Shaker)

A 55-year-old woman presented to the emergency department (ED) with the chief complaint of headache for three days, associated with nausea, vomiting, and visual changes. The headache was described as being sudden in onset, constant, bilateral, retro-orbital, and throbbing. The pain was a six out of ten in intensity. The pain was not alleviated with over the counter acetaminophen use. She was not able to describe any alleviating or exacerbating factors. The visual changes were described by the patient as “blurry vision” and “double vision” affecting her left eye greater than her right. She reported photophobia and difficulty keeping the left eye open. The patient described this difficulty of keeping the eye open as a weakness and not secondary to pain. She had approximately five episodes of non-bloody and non-bilious vomiting over the past three days and reported inability to tolerate her home medications. She also reported a sore throat and cough productive of yellow sputum for the previous two to three days, but denied fever, chills, chest pain, hemoptysis, or dyspnea.

Her past medical history included essential hypertension, hyperlipidemia, and a remote history of uterine fibroids associated with iron deficiency anemia. Prescribed medications included losartan 25 milligrams (mg) and hydrochlorothiazide 12.5 mg. She had no known drug allergies, did not smoke, drink alcohol, or use illicit drugs. She was unemployed and lived alone. The patient was post-menopausal and was pregnant three times- two of which were normal spontaneous deliveries with two living children and one prior abortion.

Vital signs were: temperature 98.8° Fahrenheit, heart rate 84 beats per minute, blood pressure 135/74 millimeters of mercury, respiratory rate of 18 breaths per minute and room air oxygen saturation 97%. Her body mass index was 42 (normal 18.5-24.9). Complete physical examination was unremarkable except her left eye’s lateral gaze was restricted by approximately 25%. Her visual acuity was 20/25 and 20/30, right and left eyes, respectively. Initial laboratory testing were resulted (Tables 1 and 2). An electrocardiogram was performed (Image 1).

Table 1. Complete blood cell count.

Serum hematology test	Value (reference range)
Complete blood cell count	
White blood cells	14.9 x 10 ³ /uL (4.0-11.0)
Hemoglobin	14 g/dL (12.0-16.0)
Hematocrit	43% (36.0-48.0)
Platelets	225 x 10 ³ /uL (150-450)
Differential	
Neutrophils	78% (35.0-80.0)
Lymphocytes	13% (20.0-50.0)
Monocytes	7% (2.0-12.0)
Eosinophils	0.6% (0.0-7.0)
Basophils	0.8% (0.0-2.0)

uL, microliters; g, grams; dL, deciliter.

CASE DISCUSSION (Tiffany Murano)

In summary, this is a 55-year-old gravida 3 para 2 woman with a past medical history of hypertension and hyperlipidemia who presents to the ED with a three day history of sudden onset bilateral retro-orbital headache with double vision. She reported a productive cough, which corresponded with the onset of the headache. Her physical examination was significant for restricted lateral gaze of the left eye with an otherwise normal neurologic examination. Her serum laboratory studies demonstrated hyponatremia and leukocytosis.

Headache is the fourth most common chief complaint in the ED and accounts for approximately 3% of ED visits in the United States.¹ Headaches may be classified as primary (e.g., migraine, tension, cluster headaches). The differential diagnosis for headache is quite broad ranging from benign conditions such as tension headache to potentially life-threatening conditions such as meningitis and stroke. When a patient presents to the ED with a headache, it is important to discern whether the onset of symptoms was progressive or sudden. Symptoms that occur suddenly, as with this patient, often indicates a vascular occlusion (e.g., thrombotic, embolic, or major vessel dissection events) or hemorrhage. The differential, cerebrovascular accident, arteriovenous malformation or a mass with a hemorrhagic component.

Migraine headaches are not generally sudden in onset but can be associated with visual changes, photophobia, nausea, and vomiting. However, the patient has no prior history of migraine headaches, and a new diagnosis of migraine headaches at the age of 55 would be unusual. Optic neuritis can cause acute visual changes and eye pain. However, the visual changes are characterized by decreased visual acuity, visual field loss, photopsia, or color vision

loss with pain in the affected eye with ocular movement.² There also may be an afferent pupillary defect. This patient demonstrated none of these findings. Moreover, this disease entity is more commonly in patients with a history of thrombophilia, taking oral contraceptives, pregnant, or post-partum and the majority of patients are under the age of 50 years which makes this diagnosis unlikely in this patient.³ Cavernous sinus thrombosis originating from a bacterial sinus infection can present with headache and ocular signs such as orbital pain but is typically not bilateral pain as described by this patient. Additionally, patients with cavernous sinus thrombosis may have proptosis, periorbital erythema and edema, and chemosis on exam, unlike this patient.⁴

The patient has restricted left eye extraocular movements on physical examination with diplopia. She complained of difficulty keeping her left open but had no ptosis noted on physical examination. The sixth cranial nerve (abducens) is responsible for abduction of the lateral rectus muscle that is necessary for horizonto-lateral gaze. Lesions that affect the sixth cranial nerve can cause impairment of lateral gaze as well as Horner's syndrome (disruption of the sympathetic innervation of the sixth cranial nerve causing miosis, ptosis, and anhidrosis). Etiologies of Horner's syndrome include pituitary lesions (e.g., infarction or hemorrhage), trauma, brachial plexus lesions, pathology to the lung apices, migraine

Table 2. Chemistry results.

Serum chemistry test	Value (reference range)
Complete metabolic panel	
Sodium	128 mmol/L (133-145)
Potassium	3.4 mmol/L (3.5-4.8)
Chloride	88 mmol/L (97-110)
Bicarbonate	27 mmol/L (23-30)
Blood urea nitrogen	7 mg/dL (6-20)
Creatinine	0.7 mg/dL (0.5-1.0)
Glucose	81 mg/dL (70-109)
Albumin	4.0 g/dL (3.5-5.2)
Bilirubin	1.0 mg/dL (<= 1.0)
Alkaline phosphatase	87 U/L (35-105)
Total protein	8.5 g/dL (6.0-8.3)
Aspartate transaminase	18 U/L (0-40)
Alanine aminotransferase	11 U/L (0-33)
Additional chemistries	
Troponin	<0.01 ng/mL (0.00-0.30)

mmol, millimoles; L, liter; mg, milligram; dL, deciliter; U, units; ng, nanogram; mL, milliliter.

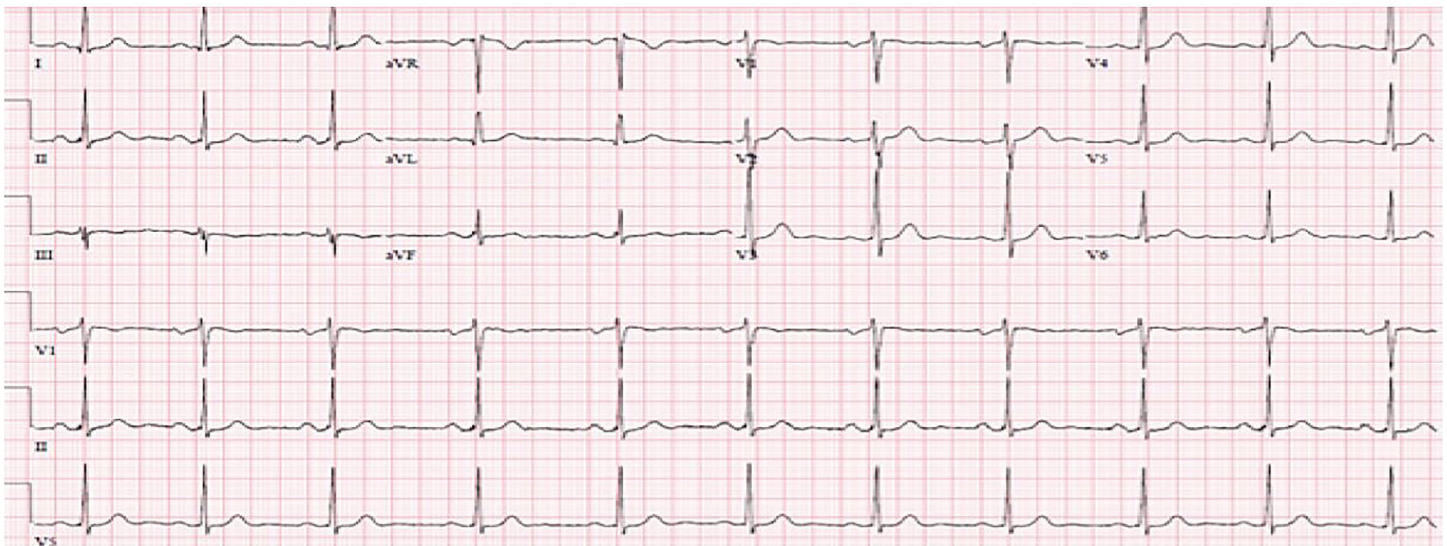


Image 1. Normal sinus rhythm at 64 beats per minute with sinus arrhythmia.

headache, idiopathic intracranial hypertension, and carotid artery pathology (e.g., ischemia or dissection). However, this patient presented with lateral gaze paralysis in the absence of Horner's syndrome. Thus, there could be a structural cause—such as a pituitary macroadenoma with or without hemorrhage—preventing normal left lateral gaze.

Another pertinent finding in this case is hyponatremia. Possible explanations for hyponatremia in conjunction with this clinical presentation and neurologic findings include syndrome of inappropriate antidiuretic hormone (SIADH), cerebral salt wasting (CSW), and adrenal insufficiency. Although all present with hyponatremia, CSW is associated with concomitant extracellular volume loss and hypovolemia while SIADH has normal to high extracellular volume and euvolemia. Urine electrolytes were not immediately available for this patient; however, she appeared to be clinically euvolemic. Adrenal insufficiency is an important cause of hyponatremia and may be primary (due to an adrenal cause), secondary (due to an anterior pituitary cause), or tertiary (due to a thalamic cause). Lesions in the pituitary result in a decrease in cortisol, increased adrenocorticotropic hormone (ACTH) and increased corticotropin-releasing hormone secretion (an anti-diuretic hormone secretagogue). Thyroid deficiency also may be seen in central adrenal insufficiency.

In addition, pituitary apoplexy may present with headache, visual disturbance, and hyponatremia as seen with this patient. The sudden onset of symptoms supports a vascular component—either a hemorrhage or embolic vascular component. A computed tomography scan of the head would be an appropriate initial imaging modality to confirm this diagnosis. According to the American College of Emergency Physicians'

clinical policy for the evaluation and management of adult patients presenting to the ED with an acute headache, there is Level B evidence that supports obtaining an emergency, non-contrast computed tomography (CT) scan of the head for patients with sudden-onset headache and focal neurologic findings. Therefore, this test would be appropriate in this case.⁵

CASE OUTCOME (Lana Shaker)

A non-contrast CT scan of the head revealed an enlarged sella turcica and an enlarged pituitary gland measuring 2.0 centimeters (cm) in its greatest superior to inferior extent, 3.3 cm in its greatest transverse diameter and 1.3 cm in its greatest anterior to posterior extent. In the central and inferior portions of the enlarged pituitary gland, there is increased density consistent with hemorrhage. The floor of the sella turcica is not eroded, and the sphenoid sinus is well aerated. The optic chiasm is deviated superiorly bilaterally (Images 2 and 3). Neurosurgery and ophthalmology services were consulted, and the patient was admitted to the intensive care unit. Her gaze palsy continued to worsen over the subsequent 24 hours (hospital day (HD) 1). Ophthalmology service was consulted and suggested that the patient likely had sixth cranial nerve palsy due to increased intracranial pressure. The neurosurgery team obtained a non-contrast magnetic resonance imaging (MRI) scan of the brain which demonstrated a pituitary macroadenoma displacing the optic chiasm. Additional serum laboratory studies were obtained to assess pituitary function and demonstrated normal thyroid stimulating hormone (TSH), low luteinizing hormone and cortisol levels, and an elevated prolactin level.

On HD 1, the patient also developed worsening hyponatremia and hypotension. She was administered

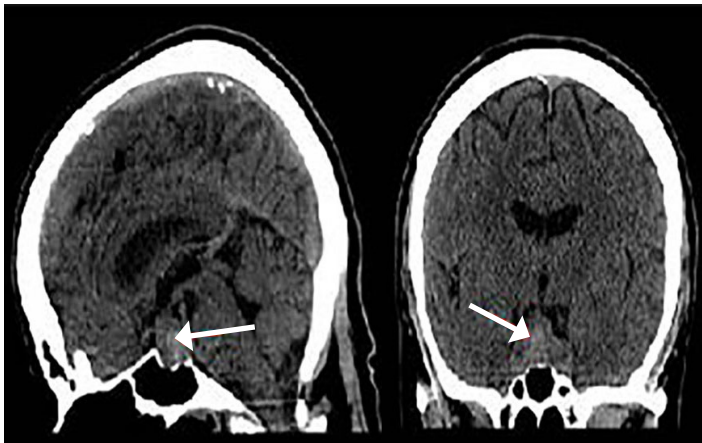


Image 2. Computed tomography of the head without contrast demonstrating enlarged pituitary gland with increased density consistent with hemorrhage (arrows).

hydrocortisone 100 mg intravenously for a suspected acute ACTH deficiency leading to adrenal crisis. A plan was made for operative intervention. On HD 2 she underwent a trans-sphenoidal surgical resection of the pituitary tumor. Over the subsequent six days, the patient's headache and visual complaints improved. Her visual acuity improved to 20/25 bilaterally. Her extra-ocular movements normalized with resolution of her cranial nerve six palsy. The hyponatremia resolved. However, she developed central hypothyroidism with both decreasing TSH and free thyroid hormone levels and was administered levothyroxine replacement. The patient was discharged on HD 8. Two week discharge follow up with neurosurgery, ophthalmology, and endocrinology services were unremarkable except for the thyroid hormone supplementation requirement.

RESIDENT DISCUSSION

Pituitary apoplexy is an acute infarction or hemorrhage of the pituitary gland. In most cases, apoplexy involves a previously unrecognized pituitary adenoma.⁴ An abrupt increase of tissue volume within the sellar region can cause headache, visual impairment, cranial nerve palsies, impairment of consciousness, and pituitary hormone deficiencies.⁴ Pituitary apoplexy is rare with an estimated incidence of 0.17 episodes per 100,000 person-years but is life threatening and must be promptly recognized and treated.⁴ Most commonly, pituitary apoplexy occurs in the fifth or sixth decade and has a slight male preponderance.^{4,5} Pituitary apoplexy can occur in non-adenomatous lesions including: hypophysitis, pituitary metastasis, craniopharyngioma, Rathke's cleft cyst, and sellar tuberculoma.⁴ Macroadenomas are more susceptible to apoplexy than microadenomas.⁶

Between 2 and 12% of patients with a pituitary adenoma experience apoplexy.⁷ Cavernous sinus invasion can be prognostic factor associated with pituitary apoplexy.⁶

The mechanisms causing pituitary apoplexy include: tumor vascular occlusion due to tumor growth, pituitary stimulation (e.g., provocative testing or gonadotropin releasing hormone analogue use, surgery, closed trauma, acute increase in blood flow due to physical activity or systemic hypertension, or coagulation disturbances (e.g., thrombocytopenia or anticoagulation).^{6,7} Macroprolactinomas and female gender have a greater association with hemorrhage.⁴

Symptoms may arise within hours to days after the onset of apoplexy.⁴ Sudden increase in intrasellar pressure can cause hypopituitarism. Moreover, sudden increases in pressure on contents and in neural structures can cause: neural palsies (most commonly cranial nerves III, IV, V, or VI), visual field impairment and visual acuity deficiency (due to optic chiasm compression), consciousness reduction (due to pressure transmitted to the brainstem), chemical meningitis (from blood leakage into the subarachnoid space), and even hemispheric signs such as hemiplegia (from intracavernous carotid artery compression and vasospasm).⁶

A high degree of suspicion is required to make the clinical diagnosis as these patients typically do not have a known history of pituitary disease.⁴ Common differential diagnoses include subarachnoid hemorrhage, meningitis, cavernous sinus thrombosis, and migraine.⁴ A CT scan of the head is more pragmatic to obtain but less sensitive to diagnose a pituitary lesion than brain MRI.^{6,8}

Hormonal pituitary evaluation is recommended as anterior pituitary deficiencies can occur in nearly 80% of patients.⁶ ACTH deficiency can lead to adrenal crisis and is life threatening, requiring immediate glucocorticoid replacement.⁵ Other deficiencies, such as hyperprolactinemia or hypothyroidism, may also occur.⁸ Hyponatremia is observed in up to 40% of cases and is due to decreased circulating cortisol in the setting ACTH deficiency or SIADH.⁶

The first step in management of patients with pituitary apoplexy is hemodynamic stabilization. Patients may require correction of electrolyte disturbances and corticosteroid administration. Further management may be either surgical or continued medical care, and some controversy exists regarding this issue.¹⁰ If consciousness or vision is impaired, surgical decompression is recommended.^{6,10} Pituitary deficiencies, however, do not generally recover.⁶ Outcome is variable and difficult to predict as patients may dramatically deteriorate from cerebral ischemia or subarachnoid hemorrhage or recover spontaneously without sequelae.⁷

FINAL DIAGNOSIS

Pituitary macroadenoma with apoplexy.

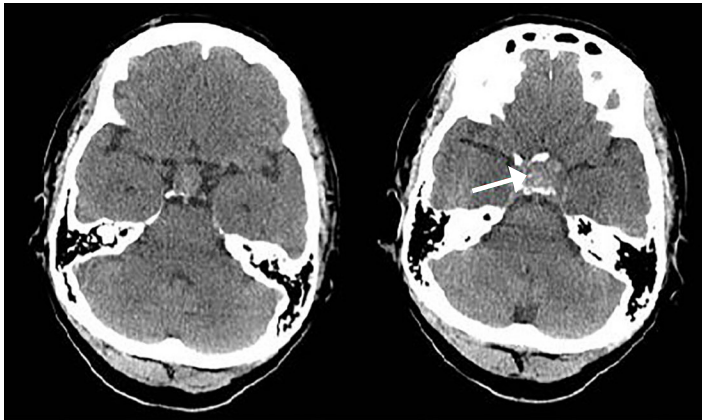


Image 3. Computed tomography of the head without contrast demonstrating enlarged sella turcica and deviated optic chiasm (arrow).

KEY TEACHING POINTS

- Pituitary apoplexy can evolve in hours to days and is life threatening.
- Pituitary apoplexy is rare, most common in the fifth and sixth decade, and has a slight male preponderance. Pituitary adenomas, specifically macroadenomas, are at highest risk of apoplexy and is often a new diagnosis.
- The pathophysiology regarding pituitary apoplexy is associated with hypertension, coagulopathy, recent surgery or closed head trauma.
- Symptoms and signs include: acute headache, nausea and vomiting, visual disturbances, ocular palsies, meningismus, and decreased level of consciousness.
- Head CT should be obtained immediately but brain MRI is most sensitive for the diagnosis of pituitary apoplexy and should be obtained if clinical suspicion is high despite non-diagnostic CT
- Treatment is comprised of circulatory support, electrolyte correction, corticosteroid administration when indicated, and potential surgical decompression.
- Outcome is variable, ranging from death or persistent neurological sequelae to spontaneous recovery.

The authors attest that their institution requires neither Institutional Review Board approval, nor patient consent for publication of this case report. Documentation on file.

Address for Correspondence: Lana Shaker, MD, Rutgers-New Jersey Medical School, Department of Emergency Medicine, 185 South Orange Ave., Newark, NJ 07103. Email: shakerl@njms.rutgers.edu.

Conflicts of Interest: By the CPC-EM article submission agreement, all authors are required to disclose all affiliations, funding sources and financial or management relationships that could be perceived as potential sources of bias. The authors disclosed none.

Copyright: © 2020 Shaker et al. This is an open access article distributed in accordance with the terms of the Creative Commons Attribution (CC BY 4.0) License. See: <http://creativecommons.org/licenses/by/4.0/>

REFERENCES

1. National Hospital Ambulatory Medical Care Survey: 2011 Emergency Department Summary Tables. Available at: https://www.cdc.gov/nchs/data/ahcd/nhamcs_emergency/2011_ed_web_tables.pdf. Accessed October 6, 2019.
2. Jenkins TM and Toosy AT. Optic neuritis: the eye as a window to the brain. *Curr Opin Neurol*. 2017;30(1):61-6.
3. Piazza G. Cerebral venous thrombosis. *Circulation*. 2012;125(13):1704-9.
4. Rochat P, von Buchwald C, Wagner A. Sinusitis and ischemic stroke. *Rhinology*. 2001;39(3):173-5.
5. Singh Y, Singh M, Saxena S, et al. Pansinusitis, cavernous sinus thrombosis and cerebral infarction. *J Med Investig Pract*. 2014;9(2):95-7.
6. Edlow JA, Panagos PD, Godwin SA, et al. Clinical policy: critical issues in the evaluation and management of adult patients presenting to the emergency department with acute headache. *Ann Emerg Med*. 2008;52(4):407-36.
7. Glezer A and Bronstein MD. Pituitary apoplexy: pathophysiology, diagnosis and management. *Arch Endocrinol Metab*. 2015;59(3):259-64.
8. Briet C, Salenave S, Bonneville JF, et al. Pituitary Apoplexy. *Endocr Rev*. 2015;36(6):622-45.
9. Bi WL, Dunn IF, Laws ER Jr. Pituitary apoplexy. *Endocrine*. 2015;48(1):69-75.
10. Pyrgelis ES, Mavridis I, Meliou M. Presenting Symptoms of Pituitary Apoplexy. *J Neurol Surg A Cent Eur Neurosurg*. 2018;79(1):52-9.
11. Briet C, Salenave S, Chanson P. Pituitary apoplexy. *Endocrinol Metab Clin North Am*. 2015;44(1):199-209.

Heroin Adulterated with the Novel Synthetic Cannabinoid, 5F-MDMB-PINACA: A Case Series

Muhammed Ershad, MD*
Maricel Dela Cruz, MD*
Ahmed Mostafa, MD*
Muhammad M. Khalid, MD*
Ryan Arnold, MD†
Richard Hamilton, MD†

*Drexel University College of Medicine, Department of Emergency Medicine, Division of Medical Toxicology, Philadelphia, Pennsylvania
†Drexel University College of Medicine, Department of Emergency Medicine, Philadelphia, Pennsylvania

Section Editors: Steven Walsh, MD

Submission history: Submitted September 3, 2019; Revision received February 20, 2020; Accepted February 21, 2020

Electronically published April 23, 2020

Full text available through open access at http://escholarship.org/uc/uciem_cpchem

DOI: 10.5811/cpchem.2020.2.45060

Introduction: Heroin can be adulterated with various substances that may or may not have pharmacological effects. Here we report a case series of 8 patients who presented to the emergency department after overdose with intravenous heroin preparation adulterated with the synthetic cannabinoid methyl 2-(1-(5-fluoropentyl)-1H-indazole-3-carboxamido)-3,3-dimethylbutanoate (5F-MDMB-PINACA).

Case Series: Except for one patient, all of them presented with a typical initial opioid toxidrome consisting of central nervous system and respiratory depression along with pinpoint pupils. Naloxone was given to them, triggering severe agitation and combative behavior along with overlapping features of anticholinergic and sympathomimetic toxidrome. All patients required multiple doses of benzodiazepines. Three were successfully treated with physostigmine.

Discussion: 5F-MDMB-PINACA is a synthetic cannabinoid that was added to heroin in samples obtained from patients reported in this case series. Patients demonstrated significant agitation after receiving naloxone for opioid toxidrome, presumably because of the removal of the depressant effect of opioids, which unmasked the excitatory effects of the synthetic cannabinoids. Three patients required physostigmine along with the benzodiazepines for control of their agitation, urine retention and abnormal vitals, suggesting the possibility of an anticholinergic toxidrome to have developed in these patients.

Conclusion: Heroin contaminated with 5F-MDMB-PINACA exhibits variable severities of anticholinergic effects, some on presentation and others only after opiate antagonism. [Clin Pract Cases Emerg Med. 2020;4(2):121–125.]

Keywords: *synthetic cannabinoids; heroin; physostigmine.*

INTRODUCTION

Heroin is often adulterated with a variety of substances including baking soda, caffeine, crushed analgesics, and scopolamine.¹ We present a consecutive patient case series

with similar presentations after overdose with intravenous (IV) heroin adulterated with the synthetic cannabinoid (SC) methyl 2-(1-(5-fluoropentyl)-1H-indazole-3-carboxamido)-3,3-dimethylbutanoate (5F-MDMB-PINACA). Within three

months, eight patients presented to the emergency department (ED) after use of IV heroin with symptoms consistent with anticholinergic toxicity and variable requirement for naloxone administration by emergency medical services (EMS).

CASE SERIES

Case 1

A 28-year-old man with a past medical history of bipolar disorder and polysubstance abuse including IV heroin, presented to the hospital by EMS after being found at home unresponsive. Family members found packets of drugs near the patient labelled “Santa Muerte (Image 1). On arrival, vital signs included a heart rate (HR) of 122 beats per minute, blood pressure (BP) 134/78 millimeters of mercury (mm Hg), respiratory rate (RR) of 38 breaths per minute, oral temperature 98.2 degrees Fahrenheit (F), and oxygen saturation (SpO₂) 78% on non-rebreather mask. Physical exam included tachycardia, flushing, dry mucous membranes and mydriasis. The patient was initially given two milligrams (mg) of intranasal (IN) naloxone in the field by EMS secondary to central nervous system (CNS) and respiratory depression, with no response. He was given a second dose of two mg IN naloxone and became agitated and combative. The patient was intubated upon ED arrival for hypoxic respiratory failure. Chest radiograph showed signs of aspiration pneumonitis, which developed into acute respiratory distress syndrome (ARDS) requiring venovenous extracorporeal membrane oxygenation (VV-ECMO). Head computed tomography was negative for acute intracranial abnormality. Complete blood count (CBC) and basic metabolic panel (BMP) were unremarkable. Urine drug screen immunoassay was positive for cocaine, opiates, fentanyl, tetrahydrocannabinol



Image 1. Packets of “Santa Muerte,” a street heroin adulterated with synthetic cannabinoid, that were retrieved from a patient found unresponsive at home.

CPC-EM Capsule

What do we already know about this clinical entity?

Synthetic cannabinoids (SC) may be added as adulterants to opiates sold on the street, which can contribute to unpredictable clinical consequences.

What makes this presentation of disease reportable?

We report a case series of eight patients who had predominantly anticholinergic features after using heroin containing the SC 5F-MDMB-PINACA.

What is the major learning point?

Patients using heroin containing SCs may exhibit severe agitation and hyperactive behavior following naloxone administration.

How might this improve emergency medicine practice?

Consider using physostigmine along with benzodiazepines in treating patients with severe agitation following naloxone-induced reversal of an opioid toxidrome.

(THC) and benzodiazepines. Comprehensive drug screen of the serum by liquid chromatography tandem mass spectrometry (LC-MS-MS) was positive for cocaine, heroin, 6-monoacetylmorphine (6-MAM), fentanyl, THC, and alprazolam. The patient remained intubated on VV-ECMO for 12 days, after which he was extubated, removed off of VV-ECMO, and discharged on day 17. Laboratory analysis of the patient’s confiscated drug by gas chromatography-mass spectrometry (GC-MS) and liquid chromatography quadrupole time-of-flight mass spectrometry (LCQ-TOF-MS) was positive for the novel SC 5F-MDMB-PINACA, heroin, and fentanyl.

Case 2

A 25-year-old man with a past medical history of IV heroin use, presented to the ED by EMS after IV heroin use. The patient initially had CNS and respiratory depression in the field and was first given two mg of IN naloxone with no response, followed by a second dose of two mg IN naloxone, which made him anxious and tachycardic. Vital signs on

arrival to the ED included a HR of 102 beats per minute, BP of 146/89 mmHg, RR 24 breaths per minute, SpO2 98% on room air, and oral temperature 97.5° F. Physical exam was positive for flushing, tachycardia, and agitation. The patient was given 4 mg of lorazepam IV in the ED. He admitted to the use of an adulterated heroin “Santa Muerte.” CBC and BMP were unremarkable. Urine drug screen immunoassay was positive for opiates, amphetamine, barbiturates and cocaine. Symptoms improved after benzodiazepine treatment, IV fluids, and supportive care. He was admitted for 24 hours and discharged the following day with no further complications. Laboratory analysis of the patient’s confiscated drug by GC-MS and LCQ-TOF was positive for the novel SC 5F-MDMB-PINACA, heroin, and fentanyl.

Case 3

A 31-year-old man with a past medical history of IV heroin use, presented to the ED by EMS for CNS and respiratory depression after IV heroin use. The patient’s girlfriend provided the history that the patient was using a new type of heroin called “Santa Muerte.” The patient was given a total of four mg IN naloxone in the field, after which he became agitated, combative, and tachycardic. His vital signs on arrival included a HR of 163 beats per minute, BP of 131/81 mmHg, RR of 29 breaths per minute, SpO2 99% on room air, and oral temperature 98.8 degrees F. While in the ED, he continued to be agitated and combative. On examination, he was tachycardic and flushed with dilated pupils and a palpable full bladder in the suprapubic region. The patient was given a total of 10 mg of lorazepam with minimal improvement of his agitation, and he was later intubated for airway protection. Complete blood count (CBC) and basic metabolic panel (BMP) were unremarkable, and urine drug screening immunoassay was positive for opiates. Serum comprehensive drug screen by LC-MS-MS was positive for heroin, 6-MAM, fentanyl, and negative for any SCs. The patient later developed ARDS, requiring increased ventilator setting and was transferred to a tertiary center for VV-ECMO. Specialty laboratory testing of the patient’s confiscated drug by GC-MS and LCQ-TOF was positive for the novel SC 5F-MDMB-PINACA, heroin, and fentanyl.

Case 4

A 25-year-old man presented to the hospital by EMS after IV heroin use. The patient was found with a drug packet labeled “Santa Muerte” in his pocket and had CNS and respiratory depression. He was given a total of four mg of IN naloxone, after which he became flushed, tachycardic, and agitated with dilated pupils. On arrival to the ED, his HR was 158 beats per minute, BP was 215/158 mmHg, RR was 26 breaths per minute, SpO2 was 99% on room air, and oral temperature was 102.1° F. On exam, he had urinary retention and anhidrosis. He was given four mg of lorazepam and



Image 2. A “50 CAL” drug packet retrieved from a patient, which contained heroin, synthetic cannabinoid, and fentanyl.

two mg of IV physostigmine, which treated his agitation. There was also marked improvement in anhidrosis and urine retention. He was admitted for 24 hours and discharged the following day with no further complications. Urine drug screen was positive for cocaine, opiates, and THC. Serum comprehensive toxicology analysis by LC-MS-MS was positive for 5F-MDMB-PINACA (5F-ADB), heroin, 6-MAM, and fentanyl. Laboratory analysis of the patient’s confiscated drug by GC-MS and LCQ-TOF was positive for the novel SC 5F-MDMB-PINACA, heroin, and fentanyl.

Case 5

A 45-year-old man was found down in the field agitated and tachycardic. On arrival to the ED, his HR was 124 beats per minute, BP 140/82 mm Hg, RR 22 breaths per minute, oxygen saturation 99%, and oral temperature 99.3° F. On exam, he had pinpoint pupils with flushing of skin. He received midazolam five mg and olanzapine 20 mg intramuscular followed by diazepam 10 mg IV after which he calmed down. He was eventually started on dexmedetomidine infusion when his agitation returned. He was admitted for 24 hours and discharged the following day with no complications. Urine drug screen was positive for opiates and fentanyl. He was found with a drug packet named “50 CAL” (Image 2), which was sent for GC-MS and LCQ-TOF and was found to be positive for 5F-MDMB-PINACA, heroin, and fentanyl.

Case 6

A 36-year-old man was found lying in the street unresponsive. He received eight mg of naloxone IN after which he became agitated. On arrival to the ED, his HR was 130 beats per minute, BP 160/100 mm Hg, RR 24 breaths per minute, oxygen saturation 95% on 100 % oxygen, and oral temperature 98.6° F. Initial physical examination revealed

restlessness, confusion, and picking behavior. Patient also had bilaterally dilated pupils with urine retention on point-of-care ultrasound. Considering an anticholinergic toxidrome, the emergency provider administered physostigmine two mg IV with improvement in agitation, picking behavior, urine retention, and relative constriction in pupillary diameter. He had received multiple doses of benzodiazepines prior to physostigmine. He was eventually intubated due to risk of aspiration from vomiting in the setting of altered mental status. His mental status and vitals improved the next day, following which he was extubated. CBC and BMP were unremarkable and urine drug screen was positive for opiates and fentanyl. The patient was found with a blue packet labeled "50 CAL," which was found to be positive for fentanyl, heroin, and 5F-MDMB-PINACA on GC-MS and LCQ-TOF.

Case 7

A 23-year-old woman was brought to the ED with severe agitation and combative behavior. Her initial vitals were HR 156 beats per minute, BP 147/64 mm Hg, RR 20 breaths per minute, and oral temperature 101.5° F. Examination revealed bilaterally dilated pupils, flushed and dry skin, and urine retention on point-of-care ultrasound. The patient received Lorazepam four mg IV and physostigmine two mg IV after which her agitation subsided, urine retention improved, pupillary diameter decreased, and skin appeared less flushed and less dry. CBC and BMP were unremarkable while her urine drug screen was positive for opiates and fentanyl. She was admitted to the floor and discharged the next day. The patient reported consuming a substance from packets labeled "50 CAL." The drug packets were not available for analysis. We were also unable to send her serum or urine for further comprehensive toxicology analysis.

Case 8

A 27-year-old man was brought to the ED after IV heroin use. He was found to be in respiratory and CNS depression with pinpoint pupils in the field by the EMS. Naloxone four mg IN was given after which he became agitated. His vitals were HR 130 beats per minute, BP 130/94 mm Hg, RR 22 breaths per minute, and temperature of 99° F. Initial examination revealed dilated pupils, dry oral mucous membrane, and flushed skin. He received lorazepam 4 mg IV and physostigmine two mg IV after which he calmed down, pupils returned back to normal size, and heart rate came down to normal; he was admitted to the floor. Urine drug screen was positive for opiates and fentanyl. He reported having ingested drugs from packets labeled "Nick" and "50 CAL," but they were unavailable for analysis.

DISCUSSION

Heroin has been historically adulterated with a variety of substances including baking soda, caffeine, acetaminophen,

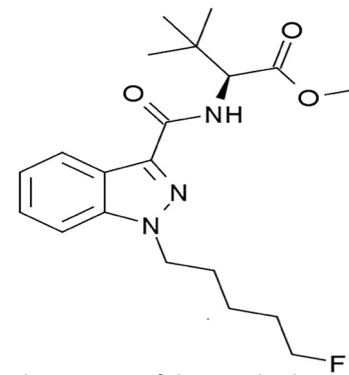


Figure. Chemical structure of the synthetic cannabinoid methyl 2-(1-(5-fluoropentyl)-1H-indazole-3-carboxamido)-3,3-dimethylbutanoate.

diphenhydramine, scopolamine, fentanyl, and clenbuterol.¹ These adulterants are usually added to increase profits by incorporating any substance that looks like the original substance and/or would have the same effect. In the months of April and August 2018, consumption of heroin that had been laced with the newer SC 5F-MDMB-PINACA gave rise to a series of patients presenting to our ED with unique clinical manifestations.

SCs, by themselves, have been widely used as drugs of abuse since the early 2000s. They have been found to have more adverse clinical presentations than the active compound marijuana itself, owing to its full agonistic action on the cannabinoid receptor type 1 (CB1) and cannabinoid receptor type 2 (CB2) receptors, as compared to marijuana, which is only a partial agonist.² Clinical effects of SC overlap with anticholinergic and sympathomimetic toxidromes.^{3,4} There have also been reported fatalities with SCs including 5F-ADB, 5F-PB-22, and AB-CHMINACA.⁵

The patients reported in our case series took opioids containing 5F-MDMB-PINACA (Figure), which is a new generation SC. Except for patient 5, all of them presented with a typical initial opioid toxidrome consisting of CNS and respiratory depression along with pinpoint pupils. Naloxone, an opioid antagonist, was given to them, which triggered severe agitation and combative behavior along with overlapping features of anticholinergic and sympathomimetic toxidrome. This was presumably because of the removal of the depressant effect of opioids by the administration of naloxone that unmasked the effects of SC.

All the patients required multiple doses of benzodiazepines. Three of the eight patients were successfully treated with physostigmine, which helped control the abnormal psychomotor activity and anticholinergic manifestations.

The initial urine drug screen test used for all eight patients was an immunoassay-based screening test. Apart from morphine (opiates), it tests for fentanyl, buprenorphine,

methadone, tramadol, cocaine, oxycodone, phencyclidine, amphetamines, barbiturates, benzodiazepines, and cannabinoids. The comprehensive serum drug screen performed in cases 1, 3 and 4 was through LC-MS-MS, which is an exceedingly sensitive and specific analytical technique that can precisely estimate the identities and concentrations of molecules within a sample.

The seized drug packets were analyzed at the Center for Forensic Science Research and Education, using GC-MS and LCQ-TOF. The samples were prepared using acid/base extraction prior to the analysis.⁶ The drug packets that were analyzed at this facility did not turn positive for any of the anticholinergic agents, thereby leading us to conclude that 5F-MDMB-PINACA potentially has anticholinergic manifestations that seem to be responding to physostigmine in our clinical experience.

CONCLUSION

Heroin contaminated with 5F-MDMB-PINACA exhibits variable severities of anticholinergic effects, some on presentation and others only after opiate antagonism. Synthetic cannabinoids affect cannabinoid CB1 and CB2 receptors, potentially causing adrenergic stimulation, sedation, hallucinations, catecholamine release, and severe tachycardia.²⁻⁴ It is also possible that synthetic cannabinoids and/or their metabolites interact directly with acetylcholine receptors to cause anticholinergic effects. In our case series, we found that physostigmine was effective in reversing the anticholinergic effects and agitation in three out of the eight patients.

The authors attest that their institution requires neither Institutional Review Board approval, nor patient consent for publication of this case report. Documentation on file.

Address for Correspondence: Muhammed Ershad, Einstein Healthcare Network, Division of Medical Toxicology, 5501 Old York Rd., Philadelphia, PA 19141. Email: docershad@gmail.com.

Conflicts of Interest: By the CPC-EM article submission agreement, all authors are required to disclose all affiliations, funding sources and financial or management relationships that could be perceived as potential sources of bias. The authors disclosed none.

Copyright: © 2020 Ershad et al. This is an open access article distributed in accordance with the terms of the Creative Commons Attribution (CC BY 4.0) License. See: <http://creativecommons.org/licenses/by/4.0/>

REFERENCES

1. Hamilton RJ, Perrone J, Hoffman R, et al. A descriptive study of an epidemic of poisoning caused by heroin adulterated with scopolamine. *Clin Toxicol.* 2000;38(6):597-608.
2. Le Boisselier R, Alexandre J, Lelong-Boulouard V et al. Focus on cannabinoids and synthetic cannabinoids. *Clin Pharmacol Ther.* 2017;101(2):220-9.
3. Schwartz MD, Trecki J, Edison LA et al. A common source outbreak of severe delirium associated with exposure to the novel synthetic cannabinoid ADB-PINACA. *J Emerg Med.* 2015;48(5):573-80.
4. Zhang MW and Ho RC. The cannabis dilemma: a review of its associated risks and clinical efficacy. *J Addict Med.* 2015;2015:707596.
5. Angerer V, Jacobi S, Franz F et al. Three fatalities associated with the synthetic cannabinoids 5F-ADB, 5F-PB-22, and AB-CHMINACA. *Forensic Sci Int.* 2017;281:e9-15.
6. Krotulski AJ, Mohr ALA, Logan BK. [Ahead of Print]. Emerging synthetic cannabinoids: development and validation of a novel liquid chromatography quadrupole time-of-flight mass spectrometry assay for real-time detection. *J Anal Toxicol.* January 7, 2020.

Novel, Inexpensive Portable Respiratory Protection Unit (PRPU) for Healthcare Workers

Christopher S. Sampson, MD
Adam Beckett, MD

University of Missouri School of Medicine, Department of Emergency Medicine,
Columbia, Missouri

Section Editor: Rick A. McPheeters, DO

Submission history: Submitted March 27, 2020; Revision received April 8, 2020; Accepted April 6, 2020

Electronically published April 15, 2020

Full text available through open access at http://escholarship.org/uc/uciem_cpem

DOI: 10.5811/cpem.2020.4.47443

Introduction: Given concern for increased aerosolization during intubation of patients with severe acute respiratory syndrome coronavirus, we sought to create a portable, inexpensive, and easily constructed device to help protect healthcare workers.

Methods: A respiratory protection unit can be constructed in approximately 30 minutes and for less than 50 United States dollars in materials, using polyvinylchloride pipe and automobile collision wrap.

Conclusion: This device provides possible increased protection during video laryngoscopy and can easily be replicated. [Clin Pract Cases Emerg Med. 2020;4(2):126–128]

Keywords: COVID-19; intubation; airway.

INTRODUCTION

Based on current evidence, the novel human coronavirus that is named severe acute respiratory syndrome coronavirus 2 (SARS-CoV-2) has been found during experimentation to remain viable when aerosolized for three hours.¹ Current US Centers for Disease Control and Prevention guidelines recommend use of the highest level of personal protective equipment (PPE) when performing aerosolization-potential procedures such as intubation.² Limited studies have shown a possible benefit of barrier protection when performing endotracheal intubation.³ We sought to create an inexpensive and easily reproducible model that could be used in resource-poor or resource rich-environments, or when negative pressure rooms are unavailable due to patient volumes.

METHODS

The following materials were used to construct the portable respiratory protection unit (PRPU): polyvinyl chloride (PVC) ½ inch pipe; PVC joints; and 36-inch wide automobile plastic collision wrap (Table).

PVC pipe can be purchased in one 10-foot piece that can be cut up into 13 pieces with a miter saw or hacksaw. Completed box dimensions are 24 inches tall and 27 inches

Table. Materials required to construct a portable respiratory protection unit.

Materials required
Miter saw or hacksaw
10 feet polyvinyl chloride ½-inch diameter pipe cut into these lengths:
#4 28-inch length
#3 22-inch length
#2 20-inch length
#2 7.5 inch (top bars)
#2 11 inch (bottom bars)
#2 ½-inch “T” fitting
#4 90-degree fittings
#4 3-way fitting
36-inch automobile plastic collision wrap (one roll)

in length. Three-way fittings are used on superior surface for the four joints and two 90-degree fittings are used on base corners. On the posterior (caudal) surface, two “T” fittings are used. Following frame construction, automobile

collision wrap is used to cover each side. Collision wrap is often used in the automotive industry to cover broken car windows and is adhesive on one side. The adhesive side of the wrap faces into the box. Each box can be constructed in approximately 30 minutes by two people (Image 1). Total material cost is less than 50 US dollars.

During intubation, the box is laid over the patient to cover his head and upper chest. Using a knife or any other sharp device, two vertical incisions can be made to place hands through (Image 2). Equipment can be passed through either the incisions or under the bottom of the plastic covering. Ideally the intubation being performed would be video laryngoscopy so that the healthcare worker would not be required to be close to the patient's oropharynx. Following intubation, the box could be removed or ventilator tubing could be passed through incisions in the plastic. To limit ventilator circuit disconnection, tubing could be passed underneath the frame. Following use, the automobile collision wrap can be discarded and the frame can be cleaned according to CDC guidelines with wipes or sprayed down with appropriate cleaning agent. Once dry, a new length of

CPC-EM Capsule

What do we already know about this clinical entity?

Given concern for healthcare worker exposure to aerosolization during intubation of the COVID+ patient, protective barriers have been suggested as a way to lessen risk.

What makes this presentation of disease reportable?

We present an inexpensive device that requires little construction.

What is the major learning point?

A portable respiratory protection unit can easily be replicated at low cost and used in the emergency department setting.

How might this improve emergency medicine practice?

Healthcare workers can be provided with some protection during airway management.



Image 1. Portable respiratory protection unit, constructed of PVC pipe and auto collision wrap, situated on a stretcher in correct position.

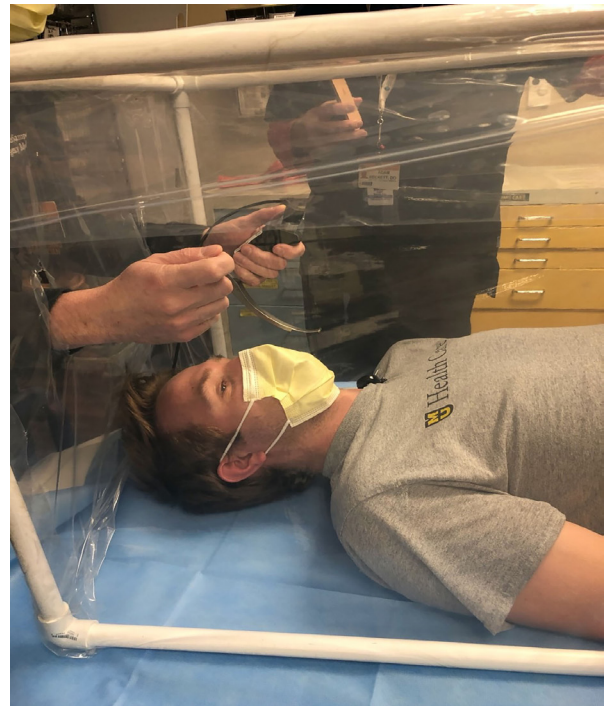


Image 2. Simulated intubation through incisions made in cephalad wall of portable respiratory protection unit.

automobile collision wrap can again be used to cover sides of the device in preparation for the next patient.

DISCUSSION

The PRPU can be assembled rapidly and easily and materials should be readily available in most countries. If auto collision wrap is not readily available, a substitute plastic material could be used; however, depending on the opacity of the material it may further limit direct visualization of the patient. The PRPU use could be expanded beyond the emergency department setting. Other potential uses include protective covering for patients during emergency medical services transport or hospital transport.

LIMITATIONS

Given the ever-changing situation and time-sensitive nature of disseminating this model, we do not have time to trial this model. By no means does this model completely contain aerosol viral particles; therefore, appropriate personal protective equipment should still be worn when intubating any known positive or suspected SARS-CoV-2 patient.

CONCLUSION

The PRPU is an inexpensive and quick to construct a protective device for healthcare workers to use during intubation of high-risk patients such as those with SARS-CoV-2. The device is easy to reuse and has many additional applications.

Appendix. Find the video at: <https://vimeo.com/403079338>.

Documented patient informed consent and/or Institutional Review Board approval has been obtained and filed for publication of this case report.

Address for Correspondence: Christopher Sampson, MD, University of Missouri School of Medicine, Department of Emergency Medicine, One Hospital Drive, Department of Emergency Medicine, Columbia, MO 65212. Email: sampsoncs@health.missouri.edu.

Conflicts of Interest: By the *CPC-EM* article submission agreement, all authors are required to disclose all affiliations, funding sources and financial or management relationships that could be perceived as potential sources of bias. The authors disclosed none.

Copyright: © 2020 Sampson et al. This is an open access article distributed in accordance with the terms of the Creative Commons Attribution ([CC BY 4.0](http://creativecommons.org/licenses/by/4.0/)) License. See: <http://creativecommons.org/licenses/by/4.0/>

REFERENCES

1. Van Doremalen N, Morris DH, Holbrook MG, et al. [Ahead of Print]. Aerosol and surface stability of SARS-CoV-2 as compared with SARS-CoV-1. *New Eng J Med* 2020 Mar 17, 2020.
2. Centers for Disease Control and Prevention. Interim infection prevention and control recommendations for patients with suspected or confirmed coronavirus disease 2019 (COVID-19) in healthcare settings. Available at: <https://www.cdc.gov/coronavirus/2019-ncov/infection-control/control-recommendations.html>. Accessed March 27, 2020.
3. Canelli R, Connor CW, Gonzalez M, et al. [Ahead of Print]. Barrier enclosure during endotracheal intubation. *New Eng J Med*. Apr 3, 2020.

Early Multi-organ Point-of-Care Ultrasound Evaluation of Respiratory Distress During SARS-CoV-2 Outbreak: Case Report

Robert Farrow II, DO, MS
Graham Becherer-Bailey, DO
Daniel Mantuani, MD, MPH
Arun Nagdev, MD

Highland Hospital / Alameda Health System, Department of Emergency Medicine,
Oakland, California

Section Editor: Rick A. McPheeters, DO

Submission history: Submitted April 1, 2020; Revision received April 8, 2020; Accepted April 7, 2020

Electronically published April 15, 2020

Full text available through open access at http://escholarship.org/uc/uciem_cpccem

DOI: 10.5811/cpcem.2020.4.47524

Introduction: Coronavirus disease 2019 (COVID-19) is caused by the virus known as severe acute respiratory syndrome coronavirus 2 (SARS-CoV-2). Several case series from Italy and China have highlighted the lung ultrasound findings of this disease process and may demonstrate its clinical utility during the current pandemic.

Case Report: We present a case of a COVID-19 patient who presented to the emergency department twice within a 24-hour period with rapidly progressing illness. A multi-organ point-of-care ultrasound (POCUS) evaluation was used on the return visit and assisted clinical decision-making.

Discussion: A multi-organ POCUS exam allows for quick assessment of acute dyspnea in the emergency department. As the lung involvement of COVID-19 is primarily a peripheral process it is readily identifiable via lung ultrasound. We believe that when applied efficiently and safely a POCUS exam can reduce clinical uncertainty and potentially limit the use of other imaging modalities when treating patients with COVID-19.

Conclusion: This case highlights the utility of an early multiorgan point-of-care assessment for patients presenting with moderate respiratory distress during the severe SARS-CoV-2 pandemic. [Clin Pract Cases Emerg Med. 2020;4(2):129–133]

Keywords: COVID-19; SARS-CoV-2; ultrasound; respiratory distress.

INTRODUCTION

Point-of-care ultrasound (POCUS) examinations of patients with acute respiratory distress have been demonstrated to be useful for patients with acute unexplained dyspnea in the emergency department (ED).¹ Multiple previous ED studies have demonstrated the ability of clinicians to rapidly and accurately differentiate a cardiac etiology (specifically acute decompensated congestive heart failure) versus other causes of acute dyspnea.^{1,2} In our early experience during the severe acute respiratory syndrome coronavirus 2 (SARS-CoV-2) outbreak, with multiple patients presenting with acute dyspnea of suspected parenchymal

pulmonary pathology, we found that the prompt differentiation between an underlying cardiac versus pulmonary source can be instrumental in both triage and early resuscitation.

Early reports from China detailed the utility of computed tomography (CT) in demonstrating the classic multifocal, ground-glass opacities that are commonly present in patients with pulmonary manifestations of the rapidly progressing viral pandemic.³ Our early, multi-organ ultrasound first strategy in the evaluation of the severely dyspneic patient centers on not assuming all patients who arrive in our ED during this large wave of patients are purely pulmonary in nature (even though we recognize the high prevalence of disease), and

using a multi-organ POCUS examination to help guide initial treatment and resuscitation. We also believe that incorporating a system-based approach in this manner will allow a reduction in CT imaging and reduce the ever-present issues of departmental contamination and CT disinfection.

Recent studies out of China have detailed ultrasound findings associated with coronavirus disease 2019 (COVID-19).^{4,5} While these findings are not specific, they are likely clinically useful in patients with severe dyspnea in conjunction with a multi-organ evaluation of cardiac function and the inferior vena cava (IVC). Furthermore, we believe that these non-specific ultrasound findings can be used in conjunction with clinical and laboratory parameters to assist defining pulmonary involvement of SARS-CoV-2, especially as it typically involves peripheral lesions near the pleura, which are well demonstrated on lung ultrasound. Herein we present a case of SARS-CoV-2 related multifocal pneumonia diagnosed by POCUS in the ED during the initial triage of a return ED visit, which highlights its clinical utility and our proposed imaging pathway for evaluating patients with acute dyspnea during the current SARS-CoV-2 outbreak.

CASE REPORT

A 56-year-old female with a past medical history of asthma and dyslipidemia presented to a community ED with one week of fever, non-productive cough, dyspnea, headache, nausea and vomiting. She denied smoking history or drug use. Travel history was significant for returning home from an amusement park in Los Angeles one week prior to onset of symptoms. Vital signs at triage were temperature (oral) 38.6° Celsius; heart rate 117 beats per minute; respiratory rate 20 breaths per minute; and pulse oximetry 93% on room air.

Clinical Course on First Emergency Department Visit

Significant laboratory results were as follows: rapid influenza diagnostic test was negative; white blood cells 11.7 10^3 per microliter (mL) (reference range 4.5-11.5 10^3 /mL), neutrophils relative 92% (reference 50-70%), lymphocyte absolute 0.55 10^3 /mL (reference 0.8-4.80 10^3 /mL), and lactic acid was 1.0 millimoles per L (reference 0.5-2.2 mmol). A two-view chest radiograph (CXR) was interpreted by the radiologist as pneumonia of the left lower lobe with interstitial changes (Image 1). After symptomatic therapy and a first dose of azithromycin, the patient was discharged home with instructions to continue antibiotic therapy and return for worsening symptoms.

Clinical Course Second Emergency Department Visit

Approximately 12 hours after discharge the patient returned to the same ED with worsening dyspnea. Upon arrival she was noted to be ill appearing, tachypneic and with moderate respiratory distress despite similar triage vital signs as the initial ED visit. Her lung exam was significant for poor inspiratory effort and rhonchi at the bases. A multi-organ

CPC-EM Capsule

What do we already know about this clinical entity?

The virus severe acute respiratory syndrome coronavirus 2 can cause severe pulmonary infection and inflammatory response in patients presenting during the coronavirus disease 2019 (COVID-19) pandemic.

What makes this presentation of disease reportable?

This case highlights the rapid progression of COVID-19 pneumonia and the utility of point-of-care-ultrasound (POCUS) in excluding alternative causes of dyspnea.

What is the major learning point?

Multiorgan-POCUS is useful for ED evaluation of dyspnea during the COVID-19 pandemic due to the peripheral nature of lung involvement.

How might this improve emergency medicine practice?

Multiorgan-POCUS has the potential to reduce diagnostic uncertainty in dyspneic patients and help limit use of other imaging modalities.

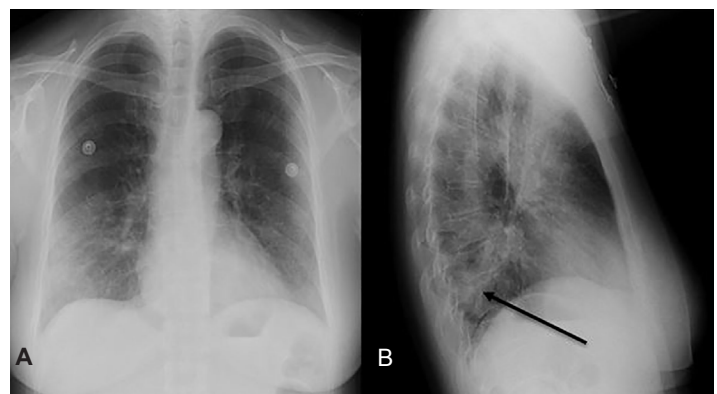


Image 1. Chest radiographs of the initial emergency department visit. Patient was dyspneic at the time. A) Posterior-anterior view demonstrating prominent interstitial markings in the mid and lower lung field bilaterally; and B) Lateral view with apparent area of retrocardiac opacity (arrow) likely representing an early consolidation in the left lateral lobe.

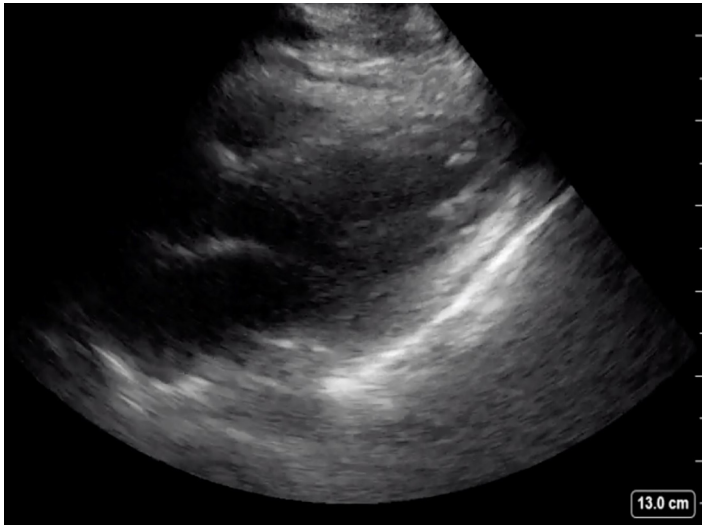


Image 2. Normal systolic ejection fraction determined by parasternal long-axis view. Image acquisition via Sonosite X-Porte system using phased array probe.

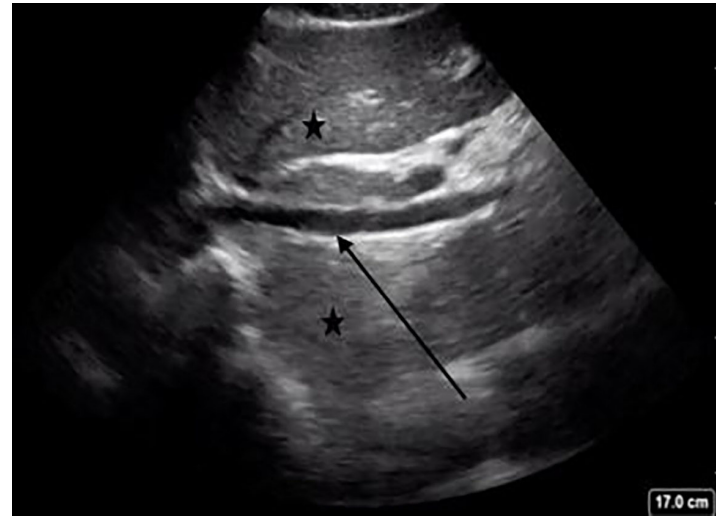

Image 3. The inferior vena cava (arrow) was determined to be non-plethoric and collapsible with respiration. In this image, the inferior vena cava is surrounded by the liver (stars). Image acquisition via Sonosite X-Porte system using phased array probe.

POCUS exam was performed to determine the cause of the patient's dyspnea.

A cardiac parasternal long-axis view demonstrated normal systolic ejection fraction and no pericardial effusion (Image 2). The IVC in the subxiphoid view showed greater than 50% collapse during inspiration (Image 3). A lung exam using a low frequency (5-2 megahertz) curvilinear transducer in the anterior, lateral, and posterior portions, showed the presence of diffuse scattered B-lines with small subpleural consolidations and effusions in each lung zone, with confluent B-lines in the posterior inferior lobes bilaterally (Image 4). POCUS findings were interpreted as the presence of a non-cardiogenic multifocal interstitial lung process with COVID-19 being high on the differential. The patient was placed in a negative pressure room, and all staff were informed to wear full personal protective equipment when interacting with the patient.

Based on the POCUS multi-organ findings, the patient was resuscitated with an intravenous bolus normal saline and treated with broad-spectrum antibiotics (levofloxacin). SARS-CoV-2 oropharyngeal and nasopharyngeal swabs were sent from the ED for testing. The infectious disease consultant agreed with a plan for admission and continuation of droplet, airborne, and contact precautions given the progression of symptoms and worsening respiratory status. She was admitted to a negative pressure room on the medical floor for continued therapy and monitoring of respiratory status. An eventual non-contrast CT of the chest demonstrated diffuse multifocal infiltrates (Image 5).

As an inpatient, the patient's antibiotic regimen was adjusted to doxycycline and cefepime. She was under observation and

isolation for six days at the hospital of presentation. At this point the SARS-CoV-2 testing had not yet resulted, but her clinical course had improved. She was discharged home with instructions to self-quarantine at home or return to the ED if symptoms worsened. SARS-CoV-2 testing resulted the day after discharge as positive for SARS-CoV-2 ribonucleic acid.

DISCUSSION

During the current SARS-CoV-2 pandemic, prompt evaluation of patients in the ED presenting with acute dyspnea is imperative. Diagnostic testing of SARS-CoV-2 has been limited to date, and in our setting will not result during a typical ED visit. Likewise, serum laboratory markers for both SARS-CoV-2 associated pneumonia and non-SARS-CoV-2 causes of acute dyspnea (decompensated heart failure, chronic obstructive pulmonary disease/asthma, pulmonary embolism) are non-specific, are also not immediately resulted, and are of limited value during the initial hospital presentation.

The role of imaging during the SARS-CoV-2 outbreak is still being established. A study of patients diagnosed with COVID-19 in Wuhan, China, demonstrated a progression of disease by CT imaging from early subclinical/asymptomatic patients with unilateral and multifocal ground-glass opacities to patients with less than one week of symptoms showing bilateral disease and transition to consolidation and interstitial changes.⁶ However, the American College of Radiology recently issued guidance that CT should not be used as a first-line test to diagnose acute SARS-CoV-2 infection, and that limiting the use of portable radiography should be attempted to reduce transmission.⁷

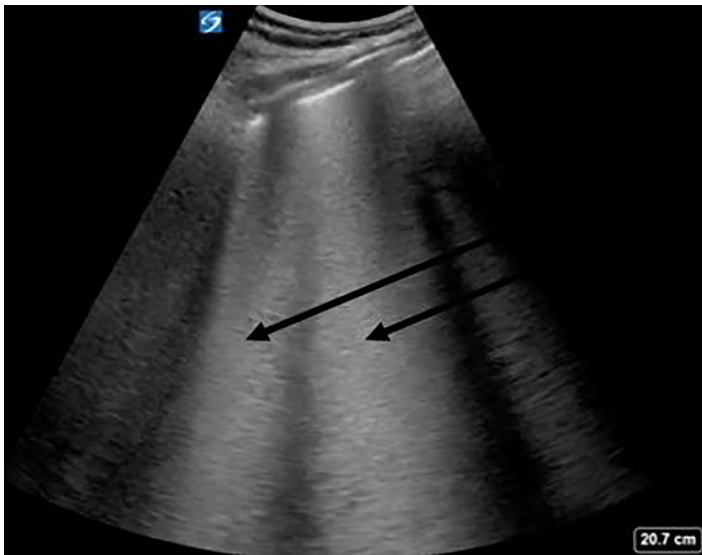

Image 4. Confluent B-lines were seen in all lung fields with increased density in the posterior lateral sections. The arrows denote B-lines that were interpreted as pulmonary infiltrates due to depth and confluence. Image acquisition via Sonosite X-Porte system using curvilinear probe.

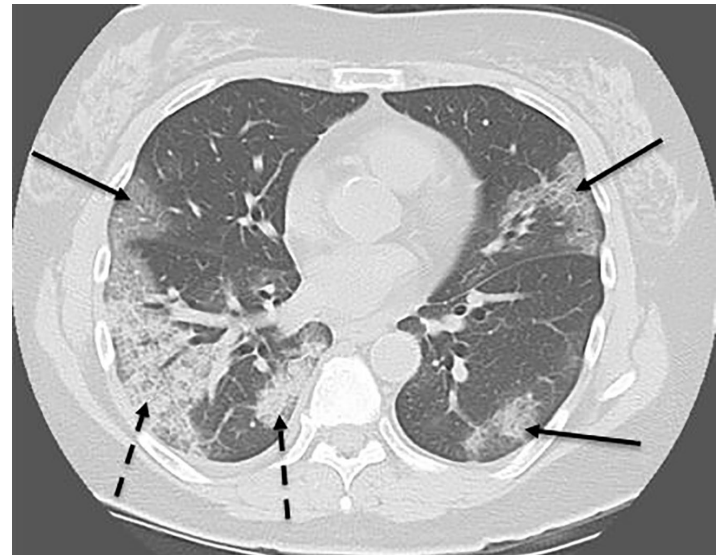


Image 5. Computed tomography of the chest without contrast in an axial cut showing diffuse multifocal infiltrates (solid arrows) with areas of consolidation and increased infiltrates in the posterior segments (dashed arrows).

POCUS holds some distinct advantages over other imaging modalities especially in times of disaster or pandemic. The characteristic ultrasonographic findings of interstitial pneumonia near the pleura are accessible, rapidly attained and reliable markers of pathology. Lung ultrasound has been shown to be more sensitive than CXR for pneumonia and pulmonary edema.^{8,9} In our anecdotal experience, ultrasonographic features of COVID-19 may be detectable earlier or more reliably than on CXR. Additionally, while assessing for findings of interstitial pneumonia, basic cardiac and IVC imaging is easily obtainable and can offer information in regard to the presence of an alternative pathology and guide resuscitation.

While the majority of patients infected with SARS-CoV-2 will experience only mild illness, a subset will progress to multifocal pneumonia, acute respiratory distress syndrome, and cardiomyopathy¹⁰⁻¹² pathologies that can be identified rapidly with POCUS.^{8,9,13-15}

CONCLUSION

The above case highlights the utility of a multiorgan approach in the evaluation of the acutely dyspneic patient during the SARS-CoV-2 pandemic. Along with lung ultrasound findings that have been described in China and Italy, we believe that the evaluation of the heart and IVC are easily obtained and extremely useful for two important reasons. First, this approach allows to rapidly determine other common causes of dyspnea in the undifferentiated patient. Second, with a more protocolized pathway on early presentation, we hope to reduce the reliance on other

imaging modalities (chest radiographs and CT) in a time when infection control is imperative. In our experience, a multi-organ ultrasound first approach for all severely dyspneic patients is an ideal approach during the global SARS-CoV-2 pandemic and especially as healthcare resources become increasingly strained.

The authors attest that their institution requires neither Institutional Review Board approval, nor patient consent for publication of this case report. Documentation on file.

Address for Correspondence: Robert Farrow, DO, Highland Hospital/Alameda Health System, Department of Emergency Medicine, 1411 East 31st Street, Oakland, CA 94602. Email: rfarrow@alamedahealthsystem.org.

Conflicts of Interest: By the CPC-EM article submission agreement, all authors are required to disclose all affiliations, funding sources and financial or management relationships that could be perceived as potential sources of bias. The authors disclosed none.

Copyright: © 2020 Farrow et al. This is an open access article distributed in accordance with the terms of the Creative Commons Attribution (CC BY 4.0) License. See: <http://creativecommons.org/licenses/by/4.0/>

REFERENCES

1. Lichtenstein DA and Mezière GA. Relevance of lung ultrasound in the diagnosis of acute respiratory failure: the BLUE protocol. *Chest* 2008;134(1):117-25.
2. Mantuani D, Nagdev A, Stone M. Three-view bedside ultrasound for the differentiation of acute respiratory distress syndrome from cardiogenic pulmonary edema. *Am. J. Emerg. Med.* 2012;30(7):1324.e1-4.
3. Zhou F, Yu T, Du R, et al. Clinical course and risk factors for mortality of adult inpatients with COVID-19 in Wuhan, China: a retrospective cohort study. *Lancet* 2020;395(10229):1054-62.
4. Peng QY, Wang XT, Zhang LN, et al. (Ahead of Print). Findings of lung ultrasonography of novel corona virus pneumonia during the 2019-2020 epidemic. *Intensive Care Med.* March 12, 2020.
5. Huang Y, Wang S, Liu Y, et al. [Ahead of Print]. A preliminary study on the ultrasonic manifestations of peripulmonary lesions of non-critical novel coronavirus pneumonia (COVID-19). *SSRN Journal.* February 28, 2020.
6. Shi H, Han X, Jiang N, et al. [Ahead of Print]. Radiological findings from 81 patients with COVID-19 pneumonia in Wuhan, China: a descriptive study. *Lancet Infect. Dis.* February 24, 2020.
7. American College of Radiology. 2020. ACR recommendations for the use of chest radiography and computed tomography (CT) for suspected COVID-19 infection | American College of Radiology. Available at: <https://www.acr.org/Advocacy-and-Economics/ACR-Position-Statements/Recommendations-for-Chest-Radiography-and-CT-for-Suspected-COVID19-Infection>. Accessed March 25, 2020.
8. Liu X, Lian R, Tao Y, et al. Lung ultrasonography: an effective way to diagnose community-acquired pneumonia. *Emerg Med. J.* 2015;32(6):433-8.
9. Pivetta E, Goffi A, Lupia E, et al. Lung ultrasound-implemented diagnosis of acute decompensated heart failure in the ED: A SIMEU Multicenter Study. *Chest* 2015;148(1):202-10.
10. Yang X, Yu Y, Xu J, et al. [Ahead of Print]. Clinical course and outcomes of critically ill patients with SARS-CoV-2 pneumonia in Wuhan, China: a single-centered, retrospective, observational study. *Lancet Respir. Med.* February 24, 2020.
11. Wang D, Hu B, Hu C, et al. [Ahead of Print]. Clinical characteristics of 138 hospitalized patients with 2019 novel coronavirus-infected pneumonia in Wuhan, China. *JAMA.* February 7, 2020.
12. Guo T, Fan Y, Chen M, et al. [Ahead of Print]. Cardiovascular implications of fatal outcomes of patients with coronavirus disease 2019 (COVID-19). *JAMA Cardiol.* March 27, 2020.
13. Moore CL, Rose GA, Tayal VS, et al. Determination of left ventricular function by emergency physician echocardiography of hypotensive patients. *Acad Emerg Med.* 2002;9(3):186-93.
14. Lichtenstein D, Goldstein I, Mourgeon E, et al. Comparative diagnostic performances of auscultation, chest radiography, and lung ultrasonography in acute respiratory distress syndrome. *Anesthesiology* 2004;100(1):9-15.
15. Al Deeb M, Barbic S, Featherstone R, et al. Point-of-care ultrasonography for the diagnosis of acute cardiogenic pulmonary edema in patients presenting with acute dyspnea: a systematic review and meta-analysis. *Acad. Emerg. Med.* 2014;21(8):843-52.

Urethral Calculi

Perry Lee, MD
Jordana Haber, MD

University of Las Vegas, Department Emergency Medicine, Las Vegas, Nevada

Section Editor: John Ashurst, DO

Submission history: Submitted March 24, 2019; Revision received May 30, 2019; Accepted May 31, 2019

Electronically published February 24, 2020

Full text available through open access at http://escholarship.org/uc/uciem_cpchem

DOI: 10.5811/cpchem.2019.5.43182

Urolithiasis is a condition with calculi commonly found within the kidney, ureter, or bladder. The urethra is an uncommon location of urolithiasis, with limited case reports and literature reviews of its presentation and management. Here we discuss a 24-year-old female who presented with urinary urgency, flank pain, and urinary retention for 12 hours. Physical exam showed a calculus at the urethral meatus. This case discusses the manual removal of a urethral calculus in a female patient with use of forceps, resulting in complete resolution of symptoms and urinary retention. [Clin Pract Cases Emerg Med. 2020;4(2):134–136.]

INTRODUCTION

Urolithiasis is a common condition seen in the emergency department (ED) that most often presents with calculi located in the kidney, ureter, or bladder. An obstructing calculi located at the urethra is an uncommon presentation where the management options are unique to its location.¹ There are limited case reports and literature reviews of urethral calculi and management in the emergency setting. In this case report, we discuss the presentation, physical exam, imaging studies, diagnosis, and manual removal of a urethral calculi.

CASE REPORT

A 24-year-old female with past medical history of nephrolithiasis presented to the ED complaining of urinary urgency, left flank pain, and urinary retention over the previous 12 hours. She spontaneously passed a renal stone one week prior at home with planned follow-up with her urologist in three days. She had been taking nitrofurantoin over the past year as prophylaxis for recurrent urinary tract infections.

Initial vital signs included temperature of 37.1° Celsius (98.7° Fahrenheit), heart rate 104 beats per minute, blood pressure 126/87 millimeters of mercury, and respiratory rate 22 breaths per minute. Initial physical exam showed a mildly uncomfortable appearing female who was non-toxic. She had left flank tenderness to deep palpation with no midline bony spinal tenderness. Abdomen was soft, non-tender, and non-distended with no palpable pulsatile mass.

The patient's blood work ordered by the triage physician was significant for a leukocytosis with white blood cell count of 14.3

thousand per cubic millimeter (K/mm³) (reference range 3.7 to 10.6 K/mm³). All other blood work was within normal limits, including a creatinine of 0.8 milligrams per deciliter (mg/dL) (reference range 0.6 to 1.5 mg/dL). Pregnancy test was negative. Computed tomography (CT) of the abdomen and pelvis without contrast ordered by the triage physician showed a distended urinary bladder with multiple bladder stones and mild left hydroureter (Image 1).

No urine sample had been provided for a urine analysis after two hours of arrival and a catheter sample was ordered. The patient's nurse reported difficulty finding the urethra for catheter placement and requested assistance. A pelvic exam was then performed showing a calculus at the urethral meatus (Image 2).

An initial attempt to manually remove the calculus using topical lidocaine gel and direct pressure on the stone through the vaginal canal was unsuccessful. A second attempt at calculus removal was successful by grasping the calculus with a hemostatic forceps (Image 3).

The patient was able to immediately void without difficulty after the 15 mm calculus was removed. She was discharged in improved condition with an outpatient urology follow-up.

DISCUSSION

Urolithiasis is a common condition with an increasing number of ED visits reported over the past decade.² It is well established that stone size and location are the major determinant of spontaneous passage with most calculi less than 5 mm passing spontaneously and calculi more than 10 mm unlikely to spontaneously pass.^{3,4} Additionally, there has

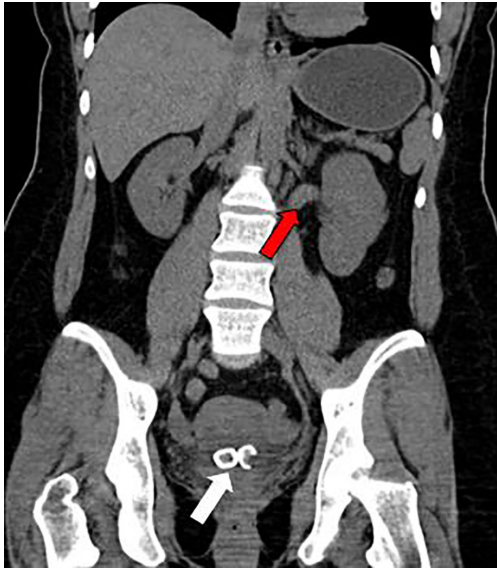


Image 1. Computed tomography of the abdomen and pelvis without contrast (coronal view) showing bladder calculi (white arrow) and hydronephrosis (red arrow).

been an increase in prevalence of women diagnosed with urolithiasis in a previously male-predominant disease.⁵

Urethral calculi are the rarest presentation of urolithiasis with no established prevalence and no standardized management and treatment.¹ In a literature review, we found the presentation and management of urethral calculi to be limited to case reports and small literature reviews. Additionally, the majority of case reports are of male patients. One case report documented a 22-year-old male presenting with penile pain and urinary retention, who was found to have a urethral calculus on bedside ultrasound and ultimately underwent lithotripsy by urology.⁵ Another reported a 54-year-old male with a urethral calculus who underwent open surgery by urology for calculus removal.⁷ A final case report documented a 64-year-old female with urinary retention and a urethral calculus that could not be extracted manually. She required pneumatic lithotripsy through a rigid cystoscope under spinal anesthesia.⁸

A study of 34 male patients with urethral stones showed a safe and effective treatment approach by retrograde manipulation of the calculi with a 16 French foley urethral catheter prior to endoscopic or extracorporeal shock wave lithotripsy.⁹ This approach requires general anesthesia and does carry intrinsic risk of bladder and urethral trauma.

CONCLUSION

Urethral calculus is a rare presentation of urolithiasis. This rare case demonstrates successful management of a urethral calculus in a female patient by manual removal of the calculus with forceps. In specific cases, direct manual removal of a

CPC-EM Capsule

What do we already know about this clinical entity?

Urethral calculi are an uncommon presentation of a urolithiasis, a common condition that most often presents with calculi located in the kidney, ureter, or bladder.

What makes this presentation of disease reportable?

An obstructing calculi located at the urethra is an uncommon presentation where the management options are unique to its location.

What is the major learning point?

In specific cases, direct manual removal of a urethral calculus with forceps can be a definitive treatment while avoiding invasive treatment and possible associated complications.

How might this improve emergency medicine practice?

This case discusses a possible solution in an uncommon presentation with limited case reports and literature reviews of urethral calculi and management in the emergency setting.

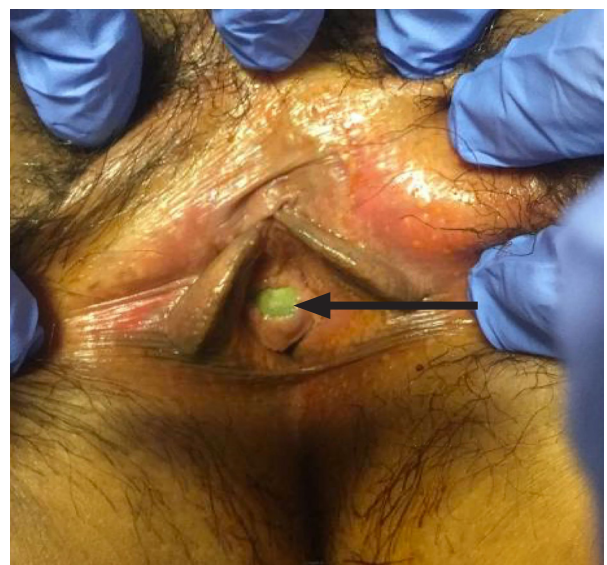

Image 2. Urethral calculus at the urinary meatus on external pelvic exam (arrow).

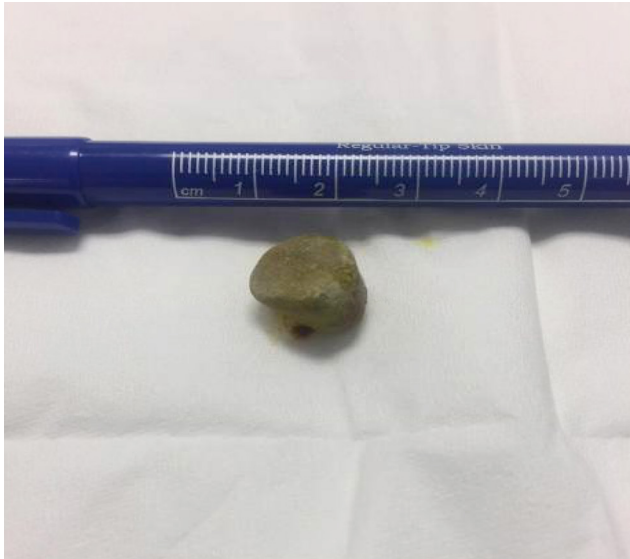

Image 3. 15-millimeter urethral calculus post-manual removal.

urethral calculus with forceps can be a definitive treatment resulting in complete resolution of symptoms and urinary retention while avoiding invasive procedures and possible associated complications.

REFERENCES

1. Koga S, Arakaki Y, Matsuoka M, et al. Urethral calculi. *Br J Urol.* 1990;65(3):288-9.
2. Fwu CW, Eggers PW, Kimmel PL, et al. Emergency department visits, use of imaging, and drugs for urolithiasis have increased in the United States. *Kidney Int.* 2013;83(3):479-86.
3. Miller OF and Kane CJ. Time to stone passage for observed ureteral calculi: a guide for patient education. *J Urol.* 1999;162(3 Pt 1):688-90.
4. Coll DM, Varanelli MJ, Smith RC. Relationship of spontaneous passage of ureteral calculi to stone size and location as revealed by unenhanced helical CT. *AJR Am J Roentgenol.* 2002;178(1):101-3.
5. Scales CD Jr, Curtis LH, Norris RD, et al. Changing gender prevalence of stone disease. *J Urol.* 2007;177(3):979-82.
6. Cakir U, Ozlem Y, Kesapli M, et al. Bedside ultrasound diagnosis of urethral calculus in emergency department. *JAD.* 2016;5(5):437-8.
7. Kaczmarek K, Golab A, Soczawa M, et al. Urethral stone of unexpected size: case report and short literature review. *Open Med (Wars).* 2016;11(1):7-10.
8. Sungur M, Baykam M, Calışkan S, et al. Urethral calculi: a rare cause of acute urinary retention in women. *Turk J Emerg Med.* 2018;18(4):170-1.
9. el-Sherif AE and Prasad K. Treatment of urethral stones by retrograde manipulation and extracorporeal shock wave lithotripsy. *Br J Urol.* 1995;76(6):761-4.

Documented patient informed consent and/or Institutional Review Board approval has been obtained and filed for publication of this case report.

Address for Correspondence: Perry Lee, MD, University of Las Vegas, Department of Emergency Medicine, 901 Rancho Lane Suite 135, Las Vegas, NV 89106. Email: perrylee11@gmail.com.

Conflicts of Interest: By the *CPC-EM* article submission agreement, all authors are required to disclose all affiliations, funding sources and financial or management relationships that could be perceived as potential sources of bias. The authors disclosed none.

Copyright: © 2020 Lee et al. This is an open access article distributed in accordance with the terms of the Creative Commons Attribution ([CC BY 4.0](http://creativecommons.org/licenses/by/4.0/)) License. See: <http://creativecommons.org/licenses/by/4.0/>

An Early Holiday Surprise: Cholecystitis Wrapped in Takotsubo Cardiomyopathy

Kevin Gould, MD
Stephen Miller, DO
Joel Moll, MD

Virginia Commonwealth University, Department of Emergency Medicine,
Richmond, Virginia

Section Editor: Scott Goldstein, MD

Submission history: Submitted October 8, 2019; Revision received January 13, 2020 Accepted January 6, 2020

Electronically published March 2, 2020

Full text available through open access at http://escholarship.org/uc/uciem_cpem

DOI: 10.5811/cpcem.2020.1.45474

This is a novel case report of a 44-year-old woman who presented to the emergency department with epigastric pain wrapping around to her back. She had no risk factors for cardiac disease, but her initial electrocardiogram (ECG) showed a Wellens syndrome pattern and she was taken urgently to the catheterization lab. After a negative catheterization, she underwent cardiac magnetic resonance imaging, which was positive for Takotsubo cardiomyopathy (TC). Ultimately, abdominal computed tomography revealed that she had cholecystitis, which likely was the cause of her TC and ECG changes. [Clin Pract Cases Emerg Med. 2020;4(2):137–141.]

INTRODUCTION

Takotsubo cardiomyopathy (TC), also known as stress cardiomyopathy, is a rare but dangerous condition that can be encountered in the emergency department (ED). TC can be difficult to diagnose as it can present as chest pain or abdominal pain; it is often identified after the fact by way of cardiac magnetic resonance imaging. There are known electrocardiographic (ECG) changes as well as transthoracic echocardiogram findings, but these can be subtle.^{1,2} We present a case report of a middle-aged female who presented to the ED with abdominal pain and was found to have concerning changes on her ECG.

CASE REPORT

A 44-year-old female with past medical history significant for gastroesophageal reflux disease, depression, insomnia, and cervical cancer in remission presented in mid-December via private vehicle to the ED with epigastric pain since the prior evening. The patient had attempted treatment at home with over-the-counter antacids without relief. She described her pain as epigastric burning, wrapping around her chest to her back, with associated diaphoresis, nausea, and vomiting. She denied fevers, hematemesis, dysuria, or vaginal discharge. The patient's cervical cancer had been treated with total abdominal hysterectomy, chemotherapy, and radiation. Her only daily medication was hormone replacement therapy. She reported

drinking one alcoholic beverage per day but denied tobacco or drug use. Family history was notable for coronary artery disease in her mother, who died of a myocardial infarction at age 54.

The patient's vital signs in triage were as follows: heart rate 77 beats per minutes; blood pressure 150/90 millimeters of mercury; respiration rate 15 breaths per minute; temperature: 36.8° Celsius; and oxygen saturation 98%. Pain was 9/10 (epigastric). An ECG was immediately obtained (Image 1). The ECG showed possible ischemia due to deep t-wave inversions across leads V1-4, and the patient was placed on a cardiac monitor.

The patient's physical exam revealed marked right upper quadrant and epigastric tenderness with a positive Murphy's sign. Her initial labs showed mild hyponatremia (133 milligrams [mg] per deciliter), leukocytosis (18.6 thousand) and troponin-I of 0.18 (normal range: < 0.03 – 0.39 nanograms per milliliter). Cardiology was urgently consulted and a stat bedside transthoracic echo showed septal wall motion abnormalities, possible apical hypokinesis, and an estimated left ventricular ejection fraction (LVEF) of 45-50%. Repeat ECG during cardiology evaluation (Image 2) showed a new left bundle branch block (LBBB). Due to the new LBBB and t-wave inversions on initial ECG concerning for Wellens syndrome the patient was given 324 mg aspirin, 4000 units heparin, 180 mg ticagrelor, and emergently taken to the catheterization lab.

A left heart catheterization was performed and revealed no significant coronary artery disease. Upon admission to the cardiac intensive care unit (ICU), the patient continued to complain of epigastric pain for which she received acetaminophen/oxycodone, pantoprazole, and a gastrointestinal (GI) cocktail that helped relieve her pain. Chest and abdominal plain radiographs obtained shortly thereafter did not show any acute pathology.

That evening, the patient underwent computed tomography abdomen/pelvis with intravenous (IV) contrast, which demonstrated gallbladder wall thickening with gallstones in both the gallbladder and cystic duct. The patient was started on empiric IV piperacillin-tazobactam. Gastroenterology and general surgery were consulted. Overnight the patient remained afebrile and her pain fully resolved.

To help elucidate the cause of the patient's wall motion abnormalities, a cardiac magnetic resonance imaging (MRI) was performed the following day. The MRI was significant for apical ballooning of the left ventricle with an ejection fraction of 49% (Image 3). Based on these findings the patient was diagnosed with Takotsubo cardiomyopathy.

The patient was transferred from the cardiac ICU to the floor, and elected conservative management of her cholecystitis via dietary changes and surgical follow-up. At discharge on hospital day 3, she was started on metoprolol 25 mg twice daily and lisinopril 5 mg daily for blood pressure control and cardiac remodeling protection. She underwent an outpatient laparoscopic cholecystectomy approximately two months later. At her three-month cardiology follow-up, the patient had persistent LBBB and her transthoracic echo showed LVEF of 55-60% with paradoxical septal wall motion, but there was no apical ballooning. At six months post-diagnosis, she had had no further episodes of TC.

CPC-EM Capsule

What do we already know about this clinical entity?
Takotsubo cardiomyopathy (TC) can present in concert with a variety of other conditions and its presentation mimics acute coronary syndrome.

What makes this presentation of disease reportable?
TC can present in a myriad of ways, in this case, due to cholecystitis. If TC is missed, it could lead to hemodynamic compromise and a potentially bad outcome.

What is the major learning point?
Cholecystitis can cause TC.

How might this improve emergency medicine practice?
Providers should keep TC on the differential for patients presenting with chest pain, as well as those presenting with abdominal pain.

DISCUSSION

The patient's chief complaint of epigastric pain has a wide differential that includes both abdominal and thoracic etiologies. Differential diagnoses include esophagitis, esophageal spasm, gastroesophageal reflux, gastritis, peptic ulcer disease, biliary colic, cholecystitis, cholangitis, esophageal rupture, pancreatitis and, because many of these conditions can mimic acute coronary syndrome (ACS), a consideration of myocardial

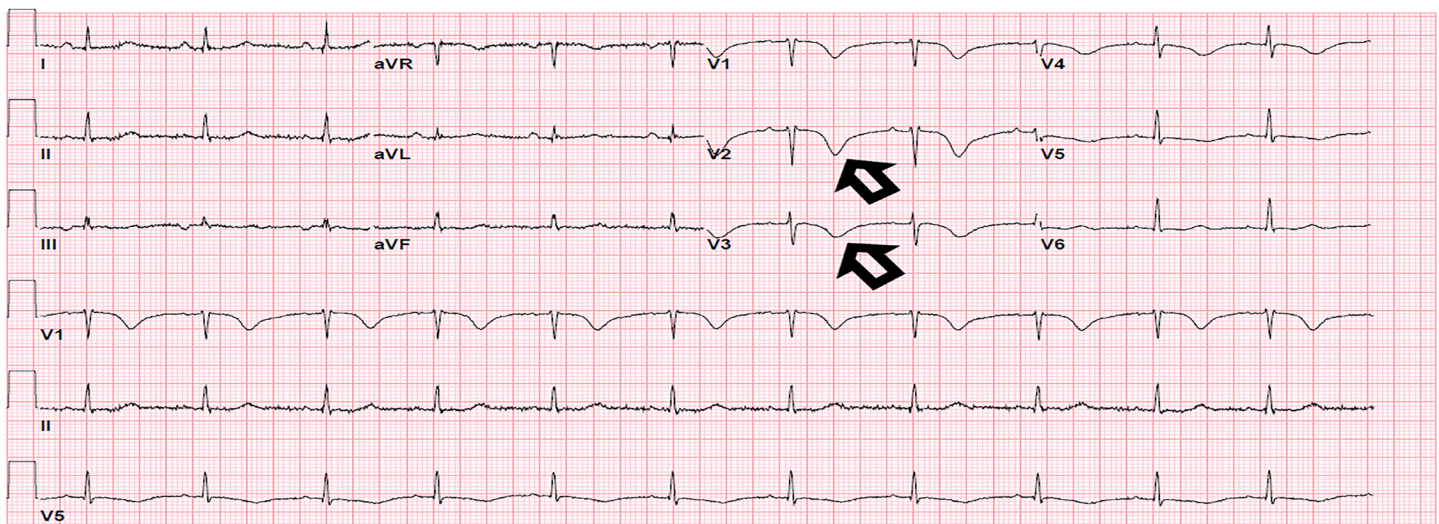


Image 1. Initial electrocardiogram with Wellen's syndrome morphology.

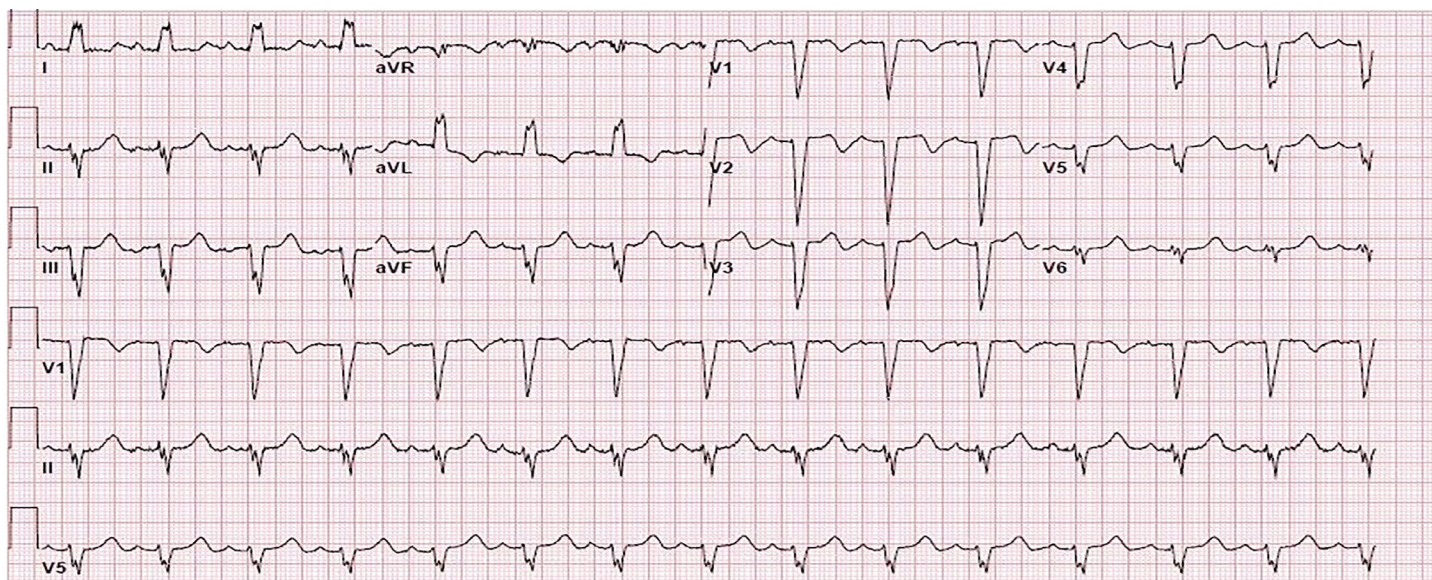


Image 2. Electrocardiogram approximately one hour after arrival showing new left bundle branch block.

ischemia is warranted. A meta-analysis of ACS presentations to both primary care and the ED found that for those presenting with epigastric pain, there was a 91% specificity (95% confidence interval [CI], 85.0-95.4) but only a 5% sensitivity (95% CI, 2.1-10.8)³ with relation to acute coronary ischemia. This, coupled with the National Registry of Myocardial Infarction II study, which found that 33% of patients with acute myocardial ischemia present without chest pain,⁴ places ACS in the differential for any patient who presents with GI symptoms. Additionally, women with acute coronary ischemia are more likely to present with atypical, non-chest pain and are at a higher risk of discharge from the ED, especially if they are <55 years old (odds ratio [OR] [6.7], 95% CI, 1.3-32.5).⁵

The patient's initial ECG was concerning for Wellens syndrome, a condition most commonly associated with critical stenosis of the left anterior descending (LAD) artery and increased risk of anterior wall myocardial infarction if not treated with percutaneous coronary intervention. Wellens syndrome can present with one of two t-wave abnormalities: a biphasic T-wave (type A, sometimes referred to as a "saddle wave," occurs in 25% of cases) and a deeply inverted T-wave (type B, occurs in 75% of cases).⁶ This change happens in V2-3 but may extend to V1-6. Wellens types A and B can be seen as T-wave changes along a continuum, as initial LAD occlusion will lead to type A changes and reperfusion can lead to type B changes. These changes can occur in a "stuttering" format if the LAD occlusion causes intermittent ischemia, with reoccurrences of type A and B morphologies.⁶ Wellens syndrome can also manifest due to vasospasm when no LAD stenosis is present.

TC is the cause of 1-2% of ACS presentations to the ED.¹ The prevalence of TC in the US is estimated to be 5.2 per

100,000 women and 0.6 per 100,000 men.⁷ First investigated by Sato et al in 1990 in Japan, the entity of Takotsubo, or stress cardiomyopathy, was named due to the apical ballooning of the heart, which looks similar to a pot used to catch octopi.⁸ Often referred to as "broken heart syndrome," it has been reported in post-menopausal women who have recently suffered severe emotional stress. Women >55 years old had 4.8 times higher odds for developing TC compared to those <55 years old.⁷

TC diagnostic criteria include the following: 1) new concerning ECG changes (most commonly ST-segment elevation and/or T-wave inversions) or increased troponins (1.8x increase as opposed to the average 6x increase associated with myocardial infarction); 2) transient akinesis/dyskinesis of the left ventricle (typically apical); and 3) absence of >50% coronary artery stenosis or culprit lesion.¹² While TC has been traditionally diagnosed via cardiac MRI, bedside transthoracic echocardiogram can be used to help diagnose it by noting apical ballooning that crosses several areas of cardiac perfusion when using the apical 4-chamber view.⁹

Many etiologies have been proposed, most relating to catecholamine-induced vasospasm, and coronary artery spasm.¹⁰ Left ventricular outflow tract (LVOT) obstruction and estrogen deficiency are additional risk factors for the development of TC.¹¹ Most TC patients will be hemodynamically stable upon presentation but approximately 10% will present in cardiogenic shock.¹² Factors associated with a shock presentation include atrial fibrillation (OR [2.03]; 95% CI, 1.22-3.40; P = 0.007), left ventricular ejection fraction <45% (OR [2.49]; 95% CI, 1.63-3.80; P <0.001), and catecholamine release (OR [2.84]; 95% CI, 1.96-4.12; P <0.001).¹² LVOT obstruction is associated with 19% of TC-

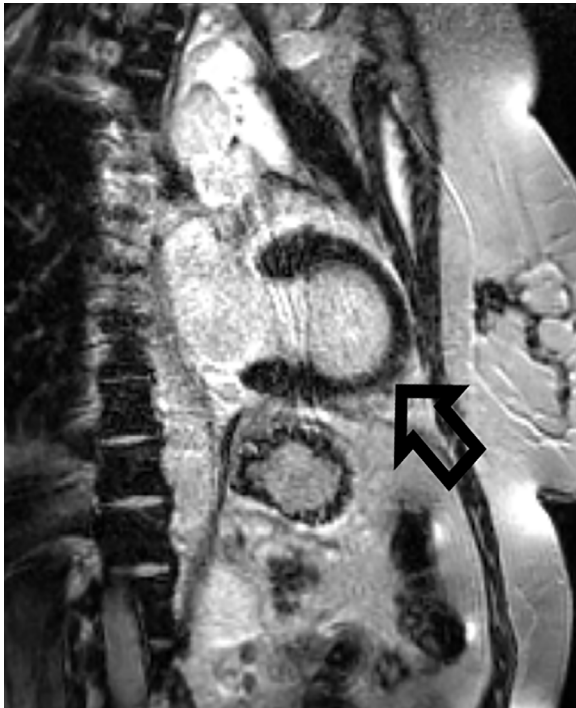

Image 3. Sagittal magnetic resonance imaging showing apical ballooning of left ventricle.

induced cardiogenic shock.¹³ While there does not appear to be any increased mortality related to LVOT obstruction-related cardiogenic shock, the management is very different.¹²

Absence of LVOT obstruction is treated with cardiogenic inotropes (typically dobutamine) to increase cardiac output. Presence of LVOT obstruction is treated with fluid resuscitation to improve pre-load as long as pulmonary congestion is not present, along with beta-blocker therapy to improve hemodynamics and potentially resolve the obstruction.¹³ It is, therefore, imperative that any patients in cardiogenic shock undergo stat echocardiogram to assess for LVOT obstruction as this will radically change their management.

In our case report, the patient's cholecystitis and the associated catecholamine surge due to pain likely caused her TC, which resulted in her ECG changes. While case reports have linked pancreatitis and concomitant Wellens syndrome with TC, our case is novel in that our patient presented with TC and Wellens syndrome due to acute cholecystitis.¹⁴

CONCLUSION

Takotsubo cardiomyopathy can mimic the presentation of acute coronary syndrome and will often meet criteria for immediate catheterization. This case reports a type B Wellens-like ECG pattern and development of a new LBBB with related TC from acute cholecystitis. Emergency providers need to be aware of TC as it can present with or quickly develop into cardiogenic shock whose treatment hinges on the presence of LVOT

obstruction. While cardiac MRI is still the gold standard for diagnosis of TC, bedside echocardiography can give the provider crucial information on the patient's cardiac hemodynamics, helping direct the best management of TC until the patient can be transported to the catheterization lab or the cardiac ICU. Importantly, as in this case, the underlying cause of TC must also be found and managed, along with the TC itself.

Documented patient informed consent and/or Institutional Review Board approval has been obtained and filed for publication of this case report.

Address for Correspondence: Kevin Gould, MD, Virginia Commonwealth University, Department of Emergency Medicine, 1250 E. Marshall St. Richmond, VA 23219. Email: kevin.gould@vcuhealthorg.

Conflicts of Interest: By the CPC-EM article submission agreement, all authors are required to disclose all affiliations, funding sources and financial or management relationships that could be perceived as potential sources of bias. The authors disclosed none.

Copyright: © 2020 Gould et al. This is an open access article distributed in accordance with the terms of the Creative Commons Attribution (CC BY 4.0) License. See: <http://creativecommons.org/licenses/by/4.0/>

REFERENCES

1. Akashi YJ, Goldstein DS, Barbaro G, et al. Takotsubo cardiomyopathy – a new form of acute reversible heart failure. *Circulation*. 2008;118(25):2754-62.
2. Templin C, Ghadri JR, Napp LC, et al. Clinical features and outcomes of Takotsubo (stress) cardiomyopathy. *N Engl J Med*. 2015;373(10):929-38.
3. Bruyninckx R, Aertgeerts B, Bruyninckx P, et al. Signs and symptoms in diagnosing acute myocardial infarction and acute coronary syndrome: a diagnostic meta-analysis. *Br J Gen Pract*. 2008;58(547):105-11.
4. Canto JG, Shlipak MG, Rogers WJ, et al. Prevalence, clinical characteristics, and mortality among patients with myocardial infarction presenting without chest pain. *JAMA*. 2000;283(24):3223-9.
5. Pope JH, Aufderheide TP, Ruthazer R, et al. Missed diagnosis of acute cardiac ischemia in the emergency department. *N Engl J Med*. 2000;342(16):1163-70.
6. Miner B and Hart EH. Wellens' syndrome. *Stat Pearls*. 2019. Available at: <https://www.ncbi.nlm.nih.gov/books/nbk482490>. Accessed June 29, 2019.
7. Deshmukh A, Kumar G, Pant S, et al. Prevalence of Takotsubo cardiomyopathy in the United States. *Am Heart J*. 2012;164(1):66-71.e1.
8. Sato H, Tateishi H, Uchida T, et al. (1990). Takotsubo type

- cardiomyopathy due to multivessel spasm. In: Kodama K, Haze K, Hon M, editors. *Clinical aspect of myocardial injury: from ischemia, to heart failure* (pp. 56-64). Kagaku Hyoronsha; Tokyo.
9. Isumo M and Akashi YJ. Role of echocardiography for Takotsubo cardiomyopathy: clinical and prognostic implications. *Cardiovasc Diagn Ther.* 2018;8(1):90-100.
 10. Paur H, Wright PT, Sikkil MB, et al. High levels of circulating epinephrine trigger apical cardiodepression in a B2-adrenergic receptor / GI-dependent manner: a new model of Takotsubo cardiomyopathy. *Circulation.* 2012;126(6):697-706.
 11. Pelliccia F, Kaski JC, Crea F, et al. Pathophysiology of Takotsubo syndrome. *Circulation.* 2017;135(24):2426-41.
 12. Di Vece D, Citro R, Cammann VL, et al. Outcomes associated with cardiogenic shock in Takotsubo syndrome. *Circulation.* 2019;139(3):413-5.
 13. De Backer O, Debonnaire P, Gevaert S, et al. Prevalence, associated factors and management implications of left ventricular outflow tract obstruction in Takotsubo cardiomyopathy: a two-year, two-center experience. *BMC Cardiovasc Disord.* 2014;14:147.
 14. Bruenjes JD, Vallabhajosyula S, Vacek CJ, et al. Acute pancreatitis-induced Takotsubo cardiomyopathy in an African American male. *ACG Case Rep J.* 2015;3(1):53-6.

Acute Jaundice in a Six-year-old: An Unusual Presentation of Atypical Kawasaki Disease

LCDR William Bylund, MD*

Gregory J. Zarow, PhD†‡

LCDR Daphne Morrison Ponce, MD§

*Naval Hospital Okinawa, Department of Emergency Medicine, Okinawa, Japan

†Combat Trauma Research Group, Naval Medical Center Portsmouth,
Portsmouth, Virginia

‡The Emergency Statistician, Idyllwild, California

§University of Michigan, Department of Emergency Medicine, Ann Arbor, Michigan

Section Editor: Rick A. McPheeters, DO

Submission history: Submitted September 11, 2019; Revision received December 20, 2019; Accepted December 19, 2019

Electronically published February 24, 2020

Full text available through open access at http://escholarship.org/uc/uciem_cpem

DOI: 10.5811/cpem.2019.12.45180

Kawasaki disease (KD) is a rare vasculitis of childhood that is critical to recognize and treat due to associated morbidity and mortality. A six-year-old male presented to our emergency department (ED) afebrile but with reported recent fevers. Exam revealed jaundice and erythematous tongue with papules, and laboratory studies indicated a direct hyperbilirubinemia. Admitted for evaluation, he developed continuous fever, increasing maculopapular rash, and subsequent desquamation of hands and feet. He ultimately met criteria for incomplete KD, was treated with intravenous immunoglobulin, and avoided cardiac complications. This presentation of incomplete KD with hyperbilirubinemia is rare because the patient was afebrile at ED presentation. [Clin Pract Cases Emerg Med. 2020;4(2):142–145.]

INTRODUCTION

Kawasaki disease (KD) is a systemic vasculitis affecting small and medium blood vessels. Originally characterized by Tomisaku Kawasaki in 1967, KD remains a challenging diagnosis based on clinical features. KD is relatively rare, with approximately 13.7 annual incidence per 100,000 in white children under five years of age. However, KD is a leading cause of acquired heart disease in North American and Japanese children, making KD identification an important area of interest for emergency providers.¹

Classic KD is defined by a daily fever for greater than five days with at least four of five clinical criteria: bilateral bulbar conjunctival injection; oral mucosa involvement; peripheral edema; polymorphous rash; and cervical lymphadenopathy (with at least one > 1.5 centimeters [cm]). A diagnosis of incomplete KD can be made if two or three of the principal features are present in association with an echocardiogram showing coronary artery abnormalities or at least three of the following laboratory findings: albumin of three grams (g) per deciliter (dL) or less; anemia for patient's age; platelet count 450,000 thousandths (K) per microliter (μL) or greater; white blood count (WBC) 15,000 K/μL or greater; elevation of alanine aminotransferase (ALT); and

sterile pyuria greater than or equal to 10 white blood cells per high-powered field.¹⁻²

Untreated, KD may progress to cardiac involvement in 25% of cases. This may include pericardial effusions, coronary artery aneurysms with rupture, cardiac ischemia, dysrhythmias, or even sudden death. Non-cardiac complications include peripheral vascular aneurysms or obstructions, nephritis, or sensorineural hearing loss.¹⁻⁴ Unfortunately, KD is difficult to diagnose in the emergency department (ED) because no single diagnostic test can efficiently establish the diagnosis of KD, and fever with rash is a common complaint. The diagnosis of incomplete KD has been associated with a delay in intravenous immunoglobulin (IVIG) treatment.¹ To demonstrate the complexity of KD diagnosis, the following case study describes an afebrile presentation of incomplete KD in the setting of acute jaundice.

CASE REPORT

An otherwise healthy six-year-old male presented to the ED on day four of illness with fevers, sore throat, and dysuria with dark urine. The patient saw his primary care physician on day one of illness with a temperature of 101.4 degrees Fahrenheit (F) and was diagnosed with a nonspecific viral illness, but his

symptoms continued to worsen despite supportive care. In the days following the office visit, he had temperatures to 102° F daily, and developed jaundice, a maculopapular rash, and an erythematous tongue with papules (Images 1 and 2).

The patient presented at the ED without a fever in the setting of acetaminophen use at home (last dose unknown). History was obtained from the mother and patient, and they endorsed slight non-productive cough but otherwise denied associated symptoms. The patient was fully immunized and his past medical history was unremarkable. Initial ED exam revealed a well-appearing patient with temperature of 99.7° F, pulse 115 beats per minute, blood pressure 98/64 millimeters of mercury, respiratory rate 22 breaths per minute, oxygen saturation 97% on room air, and weight 19.7 kilograms. His head was atraumatic and normocephalic. However, his ear, nose, and throat exam revealed an erythematous tongue with flesh-colored papules (Image 1). His sclerae were icteric and injected without exudate, and the conjunctival injection spared the limbus (Image 2). No significant cervical lymphadenopathy was detected.

Cardiac auscultation revealed a regular rate and rhythm without murmurs, and the lungs were clear bilaterally. His abdomen was non-tender even to deep palpation. Skin exam was notable for diffuse jaundice and an erythematous maculopapular rash to the abdomen and face, sparing the palms and soles. He was awake and alert, following commands, and answering questions appropriately for his age.

Initial laboratory values were obtained for diagnosis. A complete blood count had a leukocytosis to 16.3 thousandths K/ μ L (normal range: 6.0-17.0 K/ μ L) with 86% neutrophils (35%-45%), and platelet count of 369 K/ μ L (210-490 K/ μ L). Total bilirubin was elevated at 5.4 milligrams per deciliter (mg/dL) (0.3-1.8 mg/dL), and conjugated bilirubin was 2.9 mg/dL (0.0-0.3 mg/dL). Hepatic panel revealed mild transaminitis (aspartate

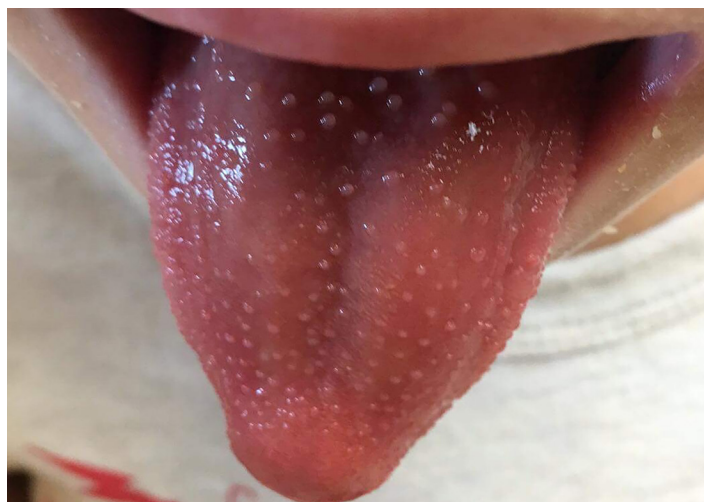

Image 1. Erythematous tongue with papules, on day of emergency department presentation (day 4 of illness).

aminotransferase, alanine aminotransferase, and alkaline phosphatase, 59 units (U) per liter (L) (17-59U/L), 169 U/L (21-72U/L), and 425 U/L (150-380U/L), respectively. Urinalysis revealed trace protein, large bilirubin, no casts, 3-5 red blood cells with trace hemolysis, and 3-5 white blood cells. An initial pharyngeal rapid strep test was negative.

The patient was admitted to the pediatric ward for antibiotics and serial exams, pending abdominal imaging, autoimmune testing, additional labs, viral serologies, and culture results. A comprehensive right upper quadrant ultrasound showed a normal appearing gallbladder and no intrahepatic or extrahepatic biliary ductal dilatation to suggest biliary obstruction. The chest radiograph noted possible right basilar airspace disease. However, given the lack of sputum, respiratory complaints, increased oxygen support, and the associated physical exam findings, pneumonia was considered to be inconsistent with the presentation.

Erythrocyte sedimentation rate (ESR) was elevated at 113 millimeters per hour mm/hr (0-10mm/hr) and C-reactive protein (CRP) was elevated at 3.5 milligrams (mg)/dL (less than 1.0mg/dL), consistent with possible KD.¹ Gamma-

CPC-EM Capsule

What do we already know about this clinical entity?

There have been case reports of jaundice in Kawasaki disease (KD). However, since it is not part of the diagnostic criteria, it is often omitted from standard teaching.

What makes this presentation of disease reportable?

This is only the second case report in United States' literature of KD presenting with acute jaundice.

What is the major learning point?

Emergency physicians should consider atypical KD in the setting of unexplained acute jaundice. Patients may be afebrile at time of presentation.

How might this improve emergency medicine practice?

Increased recognition of atypical KD can improve timely and accurate diagnosis, enabling earlier treatment and decreased complication rates.

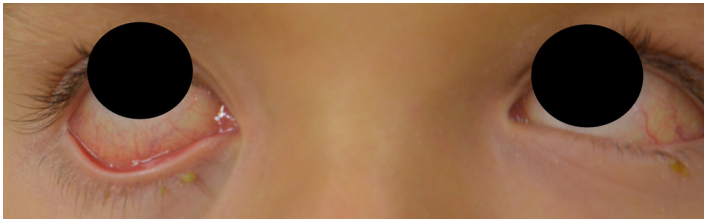

Image 2. Jaundice, icteric sclera, and conjunctival injection, day four of illness.

glutamyltransferase was elevated at 241U/L (15-73 U/L). Throat cultures, antistreptolysin O, hepatitis B surface antigen, hepatitis B core antibody, hepatitis A immunoglobulin (Ig) M, hepatitis C antibody, cytomegalovirus IgG/IgM, toxoplasmosis IgG/IgM, monospot, blood cultures, and leptospirosis testing were negative, making infectious or post-infectious etiologies less likely.

On day seven of illness (hospital day four), the patient developed bilateral cervical lymphadenopathy up to one centimeter, and his bilateral bulbar conjunctival injection worsened. Despite being afebrile at ED presentation, he continued to spike fevers in the hospital (until the sixth day of illness and third hospital day), despite administration of ibuprofen. During his admission, the patient had an elevated ALT, low albumin, thrombocytosis, and elevated WBC, thus meeting at least three supplemental criteria for KD, making incomplete KD the likely diagnosis. The case was discussed with a remote KD specialist, and the next day the patient was transferred to the intensive care unit for IVIG infusion. An echocardiogram was within normal limits, although limited by inability to assess the full length of the coronary arteries. The patient was initiated on aspirin 81 mg daily. He was discharged on low-dose aspirin with plans to obtain repeat outpatient echocardiograms.

Two weeks after discharge, the patient was evaluated by a pediatric cardiologist. Desquamation of the hands and feet were noted (Image 3). Repeat formal echocardiogram was normal, without evidence of pericardial effusion or coronary dilation. Approximately two months after his illness, the majority of the patient's symptoms had resolved and low-dose aspirin was discontinued. A repeat echocardiogram eight months after initial illness was normal, and a telephone follow-up at 10 months indicated that he continued to do well.

DISCUSSION

KD is a rare but critical diagnosis for physicians to consider in ED settings. In our patient, many other diagnoses were considered but did not fit the clinical picture. The differential diagnosis included infectious causes, such as scarlet fever associated with hepatitis, viral hepatitis, or other viral syndrome, cholangitis, and non-infectious causes, such as KD, malignant or other biliary obstruction, drug reaction, or

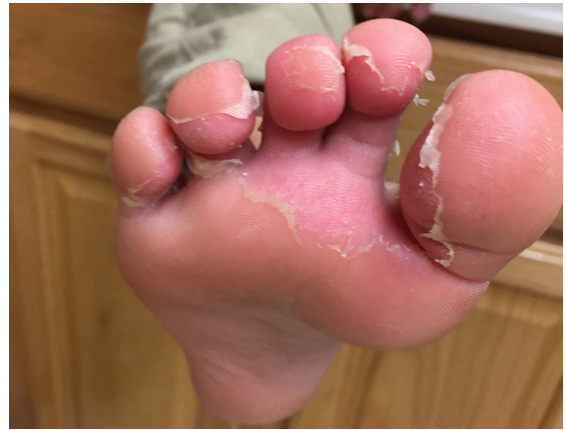

Image 3. Desquamation of feet, day 13 of illness.

an autoimmune process, such as acute rheumatic fever. At ED presentation, the patient was afebrile and only had three primary criteria for the diagnosis of KD: conjunctivitis; strawberry tongue; and maculopapular truncal rash. An autoimmune process such as rheumatic fever was considered less likely as he had no arthralgias, and the rash was not the classic well-demarcated, semi-annular rings of erythema marginatum.

The recent fevers and elevated neutrophils increased the suspicion for infectious causes of unexplained jaundice. The patient was treated with penicillin for possible scarlet fever with associated hepatitis, pending streptococcal titers. Scarlet fever was considered a potential unifying diagnosis, as hepatitis with obstructive jaundice has been reported in cases of scarlet fever.⁵⁻⁶ Post-streptococcal glomerulonephritis was considered due to his tea-colored urine, but the laboratory values were inconsistent with the diagnosis. Viral etiologies such as mononucleosis were considered, but mononucleosis screen was negative. Cholecystitis with obstruction was considered, but the patient had no abdominal tenderness, and cholecystitis would be atypical in this age group.

As in other cases, the diagnosis of KD was difficult to make initially, but eventually the patient satisfied necessary criteria for incomplete KD. He had fever for greater than five days, conjunctival injection without exudate, oral mucosal involvement, a polymorphous rash with inguinal accentuation, cervical lymphadenopathy (although below the 1.5 cm criteria), and ultimately periungual desquamation. The ESR and CRP levels were elevated, which led physicians to look for supplemental laboratory criteria. The patient ultimately met four laboratory criteria: WBC greater than 15,000-K/ μ L; platelet count over 450,000-K/ μ L; an elevated ALT; and albumin less than 3.0 mg/dL.¹

KD has previously been reported in patients with hepatitis and cholestatic jaundice. We identified nine previous case reports, with a total of 17 KD patients displaying jaundice.⁷⁻¹⁵ Although rarely reported, KD is the most common cause of

febrile obstructive jaundice following viral hepatitis. A tertiary pediatric clinic chart review study reported that one in five jaundice cases were “caused” by KD.¹³ A recent case report described KD presenting with fevers and acute acalculous cholecystitis that responded to medical treatment (IVIg and aspirin) in lieu of urgent surgical intervention.¹⁵ Systemic vasculitis may underpin both KD and some cases of jaundice, and our case adds to the growing body of literature showing an association between KD and jaundice. Further empirical evidence of an association between KD and jaundice might justify adding elevated bilirubin to the supplemental criteria for incomplete KD.

CONCLUSION

This case of incomplete KD was particularly challenging to diagnose because the patient was afebrile at time of presentation. This case also illustrates the difficulty in diagnosing incomplete KD when other more common diagnoses may initially be considered more likely, as sometimes only two or three of the clinical criteria are apparent at initial presentation.¹³⁻¹⁴ This patient had incomplete KD with associated conjugated bilirubinemia, adding to a growing body of literature showing an association between jaundice and KD. Unexplained jaundice with associated features should prompt physicians to consider KD. This case and others emphasize the importance for emergency physicians to retain a high level of suspicion for KD when a child presents with febrile or afebrile obstructive jaundice.⁷⁻¹⁵

Documented patient informed consent and/or Institutional Review Board approval has been obtained and filed for publication of this case report.

REFERENCES

1. McCrindle BW, Rowley AH, Newburger JW, et al. Diagnosis, treatment, and long-term management of Kawasaki disease: a scientific statement for health professionals from the American Heart Association. *Circulation*. 2017;135(17):e927-99.
2. Yu JJ. Diagnosis of incomplete Kawasaki disease. *Korean J Pediatr*. 2012;55(3):83-7.
3. Veiga PA, Pieroni D, Baier W, et al. Association of Kawasaki disease and interstitial nephritis. *Pediatr Nephrol*. 1992;6(5):421-3.
4. Magalhães CM, Magalhães Alves NR, Oliveira KM, et al. Sensorineural hearing loss: an underdiagnosed complication of Kawasaki disease. *J Clin Rheumatol*. 2010;16(7):322-5.
5. Gidaris D, Zafeiriou D, Mavridis P, et al. Scarlet fever and hepatitis: a case report. *Hippokratia*. 2008;12(3):186-7.
6. Elishkevitz K, Shapiro R, Amir J, et al. Hepatitis in scarlet fever. *Isr Med Assoc J*. 2004;6(9):569-70.
7. Kaman A, Aydın-Teke T, Gayretli-Aydın ZG, et al. Two cases of Kawasaki disease presented with acute febrile jaundice. *Turk J Pediatr*. 2017;59(1):84-6.
8. Grech V, Buttigieg T, Portelli A, et al. Kawasaki disease presenting as hepatitis. *Ann Trop Paediatr*. 2007;27(4):303-6.
9. Jafari SA, Kiani MA, Ahanchian H, et al. Kawasaki disease presenting as acute clinical hepatitis. *Int J Pediatr*. 2014;1(1):37-9.
10. Keeling IM, Beran E, Dapunt OE. Kawasaki disease and hepatobiliary involvement: report of two cases. *Ital J Pediatr*. 2016;42:27.
11. Kılıç BO, Baysun Ş, Gökşen TC, et al. An unusual presentation of Kawasaki disease: gallbladder hydrops and acute cholestatic hepatitis. *Case Rep Med*. 2018;2018:4930234.
12. Karpathios T, Moustaki M, Yiallourous P, et al. Severe jaundice in two children with Kawasaki disease: a possible association with Gilbert syndrome. *J Korean Med Sci*. 2012;27(1):101-3.
13. Taddio A, Pellegrin MC, Centenari C, et al. Acute febrile cholestatic jaundice in children. *J Pediatr Gastroenterol Nutr*. 2012;55(4):380-3.
14. Majumdar I and Wagner S. Kawasaki disease masquerading as hepatitis: a diagnostic challenge for pediatricians. *Clin Pediatr (Phila)*. 2016;55(1):73-5.
15. Lipe D and Bridges L. Kawasaki disease presenting as acute acalculous cholecystitis. *Clin Pract Cases Emerg Med*. 2019;3(4):383-6.

Address for Correspondence: William Bylund, MD, Naval Medical Center Portsmouth, 620 John Paul Jones Circle, Portsmouth, VA 23708. Email: William.e.bylund@mail.mil.

Conflicts of Interest: By the CPC-EM article submission agreement, all authors are required to disclose all affiliations, funding sources and financial or management relationships that could be perceived as potential sources of bias. The authors disclosed none. The views expressed here are those of the authors and do not reflect the official policy of the Department of the Navy, the Department of Defense, or the U.S. Government.

Copyright: © 2020 Bylund et al. This is an open access article distributed in accordance with the terms of the Creative Commons Attribution (CC BY 4.0) License. See: <http://creativecommons.org/licenses/by/4.0/>

Topical Tranexamic Acid for Hemostasis of an Oral Bleed in a Patient on a Direct Oral Anticoagulant

Eric Boccio, MD*†

Kyle Hultz, PharmD*

Ambrose H. Wong, MD, MEd*†

*Yale School of Medicine, Department of Emergency Medicine, New Haven, Connecticut

†Yale-New Haven Hospital, Department of Emergency Medicine, New Haven, Connecticut

Section Editor: Rick McPheeters, DO

Submission history: Submitted September 26 2019; Revision received January 22, 2020; Accepted January 28, 2020

Electronically published March 27, 2020

Full text available through open access at http://escholarship.org/uc/uciem_cpem

DOI: 10.5811/cpem.2020.1.45326

Introduction: Tranexamic acid (TXA) is an antifibrinolytic agent currently approved and utilized in the treatment of dysfunctional uterine bleeding, traumatic extracranial hemorrhage, anterior epistaxis, and dental procedures on patients with hemophilia. There is a paucity of literature evaluating the use of TXA for hemostasis in patients on direct oral anticoagulants (DOACs).

Case Report: Our patient, a 72 year-old male on rivaroxaban, presented with persistent bleeding following a punch biopsy of the buccal mucosa. Given the site of bleeding, inability to effectively tamponade, patient's anticoagulated state, and risk of impending airway compromise, a dressing was soaked with 500 milligram (mg) of TXA and was held in place with pressure using a makeshift clamp until a thrombus formed. Hemostasis was achieved preventing the need for acute ENTotolaryngologic intervention and/or intubation. The patient was observed in the medical setting overnight and discharged home without any recurrence of bleeding or adverse events.

Discussion: This case report describes our experience achieving hemostasis for an otherwise uncontrollable oral bleed in an anticoagulated patient on a DOAC who could not be reversed. Intervention is simple to perform, cost-effective, and requires few resources which are readily available in most emergency departments.

Conclusion: We report a novel application of TXA to control an oral mucosal bleed in an anticoagulated patient which was on a DOAC refractory to traditional measures. [Clin Pract Cases Emerg Med. 2020;4(2):146–149.]

Keywords: *Tranexamic acid; direct oral anticoagulant; TXA; DOAC; hemostasis.*

INTRODUCTION

Tranexamic acid (TXA) is an antifibrinolytic agent approved by the Food and Drug Administration for the treatment of cyclic, heavy menstrual bleeding and prevention of hemorrhage during tooth extractions in patients with hemophilia.¹ Recently, TXA use has expanded rapidly for a variety of off-label indications and is now considered the antifibrinolytic of choice in patients who present to the emergency department (ED) with extracranial hemorrhage following a traumatic injury.² Further analysis of the

CRASH-2 (Corticosteroid Randomization after Significant Head Injury) trial demonstrated a significant effect of TXA on favorable functional outcomes for the lowest-risk (<6% mortality) group. Due to its cost-effectiveness and exceptional safety profile TXA is recommended for patients presenting within three hours of sustaining a traumatic injury.³

Atomized nasal TXA with external compression was proven to be as effective as standard nasal packing at hemostasis, superior at preventing rebleeding events within 24 hours, and more comfortable than anterior nasal packing

and traditional external compression in managing anterior epistaxis.⁴ The use of TXA, both systemically and topically, in the setting of dental extraction and orthognathic surgery has been documented in the literature.⁵ The use of TXA suspension-soaked gauze, made from crushed 500 milligram (mg) TXA tablets and water, applied directly to the extracted cavity to prevent bleeding has been successful in hemophilia patients undergoing dental procedures.⁶ The use of a 0.05% TXA irrigation solution following orthognathic surgery and 5% TXA mouthwash administered after gingival manipulation and scaling in patients with hemophilia has also been shown to be effective in prevention and/or treatment of clinically significant oropharyngeal bleeding.⁷⁻⁸

It is important to note, however, that each of these dosage forms requires manipulation of commercially available TXA products, and may not be ideal for urgent use in the ED setting. A recent Cochrane Review examined randomized controlled trials of people on continuous treatment with vitamin K antagonists (VKA) or direct oral anticoagulants (DOAC) undergoing oral or dental procedures using antifibrinolytic agents to prevent perioperative bleeding.⁹ Although the studies demonstrated a beneficial effect of locally applied TXA for patients on continuous VKAs, no eligible trials in people on continuous treatment with DOACs were identified.

CASE REPORT

A 72 year-old-male with known past medical history inclusive of right lower extremity deep vein thrombosis currently on the DOAC rivaroxaban, myelodysplastic syndrome status post stem cell transplant complicated by graft versus host disease (GVHD), hyperlipidemia, stage three chronic kidney disease, and type II non-insulin dependent diabetes mellitus presented to the ED with right buccal mucosa bleed after undergoing punch biopsy by dermatology six hours prior. The last administered dose of rivaroxaban was earlier the same morning, as he was not instructed to hold the dose because the diagnostic punch biopsy for GVHD workup was scheduled ad hoc while he was in the hospital for routine follow-up. Despite manually holding direct pressure with a paper towel over the bleeding site, the patient stated that he had been unable to achieve hemostasis, which was affecting his ability to speak and sleep due to the continuous need to spit out blood, prompting his visit to the ED. A single, folded, paper towel sheet became saturated and required exchange every 15 minutes.

Review of systems was notable for oral bleeding, minor post-procedural pain (2/10 in severity) at the biopsy site, and three days of acute on chronic constipation, believed to be unrelated to his chief complaint. The patient denied shortness of breath, cough, hemoptysis, and dysphagia. On physical examination, the airway was intact, and there was an active, continual oozing of dark blood from a five-millimeter biopsy

CPC-EM Capsule

What do we already know about this clinical entity?

Tranexamic acid (TXA) clinical applications include menstrual bleeding, dental extractions, anterior epistaxis, and traumatic extracranial hemorrhage.

What makes this presentation of disease reportable?

Emergency department patients on direct oral anticoagulants (DOAC) may present with bleeding, which is refractory to traditional measures.

What is the major learning point?

TXA was applied topically with no major adverse effects to achieve hemostasis of an oral bleed in a patient on DOAC who could not be reversed.

How might this improve emergency medicine practice?

Further investigation into the use of topical TXA as a treatment option for refractory hemorrhage in patients on DOACs is warranted.

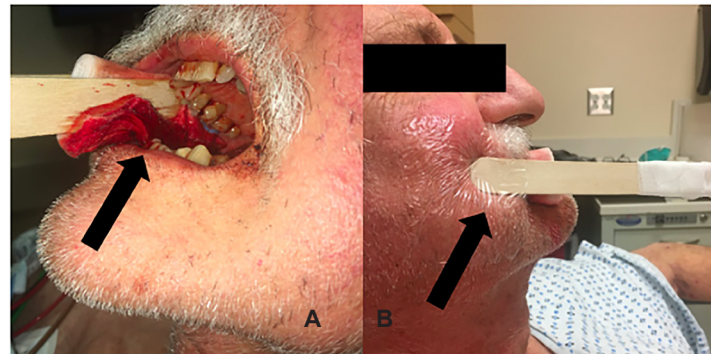


Image 1. (a) Tranexamic acid-soaked dressing held in place with tongue depressors and (b) adhesive dressing over patient's cheek.

site along the right buccal mucosa. Due to the duration of bleeding and reported amount of saturated dressings, a complete blood count, general chemistry panel, and coagulation panel were drawn, which was notable for a hemoglobin and

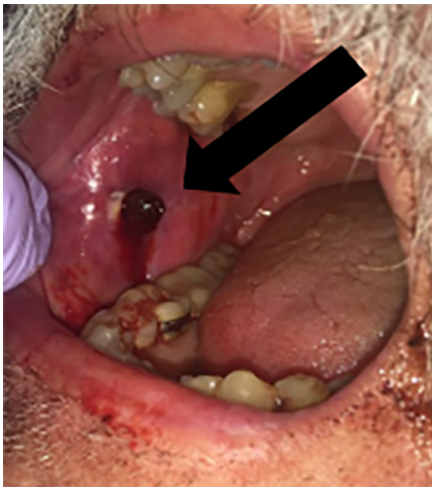


Image 2. Visualized thrombus over punch biopsy site after being treated with pressure dressing soaked in 500 milligrams of tranexamic acid and held in place for 30 minutes.

hematocrit of 12.9 grams per deciliter (g/dL) [14-17.4g/dL] and 37.6% [42-54%], respectively, with prothrombin time and international normalized ratio of 10.1 seconds [9.2-11.9 seconds] and 0.91 [0.8-1.2], respectively. The patient was placed in an examination room with continuous wall suctioning and given a Yankauer suction tip to clear his oropharynx.

Given the wide base of the biopsy site and lack of overlapping tissue, the wound was not amenable to hemostasis through placement of sutures. Thus, along with emergency pharmacy guidance and approval, a sterile 4-inch x 4-inch gauze dressing was soaked with 500 mg [5 milliliter (mL)] of 100 mg/mL TXA and placed over the bleeding site. The soaked gauze was held in place with pressure applied by two tongue depressors taped on one end with medical tape and held to the patient's cheek with an adhesive dressing (Images 1A and 1B). After 30 minutes, the device and gauze were removed, and a clot was visualized (Image 2). Due to the possibility of recurrent bleeding and impending airway compromise, the patient was admitted under the otolaryngology service for observation and was discharged from the hospital eight hours later without any significant rebleeding events. There was no 72-hour ED return visit noted within the health system's electronic health records.

DISCUSSION

TXA is a lysine analog similar in chemical structure to aminocaproic acid, but with 10 times more potency in its affinity to both the strong and weak receptor sites of the plasminogen molecule. By competitively binding to plasminogen, TXA effectively blocks the conversion of plasminogen to plasmin, thereby preventing fibrinolysis

and, in turn, promotes stabilization of the fibrin clot.¹⁰ The excellent safety profile of TXA is likely twofold: therapeutic doses do not cause platelet aggregation in vitro, and when applied topically there is little to no systemic absorption. In light of the proposed mechanism and known safety profile, we suggest further investigation into the use of topical TXA as a potential first-line or adjunctive treatment option for difficult to control or refractory hemorrhage in particular instances.

CONCLUSION

This case report addresses a novel application of TXA, a medication that has become increasingly popular in the ED setting to address a very prevalent issue among our anticoagulated patient population on DOACs, specifically achieving hemostasis that is refractory to more traditional measures. We describe our experience achieving hemostasis for an otherwise-uncontrollable oral bleeding event in a patient whose anticoagulated state could not be reversed. Our intervention is simple to perform and cost-effective (approximately \$21.10 US dollars per 100mg/mL 10mL vial). It requires very few resources, which are readily available in most EDs and, most importantly, appears effective. We believe our methods are widely generalizable and can be easily assimilated into the armamentarium of emergency medicine providers in a wide range of clinical environments.

Documented patient informed consent has been obtained and filed for publication of this case report.

Address for Correspondence: Eric Boccio, MD, Yale-New Haven Hospital, Department of Emergency Medicine, 20 York Street, New Haven CT 06510. Email: eric.boccio@yale.edu.

Conflicts of Interest: By the *CPC-EM* article submission agreement, all authors are required to disclose all affiliations, funding sources and financial or management relationships that could be perceived as potential sources of bias. The authors disclosed none.

Copyright: © 2020 Boccio et al. This is an open access article distributed in accordance with the terms of the Creative Commons Attribution (CC BY 4.0) License. See: <http://creativecommons.org/licenses/by/4.0/>

REFERENCES

1. Ker K, Edwards P, Perel P, et al. Effect of tranexamic acid on surgical bleeding: systemic review and cumulative meta-analysis. *BMJ*. 2012;344:e3054.

2. Roberts I, Perel P, Prieto-Merino D, et al. Effect of tranexamic acid on mortality in patients with traumatic bleeding: prespecified analysis of data from randomised controlled trial. *BMJ*. 2012;345:e5839.
3. Nishijima DK, Kuppermann N, Roberts I, et al. The effect of tranexamic acid on functional outcomes: an exploratory analysis of the CRASH-2 randomized controlled trial. *Ann Emerg Med*. 2019;74(1):79-87.
4. Akkan S, Corbacioglu SK, Aytar H, et al. Evaluating effectiveness of nasal compression with tranexamic acid compared with simple nasal compression and merocel packing: a randomized controlled trial. *Ann Emerg Med*. 2019;7(1):72-8.
5. Wahl MJ. Dental surgery in anticoagulated patients. *Arch Intern Med*. 1998;158(15):1610-6.
6. Coetzee MJ. The use of topical crushed tranexamic acid tablets to control bleeding after dental surgery and from skin ulcers in haemophilia. *Haemophilia*. 2007;13(4):443-4.
7. Borea G, Montebugnoli L, Capuzzi P, et al. *Oral Surg Oral Med Oral Pathol*. 1993;75(1):29-31.
8. Nuvvula S, Gaddam KR, Kamatham R. Efficacy of tranexamic acid mouthwash as an alternative for factor replacement in gingival bleeding during dental scaling in cases of hemophilia: a randomized clinical trial. *Contemp Clin Dent*. 2014;5(1):49-53.
9. Engelen ET, Schutgens RE, Mauser-Bunschoten EP, et al. Antifibrinolytic therapy for preventing oral bleeding in people on anticoagulants undergoing minor oral surgery or dental extractions. *Cochrane Database Syst Rev*. 2018;7:CD012293.
10. (2017). Cyklokapron® (tranexamic acid injection) [package insert]. New York, NY: Pharmacia & Upjohn Co, Division of Pfizer Inc.

The Ultimate Poker Face: A Case Report of Facial Diplegia, a Guillain-Barré Variant

Joshua Lowe, MD
James Pfaff, MD

Brooke Army Medical Center, Department of Emergency Medicine, Fort Sam Houston, Texas

Section Editor: Christopher Sampson, MD

Submission history: Submitted October 14, 2019; Revision received February 4, 2020; Accepted February 7, 2020

Electronically published April 23, 2020

Full text available through open access at http://escholarship.org/uc/uciem_cpccem

DOI: 10.5811/cpcem.2020.2.45556

Introduction: Facial diplegia, a rare variant of Guillain-Barré syndrome (GBS), is a challenging diagnosis to make in the emergency department due to its resemblance to neurologic Lyme disease.

Case report: We present a case of a 27-year-old previously healthy man who presented with bilateral facial paralysis.

Discussion: Despite the variance in presentation, the recommended standard of practice for diagnostics (cerebrospinal fluid albumin-cytological dissociation) and disposition (admission for observation, intravenous immunoglobulin, and serial negative inspiratory force) of facial diplegia are the same as for other presentations of GBS.

Conclusion: When presented with bilateral facial palsy emergency providers should consider autoimmune, infectious, idiopathic, metabolic, neoplastic, neurologic, and traumatic etiologies in addition to the much more common neurologic Lyme disease. [Clin Pract Cases Emerg Med. 2020;4(2):150–153.]

Keywords: *Facial Diplegia; Guillain-Barré variant.*

INTRODUCTION

Facial diplegia is a rare variant of Guillain-Barré syndrome (GBS) where patients present with bilateral facial paralysis and paresthesia. Patients usually present 1-28 days after onset of symptoms, occasionally with extremity paresthesia but often in isolation.² This variant occurs in less than 1% of all GBS patients.¹⁻² The pathophysiology of the disease is due to the acute inflammatory demyelinating polyneuropathy subtype much more often than the acute motor axonal neuropathy subtype of GBS.² Due to its resemblance to the far more prevalent neurologic Lyme disease, it can be a potential pitfall diagnosis for emergency providers.

CASE REPORT

A 27-year-old male military recruit without significant previous medical history was transported to the emergency department (ED) by ambulance with a chief complaint of bilateral facial paralysis. A resident of Puerto Rico, the

patient had recently traveled to San Antonio, Texas, for military exercises and received multiple vaccines five days prior to onset of symptoms. He began experiencing mild paresthesia in his hands and feet four days prior to ED presentation. He reported progressive neurologic signs and symptoms including being unable to close his eyes or mouth, which made sleeping and eating difficult, as well as right-sided facial numbness. He went to the military medical clinic two days prior to ED presentation where he was diagnosed with a complex migraine and discharged to the barracks on quarters (strict bed rest) with ibuprofen and ondansetron and instructions to return for follow-up the next day to evaluate for resolution of symptoms.

During the subsequent ED visit his vital signs included a heart rate of 113 beats per minute, blood pressure 117/76 millimeters of mercury, respiration 16 breaths per minute, and temperature 98.5 degrees Fahrenheit. His blood glucose was 116 milligrams per deciliter (mg/dL) (90-120 mg/dL).

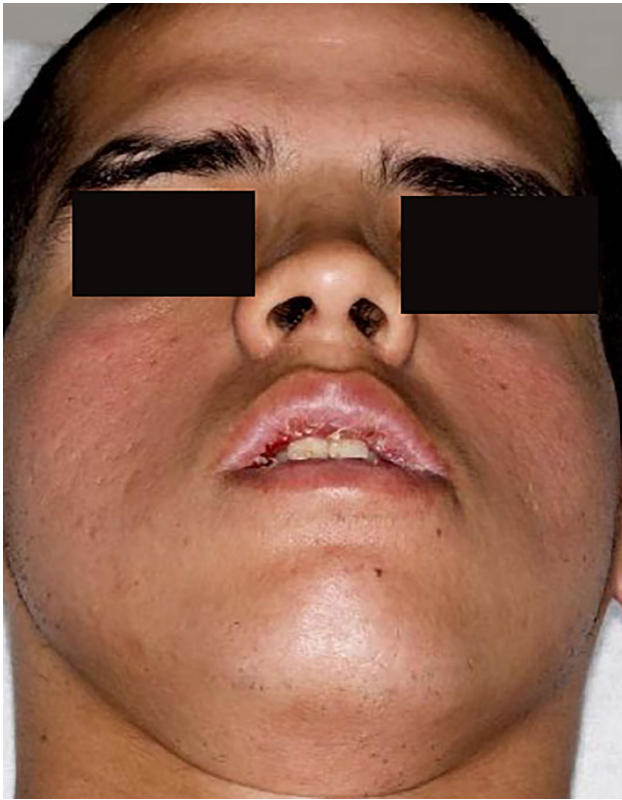

Image. Patient with facial diplegia attempting to both wrinkle forehead and smile during neurologic exam.

Physical exam revealed symmetric bilateral facial paralysis, causing difficulty in closing his eyelids and mouth, which resulted in injected conjunctiva with moderate tearing, and cheilitis (Image). He endorsed decreased soft-touch sensation in a radial distribution in his upper extremities and the distribution of his fifth lumbar nerve in his lower extremities. Bilateral Achilles reflexes were absent. Strength and reflexes were otherwise preserved in his lower extremities. He was administered one liter of Ringer's lactate, and the tachycardia improved.

Computed tomography of his head showed no masses or evidence of bleeding. Neurology was consulted and per their recommendation we obtained magnetic resonance imaging of his brain, which demonstrated no lesions, masses, or evidence of edema. A lumbar puncture was performed; it revealed albumin-cytological dissociation of cerebrospinal fluid (CSF), which is an increased protein with normal cell counts. Polymerase chain reaction did not detect any common bacterial or viral meningitis organisms. His complete blood count, comprehensive metabolic panel, and erythrocyte sedimentation rate were all within normal limits. The patient was given 10 milligrams dexamethasone intravenously in the ED, and blood cultures were obtained prior to admission.

CPC-EM Capsule

What do we already know about this clinical entity?

The treatment and disposition for all variants of Guillain-Barré syndrome (GBS) is the same.

What makes this presentation of disease reportable?

Facial diplegia is a rare variant of GBS that mimics a fairly common disease process in Lyme disease

What is the major learning point?

This case demonstrates the differential diagnosis and diagnostic pitfalls associated with facial diplegia.

How might this improve emergency medicine practice?

Clinicians should consider a thorough differential diagnosis for facial diplegia.

With a presumptive diagnosis of GBS the patient was admitted to the hospital for serial negative inspiratory flow measurements and intravenous immune globulin (IVIG), while awaiting further diagnostic testing by neurology. Serum and CSF studies detected none of the following organisms: *Borrelia burgdorferi*, Zika virus, West Nile virus, varicella-zoster virus, *Treponema pallidum*, human immunodeficiency virus, or *Mycobacterium tuberculosis*. Based upon the exam findings and diagnostic testing, the diagnosis of facial diplegia (GBS variant) was confirmed with the etiology most likely post-vaccinal. The patient received four days of IVIG and was discharged from the hospital. He returned to training with 4/5 strength and decreased light touch in his bilateral face and complete resolution of the paresthesia in his extremities. He was started on long-term daily corticosteroids by the neurologist with continued 4/5 strength and light touch in his bilateral face noted on his one month follow-up.

DISCUSSION

Facial diplegia is a rare disorder, accounting for less than 2% of all patients with facial paralysis.¹ The differential of facial diplegia includes Lyme disease, meningitis, and trauma. While Lyme disease is the most common etiology, GBS accounts for about 5% of cases (Table).¹⁻³ Although facial nerve paralysis is involved in 27-50% of GBS cases (50% of those

Table. Differential diagnosis of acute onset bilateral facial paralysis.

Category	Diagnosis
Autoimmune	Guillain-Barré syndrome
	Sarcoidosis
	Myasthenia gravis
	Amyloidosis
Infectious	Lyme disease
	Herpes simplex virus
	Varicella-zoster virus
	Human immunodeficiency virus
	Syphilis
	Human T-cell leukemia virus-1
	Poliomyelitis
	Influenza
	Cytomegalovirus
	Botulism
	Epstein-Barr virus
	Idiopathic
Bell's palsy	
Metabolic	Diabetes
Neoplastic	Leukemia
	Porphyria
	Meningioma
Neurological	Multiple sclerosis
Trauma	Skull fracture
	Parotid surgery
	Mastoid surgery

patients having bilateral involvement), facial diplegia is a rare presentation, occurring in 0.25-0.8% of all GBS patients. Causes are thought to be the same as in other variants of GBS.^{2,4}

Common features of GBS include the following: subjective peripheral paresthesia (88%); a preceding illness one to two weeks prior to symptoms (75%); and CSF albumin-cytological dissociation (88%).⁴ The diagnostic criteria include core features of facial weakness, absence of ophthalmoplegia or truncal/cervical ataxia, and monophasic disease course with 12 hours to 28 days between onset and nadir. Supportive features include antecedent infectious symptoms, presence of distal paresthesia

prior to facial diplegia, electrophysiological evidence of neuropathy, and CSF albumin-cytological dissociation.⁵

The prognosis for the facial diplegia subtype of GBS is generally favorable, as diaphragmatic paralysis has never been documented.² Corticosteroids, although classically given, have not been shown to be effective in GBS.² Although there have been no GBS-variant specific trials of treatment that show IVIG efficacy, the recommended standard of practice is still admission for observation, IVIG, and serial negative inspiratory force.²

CONCLUSION

Facial diplegia is a rare variant of GBS that presents a very challenging diagnosis to make in the ED due to its wide differential diagnosis. When presented with bilateral facial palsy emergency providers should consider autoimmune, infectious, idiopathic, metabolic, neoplastic, neurologic, and traumatic etiologies in addition to the much more common neurologic Lyme disease. Facial diplegia is a clinical diagnosis that is bolstered by the presence of albumin-cytological dissociation in the cerebral spinal fluid.² Treatment is the same as for other variants of GBS: observation; serial negative inspiratory force; and IVIG if the patient's condition begins to deteriorate.

Documented patient informed consent has been obtained and filed for publication of this case report.

Address for Correspondence: Joshua Lowe, MD, Brooke Army Medical Center, Department of Emergency Medicine, 3851 Roger Brooke Drive, JBSA-Fort Sam Houston, TX 78234. Email: beaudasious12@gmail.com.

Conflicts of Interest: By the CPC-EM article submission agreement, all authors are required to disclose all affiliations, funding sources and financial or management relationships that could be perceived as potential sources of bias. The views expressed here are those of the authors and do not reflect the official policy of the Department of the Army, the Department of Defense, or the U.S. Government.

Copyright: © 2020 Lowe et al. This is an open access article distributed in accordance with the terms of the Creative Commons Attribution (CC BY 4.0) License. See: <http://creativecommons.org/licenses/by/4.0/>

REFERENCES

1. Jain V, Deshmukh A, Gollomp S. Bilateral facial paralysis: case presentation and discussion of differential diagnosis. *J Gen Intern Med.*

- 2006;21(7):7-10.
2. Wakerley BR and Yuki N. Isolated facial diplegia in Guillain-Barré syndrome: bifacial weakness with paresthesias. *Muscle Nerve*. 2015;52(6):927-32.
3. Keane JR. Bilateral seventh nerve palsy: analysis of 43 cases and review of the literature. [Review]. *Neurology*. 1994;44(7):1198-202.
4. Kim JK, Oh SY, Sohn EH, et al. When is facial diplegia regarded as a variant of Guillain-Barré syndrome? *J Peripher Nerv Syst*. 2015;20(1):32-6.
5. Wakerley BR, Uncini A, Yuki N, et al. Guillain Barré and Miller Fisher syndromes: new diagnostic classification. *Nat Rev Neurol*. 2014;10:537-44.

Ruptured Coronary Sinus of Valsalva in the Setting of a Supracristal Ventricular Septal Defect

Abilio Arrascaeta-Llanes, MD* *Long Island Community Hospital, Department of Medicine, Patchogue, New York
Akanksha Kashyap, MD* †Long Island Community Hospital, Department of Cardiology, Patchogue, New York
Diana Meyler, MD*
Ravi Gupta, MD*
Zubin Tharayil, MD*
Waqas Khan, MD†

Section Editor: Rick A. McPheeters, DO

Submission history: Submitted June 7, 2019; Revision received October 25, 2019; Accepted November 6, 2019

Electronically published February 24, 2020

Full text available through open access at http://escholarship.org/uc/uciem_cpem

DOI: 10.5811/cpem.2019.11.44008

A sinus of Valsalva aneurysm (SOVA) is usually a silent entity until one of its complications arises, such as heart failure. SOVA itself is uncommon, but it is more frequently associated with a supracristal ventricular septal defect (SVSD). We present a 67-year-old man with a history of an asymptomatic SVSD who presented to the emergency department with signs and symptoms of heart failure. He was subsequently found to have a ruptured SOVA and underwent urgent surgical repair. [Clin Pract Cases Emerg Med. 2020;4(2):154–157.]

INTRODUCTION

Clinical presentations consistent with heart failure, conduction abnormalities, and acute coronary syndrome are frequently encountered in the emergency department (ED). A patient with a sinus of valsalva aneurysm (SOVA) may present with one of the above manifestations. SOVA is a rare cardiac condition usually resulting from a congenital incomplete fusion of the aortic media and the aortic valve annulus. It can also be caused by processes that compromise the septal wall, such as supracristal ventricular septal defects (SVSD), endocarditis, syphilis, cystic medial necrosis, and chest trauma. If ruptured, SOVA presents with symptoms of a large left-to-right shunt causing severe heart failure, necessitating urgent surgical intervention.

CASE REPORT

A 67-year-old Caucasian male presented to the ED with a three-day history of worsening dyspnea, cough, chills, and body aches. He denied chest pain, fever, recent travel, leg swelling, sick contacts, and syncope. His past medical history, prior to his ED presentation, included a ventricular septal defect (VSD), chronic atrial fibrillation, left ventricular hypertrophy, hypertension, and dyslipidemia; he denied any surgical history. During his last visit with his cardiologist six months prior to presentation, the

VSD was stable, and he was asymptomatic. In the ED, his blood pressure was 131/60 millimeters of Mercury (mmHg), heart rate was 102 beats per minute, respiratory rate was 27 breaths per minute and arterial oxygen saturation was 95% on two liters of supplemental oxygen. The remainder of the physical exam was significant for end-expiratory wheezing, an irregularly irregular pulse, and a loud, precordial continuous systolic murmur with right-sided prominence; no cyanosis, clubbing or lower extremity edema was noted. Laboratory results were significant for an elevated troponin-I of 0.063 nanogram/milliliter (ng/ml) (normal range: 0.0–0.045 ng/ml) and brain natriuretic peptide of 744 picogram/milliliter (pg/ml) (100–400 pg/ml); a complete blood count and a basic metabolic panel were within normal limits. An electrocardiogram revealed atrial fibrillation with left ventricular hypertrophy and a chest radiograph was unremarkable. The patient was admitted for presumed bronchitis and diastolic congestive heart failure exacerbation and subsequently treated with diuretics, bronchodilators, and antibiotics.

Despite the aforementioned treatment, the patient did not clinically improve. The following day, a transthoracic echocardiogram (TTE) revealed a small-to-moderate sized supracristal VSD with a left-to-right shunt. The TTE also showed a moderately dilated left ventricle cavity with a left ventricular ejection fraction (LVEF) of 50%, bilateral atrial and aortic

enlargement and a severely elevated resting pulmonary artery (PA) pressure of 55 mmHg with preserved contractility of the right ventricle. A subsequent transesophageal echocardiogram (TEE) showed a mild-to-moderately dilated aortic root at the level of the sinuses of Valsalva, with normal aortic valve annular dimensions. The right coronary sinus of Valsalva was eccentrically aneurysmal and ruptured, extending anteriorly and inferiorly into the right ventricle outflow tract (RVOT) near the patient's membranous VSD, exhibiting a "windsock effect" (Image 1,2).

A high-velocity turbulent flow was visualized from the aortic root to the RVOT. There was a small restrictive supracristal membranous VSD with a minimal shunt flow. The left ventricle was globular and Left Ventricle Ejection Fraction (LVEF) was estimated to be 25%. The right ventricle function was impaired with significant pulmonary artery hypertension.

The patient underwent an urgent right-and-left sided cardiac catheterization, which confirmed the presence of a right SOVA rupture into the RVOT with blood flow into the PA on left ventricular and aortic root angiogram (Image 3). The PA was dilated with a Pulmonary-Systemic flow ratio (Qp/Qs) of 5.33 due to the left-to-right shunt. Additionally, moderate pulmonary hypertension and moderate global left ventricular dysfunction (ejection fraction 40%) were noted.

The patient was transferred to a tertiary care facility for urgent surgical repair of the acute left-to-right SOVA-RVOT shunt. During the surgery, the aortic root was accessed via a transaortic route. The right coronary sinus had a 4-millimeter tear with an aneurysmal dilation to the RVOT. The aneurysm was resected and the area was reconstructed with a bovine pericardial patch; the SVSD was also repaired with a bovine pericardial patch. The aortic valve was not involved and did not

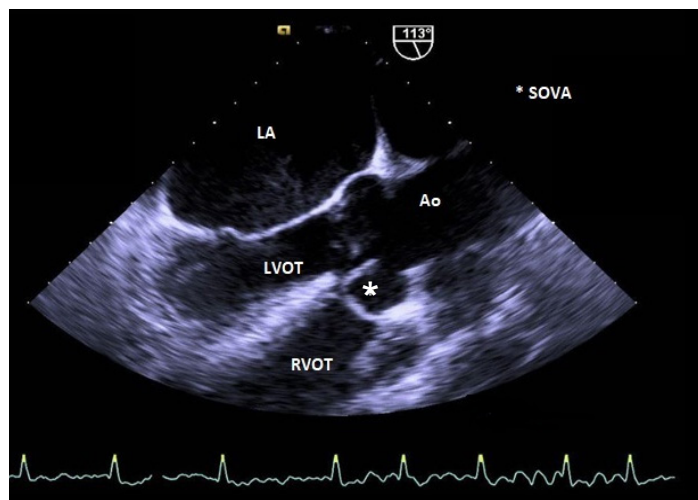


Image 1. Transesophageal echocardiogram demonstrating an eccentrically aneurysmal right sinus of Valsalva (star). LA, left atrium; LVOT, left ventricle outflow tract; Ao, aorta; RVOT, right ventricle outflow tract; SOVA, sinus of Valsalva aneurysm.

CPC-EM Capsule

What do we already know about this clinical entity?

Sinus of Valsalva Aneurysm (SOVA) is a rare, often congenital, cardiac condition resulting from incomplete fusion of the aortic media and the aortic valve annulus.

What makes this presentation of disease reportable?

Our presentation involves an elderly male with history of asymptomatic supracristal ventricular septal defects and confounding cardiac history who presents with signs and symptoms of heart failure.

What is the major learning point?

Physicians should consider ruptured SOVA in the differential for patients with a history of ventricular septal defects presenting with cardiopulmonary symptoms.

How might this improve emergency medicine practice?

Awareness of the various disease manifestations of SOVA and performing an early echocardiogram can lead to early recognition and prevent delays in appropriate therapy.

need repair. The patient performed well postoperatively and was eventually discharged.

DISCUSSION

A supracristal ventricular septal defect is a subtype of VSD that results from the absence of the subpulmonary muscular infundibulum, leaving a fibrous continuity between the aortic and pulmonic valves.^{1,2} SVSD affects the Asian population to a greater degree than the Caucasian population (5:1). The SVSD produces a left-to-right shunt with a venturi effect that results in an acquired aortic valve deformity, including the herniation of the right aortic sinus with the possible development of an aneurysm.³ The prevalence of aortic valve prolapse is around 1% at 1 year of age and 70% at 15 years of age.⁴

SOVA is an aneurysmal dilatation of one or more aortic sinuses between the annulus of the aortic valve and the sinotubular junction. SOVA can be classified as congenital

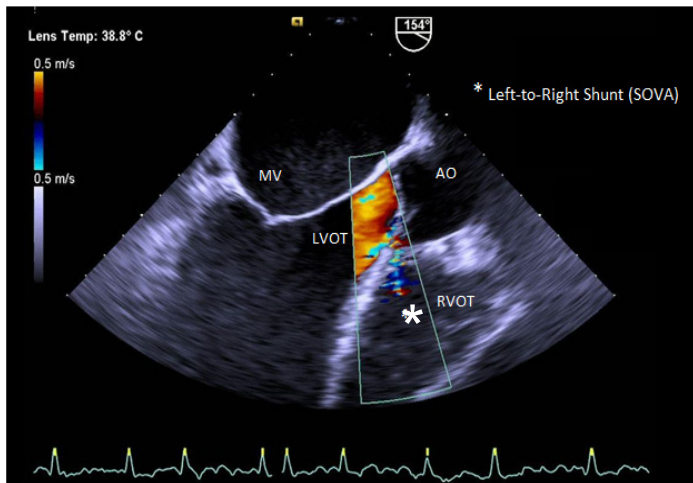


Image 2. Transthoracic echocardiogram demonstrating a ruptured sinus of Valsalva aneurysm (star). MV, mitral valve; Ao, aorta; RVOT, right ventricle outflow tract; LVOT, Left ventricle outflow tract.

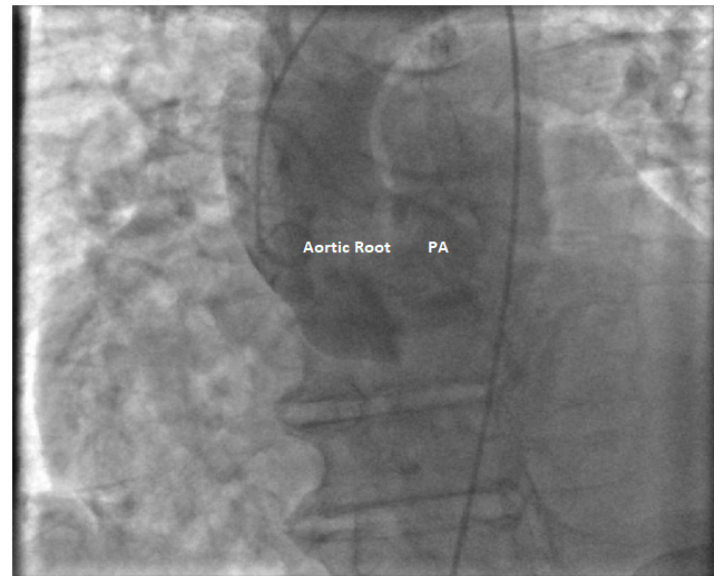

Image 3. Aortic root angiogram. Intravenous contrast shows blood flowing into the pulmonary artery (PA) from the left ventricle outflow tract.

when there is a deficiency of lamina elastica and muscular tissue surrounding the aorta or there is the presence of an acquired weakness of the aforementioned structures.^{5,6} They frequently co-occur with ventricular septal defects, aortic valve dysfunction, or other cardiac abnormalities. Although unruptured ASVs are usually asymptomatic, ruptured ASVs often cause symptoms similar to those of heart failure and produce a continuous, mechanical-sounding murmur. Transsternal or transesophageal echocardiography is usually effective in detecting ASVs. Because symptomatic ASVs pose significant risks for the patient, and because the repair of asymptomatic ASVs generally produces excellent outcomes, surgery is indicated in most cases. The primary goals of surgical repair are to close the ASV securely, remove or obliterate the aneurysmal sac, and repair any associated defects. Operative mortality is generally low except in patients with concomitant bacterial endocarditis or other infections. Late events are uncommon and tend to be related to aortic valve prosthesis or Marfan syndrome.⁷ The most frequent etiologies of congenital SOVA are Marfan's Syndrome, Ehlers-Danlos Syndrome, a bicuspid aortic valve and other connective tissue disorders. An acquired SOVA can result from degenerative connective tissue diseases, chest trauma, atherosclerosis, and infections such as syphilis, bacterial endocarditis, and tuberculosis.

The incidence of SOVA in the western population is approximately 0.09%, occurring predominantly in the male population. It represents 0.1-3.5% of all congenital heart diseases.⁷ ASVs occur much more frequently in the right coronary sinus of Valsalva. Previous reports, based on necropsy and cardiac surgery findings, estimated that 20% of ASVs are unruptured. Patients with an unruptured ASV may remain asymptomatic for a long period of time until rupture. They may

also present with dyspnea, palpitation, and angina-like chest pain. Aortic insufficiency in the patients with unruptured ASVs is common, and other valvular lesions can be observed in these patients as well. Echocardiography, as a noninvasive and portable tool, is widely used to detect ASVs. Additionally, computed tomography and cardiac magnetic resonance imaging, alone or in combination, can provide precise information about its anatomic extension and intrinsic characteristics of the pathology.^{7,8} Between the ages of 30 to 45 years, 80% of patients with a SOVA will become symptomatic; its detection is usually triggered by the manifestation of a SOVA complication. An unruptured SOVA can cause an obstruction of the RVOT, a conduction block, aortic regurgitation and/or a transient ischemic attack. A moderate-to-severely dilated SOVA can lead to blood stasis and predisposes to thrombus formation; thrombus occlusion of the coronary arteries can mimic an acute coronary syndrome.⁹ A ruptured SOVA typically presents with an audible continuous machine-like murmur, bounding pulses, aortic regurgitation and a left-to-right shunt leading to acute heart failure.⁴ Rupture typically occurs in 30% of the patients, with 30-40% of ruptures occurring between 20 and 40 years of age.^{1,6,10}

Traditionally, TTE and TEE are the initial diagnostic tests for SOVA.^{11,12} Both techniques can assess for a shunt; however, they lack sensitivity in detecting shunts less than 3 millimeters. It can be technically challenging to assess for ventricular defects, as the prolapsed cusp can occlude the shunt, resulting in a missed diagnosis in 9% of patients. Prior to surgery, contrast magnetic resonance imaging and aortography are the diagnostic tests of choice in order to better characterize the shunts.¹³

For an unruptured SOVA, the timing of surgical intervention depends on the size of the aneurysm, the rate

of progression, and any associated cardiac abnormalities, such as bicuspid valves or connective tissue diseases. An unruptured SOVA with any of the following characteristics requires surgery: greater than 5.5 centimeters (cm) in size; a yearly growth rate greater than 0.5 cm; 5.0 cm-5.5 cm in the presence of bicuspid valves or 4.0 cm-5.5 cm in the setting of connective tissue disease.¹⁴ Yearly follow up, with either cardiac computed tomography or magnetic resonance imaging, is recommended for an unruptured SOVA.

A ruptured SOVA requires urgent surgical or percutaneous correction. Percutaneous correction is increasingly favored in both elective repair of an unruptured SOVA and in urgent repair of ruptured SOVA.¹⁵ Surgical SOVA repair is performed via either primary closure or bovine patch; primary closure is preferred for repairing a small SOVA and patch closure is generally used for larger defects. The mortality rate associated with the surgery varies from 1.9% to 3.6% and the survival rate is approximately 90% at 15 years.¹⁶

CONCLUSION

Emergency physicians should keep a ruptured SOVA in the differential for patients with a known history of ventricular septal defects who present with acute heart failure, acute coronary syndrome, conduction abnormalities or transient ischemic attacks. Performing an early echocardiogram when the clinical picture is unclear can help delineate between diagnoses and prompt further investigation into the etiology. This can increase the probability of early identification of a SOVA and facilitate an appropriate management plan.

Documented patient informed consent and/or Institutional Review Board approval has been obtained and filed for publication of this case report.

Address for Correspondence: Abilio Arrascaeta-Llanes, MD, Long Island Community Hospital, Department of Emergency Medicine, 100 Hospital Road, Suite 201, Patchogue, NY zip 11733. Email: aarrascaetallanes@licommunityhospital.org

Conflicts of Interest: By the CPC-EM article submission agreement, all authors are required to disclose all affiliations, funding sources and financial or management relationships that could be perceived as potential sources of bias. The authors disclosed none.

Copyright: © 2020 Arrascaeta-Llanes et al. This is an open access article distributed in accordance with the terms of the Creative Commons Attribution (CC BY 4.0) License. See: <http://creativecommons.org/licenses/by/4.0/>

REFERENCES

- Schuller D, Emmert MY, Jacobs S, et al. Aneurysm of coronary sinus of Valsalva can rupture anytime! *Heart Surg Forum*. 2011;14(3):E210-1.
- McCarthy K, Ho S, Anderson R. Ventricular septal defects: morphology of the doubly committed juxtaarterial and muscular variants. *Images Paediatr Cardiol*. 2000;2(3):5-23.
- Bricker AO, Avutu B, Mohammed TL, et al. Valsalva sinus aneurysms: findings at CT and MR imaging. *Radiographics*. 2010;30(1):99-110.
- Layangool T, Kirawittaya T, Sangtawesin C, et al. Natural aortic valve complications of ventricular septal defect: a prospective cohort study. *J Med Assoc Thai*. 2008;91(Suppl 3):S53-9.
- Ott DA. Aneurysm of the sinus of Valsalva. *Semin Thorac Cardiovasc Surg Pediatr Card Surg Annu*. 2006;165-76.
- El-Ashry A and Estrera AL. Patch Repair of an Isolated Right Sinus of Valsalva Aneurysm. *Ann Thorac Surg*. 2016;101(6):e199-201.
- Luo Y, Fang Z, Meng W. A giant aneurysm of noncoronary sinus of Valsalva concomitant with aortic regurgitation and mitral regurgitation. *Echocardiography*. 2017;34(5):796-8.
- Angelini P. Aortic sinus aneurysm and associated defects: can we extrapolate a morphogenetic theory from pathologic findings? *Tex Heart Inst J*. 2005;32(4):560-2.
- Reichert CLA. Ruptured sinus Valsalva aneurysm, a rare cause of heart failure. *Neth Heart J*. 2008;16(2):60-1.
- Meester JAN, Verstraeten A, Schepers D, et al. Differences in manifestations of Marfan syndrome, Ehlers-Danlos syndrome, and Loeys-Dietz syndrome. *Ann Cardiothorac Surg*. 2017;6(6):582-94.
- Dev V, Goswami KC, Shrivastava S, et al. Echocardiographic diagnosis of aneurysm of the sinus of Valsalva. *Am Heart J*. 1993;126(4):930-6.
- Labovitz AJ, Noble VE, Bierig M, et al. Focused cardiac ultrasound in the emergent setting: a consensus statement of the American Society of Echocardiography and American College of Emergency Physicians. *J Am Soc Echocardiogr*. 2010;23(12):1225-30.
- Weinreich M, Yu PJ, Trost B. Sinus of Valsalva aneurysms: review of the literature and an update on management. *Clin Cardiol*. 2015;38(3):185-9.
- Hiratzka LF, Bakris GL, Beckman JA, et al. 2010 ACCF/AHA/AATS/ACR/ASA/SCA/SCAI/SIR/STS/SVM guidelines for the diagnosis and management of patients with Thoracic Aortic Disease: a report of the American College of Cardiology Foundation/American Heart Association Task Force on Practice Guidelines, American Association for Thoracic Surgery, American College of Radiology, American Stroke Association, Society of Cardiovascular Anesthesiologists, Society for Cardiovascular Angiography and Interventions, Society of Interventional Radiology, Society of Thoracic Surgeons, and Society for Vascular Medicine. *Circulation*. 2010;121(13):e266-369.
- Xiao JW, Wang QG, Zhang DZ, et al. Clinical outcomes of percutaneous or surgical closure of ruptured sinus of Valsalva aneurysm. *Congenit Heart Dis*. 2018;13(2):305-10.
- Yan F, Huo Q, Qiao J, et al. Surgery for sinus of Valsalva aneurysm: 27-year experience with 100 patients. *Asian Cardiovasc Thorac Ann*. 2008;16(5):361-5.

False Elevation of Volume Determined by Bladder Scanner Secondary to Bowel Obstruction

Sean Schowalter, MD*

Zaid Altawil, MD[†]

Elissa M. Schechter-Perkins, MD, MPH[†]

Joseph R. Pare, MD, RDMS[†]

*Beth Israel Deaconess Medical Center, Department of Internal Medicine,
Boston, Massachusetts

[†]Boston Medical Center, Department of Emergency Medicine,
Boston, Massachusetts

Section Editor: Rick A. McPheeters, DO

Submission history: Submitted September 8, 2019; Revision received November 29, 2019; Accepted December 19, 2019

Electronically published February 24, 2020

Full text available through open access at http://escholarship.org/uc/uciem_cpem

DOI: 10.5811/cpcem.2019.12.45103

Bladder scanners allow for quick determination of bladder volumes (BV) with minimal training. BV measured by a machine is generally accurate; however, circumstances exist in which falsely elevated BVs are reported. This case details a patient with a significant small bowel obstruction (SBO) due to superior mesenteric artery syndrome causing a falsely elevated BV. We believe this is the first case report of a SBO causing an elevated BV by bladder scanner. Emergency physicians should be aware of the pitfalls of using bladder scanners, and use their point-of-care ultrasound skills when possible to expand their differential. [Clin Pract Cases Emerg Med. 2020;4(2):158–160.]

INTRODUCTION

Bladder scanners have seen widespread use in emergency departments (ED) due to their ease of use and relatively low cost of application.¹ They can be used by registered nurses (RN), and are helpful in determining the presence of acute urinary retention, saving patients the discomfort of undergoing unnecessary bladder catheterization.¹ However, their use is not without diagnostic pitfalls. Previous case reports have documented inaccurate bladder volume (BV) measurements attributed to pelvic structures such as ovarian cysts and uterine myomas.^{2,3,4,5} In the following case, we present a previously unreported cause of falsely elevated BV due to abdominal pathology.

CASE REPORT

A 56-year-old female with a history of latent tuberculosis, stage IIIA non-small cell lung cancer status post right lower and middle lobectomy and lymph node dissection four months prior, was transferred from an outside hospital with concern for sepsis. She spoke only Mandarin; limited history was provided by her daughter at the bedside. Her daughter reported that the patient came to the hospital after two episodes of syncope. Her review of systems was positive for one week of worsening nausea, abdominal discomfort, poor oral intake, several episodes of bilious vomiting, and difficulty urinating. She had not had a bowel movement in the prior three days but was passing flatus.

Abnormal vital signs at the outside hospital included a blood pressure of 80/53 millimeters of mercury (mmHg) and a heart rate of 124 beats per minute.

Relevant abnormal laboratory results from outside hospital records included a leukocyte count of 16.7×10^9 cells per liter (L) (reference: $4.0\text{--}11.0 \times 10^9$ cells/L), a lactate of 6.1 millimoles (mmol)/L (reference: 0.9–1.7 mmol/L), and a sodium of 124 milliequivalents (mEq)/L (reference: 135–145 mEq/L). Her electrocardiogram was significant for sinus tachycardia. Outside hospital (OSH) chest radiography revealed unchanged chronic right hydropneumothorax without infiltrate, and an OSH abdominal radiograph report showed no evidence of an ileus or an obstruction. Prior to arrival at our institution, the patient received two liters of normal saline along with intravenous vancomycin, ceftriaxone and metronidazole.

Upon examination in our ED she was noted to be afebrile, and her blood pressure had improved to 97/54 mmHg. Her tachycardia had resolved. The patient appeared chronically ill and lethargic with a tense, diffusely tender abdomen. Repeat laboratory investigations demonstrated resolution of her elevated lactate and stable leukocytosis. A tentative diagnosis of urosepsis was made.

Given the need for a urine sample and concern for urinary retention per history, an RN performed a bladder scan in preparation for catheterization, which estimated a volume of 900

milliliters (mL). A Foley catheter was placed with removal of 600 mL of urine. On repeat bladder scan, a value of 900mL was again obtained. Discordance between bladder scan and catheterization prompted the physician to perform a point-of-care ultrasound (POCUS), which showed severely dilated bowel loops filled with fluid, concerning for a small bowel obstruction (SBO) (Image 1).

A computed tomography (CT) was ordered to confirm the diagnosis and showed marked fluid distention of the distal esophagus, stomach, and proximal duodenum to the level of the superior mesenteric artery (SMA) consistent with a SBO (Image 2). Given the distribution, findings were attributed to SMA syndrome.

A nasogastric tube was placed, which returned three liters of fecalized fluid. The patient was admitted under the general surgery service. She underwent initial lysis of her ligament of Treitz, and ultimately required duodenal jejunostomy to treat her obstruction.

DISCUSSION

Dedicated bladder scanners are a useful, non-invasive, and accurate tool for the evaluation of patients with suspected urinary retention.¹ By incorporating automated algorithms that calculate BVs, these machines have become easier to use and are essentially user-independent.⁶ This allows novice operators, including RNs, to be easily and quickly trained in their use. However, this convenience has also come at the cost of specificity, with false positive rates cited as high as 9%.^{2,7}

Possible reasons for falsely elevated BVs include ovarian and renal cysts,^{2,4} uterine myomas,³ and ascites.⁵ These elevations are likely due to an inability of bladder scanners to differentiate between fluid in the bladder and other hypochoic areas in the pelvis. This has important implications, as falsely elevated BVs can lead to unnecessary catheterizations and a delay in diagnosis, as was evident in this case. Fortunately, the physician was able to use POCUS to visualize the bladder and

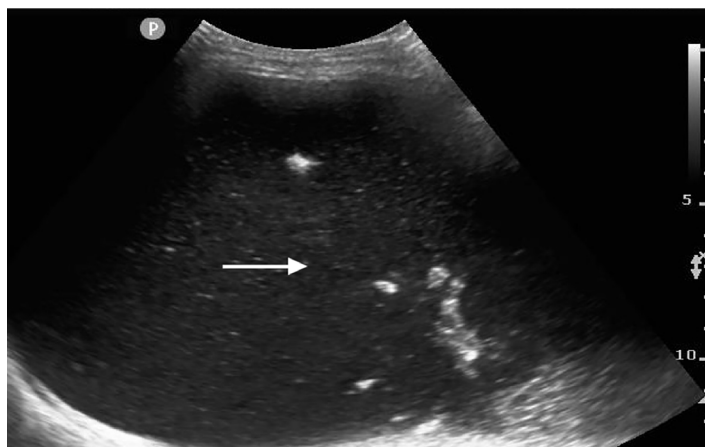


Image 1. Transverse ultrasound view of abdomen demonstrating a large amount of fluid and fecal matter within a massively distended loop of bowel. Arrow is within a distended loop of bowel.

CPC-EM Capsule

What do we already know about this clinical entity?

There are many causes of falsely elevated bladder volumes on bladder scanners including ovarian cysts, renal cysts, ascites, or uterine myomas.

What makes this presentation of disease reportable?

This was the first report of falsely elevated bladder volume due to small bowel obstruction.

What is the major learning point?

Falsely elevated volumes as measured by bladder scanners occurs in up to 9% of bladder scans.

How might this improve emergency medicine practice?

Although bladder scanners are an extremely useful tool, physicians should recognize that there are several causes of falsely elevated bladder volume.

adjacent structures to suggest the alternate diagnosis of SBO and expedite management. POCUS has been previously shown to have high sensitivity (94-100%) and specificity (81-100%) for the detection of SBO.⁸ While the current gold standard for diagnosing SBO is CT, diagnosis requires an elevated index of suspicion, and delays in obtaining CT imaging may occur.⁹ As shown in the case, POCUS was used to resolve diagnostic inaccuracies by bladder scanner and abdominal radiography.

CONCLUSION

This case represents the first report of a falsely elevated bladder volume by bladder scanner attributed to a bowel obstruction. This emphasizes the importance of further workup in cases of discordance between volumes obtained by bladder scanner and catheterization. SBO is a potentially life-threatening condition and a delay in diagnosis can lead to increased morbidity and mortality.¹⁰ Therefore, physicians should be aware of the pitfalls of routine automated bladder scanners, and use their POCUS skills when possible to expand their differential.

Documented patient informed consent and/or Institutional Review Board approval has been obtained and filed for publication of this case report.

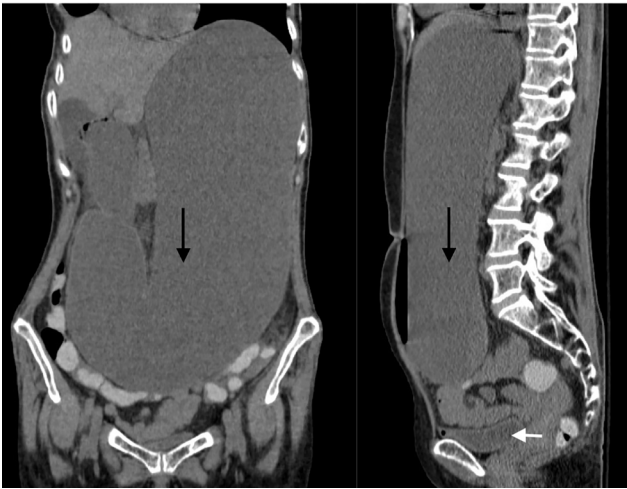

Image 2. (a) Coronal computed tomography(CT) image demonstrating a markedly distended loop of bowel; (b) Sagittal CT image demonstrating a markedly distended loop of bowel, as well as partial view of the bladder. Black arrows represent the loop of bowel. White arrow points to the bladder.

Address for Correspondence: Zaid Altawil, MD, Boston University School of Medicine and Boston Medical Center, 1 Boston Medical Center Place, Boston, MA 02118. Email: zaid.altawil@bmc.org.

Conflicts of Interest: By the CPC-EM article submission agreement, all authors are required to disclose all affiliations, funding sources and financial or management relationships that could be perceived as potential sources of bias. The authors disclosed none.

Copyright: © 2020 Schowalter et al. This is an open access article distributed in accordance with the terms of the Creative Commons Attribution (CC BY 4.0) License. See: <http://creativecommons.org/licenses/by/4.0/>

REFERENCES

1. Palese A, Buchini S, Deroma L, et al. The effectiveness of the ultrasound bladder scanner in reducing urinary tract infections: a meta-analysis. *J Clin Nurs*. 2010;19(21-22):2970-9.
2. Cho KH, Song JH, Kim WB, et al. Ovarian cystadenoma mistaken as postvoid residual urine by portable ultrasound scanning. *J Korean Cont Soc*. 2009;13(2):166.
3. Kim TH, Kim HS, Park JW, et al. Falsely elevated postvoid residual urine volume in uterine myoma. *Ann Rehabil Med*. 2017;41(2):332-6.
4. Alagiakrishnan K and Valpreda M. Ultrasound bladder scanner presents falsely elevated postvoid residual volumes. *Can Fam Physician*. 2009;55(2):163-4.
5. Prentice DM, Sona C, Wessman BT, et al. Discrepancies in measuring bladder volumes with bedside ultrasound and bladder scanning in the intensive care unit: A pilot study. *J Intensive Care Soc*. 2018;19(2):122-6.
6. Massagli TL, Cardenas DD, Kelly EW. Experience with portable ultrasound equipment and measurement of urine volumes: inter-user reliability and factors of patient position. *J Urol*. 1989;142(4):969-71.
7. Marks LS, Dorey FJ, Macairan ML, et al. Three-dimensional ultrasound device for rapid determination of bladder volume. *Urology*. 1997;50(3):341-8.
8. Pourmand A, Dimbil U, Drake A, et al. The accuracy of point-of-care ultrasound in detecting small bowel obstruction in emergency department. *Emerg Med Int*. 2018;2018:3684081.
9. Paulson EK and Thompson WM. Review of small-bowel obstruction: the diagnosis and when to worry. *Radiology*. 2015;275(2):332-42.
10. Fevang BT, Fevang JM, Søreide O, et al. Delay in operative treatment among patients with small bowel obstruction. *Scand J Surg*. 2003;92(2):131-7.

Open Dorsal Proximal Interphalangeal Dislocation

Ryan Derrah, MD
Cameron Wolterstorff, MD

Madigan Army Medical Center, Department of Emergency Medicine,
Tacoma, Washington

Section Editor: Rick A. McPheeters, DO

Submission history: Submitted August 30, 2019; Revision received December 10, 2019; Accepted December 19, 2019

Electronically published April 14, 2020

Full text available through open access at http://escholarship.org/uc/uciem_cpem

DOI: 10.5811/cpem.2019.12.45026

We report a case of a 44-year-old male with an uncommon case of an open dorsal proximal interphalangeal (PIP) dislocation. Although open PIP dislocations are often volar, dorsal dislocations are fraught with complications due to the potential for infection and damage to supportive structures. Features of this case are discussed together with its implications, including lack of standardized management in the literature, use of a closed reduction following copious irrigation, and requirement for antibiotic use. [Clin Pract Cases Emerg Med. 2020;4(2):161–163.]

INTRODUCTION

Dislocations to the proximal interphalangeal (PIP) joint are common in athletes and are typically dorsal, resulting from an axial load on a hyperextended digit.¹ Open dislocations are more commonly seen with volar dislocations and less commonly with dorsal ones.² Open injuries may not respond to normal manual reduction techniques, and therefore require surgical, open reduction.^{2,3,4,5}

CASE REPORT

A 44-year-old man, right-hand dominant, presented to our emergency department with pain and deformity to his right index finger. The injury had occurred just prior to arrival when his finger was struck while playing basketball. Radiographs from triage revealed a dorsal dislocation of the second PIP joint without evidence of fracture (Image 1).

On exam, the middle phalanx was displaced dorsally and there was a transverse laceration to the volar surface of the PIP joint exposing the flexor tendon (Images 2 and 3). This was consistent with an open PIP dislocation. Since the patient was neurovascularly intact and orthopedics was readily available, immediate reduction was not attempted and the consulting service contacted. Orthopedics evaluated the patient, anesthetized the digit, copiously irrigated the wound, reduced the dislocation, sutured, and applied a splint. Orthopedics did not recommend antibiotics, and the patient was closely followed by the orthopedics service as an outpatient. At two-month follow-up, the patient continued to have mild swelling, stiffness, and decreased flexion range of motion of the affected PIP joint.

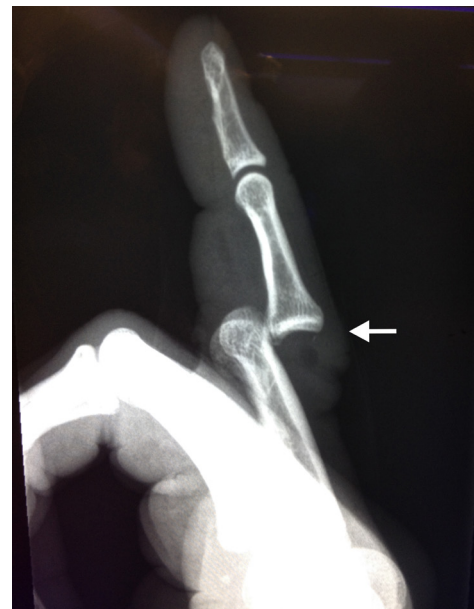

Image 1. Lateral radiograph of right index finger demonstrating dorsal dislocation of the proximal interphalangeal joint without evidence of fracture (arrow).

DISCUSSION

There are no clear guidelines or consensus for the treatment and management of open dorsal PIP dislocations, including antibiotic use. A literature search revealed a paucity of current literature dedicated specifically to this type of injury; most were orthopedic review articles

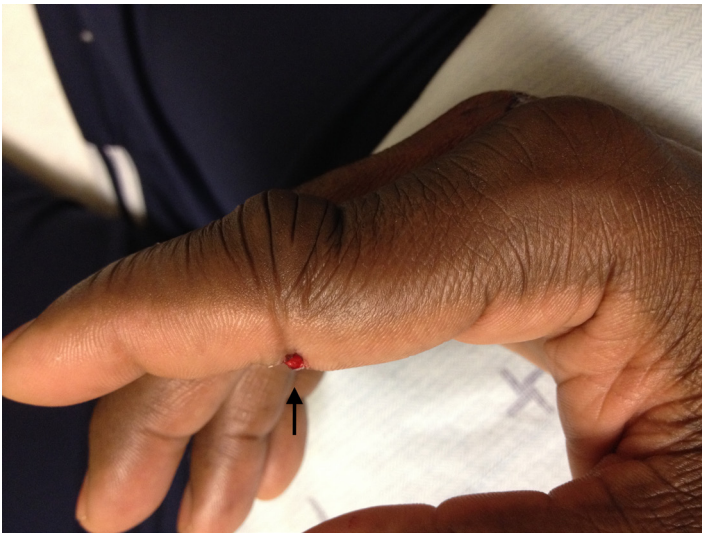

Image 2. Dorsal displacement and deformity to right index finger with laceration to volar portion of the finger (arrow).

regarding closed PIP injuries with only a cursory mention of open dislocations. The most relevant papers were two case series from the 1980s^{4,5}; however, these were reported from an orthopedic perspective and most of the patients were treated operatively.

Although open dorsal PIP dislocations may require open reduction, some are amenable to standard closed reduction, such as in our case. Preferably, anesthesia should be obtained via digital block after neurovascular assessment and prior to manipulation. As with closed dorsal dislocations, the PIP joint should be hyperextended (exaggerating the injury)

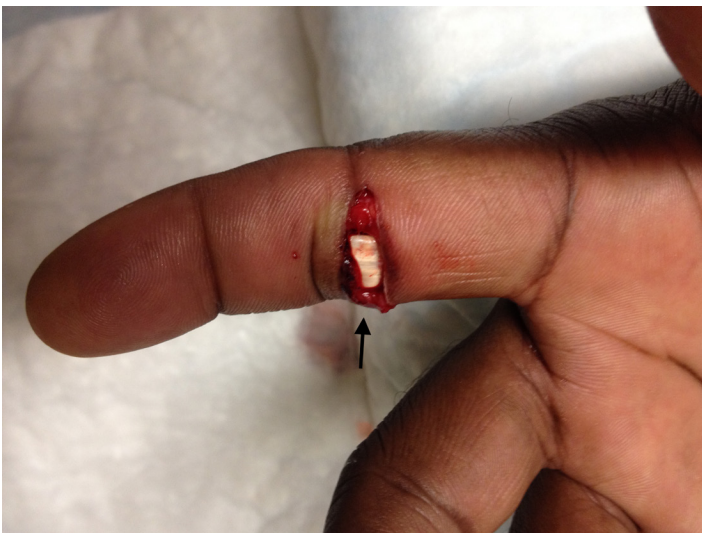

Image 3. Laceration over volar proximal interphalangeal joint, exposing flexor tendon (arrow).

CPC-EM Capsule

What do we already know about this clinical entity?

Open proximal interphalangeal (PIP) dislocations are often resistant to usual manual reduction techniques and may require surgical reduction.

What makes this presentation of disease reportable?

Open PIP dislocations are most commonly volar; dorsal dislocations can result in numerous complications.

What is the major learning point?

Open dorsal PIP dislocations may appear innocuous but are fraught with complications due to the potential for infection and damage to supportive structures.

How might this improve emergency medicine practice?

This case helps illustrate the need for specialist consultation and follow-up.

while maintaining axial traction, applying volar-directed pressure on the middle phalanx, followed by gently flexing the PIP joint.^{1,6}

There are some differing recommendations in the orthopedic/sports medicine literature regarding splinting vs “buddy taping” the finger after successful reduction.^{1,7,8} However, most of these are in the context of closed dislocations with a stable PIP joint following reduction. A conservative and safe approach would be splinting at 20-30 degrees flexion⁶ and ensuring prompt follow-up with a hand specialist, since prolonged splinting is associated with increased stiffness and contractures and early range of motion is essential.²

Although the laceration may appear superficial and innocent, it represents a direct communication to the PIP joint and surrounding structures.⁵ If grossly contaminated, surgical washout is required.⁹ In our case, the wound was relatively clean and washout was accomplished in the ED with copious irrigation. Antibiotics were deferred per orthopedic recommendation since the wound was not grossly contaminated and had been thoroughly irrigated, and open reduction was not required. However, many authors do recommend empiric antibiotics in cases of open dislocations.^{5,6,9}

CONCLUSION

Open dorsal PIP dislocations may appear innocuous but are fraught with complications due to the potential for infection and damage to supportive structures.⁵ It is important for emergency providers to recognize the significance of an open injury and obtain appropriate specialty consultation. Patients should be educated regarding potential sequelae including infection, stiffness, swelling, pain, and contractures.⁷ Discharge instructions should also emphasize the importance of close follow-up with a hand specialist and compliance with rehab.

The signed attestation by the corresponding author that this institution does not require Institutional Review Board approval for case reports has been obtained and filed for publication of this case report.

REFERENCES

1. Bindra RR and Foster BJ. Management of proximal interphalangeal joint dislocations in athletes. *Hand Clin.* 2009;25(3):423-35.
2. Freiberg A. Management of proximal interphalangeal joint injuries. *Can J Plast Surg.* 2007;15(4):199-203.
3. Muraoka S, Furue Y, Kawashima M. Irreducible open dorsal dislocation of the proximal interphalangeal joint: a case report. *Hand Surg.* 2010;15(1):61-4.
4. Green SM and Posner MA. Irreducible dorsal dislocations of the proximal interphalangeal joint. *J Hand Surg Am.* 1985;10(1):85-7.
5. Stern PJ and Lee AF. Open dorsal dislocations of the proximal interphalangeal joint. *J Hand Surg Am.* 1985;10(3):364-70.
6. Franko OI. Dislocation reduction of the PIP and DIP joints. 2012. Available at: <http://www.proceduresconsult.com/medical-procedures/dislocation-reduction-of-the-pip-and-dip-joints-IM-025-procedure.aspx#>. Accessed November 2, 2018.
7. Mangelson JJ, Stern P, Abzug JM, et al. Complications following dislocations of the proximal interphalangeal joint. *J Bone Joint Surg Am.* 2013;95(14):1326-32.
8. Paschos NK, Abuhemoud K, Gantsos A, et al. Management of proximal interphalangeal joint hyperextension injuries: a randomized controlled trial. *J Hand Surg Am.* 2014;39(3):449-54.
9. Freiberg A, Pollard BA, Macdonald MR, et al. Management of proximal interphalangeal joint injuries. *J Trauma.* 1999;46(3):523-8.

Address for Correspondence: CPT Ryan Derrah, MD, Madigan Army Medical Center, Department of Emergency Medicine, 9040 Jackson Ave., Tacoma, WA 98431. Email: ryan.r.derrah.mil@mail.mil.

Conflicts of Interest: By the CPC-EM article submission agreement, all authors are required to disclose all affiliations, funding sources and financial or management relationships that could be perceived as potential sources of bias. The authors disclosed none. The views expressed here are those of the authors and do not reflect the official policy of the Department of the Army, the Department of Defense, or the US Government.

Copyright: © 2020 Derrah et al. This is an open access article distributed in accordance with the terms of the Creative Commons Attribution (CC BY 4.0) License. See: <http://creativecommons.org/licenses/by/4.0/>

An Atypical Presentation of Cystic Echinococcosis

Bhavana Tetali, BS*†
Daniel C. Grahf, MD*‡
Elian D. Abou Asala, MD*
Daniel Axelson, MD‡

*Henry Ford Health System, Department of Internal Medicine, Detroit, Michigan
†Wayne State University School of Medicine, Detroit, Michigan
‡Henry Ford Health System, Department of Emergency Medicine, Detroit Michigan

Section Editor: Scott Goldstein, MD

Submission history: Submitted November 10, 2019; Revision received January 7, 2020; Accepted January 6, 2020

Electronically published February 24, 2020

Full text available through open access at http://escholarship.org/uc/uciem_cpccm

DOI: 10.5811/cpcem.2020.1.45842

Cystic echinococcosis (CE) is an infection caused by the *Echinococcus granulosus* tapeworm. CE generally manifests in the liver, but it may present in any organ. These patients often first present to the emergency department. Mortality over 10 years is significant for those who go undiagnosed. We report the case of a 34-year-old patient who immigrated from Yemen six years earlier. She presented with acute onset dysuria, suprapubic pain, and fever. Imaging revealed a primary multicystic mass on the right renal pole with a secondary lesion in the right hepatic lobe. On further investigation, the patient's serum was positive for echinococcus antibodies. [Clin Pract Cases Emerg Med. 2020;4(2):164–166.]

INTRODUCTION

Cystic echinococcosis (CE) is an infection caused by the *Echinococcus granulosus* tapeworm, which results in the creation of cystic structures within a range of visceral organs. Ninety percent of these cysts are in the liver or lungs. The cysts can be filled with thousands of “brood” capsules that in definitive hosts evaginate and invade surrounding host tissues. The definitive host is most often canines with intermediate hosts being sheep, cattle, and pigs.¹ Humans are incidental hosts for CE; they most frequently ingest eggs via the fecal oral route from contaminated food or water. In the United States, cases are quite rare and most are found in immigrants from endemic countries. It is estimated that these cysts enlarge by about 1-5 centimeters (cm) per year, although rates are highly variable.^{2,3} Patients may remain asymptomatic for years. Those that develop symptoms may go undiagnosed for a long period of time, especially given the low prevalence of CE in the US and the nonspecific symptoms that arise. If left unidentified and untreated, mortality from CE is estimated to be 90% by 10 years.⁴

In this case, we discuss a patient who presented to the emergency department (ED) with genitourinary complaints and was diagnosed with cystic echinococcosis (CE) of primary renal involvement, a rare anatomic location. The case exemplifies the diagnostic workup and acute management of extrahepatic CE in the ED in a high-risk patient.

CASE REPORT

A 34-year-old female with no past medical history presented to the ED complaining of dysuria, suprapubic pain,

generalized myalgias, and subjective fever for one-day duration. The patient denied recent travel, sick contacts, or contact with animals, but she had immigrated from Yemen six years prior. On presentation, the patient was febrile to 38.8° Celsius and tachycardic to 133 beats per minute. Complete blood count and lactic acid were within normal limits, and urinalysis was not consistent with a urinary tract infection.

On imaging, ultrasound revealed a complex cystic mass originating from the right upper renal pole (Image A). Evaluation by computed tomography (CT) showed a large subcapsular multicystic mass with hyperdense internal septation on the right kidney suggestive of CE, as well as a small, hypoattenuating lesion in the right lobe of the liver (Image B).⁵ Further imaging by magnetic resonance (MRI) confirmed the subcapsular multicystic mass along the right kidney measuring 7 x 5.2 x 6.1 cm consistent with CE stage III and a 1.7 cm cystic lesion in the right hepatic lobe also consistent with CE (Image C). Serum immunoglobulin G (IgG) for echinococcus was positive. The patient was diagnosed with echinococcal disease and was initiated on albendazole 200 milligrams twice a day for 3-4 months, with future plans for surgical intervention.

DISCUSSION

Echinococcal disease is caused by infection with the *Echinococcus granulosus* tapeworm with the majority of cases originating in the Middle East, South and Central America, and some sub-Saharan African countries. The clinical presentation of *Echinococcus* infection is largely dependent on the location and size of the cysts. Small or calcified cysts may

be asymptomatic, whereas larger cysts may cause mass effect, obstruction to blood or urine flow, or may present as toxic-appearing with rupture or secondary bacterial infection.⁵⁻⁷ Ruptured cysts can cause an anaphylaxis-like reaction of varying severity. Some cysts present with symptoms up to several decades after initial infection or remain asymptomatic indefinitely.⁵⁻⁷ Our patient had immigrated to the US from Yemen six years earlier, suggesting that her disease has been asymptomatic for a minimum of six years, if not longer.

The most common sites of cystic involvement are the liver (approximately 66%), followed by the lungs (25%). Less commonly reported sites include the brain, kidneys, muscle, bone, and heart.⁵⁻⁷ Cysts in the kidneys are rare, and have been reported to cause hematuria and flank pain and can potentially result in glomerulonephritis and secondary amyloidosis.⁵⁻⁷ Our patient's primary renal cyst was large enough to cause mass effect, leading to dysuria and suprapubic pain. At the time of presentation, she did not complain of hematuria or flank pain.

Generally, diagnosis of echinococcal disease is made with both imaging and serology. With regard to imaging, ultrasonography is 90-95% sensitive for CE, and CT is only moderately better at 95-100% sensitivity; however, CT is superior to ultrasonography for evaluation of extrahepatic cysts. MRI offers no major advantage over CT. Our patient had imaging by all three modalities, with CT and MRI both providing better results on the size and nature of cysts than ultrasonography (Image). When considering serology, antibody detection has greater sensitivity than antigen detection.⁹ Our patient tested positive for echinococcal IgG. IgE and IgM were not pursued as echinococcal IgG is known to have better sensitivity.

Management of these cysts are based on the WHO classification criteria and typically use a combination of observation, albendazole, PAIR (percutaneous puncture, aspiration, injection, re-aspiration), and surgery.¹⁰ Our patient's renal cyst was classified as WHO stage III, for which the recommended treatment is albendazole followed by either PAIR or surgery. Alcohol injection was not pursued given the

CPC-EM Capsule

What do we already know about this clinical entity?
Cystic echinococcosis is a parasitic infection that results in the creation of cystic structures in visceral organs, most commonly in the liver or lungs.

What makes this presentation of disease reportable?
We discuss a patient who was diagnosed with cystic echinococcosis of primary renal involvement, a rare anatomic location.

What is the major learning point?
Although these cysts are often found in the liver or lungs, they can arise in almost any organ and symptoms are often specific to the organ system affected.

How might this improve emergency medicine practice?

This case reports a rare presentation of an uncommon disease in the United States and reviews diagnostic and treatment guidelines.

size of the cyst and risk of rupture. She was discharged on albendazole and scheduled follow-up with infectious disease, urology, and general surgery.

CONCLUSION

Though echinococcal disease is uncommon in the US, careful attention should be paid in individuals who have emigrated from endemic countries within the prior 10 years given that the mortality of unidentified and untreated individuals is significant. While the liver and lungs are the most common sites of involvement, it is important to note that cysts can be found

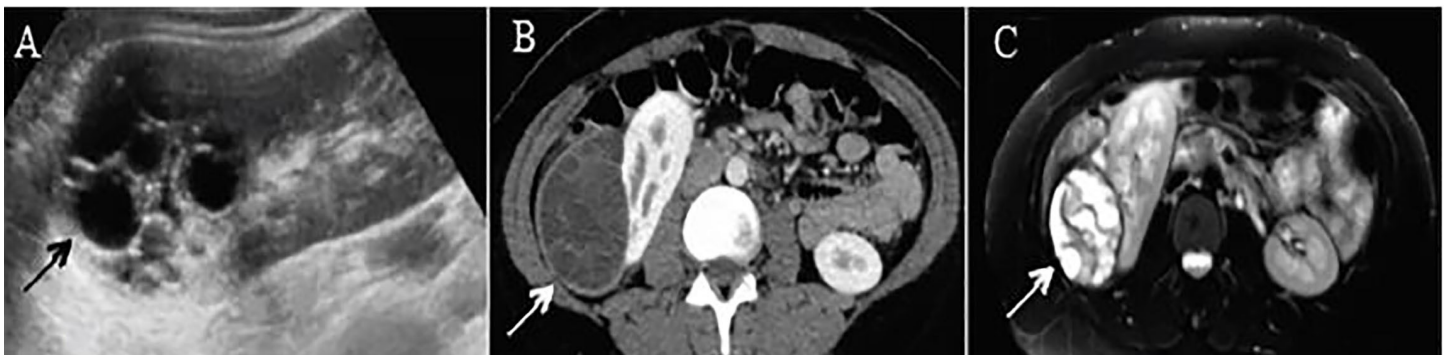

Image. Large, subcapsular multicystic renal mass with internal septations as indicated by the arrow on (A) renal ultrasound, (B) computerized tomography, and (C) magnetic resonance imaging T2.

in almost any anatomic location and the symptoms are often specific to the organ system affected. Cyst rupture can result in an anaphylaxis-like reaction of varying severity. The best imaging modality for extrahepatic cysts in particular is by CT. The majority of these patients should be started on albendazole in the ED, with definitive treatment often requiring evaluation by several subspecialists including those in infectious disease, interventional radiology, and surgery.

Documented patient informed consent and/or Institutional Review Board approval has been obtained and filed for publication of this case report.

Address for Correspondence: Daniel Axelson, MD, Henry Ford Health System, Department of Emergency Medicine, 2799 W Grand Blvd, Emergency Medicine-ECFP 250, Detroit, MI 48202. Email: daxelso1@hfhs.org.

Conflicts of Interest: By the CPC-EM article submission agreement, all authors are required to disclose all affiliations, funding sources and financial or management relationships that could be perceived as potential sources of bias. The authors disclosed none.

Copyright: © 2020 Tetali et al. This is an open access article distributed in accordance with the terms of the Creative Commons Attribution (CC BY 4.0) License. See: <http://creativecommons.org/licenses/by/4.0/>

REFERENCES

- Centers for Disease Control and Prevention. Parasites - Echinococcosis. 2012. Available at: <https://www.cdc.gov/parasites/echinococcosis/index.html>. Accessed September 21, 2019.
- Frider B, Larrieu E, Odriozola M. Long-term outcome of asymptomatic liver hydatidosis. *J Hepatol*. 1999;30(2):228-31.
- Moro PL, Gilman RH, Verastegui M, et al. Human hydatidosis in the central Andes of Peru: evolution of the disease over 3 years. *Clin Infect Dis*. 1999;29:807-12.
- Ammann RW, Eckert J. Cestodes. Echinococcus. *Gastroenterol Clin North Am*. 1996;25(3):655-89.
- Gogus C, Safak M, Baltaci S, et al. Isolated renal hydatidosis: experience with 20 cases. *J Urol*. 2003;169(1):186-9.
- Ali-Khan Z and Rausch RL. Demonstration of amyloid and immune complex deposits in renal and hepatic parenchyma of Alaskan alveolar hydatid disease patients. *Ann Trop Med Parasitol*. 1987;81(4):381-92.
- Gelman R, Brook G, Green J, et al. Minimal change glomerulonephritis associated with hydatid disease. *Clin Nephrol*. 2000;53(2):152-5.
- El-Tahir MI, Omojola MF, Malatani T, et al. Hydatid disease of the liver: evaluation of ultrasound and computed tomography. *Br J Radiol*. 1992;65(773):390-2.
- McManus DP, Zhang W, Li J, et al. Echinococcosis. *Lancet*. 2003;362(9392):1295-304.
- Brunetti E, Kern P, Vuitton DA, et al. Expert consensus for the diagnosis and treatment of cystic and alveolar echinococcosis in humans. *Acta Trop*. 2010;114(1):1-16.

Intracranial Hemorrhage Due to Secondary Hypertension from Intracranial Large Vessel Occlusion

Amit Rawal, MD*
Alex Waldman, MD*
Omar Saeed, MD†‡
Asif A. Khan, MD§

*North Florida Regional Medical Center, Department of Emergency Medicine, Gainesville, Florida

†University of Tennessee Health Science Center, Department of Neurology, Memphis, Tennessee

‡Zeenat Qureshi Stroke Institute, St. Cloud, Minnesota

§North Florida Regional Medical Center, Department of Vascular and Interventional Neurology, Gainesville, Florida

Section Editor: Rick A. McPheeters, DO

Submission history: Submitted August 17, 2019; Revision received January 27, 2020; Accepted January 23, 2020

Electronically published March 2, 2020

Full text available through open access at http://escholarship.org/uc/uciem_cpem

DOI: 10.5811/cpcem.2020.1.44908

Simultaneous hemorrhagic and ischemic strokes have been previously reported in the literature. Typically, these occur in patients secondary to dialysis, cerebral amyloid angiopathy, or thrombotic thrombocytopenic purpura.^{1,2,3} However, this is the unique case of a 62-year-old Asian female who presented with a hemorrhagic stroke suspected to be secondary to refractory hypertension from intracranial large vessel atherosclerotic flow limiting stenosis, with rapid subsequent large vessel occlusion and ischemic stroke. Questions arise such as ideal blood pressure parameters for dual management, timeliness of computed tomography angiography imaging in the emergency department for detection of large vessel occlusion during intracranial hemorrhage, and subsequent selection of treatment plan in the dual-lesion patient population. [Clin Pract Cases Emerg Med. 2020;4(2):167–170.]

INTRODUCTION

The occurrence of ischemic stroke in those with flow-limiting intracranial atherosclerotic stenosis is well documented and continues to be one of the most common causes of stroke worldwide.^{4,5,6} The incidence of intracranial atherosclerotic disease is known to be higher in the Asian and African-American populations.⁷ While cases of dual strokes with both hemorrhagic and ischemic components due to other etiology have been previously described, there is a paucity of literature in regard to intracranial hemorrhage (ICH) due to refractory secondary hypertension resulting from intracranial flow-limiting atherosclerotic occlusion. This is a case of a patient who arrived to the emergency department (ED) with a hypertensive-appearing brainstem intraparenchymal hemorrhage who was subsequently found to have severe flow-limiting intracranial stenosis that developed into ischemic cerebral infarction.

CASE REPORT

A 62-year-old, right-handed, Asian female with history of known refractory hypertension and diabetes mellitus

was brought into the ED via emergency medical services (EMS) as a stroke alert soon after experiencing sudden onset of neurologic symptoms. The patient was driving with her husband from San Francisco to Miami when she experienced confusion, slurred speech, and right-sided weakness, which subsequently progressed to unresponsiveness. En route to the ED, EMS reported a blood pressure of 240/120 millimeters of mercury (mmHg) and a glucose level of 133 milligrams per deciliter (mg/dL).

Upon arrival, her Glasgow Coma Scale was seven. Her neurologic examination demonstrated right-sided hemiplegia, left-sided withdrawal to pain, a rightward gaze preference, and reactive pupils. The patient was immediately intubated in the ED for airway protection. Initial vital signs following intubation were as follows: blood pressure 270/159 mmHg; pulse 78 beats per minute; temperature 36.7 degrees Celsius; respiratory rate 18 breaths per minute (on ventilator); pulse oximetry 100% (on 100% fraction of inspired oxygen); and body mass index of 23.5 kilograms per meter squared (kg/m²) (reference range 18.5–24.9 kg/m²). The patient was started

on a nicardipine infusion with a goal systolic blood pressure less than 190-200 mmHg and a propofol infusion for sedation before being taken for imaging.

Initial non-contrast computed tomography (CT) of the brain revealed an ICH that arose in the pons and extended into the fourth ventricle. Her only risk factor for developing the hemorrhagic stroke was the known refractory hypertension. The size of the hemorrhage measured 3.4 centimeters (cm) by 2.0 cm with a volume less than 30 milliliters (mL) (Image 1). An ICH score of three was given, suggesting a 72% mortality. The initial complete blood count and coagulation studies were within normal limits. Intracranial pressure-lowering management was initiated, which included the following: 3% hypertonic saline bolus; 30-degree head of bed elevation; and hyperventilation to target partial pressure of carbon dioxide of 35 mmHg (reference range 35-45 mmHg). Strict systolic blood pressure control to less than 140 mmHg was started with nicardipine infusion as part of the management for ICH. After initiating these measures, an emergent CT angiogram (CTA) was obtained to rule out aneurysm or arteriovenous malformation.

CTA showed a near occlusion of the left M1 (horizontal proximal) segment of the middle cerebral artery (MCA), which appeared to be chronic (Image 2). The patient was admitted to the intensive care unit with cerebral angiogram scheduled for the following morning to evaluate for left MCA stenosis or cryptogenic malformation. The cerebral angiogram

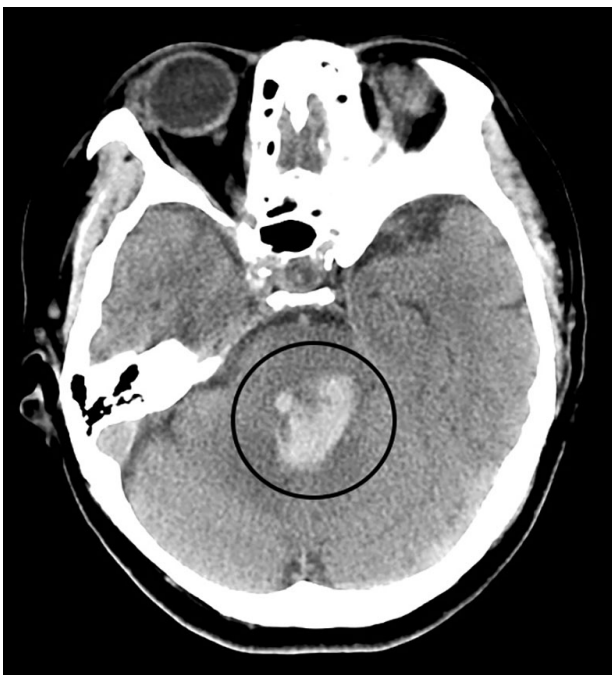


Image 1. Non-contrast computed tomography brain demonstrating pontine hemorrhage with fourth ventricle involvement (circle).

CPC-EM Capsule

What do we already know about this clinical entity?

There are established guidelines for blood pressure management, imaging modalities, and definitive treatment options to manage either ischemic or hemorrhagic stroke.

What makes this presentation of disease reportable?

This report discusses the novel presentation of a patient with simultaneous ischemic and hemorrhagic strokes secondary to hypertension from intracranial atherosclerotic stenosis.

What is the major learning point?

Clarity is needed for clinical parameters and treatment options in the dual-lesion patient.

How might this improve emergency medicine practice?

Care will be improved with better-defined management standards and other special consideration, given the unique pathophysiology in dual ischemic and hemorrhagic lesions.

revealed a nearly occluded left M1 MCA with surrounding stenosis involving the proximal M1, multiple M2 branch points, A2 (vertical, post communicating, infracallosal), and A3 (precallosal) anterior cerebral artery branch points consistent with severe intracranial atherosclerosis (Image 3). There was evidence of neovascularization suggesting chronicity of stenosis. Revascularization of the stenotic lesions at this time was considered extraordinarily high risk with the concurrent ICH due to the need for aspirin and clopidogrel during these procedures.

On hospital day three, due to concern for developing hydrocephalus, an external ventricular drain was placed, which measured normal intracranial pressure. On hospital day five, increased lethargy was noted while the patient was off of sedative medication. A repeat non-contrast CT of the brain at this time demonstrated a new, low attenuated area involving the high posterior aspect of the left frontal lobe in a MCA watershed area (Image 4). The patient's neurologic condition continued to decline, and her course was further complicated by aspiration pneumonia. The family ultimately elected to withdraw care, and she passed peacefully on hospital day nine.

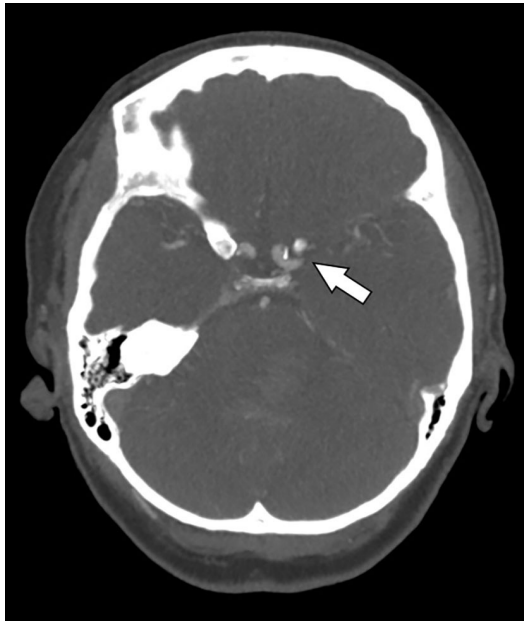


Image 2. Computed tomography angiogram demonstrating left middle cerebral artery occlusion (arrow).

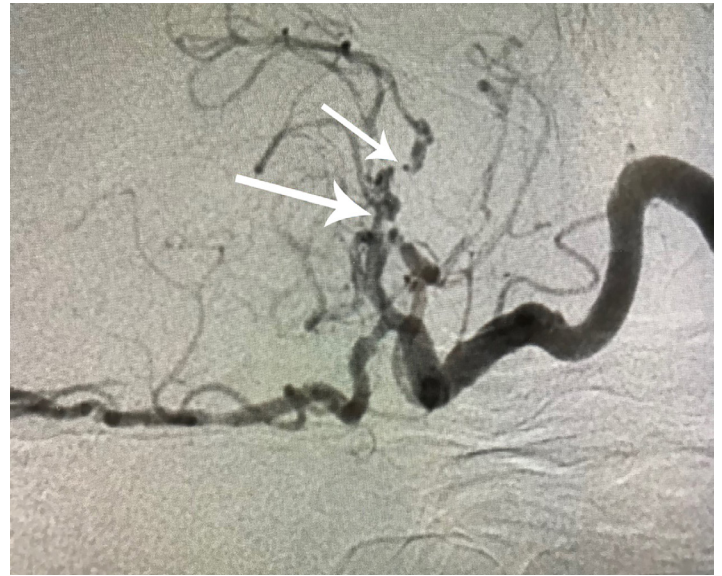


Image 3. Cerebral angiogram demonstrating near occlusion of left M1 (long arrow) and stenosis of left M2 middle cerebral artery (short arrow).

DISCUSSION

Some of the common risk factors for developing intracranial atherosclerotic disease are hypertension, smoking, diabetes mellitus, and hyperlipidemia.⁶ Race and gender also play a major role in the development of extracranial vs intracranial atherosclerotic disease.⁸ Higher incidence of intracranial atherosclerotic disease is seen in Asians from China, Japan, and Korea.⁹ In the Caucasian population, there was a decline in stroke incidence between 1990 and 2005. However, no such decline was seen in the African-American population, whose stroke rates are higher compared to both Caucasian and Southeast Asian groups.¹⁰

Intracranial arteries are made up of endothelium with smooth muscle cells and an extracellular matrix comprised mostly of collagen and elastin. Stroke due to intracranial atherosclerotic disease is caused by hemodynamic failure, in-situ thrombus from plaque disruption, and/or distal thromboembolism.¹¹ Secondary hypertension due to intracranial atherosclerotic disease is a common compensatory mechanism to maintain adequate cerebral perfusion.

Previous reports have discussed the occurrence of simultaneous hemorrhagic and ischemic events in patients secondary to dialysis, cerebral amyloid angiopathy, or thrombotic thrombocytopenic purpura.^{1,2,3} Examples of events include expanding hemorrhagic intracranial hematoma with subsequent edema that causes compression of adjacent vessels leading to ischemic stroke. There are many other mechanisms for developing ischemic stroke, which can be attributed to embolism, thrombosis, or systemic hypoperfusion.¹² In this particular patient, however, the ischemic event occurred in the

contralateral side of the hemorrhage and in a watershed pattern consistent with hypoperfusion from the underlying stenotic lesion after the lowering of blood pressure to manage the ICH. The concurrent presence of cerebral edema refractory to conventional intravenous treatments may have also contributed to the hemodynamic changes resulting in ischemic stroke.

This patient had severe refractory secondary hypertension due to flow-limiting intracranial atherosclerotic disease. We hypothesize this to be the major contributing factor to her hypertensive ICH. This has implications regarding ideal blood pressure management in the emergent setting. Questions arise whether to decrease blood pressure to limit hemorrhage extension and rebleeding or whether to maintain blood pressure to allow perfusion of the oligemic watershed parenchyma. Ideal blood pressure parameters in patients with both intracranial atherosclerotic disease and intracranial hemorrhage is currently unknown. Current American Stroke Association guidelines for ICH recommend lowering systolic blood pressure to 140 mmHg.¹³ However, patients who have ICH and flow limiting stenosis may benefit from higher blood pressure parameters to maintain adequate cerebral perfusion.

Another important point concerns the timing of CTA in the ED for patients with ICH. The common benefits of routine CTA imaging would include evaluation for aneurysm, malformations, and other intracranial vascular anomalies often seen in spontaneous hemorrhage. CTA also assists in the selection of aneurysmal treatment planning. An additional benefit of CTA in the ED during ICH would be identifying intracranial stenosis, similar to this case, which may be the underlying cause of secondary hypertension.

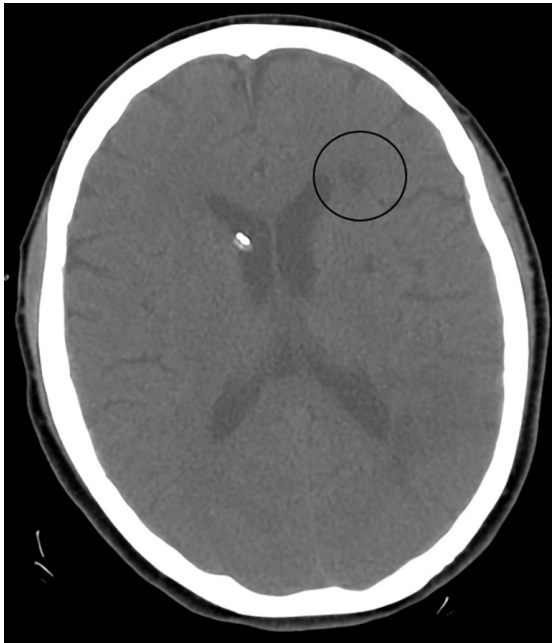

Image 4. Non-contrast computed tomography brain demonstrating a low attenuated area of the left frontal lobe in a middle cerebral artery watershed area (circle).

CONCLUSION

This is a case of intracranial hemorrhage secondary to refractory hypertension due to severe intracranial atherosclerotic stenosis. Further exploration is needed of the critical questions that arise, such as ideal blood pressure parameters for management, timeliness and routine use of CTA in the ED, and subsequent selection of treatment plan in the dual-lesion patient populations.

Documented patient informed consent and/or Institutional Review Board approval has been obtained and filed for publication of this case report.

REFERENCES

1. Toyoda K, Kumai Y, Fujii K, et al. Simultaneous onset of haemorrhagic and ischaemic strokes in a haemodialysis patient. *J Neurol Neurosurg Psychiatry*. 2002;72(5):673-4.
2. Guzzini F, Conti A, Esposito F. Simultaneous ischemic and hemorrhagic lesions of the brain detected by CT scan in a patient with thrombotic thrombocytopenic purpura. *Haematologica*. 1998;83(3):280.
3. Kang DW, Han MK, Kim HJ, et al. New ischemic lesions coexisting with acute intracerebral hemorrhage. *Neurology*. 2012;79(9):848-55.

Address for Correspondence: Amit Rawal, MD, North Regional Medical Center, Department of Emergency Medicine, 6500 W. Newberry Rd, Gainesville, FL 32605. Email: rawal.amit.r@gmail.com.

Conflicts of Interest: By the CPC-EM article submission agreement, all authors are required to disclose all affiliations, funding sources and financial or management relationships that could be perceived as potential sources of bias. The authors disclosed none.

Copyright: © 2020 Rawal et al. This is an open access article distributed in accordance with the terms of the Creative Commons Attribution (CC BY 4.0) License. See: <http://creativecommons.org/licenses/by/4.0/>

4. Matsui R, Nakagawa T, Takayoshi H, et al. A prospective study of asymptomatic intracranial atherosclerotic stenosis in neurologically normal volunteers in a Japanese cohort. *Front Neurol*. 2016;7:39.
5. Park KY, Chung CS, Lee KH, et al. Prevalence and risk factors of intracranial atherosclerosis in an asymptomatic Korean population. *J Clin Neurol*. 2006;2(1):29-33.
6. Holmstedt CA, Turan TN, Chimowitz MI. Atherosclerotic intracranial arterial stenosis: risk factors, diagnosis, and treatment. *Lancet Neurol*. 2013;12(11):1106-14.
7. Gorelick PB, Wong KS, Bae HJ, et al. Large artery intracranial occlusive disease: a large worldwide burden but a relatively neglected frontier. *Stroke*. 2008;39(8):2396-9.
8. Wityk RJ, Lehman D, Klag M, et al. Race and sex differences in the distribution of cerebral atherosclerosis. *Stroke*. 1996;27(11):1974-80.
9. Rincon F, Sacco RL, Kranwinkel G, et al. Incidence and risk factors of intracranial atherosclerotic stroke: the Northern Manhattan Stroke Study. *Cerebrovasc Dis*. 2009;28(1):65-71.
10. Guzik A and Bushnell C. Stroke epidemiology and risk factor management. *Continuum (Minneapolis, Minn)*. 2017;23(1, Cerebrovascular Disease):15-39.
11. Mohammad Y, Qattan M, Prabhakaran S. Epidemiology and pathophysiology of intracranial large artery stenosis. *The Open Atherosclerosis Thromb J*. 2010;3:3-7.
12. Deb P, Sharma S, Hassan KM. Pathophysiologic mechanisms of acute ischemic stroke: An overview with emphasis on therapeutic significance beyond thrombolysis. *Pathophysiology*. 2010;17(3):197-218.
13. Hemphill JC 3rd, Greenberg SM, Anderson CS, et al. Guidelines for the management of spontaneous intracerebral hemorrhage: a guideline for healthcare professionals from the American Heart Association/American Stroke Association. *Stroke*. 2015;46(7):2032-60.

Serotonin Syndrome versus Cannabis Toxicity in the Emergency Department

Jacob W. Baltz, MD*
Lamanh T. Le, PharmD†

*CoxHealth System, Department of Emergency Medicine, Springfield, Missouri
†CoxHealth System, Department of Pharmacy, Springfield, Missouri

Section Editor: Rick A. McPheeters, DO

Submission history: Submitted October 2, 2019; Revision received January 13, 2020; Accepted January 23, 2020

Electronically published March 2, 2020

Full text available through open access at http://escholarship.org/uc/uciem_cpccm

DOI: 10.5811/cpcem.2020.1.45410

As more states legalize marijuana, the potential of marijuana abuse could lead to an increase in the number of emergency department (ED) visits. We describe two patients who presented to the ED with dilated pupils, rigidity in both lower extremities, and clonus in both feet after inhaling the vapor of a highly potent form of marijuana. Serotonin syndrome diagnosis was initially considered in the differential diagnosis. Ultimately, high-potency marijuana abuse was the final diagnosis. Therefore, marijuana toxicity should be considered in ED patients who present with signs and symptoms similar to that of serotonin syndrome. [Clin Pract Cases Emerg Med. 2020;4(2):171–173.]

INTRODUCTION

As the legalization of cannabis becomes prevalent in the United States, effects from its abuse will result in an increase in emergency department (ED) visits.¹ We have witnessed a growing trend in our community ED among adolescents abusing a highly potent form of marijuana, butane hash oil (BHO). BHO is a concentrated form of tetrahydrocannabinol (THC) that is created by using liquid butane as a solvent to extract THC from marijuana plants. As butane is highly flammable, reports of burns and explosions have been reported from the synthesis and use of BHO. A popular trend called “dabbing” involves heating the concentrated oil and inhaling the resultant vapors. These vapors contain very high concentrations of THC, as high as 90% pure. Adolescents may use e-cigarette devices to abuse BHO as a delivery device. Such devices are easily concealed and produce almost no odor, thus leading to the potential for abuse at school and in the home.^{2,3}

Previous case reports have shown BHO abuse may lead to agitation along with neurotoxicity and cardiotoxicity.^{3,4} Since THC may activate serotonin receptors and inhibit serotonin reuptake, its abuse in high concentrations may mimic serotonin syndrome.⁵ We present two cases of adolescents with recent “dabbing” use who exhibited signs and symptoms of serotonin syndrome.

CASE REPORT

Case 1

A 17-year-old female presented to a large community ED by emergency medical services (EMS) from her home for

a possible seizure. EMS providers had witnessed agitation, altered mental status, tachycardia, muscle stiffness and tremors in the limbs, and administered 10 milligrams (mg) of midazolam intranasally. History was obtained from the EMS providers and the patient’s parents who were present in the room. The patient had been taking sertraline 50 mg daily and had also been prescribed a short course of cyclobenzaprine 5 mg every eight hours, as needed, for “muscle aches.” According to the parents, the patient had taken “a few” but stopped the cyclobenzaprine as it was not effective. No history of drug overdose or recent illness was obtained.

Upon arrival to the ED, the patient was obtunded (likely secondary to benzodiazepine), but would occasionally follow commands. Her Glasgow Coma Score was eight, scoring two points for eye-opening response, two points for verbal response, and four points for motor response. Vital signs revealed blood pressure of 135/81 millimeters of mercury (mmHg), pulse 124 beats per minute (bpm), rectal temperature of 99.6 degrees Fahrenheit (F), and 97% pulse oximetry on room air. Physical exam revealed dilated pupils of six millimeters (mm), normal neck exam, normal lung sounds, a soft and non-tender abdomen, and normal heart sounds. A neurological exam revealed rigidity in both lower extremities with a sparing of rigidity in the arms. Deep tendon reflexes showed sustained clonus in both feet, and the presence of hyper-reflexivity in the patella tendons bilaterally but with normal reflexes in the upper extremities.

Lab results showed a normal complete blood count, normal creatine kinase, normal comprehensive metabolic profile, normal arterial blood gas, normal prolactin level,

and a urine drug screen positive for THC. Electrocardiogram showed sinus tachycardia, and a non-contrasted head computed tomography was normal. Serotonin syndrome was considered in the differential diagnosis. After pediatric critical care and pediatric neurology consultation, one oral dose of cyprohepatidine 4 mg was administered. The patient was admitted to the pediatric intensive care unit. Magnetic resonance imaging of the brain was normal, and an electroencephalogram showed no epileptic activity. The patient rapidly improved and was discharged the following day. Prior to discharge, the patient admitted to “dabbing” about 30 minutes prior to arrival to the hospital. The same patient returned to the ED the following night with a similar presentation, once again associated with dabbing.

Case 2

A 16-year-old male took “a hit from a dab pen” while on the bus to school. He developed altered mental status and was transported to the ED. On arrival he was mildly obtunded, Glasgow Coma Score was 13 (three for eye-opening response, four verbal response, and six motor response). Vital signs were recorded as blood pressure 152/86 mmHg, pulse 116 bpm, oral temperature 98.6° F and 100% pulse oximetry on room air. Physical exam showed dilated pupils to five mm, tachycardia, and rigidity of the lower extremities with non-sustained clonus in the legs bilaterally. Lab results were normal with the exception of a drug screen positive for THC. This patient slowly improved over six hours of observation in the ED and was discharged home.

DISCUSSION

Psychotic states, cardiac toxicity, and neurotoxicity have been reported as clinical sequelae of THC-induced toxicity.^{4,6} Our cases show additional harmful side effects of highly concentrated THC when abused by adolescents in its vapor, or “dabbing” form. Although the cases did not show all of the hallmarks of a true serotonin syndrome, some overlap existed in physical exam findings. Serotonin syndrome may show vital sign abnormalities such as tachycardia, hypertension, and hyperthermia. Physical exam findings of serotonin syndrome may reveal agitation, ocular clonus, dilated pupils, tremor, deep tendon hyper-reflexia, muscle clonus, dry mucus membranes, and flushed skin with diaphoresis.⁷

The most striking exam finding in these two ED patients was the lower extremity rigidity with hyper-reflexivity. Animal studies have demonstrated that potent cannabinoid receptor agonists may activate the serotonin receptors (5-hydroxytryptamine_{1A} and 5-hydroxytryptamine_{2A}), and THC inhibits serotonin re-uptake.^{5,8} Therefore, it is likely that emergency physicians may see some of the hallmarks of serotonin syndrome in “dabbing” users.

CONCLUSION

Medical marijuana and cannabidiol have been used and proved to be medically safe and effective; however, as

CPC-EM Capsule

What do we already know about this clinical entity?

Serotonin syndrome and marijuana abuse are recognizable conditions encountered in the practice of emergency medicine.

What makes this presentation of disease reportable?

We report two cases of high-potency marijuana abuse that mimicked serotonin syndrome.

What is the major learning point?

When encountering potential serotonin syndrome, a thorough social history and drug testing may be needed to rule out a disease mimic.

How might this improve emergency medicine practice?

As legalized marijuana becomes more prevalent, emergency physicians should be aware of this disease mimic.

marijuana use grows there is increased access of cannabinoid products, including high-concentrate THC's. Our cases reflect that adolescents who abuse THC by heating and then inhaling the concentrated vapor, can present with signs and symptoms that mimic serotonin syndrome. For that reason, high-potency marijuana abuse should be considered when encountering young adults in the ED with these exam findings.

Documented patient informed consent and/or Institutional Review Board approval has been obtained and filed for publication of this case report.

Address for Correspondence: Jacob W. Baltz, MD, CoxHealth System, Department of Emergency Medicine, 3801 South National Avenue, Springfield, MO 65807. Email: Jacob.baltz@coxhealth.com.

Conflicts of Interest: By the CPC-EM article submission agreement, all authors are required to disclose all affiliations, funding sources and financial or management relationships that could be perceived as potential sources of bias. The authors disclosed none.

Copyright: © 2020 Baltz et al. This is an open access article distributed in accordance with the terms of the Creative Commons Attribution (CC BY 4.0) License. See: <http://creativecommons.org/licenses/by/4.0/>

REFERENCES

1. Volkow ND and Baler R. Emergency department visits from edible versus inhalable cannabis. *Ann Intern Med.* 2019;170(8):569-70.
2. Meier MH. Associations between butane hash oil use and cannabis-related problems. *Drug Alcohol Depend.* 2017;179:25-31.
3. Alzghari SK, Fung V, Rickner SS, et al. To dab or not to dab: rising concerns regarding the toxicity of cannabis concentrates. *Cureus.* 2017;9(9):e1676.
4. Rickner SS, Cao D, Kleinschmidt K, et al. A little "dab" will do ya' in: a case report of neuro-and cardiotoxicity following use of cannabis concentrates. *Clin Toxicol (Phila).* 2017;55(9):1011-3.
5. Hill MN, Sun JC, Tse Mt, et al. Altered responsiveness of serotonin receptor subtypes following long-term cannabinoid. *Int J Neuropsychopharmacol.* 2006;9(3):277-86.
6. Johns A. Psychiatric effects of cannabis. *Br J Psychiatry.* 2001;178:116-22.
7. Boyer EW and Shannon M. The serotonin syndrome. *N Engl J Med.* 2005;352(11):1112-20.
8. Egashira N, Mishima K, Katsurabayashi S. et al. Involvement of 5-hydroxytryptamine neuronal system in delta(9)-tetrahydrocannabinol-induced impairment of spatial memory. *Eur J Pharmacol.* 2002;445(3):221-9.

Pyogenic Flexor Tenosynovitis as a Rare Complication of Dyshidrotic Eczema

Waroot S. Nimjareansuk, DO
Michael Rosselli, MD

Mount Sinai Medical Center, Department of Emergency Medicine, Miami Beach, Florida

Section Editor: Austin Smith, MD

Submission history: Submitted October 2, 2019; Revision received January 4, 2020; Accepted January 23, 2020

Electronically published March 27, 2020

Full text available through open access at http://escholarship.org/uc/uciem_cpem

DOI: 10.5811/cpem.2020.1.45414

Introduction: Pyogenic flexor tenosynovitis is an unusual complication of dyshidrotic eczema. The diagnosis has traditionally been made by Kanavel's signs. Point-of-care ultrasound can be a useful adjunct in the diagnosis of this surgical emergency.

Case Report: We report the case of a 23-year-old male who presented with right middle finger pain and swelling and an overlying eczematous rash. The use of point-of-care ultrasound was performed to aid in the diagnosis of pyogenic flexor tenosynovitis. An incision and drainage was performed with deep wound cultures positive for *Staphylococcus aureus*.

Discussion: The presentation of pyogenic flexor tenosynovitis with underlying concomitant dermatological disease can complicate this challenging diagnosis. Point-of-care ultrasound can be an effective adjunct in revealing pyogenic flexor tenosynovitis rather than relying solely on the classical Kanavel's signs, leading to earlier treatment.

Conclusion: Our case demonstrates that point-of-care ultrasound can be a rapid and effective tool for the diagnosis of pyogenic flexor tenosynovitis in the setting of superimposed dermatological diseases. [Clin Pract Cases Emerg Med. 2020;4(2):174–177.]

Keywords: *flexor tenosynovitis; pyogenic; eczema; dyshidrotic; ultrasound.*

INTRODUCTION

Pyogenic flexor tenosynovitis (PFT) is an acute infection of the synovial flexor tendon sheath often presenting first to the emergency department (ED). This aggressive, closed-space infection is classically diagnosed in patients presenting with the four Kanavel's signs: uniform swelling; tenderness at the flexor tendon sheath; the digit held in flexion; and pain on passive extension.¹ The natural history of PFT usually presents two to five days after a penetrating injury and rarely by hematogenous spread.² Bacterial introduction into the skin is a common occurrence in those with predisposing dermatologic diseases as a result of self-induced skin breakdown or skin microbiome alterations owing to an imbalance of staphylococci over streptococcus.³ However, the large majority of cases result in cellulitis and not in PFT. The diagnosis of PFT is

challenging but one that must be made at the patient's first encounter as it is a surgical emergency. In conjunction with the clinical exam findings, point-of-care ultrasound (POCUS) can assist with the diagnosis of PFT and, therefore, avoid loss of hand function or amputation in severe cases.⁴

CASE REPORT

A 23-year-old right-handed male presented to the ED with right middle finger pain and swelling throughout the day. The swelling rapidly progressed over four hours predominately at the palmar aspect of the middle finger. The patient reported working as a chef and wore gloves on a daily basis. He denied trauma, fever, chills, sore throat, joint pain, penile discharge, or genital sores. He had a history of eczema mainly affecting the bilateral palmar hands and had allergies to dust, pollen, and cat

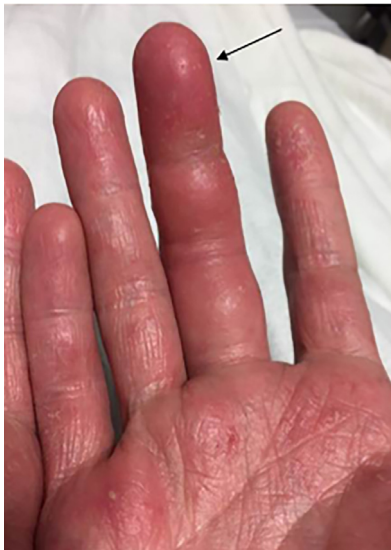

Image 1. Palmar aspect of the patient's right hand. There is erythema and swelling (black arrow) of the right middle finger held in slight flexion. An associated scaly eczematous skin eruption is shown.

dander. The patient reported using Cetaphil cream and took loratadine and diphenhydramine often. He denied any allergies to medication and had no surgeries in the past. The patient had been sexually active with one female partner for the prior six years and denied any history of sexually transmitted infections. He smoked half a pack of cigarettes per day for three years but quit one month prior. He also drank alcohol twice per month and smoked marijuana once per month.

His vitals in the ED were oral temperature 98.4 degrees Fahrenheit, heart rate of 77 beats per minute, blood pressure 128/76 millimeters of mercury, respiratory rate of 17 breaths per minute, and oxygen saturation of 99% on room air. He was well appearing and in no acute distress. His right middle finger was held in slight flexion with fusiform swelling and tenderness at the flexor surface (Image 1). He had pain with passive extension of his finger but sensation was intact. He also had a scaly erythematous skin eruption with desquamation and excoriations of his bilateral palms with several one-millimeter pustules. Laboratory testing revealed a leukocytosis of 12.69×10^3 cells per liter (L) (reference range: $4.8\text{-}10.8 \times 10^3$ cells/L) with left shift and plain film radiographs of the right hand and fingers were unremarkable. An ED POCUS of the right middle finger was performed showing anechoic fluid within the flexor tendon sheath (Images 2 and 3).

Based on clinical exam and ultrasound findings, the patient was diagnosed with flexor tenosynovitis of the right middle finger and started on vancomycin and ceftriaxone intravenously. The patient was admitted to the hospital with hand surgery consultation. He subsequently underwent an incision and

CPC-EM Capsule

What do we already know about this clinical entity?

Pyogenic flexor tenosynovitis (PFT) has traditionally been diagnosed using Kanavel's signs and requires emergent surgical intervention.

What makes this presentation of disease reportable?

PFT is a vital but rare diagnosis in the setting of concomitant overlying dermatological diseases.

What is the major learning point?

Point-of-care ultrasound (POCUS) can be used as an adjunct to diagnose PFT in the setting of an uncertain clinical picture.

How might this improve emergency medicine practice?

Emergency physicians can use clinical findings with the aid of POCUS to solidify the diagnosis of PFT.

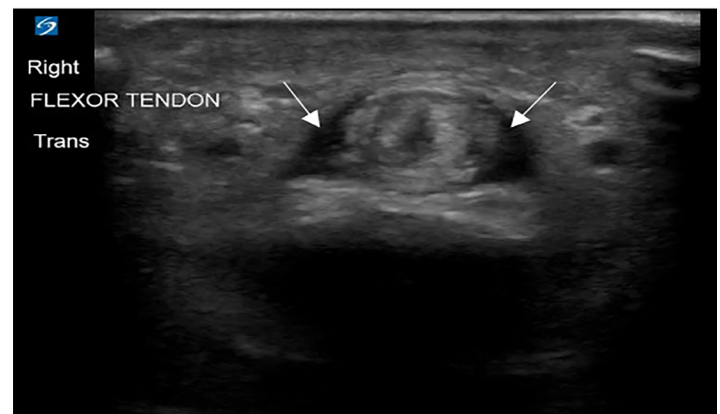


Image 2. Transverse ultrasound view of the right middle finger. The image displays anechoic fluid (white arrows) surrounding the flexor tendon within the tendon sheath.

drainage. Deep wound cultures were positive for *Staphylococcus aureus* with blood cultures producing no growth. Subsequent gonorrhea, syphilis, and human

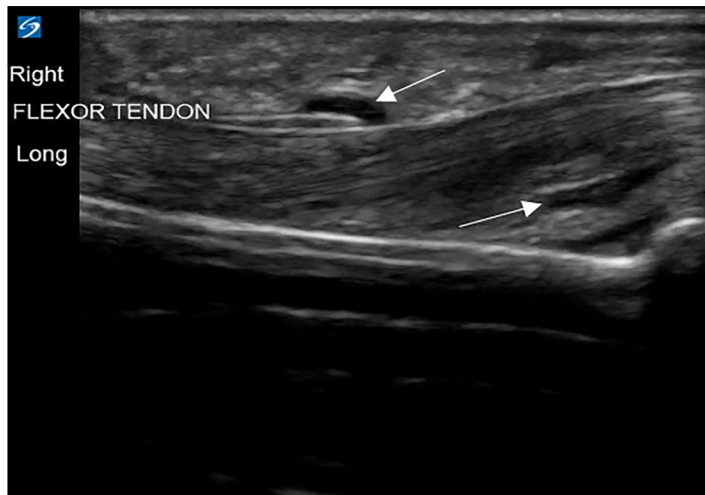

Image 3. Longitudinal ultrasound view of the right middle finger. The image displays the striated flexor tendon with anechoic fluid (white arrows) above and below the tendon.

immunodeficiency virus-1/2 testing was negative. Dermatology was consulted and the patient was diagnosed with atopic dermatitis with dyshidrotic eczema. Dermatology recommended that the patient be treated with triamcinolone 0.1% ointment once a day, clobetasol 0.05% ointment once a day, and hydroxyzine 25 milligrams at bedtime as needed. The patient improved and was discharged home on hospital day three status post incision and drainage with amoxicillin-clavulanic acid for five days and outpatient follow-up with hand surgery.

DISCUSSION

Flexor tenosynovitis is a time-sensitive diagnosis that can result in severe morbidity due to complications such as adhesions, deep space infection, tendon rupture, or amputation.^{2,4,5} Although traditionally diagnosed by the classic Kanavel's signs, there is no published study validating these signs. Dailiana et al showed that only 54% of patients had all four signs in a retrospective review.⁶ Two studies have evaluated the individual signs among patients with PFT. Pang et al showed that fusiform swelling was the most common sign in patients diagnosed with PFT and that pain along the flexor tendon sheath was a late sign.⁷ In addition, Neviaer and Gunther proposed that the earliest Kanavel's sign was pain on extension and also proposed that the inability to flex the finger entirely to the palm was an additional sign of PFT.⁸

To further complicate a challenging clinical diagnosis, most cases of PFT are caused by direct inoculation from trauma to the finger and may appear minor or even innocuous from a scrape or a scratch.⁹ This was likely the case in our patient with dyshidrotic eczema. Secondary bacterial infection of dyshidrotic eczema resulting in cellulitis is not uncommon.¹⁰ Thus, POCUS in the ED can be a useful adjunct

to elucidate the diagnosis of PFT vs cellulitis.

The normal flexor tendon sheath does not have an appreciable amount of fluid when visualized on ultrasound as the parietal and visceral layers of the sheath form a sealed synovium.^{11,12} Hypoechoic or anechoic fluid within the flexor tendon sheath has been shown to correlate with purulent discharge upon surgical intervention.^{13,14} A study published by Jardin et al showed ultrasound findings of peritendinous effusion, and thickened synovial sheath had a sensitivity of 94%, specificity of 74%, and negative predictive value of 96.7%.¹⁵ Therefore, the presence of fluid within the flexor tendon sheath can aid in the diagnosis of PFT.

CONCLUSION

Pyogenic flexor tenosynovitis may not present with all the typical Kanavel's signs. To make the detection of the disease even more challenging, overlying dermatologic diseases may mask this diagnosis. Performing a POCUS in the ED is an effective and timely adjunct to support the diagnosis of PFT, leading to earlier treatment with antibiotics and/or surgical intervention.

The documented Institutional Review Board policy has been obtained and filed for publication of this case report.

Address for Correspondence: Waroot S. Nimjareansuk, DO, Mt Sinai Medical Center, Department of Emergency Medicine, 4300 Alton Rd, Miami Beach FL 33140. Email: Waroot.nimjareansuk@msmc.com.

Conflicts of Interest: By the CPC-EM article submission agreement, all authors are required to disclose all affiliations, funding sources and financial or management relationships that could be perceived as potential sources of bias. The authors disclosed none.

Copyright: © 2020 Nimjareansuk et al. This is an open access article distributed in accordance with the terms of the Creative Commons Attribution (CC BY 4.0) License. See: <http://creativecommons.org/licenses/by/4.0/>

REFERENCES

1. Kanavel A. (1912). *Infection of the Hand*. 1st ed. Philadelphia and New York: Lea and Febiger.
2. Draeger RW and Bynum DK. Flexor tendon sheath infections of the hand. *J Am Acad Orthop Surg*. 2012;20(6):373-82.

3. SanMiguel A and Grice EA. Interactions between host factors and the skin microbiome. *Cell Mol Life Sci.* 2015;72(8):1499-515.
4. Giladi AM, Malay S, Chung KC. Management of acute pyogenic flexor tenosynovitis: literature review and current trends. *J Hand Surg Eur Vol.* 2015;40(7):720-8.
5. Padrez K, Bress J, Johnson B, et al. Case report: bedside ultrasound identification of infectious flexor tenosynovitis in the emergency department. *West J Emerg Med.* 2015;16(2):260-2.
6. Dailiana ZH, Rigopoulos N, Varitimidis S, et al. Purulent flexor tenosynovitis: factors influencing the functional outcome. *J Hand Surg Eur Vol.* 2008;33(3):280-5.
7. Pang HN, Teoh LC, Yam AK, et al. Factors affecting the prognosis of pyogenic flexor tenosynovitis. *J Bone Joint Surg Am.* 2007;89(8):1742-8.
8. Neviasser RJ and Gunther SF. Tenosynovial infections in the hand: diagnosis and management. *Instr Course Lect.* 1980;29:108-28.
9. Kennedy CD, Huang JI, Hanel DP. In brief: Kanavel's signs and pyogenic flexor tenosynovitis. *Clin Orthop Relat Res.* 2016;474(1):280-4.
10. Wollina U. Pompholyx: A review of clinical features, differential diagnosis, and management. *Am J Clin Dermatol.* 2010;11(5):305-14.
11. Bianchi S, Martinoli C, de Gautard R, et al. Ultrasound of the digital flexor system: normal and pathological findings. *J Ultrasound.* 2007;10(2):85-92.
12. Boles SD and Schmidt CC. Pyogenic flexor tenosynovitis. *Hand Clin.* 1998;14(4):567-78.
13. Jeffrey RB Jr, Lain FC, Schechter WP, et al. Acute suppurative tenosynovitis of the hand: diagnosis with US. *Radiology.* 1987;162(3):741-2.
14. Schechter WP, Markison RE, Jeffrey RB, et al. Use of sonography in the early detection of suppurative flexor tenosynovitis. *J Hand Surg Am.* 1989;14(2 Pt 1):307-10.
15. Jardin E, Delord M, Aubry S, et al. Usefulness of ultrasound for the diagnosis of pyogenic flexor tenosynovitis: a prospective single-center study of 57 cases. *Hand Surg Rehabil.* 2018;37(2):95-8.

Heterotopic Pregnancy Diagnosed with Point-of-care Ultrasound in the Emergency Department: A Case Report

Ian J. Holley, MD
Sean P. Stickles, MD

Washington University School of Medicine in St. Louis, Department of Emergency Medicine, St. Louis, Missouri

Section Editor: Shadi Lahham, MD

Submission history: Submitted November 19, 2019; Revision received February 3, 2020; Accepted February 7, 2020

Electronically published April 23, 2020

Full text available through open access at http://escholarship.org/uc/uciem_cpem

DOI: 10.5811/cpcem.2020.2.45933

Introduction: Heterotopic pregnancies are rare. However, they are occurring with increasing frequency. Unfortunately, diagnosis is frequently delayed, with patients presenting in extremis.

Case Report: We present a case of a heterotopic pregnancy diagnosed by point-of-care ultrasound (POCUS) in a woman presenting with lower abdominal pain, who had a documented normal first trimester ultrasound the day prior to presentation.

Discussion: Given the increasing rates of heterotopic pregnancies, we can no longer be reassured by the presence of an intra-uterine pregnancy (IUP) in a patient with concerning signs and symptoms of a ruptured ectopic pregnancy. A thorough POCUS evaluation of the uterus and adnexa is essential for the diagnosis of heterotopic pregnancy in the emergency department.

Conclusion: This case highlights the value POCUS brings to the emergency department evaluation of patients in early pregnancy. [Clin Pract Cases Emerg Med. 2020;4(2):178–180.]

Keywords: *Heterotopic pregnancy; Point-of-care ultrasound; POCUS; Emergency Medicine.*

INTRODUCTION

A heterotopic pregnancy occurs when there is an intrauterine pregnancy (IUP) as well as an extrauterine, or ectopic, pregnancy. Traditionally, heterotopic pregnancies have been thought to be extremely rare. This was based on early theoretical calculations from 1948, which estimated the incidence of heterotopic pregnancy to be 1 in 30,000 pregnancies.¹ However, more recent data estimates rates as high as 1:100 – 1:8000,²⁻⁴ with the highest rates occurring in patients undergoing assisted reproductive technologies (ART), such as in vitro fertilization, super ovulation, and intrauterine insemination.³

Unfortunately, owing to the diagnostic challenges, the majority of heterotopic cases present late, with patients presenting in hemorrhagic shock or with an acute abdomen after the ectopic pregnancy ruptures.⁵ Many heterotopic pregnancies are missed on routine emergency department (ED) and obstetrics (OB) ultrasounds after visualization of an IUP.^{2-4,7} In this report we present a case of a patient diagnosed with a ruptured heterotopic

pregnancy via point-of-care ultrasound (POCUS) in the ED following a documented normal IUP on routine OB ultrasound the preceding day.

CASE REPORT

A 27-year-old female, gravida 3, para 1, at eight-weeks gestation and a remote history of treated cervicitis, presented to the ED with a two-day history of diffuse, crampy abdominal pain without vaginal bleeding or urinary symptoms. The patient had been seen in clinic the day prior to ED presentation where she underwent a transvaginal ultrasound and was documented to have a live IUP at eight-weeks gestation with normal uterus and adnexa, and a small amount of free fluid in the cul-de-sac.

In the ED she was tachycardic at 116 beats per minute and normotensive. Her abdomen was diffusely tender. A point-of-care transabdominal pelvic ultrasound was performed to evaluate the pregnancy, which noted a live IUP and left adnexal ectopic pregnancy (Image and Video) with free fluid noted in the pelvis

and Morison's pouch. OB was consulted and agreed with the diagnosis. The patient was taken emergently to the operating room and underwent a left salpingectomy, and 800 milliliters of intra-abdominal blood was evacuated. The patient was able to carry the IUP to term without further complications.

DISCUSSION

Given the rarity of heterotopic pregnancies, the finding of an IUP on ultrasound may lead to false reassurance, resulting in missed extrauterine masses.¹⁻⁵ This may explain why a majority of heterotopic pregnancies are often missed on initial ultrasound imaging.^{2-4,6} While the increased use of ART may attribute to the increased rates of ectopic pregnancies in recent years, up to one half of patients with ectopic pregnancies have no identifiable risk factors.^{2-4,6}

Diagnosis of ectopic pregnancies can be difficult, and diagnosing heterotopic pregnancies are even more so. It is important that providers adopt a thorough evaluative process for women presenting with abdominal and pelvic pain in early pregnancy, with particular focus on physical exam and diagnostics, including POCUS. Physical exam findings in the setting of a ruptured extrauterine pregnancy include diffuse abdominal tenderness to light palpation or cough and cervical motion tenderness, with positive likelihood ratios of 4.2-4.5 and 4.9, respectively.⁷

Findings on ultrasound of an extrauterine pregnancy include the "blob" (extrauterine mixed echogenic mass) and "bagel" (extrauterine sac-like structure) signs in early pregnancy, fetus with measurable heart rate if presenting later,^{2,8} and signs of rupture, including fluid in the pelvis and Morison's pouch. Ultrasound evaluations in early pregnancy should include evaluation in longitudinal and transverse planes throughout the uterus, as well as the adnexa. An initial evaluation using a transabdominal approach with a low-frequency curvilinear probe

is appropriate, but should be followed by a transvaginal approach with a high-frequency endocavitary probe when concerning, but non-diagnostic, findings are noted.

CPC-EM Capsule

What do we already know about this clinical entity?

Heterotopic pregnancies are occurring with increasing frequency, and when missed result in significant morbidity for the patient.

What makes this presentation of disease reportable?

We describe a heterotopic pregnancy diagnosed on emergency department point-of-care ultrasound one day after a documented normal outpatient obstetrics ultrasound.

What is the major learning point?

Pregnant patients with abdominal pain require complete ultrasound assessment of the uterus and adnexa. The presence of intrauterine pregnancy (IUP) does not rule out an ectopic.

How might this improve emergency medicine practice?

Early identification and management of heterotopic pregnancy can provide improved outcomes for both the mother and the IUP.

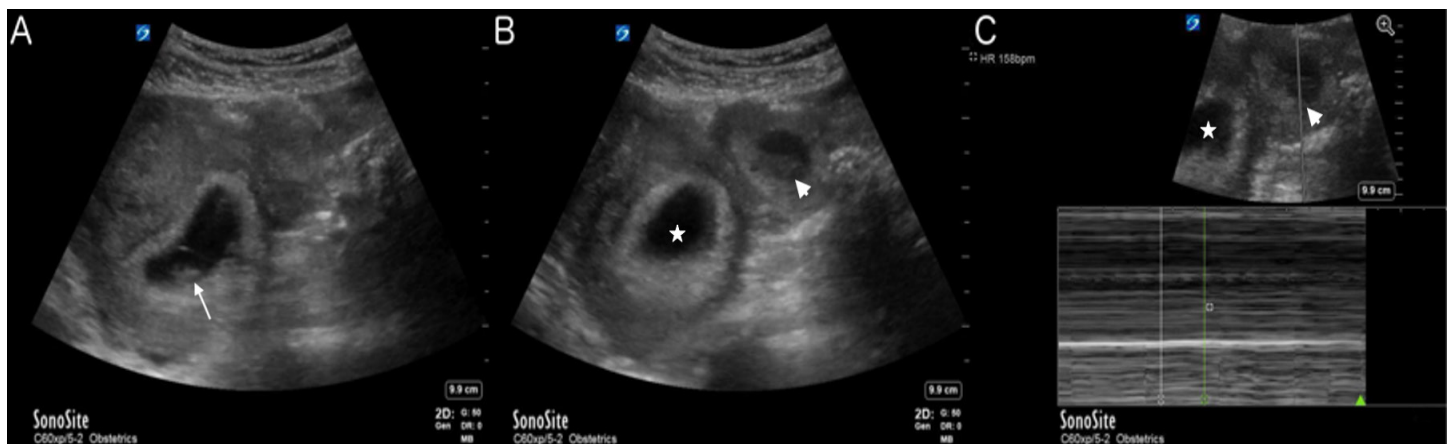


Image. A) Visualized intrauterine pregnancy (arrow); B) Uterus (star) with ectopic pregnancy (arrowhead) seen in the left adnexa; C) Uterus (star) with M-mode through the ectopic pregnancy (arrowhead) demonstrating a fetal heart rate of 158 beats per minute.

Once the heterotopic pregnancy is diagnosed, treatment is surgical. Unlike in ectopic pregnancy, there is no role for methotrexate given the concomitant IUP.⁹ The surgical approach varies based on location of the ectopic, most commonly a laparoscopic approach if stable or laparotomy if unstable.⁹ As with other early-pregnancy bleeding or ectopic rupture, Rhesus negative mothers should be given Rho(D) immune globulin.

CONCLUSION

Heterotopic pregnancy can present a diagnostic challenge in the OB clinic and ED. The increased frequency of heterotopic pregnancy, due to increased use of ART for hopeful mothers, makes it imperative that the era of “an IUP rules out an ectopic” come to an abrupt end. Providers caring for pregnant women should adopt a thorough, formalized evaluative process and consider heterotopic pregnancy in all pregnant women, particularly in those with risk factors, significant symptoms, or concerning ultrasound findings, despite the presence of an IUP.

Video. A transabdominal pelvic ultrasound demonstrating an intrauterine pregnancy (IUP) and a left adnexal mass. M-mode, which is used to determine fetal heart rate, demonstrates heart rates for the IUP and left adnexal mass of 156 beats per minute (bpm) and 158 bpm, respectively. Free fluid is visible in the right upper quadrant in Morrison’s pouch.

Documented patient informed consent has been obtained and filed for publication of this case report.

REFERENCES

1. DeVoe RW and Pratt J. Simultaneous intrauterine and extrauterine pregnancy. *Am J Obstet Gynecol* 1948;56(6):1119-26.

Address for Correspondence: Ian Holley, MD, Washington University School of Medicine in St. Louis, Department of Emergency Medicine, 660 S. Euclid Ave., Campus Box 8072, St. Louis, MO 63110. Email: ianholley@wustl.edu.

Conflicts of Interest: By the CPC-EM article submission agreement, all authors are required to disclose all affiliations, funding sources and financial or management relationships that could be perceived as potential sources of bias. The authors disclosed none.

Copyright: © 2020 Holley et al. This is an open access article distributed in accordance with the terms of the Creative Commons Attribution (CC BY 4.0) License. See: <http://creativecommons.org/licenses/by/4.0/>

2. Kwok TC and Morgan G. Think Heterotopic: A Case Report of Heterotopic Pregnancy Detected on Thorough Ultrasonography. *J Medical Cases*. 2012;3(5):326-8.
3. Breyer MJ and Costantino TG. Heterotopic gestation: another possibility for the emergency bedside ultrasonographer to consider. *J Emerg Med*. 2004;26(1):81-4.
4. Avitabile NC, Kaban NL, Siadecki SD, et al. Two cases of heterotopic pregnancy: review of the literature and sonographic diagnosis in the emergency department. *J Ultrasound Med*. 2015;34(3):527-30.
5. Press GM and Martinez A. Heterotopic pregnancy diagnosed by emergency ultrasound. *J Emerg Med*. 2007;33(1):25-7.
6. Mihmanli V, Kilickaya A, Cetinkaya N, et al. Spontaneous Heterotopic Pregnancy Presenting with Hemoperitoneum. *J Emerg Med*. 2016;50(1):44-6.
7. Crochet JR, Bastian LA, Chireau MV. Does this woman have an ectopic pregnancy? the rational clinical examination systematic review. *JAMA*. 2013;309(16):1722-9.
8. Wang PS, Rodgers SK, Horrow MM. Ultrasound of the First Trimester. *Radiol Clin North Am*. 2019;57(3):617-33.
9. Louis-Sylvestre C, Morice P, Chapron C, et al. The role of laparoscopy in the diagnosis and management of heterotopic pregnancies. *Hum Reprod*. 1997;12(5):1100-2.

Cardiac Memory-induced T-wave Inversions

Sara C. Polito, MD
Jonathan A. Giordano, DO
Benjamin L. Cooper, MD

McGovern Medical School at the University of Texas Health Science Center at Houston (UTHealth), Department of Emergency Medicine, Houston, Texas

Section Editor: Manish Amin, DO

Submission history: Submitted October 11, 2019; Revision received January 29, 2020; Accepted January 31, 2020

Electronically published April 14, 2020

Full text available through open access at http://escholarship.org/uc/uciem_cpchem

DOI: 10.5811/cpcem.2020.1.45527

Introduction: Cardiac memory refers to T-wave inversions that result when normal ventricular activation resumes following a period of abnormal ventricular activation.

Case Report: We present a case of a 29-year-old man with a pacemaker who presented with new, deep symmetric T-wave inversions caused by cardiac memory.

Discussion: Abnormal ventricular activation is most commonly induced by ventricular pacing but can also occur in the setting of transient left bundle branch blocks, ventricular tachycardia, and intermittent ventricular pre-excitation.

Conclusion: Recognition of this phenomenon may help to reduce unnecessary admissions, cardiac testing, and cardiac catheterizations. [Clin Pract Cases Emerg Med. 2020;4(2):181–184.]

Keywords: ECG; cardiac memory; T-wave inversions.

INTRODUCTION

The differential for new T-wave inversions (TWI) includes myocardial ischemia, ventricular overload syndromes (i.e., strain), Takotsubo cardiomyopathy, myopericarditis, and cerebrovascular injury.¹ Here we present a case of deep, symmetric TWI induced by a phenomenon known as cardiac memory. Cardiac memory is characterized by transient T-wave inversion after a period of abnormal ventricular activation. It is generally considered to be a benign finding, in contrast to many other causes of TWIs, although other etiologies should be ruled out prior to diagnosing cardiac memory.

CASE REPORT

A 29-year-old man with a history of second-degree Mobitz type II atrioventricular block and a dual-chamber right ventricular pacemaker (placed five weeks prior to presentation) presented to the emergency department for one week of sharp, intermittent, unprovoked, left-sided chest pain over his pacemaker site. On arrival, his pulse rate was 78 beats per minute, blood pressure 171/99 millimeters of mercury, respiratory rate 16 breaths per

minute, oxygen saturation 98% on room air, and temperature 98.3° Fahrenheit (36.7° Celsius). The patient appeared comfortable and had reproducible chest pain over the pacemaker site. A 12-lead electrocardiogram (ECG) was obtained (Image 1).

Electrolytes and complete blood count were within normal limits, and the troponin I level was undetectable. The patient was given 324 milligrams of aspirin, started on a heparin drip, and admitted to the coronary care unit for further work-up. A repeat ECG performed four hours after presentation showed a ventricular-paced rhythm (Image 2).

The troponin I level remained undetectable for three serial measurements spanning 11 hours, and the heparin drip was discontinued. A transthoracic echocardiogram showed normal left ventricular size and function without wall motion abnormalities, and mild concentric hypertrophy. The pacemaker was interrogated, revealing adequate function and battery life. An ultrasound of the left chest wall excluded a hematoma or fluid collection around the pacemaker. He was started on oral nifedipine for newly diagnosed hypertension, remained asymptomatic and was discharged the following morning. A

repeat ECG two months later revealed a return to his normal baseline T-wave morphology (Image 3).

DISCUSSION

While the presenting history and physical examination were not alarming, the initial ECG finding of deep and symmetric TWIs prompted concern for acute coronary syndrome. The differential diagnosis of new TWIs includes myocardial ischemia, ventricular overload syndromes (i.e., strain), Takotsubo cardiomyopathy, myopericarditis, and cerebrovascular injury.¹ Morphologic features of TWIs that prompt concern for acute coronary syndrome include narrow, deep amplitude and symmetry.^{1,2} The TWIs in the presenting ECG would certainly meet these criteria. The TWIs were new when compared to a prior ECG (Image 3); however, serial undetectable troponin I levels, an echocardiogram failing to reveal wall motion abnormalities, lack of concerning historical elements, and reproducible chest wall pain at the pacemaker site all refuted coronary ischemia. The distribution of the TWIs in the setting of recent ventricular pacing was most consistent with cardiac memory.

Cardiac memory refers to T-wave changes that result when normal ventricular activation resumes following a period of abnormal ventricular activation (i.e., wide QRS complexes). Abnormal ventricular activation is most commonly induced by ventricular pacing, but can also occur in the setting of transient left bundle branch blocks (LBBB), ventricular tachycardia, and intermittent ventricular pre-excitation.^{3,4} The T-wave “remembers” the vector of prior abnormal ventricular activation and reflects the direction of the wide QRS complexes after

CPC-EM Capsule

What do we already know about this clinical entity?

Cardiac memory refers to T-wave inversions (TWI) that result when normal ventricular activation resumes following a period of abnormal ventricular activation.

What makes this presentation of disease reportable?

Deep and symmetric TWIs prompted concern for acute coronary syndrome, but the distribution of the TWIs in the setting of recent ventricular pacing is most consistent with cardiac memory.

What is the major learning point?

Cardiac memory refers to T-wave changes that result when normal ventricular activation resumes and is most commonly induced by ventricular pacing.

How might this improve emergency medicine practice?

Recognition of this phenomenon may help to reduce unnecessary admissions, cardiac testing, and cardiac catheterizations.

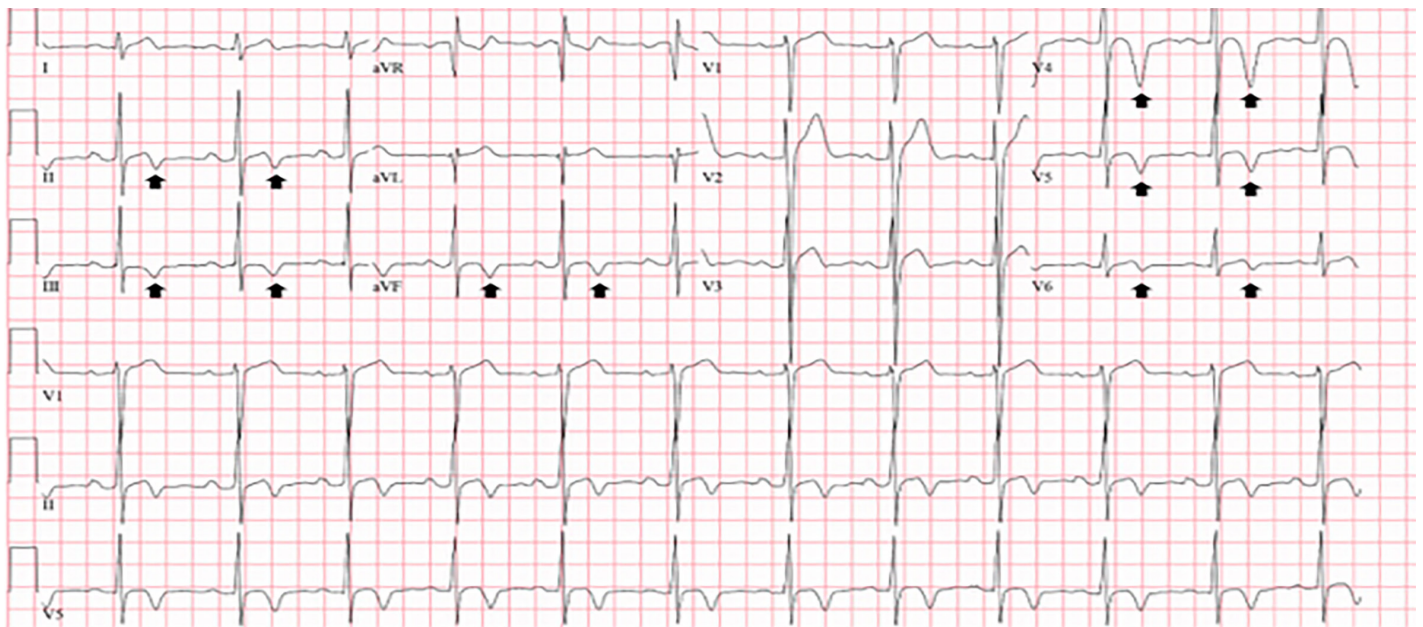


Image 1. Initial electrocardiogram on presentation revealing deep and symmetric T-wave inversions in the inferior leads (II, III, aVF) and precordial leads V4-V6 (arrows).

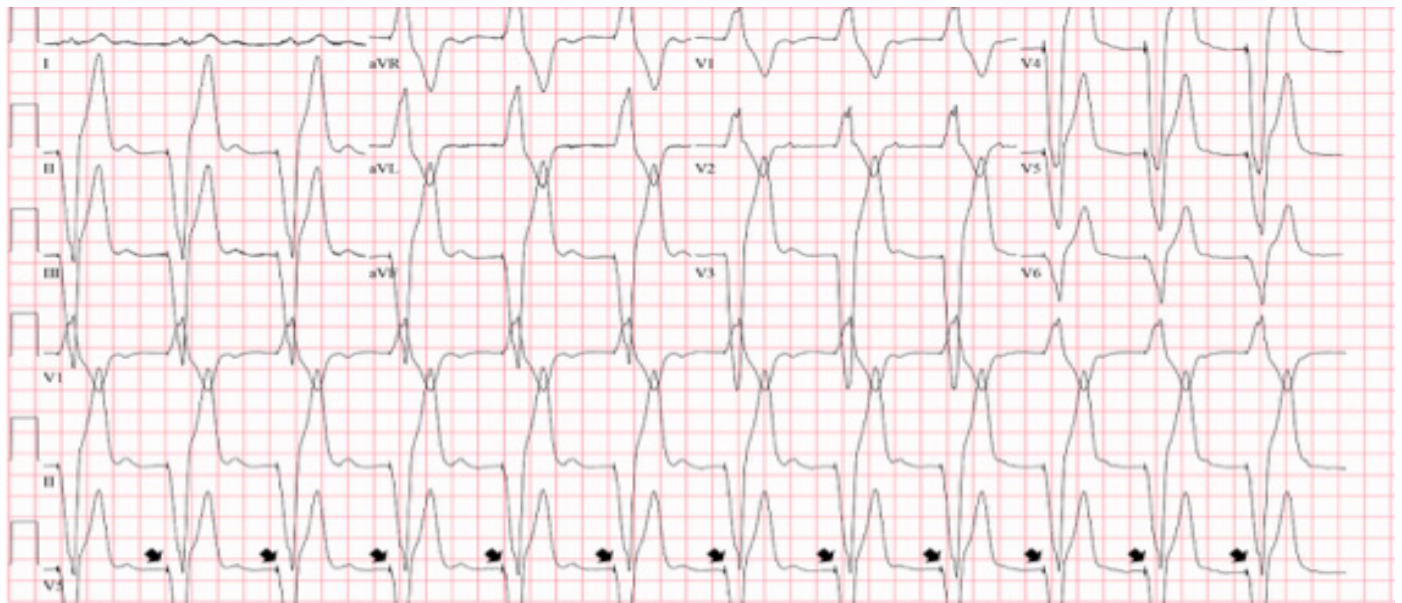


Image 2: The electrocardiogram obtained four hours after presentation revealed a paced rhythm (pacing spikes demonstrated by arrows).

restoration of normal ventricular activation.^{4,5} This results in positive T-waves in leads that had wide, positive QRS complexes during abnormal activation, and negative T-waves in leads that had wide, negative QRS complexes.

It has been shown that the duration of the T-wave changes persists for longer periods of time with increasing duration of the abnormal ventricular activation. For example, when

human subjects were electrically paced for 10 minutes, transient TWIs lasted for 15 minutes after pacing was stopped. However, when paced for two years, TWIs persisted for up to 18 months. The prevailing mechanism for the development of cardiac memory is thought to involve mechanical myocyte stretch leading to increased angiotensin II and subsequent internalization of a subunit of transient outward potassium

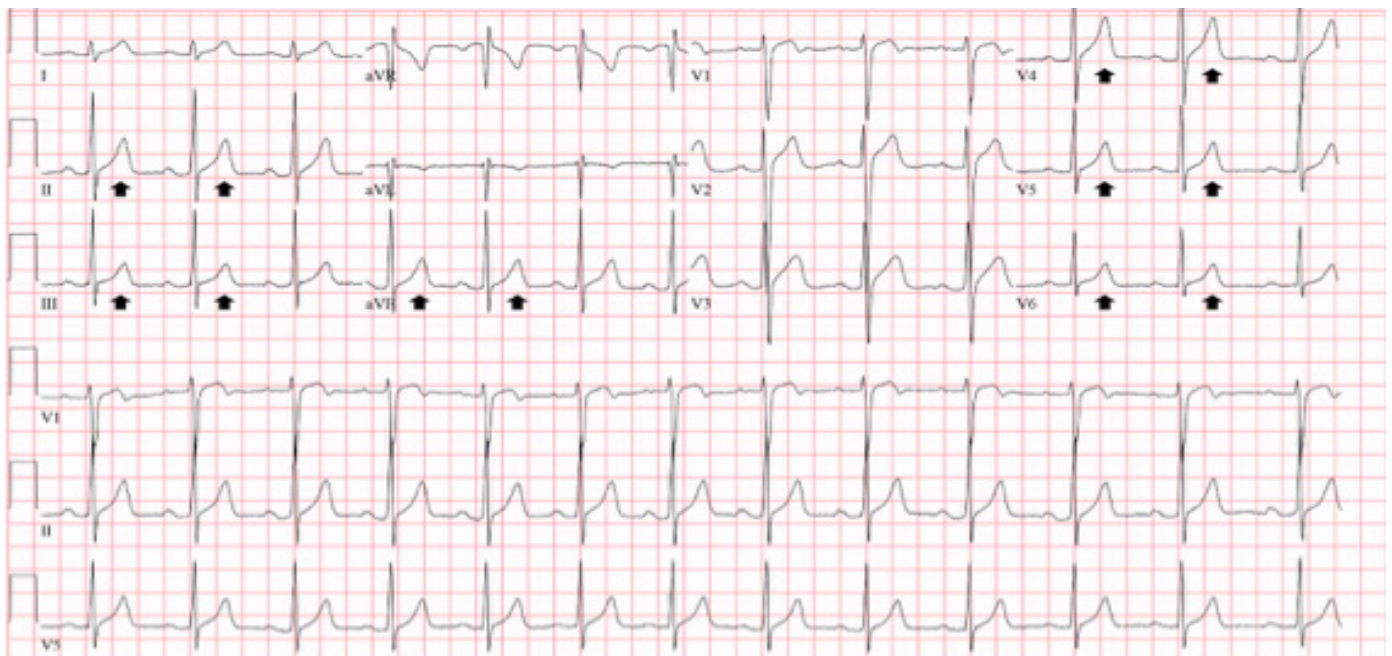


Image 3. Baseline electrocardiogram obtained one month prior to presentation, similar to the electrocardiogram performed two months later, showing resolution of T-wave inversions (arrows).

channels (I_{to}). I_{to} channels are responsible for the outward flow of potassium following depolarization; therefore, disruption of this process leads to repolarization abnormalities and morphologic changes of the T-wave.⁶

Identification of TWIs caused by cardiac memory may help to reduce unnecessary admissions, cardiac testing, and cardiac catheterizations.^{4,6} Certain characteristics in the T-wave can help to differentiate TWI caused by cardiac memory from those caused by ischemia. Shvilkin et al found 92% sensitivity and 100% specificity for diagnosing cardiac memory when the following two criteria are met:

1. A positive T-wave in aVL combined with a positive or isoelectric T-wave in lead I
2. Precordial TWI with larger magnitude than any TWI in lead III.³

Additionally, having access to an ECG with a preceding wide QRS can help diagnose cardiac memory by comparing the location of the wide QRS complexes during abnormal activation to those of the TWI during sinus rhythm.⁴ However, the diagnosis of cardiac memory should only be made after other causes of TWI are reliably ruled out.^{4,6}

Although cardiac memory has traditionally been thought of as benign, recent studies have called this into question.^{5,6} There are multiple case reports of torsades de pointes (TdP) in patients who experience cardiac memory. Changing from a pattern of abnormal ventricular activation to sinus rhythm can prolong the QT interval, placing patients at risk for TdP.^{5,6} Additionally, in patients without pacemakers, TWIs caused by cardiac memory may indicate intermittent LBBB, paroxysmal ventricular tachycardia, or intermittent ventricular preexcitation, which may be important considerations, especially in patients presenting with syncope, presyncope, or palpitations.⁶

CONCLUSION

Cardiac memory is a pattern of TWIs that occurs following resolution of wide QRS complexes. While most commonly seen in patients with ventricular pacemakers, it can be seen with intermittent LBBB, ventricular tachycardia, and intermittent ventricular preexcitation. Cardiac memory should not be diagnosed as the cause of TWI until other causes are reliably ruled out, but recognition of this phenomenon may help to reduce unnecessary admissions, cardiac testing, and cardiac catheterizations.

The signed attestation by the corresponding author that this institution does not require Institutional Review Board approval for case reports has been obtained and filed for publication of this case report.

Address for Correspondence: Benjamin L. Cooper, MD, McGovern Medical School at the University of Texas Health Science Center at Houston (UTHealth), Department of, Department of Emergency Medicine, 6431 Fannin Street, JLL 434, Houston, TX 77030. Email: benjamin.l.cooper@uth.tmc.edu.

Conflicts of Interest: By the CPC-EM article submission agreement, all authors are required to disclose all affiliations, funding sources and financial or management relationships that could be perceived as potential sources of bias. The authors disclosed none.

Copyright: © 2020 Polito et al. This is an open access article distributed in accordance with the terms of the Creative Commons Attribution (CC BY 4.0) License. See: <http://creativecommons.org/licenses/by/4.0/>

REFERENCES

1. Hayden GE, Brady WJ, Perron AD, et al. Electrocardiographic T-wave inversion: differential diagnosis in the chest pain patient. *Am J Emerg Med.* 2002;20(3):252-62.
2. Zwaan D, Biir FWHM, Wellens HJJ. Characteristic electrocardiographic pattern indicating a critical stenosis high in left anterior descending coronary artery in patients admitted because of impending myocardial infarction. *Am Hear J.* 1982;103(4):730-6.
3. Shvilkin A, Huang HD, Josephson ME. Cardiac memory: diagnostic tool in the making. *Circ Arrhythmia Electrophysiol.* 2015;8(2):475-82.
4. Waks JW, Steinhaus DA, Shvilkin A, et al. Post-pacemaker T-wave Inversions: cardiac memory. *Am J Med.* 2016;129(2):170-2.
5. Rosen MR and Bergfeldt L. Cardiac memory: the slippery slope twixt normalcy and pathology. *Trends Cardiovasc Med.* 2015;25(8):687-96.
6. Tafoya C and Singh A. Cardiac memory: a case report and review of the literature. *J Emerg Med.* 2019;57(1):85-93.

Euglycemic Diabetic Ketoacidosis in Concurrent Very Low-carbohydrate Diet and Sodium-glucose Transporter-2 Inhibitor Use: A Case Report

Matthew Earle, MD
Brian Ault, DO, MS
Caitlin Bonney, MD

University of Nevada Las Vegas, Department of Emergency Medicine, Las Vegas, Nevada

Section Editor: Steven Walsh, MD

Submission history: Submitted November 17, 2019; Revision received February 13, 2020; Accepted February 21, 2020

Electronically published April 23, 2020

Full text available through open access at http://escholarship.org/uc/uciem_cpem

DOI: 10.5811/cpcem.2020.2.45904

Introduction: With the incredibly high incidence of Type 2 Diabetes in the current population of emergency department patients, it is critical for clinicians to understand the possible complications of the treatment of this disease. Medication like canagliflozin are more common to encounter on patient's home medication lists and clinicians should be aware of how these medications, alone or combined with dietary modifications, can result in significant pathology and even mortality if not appropriately treated.

Case Report: We report a case of a patient with type II diabetes mellitus who presented with euglycemic diabetic ketoacidosis in the setting of concurrent use of canagliflozin, a sodium-glucose transporter-2 (SGLT-2) inhibitor, and strict adherence to a low-carbohydrate ketogenic diet for weight control.

Discussion: Euglycemic ketoacidosis has previously been observed in both diabetic and non-diabetic patients following strict ketogenic diets, as well as in diabetic patients being treated with SGLT-2 inhibitors.

Conclusion: As more patients choose ketogenic diets for weight control and diabetes management, clinicians should be aware of this potentially life-threatening complication in patients concurrently taking SGLT-2 inhibitors. [Clin Pract Cases Emerg Med. 2020;4(2):185–188.]

Keywords: *SGLT-2 Inhibitors; Ketoacidosis; Low-carbohydrate; Ketogenic.*

INTRODUCTION

Very low-carbohydrate, or ketogenic, diets originated in the realm of fad weight-loss diets, but the practice has moved into the armamentarium of medicine in controlling weight, epilepsy, and diabetes. Sodium-glucose transporter-2 (SGLT-2) inhibitors have also become more heavily used in the control of diabetes, leading to an increased incidence of concomitant use of ketogenic diets and SGLT-2 inhibitors to control weight in diabetic patients.^{1,2} Given that both ketogenic diet and SGLT-2 inhibitors alone can result in euglycemic ketosis,^{3,4} there is likely an increased risk of developing this derangement when the diet and medication are combined. We report here the case of a patient who developed life-threatening euglycemic ketosis

while adhering to a strict ketogenic diet with concomitant canagliflozin use.

CASE REPORT

A 31-year-old female with a history of type II diabetes mellitus (T2DM) presented to a primary care office with dizziness and shortness of breath worsening over one week. She also noted slurring of her speech, nausea, pain radiating down the posterior aspect of both legs, and constipation. She had no history of previous episodes of diabetic ketoacidosis (DKA) or hyperosmolar hyperglycemic state (HHS). The patient had been attempting to control her T2DM by following a very low-carbohydrate, ketogenic diet for about two weeks,

during which she had restricted her carbohydrate intake to 10-15 grams per day. Fluid intake included 3-4 liters of water per day and pickle juice. Over this time, she had a 12.2 kilogram weight loss. She had previously used long-acting insulin (insulin detemir) to control her glucose but had not needed to use insulin to maintain normoglycemia in weeks and was not using insulin at presentation. She stopped using insulin at the time of starting the ketogenic diet.

At the time of presentation, her T2DM management regime consisted solely of canagliflozin and dietary modifications. The patient initially presented to her primary care physician, where she was found to have a blood glucose of 133 milligrams per deciliter (mg/dL) on fingerstick and positive urine ketones. She was sent to the emergency department (ED) for further evaluation. Initial vital signs in the ED were blood pressure 126/78 millimeters of mercury, pulse 137 beats per minute, temperature 97.7° Fahrenheit (36.5° Celsius), respirations 24 breaths per minute, and oxygen saturation 100% on room air. On physical exam, the patient appeared acutely ill. Neurological exam on presentation was notable for Glasgow Coma Scale of 15, drunken affect, gait instability, and mildly slurred speech without aphasia.

Initial electrocardiogram showed sinus tachycardia with normal intervals. Chest radiograph was normal. Laboratory evaluation showed a pH on a venous blood gas of 7.056 with a bicarbonate of 8.0 milliequivalents per liter (mEq/L), blood glucose of 139 mg/dL, blood ketones of 80 mg/dL, lactate of 1.4 millimole per liter (mmol/L), and an anion gap of 29. The remainder of lab results are displayed in the Table. The patient was treated with a bolus of one L of lactated Ringer's solution, followed by an additional of one L 5% dextrose (D5) normal saline and an intravenous potassium bolus of 20 mEq. After administration of approximately 200 milliliters of D5-containing solution, the patient had normalization of her neurological deficits, with no further speech slurring or feelings of intoxication. An insulin infusion was not started emergently, in order to facilitate transfer to an appropriate facility that could provide intensive care unit (ICU) admission and management.

The patient was transferred for admission to ICU level of care for severe metabolic acidosis, ketosis, and tachycardia. The patient had an uneventful course over the next few days with normalization of her ketones and acidosis while being treated with an insulin infusion with concomitant glucose-containing fluids to maintain euglycemia. She was discharged at baseline health and was lost to follow-up.

DISCUSSION

This case demonstrates the occurrence of euglycemic ketoacidosis in a patient with T2DM concurrently following a low-carbohydrate, ketogenic diet and using an SGLT-2 inhibitor. This is an uncommon cause of altered mental status, and it is important for emergency physicians to be aware of this potential complication of diabetes management.

CPC-EM Capsule

What do we already know about this clinical entity?

Euglycemic diabetic ketoacidosis (EDKA) and its relation to sodium-glucose transporter-2 (SGLT-2) inhibitors has been previously acknowledged and cases reported.

What makes this presentation of disease reportable?

Our case represents a novel combination of extreme EDKA in a patient on an SGLT-2 inhibitor in combination with a very-low carbohydrate (or ketogenic) diet.

What is the major learning point?

Ketogenic diets and SGLT-2 inhibitor use, both singly and in combination, can lead to severe, life-threatening EDKA.

How might this improve emergency medicine practice?

Clinicians should consider EDKA in acidotic patients for whom new dietary trends can lead to significant medication interactions and morbidity.

Canagliflozin is an oral sodium-glucose cotransporter-2 (SGLT-2) inhibitor approved by the United States Food and Drug Administration (FDA) for treatment of T2DM and has been shown to improve glycemic control, weight loss, and hemoglobin A1c levels. SGLT-2 inhibitors decrease serum glucose concentrations by preventing glucose reabsorption in the proximal renal tubule of the kidney, thereby promoting glucosuria. SGLT-2 inhibitors also stimulate glucagon secretion from the alpha cells of the pancreas, minimizing the potential for hypoglycemic events. Although SGLT-2 inhibitors have shown efficacy in diabetes management, serious adverse events have been associated with their use. In 2017 the FDA initiated a boxed warning regarding the increased risk of leg and foot amputations in patients taking canagliflozin. Large surveillance studies have also noted increased risk of diabetic ketoacidosis with SGLT-2 inhibitors.⁴

Euglycemic diabetic ketoacidosis (EDKA) is a previously rare clinical condition now showing increasing prevalence with the use of SGLT-2 inhibitors. The pathogenesis of EDKA involves an increased glucagon to insulin ratio, in which ketogenesis is stimulated without

Table. Initial laboratory values of patient who presented to the emergency department with dizziness, shortness of breath, and slurred speech.

Lab	Value	RR	Units
Sodium	139	136-145	mEQ/L
Potassium	3.5	3.5-5.1	mEQ/L
Chloride	102	98-107	mEQ/L
Carbon Dioxide	8	22-30	mEQ/L
Anion Gap	29	3-11	NA
BUN	12	7-18	mg/dL
Creatinine	0.85	0.6-1.3	mg/dL
Glucose	139	70-99	mg/dL
Lactate	1.4	0.4-2.0	mMol/L
Serum Osmolality	295	280-295	mOSM/kg
Ammonia	27	<32	μMol/L
β-Hcg	NEG	NA	NA
Total Protein	8	6.4-8.2	g/dL
WBC	10.6	4-10	k/mm ³
Hemoglobin	16.1	11-15	g/dL
Platelets	287	150-400	k/mm ³
INR	0.8	NA	NA
Urine Ketones	80	NEG	mg/dL
Urine Glucose	500	NEG	mg/dL
Urine Blood	NEG	NEG	NA
Urine Protein	100	NEG	mg/dL

RR, reference range; mEQ, milliequivalents; NA, not applicable; BUN, blood urea nitrogen; mg, milligrams; dL, deciliter; mMol, millimoles; L, liter; mOSM/kg, milliosmoles per kilogram; μMol, micromoles; β-Hcg, human chorionic gonadatropin beta-subunit; NEG, negative; g, gram; WBC, white blood count; K/mm³, thousand per cubic millimeter; INR, international normalized range.

hyperglycemia. Increased glucagon levels contribute to gluconeogenesis, glycogenolysis and fatty acid metabolism to mobilize energy substrates.⁵ In diabetic patients, however, the relative shortage of insulin precludes intracellular glucose utilization, further exacerbating metabolic acidosis. SGLT-2 inhibitors promote ketoacidosis by increasing glucagon secretion and limit available circulating glucose by promoting glucosuria. SGLT-2 inhibitors also exacerbate the osmotic diuresis of ketoacidosis. Normally, glucosuria occurs when blood glucose concentrations exceed 225 mg/dL. SGLT-2 inhibitors block reabsorption of glucose in the

proximal renal tubule even at physiologic serum glucose concentrations and cause glucosuria and osmotic diuresis even in normoglycemia.

Low-carbohydrate, ketogenic diets significantly restrict the dietary supply of carbohydrates, promoting a ketogenic state of fatty acid metabolism. Although ketogenic diets induce a state of ketosis, they are not commonly associated with diabetic ketoacidosis.^{6,7} However, a previous case of ketoacidosis during a low-carbohydrate diet has been reported.⁸ Treatment for EDKA is not fundamentally different from the treatment of hyperglycemia DKA, using fluid resuscitation and insulin administration as the mainstays of therapy.^{9,10} However, patients will likely require earlier administration of glucose-containing fluids and should have the SGLT-2 inhibiting medication held. At discharge, consideration should be given to discontinuing the SGLT-2 inhibitor.

Since both low-carbohydrate, ketogenic diets and SGLT-2 inhibitors increase glucagon secretion while limiting serum glucose levels, a synergistic effect increasing the risk for EDKA is plausible. Cases of severe ketoacidosis associated with a low-carbohydrate diet and use of ipragliflozin and dapagliflozin have previously been reported.^{11,12} Low-carbohydrate/high-fat meals stimulate glucagon production and fatty acid metabolism while limiting serum glucose availability. This physiologic state is likely exacerbated by the concurrent glucagon upregulation and depletion of serum glucose caused by SGLT-2 inhibitors, leading to severe acidosis with ketosis. The limited supply of dietary carbohydrates combined with SGLT-2 inhibitor-induced glucosuria may create a state of diabetic ketoacidosis without elevated serum glucose. This association will require further study for validation.

The patient's initial altered mental status and speech changes may be attributable to her relative depletion of intracellular and intravascular glucose stores. Similar changes in mental status in patients with alcoholic ketoacidosis (AKA) have been previously attributed to intracellular hypoglycemia. As discussed above, this patient also experienced relative hypoglycemia due to her low relative insulin levels, creating a similar state as that of AKA.¹³ Thus, the treatment with the glucose-containing fluids likely terminated the patient's neurologic symptoms by resolving her relative hypoglycemia.

CONCLUSION

Euglycemic diabetic ketoacidosis is a recognized complication of SGLT-2 inhibitor use for weight and glucose control in patients with diabetes. However, there have been few if any previous published cases that were complicated by a concomitant ketogenic diet. Our goal is not to defame the practice of using ketogenic diets in an effort to control body weight and blood glucose, but to caution clinicians that ketogenic diets and SGLT-2 inhibitor use, both singly and in combination, can lead to severe, life-threatening EDKA.

Documented Institutional Review Board approval has been obtained and filed for publication of this case report.

Address for Correspondence: Matthew Earle, MD, University of Nevada Las Vegas, Department of Emergency Medicine, 01 Rancho Lane, STE 135 Las Vegas, NV 89106. Email: matthew.earle@unlv.edu.

Conflicts of Interest: By the CPC-EM article submission agreement, all authors are required to disclose all affiliations, funding sources and financial or management relationships that could be perceived as potential sources of bias. The authors disclosed none.

Copyright: © 2020 Earle et al. This is an open access article distributed in accordance with the terms of the Creative Commons Attribution (CC BY 4.0) License. See: <http://creativecommons.org/licenses/by/4.0/>

REFERENCES

- Gupta, L, Khandelwal D, Kalra, S, et al. Ketogenic diet in endocrine disorders: current perspectives. *J Postgrad Med.* 2017;63(4):242-51.
- Mobbs CV, Mastaitis J, Isoda F, et al. Treatment of diabetes and diabetic complications with a ketogenic diet. *J Child Neurol.* 2013;28(8):1009-14.
- Ueda P, Svanstrom H, Melbye M, et al. Sodium glucose cotransporter 2 inhibitors and risk of serious adverse events: nationwide register based cohort study. *BMJ.* 2018;363:k4365.
- Taylor SI, Blau JE, Rother KI. SGLT2 Inhibitors may predispose to ketoacidosis. *J Clin Endocrinol Metab.* 2015;100(8):2849-52.
- Taborski GJ. The physiology of glucagon. *J Diabetes Sci Technol.* 2010;4(6):1338-44.
- Goday A, Bellido D, Sajoux I, et al. Short-term safety, tolerability and efficacy of a very low-calorie-ketogenic diet interventional weight loss program versus hypocaloric diet in patients with type 2 diabetes mellitus. *Nutr Diabetes.* 2016 Sep;6(9):e230.
- Yabe D, Iwasaki M, Kuwata H, et al. Sodium-glucose co-transporter-2 inhibitor use and dietary carbohydrate intake in Japanese individuals with type 2 diabetes: a randomized, open-label, 3-arm parallel comparative, exploratory study. *Diabetes Obes Metab.* 2017;19(5):739-43.
- Shah P. Ketoacidosis during a low-carbohydrate diet. *N Engl J Med.* 2006;354(1):97-8.
- Lucero P and Chapela S. Euglycemic diabetic ketoacidosis in the ICU: 3 case reports and review of literature. *Case Rep Crit Care.* 2018:1-6.
- Ghazal NM, Souk KM, Hajj Boutros RA, et al. Euglycemic diabetic ketoacidosis in a patient with type II diabetes mellitus, ascites and poor nutrition on SGLT2 inhibitor. *Archives of Medicine.* 2015;7(6:3).
- Hayami T, Kato Y, Kamiya H, et al. Case of ketoacidosis by a sodium-glucose cotransporter 2 inhibitor in a diabetic patient with a low-carbohydrate diet. *J Diabetes Investig.* 2015;6(5):587-90.
- Tougaard NH, Faber J, Eldrup E. Very low carbohydrate diet and SGLT-2-inhibitor: double jeopardy in relation to ketoacidosis. *BMJ Case Rep.* 2019;12(4).
- Wrenn KD, Slovis CM, Minion GE, et al. The syndrome of alcoholic ketoacidosis. *Am J Med.* 1991;91(2):119-28.

A Case Report of Angioedema and Anaphylactic Shock Induced by Ingestion of Polyethylene Glycol

Amy Rossi, MD
Lesley Osborn, MD

University of Texas at Houston, McGovern Medical School, Department of
Emergency Medicine, Houston, Texas

Section Editor: Rick A. McPheeters, DO

Submission history: Submitted September 14, 2019; Revision received February 27, 2020; Accepted March 6, 2020

Electronically published April 23, 2020

Full text available through open access at http://escholarship.org/uc/uciem_cpccm

DOI: 10.5811/cpcem.2020.3.45218

Introduction: We report one of few documented cases of a severe anaphylactic reaction with angioedema to polyethylene glycol (PEG).

Case Report: The patient presented 30 minutes after onset of his symptoms and quickly developed hypoxia and hypotension refractory to intramuscular epinephrine, intravenous fluids, methylprednisolone, and supplemental oxygen via non-rebreather mask. He ultimately required intubation, an epinephrine infusion, and admission to the medical intensive care unit.

Discussion: This case depicts a clinical reaction to PEG, a medication rarely implicated in severe anaphylaxis or angioedema.

Conclusion: The allergenic potential of PEG-containing products should be raised, and providers should have a heightened awareness of these potential side effects. [Clin Pract Cases Emerg Med. 2020;4(2):189–192.]

Keywords: *Polyethylene glycol; PEG; allergic; angioedema.*

INTRODUCTION

Polyethylene glycol (PEG) is a compound found in a variety of products classically viewed as chemically inert substances.¹ In the medical community, it is recognized most frequently as the active ingredient in bowel-cleansing regimens such as Miralax, Go-Lytely, or Half-Lytely. It is also an additive in numerous other medications and substances ranging from intramuscular (IM) depo-provera to antibiotic tablets and ultrasound gel.² Upon review of the literature, we present only the second published case of a severe allergic reaction involving both anaphylactic shock and angioedema to PEG, particularly unique in its severity despite typical anaphylaxis treatment. Fourteen cases of anaphylactic shock secondary to substances containing PEG have been reported; however, only one of these was further complicated by angioedema.^{3,4} In the emergency department (ED), this additional complication can drastically change management of patients, necessitating an awareness of the severity of this reaction to this commonly prescribed medication.

CASE REPORT

A 76-year-old obese Caucasian male with past medical history of hypertension controlled with hydrochlorothiazide, chronic obstructive pulmonary disease on ipratropium bromide and albuterol, diabetes mellitus type II on metformin, atrial fibrillation on diltiazem and warfarin, gastroesophageal reflux disorder, and benign prostatic hypertrophy on tamsulosin presented to the ED with acute-onset shortness of breath. On initial examination, the patient was in respiratory distress, unable to speak greater than two-word phrases, with diffuse erythema and associated severe pruritus. He described an acute onset of these symptoms approximately 30 minutes prior to arrival to the ED. On initial evaluation, he gave us a piece of paper on which he had written “polyethylene glycol,” implicating this as the new and only medication or substance he had ingested in the three hours prior to presentation.

At the time of arrival, the patient’s blood pressure (BP) was 177/143 millimeters of mercury (mmHg), heart rate (HR)

163 beats per minute (bpm), respiratory rate (RR) 23 breaths per minute, oxygen saturation of 93% on room air, weight 103 kilograms (kg). He was in acute respiratory distress in tripod position, with an urticarial eruption on his trunk. Auscultation was significant for inspiratory and expiratory wheezes in all lung fields. Oropharyngeal exam revealed an edematous soft palate with a brawny texture and elevation of his tongue to the hard palate, with associated difficulty tolerating his oral secretions.

The patient immediately received 0.3 milligrams (mg) of IM epinephrine, 125 mg intravenous (IV) methylprednisolone, 50 mg IV diphenhydramine, 20 mg IV famotidine, and one liter 0.9% normal saline. Despite these interventions, the patient deteriorated rapidly, demonstrating signs of anaphylactic shock. His BP decreased to 63/42 mmHg, with a HR of 173 bpm, RR of 34 breaths per minute, and oxygen saturation of 78% on room air. It was determined that the patient would need intubation and further resuscitation with IV fluids and an epinephrine infusion to maintain his blood pressure in the setting of respiratory failure and anaphylactic shock. His oxygenation improved to 93% with application of supplemental oxygen via a non-rebreather mask at 15 liters per minute, and he maintained his mentation; thus, we elected to use fiberoptic nasopharyngoscopy to evaluate the airway for concern of significant oropharyngeal edema and the potential for a complicated endotracheal intubation.

The patient's oropharynx was prepped with topical benzocaine spray, and a 6.0 endotracheal tube (ETT) was loaded on the fiberoptic scope in preparation for emergent nasotracheal intubation if necessary during the procedure. On visualization of the pharynx, he was noted to have edema extending to the area of the hypopharynx, sparing the epiglottis and vocal cords. We elected to proceed with rapid sequence endotracheal intubation after evaluation of his airway. The intubation was performed with 200 mg IV ketamine and 200 mg IV succinylcholine. Video laryngoscopy using a 7.0 ETT resulted in first-pass success. An in-line albuterol nebulizer was then initiated. To allow for central hemodynamic monitoring and accurate titration of the patient's epinephrine infusion, right femoral central and arterial lines were placed with goal to maintain a mean arterial pressure of greater than 65 mmHg. The patient was subsequently admitted to the medical intensive care unit in critical condition.

DISCUSSION

PEGs are polymers composed of ethylene oxide that are non-ionic and hydrophilic and are thought to be chemically inert.¹ They are commonly used in industry production of medications, medical products, and cosmetics.¹ Given its chemical structure as a large hydrophilic polymer, it is effective as a bowel regimen as it does not readily cross the mucosal surface of the gastrointestinal tract.^{4,6} Due to this inherent quality, the compound has generally been viewed as minimally antigenic or reactive.⁶ However, larger PEG polymers (>1000

CPC-EM Capsule

What do we already know about this clinical entity?

Histaminergic angioedema and anaphylaxis are similar disease processes, commonly seen in the emergency department in various states of severity.

What makes this presentation of disease reportable?

Polyethylene glycol (PEG) is thought to be minimally immunogenic; however, this case report shows it may have severe allergic potential in some patients.

What is the major learning point?

All medications should be considered in an anaphylactic reaction.

How might this improve emergency medicine practice?

Emergency physicians may more readily anticipate severe reactions and a difficult airway if patients present with signs and symptoms of allergy to products containing PEG.

atomic mass units) have immunogenic properties as they are likely large enough to elicit immune responses.⁶ While in general these are poorly absorbed, it has been demonstrated that PEG polymers can be recovered in the urine and would, therefore, be able to elicit immune responses in these subjects.⁷

Of those cases with reported reactions to PEG-containing products, the majority of patients present with simple urticaria or meet criteria of anaphylaxis with greater than two body systems involved.^{3,8} However, more severe reactions involving anaphylactic shock and occurrences of ventricular arrhythmias have been documented.^{3,9} Wenande et al recently reported a summary of the known cases of allergic reactions to PEG-containing products.³ Of those reported, fewer than 20 patients experienced cardiovascular collapse indicative of anaphylactic shock and only one with co-existing angioedema.³ All cases reported with discussion of patient management detailed resolution of anaphylactic symptoms and angioedema over the course of hours with recurrent dosing of epinephrine, antihistamines, and steroids.³

Our case differed in severity to those cited above, as the patient's quick decompensation necessitated an escalation

in treatment. The primary change in management was introduction of continuous IV epinephrine to support BP. Current guidelines support administration of IM epinephrine to stable patients demonstrating anaphylaxis; however, they recommend administration of IV epinephrine if anaphylaxis appears to be severe with an immediate life-threatening manifestation. The recommended starting infusion rate is between 1-4 micrograms per minute.¹⁰ Other treatment modalities remained the same, including steroid dosing and use of H1 (histamine type 1) and H2 antagonists.

The case reported here also presented a potentially difficult endotracheal intubation secondary to the significant angioedema visualized on his initial bedside oropharyngeal exam. It was presumed to be resultant of a histaminergic reaction given the concurrent anaphylaxis, as opposed to a non-histaminergic cause, such as bradykinin-mediated or hereditary angioedema, which would require a different treatment regimen.¹¹ The patient was not actively taking angiotensin-converting-enzyme inhibitors for hypertension, one of the most implicated substances in bradykinin-mediated angioedema.¹² He had not previously had an allergic reaction or edema of his lips or oropharynx to any other substance per his report. He also had no personal or family history of similar presentations, which makes it unlikely that he suffers from hereditary angioedema.¹²

Histaminergic angioedema is a subtype of angioedema caused by a deep tissue reaction initiated by histamine release from mast cells, and by subsequent immunoglobulin E-mediated complement activation.² It causes vasodilation and vascular permeability, typically affecting the perioral and periorbital regions, but can also be seen as a non-pitting edema of the extremities and abdomen.⁵ When this reaction localizes to the oropharyngeal structures, endotracheal intubation may become extremely challenging due to severe hypopharyngeal and vocal cord edema.

Studies vary on prevalence of airway obstruction with angioedema; however, in general about 15% of all types of angioedema cases require intubation, and 50% of those needing a definitive airway require cricothyrotomy or tracheostomy.¹² We identified no recent studies with a PubMed search on rates of intubation in histamine-mediated angioedema specifically. Histaminergic angioedema is mediated by the cytokine and histamine activation implicated in anaphylaxis, and the use of antihistamines, steroids, and epinephrine is regarded as the standard of care.¹² Treatment regimens for bradykinin-induced and hereditary angioedema continue to be controversial.^{2,11} Regardless of the cause, ensuring establishment of a definitive airway, when needed, is paramount.

CONCLUSION

The exact mechanism of PEG-induced anaphylaxis has not yet been fully elucidated. It is likely initiated by uptake of PEG molecules across the gastrointestinal mucosa, and its large molecular weight and hydrophilicity prolongs this

process. We suspect that the patient was therefore able to tolerate a significant ingestion prior to onset of symptoms, and the amount ingested was likely the cause of his rapid deterioration to anaphylactic shock, despite the appropriate initial management for anaphylaxis. Although the associated side effects of PEGs are commonly restricted to abdominal discomfort, bloating, cramping, and nausea, case reports like this one suggest a need for increased awareness in all specialties that regularly prescribe these medications. Emergency providers should be especially aware of this reported complication of PEG-containing products as rapid identification and resuscitation is key to improving morbidity and mortality in these patients.

The authors attest that their institution requires neither Institutional Review Board approval, nor patient consent for publication of this case report. Documentation on file.

Address for Correspondence: Amy Rossi, MD, University of Texas at Houston, McGovern Medical School, Department of Emergency Medicine, 6431 Fannin St., Houston, TX 77030. Email: Amy.rossi@uth.tmc.edu.

Conflicts of Interest: By the CPC-EM article submission agreement, all authors are required to disclose all affiliations, funding sources and financial or management relationships that could be perceived as potential sources of bias. The authors disclosed none.

Copyright: © 2020 Rossi et al. This is an open access article distributed in accordance with the terms of the Creative Commons Attribution (CC BY 4.0) License. See: <http://creativecommons.org/licenses/by/4.0/>

REFERENCES

1. Shah S, Prematta T, Adkinson NF, et al. Hypersensitivity to polyethylene glycols. *J Clin Pharmacol*. 2013;53(3):352-5.
2. Wilkerson R. Angioedema in the Emergency department: an evidenced-based review. *Emerg Med Pract*. 2012;14(11):1-24.
3. Wenande E and Garvey LH. Immediate-type hypersensitivity to polyethylene glycols: a review. *Clin Exp Allergy*. 2016;46(7):907-22.
4. Gachoka D. Polyethylene glycol (PEG)-induced anaphylactic reaction during bowel preparation. *ACG Case Rep J*. 2015;2(4):216-7.
5. Lewis LM. Angioedema: etiology, pathophysiology, current and emerging therapies. *J Emerg Med*. 2013;45(5):789-96.
6. Knop K, Hoogenboom R, Fischer D, et al. Poly(ethylene glycol) in drug

- delivery: pros and cons as well as potential alternatives. *Angew Chem Int Ed Engl.* 2010;49(36):6288-308.
7. Brady CE, DiPalma JA, Morawski SG, et al. Urinary excretion of polyethylene glycol 3350 and sulfate after gut lavage with a polyethylene glycol electrolyte lavage solution, *Gastroenterology.* 1986;90(6):1914-18.
 8. Sampson HA, Muñoz-Furlong A, Campbell RL, et al. Second symposium on the definition and management of anaphylaxis: summary report—Second National Institute of Allergy and Infectious Disease/Food Allergy and Anaphylaxis Network Symposium. *J Allergy Clin Immunol.* 2006;117(2):391-7.
 9. Marsh WM, Bronner MH, Yantis PL. Ventricular ectopy associated with perioral colonic lavage, *Gastrointest Endosc.* 1986;(32):259-63.
 10. ECC Committee and Subcommittees and Task Forces of the American Heart Association. 2005 American Heart Association Guidelines for Cardiopulmonary Resuscitation and Emergency Cardiovascular Care. *Circulation.* 2005;112 (24):IV1-203.
 11. Long BJ, Koyfman A, Gottlieb M. Evaluation and management of angioedema in the emergency department. *West J Emerg Med.* 2019;20(4):587-600.
 12. Depetri F, Tedeschi A, Cugno M. Angioedema and emergency medicine: from pathophysiology to diagnosis and treatment. *Eur J Intern Med.* 2019;59:8-13.

A Case Report of Acute Heart Failure Due to Infective Aortic Endocarditis Diagnosed by Point-of-care Ultrasound

Ryan Gallagher, MD
Michelle Wilson, MD
Pamela Hite, MD
Bradley Jackson, MD

University of Kansas Health System, Department of Emergency Medicine, Kansas City, Kansas

Section Editor: Rick A. McPheeters, DO

Submission history: Submitted August 26, 2019; Revision received March 3, 2020; Accepted March 10, 2020

Electronically published April 27, 2020

Full text available through open access at http://escholarship.org/uc/uciem_cpem

DOI: 10.5811/cpcem.2020.3.45002

Introduction: Infective endocarditis (IE) is a life-threatening condition with significant morbidity and mortality, and can require surgical repair.

Case Report: A 36-year-old man presented to the emergency department for worsening dyspnea and chest pain. Point-of-care echocardiography demonstrated a mobile oscillating mass on the aortic valve with poor approximation of the valve leaflets, suggesting aortic valve insufficiency secondary to IE as the cause of acute heart failure. The patient underwent emergent aortic valve replacement within 24 hours.

Discussion: While point-of-care echocardiography has been well documented in identifying tricuspid vegetations, aortic valve involvement and subsequent heart failure is less well described. Earlier recognition of aortic valve vegetations and insufficiency can expedite surgical intervention, with decreased complication rates linked to earlier antimicrobial therapy.

Conclusion: This case report highlights the ability of point-of-care ultrasound to identify aortic vegetations, allowing for the earlier diagnosis and therapy. [Clin Pract Cases Emerg Med. 2020;4(2):193–196.]

Keywords: *infective endocarditis; point-of-care-ultrasound; aortic valve vegetation; cardiac valve regurgitation.*

INTRODUCTION

Infectious endocarditis (IE) is a life-threatening condition that carries significant morbidity and mortality requiring prompt diagnosis, therapy, and sometimes-invasive interventions¹ The proportion of IE patients undergoing surgery has increased over time to about 50%.¹ Valve replacement rates due to IE have increased steadily from 2000-2007 from about 15 per 1000 cases to 25 per 1000 cases of IE, and then plateaued from 2007-2011.² Between 2000 and 2011 there were 457,052 IE hospitalizations with a steady rise in incidence from 29,820 in 2000 to 47,134 in 2011.² This rise is likely related to an increase in the prevalence of risk factors for IE including invasive procedures, intravenous drug use, human immunodeficiency virus, and diabetes.¹ Also contributing to this rise is increased survival of predisposed populations such as those with congenital heart disease and prosthetic implants.² Other contributing factors to the increased

incidence of IE may be improvements in diagnostic methods as well as less-stringent recommendations for prophylactic antibiotic regimens by the American Heart Association in 2007.^{3,4}

Duke criteria for the diagnosis of IE include pathologic specimens, typical organism growth on blood cultures, and evidence on echocardiography. As neither blood culture nor pathology results are available in the emergency department (ED), the diagnosis will always require evidence on point-of-care echocardiogram to be made. With patients in need of prompt antibiotic therapy and potentially emergent surgical intervention, this then raises the question of the capability of point-of-care ultrasound to detect IE.

CASE REPORT

A 36-year-old man with no past medical history presented to the ED for worsening dyspnea, orthopnea, and

chest pain in the context of three months of night sweats, unintentional weight loss, migratory arthralgia, myalgias, and recent palmar lesions (Image 1).

Outpatient rheumatologic and infectious workup had shown only an elevated erythrocyte sedimentation rate. Initial vital signs were notable for a blood pressure of 124/41 millimeters of mercury, heart rate 127 beats per minute, respiratory rate 20 breaths per minute, oxygen saturation of 98% on room air, and a temperature of 37.4 degrees Celsius. He appeared to be in a minimal amount of respiratory distress. Physical examination revealed a new pandiastolic murmur, lower lung field crackles, and bounding peripheral pulses. Electrocardiogram revealed sinus tachycardia without ST-segment abnormalities. Point-of-care echocardiography was performed, which noted a mobile oscillating mass on the aortic valve with poor approximation of the aortic valve leaflets on diastole (Image 2, Video).

The constellation of findings was suggestive of acute heart failure from aortic insufficiency due to likely IE of the aortic valve. IE was felt more likely because the finding met the Duke minor criteria of palmar lesions consistent with Janeway lesions, with the diagnosis fully confirmed when three blood cultures subsequently revealed *Streptococcus sanguinis*. The patient was admitted and underwent emergent aortic valve replacement less than 24 hours later with surgery describing the two coronary aortic valve cusps as obliterated by infection with greater than 1.5 millimeters mobile vegetation on the remaining non-coronary cusp.

DISCUSSION

Point-of-care echocardiography provided key information, enabling the timely diagnosis of IE involving the aortic valve. While point-of-care echocardiography has previously been




Image 1. Palmar rash: Photograph of palmar lesions (arrows) provided by the patient consistent with Janeway lesions.

CPC-EM Capsule

What do we already know about this clinical entity?

Infectious endocarditis is a life-threatening condition that carries significant morbidity and mortality, requiring sometimes-invasive interventions.

What makes this presentation of disease reportable?

While point-of-care echocardiography has been documented in identifying tricuspid vegetations, aortic valve involvement and subsequent heart failure is less well described.

What is the major learning point?

Point-of-care echocardiography is useful in undifferentiated heart failure, allowing for quicker diagnosis of underlying etiology and direction of therapy.

How might this improve emergency medicine practice?

Earlier recognition of aortic valve vegetations can expedite surgical intervention, with fewer complication rates linked to earlier antimicrobial therapy.

described as capable of identifying tricuspid vegetations,^{5,6} sensitivity in aortic vegetations is not well described. Further study would be needed to compare point-of-care transthoracic echocardiography (TTE) to cardiology TTE, which has been estimated to have a sensitivity for IE around 70% for native valves and 50% for prosthetic valves with a specificity of around 90%, according to the European Society of Cardiology in 2015.⁷ Similarly, a meta-analysis of 16 articles in 2017 on TTE found a sensitivity of 66% and a specificity of 95% for detecting IE on native valve.⁸ These studies demonstrate the value of TTE in the workup for IE, despite not being as accurate as transesophageal echocardiography.⁸ Specific situations where TTE may not identify vegetations include underlying valvular thickening or calcification, prosthetic shadowing, recent vegetation migration or embolization, and poor acoustic windows secondary to obesity, hyperinflated lungs, or narrow interspaces.

The potential for an emergency physician to achieve earlier recognition of cardiac valve vegetations is valuable because patients may require emergent surgical

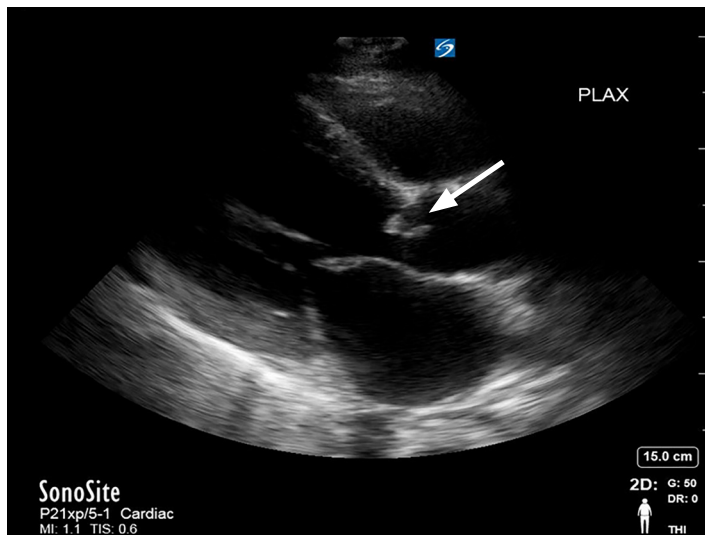


Image 2. Aortic vegetation: Parasternal long-axis view showing a mobile oscillating mass on the aortic valve (arrow).

intervention, such as the valve replacement in this case, and as decreased complication rates have been linked to the earlier initiation of antimicrobial therapy. In a series of 1437 patients from the International Collaboration on Endocarditis in 2007, the embolic stroke rate decreased from 4.8 to 1.7 per 1000 patient years from the first to the second week of antibiotic treatment.⁹

Point-of-care echocardiography may also be useful for the detection of secondary valvular complications of endocarditis, obtaining prognostic indicators, and supporting the need for surgical intervention. The valvular complications that may be seen on echocardiography are regurgitation, valve perforation, and abscess or fistula formation due to destruction of tissue by bacterial invasion and proliferation.¹ The main risk factor for complications is the length of the vegetation, with one retrospective cohort study finding the probability of sustaining a complication to be 10% when vegetations were 6 millimeters (mm) in size, 50% when lesions were 11 mm, and almost 100% when lesions were greater than or equal to 16 mm.¹⁰ Mortality has also been linked to vegetation length with one study of intravenous drug users with right-sided endocarditis demonstrating an increased mortality rate of 33% in patients with vegetations greater than 2 centimeters (cm) in length, compared to a mortality rate of only 1.3% in those with vegetations less than 2 cm in length.¹¹

CONCLUSION

Given the elusive nature of infective endocarditis, point-of-care echocardiography may not be used early enough in the diagnostic work-up. Point-of-care ultrasound was an invaluable bedside diagnostic tool in this patient with IE of the aortic valve. With a low index of suspicion to evaluate for

vegetations and the knowledge that it is possible to find them on both the tricuspid and aortic valves, a critical diagnosis can be made in a timelier manner.

Video. Aortic vegetation: Parasternal long-axis and apical four-chamber view showing a mobile oscillating mass on the aortic valve.

The authors attest that their institution requires neither Institutional Review Board approval, nor patient consent for publication of this case report. Documentation on file.

Address for Correspondence: Michelle Wilson, MD, University of Kansas Health System, Department of Emergency Medicine, 400 Cambridge, Kansas City, KS 66160. Email: mwilson21@kumc.edu.

Conflicts of Interest: By the *CPC-EM* article submission agreement, all authors are required to disclose all affiliations, funding sources and financial or management relationships that could be perceived as potential sources of bias. The authors disclosed none.

Copyright: © 2020 Gallagher et al. This is an open access article distributed in accordance with the terms of the Creative Commons Attribution (CC BY 4.0) License. See: <http://creativecommons.org/licenses/by/4.0/>

REFERENCES

1. Baddour LM, Wilson WR, Bayer AS, et al. Infective endocarditis in adults: diagnosis, antimicrobial therapy, and management of complications: a scientific statement for healthcare professionals from the American Heart Association. *Circulation*. 2015;132(15):1435-86.
2. Pant S, Patel NJ, Deshmukh A, et al. Trends in infective endocarditis incidence, microbiology, and valve replacement in the United States from 2000 to 2011. *J Am Coll Cardiol*. 2015;65(19):2070-6.
3. Thornhill M, Gibson T, Cutler E, et al. Antibiotic prophylaxis and incidence of endocarditis before and after the 2007 AHA recommendations. *J Am Coll Cardiol*. 2018;72(20):2443-54.
4. W. Wilson, K.A. Taubert, M. Gewitz, et al. Prevention of infective endocarditis: guidelines from the American Heart Association: a guideline from the American Heart Association Rheumatic Fever,

- Endocarditis, and Kawasaki Disease Committee, Council on Cardiovascular Disease in the Young, and the Council on Clinical Cardiology, Council on Cardiovascular Surgery and Anesthesia, and the Quality of Care and Outcomes Research Interdisciplinary Working Group. *Circulation*. 2007;116(15):1736-54.
5. Scott C. Man with acute respiratory distress. Tricuspid vegetation concerning for infective endocarditis. *Ann Emerg Med*. 2016;67(2):295, 300.
 6. Seif D, Meeks A, Mailhot T, et al. Emergency department diagnosis of infective endocarditis using bedside emergency ultrasound. *Crit Ultrasound J*. 2013;5(1):1.
 7. Habib G, Lancellotti P, Antunes MJ, et al. 2015 ESC Guidelines for the management of infective endocarditis: The Task Force for the Management of Infective Endocarditis of the European Society of Cardiology (ESC). Endorsed by: European Association for Cardio-Thoracic Surgery (EACTS), the European Association of Nuclear Medicine (EANM). *Eur Heart J*. 2015;36(44):3075-128.
 8. Bai AD, Steinberg M, Showler A, et al. Diagnostic accuracy of transthoracic echocardiography for infective endocarditis findings using transesophageal echocardiography as the reference standard: a meta-analysis. *J Am Soc Echocardiogr*. 2017;30(7):639-46.e8.
 9. Dickerman SA, Abrutyn E, Barsic B, et al. The relationship between the initiation of antimicrobial therapy and the incidence of stroke in infective endocarditis: an analysis from the ICE Prospective Cohort Study (ICE-PCS). *Am Heart J*. 2007;154(6):1086-94.
 10. Sanfilippo AJ, Picard MH, Newell JB, et al. Echocardiographic assessment of patients with infectious endocarditis: prediction of risk for complications. *J Am Coll Cardiol*. 1991;18(5):1191-9.
 11. S.R. Hecht and M. Berger. Right-sided endocarditis in intravenous drug users. Prognostic features in 102 episodes. *Ann Intern Med*. 1992;117(7):560-6.

Eagle Syndrome: A Rare Case of Atraumatic, Painful Cervical Neck Swelling

Cameron P. Worden, BS*
Sanjeeb S. Bhandari, MD†
Benjamin B. Cable, MD‡
Damon R. Kuehl, MD†

*Virginia Tech Carilion School of Medicine, Roanoke, Virginia
†Virginia Tech Carilion, Department of Emergency Medicine, Roanoke, Virginia
‡Virginia Tech Carilion Clinic School of Medicine, Division of Otolaryngology, Department of Surgery, Roanoke, Virginia

Section Editors: Christopher Sampson, MD

Submission history: Submitted December 23, 2019; Revision received March 26, 2020; Accepted March 19, 2020

Electronically published April 23, 2020

Full text available through open access at http://escholarship.org/uc/uciem_cpem

DOI: 10.5811/cpcem.2020.3.46284

Introduction: Painful neck swelling is a common emergency complaint but can present diagnostic challenges. Eagle syndrome is a rare clinical entity in which a pathologically elongated styloid process or ossified stylohyoid ligament produces a constellation of symptoms in the head and neck region.

Case Report: We present the case of a 50-year-old male with a spontaneous, atraumatic fracture of an elongated styloid process associated with hematoma formation and radiological findings of airway impingement.

Discussion: The classic triad for Eagle syndrome consists of unilateral cervicofacial pain, globus sensation, and dysphagia. Diagnosis of Eagle syndrome should be made based on a combination of physical examination and radiological findings. Treatment options vary based on severity of symptoms.

Conclusion: Although more likely to be an indolent and progressive complaint, providers in the acute care setting should be familiar with Eagle syndrome due to the potential for a spontaneous fracture of an elongated styloid process to cause acute, painful neck swelling and life-threatening airway compromise. [Clin Pract Cases Emerg Med. 2020;4(2):197–200.]

Keywords: *Eagle syndrome; atraumatic; fracture; airway impingement; hematoma.*

INTRODUCTION

Painful neck swelling is a common emergency complaint but can present diagnostic challenges. The complex anatomy of the neck makes isolating the cause of the swelling and pain a challenge for clinicians. History is critical in determination of the cause, especially the timing of onset of symptoms. While infection and trauma are common causes of painful cervical neck swelling, less common causes should also be considered in any differential diagnosis. Patients with acute, atraumatic pain and swelling of the cervical tissues (immediate to <24 hours) should also undergo investigation for pathology within other specific anatomic structures in this area of the neck including the following: sudden salivary gland obstruction; arterial rupture or dissection; thrombosis

of deep (superior vena cava syndrome) or superficial veins (Lemierre's syndrome); and possibly acute thyroid disease.^{1,2}

When faced with this diagnostic dilemma, emergency physicians and specialists often turn to a computed tomography (CT) with intravenous (IV) contrast for assistance. While spontaneous injury to the cervical structures or ligamentous rupture or tear are rarely considered, and not routinely discussed in emergency medicine textbooks, fracture of the styloid process can occur spontaneously as part of a more complex constellation of symptoms known as Eagle syndrome, which leads to cervical neck pain and swelling.¹ Here we present the first reported case of Eagle syndrome with a spontaneous, atraumatic fracture of an elongated styloid process resulting in hematoma formation and radiological findings of airway impingement.³

CASE REPORT

A 50-year-old man presented to the emergency department (ED) complaining of progressively worsening swelling over the angle of his left jaw associated with difficulty speaking, described as hoarseness and pain with phonation, as well as difficulty swallowing. It began spontaneously one day previously, right after he felt a snap or pop. There were no triggering incidents, although he was unclear if he was talking or swallowing at the time. It was associated with a non-radiating, moderate intensity pain, just below the angle of the mandible on his left side that increased in severity when he moved his jaw to speak, turn, or swallow. Over the course of 12 hours he developed worsening anterior cervical neck swelling and progressive odynophagia, dysphagia, and hoarseness. His medical history was significant for hypertension and left-sided Bell's palsy since 2014, which was associated with ipsilateral tinnitus.

On examination, he was hypertensive with a blood pressure of 187/105 millimeters of mercury, heart rate 91 beats per minute, temperature 98.4° Fahrenheit, and oxygen saturation 100% on room air. The patient's physical exam was unremarkable with the exception of palpable and visible swelling to the soft tissues below the left side of the mandible and clear discomfort on swallowing. Concern for a vascular abnormality such as aneurysm or thrombosis prompted immediate CT of the neck with IV contrast. This imaging revealed a fracture through an elongated, calcified left styloid process (Image 1) with hematoma formation causing mass effect on the left lateral hypopharyngeal wall (Image 2).

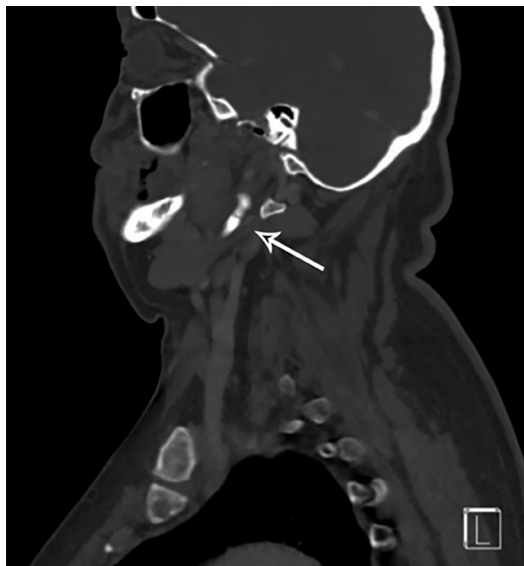

Image 1. Computed tomography of the neck with intravenous contrast in sagittal view showing an elongated left styloid process with associated atraumatic fracture, indicated by arrow.

CPC-EM Capsule

What do we already know about this clinical entity?

Eagle syndrome is a rare clinical entity in which a pathologically elongated styloid process or ossified stylohyoid ligament produces a constellation of symptoms in the head and neck region.

What makes this presentation of disease reportable?

This is the first reported case of Eagle syndrome with a spontaneous, atraumatic fracture of an elongated styloid process resulting in hematoma formation and airway impingement.

What is the major learning point?

There is a potential for Eagle syndrome to present as a spontaneous, atraumatic fracture of an elongated styloid process leading to acute neck swelling and life-threatening airway compromise.

How might this improve emergency medicine practice?

This report highlights an important differential in the workup of painful neck swelling that has the potential to lead to life-threatening complications if not promptly recognized.

The patient was preliminarily diagnosed with a spontaneous fracture of an elongated calcified styloid ligament with hematoma formation and was admitted to observation with otolaryngology (ENT) consultation for airway monitoring and the potential for surgical intervention if worsening airway impingement. He did well with no further progression of symptoms and was discharged after 24 hours. At follow-up with ENT services one week post-ED visit, swelling was markedly reduced and his pain had fully resolved. The spontaneous fracture was thought to be corrective and no further surgical intervention was required.^{4,5} He has had no further symptoms one year from his injury.

DISCUSSION

The styloid process is a slender bony extension of the temporal bone projecting immediately anterior to the

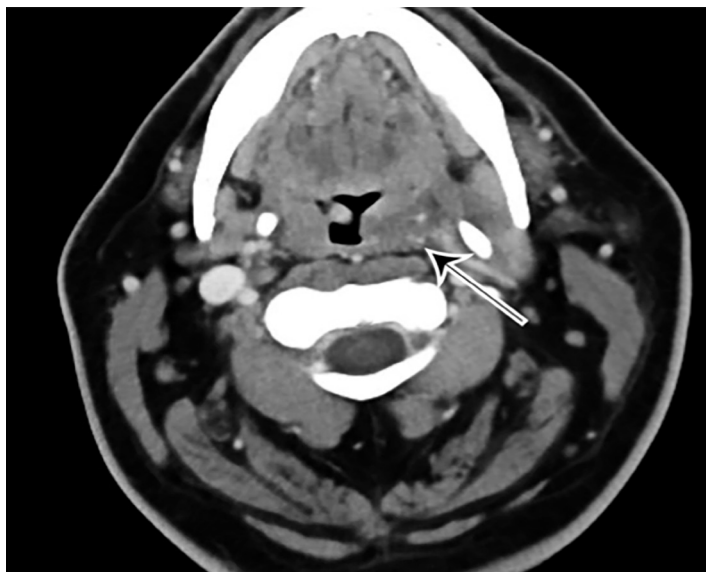


Image 2. Computed tomography of the neck with intravenous contrast in axial view showing fluid tracking along the fractured left styloid process producing a mass effect on the left lateral hypopharyngeal wall, indicated by arrow.

stylomastoid foramen. In a normal adult, the styloid process is approximately 2.5 cm in length, whereas an elongated styloid process is defined as > 3 cm.⁶ While it is estimated that approximately 4-28% of the general population have an elongated styloid process, few are symptomatic.⁷ Reasons for the elongation are poorly understood. Possible pathophysiological mechanisms include the following: 1) a congenital elongation of the styloid process due to the persistence of a cartilaginous element connecting it to the temporal bone; 2) ossification of the stylohyoid ligament; and 3) growth of osseous tissue at the insertion of the styloid ligament.⁴

Eagle syndrome is an uncommon and often-confusing clinical entity, likely due to the variable constellation of symptoms that can develop.⁸ It is characterized by a pathologically elongated styloid process or ossified stylohyoid ligament producing symptoms in the head and neck region. As first described by Watt W. Eagle in the 1930s, Eagle syndrome classically presents as a triad of globus sensation, dysphagia, and unilateral cervicofacial pain typically occurring after tonsillectomy.⁶ He proposed that scar tissue that developed as a consequence of the surgery around the mineralized complex resulted in compression of surrounding cranial nerves V, VII, IX, and X leading to chronically progressive symptoms.⁶ However, the current definition of Eagle syndrome has evolved to include a myriad of additional symptoms including carotid compression resulting in syncope and transient ischemic attacks, otalgia, tinnitus, odynophagia, and generalized cervicofacial pain that all derive

from a pathologically elongated styloid process or calcified stylohyoid ligament.^{8,9,10}

In the acute care setting, painful cervical neck swelling should include a differential of infection or trauma, as well as less common etiologies including sudden salivary gland obstruction, arterial rupture or dissection, thrombosis (Lemierre's syndrome), acute thyroid disease, and ligamentous injury.^{1,2} In our patient, accompanying symptoms of dysphonia and dysphagia likely resulted from the compression of the left lateral hypopharyngeal wall and associated neurovasculature due to the hemorrhage and swelling in the parapharyngeal space from the styloid process fracture. Our patient did extremely well, but expanding hematomas, especially in the anticoagulated patient, make this uncommon and benign condition potentially life threatening in the acute phase of injury.

Diagnosis of Eagle syndrome should be made based on a combination of physical examination and radiological findings. The imaging method of choice is CT of the neck with IV contrast. Panoramic radiography may be diagnostic, although it does not narrow the differential in the acute setting.¹¹ Treatment options for Eagle syndrome vary based on severity of symptoms. Non-surgical interventions ranging from simple reassurance to local corticosteroid injections can be successful for mild to moderate symptoms. For severe cases, surgical excision of the elongated styloid process or ossified stylohyoid ligament is recommended via a transcervical (extraoral) approach for proper visualization of anatomical structures and a decreased incidence of deep cervical space infection.^{4,5}

CONCLUSION

Spontaneous fracture or ligamentous injury of the styloid process should be considered in a patient presenting with acute onset, atraumatic, painful cervical neck swelling. The classic triad for Eagle syndrome consists of unilateral cervicofacial pain, globus sensation, and dysphagia. Although more likely to be an indolent and progressive complaint, providers in the acute care setting should be familiar with Eagle syndrome due to the potential for a spontaneous fracture of an elongated styloid process to cause acute painful neck swelling and life-threatening airway compromise. While history and physical exam findings are critical in suspecting the condition, CT imaging is required to confirm the diagnosis, exclude alternate serious clinical entities, and guide management.

The authors attest that their institution requires neither Institutional Review Board approval, nor patient consent for publication of this case report. Documentation on file.

Address for Correspondence: Cameron Worden, BS, Virginia Tech Carilion School of Medicine, 2 Riverside Circle, Roanoke, VA 24011. Email:cpworden@carilionclinic.org.

Conflicts of Interest: By the CPC-EM article submission agreement, all authors are required to disclose all affiliations, funding sources and financial or management relationships that could be perceived as potential sources of bias. The authors disclosed none.

Copyright: © 2020 Worden et al. This is an open access article distributed in accordance with the terms of the Creative Commons Attribution (CC BY 4.0) License. See: <http://creativecommons.org/licenses/by/4.0/>

REFERENCES

1. Tintinalli JE, Stapczynski JS, Ma OJ, et al. (2011). *Tintinalli's Emergency Medicine: A Comprehensive Study Guide*, (7th ed). New York, NY: The McGraw-Hill Companies.
2. Schwetschenau E and Kelley DJ. The adult neck mass. *Am Fam Physician*. 2002;66(5):831-8.
3. Orlik K, Griffin GD, Zoumberakis E. Unilateral neck pain: a case of Eagle syndrome with associated nontraumatic styloid fracture. *Am J Emerg Med*. 2014;32(1):112.e1-2.
4. Strauss M, Zohar Y, Laurian N. Elongated styloid process syndrome: intraoral versus external approach for styloid surgery. *Laryngoscope*. 1985;95(8):976-9.
5. Jalisi S, Jamal BT, Grillone GA. Surgical management of long-standing Eagle's syndrome. *Ann Maxillofac Surg*. 2017;7(2):232-6.
6. Eagle WW. Elongated styloid process: symptoms and treatment. *AMA Arch Otolaryngol*. 1958;67(2):172-6.
7. Keur JJ, Campbell JPS, McCarthy JF, et al. The clinical significance of the elongated styloid process. *Oral Surg Oral Med Oral Pathol*. 1986;61(4):399-404.
8. Galletta K, Siniscalchi EN, Cicciu M, et al. Eagle syndrome: a wide spectrum of clinical and neuroradiological findings from cervico-facial pain to cerebral ischemia. *J Craniofac Surg*. 2019;30(5):e424-8.
9. Todo T, Alexander M, Stokol C, et al. Eagle syndrome revisited: cerebrovascular complications. *Ann Vasc Surg*. 2012;26(5):729.e1-5.
10. Bremmer E, Sergent S, Ashurst J. Eagle syndrome. *Clin Pract Cases Emerg Med*. 2018;2(4):359-60.
11. Murtagh RD, Caracciolo JT, Fernandez G. CT findings associated with Eagle syndrome. *AJNR Am J Neuroradiol*. 2001;22(7):1401-2.

Gastric Adenocarcinoma Presenting as Chronic Back Pain: A Case Report

Alexandra Chitty, DO
Dennis Cardriche, MD
Thomas H. Matese Jr, DO

HCA Healthcare, St. Lucie Medical Center, Department of Emergency Medicine,
Port St. Lucie, Florida

Section Editor: Rick A. McPheeters, DO

Submission history: Submitted January 21, 2020; Revision received March 27, 2020; Accepted March 20, 2020

Electronically published April 23, 2020

Full text available through open access at http://escholarship.org/uc/uciem_cpem

DOI: 10.5811/cpcem.2020.3.46660

Introduction: Early stage gastric cancer is usually asymptomatic. It is not until later stages of the disease, usually with metastasis, that patients typically develop symptoms that would prompt further evaluation.

Case Report: We present a case of a patient with chronic back pain who was found to have a gastric antral mass as the etiology of her pain. The patient proceeded to have a partial gastrectomy with complete surgical excision of her early-stage gastric cancer, after which her chronic back pain resolved.

Conclusion: This case demonstrates the importance of considering significant pathology in patients presenting with chronic complaints to the emergency department. [Clin Pract Cases Emerg Med. 2020;4(2):201–204.]

Keywords: *Gastric adenocarcinoma; gastric cancer; back pain; chronic back pain.*

INTRODUCTION

In 2016, back symptoms were the sixth most common reason for emergency department (ED) visits.¹ Patients presenting with chronic back pain are often presumed to have a musculoskeletal etiology of pain. Multiple limb- or life-threatening diagnoses must be considered in these patients. Some of those diagnoses include acute spinal cord compression, cauda equina syndrome, aortic dissection, abdominal aortic aneurysm, and spinal infections, or hematomas. Another etiology commonly seen in the ED is back pain due to pathologic fractures of the spine secondary to metastatic disease. However, to our knowledge no case reports have been noted in the literature that describe early gastric cancer presenting with a primary symptom of back pain. We believe this is a unique case report.

CASE REPORT

A 76-year-old female former smoker with a past medical history of hypertension and hypothyroidism presented to the ED at a community hospital with a chief complaint of intermittent left upper back pain for one year. The patient reported that she

was not a local resident and had flown into the area four days prior. She reported acute worsening of her left upper back pain over the prior two days, localized the pain to underneath her left shoulder blade, and rated it as severe. She denied any obvious provoking factors and reported minimal relief when lying still on a heating pad. She had previously been seen by her primary care physician for the same complaint and had been started on celecoxib. The patient reported epigastric pain with celecoxib and noted that she had discontinued use.

The patient denied syncope, fever, chills, midline back pain, chest pain, dyspnea, cough, hemoptysis, nausea, vomiting, dysuria, hematochezia, and melena. She admitted to occasional heartburn. She was accompanied by her friend who reported that while out shopping the day prior, the patient had had a relatively brief episode where she became pale appearing and reported feeling weak, lightheaded, and nauseated. The patient had no surgical history and denied a history of alcohol use. She did report a 10-pound weight loss over the prior six months, which she attributed to grief over her husband's recent death. She denied any specific trauma or injury but admitted to having lifted her husband multiple times prior to his death.

On arrival to the ED, the patient's vital signs were reported as follows: temperature 36.9 degrees Celsius; heart rate 90 beats per minute; blood pressure 101/76 millimeters of mercury; respiratory rate 18 breaths per minute; pulse oximetry 100% on room air. On examination, the patient was alert, non-toxic appearing, and seemed to be in mild discomfort. Upon examination of the eyes, she was noted to have conjunctival pallor. Her lungs were clear to auscultation. Although appearing mildly dyspneic, she demonstrated no other signs of respiratory distress. Her cardiovascular exam revealed a regular rate and rhythm with brisk capillary refill and equal pulses. Her abdomen was soft, non-distended with mild epigastric tenderness to palpation without guarding, rigidity, or evidence of peritoneal irritation. There was no palpable or pulsatile mass noted.

Her back appeared to be atraumatic without rash or skin discoloration. She had no midline vertebral tenderness to palpation and no tenderness was elicited upon palpation around the inferomedial aspect of the left scapula where the patient had reported the pain was located. There was no paraspinal tenderness or muscle spasm and no costovertebral tenderness. The patient had painless range of motion of her back. Her neurologic and extremity exams were unrevealing. A rectal exam demonstrated external hemorrhoids, normal sphincter tone, no saddle anesthesia, and no gross blood.

The patient's vague symptoms, history, and the inability to duplicate the pain, coupled with the fact that the pain was severe and continual raised concern for a potentially serious etiology. We included pulmonary embolism, aortic dissection, aortic aneurysm, and acute coronary syndrome in the differential diagnosis that warranted further investigation.

A computed tomography angiography of the chest showed no evidence of pulmonary embolus, aortic aneurysm, aortic dissection, or any other acute pathology. A computed tomography of the abdomen and pelvis with intravenous (IV) contrast demonstrated stenosis of the celiac artery with post-stenotic dilation with no evidence of downstream ischemia. The only significant lab abnormality was a hemoglobin of 8.4 grams per deciliter (g/dL) (13.0–18.0 g/dL) and a hematocrit of 26.8% (40.0–52.0%) to which the patient denied a known history of anemia. A fecal occult blood test was noted to be positive.

A bleeding peptic ulcer was suspected as the etiology of the patient's symptoms. However, given the acute worsening of pain two days prior, there was concern that a small peptic ulcer perforation could not be ruled out. She was treated with 40 milligrams of IV pantoprazole in the ED and was admitted to the hospital where she was evaluated by a gastroenterologist.

The following day, the patient's hemoglobin dropped to 7.5 g/dL and her hematocrit dropped to 23%. The patient underwent an esophagogastroduodenoscopy and was found to have erosive gastritis with a large, ulcerated, and partially obstructing antral mass. The biopsy revealed infiltrating, poorly differentiated adenocarcinoma. The patient was subsequently evaluated by a general surgeon and underwent a robot-assisted distal

CPC-EM Capsule

What do we already know about this clinical entity?

Early symptoms of gastric cancer can be vague and non-specific.

What makes this presentation of disease reportable?

This is the first presentation reported in the literature of a patient with a primary complaint of back pain who was found to have early gastric cancer.

What is the major learning point?

This case highlights the importance of considering life-threatening diagnoses in patients who present with vague and even chronic complaints.

How might this improve emergency medicine practice?

This case demonstrates the importance of performing a thorough physical examination and having a high index of suspicion for serious pathology, especially in the elderly with vague complaints.

gastrectomy (approximate 60% gastrectomy) with Billroth-II reconstruction. There was no evidence of metastatic disease intra-abdominally. The distal gastrectomy specimen that was removed measured 13 centimeters (cm) x 8 cm x 6 cm. The mucosal surface demonstrated a tan, fungating mass, measuring 6 cm x 4 cm. The final diagnosis was moderately differentiated (grade 2) infiltrating adenocarcinoma of intestinal type with tumor invasion into the muscularis propria. Thirty-six lymph nodes and all margins were free of tumor. The pathologic stage was pT2 pN0.

Following surgery, the patient underwent chemotherapy for three months and eventually stopped given the severity of side effects she had experienced. I spoke with her nine months following her ED visit and she reported that her chronic back pain did in fact resolve following surgical excision of her gastric cancer. The patient remains in complete remission.

DISCUSSION

The American Cancer Society predicts that 27,600 cases of stomach cancer will be diagnosed in the United States

in 2020 and 11,010 people will die from this type of cancer in the US in 2020.² EDs often serve as the entrance into the healthcare system for those labeled with a first-time cancer diagnosis.³ Fifty-two percent of patients ultimately diagnosed with gastric cancer at one urban institution were admitted to the hospital from the ED.³ Those patients who were diagnosed after an ED visit were determined to have poorer survival estimates as these patients often had later stage disease.³ Because early symptoms of gastric cancer can be vague and non-specific, one should consider this diagnosis in patients presenting with poor appetite, weight loss, early satiety, nausea, anorexia, abdominal pain, dysphagia, or melena, as well as back pain or fatigue.⁴

Gastric cancer is not a diagnosis that is typically made in the ED, but ED evaluation can lead to admission for further evaluation of a potentially malignant process. Consider admitting patients who may be presenting with a first-time cancer diagnosis especially in those who lack reliable follow-up care, as early initiation of the diagnostic process and prompt therapeutic intervention can improve patient prognosis. It is prudent to keep such a diagnosis in mind and to broaden one's differential diagnosis. While the focus of this case report was to highlight a unique presentation of early gastric cancer, we also emphasize the importance of a thorough physical examination, especially in those patients presenting with chronic complaints. For example, if a patient presenting with chronic back pain presumed to be of musculoskeletal nature does not have abnormalities on examination such as tenderness to palpation, significant muscle spasm, or pain on movement, consider that there may be some other pathology present.

A bleeding peptic ulcer with a possible microperforation was considered on ED evaluation of this patient, which prompted hospital admission. The patient did have multiple symptoms at presentation concerning for gastric cancer, many of them also consistent with a diagnosis of peptic ulcer disease. These symptoms included epigastric pain, occult gastrointestinal bleeding, unintentional weight loss, nausea, fatigue, and back pain. Fortunately, this patient was found to have early-stage gastric adenocarcinoma that was surgically resected in a timely fashion.

Upon review of the literature, we found a published case report that presents a patient with worsening back pain who was found to have lytic lesions in the vertebrae and who was ultimately found to have signet-ring cell gastric adenocarcinoma.⁵ However, we found no similar case reports of patients presenting primarily with back pain due to gastric cancer that were not associated with other pathologies, such as bony metastasis.

It seems that our patient's back pain was likely a referred pain from the visceral autonomic nervous system. We already know that the nervous system plays a role in the development of cancer and that there is a complex relationship between pain and carcinogenesis.⁶ There are many algogenic mediators involved in the process of carcinogenesis that alter human

pain pathways.⁶ This patient's back pain resolved following excision of her gastric cancer.

CONCLUSION

This case demonstrates the importance of gathering an appropriate history, performing a thorough physical examination, and considering non-musculoskeletal, serious pathology in elderly patients with a long pain history, vague complaints, and a physical examination that is contrary to a simple musculoskeletal problem. It is important to note that the function of the history and physical examination is to look for confirmatory and non-confirmatory elements that may help lead one to the correct diagnosis. Chronic back pain is a very common complaint in the ED. Taking a few extra minutes to listen to a patient and to perform a thorough examination can lead to a timely diagnosis of a life-threatening illness that can generate a better prognosis for the patient. We owe it to our patients to consider life-threatening illnesses, including cancer, during ED evaluation.

The authors attest that their institution requires neither Institutional Review Board approval, nor patient consent for publication of this case report. Documentation on file.

Address for Correspondence: Alexandra Chitty, DO, St. Lucie Medical Center, Department of Emergency Medicine, 1800 SE Tiffany Avenue, Port St. Lucie, FL 34952. Email: Alexandra.Chitty@hcahealthcare.com.

Conflicts of Interest: By the CPC-EM article submission agreement, all authors are required to disclose all affiliations, funding sources and financial or management relationships that could be perceived as potential sources of bias. This research was supported (in whole or in part) by HCA Healthcare and/or an HCA Healthcare affiliated entity. The views expressed in this publication represent those of the author(s) and do not necessarily represent the official views of HCA Healthcare or any of its affiliated entities. The authors disclosed none.

Copyright: © 2020 Chitty et al. This is an open access article distributed in accordance with the terms of the Creative Commons Attribution (CC BY 4.0) License. See: <http://creativecommons.org/licenses/by/4.0/>

REFERENCES

- Centers for Disease Control and Prevention. National Hospital Ambulatory Medical Care Survey: 2016 Emergency Department Summary Tables. Available at: <https://www.cdc.gov/nchs/data/nhamcs/>

- web_tables/2016_ed_web_tables.pdf. Accessed June 9, 2019.
2. American Cancer Society. Key statistics about stomach cancer. Available at: <https://www.cancer.org/cancer/stomach-cancer/about/key-statistics.html>. Accessed January 19, 2020.
3. Solsky I, Rapkin B, Wong K, et al. Gastric cancer diagnosis after presentation to the ED: the independent association of presenting location and outcomes. *Am J Surg*. 2018;216(2):286-92.
4. Wanebo HJ, Kennedy BJ, Chmiel J, et al. Cancer of the stomach. *Ann Surg*. 1993;218(5):583-92.
5. Dittus C, Mathew H, Malek A, et al. Bone marrow infiltration as the initial presentation of gastric signet ring cell adenocarcinoma. *J Gastrointest Oncol*. 2014;5(6):E113-6.
6. Schmidt BL. What pain tells us about cancer. *Pain*. 2015;156(Suppl 1):S32-4.

Accidental Chlorine Gas Exposure in a Pediatric Patient: A Case Report

Ashley Antolick, MD
Lindsey Ouellette, MPH
Bryan Judge, MD
Brad Riley, MD
JS Jones, MD

Spectrum Health - Michigan State University Emergency Medicine Residency
Program, Grand Rapids, Michigan

Section Editor: Rick A. McPheeters, DO

Submission history: Submitted January 29, 2020; Revision received February 26, 2020; Accepted March 20, 2020

Electronically published April 23, 2020

Full text available through open access at http://escholarship.org/uc/uciem_cpem

DOI: 10.5811/cpcem.2020.3.46746

Introduction: Chlorine gas is a known irritant of the respiratory tract, which may cause damage to various systems depending on time of exposure and concentration of the gas. Current treatments are mainly supportive. While no definitive studies have been completed to date, it has been noted that treatment with a sodium bicarbonate solution via nebulizer may lead to improved outcomes for patients dealing with chlorine gas exposure.

Case Report: We present a case of a nine-year-old child arriving at the emergency department after exposure to chlorine gas. Complete recovery from his symptoms occurred rapidly with the administration of nebulized sodium bicarbonate.

Discussion: Inhaled chlorine gas acts as a mucous membrane irritant, with symptoms usually beginning within minutes of exposure. Inhaled nebulized sodium bicarbonate has been suggested as a therapy for chlorine exposure. Although its mechanism of action is not well understood, it is thought that inhaled sodium bicarbonate neutralizes the hydrochloric acid formed when the chlorine gas reacts with the water in the lungs.

Conclusion: Nebulized sodium bicarbonate solution at a low concentration appeared to rapidly and effectively reverse the symptoms due to chlorine gas inhalation in a young child. [Clin Pract Cases Emerg Med. 2020;4(2):205–207.]

Keywords: *Chlorine gas exposure; treatment; nebulized sodium bicarbonate; pediatric.*

INTRODUCTION

Chlorine gas exposure can occur from multiple sources including in-home cleaning products or accidental mixing of ammonia and bleach, swimming pool chlorination reactions, industrial accidents, and intentional exposures with intent to harm as a chemical weapon.^{1,2} Because of the prolific and widespread use of chlorine in both industrial and household environments, the gas is one of the most common substances involved in toxic inhalation.³ Toxic effects are dependent on the time of exposure and the concentration of the gas and are

mediated by chlorine's reaction with water on the mucosal surfaces to form hypochlorous and hydrochloric acids.² The most common presenting complaints after exposure to the gas are cough and dyspnea, but may also include wheezing, sore throat, chest pain, eye and nose irritation, and nausea.² Because the respiratory system is generally the most adversely affected by this gas, exposure can lead to serious pulmonary edema and acute respiratory distress syndrome, respiratory failure, pneumomediastinum, and death.¹ Treatments leading to symptomatic relief and prevention of further

complications are paramount. One such treatment described in previous literature is the administration of nebulized sodium bicarbonate.³⁻⁵ While the mechanism of action is not completely understood, it is thought that the bicarbonate neutralizes the hydrochloric acid produced when the chlorine gas reacts with water in the moist environment of the mucosa and epithelium in the respiratory tract. In this report, we present a case of a nine-year-old male who presented to the emergency department (ED) with respiratory symptoms after inhaling the vapors of chlorinated tablets.

CASE REPORT

A nine-year-old male opened a canister of chlorine tablets that was kept near the family pool. After accidentally inhaling chlorine fumes, he immediately became dyspneic. The child had a history of mild asthma. His mother gave the patient an albuterol nebulizer treatment at home without improvement. He was taken to the ED by emergency medical services. On arrival to the hospital, he reported difficulty breathing, persistent dry cough, and chest pain. His vital signs were pulse 125 beats per minute, respirations 32 breaths per minute, blood pressure 102/62 millimeters of mercury, and temperature 37.2° Celsius. Oxygen saturation was 91% on room air. His face was flushed, and his conjunctivae were injected bilaterally. There were no lesions noted in the mouth or upper airway. He had coarse, upper airway breath sounds without retractions or wheezing.

The patient had two episodes of desaturation to 89% and he was placed on one liter supplemental oxygen via nasal cannula with improvement to 98%. He was then given 4 milliliter (mL) of 3.75% sodium bicarbonate in nebulized saline solution over 15 minutes. The nebulized sodium bicarbonate was administered approximately 90 minutes after initial exposure. Chest radiographs were unremarkable. His symptoms significantly improved after administration of the sodium bicarbonate; he no longer complained of pain or cough and was weaned to room air with oxygen saturations in the upper 90s. The child was admitted and continued to improve without any further interventions and remained on room air. He was discharged within 24 hours without any further complication.

DISCUSSION

In 2012, an estimated 4876 visits to EDs occurred after pool chemical-associated health events, such as the one highlighted in this report.⁶ The wide availability of chlorinated compounds as household disinfectants and swimming pool chlorinators makes these agents potentially hazardous to a large segment of the population, especially children. Concentrated chlorine gas may be generated when aging swimming pool chlorination tablets decompose or are inadvertently introduced to a swimming pool while swimmers are present.⁷ Predisposing factors to inhalation injury include asthma, smoking, atopic allergies, and chronic exposure to chlorine gas.¹ Inhaled chlorine gas acts as

CPC-EM Capsule

What do we already know about this clinical entity?

Chlorine gas inhalation can cause acute injury to the respiratory tract that in severe cases may result in pulmonary edema, pneumonia, or respiratory failure.

What makes this presentation of disease reportable?

An unusual exposure to chlorine gas caused respiratory symptoms in a child with a unique and effective means of management in the emergency department.

What is the major learning point?

Inhaled sodium bicarbonate neutralizes hydrochloric acid. Nebulized sodium bicarbonate at low concentrations appeared to reverse the pulmonary symptoms in our patient.

How might this improve emergency medicine practice?

This case report adds to the emergency physician's toolbox by providing a potential quick and effective means of managing an exposure to chlorine gas.

a mucous membrane irritant, with symptoms usually beginning within minutes of exposure.³ As with all irritant gases, the airway injuries caused by chlorine gas may result in clinical manifestations similar to those of asthma. When the patient hyperventilates, an increased amount of chlorine is inhaled into the lungs, thereby causing more lung injury.

Inhaled nebulized sodium bicarbonate has been suggested as a therapy for chlorine exposure. Although its mechanism of action is not well understood, it is thought that inhaled sodium bicarbonate neutralizes the hydrochloric acid formed when the chlorine gas reacts with the water in the lungs.³ Although oral sodium bicarbonate is not recommended for neutralizing acid ingestions because of the problems associated with the exothermic reaction and production of carbon dioxide in the relatively closed gastrointestinal tract, the rapid exchange in the lungs of air with the environment facilitates heat dissipation.⁷ Recommended dose concentrations are between 3.75–4.25%. A 3.75% concentration is made by combining in a nebulizer 3 mL of 8.4% sodium bicarbonate and 3 mL of normal saline solution. No one has examined the effect of

differing concentrations of sodium bicarbonate solution or the optimal therapeutic timing of administration after exposure to irritant gases.

Use of inhaled sodium bicarbonate has been advocated in case reports and observational studies since 1976.⁸ Only one randomized controlled trial has been performed.³ In 2006, Aslan and colleagues treated 44 subjects with nebulized salbutamol (5 milligrams [mg]), intravenous prednisolone (1 mg per kilogram per day), and either nebulized placebo or 4 mL of 4.20 % nebulized sodium bicarbonate solution. The only significant difference between the two groups was an increase in forced expiratory volume in the bicarbonate group at 240 minutes (2.9 vs 2.4 L). Although the quality-of-life scores improved significantly in both groups of patients after treatment, there was no significant difference found between the groups.

In our case, the patient was not improved after both supplemental oxygen and nebulizer treatment prior to arrival and thus the use of an adjunctive therapy was warranted. Our patient had complete resolution of symptoms with a single treatment of 3.75% nebulized sodium bicarbonate. He did not experience any adverse effects and was discharged 24 hours later without any progression of his symptoms despite his history of asthma. This patient likely had a mild chlorine exposure but was still significantly symptomatic and, as with the prior case reports, this treatment has been shown to be beneficial in both mild and more severe cases of chlorine inhalation. In addition, no adverse effect or long-term complication of nebulized bicarbonate sodium has been reported to date.⁸

CONCLUSION

Nebulized sodium bicarbonate solution at a low concentration appeared to rapidly and effectively reverse the symptoms due to chlorine gas inhalation in a young child. As there is limited evidence for current treatment modalities for this relatively common toxicological emergency, further long-term prospective clinical trials are needed to add support and evidence of safety for this adjunctive therapy.

The authors attest that their institution requires neither Institutional Review Board approval, nor patient consent for publication of this case report. Documentation on file.

Address for Correspondence: Jeffrey Jones, MD, Spectrum Health-Michigan State University, Department of Emergency Medicine, 15 Michigan NE, Suite 701, MC 038, Grand Rapids, MI 49503. Email: jeffrey.jones@spectrumhealth.org

Conflicts of Interest: By the *CPC-EM* article submission agreement, all authors are required to disclose all affiliations, funding sources and financial or management relationships that could be perceived as potential sources of bias. The authors disclosed none.

Copyright: © 2020 Antolick et al. This is an open access article distributed in accordance with the terms of the Creative Commons Attribution ([CC BY 4.0](http://creativecommons.org/licenses/by/4.0/)) License. See: <http://creativecommons.org/licenses/by/4.0/>

REFERENCES

1. Sever M, Mordeniz C, Sever F, et al. Accidental chlorine gas intoxication: evaluation of 39 patients. *J Clin Med Res*. 2009;1(5):274-9.
2. Vajner JE and Lung D. Case files of the University of California San Francisco medical toxicology fellowship: acute chlorine gas inhalation and the utility of nebulized sodium bicarbonate. *J Med Toxicol*. 2013;9(3):259-65.
3. Aslan S, Kandiş H, Akgun M, et al. The effect of nebulized NaHCO₃ treatment on "RADS" due to chlorine gas inhalation. *Inhalation Toxicol*. 2006;18(11):895-900.
4. Douidar SM. Nebulized sodium bicarbonate in acute chlorine inhalation. *Pediatr Emerg Care*. 1997;13(6):406-7.
5. Vinsel PJ. Treatment of acute chlorine gas inhalation with nebulized sodium bicarbonate. *J Emerg Med*. 1990;8(3):327-9.
6. Hlavska MC, Robinson TJ, Collier SA, et al. Pool chemical-associated health events in public and residential settings—United States, 2003–2012, and Minnesota, 2013. *Morb Mortal Wkly Rep*. 2014;63(19):427-30.
7. Nelson LS and Odujebe OA. 2019. Simple asphyxiants and pulmonary irritants. In: Hoffman RS, Howland M, Lewin NA, et al. *Goldfrank's Toxicologic Emergencies, 11th edition* (pp. 1651-62). New York, NY: McGraw-Hill.
8. Tuong AH, Despreaux T, Loeb T, et al. Emergency management of chlorine gas exposure – a systematic review. *Clin Toxicol*. 2019;57(2):77-98.

A Case of Hyperkalemia Versus Pseudohyperkalemia in Chronic Lymphocytic Leukemia

Rachel D. Le, MD*
Sean P. Geary, MD†

*Albany Medical Center Hospital, Department of Emergency Medicine, Albany, New York
†Albany Medical Center Hospital, Department of Emergency Medicine and
Department of Surgery, Division of Surgical Critical Care, Albany, New York

Section Editors: Scott Goldstein, MD

Submission history: Submitted January 10, 2020; Revision received February 14, 2020; Accepted March 19, 2020

Electronically published April 23, 2020

Full text available through open access at http://escholarship.org/uc/uciem_cpccem

DOI: 10.5811/cpcem.2020.3.46481

Introduction: Both hyperkalemia and pseudohyperkalemia occur in the emergency department. True hyperkalemia necessitates emergent treatment while pseudohyperkalemia requires recognition to prevent inappropriate treatment. It is imperative that the emergency physician (EP) have an understanding of the causes and clinical presentations of both phenomena.

Case Report: We present a case of an 88-year-old male with chronic lymphocytic leukemia (CLL) and suspected blast crisis who was found to have elevated serum potassium levels without other manifestations of hyperkalemia and eventually was determined to have pseudohyperkalemia due to white cell fragility.

Discussion: Differentiation of hyperkalemia and pseudohyperkalemia is a critical skill for the EP. We discuss multiple causes of hyperkalemia and pseudohyperkalemia in an effort to broaden the knowledge base.

Conclusion: We present a case of CLL as an unusual cause of pseudohyperkalemia and review common causes of pseudohyperkalemia. [Clin Pract Cases Emerg Med. 2020;4(2):208–210.]

Keywords: *pseudohyperkalemia; hyperleukocytosis; chronic lymphocytic leukemia.*

INTRODUCTION

Hyperkalemia is a potentially life-threatening electrolyte derangement that requires early diagnosis and prompt treatment to prevent significant morbidity and mortality. Pseudohyperkalemia is an *in vitro* increase in serum potassium without *in vivo* increase and thus lacks clinical manifestations of hyperkalemia.¹ Every emergency physician (EP) has encountered pseudohyperkalemia as a result of hemolysis from pre-analytical errors.² Fortunately, the laboratory usually identifies hemolysis at the time of reporting. We present a case of pseudohyperkalemia without apparent hemolysis in a patient with chronic lymphocytic leukemia (CLL), and we present a review of pseudohyperkalemia in the literature.

CASE REPORT

An 88-year-old male with baseline dementia and known CLL diagnosed in 2016 (although he had not been receiving treatment)

initially presented to an outside hospital with bilateral lower extremity edema. There, he was found to have a white blood cell count of 280,000 cells per microliter (cells/ μ L) (reference range: 4,400-10,400 cells/ μ L), an increase from 120,000 cells/ μ L 10 months prior. He was subsequently transferred due to concerns for transformation. At our institution, the patient denied any specific complaints. In discussion with the transferring physician, it was determined that the patient initially presented for lower extremity pain and fatigue, and was found to have negative bilateral deep venous thrombosis studies.

On physical exam, the patient was a cachectic, elderly male found to be normothermic at 36.9° Celsius, with a blood pressure of 114/68 millimeters of mercury, heart rate of 88 beats per minute, respiratory rate of 14 breaths per minute, and oxygen saturation of 95% on room air. Otherwise, he had an unremarkable exam with the exception of symmetric 1+ lower extremity edema without evidence of cellulitis.

Upon arrival, repeat laboratories demonstrated stable hyperleukocytosis of 279,000 cells/ μ L, but also a potassium of 6.7 mEq/L (reference range: 3.4-5.2 mEq/L) without reported visible hemolysis. It should be noted the patient had a reported potassium of 4.5 mEq/L at the outside hospital earlier that day. The patient continued to deny any symptoms, and an electrocardiogram (ECG) was obtained that did not show evidence of hyperkalemia. One liter of normal saline and furosemide 20 milligrams were given intravenously with a repeat potassium elevated to 9.4 mEq/L, this time with some hemolysis. Given the rapidly escalating potassium level despite an initial trial of therapy and a normal ECG, a point-of-care potassium was drawn and returned as 3.8 mEq/L. Since this value was more consistent with the outside hospital level and there was a lack of clinical and ECG findings to suggest hyperkalemia, no further interventions were performed in the emergency department.

Over the course of his hospitalization, the patient had multiple elevated potassium levels, usually with interpreted hemolysis, although occasionally without reported hemolysis. In fact, the patient had his apparently elevated potassium treated with a hyperkalemia cocktail of calcium gluconate, insulin, dextrose, and sodium polystyrene on at least one occasion during his hospital stay. The patient never had physical manifestations of hyperkalemia nor were there ECG changes.

DISCUSSION

In vivo hyperkalemia is a common electrolyte derangement typically seen in chronic kidney disease as well as in acute processes such as rhabdomyolysis and diabetic ketoacidosis. Conversely, pseudohyperkalemia is an in vitro increase in serum potassium. Hemolysis can occur during the pre-analytical process, particularly with mechanical trauma during venipuncture, prolonged tourniquet time, and fist clenching, all of which may cause extracellular movement of potassium from myocytes.²

Cases of pseudohyperkalemia associated with thrombocytosis and leukocytosis have been reported in the literature since the 1950s.^{1,3} Pseudohyperkalemia has been associated with hyperleukocytosis, more commonly in CLL in adults, but also acute lymphoblastic leukemia in children.^{4,9} It is thought that hyperleukocytosis increases cell fragility, making cell lysis more common during specimen collection, particularly with smaller-bore needles, as well as transport and centrifugation. Since leukocytes are more prone to lysis than erythrocytes, laboratory detection may not be apparent if erythrocytes are unaffected. This may lead to the spurious reporting of elevated potassium without the expected caveat of hemolysis and explain why in our case the use of the point-of-care test showed a normal potassium. Moreover, at our institution, we use a pneumatic tube system to transport laboratory specimens, which would further increase the risk of fragile cell lysis compared to a bedside test without transport.

Although we highlight pseudohyperkalemia in the setting of hematologic malignancy, rarer etiologies of pseudohyperkalemia

CPC-EM Capsule

What do we already know about this clinical entity?

Pseudohyperkalemia is an in vitro increase in serum potassium associated with thrombocytosis and leukocytosis, processes that increase cell fragility and lysis.

What makes this presentation of disease reportable?

Reported cases of pseudohyperkalemia, especially relating to unusual causes such as leukemia, contribute to the limited body of knowledge currently in the literature.

What is the major learning point?

Differentiating true hyperkalemia from pseudohyperkalemia is imperative as the inappropriate treatment of pseudohyperkalemia can lead to devastating hypokalemia.

How might this improve emergency medicine practice?

Maintaining suspicion for pseudohyperkalemia in the appropriate clinical setting will decrease the frequency of inappropriate treatment.

exist in the literature. There are cases of pseudohyperkalemia associated with postsplenectomy thrombocytosis following trauma as well as hepatosplenic schistosomiasis infection.¹⁰⁻¹¹ Familial pseudohyperkalemia is an autosomal dominant, albeit exceedingly rare, disorder in which erythrocyte plasma membranes exhibit temperature-dependent permeability of potassium in vitro.¹² Although vastly different pathologies, it can be inferred that processes that promote cell fragility increase the risk of pseudohyperkalemia. Thus, clinical suspicion for pseudohyperkalemia should be maintained in patients with these predispositions. Likewise, underlying hematological disorders should be considered in patients with suspected pseudohyperkalemia without known disease.

Differentiating true hyperkalemia from pseudohyperkalemia is important as hyperkalemia in patients with leukocytosis in the setting of known or suspected malignancy is concerning for tumor lysis syndrome (TLS), an oncologic emergency involving lysis of malignant cells and extracellular release of potassium and phosphate as well as the generation of uric acid.

Treatment of hyperkalemia in TLS is similar to that of hyperkalemia in other patients.

The inappropriate treatment of pseudohyperkalemia can lead to devastating hypokalemia. Nevertheless, multiple case reports as early as the 1980s have cited the inappropriate treatment of hyperkalemia in hyperleukocytosis.^{6,13} We aim to add to the body of knowledge of pseudohyperkalemia. Inappropriate treatment of pseudohyperkalemia can be detrimental. It is imperative that treatment be started with appropriate clinical suspicion rather than solely laboratory findings, which have inherent limitations and errors.

CONCLUSION

Differentiating true hyperkalemia, a medical emergency, from pseudohyperkalemia, where treatment can be detrimental is important for the EP. In order to do this, the EP needs to be familiar with the plethora of causes of pseudohyperkalemia from the more common hemolysis to the much rarer thrombosis and extreme leukocytosis or thrombocytosis.

The authors attest that their institution requires neither Institutional Review Board approval, nor patient consent for publication of this case report. Documentation on file.

REFERENCES

- Hartmann RC and Mellinkoff SM. Relationship of platelets to serum potassium concentration. *J Clin Invest.* 1955;34:938.
- Stankovic AK and Smith S. Elevated serum potassium values. *Am J Clin Pathol.* 2004;121(Suppl 1):105-12.
- Chumbley LC. Pseudohyperkalemia in acute myelocytic leukemia. *JAMA.* 1970;211(6):1007-9.
- Cao J and Karger AB. Critically elevated potassium in a 55-year-old female with chronic lymphocytic leukemia. *Lab Med.* 2018;49(3):280-3.
- Chan JS, Baker SL, Bernard AW. Pseudohyperkalemia without reported haemolysis in a patient with chronic lymphocytic leukaemia. *BMJ Case Rep* 2012. doi: 10.1136/bcr.12.2011.5330.
- De Rosales AR, Siripala DS, Bodana S, et al. Pseudohyperkalemia: look before you treat. *Saudi J Kidney Dis Transpl.* 2017;28(2):410-14.
- Jain AG, Tauseef A, Hasan SA, et al. Pseudohyperkalemia: to treat or not to treat. *Cureus.* 2018;10(11):e3570.
- Alhaj Moustafa M, Malkovska V, Elmahdy S, et al. A challenging case of pseudohyperkalemia in chronic lymphocytic leukemia. *J Investig Med High Impact Case Rep.* 2017;5(4):2324709617746194
- Merritt M, Kline H, Garimella S, et al. Pseudohyperkalemia in a patient with T-cell acute lymphoblastic leukemia and hyperleukocytosis. *J Pediatr Intensive Care.* 2018;7(3):166-8.
- Raees A and Issac AM. Postsplenectomy thrombocytosis and pseudohyperkalemia in trauma: a case report and review of literature. *J Trauma.* 2009;67(1):E17-9.
- Johnson CM and Hughes MK. Pseudohyperkalemia secondary to postsplenectomy thrombocytosis. *Am Surg.* 2001;67(2):168-70.
- Lambertucci JR, Otoni A, Rodrigues VL. Pseudohyperkalemia and pseudohyperphosphatemia after splenectomy in hepatosplenic schistosomiasis mansoni. *Rev Soc Bras Med Trop.* 2008;41(6):692.
- Nanji AA. Unnecessary treatment of hyperkalemia in a patient with chronic granulocytic leukemia. *Can Med Assoc J.* 1983;129(11):1180.

Address for Correspondence: Sean P. Geary, MD, Albany Medical Center, Department of Emergency Medicine, 47 New Scotland ave. Mail Code 139, Albany, NY 12208. Email: gearys@amc.edu.

Conflicts of Interest: By the CPC-EM article submission agreement, all authors are required to disclose all affiliations, funding sources and financial or management relationships that could be perceived as potential sources of bias. The authors disclosed none.

Copyright: © 2020 Le et al. This is an open access article distributed in accordance with the terms of the Creative Commons Attribution (CC BY 4.0) License. See: <http://creativecommons.org/licenses/by/4.0/>

High-Pressure Injection Injury of the Face: A Case Report on Presentation and Management

Edan Zitelny, MSIV*
Blake Briggs, MD†
Rachel Little, MD†
David Masner, DO†

*Wake Forest School of Medicine, Department of Emergency Medicine, Winston-Salem, North Carolina

†Wake Forest University Baptist Medical Center, Department of Emergency Medicine, Winston-Salem, North Carolina

Section Editors: Austin Smith, MD

Submission history: Submitted October 21, 2019; Revision received March 17, 2020; Accepted March 20, 2020

Electronically published April 23, 2020

Full text available through open access at http://escholarship.org/uc/uciem_cpccem

DOI: 10.5811/cpccem.2020.3.45637

Introduction: High-pressure injection injuries have been chronicled for decades.¹ These injuries often affect distal extremities as they are most commonly involved in workplace accidents.¹ However, we discuss a young male with a paint-gun injection injury to his face.

Case Report: We discuss the case of a young man presenting to the emergency department after high-pressure injection injury to the face. He eventually underwent extensive debridement of the face. We discuss differences in caring for an injection wound to an extremity versus the face, including time sensitivity of treatment, initial stabilizing measures, and critical steps.

Discussion: This case demonstrates a rare presentation of a high-pressure paint injection injury. This injury presented a unique surgical challenge where, despite compartment syndrome being less common, cosmetic outcome and infectious complication prevention remained critical priorities.

Conclusion: While similarities exist in management of an injection injury to a limb, due to the rarity and deceptive appearance of this particular injury to the face, high suspicion along with urgent imaging and surgical consultation is warranted. [Clin Pract Cases Emerg Med. 2020;4(2):211–213.]

Keywords: *compartment, pressure, injection injury, plastics, face.*

INTRODUCTION

High-pressure injection injuries present unique pathology. They cause devastating deep tissue damage despite small, innocuous, and usually painless skin lesions most commonly occurring on the hands, fingers, or feet. The skin lesions associated with these injuries often dwarf the severity of the damage occurring below the surface, as foreign chemical irritants are introduced into a closed compartment.² They are true surgical emergencies, requiring prompt surgical debridement, decompression, and thorough cleansing in the operating room to counter the risk of infection and compartment syndrome.² While these injuries are often devastating, they are rare. According to a 1991 study, only one in 600 hand traumas include an injection injury under high pressure, with injection injuries to the feet even more rare.³ Without adequate treatment,

surgical intervention, and proper follow-up care, morbidity is significant with amputation rates that reach as high as 48%.³

We report the case of a high-pressure injection injury to a unique anatomical location: the face. This case serves as a platform to explore the importance of the anatomical location of these injuries and how the location may guide treatment. Regardless of the misleading appearance of the wound and the low likelihood of compartment syndrome, high-pressure injection injuries to the face require a high level of suspicion and a low threshold for imaging and surgical consultation.

CASE REPORT

A 19-year-old male with no significant past medical history presented as a transfer to our Level I trauma center with a chief complaint of right facial injury. Eight hours prior

to arrival to our emergency department (ED), the patient accidentally discharged a pressurized, spray-paint gun while attempting to troubleshoot his equipment at work. Due to a language barrier, an interpreter was used throughout the patient encounter. The history was obtained from the patient interview and a review of medical records provided by an outside hospital. The patient endorsed right facial pain and dysphagia. He denied any eye pain, dysarthria, decreased vision, or trouble breathing. At the outside hospital, the patient was administered a dose of ampicillin/sulbactam for broad-spectrum antibiotic coverage and underwent computed tomography of the face and sinuses with contrast (Image 1). The imaging demonstrated “soft tissue hematoma/contusion involving right premolar and premandibular soft tissue regions,” as well as “hyperdense material likely paint [and] no infraorbital injury.”

Review of systems demonstrated facial swelling, sinus pain, sinus pressure, and trouble swallowing. The rest of review of systems was negative.

On arrival to our ED, the patient was hemodynamically stable with normal vital signs and was in no acute distress. His physical exam revealed swelling of the right face extending from his cheek just below the eye to the right upper lip (Image 2). The affected area was tender to palpation. The ocular exam was normal. Laboratory studies revealed a mild leukocytosis but were otherwise normal. Otorhinolaryngology was consulted for bedside evaluation. Upon review of the patient, they attempted an incision and drainage at the bedside with normal saline flushes of the region and decided to admit him for observation and eventual operative management.

The patient underwent excision and debridement of the face. He received his nutrition via nasogastric tube. Antibiotics were given and all cultures were pan-negative

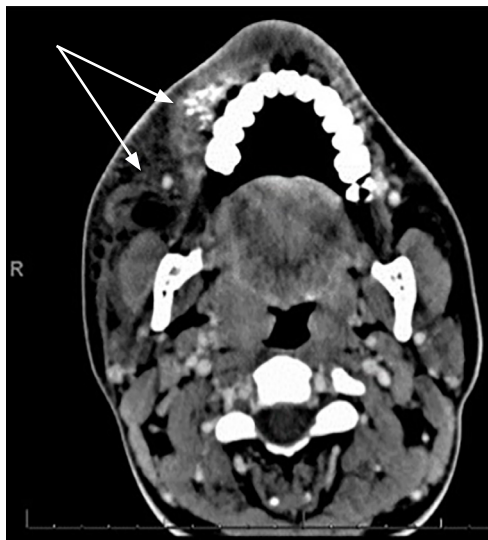

Image 1. Computed tomography horizontal view demonstrating soft tissue hematoma/contusion and hyperdense material (arrowheads).

CPC-EM Capsule

What do we already know about this clinical entity?

High-pressure injection injuries, while appearing innocuous, are dangerous. Usually affecting distal limbs, they can cause compartment syndrome and necrosis.

What makes this presentation of disease reportable?

A pressure injection injury to the face is rare, with no current guidelines for management. This case may provide guidance in presentation and care.

What is the major learning point?

There are distinct differences in caring for an injection wound to extremity vs face, such as time sensitivity of treatment and initial stabilizing measures.

How might this improve emergency medicine practice?

Due to the rarity and deceptive appearance of this injury, high suspicion along with urgent imaging and surgical consultation is warranted.

for bacterial and fungal pathogens. Pain was managed with oxycodone and acetaminophen. He was discharged one week after admission without issue.

DISCUSSION

This case demonstrates a rare presentation of a high-pressure paint injection injury. The anatomical location of this injury presented a unique challenge to the management of this patient because the region of the injury was distinct from the more common presentations of paint injection injuries. Most often located on the hand or digits, paint injection injuries are surgical emergencies warranting debridement in a sterile setting and separation of fascial layers with the hope of preventing infections such as necrotizing fasciitis.² The presentation of our patient differed significantly as his injection injury was located in the maxillofacial region lateral to the nose, medial to the temporomandibular joint, inferior to the orbits, and superior and anterior to the maxillary sinuses. This facial location of the injury greatly decreased the risk for compartment syndrome and

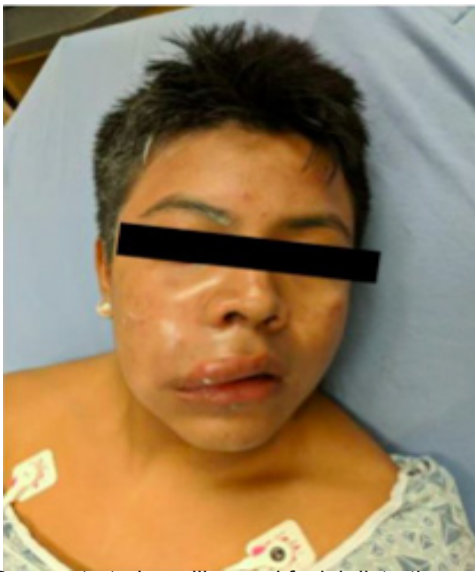

Image 2. Demonstrated swelling and facial distortion on the right side from high-pressure paint injection injury.

allowed time for both the otorhinolaryngology and emergency medicine teams to properly evaluate the injury to determine the best course of action for this patient. This injury presented a unique surgical challenge where, despite compartment syndrome being less common, cosmetic outcome and infectious complication prevention remained critical priorities.

Initially the decision to attempt bedside incision and drainage (I&D) was made with the hope that irrigation would help flush out the region of the paint and alleviate the need for an invasive surgical debridement. It was quickly discovered that with such an elevated pressure of injection into the region, the paint was affixed very firmly to the surrounding tissue. Bedside irrigation was not thorough enough to address the extent of this injury. The patient was admitted to the hospital to the otorhinolaryngology service in stable condition. While official guidelines do not exist as to whether I&D is indicated for this injury, several case reports suggest that I&D is not successful in fully addressing the extent of paint injection injuries and surgery is indicated regardless of the injury location.^{1,4,5}

The management of this patient was unique given the rarity, acuity, and severity of his presentation and the lack of concrete guidelines for a high-pressure paint injection injury to the face. Based on our literature review, there have only been two prior cases reporting high-pressure injection injury to the face, neither of which underwent acute surgical management from the ED. One case was observed and discharged as the high-pressure injury was only to the upper lip and the second case detailed granulomatous changes years later due to retained paint in the tissue causing a foreign body reaction.^{6,7}

CONCLUSION

High-pressure injection injuries to the face have a lower risk of compartment syndrome than high-pressure injection injuries to extremities; however, due to the rarity of reported cases, it is impossible to determine the risk of infectious complications, long-term neurovascular sequelae, or anatomical deformity. This case highlights the high level of suspicion emergency physicians must have despite the deceptive appearance of craniofacial high-pressure injuries and emphasizes the need for a low threshold for imaging and immediate surgical consultation.

Documented Institutional Review Board approval has been obtained and filed for publication of this case report.

Address for Correspondence: Blake Briggs, MD, Wake Forest Medical Center, Department of Emergency Medicine, Meads Hall, 2nd Floor, 1 Medical Center Blvd., Winston-Salem, NC 27107. Email: bbriggs@wakehealth.edu.

Conflicts of Interest: By the CPC-EM article submission agreement, all authors are required to disclose all affiliations, funding sources and financial or management relationships that could be perceived as potential sources of bias. The authors disclosed none.

Copyright: © 2020 Zitelny et al. This is an open access article distributed in accordance with the terms of the Creative Commons Attribution (CC BY 4.0) License. See: <http://creativecommons.org/licenses/by/4.0/>

REFERENCES

1. Booth CM. High pressure paint gun injuries. *BMJ*. 1977;2(6098):1333-5.
2. Verhoeven N and Hierner R. High-pressure injection injury of the hand: an often underestimated trauma: case report with study of the literature. *Strategies Trauma Limb Reconstr*. 2008;3(1):27-33.
3. Neal NC and Burke FD. High-pressure injection injuries. *Injury*. 1991;22(6):467-70.
4. Zook EG and Kinkead LR. Pressure gun injection injuries of the hand. *Am J Emerg Med*. 1979;8(7):264-6.
5. Yazar M, Gül Z, Güneç AC, et al. High pressure paint gun injury of the index finger: a case report. *Plast Aesthet Res*. 2015;2(6):350.
6. Chu FY, Wu KC, Lin HJ. Craniofacial high-pressure air injection injury. *Ann Emerg Med*. 2007;49(1):113-5.
7. Mushtaq J, Walker A, Hunter B. Under pressure: progressively enlarging facial mass following high-pressure paint injection injury. *BMJ Case Rep*. 2016. doi: 10.1136/bcr-2015-212817.

Rare External Jugular Vein Pseudoaneurysm

Patrick J. Wallace, DO, MS
Jordana Haber, MD

University of Nevada Las Vegas, Department of Emergency Medicine,
Las Vegas, Nevada

Section Editor: Rick A. McPheeters, DO

Submission history: Submitted September 4, 2019; Revision received December 20, 2019; Accepted December 18, 2019

Electronically published March 2, 2020

Full text available through open access at http://escholarship.org/uc/uciem_cpccem

DOI: 10.5811/cpcem.2019.12.45076

External jugular vein pseudoaneurysm is a very rare cause of a neck mass due to the low pressure venous system. This case demonstrates a 27-year-old female who presented to the emergency department with a non-tender, compressible, left-sided neck mass that enlarged with valsalva and talking, and intermittent paresthesias. Upon workup, she was diagnosed with an external jugular vein pseudoaneurysm. Complications of this diagnosis are mentioned in the literature; however, most patients with an external jugular vein pseudoaneurysm or aneurysm can be safely discharged with close follow-up with a vascular surgeon. [*Clin Pract Cases Emerg Med.* 2020;4(2):214–218.]

INTRODUCTION

Venous aneurysms are very rare compared to arterial aneurysms.¹⁻⁷ This is postulated to be related to the low pressure system in the superior vena cava.^{2,3,6,8} Because of this 77% of venous aneurysms are located in lower extremities.⁷ In addition, pseudoaneurysms of the external jugular vein are less common than aneurysms of the internal jugular vein, making them an exceedingly rare entity.^{3,5,7}

An aneurysm is defined as a dilation of all three layers of the vein wall. The histology of an aneurysm may show thinning of the elastic fiber wall, decreased smooth muscle in the media, and replacement of smooth muscle by fibrous tissue,^{7,9,10} whereas pseudoaneurysm is a tear through the outer layers of venous wall, the tunica adventitia and tunica media. The histology of a pseudoaneurysm shows collection of blood and thrombus in the wall.

CASE REPORT

An otherwise healthy 27-year-old African-American female presented to the emergency department complaining of a left neck mass with associated paresthesias radiating up her left lateral neck and down the left arm. These paresthesias were intermittent and positional. She noticed the mass present suddenly about two months prior to presentation and endorsed gradual increase in size, in addition to intermittent and positional paresthesias. The mass was painless and enlarged with talking and valsalva maneuvers. She denied any recent interventions including

massage, chiropractics, or neck manipulation. She had no known personal or family history of connective tissue disease. The patient also denied social history including smoking, alcohol, or substance use. However, she had been in a motor vehicle accident about four months prior without any significant injuries or immediate complications. This was a low-speed crash and the patient was able to self-extricate and self-ambulate without assistance immediately after the injury. No medical evaluation or imaging was completed at that time.

On physical exam, she had a 2-centimeter (cm) soft, compressible, non-pulsatile, nontender mass that enlarged with valsalva and talking along the antero-lateral left neck (Image 1). The mass was soft and mobile. It did not move or change in size with respirations or swallowing. There was no overlying erythema, warmth, ecchymosis, induration, or surrounding lymphadenopathy. Strength and sensation were intact in all extremities. Adson's, Allen's, and Roo's tests were all normal. Her paresthesias were not exacerbated with movement of her neck or arm, compression or distraction of the neck, or with Spurling's maneuver. Her neck was non-tender without restriction of motion, hypertonicity of muscles, or edema.

Basic blood work showed no abnormal findings. Computed tomography (CT) of the neck with contrast showed a 1.7 cm x 1.4 cm x 2 cm pseudoaneurysm of the left external jugular vein (Images 2 and 3). The case was discussed with the vascular surgeon on call. The patient had

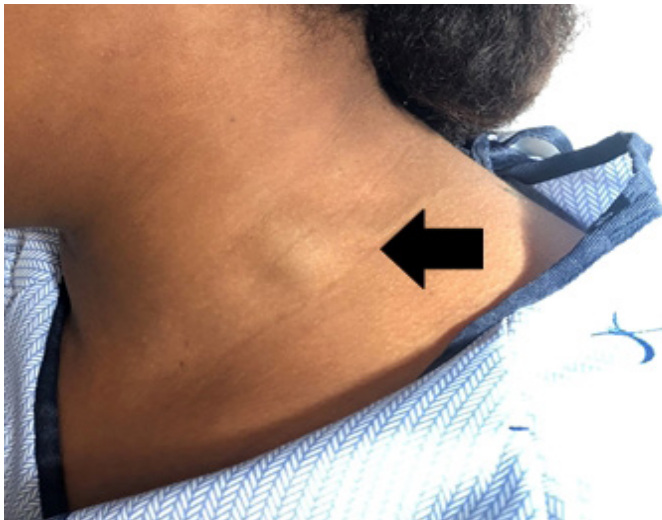

Image 1. Two-centimeter left external jugular pseudoaneurysm as seen on physical exam.

no signs that the pseudoaneurysm was expanding, causing airway compromise, had active extravasation, or was causing emergent neurological involvement at that time. We agreed she was safe for discharge at that time and could follow up with vascular surgery as an outpatient.

DISCUSSION

We found minimal literature on the topic of external jugular vein aneurysm and pseudoaneurysm, with only two other case reports of pseudoaneurysm published. We could not find any articles that had performed a formal review of the

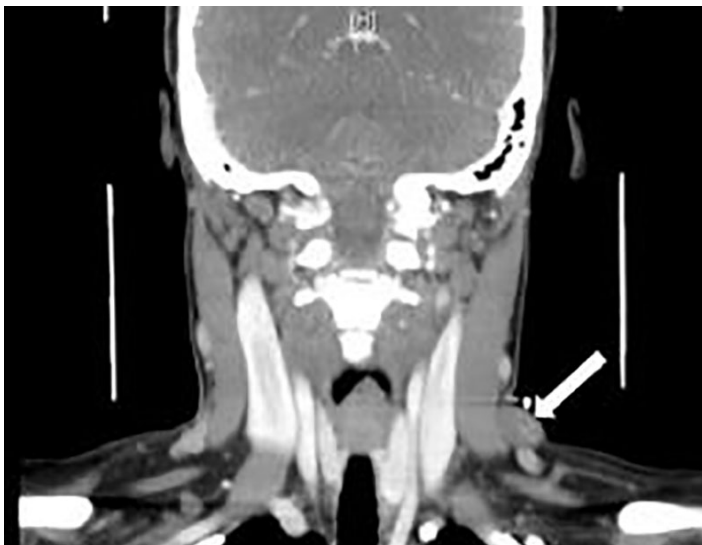


Image 2. Computed tomography with contrast coronal view of left external jugular venous pseudoaneurysm (arrow).

CPC-EM Capsule

What do we already know about this clinical entity?

External jugular venous pseudoaneurysm is a rare presentation. It is rarely symptomatic and often caused by trauma or cannulation of the internal jugular vein.

What makes this presentation of disease reportable?

Although ultrasound or computed tomography (CT) with angiography is recommended, in this case we demonstrate CT with contrast is sufficient to make the diagnosis.

What is the major learning point?

Ultrasound is the standard of care imaging modality. If asymptomatic, most pseudoaneurysms can be safely discharged and follow up with vascular surgery as an outpatient.

How might this improve emergency medicine practice?

Complications are very rare and often not life-threatening and can be managed as an outpatient.

literature. The table below compares the case reports available in this field of research.

The most common presentation for aneurysm and pseudoaneurysm is a pulsatile, palpable mass that enlarges with valsalva.^{1,10} Other symptoms include pain, dysphagia, hoarseness, and neurological findings.^{1,6} Doppler ultrasound is the gold standard and recommended first imaging technique for aneurysms and pseudoaneurysms.^{5,11}

Ultrasound can show turbulent flow and dilation with 95% accuracy for pseudoaneurysm.¹ It is non-invasive and helps differentiate vascular from non-vascular causes. Arterial pseudoaneurysms are seen as pulsatile and turbulent waveform on Doppler ultrasound.⁴ (CT angiography, magnetic resonance imaging, and magnetic resonance venography can more accurately demonstrate size and extent, but are not first line.^{5,6,8,11,12} Additionally, CT with intravenous contrast may be a suitable imaging modality in cases where ultrasound or clinical uncertainty requires a CT without angiography. To our knowledge this is the only case in the literature where an external jugular vein pseudoaneurysm was diagnosed with a contrast CT without angiography.

Table. Comparison list of articles on the topic of aneurysm and pseudoaneurysm of the external jugular vein.

Author, date	Age	Location	Type	Symptomatic (excluding swelling)	Intervention	Complications	Size	Medical History
Ekim et al. 2002 ⁹	21 M	External Jugular	Aneurysm	No	Surgical	None	2.0 cm diameter	None
Mohanty et al. 2013 ¹¹	12 M	External Jugular	Aneurysm	No	Surgical	None	3.4 x 3.3 x 3.0 cm	None
Lucatelli et al. 2017 ¹⁵	56 F	External Jugular	Aneurysm	No	Surgical	None	3.0 x 3.0 cm	Hypertension, mixed connective tissue disease
Lee et al. 2006 ⁷	63 F	External Jugular	Aneurysm	No	None	None	2.8 cm diameter	None
Kirmani et al. 2011 ⁸	35 M	External Jugular	Aneurysm	No	None	None	3.0 x 1.5 cm	None
Karapolat et al. 2004 ⁶	4 M	External Jugular	Aneurysm	No	Surgical	None	1) 1.0 x 1.0 cm; 2) 2.0 x 1.0 cm	none
Grigorescu et al. 2012 ⁵	58 F	External Jugular	Pseudoaneurysm	Yes. Cervical constriction, pulsatile burning sensation	Avoid excessive physical exertion	None	3.5 x 3.0 cm	Hypertension, atrial fibrillation, mitral and aortic regurgitation, pulmonary hypertension
Drakonaki et al. 2011 ⁴	74 F	External Jugular	Aneurysm	No	None	None	2.2 cm	Internal jugular vein catheterization 2 years prior
Chapman et al. 2018 ³	75 F	External Jugular	Aneurysm	No	Surgical	None	"Ping pong-ball size"	Hypertension
Basbug et al. 2015 ²	19 F	External Jugular	Aneurysm	No	Surgical	None	2.5 x 3.5 x 1.5 cm	Lipoma excision Right supraclavicular region 11 years prior
Regina et al. 1992 ¹⁴	39 F	External Jugular	Aneurysm	No	Surgical	None	4.0 cm	None
Shah et al. 2015 ¹²	25 M	External Jugular	Pseudoaneurysm	No	Surgical	None; of note hemorrhage and thrombosis were present on histology	7.0 x 6.0 cm	None
Swaika et al. 2013 ¹³	8 M	External Jugular	Aneurysm	No	Surgical	None	2.0 x 1.0 cm	None

M, male; F, female; cm, centimeter.

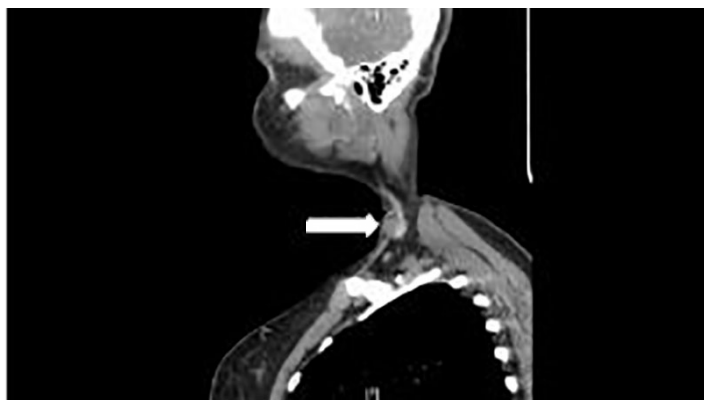

Image 3. Computed tomography with contrast sagittal view of left external jugular venous pseudoaneurysm (arrow).

Venous aneurysms are classified as primary (congenital) and secondary (acquired).^{2,5,8} Causes of primary venous aneurysms are not fully understood,^{9,13} while possible etiologies for secondary aneurysms within the venous system include thoracic outlet obstruction, trauma, chronic inflammation, degeneration, and increased venous pressure.^{2,4,5,11,14} Known risk factors for secondary venous aneurysms include recent trauma, cardiovascular disease, and age.³

Pseudoaneurysms in the arterial system of the neck have similar underlying etiology to include trauma,^{1,3} venous valve insufficiency,³ tumor,³ and iatrogenic causes such as surgical interventions or central line complications.¹ There are currently only two other case reports on external jugular vein pseudoaneurysm.^{5,12} Shah et al discusses one of these case reports, specifically a fusiform dilation. This patient had no past medical history and no evidence of trauma other than repeated irritation to the neck by the sling and buckle of his rifle.¹²

Venous aneurysms and pseudoaneurysms are a rare cause of neck masses.^{4,15} The differential diagnosis includes lymphocele, cavernous hemangioma, hygroma, abscess, cyst, laryngocele, lymph node, tumor, thyroglossal cyst, and branchial cleft cyst.^{4,5,12,15} Enlargement of the mass with valsalva or excursion is suspicious for laryngocele, aneurysm, or pseudoaneurysm.^{8,10}

Complications may include pulmonary embolism, thrombus formation or thrombophlebitis, and rupture.^{5,6,8,10,12} The research suggests there is risk of major embolic complications from jugular vein aneurysms. However, McCready et al states: "Based on the few cases in the literature, rupture or thromboembolic complications in patients with axillary or subclavian venous aneurysms do not appear to occur. Conservative therapy is appropriate for patients with axillary and subclavian venous aneurysms."¹⁰ At the time of this publication there were no reports in the literature of any of the above-mentioned complications from external jugular vein pseudoaneurysm. These complications are mostly seen in the lower extremities from popliteal and femoral aneurysms.^{7,10,14}

Surgical indications include large aneurysms compressing nearby structures, potential for thrombus, cosmetic reasons, or presence of symptoms.^{7,10} Venous aneurysms of the neck are often asymptomatic requiring no intervention and can be monitored.^{1,2,5} Approximately 89% of iatrogenic pseudoaneurysms will heal spontaneously without intervention.¹ Upon our review, the case reports where patients underwent surgery were all for cosmetic reasons. Management can include supportive care and outpatient follow-up with surgery. Symptomatic patients may need to be admitted for observation if there are concerns for rapidly enlarging pseudoaneurysm, rupture, or signs of hemodynamic instability. As noted in the table below, none of the patients discussed in these case reports had concerning symptoms that would warrant admission and we believe the majority of patients with jugular vein pseudoaneurysms can be safely discharged and follow-up with a vascular surgeon.

CONCLUSION

Pseudoaneurysms of the external jugular vein are very rare with only two other case reports published in the literature. Pseudoaneurysm presents as a pulseless mass that enlarges with valsalva and exertion. No complications have been reported in the literature and no intervention is indicated in the asymptomatic patient. If asymptomatic, patients can be safely discharged with outpatient referral to surgery for cosmetic excision.

Documented patient informed consent and/or Institutional Review Board approval has been obtained and filed for publication of this case report.

Address for Correspondence: Patrick J. Wallace, MS, DO, University of Nevada Las Vegas, Department of Emergency Medicine, 901 Rancho Ln, Ste 135, Las Vegas, NV 89106. Email: Patrick.wallace@unlv.edu.

Conflicts of Interest: By the CPC-EM article submission agreement, all authors are required to disclose all affiliations, funding sources and financial or management relationships that could be perceived as potential sources of bias. The authors disclosed none.

Copyright: © 2020 Wallace et al. This is an open access article distributed in accordance with the terms of the Creative Commons Attribution (CC BY 4.0) License. See: <http://creativecommons.org/licenses/by/4.0/>

REFERENCES

1. Abdel-Aty Y and Bellew M. Endovascular management of a refractory pseudoaneurysm of the sternocleidomastoid artery caused by attempted internal jugular central line placement with long

- term follow-up: a case report and review. *Case Rep Otolaryngol*. 2018;2018:8324908.
2. Basbug HS, Bitargil M, Karakurt A, et al. External jugular vein aneurysm in a young woman: An uncommon cause of neck mass. *Int J Cardiovasc Acad*. 2016;2(1):16-18.
 3. Chapman DR, Ho RE, Gangemi A. A case report of a rare, spontaneous external jugular vein aneurysm. *Int J Surg Case Rep*. 2018;52:8-10.
 4. Drakonaki EE, Symvoulakis EK, Fachouridi A, et al. External jugular vein aneurysm presenting as a cervical mass. *Int J Otolaryngol*. 2011;2011:485293.
 5. Grigorescu I, Dumitrascu DL, Manole S, et al. Pseudoaneurysm of the external jugular vein communicating with the internal jugular vein. case report. *Med Ultrason*. 2012;14(3):257-60.
 6. Karapolat S, Erkut B, Unlu Y. Multiple aneurysms of the left external jugular vein. *Turk J Med Sci*. 2005;35:43-45.
 7. Lee HY, Lee W, Cho YK, et al. Superficial venous aneurysm. Reports of 3 cases and literature review. *J Ultrasound Med*. 2006;25(6):771-6.
 8. Kirmani S, Rashid M, Ali I, et al. External jugular vein aneurysm: a rare cause of neck swelling. *J Ultrasound Med*. 2011;30(8):1156-66.
 9. Ekim H and Ozen S. Primary venous aneurysm of the external jugular vein. *East J Med*. 2002;7(1):24-5.
 10. McCready RA, Bryant MA, Divilbiss JL, et al. Subclavian venous aneurysm: case report and review of the literature. *J Vasc Surg*. 2007;45(5):1080-2.
 11. Mohanty D, Jain BK, Garg PK, et al. External jugular vein aneurysm: case report. *J Nat Sci Biol Med*. 2013;4(1):223-5.
 12. Shah NM, Shah VS, Dalai PR, et al. A pseudoaneurysm of the external jugular vein – a case report. *BMJ*. 2015;7(2):52-4.
 13. Swaika S, Basu S, Bhadra RC, et al. Multiple venous aneurysms of neck. *J Indian Assoc Pediatr Surg*. 2013;18(1):25-6.
 14. Regina G, Cardia G, Squeo MA, et al. Aneurysm of the internal jugular vein—a case report. *Vasc Surg*. 1988;22(3):169-71.
 15. Lucatelli P, Tommasino G, Guaccio G, et al. External jugular vein spontaneous aneurysm, diagnosis, and treatment with video. *Ann Vasc Surg*. 2017;41:282.e11-282.e13.

A Case of COVID-19 Pneumonia in a Young Male with Full Body Rash as a Presenting Symptom

Madison Hunt, MD
Christian Koziatek, MD

New York University School of Medicine, Department of Emergency Medicine, New York, New York
Bellevue Hospital Center, Department of Emergency Medicine, New York, New York

Section Editor: Rick A. McPheeters, DO

Submission history: Submitted March 21, 2020; Revision received March 25, 2020; Accepted March 25, 2020

Electronically published March 28, 2020

Full text available through open access at http://escholarship.org/uc/uciem_cpccem

DOI: 10.5811/cpcem.2020.3.47349

Background: In December 2019 the coronavirus disease of 2019 (COVID-19), caused by the severe acute respiratory syndrome coronavirus 2, was identified in Wuhan, China. In the ensuing months, the COVID-19 pandemic has spread globally and case load is exponentially increasing across the United States. Emergency departments have adopted screening and triage procedures to identify potential cases and isolate them during evaluation.

Case Presentation: We describe a case of COVID-19 pneumonia requiring hospitalization that presented with fever and extensive rash as the primary presenting symptoms. Rash has only been rarely reported in COVID-19 patients, and has not been previously described. [Clin Pract Cases Emerg Med. 2020;4(2):219–221.]

Keywords: COVID-19; coronavirus; rash.

CASE PRESENTATION

A 20-year-old previously healthy male originally presented to an urgent care center with a chief complaint of fever and rash. He was diagnosed with a viral upper respiratory infection and sent home with supportive care. Six days later, the patient presented to the emergency department (ED) with continued fever and rash. Vital signs included a temperature of 103.0° Fahrenheit, heart rate 115 beats per minute, blood pressure 93/54 millimeters of mercury, respiratory rate 24 breaths per minute, and an oxygen saturation of 91%. Physical examination revealed a diffuse, morbilliform rash across the trunk and extremities, sparing the face (Images 1 and 2). There was no mucosal or ocular involvement. Chest radiograph revealed bilateral infiltrates consistent with multifocal pneumonia (Image 3). Labs included a normal leukocyte count (8300 units per liter [uL], reference range 4200-9100/uL) with an absolute lymphocyte count of 800/uL (reference range 1300-3600/uL). A C-reactive protein was elevated at 118.5 milligrams per liter (mg/L) (reference range 0-5 mg/L). A rapid strep test and an human immunodeficiency virus test were both negative, as was a respiratory viral panel. The patient required escalating

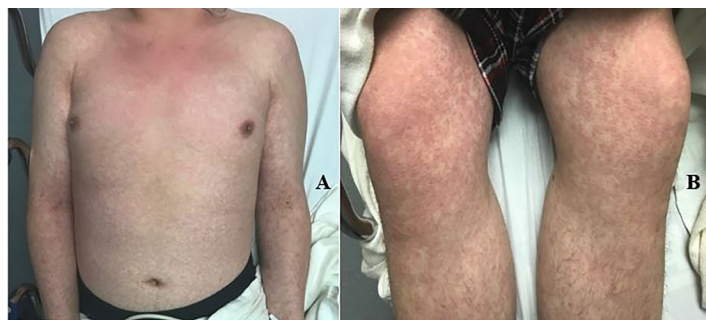


Image 1. Image of the anterior trunk and upper extremities (A) and anterior lower extremities (B) demonstrating a diffuse, morbilliform, maculopapular rash.

amounts of supplemental oxygen during his ED course and was admitted to the intensive care unit (ICU). A severe acute respiratory syndrome coronavirus 2 (SARS-CoV-2) polymerase chain reaction test resulted positive on hospital day two. The patient remains hospitalized in the ICU on hospital day six.

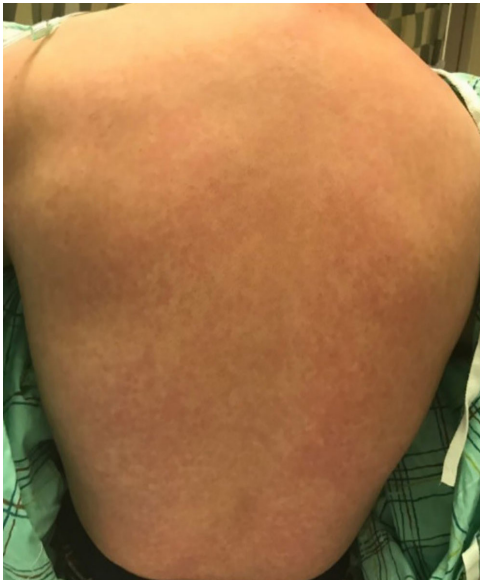

Image 2. Image of the posterior trunk similarly demonstrates a diffuse, maculopapular morbilliform rash.

DISCUSSION

We describe a case of COVID-19 pneumonia in a young, healthy male requiring hospitalization, which presented with fever and extensive rash. The rash was morbilliform, maculopapular, and nonpruritic, and appeared consistent with a viral exanthem. The clinical characteristics of COVID-19 have been described in several publications, most thoroughly in a case series of 1099 patients by Guan et al. Fever, cough, congestion, and dyspnea are the most common presenting symptoms. Only 2/1099 patients were noted to have any skin

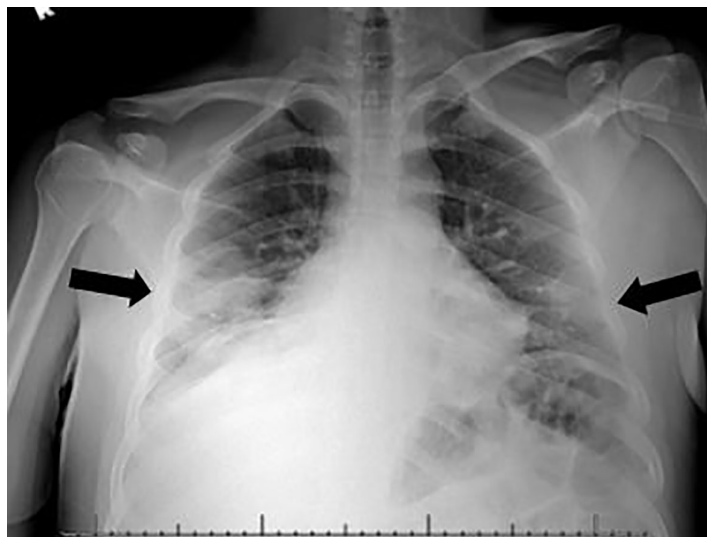


Image 3. A chest radiograph demonstrating bilateral infiltrates consistent with bilateral multifocal pneumonia.

CPC-EM Capsule

What do we already know about this clinical entity?

Coronavirus disease of 2019 (COVID-19) typically initially presents with symptoms similar to other viral respiratory infections, most commonly with fever, cough, fatigue, myalgias, and congestion.

What is the major impact of the image(s)?

This case describes a COVID-19 patient who presented with a full body rash, which is a rare presenting symptom in previous studies and has not been described previously in the literature.

How might this improve emergency medicine practice?

COVID-19 may rarely present with an associated morbilliform viral eruption and should not be discarded as a diagnostic possibility in patients with viral syndrome and rash.

rash, and the rash was not described¹; no other publications have noted or described skin manifestations as a presenting symptom.¹⁻⁵ Rash may be a rare presenting symptom of COVID-19 and should be kept in mind by front-line providers.

Documented patient informed consent has been obtained and filed for publication of this image in emergency medicine.

Address for Correspondence: Christian Koziatek, MD, New York University School of Medicine, Department of Emergency Medicine, 462 First Avenue, Room A340A, New York, NY 10016. Email: ckoziatek@gmail.com.

Conflicts of Interest: By the CPC-EM article submission agreement, all authors are required to disclose all affiliations, funding sources and financial or management relationships that could be perceived as potential sources of bias. The authors disclosed none.

Copyright: © 2020 Hunt et al. This is an open access article distributed in accordance with the terms of the Creative Commons Attribution (CC BY 4.0) License. See: <http://creativecommons.org/licenses/by/4.0/>

REFERENCES

1. Guan WJ, Ni ZY, Hu Y, et al. Clinical characteristics of coronavirus disease 2019 in China. *N Engl J Med.* 2020. In Press.
2. Xu XW, Wu XX, Jiang XG, et al. Clinical findings in a group of patients infected with the 2019 novel coronavirus (SARS-Cov-2) outside of Wuhan, China: Retrospective case series. *BMJ.* 2020;368:m606.
3. Shi H, Han X, Jiang N, et al. Radiological findings from 81 patients with COVID-19 pneumonia in Wuhan, China: a descriptive study. *Lancet Infect Dis.* 2020. In Press.
4. Zhou F, Yu T, Du R, et al. Clinical course and risk factors for mortality of adult inpatients with COVID-19 in Wuhan, China: a retrospective cohort study. *Lancet.* 2020;pii:S0140-6736(20)30566-3.
5. Wu Z and McGoogan JM. Characteristics of and important lessons from the coronavirus disease 2019 (COVID-19) outbreak in China: summary of a report of 72 314 cases from the Chinese Center for Disease Control and Prevention. *JAMA.* February 2020. In Press.

Image to Fit the Clinical Picture: Point-of-care Ultrasound Assessment of Ebstein's Anomaly in Peru

Ashley C. Rider, MD*
Andrea Dreyfuss, MD, MPH*
Roberto Inga, MD†

*Highland Hospital, Alameda Health System, Oakland, California
†Hospital Nacional Dos de Mayo, Department of Emergency Medicine, Lima, Peru

Section Editor: Rick A. McPheeters, DO

Submission history: Submitted August 1, 2019; Revision received November 30, 2019; Accepted December 18, 2019

Electronically published February 24, 2020

Full text available through open access at http://escholarship.org/uc/uciem_cpem

DOI: 10.5811/cpcem.2019.12.44783

Ebstein's anomaly is a congenital heart defect that when left untreated can lead to unique physical exam and ultrasound findings. This case describes a patient who presented with dyspnea and was found to have cyanosis, clubbing, and dilation of right-sided chambers on point-of-care ultrasound. The series of images highlights findings in late-stage Ebstein's anomaly and serves as a springboard for the discussion of the pathophysiology, diagnosis, and treatment of this rare congenital heart disease. [Clin Pract Cases Emerg Med. 2020;4(2):222–224.]

CASE PRESENTATION

A 20-year-old male presented to the emergency department with progressive dyspnea. He was noted to have hypoxemia, clubbing of the fingers (Image 1), and perioral cyanosis (Image 2). Point-of-care ultrasound revealed a severe anatomic abnormality of the heart consistent with Ebstein's anomaly (Image 3 and video).

DISCUSSION

Ebstein's anomaly is caused by a congenital insufficiency of the tricuspid valve due to the apical displacement of the annulus. This leads to a dilated atrium and atrialization of the right ventricle as seen in this ultrasound image of a standard apical 4-chamber view.¹ Other cardiac anomalies are commonly associated, such as atrial septal defect and ventricular septal defect.²

Ebstein's anomaly accounts for less than 1% of congestive heart failure (CHF) and varies in severity.³ If tricuspid regurgitation is severe, symptoms such as CHF and cardiomegaly may develop in the neonatal period.¹ Mild cases of Ebstein's anomaly may remain undiagnosed until late childhood or adulthood, when presenting symptoms may include cyanosis and decreased exercise tolerance, as with this case. Adults also have a high risk of atrial tachyarrhythmia and ventricular pre-excitation, which predisposes patients to lethal arrhythmias.⁴

Patients with Ebstein's anomaly may require medical or surgical treatment for atrialization of the right ventricle.⁵ Medical

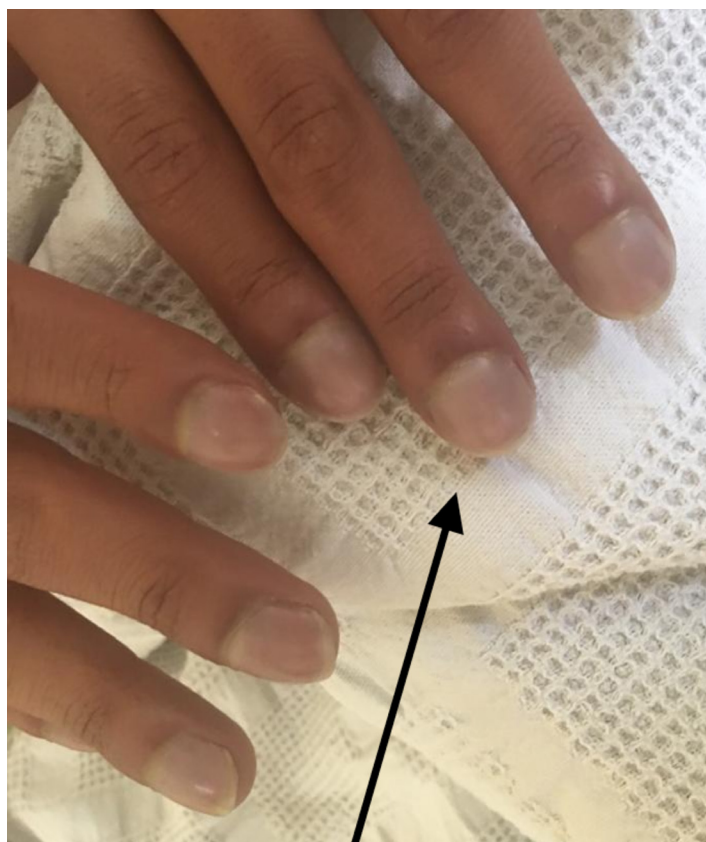


Image 1. Fingers of patient (arrow) demonstrating cyanosis and clubbing.

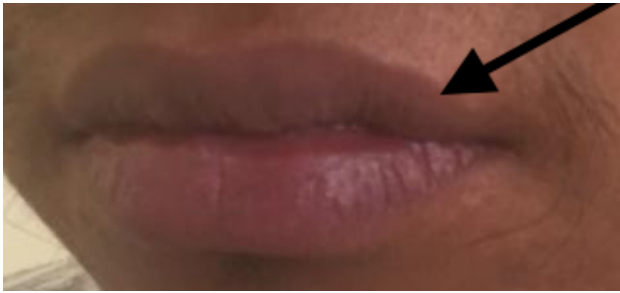

Image 2. Mild cyanosis of lips (arrow) demonstrating chronic hypoxemia.

treatment includes diuresis, angiotensin-converting enzyme inhibitors, and digoxin. Tricuspid valve repair or replacement may be indicated in patients experiencing deteriorating exercise capacity, cyanosis (finger oxygen saturation <90%), paradoxical embolism, cardiomegaly, or reduction of right heart function.⁵ Surgical intervention should not be delayed until right heart failure occurs as this is associated with poor outcomes.⁴ Most cases of Ebstein's anomaly fare well, especially when surgically corrected, with the majority of patients living to at least age 60.³

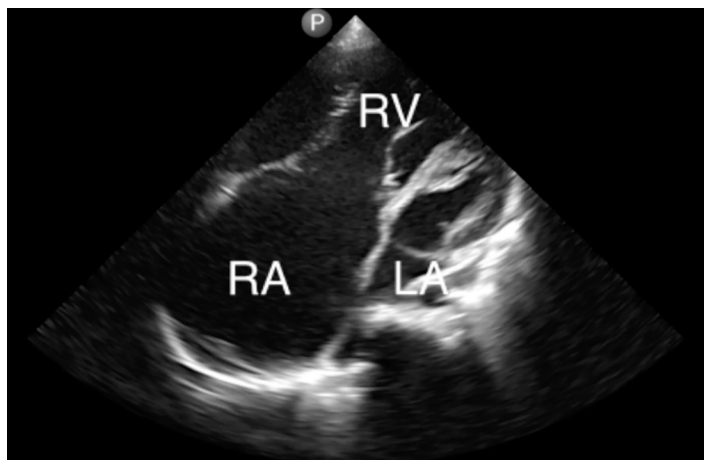


Image 3. Point-of-care ultrasound apical 4-chamber view of patient with Ebstein's anomaly demonstrating the dilated right heart chambers. The left ventricle is demonstrated by the arrow. RV, right ventricle; RA, right atrium; LA, left atrium.

Video. An apical 4-chamber cardiac ultrasound obtained in a patient with Ebstein's anomaly demonstrating the dilated right-sided chambers. The left ventricle is demonstrated by the arrow. RV, right ventricle; RA, right atrium; LA, left atrium arrow.

Documented patient informed consent and/or Institutional Review Board approval has been obtained and filed for publication of this case report.

CPC-EM Capsule

What do we already know about this clinical entity?

Ebstein's anomaly is a form of congenital heart disease caused by insufficiency of the tricuspid valve, leading to a dilated atrium and atrialization of the left ventricle.

What is the major impact of the image(s)?

These images show physical exam findings and point-of-care ultrasound (POCUS) features of late-stage Ebstein's anomaly in a patient in Peru.

How might this improve emergency medicine practice?

In settings with limited access to pediatric cardiac surgery, patients may present with late manifestations of the disease. POCUS ultrasound may help in the diagnosis.

Address for Correspondence: Ashley C. Rider, MD, Highland Hospital, Alameda Health System, Department of Emergency Medicine, 1411 E. 31st Street, Oakland, CA 94602. Email: ashley.christine.rider@gmail.com.

Conflicts of Interest: By the CPC-EM article submission agreement, all authors are required to disclose all affiliations, funding sources and financial or management relationships that could be perceived as potential sources of bias. The authors disclosed none.

Copyright: © 2020 Rider et al. This is an open access article distributed in accordance with the terms of the Creative Commons Attribution (CC BY 4.0) License. See: <http://creativecommons.org/licenses/by/4.0/>

REFERENCES

1. Attenhofer Jost CH, Connolly HM, Dearani JA, et al. Ebstein's anomaly. Congenital heart disease for the adult cardiologist. *Circulation*. 2007;115(2):277-85.
2. Luu Q, Choudhary P, Jackson D, et al. Ebstein's anomaly in those surviving to adult life: a single centre experience. *Heart Lung Circ*. 2015;24(10):996-1001.
3. Choudhary P, Luu Q, Caniffe C, et al. Abstract 18937: Ebstein's anomaly in adults: favourable outcomes from a single specialist centre experience. *Circulation*. 2018;130(suppl 2):A18937.
4. Stout KK, Daniels CJ, Aboulhosn JA, et al. 2018 AHA/ACC Guideline for

the Management of Adults with Congenital Heart Disease: a report of the American College of Cardiology/American Heart Association Task Force on Clinical Practice Guidelines. *Circulation*. 2019;139(14):e698-800.

5. Riaz KR and Ali YS. Ebstein anomaly guidelines. Available at: <https://emedicine.medscape.com/article/154447-guidelines>. Accessed June 17, 2019.

A Rare Case of Hip Pain Secondary to Pigmented Villonodular Synovitis

Gary Lai, DO*

Brett Staller, MD†

Bhaskar Ganguly, MD‡

Quan Ta, BS§

Alexander J. Scumpia, DO, MSc*

*Broward Health, Department of Emergency Medicine, Coral Springs, Florida

†Broward Health, Department of Diagnostic Radiology, Coral Springs, Florida

‡Broward Health, Department of Internal Medicine, Coral Springs, Florida

§Florida Atlantic University, Boca Raton, Florida

Section Editor: Anna McFarlin, MD

Submission history: Submitted September 16, 2019; Revision received December 6, 2019; Accepted December 19, 2019

Electronically published February 24, 2020

Full text available through open access at http://escholarship.org/uc/uciem_cpem

DOI: 10.5811/cpcem.2019.12.45253

A 19-year-old Asian male presented to our emergency department with atraumatic right hip pain radiating to the right groin associated with pain on ambulation. Magnetic resonance imaging of the right hip with and without contrast revealed the diagnosis. Pigmented villonodular synovitis is a rare, monoarticular benign tumor originating from the synovium of the joint. The treatment is synovectomy of the pathological joint to prevent further disease progression. [Clin Pract Cases Emerg Med. 2020;4(2):225–226.]

CASE PRESENTATION

A 19-year-old Asian male presented to our emergency department (ED) with a one-day history of atraumatic right hip pain radiating to the right groin associated with pain on ambulation. The patient denied weakness or numbness of his extremity, fever, chills, or recent illness. Physical examination only revealed decreased range of motion and pain with internal rotation and flexion of the right hip. ED labs consisting of complete blood count, complete metabolic profile, C-reactive protein, and erythrocyte sedimentation rate were within normal limits. Ultrasound with Doppler of the patient's scrotum was unremarkable. Computed tomography of the abdomen and pelvis with intravenous contrast demonstrated a right hip fluid collection consistent with inflammation or infection. Magnetic resonance imaging (MRI) of the right hip with and without contrast suggested the diagnosis (Image).

DISCUSSION

Pigmented villonodular synovitis. Pigmented villonodular synovitis (PVNS) is a rare, monoarticular benign tumor originating from the synovium of the joint.^{1,2} More commonly, this tumor is slow-growing, involving a localized portion of the joint or, in rarer cases, diffuse with malignant-type features (ie, involving the entire joint, or extra-articular lesions).³⁻⁵ The incidence of intra-articular PVNS predominately occurs in

young adults (median age of 30 years) and has been reported to be 1.8 per million with equal gender distribution.⁴ The hip is the second most common joint affected (15% of all cases), with the knee the most prevalent of joints affected. MRI is the

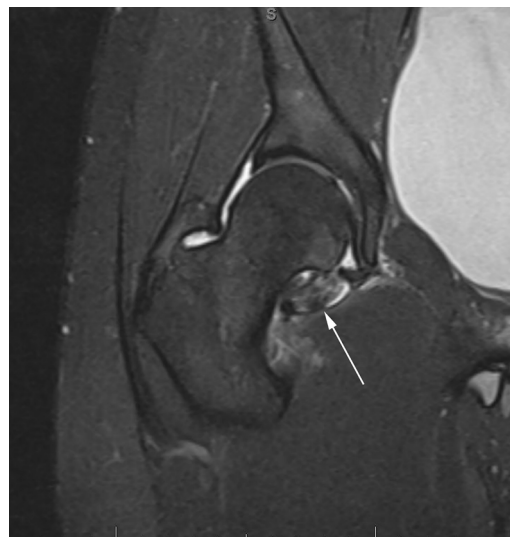


Image. Coronal magnetic resonance imaging (T1-weighted) of the patient's right hip demonstrating the hypointense lesion caused by the hemosiderin deposition in the hyperplastic synovium characteristic of pigmented villonodular synovitis (white arrow).

radiographic study of choice to identify hyperplastic synovium lesion(s) characteristic of PVNS.⁴ The treatment is complete synovectomy of the pathological joint to prevent further disease progression; with a recurrence rate of 7.7 to 17.8%.¹ This case illustrates the necessity of a broad ED differential diagnosis (i.e., neoplasms, infection, etc.) accompanied with multiple diagnostic modalities for optimum patient outcome.

Documented patient informed consent and/or Institutional Review Board approval has been obtained and filed for publication of this case report.

Address for Correspondence: Alexander J. Scumpia, DO, Broward Health, Department of Emergency Medicine, 3000 Coral Hills Dr, Coral Springs, FL 33065. Email: ascumpia@yahoo.com.

Conflicts of Interest: By the CPC-EM article submission agreement, all authors are required to disclose all affiliations, funding sources and financial or management relationships that could be perceived as potential sources of bias. The authors disclosed none.

Copyright: © 2020 Lai et al. This is an open access article distributed in accordance with the terms of the Creative Commons Attribution (CC BY 4.0) License. See: <http://creativecommons.org/licenses/by/4.0/>

REFERENCES

1. Steinmetz S, Rougemont AL, Peter R. Pigmented villonodular synovitis of the hip. *EFFORT Open Rev.* 2016;1(6):260-6.
2. Elumogo CO, Kochenderfer JN, Civelek AC, et al. Pigmented villonodular synovitis mimics metastases on fluorine 18 fluorodeoxyglucose position emission tomography-computed tomography. *Quan Imaging Med Surg.* 2016;6(2):218-23.
3. Koto K, Murata H, Sakabe T, et al. Magnetic resonance imaging and thallium-201 scintigraphy for the diagnosis of localized pigmented villonodular synovitis arising from the elbow: a case report and review of the literature. *Exp Ther Med.* 2013;5(5):1277-80.
4. Bertoni F, Unni KK, Beabout JW, et al. Malignant giant cell tumor of the tendon sheaths and joints (malignant pigmented villonodular synovitis). *Am J Surg Pathol.* 1997;21(2):153-63.
5. Shabat S, Kollender Y, Merimsky O, et al. The use of surgery and yttrium 90 in the management of extensive and diffuse pigmented villonodular synovitis of large joints. *Rheumatology (Oxford).* 2002;41(10):1113-8.

CPC-EM Capsule

What do we already know about this clinical entity?

Pigmented villonodular synovitis (PVNS) is a rare, monoarticular benign tumor originating from the synovium of the joint.

What is the major impact of the image(s)?

The image demonstrates the hypointense lesion caused by the hemosiderin deposition in the hyperplastic synovium characteristic of PVNS.

How might this improve emergency medicine practice?

This case illustrates the necessity of a broad differential diagnosis in a very common patient chief complaint (arthralgia) for optimum patient outcome.

Bowel Perforation in the Emergency Department Related to Bevacizumab Therapy and Recurrent Ovarian Cancer

Stuart A. Ostby, MD*
 Michael Olushoga, MD†
 Charles A. Leath III, MD‡
 Samuel L. Burleson, MD†

*University of Alabama at Birmingham, Department of Obstetrics and Gynecology, Birmingham, Alabama

†University of Alabama at Birmingham, Department of Emergency Medicine, Birmingham, Alabama

‡University of Alabama at Birmingham, Department of Obstetrics and Gynecology, Division of Gynecologic Oncology, Birmingham, Alabama

Section Editor: Rick A. McPheeters, DO

Submission history: Submitted October 5, 2019; Revision received December 20, 2019; Accepted January 28, 2020

Electronically published March 27, 2020

Full text available through open access at http://escholarship.org/uc/uciem_cpem

DOI: 10.5811/cpcem.2020.1.45374

Case Presentation: We describe the presentation to the emergency department of a patient with recurrent ovarian cancer treated with bevacizumab with the complication of bowel perforation.

Discussion: We review the frequency and outcomes of bevacizumab-related bowel perforation. We also report the patient's imaging findings, including the radiologic presentation of free intraperitoneal air and portal venous gas, both indicative of bowel perforation and the need for emergent surgical evaluation. Our case also illustrates the potentially catastrophic side effects of bevacizumab and other targeted oncologic therapies of which emergency physicians may not be aware. [Clin Pract Cases Emerg Med. 2020;4(2):227–229.]

Keywords: *bevacizumab; oncologic emergency; bowel ischemia.*

CASE PRESENTATION

A 69-year-old, African-American female with recurrent stage IIIC ovarian carcinoma treated with bevacizumab presented to the emergency department (ED) with abdominal pain, distention, vomiting, and hypotension. After initial stabilization, an upright abdominal radiograph (Image 1) revealed peritoneal free air and portal venous gas concerning for bowel perforation, which was confirmed by computed tomography (CT) of the abdomen and pelvis (Images 2 and 3).

The patient was admitted to the gynecology oncology service and maintained on crystalloids and antibiotics. She had minimal symptoms. In accordance with her wishes, no further aggressive intervention was pursued, and she died on hospital day three.

DISCUSSION

Bevacizumab is a monoclonal antibody targeting the vascular endothelial growth factor receptor used in multiple

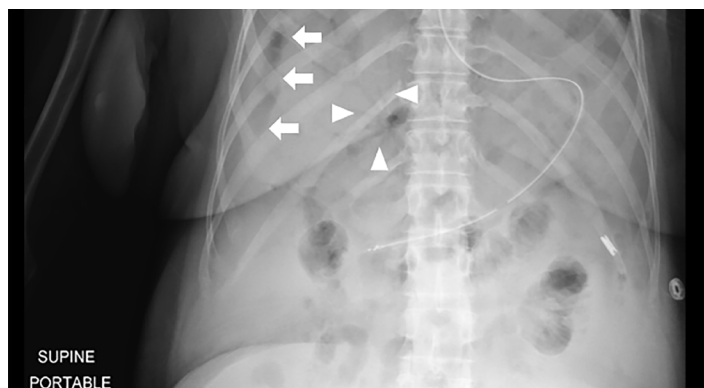


Image 1. Upright abdominal radiograph revealing free air along the lateral margin of the liver (arrows) and branching gas in the liver (triangles), concerning for portal venous gas.

cancer types, including ovarian.^{1,2} Complications include bowel perforation and gastrointestinal (GI) bleeding.³ The

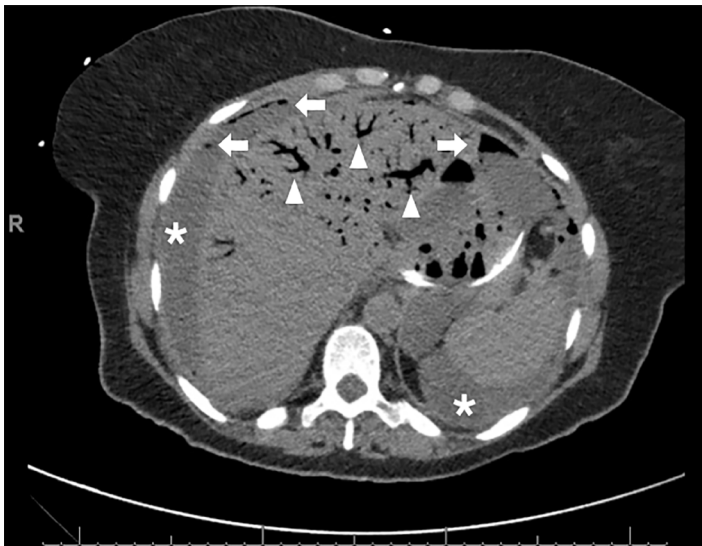


Image 2. Computed tomography scan of the abdomen revealing extensive ascites (*), intraperitoneal free air (arrows), and extensive branching portal venous gas (triangles), indicative of bowel ischemia, necrosis, and perforation.

incidence of bowel perforation in ovarian cancer treated with bevacizumab is estimated to be 2-3%,⁴ with a relative risk of 2.57 compared to ovarian cancer alone.⁵ Bowel perforation and other severe GI pathologies are seen with other commonly-used targeted therapies such as sunitinib, sorafenib, everolimus, and temsirolimus.⁶ This patient had

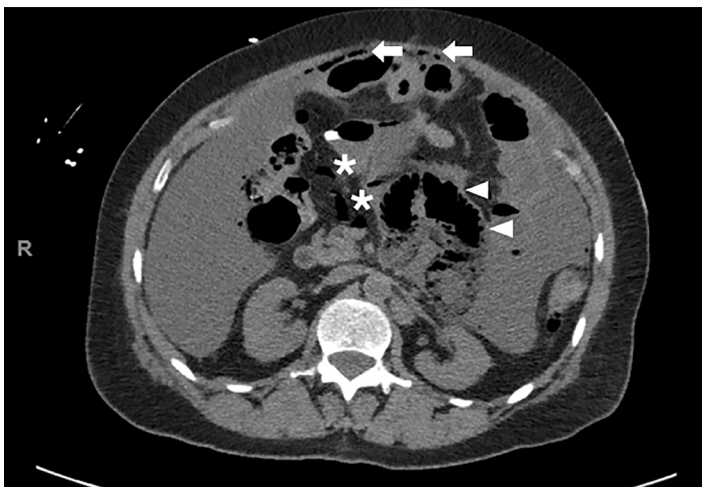


Image 3. Computed tomography of the abdomen revealing intraperitoneal free air (arrows), bowel wall pneumatosis (triangles), and air in the mesenteric vasculature (*).

CPC-EM Capsule

What do we already know about this clinical entity?

Bevacizumab is an increasingly used targeted chemotherapeutic agent with infrequent, severe complications including gastrointestinal perforation.

What is the major impact of the image(s)?

Severe ischemic bowel related to bevacizumab therapy and widespread diagnostic findings of mesenteric ischemia, portal venous gas, and free air are demonstrated.

How might this improve emergency medicine practice?

Early recognition and diagnosis for bowel perforation in patients on bevacizumab is essential to allow prompt surgical evaluation and therapy.

other independent risk factors for perforation including bowel resection-reanastomosis, peritoneal carcinomatosis, and partial small bowel obstructions.

Bowel perforation secondary to bevacizumab has an estimated 60-day mortality of 25%.² The diagnosis is confirmed by radiographs or CT of the abdomen demonstrating intraperitoneal free air, pneumatosis intestinalis, or portal venous gas. While management is generally surgical, supportive care, including antibiotics, parenteral nutrition, and fluid resuscitation, has been successful in poor surgical candidates.

In summary, we report a case of bowel perforation related to bevacizumab therapy. This case demonstrates the potentially life-threatening side effects of bevacizumab and other frequently-used, targeted therapies requiring ED diagnosis and resuscitation, and the complex imaging findings associated with the diagnosis of bowel perforation in a patient with recurrent ovarian cancer.

The documented Institutional Review Board Policy has been obtained and filed for publication of this case report.

Address for Correspondence: Samuel Burleson, MD, University of Alabama at Birmingham, Department of Emergency Medicine, Old Hillman Building Suite 251, 619 19th St. S, Birmingham, AL 35249. Email: slburleson@uabmc.edu.

Conflicts of Interest: By the CPC-EM article submission agreement, all authors are required to disclose all affiliations, funding sources and financial or management relationships that could be perceived as potential sources of bias. The authors disclosed none.

Copyright: © 2020 Ostby et al. This is an open access article distributed in accordance with the terms of the Creative Commons Attribution (CC BY 4.0) License. See: <http://creativecommons.org/licenses/by/4.0/>

REFERENCES

1. Liu FW, Cripe J, Tewari KS. Anti-angiogenesis therapy in gynecologic malignancies. *Oncology (Williston Park)*. 2015;29;350-60.
2. Badgwell BD, Camp ER, Feig B, et al. Management of bevacizumab-associated bowel perforation: a case series and review of the literature. *Ann Oncol* 2007. 19;577-82.
3. Bamias A, Gibbs E, Khoon Lee C, et al. Bevacizumab with or after chemotherapy for platinum-resistant recurrent ovarian cancer: exploratory analyses of the AURELIA trial. *Ann Oncol*. 2017;28;1842-8.
4. Han E and Monk B. What is the risk of bowel perforation associated with bevacizumab therapy in ovarian cancer? *Gynecol Oncol*. 2007;105;3-6.
5. Burger RA, Brady MF, Bookman MA, et al. Risk factors for GI adverse events in a phase III randomized trial of bevacizumab in first-line therapy of advanced ovarian cancer: a gynecologic oncology group study. *J Clin Oncol*. 2014;32;1210-7.
6. Thornton E, Howard SA, Jagannathan J, et al. Imaging features of bowel toxicities in the setting of molecular targeted therapies in cancer patients. *Br J Radiol*. 2012;85(1018):1420-6.

Ultrasonography of a Helical Left Common Carotid Artery

Bethany J. Busack, MD*

Vy Tran, MD†

Christopher D. Busack, MD‡

Christine J. Butts, MD*

*Louisiana State University Health Sciences Center, Department of Emergency Medicine, New Orleans, Louisiana

†Ochsner Clinic Foundation, Department of Anesthesiology, New Orleans, Louisiana

‡Tulane University School of Medicine, Department of Anesthesiology, New Orleans, Louisiana

Section Editors: Scott Goldstein, MD

Submission history: Submitted December 27, 2019; Revision received February 18, 2020; Accepted February 18, 2020

Electronically published April 23, 2020

Full text available through open access at http://escholarship.org/uc/uciem_cpccem

DOI: 10.5811/cpcem.2020.2.46272

Case Presentation: An 83-year-old woman was admitted to the intensive care unit for septic shock at which point an internal jugular central venous line was placed. The patient's common carotid artery was visualized in an atypical location, lateral to the internal jugular vein. Further inspection revealed the common carotid artery travelling in a rotational trajectory around the internal jugular vein.

Discussion: For at least two decades, point-of-care ultrasound has become the standard of care for placing central venous lines. This surprising anatomical orientation is rare and cautions physicians to fully explore a patient's anatomy prior to placing central lines. [Clin Pract Cases Emerg Med. 2020;4(2):230–231.]

Keywords: *Ultrasound; central venous access; internal jugular vein; anatomy.*

CASE PRESENTATION

An 83-year-old woman was admitted to the intensive care unit for septic shock. During central venous catheter placement, ultrasonography was used to guide insertion. When the probe was placed on the left side of the neck in a neutral position, the internal jugular vein (IJV) was noted to be medial to the common carotid artery (CCA) (Image, Panel A). Upon scanning caudad approximately eight centimeters, the CCA coursed medially in a rotational trajectory nearly 180 degrees (Video) ending up in its typical orientation, medial to the IJV (Image, Panel B and C).

DISCUSSION

The variability in CCA and IJV orientation has been studied with multiple imaging modalities. In a series of 188 patients undergoing ultrasonography, only one patient demonstrated an IJV in the medial position.¹ Rotation of the CCA and IJV has not been described to our knowledge. However, one case report describes a duplicated IJV, with the medial branch crossing the CCA.² A magnetic resonance angiography study found increasing age to be positively correlated with vessel tortuosity.³ Although it did not comment

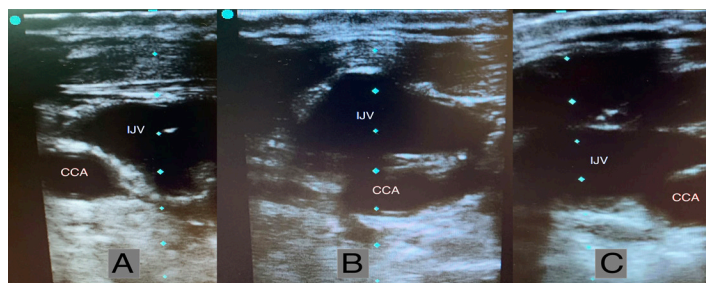


Image. (A) Ultrasonography of patient's left neck in a neutral position showing the common carotid artery (CCA) lateral to the internal jugular vein (IJV), (B) coursing posteriorly as it travels caudad in a rotational trajectory, and (C) ultimately reaching its typical orientation medial to the IJV.

on position of the CCA in reference to the IJV, this study suggests that the anatomy of the carotid artery in an elderly patient, such as the patient in this case, may not follow the typical configuration. Delineating the full extent of the patient's particular anatomy prior to needle insertion, perhaps

particularly in older patients, helps to avoid inadvertent arterial puncture and increase successful venipuncture. Additional parameters, such as vessel compressibility and wall thickness, should be used in conjunction with the traditional anatomic orientation to properly identify the vein from the artery prior to cannulation.

Video. With the provider at the head of the bed with the ultrasound probe on the patients left neck, we initially see the common carotid lateral to the internal jugular vein. Sliding the probe caudad, the artery dives in a spiral trajectory posterior to the vein, ultimately reaching its typical orientation medial to the vein just above the clavicle.

Documented patient informed consent has been obtained and filed for publication of this case report.

Address for Correspondence: Bethany Busack, MD, Louisiana State University Health Science Center, Department of Emergency Medicine, 1201 Canal St, #359, New Orleans, LA 70112. Email: bbusac@lsuhsc.edu.

Conflicts of Interest: By the CPC-EM article submission agreement, all authors are required to disclose all affiliations, funding sources and financial or management relationships that could be perceived as potential sources of bias. The authors disclosed none.

Copyright: © 2020 Busack et al. This is an open access article distributed in accordance with the terms of the Creative Commons Attribution (CC BY 4.0) License. See: <http://creativecommons.org/licenses/by/4.0/>

CPC-EM Capsule

What do we already know about this clinical entity?

The anatomic location of the common carotid artery is typically medial to the internal jugular vein, however may lie posteriorly, anteriorly, or rarely laterally.

What is the major impact of the image(s)?

The image reiterates the importance of using multiple modalities, rather than location alone, to ensure proper identification of the internal jugular vein prior to cannulation.

How might this improve emergency medicine practice?

The image encourages physicians to fully scan the neck prior to venous cannulation in order to identify the correct vessel and delineate atypical venous anatomy.

REFERENCES

1. Turba UC, Uflacker R, Hannegan C, et al. Anatomic relationship of the internal jugular vein and the common carotid artery applied to percutaneous transjugular procedures. *Cardiovasc Intervent Radiol.* 2005;28(3):303-6.
2. Kenji Kayashima, Ryo Fukui, Keiko Imai, et al. Ultrasonographic images of internal jugular vein duplication. *Anesthesiology.* 2016;124(4):958.
3. Jeon SJ, Kwak HS, Chung GH. Widening and rotation of carotid artery with age: geometric approach. *J Stroke Cerebrovasc Dis.* 2018;27(4):865-70.

55 year-old Female with Hematuria

Drew A. Long, MD
Brit Long, MD

San Antonio Military Medical Center, Department of Emergency Medicine, Fort Sam Houston, Texas

Section Editors: Scott Goldstein, MD

Submission history: Submitted December 20, 2019; Revision received February 23, 2020; Accepted February 28, 2020

Electronically published April 23, 2020

Full text available through open access at http://escholarship.org/uc/uciem_cpccem

DOI: 10.5811/cpcem.2020.2.46271

Case Presentation: A 55 year-old female presented to the emergency department with left sided abdominal pain and hematuria. Computed tomography scan of her abdomen and pelvis demonstrated a large left renal mass with extension into the left ureter, left renal vein, and inferior vena cava. She was admitted and treated for presumed renal cell carcinoma (RCC).

Discussion: RCC may present with abdominal or flank pain and hematuria, but more commonly presents with vague symptoms. RCC should be suspected in a patient presenting with hematuria and abdominal or flank pain, especially if vague symptoms such as fatigue or anorexia are also present. [Clin Pract Cases Emerg Med. 2020;4(2):232–233.]

Keywords: *hematuria; flank pain; renal cell carcinoma.*

CASE PRESENTATION

A 55 year-old female with a history of lymphoma, paroxysmal nocturnal hematuria, and undifferentiated renal masses presented to the Emergency Department with left sided abdominal and flank pain, fatigue, and hematuria. Abdominal examination demonstrated mild left upper quadrant tenderness. Complete blood count revealed a hemoglobin of 6.6 grams per deciliter and platelet count of 5,000 per microliter. Urinalysis demonstrated large (3+) blood and >182 red blood cells per high-powered field. Computed Tomography (CT) scan with intravenous (IV) contrast of her abdomen and pelvis was obtained (Image).

DISCUSSION

CT scan was notable for an 8.2- centimeter necrotic mass in the left kidney with extension into the left renal vein, inferior vena cava (IVC), and left ureter. The patient was admitted to the hospital and transfused with 2 units of packed red blood cells and 1 unit of platelets. Oncology and urology services were concerned for renal cell carcinoma (RCC). The patient was scheduled for outpatient palliative radiation therapy and started on rituximab and eculizumab.

RCC is the most common type of kidney cancer in adults, responsible for 90-95% of cases.¹ The classic triad of hematuria, flank pain, and a palpable flank mass occurs in 5-10% of cases.²

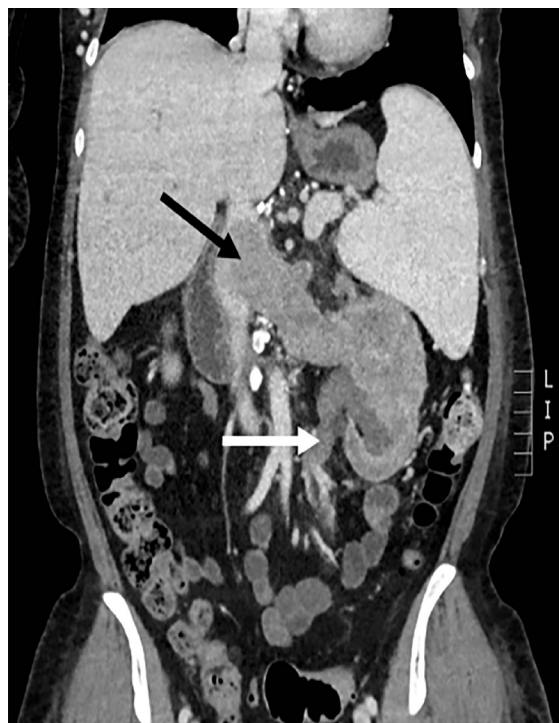

Image. Coronal view of Computed Tomography of abdomen/pelvis with intravenous contrast demonstrating a necrotic mass in the left kidney with extension into the inferior vena cava (black arrow) and ureter (white arrow).

When present, this triad indicates a more advanced stage of the disease. More commonly, patients with RCC present with nonspecific symptoms such as fatigue, anorexia, weight loss, or fever of unknown origin.³

It is estimated that RCC invades the IVC and forms a venous tumor thrombosis in up to 10% of cases,⁴ as seen in the presented patient. CT scan with IV contrast is highly sensitive for detecting both RCC and invasion into either the ureter or IVC.⁵ The Emergency Physician must consider this diagnosis in a patient with hematuria, especially in the setting of abdominal or flank pain, fatigue, anorexia, or weight loss.

The authors attest that their institution requires neither Institutional Review Board approval, nor patient consent for publication of this case report. Documentation on file.

Address for Correspondence: Drew Long, MD, San Antonio Military Medical Center, Department of Emergency Medicine, 3551 Roger Brooke Dr., Fort Sam Houston, TX 78234. Email: drewlong22@yahoo.com.

Conflicts of Interest: By the CPC-EM article submission agreement, all authors are required to disclose all affiliations, funding sources and financial or management relationships that could be perceived as potential sources of bias. The authors disclosed none. This review does not reflect the views or opinions of the U.S. government, Department of Defense or its Components, U.S. Army, U.S. Air Force, or SAUSHEC EM Residency Program.

Copyright: © 2020 Long et al. This is an open access article distributed in accordance with the terms of the Creative Commons Attribution (CC BY 4.0) License. See: <http://creativecommons.org/licenses/by/4.0/>

REFERENCES

1. Cheville JC, Lohse CM, Zincke H, et al. Comparisons of outcome and prognostic features among histologic subtypes of renal cell

CPC-EM Capsule

What do we already know about this clinical entity?
Renal cell carcinoma (RCC) is the most common type of kidney cancer in adults. It may present with hematuria or flank pain, but more commonly presents with vague symptoms.

What is the major impact of the image(s)?
This image depicts RCC invading surrounding anatomic structures, leading to the clinical manifestation of hematuria.

How might this improve emergency medicine practice?
Emergency clinicians must suspect this diagnosis in adult patients with vague symptoms, especially if they have hematuria or flank pain.

carcinoma. *Am J Surg Pathol.* 2003;27(5):612-24.

2. Luciani LG, Cestari R, Tallarigo C. Incidental renal cell carcinoma—age and stage characterization and clinical implications: study of 1092 patients (1982–1997). *Urology.* 2000;56(1):58-62.
3. Choyke PL, Amis ES, Jr, Bigongiari LR, et al. Renal cell carcinoma staging. ACR appropriateness criteria. *Radiology.* 2000;215(Suppl):721-5.
4. Marshall VF, Middleton RG, Holswade GR, et al. Surgery for renal cell carcinoma in the vena cava. *J Urol.* 1970;103:414-20.
5. Lawrentschuk N, Gani J, Riordan R, et al. Multidetector computed tomography vs magnetic resonance imaging for defining the upper limit of tumour thrombus in renal cell carcinoma: a study and review. *BJU Int.* 2005;96(3):291-5.

A 45-year-old Female with an Atypical Presentation of Pharyngitis

Artur Schander, DO, PhD, MS*

Andrew A. Glickman, DO, MS†

Nancy Weber, DO, MS, MBA‡§

Brian Rodgers, MD**

Michael B. Carney, DO††

*Sacred Heart Hospital, Department of Emergency Medicine, Pensacola, Florida

†HCA/USF Morsani College of Medicine GME Consortium: Brandon Regional Hospital, Department of Emergency Medicine, Brandon, Florida

‡Texas Tech University Health Sciences Center, Department of Emergency Medicine, El Paso, Texas

§Paul L. Foster School of Medicine, Department of Emergency Medicine, El Paso, Texas

**Dallas Ear Institute, Dallas, Texas

††Reynold's Memorial Hospital, Department of Emergency Medicine, Glen Dale, West Virginia

Section Editors: John Ashurst, DO

Submission history: Submitted February 15, 2020; Revision received none; Accepted February 22, 2020

Electronically published April 27, 2020

Full text available through open access at http://escholarship.org/uc/uciem_cpem

DOI: 10.5811/cpem.2020.2.46974

Introduction: Emergency physicians are trained to treat a variety of ailments in the emergency department (ED), some of which are emergent, while others are not. A common complaint seen in the ED is a sore throat. While most sore throats are easily diagnosed and treated, less common causes are often not considered in the differential diagnoses. Therefore, the purpose of this case study was to present an atypical case of sore throat and discuss differential diagnoses.

Case Presentation: The patient was a 45-year-old female who presented to the ED with a three-day history of sore throat that was exacerbated by eating and drinking. The patient was not on any prescription medications, but tried over-the-counter medications for the sore throat without any improvement in symptoms. Review of systems was positive for sore throat, fevers, and chills. Physical examination of her oropharynx revealed mildly dry mucous membranes with confluent plaques and white patchy ulcerative appearance involving the tongue, tonsils, hard palate, and soft palate. Rapid streptococcal antigen, mononucleosis spot test, and KOH test were performed and found to be negative.

Discussion: After initial testing was negative, a follow-up complete blood count with differential and complete metabolic profile were ordered. The patient was found to have decreased lymphocytes and platelets. Based upon those results, a diagnosis was made in the ED, the patient was started on medication, and further laboratory workup was ordered to confirm the diagnosis. ED providers should consider non-infectious as well as infectious causes for a sore throat, as this might lead to a diagnosis of an underlying condition. [Clin Pract Cases Emerg Med. 2020;4(2):234–240.]

Keywords: HIV; AIDS; oral hairy leukoplakia; oral lesion.

CASE PRESENTATION

A 45-year-old African-American female presented to the emergency department (ED) of a rural, academic medical center with a three-day history of “sore throat.” The patient rated her pain as a 7/10 and described the pain as a “burning pain and a

raw sensation,” which was exacerbated by eating and drinking. She stated that she had tried over-the-counter (OTC) ibuprofen, lozenges, and oral benzocaine throat spray without any improvement in her symptoms. The patient admitted to a past medical history of hypertension, gastroesophageal reflux disease

(GERD), depression, and bipolar disorder. However, she denied taking any medications for her medical conditions. She admitted to a one-pack-per-day smoking history and occasional alcohol use, but denied illicit drug use, specifically intravenous drug use (IVDU). The patient informed the practitioners that she had recently moved to the area; therefore she did not have a primary care physician, hence coming to the ED.

A review of her systems was negative for nausea, vomiting, diarrhea, shortness of breath (SOB), pain while taking a breath, cough, chest pain (CP), and skin lesions. She also denied any muscular pain, muscular weakness, or joint pain. The patient also denied any vaginal ulcerations or vaginal discharge. She did, however, admit to fevers and chills, and stated that the highest recorded temperature at home was 39.2°C. Vital signs upon presentation were as follows: temperature 38.1°C; blood pressure 108/73 millimeters of mercury; pulse 108 beats per minute; respiratory rate 16 breaths per minute, and oxygen saturation 99% on room air.

Physical examination revealed an African-American female sitting comfortably on the stretcher in no apparent respiratory distress. The patient appeared non-toxic, and conversation revealed no evidence of hoarse or muffled speech. A focused head, eyes, ears, nose, and throat exam revealed no oropharyngeal masses or uvular deviation, and no submental induration or tenderness were appreciated on examination. A bluish discoloration was appreciated on the tongue, but the patient admitted to using lozenges just prior to examination.

A focused examination of her oropharynx demonstrated mildly dry mucous membranes with confluent plaques and a white, patchy, ulcerative appearance of the uvula, tonsils, tonsillar pillars, hard palate, anterior one-third of the soft palate, and the side of her tongue (Images 1 and 2).

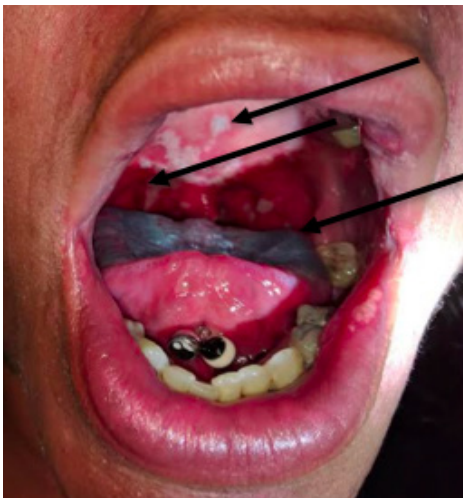

Image 1. Raised corrugated plaques that could not be scraped off on exam, located on the oropharynx, soft palate, hard palate, and the side of her tongue.

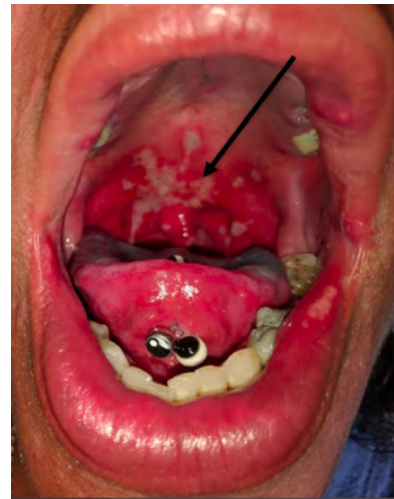

Image 2. White, confluent, fluffy, hyperkeratotic lesions in a patient presenting with complaint of sore throat.

Given the patient's pyrexia and symptomology, rapid streptococcal antigen and a mononucleosis spot (Monospot) test were obtained. The results for the Monospot test and rapid group A strep antigen screen were negative. KOH testing was performed on the posterior pharyngeal lesion for a possible fungal etiology and was found to be negative. Given the negative test results and appearance of the lesion, the patient was interviewed again. We specifically inquired about high-risk sexual behavior, IVDU, and using immunosuppressive medication, all of which the patient denied. She was then offered basic lab work consisting of a complete blood count (CBC) with differential and complete metabolic profile (CMP) (Table 1).

Based upon those results, a diagnosis was made in the ED, the patient was started on medications, and further laboratory work was ordered to confirm the diagnosis.

CASE DISCUSSION

This 45-year-old African-American patient presented with a history of increasing sore throat over the course of three days, which was not relieved with OTC medications. The patient's odynophagia led to decreased oral intake, which was accompanied by fevers and chills over those same three days. Causes for pharyngitis can be broadly placed into two categories: infectious and non-infectious causes.

Non-Infectious

I initially considered non-infectious causes; however, as this was a clinicopathological case, I wanted to expand my differential diagnosis, and I felt those could be quickly excluded given her history and presentation (H&P) and the fact that the patient had a fever. A drug-induced presentation such as dental decay secondary to

Table 1. Complete blood count with differential and complete metabolic panel.

Complete blood count		Reference range
WBC	4.6	4.5-11.0 x 10 ⁹ /L
RBC	4.03 L	4.20-5.40 x10 ¹² cell/ L
Hgb	14.4	12.0-16.0 g/L
Hct	40.0	37-47%
MCV	99.3	81-101 fL
MCH	35.8 H	26-34 pg
MCHC	36.0	32-36 g/L
RDW	11.7	11.5-14.5%
Pit Count	117 L	130-400 x 10 ⁹ /L
Granulocyte	88.2 H	42.2-75.2 %
Lymphocytes	7.6 L	20.5-51.1 %
Monocytes	3.8	1.7-9.3 %
Eosinophils	0.1	0-5 %
Basophils	0.3	0-3 %
Absolute Granulocytes	4.0	1.4-6.5 x 10 ⁹ /L
Absolute Lymphocytes	0.3	1.2-3.4 x 10 ⁹ /L
Absolute Monocytes	0.17	0.0-0.82 x 10 ⁹ /L
Absolute Eosinophils	0.0	0.0-0.52 x 10 ⁹ /L
Absolute Basophils	0.01	0.0-0.2 x 10 ⁹ /L
Complete metabolic panel		
Sodium	138	137-145 mmol/L
Potassium	3.7	3.5-5.2 mmol/L
Chloride	99	98-107 mmol/L
Carbon dioxide	30	22-30 mmol/L
Anion gap	9	3 and 10 mEq/L
BUN	11	7-17 mg/dL
Creatinine	0.71	0.52-1.04 mg/dL
BUN/CR ratio	15.5	10-20
Calculated osmolality	262 L	275-295 mOsm
Glucose	85	74-106 mg/dL
Calcium	8.5	8.4-10.2 mg/dL
T. Bilirubin	0.7	0.2-1.3 mg/dL
AST	24	14-36 U/L
ALT	18	9-52 U/L
Alkaline Phosphate	95	38-126 U/L
Albumin	3.3 L	3.5-5.5 g/dL

WBC, white blood cell count; RBC, red blood cell count; Hgb, hemoglobin; Hct, hematocrit; MCV, mean corpuscular volume; fL, femtoliter; MCH, mean corpuscular hemoglobin; pg, picogram; MCHC, mean corpuscular hemoglobin concentration; RDW, red cell distribution width; Pit, platelet count; BUN, blood urea nitrogen, CR, creatinine; mOsm, milliosmole; T, total; AST, aspartate aminotransferase; ALT, alanine aminotransferase; mmol, millimole; mg, milligrams; dL, deciliter; U, units; L, liter; g, grams.

methamphetamine use was quickly excluded, as this mostly involves the teeth. I briefly considered ingestion of a foreign body, caustic or alkaline burns, and thermal burns, but this was quickly ruled out as this was not consistent with her H&P and by the fact that she had white plaques on examination. Stevens-Johnson syndrome and fixed drug reactions do have oral involvement, but can be quickly ruled out as there were no skin rashes on this patient.

I next turned my attention to autoimmune disorders, which can have oral involvement, and I considered serositis, myositis, and Sweet's syndrome, but I quickly dismissed these diagnoses as the patient did not have systemic symptoms seen with these disorders. Specifically, she had denied the following: a) SOB, CP, and abdominal pain (serositis); b) muscular pain or weakness (polymyositis, dermatomyositis); and c) skin rash (dermatomyositis, Sweet's syndrome).

The final causes I considered in the non-infectious category were neoplastic causes. Leukemia can present with thrush, but I quickly ruled this out, as this patient had a normal total white blood cell count, no systemic symptoms, and the scrapings of the oropharyngeal lesions had yielded a negative KOH preparation. The patient did admit to a history of smoking and, therefore, I strongly considered oropharyngeal cancer. While this diagnosis remained high on my differential diagnosis, I felt that the precipitous onset of symptoms in addition to the fever made this diagnosis less likely than an infectious cause and, therefore, I turned my attention to infectious causes.

Infectious Causes

The most common causes for pharyngitis are of viral etiology, including infections due to rhinovirus, adenovirus, coxsackie, influenza, and Epstein-Barr virus (EBV). Considering the patient's age and the extensive involvement of the lesions (Images 1 and 2), a simple viral infection was less likely. However, an infection with EBV causing mononucleosis should remain on the differential, keeping in mind that the heterophile test (Monospot test) can take over one week until it turns positive and in this case the patient's symptoms have been present for only three days. However, mononucleosis often presents with monocytosis, which was not the case with this patient (Table 1), making mononucleosis a less likely diagnosis.

Bacterial causes of pharyngitis are very common, with the most common pathogen being *Streptococcus pyogenes*, aka group A beta-hemolytic streptococcal infection (GABHS), which can ultimately lead to rheumatic fever. However, considering the patient's age, the negative rapid group A strep antigen screen, and the extensive involvement of the lesions, especially the hard palate and tongue, make a bacterial etiology unlikely. Further, the Centor Score on this patient was found to be only 2, giving the patient a low risk of 11-17% of GABHS.

Sore throat and odynophagia can also be a presentation of bacterial infection leading to a peritonsillar abscess, infection of the floor of the mouth such as Ludwig's angina, or infection

of the retropharyngeal or submandibular spaces. On physical examination, the patient did not have uvular deviation, tongue elevation, or signs of airway compromise, such as stridor, drooling, inability to tolerate secretions, muffled voice, or hypoxia, making these diagnoses less likely. These physical findings, in addition to the fact that the patient was up to date on her immunizations, made diagnoses such as epiglottitis, bacterial tracheitis, and diphtheria also less likely.

Another rare presentation to consider in this patient would be Lemierre's syndrome, which is also known as infectious thrombophlebitis of the internal jugular vein caused by *Fusobacterium necrophorum*. In general, this disease is associated with lethargy, swollen lymph nodes, and a prolonged disease course leading to sepsis. This patient did not have any lymphadenopathy and while tachycardic with a mild fever, did not appear septic. Since this was a clinicopathology case, there was likely nothing common about it, and therefore the zebras had to be considered. It is unclear in this case whether recent orogenital contact exposure had occurred; therefore, I added gonococcal and herpes simplex virus (HSV) pharyngitis to the differential diagnosis.

At this point in time, I had almost ruled out the majority of my working differential diagnosis while a possibility for mononucleosis, oropharyngeal cancer, and possible gonococcal or HSV pharyngitis persisted, which led me to question what I was missing and if there were any further clues from this patient. The patient is a smoker, which increased the risk of oral or systemic cancers, but she denied IVD and alcohol use. She also denied risky sexual behavior and any current prescription medications or being immunosuppressed, thus making many of the above "less common causes" less likely.

In addition, while the patient denied using any prescription medications, I was wondering if there was a component of medication non-compliance that could point us in the right direction. Upon further exploration, I learned the patient had a history of bipolar disorder, depression, hypertension, GERD, and had no primary care physician, meaning she had no regular screenings or check-ups. These together call into question the reliability of the history of present illness (HPI), and whether she might have a higher risk of any type of infectious, immunosuppression, precancerous, or cancerous process. However, since I was unable to further derive much information from her HPI, I next focused on the laboratory results. The patient was found to have a normal absolute WBC cell count. Interestingly, the differential of the CBC results revealed lymphopenia with a lymphocyte percentage of 7.6%, which raised concern for immunosuppression given that the normal percent of lymphocyte count for an adult female CBC should fall in the range of 20-51% (Table 1). Further, while the normal absolute lymphocyte cell count in a healthy adult should be approximately $1.2-3.4 \times 10^9/L$, the absolute lymphocyte count

result in this case was $0.3 \times 10^9/L$ (Table 1). Furthermore, her low platelet counts of $117 \times 10^9/L$ (normal: $130-400 \times 10^9/L$) sparked my interest. It is well known that thrombocytopenia is very common in patients with human immunodeficiency virus (HIV) and acquired immune deficiency syndrome (AIDS) and is often associated with disease progression.¹

In conclusion, after pulling together the HPI, social history, patient's fever, and physical exam findings, along with the finding of lymphopenia and thrombocytopenia, I was convinced that these were consistent with HIV/AIDS defining illness, likely HIV oral lesions (HIV-OL), specifically oral hairy leukoplakia (OHL).

CASE OUTCOME

The patient was clinically diagnosed with OHL, and discharged with a prescription for high-dose acyclovir. The patient was informed that we suspected immunosuppression to be the cause of her lesions and further laboratory workup was ordered and sent for serological and immunological analysis. The earlier suspicion of HIV infection was confirmed a few days later, when infectious disease (ID) serologies detected HIV-1 RNA with a HIV-1 viral load totaling 192,000 copies/mL. Further, the patient was found to have reactive hepatitis-C antibodies (Table 2). The patient was also tested for syphilis, chlamydia, gonorrhea, and hepatitis A and B, all of which were found to be negative (Table 2).

The patient was contacted immediately and was referred to the local ID physician for further evaluation and treatment. She was started on antiretroviral therapy (ART). Further follow-up showed that the patient's symptoms resolved after she was started on STRIBILD (elvitegravir/cobicistat/emtricitabine/tenofovir) and that she continued to follow up with the ID physician. Five months after the patient was started on STRIBILD, her absolute CD4 count had improved from her initial count of 192 cells/mm³ to 1029 cells/mm³. Her HIV-1 viral load had declined at that point in time to 131,000 copies/mL.

RESIDENT DISCUSSION

Chief complaint of pharyngitis, or sore throat, represents one of the most common reasons for ED visits and accounts for a total of 2.6 million ED visits annually.² The patient's complaint is often manifested as a constellation of symptoms consisting of throat pain exacerbated by swallowing, which may or may not radiate to the ears and neck, prompting patients to present to the ED for evaluation. Various subtypes of pharyngitis are more prevalent among different patient populations. Swelling, erythema with or without exudate, and inflammation involving the soft tissues of the oropharynx are the causes for the clinical symptoms of pharyngitis, but any involvement of the anatomic structures in the hypopharynx or nasopharynx can also lead to a sore throat.³

Acute pharyngitis has a wide range of pathological etiologies, thus emergency physicians should consider a broad

Table 2. Infectious disease serology and immunology of patient with suspected immunosuppression.

Test	Result	Reference range
Treponema pallidum Ab	Nonreactive	Nonreactive
<i>C. trachomatis</i> RNA	Not Detected	Not detected
Cryptococcus Ag Screen	Not Detected	Not detected
Hepatitis A IgM Ab	Nonreactive	Nonreactive
Hepatitis B Antigen	Nonreactive	Nonreactive
Hepatitis B Core IgM Ab	Nonreactive	Nonreactive
Hepatitis C Antibody	Reactive H	Nonreactive
HIV-1 RNA log copies/mL	5.28 H	1.30-7.00 log copies/mL*
HIV- RNA PCR copies/mL	192000 H	20-10,000 copies/mL*
HIV Genotype	Detected	Not detected
HIV-2 Antibody Conf	Negative	Negative
Infectious Mono Assay	Negative	Negative
<i>N. Gonorrhoeae</i> RNA	Not Detected	Not detected
Absolute CD4 Count	192 L	600-1,200 cell/mm ³
HLA-B57.01	Negative	Negative

*Assay quantification result range.

C, chlamydia; *RNA*, ribonucleic acid; *H*, high; *L*, low; *HIV*, human immunodeficiency virus; *PCR*, polymerase chain reaction; *mono*, mononucleosis; *N*, Neisseria.

differential when encountering a patient with pharyngitis, especially if the H&P does not fit the presenting clinical picture. While some physicians choose to empirically treat pharyngitis with antibiotics, other emergency physicians use a variety of scoring systems to differentiate between viral, fungal, and bacterial etiology. A common decision tool used in the ED is the Centor Score decision tool to guide the diagnosis and treatment of GABHS. Most patients presenting to the ED with a sore throat will be diagnosed with uncomplicated infectious pharyngitis with a benign disease course. However, there is a small subset of patients who either present with an atypical presentation of pharyngitis or have a suspicious past medical history, which must prompt the practitioner to expand his or her differential diagnosis and diagnostic approach. One such subset is comprised of immunocompromised patients who can present with a variety of oral lesions. Unfortunately, in developed countries, and in the era of ART, physicians often do not consider differential diagnoses for oral lesions where undiagnosed HIV infection could be the underlying cause for such lesions.

Worldwide, infection with HIV is the most common cause leading to an immunocompromised physical state in patients and it presents a major global health issue. The prevalence of HIV-infected people worldwide in 2018 was estimated to be 37.9 million with an incidence rate of 1.7 million.⁴ In the

United States, the prevalence is estimated to be 1.1 million with an incidence rate of ~40,000 people.⁵ In 2018, only 23.3 million infected individuals had access to ART worldwide, and the death toll secondary to AIDS-related illnesses was estimated to be 770,000 people.⁴ Further, it is estimated that 21% of all people worldwide and 14% of people in the US living with HIV do not know their HIV status and do not receive any treatment.⁴

The World Health Organization published a classification for HIV-OL, which has been the mainstay of defining lesions that are commonly observed in patients with HIV. The classification system separates HIV-OL into three categories: 1) oral lesions strongly associated with HIV-infection; 2) lesions less commonly associated with HIV infection; and 3) lesions directly observed in HIV infection.⁶ Oral candidiasis (OC) and OHL are the two most prevalent HIV-OL lesions that are observed in the group of oral lesions strongly associated with HIV infection.⁶ This was validated in a study that assessed oral lesions in ART naïve patients and found that OC followed by OHL have the highest incidence of HIV-OL.⁷ It is known that certain HIV-OL observed in patients with diagnosed or undiagnosed HIV have a positive correlation predicting the progression to AIDS.⁸⁻¹⁰

OHL is a clinical presentation that is found almost exclusively in untreated patients with advanced HIV. Further, OHL is the result of an acute EBV infection or reactivation of a latent EBV infection and results from an impaired oral mucosal cell-mediated immunity.^{11,12} This malfunction of oral mucosal immunity is believed to be multifactorial. It has been reported that the HIV virus indirectly impairs nitric oxide and lysozymes production and IgA synthesis and secretion by the oral mucosa that normally function as bactericidal, fungicidal, and viricidal agents leading to OHL.¹² Most recently, it has been suggested that HIV impairs the oral mucosal barrier in addition to suppressing CD4+ T cells by also suppressing the Th17 T-cells, which secrete IL-17 and IL-23 cytokines, which further weakens the oral mucosal immunity and predisposes it to opportunistic infections.^{12,13}

Grossly, OHL appears as white, patchy, raised, corrugated tissue overgrowth present on the lateral surfaces of the tongue, hard palate, and oropharynx, and the projected material present on the surface contributes to the “hairy” appearance.^{14,15} The visualized lesions are more common on the tongue, and are often more prevalent in males as compared to females.¹⁶ Pathognomonically, these lesions are unable to be scraped away during examination, which is often useful in separating it from OC.^{14,15} Microscopically and histologically, OHL is characterized by a benign stratified squamous epithelial hyperplasia with characteristic pallor.^{14,15} While OHL is considered a “benign” oral manifestation of HIV infection, it is of the utmost importance to diagnose this lesion due to the fact that it can represent the first physical sign of significant immunosuppression in HIV-infected patients. Clinical

appearance alone is often sufficient for diagnosis. However, if confirmation is required, liquid-based cytology with in situ hybridization for EBV can be used for diagnosis and is a simple, noninvasive tool that is equivalent to traditional punch biopsy of the lesion.¹⁷ OHL usually resolves after the patient is started on ART therapy, but some clinicians have advocated starting a patient on acyclovir or valacyclovir upon diagnosis OHL, especially if the patient is symptomatic.^{10,15}

HIV viral load has been shown to have a positive correlation to the development of oral lesions, as a viral load of 30,000 copies/mm³ exhibited oral lesions related with HIV, independent of a patient's total CD4 cell count.¹⁸ Commonly, the median CD4+ count when OHL is first visualized by practitioners ranges between 235-468 cell/mm³.^{2,9} Oral lesions are generally an early sign of HIV infection, but could also be used to predict the clinical manifestations and progression of HIV/AIDS infections in patients.⁴ Literature demonstrates an inverse relationship between the development of OHL and declining CD4 + counts and it has been shown that HIV infection with OHL often progresses to AIDS with CD4 counts of less than 200 cell/mm³.^{5,10} Further elucidating the inverse relationship between the presence of OHL and declining CD4+ counts, one study found that "the probability of developing AIDS at the time of HIV diagnosis with the presence of OHL when not receiving ART is 48% by 16 months and 83% at 31 months, respectively."^{13,18}

While some oral lesions observed with OHL have historically been identified as an "AIDS defining illness," it should be noted that in recent years patients have presented with OHL and other oral lesions who were not infected with HIV.¹⁵ Patients with immunosuppression secondary to various etiologies, such as solid organ transplant on maintenance anti-rejection medications, chronic steroids use, or hematologic malignancies, have all presented clinically with OHL.^{7,15} This case report demonstrates that atypical pharyngeal lesions should prompt the treating physician to consider immunosuppression as a possible etiology. It is noteworthy to add that some emergency physicians have been hesitant in the past to perform HIV testing in the ED for various reasons including difficulty following up on results, inability to counsel patient on results, and lack of access to follow-up.¹⁹⁻²² The authors disagree with this notion and, as is demonstrated in this case, it is the duty of the emergency physician to order testing so that an appropriate diagnosis and treatment referral can be given to the patient.

In 2006 the CDC updated the HIV testing guidelines to include testing all patients who present to healthcare facilities with concern for possible infection, including the ED.¹⁹⁻²² It is recommended that counseling should be provided to the patient prior to HIV testing, and also after testing, if the results are in fact positive.¹⁹⁻²² A cross-sectional analysis using data from two large national healthcare surveys from the years 2009-2014 was performed and found that HIV testing in EDs was nationally low, despite the

updated CDC recommendation in 2006.²⁰ The conclusion reached by the authors is that testing for HIV should be performed in the ED, especially in patients who solely rely on ED visits for their healthcare.²⁰ In conclusion, emergency physicians must be reminded that HIV-OL may present in the ED setting and physicians should consider serological testing while in the ED so that the appropriate follow-up and treatment for the patient can be initiated.

FINAL DIAGNOSIS

Oral hairy leukoplakia, presenting as an AIDS defining illness. Reactive hepatitis C antibody, indicating current or prior hepatitis C infection.

KEY TEACHING POINTS

- Pharyngitis is common in the emergency department (ED), accounting for 2.6 million visits annually, and is most often caused by viral, bacterial, and fungal pathogens.
- Atypical presentations of pharyngitis should prompt the ED provider to expand their differential diagnosis, especially if there are concerns for possible immunosuppression.
- Oral hairy leukoplakia (OHL) is the second most prevalent HIV defining oral lesion, after candida.
- OHL is typically a white, patchy area on oral mucosa that is unable to be scraped off, and may have pedunculated tissue, hence the "hairy" descriptor.
- OHL has historically been an "AIDS defining illness," but can also be seen with solid organ transplant immunosuppression, chronic steroid use, or hematologic malignancies.

Documented patient informed consent and/or Institutional Review Board approval has been obtained and filed for publication of this case report.

Address for Correspondence: Artur Schander, DO, Sacred Heart Hospital, Department of Emergency Medicine, 5151 North 9th Ave, Pensacola, FL 32504. Email: aschande@live.unthsc.edu.

Conflicts of Interest: By the *CPC-EM* article submission agreement, all authors are required to disclose all affiliations, funding sources and financial or management relationships that could be perceived as potential sources of bias. The authors disclosed none.

Copyright: © 2020 Schander et al. This is an open access article distributed in accordance with the terms of the Creative Commons Attribution ([CC BY 4.0](http://creativecommons.org/licenses/by/4.0/)) License. See: <http://creativecommons.org/licenses/by/4.0/>

REFERENCES

1. Metcalf Pate KA and Mankowski JL. HIV and SIV associated thrombocytopenia: an expanding role for platelets in the pathogenesis of HIV. *Drug Discov Today Dis Mech.* 2011;8(1-2):e25-32.
2. Centers for Disease Control and Prevention. Ambulatory and Hospital Care Statistics. National Hospital Ambulatory Medical Care Survey. Available at: https://www.cdc.gov/nchs/data/ahcd/nhamcs_factsheet_ed_2009.pdf. Accessed February 16, 2019.
3. Weber R. Pharyngitis. *Prim Care.* 2014;41(1):91-8.
4. UNAIDS. Global HIV and AIDS statistics-2019 fact sheet. 2019. Available at: https://www.unaids.org/sites/default/files/media_asset/UNAIDS_FactSheet_en.pdf. Accessed August 16, 2019.
5. Centers for Disease Control and Prevention. HIV Surveillance Report: Diagnoses of HIV Infection in the United States and Dependent Areas, 2017. 2018. Available at: <https://www.cdc.gov/hiv/pdf/library/reports/surveillance/cdc-hiv-surveillance-report-2017-vol-29.pdf>. Accessed August 16, 2019.
6. Williams DM. Classification and diagnostic criteria for oral lesions in HIV infection. *J Oral Pathol Med.* 1993;22(7):289-91.
7. Taiwo OO and Hassan Z. The impact of highly active antiretroviral therapy (HAART) on the clinical features of HIV-related oral lesions in Nigeria. *AIDS Res Ther.* 2010;7:19-25.
8. Kamiru HN and Naidoo S. Oral HIV lesions and oral health behaviour of HIV-positive patients attending the Queen Elizabeth II Hospital, Maseru, Lesotho. *SADJ.* 2002;57(11):479-82.
9. Frimpong P, Amponsah EK, Abebrese J, et al. Oral manifestations and their correlation to baseline CD4 count of HIV/AIDS patients in Ghana. *J Korean Assoc Oral Maxillofac Surg.* 2017;43(1):29-36.
10. Birnbaum W, Hodgson TA, Reichart PA, et al. Prognostic significance of HIV-associated oral lesions and their relation to therapy. *Oral Dis.* 2002;8(Suppl2):110-4.
11. Leao JC, Ribeiro CMB, Carvalho AAT, et al. Oral complications of HIV disease. *Clinics (Sao Paulo).* 2009;64(5):459-70.
12. Heron SE and Elahi S. HIV infection and compromised mucosal immunity: oral manifestations and systemic inflammation. *Front Immunol.* 2017;8:241.
13. Weaver CT, Hatton RD, Mangan PR, et al. IL-17 family cytokines and the expanding diversity of effector T cell lineages. *Annu Rev Immunol.* 2007;25:821-52.
14. Andarade SA and Ribeiro MM. Hairy tongue: differential diagnosis by use of widefield optical fluorescence. *Braz Dent J.* 2019;(2):191-6.
15. Greenspan JS, Greenspan D, Webster-Cyriaque J. Hairy leukoplakia; lessons learned: 30-plus years. *Oral Dis.* 2016;22(Suppl1):120-7.
16. Dongo M, Gonçalves LS, Ferreira SM, et al. Gender differences in oral manifestations among HIV-infected Brazilian adults. *Int Dent J.* 2013;63(4):189-95.
17. Braz-Silva PH, Santos RT, Schussel JL, et al. Oral hairy leukoplakia diagnosis by Epstein-Barr virus in situ hybridization in liquid-based cytology. *Cytopathology.* 2014;25(1):21-6.
18. Bravo IM, Corenti M, Escalona L, et al. Prevalence of oral lesions in HIV patients related to CD4 cell count and viral load in a Venezuelan population. *Med Oral Patol Oral Cir Bucal.* 2006;11(1):e33-9.
19. Branson BM. Expanded HIV testing in the emergency department: Implementing the CDC recommendations. Available at: <https://www.medscape.org/viewarticle/572198>. Accessed February 28, 2019.
20. Olatosi B and Siddiqi KA. Towards ending the human immunodeficiency virus epidemic in the US: state of human immunodeficiency virus screening during physician and emergency department visits, 2009 to 2014. *Medicine (Baltimore).* 2020;99(2):e18525.
21. McKenna M. HIV testing: Should the emergency department take part? *Ann Emerg Med.* 2007;49(2):190-2.
22. Haukoos JS and Hopkins E. Understanding HIV screening in the emergency department: Is perception reality? *Acad Emerg Med.* 2013;20(3):309-12.

Low Back Pain and Swelling as an Atypical Presentation of IgA Vasculitis

Clay T. Winkler, DO*
Raymond W. Dobson, BA†
Michael J. Tranovich, DO‡

*Prisma Health - University of South Carolina School of Medicine, Department of Emergency Medicine, Columbia, South Carolina

†West Virginia School of Osteopathic Medicine, Lewisburg, West Virginia

‡Ohio Valley Medical Center, Department of Emergency Medicine, Wheeling, West Virginia

Section Editor: John Ashurst, DO, MSc

Submission history: Submitted July 17, 2019; Revision received November 6, 2019; Accepted November 26, 2019

Electronically published April 14, 2020

Full text available through open access at http://escholarship.org/uc/uciem_cpccem

DOI: 10.5811/cpcem.2019.11.44574

Introduction: Immunoglobulin A vasculitis (IgA vasculitis), formerly Henoch-Schonlein purpura, is the most common vasculitis in children.

Case Report: A 6-year-old female presented with low back pain and swelling, difficulty ambulating, and rash two weeks after a respiratory infection. She was approached with a broad differential and ultimately diagnosed with IgA vasculitis.

Discussion: Cutaneous manifestations, arthralgias, renal and gastrointestinal involvement are the most common presenting signs of IgA vasculitis. Only two cases of IgA vasculitis associated with lumbar pain and swelling were identified in the literature.

Conclusion: While rash and joint pain are common presenting signs of IgA vasculitis, practitioners should be aware it can present atypically. [Clin Pract Cases Emerg Med. 2020;4(2):241–243.]

Keyword: *IgA vasculitis; Henoch-Schonlein purpura; HSP; lumbar swelling.*

INTRODUCTION

Immunoglobulin A (IgA) vasculitis is the most common vasculitis in children.¹ IgA vasculitis, formerly known as Henoch-Schönlein purpura, is comprised of a clinical tetrad of palpable purpura, arthralgias, abdominal pain, and renal disease, all in the absence of thrombocytopenia or coagulopathy.¹ Subcutaneous edema, either periorbital or dependent edema in the hands, feet, and genitals, are all well documented in the literature.¹⁻³ The diagnosis of IgA vasculitis is typically made by clinical examination and presence of the palpable purpuric rash along with two to three of the other classical findings of the clinical tetrad, although IgA deposition can aid the diagnosis.¹ We present a case of a six-year-old female who presented to the emergency department (ED) due to non-traumatic back pain, swelling, and refusal to ambulate.

CASE REPORT

A six-year-old female was brought by a family member to the ED complaining of low back pain and swelling. The patient's symptoms had been ongoing for several days. She denied any history of trauma. She was refusing to ambulate secondary to pain in the joints of the lower extremities. She also noted mild nausea, ankle swelling, and a rash on her lower extremities bilaterally. The patient's family also described her as having a previous upper respiratory infection approximately two weeks prior. The patient was fully immunized and had an unremarkable past medical, surgical, and family history. She had been taking ibuprofen for her symptoms, but otherwise took no medications.

She was afebrile with a temperature of 99.0° Fahrenheit, and had a heart rate of 112 beats a minute, a blood pressure of 123/81 milligrams of mercury, a respiratory rate of 18

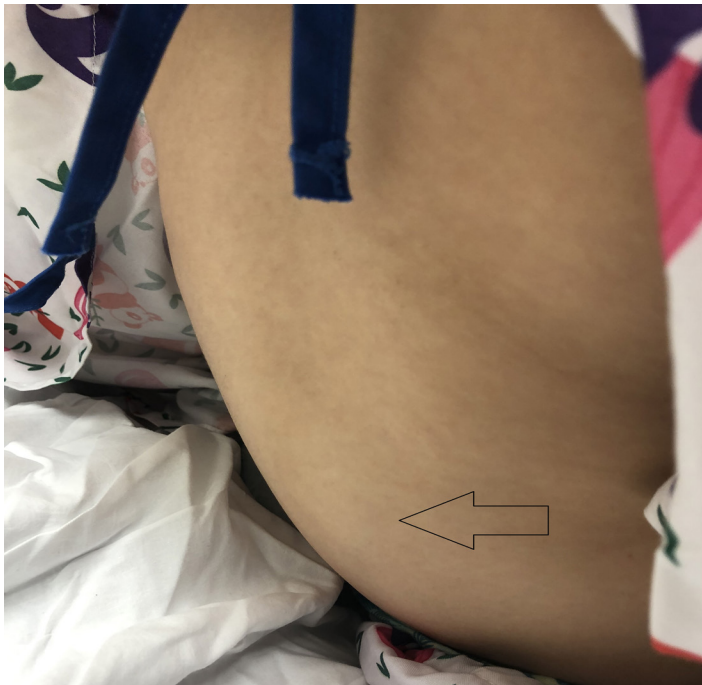

Image 1. Photograph of the patient's lower back demonstrating lumbar soft tissue swelling indicated by the arrow.

breaths per minute, and 99% pulse oximetry on room air. She was refusing to ambulate secondary to pain but was otherwise nontoxic appearing. There was an oval area of cutaneous edema, similar in shape to an American football, approximately 10 centimeters (cm) vertically and 8 cm transversely, stretching from her lower thoracic spine down to her lower lumbar spine over which she had moderate tenderness (Image 1). She had mild, non-pitting pedal edema and was noted to have a palpable purpuric rash over her ankles and lower legs. Abdominal and neurologic examinations were benign, and the remainder of the physical exam was unremarkable.

Laboratory studies included an unremarkable complete blood count, prothrombin time, partial thromboplastin time, and complete metabolic panel. Urinalysis was significant for hematuria with 10-15 red blood cells seen per high-powered field on microscopy and without proteinuria. The patient was also noted to have an elevated erythrocyte sedimentation rate at 44 millimeters per hour (normal is <30) and an elevated C-reactive protein at 1.8 milligrams per liter (normal is <1.0). Radiographs of the lumbar spine demonstrated subcutaneous edema but were otherwise unremarkable (Image 2).

The patient was treated with a weight-based dose of ibuprofen and was observed ambulating without difficulty around the ED. She was discharged with a 48-hour follow-up in the ED. At her follow-up it was noted that she no longer had any pain or swelling of her lower back and the remainder of her symptoms were resolving as well.

CPC-EM Capsule

What do we already know about this clinical entity?

Immunoglobulin A (IgA) vasculitis is a common pediatric disease that is a combination of a rash, arthralgias, abdominal pain, and renal disease with varying penetrance.

What makes this presentation of disease reportable?

This presentation of IgA vasculitis is a rare presentation only previously described in the literature twice.

What is the major learning point?

The major learning point is that IgA vasculitis will commonly have atypical presentations and should be considered in unusual cases.

How might this improve emergency medicine practice?

This article helps highlight the importance to consider IgA vasculitis in the differential while treating the pediatric patient in the emergency department.

DISCUSSION

IgA vasculitis is known to have varying presentations, sometimes including edema of the hands, feet, and even genitals.^{2,3,6} Varying penetrance of clinical features appears to be somewhat common and is well documented.^{2,6} In one retrospective study of 150 patients diagnosed with IgA vasculitis, all had cutaneous manifestations, whereas 74% had arthralgias, 54% had renal involvement, and 51% had abdominal involvement.² Gastrointestinal symptoms occur in approximately 50% of cases and can range from nausea and vomiting to intestinal bleeding or intussusception.¹ Renal involvement can range from a small amount of hematuria or proteinuria to nephrotic-range proteinuria and elevated creatinine.¹ Diagnosis is usually clinical and based on the presence of classical symptoms, but can be aided by skin and renal biopsy demonstrating IgA deposits.¹ Complications of IgA vasculitis include chronic kidney disease or, rarely, intussusception.² Treatment is generally aimed at symptom relief; use of corticosteroids is controversial.^{1,2}

After a literature review, we identified only two previous cases of IgA vasculitis associated with lumbar pain and swelling in a child diagnosed with IgA vasculitis.^{4,5} In one of these cases,

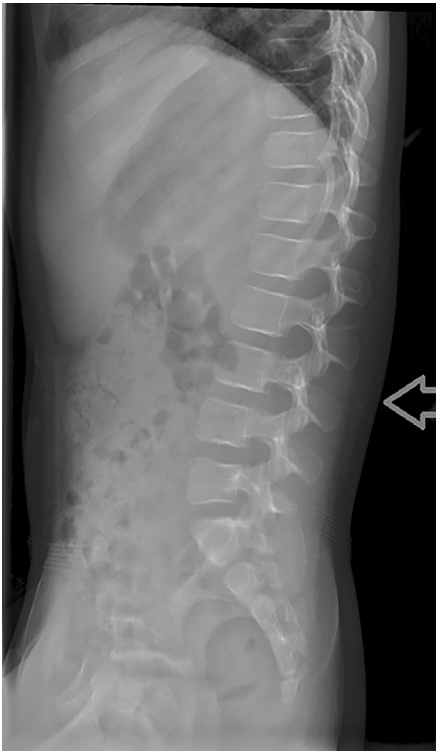


Image 2. Lateral radiograph of the lumbar spine with noted subcutaneous edema and soft tissue swelling noted by the arrow.

the patient's presenting symptoms were abdominal pain rather than back pain. This patient had hemoccult-positive stool and only later developed the lumbar swelling on day 3 of hospitalization.⁴ The lumbar swelling resolved after two days; however, that patient did develop facial edema that required ongoing corticosteroid treatment.⁴ In the second case, the patient's presenting symptom was back pain and refusal to ambulate after a febrile illness and development of a rash. Magnetic resonance imaging was performed, which demonstrated edema of the lumbosacral fascial planes.⁵

The lumbar swelling noted in those two cases and in our case is likely the same mechanism of dependent edema, which commonly leads to swelling of the hands and feet. We approached our patient with a broad differential diagnosis. After a thorough physical examination and laboratory studies, she was diagnosed with IgA vasculitis, treated accordingly, and discharged home.

CONCLUSION

This case illuminates an atypical presentation of IgA vasculitis that is notable for its comparative rarity, having been noted only twice previously in the literature.^{4,5} The patient's atraumatic low back pain and swelling elicited a wide differential diagnosis on her presentation. Only after a thorough examination and laboratory studies did we determine

that it was a presentation of IgA vasculitis. This case demonstrates the importance for clinicians to be aware that this common diagnosis can present in uncommon ways.

The documented attestation from the authors that their institution requires neither Institutional Review Board approval, nor patient consent for publication of this case report has been obtained and filed.

Address for Correspondence: Clay T. Winkler, DO, Prisma Health-University of South Carolina School of Medicine, Department of Emergency Medicine, 5 Richland Medical Park Dr., Columbia, SC 29203. Email: clay.winkler@prismahealth.org.

Conflicts of Interest: By the *CPC-EM* article submission agreement, all authors are required to disclose all affiliations, funding sources and financial or management relationships that could be perceived as potential sources of bias. The authors disclosed none.

Copyright: © 2020 Winkler et al. This is an open access article distributed in accordance with the terms of the Creative Commons Attribution ([CC BY 4.0](http://creativecommons.org/licenses/by/4.0/)) License. See: <http://creativecommons.org/licenses/by/4.0/>

REFERENCES

1. McCarthy HJ and Tizard EJ. Clinical practice: diagnosis and management of Henoch-Schönlein purpura. *Eur J Pediatr*. 2010;169(6):643.
2. Trapani S, Micheli A, Grisolia F, et al. Henoch Schonlein purpura in childhood: epidemiological and clinical analysis of 150 cases over a 5-year period and review of literature. *Semin Arthritis Rheum*. 2005;35(3):143.
3. Nussinovitch M, Prais D, Finkelstein Y, et al. Cutaneous manifestations of Henoch-Schönlein purpura in young children. *Pediatr Dermatol*. 1998;15(6):426-8.
4. Duman MA, Duru NS, Çalışkan B, et al. Lumbar swelling as the unusual presentation of Henoch-Schonlein purpura in a child. *Balkan Med J*. 2016;33(3):360-2.
5. Schaefer B and Soprano C. Five-year-old boy presenting with severe back pain, swelling, and refusal to walk. *Clin Pediatr (Phila)*. 2014;53(1):95-7.
6. Johnson EF, Lehman JS, Wetter DA, et al. Henoch-Schönlein purpura and systemic disease in children: retrospective study of clinical findings, histopathology and direct immunofluorescence in 34 paediatric patients. *Br J Dermatol*. 2015;172(5):1358-63.

Fever Unmasked Brugada Syndrome in Pediatric Patient: A Case Report

Orhay Mirzapolos, DO
Perry Marshall, DO
April Brill, DO

Midwestern University, Department of Emergency Medicine, Downers Grove, Illinois

Section Editors: Shahram Lotfipour, MD, MPH

Submission history: Submitted July 10, 2019; Revision received February 9, 2020; Accepted February 10, 2020

Electronically published April 23, 2020

Full text available through open access at http://escholarship.org/uc/uciem_cpem

DOI: 10.5811/cpcem.2020.2.44418

Introduction: Brugada syndrome is an arrhythmogenic disorder that is a known cause of sudden cardiac death. It is characterized by a pattern of ST segment elevation in the precordial leads on an electrocardiogram (EKG) due to a sodium channelopathy.

Case Report: This case report highlights the case of a five-year-old female who presented to the emergency department with a febrile viral illness and had an EKG consistent with Brugada syndrome.

Discussion: Fever is known to accentuate or unmask EKG changes associated with Brugada due to temperature sensitivity of the sodium channels.

Conclusion: Febrile patients with Brugada are at particular risk for fatal ventricular arrhythmias and fevers should be treated aggressively by the emergency medicine provider. Emergency medicine providers should also consider admitting febrile patients with Brugada syndrome who do not have an automatic implantable cardioverter-defibrillator for cardiac monitoring. [Clin Pract Cases Emerg Med. 2020;4(2):244–246.]

Keywords: *Brugada; pediatric; viral illness; arrhythmias; fever.*

INTRODUCTION

Brugada syndrome is an important cause of sudden cardiac death and is prevalent in a young patient population. Nevertheless, the classic electrocardiogram (EKG) findings associated with the disease may not always be present in individuals with Brugada syndrome.¹ The characteristic ST-segment elevations in the precordial leads are caused by a loss of function mutation of sodium channels involved in phase 0 of the cardiac cycle.² A new hypothesis is that these sodium channels are also temperature sensitive. As a result, a fever accentuates impaired sodium channels influx to not only unmask classic Brugada EKG changes, but may also induce potentially fatal ventricular arrhythmias.¹ As demonstrated in this case report, a young female presented to the emergency department (ED) for the evaluation of a febrile viral illness and was found to have this life-threatening cardiac anomaly on her EKG.

CASE REPORT

A five-year-old African-American female presented to a community hospital ED with two days of subjective fevers. This fever was associated with nasal congestion, a productive cough, a sore throat, and injected conjunctiva. She also complained of nausea, and her mother reported decreased oral intake. Her mother denied any history of syncopal episodes. The patient was born full term and had no past medical history. Her immunizations were up to date with the exception of an annual influenza vaccine. Furthermore, she had no notable family medical history and, specifically, no family history of sudden cardiac death.

In the ED she was ill appearing, but she was well-hydrated and non-toxic in appearance. Her vitals were as follows: temperature 101 degrees Fahrenheit, heart rate 118 beats per minute, blood pressure 105/70 millimeters of mercury, respiratory rate 20 breaths per minute, saturating 98% on room air.

On physical exam, her ears, nose and throat exam were only notable for congestion and an erythematous pharynx. Her lungs were clear to auscultation bilaterally. On cardiac exam, she was tachycardic with an irregular rhythm. There were no murmurs, rubs, or gallops heard. Her abdomen was soft and non-tender. Lastly, her skin exam was unremarkable.

Her complete blood count (CBC), complete metabolic panel (CMP), magnesium, and troponin were within normal limits, but did test positive for influenza A. Her chest radiograph was negative. Her EKG (Image) showed a sinus rhythm with frequent premature ventricular contractions, a right axis, and coved ST elevation in V1-V2.

Upon recognition of the Brugada pattern on her EKG, it was determined that she required higher level of care than was available at the community hospital. She was transferred to a children's hospital and evaluated by pediatric cardiology. While there, an echocardiogram was performed and was negative for structural heart disease. She also underwent an electrophysiology study, which was negative for inducible arrhythmias. Thus, the decision was made to defer automatic implantable cardioverter-defibrillator (AICD) placement. The patient and her family were referred for genetic testing, but they chose not to complete the testing. Currently, she is followed regularly by a pediatric cardiologist and has had no adverse cardiac events to date.

DISCUSSION

Brugada syndrome was first recognized in 1992 and has since been identified as an autosomal dominant, inherited sodium channelopathy.³ Specifically, a loss of function mutation of the SCN5A gene causes an impairment of sodium influx during phase 0 of the cardiac cycle.² Classic EKG findings include three types of ST elevations in V1-V3: coved,

saddleback, or a combination.³ The diagnostic criteria for Brugada syndrome is the presence of a type I pattern (coved

CPC-EM Capsule

What do we already know about this clinical entity?

Brugada syndrome is an important cause of sudden cardiac death as a result of a loss of function mutation of sodium channels.

What makes this presentation of disease reportable?

Fever provokes electrocardiogram (ECG) changes in asymptomatic individuals with Brugada and the ECG may revert to normal when the patient becomes afebrile.

What is the major learning point?

The impaired sodium channels are thought to be temperature sensitive. Fever is the state most likely to induce ventricular arrhythmia in children with Brugada.

How might this improve emergency medicine practice?

Physicians must be cognizant of the potentially life-threatening complications of fevers in this patient population and have a low threshold for admission.

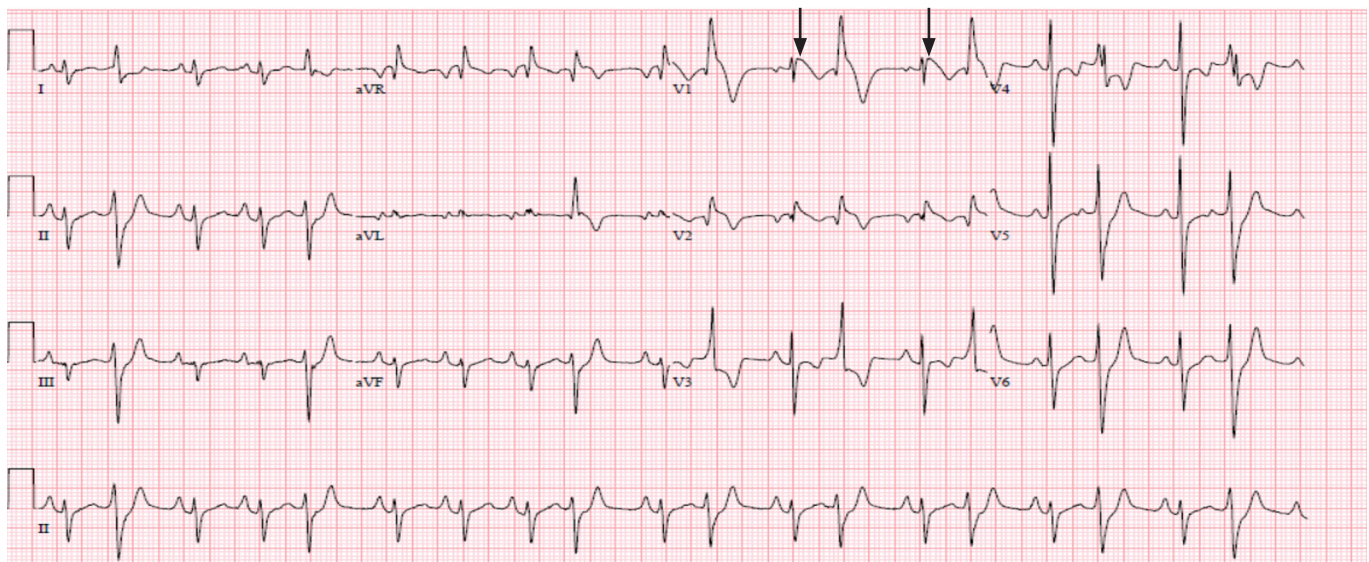


Image. Patient's electrocardiogram showing Brugada pattern coved ST elevation in V1-V2 (arrows).

ST elevation) on EKG with one of the following: documented ventricular arrhythmia; family history of sudden cardiac death; type I pattern EKG in a family member; induced ventricular arrhythmia with electrical stimulation; or history of unexplained syncope.⁴

Fever provokes these EKG changes in asymptomatic individuals with Brugada and the EKG may revert to normal when the patient becomes afebrile. While the exact mechanism is unknown, it is postulated that the sodium channels are temperature sensitive and thus fever exacerbates the impairment of sodium influx through the channel.¹ This leads to nonhomogeneous repolarization of the right ventricle and thus creates a potential for re-entry arrhythmias.³ In fact, fever has been associated with 18% of cardiac arrests in patients with Brugada.⁴ In children, symptomatic Brugada is most frequently associated with fever.⁷ As clinicians, it is important to recognize that fever is the state most likely to induce ventricular arrhythmia in children with Brugada.⁵ Parents need to be educated to treat fevers aggressively and hospital admission for cardiac monitoring should be considered for patients without an AICD. Furthermore, EPs should not be falsely reassured by the normalization of the EKG in this patient population.⁶

Treatment of asymptomatic patients with Brugada is controversial in adults and not well studied in pediatrics. Symptomatic patients with a history of arrhythmia, syncope, or family history of sudden cardiac death should all receive an AICD. Those who are asymptomatic commonly undergo electrophysiology studies and if no inducible arrhythmia is found, they are typically managed conservatively with close follow-up.³

CONCLUSION

Brugada syndrome is primarily reported in adults, with limited data on its presentation in pediatrics. In both adults and pediatrics, a febrile illness may unmask an underlying Brugada pattern EKG, even in individuals with previously normal EKGs. The impaired sodium channels are thought to be temperature sensitive, and thus fever exaggerates the impaired sodium influx. This not only emphasizes the EKG changes, but also places the patient at risk for fatal arrhythmias. This case report demonstrates an instance in which these EKG changes were only revealed as a result of a febrile illness. While there have been a handful of similar case reports published in the literature, it is still a novel concept for many clinicians. EPs in particular must be cognizant of the potentially life-threatening complications

of fevers in this patient population and have a low threshold for admission.

The authors attest that their institution requires neither Institutional Review Board approval, nor patient consent for publication of this case report. Documentation on file.

Address for Correspondence: Orhay Mirzapolos, DO, Midwestern University, Department of Emergency Medicine, 555 31st Street, Downers Grove, IL 60515. Email: omirzapolos51@midwestern.edu.

Conflicts of Interest: By the CPC-EM article submission agreement, all authors are required to disclose all affiliations, funding sources and financial or management relationships that could be perceived as potential sources of bias. The authors disclosed none.

Copyright: © 2020 Mirzapolos et al. This is an open access article distributed in accordance with the terms of the Creative Commons Attribution (CC BY 4.0) License. See: <http://creativecommons.org/licenses/by/4.0/>

REFERENCES

1. Amin AS, Klemens AO, Verkerk PG, et al. Fever-triggered ventricular arrhythmias in Brugada syndrome and type 2 long-QT syndrome. *Neth Heart J*. 2010;18:165-9.
2. Mok NS, Priori SG, Napolitano C, et al. A newly characterized SCN5A mutation underlying Brugada syndrome unmasked by hyperthermia. *J Cardiovasc Electr*. 2003;14(4):407-11.
3. Vohra J. Diagnosis and management of Brugada syndrome. *Heart Lung Circ*. 2011;20:751-6.
4. Ahmad S and Ahmed I. Brugada syndrome in the context of a fever: a case study and review of current knowledge. *Brit J Cardiol*. 2017;24(117).
5. Zaidi AN. An unusual case of Brugada syndrome in a 10-year-old child with fevers. *Congenit Heart Dis*. 2010;5:594-8.
6. Grogan SP, Cube RP, Edwards JA. Brugada syndrome unmasked by fever. *Mil Med*. 2011;176:946-9.
7. Kim G, Kyung YC, Kang IS, et al. A pediatric case of Brugada syndrome diagnosed by fever-provoked ventricular tachycardia. *Korean J of Pediatr*. 2014;57(8):374-8.

Unsuspecting Dietary Factors in Hyperkalemia: A Case Report on Why History Matters

Kevin McLendon, DO*†
Matthew Wiggins, MD*
Derek Hunt, DO*
Alex Gauthier, DO‡
Deepu Thoppil, MD‡

*Merit Health Wesley, Department of Emergency Medicine, Hattiesburg, Mississippi

†William Carey University College of Osteopathic Medicine, Department of Emergency Medicine, Hattiesburg, Mississippi

‡Merit Health Wesley, Department of Internal Medicine, Hattiesburg, Mississippi

Section Editor: John Ashurst, DO

Submission history: Submitted March 14, 2019; Revision received January 28, 2020; Accepted March 10, 2020

Electronically published April 23, 2020

Full text available through open access at http://escholarship.org/uc/uciem_cpem

DOI: 10.5811/cpcem.2020.3.43095

Introduction: We present a case of hyperkalemia secondary to excessive dietary intake of hard caramel candies.

Case Report: An 88-year-old male who presented with acute abdominal pain and vomiting was found to have hyperkalemia of 6.9 milliequivalents per liter. He was stabilized, treated, and discharged the following day after resolution. The cause was identified as his daily consumption of 200 hard caramel candies.

Discussion: The patient had been consuming sugar-free candies, which induced a chronic diarrhea. This led to potassium wasting and augmentation of his home medications. When he transitioned to eating regular caramel candies, he retained too much potassium leading to his presentation.

Conclusion: While often overlooked, dietary history is a crucial part of history-taking to ensure that the underlying cause for illness is discovered and addressed. [Clin Pract Cases Emerg Med. 2020;4(2):247–250.]

Keywords: *Hyperkalemia; diet; history taking; dietary habits; sorbitol and diarrhea.*

INTRODUCTION

In this case of hyperkalemia a patient with previous, stable, chronic kidney disease (CKD) and regular primary care induced his own hyperkalemia secondary to obscure dietary habits. Dietary habits and nutrition are an often-neglected aspect of medical education, especially for the emergency physician. However, for our patient's health, it is imperative that we discover the causative factor for his or her presentation to best prevent the condition from reoccurring. This is much more critical in the setting of hyperkalemia as mild elevations have been associated with short- and long-term increased mortality.¹

Hyperkalemia is often associated with CKD with prevalence as high as 20%. It has been suggested that in

CKD above-normal potassium concentrations are present to induce stress on the remaining functional renal cells, which respond to additional diuresis of the potassium.² This delicate system is able to maintain homeostasis in the absence of any additional insult. The insult may come from acute changes in renal excretion, fecal excretion, dietary intake, or metabolic acidosis.¹ While dietary potassium has been implicated in the past, no previous literature suggests sugar substitutes in food as a causative factor.²

CASE REPORT

An 88-year-old male presented to the emergency department (ED) with a one-day history of nausea and vomiting associated with severe, crampy, and diffuse

abdominal pain beginning that morning. The patient also reported daily diarrhea for longer than one month, but it was never problematic and had spontaneously resolved approximately one week prior to arrival. He described his pain as similar to what he had experienced in a previous episode of peritonitis as a young man, which required an exploratory laparotomy; he also reported a history of multiple abdominal surgeries. The vomit was non-bilious and non-bloody; he stated it looked just like the tea he regularly drinks. He denied any associated symptoms of fever, chills, weakness, or body aches.

The patient's last primary care visit was two weeks prior to arrival where routine labs including renal function and electrolytes were performed. All studies were reported within his baseline. He had an extensive medical history that included diet-controlled type 2 diabetes mellitus, hypertension, hyperlipidemia, coronary artery disease, chronic obstructive pulmonary disease, and stable stage 3A CKD. Baseline renal function was recorded as creatinine 1.60 milligrams per deciliter (mg/dL) (normal range 0.6-1.3 mg/dL) and glomerular filtration rate (GFR) of 45 milliliters per minute per 1.73 meters squared (mL/min/1.73 m²) (normal range for non-African American \geq 60).

While he had spontaneous improvement of his abdominal pain prior to emergency physician assessment he continued to have generalized tenderness to palpation, without rebound. We obtained a complete blood count with differential, a comprehensive metabolic panel, and a computed tomography (CT) of the abdomen and pelvis. The initial laboratory results revealed hyperkalemia of 6.9 milliequivalents per liter (normal 3.6-4.9 mmol/L, critical high $>$ 6.0 mmol/L), which was not included on the original differential diagnosis. We also noted mild worsening of his baseline renal function with an increase of creatinine to 1.75 mg/dL, and decrease of GFR to 35 mL/min/1.73m². Once the hyperkalemia was identified as a non-hemolyzed sample, therapy was initiated with one-gram intravenous (IV) calcium gluconate, performance of an electrocardiogram (ECG), one liter normal saline fluid bolus, 10 units IV insulin, 25 grams D50, plus 7.5 mg nebulized albuterol. The ECG revealed a paced rhythm at 60 beats per minute and T-wave inversions in leads V3-V6 without hyperacute T waves (Image). The CT revealed no acute process, and the patient was admitted to the hospital for further management and treatment of his hyperkalemia.

Once admitted, the patient reported a long history of xerostomia, which he self-treated by eating hard caramel candies throughout the day for many months. His medication list included clopidogrel, atorvastatin, enalapril, and spironolactone. At this time a lengthy conversation ensued in an attempt to determine the cause of his sudden, symptomatic hyperkalemia. It was determined that he previously had been taking supplemental potassium while he was taking furosemide. In November he discontinued the supplemental

CPC-EM Capsule

What do we already know about this clinical entity?

Hyperkalemia is a potentially fatal abnormality that is often caused by medications or kidney disease.

What makes this presentation of disease reportable?

Underlying cause in this patient is dietary source which is often an overlooked piece in the patient history.

What is the major learning point?

Do not overlook the diet as a cause, and remember to search for the underlying etiology when treating pathology.

How might this improve emergency medicine practice?

As a reminder to pause and take more inclusive histories from our patients, which can become underrated in the busy ED setting.

potassium because his serum level was "borderline high." In December, he switched from furosemide to spironolactone due to a recurrence of hypokalemia. His monthly follow-up in January revealed a normal potassium, but he was subsequently admitted two weeks later for this episode of hyperkalemia with abdominal pain (Figure).

His diet consisted primarily of canned soups, sandwiches, and one gallon of sugar-free peach iced tea daily. He further reported consuming a large quantity of hard caramel candies each week. When asked about the candy he stated that he bought a 10-pound bag weekly for himself, roughly 200 candies consumed daily. During his primary care visit in December, he switched to sugar-free caramel candies as part of an attempt at improving his glucose control. Also, at this visit furosemide was discontinued, and he was started on spironolactone (Figure 2). This happened to coincide with the onset of his reported chronic diarrhea. One week prior to ED presentation, he stopped eating the sugar-free candies because the taste "just wasn't the same," and switched back to the original caramel candies. This resolved his diarrhea, although he had never noticed the correlation until after his conversation with care providers.

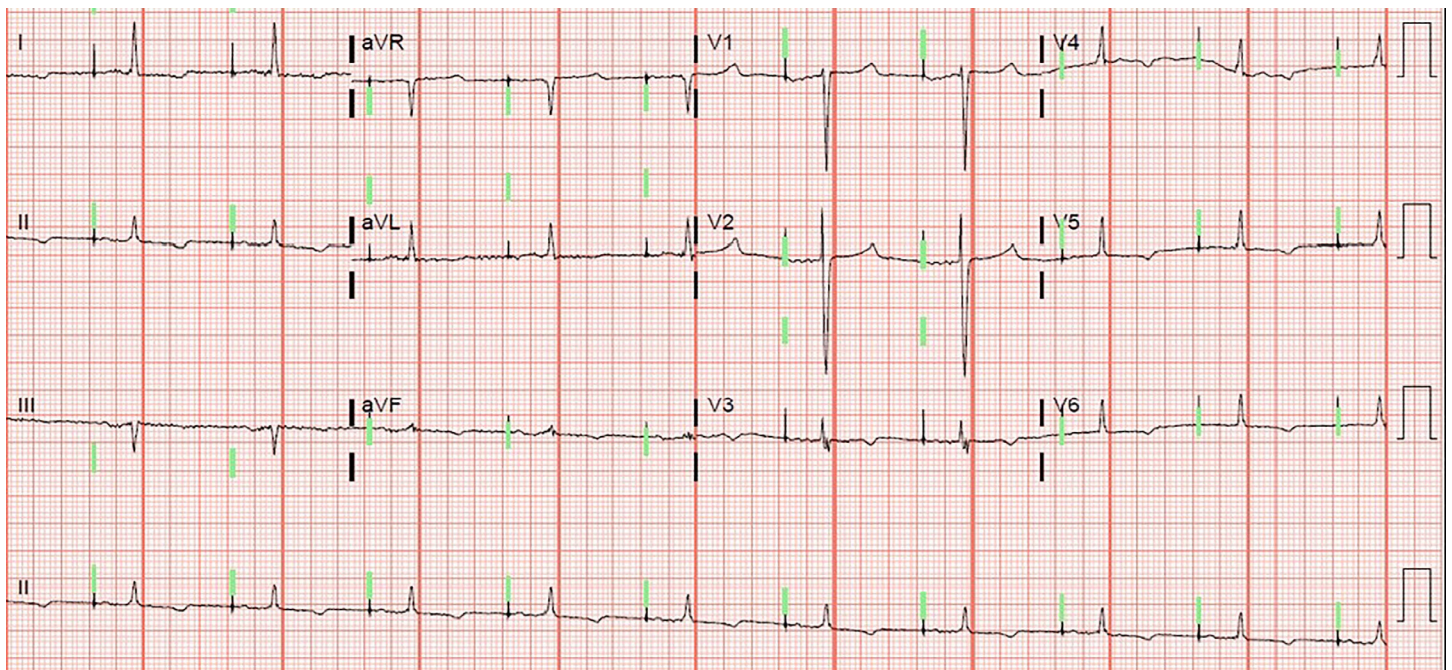


Image. Electrocardiogram of 88-year-old man who presented with sudden, symptomatic hyperkalemia.

DISCUSSION

Potassium regulation is dependent on dietary intake and renal and bowel excretion. In a patient without CKD this likely would not have caused the dramatic response seen here. While high dietary potassium can overcome the body's ability to adapt to excess excretion, the patient was also augmenting his own reserve by the amount of sorbitol-induced diarrhea prior to his cessation from sugar-free candies. Review of diet discovered the patient had an abnormally high daily intake of both 200 caramel candies and one gallon of sugar-free, peach iced tea. From the tea, he was consuming approximately 16 servings of potassium-based sweetener daily. Although no data was available on the true quantity of potassium in each serving, there is literature to suggest potassium-based sweetener substitutes have higher bioavailability than natural potassium and are often under-reported quantities of dietary potassium.¹ In the caramel candy there is no reported potassium, nor evidence of potassium in the ingredients list; however, the sugar-free version contains sorbitol as the sweetener. Sorbitol is known to induce osmotic diarrhea.⁴

The quantity of intake (200 candies/day) explained his chronic diarrhea from mid-December until one week prior to arrival. Osmotic diarrhea is also associated with increased fecal loss of potassium.⁵ The patient likely would have developed hyperkalemia initially when switched from furosemide to spironolactone as it was coupled with enalapril in the setting of CKD.⁶ The presentation was delayed and offset initially by the co-initiation of sorbitol intake from

sugar-free caramel candies, which increased fecal potassium loss and allowed his previous outpatient potassium level to result within normal limits. Once the excess potassium loss was stopped by switching back to original caramel candies (which contain no sorbitol), the diarrhea resolved, and the medication combination and elevated dietary intake of potassium culminated in the patient's presentation. If untreated, his renal function would likely have deteriorated further and his potassium may have continued to elevate to fatal levels.

CKD places a patient at increased risk for hyperkalemia, especially in the setting of concurrent use with potassium-sparing diuretics.^{2,6} As a dietary cause, salt substitutes are a well-known source of potassium.³ This case presents an entirely new class of food, sugar-free items, as a causative factor for hyperkalemia. It also includes a unique case of self-temporizing potassium normalization with increased excretion due to the patient's consumption of sugar-free candies until his abrupt discontinuation in favor of the original versions made with real sugar. The increasing abundance of sugar substitutes in food items may pose a threat to patients in the future. If this patient had not had such high dietary intake of potassium from his potassium-laden, sugar-free tea, he likely would have been found hypokalemic earlier from the sugar-free caramel candy, sorbitol-induced, chronic osmotic diarrhea. Both sugar-free foods in this case can create concerning electrolyte abnormalities on their own and require the attention of the astute provider in history-taking to determine the underlying cause.

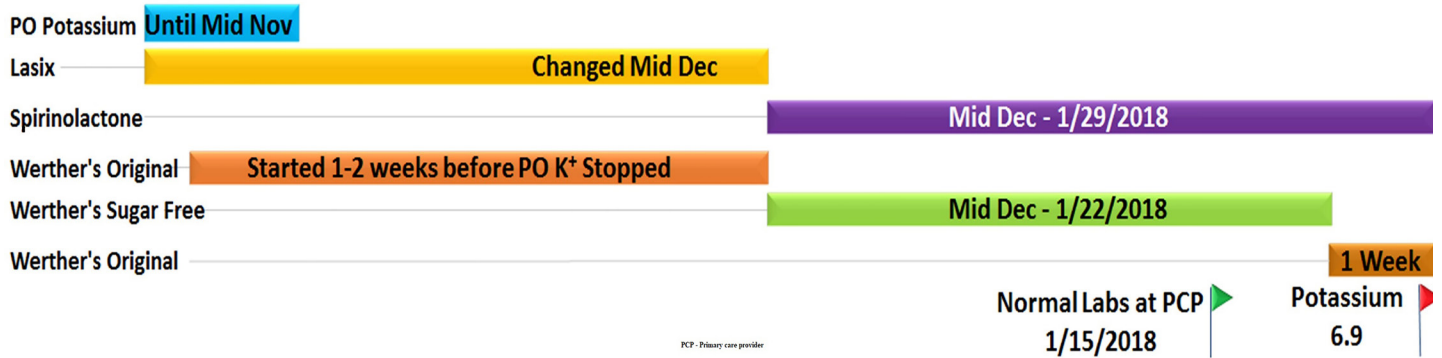


Figure. Timeline of medications and caramel candy type in a patient whom developed hyperkalemia.

CONCLUSION

This case highlights the importance of good history-taking, as it can mean the difference in diagnosing the underlying cause of a disease and preventing future complications.⁷ More specifically, this case highlights the importance of a dietary history, something too often ignored in the ED. It can be easy to focus on the immediate treatment and stabilization of patients, but we must also be advocates for our patients and remember to search for the underlying cause.

Address for Correspondence: Kevin McLendon, DO, Merit Health Wesley, Department of Emergency Medicine, 5001 Hardy St., Hattiesburg, MS 39402. Email: kevin.mclendon@merithealthwesley.com.

Conflicts of Interest: By the CPC-EM article submission agreement, all authors are required to disclose all affiliations, funding sources and financial or management relationships that could be perceived as potential sources of bias. The authors disclosed none.

Copyright: © 2020 McLendon et al. This is an open access article distributed in accordance with the terms of the Creative Commons Attribution (CC BY 4.0) License. See: <http://creativecommons.org/licenses/by/4.0/>

Documented Institutional Review Board exemption has been obtained and filed for publication of this case report.

REFERENCES

1. Picard K. Potassium additives and bioavailability: Are we missing something in hyperkalemia management? *JRN*. 2019;29(4):350-3.
2. Gennari F and Segal A. Hyperkalemia: an adaptive response in chronic renal insufficiency. *KI*. 2002;62(1):1-9.
3. Batra V and Villgran V. Hyperkalemia from dietary supplements. *Cureus*. 2016;8(11):e859.
4. Islam MS. Sorbitol-based osmotic diarrhea: Possible causes and mechanism of prevention investigated in rats. *WJG*. 2006;12(47):7635.
5. McCarran W. Rehydration Project: Medical education teaching medical students about diarrhoeal diseases. Available at: <http://rehydrate.org/diarrhoea/tmsdd/2med.htm#Consequences>. Accessed March 13, 2019.
6. Good C. Diet and serum potassium in patients on ACE inhibitors. *JAMA*. 1995;274(7):538.
7. Anani S, Goldhaber G, Wasserstrum Y, et al. The 'SILENT alarm': when history taking reveals a potentially fatal toxicity. *Eur J Case Rep Intern Med*. 2018;5(6).

Brugada Syndrome: Presentation and Management of the Atypical Patient in the Emergent Setting

Alexander Nguyen, BA*†
Mario Flores, BS†
Vilmogil Tano, MD†

*Henry Ford Wyandotte Hospital, Department of Emergency Medicine, Wyandotte, Michigan
†Burrell College of Osteopathic Medicine at New Mexico State University, Department of
Emergency Medicine, Las Cruces, New Mexico

Section Editor: Rick A. McPheeters, DO

Submission history: Submitted July 29, 2019; Revision received January 3, 2020; Accepted January 1, 2020

Electronically published April 14, 2020

Full text available through open access at http://escholarship.org/uc/uciem_cpccem

DOI: 10.5811/cpcem.2020.1.44675

Introduction: Brugada syndrome is a genetic disorder of the heart's electrical system that increases a patient's risk of sudden cardiac death. It is a syndrome most prevalent in Southeast Asians and is found 36 times more commonly in Asians than in Hispanics.

Case Report: We report and discuss a case of a 68-year-old Hispanic male who presented with clinical and electrocardiogram abnormalities consistent with Brugada syndrome.

Discussion: The patient's age and ethnicity represents an atypical presentation of this rare syndrome and the lack of reported studies in the literature pertaining to these demographics reflect this.

Conclusion: Further studies and characterizations are necessary as manifestations continue to be unearthed. As such, Brugada Syndrome should be considered in the differential diagnosis for a myriad of patient populations. [Clin Pract Cases Emerg Med. 2020;4(2):251–254.]

Keywords: *syncope; ventricular tachycardia; ventricular fibrillation; emergency department; sudden cardiac death.*

INTRODUCTION

Brugada syndrome, an autosomal dominant disorder of the heart's electrical system, was first described in medical literature in 1992 as a frequent cause of syncope, ventricular tachyarrhythmia, and sudden cardiac death.²

³ An extremely rare phenomenon affecting an estimated 0.05% of people worldwide, it presents at an average age of 41 years and tends to affect men and those of Asian ancestry most frequently.^{3,4} The electrocardiogram (ECG) of a patient with this syndrome classically demonstrates ST-segment elevations in leads V1 to V3 and a right bundle branch block pattern.³ Here we discuss a case of an elderly Hispanic patient with no significant past medical history who presented to the emergency department (ED) with first-time signs and symptoms consistent with Brugada syndrome.

CASE REPORT

A 68-year-old Hispanic male with no significant past medical history was brought to the ED by emergency medical services (EMS) for confusion and altered mental status. EMS reported that they were called by the patient's wife when she discovered him breathing erratically and could not rouse him. Upon arrival to the ED, the patient was obtunded and began to experience cardiac arrest with ventricular fibrillation. He was subsequently intubated and given Advanced Cardiac Life Support where cardiopulmonary resuscitation was administered and the patient was defibrillated. He went on to experience return of spontaneous circulation. An ECG obtained in the ED during this event demonstrated ST-segment elevations in V1-V3 and specific repolarization abnormalities in V1 and V2 (Image).

Additional ECG findings included the following: first-degree atrioventricular (AV) block, PR interval of 220 milliseconds (120-200 milliseconds), and QRS duration of 0.11 seconds (0.08-0.12 seconds).

The patient was placed on an amiodarone infusion and transferred to a medical facility with a cardiac catheterization laboratory. Emergent cardiac catheterization was performed due to concerns for ST-elevation myocardial infarction (STEMI), but no acute findings were discovered. Laboratory values from the initial blood draw in the ED demonstrated the following: sodium 132 milliequivalent per liter (meq/L) (normal 136-145 meq/L); potassium 3.3 meq/L (normal 3.5-5.0 meq/L); magnesium 3.3 milligram per deciliter (mg/dL) (normal 1.5-2.4 mg/dL); glucose 197 mg/dL; troponin <0.02 nanograms per milliliter; brain natriuretic peptide (BNP) 65; prothrombin time (PT) 13.6 seconds (normal 11-13 seconds); international normalized ratio (INR) 1.3 seconds; and thyroid stimulating hormone (TSH) 59.4 milliunits per liter (mU/L) (normal 0.5-5.0 mU/L).

Following cardiac catheterization, the patient was transferred to the intensive care unit where all vital signs remained stable and within normal limits. With members of the patient's immediate family at bedside, information pertaining to his personal history was elicited for the first time. They reported that the patient had been in good health prior to the onset of his confusion and at no point did he complain of any discomfort or associated symptoms. Furthermore, they denied any significant past medical or surgical events in the patient's history, including any personal or family history of heart disease or sudden cardiac death. They stated that the patient had no allergies, did not take any medications, never used tobacco or illicit drugs, and consumed alcohol occasionally during social events.

The following day, the patient was extubated with excellent response and was found to have no focal deficits on physical exam. Thyroid replacement therapy was initiated for severe hypothyroidism discovered incidentally during the aforementioned care. Although no additional adverse cardiac events would occur for the duration of his hospital stay, the patient agreed to placement of an implantable-cardioverter defibrillator (ICD) as recommended for secondary prevention of Brugada syndrome.

Further work-up of the patient during his hospital course included the following: magnetic resonance imaging of the brain, which demonstrated multiple small areas of infarct in the bilateral cerebral hemispheres and no other significant findings. Computed tomography angiography of the head and neck were found to be normal. After demonstrating an ability to ambulate 300 feet with front-wheel walker, the patient was discharged home on aspirin and statin medication.

Left heart catheterization was performed 18 days later as recommended by the patient's electrophysiologist.

CPC-EM Capsule

What do we already know about this clinical entity?

Brugada syndrome is a rare genetic disease of the heart associated with arrhythmia and sudden cardiac death.

What makes this presentation of disease reportable?

Our Hispanic patient represents an atypical presentation of a disease most prevalent in Asians and lends credence to the need for further evaluation of this disorder.

What is the major learning point?

Brugada syndrome should be considered in the differential diagnosis for various patient populations.

How might this improve emergency medicine practice?

Broadening the differential diagnosis will aid early recognition, particularly in the elderly with unremarkable cardiac histories.

The right coronary artery was found without stenosis or blockage; the left anterior descending artery was patent; and overall coronary circulation and left ventricular function were normal. These findings, coupled with the patient's presenting symptoms and findings found on ECG in the ED, ultimately corroborated a diagnosis of Brugada syndrome with a type 1 pattern.

DISCUSSION

The average age of presentation of Brugada syndrome is 41 years, and men are affected far more frequently than women (9:1 ratio).³ This syndrome is believed to affect 0.5 per 1000 people worldwide, with Asians affected nine times more often than Caucasians and 36 times more often than Hispanics.¹ All patients, regardless of ethnicity, are predisposed to suffering from ventricular tachycardia, ventricular fibrillation, and sudden cardiac death.³ Moreover, patients are predisposed to suffering from concurrent cardiac abnormalities that include right bundle branch block, first-degree AV block, intraventricular conduction delay, and sick sinus syndrome.⁴

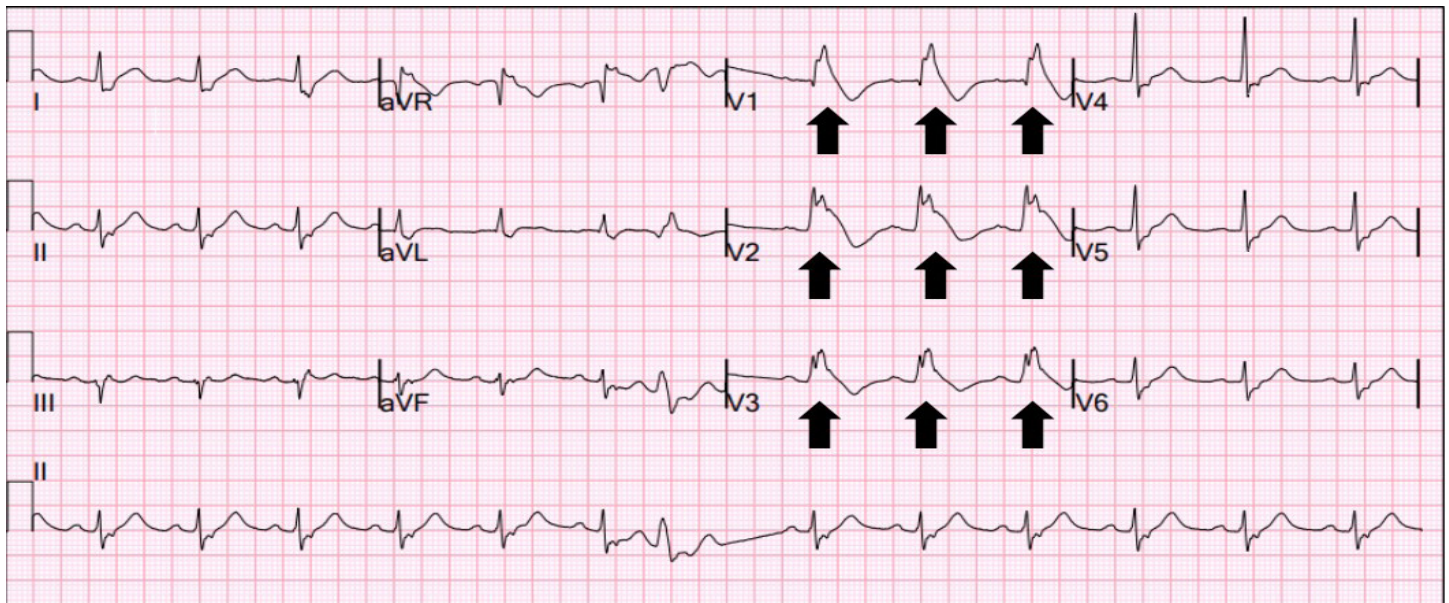


Image. Initial patient electrocardiogram obtained in the ED. Black arrows demonstrate ST-segment elevation in a coved pattern consistent with a Type 1 Brugada pattern.

Several mechanisms have been implicated in the pathophysiology of Brugada syndrome. In the inherited, autosomal dominant form of the syndrome, a gene mutation alters the structure and function of sodium ion channels found in the heart. Impaired ion channels prevent the flow of sodium into the cardiac cell, which adversely affects the heart rhythm.⁴ One proposed mechanism is through mutation of the SCN5A gene, which is responsible for the production of cardiac sodium channels. The SCN5A gene is by far the most commonly affected gene found in as many as 30% of affected individuals. Conversely, other individual gene mutations are responsible for less than one percent of all presentations.⁴ In the acquired form of the syndrome, exposures from drugs and other environmental instigators alter ion levels in the blood, resulting in altered cardiac conductivity.⁵ Implicated electrolyte abnormalities include hypercalcemia, as well as hyperkalemia and hypokalemia.⁵

Diagnosis of Brugada syndrome is based on classic ECG findings that include ST-segment elevations in leads V1 to V3 and right bundle branch block patterns on ECG in conjunction with one of the following: history of ventricular tachycardia or fibrillation; family history of sudden cardiac death or a coved pattern on ECG; or agonal breathing during sleep.³ Our patient's diagnosis was corroborated by way of ventricular fibrillation occurring in the ED and ST-segment elevations in leads V1 to V3 found on ECG.³

Unfortunately, Brugada syndrome predisposes a patient to a lifetime risk of sudden cardiac death, and there are currently no pharmacologic treatments to reduce this risk.⁶ Thus, ICD is

often recommended and was the treatment modality of choice used in our patient. ICD has the greatest efficacy in averting sudden cardiac death, but the decision to use the device depends on the patient's ability to tolerate it.⁷ If a patient cannot tolerate an ICD, pharmacologic therapy then serves as a second-line treatment modality. Pharmaceuticals can be used in the acute management of an arrhythmic storm, to prevent arrhythmia in patients with an implanted ICD requiring multiple shocks, and in cases where ICD implantation is contraindicated or not feasible – as may be the case in children or upon patient refusal.⁸

The following drugs have been found to be of great benefit: quinidine, disopyramide, quinine sulphate, beta agonists, phosphodiesterase inhibitors, bepridil, and traditional Chinese medicines such as wenxin keli and dimethyl lithospermate B.⁸ In contrast, contraindicated drugs that serve as sodium channel blockers with the ability to induce cardiac arrhythmias in Brugada syndrome include the following: ajmaline, procainamide, flecainide, propafenone and pilsicainide.⁸ Thus, it is imperative that physicians maintain Brugada syndrome atop the differential diagnosis for patients presenting with syncope, ventricular fibrillation, or STEMI, so as to avoid treating presentations with potentially underlying Brugada syndrome with a contraindicated medication.

Anticipation of Brugada syndrome in a particular patient demographic or age group should not be expected. Although it rarely presents in the geriatric and Hispanic populations and is not well studied in these individuals, it is a life threat

necessitating clarity in presentation, modes of treatment, and overall mortality risk for this particular patient demographic.⁹ Further compounding this issue is the profound increase in the incidence of syncope associated with Brugada syndrome during the seventh decade of life.⁹ As the various causes of syncope are complex and multifactorial, a diagnosis of Brugada syndrome can be missed or even veiled by comorbid causes of syncope such as arrhythmias, AV blocks, and atrial fibrillation found in the elderly.⁹

There have been rare reports of SCN5A gene mutation variants that are capable of inducing Brugada syndrome under hypothyroid conditions. This is explained by thyroid hormone affecting cardiac myocyte action potential duration and repolarization currents.¹⁰ It remains a possibility that our patient's clinical deterioration was incited by untreated hypothyroidism, but the association remains unclear. Future studies elucidating the relationship between hypothyroidism and Brugada syndrome are needed.

CONCLUSION

Our patient's age and ethnicity represent an atypical presentation of Brugada syndrome, and the lack of reported studies in the literature pertaining to this demographic reflect this. It is critically important to establish a diagnosis of Brugada syndrome in a patient lacking a personal or family history of this syndrome, as a first-time diagnosis in a single individual implicates their entire family. Furthermore, patients must be cautioned about the use of anesthetics, antihistamines, cocaine, antiarrhythmics, and psychotropic drugs as they have been found to provoke Brugada syndrome.¹¹ Brugada syndrome's abrupt symptomatology, high mortality rate, and ability to present atypically make this a challenging disorder to manage. It is for all of these reasons that Brugada syndrome will continue to serve as a significant life threat that emergency physicians will be relied upon to recognize and manage.

The signed attestation by the corresponding author that this institution does not require Institutional Review Board approval for case reports has been obtained and filed for publication of this case report.

Address for Correspondence: Alexander Nguyen, BA, Burrell College of Osteopathic Medicine at New Mexico State University, Department of Emergency Medicine, 3501 Arrowhead Dr., Las Cruces, NM 88001. Email: alexander.nguyen@mybcom.org.

Conflicts of Interest: By the CPC-EM article submission agreement, all authors are required to disclose all affiliations, funding sources and financial or management relationships that could be perceived as potential sources of bias. The authors disclosed none.

Copyright: © 2020 Nguyen et al. This is an open access article distributed in accordance with the terms of the Creative Commons Attribution (CC BY 4.0) License. See: <http://creativecommons.org/licenses/by/4.0/>

REFERENCES

1. Vutthikraivit W, Rattanawong P, Putthapiban P, et al. Worldwide Prevalence of Brugada Syndrome: A Systematic Review and Meta-Analysis. *Acta Cardiol Sin.* 2018;34(3):267-77.
2. Romero J, Li D, Avendano R, et al. Brugada Syndrome: Progress in Genetics, Risk Stratification, and Management. *Arrhythmia & Electrophysiol Rev.* 2019;8(1):19-27.
3. Switzer MP, Teleb M, Agunanne E, et al. A variant of Brugada syndrome. *Proc (Bayl Univ Med Cent).* 2017;30(1):62-3.
4. Brugada R, Campuzano O, Sarquella-Brugada G, et al. Brugada Syndrome. *GeneReviews.* 2005.
5. Antzelevitch C, Brugada P, Borggrefe M, et al. Brugada syndrome: report of the Second Consensus Conference. *Heart Rhythm.* 2005;2(4):429-40.
6. Lo R, Mehta S, Witkes D, et al. Brugada Syndrome: Case Report and Review of the Literature. *EP Lab Digest.* 2004;4(6).
7. Sieira J and Brugada P. Brugada Syndrome: Defining the Risk in Asymptomatic Patients. *Arrhythm Electrophysiol Rev.* 2016;5(3):164-9.
8. Brodie OT, Michowitz Y, Belhassen B. Pharmacological Therapy in Brugada Syndrome. *Arrhythm Electrophysiol Rev.* 2018;7(2):135-42.
9. Kagolanu D, Pacas C, Jilani U, et al. Brugada Syndrome: Age is just a number. *The New York Medical Journal.* 2018;12(1).
10. Taira K, Fujino A, Watanabe T, et al. Brugada-Type Electrocardiogram in a Patient with Hypothyroidism. *J Cardiol Cases.* 2010;2(3):147-50.
11. Mizusawa Y and Wilde A. Brugada Syndrome. *Circulation: Arrhythmia and Electrophysiol.* 2012;5(6):606-16.

Spontaneous Carotid Artery Dissection Presenting as Trigeminal Neuralgia in the Emergency Department

Robert Look, MA, DO*
Thomas J. Terlau, MA†
Ryan Misek, DO*‡

*Midwestern University, Chicago College of Osteopathic Medicine, Department of Emergency Medicine, Downers Grove, Illinois

†Midwestern University, Chicago College of Osteopathic Medicine, Downers Grove, Illinois

‡Midwestern University, Chicago College of Osteopathic Medicine, Department of Clinical Education, Downers Grove, Illinois

Section Editor: John Ashurst, DO

Submission history: Submitted July 28, 2019; Revision received October 21, 2019; Accepted January 20, 2020

Electronically published April 14, 2020

Full text available through open access at http://escholarship.org/uc/uciem_cpem

DOI: 10.5811/cpem.2020.1.44664

Introduction: Carotid artery dissection (CAD) is a critical diagnosis in the emergency department (ED). Trigeminal neuralgia, while not uncommon, may cause the patient significant discomfort but generally is not attributed to severe morbidity and mortality.

Case Report: We present a case of spontaneous CAD presenting with the classic intermittent “lightning-like” jaw and head pain suggestive of trigeminal neuralgia that was ultimately diagnosed utilizing computed tomography angiogram after multiple visits to the ED.

Discussion: Coincidentally the patient had been started on anticoagulation a few days prior and no additional intervention was required.

Conclusion: This case report discusses current recommendations for diagnosis, treatment, and long-term prognosis of CAD. [Clin Pract Cases Emerg Med. 2020;4(2):255–258.]

Keywords: *Carotid Artery Dissection; Trigeminal Neuralgia.*

INTRODUCTION

Carotid artery dissection (CAD) occurs when the integrity of the arterial wall is compromised, allowing blood to collect between layers of the arterial wall forming an intramural hematoma. This can result in cerebral ischemia due to mechanical obstruction of blood flow or thromboembolism formation. CADs are categorized as spontaneous or traumatic based on history of antecedent trauma. Arterial dissections are a common cause of stroke in young patients; however, they can occur in all ages. We describe a patient who presented to the emergency department (ED) on two consecutive days with complaint of intermittent, sudden, “lightning-like,” left lower face pain. Initial non-contrast neuroimaging was unremarkable, and the patient did not have any objective neurological

deficits. Upon second visit to the ED, her pain returned and was significantly worse. Computed tomography angiography (CTA) of head and neck revealed the patient had a left internal CAD. This case describes an atypical presentation of a potentially serious condition in a patient presenting with trigeminal neuralgia-type symptoms, which could have led to life-threatening consequences if not identified and treated.

CASE REPORT

A 76-year-old Caucasian female with a past medical history of atrial fibrillation (not on anticoagulation), hypertension, chronic obstructive pulmonary disease, and obstructive sleep apnea presented to the ED complaining of intermittent, left-sided jaw and lower face pain onset that

particular morning. She described her pain as “sharp and lightning-like,” causing her to wake up in the middle of the night. Patient reported similar symptoms three months prior after she had “dental work” completed; however, she denied any recent dental procedures. She also denied any other symptoms during initial presentation. Neurologic exam was normal, including cranial nerve testing, upper and lower extremity sensorimotor function, and cerebellar testing. The patient had mild tenderness over the left side of her mandible and the jaw opened and closed without palpable clicking or grinding. Vital signs revealed a temperature of 36.4° Celsius, heart rate of 105 beats per minute, respirations of 18 breaths per minute, blood pressure of 151/101 millimeters of mercury, and pulse oximetry of 96% on room air.

The differential diagnosis included acute myocardial infarction, trigeminal neuralgia, temporal arteritis, temporomandibular joint dysfunction, herpes zoster, subarachnoid hemorrhage, dentalgia, and other causes of acute jaw pain in an elderly female patient. CTA of the head and facial bones without intravenous (IV) contrast were grossly normal. Electrocardiogram revealed rate-controlled atrial fibrillation without acute ischemic changes. Chest radiograph was clear. Laboratory analysis revealed an erythrocyte sedimentation rate of 34 millimeters per hour (mm/hr) (reference range 0-30 mm/hr); the remainder of the

CPC-EM Capsule

What do we already know about this clinical entity?

Carotid artery dissection can present in a variety of ways, ranging from unilateral headache to Horner's syndrome, and can be a severely debilitating disease.

What makes this presentation of disease reportable?

The pain associated with carotid artery dissection is usually not described as “lightning-like” jaw pain, mimicking trigeminal neuralgia or dental pain.

What is the major learning point?

Always expand your workup and differential diagnosis on patients who return multiple times for the same complaint, or with progression of disease process

How might this improve emergency medicine practice?

Including carotid artery dissection in our differential for unilateral jaw pain in patients with no intraoral, dental, or facial abnormalities on physical exam.

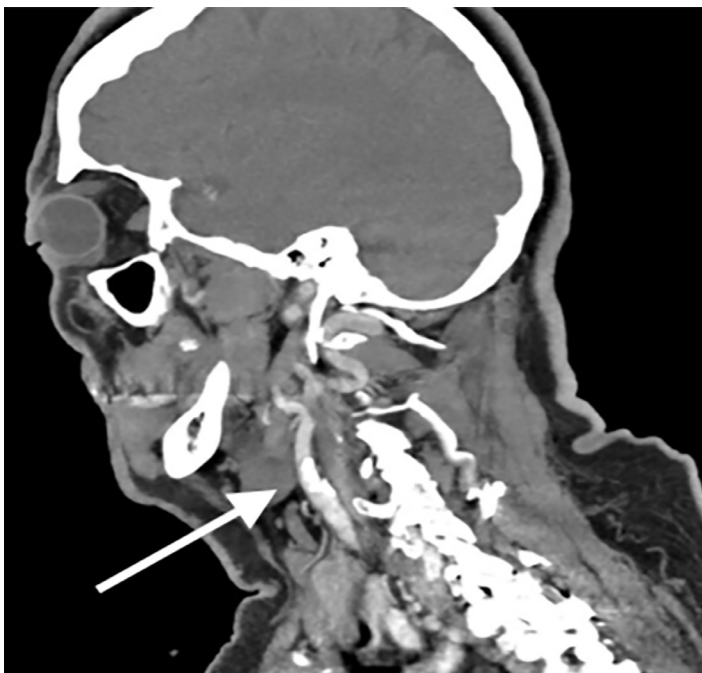

Image 1. Sagittal view of computed tomography with angiography of the head and neck identifying an intimal flap in the left internal carotid artery consistent with a carotid artery dissection.

complete blood count, complete metabolic panel, thyroid stimulating hormone, troponin-I, urinalysis, and magnesium level were unremarkable.

The patient was restarted on apixaban after speaking with her cardiologist, given her history of atrial fibrillation. Neurology was consulted about the possibility of these symptoms being representative of trigeminal neuralgia and starting carbamazepine; however, neurology requested no medication changes and for the patient to follow up with her dentist prior to outpatient neurology follow-up to rule out dental causes. Patient was ultimately discharged home with outpatient neurology and dental follow-up.

The patient returned to the ED with complaints of similar pain two days later; however, this time her left lower face and jaw pain was present leaving the patient in moderate to severe distress. Given the repeat visit and failure of outpatient therapy, early neurology consultation was obtained regarding analgesic recommendations while the workup ensued. The consulting neurologist recommended methylprednisolone 250 milligrams (mg) IV

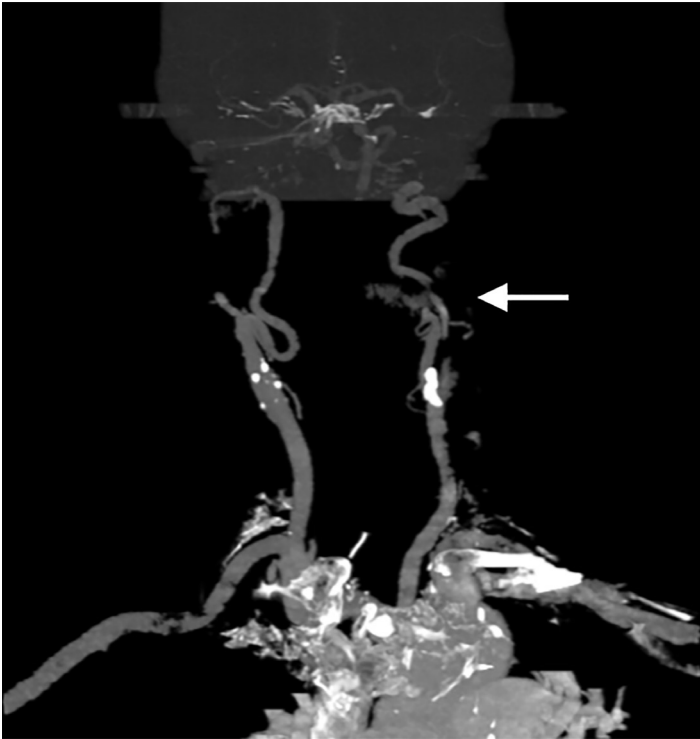


Image 2. Coronal view of computed tomography with angiography of the head and neck identifying an irregular 50-60% narrowing of proximal mid-cervical segment of left internal carotid artery with intimal flap consistent with carotid artery dissection.

and ketorolac for analgesia. The patient's pain remained refractory and IV fentanyl was given; we considered other diagnoses including CAD. CTA of the head and neck was obtained, which revealed a CAD of the left internal carotid artery (Images 1 and 2). The patient still did not exhibit any neurologic findings. Neurosurgeons whom we consulted at a tertiary-care hospital recommended continuing anticoagulation with close follow-up at their outpatient specialty clinic.

During hospitalization, the patient did not develop any neurologic deficits. Pain was controlled with IV hydromorphone and methylprednisolone 125 mg every 12 hours. She was ultimately discharged within 24 hours and continued on oral apixaban and steroids.

DISCUSSION

This patient's presenting symptoms resembled trigeminal neuralgia. Had the CTA not been performed, the CAD might have been missed. It is unclear whether the CAD was the true etiology of the patient's "lightning-like" pain or was merely a concomitant or incidental finding.

The average annual incidence rate for spontaneous internal CAD is 1.72 per 100,000 population (95% confidence interval, 1.13 to 2.32).¹ However, incidence is

thought to be underestimated due to many patients being asymptomatic.¹ While the pathophysiology of CAD is not well understood, a common theory is a multifactorial cause involving both genetic predisposition and environmental factors, such as infection or minor trauma acting as a trigger. Some evidence suggests that up to 50% of patients with CAD have autosomal dominant, skin connective-tissue abnormalities.² It is also common for patients with CAD to have concomitant arterial abnormalities suggesting a constitutional arteriopathy.² The inciting trauma for CAD has been reported to be as minor as practicing yoga, painting a ceiling, coughing, sneezing, or vomiting.³ Many patients do not recall a trauma or inciting event.³ History of recent upper respiratory infection has been suggested as a potential trigger for dissections due to the seasonal variation of their incidence, peaking in the fall.³

The most frequently encountered symptoms in CAD are headache, neck pain, cerebral ischemia (transient ischemic attack or infarct), Horner syndrome, and cranial nerve palsies.³ Recent-onset unilateral headaches with continuous pain have been considered the most important paucisymptomatic of cervical (vertebral and carotid) artery dissections.⁴ The diagnostic criteria for headache attributed to cervical artery dissection includes two of the following: temporal pain that evolves to encompass other signs of cervical artery dissection; pain that improves/resolves after one month of onset or worsens contemporarily with other signs of cervical arterial lesions; pain that is severe and continues for days (most sensitive finding) or precedes signs of acute retinal/cerebral ischemia; and/or pain that is unilateral and ipsilateral to dissected cervical artery.⁴ Unilateral neck pain is seen in about 25% of patients, and unilateral facial/orbital pain in about 50% of patients.³ Approximately 10% of pain is isolated to the face or neck; most pain will progress to a unilateral headache in the temporal and frontal regions.³

Cerebral or retinal ischemic symptoms are reported in 50-95% of patients with a spontaneous dissection of the carotid artery and are commonly preceded by transient monocular blindness.³ Sudden onset Horner syndrome is seen in less than half of patients with CAD, but is considered to be specific for CAD when it occurs in conjunction with unilateral headache or facial pain. Cranial nerve palsies are a relatively rare finding, occurring in 7-12% of CAD cases.^{2,3} When they do occur, the hypoglossal nerve is most commonly affected, but the oculomotor, trigeminal, and facial nerves may also be involved. In a retrospective study of 245 patients who were diagnosed with spontaneous cervical artery dissections, only 8% presented with pain as their only symptom.⁵ The pain was most often described as having a gradual onset and progressing into a steady ache or sharp pain.^{3,5} However, four patients reported a sudden "thunderclap" headache at the presumed time of onset.^{3,5} Literature search by the authors did not identify any previously published reports of vertebral or CAD

presenting with only the paroxysmal “lightning-like” pain resembling that of trigeminal neuralgia, making our patient’s presentation unique.

Diagnosis of CAD can be made on magnetic resonance imaging (MRI) with angiography, CTA, or conventional angiography, the latter of which has been largely replaced.² MRI with angiography is generally the preferred method; however, CTA can be used when there is limited access to MRI, such as in the ED. The acute phase of CAD is treated with either anticoagulant or antiplatelet drug therapy to prevent ischemic events. Research indicating which is better is unclear and ongoing.⁶ Treatment plans are largely made on a case by case basis.⁶ Prognosis is generally good with a mortality rate of less than 5%, and ischemic event recurrence rate of less than 13%.²

CONCLUSION

Carotid artery dissection, while uncommon, is a critical diagnosis that emergency providers should consider in patients presenting with head, neck, or jaw pain with a focal neurological deficit. When no deficit is identified, it should still be considered when risk factors such as reported trauma and genetic factors are present. It is imperative that providers maintain a broad differential and consider CTA when this diagnosis is considered, especially in the patient with multiple presentations when a causative lesion contributing to their symptoms has not yet been identified.

The signed attestation by the corresponding author that this institution does not require Institutional Review Board approval for case reports has been obtained and filed for publication of this case report.

Address for Correspondence: Robert Look, DO, PGY-2, Northwestern University, Department of Emergency Medicine, 555 31st Street, Downers Grove, IL 60515. Email: rlook72@northwestern.edu.

Conflicts of Interest: By the *CPC-EM* article submission agreement, all authors are required to disclose all affiliations, funding sources and financial or management relationships that could be perceived as potential sources of bias. The authors disclosed none.

Copyright: © 2020 Look et al. This is an open access article distributed in accordance with the terms of the Creative Commons Attribution ([CC BY 4.0](https://creativecommons.org/licenses/by/4.0/)) License. See: <http://creativecommons.org/licenses/by/4.0/>

REFERENCES

1. Lee VH, Brown RD, Mandrekar JN, et al. Incidence and outcome of cervical artery dissection: a population-based study. *Neurology*. 2006;67(10):1809-12.
2. Debette S and Leys D. Cervical-artery dissections: predisposing factors, diagnosis, and outcome. *Lancet Neurol*. 2009;8(7):668-78.
3. Schievink WI. Spontaneous dissection of the carotid and vertebral arteries. *New Engl J Med*. 2001;344(12):898-906.
4. Gallerini S, Marsili L, Bartalucci M, et al. Headache secondary to cervical artery dissections: practice pointers. *Neurol Sci*. 2019;40(3):613-5.
5. Arnold M, Cumurciuc R, Stapf C, et al. Pain as the only symptom of cervical artery dissection. *J Neurol Neurosurg Psychiatry*. 2006;77(9):1021-4.
6. Lau JT, Hunt JS, Bruner DI, et al. Cervical artery dissection and choosing appropriate therapy. *Clin Pract Cases Emerg Med*. 2017;1(3):225-8.

Diet-induced Ketoacidosis in a Non-diabetic: A Case Report

Sam Slade, DO, MBA
John Ashurst, DO, MSc

Midwestern University, Kingman Regional Medical Center, Department of Emergency
Medicine, Kingman, Arizona

Section Editor: Rick A. McPheeters, DO

Submission history: Submitted July 31 2019; Revision received February 19, 2020; Accepted February 21, 2020

Electronically published April 23, 2020

Full text available through open access at http://escholarship.org/uc/uciem_cpem

DOI: 10.5811/cpcem.2020.2.44736

Introduction: Anion gap metabolic acidosis is a common disorder seen in the emergency department. The differential can include toxicological, renal, endocrine, infectious, and cardiogenic disorders. Ketosis, however, is one of the rarer causes of metabolic acidosis seen by the emergency physician in developed nations.

Case Report: A 53-year-old female presented after starting a low-carbohydrate ketogenic diet for weight loss. She reported xerostomia, nausea with abdominal pain and a 17-pound weight loss over the previous 22 days. Labs revealed an anion-gap metabolic acidosis with ketosis. She was treated with 5% dextrose in normal saline and a sliding scale insulin coverage. Her anion gap corrected during her hospital course and was discharged on hospital day three.

Discussion: The ketogenic diet typically consists of a high-fat, adequate protein and low carbohydrate diet that has previously been thought to be relatively safe for weight loss. However, when carbohydrates are completely removed from the diet an overproduction of ketones bodies results in ketoacidosis. Treatment should be aimed at halting the ketogenic process and patient education.

Conclusion: Although rarely included in the differential for metabolic acidosis, diet-induced ketosis should be included by the emergency physician when faced with a patient who recently changed their eating patterns. [Clin Pract Cases Emerg Med. 2020;4(2):259–262.]

Keywords: *Anion-Gap Metabolic Acidosis; Ketosis; Diet-Induced Ketosis.*

INTRODUCTION

Anion gap metabolic acidosis is a common, life-threatening diagnosis in the emergency department (ED) with various potential etiologies. CAT MUD PILES is a mnemonic often used to help remember the most common causes of anion gap metabolic acidosis (Table 1). However, starvation ketosis is one of the rarer causes of ketoacidosis. Ketosis is typically prevented with diets that consist of 100 grams (g) of carbohydrates per day, and as little as 7.5 g of glucose a day can decrease ketone production. We present a case of a 53-year-old female with a high anion gap metabolic acidosis whose history and workup did not correlate with traditional causes. She was found to have a ketoacidosis caused by a zero carbohydrate diet used for weight loss. It is important to raise awareness of this disease, as the popularity of protein- and

fat-rich diets that minimize carbohydrate intake are becoming increasingly popular.

CASE REPORT

A 53-year-old female presented to the ED with six days of nausea and vomiting. She also noted feeling progressively weak with xerostomia and lower abdominal pain for several days prior to presentation. Further history revealed that she was a previous vegetarian who over the prior 22 days was attempting to lose weight by eating solely meat and eggs. She reported a 17-pound weight loss over the time period and noted that she was consuming only minimal carbohydrates. She took no medications and denied chronic alcohol use.

Her vitals upon arrival were as follows: temperature 97.1 degrees Fahrenheit, heart rate 77 beats per minute, respiratory

Table 1. Common causes of metabolic acidosis presented as a mnemonic CAT MUD PILES.

C	carbon monoxide cyanide congenital heart failure
A	aminoglycosides
T	Theophylline Toluene
M	Methanol
U	Uremia
D	Diabetic Ketoacidosis Alcoholic Ketoacidosis Starvation Ketoacidosis
P	Paracetamol/acetaminophen Phenformin Paraldehyde
I	Iron Isoniazid Inborn errors of metabolism
L	Lactic acidosis
E	Ethanol Ethylene glycol
S	Salicylates

rate 16 breaths per minute, blood pressure 160/106 millimeters of mercury, and oxygen saturation 97% on room air. She weighed 73 kilograms with her stated height of 5 feet 6 inches and had a body mass index of 26. The physical exam revealed dry mucous membranes and a benign abdominal exam.

The patient was given two liters (L) of normal saline intravenously (IV) and four milligrams of ondansetron IV for nausea. Labs were drawn due to a concern for abnormal electrolytes as well as her change in diet. Labs revealed an anion gap acidosis with ketosis (Table 2).

In the ED she received antiemetics, two L of normal saline and an infusion of D5NS at 150 cubic centimeters (cc) an hour,

CPC-EM Capsule

What do we already know about this clinical entity?

The ketogenic diet consists of a high-fat, adequate protein and low carbohydrates. When carbohydrates are removed however, ketone bodies can form, causing ketoacidosis.

What makes this presentation of disease reportable?

Although ketoacidosis is common with other disorders, diet-induced ketoacidosis is typically not included in the differential of most emergency physicians (EP).

What is the major learning point?

Diet-induced ketoacidosis should be included in patients with an unexplained metabolic acidosis and further history should be gathered into any recent dietary changes.

How might this improve emergency medicine practice?

The EDP should keep a broad differential when faced with a patient with metabolic acidosis and search for the underlying cause.

and her symptoms greatly improved. By the time she was admitted to the hospital, her gap had closed to a level of 12. She continued to receive an infusion of 5% dextrose in normal saline (D5NS) at 150 cc an hour as well as insulin subcutaneously on a sliding scale after admittance to the hospital. Her anion gap remained within the normal limits while in the hospital and her insulin was discontinued. After returning to a normal diet, her glucose remained stable and she was discharged after three days with only potassium supplement prescriptions. Since discharge, she established a balanced diet and symptoms ceased.

DISCUSSION

The ketogenic diet is a high-fat, adequate protein, low-carbohydrate diet that could be beneficial for diseases such as epilepsy, but the emergency provider is most likely to see its use during episodes of weight loss.¹ After only several days of low-carbohydrate dieting, the body depletes its glucose stores and adipose cells begin ketogenesis to supply the brain with glucose.¹ During this process, there is an overproduction of acetyl-CoA, which produces beta-hydroxybutyrate,

Table 2. Laboratory data.

Variable	Reference range, adults	On presentation to the emergency department	On admission to the hospital	Hospital day 2	Hospital day 3/ discharge
Sodium (mEq/L)	137–145	139	141	139	139
Potassium (mEq/L)	3.5–5.1	4.8	3.8	2.8	2.8
Chloride (mEq/L)	100–108	103	111	105	97
Carbon dioxide (mEq/L)	22–30	8	18	26	34
Glucose (mg/dL)	74–106	163	179	159	102
Urea nitrogen (mg/dL)	6–20	12	10	6	6
Creatinine (mg/dL)	0.52–1.04	0.70	0.60	0.50	0.50
Calcium (mg/dL)	8.4–10.2	10.2	9.1	9.0	8.8
Phosphorus (mg/dL)	2.5–4.5	N/A	2.1	1.9	2.8
Magnesium (mg/dL)	1.6–2.3	N/A	2.0	1.9	1.9
Anion gap	1–12	28	12	8	8
Osmolality, calculated (mOs/kg)	225–285	281	285	279	275
Osmolality, serum	275–295	302	N/A	N/A	N/A
Albumin (g/dL)	3.5–5.0	5.3	N/A	N/A	N/A
Alcohol, (ethanol) (mg/dL)	0–10	< 10	N/A	N/A	N/A
Acetaminophen (ug/mL)	10–30	<10	N/A	N/A	N/A
Salicylate (mg/dL)	0–2	<1	N/A	N/A	N/A
Acetone (mmol/L)	0.0–0.06	4.9	3.4	N/A	N/A
Lactic acid (mmol/L)	0.7–2.0	1.4	N/A	N/A	N/A
Urinalysis					
Leukocyte esterase	Negative	Negative	N/A	N/A	N/A
Nitrites	Negative	Negative	N/A	N/A	N/A
Protein (mg/dL)	Negative	100	N/A	N/A	N/A
Glucose (mg/dL)	Negative	50	N/A	N/A	N/A
Ketones (mg/dL)	Negative	80	N/A	N/A	N/A
Specific gravity	1.003–1.035	1.024	N/A	N/A	N/A
Arterial blood gas					
pH	7.35–7.45	7.289	N/A	N/A	N/A
pCO ₂ (mm Hg)	35.0–45.0	23.7	N/A	N/A	N/A
pO ₂ (mm Hg)	80.0–100.0	93.2	N/A	N/A	N/A
Bicarbonate (mEq/L)	22.0–26.0	11.1	N/A	N/A	N/A
Hemoglobin A1c (%)	4.0–5.6	5.8	N/A	N/A	N/A

mEq, milliequivalent; L, liter; mg, milligram; dL, deciliter; N/A, not available; mOs, milliosmoles; kg, kilogram; g, grams; ug, micrograms; mL, milliliter; mmol, millimole; pCO₂, partial pressure of carbon dioxide; mm Hg, millimeters of mercury; pO₂, partial pressure of oxygen.

acetoacetate, and acetone in the liver.¹ These ketone bodies are then used as a source of energy for the body, but their overproduction could lead to ketoacidosis.¹

Diet-induced ketosis is more likely to occur in children, and pregnant or lactating females due to lower glycogen stores, inherent insulin resistance, and increased lipolysis from pregnant and lactating females.² While starvation ketosis usually does not result in a bicarbonate level less than 18 milliequivalents per liter (mEq/L),³ our patient's initial bicarbonate level was 8 mEq/L. Based upon the patient's medical history and risk factors, she should not have reached

the stage of ketoacidosis. However, the lack of carbohydrates in her diet increased the possibility of a component of starvation ketosis.

Ketogenic diets have been proven to be safe and effective in treating obesity and have shown that patients do not develop anion gap acidosis due to the diet.⁴ A similar case related to the Atkins diet was reported in 2004 and had a similar presentation.⁵ There have been at least four more cases of low-carb, high-protein diets causing high anion gap metabolic acidosis with associated ketones in the blood or urine.⁶ All cases involved women and had a similar positive outcome.

Treatment should be aimed at halting the ketogenic process through the consumption of carbohydrates or providing the patient with intravenous fluids that contain dextrose. Patients with any underlying conditions that may cause them to be prone to ketoacidosis should avoid a ketogenic diet regimen. These conditions would include, but are not limited to, chronic alcoholism, pregnancy, lactation and diabetes. In addition, any person on the ketogenic diet should eat at least 100 g of carbohydrates a day to avoid ketoacidosis.

CONCLUSION

Diet-induced ketoacidosis is a rare disease and may be difficult to diagnose due to incomplete diet history and similarity to other common diseases. To avoid this, the patient should be asked about diet history especially in those who present with vomiting, diarrhea, and symptoms similar to diabetic ketoacidosis without a history of diabetes. Prevention is imperative with this disease and can be avoided by eating a minimum amount of carbohydrates daily. Also patients who are chronic alcoholics, pregnant, lactating, or diabetic should not participate in this diet due to a high risk of ketoacidosis.

Reference values are affected by many variables, including the patient population and laboratory methods used. The range was comprised from Kingman Regional Medical Center adults who were not pregnant and did not have medical conditions that could affect the results. Therefore, they may not be appropriate for all patients.

The authors attest that their institution requires neither Institutional Review Board approval, nor patient consent for publication of this case report. Documentation on file.

Address for Correspondence: John Ashurst, DO, MSc, Kingman Regional Medical Center, Department of Emergency Medicine, 3269 Stockton Hill Road, Kingman, AZ 86409. Email: Ashurst.john.32.research@gmail.com.

Conflicts of Interest: By the CPC-EM article submission agreement, all authors are required to disclose all affiliations, funding sources and financial or management relationships that could be perceived as potential sources of bias. The authors disclosed none.

Copyright: © 2020 Slade et al. This is an open access article distributed in accordance with the terms of the Creative Commons Attribution (CC BY 4.0) License. See: <http://creativecommons.org/licenses/by/4.0/>

REFERENCES

1. Paoli A. Ketogenic diet for obesity: friend or foe? *Int J Environ Res Public Health*. 2014;11(2):2092-107.
2. Zhou C and Byard RW. Septic ketoacidosis—a potentially lethal entity with renal tubular epithelial vacuolization. *J Forensic Sci*. 2017;62:122-12.
3. Charfen MA and Fernández-Frackelton M. Diabetic ketoacidosis. *Emerg Med Clin North Am*. 2005;23:609-28.
4. Gomez-Arbelaez D, Crujeiras AB, Castro, AI, et al. Acid–base safety during the course of a very low-calorie-ketogenic diet. *Endocr J*. 2017;58:81-90.
5. Chen T, Smith W, Rosenstock JL, et al. A life-threatening complication of Atkins diet. *Lancet*. 2006;367:958.
6. Ullah W, Hamid M, Mohammad Ammar AH, et al. Another “D” in MUDPILES? A review of diet-associated nondiabetic ketoacidosis. *J Investig Med High Impact Case Rep*. 2018;6:232470961879626.

Portal Venous Thrombosis Associated with Use of Etonogestrel/ethinyl Estradiol Vaginal Ring

Katelynn E. Bailey, DO*
Michael J. Tranovich, DO†

*Charleston Area Medical Center, Department of Emergency Medicine, Charleston, West Virginia

†Allegheny Health Network, Department of Emergency Medicine, Canonsburg, Pennsylvania

Section Editor: Rick A. McPheeters, DO

Submission history: Submitted July 31, 2019; Revision received December 30, 2019; Accepted January 1, 2020

Electronically published April 14, 2020

Full text available through open access at http://escholarship.org/uc/uciem_cpem

DOI: 10.5811/cpcem.2020.1.44654

Introduction: Portal venous thrombosis is a life-threatening cause of abdominal pain. In younger patients, heritable thrombophilias, pregnancy, tobacco use, and oral contraceptives are associated.

Case Report: A 26-year-old woman prescribed contraceptive vaginal ring presented with abdominal pain and was diagnosed with an extensive portal venous thrombosis. Management included heparin and later an oral anticoagulant with good short-term outcome.

Discussion: Women using hormonal contraception are approximately four times more likely to develop thromboembolism. Risk of thromboembolism is similar between users of intravaginal and oral contraceptives.

Conclusion: Portal venous thrombosis must be considered in women presenting with abdominal pain who are prescribed hormonal contraceptives, including intravaginal forms. [Clin Pract Cases Emerg Med. 2020;4(2):263–266.]

Keywords: *portal venous thrombosis; etonogestrel/ ethinyl vaginal ring; contraception; complications.*

INTRODUCTION

Abdominal pain continues to be one of the most common complaints evaluated in the emergency department (ED) in the United States. According to Meltzer et al abdominal pain comprised approximately 23 million visits to the ED in one year.¹ Comparatively, mesenteric venous thrombosis is a relatively rare condition, accounting for less than 0.02% of all hospital admissions.^{2,3} The mean age of mesenteric thrombosis is 45-60 years, with a large proportion occurring in the sixth and seventh decades.²⁻⁴ In younger individuals, mesenteric thrombosis is often associated with the following: heritable thrombophilias (e.g., protein C or protein S deficiency); acquired thrombophilias (e.g., pregnancy or medication use, commonly oral contraceptives); intra-abdominal causes (e.g., cirrhosis or trauma); or idiopathic causes.² This is a case of a 26-year-old woman who presented to the ED with right upper quadrant abdominal pain due to extensive thrombus within

the superior mesenteric, main portal, distal splenic, and intrahepatic portal veins. After extensive diagnostic testing, the only identified thrombotic risk factor was the use of an etonogestrel/ethinyl estradiol vaginal ring (NuvaRing).

CASE REPORT

A 26-year-old woman without medical history presented to the ED due to abdominal pain for approximately 12 hours. The patient reported no tobacco use, and her only prescribed medication was the etonogestrel/ethinyl estradiol intravaginal ring. The patient had been evaluated earlier in the day at an urgent care facility; the urgent care provider then sent the patient to the ED for an apparent abnormal urinalysis (UA). In the ED, she was complaining of mid-epigastric and right upper quadrant abdominal pain along with continued nausea. She also noted back pain, a headache, and bilateral upper extremity numbness since that morning. She noted her bilateral upper extremity numbness

and headache had become intermittent. She denied any associated diarrhea, constipation, dysuria, fever, chills, recent travel, or trauma.

The patient's vital signs included the following: temperature 98.0° Fahrenheit; heart rate 76 beats per minute; respirations 18 breaths per minute; blood pressure 129/53 millimeters of mercury; and pulse oximetry 98% on room air. On physical exam, she exhibited moderate tenderness to palpation of the right upper quadrant and epigastric area. The remainder of the physical exam was unremarkable.

There were no considerable lab abnormalities except for "small" bilirubin noted on the UA. Urine pregnancy test was negative. The patient had a computed tomography (CT) of the abdomen/pelvis with intravenous (IV) contrast, which demonstrated an extensive thrombus within the superior mesenteric vein, extending into the main portal vein, intrahepatic portal veins, and distal splenic vein (Image 1). She was administered IV heparin 5800 units bolus and a continuous IV heparin infusion of 18 units per kilogram per hour. She was then transferred to a tertiary care center.

At the tertiary care center, the patient was maintained on the heparin infusion until she was later transitioned to rivaroxaban. The patient underwent extensive hematologic testing including the following: protein C; protein S; anti-thrombin III; alpha fetoprotein, homocysteine; factor 5 gene mutation; prothrombin gene mutation; anti-cardiolipin antibody IgG and IgM by ELISA; anti-beta2-GP I antibody; JAK2 V617F mutation; and mutation in exon 12 of JAK2. No abnormalities were detected. The patient also had normal venous Doppler studies of the bilateral upper and lower extremities. Ultimately she was discharged home on hospital day 3 on rivaroxaban 15 milligrams twice daily with hematology follow-up and discontinuation of hormonal contraception.

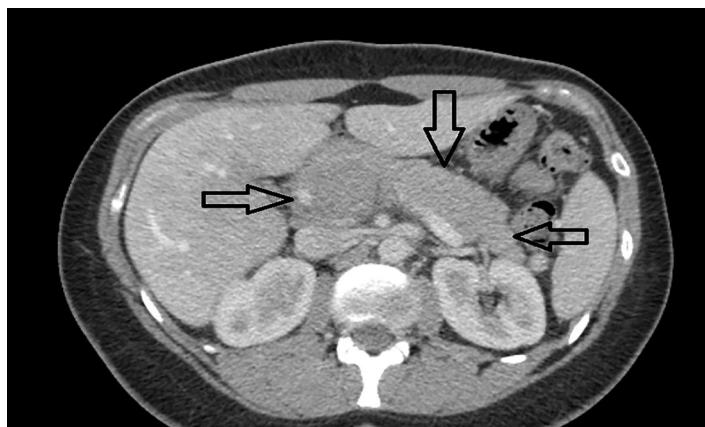


Image. Axial image of abdominal/pelvis computed tomography with contrast demonstrates the thrombus, indicated by the black arrows, in the superior mesenteric vein and extending toward the splenic vein.

CPC-EM Capsule

What do we already know about this clinical entity?

Portal venous thrombosis is well studied in the literature and has known risk factors such as age, heritable and acquired coagulopathies, and idiopathic causes.

What makes this presentation of disease reportable?

This patient's only risk factor predisposing her to a large portal venous thrombosis was the use of an etonogestrel/ ethinyl estradiol vaginal ring contraceptive.

What is the major learning point?

Emergency physicians should be cognizant that all forms of contraception with exogenous hormones expose patients to a risk of significant thrombosis.

How might this improve emergency medicine practice?

Practitioner awareness regarding thrombotic risk related to all forms of hormonal contraception, including intravaginal forms, may assist in accurate diagnosis.

DISCUSSION

The clinical presentation, diagnosis, and management of portal and mesenteric venous thrombosis has been thoroughly investigated in the literature. In the acute setting, mesenteric venous thrombosis most commonly causes abdominal pain in 91-100% of cases.⁵ The test of choice for the diagnosis of mesenteric venous thrombosis is a contrast-enhanced CT.⁶ Laboratory testing is not especially helpful as most tests do not correlate specifically to the diagnosis of mesenteric thrombus.⁵ Once the diagnosis is established, treatment includes resolving the current thrombus and preventing further thrombotic events. Anticoagulation with low-molecular-weight heparin as soon as the diagnosis is made has been shown to improve survival.⁷ Transitioning to an oral anticoagulant is then performed. According to the 2016 CHEST guidelines, patients with venous thromboembolism should be treated for a minimum of six months. These guidelines are commensurate with those set forth by the European

Association for the Study of the Liver, specifically for mesenteric thrombus.^{8,9} After the acute thrombotic event has been stabilized, the patient requires hematologic testing to assess for prothrombotic diseases.⁵

Women using hormonal contraception are approximately four times more likely to develop venous thromboembolism compared to women not prescribed hormonal contraception.¹⁰ Studies report the association between hormonal contraception and increased risk of thromboembolism is related to the alteration of procoagulant factors and endogenous anticoagulant proteins. The estrogen components of hormonal contraception seem to cause an increase in the procoagulant factors II, VII, VIII, X and fibrinogen, and a decrease in antithrombin and tissue factor pathway inhibitor activity.^{11,12} It should be noted that the formulation, administration route, dose, and progesterone type (in combined formulations), all affect the overall risk of thrombosis.^{11,12} There is a general misnomer that non-oral forms of hormonal contraception (e.g., etonogestrel/ethinyl estradiol vaginal ring) have a lower risk of thrombotic events compared to oral contraception.

The Transatlantic Active Surveillance on Cardiovascular Safety of NuvaRing study, published in 2013, did not specifically report episodes of mesenteric venous thrombosis, although it did report that episodes of venous and arterial thromboembolism were similar between clinical users of intravaginal contraceptive rings and oral contraceptives.¹³ While mesenteric thrombosis associated with intravaginal contraception is rare, two similar cases have been reported in the literature.^{14,15} In addition, when obtaining medication history from patients, non-oral medications can often be missed or discounted by clinicians. Although research is somewhat limited, the etonogestrel/ethinyl estradiol vaginal ring does appear to have the same amount of cardiovascular risk associated with its use as its well-studied counterpart, oral contraceptive pills.¹³

CONCLUSION

This case highlights that women without known, primary thrombotic risk factors can still suffer major, life-threatening thrombosis when using hormonal contraception, regardless of form. The diagnosis of mesenteric and portal venous thrombosis must be considered in women presenting with abdominal pain who are prescribed hormonal contraceptives, including intravaginal forms.

The documented attestation from the authors that their institution requires neither Institutional Review Board approval, nor patient consent for publication of this case report has been obtained and filed.

Address for Correspondence: Katelynn E. Bailey, DO, MSc, Charleston Area Medical Center, Department of Emergency Medicine, 3110 MacCorkle Ave SE, Charleston, WV 25304. Email: Katelynn.Bailey@camc.org.

Conflicts of Interest: By the *CPC-EM* article submission agreement, all authors are required to disclose all affiliations, funding sources and financial or management relationships that could be perceived as potential sources of bias. The authors disclosed none.

Copyright: © 2020 Bailey et al. This is an open access article distributed in accordance with the terms of the Creative Commons Attribution ([CC BY 4.0](http://creativecommons.org/licenses/by/4.0/)) License. See: <http://creativecommons.org/licenses/by/4.0/>

REFERENCES

- Meltzer AC, Pines JM, Richards LM, et al. US emergency department visits for adults with abdominal and pelvic pain (2007-13): Trends in demographics, resource utilization and medication usage. *Am J Emerg Med.* 2017;35(12):1966-9.
- Harnik IG and Brandt LJ. Mesenteric venous thrombosis. *Vasc Med.* 2010;15(5):407-18.
- Russell CE, Wadhwa RK, Piazza G. Mesenteric venous thrombosis. *Circulation.* 2015;131(18):1599-603.
- Acosta S, Alhadad A, Svensson P, et al. Epidemiology, risk and prognostic factors in mesenteric venous thrombosis. *Br J Surg.* 2008;95(10):1245-51.
- Hmoud B, Singal AK, Kamath PS. Mesenteric venous thrombosis. *J Clin Exp Hepatol.* 2014;4(3):257-63.
- Grant PJ, Courey AJ, Hanigan S, et al. Special topics in venous thromboembolism [Internet]. Ann Arbor (MI): Michigan Medicine University of Michigan. 2019. Available at: <https://www.ncbi.nlm.nih.gov/books/NBK544377/>. Accessed July 28, 2019.
- Condat B, Pessione F, Denninger MH, et al. Recent portal or mesenteric venous thrombosis: increased recognition and frequent recanalization on anticoagulant therapy. *Clin Liver Dis.* 2003;32(3):466-70.
- Intagliata NM, Caldwell SH, Tripodi A. Diagnosis, development, and treatment of portal vein thrombosis in patients with and without cirrhosis. *Gastroenterology.* 2019;156(6):1582-99.
- Kearon C, Akl EA, Ornelas J, et al. Antithrombotic therapy for VTE disease: CHEST guideline and expert panel report. *Chest.* 2016;149(2):315-52.
- Sitruk-Ware R. Hormonal contraception and thrombosis. *Fertil Steril.* 2016;106(6):1289-94.
- Klok FA and Barco S. Optimal management of hormonal contraceptives after an episode of venous thromboembolism. *Thromb Res.* 2019;181 Suppl 1:S1-S5.Tc.
- Tchaikovski SN and Rosing J. Mechanisms of estrogen-induced

- venous thromboembolism. *Thromb Res.* 2010;126(1):5-11.
13. Dinger J, Mohner S, Heinemann K. Cardiovascular risk associated with the use of an etonogestrel-containing vaginal ring. *Obstet Gynecol.* 2013;122(4):800-8.
14. Eilbert W, Hecht B, Zuiderveld L. Acute mesenteric venous thrombosis with a vaginal contraceptive ring. *West J Emerg Med.* 2014;15(4):395-7.
15. Voora D and Vijayan A. Mesenteric vein thrombosis associated with intravaginal contraceptives: a case report and review of the literature. *J Thromb Thrombolysis.* 2003;15(2):105-8.

Subacute Presentation of Central Cord Syndrome Resulting from Vertebral Osteomyelitis and Discitis: A Case Report

Thomas Dang, BA*
Fanglong Dong, PhD*
Greg Fenati, DO*†
Massoud Rabiei, BS*
Melinda Cerda, MM*
Michael M. Neeki, DO, MS*†

*Arrowhead Regional Medical Center, Department of Emergency Medicine, Colton, California
†California University of Science and Medicine, Department of Emergency Medicine, San Bernardino, California

Section Editor: John Ashurst, DO

Submission history: Submitted June 21, 2019; Revision received none; Accepted August 30, 2019

Electronically published April 23, 2020

Full text available through open access at http://escholarship.org/uc/uciem_cpccem

DOI: 10.5811/cpcem.2019.8.44201

Introduction: Central cord syndrome (CCS) is a clinical syndrome of motor weakness and sensory changes. While CCS is most often associated with traumatic events. There have been few documented cases being caused by abscesses resulting from osteomyelitis.

Case Report: A 56-year-old male presented to a regional trauma center complaining of excruciating neck and bilateral upper extremity pain. Computed tomography of the cervical and thoracic regions revealed severe discitis and osteomyelitis of the fourth and fifth cervical (C4-C5) with near-complete destruction of the C4 vertebral body, as well as anterolisthesis of C4 on C5 causing compression of the central canal. Empiric intravenous (IV) antibiotic therapy with ampicillin/sulbactam and vancomycin was initiated, and drainage of the abscess was scheduled. After the patient refused surgery, he was planned to be transferred to a skilled nursing facility to receive a six-week course of IV vancomycin therapy. A month later, patient returned to emergency department with the same complaint due to non-compliance with antibiotic therapy.

Discussion: Delayed diagnosis and treatment of osteomyelitis can result in devastating neurological sequelae, and literature supports immediate surgical debridement. Although past evidence has suggested surgical intervention in similar patients with presence of abscesses, this case may suggest that antibiotic treatment may be an alternative approach to the management of CCS due to an infectious etiology. However, the patient had been non-compliant with medication, so it is unknown whether there was definite resolution of the condition.

Conclusion: In patients presenting with non-traumatic central cord syndrome, it is vital to identify risk factors for infection in a thoroughly obtained patient history, as well as to maintain a low threshold for diagnostic imaging. [Clin Pract Cases Emerg Med. 2020;4(2):267–271.]

Keywords: *central cord syndrome; vertebral osteomyelitis; discitis; case report.*

INTRODUCTION

Central cord syndrome (CCS) is a clinical syndrome of motor weakness and sensory changes that presents disproportionately greater in the upper extremities as compared to the lower extremities.¹⁻³ While CCS is most often associated with traumatic events, there also have been

a few documented cases being caused by other types of lesions such as demyelination or abscesses resulting from osteomyelitis.⁴ Cases of cervical osteomyelitis and the associated CCS are rare. We present a unique case of subacute CCS in a 56-year-old male with cervical vertebral osteomyelitis and discitis who recovered from his

symptoms with conservative management and without any recommended surgical intervention.

CASE REPORT

A 56-year-old male presented to a regional trauma center complaining of excruciating neck and bilateral upper extremity pain. He described a progressive weakness for the preceding month and specifically noted being unable to flex or abduct his bilateral shoulders without lying supine, necessitating assistance to complete activities of daily living. Patient history revealed poorly controlled type II diabetes mellitus, hepatitis C, methamphetamine use, and a history of remote intravenous (IV) heroin use. He reported progressively worsening generalized fatigue and constipation over the prior few months. In addition, he was experiencing mild persistent odynophagia without dysphagia. He denied any fevers, chills, bowel or bladder incontinence, shortness of breath, or focal weakness in the lower extremities.

On presentation, the patient was oriented and presented with a blood pressure 123/80 millimeters of mercury, heart rate 89 beats per minute, respiratory rate 18 breaths per minute, temperature 98.3° Fahrenheit, and oxygen saturation 99% on room air. Physical examination revealed tenderness to palpation of the cervical region midline at the levels of the C3-C5 spinous processes. No step off or any obvious abnormality was noted in the cervical region. Motor strength was noted to be 4+/5 in the bilateral upper extremities with decreased shoulder abduction and flexion, as well as decreased sensation to pinprick over the right C4 and C5 dermatomes. The rest of the physical and neurological exam was within normal limits.

Complete blood count revealed normal white blood cell count, elevated erythrocyte sedimentation rate of 52 millimeters per hour (mm/h) [normal range 0-15 mm/h], normal C-reactive protein level, and mild anemia with a hemoglobin of 12.5 grams per deciliter (g/dL) [normal range 13.5-17.5 g/dL] and hematocrit of 36.7 [normal range 41%-50%]. Additional tests provided evidence of poorly controlled diabetes, including 4+ glucose in urine, random serum glucose of 219 milligrams per deciliter, and HgbA1C of 9.7%.

Computed tomography (CT) of the cervical and thoracic regions without contrast revealed evidence of severe discitis and osteomyelitis of C4-C5 with near-complete destruction of the C4 vertebral body, as well as anterolisthesis of C4 on C5 causing narrowing of the central canal (Image 1). Additionally, there appeared to be prevertebral, soft tissue swelling that was concerning for retropharyngeal abscess. Follow-up magnetic resonance imaging (MRI) with and without gadolinium of the cervical, thoracic, and lumbar spine confirmed the earlier CT findings of C4-C5 discitis and osteomyelitis with confirmation of surrounding prevertebral and epidural abscess (Image 2). In addition, MRI confirmed evidence of cord compression, although there was no signal change within the cord itself. Given these findings, the neurosurgery service recommended biopsy of the area

CPC-EM Capsule

What do we already know about this clinical entity?

Central cord syndrome (CCS) is a clinical syndrome of motor weakness and sensory changes that can result in potentially devastating neurological sequelae.

What makes this presentation of disease reportable?

While CCS is associated with traumatic events, patients may present with subtle neurological deficits without an obvious inciting event.

What is the major learning point?

CCS requires timely diagnosis and treatment to prevent further neurological damage. In patients with risk for infection, early diagnosis may prevent increased morbidity.

How might this improve emergency medicine practice?

Early diagnosis of CCS caused by infection may allow alternative, non-surgical management that improves patient outcome.

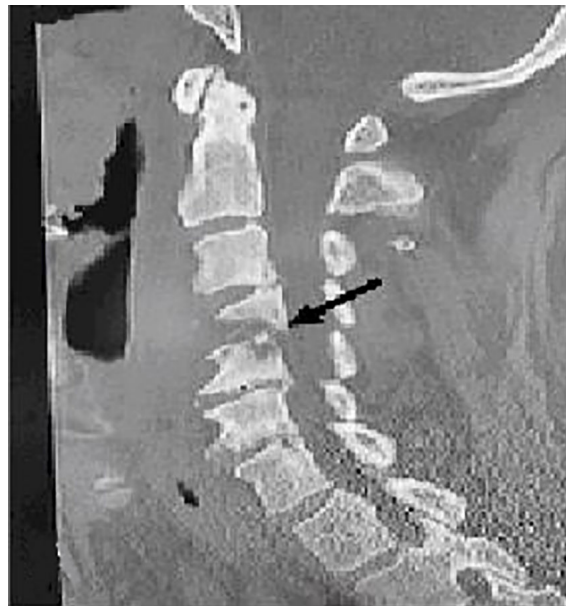

Image 1. Computed tomography scan of sagittal plane of cervical spine showing fourth and fifth cervical osteomyelitis (arrow) upon admission.

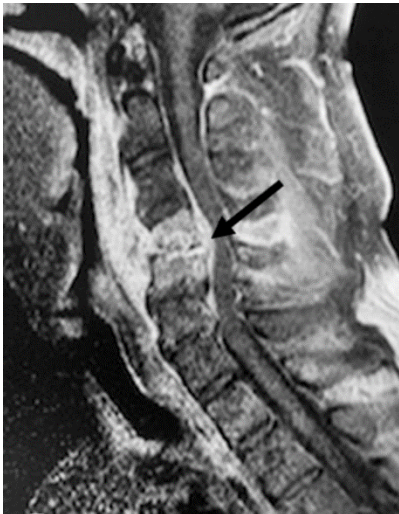

Image 2. Magnetic resonance imaging of sagittal plane of cervical spine showing fourth and fifth cervical osteomyelitis (arrow) upon admission.

around the cervical spine and to defer the initiation of antimicrobial therapy until after the biopsy was obtained.

Following the neurosurgery recommendation, interventional radiology was consulted to perform the biopsy but declined the procedure, citing risks associated with any interventions around the cervical spine. Subsequently, empiric IV antibiotic therapy of 3 gram (g) of ampicillin/sulbactam (every six hours) daily and 1.25 g of vancomycin twice daily was initiated for 10 days per infectious disease recommendations, and incision and drainage of the abscess with concurrent vertebral lesion biopsy was scheduled by neurosurgery.

On the day of the scheduled surgery, the patient stated that he no longer wished to proceed with the planned procedure. Given the patient's refusal to proceed with surgical intervention, the decision was made to discharge him to a skilled nursing facility (SNF) with a peripherally inserted central catheter for a six-week treatment of IV antibiotics of vancomycin 1 g twice daily via peripherally inserted central line, along with strict cervical spine precautions that included cervical orthosis. Blood cultures remained negative throughout the course of the patient's SNF stay, and infectious workup including chest radiograph, urine culture, and echocardiogram were noncontributory in identifying the primary source of infection. By the time of his discharge, 10 days later, the patient's bilateral upper extremity weakness improved, and he reported decreased neck and arm pain.

About a month later, he once again returned to the emergency department with complaints of neck and back pain, which revealed he had been noncompliant with the antibiotic regiment previously prescribed. He refused any further workup and signed himself out against medical advice. Two years after the event, the patient presented to the

same facility with complaint of chronic cervical pain, and a cervical CT without contrast revealed fusion of C4-C5 vertebrae (Image 3).

DISCUSSION

Patients with CCS differ widely in presentation with varying sensory loss below the level of injury and may present with or without bladder dysfunction.^{1,2,5} It is most commonly associated with traumatic injuries, as approximately 9% of all traumatic spinal cord injuries result in CCS. It is particularly prevalent in older patients suffering cervical hyperextension injuries in the setting of high-velocity trauma.^{1,2,5-8} Despite its association with traumatic causes, there have been documented cases of CCS resulting from infection such as osteomyelitis and discitis.⁴

Osteomyelitis is a serious condition that rarely affects the spine, representing about 1% of all bone infections.³ Osteomyelitis presents a significant risk to patients, as infection can extend to a contiguous site, leading to discitis or abscesses.⁹ Among these incidents, cases confined to the cervical region represent only 3-6% of cases of spinal osteomyelitis.³ Despite their lower incidence, cervical infections are often associated with worse neurological outcomes, which may be related to the potential for more dynamic motion of the cervical spine compared to the thoracic or lumbar spine.¹⁰

There have been documented incidences of cervical epidural abscesses in literature, but very scant presentations

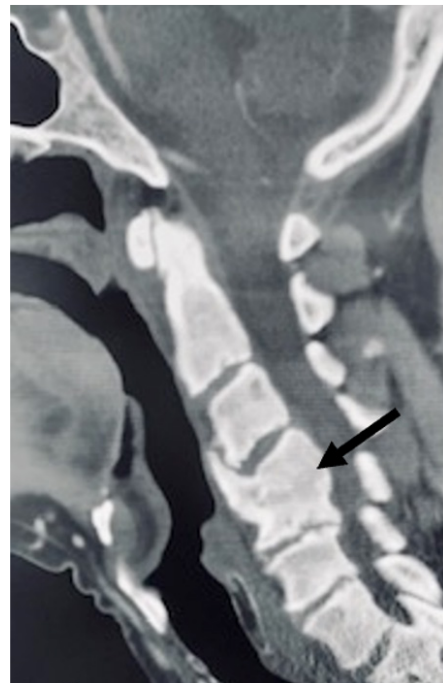


Image 3. Computed tomography scan of sagittal plane of cervical spine showing fourth and fifth cervical fusion (arrow) two years after initial presentation.

Table. Summary of previous published case reports involving cervical spine abscess with sub-acute neurological symptoms, detailing age and gender, relevant comorbidities, level of infection, presentation, outcome, and duration of original onset.*

Author(s)	Age/ gender	Relevant comorbidities	Level of infection	Presentation	Treatment	Outcome	Primary source of infection	Onset
Trombly and Guest, 2007 ¹¹	60M	80 Pack-years smoking	C5-C7	Loss of sensation in arms bilaterally, unable to move arms or legs	Surgery, 6 Weeks of antibiotics	Independent walking in 2-3 weeks	None identified	One month of non-specific neurological symptoms
Schimmer et al, 2002 ³	65M	Unknown	C4-C5	Tetraplegia	Surgery	Continued complete neurological injury	Unknown	Tetraplegia for at least two days
Ahlback et al, 1970 ¹²	44F	Diabetes mellitus	C1-C2	Cervical pain, stiffness, limited ROM, neurological symptoms	Cervical collar, antibiotics	Residual cervical stiffness and limited ROM at 7-year follow-up	Left otitis media	6-weeks post-tonsillectomy
Zigler et al, 1987 ¹²	56F	Chronic renal failure, CHF	C1-C2	Hyperreflexia, positive Babinski sign	Soft collar, surgery	Full recovery, died shortly later due to CHF/ Pneumonia	Cat scratch in left leg leading to septicemia	2 Weeks
Limbird et al, 1988 ¹²	61M	Hypertension, Renal Failure	C1-C2	Neck pain, central cord syndrome	Halo traction, antibiotics	Death secondary to myocardial infarction	None identified	3 Months
Azizi et al, 1995 ¹²	65M	Diabetes mellitus, cranial nerve abnormalities	Clivus-C1	Right ptosis, abducens nerve palsy, left facial weakness, cervical/ shoulder pain	Halo neck stabilizer, antibiotics	Residual abducens palsy with otherwise full recovery	Left otitis externa	6 Months
Fukutake et al, 1998 ¹²	74M	Cervical spondylosis	C1-C2	Fever, cervical pain, difficulty ambulating, numbness in upper extremity	Antibiotics, surgery	Full resolution at 3 months	Post-TURP procedure, pneumonia	1 Month
Kuriomoto et al, 1998 ¹²	72F	Diabetes mellitus	C2	Afebrile, cervical pain and stiffness, right hemiparesis	Steroids, insulin, Antibiotics, Surgery	Right hemiparesis persisted	Non identified	2 Weeks
Yuceer et al, 2000 ¹²	72M	HIV	C2-C3	Neck pain and 4 limb weakness	Decompression and antibiotics	Full resolution by 6 months	Bilateral pneumonia	20 Days

*M, male; F, female; C, cervical; ROM, range of motion; TURP, transurethral resection of the prostate; CHF, congestive heart failure; HIV, human immunodeficiency virus.

with the subacute nature of this case of CCS (Table). Trombly and Guest documented a CCS secondary to an underlying vertebral osteomyelitis and epidural abscess, but the patient had the abrupt onset of symptoms secondary to minor trauma.¹¹ Schimmer et al retrospectively studied 15 patients with osteomyelitis of the cervical spine and of the nine patients presenting with neurological symptoms, only one had been experiencing neurologic symptoms for at least

two days – the remaining eight had sought medical attention within 24 hours of onset of neurological deficit.³ However, over a third of the patients had been experiencing worsening neck pain over several weeks with one of them experiencing pain for as long as four months, although these were present without coinciding neurological symptoms.³ Similarly, Khalid et al reviewed cases of upper cervical epidural abscesses, and few were associated with neurological symptoms that were

subacute in onset.¹² Of the cases that had at least two weeks of neurological symptoms prior to presentation, only one presented with CCS similar to the patient described above.¹²

Although rare, cases of pyogenic spinal vertebrae infections are on the rise, which is associated to increased life expectancy and higher prevalence of comorbidities with aging that result in immunosuppression.^{13,14} Misdiagnosis and delayed diagnosis can lead to devastating neurological sequelae, which is more significant when the cervical spine is involved; therefore, appropriate treatment should be initiated as soon as possible.¹⁵ Literature supports immediate surgical debridement in traumatic cases of osteomyelitis and epidural abscesses, even in the absence of neurological symptoms.^{3,15} While past studies suggest surgical intervention in this patient due to the presence of abscesses, he ultimately refused the procedure, and treatment consisting of antibiotic therapy provided initial relief of symptoms. However, it should be taken into consideration that the patient had been non-compliant with medication and follow-up, so it is unknown whether there was definite resolution of the condition. Nevertheless, this case may suggest that conservative antibiotic treatment may be an alternative approach to immediate surgical intervention in CCS due to infectious etiology.

CONCLUSION

Pyogenic spinal vertebrae infections are rare, but they can present as a subacute cause of neurological symptoms, especially when the cervical spinal cord is affected. In patients presenting with non-traumatic central cord syndrome, it is vital to identify risk factors for infection in a thoroughly obtained patient history, as well as to maintain a low threshold for diagnostic imaging.

ACKNOWLEDGEMENTS

The authors thank Tristen Burt for their contributions in writing and editing.

The documented Institutional Review Board approval has been obtained and filed.

REFERENCES

1. Harrop JS, Sharan A, Rattliff J. Central cord injury: pathophysiology, management, and outcomes. *Spine J*. 2006;6(6 Supplement):S198-206.
2. Schneider RC, Thompson JM, Bebin J. The syndrome of acute central cervical spinal cord injury. *J Neurol Neurosurg Psychiatry*. 1958;21(3):216-27.
3. Schimmer RC, Jeanneret C, Nunley PD, et al. Osteomyelitis of the cervical spine: a potentially dramatic disease. *Clin Spine Surg*.

Address for Correspondence: Michael M. Neeki, DO, MS
Arrowhead Regional Medical Center, Department of Emergency
Medicine, 400 N. Pepper Ave., Colton, CA 92324. Email:
armcemresearch@gmail.com.

Conflicts of Interest: By the CPC-EM article submission agreement, all authors are required to disclose all affiliations, funding sources and financial or management relationships that could be perceived as potential sources of bias. The authors disclosed none.

Copyright: © 2020 Dang et al. This is an open access article distributed in accordance with the terms of the Creative Commons Attribution (CC BY 4.0) License. See: <http://creativecommons.org/licenses/by/4.0/>

- 2002;15(2):110.
4. Dhandapani S, Karthigeyan M, Sahoo SK, et al. Tectal glioma presenting with clinical triad of obesity, amenorrhea and central cord syndrome with radiological pentad of hydrocephalus, empty sella, suprapineal diverticula, Chiari and syrinx. *Childs Nerv Syst*. 2017;33(2):385-7.
5. Schneider RC, Cherry G, Pantek H. The syndrome of acute central cervical spinal cord injury; with special reference to the mechanisms involved in hyperextension injuries of cervical spine. *J Neurosurg*. 1954;11(6):546-77.
6. McKinley W, Santos K, Meade M, et al. Incidence and outcomes of spinal cord injury clinical syndromes. *J Spinal Cord Med*. 2007;30(3):215-24.
7. Nowak DD, Lee JK, Gelb DE, et al. Central cord syndrome. *J Am Acad Orthop Surg*. 2009;17(12):756-65.
8. Stevenson CM, Dargan DP, Warnock J, et al. Traumatic central cord syndrome: neurological and functional outcome at 3 years. *Spinal Cord*. 2016;54(11):1010-5.
9. Akhondi H and Baker MB. Epidural abscess. In: *StatPearls*. Treasure Island (FL): StatPearls Publishing; 2019.
10. Stricsek G, Iorio J, Mosley Y, et al. Etiology and surgical management of cervical spinal epidural abscess (SEA): a systematic review. *Glob Spine J*. 2018;8(4 Suppl):59S-67S.
11. Trombly R and Guest JD. Acute central cord syndrome arising from a cervical epidural abscess: case report. *Neurosurgery*. 2007;61(2):E424.
12. Al-Hourani K, Al-Aref R, Mesfin A. Upper cervical epidural abscess in clinical practice: diagnosis and management. *Glob Spine J*. 2016;06(04):383-93.
13. Sebben AL, Graells XS, Benato ML, et al. High cervical spine spondylodiscitis management and literature review. *Rev Assoc Médica Bras*. 2017;63(1):18-20.
14. Chao D and Nanda A. Spinal epidural abscess: a diagnostic challenge. *Am Fam Physician*. 2002;65(7):1341.
15. Mackenzie A, Laing R, Smith C, et al. Spinal epidural abscess: the importance of early diagnosis and treatment. *J Neurol Neurosurg Psychiatry*. 1998;65(2):209-12.

**JOIN
CAL/AAEM!**



CALAAEM

CALIFORNIA CHAPTER DIVISION OF THE
AMERICAN ACADEMY OF EMERGENCY MEDICINE

*Championing
individual physician rights
and workplace fairness*

BENEFITS

- *Western Journal of Emergency Medicine* Subscription
- CAL/AAEM News Service email updates
- Discounted AAEM pre-conference fees
- And more!

CAL/AAEM NEWS SERVICE

- Healthcare industry news
- Public policy
- Government issues
- Legal cases and court decisions

In collaboration with our official journal

WestJEM Integrating Emergency Care
with Population Health



FACEBOOK.COM/CALAAEM



FOLLOW US @CALAAEM

[HTTP://WWW.CALAAEM.ORG](http://www.calaaem.org)



ADVANCED >

INSPIRED

> CALIFORNIA ACEP'S ANNUAL CONFERENCE 2020

Education is targeted to Medical Students and Residents, but all are welcome to attend.

Friday, September 25, 2020

Westin San Diego Gaslamp Quarter



CALIFORNIA ACEP
AMERICAN COLLEGE OF EMERGENCY PHYSICIANS