

Colocutaneous Fistula after Percutaneous Endoscopic Gastrostomy (PEG) Tube Insertion

Matthew Warner, MD
Muhammad Durrani, DO, MS

Inspira Medical Center, Department of Emergency Medicine, Vineland, New Jersey

Section Editor: Rick A. McPheeters, DO

Submission history: Submitted May 20, 2020; Revision received July 8, 2020; Accepted July 24, 2020

Electronically published October 5, 2020

Full text available through open access at http://escholarship.org/uc/uciem_cpem

DOI: 10.5811/cpem.2020.7.48335

Case Presentation: A 48-year-old-female presented to the emergency department with dislodgement of her percutaneous endoscopic gastrostomy (PEG) tube, necessitating bedside replacement. Replacement was done without difficulty and gastrografen radiography was obtained to confirm positioning. Radiography revealed contrast filling the colon at the splenic flexure and proximal descending colon suggestive of colocutaneous fistula formation.

Discussion: The patient required hospitalization with surgical consultation, initiation of parenteral nutrition, and conservative management of the fistula with surgical replacement of the PEG tube. Although rare, it is paramount for the emergency physician to be aware of this complication when undertaking bedside replacement of PEG tubes. [Clin Pract Cases Emerg Med. 2020;4(4):632–633.]

Keywords: *Colocutaneous fistula; percutaneous endoscopic gastrostomy; parenteral nutrition.*

CASE PRESENTATION

A 48-year-old female with past medical history of failure to thrive requiring percutaneous endoscopic gastrostomy (PEG) tube placement presented to the emergency department (ED) with PEG tube dislodgement. Her PEG tube was initially placed in 2009, with surgical replacements in 2012 and 2018. Examination revealed a soft, nontender, non-distended abdomen with an open gastrostomy tract. ED course included placement of a new gastrostomy tube into the existing tract and confirmatory gastrografen radiography (Image).

DISCUSSION

The confirmatory radiography revealed contrast filling the colon at the splenic flexure and proximal descending colon suggestive of colocutaneous fistula formation, without peritoneal extravasation. This required hospitalization with surgical consultation for removal of the misplaced PEG tube, initiation of parenteral nutrition, intravenous antibiotics, and surgical reinsertion of the PEG tube after conservative management of the colocutaneous fistula. Colocutaneous fistulas are a rare complication of PEG tube insertion with incidence rates of 0.5-3%.¹ Fistula formation is mediated by PEG tube penetration of interposed colon between the stomach

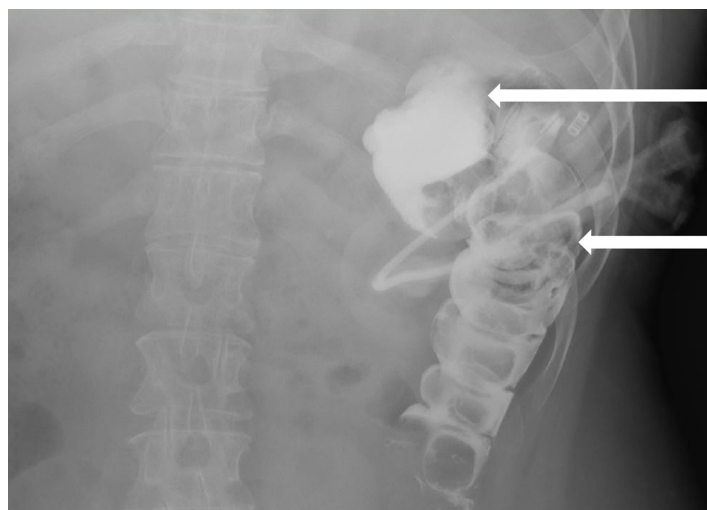


Image. Gastrografen radiography showing percutaneous endoscopic gastrostomy tube in the colon with contrast filling colon at the splenic flexure (top arrow) and proximal descending colon (bottom arrow) suggestive of colocutaneous fistula formation.

and abdominal wall during the initial insertion.¹⁻⁵ Fistula formation occurs at the time of initial insertion but symptoms

manifest after reinsertion of the PEG tube fails to completely pass the tube through the interposed colon to enter the stomach.^{2,3} Risk factors include adhesions from previous laparotomy, postural and spinal abnormalities, and high-riding transverse colon.¹ Symptoms include sudden onset diarrhea after PEG tube feeds, visualization of undigested feeding formula, and feculent vomiting with retrograde passage of material from the colon.¹ Upper endoscopy with water-soluble contrast is the diagnostic modality of choice.¹⁻⁵ Treatment ranges from conservative management aimed at decreasing fistula output and allowing for spontaneous closure after infection control, nutritional optimization and establishing wound care to surgical repair. Since emergency physicians change a large number of PEG tubes, recognition and awareness of this rare complication is important to clinical practice.

The authors attest that their institution requires neither Institutional Review Board approval, nor patient consent for publication of this case report. Documentation on file.

Address for Correspondence: Matthew Warner, MD, Inspira Medical Center, 1505 W Sherman Ave, Vineland, NJ 08360. Email: matthew.warner@ihn.org.

Conflicts of Interest: By the *CPC-EM* article submission agreement, all authors are required to disclose all affiliations, funding sources and financial or management relationships that could be perceived as potential sources of bias. The authors disclosed none.

Copyright: © 2020 Warner et al. This is an open access article distributed in accordance with the terms of the Creative Commons Attribution ([CC BY 4.0](http://creativecommons.org/licenses/by/4.0/)) License. See: <http://creativecommons.org/licenses/by/4.0/>

REFERENCES

1. Lee J, Kim J, Kim HI, et al. Gastrocolocutaneous fistula: an unusual case of gastrostomy tube malfunction with diarrhea. *Clin Endosc*. 2018;51(2):196-200.
2. Yamazaki T, Sakai Y, Hatakeyama K, et al. Colocutaneous fistula after percutaneous endoscopic gastrostomy in a remnant stomach. *Surg Endosc*. 1999;13(3):280-2.
3. Chime C, Ravi M, Daniel M, et al. Gastrocolic fistula: a rare presentation of colon cancer. *Case Rep Gastrointest Med*. 2018;2018:6958925-3.
4. Friedmann R, Feldman H, Sonnenblick M. Misplacement of percutaneously inserted gastrostomy tube into the colon: report of 6 cases and review of the literature. *JPEN J Parenter Enteral Nutr*. 2007;31(6):469-76.
5. Hucl T and Spicak J. Complications of percutaneous endoscopic gastrostomy. *Best Pract Res Clin Gastroenterol*. 2016;30(5):769-81.

CPC-EM Capsule

What do we already know about this clinical entity?

Colocutaneous fistulas are a rare complication of percutaneous endoscopic gastrostomy (PEG) tube insertion mediated by PEG tube penetration of interposed colon between the stomach and abdominal wall.

What is the major impact of the image(s)?

Contrast filling the splenic flexure and proximal descending colon suggests colocutaneous fistula formation, requiring prompt recognition and surgical consultation.

How might this improve emergency medicine practice?

Emergency physicians change a large number of PEG tubes; therefore, recognition and awareness of this rare complication is important to clinical practice.