

CPC Emergency Medicine

Volume IV, Number 4, November 2020

Open Access at www.cpcem.org

ISSN: 2474-252X

Clinical Practice and Cases in Emergency Medicine

In Collaboration with the *Western Journal of Emergency Medicine*

Clinicopathological Cases from the University of Maryland

- 499 **40-year-old Male with a Headache and Altered Mental Status**
Rubenstein RJ, Alblaihed L, ZDW Dezman, Bontempo LJ

Medical Legal Case Reports

- 505 **Three Medicolegal Cases of Searching for the Stone: Lessons Learned Along the Journey**
Jacobson AA, Sakamoto AE, Moore GP, Boie ET

Case Reports

- 509 **Prolonged Duration of Viral Shedding of SARS-CoV-2: A Case Report**
Fong B, London KS
- 513 **Case Report: Pediatric Patient with COVID-19 and Multisystem Inflammatory Syndrome in Children**
Burger MW, Moore MA, Wilburn JM
- 517 **Delirium Associated with Salicylate and Acetaminophen Overdose in a Patient with COVID-19: A Case Report**
Wen TH, Chu J, Allenspach DM, Van DC
- 521 **Spontaneous Pneumothorax as a Complication of COVID-19 Pneumonia: A Case Report**
Perice L, Roit Z, Llovera I, Flanagan-Kundle MG
- 524 **Isolated COVID-19 Infection Precipitates Myasthenia Gravis Crisis: A Case Report**
Moschella P, Roth P
- 527 **The Evolution of Ultrasound in Medicine: A Case Report of Point-of-care Ultrasound in the Self-diagnosis of Acute Appendicitis**
Knapp B, Feyzeau K, Smith A, Byars D, Goodmurphy C, Jones M
- 530 **Immunocompromised Child on Infliximab: A Case Report of *Listeria monocytogenes* Meningitis**
Halfman C, Slate L, Yamamoto J, Jones S
- 533 **Cerebral Malaria in a Patient with Recent Travel to the Congo Presenting with Delirium: A Case Report**
Roberson MT, Smith AT

Contents continued on page iii



UC Irvine Health



A Peer-Reviewed, International Professional Journal



**ACOEP stands with all emergency
physicians and providers on the
front line. We thank you for your
tireless work and effort.**



www.acoep.org

Clinical Practice and Cases in Emergency Medicine

Indexed in PubMed and full text in PubMed Central

Rick A. McPheeters, DO, Editor-in-Chief

Kern Medical/UCLA- Bakersfield, California

Mark I. Langdorf, MD, MHPE, Senior Associate Editor

University of California, Irvine School of Medicine- Irvine, California

Shahram Lotfipour, MD, MPH, Senior Associate Editor

University of California, Irvine School of Medicine- Irvine, California

Shadi Lahham, MD, MS, Associate Editor

University of California, Irvine School of Medicine- Irvine, California

Manish Amin, DO, Associate Editor

Kern Medical/UCLA- Bakersfield, California

John Ashurst, DO, Decision Editor/ ACOEP Guest Editor

Kingman Regional Health Network, Arizona

Anna McFarlin, MD, Decision Editor

Louisiana State University Health Science Center- New Orleans, Louisiana

Austin Smith, MD, Decision Editor

Vanderbilt University Medical Center-Nashville, Tennessee

Christopher Sampson, MD, Decision Editor

University of Missouri- Columbia, Missouri

Joel Moll, MD, Decision Editor

Virginia Commonwealth University School of Medicine- Richmond, Virginia

Scott Goldstein, DO, Decision Editor

Sidney Kimmel College of Medicine- Philadelphia, Pennsylvania

Steven Walsh, MD, Decision Editor

Einstein Medical Center Philadelphia-Philadelphia, Pennsylvania

Melanie Heniff, MD, Decision Editor

University of Indiana School of Medicine- Indianapolis, Indiana

Gentry Wilkerson, MD, Decision Editor

University of Maryland School of Medicine

Editorial Board

Amin A. Kazzi, MD, MAAEM

The American University of Beirut, Beirut, Lebanon

Anwar Al-Awadhi, MD

Mubarak Al-Kabeer Hospital, Jabriya, Kuwait

Arif A. Cevik, MD

United Arab Emirates University
College of Medicine and Health Sciences, Al Ain, United Arab Emirates

Abhinandan A. Desai, MD

University of Bombay Grant Medical College, Bombay, India

Bandr Mzahim, MD

King Fahad Medical City, Riyadh, Saudi Arabia

Barry E. Brenner, MD, MPH

Case Western Reserve University

Brent King, MD, MMM

University of Texas, Houston

Daniel J. Dire, MD

University of Texas Health Sciences Center San Antonio

David F.M. Brown, MD

Massachusetts General Hospital/Harvard Medical School

Edward Michelson, MD

Texas Tech University

Edward Panacek, MD, MPH

University of South Alabama

Erik D. Barton, MD, MBA

Icahn School of Medicine, Mount Sinai, New York

Francesco Dellacorte, MD

Azienda Ospedaliera Universitaria "Maggiore della Carità," Novara, Italy

Francis Counselman, MD

Eastern Virginia Medical School

Gayle Galleta, MD

Sorlandet Sykehus HF, Akershus Universitetssykehus, Lorenskog, Norway

Hjalte Björnsson, MD

Icelandic Society of Emergency Medicine

Jacob (Kobi) Peleg, PhD, MPH

Tel-Aviv University, Tel-Aviv, Israel

Jonathan Olshaker, MD

Boston University

Katsuhiko Kanemaru, MD

University of Miyazaki Hospital, Miyazaki, Japan

Khrongwong Musikatavorn, MD

King Chulalongkorn Memorial Hospital, Chulalongkorn University, Bangkok, Thailand

Leslie Zun, MD, MBA

Chicago Medical School

Linda S. Murphy, MLIS

University of California, Irvine School of Medicine Librarian

Nadeem Qureshi, MD

St. Louis University, USA
Emirates Society of Emergency Medicine, United Arab Emirates

Niels K. Rathlev, MD

Tufts University School of Medicine

Pablo Aguilera Fuenzalida, MD

Pontificia Universidad Católica de Chile, Región Metropolitana, Chile

Peter A. Bell, DO, MBA

Liberty University
College of Osteopathic Medicine

Peter Sokolove, MD

University of California, San Francisco

Robert M. Rodriguez, MD

University of California, San Francisco

Robert Suter, DO, MHA

UT Southwestern Medical Center

Robert W. Derlet, MD

University of California, Davis

Rosidah Ibrahim, MD

Hospital Serdang, Selangor, Malaysia

Samuel J. Stratton, MD, MPH

Orange County, CA, EMS Agency

Scott Rudkin, MD, MBA

University of California, Irvine

Scott Zeller, MD

University of California, Riverside

Steven Gabaeff, MD

Clinical Forensic Medicine

Steven H. Lim, MD

Changi General Hospital, Simei, Singapore

Terry Mulligan, DO, MPH, FIFEM

ACEP Ambassador to the Netherlands Society of Emergency Physicians

Vijay Gautam, MBBS

University of London, London, England

Wirachin Hoonpongmanont, MD, MSBATS

Stirraj Hospital, Mahidol University, Bangkok, Thailand

Advisory Board

Amal Khalil, MBA

UC Irvine Health School of Medicine

Elena Lopez-Gusman, JD

California ACEP
American College of Emergency Physicians

Adam Levy, BS

American College of Osteopathic Emergency Physicians

John B. Christensen, MD

California Chapter Division of AAEM

Lori Winston, MD

California ACEP
American College of Emergency Physicians
Kaweah Delta Healthcare District

Mark I. Langdorf, MD, MHPE

UC Irvine Health School of Medicine

Jorge Fernandez, MD

California ACEP
American College of Emergency Physicians
University of California, San Diego

Peter A. Bell, DO, MBA

American College of Osteopathic Emergency Physicians
Liberty University, College of Osteopathic Medicine

Robert Suter, DO, MHA

American College of Osteopathic Emergency Physicians
UT Southwestern Medical Center

Shahram Lotfipour, MD, MPH

UC Irvine Health School of Medicine

Brian Potts, MD, MBA

California Chapter Division of AAEM
Alta Bates Summit-Berkeley Campus

Editorial Staff

Leila Danishgar, BS

Editorial Director

Nicholas Gossett, BS

CPC-EM Associate Editorial Director
Associate Marketing Director

Maria Nguyen, BS

WestJEM Associate Editorial Director

June Casey, BA

Copy Editor

Alissa Fiorentino, BA

WestJEM Staff Liaison

Cassandra Saucedo, BS

CPC-EM Publishing Director

Ishan Shah, BS

CPC-EM Associate Publishing Director
Associate Marketing Director

Christine Louis, BS

WestJEM Publishing Director

Isabelle Nepomuceno, BS
WestJEM Associate Publishing Director
Associate Marketing Director

Official Journal of the California Chapter of the American College of Emergency Physicians, the American College of Osteopathic Emergency Physicians, and the California Chapter of the American Academy of Emergency Medicine



Available in MEDLINE, PubMed, PubMed Central, Google Scholar, eScholarship, DOAJ, and OASPA.

Editorial and Publishing Office: WestJEM/Department of Emergency Medicine, UC Irvine Health, 333 City Blvd, West, Rt 128-01, Orange, CA 92866, USA

Office: 1-714-456-6389; Email: Editor@westjem.org

Clinical Practice and Cases in Emergency Medicine

Indexed in PubMed and full text in PubMed Central

This open access publication would not be possible without the generous and continual financial support of our society sponsors, department and chapter subscribers.

Professional Society Sponsors

AMERICAN COLLEGE OF OSTEOPATHIC EMERGENCY PHYSICIANS
CALIFORNIA ACEP

CALIFORNIA CHAPTER DIVISION OF
AMERICAN ACADEMY OF EMERGENCY MEDICINE

Academic Department of Emergency Medicine Subscribers

Albany Medical College Albany, NY	INTEGRIS Health Oklahoma City, OK	Robert Wood Johnson University Hospital New Brunswick, NJ	University of Florida, Jacksonville Jacksonville, FL
American University of Beirut Beirut, Lebanon	Kaweah Delta Health Care District Visalia, CA	Rush University Medical Center Chicago, IL	University of Illinois at Chicago Chicago, IL
Arrowhead Regional Medical Center Colton, CA	Kennedy University Hospitals Turnersville, NJ	Southern Illinois University Carbondale, IL	University of Illinois College of Medicine Peoria, IL
Augusta University Augusta GA	Kern Medical Bakersfield, CA	St. Luke's University Health Network Bethlehem, PA	University of Iowa Iowa City, IA
Baystate Medical Center Springfield, MA	Lakeland HealthCare St. Joseph, MI	Stanford/Kaiser Emergency Medicine Residency Program Stanford, CA	University of Louisville Louisville, KY
Beaumont Hospital Royal Oak, MI	Lehigh Valley Hospital and Health Network Allentown, PA	Staten Island University Hospital Staten Island, NY	University of Maryland Baltimore, MD
Beth Israel Deaconess Medical Center Boston, MA	Loma Linda University Medical Center Loma Linda, CA	SUNY Upstate Medical University Syracuse, NY	University of Michigan Ann Arbor, MI
Boston Medical Center Boston, MA	Louisiana State University Health Sciences Center New Orleans, LA	Temple University Philadelphia, PA	University of Missouri, Columbia Columbia, MO
Brigham and Women's Hospital Boston, MA	Madigan Army Medical Center Tacoma, WA	Texas Tech University Health Sciences Center El Paso, TX	University of Nebraska Medical Center Omaha, NE
Brown University Providence, RI	Maimonides Medical Center Brooklyn, NY	University of Alabama, Birmingham Birmingham, AL	University of South Alabama Mobile, AL
Carl R. Darnall Army Medical Center Fort Hood, TX	Maricopa Medical Center Phoenix, AZ	University of Arkansas for Medical Sciences Little Rock, AR	University of Southern California/Keck School of Medicine Los Angeles, CA
Conemaugh Memorial Medical Center Johnstown, PA	Massachusetts General Hospital Boston, MA	University of California, Davis Medical Center Sacramento, CA	University of Tennessee, Memphis Memphis, TN
Desert Regional Medical Center Palm Springs, CA	Mayo Clinic College of Medicine Rochester, MN	University of California Irvine Orange, CA	University of Texas, Houston Houston, TX
Doctors Hospital/Ohio Health Columbus, OH	Mt. Sinai Medical Center Miami Beach, FL	University of California, Los Angeles Los Angeles, CA	University of Texas Health San Antonio, TX
Eastern Virginia Medical School Norfolk, VA	North Shore University Hospital Manhasset, NY	University of California, San Diego La Jolla, CA	University of Warwick Library Coventry, United Kingdom
Einstein Healthcare Network Philadelphia, PA	Northwestern Medical Group Chicago, IL	University of California, San Francisco San Francisco, CA	University of Washington Seattle, WA
Emory University Atlanta, GA	Ohio State University Medical Center Columbus, OH	UCSF Fresno Center Fresno, CA	University of Wisconsin Hospitals and Clinics Madison, WI
Genesys Regional Medical Center Grand Blanc, Michigan	Ohio Valley Medical Center Wheeling, WV	University of Chicago, Chicago, IL	Wake Forest University Winston-Salem, NC
Hartford Hospital Hartford, CT	Oregon Health and Science University Portland, OR	University of Colorado, Denver Denver, CO	Wright State University Dayton, OH
Hennepin County Medical Center Minneapolis, MN	Penn State Milton S. Hershey Medical Center Hershey, PA	University of Florida Gainesville, FL	
Henry Ford Hospital Detroit, MI	Presence Resurrection Medical Center Chicago, IL		

State Chapter Subscribers

ARIZONA CHAPTER DIVISION OF THE
AMERICAN ACADEMY OF EMERGENCY MEDICINE
CALIFORNIA CHAPTER DIVISION OF THE
AMERICAN ACADEMY OF EMERGENCY MEDICINE
FLORIDA CHAPTER DIVISION OF THE
AMERICAN ACADEMY OF EMERGENCY MEDICINE

GREAT LAKES CHAPTER DIVISION OF THE
AMERICAN ACADEMY OF EMERGENCY MEDICINE
TENNESSEE CHAPTER DIVISION OF THE
AMERICAN ACADEMY OF EMERGENCY MEDICINE

UNIFORMED SERVICES CHAPTER DIVISION OF THE
AMERICAN ACADEMY OF EMERGENCY MEDICINE
VIRGINIA CHAPTER DIVISION OF THE
AMERICAN ACADEMY OF EMERGENCY MEDICINE

International Society Partners

EMERGENCY MEDICINE ASSOCIATION OF TURKEY
LEBANESE ACADEMY OF EMERGENCY MEDICINE
MEDITERRANEAN ACADEMY OF EMERGENCY MEDICINE

NORWEGIAN SOCIETY FOR EMERGENCY MEDICINE
SOCIEDAD ARGENTINA DE EMERGENCIAS

SOCIEDAD CHILENO MEDICINA URGENCIA
THAI ASSOCIATION FOR EMERGENCY MEDICINE

To become a *WestJEM* departmental sponsor, waive article processing fee, receive print and copies for all faculty and electronic for faculty/residents, and free CME and faculty/fellow position advertisement space, please go to <http://westjem.com/subscribe> or contact:

Alissa Fiorentino
WestJEM Staff Liaison
Phone: 1-800-884-2236
Email: sales@westjem.org

JOURNAL FOCUS

Clinical Practice and Cases in Emergency Medicine (CPC-EM) is a MEDLINE-indexed internationally recognized journal affiliated with the *Western Journal of Emergency Medicine* (WestJEM). It offers the latest in patient care case reports, images in the field of emergency medicine and state of the art clinicopathological and medicolegal cases. CPC-EM is fully open-access, peer reviewed, well indexed and available anywhere with an internet connection. CPC-EM encourages submissions from junior authors, established faculty, and residents of established and developing emergency medicine programs throughout the world.

Table of Contents *continued*

- 537 Apnea and Diffuse Alveolar Hemorrhage Caused by Cocaine and Heroin Use: A Case Report**
G Logan, E Robalino, T MacIntosh, Ganti L
- 540 Thyroid Storm, Rhabdomyolysis, and Pulmonary Embolism: An Unusual Triad Case Report**
MB Silverman, J Wray, RE Bridwell, A Cibrario
- 544 Giant Bladder Calculus in an Adult- A Persistent Problem in the Developing World: A Case Report**
AK Vidhyarthy, T Hameed, R Lal, A Kumar, S Sahni, N Mendoza
- 548 A Case Report of a Novel Harm Reduction Intervention Used to Detect Opioid Overdose in the Emergency Department**
KE Schreyer, S Malik, A Blome, JL D'Orazio
- 551 Case Report: A Near Miss of Pulmonary Embolism in a Division 1 Collegiate Basketball Player**
NM Chill, AJ Monseau, BJ Balcik, RD Sikora, K Oppenlander
- 555 Ureteral Stone Mimics Appendicitis: A Point-of-care Ultrasound Case Report**
C Shavor, J Pagenhardt, Y Sun, C Kraft, B End, J Minardi
- 559 Ruptured Ectopic Pregnancy with an Intrauterine Device: Case Report and Sonographic Considerations**
DD Jones, T Kummer, JS Schoen
- 564 Sequelae of Anticoagulant Therapy in a Patient with History of Pulmonary Malignancy: A Case Report**
CB Gilsdorf, HE Davis
- 569 The Woes of a Stuffy Nose: A Case Report of Allergic Fungal Sinusitis**
T Lopachin, G Landers
- 572 Inhaled Tranexamic Acid for Massive Hemoptysis in the Setting of Oral Anticoagulation: A Case Report**
JM Dempsey, M Jones, J Bronner, C Greer, GT Howington
- 576 A Case Report Highlighting That Silica Gel Products Are Not Always Benign**
N Lassiter, N Yang, L Tiyyagura, KS Whitlow
- 580 Case Report and Literature Review: Post-Arthroscopy Pneumothorax with Anterior Decompression**
MA Cassone, KL Kish, JR Nester, LM Hoffman
- 584 One Notable Complication of Nasopharyngeal Airway: A Case Report**
B Briggs, C Countryman, HD McGinnis
- 587 Case Report of a Left-sided Superior Vena Cava Causing Unique Positioning of Central Line**
M Mancera, N Genthe, N Lepa

Policies for peer review, author instructions, conflicts of interest and human and animal subjects protections can be found online at www.cpcem.org.

Table of Contents *continued*

- 591 **Pharmacologically-induced Recreational Priapism: Case Report and Review**
G Kunas, JA Smereck, D Ladkany, JE Davis
- 595 **“Botched”: A Case Report of Silicone Embolism Syndrome After Penile and Scrotal Injection**
A Singarajah, A Wang, J Sayegh, GM Vilke, FC Quenzer
- 599 **An Unusual Case of Tetanus Masquerading as an Acute Abdomen: A Case Report**
R Kumar Thakur, R Singh, S Nepal, P Ghimire
- 603 **A Case Report of B-cell Lymphoblastic Leukemia/Lymphoma Presenting as Isolated Torticollis in a 2-year-old Female**
M Boushra
- 607 **Case Report: Spontaneous Rupture of Inferior Epigastric Artery Masquerading as Inguinal Hernia**
K Sulkowski, C Young
- 610 **Gastric Diverticulum Presenting as Hematemesis: A Case Report Detailing an Uncommon Presentation of an Already Rare Entity**
M Massa, K Newbold
- 613 **Dysphagia Alone as a Unique Presentation of Wound Botulism in the Emergency Department: A Case Report**
RH Wyatt, E Shtull-Leber, TE Kelly
- 617 **A Case Report of Neonatal Supraventricular Tachycardia Resolved with Single-Syringe Adenosine**
M McDowell, T Ahmed, B Schroeder, S Staley
- 620 **Case Report: Delayed Presentation of Bowel Obstruction Caused by Blunt Abdominal Trauma**
NH George, CA Baldi, JM Tonascia, S Moayed
- 623 **Case Report of Traumatic Uterine Rupture in a Multigravida Woman with Emergency Department Cesarean Section**
KS Wiese, S Ernest, WS Dukes
- Images in Emergency Medicine**
- 626 **A Case of Bilateral Hearing Loss**
B Ryabtsev, M Slane
- 628 **Point-of-care Ultrasound in the Evaluation of Mitral Valve Regurgitation and Mitral Annular Calcification**
B Schoenberg, M Alkhattabi, S Lahham
- 630 **A 61-year-old Female with Right Upper Abdominal Pain**
DA Long, B Long
- 632 **Colocutaneous Fistula after Percutaneous Endoscopic Gastrostomy (PEG) Tube Insertion**
M Warner, M Durrani
- 634 **Extensive Upper Airway Hematoma Secondary to Supratherapeutic Warfarin Anticoagulation**
TO Oyedokun, KM Durr
- 636 **Female with Vaginal Bleeding**
M Quilon, A Glucksman, G Emmanuel, J Greenstein, B Hahn

Clinical Practice and Cases in Emergency Medicine (CPC-EM) is a open-access Medline-indexed internationally recognized journal affiliated with the *Western Journal of Emergency Medicine* (WestJEM). CPC-EM is distributed electronically to 19,000 emergency medicine scholars. This includes our sponsors California ACEP, the American College of Osteopathic Emergency Physicians, California Chapter of AAEM, and over 83 academic department of emergency medicine subscribers and 8 AAEM State Chapters.

Clinical Practice and Cases in Emergency Medicine

Indexed in PubMed and full text in PubMed Central

Table of Contents *continued*

Fall 2019 and Spring 2020 The American College of Osteopathic Emergency Medicine (ACOEP) FOEM Competition

The Foundation for Osteopathic Emergency Medicine (FOEM) promotes research and graduate medical education to advance the science of patient centric holistic emergency care consistent with the osteopathic philosophy. Each year FOEM hosts a number of research competitions that are presented at the American College of Osteopathic Emergency Physicians (ACOEP) fall scientific assembly and spring seminar. This issue of Clinical Practice and Cases in Emergency Medicine (CPC-EM) highlights FOEM clinical pathological cases and case reports presented at the 2019 ACOEP Scientific Assembly and the 2020 ACOEP Spring Seminar.

Clinicopathological Cases

- 638 Clinicopathological Conference: 54-year-old with Facial Swelling for One Month**
JE Pile, A Dawson, L Maxa

Case Reports

- 642 Morel-Lavallée Lesion Following a Low-speed Injury: A Case Report**
D Porter, J Conley, J Ashurst
- 645 A Case Report of Pulmonary Sarcoidosis: An Uncommon Cause of Chest Pain**
J Truong, J Ashurst
- 649 Intracranial Air Embolism after Inferior Alveolar Nerve Block: A Case Report**
M Gillespie, C Gunsolly
- 653 Miller-Fisher Syndrome: A Case Report and Review of the Literature**
J Truong, J Conley, J Ashurst
- 656 Appropriate Evaluation of Psychiatric Patients Highlighted by Creutzfeldt-Jakob Disease: A Case Report**
K Bartlett, KE Kane, BG Kane, KR Weaver, GC Barr
- 660 Pulmonary Embolism Presenting as an Anterior ST-elevation Myocardial Infarction: A Case Report**
V Ladage, M Jones, F Ahmad, C Plamoottil, R Misek, N Alexander-Anyagou
- 664 Palmoplantar Pustulosis: A Case Report**
A Dulski, V Varamo
- 668 Sepsis-induced Autoimmune Hemolytic Anemia: A Case Report**
Z Edwards, S DeMeo
- 671 A Noteworthy Case Report of Neuroborreliosis in an Unvaccinated Pediatric Patient**
AR Walker, T Morales-Yurick

Images in Emergency Medicine

- 675 Secondary Syphilis**
S Ehlers, S Sergent, J Ashurst

Clinical Practice and Cases in Emergency Medicine (CPC-EM) is a open-access Medline-indexed internationally recognized journal affiliated with the Western Journal of Emergency Medicine (WestJEM). CPC-EM is distributed electronically to 19,000 emergency medicine scholars. This includes our sponsors California ACEP, the American College of Osteopathic Emergency Physicians, California Chapter of AAEM, and over 83 academic department of emergency medicine subscribers and 8 AAEM State Chapters.

CPC**EM** Clinical Practice & Cases

CALL FOR SUBMISSIONS

- Patient Care Case Reports
- Images in Emergency Medicine

Fully open-access, peer reviewed,
well indexed: CPC-EM is available
anywhere with an internet
connection at **CPCEM.org**

***Clinical
Practice and
Cases in
Emergency
Medicine*** is an
internationally
recognized
journal
affiliated with
the MEDLINE-
indexed
***Western
Journal of
Emergency
Medicine***

**CPC-EM encourages submissions from junior authors and
countries with developing emergency medicine programs**

CPC**EM** Clinical Practice & Cases

CALL FOR CPC-EM SECTION EDITORS!

- Medical-Legal Case Reports
- Case Reports/Images in
Emergency Medicine

**Send your CV and letter of interest to
editor@cpcem.org**



Journal of Education & Teaching *in* Emergency Medicine

A publication of **CORD**

Education

We believe that all learners should benefit from active learning.

We are an online, open access, peer-reviewed journal-repository for EM educators in all major topic areas.

Scholarship

We believe educators should advance through the scholarship of their educational work. JETem gives you the opportunity to publish & distribute your outstanding, scholarly academic work.

Submit your content or contact us to become a reviewer!



visualem



small groups



tbl



simulation



lecture



oral boards



podcasts



curriculum



innovations

www.jetem.org



published by

eScholarship University of California

40-year-old Male with a Headache and Altered Mental Status

Rebecca J. Rubenstein, MD*

Leen Alblaihed, MD†

Zachary D.W. Dezman, MD, MS, MS†

Laura J. Bontempo, MD, MEd†

*University of Maryland Medical Center, Department of Emergency Medicine, Baltimore, Maryland

†University of Maryland School of Medicine, Department of Emergency Medicine, Baltimore, Maryland

Section Editor: Joel Moell, MD

Submission history: Submitted August 19, 2020; Revision received September 26, 2020; Accepted October 5, 2020

Electronically published October 20, 2020

Full text available through open access at http://escholarship.org/uc/uciem_cpccm

DOI: 10.5811/cpcem.2020.10.49546

A 40-year-old man presents to the emergency department with headache, nausea and paresthesias, with subsequent fever and mental status change. Magnetic resonance imaging showed increased fluid-attenuation inversion recovery signal involving multiple areas of the brain, including the pons. This case takes the reader through the differential diagnosis of rhombencephalitis (inflammation of the hindbrain) with discussion of the unanticipated ultimate diagnosis and its treatment. [Clin Pract Cases Emerg Med. 2020;4(4):499–504]

CASE PRESENTATION (Dr. Rubenstein)

A 40-year-old male was brought by a friend to the emergency department (ED) for evaluation with a chief complaint of headache. The patient reported a headache that was diffuse, severe in intensity, throbbing in nature, and gradual in onset. The headache started when he lay down to sleep that evening. It was associated with nausea and numbness and tingling in his bilateral hands and feet. The headache was preceded by several hours of fatigue and generalized weakness. The patient drank six 12-ounce beers before going to bed. The friend at the bedside explained that he typically drank that amount, and expressed concern because the patient seemed much more intoxicated than he typically would be after drinking that amount.

The patient had a past medical history of depression and anxiety. He had a surgical history of an open reduction and internal fixation of a right calcaneal fracture 10 years prior. He took sertraline 100 milligrams (mg) daily, and had no drug allergies. He smoked one pack of cigarettes per day and was a daily drinker, but had not experienced alcohol withdrawal. He denied use of illicit drugs. Family history was notable for a cerebrovascular accident and myocardial infarction in his parents, and vertigo in a sibling. He worked as a contractor for a gas and electric company, and spent most of his day outside. He had no recent travel history. A review of systems revealed a one-week history of right ankle pain, swelling, and redness that the patient attributed to a “spider bite.”

The patient was alert, oriented, and uncomfortable but non-toxic appearing on the initial exam. His temperature

was 36.8° Celsius (C), with a heart rate of 71 beats per minute, blood pressure (BP) of 139/83 millimeters (mm) of mercury, and an oxygen saturation of 98% on room air with a respiratory rate of 16 breaths per minute. He weighed 82.6 kilograms (kg), was 1.96 meters tall with a body mass index of 22.5 kg/m². He appeared well developed and well nourished. His head was normocephalic and atraumatic. He had moist mucous membranes, without oral lesions, and with a normal oropharynx. Pupils were 2 mm, equal, and sluggishly reactive to light. His extraocular movements were normal. There was no scleral icterus or conjunctival pallor. Visual acuity was grossly normal. The neck was supple without cervical lymphadenopathy, meningismus, or midline or paraspinal cervical spine tenderness. Heart was regular rate and rhythm, without murmur, rubs, or gallops. Breath sounds were clear bilaterally without wheezing, rhonchi, or rales. Abdomen was soft and nontender, without rebound, guarding, or rigidity, and with normoactive bowel sounds. Extremities were warm and well perfused with good distal pulses.

There was a small area of blanching erythema and ecchymosis in the right lateral malleolar region. There was no increased warmth, edema, other evidence of trauma, or painful or limited range of motion of the ankle. Neurologic exam showed cranial nerves II–XII intact, 4/5 strength throughout the bilateral upper extremities, 5/5 strength throughout the bilateral lower extremities, with normal tone, and normal sensation throughout. Speech was clear and fluent, and mood and affect were appropriate. Skin was warm and dry. A

papular rash was noted on his lower extremities (Image). It did not involve the palms or soles.

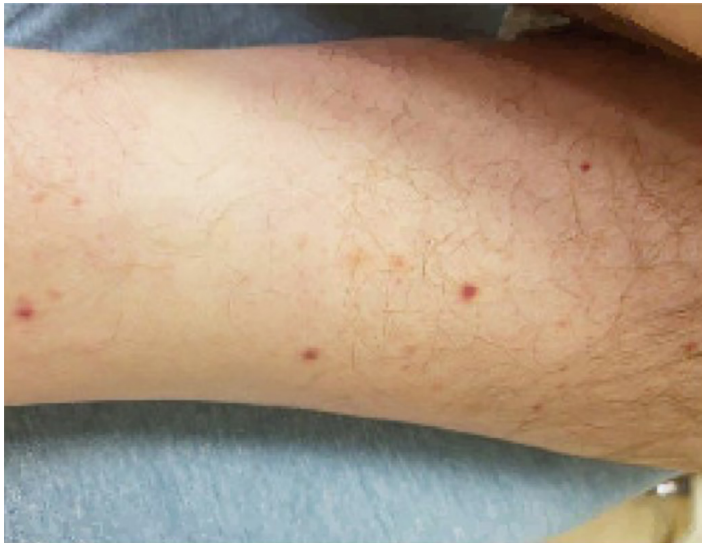

Image. Left lower extremity rash of a 40-year-old male who presented with a headache and altered mental status.

The patient's initial laboratory testing results are shown in Table 1. His electrocardiogram showed a normal sinus rhythm, with normal axis, normal intervals, and no ST-segment elevation, depression, or T-wave inversions. Two hours after his initial evaluation, he began vomiting and complained of dysarthria, dysphagia, and vertigo. Tongue fasciculations were present. He received a dose of metoclopramide. Due to concern for an acute cerebral vascular accident, a computed tomography (CT) of the head, and a CT angiography of the head and neck were subsequently performed and showed no acute abnormality. Neurology was consulted, and a magnetic resonance imaging (MRI) of the brain without contrast was obtained per their recommendation. The MRI was markedly limited by motion artifact and was of poor diagnostic quality. As described by radiology, the image showed foci of increased fluid-attenuation inversion recovery (FLAIR) signal involving portions of the cortex of the frontal lobes bilaterally, deep periventricular white matter, left side of midbrain, throughout the pons, and in the deep left cerebellar hemisphere.

The patient was reassessed when he returned from MRI. His BP and heart rate were relatively unchanged, but he was febrile (38.4°C). The patient had become somnolent and he was no longer managing his oral secretions. It was determined that he was no longer adequately protecting his airway. He was intubated without complication, blood cultures were drawn, and he was started on empiric broad-spectrum intravenous (IV) antibiotics. A lumbar puncture was

Table 1. Blood laboratory results of a 40-year-old male with a headache and altered mental status.

Complete blood cell count	Patient value	Normal
White blood cells	9.4 K/mcL	4.8 - 10.9 K/mcL
Hemoglobin	13.4 g/dL	14 - 18 g/dL
Hematocrit	38.5 %	42.0 - 52.0 %
Platelets	244 K/mcL	130 - 400 K/mcL
Differential		
Polymorphonuclear leukocytes	46 %	
Lymphocytes	40 %	
Monocytes	13 %	
Eosinophils	0 %	
Serum chemistries		
Sodium	137 mmol/L	136 - 144 mmol/L
Potassium	3.4 mmol/L	3.5 - 5.3 mmol/L
Chloride	102 mmol/L	98 - 107 mmol/L
Bicarbonate	24 mmol/L	22 - 32 mmol/L
Anion gap	11	2 - 11
Blood urea nitrogen	11 mg/dL	7 - 25 mg/dL
Creatinine	0.77 mg/dL	0.90 - 1.30 mg/dL
Glucose	206 mg/dL	75 - 110 mg/dL
Calcium	8.9 mg/dL	8.6 - 10.3 mg/dL
Magnesium	1.7 mg/dL	1.8 - 2.5 mg/dL
Total protein	7.7 g/dL	6.0 - 8.1 g/dL
Albumin	3.9 g/dL	3.3 - 4.6 g/dL
Aspartate aminotransferase	26 IU/L	15 - 41 IU/L
Alanine aminotransferase	36 IU/L	7 - 52 IU/L
Alkaline phosphatase	72 IU/L	32 - 91 IU/L
Total bilirubin	36 mg/dL	0.10 - 1.30 mg/dL
Ammonia	36 umol/L	16 - 53 umol/L

K, thousand; mcL, microliter; g, grams; dL, deciliter; mmol, millimole; L, liter; mg, milligram; IU, international units; umol, micromole.

performed and cerebrospinal fluid (CSF) was obtained. The results are shown in Table 2. A diagnostic test was sent, which confirmed the diagnosis.

CASE DISCUSSION (Dr. Alblaihed)

Headache is one of the most common complaints seen in the ED. When a patient presents with headache, fever, and neurological symptoms, such as altered mental status, this is extremely concerning for encephalitis or meningoencephalitis.

I began by looking at the causes of altered mental status. These can include anoxic or ischemic insults, metabolic

Table 2. Cerebrospinal fluid results of a 40-year-old male with a headache and altered mental status.

Test	Patient value	Normal
Glucose	102 mg/dL	50 - 80 mg/dL
Protein	177 mg/dL	15 - 45 mg/dL
White blood cells (WBC) (Tube 1, Tube 4)	39 mm ³ , 54 mm ³	0 - 5 mm ³
Red blood cells (Tube 1, Tube 4)	4 mm ³ , 0 mm ³	0 - 5 mm ³
Neutrophils (Tube 1, Tube 4)	96 % , 54 %	3 - 7 %
Lymphocytes (Tube 1, Tube 4)	2 % , 2 %	28 - 96 %
Monocytes (Tube 1, Tube 4)	2 % , 8 %	16 - 56 %
Gram stain	Few WBC. No organisms seen.	
Color	Colorless	
Clarity	Clear	

dL, deciliter; mg, milligram; mm³, cubic millimeters; WBC, white blood cells.

derangements, nutritional deficiency, trauma, and toxins or medications effects. Systemic infections can present as delirium, while traumatic brain injury, malignant hypertension, and seizures can cause encephalopathy. Rare causes include Hashimoto's encephalopathy, mitochondrial cytopathy, and paraneoplastic syndromes.¹ I went back to see if there were clues in the patient presentation that could help me narrow down this wide differential diagnosis.

The patient presented with one week of ankle pain, redness, and swelling due to a "possible bite." He had suddenly developed fatigue, generalized weakness, and muscle aches over the prior day. He then began to complain of a headache that was severe, generalized, throbbing, and started when he lay down. This headache was associated with nausea and paresthesias. On exam he had sluggish pupils, although this is nonspecific. His ankle showed normal range of motion but also had a small area of ecchymosis and erythema (possible bite). He had a rash. His neurological exam was incomplete. It would have been helpful to know details of the cerebellar exam since the patient had complained of vertigo. It is unclear whether the patient had a normal gait or if nystagmus was present. Regarding the vital signs and laboratory results, nothing was overtly concerning.

During his ED evaluation he became dizzy, dysarthric, and had dysphagia. He was treated with IV fluids (IVF) and metoclopramide. This raised my concern for serotonin syndrome, especially because he was taking sertraline at home. It was reassuring that there were no reports of muscle stiffness or rigidity, hyperthermia, tachycardia, dilated pupils, or hypertension. Another concern was that the patient developed central pontine myelinolysis (CPM) from the IVF. Although he did not suffer from hyponatremia, CPM can occur unrelated to the sodium concentration in malnourished, chronic alcohol abusers by means of increasing the extracellular osmotic pressure upon refeeding. However, this patient had no history of starvation or malnutrition. The CT and CT angiography that were done were reportedly normal.

Within hours of his presentation to the ED, he developed tongue fasciculation which, to me, usually means alcohol withdrawal; however, there are many other causes such as lower motor neuron disease, muscle-specific receptor tyrosine kinase, myasthenia gravis, brainstem lesions, base of skull tumors, radiation of the skull base, unilateral hypoglossal neuropathy, and syringomyelia.² Following his MRI, he required intubation for altered mental status. His course was acute and rapidly progressing. This will help me eliminate chronic processes as a cause for his presentation.

Other things I noticed were that he was febrile, with a normal heart rate, oxygen saturation, and BP. Fever without tachycardia (Faget sign) is associated with several tick- and mosquito-borne illnesses. The patient had CSF results that were nonspecific, most likely viral etiology; however, with "clearing" of the red blood cells, it is unlikely to be herpes simplex virus. The MRI showed increased FLAIR signal to the pons (more on the left), frontal subcortical, genu of the corpus callosum, frontal parasagittal, and the periventricular as well as cerebellar (left) areas. These are findings of atypical rhombencephalitis (hindbrain).

To summarize: This is a 40-year-old man with a fever, headache, neurological symptoms, rash, ankle swelling, and tongue fasciculations whose symptoms progress to bulbar weakness requiring intubation. His MRI is concerning for rhombencephalitis.

Putting the clinical picture together, the MRI was my biggest clue to narrowing down my differential diagnosis. Rhombencephalitis, inflammation affecting the hindbrain, was present on the MRI as well as frontal and periventricular FLAIR. Adding to that the acuity of presentation, and the possible "bite" to the ankle, I came up with a list of diagnoses (Table 3).

The causes of rhombencephalitis that are consistent with this patient's presentation and, therefore, remain on my

Table 3. Causes of rhombencephalitis.³

Infection	
Viral	<ul style="list-style-type: none"> • Rabies • Enterovirus 71 • Herpes simplex virus (HSV) • Epstein-Barr virus (EBV) • Human herpesvirus 6 (HHV6) • Flaviviruses (eg, West Nile virus and Japanese encephalitis virus) • Eastern equine encephalitis
Bacterial	<ul style="list-style-type: none"> • Listeria • Mycobacterium tuberculosis • Rickettsia, Borrelia burgdorferi, Salmonella typhi, Legionella bozemanii, and Mycoplasma pneumoniae (rarely causes encephalitis but can involve the brainstem) • Pneumococcus
Autoimmune	<ul style="list-style-type: none"> • Behçet disease (most common autoimmune cause) • Multiple sclerosis • Systemic lupus erythematosus • Acute disseminated encephalomyelitis • Progressive multifocal leukoencephalopathy • Paraneoplastic syndromes
Other	<ul style="list-style-type: none"> • Lymphoma (rare)

differential diagnosis are the following (similarities with the case are in **bold**):

- West Nile encephalitis (WNE):⁴
 - Endemic to the United States, typically through mosquito **bite**
 - **Rapid** onset
 - “Flu-like symptoms” with nausea, vomiting, myalgias, **fever, headache, rash, tongue fasciculations**
 - Neurological symptoms include lower motor neuron **weakness**, flaccid paralysis, and paresthesias
 - MRI findings show abnormalities in the **pons**
 - White blood cell count is usually **normal**
 - CSF is nonspecific but may show a **viral picture** similar to this patient’s
- Eastern equine encephalitis (EEE) (Acute disseminated encephalomyelitis):⁵
 - Extremely rare, typically transmitted through mosquito or snake **bite** (copperhead and cottonmouth)
 - 4-10 days incubation
 - **Fever**, chills, malaise, arthralgia, and myalgia
 - Encephalitis develops after several days
 - Diagnosed by detecting EEE virus immunoglobulin (Ig) M in CSF
- Listeria rhombencephalitis:⁶
 - The most common cause of rhombencephalitis, usually in immunocompetent patients
- Biphasic illness.
 - Prodrome of <16 days, **fever**, nausea, vomiting, **headache**
 - Followed by neurological symptoms: cranial nerve palsy (VI, VII), cerebellar dysfunction, **motor dysfunction**, sensory dysfunction, **altered mental status**
- Rash can be present
- CSF analysis shows:
 - Neutrophilia and lymphocytosis
 - Increased protein with normal glucose
 - Cultures can be negative
- Polymerase chain reaction (PCR) may be negative
- MRI is diagnostic: predilection for the dorsal **brain stem** and cerebellum, specifically the floor of the fourth ventricle.
- Rocky Mountain spotted fever (RMSF) encephalitis:
 - Transmitted via tick **bite**
 - Progresses over days
 - **Fever, headache**, myalgia, nausea
 - **Delayed petechial rash starting over the ankles** and wrists
 - **Joint swelling** can be present
 - Neurological symptoms including ataxia, seizures, dysarthria
 - MRI: increased intensity in perivascular spaces⁷
 - Labs will show thrombocytopenia, elevated transaminases, hyponatremia
- Lyme neuroborreliosis:
 - Encephalitis is rare in Lyme disease
 - Slower onset
 - **Fever**, myalgia, **headache**, arthritis, **rash**
 - Diagnosed with Lyme PCR in CSF; it has variable sensitivity
 - MRI: foci of **periventricular / subcortical** T2 hyperintensity, nerve root enhancement, and meningeal enhancement⁸
- Anaplasmosis (human granulocytic ehrlichiosis):⁹
 - Symptoms range from asymptomatic to fatal
 - Tick bite → 5-day incubation → fever, myalgia, **headache**, nausea, arthralgia, possibly **rash**
 - Neurological symptoms include facial palsy, demyelinating polyneuropathy, brachial plexopathy
 - Rarely involves the central nervous system
 - Leukopenia, thrombocytopenia, elevated liver enzymes
 - Wright or Giemsa-stained blood smears (25-75% sensitive)
 - PCR up to 90% sensitive before antibiotics are given
 - Diagnosed by detecting IgM, IgG by immunofluorescence
- Ehrlichiosis:
 - Symptoms start 1-2 weeks after tick bite
 - **Commonly fever**, chills, **severe headache**, myalgias,

- and a maculopapular rash
- Less common symptoms include **nausea**, vomiting, and confusion
- Can include meningoencephalitis, seizures and coma
- Rarely peripheral neuropathies and cranial neuritis
- *Borrelia miyamotoi*:
 - Transmitted via the same tick as Lyme disease.
 - Similar symptoms as Lyme disease (minus rash)
 - **Fever, headache**, fatigue, myalgia
 - Labs may be normal, or may show leukopenia, thrombocytopenia, elevated liver enzymes, proteinuria
 - Detectable by PCR
- *Q fever (Coxiella burnetii)*:
 - **Fever, headache**, sore throat, malaise, nausea, diarrhea, chest pain, nonproductive cough, pneumonia, and hepatitis
 - Neurological manifestations occur in about 1% of patients and include meningitis, **encephalitis**, myelitis and/or peripheral neuropathy
 - Detected by indirect immunofluorescence assay.

Putting together the patient's clinical presentation, I think the most likely cause is an infectious encephalitis due to a tick bite. As with many other tick-borne diseases, the symptoms and labs are largely non-specific, thus confounding the diagnosis and making it difficult to pinpoint the exact etiology. Based on the reasoning above, the items remaining on my differential diagnosis are RMSF, WNE, listeria rhombencephalitis, anaplasmosis, Q fever, ehrlichiosis, and Lyme neuroborreliosis. Although neurological involvement in West Nile virus (WNV) encephalitis is <1%, patients who have the disease have tongue fasciculations, lower motor neuron disease and weakness, and local paresthesia. It has a rapid progression, similar to this patient, and the MRI findings involve the pons, which is also similar to this patient. I conclude that **WNV is the culprit in this case**, and the **diagnostic test would be a CSF IgM for WNV**.

CASE OUTCOME (Dr. Rubenstein)

The diagnostic test was an Ehrlichia PCR, which detected *Ehrlichia ewingii*. The patient was admitted to the intensive care unit (ICU), and was continued on vancomycin, ceftriaxone, ampicillin, and acyclovir. Per neurology and radiology, possible etiologies of the MRI findings included multifocal infectious processes, encephalitis, and acute disseminated encephalomyelitis.

While in the ICU, additional history was obtained from the patient's wife. She reported that he had intermittent fevers for several days preceding admission and multiple recent tick and mosquito bites. She also stated that he had a several-year history of recurrent sinusitis, bronchitis, and pneumonia. He was subsequently started on doxycycline with concern for tick-borne illness. With a history of recurrent upper and lower respiratory tract infections, there was concern that

an undiagnosed underlying immunodeficiency could have contributed to his severe course.

Unfortunately, over the next several hours, the patient's clinical condition worsened. He was persistently hyperpyrexia despite antipyretics, BPs were labile, and neurologic exam revealed bilaterally fixed and dilated pupils. A repeat CT of the head was performed and showed interval development of significant edema, and a small area of hemorrhage with mass effect and midline shift. All sedating medications were held, and he remained unresponsive with loss of oculocephalic, corneal, and gag reflexes. An electroencephalogram was obtained and showed no variability or reactivity, further indicative of a poor prognosis.

After discussion with the family, and in consideration of the patient's wishes, he was transitioned to comfort care with a plan for compassionate ventilator weaning. Within three days of his initial presentation, the patient died. The cause of death was hemorrhagic encephalitis leading to cerebral edema and brain herniation. Two days posthumously, the ehrlichia PCR resulted.

RESIDENT DISCUSSION

Ehrlichiosis, a zoonosis, describes an illness caused by bacteria of the genus *Ehrlichia*, most commonly *E. chaffeensis*, and *E. ewingii*. They are obligate intracellular pathogens and were discovered to cause disease in humans in 1986, and in 1999, respectively.^{10,11} The incidence and prevalence of ehrlichiosis has been steadily increasing since it was discovered. The disease primarily occurs in the geographic distribution of its arthropod vector, the lone star tick (*Amblyomma americanum*): South Central, Midwest, and Eastern United States. The vertebrate reservoir for *E. chaffeensis* is deer, while *E. ewingii* is found in both deer and dogs. The peak transmission of Ehrlichia occurs in summer and peaks in June and July.¹² Ehrlichiosis is overwhelmingly transmitted through tick bites, but the disease has been transmitted through blood transfusion, kidney transplantation, and direct contact with a slaughtered deer.¹³

The signs and symptoms of ehrlichiosis typically occur within 5-14 days after the bite of an infected tick. Signs and symptoms in the first few days of illness most commonly include fever, as well as headache, malaise, myalgias, and confusion. Rash occurs in less than 30% of adults and up to 60% of children. The rash is nonpruritic and can vary in appearance from petechial to maculopapular to macular. Late signs and symptoms include encephalitis, meningitis, coagulopathies, organ failure, and death. Risk factors for severe disease include an immunocompromised state, the extremes of age, and delayed treatment.¹⁴

The workup in the ED will depend on the presenting symptoms and severity of illness. It is important to note that the tick bite is not painful, and it is unlikely that your patient will remember being bitten. It is the job of the clinician to keep tick-borne illnesses such as ehrlichiosis on the differential diagnosis for patients presenting with nonspecific

febrile illnesses in an endemic area, especially during peak transmission months in the summer. A thorough history should include a history of recent tick bites and exposure to wooded areas or high grass.

In a patient with fever, altered mental status, or headache of uncertain origin, a lumbar puncture should be considered. Most commonly, CSF analysis shows lymphocytic pleocytosis with elevated protein. The most common lab abnormalities found in patients with ehrlichiosis include leukopenia, thrombocytopenia, transaminitis, elevated lactate dehydrogenase, and elevated alkaline phosphatase. The CSF and laboratory findings are nonspecific and cannot definitively diagnose ehrlichiosis.

Treatment for ehrlichiosis should not be delayed by the lack of a diagnosis. If there is a suspicion, treatment should be started immediately. Ehrlichiosis can be diagnosed by PCR, serology, immunohistochemical assay and culture, and blood-smear microscopy; however, these are not universally available. Which test to send should be decided based on institutional availability and in consultation with an infectious disease expert.

Doxycycline is the treatment of choice for ehrlichiosis in patients of all ages. The dosing regimen for adults is 100 mg either orally or IV, twice daily. For children less than 45 kg, the dose is 2.2 mg/kg/dose, either IV or orally, twice daily. In a child less than or equal to eight years of age, doxycycline should still be administered, as the benefits of treatment outweigh the risks of potential adverse effects. There is evidence that a short course of doxycycline does not result in permanent teeth staining or enamel hypoplasia. The minimum recommended course of doxycycline is five to seven days, and treatment should continue at least three days after the subsidence of fever or until there is evidence of clinical improvement. In a critically ill patient, or in a patient with severe disease, typical broad-spectrum antibiotic coverage should be started along with doxycycline, as the presentation is nonspecific and can overlap with many other disease processes.

FINAL DIAGNOSIS

Hemorrhagic encephalitis secondary to ehrlichiosis leading to cerebral edema and brain herniation.

KEY TEACHING POINTS

- Ehrlichiosis must be considered for a patient with a febrile illness of unknown origin, especially in an endemic area during the summer months.
- Practitioners should maintain a high clinical suspicion for all tick-borne diseases in patients from endemic regions who present with nonspecific febrile illnesses.
- Endemic areas include the South Central, Midwest, and Eastern United States.
- Treatment of choice is doxycycline for patients of all ages.

The authors attest that their institution requires neither Institutional Review Board approval, nor patient consent for publication of this case report. Documentation on file.

Address for Correspondence: : Laura Bontempo, MD, MEd, University of Maryland, Department of Emergency Medicine, 110 S Paca Street, 6th Floor, Suite 200, Baltimore, MD 21201. Email: Lbontempo@som.umaryland.edu.

Conflicts of Interest: By the CPC-EM article submission agreement, all authors are required to disclose all affiliations, funding sources and financial or management relationships that could be perceived as potential sources of bias. The authors disclosed none.

Copyright: © 2020 Rubenstein et al. This is an open access article distributed in accordance with the terms of the Creative Commons Attribution (CC BY 4.0) License. See: <http://creativecommons.org/licenses/by/4.0/>

REFERENCES

1. Kennedy PGE. Viral encephalitis: causes, differential diagnosis, and management. *J Neurol Neurosurg Psychiatry*. 2004;75(suppl 1):i10-5.
2. Singh N, Ray S, Srivastava A. Clinical mimickers of amyotrophic lateral sclerosis-conditions we cannot afford to miss. *Ann Indian Acad Neurol*. 2018;21(3):173-8.
3. Jubelt B, Mihai C, Li TM, et al. Rhombencephalitis / Brainstem encephalitis. *Curr Neurol Neurosci Rep*. 2011;11(6):543-52.
4. Habarugira G, Suen WW, Hobson-Peters J, et al. West Nile virus: an update on pathobiology, epidemiology, diagnostics, control and "one health" implications. *Pathogens*. 2020;9(7):589.
5. Deresiewicz RL, Thaler SJ, Hsu L, et al. Clinical and neuroradiographic manifestations of eastern equine encephalitis. *N Engl J Med*. 1997;336(26):1867-74.
6. Just M, Krämer G, Higer HP, et al. MRI of Listeria rhombencephalitis. *Neuroradiology*. 1987;29(4):401-2.
7. Baganz MD, Dross PE, Reinhardt JA. Rocky Mountain spotted fever encephalitis: MR findings. *Am J Neuroradiol*. 1995;16(4):919-22.
8. Lindland ES, Solheim AM, Andreassen S, et al. Imaging in Lyme neuroborreliosis. *Insights Imaging*. 2018;9(5):833-44.
9. Dylewski J, Domingo M-C, Thivierge K. A Hail Mary diagnostic success: human granulocytic anaplasmosis. *Infect Dis Clin Pract*. 2019;27(4):226-7.
10. Maeda K, Markowitz N, Hawley RC, et al. Human infection with *Ehrlichia canis*, a leukocytic *Rickettsia*. *N Engl J Med*. 1987;316(14):853-6.
11. Buller RS, Arens M, Hmiel SP, et al. *Ehrlichia ewingii*, a newly recognized agent of human ehrlichiosis. *N Engl J Med*. 1999;341(3):148-55.
12. Rau A, Munoz-Zanzi C, Schotthoefer AM, et al. Spatio-temporal dynamics of tick-borne diseases in North-Central Wisconsin from 2000–2016. *Int J Environ Res Public Health*. 2020;17(14):5105.
13. Bakken JS, Krueth JK, Lund T, et al. Exposure to deer blood may be a cause of human granulocytic ehrlichiosis. *Clin Infect Dis*. 1996;23(1):198.
14. Biggs HM. Diagnosis and management of tickborne rickettsial diseases: Rocky Mountain spotted fever and other spotted fever group rickettsioses, ehrlichioses, and anaplasmosis — United States. *MMWR Recomm Rep*. 2016;65(No. RR-2):1–44.

Three Medicolegal Cases of Searching for the Stone: Lessons Learned Along the Journey

Ashley A. Jacobson, MD*
Ayumi E. Sakamoto, BA†
Gregory P. Moore, MD, JD*
Eric T. Boie, MD*

*Mayo Clinic, Department of Emergency Medicine, Rochester, Minnesota
†Mayo Clinic, Kogod Center on Aging, Rochester, Minnesota

Section Editor: Melanie Heniff, MD

Submission history: Submitted June 10, 2020; Revision received August 25, 2020; Accepted September 4, 2020

Electronically published October 20, 2020

Full text available through open access at http://escholarship.org/uc/uciem_cpccem

DOI: 10.5811/cpcem.2020.9.48652

We present three medicolegal cases of medical negligence settled out of court. These cases all involved patients who presented to the emergency department (ED) with a suspected diagnosis of kidney stone. Highlighted are the importance of patient communication, addressing incidental findings found during a patient's ED visit, anticipating complications, and the need for thorough documentation. [Clin Pract Cases Emerg Med. 2020;4(4):505–508.]

Keywords: *Malpractice; kidney stone; contributory negligence.*

INTRODUCTION

Many emergency physicians (EP) recognize the need for a complete laboratory evaluation and imaging to evaluate a patient's presenting complaint within the emergency department (ED). Frequently, the importance of communicating with patients on incidental findings and ensuring they have a clear understanding of the discharge plan is not recognized. Complications of the diagnosis should also be anticipated and discussed. Three cases below illustrate how these factors can lead to medical negligence and financial liability. We also review the legal defenses of contributory negligence and comparative fault as a tool to decrease provider liability.

CASE 1: *Kline versus St. Luke's University Health Network et al*

A 49-year-old male with a history of kidney stones presented to the ED with severe back pain and trouble urinating. A computer axial tomography (CT) of the kidneys, ureter and bladder (KUB) was obtained and the study confirmed the presence of kidney stones in both kidneys, as well as a ureteral stone obstruction. In addition to the stones, the radiologist noted that there was a large hematoma or blood clot that could have been a mass in the bladder wall. The patient was discharged with a kidney stone diagnosis and advised to schedule an appointment with a urologist within three to five days. The

patient returned a year later with worsening symptoms and was diagnosed with a tumor that had overtaken the majority of his bladder. Surgery to remove the tumor was unsuccessful.

Further review confirmed that it was the identical mass identified on CT a year earlier. The operation also revealed that the mass had evolved into an advanced cancer. The patient denied that he had been informed about the tumor when he was sent home with the diagnosis of kidney stone. Furthermore, he claimed that if he had been told about the mass, he would have more seriously heeded his doctor's instructions to see a urologist. The patient brought suit as a plaintiff claiming that the delay and ambiguity of his diagnosis significantly decreased his chances of survival, in addition to subjecting him to another more invasive surgery. Although the defendants admitted that the radiologist's notes indicated that the mass was potentially malignant, they contended that the patient was well informed about the mass and instructed to see a urologist, alleging that it was the patient's very own negligence that caused the harm by not complying with the discharge orders. A settlement of 10 million dollars was rewarded.¹

CASE 2: *Anonymous versus Anonymous*

A 49-year-old female presented to the ED with abdominal pain. A CT was performed showing an obstructing kidney stone. A urinalysis was ordered by the EP to rule out urinary

tract infection (UTI); however, nursing staff never obtained the specimen and the EP discharged the patient knowing that it had not been obtained. The patient presented a second time and ultimately died three days later from severe urosepsis secondary to an untreated UTI. A lawsuit was initiated for failure to complete the testing ordered, ultimately leading to delay in diagnosis and treatment, and subsequent death. The plaintiff argued that a urine sample is required for proper management of an obstructing kidney stone and that would have shown evidence of a UTI. The plaintiff claimed that if the diagnosis had been established on the first visit, she would have subsequently been treated with antibiotics, and death would have been prevented. The EP claimed a urine sample was attempted but was unsuccessful, and that even if the urinalysis had been completed, it might not have shown infection. A settlement of 2.6 million dollars was reached.²

CASE 3: *Anonymous versus Anonymous*

A 35-year-old female presented to the ED with back pain. A CT KUB and urinalysis were completed demonstrating a kidney stone and concomitant UTI. Antibiotics and pain medication were prescribed. She was counseled to follow up with urology in two to four days. The patient went home under the impression she would pass the stone at home after discussion with the EP. Unfortunately, the pharmacy was closed and the patient did not fill the antibiotic medication that evening. The next morning, she was found confused and transported again to the ED in septic shock. The patient ultimately recovered after a two-week hospital stay that resulted in amputation of one forearm and bilateral feet. The plaintiff brought suit and argued that the importance of filling the prescription was not explained to her. The defense argued that she had received proper treatment and it was because of the patient's negligence in not picking up her medication in a timely matter that she had a bad outcome. A settlement of 1.08 million dollars was reached.³

DISCUSSION

Ms. Sakamoto and Dr. Moore

These three cases illustrate some of the pitfalls and mistakes that can lead to increased liability for the EP. These may occur in the general ED diagnosis and treatment of patients of many diagnoses and specifically when evaluating for potential ureteral calculus.

Incidental CT findings are a common occurrence. A study by Thompson et al in 2011 reported that around 33.4% of 682 CTs performed in the ED of an urban Level I trauma center revealed at least one incidental finding. However, these findings were disclosed to the patient in discharge paperwork only 9.8% of the time. Alarming, some potentially life-threatening incidental findings such as aortic dilations and pulmonary nodules were only disclosed 33.3% and 25% of the time, respectively. In addition, patients were much less

likely to receive disclosure if they did not have more than one incidental finding. Because this study only accounted for written disclosure on discharge paperwork, it is plausible that many patients were verbally informed of a finding. Nonetheless, the study reveals a lack of proper and thorough documentation and discharge instructions for patients with incidental findings.⁴

A similar study was conducted at another ED trauma center that considered the severities of incidental findings. Of 848 CTs, there were 289 incidental findings of varying severities. The incidental findings were classified as Category 1 (needing attention before discharge), Category 2 (requiring follow-up with a primary care provider in 1-2 weeks), or Category 3 (no follow-up needed). Of the 289 incidental findings, 31 were designated as Category 1, while 108 were Category 2, and 145 were Category 3. Only 48.4% of Category 1 incidental findings (15/31) had proper documentation of treatment, management, and follow-up.⁵ Collectively, these reports shed light on the significant lack of thorough disclosure and documentation of incidental CT findings in emergency care.

It is critical that ED patients are made aware of incidental findings and laboratory tests ordered from the ED. Every ED, hospital, radiology department, and laboratory should have defined mechanisms to identify and communicate abnormalities. The patient should be informed verbally of the importance of future studies, evaluation, and treatment. This should then be documented on the discharge instructions and in the chart, eg, "x-ray discrepancy discussed." It is optimal if the primary physician or consultant can be informed as well.

When incidental findings or lab abnormalities are discovered after patient discharge, the information should be relayed to the patient via electronic, phone, or mailed communication, as well as to the primary physician or consultant, if possible, to avoid liability.

A safe "triangle" in these situations should be constructed between the following three points: 1) the EP; 2) the patient; and 3) the primary/consultant physician. When malpractice cases are pursued due to lack of communication of abnormal results that result in bad outcomes, the defendant is rarely successful in avoiding liability. The authors have identified multiple cases of abnormal tests that were not followed up and subsequently litigated. Not a single case reviewed was ruled in favor of the defendant.

Dr. Jacobson and Dr. Boie

Nephrolithiasis typically presents as unilateral flank pain with radiation to the groin. The initial workup for first-time kidney stone typically consists of ordering a non-contrast CT abdomen/pelvis. A non-contrast CT abdomen/pelvis, at conventional radiation doses, is 94-97% sensitive and 96-99% specific for diagnosis of ureteral calculi and has become the gold standard for diagnosis when compared to renal and bladder ultrasound or abdominal radiography for first-time

stone diagnosis.⁶ If there is concern for obstruction, a clean urine sample should be obtained for urinalysis and urine culture with concern for acute complicated UTI. If pyuria and bacteriuria are present, antibiotics should be administered and a urologic specialist consulted for consideration of possible surgical decompression.^{6,7}

One single-center, prospective, observational study found that 7.8% of patients with kidney stones had concurrent UTI; this study did not comment on obstruction.⁸ Kidney stones account for approximately 66% of obstructive pyelonephritis.⁷ It is important to note that the urinalysis may appear deceptively normal if the infection is proximal to the obstruction.^{7,9} Additional risk factors that include perinephric fat stranding on CT, greater than 50 white blood cells per high-powered field on urine microscopy, a positive urine Gram stain, elevated procalcitonin, and elevated C-reactive protein can help risk stratify for possible proximal infection with a greater number of factors present increasing the likelihood of concurrent UTI.⁹ Obstructive kidney stone with subsequent pyelonephritis and sepsis has a 19% mortality rate without surgical decompression vs 9% mortality rate with intervention.⁷ As our cases illustrate, overwhelming urosepsis can occur rapidly, and admission to the hospital with prompt treatment may be optimal.

It is imperative to identify concomitant urine infection to decrease morbidity and mortality. In Case 3, the patient was prescribed antibiotics for a non-obstructed kidney stone with concurrent UTI, which is the standard of care. However, she was unable to pick up the medication from the pharmacy right away resulting in septic shock and significant morbidity of forearm and bilateral foot amputations.

Overall, discharged patients are prone to rapid deterioration from sepsis if concomitant infection is present. A first dose of antibiotics given in the ED, prior to discharge, would ensure initial compliance and theoretically improve patient outcomes. In general, urology consultation is recommended if a stone is obstructing the ureter and the urine is infected to insure optimal treatment and disposition for patient care.³

Contributory negligence is “conduct on the part of the plaintiff which falls below the standard to which he should conform for his own protection, and which is a legally contributing cause co-operating with the negligence of the defendant in bringing about the plaintiff’s harm.”¹⁰ In other words, if the patient is partly to blame for what happened then they may be assigned responsibility for the poor outcome as well as the care provider. This concept originated with the landmark legal case of *Butterfield v Forrester*.¹¹ In this infamous case in 1809, a man was riding his horse extremely fast and was knocked off after hitting a pole that had recently been placed by the defendant. The jury determined that any person riding in a reasonable manner would have noticed the pole, thus avoiding the entire accident. Since the plaintiff’s own actions resulted in

the accident, it was determined he should not be allowed to recover any damages.

Currently, four states (Alabama, Maryland, North Carolina, Virginia) and the District of Columbia recognize pure contributory negligence.¹² If the patient is at all responsible for the negative outcome, they are not allowed to pursue their lawsuit. Most courts view contributory negligence as inherently unfair. These jurisdictions have replaced pure contributory negligence with comparative fault. This concept allows the plaintiff to recover some damages minus the plaintiff’s degree of fault. For example, a jury awards \$100,000 to a case where the patient was deemed 90% at fault and the physician 10%. In this case, the plaintiff would only receive \$10,000 (10%), which was the direct fault of the physician’s negligence.¹²

States have adopted different versions of comparative fault. Pure comparative fault as described above is recognized in 13 states. Eleven states recognize modified comparative fault – 50% bar, which allows the plaintiff to recover damages only if their percent at fault is less than or equal to 50%. If the plaintiff patient is more than 50% at fault, then he or she cannot recover any damages. Twenty-two states acknowledge modified comparative fault – 51% bar. In this rule, the plaintiff cannot recover damages if he or she is found to be greater than or equal to 51% at fault.¹²

For example, in *Harlow v Chin*, the patient was found 13% at fault for not seeking further medical workup for worsening pain from an undiagnosed cervical disc herniation ultimately leading to quadriplegia. This resulted in an award of 87% to the plaintiff.¹³ Looking at Case 1, the concept of comparative fault was advocated by the defense. At trial, the patient was determined to be 15% at fault, the EP 15%, and the emergency medicine resident physician 60%, thus awarding the patient \$8.5 million from the \$10 million verdict (ie, 85% determined due to be the direct negligence of the physicians’ malpractice).¹ Overall, it is crucial for all incidental findings to be reported and clearly explained to the patient even if they had already been discharged from the ED.

Without proper systems in place to relay such findings, more patients will suffer and increased liability will ensue. Therefore, clear and effective communication is critical in the ED so that the patient is properly notified of any abnormal findings and advised to follow up appropriately. The physician should thoroughly inform the patient of the importance of a follow-up and the consequences of not doing so. Again, these disclosures should be well documented to ensure legal protection if patient outcomes are unfavorable.¹² If this is accomplished, the defense of comparative fault or contributory negligence will be viable.

CONCLUSION

We have presented three selected cases of claims of medical negligence that were settled before trial and not taken to court. They illustrate the importance of addressing

incidental findings and communicating the results, and following up on laboratory ordering and result analysis. If proper communication and documentation are done by the provider, a legal defense of contributory negligence or comparative fault is a viable and accepted approach to avoiding successful litigation.

Take-home Points

1. Incidental findings are not an infrequent occurrence when ordering CTs and subsequently become more health threatening to the patient than the primary medical issue. It behooves the physician to ensure follow-up of incidental findings.
2. It is extremely important to adequately document conversations, risks/benefits, and return precautions with the patient within written documentation.
3. It is vital to identify concomitant urine infection to decrease mortality in patients presenting with an obstructive kidney stone. Urology consultation is recommended if a stone is infected for surgical decompression and/or hospital admission. Consider first dose of antibiotics in the ED before discharge.
4. Be aware of the law in your state. Patients can be held responsible and assigned a percentage of fault if their action or inaction contributed to a poor outcome and harm.
 - Pure Contributory Negligence: Alabama, Maryland, North Carolina, Virginia, the District of Columbia
 - Pure Comparative Fault: Alaska, Arizona, California, Florida, Kentucky, Louisiana, Mississippi, Missouri, New Mexico, New York, Rhode Island, South Dakota, Washington
 - Modified Comparative Fault–50% bar: Arkansas, Colorado, Georgia, Idaho, Kansas, Maine, Nebraska, North Dakota, Tennessee, Utah, West Virginia
 - Modified Comparative Fault–51%bar: Connecticut, Delaware, Hawaii, Illinois, Indiana, Iowa, Massachusetts, Michigan, Minnesota, Montana, Nevada, New Hampshire, New Jersey, Oklahoma, Ohio, Oregon, Pennsylvania, South Carolina, Texas, Vermont, Wisconsin, Wyoming.

The authors attest that their institution requires neither Institutional Review Board approval, nor patient consent for publication of this medical legal case report. Documentation on file.

Address for Correspondence: Gregory P. Moore, MD, JD, Mayo Clinic, Department of Emergency Medicine, 507 Nisqually Street, Steilacoom, WA 98388. Email: gmoore4408@aol.com.

Conflicts of Interest: By the *CPC-EM* article submission agreement, all authors are required to disclose all affiliations, funding sources and financial or management relationships that could be perceived as potential sources of bias. The authors disclosed none.

Copyright: © 2020 Jacobson et al. This is an open access article distributed in accordance with the terms of the Creative Commons Attribution ([CC BY 4.0](http://creativecommons.org/licenses/by/4.0/)) License. See: <http://creativecommons.org/licenses/by/4.0/>

REFERENCES

1. *Kline v. St. Luke's University Health Network, et al.* Lehigh County (PA) Court of Common Pleas, Case No. 2017-C-2747. MMVSE No. 200335.
2. *Anonymous v Anonymous.* Medical Malpractice: Verdicts, Settlements and Experts. March, 2020;36(3):5.
3. *Anonymous v Anonymous.* Medical Malpractice: Verdicts, Settlements and Experts. 2020; 36(4):5.
4. Thompson RJ, Wojcik SM, Grant WD, et al Incidental findings on CT scans in the emergency department. *Emerg Med Int.* 2011;2011:624847.
5. Paluska TR, Sise MJ, Sack DI, et al. Incidental CT findings in trauma patients: incidence and implications for care of the injured. *J Trauma.* 2007;62(1):157-61.
6. Manthey DE and BA Nicks. (2018). Urologic stone disease. In: Tintinalli JE (Ed.), *Tintinalli's Emergency Medicine: A Comprehensive Study Guide, 9th ed.* New York, NY: McGraw-Hill Education.
7. Marien T and Miller NL. Treatment of the Infected stone. *Urol Clin North Am.* 2015;42(4):459-72.
8. Abrahamian FM, Krishnadasan A, Mower WR, et al. Association of pyuria and clinical characteristics with the presence of urinary tract infection among patients with acute nephrolithiasis. *Ann Emerg Med.* 2013;62(5):526-33.
9. Manka M, Wymer K, Sharma V, et al. A novel clinical risk score to predict true infection in the setting of obstructing urolithiasis. *J Urol.* 2019;201(4S):1048-9.
10. Restatement (Second) of Torts, Section 463-96.
11. *Butterfield v. Forrester.* 11 East. 60, 103 Eng. Rep. 926 (K.B. 1809).
12. Moore GP. Liability of emergency physicians for studies ordered in the emergency department: court cases and legal defenses. *J Emerg Med.* 2011;40(2):225-8.
13. *Harlow v. Chin.* 54 N.E.2d 602 (Mass. 1989).

Prolonged Duration of Viral Shedding of SARS-CoV-2: A Case Report

Brandon Fong, MD
Kory S. London, MD

Thomas Jefferson University Hospital, Department of Emergency Medicine,
Philadelphia, Pennsylvania

Section Editor: Rick A. McPheeters, DO

Submission history: Submitted July 8, 2020; Revision received July 23, 2020; Accepted July 24, 2020

Electronically published August 8, 2020

Full text available through open access at http://escholarship.org/uc/uciem_cpem

DOI: 10.5811/cpcem.2020.7.49005

Introduction: The literature on the clinical course of severe acute respiratory syndrome coronavirus 2 (SARS-CoV-2) suggests patients continue shedding viral particles typically for an average of 20 days until the body builds immunity against the infection. However, a few cases have shown prolonged duration in viral shedding and highlight the significant increased mortality in these patients. It has also been suggested that multiple strains of SARS-CoV-2 exist, keying the possibility to reinfection.

Case Report: We present a case of a 57-year-old male who presented twice over 37 days with symptoms related to SARS-CoV-2, and only on his second visit was found to be in hypoxemic respiratory failure and cardiogenic shock. He also reportedly had a period of convalescence in between presentations.

Discussion: This case highlights the still unclear disease course of SARS-CoV-2 and the need for diligence in providing strong follow-up instructions and evaluation for sequelae of the infection. [Clin Pract Cases Emerg Med. 2020;4(4):509–512.]

Keywords: SARS-CoV-2; hypoxemic; respiratory failure; cardiogenic shock.

INTRODUCTION

The novel severe acute respiratory syndrome coronavirus 2 (SARS-CoV-2) outbreak has been shown to cause respiratory failure, cytokine storm, and disease complications such as thrombosis.¹⁻⁴ The immune system takes around three weeks to develop antibodies to combat the infection and enter into a period of convalescence. This is consistent with prior studies that reported the median duration of viral shedding to be 20 days.² However, one case report and retrospective study documented in China noted prolonged shedding of viral ribonucleic acid (RNA) as detected by reverse transcription-polymerase chain reaction (RT-PCR).⁶ Finally, a single case of a patient with an initially severe course of SARS-CoV-2 was readmitted nearly two months later after a mild recurrence of symptoms.⁵ None of these patients developed severe symptoms late in their course. Herein we present a case of a patient who presented initially with mild symptoms of SARS-CoV-2 and was later readmitted with a fulminant course.

This case challenges the understanding of viral immunity and progression of this novel disease.

CASE REPORT

A 57-year-old male with a past medical history of hypertension, type 2 diabetes mellitus, coronary artery disease with history of non-ST elevation myocardial infarction in February 2019, and ischemic cardiomyopathy with reduced ejection fraction of 40% initially presented to the emergency department in mid-April with symptoms of subjective fever, cough, and mild chest pain for four days. He tested positive for SARS-CoV-2 via RT-PCR, along with a one-view chest radiograph (CXR) interpreted as multifocal pneumonia of bilateral lower lobes (Image 1).

His electrocardiogram (ECG) showed normal sinus rhythm along with unchanged infero-lateral ST depression from prior ECGs. His vital signs were within normal limits. He was observed for one day and discharged with self-

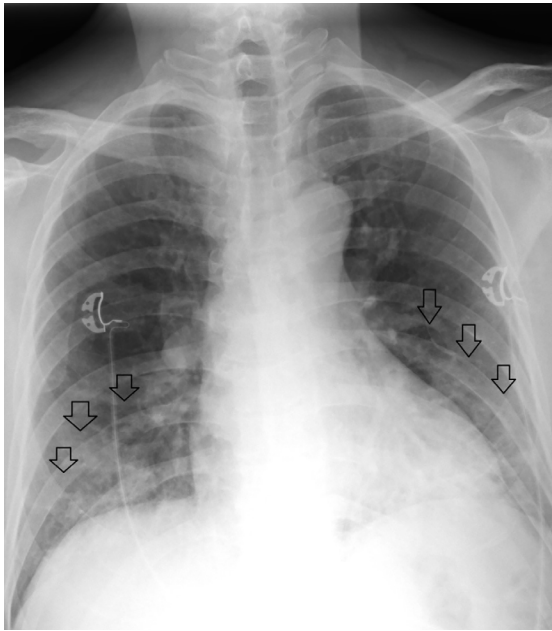


Image 1. Initial anterior-posterior chest radiograph of a patient with coronavirus disease 2019 demonstrating bilateral lower lobe infiltrates (arrows).

isolation precautions. After discussion with his roommates and landlord, we learned that his symptoms had improved in the intervening period but never resolved.

In mid-May he was brought in by emergency medical services for fatigue and respiratory distress, having worsened over the previous 48 hours. His triage vital signs were oral temperature of 97.4° Fahrenheit, heart rate 140 beats per minute, blood pressure 73/32 millimeters of mercury (mmHg), respiratory rate of 26 breaths per minute, and pulse oximetry of 63% on room air. He was placed on bilevel positive airway pressure and subsequently became obtunded. He went into pulseless electrical activity (PEA), coded with return of spontaneous circulation after 20 minutes, and was intubated. Physical examination was remarkable for crackles in bilateral bases of the lungs and cold distal upper and lower extremities. ECG was non-diagnostic but showed sinus tachycardia without ST segment elevation. Point-of-care ultrasound showed a severely depressed ejection fraction without evidence of pulmonary embolism/hypertension.

Significant laboratory results were as follows: repeat SARS-CoV-2 positive; white blood cells 12.3 thousand per cubic millimeter (K/mm^3) (reference range 4.5-11.5 K/mm^3); lactic acid was 15 millimoles per liter (mmol/L) (reference range 0.5-2.2 mmol/L); troponin 889 nanograms per liter (ng/L) (reference range <6 ng/L); creatinine 1.75 milligrams per deciliter (mg/dL) (reference range 0.84-1.21 mg/dL); venous blood gas pH 6.89 (reference range 7.32-7.43) and partial pressure of carbon dioxide (pCO_2) of 81 mmHG (reference range 38-50 mmHg); D-dimer 2735 nanograms

CPC-EM Capsule

What do we already know about this clinical entity?

While the novel coronavirus disease 2019 has a median viral shedding course of 20 days, one study reported prolonged viral shedding greater than 20 days.

What makes this presentation of disease reportable?

Our patient was seen and treated twice, 37 days apart, with a period of convalescence intervening, and suffered a fulminant and fatal disease course.

What is the major learning point?

The case highlights the still unclear disease course. Patients suffer many sequelae, but primary severe acute respiratory coronavirus 2 is also a highly morbid disease.

How might this improve emergency medicine practice?

This case shows importance of educating patients about return precautions and for adequate follow-up care to monitor progression of symptoms after 20 days.

per milliliter (reference range <250 ng/mL). He was human immunodeficiency virus negative with no prior history of liver dysfunction. A one-view CXR was interpreted as multifocal pneumonia, but with markedly worsening bilateral pulmonary infiltrates compared to his previous CXR from his prior visit (Image 2).

He was admitted to the medical intensive care unit (MICU) for hypoxemic respiratory failure with mixed picture of cardiogenic shock and septic shock and was started on vancomycin, piperacillin/tazobactam, and azithromycin for broad-spectrum antimicrobial coverage. In the MICU, the patient continued to have low mean arterial pressures despite being on multiple vasopressor medications: norepinephrine; vasopressin; and epinephrine. He was started on dexamethasone for concern for adrenal insufficiency. He developed acute renal failure and ischemic hepatitis with elevated creatinine to 4.89 mg/dL; alanine transaminase 6666 units per liter (U/L) (reference range 7-55 U/L); and aspartate aminotransferase of 7115 U/L (reference range 8-48 U/L), respectively. On his third day of hospitalization, he went into PEA again and finally into asystole and was not revivable. His blood, urine, and sputum cultures were ultimately negative.

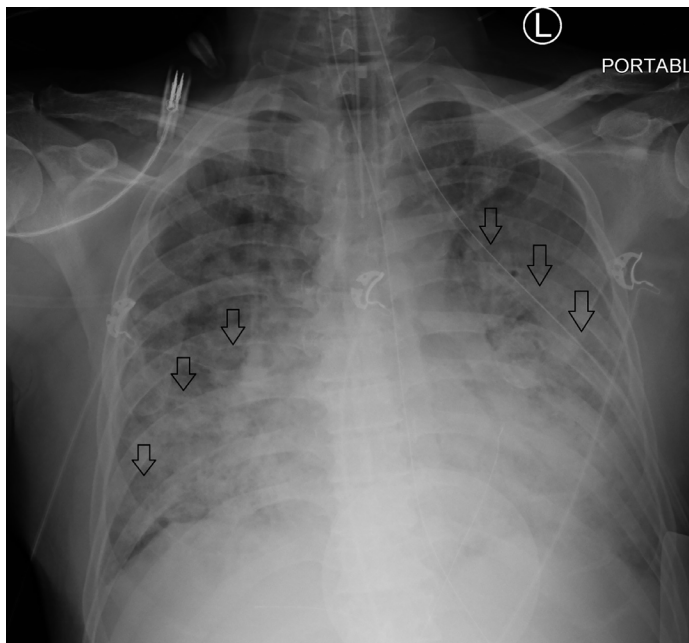


Image 2. Anterior-posterior chest radiograph (CXR) 37 days after the CXR shown in Image 1 in a patient with coronavirus disease 2019, demonstrating markedly worsening bilateral pulmonary infiltrates (arrows).

DISCUSSION

This case raises the possibility that patients may suffer cardiopulmonary compromise long after their initial presentation of SARS-CoV-2, or may be prone to re-infection. One study reported a median duration of viral shedding of 20.0 days (interquartile range [17.0–24.0]) following symptom onset.¹ These patients developed acute respiratory distress syndrome between 8-12 days following onset of symptoms. Moreover, another report from China showed, in a cohort of 41 patients, the duration of RNA shedding ranged from 18-48 days.² These patients also had severe illness at their index visits, followed by convalescence with persistent shedding of the virus. One final case report from China documented how a patient who developed acute respiratory distress from SARS-CoV-2 12 days into their illness, had persistent viral shedding in the respiratory tract for 46 days from illness onset.⁶ None of these patients had a similar course to our patient, who suffered a very late fulminant course with respiratory failure and shock 37 days following onset of symptoms.

Recently, a study of convalescent serum revealed that many patients do not develop high levels of neutralizing antibody activity.⁷ This finding leaves unclear the issue of duration of immunity post-infection. Similarly, it has been shown that there is significant genetic variation in SARS-CoV-2, with the possibility of coexisting viral strains in some communities.⁸ This posits the possibility that patients may become re-infected with different SARS-CoV-2 strains and, ergo, prior infection may not necessarily be protective. While specific genetic serotyping of the patient was not available,

given the very long duration between initial symptoms and decompensation, this suggests the possibility that he may have suffered two distinct illnesses.

There are certain risk factors that place patients at a higher likelihood of susceptibility to prolonged viral shedding and complications. One study reported these risk factors included male gender, being elderly, and having hypertension, along with mechanical ventilation and corticosteroid use; however, the study data did not incorporate patients past duration of RNA shedding after 22 days.⁹ Our patient had two of these risk factors (male and concomitant hypertension) reinforcing his chances of prolonged viral shedding. Additionally, he also had a complex past medical history, having suffered a recent myocardial infarction one year prior to his death. Known coronary artery disease is an especially troubling risk factor, with dramatically increased rates of morbidity and mortality.^{3,10} Our case reiterates this finding with our patient who had extensive cardiovascular comorbidities, thus increasing his predisposition to cardiac complications resulting in his cardiogenic shock.

CONCLUSION

In this case, a patient returned five weeks following mild SARS-COV-2 infection with a fulminant course. Increased attention to those with significant comorbidities and providing strict and accurate follow up information to patients is essential given the unknowns associated with this novel disorder.

The authors attest that their institution requires neither Institutional Review Board approval, nor patient consent for publication of this case report. Documentation on file.

Address for Correspondence: Kory S. London, MD, Thomas Jefferson University Hospital, Department of Emergency Medicine, 1020 Sansom Street, Suite 239, Philadelphia, PA 19107. Email: kory.london@jefferson.edu.

Conflicts of Interest: By the CPC-EM article submission agreement, all authors are required to disclose all affiliations, funding sources and financial or management relationships that could be perceived as potential sources of bias. The authors disclosed none.

Copyright: © 2020 Fong et al. This is an open access article distributed in accordance with the terms of the Creative Commons Attribution (CC BY 4.0) License. See: <http://creativecommons.org/licenses/by/4.0/>

REFERENCES

1. Li X and Ma X. Acute respiratory failure in COVID-19: is it “typical” ARDS? *Crit Care*. 2020;24(1):198.
2. Zhou B, She J, Wang Y, et al. The duration of viral shedding of

- discharged patients with severe COVID-19. *Clin Infect Dis*. 2020. In press.
3. Lazaridis C, Vlachogiannis NI, Bakogiannis C, et al. Involvement of cardiovascular system as the critical point in coronavirus disease 2019 (COVID-19) prognosis and recovery. *Hellenic J Cardiol*. 2020. In press.
 4. Barnes GD, Burnett A, Allen A, et al. Thromboembolism and anticoagulant therapy during the COVID-19 pandemic: interim clinical guidance from the anticoagulation forum. *Journal Thromb Thrombolys*. 2020;50:72-81.
 5. Li XJ, Zhang ZW, Zong ZY. A case of a readmitted patient who recovered from COVID-19 in Chengdu, China. *Critic Care*. 2020;24(1):152.
 6. Liu Y, Chen X, Zou X, et al. A severe-type COVID-19 case with prolonged virus shedding. *J Formos Med Assoc*. 2020. In press.
 7. Robbiani DF, Gaebler C, Muecksch F, et al. Convergent antibody responses to SARS-CoV-2 in convalescent individuals. *Nature*. 2020. In press.
 8. Pachetti M, Marini B, Benedetti F, et al. Emerging SARS-CoV-2 mutation hot spots include a novel RNA-dependent-RNA polymerase variant. *J Transl Med*. 2020;18(1):179.
 9. Xu K, Chen Y, Yuan J, et al. Factors associated with prolonged viral RNA shedding in patients with COVID-19. *Clin Infect Dis*. 2020;71(15):799-806.
 10. Bonow RO, Fonarow GC, O'Gara PT, et al. Association of coronavirus disease 2019 (COVID-19) with myocardial injury and mortality. *JAMA Cardiol*. 2020. In press.

Case Report: Pediatric Patient with COVID-19 and Multisystem Inflammatory Syndrome in Children

MacKenzie W. Burger, MD
Marcus A. Moore, DO
John M. Wilburn, MD

Wayne State University School of Medicine, Detroit Medical Center Sinai-Grace Hospital, Department of Emergency Medicine, Detroit, Michigan

Section Editor: Anna McFarlin, MD

Submission history: Submitted May 21, 2020; Revision received August 20, 2020; Accepted August 21, 2020

Electronically published September 8, 2020

Full text available through open access at http://escholarship.org/uc/uciem_cpem

DOI: 10.5811/cpcem.2020.8.48376

Introduction: Coronavirus disease 2019 (COVID-19) rarely manifests with severe complications in pediatric patients. An association between COVID-19 and a Kawasaki-like inflammatory syndrome has recently presented in pediatric patients.

Case Report: We report a unique case of multisystem inflammatory syndrome in children presenting with characteristic findings in a child who later developed cardiogenic shock requiring venoarterial extracorporeal membrane oxygenation.

Conclusion: Recognition of these early signs and symptoms facilitates screening and risk stratification of pediatric COVID-19 cases associated with increased morbidity. [Clin Pract Cases Emerg Med. 2020;4(4):513–516.]

Keyword: COVID-19; Kawasaki Disease; PMI; ECMO.

INTRODUCTION

The coronavirus disease 2019 (COVID-19) pandemic has caused more than 21.7 million confirmed cases and 771,000 deaths worldwide as of August 17, 2020.¹ Adult patients comprise the majority of serious cases with acute respiratory failure contributing to significant morbidity and mortality. Pediatric cases of COVID-19 are often associated with mild illness or an absence of symptoms, with critical pediatric cases causing respiratory failure or multiple organ dysfunction syndrome in less than 1% of patients.² We describe a case of a pediatric patient with COVID-19 who initially presented to the emergency department (ED) with signs of an early developing atypical Kawasaki disease (KD) vs streptococcal pharyngitis and who later developed multisystem inflammatory syndrome in children (MIS-C) with myocarditis and cardiogenic shock requiring venoarterial extracorporeal membrane oxygenation (VA-ECMO).

Recent literature has identified cases of a syndrome similar to KD occurring concurrently with or subsequent to COVID-19 in a vulnerable pediatric cohort, with an association between severe acute respiratory syndrome coronavirus 2 (Sars-CoV-2)

and inflammatory vasculitis.³ As of August 2020, there were 570 confirmed MIS-C cases in 40 states, with 10 reported deaths.⁴ ECMO was used in a smaller percent of patients, with a case series of 186 MIS-C cases reporting VA-ECMO use in eight patients.⁵ The majority of MIS-C cases are reported in medicine and pediatric journals from the perspective of authors who did not interact with the patient early in his or her disease course in the ED, with sentinel signs days before decompensation. This is a case report of a pediatric patient with COVID-19 developing myocarditis and cardiogenic shock with cardiac arrest and subsequent VA-ECMO use following an initial presentation of suspected early KD vs early toxic shock syndrome now increasingly recognized as a separate inflammatory syndrome in pediatric COVID-19 cases. Recognition of this pro-inflammatory phenotype, MIS-C, is necessary to effectively risk stratify pediatric patients with COVID-19.

CASE REPORT

During the COVID-19 pandemic, a six-year-old Black female presented to an urban ED after an episode

of syncope with two days of subjective fevers, sore throat, abdominal pain, and a newly developing rash. History was obtained from her parents, who reported loss of appetite and increased fatigue. Her parents were treating her fever with acetaminophen, but they became concerned when the patient had a brief episode of syncope when attempting to stand. Prior to this illness, she had no remarkable past medical history and was up to date with vaccinations. Family was unaware of any sick contacts.

The patient was tired on examination, but appropriately interactive. She had a fever of 39.5° Celsius (C) and was tachycardic with a heart rate of 138 beats per minute (bpm). Other vitals were unremarkable. Her fever defervesced to 36.8°C with acetaminophen and ibuprofen, and the heart rate subsequently normalized. An electrocardiogram (ECG) was not obtained due to clinical impression that orthostasis was secondary to dehydration. The abdominal examination was benign, her throat was minimally erythematous, and her lips were cracked. She did not have lymphadenopathy. Streptococcal polymerase chain reaction (PCR) testing (rapid strep) was positive. On reevaluation, a blanchable erythematous rash initially present on her hands and abdomen had spread to her bilateral lower extremities and the dorsum of her feet. A diagnosis of early KD was considered due to the high fever and cutaneous symptoms, but the patient did not meet criteria for diagnosis. She was given amoxicillin and close follow-up.

The patient returned to the ED three days later with persistent fever and periumbilical abdominal pain, as well as new-onset difficulty breathing, bilateral conjunctivitis, and swollen hands. She had delayed capillary refill, and she was tachypneic and hypotensive with a blood pressure of 70/40 millimeters of mercury (mm Hg). An ECG revealed a heart rate of 116 bpm (reference [ref] range 75-115 bpm) with a prolonged PR interval of 188 milliseconds (ms) (90-170 ms) consistent with first-degree atrioventricular block (Image). Labs were pertinent for ferritin 699 nanograms (ng) per milliliter (mL) (ref: 11-306.8 ng/mL); albumin 3.8 gram (gm) per deciliter (dL) (ref: 3.8-4.7 gm/dL); lactate dehydrogenase 794 units (U) per liter (L) (ref: 140-271 U/L); blood urea nitrogen 33 milligrams (mg)/dL (ref: 7-25 mg/dL); creatinine 1.09 mg/dL (ref: 0.3-0.6 mg/dL), high-sensitivity troponin 114 ng/L (ref: 3-17 ng/L), D dimer 4.21 mg/L (ref: <0.5 mg/L); fibrinogen 834 mg/dL (ref: 186-466 mg/dL); C-reactive protein 450 mg/L (ref: <5.0 mg/L); and hyponatremia with a serum sodium of 118 millimoles (mmol)/L (ref: 136-145 mmol/L). Central and arterial lines were placed, and epinephrine and dopamine drips were started after point-of-care ultrasound revealed diminished left heart function.

A comprehensive cardiac echocardiogram (echo) was obtained upon admission that revealed mildly decreased left ventricular (LV) function, septal hypokinesis, and mild mitral valve (MV) insufficiency with an ejection fraction (EF) of 59%. There were no coronary artery aneurysms. She was admitted to the pediatric intensive care unit for cardiogenic shock vs

CPC-EM Capsule

What do we already know about this clinical entity?

Multisystem inflammatory syndrome in children (MIS-C) case definition: a patient <21 years with fever, inflammation, severe illness requiring hospitalization with multisystem involvement and current/recent coronavirus disease 2019.

What makes this presentation of disease reportable?

Spanning two emergency department visits with a worsening clinical presentation, this case of MIS-C is an example of what not to miss.

What is the major learning point?

Awareness of early symptoms and screening labs are key as most MIS-C patients recover with appropriate intervention.

How might this improve emergency medicine practice?

Familiarizing physicians with MIS-C and appropriate screening labs will heighten awareness when potential MIS-C patients present.

septic shock from KD vs toxic shock syndrome. High-dose aspirin 10 mg/kilogram (kg) every six hours by mouth and intravenous (IV) immunoglobulin 2 cubic centimeter (cc)/kg were initiated along with broad-spectrum antibiotics. COVID-19 PCR testing was positive. Overnight, the patient became increasingly hypoxic and had an accelerated junctional rhythm before developing a bradyarrhythmia, seizure-like activity, and pulseless electrical activity cardiac arrest with return of spontaneous circulation in five minutes. Patient was intubated, sedated, and had several runs of non-sustained ventricular tachycardia before VA-ECMO therapy was initiated for cardiogenic shock.

Patient was successfully taken off ECMO after a course of approximately six days. LV dysfunction and renal failure resolved with repeat comprehensive echo revealing mild concentric LV hypertrophy, normal LV function, trivial MV insufficiency, and mild pulmonary valve insufficiency with an EF of 69%. On discharge, neurological function was within normal limits and consistent with baseline mentation.

DISCUSSION

Pediatric patients presenting with febrile illness are common, similar to this patient who was initially treated

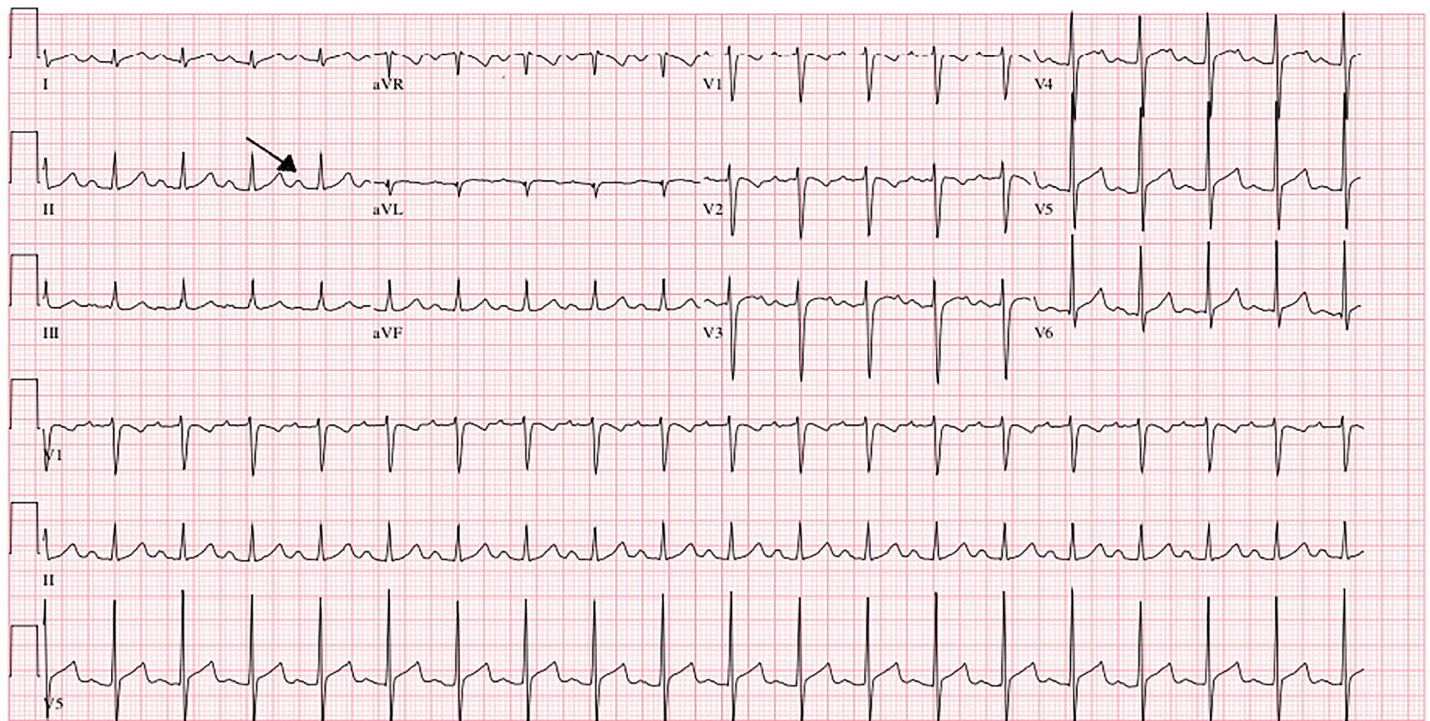


Image. Electrocardiogram of a six-year-old female with multisystem inflammatory syndrome in children reveals first-degree atrioventricular block identified by arrow in lead II.

symptomatically and given appropriate medical follow-up prior to decompensating days later. However, during the COVID-19 pandemic, it is imperative that emergency physicians effectively screen non-toxic appearing, febrile pediatric patients for indicators of MIS-C. Our patient was not tested for COVID-19 at the time of the initial encounter for several reasons. COVID-19 PCR testing was restricted to patients with hypoxia and clinical presentations consistent with the known disease at the time, which our patient lacked. Furthermore, testing of pediatric patients was not routine due to lack of known pediatric morbidity and mortality. We now recognize that febrile pediatric patients should undergo COVID-19 testing, but MIS-C can still present with a negative PCR screen and positive immunoglobulin G antibodies following an acute infection. A negative COVID-19 screen also does not exclude the diagnosis due to the imperfect sensitivity of the PCR testing.⁵

What is now being referred to as MIS-C was unknown at time of treatment. We considered developing KD as an etiology; however, the patient did not have five days of fever or four of the five required additional criteria for diagnosis. On the initial visit, our febrile patient had a positive streptococcal PCR test and complaints of abdominal pain and a sore throat, so she was treated for streptococcal pharyngitis. However, clinically the diagnosis of streptococcal pharyngitis was unconvincing, as she had an unremarkable pharyngeal examination. Similar cases of COVID-19-positive pediatric patients were being reported weeks later around the United States. In retrospect, our patient was fitting a similar pattern

presenting rarely in pediatric patients with COVID-19.³

KD, or mucocutaneous lymph node syndrome, is an inflammatory disease of the middle-sized blood vessels with a severe complication of coronary artery aneurysms. There is no single test that identifies KD; rather it is a clinical diagnosis that most commonly affects children younger than five years of age. Classic KD requires fever of five days with four of the five following criteria: bilateral conjunctivitis; a maculopapular rash; mucous membrane changes; cervical adenopathy; and edema or erythema of the hands and feet.⁶ Incomplete KD is defined as fever of five days with fewer than four diagnostic criteria. Many experts also believe that KD can be diagnosed in the presence of classic features with fewer than five days of fever by experienced clinicians. Both complete and incomplete KD are complicated by coronary aneurysms, so it is important for incomplete KD to remain on the differential. Another variation, KD shock syndrome (KDSS), refers to KD patients with greater than 20% decrease in systolic blood pressure.⁷ On repeat presentation, our patient met criteria for classic KD and KDSS and received treatment with IV immunoglobulin (IG) and high-dose aspirin therapy.

Toxic shock syndrome and KDSS can be difficult to distinguish, as both present with shock, fever, and a rash. Our patient was treated with broad-spectrum antibiotics including clindamycin for streptococcal exotoxin along with receiving IVIG and high-dose aspirin; this was continued until initiation of VA-ECMO, which requires heparinization. Echocardiography can help with differentiation, as tricuspid

regurgitation, mitral regurgitation, and coronary artery dilation are associated with KD.⁷ The average age of patients also varies by diagnosis. KD most commonly affects children younger than five years old. The typical age for pediatric toxic shock syndrome is younger than two years, and MIS-C affects patients younger than 21, with an average age of eight.⁵

Viral infections have been hypothesized to incite the cytokine storm and inflammatory changes that characterize KD. Inflammatory markers are also used as a prognostic factor in COVID-19. Elevated d-dimer (>3,000 ng/mL fibrinogen equivalent units), C-reactive protein (>3 mg/dL), B-type natriuretic peptide (>400 picograms/mL), and increased fibrinogen (>400 mg/dL) are associated with more severe presentations, and most MIS-C cases have elevations in at least four of these inflammatory biomarkers.^{5,8} Elevations in troponin, creatine phosphokinase, lactate dehydrogenase, low albumin, and hyponatremia have also been present in other patients with COVID-19 positive MIS-C. Obtaining laboratory studies of these markers and echocardiography may help identify and risk stratify pediatric patients with COVID-19 and early presentations of MIS-C.

Non-toxic appearing pediatric patients with a fever for more than 48 hours and a rash or gastrointestinal symptoms should be screened for MIS-C. Appropriate screening labs are complete blood count, C-reactive protein, comprehensive metabolic panel, d-dimer, ferritin, fibrinogen, prothrombin time, partial thromboplastin time, international normalized ratio B-type natriuretic peptide, and troponin. Laboratory tests to evaluate other etiologies should also be obtained and include urinalysis, urine cultures, blood cultures, and viral studies as warranted. Patients should be admitted for further evaluation and management if any of these laboratory findings are abnormal. Laboratory studies indicative of severe disease include hyponatremia, elevations in d-dimer and C-reactive protein levels, increased ferritin, and evidence of myocardial injury or multiple organ dysfunction syndrome. First-degree heart blocks, which this patient presented with, may also be seen in pediatric patients with myocarditis.⁹ Sinus tachycardia, arrhythmias, and non-specific changes are electrocardiography findings reported with MIS-C.

CONCLUSION

In the era of COVID-19, it appears that there are multiple locations where multisystem inflammatory syndrome in children is affecting pediatric patients who are COVID-19 positive.^{3,10} We recommend laboratory screening, cardiac monitoring, acetaminophen for fever, an ECG, and cardiac point-of-care ultrasound in the ED for patients in which this syndrome is suspected. Toxic-appearing pediatric patients with suspected MIS-C should also receive early vasopressors, IVIG, judicious fluids, and broad-spectrum antibiotics in addition to early intensive care unit and cardiology consultations and transfer to a facility with extracorporeal membrane oxygenation capability. Early identification,

prognostication, and treatment of COVID-19 positive patients with MIS-C requires further research.

Patient consent has been obtained and filed for the publication of this case report.

Address for Correspondence: MacKenzie Burger, MD, Wayne State University School of Medicine, Detroit Medical Center Sinai-Grace Hospital, Department of Emergency Medicine, 6071 Outer Drive W., Detroit, MI 48235. Email: MBurger2@dmc.org.

Conflicts of Interest: By the CPC-EM article submission agreement, all authors are required to disclose all affiliations, funding sources and financial or management relationships that could be perceived as potential sources of bias. The authors disclosed none.

Copyright: © 2020 Burger et al. This is an open access article distributed in accordance with the terms of the Creative Commons Attribution (CC BY 4.0) License. See: <http://creativecommons.org/licenses/by/4.0/>

REFERENCES

1. World Health Organization. Coronavirus disease (COVID-19) outbreak situation. 2020. Available at: <https://www.who.int/emergencies/diseases/novel-coronavirus-2019>. Accessed August 18, 2020.
2. Dong Y, Mo X, Hu Y, et al. Epidemiology of COVID-19 among children in China. *Pediatrics*. 2020;145(6):e20200702.
3. DeBiasi RL, Song X, Delaney M, et al. Severe COVID-19 in children and young adults in the Washington, DC metropolitan region *J Pediatr*. 2020;223:199-203.e1.
4. Centers for Disease Control and Prevention. Health Department-Reported Cases of Multisystem Inflammatory Syndrome in Children (MIS-C) in the United States. 2020. Available at: <https://www.cdc.gov/mis-c/cases/index.html>. Accessed August 18, 2020.
5. Feldstein LR, Rose EB, Horwitz SM, et al. Multisystem inflammatory syndrome in U.S. children and adolescents. *N Engl J Med*. 2020;383:334-46.
6. Burns JC and Glodé MP. Kawasaki syndrome. *Lancet*. 2004;364(9433):533-44.
7. Lin YJ, Cheng MC, Lo MH, et al. Early differentiation of Kawasaki disease shock syndrome in a pediatric intensive care unit. *Pediatr Infect Dis J*. 2015;34(11):1163-7.
8. Zhou F, Yu T, Du R, et al. Clinical course and risk factors for mortality of adult inpatients with COVID-19 in Wuhan, China: a retrospective cohort study. *Lancet*. 2020;395(10229):1054-62.
9. Baruteau AE, Pass RH, Thambo JB, et al. Congenital and childhood atrioventricular blocks: pathophysiology and contemporary management. *Eur J Pediatr*. 2016;175(9):1235-48.
10. Jones VG, Mills M, Suarez D, et al. COVID-19 and Kawasaki disease: novel virus and novel case. *Hosp Pediatr*. 2020;10(6):537-40.

Delirium Associated with Salicylate and Acetaminophen Overdose in a Patient with COVID-19: A Case Report

Tyler H. Wen, BA*
Jason Chu, MD†
Danielle M. Allenspach, PA†
David C. Van, MD, MS†

*Columbia University Vagelos College of Physicians and Surgeons, New York, New York
†Columbia University Irving Medical Center, Department of Emergency Medicine, New York, New York

Section Editor: Scott Goldstein, MD

Submission history: Submitted June 3, 2020; Revision received August 26, 2020; Accepted August 21, 2020

Electronically published September 8, 2020

Full text available through open access at http://escholarship.org/uc/uciem_cpchem

DOI: 10.5811/cpchem.2020.8.48559

Introduction: The coronavirus disease 2019 (COVID-19) pandemic has created numerous clinical challenges for physicians, in part due to its wide range of clinical manifestations and associated complications.

Case Report: Here we present the case of a 69-year-old man who was admitted to the emergency department with fever, dyspnea, and altered mental status. We believe the patient's condition was precipitated by a COVID-19 infection-induced delirium, a setting in which he ingested aspirin and acetaminophen in overdose that required lifesaving interventions.

Conclusion: This case illustrates the potential for neuropsychiatric effects in COVID-19 patients due to both direct viral central nervous system pathology and pandemic-related psychosocial stressors. [Clin Pract Cases Emerg Med. 2020;4(4):517–520.]

Keywords: COVID-19; delirium; neuropsychiatric effects; overdose.

INTRODUCTION

During the coronavirus disease 2019 (COVID-19) pandemic, our New York City hospital emergency department (ED) was inundated with patients who presented with respiratory symptoms typical of the COVID-19 infection (dyspnea, fever, and dry cough).¹ While many patients develop subsequent renal, cardiovascular, or other organ complications, psychiatric or mental status changes are less common.^{1,2} We report a case of a 69-year-old patient with COVID-19 symptoms with concurrent altered mental status (AMS). Although initial workup revealed active COVID-19 infection, the workup of AMS represented a diagnostic challenge.

CASE REPORT

A 69-year-old male with diabetes mellitus and hypertension was brought to the ED during the height of the COVID-19 outbreak with fever, dyspnea, and AMS. The patient's agitation and confusion stymied interview attempts,

but a health records review showed he had been evaluated in the ED three days earlier for fever and cough. He was thought to have a probable COVID-19 infection at that time, but his condition did not warrant admission and the ED was not offering COVID-19 testing for outpatients.

Initial vital signs were notable for tachycardia to 120 beats per minute, blood pressure of 140/90 millimeters of mercury (mm Hg), tachypnea to 22 breaths per minute, oxygen saturation of 96% on room air, and an oral temperature of 38.2° Celsius. Staff noted his breaths were remarkably deep with coarse basilar lung sounds. The patient was in moderate respiratory distress with diaphoresis, cold and mottled extremities and 5-millimeter pupils. No focal neurological deficits or signs of head trauma were noted, but the patient was acutely agitated and restless, shifting repeatedly in the stretcher from side to side.

The providers contacted his wife by telephone and learned that his medications included acetaminophen and insulin.

She related that after returning home from the ED three days earlier, he began self-treating his fever but appeared increasingly confused. His wife denied that the patient had any psychiatric or substance abuse history.

A differential diagnosis at the time included infectious etiologies (e.g., sepsis syndrome, encephalitis); drug toxicity or withdrawal; neurological events (e.g., stroke); and metabolic disorders (e.g., hyperglycemic hyperosmolar state, hypoglycemia). His initial workup revealed a bedside fingerstick glucose of 234 milligrams (mg) per deciliter (dL) (reference range [ref]: 70-99 mg/dL), benign electrocardiogram and head computed tomography findings, and bilateral opacities on chest radiograph consistent with viral pneumonia. Severe acute respiratory syndrome coronavirus 2 (SARS-CoV-2) reverse transcriptase-polymerase chain reaction test was positive. Laboratory tests were as follows: arterial blood gas- pH 7.50 (ref: 7.35-7.45); partial pressure of carbon dioxide 18 mm Hg (ref: 35-45 mm Hg); partial pressure of oxygen 98 mm Hg (ref: 80-100 mm Hg); bicarbonate 14 millimoles (mmol) per liter (L) (ref: 22-29 mmol/L); serum anion gap 27 (ref: 8-17); aspartate aminotransferase 69 units (U) per L (ref: 5-40 U/L); and alanine aminotransferase 51 U/L (ref: 7-56 U/L). The blood gas and metabolic panel revealed a mixed anion gap metabolic acidosis with respiratory alkalosis.

With this new information, clinical staff pivoted to focus on toxic and metabolic etiologies. A serum toxicology screen showed a salicylate level of 52.2 mg/dL (therapeutic range: 0-30mg/dL); acetaminophen level of 70.8 microgram (mcg) per mL (therapeutic range: 10-30 mcg/mL); and undetectable ethanol level. Poison control was consulted, and the patient was admitted to the intensive care unit for urinary alkalization with a sodium bicarbonate infusion for salicylate toxicity and intravenous N-acetylcysteine for acetaminophen toxicity. However, he became oliguric with persistently elevated salicylate levels and refractory confusion requiring hemodialysis. The patient's mental status improved over three days after hemodialysis.

Upon regaining mental clarity, the patient volunteered that he had deliberately taken large quantities of aspirin and acetaminophen in an attempt to take his own life. He expressed feeling helpless after believing that he had an untreatable COVID-19 infection. His worsening dyspnea further exacerbated the mental anguish, leading him to become increasingly certain that he was dying. The patient also became more confused in the days leading up to his admission, and stated he felt he had no choice but to take large amounts of pain medication.

Eventually he endorsed both lapses and confabulations in his memory during the peak of his symptoms, and thought that his confusion and impaired judgment precipitated the medication overdose. He denied any current suicidal ideation. Psychiatry consultants agreed that the overdose primarily occurred in the context of delirium and felt that his risk of

CPC-EM Capsule

What do we already know about this clinical entity?

While the respiratory, cardiovascular and renal effects of coronavirus disease 2019 (COVID-19) are well described, understanding of its brain effects is limited and evolving.

What makes this presentation of disease reportable?

There is a growing realization that COVID-19 can have neuropsychiatric effects, but reports in the medical literature are limited.

What is the major learning point?

COVID-19, along with advanced age, fever, societal stressors and pharmacologic effects, can all contribute to neuropsychiatric dysfunction in affected patients.

How might this improve emergency medicine practice?

Our case highlights an infrequently encountered condition for emergency practitioners to consider when managing altered mental status in patients with COVID-19.

future self-harm was low since he had no history of suicidality or underlying psychiatric disorder. The patient was ultimately released 10 days after admission with community support referrals but no new medications.

DISCUSSION

In retrospect, the patient's presentation of fever and AMS with a mixed anion gap metabolic acidosis and respiratory alkalosis was consistent with salicylate toxicity, a condition whose pathophysiology and treatment protocols are well established.^{3,4} Unique to this case was its situation within the COVID-19 pandemic, which was a distracting alternate etiology for the patient's fever. This was bolstered by his prior ED visit which, although testing was not indicated, was consistent with a COVID-19 infection. At that time, the patient was discharged with acetaminophen due to reassuring vital signs; his mental status only began to deteriorate after returning home.

While acute salicylate poisoning may have contributed to the patient's presentation of AMS, neurological findings are typically associated with higher levels of serum salicylate concentrations (80-90 mg/dL) than those observed in our

patient (52 mg/dL).⁵ Alternatively, chronic salicylate toxicity can manifest with a variety of neurologic findings (including confusion, delirium, agitation, and coma) associated with lower serum salicylate levels.⁵ In our case the ingestion pattern remains unclear: the patient was unsure whether he had taken a bottle of 100 “PM” pills and acetaminophen as a single ingestion or as multiple large doses over several days. Regardless, a history of confusion preceding the overdose suggests that a COVID-19 infection was independently responsible for his initial delirium.

Present data suggests that the SARS-CoV-2 virus responsible for COVID-19 may induce an over-exaggerated host immune response (“cytokine storm”) causing increased systemic vascular permeability and a state of viral sepsis with multiorgan dysfunction.^{1,2} This increase in endothelial permeability along the blood-brain barrier (BBB) can lead to cerebral edema and subsequent central nervous system (CNS) dysfunction.² Furthermore, there is evidence suggesting that SARS-CoV-2 can invade the CNS; viral ribonucleic acid has been detected in the CNS neuronal cells of COVID-19 patients, and autopsies have revealed cerebral hyperemia with neuronal degeneration.^{6,7} Proposed mechanisms of CNS viral entry include viral invasion of peripheral nerves with retrograde spread and trans-synaptic transmission, transcribrial spread via olfactory epithelial cells expressing angiotensin-converting enzyme 2 receptors, direct viral invasion of vascular endothelial cells along the BBB, and viral infection of leukocytes that migrate through the BBB (Trojan horse mechanism).^{6,8}

There has also been at least one reported case of COVID-19-associated acute necrotizing encephalopathy, a rare complication of viral infections that results from neurotoxic cytokine accumulation and cerebral edema-induced necrosis.^{2,9} AMS can be an indicator of overall COVID-19 illness severity. Mao et al found that 15% of inpatients with severe COVID-19 infections presented with impaired consciousness during the early days of the pandemic in Wuhan, China, compared to 7.5% of inpatients with non-severe courses.⁶

Apart from physiological factors that increase risk of delirium (including direct viral CNS pathology, pharmacological effects, hypoxemia, fever, and advanced age), we believe that the COVID-19 pandemic’s widespread social impacts also contributed to the patient’s psychiatric decompensation and suicidality.¹⁰ Our patient related pre-admission feelings of despair and hopelessness regarding his respiratory symptoms, perceiving that he had an untreatable and fatal COVID-19 infection. This milieu of despair was possibly compounded by physical isolation, media coverage of high mortality rates, a lack of definitive treatments, and a pervasive sense of uncertainty.^{11,12} Social isolation hindered access to community venues for discussing his fears, further exacerbating his mental anguish (Figure).

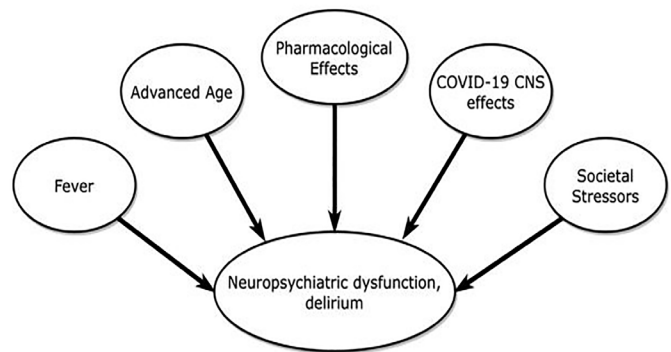


Figure. Numerous factors are likely to contribute to delirium in patients with coronavirus disease 2019 infection. COVID-19, coronavirus disease 2019; CNS, central nervous system.

Li et al showed an increase risk of suicide in patients with mental disorders and socioeconomic deprivation, which may be heightened in a pandemic.¹³ Suicides directly attributed to a fear of COVID-19 infection and isolation measures have already been reported.¹⁴ Lastly, the unique burden of managing hospitalized patients in the “COVID era” has also affected healthcare staff, in whom rates of psychological stress, burnout and depression appears to have risen.¹⁵ Clearly the increased workload in some centers is a factor, but many clinicians have managed COVID-19-infected colleagues, experienced uncertainty of personal protective equipment availability, and needed to provide unprecedented personal attention to patients whose family members were disallowed from visiting at the bedside. All these factors predicate the need for increased awareness of the current pandemic’s profound psychosocial impact on both patient and provider.

CONCLUSION

Our case suggests an increased risk of altered mental status in COVID-19 patients due to a combination of neurophysiological and psychosocial stressors. If unrecognized and untreated, patients with delirium can potentially exhibit dangerous behaviors such as self-harm or suicidal ideation; our patient was driven to an overdose of multiple medications as a sequela of his delirium and required lifesaving interventions. Informing families of COVID-19 patients to stay vigilant for signs of confusion or AMS may help avert similar episodes. Additional close monitoring and proactive management of cognitive changes should be considered for high-risk patients, such as those living alone or lacking social support.

The authors attest that their institution requires neither Institutional Review Board approval, nor patient consent for publication of this case report. Documentation on file.

Address for Correspondence: David C. Van, MD, MS, Columbia University Irving Medical Center, Department of Emergency Medicine, 622 West 168th Street, VC-260, New York, NY 10032. Email: dcv8@cumc.columbia.edu.

Conflicts of Interest: By the CPC-EM article submission agreement, all authors are required to disclose all affiliations, funding sources and financial or management relationships that could be perceived as potential sources of bias. The authors disclosed none.

Copyright: © 2020 Wen et al. This is an open access article distributed in accordance with the terms of the Creative Commons Attribution (CC BY 4.0) License. See: <http://creativecommons.org/licenses/by/4.0/>

REFERENCES

1. Cascella M, Rajnik M, Cuomo A, et al. Features, evaluation and treatment coronavirus (COVID-19). 2020. Available at: <https://www.ncbi.nlm.nih.gov/books/NBK554776>. Accessed August 24, 2020.
2. Wu X, Wu W, Pan W, et al. Acute necrotizing encephalopathy: an underrecognized clinicoradiologic disorder. *Mediators Inflamm*. 2015;2015:792578.
3. Bowers D, Mason M, Clinkscales M. Managing acute salicylate toxicity in the emergency department. *Adv Emerg Nurs J*. 2019;41(1):76-85.
4. Nelson L, Howland MA, Lewin NA, et al. (2019). Lugassy D. Salicylates. In: *Goldfrank's Toxicologic Emergencies, 11th ed.* (p. 555-566). New York, NY: McGraw-Hill Education.
5. Temple AR. Acute and chronic effects of aspirin toxicity and their treatment. *Arch Intern Med*. 1981;141(3 Spec No):364-9.
6. Mao L, Jin H, Wang M, et al. Neurologic manifestations of hospitalized patients with coronavirus disease 2019 in Wuhan, China. *JAMA Neurol*. 2020;77(6):1-9.
7. Puelles VG, Lütgehetmann M, Lindenmeyer MT, et al. Multiorgan and renal tropism of SARS-CoV-2. *N Eng J Med*. 2020;383(6):590-2.
8. Zubair AS, McAlpine LS, Gardin T, et al. Neuropathogenesis and neurologic manifestations of the coronaviruses in the age of coronavirus disease 2019: a review. *JAMA Neurol*. 2020. In press.
9. Poyiadji N, Shahin G, Noujaim D, et al. COVID-19-associated acute hemorrhagic necrotizing encephalopathy: CT and MRI features. *Radiology*. 2020;296(2):E119-20.
10. Ahmed S, Leurent B, Sampson EL. Risk factors for incident delirium among older people in acute hospital medical units: a systematic review and meta-analysis. *Age Ageing*. 2014;43(3):326-33.
11. Roser M, Ritchie H, Ortiz-Ospina E, et al. Mortality risk of COVID-19. 2020. Available at: <https://ourworldindata.org/mortality-risk-covid?country=USA>. Accessed August 24, 2020.
12. Rajkumar RP. COVID-19 and mental health: a review of the existing literature. *Asian J Psychiatr*. 2020;52:102066.
13. Li Z, Page A, Martin G, et al. Attributable risk of psychiatric and socio-economic factors for suicide from individual-level, population-based studies: A systematic review. *Soc Sci Med*. 2011;72(4):608-6.
14. Mamun MA and Gri MD. First COVID-19 suicide case in Bangladesh due to fear of COVID-19 and xenophobia: possible suicide prevention strategies. *Asian J Psychiatr*. 2020;51:102073.
15. Spoorthy M, Pratapa S, Mahant S. Mental health problems faced by healthcare workers due to the COVID-19 pandemic: a review. *Asian J Psychiatr*. 2020;51:102119.

Spontaneous Pneumothorax as a Complication of COVID-19 Pneumonia: A Case Report

Leland Perice, MD*

Zhanna Roit, MD*

Ingrid Llovera, MD*

Mary G. Flanagan-Kundle, MS, PA-C†

*North Shore University Hospital – Northwell Health, Department of Emergency Medicine, Manhasset, New York

†Touro College School of Health Sciences, Physician Assistant Program, Bay Shore, New York

Section Editor: Rick A. McPheeters, DO

Submission history: Submitted July 16, 2020; Revision received August 26, 2020; Accepted August 24, 2020

Electronically published September 8, 2020

Full text available through open access at http://escholarship.org/uc/uciem_cpem

DOI: 10.5811/cpem.2020.8.49139

Introduction: Coronavirus disease 2019 (COVID-19) is caused by the severe acute respiratory syndrome coronavirus 2. It typically presents with respiratory symptoms such as fevers, cough, and shortness of breath. As the number of cases increases, however, COVID-19 is being increasingly recognized as being associated with a variety of other respiratory pathologies.

Case Report: We present the case of a 59-year-old man with COVID-19 pneumonia who acutely decompensated after having been on the medicine floor for two weeks. He was found to have a tension pneumothorax. This was treated with a needle decompression followed by a chest tube insertion. The patient subsequently recovered and was discharged.

Conclusion: This case highlights the importance of considering tension pneumothorax as a possible cause of shortness of breath in patients with COVID-19 pneumonia. [Clin Pract Cases Emerg Med. 2020;4(4):521–523.]

Keywords: COVID-19; tension pneumothorax; necrotizing pneumonia; point-of-care ultrasound.

INTRODUCTION

On March 11, 2020, coronavirus disease 2019 (COVID-19) was declared a global pandemic by the World Health Organization after it was identified in Wuhan, China in December 2019. As of September 1, 2020 there have been 169,419 deaths nationally.¹ The symptoms of COVID-19 typically include shortness of breath, dry cough, fever, fatigue, muscle aches, and sore throat. There is an incubation period of 1-14 days before the onset of symptoms.² In more severe cases, patients are hypoxic and develop acute respiratory failure, requiring intensive care and mechanical ventilatory support. Many of these patients have radiographic findings of bilateral lung, ground-glass opacities.³

In the context of a pandemic, many healthcare institutions have created protocols to efficiently address the most common presentations of this disease. Yet despite often presenting with similar symptoms, it is important to keep a

wide differential when treating these patients as COVID-19 has been linked to a variety of pathologies. Reported complications secondary to COVID-19 include myocarditis, pulmonary embolism, large vessel cerebral vascular accidents, and acute respiratory distress syndrome.⁴ Here we present a patient who initially presented to the emergency department (ED) with shortness of breath and hypoxia, and while an inpatient rapidly decompensated secondary to a spontaneous tension pneumothorax.

CASE REPORT

A 59-year-old male with no past medical history presented to the ED with cough, fevers, and shortness of breath. He was found to be hypoxic requiring 15 liters of oxygen on a non-rebreather mask to maintain an oxygen saturation above 90% on pulse oximetry. Computed tomography (CT) angiogram of the chest performed in the

ED found pulmonary emboli within the segmental branches of the right upper and both lower lobe pulmonary arteries along with patchy areas of ground-glass opacities and consolidation. Polymerase chain reaction tests of nasal and pharyngeal swabs and sputum performed in the ED were positive for severe acute respiratory syndrome coronavirus 2 RNA. He was started on a therapeutic dose of enoxaparin and then admitted to the medicine floor for further treatment.

His respiratory status improved and he was eventually weaned to one liter of oxygen via nasal cannula by day 10 of hospitalization. On day 11 of hospitalization the patient had a sudden desaturation to 60% on pulse oximetry. The rapid response team was called, and a portable chest radiograph (CXR) was performed, which found a large pneumothorax (Image 1).

Emergent needle decompression of the tension pneumothorax with an 18-gauge needle and subsequent 10 French chest tube placement were immediately performed. The patient had rapid clinical improvement after needle decompression with improvement of his oxygen saturation to 100% while on 15 liters of oxygen through a non-rebreather mask and re-expansion of his lung on CXR (Image 2).

On day 18 of hospitalization the patient's hemoglobin dropped from 9.1 grams (g) per deciliter (dL) to 7.2 g/dL. Repeat CT was subsequently performed and showed bilateral loculated hemopneumothoraces. The patient was started on vancomycin and piperacillin/tazobactam due to concern for necrotizing pneumonia as the underlying cause of the new lung changes, and his anticoagulation was switched from therapeutic enoxaparin injections to a heparin infusion. He continued to clinically improve, and the chest tube was removed. He was eventually discharged from the hospital on apixaban, doxycycline hyclate, and amoxicillin/clavulanate potassium.

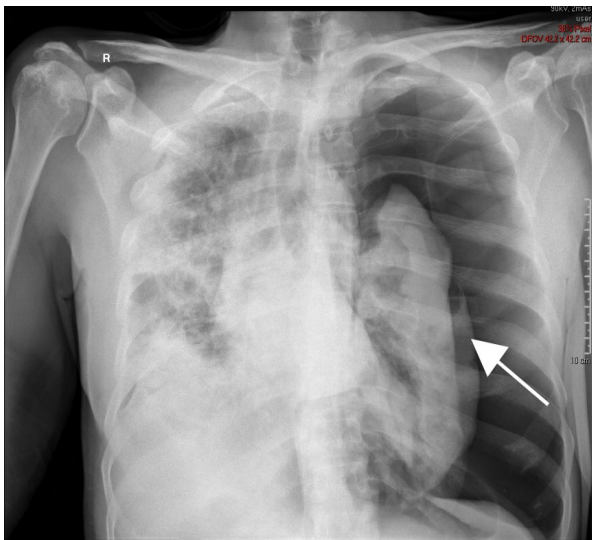


Image 1. Tension pneumothorax of the left lung on chest radiograph. Arrow indicates compressed left lung surrounded by free air.

CPC-EM Capsule

What do we already know about this clinical entity?

Coronavirus disease 2019 (COVID-19) is known to present with respiratory symptoms such as cough, fevers, and shortness of breath.

What makes this presentation of disease reportable?

Pneumothorax is not a known complication of COVID-19. Here we present a patient whose pneumothorax occurred as a direct complication of COVID-19.

What is the major learning point?

Pneumothorax should be in the differential diagnosis of patients with COVID-19 who present with shortness of breath.

How might this improve emergency medicine practice?

Patients with COVID-19 and shortness of breath should have early evaluation with a chest radiograph or point-of-care ultrasound.

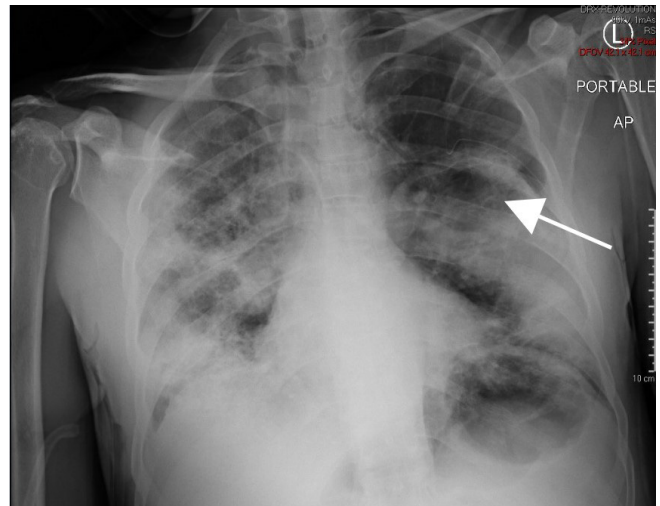


Image 2. Tension pneumothorax improved after chest tube placement. Arrow indicates area of re-expansion.

DISCUSSION

We present a case of a healthy 59-year-old male, admitted to the hospital for COVID-19 pneumonia, who acutely decompensated secondary to a tension pneumothorax after having improved for 11 days on the medical floor. He had

been improving from COVID-19 for three weeks prior to deteriorating. The patient subsequently improved with chest thoracostomy and antibiotics.

Although the pneumothorax cannot definitively be considered a complication of COVID-19, our patient otherwise had no risk factors for developing a spontaneous pneumothorax. Multiple case reports from other sources have also documented spontaneous pneumothoraxes in healthy patients with COVID-19.⁵⁻⁶ In these other case reports the pneumothoraxes occurred many weeks into the course of the illness as in the case of our patient. This is also consistent with the evolution of radiological lung findings described in a patient from Wuhan, China, who was critically ill with COVID-19 pneumonia.⁷ The initial ground-glass opacities progress to consolidations and then within weeks eventually develop into large bullae. It is possible that these bullae rupture with increases in intrathoracic pressure, such as from coughing, resulting in a pneumothorax. This is a possible mechanism by which a pneumothorax can be a direct complication of COVID-19 pneumonia in patients who otherwise have no specific risk factors for pneumothorax. It is also possible that these bullae result in bleeding, as seen in our patient, or become superinfected.

COVID-19 often presents with hypoxia and shortness of breath with the diagnosis of pneumonia. Early mechanical ventilation has been suggested for acute hypoxemic respiratory failure in the context of COVID-19.⁸⁻⁹ However, this case demonstrates the importance of considering other diagnoses, keeping a broad differential in mind, and not anchoring on the most common COVID-19-related clinical sequelae. It is important that the clinician perform a thorough clinical exam to assess whether there are complications such as a tension pneumothorax. It is easily reversible but if left undiagnosed can cause rapid deterioration and death. If our patient had empirically been placed on mechanical ventilation with a tension pneumothorax, the clinical outcome would likely have been worse.

Patients with COVID-19 should all have early radiological evaluation and repeat evaluation during any decompensation to evaluate for pneumothorax as the underlying cause of decompensation. This case highlights the importance of point-of-care ultrasound, which could have found the tension pneumothorax sooner and resulted in earlier placement of the chest tube. Making the diagnosis of a tension pneumothorax quickly is essential to early, lifesaving intervention.

CONCLUSION

The emergency physician should include pneumothorax in the differential diagnosis of suspected COVID patients who present with shortness of breath. Tension pneumothorax is an

easily reversible cause of shortness of breath but, if untreated, can be lethal.

The authors attest that their institution requires neither Institutional Review Board approval, nor patient consent for publication of this case report. Documentation on file.

Address for Correspondence: Zhanna Roit, MD, North Shore University Hospital – Northwell Health, Department of Emergency Medicine, 300 Community Drive, Manhasset, NY 11030. Email: zroit@northwell.edu.

Conflicts of Interest: By the *CPC-EM* article submission agreement, all authors are required to disclose all affiliations, funding sources and financial or management relationships that could be perceived as potential sources of bias. The authors disclosed none.

Copyright: © 2020 Perice et al. This is an open access article distributed in accordance with the terms of the Creative Commons Attribution ([CC BY 4.0](http://creativecommons.org/licenses/by/4.0/)) License. See: <http://creativecommons.org/licenses/by/4.0/>

REFERENCES

- Centers for Disease Control and Prevention. Provisional death counts for coronavirus disease 2019 (COVID-19). 2020. Available at: <https://www.cdc.gov/nchs/nvss/vsrr/covid19/index.htm>. Accessed July 17, 2020.
- Guan WJ, Ni ZY, Hu Y, et al. Clinical characteristics of coronavirus disease 2019 in China. *N Engl J Med*. 2020;382:1708-20.
- Shi H, Han X, Jiang N, et al. Radiological findings from 81 patients with COVID-19 pneumonia in Wuhan, China: a descriptive study. *Lancet Infect Dis*. 2020;20(4):425-34.
- Bobbio A, Dechartres A, Bouam S, et al. Epidemiology of spontaneous pneumothorax: gender-related differences. *Thorax*. 2015;70(7):653-8.
- Flower L, Carter JPL, Rosales Lopez J, et al. Tension pneumothorax in a patient with COVID-19. *BMJ Case Rep*. 2020;13(5):e235861.
- Spiro JE, Sisovic S, Ockert B, et al. Secondary tension pneumothorax in a COVID-19 pneumonia patient: a case report. *Infection*. 2020. In press.
- Sun R, Liu H, Wang X. Mediastinal emphysema, giant bulla, and pneumothorax developed during the course of COVID-19 Pneumonia. *Korean J Radiol*. 2020;21(5):541-4.
- Marini JJ and Gattinoni L. Management of COVID-19 respiratory distress. *JAMA*. 2020;323(22):2329-30.
- Poston JT, Patel BK, Davis AM. Management of critically ill adults with COVID-19. *JAMA*. 2020. In press.

Isolated COVID-19 Infection Precipitates Myasthenia Gravis Crisis: A Case Report

Phillip Moschella, MD, PhD*
Prerana Roth, MD†

*University of South Carolina School of Medicine Greenville, Prisma Health: Upstate Affiliate, Department of Emergency Medicine, Greenville, South Carolina

†University of South Carolina School of Medicine Greenville, Prisma Health: Upstate Affiliate, Department of Infectious Disease, Greenville, South Carolina

Section Editor: Joel Moll, MD

Submission history: Submitted July 13, 2020; Revision received September 17, 2020; Accepted September 18, 2020

Electronically published October 9, 2020

Full text available through open access at http://escholarship.org/uc/uciem_cpem

DOI: 10.5811/cpcem.2020.9.49049

Introduction: Coronavirus disease 2019 (COVID-19) has spread around the world and caused hundreds of thousands of fatalities across a wide spectrum of patients with varying severity and presenting complaints. The discussion of the ability of this disease to cause significant illness in patients with various risk factors such as myasthenia gravis is important to help guide physicians on recognition and treatment options as the pandemic matures.

Case Report: Here we discuss a single case of isolated COVID-19 infection that precipitated a myasthenic crisis with no other clinical sequelae in a patient who presented to the emergency department (ED). This report highlights some of the initial difficulties and delay in diagnosis encountered earlier in the pandemic with limited testing supplies and processing labs; however, prompt ED recognition and treatment still led to a favorable outcome.

Conclusion: The patient recovered during this initial presentation and was successfully treated with plasma exchange and steroids only. It is important to recognize that myasthenia gravis patients may represent a uniquely vulnerable population that requires enhanced surveillance and screening to prevent significant morbidity and mortality. This case describes how even a mild infection with no significant clinical sequelae or significant signs on imaging studied can precipitate a crisis event. [Clin Pract Cases Emerg Med. 2020;4(4):524–526.]

Keywords: COVID-19; plasma exchange; myasthenic crisis.

INTRODUCTION

The current disease outbreak featuring the novel coronavirus (severe acute respiratory syndrome coronavirus; SARS-CoV-2) has sparked a global pandemic, namely coronavirus disease 2019 (COVID-19). This novel coronavirus belongs to the *Coronaviridae* family and is comprised of single-stranded, positive-sense ribonucleic acid genomes that can cause both respiratory and/or enteric disease symptoms.¹ The current SARS-CoV-2 pandemic started in China in late 2019 and has sickened millions and killed thousands across the globe.^{2,3} COVID-19 primarily causes a respiratory disease with a wide spectrum of disease

severity that ranges from mild to almost no upper respiratory symptoms to severe acute respiratory distress syndrome, pneumonia, multiorgan failure, and death.² The world's experience with the SARS-CoV-2 pandemic is rapidly evolving as the virus continues to spread with increased mortality in high-risk groups of patients, including the elderly and those with comorbidities such as obesity and diabetes.

It is not yet known how COVID-19 affects myasthenia gravis patients. To date, there are two published reports of only six total patients that have been described in the current literature.^{4,5} These isolated reports provide only limited guidance for the emergency physician on the recognition of

COVID-19 in myasthenia gravis patients as they may present to the emergency department (ED), and none describe successful treatment using plasma exchange. This report highlights how isolated infection with COVID-19 with no signs on initial imaging studies can trigger a myasthenic crisis without any other clinical symptoms and how this patient was successfully treated with plasma exchange and steroid therapy alone.

CASE REPORT

A 70-year-old male with a history of myasthenia gravis, hypertension, hyperlipidemia, diabetes, and coronary artery disease presented to one of our EDs in March 2020 with shortness of breath and cough. While he did not routinely use supplemental oxygen at home, he had started using it recently as he felt he was having a myasthenic crisis. The patient denied chest pain or fevers but did report some subjective chills and a non-productive cough. Overall, he described that he felt as though his chest was “not moving well and it’s weak” and that he was “belly breathing.” The patient reported that he was strictly adhering to social distancing and the stay-at-home recommendations because of his health history and had no known sick contacts, no recent travel, no new medications, and was not on any antibiotic therapy.

The patient’s vital signs in triage were as follows: heart rate 68 beats per minute; blood pressure 99/51 millimeters of mercury (mm Hg), respiration rate 18 breaths per minute; temperature: 36.3° Celsius; and with an oxygen saturation 96% on two liters nasal cannula as he could not tolerate room air alone. His physical exam revealed a respiratory rate of 28 breaths per minute. He was only able to speak in two-word sentences and had labored breathing with diminished breath sounds throughout. After taking a deep breath, he was only able to get to the letter “D” when reciting the alphabet. Evaluation by respiratory therapy showed a negative inspiratory force of -10 mm Hg (reference (ref) range: >-60 mm Hg) and a vital capacity of 960 milliliters (mL) (ref range: >30mL/kilogram ideal body weight). There were no other significant findings on physical exam.

Initial venous blood gas on two liters nasal cannula showed partial pressure of oxygen of 37 mm Hg (30-40 mm Hg), and partial pressure of carbon dioxide of 53 mm Hg (ref range: 35-45 mm Hg) with a pH of 7.4 (ref range: 7.35-7.45). Other laboratory work-up included the following: complete blood count; comprehensive metabolic panel; B-type natriuretic peptide (BNP), lactic acid; two blood cultures; procalcitonin; serum cortisol level; thyroid stimulating hormone; and free thyroxine levels. The patient had a mild leukocytosis with a white blood cell count of 12.5×10^9 /liter (L) (ref range: 4.5 to 11.0×10^9 /L). His procalcitonin was negative at 0.02 nanograms (ng)/mL (<0.15 ng/mL), and brain-type natriuretic peptide only mildly elevated at 147 picograms (pg)/mL (ref range: <100 pg/mL). His initial troponin was 0.07 ng/mL (ref range: <0.1 ng/mL). Renal

CPC-EM Capsule

What do we already know about this clinical entity?

Myasthenia gravis carries the risk of significant morbidity and mortality. It is unknown whether coronavirus disease 2019 (COVID-19) infection can precipitate a crisis.

What makes this presentation of disease reportable?

This is one of only a few reports demonstrating an association between COVID-19 infection and myasthenic crises.

What is the major learning point?

COVID-19 can present atypically in these patients and likely precipitate a myasthenic crisis. This patient was successfully treated with steroids and plasma exchange.

How might this improve emergency medicine practice?

Providers should include surveillance for COVID-19 infection in patients with myasthenia gravis to prevent significant morbidity or mortality.

function was normal with a creatinine of 0.74 milligrams per deciliter (mg/dL) (ref range: 0.6-1.2 mg/dL).

His admission chest radiograph (CXR) showed no acute cardiopulmonary abnormality. His other laboratory values were unremarkable. A SARS-CoV-2 polymerase chain reaction (PCR) test was sent to the health department as per hospital protocol. At that time, our hospital policy was to add routine testing for all patients admitted for any respiratory complaints to help guide personal protective equipment use and transfer positive patients to designated COVID-19 hospitals within our system. The result of this testing was pending at this time of initial admission.

Due to impending respiratory compromise, and following discussion with the patient and his wife, it was decided to proceed with intubation in the ED. The initial diagnosis was acute myasthenia gravis crisis. The patient’s myasthenia gravis had been diagnosed in November 2019 when he presented with stroke-like symptoms of diplopia and dysphagia. He was found to have acetylcholine receptor antibody positive/Musk-receptor antibody negative myasthenia gravis. Since his initial diagnosis in 2019, he had been well controlled on prednisone 30 mg daily, methotrexate, and pyrostigmine 60 mg four times daily. He

had no hospitalizations between discharge in December 2019 and this case presentation in March 2020.

Due to persistent hypotension during this encounter, stress-dose steroids (100 mg of hydrocortisone sodium succinate) were started in the ED. Neurology recommended immediately starting plasma exchange, and the patient underwent five sessions in the ensuing five days. The SARS-CoV-2 PCR resulted as positive on day three, and infectious disease was consulted. The risks of medication interactions with hydroxychloroquine was thought to outweigh the benefits and thus was not initiated. The patient was not a candidate for remdesivir as part of an initial medication trial as he never developed any infiltrates on CXR throughout his hospital course. Current data is evolving but early reports show only a 68% sensitivity for CXR in diagnosing COVID-19 at time of admission.⁶ Thus, in total no specific COVID-19 treatments were pursued. Interestingly, with plasma exchange and stress-dose steroid therapy alone, the patient was able to be extubated on day five and had no other complications during his hospital course through discharge.

DISCUSSION

Knowledge regarding how SARS-CoV-2 affects different populations is accumulating as researchers describe their experiences during this pandemic. There are a few case reports of COVID-19 causing myasthenic crises; however, the outcomes and disease course seem to vary widely.^{4,5} It is unclear which patient or disease feature can result in worse outcomes, and thus more study is needed. Current treatment guidelines for myasthenic crises include both intravenous immunoglobulin (IVIG) and plasma exchange as first-line options.⁷ In this particular situation of COVID-19 triggering a crisis we believe that using plasma exchange expedited recovery through removing inflammatory cytokines related to COVID-19 infection that may have been one of the triggers for this patient's myasthenic crisis. Studies are ongoing to assess the efficacy of plasma exchange as a treatment for COVID-19. Currently available IVIG would not have protective antibodies against COVID-19; thus, therapeutic plasma exchange was preferable over IVIG in this particular situation.

CONCLUSION

This case highlights that COVID-19 can present atypically in patients with myasthenia gravis and can independently precipitate a crisis event. In addition, judicious but prompt intubation,

stress-dose steroids, and plasma exchange may be integral in the treatment of patients with myasthenia gravis and COVID-19.

The authors attest that their institution requires neither Institutional Review Board approval, nor patient consent for publication of this case report. Documentation on file.

Address for Correspondence: Phillip Moschella, MD PhD, University of South Carolina School of Medicine Greenville, Department of Emergency Medicine, 701 Grove Rd., Greenville, SC 29605. Email: phillip.moschella@prismahealth.org.QWAE

Conflicts of Interest: By the CPC-EM article submission agreement, all authors are required to disclose all affiliations, funding sources and financial or management relationships that could be perceived as potential sources of bias. The authors disclosed none.

Copyright: © 2020 Moschella et al. This is an open access article distributed in accordance with the terms of the Creative Commons Attribution (CC BY 4.0) License. See: <http://creativecommons.org/licenses/by/4.0/>

REFERENCES

1. Banerjee A, Kulcsar K, Misra V, et al. Bats and coronaviruses. *Viruses*. 2019;11(1):41.
2. Zhang L and Liu Y. Potential interventions for novel coronavirus in China: a systematic review. *J Med Virol*. 2020;92(5):479-90.
3. COVID-19 Dashboard by the Center for Systems Science and Engineering (CSSE) at Johns Hopkins University (JHU). Available at: <https://coronavirus.jhu.edu/map.html>. Accessed on July 6, 2020.
4. Singh S and Govindarajan R. Covid-19 and generalized myasthenia gravis exacerbation: a case report. *Clin Neurol Neurosurg*. 2020;196:106045.
5. Anand P, Slama MC, Kaku M, et al. COVID-19 in patients with myasthenia gravis. *Muscle Nerve*. 2020;62(2):254-8.
6. Cozzi D, Albanesi M, Cavigli E, et al. Chest X-ray in new coronavirus disease 2019 (COVID-19) infection: findings and correlation with clinical outcome. *Radiol Med*. 2020;125(8):730-7.
7. Sanders D, Wolfe G, Benatar M, et al. International consensus guidance for management of myasthenia gravis: Executive summary. *Neurology*. 2016;87(4):419-25.

The Evolution of Ultrasound in Medicine: A Case Report of Point-of-care Ultrasound in the Self-diagnosis of Acute Appendicitis

Barry Knapp, MD*
Kean Feyzeau, MD*
Austin Smith, MS†
Donald Byars, MD*
Craig Goodmurphy, PhD†
Matt Jones, MD*

*Eastern Virginia Medical School, Department of Emergency Medicine, Norfolk, Virginia
†Eastern Virginia Medical School, Department of Anatomy and Pathology, Norfolk, Virginia

Section Editor: Shadi Lahham, MD, MS

Submission history: Submitted May 13, 2020; Revision received July 10, 2020; Accepted July 9, 2020

Electronically published September 3, 2020

Full text available through open access at http://escholarship.org/uc/uciem_cpccem

DOI: 10.5811/cpcem.2020.7.48158

Introduction: Point-of-care ultrasound (POCUS) education during medical school develops physicians who are properly prepared for the next generation of medicine. The authors present the case of a first-year medical student who self-diagnosed appendicitis using POCUS.

Case Report: A 25-year-old, first-year medical student presented to the emergency department with lower abdominal pain. What seemed like a straightforward appendicitis presentation came with a twist; the student brought self-performed ultrasound imaging of his appendix.

Conclusion: The student's ultrasound skill set reflects favorably on the rapid evolution of ultrasound teaching in medical education. [Clin Pract Cases Emerg Med. 2020;4(4):527–529.]

Keywords: *ultrasound; point-of-care; appendicitis; education; medical school.*

INTRODUCTION

Point-of-care ultrasound (POCUS), the acquisition and interpretation of ultrasound images at the bedside, is an essential skill for the next generation of physicians. The integration of POCUS into undergraduate medical education (UGME) curricula is occurring at an accelerated rate. This no doubt reflects on the recognition that POCUS promotes patient safety, clinical efficiency, and elevates the level of care physicians can offer their patients. One benefit of early medical school integration is that students develop ultrasound skills in parallel with learning human anatomy – a critical element that accelerates sonographic learning. It cannot be overstated that the development of an early sonographic skill set is meant to augment the patient interview and clinical exam, not replace them. Each is an essential competency developed and ingrained early in medical school although

through different educational pathways. Today's medical students benefit from the ability to develop their sonographic skill set in parallel with learning the traditional pillars of medicine: inspection, palpation, percussion, and auscultation.

POCUS has become commonplace in many medical specialties and is evolving in others. The ability to evaluate and diagnose patients with emergent conditions using ultrasound is best illustrated in emergency medicine (EM). Diagnosing acute conditions such as appendicitis are well within the capabilities of ultrasound-trained clinicians. EM-trained physicians using POCUS to evaluate for appendicitis have been shown to have comparable operating characteristics (sensitivity, specificity, positive and negative predictive value) to comprehensive ultrasounds interpreted by radiologists.¹ Although abdominal ultrasound for appendicitis is traditionally considered technically difficult, we present a case of a novice UGME

sonographer self-diagnosing appendicitis. This is the first case report in the literature that readily demonstrates the rapid transition of medical school sonographic training in the classroom to a clinically relevant diagnostic tool.

CASE REPORT

A 25-year-old first-year medical student arrived in the emergency department (ED) with 24 hours of lower abdominal pain. The pain was worse with cough, yard work, and eventually with walking. The clinical exam demonstrated right lower quadrant tenderness without peritoneal signs. His vital signs were normal except for mild tachycardia. Lab work, including urinalysis, was unremarkable.

Although the clinical presentation in this case was typical of appendicitis, in many institutions the next step is to obtain a computed tomography (CT) to confirm the diagnosis. The use of CT to diagnose appendicitis approaches 90% in some centers.² Although CT in adults is more accurate than ultrasound in making the diagnosis of appendicitis (sensitivity 0.96 vs 0.85), ultrasound is an attractive alternative that can eliminate radiation exposure.³

In this case, what seemed like an otherwise straightforward appendicitis presentation came with a twist; the student brought self-performed ultrasound imaging of his appendix. Prior to his ED visit, the student went to our ultrasound teaching lab and was able to identify his inflamed appendix (without a proctor). He printed his ultrasound images and presented them to the ED attending physician. The images demonstrated an enlarged appendix (approximately 1 centimeter) with appendicolith (Image).

The emergency physician also used POCUS to reaffirm the sonographic diagnosis of appendicitis (noncompressible,

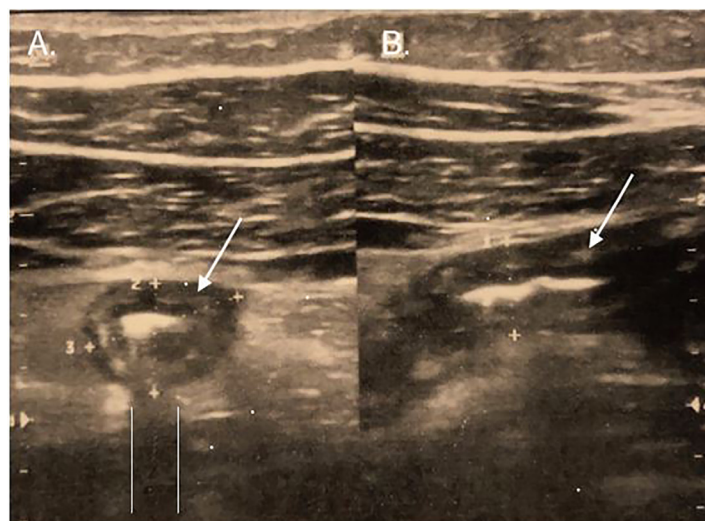


Image. First-year medical student self-images of enlarged appendix with appendicolith in short (A) and long axis (B) are indicated by the arrows. Appendix measurements are greater than 0.9 centimeters in all dimensions. Note the bright white appendicolith causing a posterior acoustic shadow (parallel white lines) in the short axis view.

CPC-EM Capsule

What do we already know about this clinical entity?

Diagnosing appendicitis using ultrasound is accurate and efficient. It is an advanced skill that can challenge even experienced sonographers.

What makes this presentation of disease reportable?

This is the first report in the literature of a medical student extrapolating a basic ultrasound skill set to self-diagnose appendicitis.

What is the major learning point?

The self-diagnosis of appendicitis by a 1st-year medical student demonstrates the rapid ultrasound skill development by future physicians.

How might this improve emergency medicine practice?

Point-of-care ultrasound taught by emergency physicians elevates the clinical skill set of future physicians.

focal ileus, tubular structure measuring greater than 6 millimeters in anterior-posterior diameter).⁴ Visualization of periappendiceal inflammation as well as an appendicolith, helped to confirm the diagnosis.

The patient was taken to the operating room without further imaging and had an uneventful appendectomy. Appendicitis was confirmed upon pathologic review of the specimen.

DISCUSSION

It is clear that basic patient evaluation skills taught early in medical school become the framework students rely on during their clinical years and beyond. It is our goal to integrate the use of sonography as a standard part of a student's history and physical exam. An integrated UGME ultrasound program helps students develop symbiotic clinical and sonographic skill sets. Students at our medical school Eastern Virginia Medical School (EVMS) have an ultrasound transducer in their hands as early as the orientation week of their first year.

The framework of sonographic teaching at our institution is structured around 10 core ultrasound skills that every student should graduate with. These core skills range from echocardiography to procedural guidance (Table).

Abdominal ultrasound education at our institution is focused primarily on common hepatobiliary and renal

Table. Ten core ultrasound competencies required for medical school graduation.

1. Cardiac ejection fraction estimation.
2. Cardiac evaluation for pericardial tamponade.
3. Cardiac evaluation for right ventricular strain.
4. Lung assessment for pneumothorax.
5. Identification of abdominal aortic aneurysm and aortic dissection.
6. Assessment for hemoperitoneum.
7. Identification of cholelithiasis (gallstones).
8. Identification of intrauterine pregnancy, gestational age and fetal lie.
9. Assessment for common cancers (renal and liver).
10. Establishment of ultrasound-guided vascular access.

disorders. Although we do not formally train students to specifically image the appendix, the ultrasound skill set they develop during the first few months of training makes this an achievable endeavor.

POCUS is becoming the standard of care in many areas of clinical medicine. The early integration of POCUS into UGME curricula is the key to arming the next generation of physicians with the tools necessary to elevate the current standard of patient care.⁵

Although anecdotal, this report of the self-diagnosis of acute appendicitis by a medical student is evidence of a novice learner's ability to rapidly extrapolate basic sonographic concepts into more advanced skills.

CONCLUSION

The medical student's ultrasound skills reflect favorably on the rapid evolution of ultrasound teaching in undergraduate medical education. As the use of ultrasound in the clinical setting expands for both diagnostic and procedural indications, it is important for medical schools to properly prepare future physicians.

The authors attest that their institution requires neither Institutional Review Board approval, nor patient consent for publication of this case report. Documentation on file.

Address for Correspondence: Barry J. Knapp, MD, Eastern Virginia Medical School, Department of Emergency Medicine, 600 Gresham Drive, Raleigh Building, Suite 304, Norfolk, VA 23507. Email: knappbj@evms.edu.

Conflicts of Interest: By the *CPC-EM* article submission agreement, all authors are required to disclose all affiliations, funding sources and financial or management relationships that could be perceived as potential sources of bias. The authors disclosed none.

Copyright: © 2020 Knapp et al. This is an open access article distributed in accordance with the terms of the Creative Commons Attribution ([CC BY 4.0](http://creativecommons.org/licenses/by/4.0/)) License. See: <http://creativecommons.org/licenses/by/4.0/>

REFERENCES

1. Benabbas R, Hanna M, Shah J, et al. Diagnostic accuracy of history, physical examination, laboratory tests, and point-of-care ultrasound for pediatric acute appendicitis in the emergency department: a systematic review and meta-analysis. *Acad Emerg Med.* 2017;24(5):523-51.
2. Drake FT, Alfonso R, Bhargava P, et al. Enteral contrast in the computed tomography diagnosis of appendicitis: comparative effectiveness in a prospective surgical cohort. *Ann Surg.* 2014;260(2):311-6.
3. Dahabreh IJ, Adam GP, Halladay CW, et al. Diagnosis of right lower quadrant pain and suspected acute appendicitis. 2015. Available at www.effectivehealthcare.ahrq.gov/reports/final.cfm. Accessed May 1, 2020.
4. Fischer JW, Sivitz AB, Abo AM. (2014). Pediatric Applications. In Ma O, Mateer JR, Reardon RF, Joing SA. (Eds.). *Ma and Mateer's Emergency Ultrasound*, 3rd ed. New York, NY: McGraw-Hill.
5. Tarique U, Tang B, Singh M, et al. Ultrasound curricula in undergraduate medical education: a scoping review. *J Ultrasound Med.* 2018;37(1):69-82.

Immunocompromised Child on Infliximab: A Case Report of *Listeria monocytogenes* Meningitis

Camille Halfman, MD
Luke Slate, BA
Julienne Yamamoto, MD
Samantha Jones, MD

SUNY Upstate Medical University, Department of Emergency Medicine, Syracuse, New York

Section Editor: Rick A. McPheeters, DO

Submission history: Submitted May 5, 2020; Revision received June 26, 2020; Accepted July 9, 2020

Electronically published September 9, 2020

Full text available through open access at http://escholarship.org/uc/uciem_cpem

DOI: 10.5811/cpem.2020.7.48053

Introduction: Patients with naturally occurring, impaired cell-mediated immunity secondary to age and pregnancy are known to be at risk of developing severe and invasive *Listeria monocytogenes* infections. Immunosuppressant medications, particularly infliximab, are also known to increase this risk.

Case Report: We present the case of a seven-year-old female on infliximab who was diagnosed with culture positive *L. monocytogenes* meningitis after a negative cerebral spinal fluid polymerase chain reaction (PCR).

Conclusion: Patients receiving infliximab who display signs of central nervous system infection should be suspected to have *L. monocytogenes* as an infecting agent, and empiric addition of ampicillin to their antibiotic regimen should be considered, with substitution of trimethoprim-sulfamethoxazole in cases of penicillin allergy, regardless of initial PCR results. [Clin Pract Cases Emerg Med. 2020;4(4):530–532.]

Keywords: *listeria monocytogenes*; *infliximab*.

INTRODUCTION

Listeria monocytogenes is a facultative anaerobic, gram-positive bacillus found in the intestinal flora of many animals and humans, and is spread through contaminated foods such as unpasteurized milk, soft cheeses, undercooked meats, and raw vegetables. It is almost universally susceptible to ampicillin but, if left untreated, it can cause serious infection with a propensity for sepsis, pneumonia, and meningoenzephalitis. It has also been documented to cause acute hydrocephalus secondary to invasion of the brainstem and is often fatal.¹³

Patients with naturally occurring, impaired cell-mediated immunity secondary to extremes of age and pregnancy are known to be at risk of developing severe and invasive *L. monocytogenes* infections. These populations are routinely advised to avoid potential sources of *L. monocytogenes* and are empirically treated with ampicillin when severe bacterial

infection is suspected. Due to the significant mortality of listeriosis infection and the fact that it is not well covered by standard empiric antibiotic treatment, a high index of suspicion for this organism should be maintained.³

A number of listeriosis cases in adults who are immunocompromised secondary to infliximab use have been reported.^{1,11} Infliximab is a tumor necrosis factor- α (TNF- α) inhibitor commonly used in treatment of rheumatoid arthritis and Crohn's disease. TNF- α is a protein produced by monocytes, macrophages, B-cells, T-cells, and fibroblasts to stimulate proliferation of cytokines and inflammatory cascades. Immunosuppression secondary to TNF- α inhibitor therapy is a known risk factor for *Listeria* infection,^{4,5} although the American Academy of Pediatrics has not yet recommended empiric coverage in patients receiving TNF- α inhibitor therapy. Here, we present a seven-year-old female on infliximab therapy who developed listeria meningitis despite a

negative polymerase chain reaction (PCR) assay of cerebral spinal fluid (CSF).

CASE REPORT

A seven-year-old female presented to the emergency department (ED) for fever and headache for one day. She was reportedly very tired after returning from school and took a nap. Upon waking, she complained of a headache and had a documented fever of 40° Celsius. Shortly after taking ibuprofen, she had an episode of emesis and subsequently sought medical attention. In the ED, she reported headache, decreased appetite, photophobia, and nausea. She had received induction of infliximab 20 days prior to presentation after a diagnosis of Crohn's disease, and had her second infusion two days prior. She was also taking prednisone daily. She was tachycardic, febrile, uncomfortable-appearing and photophobic. She had no focal neurologic deficits. She did display nuchal rigidity, but Kernig's and Brudzinski's signs were negative.

Blood work was obtained and the patient was given 20 milliliters per kilogram normal saline bolus with minimal improvement in tachycardia. The patient's white blood cell count was 13.7×10^3 /microliter (μL) (reference range 4.5 -13 $\times 10^3$ / μL), absolute neutrophil count 8.79×10^3 / μL (reference range 1.5 - 8.0 $\times 10^3$ / μL), and urinalysis was within normal limits. Blood and urine cultures were obtained, and a respiratory viral panel returned positive for coronavirus.

Empiric treatment of suspected meningitis was initiated with vancomycin and ceftriaxone. Lumbar puncture was performed under ketamine sedation and the patient was admitted to the pediatric hospitalist service. CSF analysis showed 2025 total nucleated cells (90% neutrophils, reference range < 7) and 6 red blood cells (RBCs)/ μL (reference range < 2) in Tube 1; 1640 total nucleated cells (92% neutrophils) and 6 RBCs/ μL in Tube 3. CSF glucose was 56 milligrams per deciliter (mg/dL) (reference range 60 – 80 mg/dL), protein was 99 mg/dL (reference range 15 – 45 mg/dL). Gram stain showed +4 white blood cells but no organisms noted. Shortly after admission, CSF PCR returned negative for *L. monocytogenes*, *E. coli* K1, *H. influenzae*, *N. meningitidis*, *S. agalactiae*, *S. pneumoniae*, *C. neoformans/gatti*, cytomegalovirus, enterovirus, herpes simplex virus 1 and 2, human herpesvirus 6, human parechovirus, and varicella zoster virus.

Upon admission, the patient's immunosuppressive medications were discontinued. Antibiotic coverage was not broadened from vancomycin and ceftriaxone owing to the negative CSF PCR. She continued to be intermittently febrile and displayed worsening mental status. On the second day of hospitalization, the patient's CSF and blood cultures were positive for *L. monocytogenes*, and her antibiotic regimen was changed to ampicillin and gentamicin. Her fevers resolved, her mental status and symptoms improved, and she was discharged from the hospital on day eight after a peripherally inserted central catheter was placed to receive a total of 21 days of ampicillin. The patient did not have recurrence of her

CPC-EM Capsule

What do we already know about this clinical entity?

Listeria monocytogenes infections have been documented in patients taking infliximab, and require a tailored antibiotic regime for successful treatment.

What makes this presentation of disease reportable?

A pediatric patient on infliximab therapy developed Listeria meningitis despite a negative polymerase chain reaction assay of cerebral spinal fluid.

What is the major learning point?

Infliximab increases chances of opportunistic infections, and ampicillin should be added to initial empiric antibiotic coverage.

How might this improve emergency medicine practice?

Reduce delay to definitive antibiotic treatment in an immunocompromised patient.

Crohn's symptoms while hospitalized, and she was switched to methotrexate for outpatient therapy.

DISCUSSION

There are few case reports in the literature of *L. monocytogenes* infection in an immunocompetent host; however, it is an agent to be suspected in the immunocompromised population. Many of the reported cases occur in adult patients receiving infliximab for the treatment of rheumatoid arthritis.¹¹ Listeriosis is rarely documented in immunocompetent children,^{2,9,14} with iron overload being suggested as a potential risk factor.⁹

Three-month mortality in patients with bacteremia has been found to be 45%.³ Mortality increased when there was a delay in administration of appropriate beta-lactam inhibiting agents, such as ampicillin. Relapses have occurred in immunocompromised patients after 14 days of treatment,⁷ leading to recommendations of three to six weeks for the immunocompromised with bacteremia and four to eight weeks for those with central nervous system infections.

Gentamicin has been reported to have synergistic effects with ampicillin in the treatment of listeriosis. Trimethoprim-sulfamethoxazole has been used to treat listeriosis successfully¹² in the case of penicillin allergy.

The PCR assay for the *hyl* gene, encoding listeriolysin O, has been reported to be specific and more sensitive than culture after antibiotic therapy has been initiated, with up to 10% of culture negative CSF having a positive PCR result in cases otherwise attributed to listeriosis based on clinical presentation and imaging results.⁶ The patient presented here is unique in that the CSF obtained at time of presentation resulted in a negative PCR assay but positive culture, demonstrating a rare false-negative PCR result.

It has been proposed that TNF- α plays an important role in the defense against infections.¹⁵ Infliximab, an anti-TNF- α agent, has found success in the treatment of inflammatory conditions such as rheumatoid arthritis and more recently Crohn's disease. Clinicians should be aware of the increased risk of listeriosis and empirically cover as indicated for this not infrequently fatal infection regardless of initial PCR results.

CONCLUSION

Patients receiving infliximab who display signs of central nervous system infection should be suspected to have *L. monocytogenes* as an infecting agent and empiric addition of ampicillin to their antibiotic regimen should be considered, with substitution of trimethoprim-sulfamethoxazole in cases of penicillin allergy, regardless of initial PCR results.

The authors attest that their institution requires neither Institutional Review Board approval, nor patient consent for publication of this case report. Documentation on file.

Address for Correspondence: Camille Halfman, MD, SUNY Upstate Medical University, Department of Emergency Medicine, 550 E. Genesee St, Syracuse, NY 13210. Email: halfmanc@upstate.edu.

Conflicts of Interest: By the CPC-EM article submission agreement, all authors are required to disclose all affiliations, funding sources and financial or management relationships that could be perceived as potential sources of bias. The authors disclosed none.

Copyright: © 2020 Halfman et al. This is an open access article distributed in accordance with the terms of the Creative Commons Attribution (CC BY 4.0) License. See: <http://creativecommons.org/licenses/by/4.0/>

REFERENCES

1. Bowie VL, Snella KA, Gopalachar AS, et al. Listeria meningitis associated with infliximab. *Ann Pharmacother.* 2004;38(1):58-61.
2. Castellazzi ML, Marchisio P, Bosis S. *Listeria monocytogenes* meningitis in immunocompetent and healthy children: a case report and a review of the literature. *Ital J Pediatr.* 2018;44(1):152.
3. Charlier C, Perrodeau É, Leclercq A, et al. Clinical features and prognostic factors of listeriosis: the MONALISA national prospective cohort study. *Lancet Infect Dis.* 2017;17(5):510-9.
4. Davies HD and Committee on Infectious Diseases. Infectious complications with the use of biologic response modifiers in infants and children. *Pediatrics.* 2016;138(2):e20161209.
5. Downey C. Serious infection during etanercept, infliximab and adalimumab therapy for rheumatoid arthritis: a literature review. *Int J Rheum Dis.* 2016;19(6):536-50.
6. Le Monnier A, Abachin E, Beretti JL, et al. Diagnosis of *Listeria monocytogenes* meningoencephalitis by real-time PCR for the *hyl* gene. *J Clin Microbiol.* 2011;49(11):3917-23.
7. Mandell G, Bennett JE, Dolin R. (2010). Principles and Practice of Infectious Diseases. 7th ed. Philadelphia, PA: Churchill Livingstone.
8. Moellering RC Jr, Medoff G, Leech I, et al. Antibiotic synergism against *Listeria monocytogenes*. *Antimicrob Agents Chemother.* 1972;1(1):30-4.
9. Peer MA, Nasir RA, Kakru DK, et al. *Listeria monocytogenes* meningoencephalitis in an immunocompetent, previously healthy 20-month old female child. *Indian J Med Microbiol.* 2010;28(2):169-71.
10. Shimbo A, Takasawa K, Nishioka M, et al. Complications of *Listeria meningitis* in two immunocompetent children. *Pediatr Int.* 2018;60(5):491-2.
11. Slifman NR, Gershon SK, Lee JH, et al. *Listeria monocytogenes* infection as a complication of treatment with tumor necrosis factor α -neutralizing agents. *Arthritis Rheum.* 2003;48(2):319-24.
12. Spitzer PG, Hammer SM, Karchmer AW. Treatment of *Listeria monocytogenes* infection with trimethoprim-sulfamethoxazole: case report and review of the literature. *Rev Infect Dis.* 1986;8(3):427-30.
13. Ulloa-Gutierrez R, Avila-Aguero ML, Huertas E. Fulminant *Listeria monocytogenes* meningitis complicated with acute hydrocephalus in healthy children beyond the newborn period. *Pediatr Emerg Care.* 2004;20(4):233-7.
14. Villa G, Diana MC, Solari N, et al. *Listeria meningitis* in an immunocompetent child. *Pediatr Emerg Care.* 2017;33(8):579-81.
15. White DW, Badovinac VP, Fan X, et al. Adaptive immunity against *Listeria monocytogenes* in the absence of type I tumor necrosis factor receptor p55. *Infect Immun.* 2000;68(8):4470-6.

Cerebral Malaria in a Patient with Recent Travel to the Congo Presenting with Delirium: A Case Report

Megan T. Roberson, MD
Austin T. Smith, MD

Vanderbilt University Medical Center, Department of Emergency Medicine,
Nashville, Tennessee

Section Editor: Scott Goldstein, MD

Submission history: Submitted May 1, 2020; Revision received August 7, 2020; Accepted August 14, 2020

Electronically published October 19, 2020

Full text available through open access at http://escholarship.org/uc/uciem_cpccem

DOI: 10.5811/cpcem.2020.8.47995

Introduction: Cerebral malaria, a syndrome of altered consciousness, is a rare and severe neurologic complication resulting from *Plasmodium falciparum*.¹ Historically, cerebral malaria has been seen more frequently in children rather than adults. To complicate the diagnosis, cerebral malaria has few specific symptoms and neurologic findings can vary with each case.

Case Report: We describe a case of a 61-year-old male who returned from the Democratic Republic of Congo and presented to the emergency department with dehydration, fatigue, and intermittent confusion. He was ultimately diagnosed with cerebral malaria caused by *P. falciparum*.

Conclusion: Even with close monitoring and appropriate treatment, cerebral malaria carries a severe risk of long-term neurocognitive deficits and a high mortality rate. [Clin Pract Cases Emerg Med. 2020;4(4):533–536.]

Keywords: *Malaria; cerebral malaria; fever in returned traveler; Plasmodium falciparum; delirium; altered mental status; travel history; infectious disease; tropical medicine.*

INTRODUCTION

Cerebral malaria is an uncommon disease process but should be considered in any patient presenting with neurologic complaints and recent travel to a malaria-endemic area. Most cases of malaria in developed countries are seen in travelers returning from malaria-endemic countries. The World Health Organization (WHO) estimated 228 million cases of malaria worldwide in 2018.² Of those cases 93% occurred in Africa with the Democratic Republic of Congo (DRC) accounting for 12% of all malaria cases worldwide, second only to Nigeria.² It is estimated there are 57 cases of malaria per 1000 population at risk worldwide.² Cerebral malaria is uncommon, especially in the United States (US). Further, the majority of the literature on cerebral malaria is focused on the pediatric populations as it is much more common in children.³

We present a case of a 61-year-old male who presented to our emergency department (ED) with diarrhea, fatigue, and delirium after return from the DRC two days prior. He was diagnosed with cerebral malaria and transferred to the

intensive care unit (ICU) where he was successfully treated and ultimately left the hospital with no neurologic deficits.

CASE REPORT

A 61-year-old male with a past medical history of hypertension presented to our ED with a chief complaint of fatigue. The patient had been visiting friends and relatives in the DRC and had returned to the US two days prior to presentation. History was obtained primarily from the patient's son as his father was delirious, which limited his ability to provide a comprehensive history. The son stated that the patient's symptoms began one week prior to presentation while still in the DRC. The patient returned to the US in a feeble state per the son. He had very little oral intake over the prior week and would wake up confused and disoriented during the three days prior, including not recognizing his own house or shower on the day of presentation. The patient's confusion would wax and wane but seemed worse upon waking in the morning and after napping, and would improve throughout the day. He reported night sweats and

chills but no known fevers. He had multiple episodes of dark diarrhea, but no bright red blood or black stools. He had a mild cough but no dyspnea or chest pain. He also reported nausea without vomiting.

A review of systems was otherwise negative including absence of headache, vision changes, numbness, focal weakness, or skin eruptions. The patient did endorse multiple mosquito bites but had been on malaria prophylaxis with doxycycline, which he had continued to take upon his return to the US. The patient's compliance with medication along with other precautions and malaria preventative measures such as mosquito nets and permethrin spray was not determined in the ED due to the patient's critical illness and need for resuscitation. He visited the international travel clinic prior to his trip and had been vaccinated for both yellow fever and typhoid. He was unaware of any sick contacts.

On arrival, his vital signs were significant for hypotension with a blood pressure of 103/62 millimeters mercury, tachycardia with a pulse of 123 beats per minute, an oral temperature of 100.3 degrees Fahrenheit with oxygen saturation 98% on room air. Differential diagnosis included meningitis, Ebola virus disease (EVD), chikungunya, enteric fever, filariasis, tick-borne rickettsiae, schistosomiasis, dengue, yellow fever, and malaria. An immediate consult to infectious disease (ID) was placed due to the concern for recent travel to an EVD-endemic area. The ID service determined that the patient was not in a place that had known active EVD at the time; therefore, EVD protocol was not initiated. An electrocardiogram (ECG) was obtained, which showed sinus tachycardia with a QTc interval of 369 milliseconds (msec).

His physical exam was notable only for lethargy. He was slow to answer questions but would answer appropriately. He had no focal neurologic deficits and was alert and oriented to self, place and year, but not to month. He had no neck pain, neck stiffness, jaundice, scleral icterus, or skin eruption.

Laboratory evaluation was significant for a normal white blood cell count with thrombocytopenia (platelets 111 per microliter [K/mcL] [reference range 135-371 K/mcL]) and anemia (hemoglobin nine grams per deciliter [g/dL] [reference range 14.0-18.1 g/dL], and hematocrit 25% (reference range 41-49%). His serum sodium was slightly low at 131 millimoles per liter (mmol/L) (reference range 136-145 mmol/L) with otherwise normal electrolytes and a normal serum creatinine. Glucose was 177 milligrams/dL (mg/dL) (reference range 70-99 mg/dL). His alanine aminotransferase and aspartate aminotransferase were elevated at 228 units (U/L) (reference range 5-55 U/L) and 125 U/L (reference range 5-40 U/L), respectively. Total bilirubin was elevated at 3.1 milligrams per deciliter (mg/dL) (reference range 0.2-1.2mg/dL), as well as direct bilirubin a 1.3 mg/dL (reference range 0.0-0.5 mg/dL). His serum lactate was 4.9 millimoles (mmol)/L (reference range 0.5-2.2 mmol/L), lactate dehydrogenase elevated at 964 U/L (reference range 125-220

CPC-EM Capsule

What do we already know about this clinical entity?

Cerebral malaria is a rare, poorly understood complication of Plasmodium falciparum that carries significant morbidity and mortality.

What makes this presentation of disease reportable?

Cerebral malaria is rare and not commonly seen in the United States.

What is the major learning point?

Cerebral malaria should be considered in any patient presenting with neurologic symptoms with recent travel to malaria endemic areas.

How might this improve emergency medicine practice?

Prompt recognition and treatment of this deadly disease is important to reducing the morbidity and mortality associated with this disease.

U/L) with a low haptoglobin and a normal prothrombin time test. Urinalysis was without signs of infection. A peripheral blood smear was obtained, which showed malarial parasites present concerning for *Plasmodium falciparum* infection with an initial parasite load of 10%. Multiple (between one and three) intra-erythrocyte rings were seen within single erythrocytes, which are consistent with malaria and was confirmed by ID.

The recommendations of the ID consultant were doxycycline and intravenous (IV) quinidine, and the patient was admitted to the ICU for continuous IV therapy and closer monitoring of his mental status as well as for the need for frequent laboratory draws and ECGs. IV quinidine can cause significant hyperinsulinemia and resultant hypoglycemia; therefore, the patient received hourly glucose checks. In addition, quinidine can prolong the QT interval, and the patient required hourly ECGs with ID recommendations of stopping quinidine if QTc increased by greater than 50% of patient's initial baseline and holding the medication until the QTc fell to less than 25% above the original value.

The patient continued to have waxing and waning levels of consciousness and required 24 hours of IV quinidine after which his peripheral smear showed a malarial burden of 0.7%, and he was transitioned to oral quinine. He did not have

episodes of hypoglycemia and his longest QTc interval was 540 msec. The patient's mental status slowly improved as his malarial burden decreased. He required three days in the ICU and was then transferred to the floor. He completed a three-day course of oral quinine while in the hospital, and his final smear had a parasite load of 0%. The patient was discharged on hospital day five on oral doxycycline to finish a total seven-day course. He followed up in the ID clinic two weeks after discharge and had no sequelae. His mental status had returned to normal, he had had no fevers, and had begun to regain his strength.

DISCUSSION

The definition of severe malaria constitutes a multitude of symptoms including altered level of consciousness, respiratory distress, shock, acute kidney injury, convulsions and others, but has one unifying factor in that it can only be caused by the *P. falciparum* species and is associated with a high mortality rate (greater than 5%) even with appropriate treatment.⁴ Cerebral malaria is a subset of severe malaria and is associated with an impaired level of consciousness. It is difficult to diagnose as it has no specific pathognomonic features to differentiate it from non-cerebral malaria as other malarial species can alter consciousness by separate pathophysiological processes.⁴ These include metabolic abnormalities or systemic effects of infection such as high fever.⁴ WHO characterizes cerebral malaria by unarousable or deep coma with asexual forms of *P. falciparum* parasites on peripheral blood smears and no other cause to explain the altered level of consciousness.⁵ WHO further reported that most published studies use the term cerebral malaria when referring to the syndrome in which altered consciousness, associated with a malarial infection, cannot be attributed to a non-malarial cause. This describes our patient as he was not comatose on arrival to the ED.⁶ As of yet, there has been no agreed upon definition for cerebral malaria, and in practice any patient with altered level of consciousness or other signs of neurologic impairment should be treated as cerebral malaria.

Our patient was from the DRC and had been there visiting friends and relatives (VFR), which is important to note as studies have shown that VFRs are at higher risk for diseases that are largely preventable, including malaria.⁷ The reason for this is multifactorial and includes barriers to preventative medical care prior to travel as well as patient misconceptions regarding their risk.⁷ VFRs in the US have higher levels of poverty, lower levels of formal education, and lower insurance coverage, which leads to less preventative pre-travel medical services.⁷ In addition, many VFRs are thought to perceive less personal risk secondary to their cultural and geographic familiarity with the area, as well as an idea that diseases such as malaria are "normal" or "expected" in the country they are visiting.⁷

In addition to the difficulty in diagnosing cerebral malaria, the treatment carries its own risks. Quinidine has been associated with torsades de pointes related to prolongation of

the QT interval as well as hypoglycemia secondary to hyperinsulinemia.^{8,9} Because of this, frequent ECGs must be performed and labs drawn, and the patient's neurologic status must be closely monitored. Another treatment option is exchange transfusion, which has been used in cases of severe malaria, in particular for patients with a parasite load greater than 10%.¹⁰ Exchange transfusion has been shown to improve laboratory values; however, it has not been shown to increase parasite clearance, ICU and hospital length of stay, in-hospital mortality, and cost of hospitalization.¹⁰ Our patient had a parasite load of 10% and could have potentially been treated with exchange transfusion as well as the other treatments above; however, ID did not feel this was warranted and exchange transfusion was not pursued.

CONCLUSION

Cerebral malaria is a leading cause of malaria mortality worldwide, accounting for 20% of adult deaths and 15% of childhood deaths.¹¹ Even with appropriate treatment early in the disease course, patients still have a high risk of death and up to 25% of survivors will have neurologic sequelae.¹¹ While many factors contribute to a patient's prognosis, including end-organ damage and severity of neurologic dysfunction, treatment must be given as early as possible to maximize the chance of recovery.⁶ To diagnose this rare disease process early in its course, emergency physicians should be aware of the symptoms and the need for screening in patients returning from a malaria-endemic area with altered levels of consciousness.

The authors attest that their institution requires neither Institutional Review Board approval, nor patient consent for publication of this case report. Documentation on file.

Address for Correspondence: Austin T. Smith, MD, Vanderbilt University Medical Center, Department of Emergency Medicine, 703 Oxford House Nashville, TN 37232-4700. Email: Austin.Smithut@gmail.com.

Conflicts of Interest: By the CPC-EM article submission agreement, all authors are required to disclose all affiliations, funding sources and financial or management relationships that could be perceived as potential sources of bias. The authors disclosed none.

Copyright: © 2020 Roberson et al. This is an open access article distributed in accordance with the terms of the Creative Commons Attribution (CC BY 4.0) License. See: <http://creativecommons.org/licenses/by/4.0/>

REFERENCES

1. World Health Organization. Number of Malaria Cases. 2018. Available at: <http://www.who.int/malaria/en/>. Accessed August 4, 2018.

2. World Health Organization. World Malaria Report. 2019. Available at: <https://www.who.int/publications-detail/world-malaria-report-2019>. Accessed February 2, 2019.
3. World Health Organization. Malaria in Children under Five. 2018. Available at: www.who.int/malaria/areas/high_risk_groups/children/en/. Accessed August 4, 2018.
4. Newton CR and Krishna S. Severe falciparum malaria in children: current understanding of pathophysiology and supportive treatment. *Pharmacol Ther*. 1998;79(1):1-53.
5. World Health Organization. Severe Falciparum Malaria. 2000. Available at: <https://www.ncbi.nlm.nih.gov/pubmed/11103309>. Accessed February 21, 2019.
6. Tropical Medicine and International Health. Severe Malaria. 2014. Available at: <https://www.who.int/malaria/publications/atoz/who-severe-malaria-tmih-supplement-2014.pdf?ua=1>. Accessed February 21, 2019.
7. Angell S and Cetron M. Health disparities among travelers visiting friends and relatives abroad. 2005. Available at: https://www-acpjournals-org.proxy.library.upenn.edu/doi/full/10.7326/0003-4819-142-1-200501040-00013?url_ver=Z39.88-2003&rft_id=ori:rid:crossref.org&rft_dat=cr_pub%20%20pubmed. Accessed June 27, 2020.
8. Bauman JL, Bauernfeind RA, Hoff JV, et al. Torsade de pointes due to quinidine: observations in 31 patients. *Am. Heart J*. 1984;107(3):425-30.
9. Phillips RE, Looareesuwan S, White NJ, et al. Hypoglycaemia and antimalarial drugs: quinidine and release of insulin. *Br Med J (Clin Res Ed)*. 1986;292(6531):1319-21.
10. Lin J, Huang X, Qin G, et al. Manual exchange transfusion for severe imported falciparum malaria: a retrospective study. *Malar J*. 2018;17(1):32.
11. Wang W, Qian H, Cao J. Stem cell therapy: a novel treatment option for cerebral malaria? *Stem Cell Res Ther*. 2015;6(1):141.

Apnea and Diffuse Alveolar Hemorrhage Caused by Cocaine and Heroin Use: A Case Report

Gideon Logan, MD*
Ernesto Robalino, MD†
Tracy MacIntosh, MD*
Latha Ganti, MD*

*University of Central Florida College of Medicine, Department of Emergency Medicine, Orlando, Florida

†University of Central Florida College of Medicine, Department of Internal Medicine, Orlando, Florida

Section Editor: Rick A. McPheeters, DO

Submission history: Submitted May 27, 2020; Revision received June 28, 2020; Accepted July 9, 2020

Electronically published October 5, 2020

Full text available through open access at http://escholarship.org/uc/uciem_cpem

DOI: 10.5811/cpcem.2020.7.48438

Introduction: Drug overdose represents a growing reason for emergency department visits and hospitalizations in the United States. Co-ingestion of multiple substances is also on the rise, and toxidromes can be seen from any of multiple drugs in a single patient.

Case Report: We present a case of diffuse alveolar hemorrhage secondary to cocaine abuse in a patient who was apneic and unresponsive after heroin overdose. The patient responded to supportive care and was discharged with complete return to physical and mental baseline.

Conclusion: Clinicians must be vigilant for any number of concomitant toxidromes when a patient is brought in with complications following drug overdose. [Clin Pract Cases Emerg Med. 2020;4(4):537–539.]

Keywords: *opioid use; cocaine use; overdose; toxidrome.*

INTRODUCTION

Heroin is a semisynthetic drug able to cross the blood-brain barrier with affinity for *mu* opioid receptors producing analgesia and euphoria. Cocaine is a plant-derived stimulant drug that blocks the re-uptake of serotonin, dopamine, and norepinephrine, among other modes of action. Co-ingestion of heroin with cocaine remains a growing sector of illicit drug use and represents a poor prognostic indicator for drug addiction recovery from either substance individually, with or without medication-assisted treatment.¹

While the euphoric effects of heroin and cocaine co-ingested have been described as synergistic, the toxic effects remain additive depending on the total dose, route, form, and frequency of use.¹ Opioid overdose causes miosis and respiratory depression leading to hypoxemia, eventual coma, and then death. Cocaine abuse affects multiple organ systems including pulmonary effects, notably pulmonary hypertension, acute eosinophilic pneumonia, and diffuse alveolar hemorrhage (DAH).² Here we present a case of heroin/cocaine

co-ingestion causing initial apnea and hypoxemia, and then DAH requiring mechanical ventilation and supportive care.

CASE REPORT

A 20-year-old male with a history of polysubstance abuse presented to the emergency department (ED) after being found unconscious by family members in a car. The patient was with his father and a cousin, and all three individuals were snorting both heroin and cocaine. Emergency medical services (EMS) reported the patient was apneic and had peripheral capillary oxygen saturation (SpO₂) 65% at the time of arrival, but they were able to raise oxygen saturations to 92% with use of bag-valve-mask. EMS administered two doses of two milligrams intramuscular naloxone with spontaneous return of breathing and consciousness.

On initial presentation to the ED, the patient's vitals were as follows: heart rate 123 beats per minute; blood pressure 98/79 millimeters of mercury (mm Hg); respiratory rate 21 breathes per minute; SpO₂ 100% on six liters per minute

oxygen via nasal canula. and temperature 36.7° Celsius. The patient was awake and alert and able to answer questions with a primary complaint of chest tightness and persistent scant hemoptysis. The patient's family noted epistaxis about five minutes after initial drug ingestion. After two liters of normal saline were bolused, the patient showed a reduction of pulse to 94 beats per minute and an increase in systolic blood pressure to 116 mm Hg. On physical exam, no obvious sources of bleeding were identified intranasally, within the oropharynx or mouth. Auscultation of the lungs demonstrated coarse breath sounds in all lung fields. Initial blood laboratory tests, including a complete blood count and coagulation panel, were normal. Initial chest radiography demonstrated bilateral extensive alveolar densities (Image 1) The patient's respiratory and mental status were maintained without need for additional doses of naloxone.

Three hours after arrival to the ED, the patient's oxygen saturation began to decline, and he became tachypneic, tachycardic, and hypotensive. The patient required invasive mechanical ventilation for hypoxic acute respiratory failure. After initial intubation with confirmation of tube placement via capnography and radiography, achieving adequate oxygen saturation of >92% required acute respiratory distress syndrome protocol, volume-control ventilator settings: rate 24, tidal volume 440 milliliters, fraction of inspired oxygen (FiO₂) 100%, positive end-expiratory pressure (PEEP) 15 centimeters water. The patient was then admitted to the medical-surgical intensive care unit for further management.

During his hospital stay, the patient remained hemodynamically stable, afebrile, without leukocytosis or lactic acidosis. Electrocardiogram (ECG) did not show

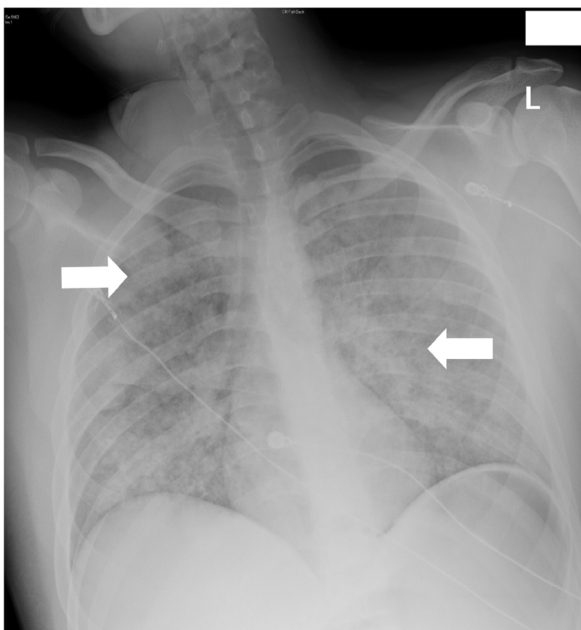


Image 1. Chest radiograph at initial presentation showing diffuse pulmonary infiltrates. White arrows showing infiltrates.

CPC-EM Capsule

What do we already know about this clinical entity?

Drug toxidromes are sometimes thought of as singular, but patients using multiple drugs can show multiple toxidromes at the same time.

What makes this presentation of disease reportable?

We present a case of apnea and altered mentation from heroin overdose that was reversed, followed by onset of diffuse alveolar hemorrhage from delayed cocaine toxicity.

What is the major learning point?

Clinicians must keep suspicion for multiple toxidromes when symptoms are consistent with drug use or the patient is triaged as "overdose."

How might this improve emergency medicine practice?

"Red flag" history and physical exam findings should prompt attention for multiple toxidromes and adequate observation in drug use patients.

evidence of ischemic changes and serial troponins were normal. Non-contrast enhanced computed tomography of the chest showed extensive bilateral diffuse pulmonary infiltrates with sparing of the periphery (Image 2).

Bronchoscopy revealed moderate to severe diffuse bronchial hyperemia and mucosal erosions, and successive aliquots of bronchoalveolar lavage showed progressively increasing blood-tinged secretions. Rheumatologic workup was unremarkable. Sputum and blood cultures were negative, and bronchial lavage cultures had no growth. The patient was treated empirically with piperacillin-tazobactam and azithromycin. After the first 24 hours with mechanical ventilation, the patient tolerated lower settings of FiO₂ and PEEP and was later transitioned to non-invasive ventilatory support, with return to baseline ventilatory status and discharged home on hospital day six.

DISCUSSION

In 2016, opioid overdose accounted for 200,322 ED visits and 85,944 hospitalizations, while cocaine overdose accounted for 19,709 ED visits and 8723 hospitalizations.³ Drug overdose will continue to affect every aspect of the healthcare system in the emergency, inpatient, and outpatient settings.

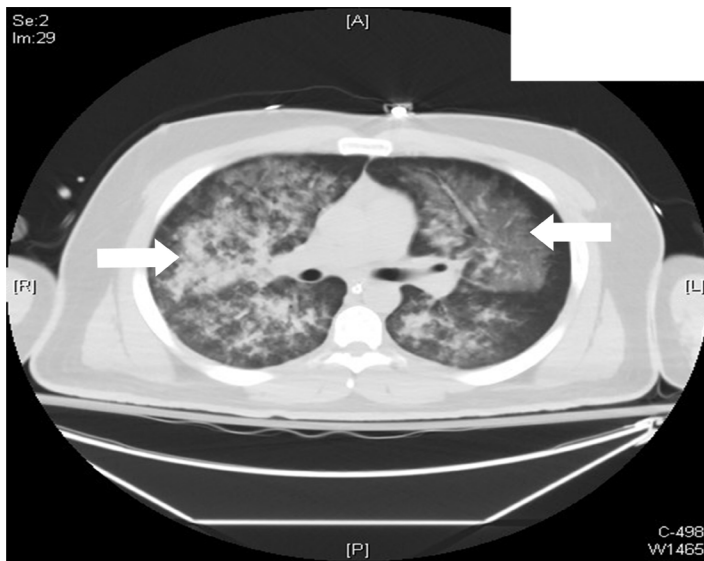


Image 2. Non-contrast enhanced computed tomography of the chest showing diffuse infiltrates located centrally. White arrows showing infiltrates.

Alveolar hemorrhage is a respiratory emergency that needs to be recognized and treated early due to risks of high mortality.⁴ Clinical presentation can have a wide variety of symptoms including subtle symptoms of fever, dyspnea, and hemoptysis. In this case, multiple other etiologies were ruled out as causative of DAH,⁵ leaving cocaine-induced DAH the likely culprit. The ECG did not demonstrate ischemia, and serial troponins were negative ruling out cardiogenic sources of alveolar hemorrhage. Aspiration pneumonitis was considered given the altered and apneic initial presentation but was unlikely to have caused the extent of diffuse alveolar involvement seen. Rheumatologic markers were all negative making vasculitic etiologies unlikely, and cultures of sputum, blood, and bronchoalveolar lavage were negative for causative pathogens making infectious etiologies unlikely, although broad-spectrum antibiotics were started at first.

As demonstrated in the above case, co-ingestion of illicit drugs can be challenging to treat with multiple toxidromes playing out simultaneously in a single patient. What first presented as solely a heroin overdose with adequate reversal and stability quickly deteriorated secondary to cocaine-induced toxicity. While the treatment of opioid overdose is more straightforward with specific, targeted reversal agents and supportive care, the treatment of cocaine overdose lacks a targeted reversal agent and relies on the mainstay of supportive medications and treatments based on symptomatology. The exact emergency management for many drug overdose patients depends on practitioner preference and practice location, but a few key red-flag qualities that supported a more prolonged observation period in this case included knowledge of co-ingestion, degree of apnea and hypoxemia on initial presentation, and amount of naloxone required for reversal of respiratory depression and altered mental status. The presence of atypical physical exam findings

(hemoptysis in this case) can also be a clue to severity and help guide decisions on disposition of overdose patients.

CONCLUSION

Drug overdose is a common presenting complaint in many EDs and providers must address the toxicity from myriad abused substances, both illicit and prescribed. This case presented “routinely” with apnea and hypoxemia from heroin overdose that was corrected with naloxone but was complicated by diffuse alveolar hemorrhage caused by cocaine toxicity. While this case had a collateral historian to corroborate the details of the extent of the drug use, not all patients’ drug use will be so easily identified. Attention to any red-flag components of the history and unexpected physical exam findings will guide required interventions and disposition. Clinicians must maintain high suspicion for multiple toxidromes of co-ingested drugs when any drug overdose patient is treated.

The authors attest that their institution requires neither Institutional Review Board approval, nor patient consent for publication of this case report. Documentation on file.

Address for Correspondence: Gideon Logan, MD, UCF College of Medicine, Department of Emergency Medicine, 720 W. Oak St. Ste. 201, Kissimmee, FL 34741. Email: Gideon.Logan@ucf.edu.

Conflicts of Interest: By the CPC-EM article submission agreement, all authors are required to disclose all affiliations, funding sources and financial or management relationships that could be perceived as potential sources of bias. The authors disclosed none.

Copyright: © 2020 Logan et al. This is an open access article distributed in accordance with the terms of the Creative Commons Attribution (CC BY 4.0) License. See: <http://creativecommons.org/licenses/by/4.0/fr>

REFERENCES

1. Leri F, Bruneau J, Steward J. Understanding polydrug use: review of heroin and cocaine co-use. *Addiction*. 2002;98(1):7-22.
2. Haim DY, Lippmann ML, Goldberg SK, et al. The pulmonary complications of crack cocaine. A comprehensive review. *Chest*. 1995;107(1):233-40.
3. Centers for Disease Control and Prevention. 2019 Annual Surveillance Report of Drug-Related Risks and Outcomes — United States Surveillance Special Report. Available at <https://www.cdc.gov/drugoverdose/pdf/pubs/2019-cdc-drug-surveillance-report.pdf>. Accessed January 2, 2020.
4. Collard HR and Schwarz MI. Diffuse alveolar hemorrhage. *Clin Chest Med*. 2004;25(3):583-92.
5. Schwarz MI and Fontenot AP. Drug-induced diffuse alveolar hemorrhage syndromes and vasculitis. *Clin Chest Med*. 2004;25(1):133-40.

Thyroid Storm, Rhabdomyolysis, and Pulmonary Embolism: An Unusual Triad Case Report

Montane B. Silverman, BA*
Jesse Wray, MD†
Rachel E. Bridwell, MD†
Amber Cibrario, DO†

*Uniformed Services University F. Edward Hebert School of Medicine, Bethesda, Maryland
†Brooke Army Medical Center, Department of Emergency Medicine, Fort Sam Houston, Texas

Section Editor: Scott Goldstein, DO

Submission history: Submitted April 18, 2020; Revision received July 4, 2020; Accepted July 16, 2020

Electronically published September 3, 2020

Full text available through open access at http://escholarship.org/uc/uciem_cpem

DOI: 10.5811/cpem.2020.7.47774

Introduction: Thyroid storm is a medical emergency associated with significant mortality. Hyperthyroid states have been associated with hypercoagulability as well as rhabdomyolysis. However, the pathophysiology of this association remains under investigation.

Case Report: A 62-year-old male patient presented to the emergency department with weakness and was found to have thyroid storm with concurrent submassive pulmonary embolisms and rhabdomyolysis. To our knowledge, this is the first reported presentation of this triad.

Conclusion: This case highlights the potentially difficult diagnosis and management of thyroid storm, as well as associated life-threatening complications, including venous thromboemboli and rhabdomyolysis. [Clin Pract Cases Emerg Med. 2020;4(4):540–543.]

Keywords: *Thyroid storm; rhabdomyolysis; pulmonary embolism; case report.*

INTRODUCTION

Hyperthyroid states exist on a spectrum of disease severity; this spectrum ranges from subclinical hyperthyroidism to clinical manifestations of this hormone derangement, or thyrotoxicosis, to the most severe form with multisystem involvement and evidence of systemic decompensation – thyroid storm.¹ Thyroid storm most commonly affects female patients, with an associated mortality rate between 8-25%, and those over 60 years of age have worse outcomes.¹ This life-threatening condition characterized by adrenergic overactivity can be secondary to a myriad of etiologies and is often triggered by stress-inducing states such as surgery, trauma, or infection.¹

Classically, thyroid storm is a clinical diagnosis of thyrotoxicosis with multisystem deterioration. This diagnosis is augmented by clinical scoring systems such as the Burch-Wartofsky Point Scale (BWPS). BWPS uses a point scale to assign patients into three categories suggesting their likelihood of progressing to fulminant thyroid storm. The scale

incorporates temperature, central nervous system effects, gastrointestinal and hepatic dysfunction, heart rate, evidence of congestive heart failure, and the presence or absence of atrial fibrillation as well as a precipitating event (Table).^{1,2}

Previous literature has demonstrated that hyperthyroid states have been associated with hypercoagulability leading to venous thromboembolic (VTE) events such as cerebral thrombosis, deep vein thrombosis (DVT), and pulmonary embolism (PE).³⁻¹⁰ Additionally, multiple cases report rhabdomyolysis as a sequela of hyperthyroid states.¹¹⁻¹⁵ To our knowledge, this is the first reported case of a patient with thyroid storm complicated by both rhabdomyolysis and submassive PE at time of presentation to the emergency department (ED).

CASE REPORT

A 62-year-old male with past medical history of prior cerebral vascular accident and coronary artery disease presented to the ED by emergency medical services with three days of extremity weakness, fatigue, and imbalance. The patient's

Table. The Burch-Wartofsky Point Scale is used as a clinical scoring system for hyperthyroid states.

Criteria	Point value
Temperature (°F)	
<99	0
99-99.9	5
100-100.9	10
101-101.9	15
102-102.9	20
103-103.9	25
>104.0	30
Central Nervous System Symptoms	
None	0
Mild (agitation)	10
Moderate delirium, psychosis, lethargy)	20
Severe (seizure, coma)	30
Gastrointestinal-hepatic Symptoms	
None	0
Moderate (diarrhea, nausea/vomiting, abdominal pain)	10
Severe (unexplained jaundice)	20
Cardiovascular dysfunction (beats/min)	
<90	0
90-109	5
110-119	10
120-129	15
130-139	20
>140	25
Atrial fibrillation	
Absent	0
Present	10
Heart failure	
None	0
Mild (pedal edema)	5
Moderate (bibasilar rales)	10
Severe (pulmonary edema)	15
Precipitant history	
Absent	0
Present	10
Total Score	
Thyroid Storm Unlikely	<25
Impending Storm	25-45
Highly Suggestive of Thyroid Storm	>45

F, Fahrenheit; min, minutes.

spouse reported that he experienced lethargy, myalgias, decreased appetite, subjective fevers, and poor sleep over this time. One day prior to presentation, the patient fell secondary to generalized weakness without a loss of consciousness, which

CPC-EM Capsule

What do we already know about this clinical entity?

Thyroid storm is a medical emergency with significant mortality. Hyperthyroid states have been associated with both hypercoagulability and rhabdomyolysis.

What makes this presentation of disease reportable?

To our knowledge this is the first reported case of a patient presenting to the ED with thyroid storm, rhabdomyolysis, and a pulmonary embolism.

What is the major learning point?

Thyroid storm can be associated with life-threatening complications such as rhabdomyolysis and pulmonary embolism.

How might this improve emergency medicine practice?

By having suspicion for additional life-threatening complications, the emergency provider can improve the management of thyroid storm.

ultimately prompted presentation for medical evaluation, after lying on the floor for approximately four hours.

On presentation to the ED, vital signs included heart rate of 121 beats per minute (bpm), blood pressure of 130/103 millimeters of mercury (mm Hg), respiratory rate of 20 breaths per minute with a saturation of 95% on room air, and oral temperature of 101.5 degrees Fahrenheit. Physical examination was notable for tachycardia, diffuse abdominal pain without evidence of peritonitis, a resting tremor, and mild confusion.

Electrocardiogram was notable for sinus tachycardia to 121 bpm without evidence of ischemia or right heart strain. Serum studies demonstrated a thyroid stimulating hormone level of 0.007 microinternational units (uIU) per microliter (uL) (normal 0.27-5.00 uIU/uL), free T4 (FT4) of 2.94 nanograms per deciliter (ng/dL) (normal 0.6-1.8 ng/dL), elevation of aminotransferases with an aspartate aminotransferase of 232 units (U) per liter (L) (normal 5-40 U/L) and an alanine aminotransferase of 78 U/L (normal 4-41 U/L), creatinine of 1.23 milligrams (mg)/dL (normal 0.67-1.17 mg/dL), troponin of 0.081 ng/mL (normal <0.03 ng/mL), and B type natriuretic peptide was elevated to 2852 picograms (pg)/mL (normal <900 pg/mL). Creatinine kinase (CK) was also elevated to 32,290 IU/L (normal 24-170 IU/L), and urinalysis demonstrated large amounts of blood with only two red blood cells/high powered

field (normal 0-3). A computed tomography (CT) of the abdomen and pelvis showed no abnormalities, although a PE was noted in the right lower lobe of the lung (Image), which was confirmed with a subsequent CT pulmonary angiogram along with an additional right upper lobe PE.

Based on the patient's presentation with abnormal thyroid function, BWPS score was calculated as 50, which is highly suggestive of thyroid storm. He was started on propranolol, propylthiouracil, Lugol's iodine solution, and hydrocortisone with improvement of his vital signs and symptoms over the following several days. Therapeutic heparin was initiated for multiple submassive pulmonary emboli, with resolution of elevated troponin. Anticoagulation was transitioned to apixaban for continued outpatient treatment.

Additionally, the patient was diagnosed with rhabdomyolysis in the setting of myalgias, elevated CK well above five times the upper limit of normal, acute kidney injury, and myoglobinuria. He received intravenous fluids with a urine output goal of 200-300 mL/hour as well as allopurinol due to hyperuricemia. CK and uric acid levels were trended throughout hospitalization, which progressively improved prior to discharge. He was ultimately discharged after an otherwise uneventful hospitalization.

DISCUSSION

Both hyperthyroidism and hypothyroidism precipitate a variety of physiologic derangements, including hypercoagulable and hypocoagulable states. The effects of these changes in coagulability range from subclinical to fatal coagulative events.³ There is no current consensus on the pathophysiology of this hypercoagulability as numerous studies have shown a wide effect of hyperthyroidism on platelets, coagulations factors, and von Willebrand factor.^{4,5} However, a variety of data demonstrates that increased levels of thyroid hormone alter the coagulation-fibrinolysis equilibrium and this increase in hormone level is an independent risk factor for VTE.^{3,5-6}

A clear dose response of FT4 in both PE and DVT has been established.⁷ While this association could be attributed to a non-thyroidal illness syndrome, in which a decrease in peripheral conversion of T4 to T3 is seen, this has been generally dismissed in the literature based on increased levels of T3 in cases of VTE associated with hyperthyroid disease.⁷ Although thyrotoxicosis and thyroid storm precipitate both arterial and venous thrombosis, the majority of the literature on hypercoagulability focuses on endocrine management rather than that of VTEs.^{8,9} The management, prophylaxis, and occurrence of VTE in patients with thyroid storm remain a site of investigation, although quelling the precipitating event and preventing VTE propagation are the mainstay of treatment.

Despite the current body of literature reflecting hypothyroidism as a risk factor for the development of rhabdomyolysis, there are very limited data that have

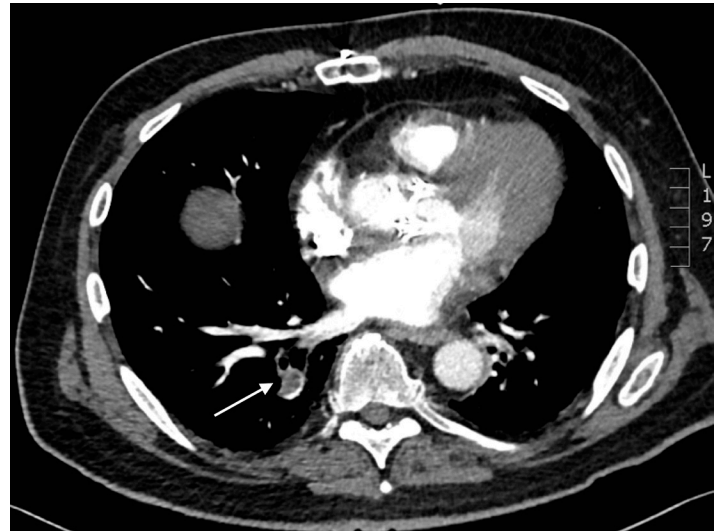

Image. Computed tomography of the chest with contrast demonstrating a right lower lobe pulmonary embolism (arrow).

demonstrated an association between hyperthyroid states and rhabdomyolysis.¹⁰⁻¹² These limited cases occurred both with and without significant exertion.¹³ While the pathophysiology of hyperthyroid-induced rhabdomyolysis has not been established, it is hypothesized that the increased metabolic rate exhausts muscular substrates and energy stores.^{11,12} By definition, rhabdomyolysis requires elevated CK levels and myalgias, which differentiates it from the other neuromuscular-involved pathologies of hyperthyroidism such as thyrotoxic myopathy, thyrotoxic periodic paralysis, and thyroid ophthalmopathy.^{11,14} In this case, the patient sustained a fall resulting in multiple hours on the ground, a common precipitant of rhabdomyolysis. However, the patient had been experiencing generalized symptoms including myalgias and weakness prior to the fall. Although it is probable that the fall contributed to the patient developing rhabdomyolysis, hyperthyroidism likely also contributed either directly via increased metabolism or indirectly via generalized weakness resulting in a fall.

Much like the above case, a similar presentation described a patient with thyroid storm who subsequently developed rhabdomyolysis as well as a DVT and subclinical PE during her hospitalization.¹⁵ Although that prior case established these three diagnostic entities occurring in a single patient, our case is the first report of a patient with these pathologies diagnosed both simultaneously and acutely on presentation in the ED. A review of the current literature did not find independent correlation between VTE disease and rhabdomyolysis. Without independent correlation between these two entities, hyperthyroid pathology is the most likely underlying etiology related to both the PE and rhabdomyolysis. The authors hypothesize that this patient developed a venous thrombosis with embolization to the pulmonary arteries as a consequence of the hyperthyroid

condition. Additionally, rhabdomyolysis was likely from the hypermetabolic state induced by the thyroid storm itself, the fall sustained secondary to weakness from thyroid storm, or a combination of these two factors.

CONCLUSION

With the established severe morbidity and mortality of thyroid storm, it is crucial that emergency physicians quickly recognize and manage this pathology. Diagnostic tools such as the BWPS can aid in early identification. Emergency physicians must also be aware of conditions associated with thyroid storm that can further compound morbidity and mortality. While the pathophysiology of thyroid storm and its association with hypercoagulability and rhabdomyolysis remains nebulous, their association can generate critically ill patients. The above case demonstrates that both venous thromboembolic disease and rhabdomyolysis can occur acutely with thyroid storm, reflecting the heightened suspicion that physicians should maintain for the resulting rhabdomyolysis and VTE in patients presenting with thyroid storm.

The authors attest that their institution requires neither Institutional Review Board approval, nor patient consent for publication of this case report. Documentation on file.

Address for Correspondence: Montane B. Silverman, BA, F. Uniformed Services University Edward Hebert School of Medicine, 4301 Jones Bridge Rd, Bethesda, MD 20814. Email: montane.silverman@usuhs.edu.

Conflicts of Interest: By the CPC-EM article submission agreement, all authors are required to disclose all affiliations, funding sources and financial or management relationships that could be perceived as potential sources of bias. The views expressed here are those of the authors and do not reflect the official policy of the Department of the Army, the Department of Defense, or the U.S. Government.

Copyright: © 2020 Silverman et al. This is an open access article distributed in accordance with the terms of the Creative Commons Attribution (CC BY 4.0) License. See: <http://creativecommons.org/licenses/by/4.0/>

REFERENCES

- Ross DS, Burch HB, Cooper DS, et al. 2016 American Thyroid Association Guidelines for Diagnosis and Management of Hyperthyroidism and Other Causes of Thyrotoxicosis. *Thyroid*. 2016;26(10):1343-421.
- Burch HB and Wartofsky L. Life-threatening thyrotoxicosis: thyroid storm. *Endocrinol Metab Clin North Am*. 1993;22(2):263-77.
- Squizzato A, Romualdi E, Büller HR, et al. Clinical review: thyroid dysfunction and effects on coagulation and fibrinolysis: a systematic review. *J Clin Endocrinol Metab*. 2007;92(7):2415-20.
- Franchini M, Lippi G, Targher G. Hyperthyroidism and venous thrombosis: a casual or causal association? A systematic literature review. *Clin Appl Thromb*. 2011;17(4):387-92.
- Ordookhani A and Burman KD. Hemostasis in overt and subclinical hyperthyroidism. *Int J Endocrinol Metab*. 2017;15(3):e44157.
- Stuijver DJF, van Zaane B, Romualdi E, et al. The effect of hyperthyroidism on procoagulant, anticoagulant and fibrinolytic factors: a systematic review and meta-analysis. *Thromb Haemost*. 2012;108(6):1077-88.
- Elbers LPB, Fliers E, Cannegieter SC. The influence of thyroid function on the coagulation system and its clinical consequences. *J Thromb Haemost*. 2018;16(4):634-45.
- Lodha A, Haran M, Frankel R, et al. Thyrotoxicosis causing arterial and venous thrombosis. *Am J Med Sci*. 2009;338(5):428.
- Min T, Benjamin S, Cozma L. Thromboembolic complications of thyroid storm. *Endocrinol Diabetes Metab Case Rep*. 2014;2014:130060.
- Hosojima H, Iwasaki R, Miyauchi E, et al. Rhabdomyolysis accompanying thyroid crisis: an autopsy case report. *Intern Med*. 1992;31(10):1233-5.
- Lichtstein DM and Arteaga RB. Rhabdomyolysis associated with hyperthyroidism. *Am J Med Sci*. 2006;332(2):103-5.
- Bennett WR and Huston DP. Rhabdomyolysis in thyroid storm. *Am J Med*. 1984;77(4):733-5.
- Lindner LS and Emkey GR. Exertion-related rhabdomyolysis observed with hyperthyroidism. *Am J Med*. 2015;128(6):e7-8.
- Cakir M, Mahsereci E, Altunbas H, et al. A case of rhabdomyolysis associated with thyrotoxicosis. *J Natl Med Assoc*. 2005;97(5):732-4.
- Umez T, Ashitani K, Toda T, et al. A patient who experienced thyroid storm complicated by rhabdomyolysis, deep vein thrombosis, and a silent pulmonary embolism: a case report. *BMC Res Notes*. 2013;6:198-202.

Giant Bladder Calculus in an Adult- A Persistent Problem in the Developing World: A Case Report

Ajit Kumar Vidhyarthi, MBBS*
Tariq Hameed, MBBS, MS†
Rohit Lal, MBBS*
Awadh Kumar, MBBS, MS*
Shivanand Sahni, MBBS, MS*
Nanse Mendoza, MD‡

*Darbhanga Medical College and Hospital, Department of Surgery, Darbhanga, India
†Hamdard Institute of Medical Sciences and Research, New Delhi, India
‡Kern Medical Center, Department of Emergency Medicine, Bakersfield, California, United States of America

Section Editor: Scott Goldstein, DO

Submission history: Submitted April 11, 2020; Revision received July 22, 2020; Accepted July 22, 2020

Electronically published September 23, 2020

Full text available through open access at http://escholarship.org/uc/uciem_cpccem

DOI: 10.5811/cpcem.2020.7.47653

Introduction: Giant urinary bladder calculus in an adult is an uncommon entity. The number of patients with giant bladder calculi has decreased over recent years owing to wider availability of healthcare and better diagnostic modalities.

Case Report: We present a case of a young adult without any history of recurrent urinary tract infections or bladder outlet obstruction with giant vesical calculus who presented to the emergency department with gross hematuria, abdominal pain, and dysuria. Investigations revealed a large calculus in the urinary bladder, and suprapubic cystolithotomy was performed. A large stone of 6.5×6×5.5 centimeters, weighing 125 grams, was removed. On follow-up, the patient was free of any symptoms and cystoscopy was normal.

Conclusion: Urinary outflow obstruction must be ruled out in all patients with giant vesical calculus. Patients without any predisposing condition should be treated as a separate entity and evaluated accordingly. Multiple surgical treatment modalities are available for bladder calculus patients. Treatment is personalised as per size of stone, number of stones, and associated comorbidities. [Clin Pract Cases Emerg Med. 2020;4(4):544–547.]

Keywords: *giant vesical calculus; gross hematuria; suprapubic cystolithotomy.*

INTRODUCTION

Urinary bladder calculi comprise approximately 5% of all cases of urolithiasis.¹ A urinary bladder calculus more than 100 gram (gm) in weight is classically labelled as giant vesical calculus.² Fewer than 100 cases have been reported in the literature with weight more than 100 gm and almost all of them had bladder outlet obstruction.³ Not many cases of giant vesical calculus are reported in the modern era because of widespread access to healthcare facilities including radiograph and ultrasonography. Bladder calculi have a varied presentation ranging from completely asymptomatic to dysuria, lower abdominal pain, gross hematuria, and retention

of urine.⁴ Here we report a case of giant vesical calculus in an otherwise healthy adult male who presented to the emergency department (ED) with gross hematuria, lower abdominal pain, and dysuria.

CASE REPORT

A 34-year-old Indian male presented to the ED with complaints of gross hematuria, severe dysuria, and pain in the lower abdomen for two days. He reported a history of 4–5 episodes of increased frequency of micturition associated with poor urinary stream and dull aching pain in his lower abdomen during the prior three years. He also reported passing blood in

his urine occasionally in the preceding month, which was towards the end of the act of micturition. The patient was non-diabetic and denied history of tobacco or alcohol abuse. On physical examination he was afebrile and there was tenderness and fullness in the hypogastrium. Prostate was normal on digital rectal examination. A three-way Foley catheter was introduced and the bladder irrigated with normal saline after taking urine samples for routine and microscopic examination.

Urine lab work showed the presence of red blood cells (RBC) more than 200 per high power field (HPF) (reference range 4 RBC/HPF), and pus cells were 30/HPF. Urine culture showed *Escherichia coli* sensitive to *amikacin*. His total leucocyte count was 13,800 per microliter (μ l) (reference range 4000-11000/ μ l) with neutrophils accounting for 84% in differential leucocyte count. His blood urea, serum creatinine, and blood glucose levels were in normal range. Ultrasonography suggested a large vesical calculus with bilateral normal kidneys. Radiography of kidney-ureter-bladder revealed a radio-opaque shadow in the pelvic region measuring approximately 6×5 cm in size (Image 1). Antibiotics were started to control urinary tract infection, and open cystolithotomy was performed. A large calculus (6.5×6×5 cm, and weighing 125 gm) was removed (Image 2). Postoperative period was uneventful. The patient was discharged on postoperative day 3, and the catheter was removed at postoperative day 14. The patient had no further episodes of hematuria, and his lower urinary tract symptoms were also relieved. At six weeks post-surgery, follow-up

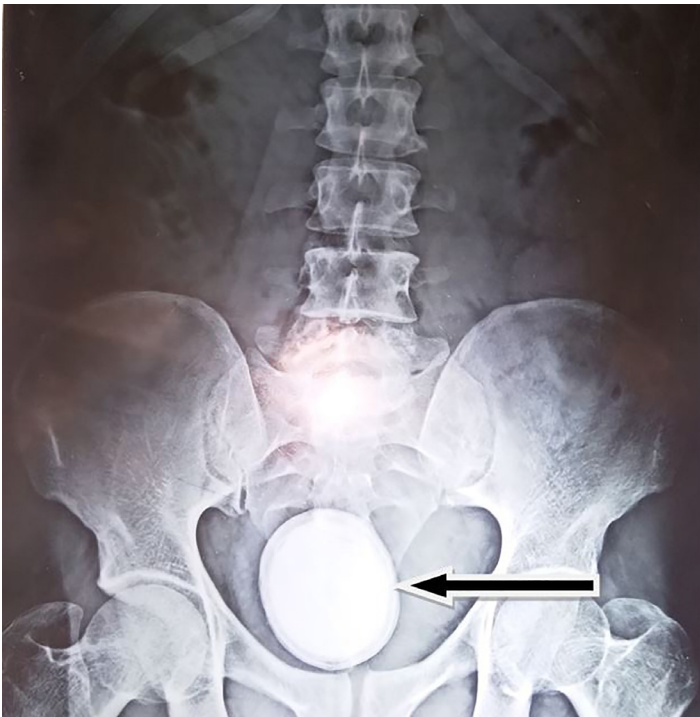


Image 1. Radiograph of kidney, ureters and bladder showing a giant radiodensity overlying the bladder.

CPC-EM Capsule

What do we already know about this clinical entity?

Urinary bladder calculus is an uncommon problem. This is an important subset of all types of urolithiasis.

What makes this presentation of disease reportable?

Due to better diagnostics, vesical calculi are found early which makes it unusual to have a young adult with giant vesical calculus coming to emergency department.

What is the major learning point?

Giant vesical calculus may present without infravesical obstruction. In such cases etiology of stone formation should be thoroughly investigated.

How might this improve emergency medicine practice?

As demonstrated in this case, giant vesical calculus must be considered in young adults presenting to emergency departments.

cystoscopy was normal without any residual stone, bladder outlet obstruction, or cystitis/urethritis.

DISCUSSION

Urinary tract stones have continued to be a cause of concern for humans since time immemorial, and symptoms of bladder calculus were described by Hippocrates.⁵ Prevalence rate of urinary tract stones in developed countries is between 4-20%, while in Asia it is estimated to be between 1-19.1%.^{6,7} Bladder calculi are usually secondary to calculi in the kidney or ureter, and it is rare to find primary bladder calculus in healthy adults. Bladder calculi constitute approximately 5% of all urinary tract stones.¹ Bladder stones in adults are composed of uric acid in almost 50% of the cases without having features of gout or hyperuricemia.⁸

All factors causing urinary stasis, such as benign prostatic hyperplasia, neurogenic bladder, urethral strictures, and recurrent urinary tract infections, lead to formation of stones in urinary bladder.⁹ Foreign bodies such as stents and catheter act as niduses for stone formation.¹ A giant bladder stone was reported in a patient who had undergone augmentation cystoplasty.⁹ It is unusual to have giant bladder stone without any such predisposing condition and this needs further discussion and investigations. Giant bladder calculi without any known predisposing factor should be considered

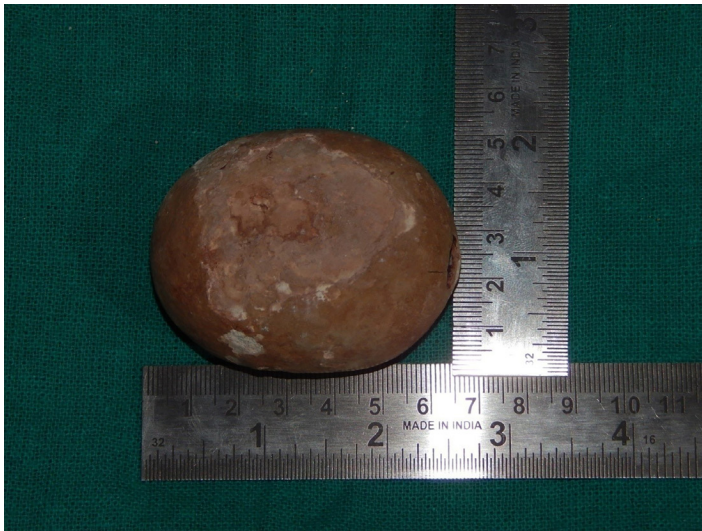

Image 2. Giant vesical calculus measuring 6.5 x 6 x 5 centimeters.

as a separate entity, and further evaluation regarding etiology and treatment is required.

Bladder stones have varied clinical presentations ranging from completely asymptomatic to acute retention of urine. A young male with giant vesical calculus was having defecatory problems, and his symptoms resolved on removal of stone.¹⁰ Giant vesical calculus has also been reported with bilateral hydronephrosis.¹⁰ Patients have also presented with pollakiuria and hematuria.³ A case has been described in the literature where a giant vesical calculus presented as acute renal failure.¹¹ In children, bladder stones may present as priapism and enuresis.¹²

Treatment of bladder stones has undergone a sea change in last few centuries. The first documented suprapubic lithotomy was performed by Pierre Franco in 1561.⁴ Bigelow in 1874 advanced bladder stone surgery by designing a larger lithotrite with which he performed litholapaxy.⁴ Recently advanced endourological procedures have replaced an open approach to urinary tract stones but an open surgical approach is still used if stones have atypical presentation, are large or multiple in number, or if advanced facilities are not available.^{13,14} Endourological procedures such as pneumatic lithotripsy are equally effective and safe with considerably lower morbidity.¹⁵ Percutaneous cystolithotripsy has a greater than 90% stone-free rate with the added benefit of no increased risk of developing urethral stricture as no endoscopic sheath is passed per urethra.^{16,17} Stone clearance rate and success of lithotripsy also depends on size and Hounsfield unit of stones.¹⁸ Extracorporeal shock wave lithotripsy is better for high-risk surgical patients or those having smaller stones.¹⁶

CONCLUSION

Giant urinary bladder stones are rare and have different ways of presentation. Finding the cause of stone formation is

as important as diagnosis itself. Any pathology causing bladder outlet obstruction must be diagnosed and treated to prevent recurrence. A young male without any infravesical obstruction or recurrent urinary tract infections presenting with giant vesical calculus is an uncommon presentation. Such giant stones should be treated as a separate entity, and further research must be conducted to find the etiology of stone formation in such cases. Prompt diagnosis, early intervention, and follow-up are paramount to having a good prognosis. Treatment modality for each patient differs with respect to the size and number of stones and associated comorbidities.

The authors attest that their institution requires neither Institutional Review Board approval, nor patient consent for publication of this case report. Documentation on file.

Address for Correspondence: Tariq Hameed, MBBS, MS, Department of Surgery, Hamdard Institute of Medical Sciences and Research, New Delhi, PIN- 110062. Email: drtariqhameed@gmail.com.

Conflicts of Interest: By the CPC-EM article submission agreement, all authors are required to disclose all affiliations, funding sources and financial or management relationships that could be perceived as potential sources of bias. The authors disclosed none.

Copyright: © 2020 Vidhyarthi et al. This is an open access article distributed in accordance with the terms of the Creative Commons Attribution (CC BY 4.0) License. See: <http://creativecommons.org/licenses/by/4.0/>

REFERENCES

- Schwartz BF and Stoller ML. The vesical calculus. *Urol Clin North Am.* 2000;27(2):333-46.
- Becher RM, Tolia BM, Newman HR. Giant vesical calculus. *JAMA.* 1978;239(21):2272-3.
- Tahtalı İN and Karataş T. Giant bladder stone: a case report and review of the literature. *Turk J Urol.* 2014;40(3):189-91.
- Hammad FT, Kaya M, Kazim E. Bladder calculi: Did the clinical picture change? *Urology.* 2006;67(6):1154-8.
- Tefekli A and Cezayirli F. The history of urinary stones: in parallel with civilization. *ScientificWorldJournal.* 2013;2013:423964.
- Trinchieri A. Epidemiology of urolithiasis. *Arch Ital Urol Androl.* 1996;68(4):203-50.
- Liu Y, Chen Y, Liao B, et al. Epidemiology of urolithiasis in Asia. *Asian J Urol.* 2018;5(4):205-14.
- Leslie SW, Sajjad H, Murphy PB. (2020). Bladder stones. In: *StatPearls.* Treasure Island, FL: StatPearls Publishing.

9. Kumar S and Jayant K. Massive vesical calculi formation as a complication of augmentation cystoplasty. *Nephrourol Mon.* 2014;7(1):e222297.
10. Rahman M, Uddin A, Das GC, et al. A giant vesical calculus. *Mymensingh Med J.* 2007;16(2 Suppl):S57-9.
11. Wei W and Wang J. A huge bladder calculus causing acute renal failure. *Urol Res.* 2010;38(4):231-2.
12. Ho K and Segura J. (2007). Lower urinary tract calculi. Wein A, Kavoussi L, Novick A, Partin A, Peters C (Eds.). *Campbell-Walsh Urology* (p. 2662-73). Philadelphia, PA: Saunders Elsevier.
13. Maranna H, Hameed T, Lal P. A large ureteric calculus: Is there a role for open surgery in the modern era? *Int Surg J* 2019;6(10):3860-2.
14. Ozturk H, Dagistan E, Uyeturk U. A child with a large bladder stone: a case report. *Ped Urol Case Rep* 2014;1(4):22-8.
15. Isen K, Em S, Kilic V, et al. Management of bladder stones with pneumatic lithotripsy using a ureteroscope in children. *J Endourol.* 2008;22(5):1037-40.
16. Torricelli FC, Mazzucchi E, Danilovic A, et al. Surgical management of bladder stones: literature review. *Rev Col Bras Cir.* 2013;40(3):227-33.
17. Tugcu V, Polat H, Ozbay B, et al. Percutaneous versus transurethral cystolithotripsy. *J Endourol.* 2009;23(2):237-41.
18. Bhatia R, Hameed T, Lal P, et al. Evaluation of outcome of ureteroscopic pneumatic lithotripsy in single lower ureteric calculus and its association with CT parameters. *J Urol.* 2019;9(10):153-61.

A Case Report of a Novel Harm Reduction Intervention Used to Detect Opioid Overdose in the Emergency Department

Kraftin E. Schreyer, MD
Saloni Malik, MD, MPH
Andrea Blome, MD
Joseph L. D’Orazio, MD

Temple University Hospital, Department of Emergency Medicine, Philadelphia, Pennsylvania

Section Editor: Scott Goldstein, DO

Submission history: Submitted April 28, 2020; Revision received July 23, 2020; Accepted July 24, 2020

Electronically published September 18, 2020

Full text available through open access at http://escholarship.org/uc/uciem_cpem

DOI: 10.5811/cpcem.2020.7.47936

Introduction: As over 130 people die daily from opioid overdose in the United States, harm reduction strategies have become increasingly important. Because public restrooms are a common site for opioid overdose, emergency department waiting room restrooms (EDWRR) should be considered especially high-risk areas.

Case Report: We present the case of a patient found after a presumed opioid overdose in our EDWRR. Staff were alerted to his condition by a reverse motion detector (RMD), and rapidly treated him with naloxone.

Conclusion: The RMD is a novel intervention that can save lives and should be considered in EDs with a high incidence of opioid overdose. [Clin Pract Cases Emerg Med. 2020;4(4):548–550.]

Keywords: *Harm reduction; opioid use disorder; overdose; opioid overdose.*

INTRODUCTION

As over 130 people die daily from opioid overdose in the United States, healthcare facilities have an important role in treating patients with opioid use disorder (OUD).¹ These patients commonly present to emergency departments (ED) not only for acute overdoses, but also for a variety of health problems that are associated with substance use. Harm reduction techniques are becoming increasingly important in combating OUD. These “interventions aimed at reducing the negative effects of health behaviors without necessarily extinguishing the problematic health behaviors completely” can make a significant public health impact.² In the context of OUD, harm reduction techniques have targeted the negative consequences of opioid use, such as overdose and transmission of hepatitis C and human immunodeficiency virus infection, rather than opioid use itself.^{2,4} Such harm reduction strategies include syringe exchange, supervised consumption, bystander naloxone distribution, drug screening services, and opioid maintenance programs.^{2,3}

People who inject drugs, especially unsheltered individuals, frequently use public restrooms for the relatively

clean and private environment while also providing both good lighting and access to tap water.⁵ Overdoses, both fatal and non-fatal, commonly occur in public restrooms in places like restaurants, small businesses, and hospitals.⁵⁻⁷ While some patients with OUD enter EDs via ambulance or private vehicle after an overdose, some patients enter the ED waiting room for unrelated reasons, and subsequently may use drugs in an ED restroom while waiting to be seen by a provider. Reverse or anti-motion detectors (RMD) have been used successfully to reduce overdose deaths and the harm associated with OUD in the outpatient setting including clinics and supervised injection sites, but to our knowledge there are no reports of implementation in ED waiting room restrooms (EDWRR).^{5,8,9}

There has been an increase in drug-related ED visits from 3.19 per 1000 in 2017 to 7.69 per 1000 visits in 2018 in the City of Philadelphia.¹⁰ Our ED is located in the Kensington section of Philadelphia, which has been described as the “largest open-air narcotics market for heroin on the East Coast,” and saw the greatest number of nonfatal overdoses and the highest number of naloxone administrations in Philadelphia in 2018.^{10,11} An RMD medical alert system Alert1

(AlertOneServices, LLC, Williamsport, PA) was installed in one of our EDWRRs in May 2019.

We present the case of a patient found in our EDWRR after a suspected opiate overdose. Staff were alerted to the patient's condition by an RMD.

CASE REPORT

In August 2019, at approximately 6:30 PM, the RMD located in the EDWRR alarmed, prompting nursing, physician, and security staff to respond. A 27-year-old White male with past medical history of OUD and bipolar disorder was found lying on the floor of the restroom, unconscious, apneic, and cyanotic with pinpoint pupils. A syringe was noted to be lying on the floor next to the patient, and he later reported injecting while in the EDWRR.

An ED nurse then obtained intranasal naloxone from the ED Pyxis MedStation (Pyxis Corporation, San Diego, CA) and administered two milligrams intranasally. Within a minute, the patient had an improvement in mental status and respirations. He was observed for several minutes without clinical deterioration. Unfortunately, he refused further care and left the ED without further treatment or monitoring. He subsequently established care with our on-campus, office-based opioid treatment program and started on buprenorphine/naloxone. At the time of the overdose event, the patient was living on the street and using more than 10 bags of heroin per day. He has since relocated to live with his family and has been stable on buprenorphine/naloxone ever since. He last filled his prescription within a week of the writing of this case report.

DISCUSSION

This case report demonstrates that RMDs are effective at alerting staff to an unconscious patient in an EDWRR. The staff was able to respond quickly, reverse an opioid overdose with naloxone, and prevent significant morbidity and mortality. While some would argue that reversal of an opioid overdose with naloxone neither prevents a future overdose nor provides long-term treatment for OUD, this patient was able to survive the overdose event to later engage with recovery services. Harm reduction strategies like this are increasingly important during the opioid epidemic as more patients die annually from opioid overdose.

Our ED is a community affiliate of an academic institution that sees an annual volume of about 49,000 patients; 3.5% of visits have a primary diagnosis of non-fatal opioid overdose. On average, 4.8 patients per day present to this ED primarily for non-fatal opioid overdose. It is staffed by two attending physicians, seven nurses, and three security guards, and is equipped with six restrooms; two are located in the main ED waiting room area, two are located in the main ED, and two are located in the separate minor care section of the ED. Both EDWRRs are private, all-gender restrooms.

At our institution, costs for RMD equipment and installation totaled \$4,700 and installation took one week. The RMD is set on

CPC-EM Capsule

What do we already know about this clinical entity?

As over 130 people die daily from opioid overdose in the United States. Harm reduction strategies have become increasingly important.

What makes this presentation of disease reportable?

To our knowledge this is the first report of a reverse motion detector (RMD) used in an emergency department (ED) setting.

What is the major learning point?

The RMD is a novel intervention that can save lives and should be considered in EDs with a high incidence of opioid overdose.

How might this improve emergency medicine practice?

Installation of RMDs in EDs with a high incidence of opioid overdose is documented here to have saved a life, and may be cost-effective. Although false alarms are common, this novel intervention can save lives.

a timer to trigger when the door to the restroom is closed. After a total time of 120 seconds of no motion, an alarm activates. The alarm consists of both a loud sound and flashing lights. The sound can be heard throughout the ED, and the lights flash in the main ED, the triage area, and in the main waiting room. The alarm can only be turned off by using a key on a wall-mounted console located adjacent to the EDWRR where the RMD is installed. The alarm triggers an immediate response by at least one security guard, one nurse, and one physician to the EDWRR to determine whether further intervention is needed. Upon arrival at the EDWRR, staff knock and verbalize that the door will be opened, to make every effort to protect the privacy of the occupant.

In the first four months after installation, the RMD alarmed a total of 367 times. While each alarm did require the response of staff, the response time was brief. This presumably had no impact on the care of other patients in the ED during that time, because there were additional staff members in each of the response groups available to care for other patients. The most common cause of a false alarm was the EDWRR being closed without being occupied. The addition of signage in the waiting room and a mechanism to prop the door open reduced the frequency of false alarms.

While there is literature supporting the use of harm reduction techniques, including RMDs, in public restrooms,

to our knowledge this case report is the first evidence supporting the use of an RMD in an ED. In comparison to the cost of the RMD, the potential cost of morbidity and mortality associated with opioid overdose is much greater. Furthermore, this case illustrates the potential for a life-saving incident to begin the process of long-term recovery from OUD.

CONCLUSION

This case report suggests that reverse motion devices in ED waiting room restrooms can effectively alert staff to an unconscious patient with an opioid overdose. The RMD is a novel, cost-effective intervention that can save lives and should be considered in EDs located in areas with a high incidence of opioid overdose.

The authors attest that their institution requires neither Institutional Review Board approval, nor patient consent for publication of this case report. Documentation on file.

Address for Correspondence: Kraftin E. Schreyer, MD, Temple University Hospital, Department of Emergency Medicine, 1316 W. Ontario Street, 10th floor Jones Hall, Philadelphia, PA 19140. Email: Kraftin.schreyer@tuhs.temple.edu.

Conflicts of Interest: By the *CPC-EM* article submission agreement, all authors are required to disclose all affiliations, funding sources and financial or management relationships that could be perceived as potential sources of bias. The authors disclosed none.

Copyright: © 2020 Schreyer et al. This is an open access article distributed in accordance with the terms of the Creative Commons Attribution ([CC BY 4.0](http://creativecommons.org/licenses/by/4.0/)) License. See: <http://creativecommons.org/licenses/by/4.0/>

REFERENCES

- Centers for Disease Control and Prevention. Understanding the Epidemic. 2020. Available at: <https://www.cdc.gov/drugoverdose/epidemic/index.html>. Accessed December 27, 2019.
- Hawk M, Coulter RWS, Egan JE, et al. Harm reduction principles for healthcare settings. *Harm Reduct J*. 2017;14(1):70.
- Marshall BDL, Green TC, Yedinak JL, et al. Harm reduction for young people who use prescription opioids extra-medically: Obstacles and opportunities. *Int J Drug Policy*. 2016;31:25-31.
- Principles of Harm Reduction. Harm Reduction Coalition. Available at: <https://harmreduction.org/about-us/principles-of-harm-reduction/>. Accessed December 27, 2019.
- Fozouni L, Buchheit B, Walley AY, et al. Public restrooms and the opioid epidemic. *Subst Abuse*. 2019;1-5.
- Fadulu L. Is your local coffee shop a low-key opioid clinic? 2018. Available at: <https://www.theatlantic.com/health/archive/2018/09/opioid-crisis-service-workers/570778/>. Accessed December 2, 2019.
- Bebinger M. Public restrooms become central to the opioid epidemic. 2017. Available at: <https://www.npr.org/sections/health-shots/2017/05/08/526523520/public-restrooms-become-ground-zero-in-the-opioid-epidemic>. Accessed December 2, 2019.
- Freyer F. This doctor's workplaces: a bathroom, a van, and the streets. 2019. Available at: <http://www.advisory.com/daily-briefing/2019/01/24/overdose-van>. Accessed December 2, 2019.
- Knowles M. How a reverse motion detector helps a Boston physician save lives. 2019. Available at: <https://www.beckershospitalreview.com/opioids/how-a-reverse-motion-detector-helps-a-boston-physician-save-lives.html>. Accessed December 2, 2019.
- City of Philadelphia Department of Health. Substance Abuse Data Report. 2018. Available at: <https://www.phila.gov/media/20191126111554/Substance-Abuse-Data-Report-11.25.19>. Accessed December 30, 2019.
- Percy J. Trapped by the 'Walmart of Heroin'. 2018. Available at: <https://www.nytimes.com/2018/10/10/magazine/kensington-heroin-opioid-philadelphia.html>. Accessed November 1, 2019.

Case Report: A Near Miss of Pulmonary Embolism in a Division 1 Collegiate Basketball Player

Nicholas M. Chill, MD
Aaron J. Monseau, MD
Brenden J. Balcik, MD
Rosanna D. Sikora, MD,
Kathryn Oppenlander, MD

West Virginia University School of Medicine, Department of Emergency Medicine,
Morgantown, West Virginia

Section Editor: Rick A. McPheeters, DO

Submission history: Submitted April 25, 2020; Revision received July 27, 2020; Accepted July 24, 2020

Electronically published September 17, 2020

Full text available through open access at http://escholarship.org/uc/uciem_cpem

DOI: 10.5811/cpcem.2020.7.47887

Introduction: The clinical presentation of pulmonary embolism (PE) is often associated with classic vital instability such as tachycardia, hypoxia, and tachypnea. This critical diagnosis is often less likely if a patient is negative by Pulmonary Embolism Rule-Out Criteria (PERC) standards with a low pre-test probability of disease. Caution must be used when evaluating elite athletes with the PERC rule due to low resting heart rate and certain risk factors, which are inherent to athletics.

Case Report: We report the case of a 20-year-old male Division 1 collegiate athlete with pleuritic chest pain diagnosed with PE despite being PERC negative. His presenting heart rate (HR) of 79 beats per minute was correctly determined to be tachycardic relative to his resting HR of 47-60 beats per minute. Despite his PERC negative status, PE was found after an elevated D-dimer and subsequent computed tomography angiography.

Conclusion: Special consideration should be used when evaluating elite athletes for PE, as their resting physiology may differ from the general population. Additionally, certain risk factors for thromboembolic disease are inherent in competitive athletics and should be considered during an initial risk assessment. The presented patient was successfully treated with oral anticoagulation for three months and was able to return to play. [Clin Pract Cases Emerg Med. 2020;4(4):551–554.]

Keywords: *pulmonary embolism; athlete; PERC.*

INTRODUCTION

Pulmonary embolism (PE) is a leading cause of morbidity and mortality worldwide with an estimated 60,000-100,000 deaths per year. It is often associated with chronic and acute medical conditions, recent surgeries, malignancy, obesity, and known thrombophilia.^{1,2} A well-conditioned athlete may not fit this classic image, but the nature of competitive athletics exposes them to certain thrombogenic risk factors. With a wide range of presenting symptoms and severity, PE can be a difficult clinical diagnosis. Risk stratification is the initial step in the evaluation for a PE and can be performed using clinical decision rules such as the Wells Criteria or clinician gestalt.³

Once the patient is determined to be low risk for PE, the Pulmonary Embolism Rule-Out Criteria (PERC) rule is an effective tool for helping physicians determine the need for further workup and imaging in cases where PE may be considered. The PERC rule is meant to be applied to patients already determined to be low risk for PE and consists of the following eight, easily obtainable, objective measurements and historical factors: age <50; heart rate <100 beats per minute; pulse oximetry >94% at room air; no use of exogenous estrogen; no prior history of venous thromboembolism (VTE); no recent surgery or trauma requiring intubation or hospitalization in the prior four weeks; no unilateral leg swelling.⁴ The PERC rule is 97% sensitive when used appropriately, and can decrease

unnecessary testing and ionizing radiation.^{4,5} Caution must be used when applying these criteria to elite athletes whose physiology may differ from that of the general population. We discuss the case of a PERC negative, otherwise healthy athlete who was diagnosed with PE, as well as some common diagnostic pitfalls in this patient population.

CASE REPORT

A 20-year-old Black male, Division 1 collegiate basketball player presented to a student health urgent care clinic with an insidious two-day history of complaint of dry cough, sore throat, and myalgias, as well as chest pain starting one day prior to evaluation. He described his chest pain as an “achy pressure,” radiating down his right arm, intermittent and worse with deep inspiration and laying supine. He denied smoking cigarettes or marijuana but did vape frequently. He had no recent injury, chest exercises, or concern for musculoskeletal injury, or history of deep vein thrombosis (DVT) or PE. The most recent airplane flight was approximately three hours long and greater than six weeks prior to presentation. He had no leg swelling. He had a remote history of right knee arthroscopic meniscus repair seven months prior. He had a history of acid reflux controlled through diet. His vital signs were normal (pulse 79 beats per minute, blood pressure 111/88 millimeters of mercury, respiratory rate 15 breaths per minute, temperature 36.8° Celsius, oxygen saturation 99%). Due to concern for cardiopulmonary pathology, he was sent to the emergency department (ED) for further evaluation.

On arrival to the ED, his vital signs were again normal. He appeared acutely ill and in mild distress. There was no edema to the lower extremities and he did not report leg pain to the emergency providers. His physical exam was otherwise unremarkable. Complete blood count, basic metabolic panel, and troponin were found to be within normal limits. Additional lab work included elevated D-dimer of 592 nanograms (ng) per milliliter (mL) (normal <232 ng/mL). A D-dimer was ordered because of the patient’s status as an athlete. PERC may not have applied due to concern that his presenting heart rate may have been above his baseline. Electrocardiogram and plain chest radiography at the time were normal. A point-of-care echocardiogram showed no evidence of right heart strain and no pericardial effusion.

Given his concerning presentation and abnormal lab work, computed tomography (CT) angiography of the chest was performed demonstrating PE involving the right posterior basal segmental pulmonary artery with associated hemorrhage vs developing pulmonary infarct (Image). He was started on heparin infusion and admitted for further evaluation. After diagnosis of PE was made, the admitting hospitalist noted that there was tenderness along his posterior knee and distal thigh, as well as pain with active and passive range of motion of his knee. These exam findings were not noted in the initial provider’s documentation.

CPC-EM Capsule

What do we already know about this clinical entity?

Pulmonary embolism (PE) is a critical diagnosis with high morbidity and mortality. Clinical decision tools are available to reliably assess pretest probability.

What makes this presentation of disease reportable?

Based off of history and physical exam, the presented patient may fall into the low-risk category for PE.

What is the major learning point?

Heart rate is factored into clinical decision tools for PE, but this may be an unreliable metric when evaluating an elite athlete.

How might this improve emergency medicine practice?

Knowing inherent risk factors within competitive athletics and understanding athlete physiology can help raise a provider’s suspicion for PE.

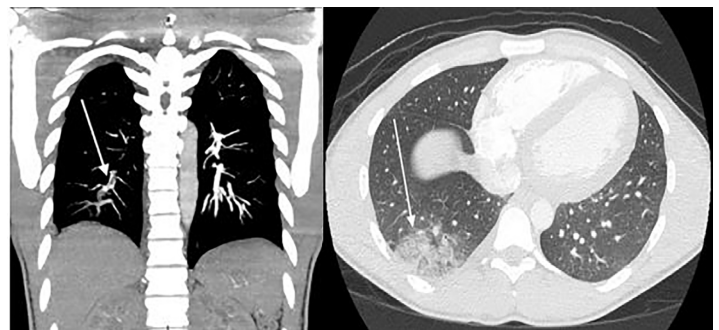

Image. Computed tomographic angiography of the chest in coronal (left) and axial (right) views. Arrows point to pulmonary embolism involving the right posterior basal segmental pulmonary artery (left) and associated hemorrhage versus developing pulmonary infarct (right).

During his hospital course he underwent venous duplex imaging, which was negative for lower extremity DVT, and transthoracic echocardiogram was normal. His oxygen saturations remained above 97% and his highest documented heart rate was 79 beats per minute. His hypercoagulability workup was negative except for equivocal lupus

anticoagulant. No clear provoking factors were identified, as his surgery was over six months prior to presentation, and he had no recent team flights or travel in the prior one month. His chest pain and shortness of breath improved on day two of his hospital stay. He was transitioned to apixaban for anticoagulation and discharged home with precautions not to participate in contact sports.

At his three-month follow-up with hematology/oncology, he was found to have a persistently elevated D-dimer and underwent repeat CT angiography of his chest. The CT showed focal right lower lobe opacity consistent with scarring but no residual PE. He was no longer experiencing chest pain or shortness of breath. Additional hypercoagulability workup including protein C, S, and cardiolipin antibody, and beta-2 glycoprotein was negative as well. The PE was ultimately determined to be provoked from either his airplane travel six weeks prior or his arthroscopic meniscus repair seven months prior. He was taken off of anticoagulation and cleared for participation in contact sports. He was instructed to take 81 milligrams aspirin on days of team travel if on a bus or plane. He was able to make a full recovery and returned to competitive Division I basketball.

DISCUSSION

PE is a critical, potentially life-threatening diagnosis in which a failure to identify may lead to catastrophic morbidity or mortality. Although athletes are typically thought to be lower risk for thromboembolic disease given their elevated activity levels and perception of peak physical fitness, they are often exposed to thrombogenic risk factors that have been shown to make them more susceptible.⁶ Virchow's triad classically reduces VTE risk factors into three broad categories: hypercoagulability; endothelial damage; and venous stasis.⁷ Athletes are subject to risk factors in all three categories.

Extensive travel and limb immobilization secondary to injury can result in hemostasis. Dehydration and subsequent hemoconcentration following extensive physical exertion can lead to hypercoagulability. Musculoskeletal trauma and surgical intervention from injuries can cause endothelial damage.^{6,7} Additionally, Paget-Schroetter syndrome is a cause of effort-related thrombosis in athletes with repetitive overhead motion. With this condition, external rotation of the upper extremity can cause subclavian vein compression between the clavicle and first rib, leading to microtrauma of the endothelium, as well as stasis.^{8,9} A combination of the aforementioned circumstances contributed to a total of 55 cases of VTE within professional sports in the United States between 1999–2016, with PE present in 15 of those.¹⁰ In the case of the presented athlete, PE was suspected to have been provoked from either his airplane travel six weeks prior or his meniscus repair seven months prior.

When evaluating the general population, the PERC has shown to be a valuable tool in reducing unnecessary imaging and ionizing radiation.⁵ However, caution must be used when

applying these criteria to elite athletes who have been shown to have lower-than-average resting heart rates.¹¹ This caution should be extended to any patient with possible lower resting heart rates from other causes. For example, a patient on a beta blocker may have a blunted tachycardic response to a PE.¹² It is well known that sinus tachycardia is one of the most common presenting signs in PE. This is reflected in the PERC criteria, which uses greater than 99 beats per minute as a cutoff. The presented athlete's resting heart rate ranged from 47–60 beats per minute during hospitalization and at outpatient follow-up appointments. His presenting heart rate of 79 beats per minute was an outlier and was correctly interpreted as relative tachycardia. When analyzing this patient using PERC criteria, his total score was zero, which precluded any further testing for PE.

Had the attending physician not recognized relative tachycardia, deemed this patient as moderate risk and subsequently ordered D-dimer for further evaluation, the diagnosis of PE might have been missed given his otherwise negative workup. An argument can be made that since he did not report any symptoms of DVT initially he could have been deemed low risk and the PERC rule could have been applied. He would have been PERC negative, a D-dimer would not have been ordered, and the diagnosis of PE would have been missed. While the Wells Criteria score is often used as an objective measure for risk stratification in PE, it is also prone to error in a patient population that may not have a normal physiologic response when compared to the general population, such as relative tachycardia. This underscores the importance of understanding these clinical decision rules as well as the patient's baseline physiology.

While the PERC rule is often praised for its ease of use with objective measurements, it must be restated that it should only be applied to a low-risk population. It is up to the provider to determine whether the patient falls into the low-risk population, which remains a largely subjective decision using the Wells Criteria or clinician gestalt. With the classic association between VTE and inactivity, obesity, and chronic medical conditions, athletes may be at risk of a missed diagnosis, as they are often perceived as lowest risk due to their cardiovascular health and fitness.

CONCLUSION

Pulmonary embolism can be an elusive diagnosis but should be considered frequently due to the potential for significant morbidity and mortality. It is a misconception that a healthy, well-appearing athlete is devoid of risk factors for VTE, as the inherent nature of competitive athletics exposes individuals to conditions that may promote thrombosis. Additionally, vital signs that may appear normal for a typical patient may be abnormal in an athlete with high physiologic reserve. Clinical decision rules are excellent tools for ruling out PE when used appropriately, but some pitfalls remain when evaluating elite athletes.

The Institutional Review Board approval has been documented and filed for publication of this case report.

Address for Correspondence: Nicholas M. Chill, MD, West Virginia University School of Medicine, Department of Emergency Medicine, PO Box 9149, Robert C. Byrd Health Sciences Center, Morgantown, WV 26506. Email: nchill@hsc.wvu.edu.

Conflicts of Interest: By the *CPC-EM* article submission agreement, all authors are required to disclose all affiliations, funding sources and financial or management relationships that could be perceived as potential sources of bias. The authors disclosed none.

Copyright: © 2020 Chill et al. This is an open access article distributed in accordance with the terms of the Creative Commons Attribution ([CC BY 4.0](https://creativecommons.org/licenses/by/4.0/)) License. See: <http://creativecommons.org/licenses/by/4.0/>

REFERENCES

1. Heit JA, Spencer FA, White RH. The epidemiology of venous thromboembolism. *J Thromb Thrombolysis*. 2016;41(1):3-14.
2. Guasch E, Mont L, Sitges M. Mechanisms of atrial fibrillation in athletes: what we know and what we do not know. *Neth Heart J*. 2018;26(3):133-45.
3. Wells PS, Anderson DR, Rodger M, et al. Excluding pulmonary embolism at the bedside without diagnostic imaging: management of patients with suspected pulmonary embolism presenting to the emergency department by using a simple clinical model and D-dimer. *Ann Intern Med*. 2001;135(2):98-107.
4. Kline JA, Courtney DM, Kabrhel C, et al. Prospective multicenter evaluation of the pulmonary embolism rule-out criteria. *J Thromb Haemost*. 2008;6(5):772-80.
5. Buchanan I, Teeple T, Carlson M, et al. Pulmonary embolism testing among emergency department patients who are pulmonary embolism rule-out criteria negative. *Acad Emerg Med*. 2017;24(11):1369-76.
6. Casals M, Martínez JA, Caylà JA, et al. Do basketball players have a high risk of pulmonary embolism? A scoping review. *Med Sci Sports Exerc*. 2016;48(3):466-71.
7. Grabowski G, Whiteside W, Kanwisher M. Venous thrombosis in athletes. *J Am Acad Orthop Surg*. 2013;21(2):108-17.
8. Meyering C and Howard T. Hypercoagulability in athletes. *Curr Sports Med Rep*. 2004;3(2):77-83.
9. Zell L, Kinderman W, Marschall F, et al. Paget-Shroetter syndrome in sport activities: case study and literature review. *Angiology*. 2001;52(5):337-42.
10. Bishop M, Astolfi M, Padegimas E, et al. Venous thromboembolism within professional American sport leagues. *Orthopaed J Sports Med*. 2017;5(12):1-9
11. Fagard RH. Impact of different sports and training on cardiac structure and function. *Cardiol Clin*. 1992;10(2):241-56.
12. Bajaj N, Bozarth AL, Guillot J, et al. Clinical features in patients with pulmonary embolism at a community hospital: analysis of 4 years of data. *J Thromb Thrombolysis*. 2014;37(3):287-92.

Ureteral Stone Mimics Appendicitis: A Point-of-care Ultrasound Case Report

Cindy Shavor, MD*
Justine Pagenhardt, MD*
YuanYuan Sun, MD*
Clara Kraft, MD*
Bradley End, MD*†
Joseph Minardi, MD*†

*West Virginia University School of Medicine, Department of Emergency Medicine,
Morgantown, West Virginia

†West Virginia University School of Medicine, Department of Medical Education,
Morgantown, West Virginia

Section Editor: Rick A. McPheeters, DO

Submission history: Submitted May 12, 2020; Revision received July 30, 2020; Accepted July 24, 2020

Electronically published October 5, 2020

Full text available through open access at http://escholarship.org/uc/uciem_cpem

DOI: 10.5811/cpcem.2020.7.48155

Introduction: Abdominal pain is a common complaint in the emergency department. Point-of-care ultrasound (POCUS) is a rapid modality to evaluate for the etiology.

Case Report: A teenage male presented with symptoms concerning for appendicitis. POCUS revealed a non-peristalsing, non-compressible, tubular structure containing an echogenic stone. This was determined to be a ureteral stone within a dilated ureter, not appendicitis.

Conclusion: We propose a syndromic sonographic approach to right lower quadrant pain (RLQ) that includes the gallbladder, right kidney, bladder, and right adnexa, in addition to RLQ landmarks. This case emphasizes the value of such an approach to avoid diagnostic error. [Clin Pract Cases Emerg Med. 2020;4(4):555–558.]

Keywords: *Point-of-care; syndromic approach; appendicitis; ureteral stone; case report.*

INTRODUCTION

Abdominal pain is a common presenting symptom for pediatric patients in the emergency department (ED). Pediatric patients or intellectually disabled patients can be challenging to care for due to their limited ability to explain symptoms, localize pain, and collaborate for a thorough exam.¹ Even when a pediatric patient is able to localize pain, multiple diagnoses could be possible. A prime example is the complaint of right lower quadrant (RLQ) pain. Appendicitis is the most common surgical concern to rule out in the pediatric population. However, other diagnoses including intussusception, ovarian pathology, and inflammatory bowel disease such as Crohns must be considered.^{2,3} Selecting an imaging modality to safely and quickly evaluate patients is important.⁴ Ultrasound is a fast, inexpensive, and safe imaging technique that avoids radiation exposure in the pediatric patient.^{5,6}

CASE REPORT

A 17-year-old male presented to the ED with complaints of RLQ abdominal pain. He reported that the pain began a few hours prior to presentation to the ED. Associated symptoms included nausea and subjective fevers. Vital signs showed an elevated heart rate of 106 beats per minute and elevated blood pressure of 130/90 millimeters of mercury (mm Hg). He was afebrile without any increased work of breathing and normal oxygen saturation on room air. He was in no acute distress. Abdominal exam revealed positive bowel sounds and isolated RLQ tenderness without peritoneal signs. There was no suprapubic tenderness or costovertebral angle tenderness noted. The remainder of his examination was unremarkable.

Laboratory results showed a normal white blood cell count, normal C-reactive protein, and normal creatinine. A focused RLQ point-of-care ultrasound (POCUS) evaluating for appendicitis was performed. During the scan, a

hyperechoic circular focus with acoustic shadowing was noted to be within a hypoechoic, non-peristalsing, non-compressible, tubular structure adjacent to the iliac vessels (Images 1-3). This was not the typical sonographic appearance of an infected appendix as there was no surrounding mesenteric fat stranding, free fluid, or hyperemia. Additionally, the walls of the tubular structure were thinner and did not have the alternating layered appearance typical of intestinal structures.

Because the clinical and sonographic findings were discordant, a computed tomography (CT) was performed confirming the suspicion that the finding in the RLQ was a large, 11-mm obstructing ureteral stone with hydronephrator and hydronephrosis.

The patient was treated supportively with intravenous fluids and pain control and was admitted to the hospital. The patient underwent cystoscopy with placement of ureteral stent. He was discharged and later returned for stent replacement, lithotripsy, and stone extraction. The patient recovered without any noted complications.

DISCUSSION

Ultrasound evaluation for RLQ pain is a common modality to diagnose appendicitis. Typical appearance of an inflamed appendix is a blind-ending, tubular, non-compressible structure without peristalsis that is greater than 6 mm in diameter. Other features include possible surrounding fluid, appendicolith, hyperemia of the bowel wall, inflamed surrounding mesenteric fat and lymphadenopathy.¹ A dilated ureter is also a tubular, non-compressible structure without peristalsis. The ureter will typically appear as a thin-walled structure, whereas, the appendix has a multi-layered appearance. Often, an inflamed appendix will have a wall that appears thick due to the loss of definition of the layers. A ureteral stone may not look significantly different than an appendicolith. Because of these features, it would be possible for a physician to mistake these findings for those of acute appendicitis.

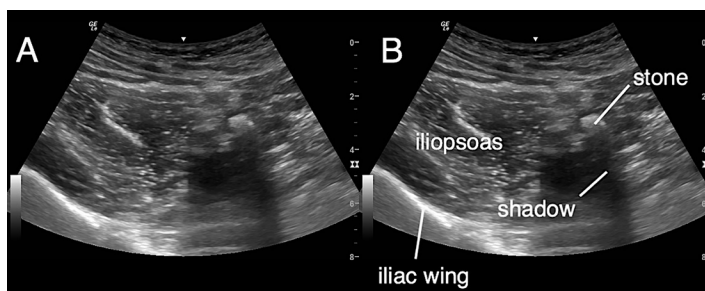


Image 1. Ultrasound right lower quadrant (RLQ), short axis, curvilinear probe. The landmarks of a RLQ ultrasound can be noted in short axis using the curvilinear probe with the iliac wing and iliopsoas muscle in view. Medial to the iliopsoas a hyperechoic focus representing a stone with acoustic shadowing is noted.

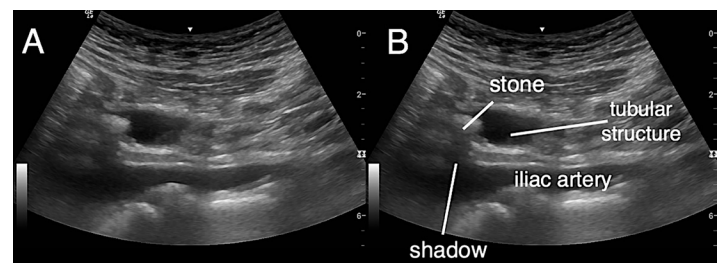


Image 2. Ultrasound right lower quadrant, long axis, curvilinear probe. A hyperechoic circular focus with acoustic shadowing is noted within a hypoechoic, non-peristalsing, non-compressible, tubular structure superior to the iliac vessels. A ureteral stone is identified as a hyperechoic structure, which demonstrates acoustic shadowing within the dilated ureter.

CPC-EM Capsule

What do we already know about this clinical entity?

Point-of-care ultrasound (POCUS) is used to diagnose appendicitis and renal stones. Variations of pathology can mimic other syndromes leading to error.

What makes this presentation of disease reportable?

The uncommon presentation of a ureteral stone in the right lower quadrant could be easily mistaken for acute appendicitis leading to incorrect treatment.

What is the major learning point?

A ureteral stone may mimic the appearance of acute appendicitis. A systematic syndromic approach to POCUS can aid in rapid, accurate diagnosis.

How might this improve emergency medicine practice?

Recognizing the distinguishing factors between related pathologies on POCUS can limit medical errors.

The incidence of renal stones has been increasing in pediatric patients.⁷ CT is becoming more commonplace as an evaluation modality to assess for renal stones in these patients. It is important to limit radiation exposure, especially in the pediatric population, as younger patients have a longer lifetime risk of malignancy related to radiation

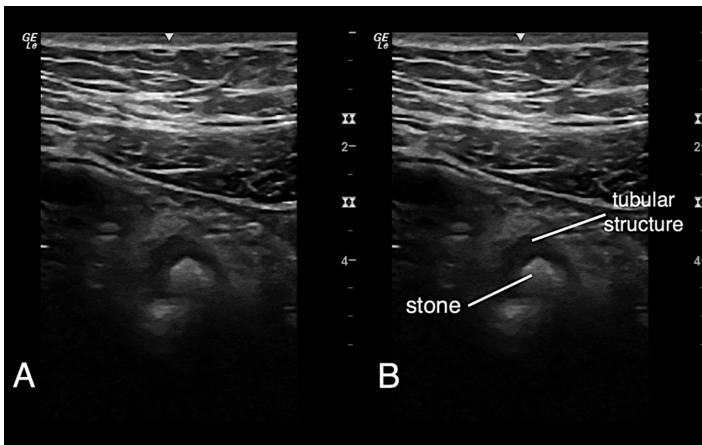


Image 3. Ultrasound right lower quadrant, short axis, high frequency linear probe. A hyperechoic circular object is noted within a hypoechoic tubular structure. The hyperechoic object is a ureteral stone noted within a dilated ureter.

exposure through repeated examinations during their lives. CT is considered the gold standard for the diagnosis of renal stones in adults; however, it is advisable to employ strategies that limit this radiation exposure in children.⁶ Ultrasound also has the additional advantages including availability and lower cost. A study by Passerotti et al prospectively evaluated the ability of ultrasound to detect renal stones when compared to CT. In the study, ultrasound was found to have a 76% sensitivity and 100% specificity. The stones that were missed by ultrasound but identified by CT were on average 2.3 mm.⁸

While acute appendicitis is the most common surgical cause of RLQ pain, the spectrum of disease and differential diagnosis is quite broad and includes many etiologies that might be evaluated with a thoughtful, systematic, syndromic approach to the POCUS examination. Rather than focusing on a single organ or organ system, a syndromic POCUS is complaint based and may include multiple organ systems. The focused assessment with sonography in trauma (FAST) exam is likely the most common example. Another example may include evaluating the renal system as well as the aorta in an older patient with flank pain. In a review article, Chang, Schooler and Lee discuss the errors of diagnosing pathologic conditions in children who present with RLQ pain. They urged the consideration of etiologies beyond acute appendicitis: 1) congenital causes such as gastrointestinal duplication systems, Meckel's diverticulum, and urachal abnormalities; 2) other inflammatory or infectious causes such as Crohn's colitis, ulcerative colitis, Henoch-Schönlein purpura, mesenteric adenitis, omental infarction, and pelvic inflammatory disease; 3) neoplastic causes such as colonic polyps, ovarian masses, and lymphoma; and 4) other genitourinary causes such as pyelonephritis, ovarian

torsion, ovarian cysts, endometriosis, and renal stones. Many of these conditions in the pediatric population are initially evaluated with ultrasound studies.⁹

A few case reports similarly discuss the initial evaluation of RLQ pain for appendicitis that revealed alternate pathology. One such case report discussed the use of ultrasound to diagnose a torn rectus abdominus muscle.¹⁰ The other case report described a patient with RLQ ultrasound that showed a tubular, non-peristalsing structure with a target appearance on short axis. This case was presumed to be appendicitis and the patient was taken for surgical intervention. Ultimately, the appendix was normal, and a torsed Meckel's diverticulum was discovered. The RLQ ultrasound had identified the cause, which was misinterpreted as an inflamed appendix.¹¹

There is value in discussing systematic syndromic ultrasound focused on a complaint-based evaluation rather than an organ-based approach. This necessitates evaluating multiple anatomic structures in the region of concern to systematically rule in or out pathological findings. This case was discussed with senior clinical ultrasound faculty at a joint case review focused on quality improvement in scanning technique and education. Anecdotally, another senior physician reported a similar case of hydronephrosis detected when initially scanning a pediatric patient with another diagnosis in mind. With this occurrence, we recommend scanning other potential areas of interest based on the patient's clinical history, physical examination, and laterality of pain. For instance, this patient was having RLQ pain; scanning the gallbladder, right kidney, bladder, right adnexa, and right lower quadrant (Video) would have identified the right hydronephrosis and added further insight into the initial ultrasound finding in the RLQ of a hyperechoic object within a tubular structure.

CONCLUSION

We present an ultrasound case of ureteral stone mimicking not only the symptoms, but also the sonographic findings of acute appendicitis. Nephrolithiasis, ureteral stones, and appendicitis are common diagnoses in the ED. With a thoughtful clinical approach and more systematic, syndromic POCUS, an accurate, timely diagnosis was made. A broad differential should be considered in the evaluation of RLQ pain, with a POCUS examination focused on high yield, relevant anatomical areas including multiple, right-sided organs including the gallbladder, right kidney, appendix, and right adnexa.

Video. Ultrasound right lower quadrant noting the various views and landmarks utilized to identify a ureteral stone within a dilated ureter.

The Institutional Review Board approval has been documented and filed for publication of this case report.

Address for Correspondence: Justine Pagenhardt, MD, West Virginia University School of Medicine, Department of Emergency Medicine, 1 Medical Center Drive, Morgantown, WV 26506. Email: jpagenha@hsc.wvu.edu.

Conflicts of Interest: By the CPC-EM article submission agreement, all authors are required to disclose all affiliations, funding sources and financial or management relationships that could be perceived as potential sources of bias. The authors disclosed none.

Copyright: © 2020 Shavor et al. This is an open access article distributed in accordance with the terms of the Creative Commons Attribution (CC BY 4.0) License. See: <http://creativecommons.org/licenses/by/4.0/>

REFERENCES

1. Fonio P, Coppolino F, Russo A, et al. Ultrasonography (US) in the assessment of pediatric non traumatic gastrointestinal emergencies. *Crit Ultrasound J*. 2013;5(Suppl 1):S12.
2. Nelson MJ, Paterson T, Raio C. Case report: transient small bowel intussusception presenting as right lower quadrant pain in a 6-year-old male. *Crit Ultrasound J*. 2014;6(1):1-4.
3. Purysko AS, Remer EM, Filho HML, et al. Beyond appendicitis: common and uncommon gastrointestinal causes of right lower quadrant abdominal pain at multidetector CT. *Radiographics*. 2011;31(4):927-47.
4. Collieran GC, Callahan MJ, Paltiel HJ, et al. Imaging in the diagnosis of pediatric urolithiasis. *Pediatr Radiol*. 2017;47(1):5-16.
5. Rahim AFA, Halim ZNA, Pusppanathan J, et al. An overview of ultrasound testing for lesion detection in human kidney. *J Tomogr Syst Sensor Appl*. 2018;1(1):29-34.
6. Morrison JC, Kawal T, Batavia JP, et al. Use of ultrasound in pediatric renal stone diagnosis and surgery. *Curr Urol Rep*. 2017;18(3):22.
7. Tasian GE, Ross ME, Song L, et al. Annual incidence of nephrolithiasis among children and adults in South Carolina from 1997 to 2012. *Clin J Am Soc Nephrol*. 2016;11(3):488-96.
8. Passerotti C, Chow JS, Silva A, et al. Ultrasound versus computerized tomography for evaluating urolithiasis. *J Urol*. 2009;182(4 Suppl):1829-34.
9. Chang PT, Schooler GR, Lee EY. Diagnostic errors of right lower quadrant pain in children: beyond appendicitis. *Abdom Imaging*. 2015;40(7):2071-90.
10. Minardi J, Shaver E, Monseau A, et al. Right lower quadrant pain in a young female: ultrasound diagnosis of rectus abdominis tear. *J Emerg Med*. 2015;49(5):623-6.
11. Choi J, Dorinzi N, Pagenhardt J, et al. Sonographic detection of a torsed Meckel's diverticulum misinterpreted as acute appendicitis. *Clin Pract Cases Emerg Med*. 2019;3(3):278-81.

Ruptured Ectopic Pregnancy with an Intrauterine Device: Case Report and Sonographic Considerations

Derick D. Jones, MD, MBA*†
Tobias Kummer, MD*
Jessica C. Schoen, MD, MS*†

*Mayo Clinic, Department of Emergency Medicine, Rochester, Minnesota
†Mayo Clinic Health System Albert Lea and Austin, Department of Emergency
Medicine, Austin, Minnesota

Section Editor: Rick A. McPheeters, DO

Submission history: Submitted May 17, 2020; Revision received July 17, 2020; Accepted July 24, 2020

Electronically published October 20, 2020

Full text available through open access at http://escholarship.org/uc/uciem_cpchem

DOI: 10.5811/cpchem.2020.7.48258

Introduction: Ectopic pregnancy carries a high morbidity and mortality; patients are at risk for rupture and life-threatening hemorrhage.

Case Report: We present a rare case of ruptured abdominal ectopic pregnancy in a patient with a well-positioned intrauterine device (IUD) and discuss the diagnostic utility that transabdominal point-of-care ultrasound (POCUS) can have when performed at the bedside.

Conclusion: While pregnancy with an IUD in place is rare, when it is encountered the emergency provider should maintain a high degree of suspicion for extrauterine pregnancy and perform prompt evaluation for hemorrhagic shock using diagnostic POCUS. [Clin Pract Cases Emerg Med. 2020;4(4):559–563.]

Keywords: *ectopic pregnancy; point-of-care ultrasound; intrauterine device.*

INTRODUCTION

In the general population, the incidence of ectopic pregnancy is estimated at 2%.^{1,2} However, among patients presenting to the emergency department (ED) with complaints of first-trimester abdominal pain, vaginal bleeding, or both, the prevalence of ectopic pregnancy is significantly higher, ranging from 6-16%.¹⁻⁴ Ectopic pregnancy continues to confer significant maternal risk with ruptured ectopic pregnancies accounting for approximately 3% of maternal deaths.⁵

There are a variety of effective contraceptive methods available including female or male sterilization, oral contraceptive pills, long-acting reversible contraceptives, and male condoms.⁶ From 2015 to 2017, approximately 10% of women in the United States aged 15-49 who used contraception reported using long-acting reversible contraceptives (including contraceptive implants and intrauterine devices [IUD]).⁶ In the case of contraceptive failure, current IUD use significantly increases the risk for ectopic pregnancy when compared to other contraceptive methods. In a case-control study by Li et al, the risk of ectopic pregnancy was approximately four-fold higher for current oral contraceptive users and more than

20-fold higher in current IUD users compared to women currently not using contraception.⁷ Additionally, IUD use increases the risk that an ectopic pregnancy will implant at a more distal site.⁸ In their study population, Bouyer et al found that ectopic pregnancies that occurred with an IUD in place more frequently implanted in distal sites including the ovary (5%) and abdomen (2%). (Overall rates of implantation in the ovary and the abdomen were 3.2% and 1.3%, respectively.)⁸

Ruptured ectopic pregnancy is potentially life threatening. Therefore, the emergency provider needs to maintain a high index of suspicion in the right clinical setting. Point-of-care ultrasound (POCUS) is commonly used to assist in the diagnosis and management of a variety of conditions, including ectopic pregnancy.⁹⁻¹² Here, we present a case of a ruptured abdominal ectopic pregnancy in a 21-year-old female with an IUD, diagnosed by POCUS in the ED.

CASE REPORT

A healthy 21-year-old female presented to the local community ED for evaluation of syncope and abdominal pain. She had been evaluated at the local urgent care three days

prior, complaining of constipation and was discharged with a prescription for lactulose. The following day she developed abdominal cramping and several near-syncope spells. The day of presentation, the patient took a dose of lactulose and then developed sudden onset diarrhea and worsening abdominal pain. While seated on the toilet, she suffered a brief syncopal episode without associated trauma. She reported that her last menstrual period was one month prior and that she had a levonorgestrel IUD in place for contraception. She reported no fever, vomiting, or vaginal bleeding.

On arrival in the ED, the patient was awake, alert, and in no distress. Vital signs included a temperature of 36.5° Celsius, heart rate of 84 beats per minute, blood pressure of 78/64 millimeters of mercury (mm Hg), respiratory rate of 18 breaths per minute, and oxygen saturation of 100% on room air. On examination, her abdomen was soft and mildly distended with diffuse tenderness to palpation; she had no guarding. The patient was maintained on a cardiac monitor, and a peripheral intravenous line was established. She was resuscitated with one liter normal saline bolus and her blood pressure improved to 101/55 mm Hg. Initial laboratory evaluation revealed anemia: hemoglobin 7.9 grams (g) per deciliter (dL) (reference [ref] range: 12.0-15.5 g/dL) and hematocrit 23.4% (ref range: 34.9-44.5%). Her electrolytes, blood glucose, and lactate were unremarkable.

The patient's abdominal pain, unexplained anemia, and history of syncope raised concern for hemoperitoneum. POCUS was notable for free fluid in the hepatorenal recess (Morison's pouch) in the right upper quadrant (Image 1). Transabdominal point-of-care pelvic ultrasound demonstrated an IUD, but no visible intrauterine pregnancy (IUP) (Image 2). Subsequently, the urine pregnancy test result returned and was positive.

The obstetric physician on-call was consulted, evaluated the patient in the ED, reviewed the POCUS

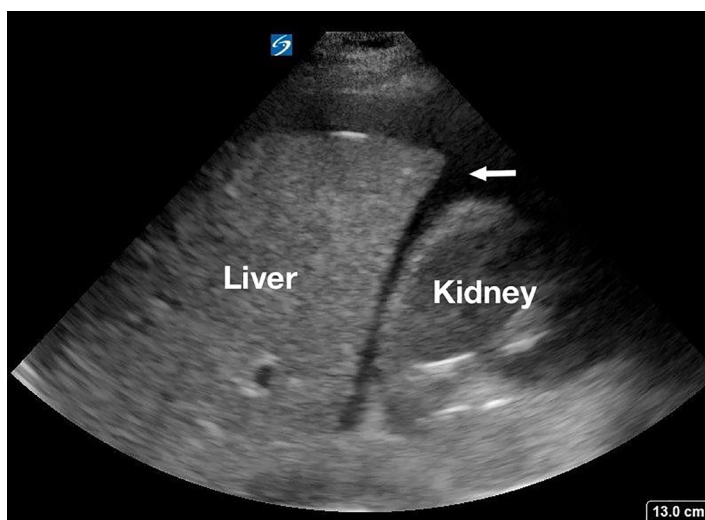

Image 1. Point-of-care ultrasound of the right upper quadrant of the abdomen demonstrating free fluid in Morison's pouch (arrow).

CPC-EM Capsule

What do we already know about this clinical entity?

Given the significant morbidity and mortality associated with ectopic pregnancy, a high index of suspicion must be maintained. The diagnosis can be challenging.

What makes this presentation of disease reportable?

We present a rare case of ruptured abdominal ectopic pregnancy in a patient with a well-positioned intrauterine device.

What is the major learning point?

When ectopic pregnancy is suspected, an empty uterus and free fluid in Morison's pouch visualized with ultrasound are highly specific for ruptured ectopic pregnancy.

How might this improve emergency medicine practice?

Performing diagnostic point-of-care ultrasound when there is suspicion for extrauterine pregnancy can decrease unnecessary or dangerous delays in treatment.

images, and requested comprehensive transvaginal (TV) ultrasound (Image 3). This demonstrated a 10-centimeter heterogeneous mass posterior to the uterus, moderate free fluid in the pelvis, and no evidence of intrauterine pregnancy (IUP) or adnexal abnormality. The IUD was noted to be in good position in the endometrial canal. In consultation with the obstetrician, because these findings raised concern for alternate pathology (such as malignancy) that might require subspecialty care, the decision was made to transfer the patient to the regional tertiary care center for definitive management. Repeat hemoglobin was 6.2 g/dL (ref range: 12.0-15.5 g/dL). Transfusion with one unit of packed red blood cells was initiated, and she was transferred via air ambulance.

On arrival to the referral ED, she was hemodynamically stable with a blood pressure of 119/54 mm Hg and a heart rate of 82 beats per minute. She was evaluated by gynecologic surgery and promptly taken to the operating room. She was noted to have extensive hemoperitoneum and organized clot posterior to the uterus. Once removed, the site of the ectopic pregnancy appeared to be abdominal in the posterior cul de sac medial to the left uterosacral ligament and lateral to the rectum. This was excised and later confirmed by pathology.

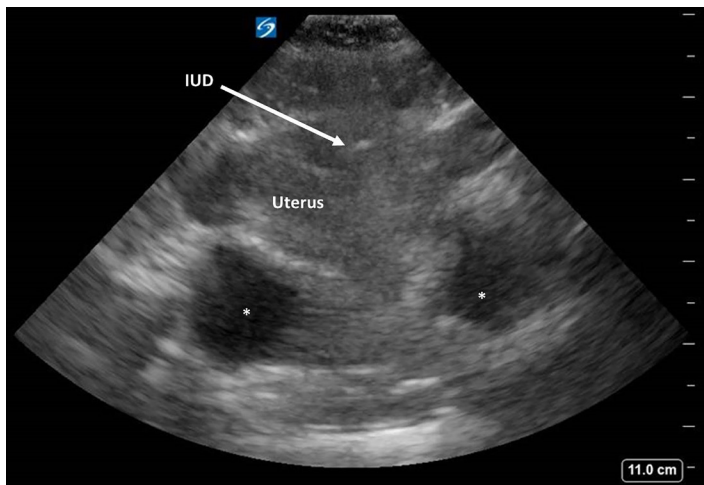


Image 2. Transabdominal point-of-care ultrasound of the pelvis demonstrating an intrauterine device within the uterus (arrow), no evidence of intrauterine pregnancy, and free fluid posterior to the uterus (asterisks).

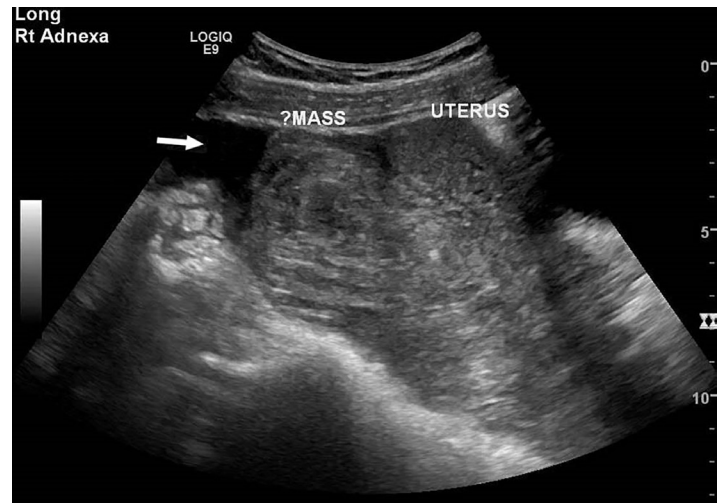


Image 3. Short axis. Transvaginal ultrasound demonstrating a 10-centimeter heterogeneous mass posterior to the uterus, moderate free fluid in the pelvis (arrow), and no evidence of intrauterine pregnancy or adnexal abnormality.

The patient tolerated the procedure well and was discharged later that day. Because of the abdominal location of the ectopic pregnancy, she was treated with intramuscular methotrexate and followed until beta human gonadotropin (hCG) levels were negative approximately four weeks later.

DISCUSSION

Because of the significant morbidity and mortality associated with ectopic pregnancy, a high index of suspicion must be maintained. The diagnosis, however, can be challenging. Risk factors for ectopic pregnancy include previous ectopic pregnancy, previous tubal surgery, documented tubal pathology, in utero diethylstilbestrol exposure, previous genital infection such as pelvic inflammatory disease, infertility, a history of smoking, and age greater than 35 years; however, ectopic pregnancy frequently occurs in women with no known risk factors.^{1,2,13} Additionally, the diagnosis cannot be reliably confirmed or excluded based on history or physical exam findings alone.^{1,3,4,13}

Many patients present before rupture and can be diagnosed rapidly with a combination of quantitative serum hCG test and POCUS.^{1,2,13} Transvaginal ultrasound is the diagnostic imaging modality of choice^{1,2,13} and is highly sensitive (87-99%) and specific (94-99.9%).¹³ Although TV ultrasound is the preferred imaging modality, it is not readily available in all EDs, especially in non-academic or rural settings. In the absence of TV ultrasound, transabdominal pelvic ultrasound can be sufficient to rule out ectopic pregnancy when an IUP is identified.⁹ While the gestational sac is the earliest sign of an IUP, less experienced practitioners should consider using a visible yolk sac as a more definitive sign of an IUP. A pseudogestational sac can be seen in ectopic pregnancy and mimic the gestational sac of a normal pregnancy.^{2,13}

Classically, patients with ruptured ectopic pregnancy present with signs of shock (eg, tachycardia, hypotension),² but the degree of hemodynamic instability can be variable.^{1,10} In one study, only 12% of patients with confirmed ruptured ectopic pregnancy presented with tachycardia and hypotension.¹⁰ Hemodynamically unstable patients or those with signs of intraperitoneal bleeding require operative intervention for definitive management.^{1,2}

When an ectopic pregnancy is suspected, the presence of free fluid in the right upper quadrant (Morison's pouch) noted on POCUS should raise the suspicion of a ruptured ectopic pregnancy with hemorrhage.^{10,11} Early identification of hemoperitoneum reduces the time to diagnosis and operative management when compared to patients evaluated with consultative pelvic ultrasound performed by other imaging specialists.¹⁰ In some cases, the ectopic pregnancy may be visible on transabdominal ultrasound and can confirm the diagnosis at the bedside.¹² A quantitative beta hCG level can provide a context for the ultrasound findings but should not be used as the deciding factor to perform an ultrasound.

Abdominal ectopic pregnancies are infrequent with an estimated incidence of about 1% of ectopic pregnancies.^{2,8,14} Abdominal ectopic pregnancies can implant on the omentum, serosa, pouches surrounding the uterus and adnexa, bowel, abdominal organs, retroperitoneum, and abdominal wall.¹⁵ They are often misdiagnosed and are associated with high maternal morbidity and mortality. The maternal mortality rate for abdominal ectopic pregnancies is estimated at 7.7 times higher than that observed for tubal ectopic pregnancies and 90 times higher than that observed for IUPs.¹⁴ In the 225 cases of early (<20 weeks gestation) abdominal ectopic pregnancy reviewed by Pool et al, blood

loss or hemoperitoneum occurred in 48%, blood transfusion was required in 24%, and there were seven maternal deaths (3%).¹⁵ As previously mentioned, in the case of contraceptive failure, current IUD use significantly increases the risk for ectopic pregnancy,⁷ and is an independent risk factor for distal implantation site, including the abdomen.⁸

We present a rare case of ruptured abdominal ectopic pregnancy in a patient with a well-positioned IUD. Because of their rarity and variable sites of implantation, abdominal ectopic pregnancies present a diagnostic challenge. This case again illustrates that when ectopic pregnancy is suspected, transabdominal POCUS performed by the emergency provider demonstrating free fluid in Morison's pouch and no visible IUP is consistent with a diagnosis of ruptured ectopic pregnancy¹⁰⁻¹² and urgent operative intervention is required.^{2,11}

In this case, the lack of tubal or adnexal abnormality and the presence of a retrouterine mass on TV ultrasound raised concern for an alternate diagnosis and prompted the transfer of the patient to a tertiary referral center. It is important to consider that patients with an IUD and ectopic pregnancy are at increased risk for implantation at distal sites, and the possibility of an abdominal pregnancy must be considered. This diagnosis cannot be excluded by normal-appearing adnexa on TV ultrasound. Efforts to confirm the diagnosis with formal imaging studies may lead to potentially unnecessary or dangerous delays in treatment or patient transfer.

CONCLUSION

Ectopic pregnancy carries high morbidity and mortality; patients are at risk for rupture and life-threatening hemorrhage. While pregnancy with an IUD in place is rare, when it is encountered the emergency provider should be highly suspicious of an extrauterine pregnancy and consider the increased risk of distal sites of implantation such as the abdomen. This should prompt the emergency provider to pay close attention to signs of hemorrhagic shock and perform diagnostic POCUS. When an ectopic pregnancy is suspected, an empty uterus and free fluid in Morison's pouch visualized with transabdominal POCUS are highly specific for ruptured ectopic pregnancy. In conjunction with resuscitative efforts of hemorrhagic instability if present, definitive treatment with laparoscopy should be pursued as quickly as possible. Efforts to confirm the diagnosis with formal imaging studies may lead to potentially unnecessary or dangerous delays in treatment or patient transfer.

The authors attest that their institution requires neither Institutional Review Board approval, nor patient consent for publication of this case report. Documentation on file.

Address for Correspondence: Derick D. Jones, MD, MBA, Mayo Clinic, 200 First Street SW, Rochester, MN, 55905. Email: jones.derick@mayo.edu.

Conflicts of Interest: By the CPC-EM article submission agreement, all authors are required to disclose all affiliations, funding sources and financial or management relationships that could be perceived as potential sources of bias. The authors disclosed none.

Copyright: © 2020 Jones et al. This is an open access article distributed in accordance with the terms of the Creative Commons Attribution (CC BY 4.0) License. See: <http://creativecommons.org/licenses/by/4.0/>

REFERENCES

1. Murray H, Baakdah H, Bardell T, et al. Diagnosis and treatment of ectopic pregnancy. *CMAJ*. 2005;173(8):905-12.
2. American College of Obstetricians and Gynecologists' Committee on Practice Bulletins-Gynecology. ACOG Practice Bulletin No. 193: Tubal ectopic pregnancy. *Obstet Gynecol*. 2018;131(3):e91-103.
3. Dart RG, Kaplan B, Varaklis K. Predictive value of history and physical examination in patients with suspected ectopic pregnancy. *Ann Emerg Med*. 1999;33(3):283-90.
4. Buckley RG, King KJ, Disney JD, et al. History and physical examination to estimate the risk of ectopic pregnancy: validation of a clinical prediction model. *Ann Emerg Med*. 1999;34(5):589-94.
5. Creanga AA, Syverson C, Seed K, et al. Pregnancy-related mortality in the United States, 2011–2013. *Obstet Gynecol*. 2017;130(2):336-73.
6. Daniels K and Abma JC. Current contraceptive status among women aged 15-49: United States, 2015-2017. 2018. Available at: <https://www.cdc.gov/nchs/products/databriefs/db327.htm> . Accessed May 25, 2019.
7. Li C, Zhao WH, Meng CX, et al. Contraceptive use and the risk of ectopic pregnancy: a multi-center case-control study. *PLoS ONE*. 2014;9(12):e15031.
8. Bouyer J, Coste J, Fernandez H, et al. Sites of ectopic pregnancy: a 10 year population-based study of 1800 cases. *Hum Reprod*. 2002;17(12):3224-30.
9. Stein JC, Wang R, Adler N, et al. Emergency physician ultrasonography for evaluating patients at risk for ectopic pregnancy: a meta-analysis. *Ann Emerg Med*. 2010;56(6):674-83.
10. Rodgerson JD, Heegaard WG, Plummer D, et al. Emergency department right upper quadrant ultrasound is associated with a reduced time to diagnosis and treatment of ruptured ectopic pregnancies. *Acad Emerg Med*. 2001;8(4):331-6.
11. Moore C, Todd WM, O'Brien E, et al. Free fluid in Morison's pouch on bedside ultrasound predicts need for operative intervention in suspected ectopic pregnancy. *Acad Emerg Med*. 2007;14(8):755-8.

12. Neth MR, Thompson MA, Gibson CB, et al. Ruptured ectopic pregnancy in the presence of an intrauterine device. *Clin Pract Cases Emerg Med.* 2019;3(1):51-4.
13. Kirk E, Bottomley C, Bourne T. Diagnosing ectopic pregnancy and current concepts in the management of pregnancy of unknown location. *Hum Reprod Update.* 2014;20(2):250-61.
14. Atrash HK, Friede A, Hogue CJ. Abdominal pregnancy in the United States: frequency and maternal mortality. *Obstet Gynecol.* 1987;69(3 Pt 1):333-7.
15. Poole A, Haas D, Magann EF. Early abdominal ectopic pregnancies: a systemic review of the literature. *Gynecol Obstet Invest.* 2012;74(4):249-60.

Sequelae of Anticoagulant Therapy in a Patient with History of Pulmonary Malignancy: A Case Report

Christopher B. Gilsdorf, DO*†
Hillary E. Davis, MD, PhD*

*University of Tennessee Medical Center, Department of Emergency Medicine, Knoxville, Tennessee

†University of Tennessee Medical Center, Department of Family Medicine, Knoxville, Tennessee

Section Editor: Rick A. McPheeters, DO

Submission history: Submitted May 19, 2020; Revision received July 11, 2020; Accepted July 24, 2020

Electronically published October 5, 2020

Full text available through open access at http://escholarship.org/uc/uciem_cpem

DOI: 10.5811/cpcem.2020.7.48317

Introduction: In patients with known malignancy and possible intracranial metastatic disease who are receiving treatment with therapeutic anticoagulation, limited data exist regarding risk of intracranial bleeding.

Case Report: We present a case of a 64-year-old female with known lung malignancy, evidence of possible metastatic disease, and bilateral deep vein thrombosis, who suffered severe intracranial hemorrhage following initiation of therapeutic anticoagulation. Current guidelines, available risk-stratification tools, and treatment options with their risks are discussed.

Conclusion: In patients with known or suspected intracranial metastatic disease, clinical decision tools can assist both the clinician and the patient in weighing risks and benefits of anticoagulation. [Clin Pract Cases Emerg Med. 2020;4(4):564–568.]

Keywords: *anticoagulation; malignancy; intracranial hemorrhage; venous thromboembolism; brain metastases.*

INTRODUCTION

Therapeutic anticoagulation is used in a variety of clinical settings to prevent the feared sequelae of venous thromboembolism (VTE), including thrombus propagation, venous insufficiency, and pulmonary embolus (PE), in patients with predisposing conditions including hypercoagulable states, atrial fibrillation, and mechanical cardiac valve replacements. However, initiation of anticoagulation is not without significant risk for hemorrhage, particularly in certain patient populations. Several evidence-based clinical decision tools aid in risk stratification of at-risk patients but do not explicitly address known malignancy.¹ We present a case in which anticoagulation therapy was initiated in a patient with a pre-existing neoplasm with possible metastatic spread that resulted in an unfortunate patient outcome likely secondary to undiagnosed intracranial metastases.

CASE REPORT

A 64-year-old White female with history of stage I squamous cell carcinoma of the right middle lung, renal transplant secondary to membranous glomerulonephritis, history of previous VTE, hypertension, chronic obstructive pulmonary disease, and stage four chronic kidney disease presented to the emergency department (ED) for treatment of deep venous thrombosis (DVT). The patient had been sent by her pulmonologist after obtaining outpatient, lower-extremity venous Doppler ultrasounds earlier that day. The patient had been recently hospitalized for an episode of pneumonia and discharged two weeks prior during which her warfarin had been discontinued for unclear reasons; her history of stage I (T1a, N0) squamous cell cancer of the lung had been only minimally addressed during this admission. The patient had not had a positron emission tomography to assess her tumor staging in nearly 10 months. Additionally, her most recent

oncology notes from six months prior following two treatments of stereotactic ablative radiotherapy demonstrated a stable computed tomography (CT) of the thorax and recommended surveillance CT in six months. However, a CT of the abdomen obtained three weeks prior to her ED visit to assess for urinary pathology showed a nonspecific 1.9-centimeter (cm) hypodensity of the liver, potentially concerning for metastatic disease.

On the day of her ED evaluation, she endorsed right lower leg swelling without redness and right leg pain causing difficulty with ambulation. She denied weakness or sensory loss, bladder or bowel dysfunction, headache, fever, chest pain, dyspnea, and all other review of systems. The patient's presenting vital signs were grossly normal as she was afebrile (36.2° Celsius) with a heart rate of 81 beats per minute, respiratory rate of 16 breaths per minute, blood pressure of 136/82 millimeters of mercury (mm Hg), and an oxygen saturation of 97% on room air. The patient's physical examination was remarkable for mild tenderness in the posterior aspect of the right upper, middle, and lower leg, with intact distal neurovascular status. There was no overlying erythema or edema. The rest of her physical examination was grossly normal, including a neurologic examination without any deficits.

The patient's laboratory workup was remarkable for a creatinine of 2.07 milligrams per deciliter (mg/dL) (normal range 0.57-1.00 mg/dL) and estimated glomerular filtration rate of 25 (normal >58), elevated leukocyte count of 13.2 thousand (K)/microliter (μL) (normal range 3.4-10.8 K/μL), platelet count of 96 K/μL (normal range 150-379), prothrombin time of 13 seconds (normal range 9.1-12.0), international normalized ratio (INR) of 1.26 (normal range 0.80-1.20), and partial thromboplastin time of 27.6 seconds (normal range 24.4-31.4). Her lower-extremity venous Doppler studies, reviewed upon arrival in the ED, demonstrated acute deep venous occlusive disease of the bilateral peroneal veins and the right common femoral vein in addition to acute superficial occlusion of the right greater saphenous vein.

Given the patient's prior history of VTE, previous renal transplant, and current findings of bilateral DVT, both the vascular surgery and transplant services were consulted; both recommended initiation of intravenous heparin infusion for full anticoagulation treatment. Heparin bolus and drip were initiated. The hospitalist was consulted to admit the patient, agreed with the plan for therapeutic heparin infusion, and noted the patient would now require lifelong anticoagulation given that this was her second episode of VTE. The hematology/oncology service was consulted, but did not evaluate the patient the day of admission. The patient had a non-contrast CT of the thorax performed shortly after initiation of heparin to evaluate for persistent pneumonia. This study demonstrated an enlarging hepatic lesion consistent with metastatic disease that had increased in diameter from 1.9 cm to 2.4 cm over the prior three weeks.

CPC-EM Capsule

What do we already know about this clinical entity?

Venous thromboembolic disease is a common comorbid condition in patients suffering from malignancy, and anticoagulant pharmacotherapy is considered standard of care.

What makes this presentation of disease reportable?

We discuss a patient with known malignancy initiated on anticoagulation despite possible metastatic disease and who suffered a poor outcome.

What is the major learning point?

In treating venous thromboembolism secondary to malignancy, risk-stratification tools, type of malignancy, and shared decision-making should guide treatment.

How might this improve emergency medicine practice?

Knowledge of indications and contraindications for acute anticoagulant use in the setting of malignancy can guide proper pharmacotherapy and avoid adverse events.

Six hours after admission, the patient developed a headache. Two hours later she subsequently developed lethargy and confusion, which progressed over minutes to obtundation. The patient was tachypneic, possessed anisocoria, and was hypertensive to a systolic blood pressure of 200 mm Hg. The hospitalist discontinued the heparin drip, called for a code intubation, ordered protamine, and transferred the patient to the intensive care unit. A non-contrast CT head was performed to evaluate for suspected intracranial hemorrhage (ICH). Her CT demonstrated a large right parietal/temporal/occipital hemorrhage and a right subdural hematoma accompanied by 1.8 cm right-to-left midline shift, uncal herniation, and contralateral brainstem compression (Images 1 and 2). The radiologist did not address potential metastatic etiology of her bleed.

The neurosurgery service was consulted and a craniotomy was offered to the patient's family but was declined after being counseled on the patient's likely "poor prognosis" even after intervention. Instead, the patient's family opted to pursue

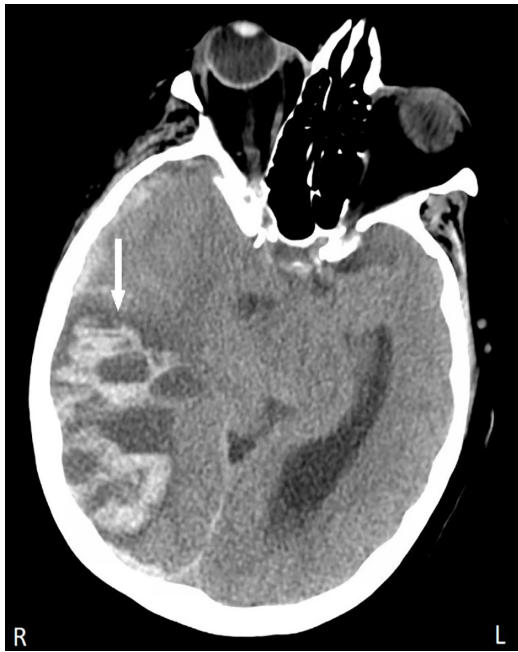

Image 1. Axial view of noncontrast computed tomography of the brain depicting a large right-sided parietal/temporal/occipital hemorrhage (arrow) with right-to-left midline shift in a 64-year-old female with history of non-small-cell lung cancer following initiation of therapeutic heparin anticoagulation for treatment of deep venous thrombosis.

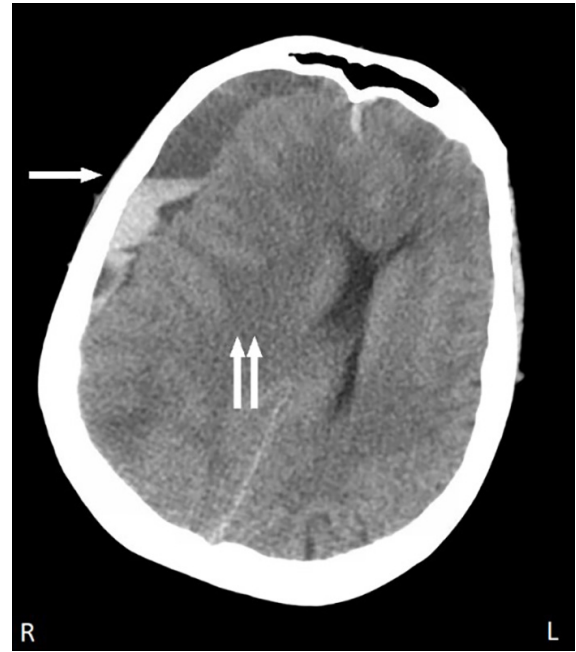


Image 2. Axial view of noncontrast computed tomography of the brain depicting a right-sided acute-on-chronic subdural hematoma (arrow) with right-to-left midline shift and ventricular obliteration (double arrow) in a 64-year-old female with history of non-small-cell lung cancer following initiation of therapeutic heparin anticoagulation for treatment of deep venous thrombosis.

comfort measures. The patient was terminally extubated later that day and shortly thereafter died.

DISCUSSION

VTE is a significant cause of morbidity and mortality in patients with malignancy; it is in fact the leading cause of death in patients suffering malignancy after cancer itself.² Therapeutic anticoagulation has proven to reduce morbidity and mortality in this population.³ While the patient experienced a poor outcome following initiation of heparin in this case, she had been on warfarin within two weeks of her ED visit. Thus, it was surprising that the patient experienced an intracranial bleed. We hypothesize that this consequence was a result of progression and spread of her underlying malignancy. As patients without fully characterized malignancies present with increasing frequency to the ED, it is important for healthcare providers to familiarize themselves with the indications, benefits, risks and alternatives of anticoagulation therapies for the treatment of VTE.

While warfarin, unfractionated heparin (UFH) and low-molecular-weight heparin (LMWH), fondaparinux, and direct oral anticoagulants (DOAC) are all commonly used in the acute treatment of VTE in patients with malignancy, evidence demonstrates a slight mortality benefit in LMWH over UFH in this patient population; its once-daily dosing also makes it an attractive option over UFH.^{4,5} Therefore, LMWH is considered first-line therapy for immediate anticoagulation

after diagnosis in the first five days of therapy, until concurrently initiated warfarin therapy has reached therapeutic levels.^{4,5} This patient's poor renal function and potential interaction with her immunosuppressant medications unfortunately precluded LMWH use. DOACs are used in some patients with malignancy, but barriers to their use exist. Due to shared metabolic pathways with DOACs, some chemotherapeutic agents may be less efficacious, with concurrent increased risk of bleeding; additionally, vomiting reduces gastrointestinal absorption of DOACs.⁵

Pre-existing evidence of metastatic disease had never been definitively confirmed in this patient. However, the enlarging hepatic nodule noted on multiple CTs was concerning for interim development of disease spread. Given her outcome, it must be considered whether initiation of anticoagulation was inappropriate in her clinical setting. Based on the available evidence, the answer is not entirely clear, but the patient lacked absolute contraindications and had only limited relative contraindications to anticoagulant therapy.⁶ One example was the patient's thrombocytopenia as her platelet count was 96,000; this put her at increased risk of ICH, but she was not in the highest risk group of severe thrombocytopenia, defined in one study as a platelet count less than 50,000.⁷ Elevated prothrombin time was in fact found to be more predictive of risk of ICH.⁸

Several risk-stratification tools exist to attempt to quantify a given patient's risk of major hemorrhagic event on

anticoagulation, which can serve as an aid to shared decision-making between physician and patient. The HAS-BLED (Hypertension, Abnormal liver/renal function, Stroke history, Bleeding history or predisposition, Labile INR, Elderly, Drug/alcohol usage) scoring system, validated for use in patients receiving anticoagulation for VTE prevention in atrial fibrillation, is frequently used for risk stratification and risk assessment, but does not list current or previous malignancy among its scoring criteria.¹ The ATRIA (anticoagulation and risk factors in atrial fibrillation) study is another risk-stratification tool for bleeding, created for patients on warfarin; it likewise does not address malignancy as a scoring criterion.⁹ A third, comprehensive tool, HEMORR₂HAGES (Hepatic or renal disease, Ethanol abuse, Malignancy, Older than 75 years, Reduced platelet count or function, Hypertension, Anemia, Genetic factors, Excessive fall risk, Stroke), does take into account pre-existing malignancy.¹⁰ However, the HEMORR₂HAGES tool, essentially a composite of multiple other risk-stratification scoring systems, does not clearly define cutoffs or criteria for several of its components, including hepatic or renal disease.

The type of intracranial lesion matters when it comes to risk of ICH on therapeutic anticoagulation; gliomas were found in one meta-analysis to confer higher risk compared to many other primary or secondary brain lesions. The risk of spontaneous ICH was fourfold higher in metastatic renal cell carcinoma and melanoma than in non-small cell lung cancer (NSCLC) and breast cancer, although independent of anticoagulant use.^{11,12} Patients with brain metastases from NSCLC had a relatively low risk of spontaneous bleeding on anticoagulation, with a study showing a rate of only 1.2% over 580 person-years. However, this result may be biased as all patients in these studies received directed radiotherapy, which has been proven to blunt angiogenesis.^{13,14} The incidence of spontaneous bleeding in patients not receiving radiotherapy is unknown. Therefore, due to this patient's primary tumor, she would not have been considered high risk for ICH from anticoagulation therapy.

In this patient, no advanced brain imaging was obtained prior to initiating therapeutic anticoagulation. There is a lack of consensus statements in the literature addressing the need for advanced imaging in similar patient groups to rule out brain metastases prior to initiating anticoagulation.¹⁵ One approach is to examine both the risk of brain metastases and the likelihood of such metastases to bleed, if present.¹⁵ Patients with high-risk neoplasms, headaches, or focal neurological deficits should undergo imaging, preferably with magnetic resonance imaging, if therapeutic anticoagulation could be safely delayed.¹⁵ Otherwise, alternative treatment modalities such as inferior vena cava filters or initiating anticoagulation with available reversal agents may need to be considered.

CONCLUSION

We presented a case of intracranial hemorrhage following re-initiation of anticoagulation therapy for acute venous

thromboembolism in a patient with known pre-existing lung neoplasm with findings concerning for metastatic progression. In select patients with known or suspected intracranial metastatic disease, the risks and benefits of initiation of anticoagulation need to be carefully weighed by both the clinician and patient.

The Institutional Review Board approval has been documented and filed for publication of this case report.

Address for Correspondence: Christopher B. Gilsdorf, DO, Leconte Medical Center, Department of Emergency Medicine, 742 Middle Creek Rd., Sevierville, TN 37862. Email: christopher_gilsdorf@teamhealth.com.

Conflicts of Interest: By the CPC-EM article submission agreement, all authors are required to disclose all affiliations, funding sources and financial or management relationships that could be perceived as potential sources of bias. The authors disclosed none.

Copyright: © 2020 Gilsdorf et al. This is an open access article distributed in accordance with the terms of the Creative Commons Attribution (CC BY 4.0) License. See: <http://creativecommons.org/licenses/by/4.0/>

REFERENCES

1. Brown JD, Goodin AJ, Lip GY, et al. Risk stratification for bleeding complications in patients with venous thromboembolism: application of the HAS-BLED bleeding score during the first 6 months of anticoagulant treatment. *J Am Heart Assoc.* 2018;7(6):e007901.
2. Khorana AA, Francis CW, Culakova E, et al. Thromboembolism is a leading cause of death in cancer patients receiving outpatient chemotherapy. *J Thromb Haemost.* 2007;5(3):632–4.
3. Streiff MB. Thrombosis in the setting of cancer. *Hematology Am Soc Hematol Educ Program.* 2016;2016:196–205.
4. Hakoum MB, Kahale LA, Tsolakian IG, et al. Anticoagulation for the initial treatment of venous thromboembolism in people with cancer. *Cochrane Database Syst Rev.* 2018;1(1):CD006649.
5. Farge D, Bounameaux H, Brenner B, et al. International clinical practice guidelines including guidance for direct oral anticoagulants in the treatment and prophylaxis of venous thromboembolism in patients with cancer. *Lancet Oncol.* 2016;17(10):e452–66.
6. Key NS, Khorana AA, Kuderer NM, et al. Venous thromboembolism prophylaxis and treatment in patients with cancer: ASCO Clinical Practice Guideline Update. *J Clin Oncol.* 2020;38(5):496–520.
7. Neunert C, Noroozi N, Norman G, et al. Severe bleeding events in adults and children with primary immune thrombocytopenia: a systemic review. *J Thromb Haemost.* 2015;13(3):457–64.
8. Chen CY, Tai CH, Tsay W, et al. Prediction of fatal intracranial hemorrhage in patients with acute myeloid leukemia. *Ann Oncol.* 2009;20(6):1100–4.

9. Fang MC, Go AS, Chang Y, et al. A new risk scheme to predict warfarin-associated hemorrhage: the ATRIA (anticoagulation and risk factors in atrial fibrillation) study. *J Am Coll Cardiol*. 2011;58(4):395–401.
10. Gage BF, Yan Y, Milligan PE, et al. Clinical classification schemes for predicting hemorrhage: results from the National Registry of Atrial Fibrillation (NRAF). *Am Heart J*. 2006;151(3):713–9.
11. Zwicker JI, Leaf RK, Carrier M. A meta-analysis of intracranial hemorrhage in patients with brain tumors receiving therapeutic anticoagulation. *J Thromb Haemost*. 2016;14(9):1736–40.
12. Donato J, Campigotto F, Uhlmann EJ, et al. Intracranial hemorrhage in patients with brain metastases treated with therapeutic enoxaparin: a matched cohort study. *Blood*. 2015;126(4):494–9.
13. Srivastava G, Rana V, Wallace S, et al. Risk of intracranial hemorrhage and cerebrovascular accidents in non-small cell lung cancer brain metastasis patients. *J Thorac Oncol*. 2009;4(3):333–7.
14. Wachsberger P, Burd R, Dicker AP. Tumor response to ionizing radiation combined with antiangiogenesis or vascular targeting agents: Exploring mechanisms of interaction. *Clin Cancer Res*. 2003;9(6):1957–71.

The Woes of a Stuffy Nose: A Case Report of Allergic Fungal Sinusitis

Tyler Lopachin, MD
Grace Landers, MD

Naval Medical Center Portsmouth, Department of Emergency Medicine,
Portsmouth, Virginia

Section Editor: Shadi Lahham, MD, MS

Submission history: Submitted February 7, 2020; Revision received April 6, 2020; Accepted April 17, 2020

Electronically published October 26, 2020

Full text available through open access at http://escholarship.org/uc/uciem_cpem

DOI: 10.5811/cpcem.2020.4.46866

Introduction: Allergic fungal sinusitis (AFS) is a relatively uncommon cause of sinus pain and congestion. Extreme cases may require specialty evaluation and surgical treatment.

Case Report: In this case, an otherwise healthy young man presented to the emergency department with sinus pain and congestion for two weeks and was admitted to surgery for resection of his AFS.

Conclusion: This case demonstrates how a thorough history and physical exam can help catch potentially serious diseases, such as allergic fungal sinusitis, from the frequently benign chief complaint of sinus pain. [Clin Pract Cases Emerg Med. 2020;4(4):569–571.]

Keywords: *Headache; sinus pain; congestion; stuffy nose; eye pain.*

INTRODUCTION

Sinusitis is one of the most common complaints in the country, developing in 12.5% of the entire United States population during a given year.¹ The vast majority of these cases are caused by benign, self-limiting viral infections.² Treatment in the emergency department (ED) revolves around symptomatic care with decongestants.² Certain aspects of the history and physical exam, however, should raise the alarm for a more serious diagnosis. High-risk historical features, such as a diabetes, recent trauma, or immunocompromised status, or concerning physical exam findings such as pain with extraocular movement and proptosis warrant additional imaging or laboratory testing.

CASE REPORT

The patient was a 27-year-old male without past medical history who presented with sinus congestion for two weeks. He stated that he had issues with sinus congestion many times before but this episode appeared to be more extreme than previous ones. He had been seen by his primary care doctor twice and given guaifenesin and pseudoephedrine for symptomatic relief. The night of presentation he complained of a headache that had gotten worse overnight with increasing sinus pressure. He denied fevers, chills, or blurry vision. The remainder of his review of systems was negative. On

physical exam, vital signs were within normal limits and he was afebrile. Notably, there was mild right periorbital swelling along with multiple right nasal polyps on physical exam. In addition, he exhibited marked tenderness to palpation of right frontal, ethmoid, and maxillary sinuses. His extraocular movement was intact but notable for pain with vertical gaze in his right eye and diplopia. Otherwise, he demonstrated a normal physical exam with a non-focal neurological exam.

Initial laboratory evaluation that included complete blood count and basic metabolic panel was unremarkable. A computed tomography was ordered due to concern for the patient's pain with extraocular movements and demonstrated destruction of the medial orbital wall and compression of the right superior rectus muscle (Image). The patient was diagnosed with allergic fungal sinusitis (AFS) with possible superimposed bacterial infection. He was admitted to the hospital under the otorhinolaryngology service with ophthalmologic consultation. On hospital day one a polypectomy was performed with debridement of the fungus. The patient did well postoperatively and was discharged home with doxycycline and outpatient follow-up.

DISCUSSION

This case highlights an unusual etiology of an extremely common and often benign complaint—nasal

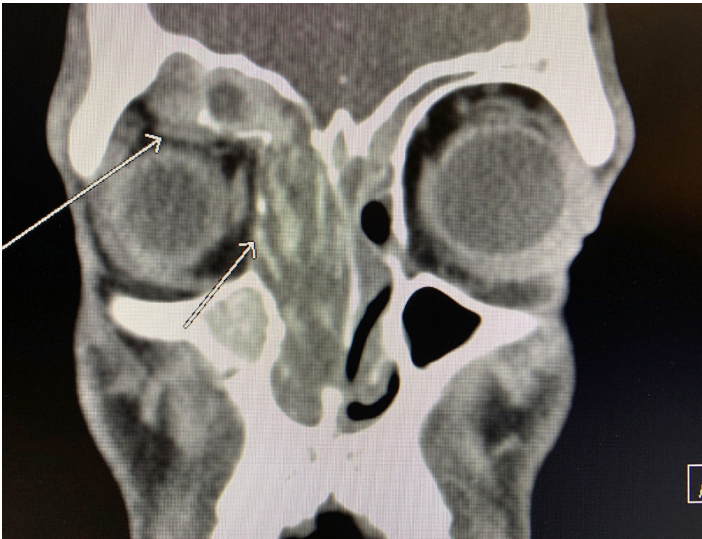


Image. Computed tomography demonstrating allergic fungal sinusitis. The shorter arrow notes destruction of orbital wall, with longer arrow demonstrating compression of superior rectus muscle.

congestion. However, as discussed earlier, there are a few parts of this patient's history and physical that raised concern, specifically symptoms lasting two weeks without relief in spite of appropriate symptomatic care. The patient's lack of improvement suggests a more serious etiology. Monocular pain with vertical gaze was perhaps the most troubling finding, especially in the presence of periorbital swelling. Often pain with eye movement is associated with orbital cellulitis, but it can occur with an intraorbital process that disrupts the function of the extraocular muscles. Finally, the patient's nasal polyp disease and history of frequent nasal congestion are associated with his ultimate diagnosis, AFS.

Seen in patients with nasal polyps and asthma, AFS occurs when an airborne fungus begins to colonize the sinuses, leading to a predominately eosinophilic inflammatory response that causes thick mucus and debris to block the sinus spaces.³ The most commonly implicated species of fungi are *Bipolaris*, *Curvularia*, *Aspergillus*, *Exserohilum*, and *Drechslera*, all of which can infect an immunocompetent healthy host.⁴ In turn, eosinophilic degranulation products cause destruction of nasal mucosa and surrounding bony structures. Ultimately, this leads to bacterial colonization and penetration into the orbit itself, worsening clinical symptoms and inflammatory response. If untreated, as in this patient, localized destruction and intraorbital invasion occurs.⁵

While some patients can be medically managed with decongestants, the mainstay of treatment for patients who have failed outpatient management is endoscopic surgical removal of the fungus. It not only aids in the diagnosis, but allows the removal of the affecting material. This, in turn, provides better access for the administration of topical steroids

CPC-EM Capsule

What do we already know about this clinical entity?

Allergic fungal sinusitis is a disorder involving fungal colonization of the sinuses and subsequent inflammatory response in immunocompetent patients.

What makes this presentation of disease reportable?

This is a case of a serious diagnosis that required surgical management presenting in the emergency department as a common, often-benign complaint, sinusitis.

What is the major learning point?

Pain with extraocular muscle movement in the setting of sinus pain or headache should prompt further evaluation.

How might this improve emergency medicine practice?

This case highlights the importance of good physical exam and history taking, and provides some useful red flags when evaluating a patient with sinusitis.

postoperatively.⁶ Patients are also treated with systemic steroids both before and after the surgery. While preoperative dosing is more controversial, postoperative dosing consists of 0.5 milligrams per kilogram daily of prednisone and tapering down over the course of many weeks.⁷ Unfortunately, recurrence is common, and patients may need repeat surgical removal or long-term immune modulation; however, the latter is more controversial.³

CONCLUSION

While sinus pain and congestion are common presenting symptoms in the ED, this case demonstrates how even seemingly benign chief complaints can lead to potentially serious diagnoses. This case illustrates the importance of good history and physical exam skills for emergency physicians. It also highlights some key red flags to recognize in a patient with sinus pain.

The authors attest that their institution requires neither Institutional Review Board approval, nor patient consent for publication of this case report. Documentation on file.

Address for Correspondence: Tyler Lopachin, MD, Naval Medical Center, Department of Emergency Medicine, 620 John Paul Jones Cir, Portsmouth, VA 23708. Email: tyler.r.lopachin.mil@mail.mil.

Conflicts of Interest: By the CPC-EM article submission agreement, all authors are required to disclose all affiliations, funding sources and financial or management relationships that could be perceived as potential sources of bias. The authors disclosed none. The views expressed here are those of the authors and do not reflect the official policy of the Department of the Navy, the Department of Defense, or the U.S. Government.

Copyright: © 2020 Lopachin et al. This is an open access article distributed in accordance with the terms of the Creative Commons Attribution (CC BY 4.0) License. See: <http://creativecommons.org/licenses/by/4.0/>

REFERENCES

1. Blackwell DL, Lucas JW, Clarke TC. Summary health statistics for U.S. adults: national health interview survey, 2012. *Vital Health Stat.* 2014;(260):1-161.
2. Tan T, Little P, Stokes T. Antibiotic prescribing for self limiting respiratory tract infections in primary care: Summary of NICE guidance. *BMJ.* 2008;337:a437.
3. Schlosser, RJ and Hamilos D. Allergic fungal rhinosinusitis Uptodate. Waltham, MA: UpToDate Inc. Accessed Dec 20, 2019. (UpToDate)
4. Manning SC, Schaefer SD, Close LG, et al. Culture-positive allergic fungal sinusitis. *Arch Otolaryngol Head Neck Surg.* 1991;117(2):174-8.
5. Hamilos DL and Lund VJ. Etiology of chronic rhinosinusitis: the role of fungus. *Ann Otol Rhinol Laryngol Suppl.* 2004;193:27-31.
6. Thomas WW 3rd, Harvey RJ, Rudmik L, et. Al. Distribution of topical agents to the paranasal sinuses: an evidence-based review with recommendations. *Int Forum Allergy Rhinol.* 2013;3(9):691-703.
7. Peters AT, Spector S, Hsu J, et.al, Diagnosis and management of rhinosinusitis: a practice parameter update. *Allergy Asthma Immunol.* 2014;113(4):347-85.

Inhaled Tranexamic Acid for Massive Hemoptysis in the Setting of Oral Anticoagulation: A Case Report

Jacqueline M. Dempsey, PharmD*
Mandy Jones, PharmD, MPAS†
Jonathan Bronner, MD‡
Connor Greer, MD‡
Gavin T. Howington, PharmD*†

*University of Kentucky HealthCare, Department of Pharmacy Services, Lexington, Kentucky
†University of Kentucky, Department of Pharmacy Practice and Science, Lexington, Kentucky
‡University of Kentucky HealthCare, Department of Emergency Medicine, Lexington, Kentucky

Section Editor: Steven Walsh, MD

Submission history: Submitted June 2, 2020; Revision received July 25, 2020; Accepted July 31, 2020

Electronically published October 5, 2020

Full text available through open access at http://escholarship.org/uc/uciem_cpccem

DOI: 10.5811/cpcem.2020.7.48525

Introduction: We discuss a case of massive hemoptysis in the setting of a direct-acting oral anticoagulant (DOAC) successfully managed with nebulized tranexamic acid (TXA).

Case Report: Per the American College of Cardiology and the American Society of Hematology, it is recommended that significant bleeding associated with a DOAC be treated with either 4-factor prothrombin complex concentrate or andexanet alfa. However, our patient was at high risk for thrombotic complications given a recent pulmonary embolism.

Conclusion: We demonstrate that it is reasonable to trial nebulized TXA given its low cost, ease of administration, and safety profile. Additionally, this report discusses a unique dosing strategy and a previously unreported complication associated with nebulization of undiluted TXA. [Clin Pract Cases Emerg Med. 2020;4(4):572–575.]

Keywords: *rivaroxaban; hemoptysis; tranexamic acid.*

INTRODUCTION

Hemoptysis is the expectoration of blood that originates from the airway, and can be classified as either non-massive or massive in nature.¹ Massive hemoptysis lacks a clear definition but is often considered to be greater than 200 milliliters (mL) per day.^{1,2} Mortality rates vary based on etiology and comorbidities; however, hemoptysis is typically considered a medical emergency secondary to the risk for asphyxiation.¹ Tranexamic acid (TXA) is an antifibrinolytic agent that prevents degradation of existing fibrin clots. It is a lysine analog that forms a reversible complex with plasminogen, displacing it from fibrin, resulting in the inhibition of fibrinolysis. Additionally, TXA inhibits the proteolytic activity of plasmin.³ Intravenous and oral TXA have been studied in the setting of hemoptysis with inconsistent results; however, a promising trial was recently published on the use of nebulized TXA.^{2,4,5}

Few attempts have been made to inhibit bleeding related to direct oral anticoagulants (DOAC) with TXA, and those cases published demonstrate variable results.^{6–8} Many published cases of hemoptysis in the setting of rivaroxaban use were resolved by holding anticoagulation; however, these reports were not designated as massive hemoptysis and did not mention consideration of anticoagulation reversal.^{9,10} There is limited evidence discussing the use of nebulized TXA for management of massive hemoptysis in the setting of anticoagulation with a DOAC.

The relatively benign side-effect profile of nebulized TXA makes it a low-risk pharmacologic option for the management of hemoptysis. The use of this agent has been briefly investigated for both hemoptysis and post-tonsillectomy bleeding. To our knowledge, the use of TXA for management of hemoptysis in the setting of a DOAC has been

reported only minimally. We describe the use of nebulized TXA in a medically complex patient receiving a DOAC to avoid complications associated with hemoptysis as well as the need for administration of 4-factor prothrombin complex concentrate (4F-PCC).

CASE REPORT

A 65-year-old male presented to the emergency department (ED) via emergency medical services (EMS) for evaluation secondary to a possible gastrointestinal bleed. Per EMS, approximately 300 mL of frank blood were noted in a bucket located in the patient's home. Soon after arriving to the ED the patient was found to be experiencing massive hemoptysis. The patient's vital signs on arrival included a blood pressure of 135/80 millimeters of mercury, a heart rate of 104 beats per minute, and respiratory rate of 35 breaths per minute. Additionally, his oxygen saturation was 92% on room air. Pertinent past medical history included chronic obstructive pulmonary disease, left upper lobe pulmonary mass concerning for malignancy or infection, heart failure, and tobacco use. Additionally, the patient had been discharged from the hospital four days prior with a new prescription for rivaroxaban 15 milligrams (mg) by mouth twice daily for 21 days, followed by 20 mg once daily after being diagnosed with a subsegmental pulmonary embolism (PE). Enoxaparin had been transitioned to rivaroxaban while inpatient, and outpatient adherence to rivaroxaban was confirmed.

The patient continued to expectorate a large volume of blood, and there was concern for impending airway compromise. Prior to consideration of 4F-PCC, the decision was made to trial nebulized TXA. An intravenous solution of TXA 500 mg was initially nebulized directly with a Hudson RCI Micro Mist nebulizer (Teleflex Incorporated, Wayne, PA) at an oxygen flow rate of 8 L per minute. When using undiluted TXA, the solution began to crystallize, preventing further nebulization, which has not previously been reported. Subsequently, respiratory therapy added 3 mL of 0.9% sodium chloride, resulting in a final concentration of 62.5 mg/mL. Nebulization was completed successfully in approximately 10 minutes. Shortly after administration, the volume and frequency of hemoptysis significantly decreased with only occasional blood-tinged sputum. No systemic reversal of anticoagulation was required. Notable labs on admission included an elevated international normalized ratio of 2.9 (reference range 0.9-1.1) likely secondary to malnutrition and possibly rivaroxaban use, as well as an anti-factor Xa level > 2.0 international units/mL.¹¹

The patient was subsequently admitted to the pulmonary intensive care unit and continued TXA 500 mg nebulized every eight hours for a total of three doses. A diagnostic bronchoscopy was never performed per patient request. Anticoagulation was held throughout

CPC-EM Capsule

What do we already know about this clinical entity?

Nebulized tranexamic acid (TXA) has demonstrated promising results when used to treat hemoptysis.

What makes this presentation of disease reportable?

A patient presenting with massive hemoptysis exacerbated by direct-acting oral anticoagulant (DOAC) was treated with nebulized TXA.

What is the major learning point?

Consideration of nebulized TXA for the treatment of massive hemoptysis is reasonable for patients on DOACs.

How might this improve emergency medicine practice?

When treating hemoptysis exacerbated by anticoagulation with a DOAC, nebulized TXA may lead to rapid resolution and less need for anticoagulation reversal.

the admission, and bleeding ultimately subsided. The patient was discharged two days after admission and anticoagulation was not resumed.

DISCUSSION

We have reported a case of massive hemoptysis in the setting of rivaroxaban therapy managed with nebulized tranexamic acid. A recently published randomized, controlled trial evaluated the use of TXA 500 mg nebulized every eight hours for up to five days in 55 patients.² When compared to placebo, nebulized TXA was superior in decreasing the amount of expectorated blood starting at day two of treatment as well as the duration of bleeding at day five. Approximately 57% of patients included in this study were on an anticoagulant or an antiplatelet agent. However, only one of these patients was receiving a DOAC. Additionally, patients with massive hemoptysis, defined as greater than 200 mL, were excluded making the trial less applicable to our patient.

Per the American College of Cardiology and the American Society of Hematology, it is recommended that significant bleeding associated with a DOAC be treated with either 4F-PCC or andexanet alfa.^{12,13} Andexanet alfa is not a formulary agent at our institution. Thus, we use 4F-PCC

when pharmacologic intervention is deemed necessary for management of bleeding in the setting of a DOAC. Given the patient's possible malignancy and recent PE, there was concern regarding his prothrombotic risk.¹⁴ Additionally, 4F-PCC is significantly more expensive than TXA. Therefore, we opted to trial nebulized TXA due to its safety profile and low cost.

Per our literature search, one case of hemoptysis in the setting of rivaroxaban use was successfully managed with nebulized TXA.⁸ This case described a patient with a similar presentation of massive hemoptysis, which was attributed to stage IV adenocarcinoma. The patient had recently been diagnosed with a PE and was receiving active treatment with rivaroxaban. The authors noted concern for diffuse alveolar hemorrhage and proceeded with nebulized TXA 1000 mg (50 mg/mL) to avoid the need for systemic reversal of anticoagulation. Immediate symptom resolution was reported, and the patient did not receive any subsequent doses of TXA. An additional case report of cancer-related, non-massive hemoptysis described using a dose of TXA 1000 mg nebulized over 45 minutes.¹⁵ We describe a case of massive hemoptysis in the setting of anticoagulation with a DOAC successfully treated with nebulized TXA at a dose of 500 mg.

Nebulized TXA can be prepared and administered quickly, allowing for rapid reassessment of the need for further interventions. The initial dose of TXA was completed within approximately 10 minutes of initiation, and significant improvement of symptoms was noted immediately after completion. Several concentrations of TXA have been documented in the literature as successfully nebulized, ranging from 10mg/mL to 100mg/mL.^{2,8,15} The combination of undiluted tranexamic acid 100 mg/mL and the Micro Mist nebulizer resulted in crystallization that slowed the nebulization process. However, crystallization resolved after the addition of 3 mL of 0.9% sodium chloride. Currently, we do not have a clear explanation for this issue.

CONCLUSION

We report a case of massive hemoptysis in the setting of rivaroxaban use successfully treated with nebulized TXA. These results are consistent with the growing body of literature surrounding this topic. In the case of massive hemoptysis where rapid resolution is essential, it is reasonable to consider nebulized TXA prior to initiation of systemic anticoagulation reversal when indicated. Further investigation is needed to determine optimal dosing and concentration of TXA. At this time, emergency providers should be aware of the possibility of crystallization if using undiluted TXA.

The authors attest that their institution requires neither Institutional Review Board approval, nor patient consent for publication of this case report. Documentation on file.

Address for Correspondence: Jacqueline Dempsey, PharmD, University of Kentucky HealthCare, Department of Pharmacy Services, 800 Rose St., Room H110, Lexington, KY 40536. Email: jackie.dempsey@uky.edu.

Conflicts of Interest: By the CPC-EM article submission agreement, all authors are required to disclose all affiliations, funding sources and financial or management relationships that could be perceived as potential sources of bias. The authors disclosed none.

Copyright: © 2020 Dempsey et al. This is an open access article distributed in accordance with the terms of the Creative Commons Attribution (CC BY 4.0) License. See: <http://creativecommons.org/licenses/by/4.0/>

REFERENCES

1. Bidwell JL and Pachner RW. Hemoptysis: diagnosis and management. *Am Fam Physician*. 2005;72(7):1253-60.
2. Wand O, Guber E, Guber A, et al. Inhaled tranexamic acid for hemoptysis treatment: a randomized controlled trial. *Chest*. 2018;154(6):1379-84.
3. McCormack PL. Tranexamic acid: a review of its use in the treatment of hyperfibrinolysis. *Drugs*. 2012;72(5):585-617.
4. Tscheikuna J, Chvaychoo B, Naruman C, et al. Tranexamic acid in patients with hemoptysis. *J Med Assoc Thai*. 2002;85(4):399-404.
5. Bellam BL, Dhibar DP, Suri V, et al. Efficacy of tranexamic acid in haemoptysis: a randomized, controlled pilot study. *Pulm Pharmacol Ther*. 2016;40(2016):80-3.
6. Honda Y, Furugohri T, Morishima Y. Tranexamic acid failed to reverse the anticoagulant effect and bleeding by an oral direct Factor Xa inhibitor edoxaban. *Pharmacology*. 2017;101(1-2):92-5.
7. Levy JH, Moore KT, Neal MD, et al. Rivaroxaban reversal with prothrombin complex concentrate or tranexamic acid in healthy volunteers. *J Thromb Haemost*. 2018;16(1):54-64.
8. Komura S, Rodriguez RM, Peabody CR. Hemoptysis? Try inhaled tranexamic acid. *J Emerg Med*. 2018;54(5):e97-9.
9. Ali M, Mujahid A, De Silva PMKR, et al. Hemoptysis: an unusual presentation associated with idiopathic pulmonary fibrosis treatment. In: American Thoracic Society International Conference Meetings Abstracts American Thoracic Society International Conference Meetings Abstracts. *American Thoracic Society*. 2019:A6352.
10. Elikowski W, Małek M, Skowroński M, et al. [Hemoptysis during concomitant treatment with rivaroxaban and amiodarone in a patient with a history of pulmonary disease]. *Pol Merkur Lekarski*. 2015;39(232):227-30.
11. Yeo CH, Eranki V, Pillai A, et al. Rivaroxaban and its effect on international normalised ratio: a prospective study of 28 hip and knee arthroplasty patients. *Am Med J*. 2012;3(2):126-9.
12. Tomaselli GF, Mahaffey KW, Cuker A, et al. 2017 ACC expert consensus decision pathway on management of bleeding in patients on oral anticoagulants: a report of the American College of

- Cardiology Task Force on Expert Consensus Decision Pathways. *J Am Coll Cardiol.* 2017;70(24):3042-67.
13. Cuker A, Burnett A, Triller D, et al. Reversal of direct oral anticoagulants: guidance from the Anticoagulation Forum. *Am J Hematol.* 2019;94(6):697-709.
14. Joseph R, Burner J, Yates S, et al. Thromboembolic outcomes after use of a four-factor prothrombin complex concentrate for Vitamin K antagonist reversal in a real-world setting. *Transfusion.* 2016;56(4):799-807.
15. Hankerson MJ, Raffetto B, Mallon WK, et al. Nebulized tranexamic acid as a noninvasive therapy for cancer-related hemoptysis. *J Palliat Med.* 2015;18(12):1060-2.

A Case Report Highlighting That Silica Gel Products Are Not Always Benign

Nolan Lassiter, BA*
Nhia Yang, DNP†
Lakshma Tiyyagura, MD‡
K. Scott Whitlow, DO§

*Touro University - California - College of Osteopathic Medicine, Vallejo, California
†Sacramento City College, Stockton, California
‡Gastroenterology, Stockton, California
§Touro University - California - College of Osteopathic Medicine, Department of Emergency Medicine, Vallejo, California

Section Editor: Rick A. McPheeters, DO

Submission history: Submitted April 13, 2020; Revision received July 26, 2020; Accepted July 31, 2020

Electronically published October 9, 2020

Full text available through open access at http://escholarship.org/uc/uciem_cpem

DOI: 10.5811/cpcem.2020.7.47673

Introduction: Silica gel packets are commonly used desiccants for medication products; these packets generally only pose a choking risk in young children. However, new cylindrical desiccant canisters have been developed, which may increase the risk for obstruction in adults.

Case Report: An elderly male presented to the emergency department complaining of difficulty swallowing after taking his morning medications. Through a diligent work-up a desiccant canister was found lodged in the lower esophageal sphincter. The patient was endotracheally intubated and a Roth Net retriever was used to remove the canister.

Conclusion: Cylindrical desiccant canisters pose an increased risk of esophageal obstruction. [Clin Pract Cases Emerg Med. 2020;4(4):576–579.]

Keywords: *Silica gel; esophageal obstruction; desiccant.*

INTRODUCTION

Silica gel products are usually considered minimally toxic substances and primarily pose a risk of choking hazard in young children.¹ Acute and prolonged oral ingestion of silica is not associated with toxicities of note.² In fact, oral silica gel ingestion is considered so innocuous that it is used in the formulation of solid drugs to serve as a lubricant.³ However, this is not to say that silica gel is an entirely benign substance. It has been known to rarely cause silicosis, a fibrotic lung disease that develops due to occupational exposure of respirable silica, with a death rate of 0.74 per one million in 2010.^{4,5}

Silica gel packets are a common device used as desiccants and are generally made of a paper or cloth that allows the silica to remove moisture from its environment.² The packets serve as such for many over-the-counter and prescription medication products. These packets are frequently ingested by young children, accounting for 2.1% of the annual calls to poison control centers. Fortunately, a vast majority of ingested

silica results in an innocuous event, while only occasionally resulting in self-limited mouth and throat discomfort.⁶ Until recently, silica gel has ubiquitously been packaged in paper or cloth packets that have posed a simple choking hazard in young children (Image 1). However, medical device

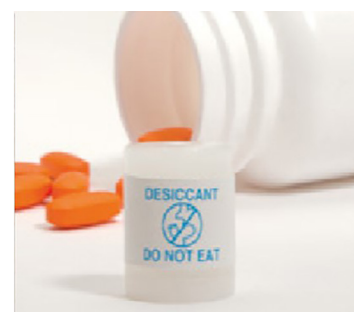

Image 1. (Left) Image of traditional desiccant package.¹ (Right) Image of new desiccant cylindrical canister for medications.⁷

manufacturers have developed a new cylindrical canister that can serve as housing for the silica gel desiccant to be stored with medications (Image 1). These new cylindrical desiccant containers may pose a significant choking hazard in adults. We report a case of a 70-year-old male with a complaint of a foreign body (FB) sensation in his esophagus, chest pain, and an inability to swallow, who unknowingly ingested one of these cylindrical desiccant containers with his daily medications.

CASE REPORT

A 70-year-old male presented to an urban community emergency department (ED) complaining of substernal chest pain, FB sensation in his esophagus, and difficulty swallowing after taking his multiple, morning oral medications. He stated that he felt as if “something had gotten stuck in his throat” after taking his morning medications. The patient had a past medical history significant for chronic dysphagia, Barrett’s esophagus, congestive heart failure, nystagmus, hyperlipidemia, hypertension, renal insufficiency, and lower esophageal sphincterotomy. After undergoing evaluations for chest pain and epigastric pain, which were negative, he was tolerating per oral (PO) fluids post glucagon and metoclopramide therapy. The ED care team concluded the patient could be discharged safely for out-patient follow-up. A final ambulatory test and a second PO challenge were administered prior to discharge. Upon this PO challenge he reported that he was again unable to swallow PO liquids and had a return of the feeling of “a knot in my esophagus.”

The discharge was halted, and a non-contrast computed tomography (CT) of the chest was ordered to evaluate the esophagus for stricture or FB. The CT results showed a 15-millimeter (mm) FB located within the gastroesophageal (GE) junction/lower esophageal sphincter (LES) causing a moderately distended and fluid-filled esophagus (Image 2). The ED care team again attempted

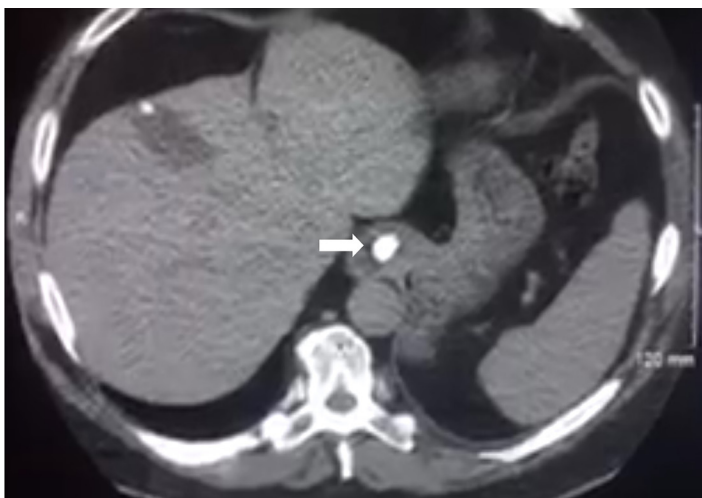


Image 2. Image of this patient’s computed tomography with the foreign body located near the gastroesophageal junction (arrow).

CPC-EM Capsule

What do we already know about this clinical entity?

There is one previously reported incident of a desiccant canister causing esophageal obstruction in a patient with pre-existing esophageal stricture.

What makes this presentation of disease reportable?

Obstruction occurred at the gastroesophageal junction in a patient with esophageal stricture.

What is the major learning point?

Cylindrical desiccant canisters may easily be mistaken for medications and cause harm in patients with esophageal strictures.

How might this improve emergency medicine practice?

Risk of esophageal obstruction has increased in the elderly who take many medications and could easily confuse the canister for a pill.

to mechanically and pharmacologically dislodge the distal FB but was unsuccessful. The fluid in the esophagus was suctioned via insertion of a nasogastric tube to prevent aspiration and to empty the esophagus for possible esophagogastroduodenoscopy (EGD).

The patient was admitted to the hospitalist service with a gastroenterology consultation for urgent EGD. Upon further inspection with an EGD, the desiccant canister was found in the GE junction along with esophageal strictures (Image 3). The EGD was initially performed under procedural sedation but the endoscopist was also unable to advance the FB through the GE junction with the endoscope alone. The endoscopist then had the patient endotracheally intubated, placed under deep sedation, and performed a second EGD attempt to remove the FB via a Roth Net retriever (STERIS Healthcare, Mentor, OH), which was successful. The FB, after successful removal, was determined to be a cylindrical silica gel canister measuring 11.5 mm. There were no complications secondary to the EGD, deep sedation, intubation, or removal of the FB. The patient tolerated the procedure well, was extubated quickly post EGD and was discharged home after recovery with instructions to follow up with the gastroenterologist as an outpatient. He was also educated

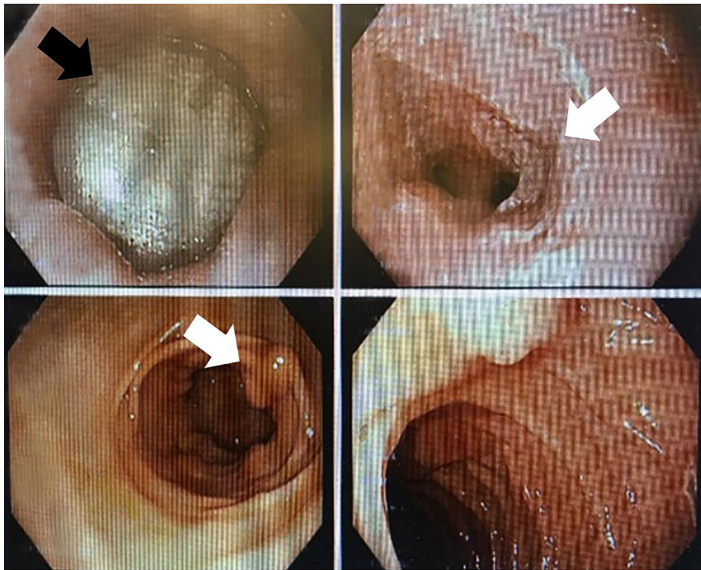


Image 3. Image of this patient's esophagogastroduodenoscopy with the foreign body in sight at the gastroesophageal junction displaying the esophageal strictures (white arrows) as well as the trapped desiccant canister (black arrow).

to avoid taking multiple medications at once without identifying them.

DISCUSSION

These relatively recently deployed, cylindrical, silica gel containers, such as the one in this case, are filled with desiccants like bentonite clay and silica gel, with a purpose of moisture absorption to keep products dry and control odors. This patient presented with an esophageal obstruction caused by accidental ingestion of a cylindrical silica gel canister while administering his own medications. He had a history of a known high-grade esophageal stricture, making the risk of esophageal FB obstruction higher and the potential retrieval process even more challenging. In such a case, any patient with any form of esophageal stricture and a retained esophageal FB will require endoscopic retrieval to remove it, if medical management fails.¹⁰ The clinical decision to implement the use of the Roth Net retriever to remove the FB was based on the failure of simple advancement of the FB into the stomach, the patient's history of esophageal stricture, and radiographic (CT) imaging providing the precise location and size of the FB.⁸ The retrieved FB was an 11.5-mm cylindrical, silica gel container. The patient did well without any complications after the procedure.

A similar obstruction by a desiccant canister in a patient with pre-existing esophageal strictures was reported in 2015; however, in that case the canister became lodged in the esophagus unlike in our case where the canister was lodged in the LES and GE junction.¹⁰ As evidenced

in this case report and the previously reported literature, the new cylindrical desiccant canisters pose an increased risk of esophageal obstruction in patients with high risk of esophageal obstruction, such as pre-existing esophageal strictures. As patients are frequently required to take many medications daily, it should not be surprising that one could inadvertently ingest a desiccant canister that may be the same color and relative shape of medications themselves, especially if the patient is older with decreased visual acuity.

These desiccant containers appear to have been designed for efficiency of manufacturing and insertion into bottles or other containers. A pamphlet from Clariant, a chemical company that specializes in helping medical device companies with production as well as creating chemicals and polymers used in medical devices such as silica desiccant canisters, describes the canisters as having an “[i]nnovative design and construction [that] allow[s] these components to be inserted automatically at high rates of speed.”⁷ Additionally, the product sheet for the rigid desiccant canisters (for high-speed automatic insertion) describes the product as being “cost-efficient” and having a “robust design.”⁷ All these descriptions place an emphasis on production efficiency and cost reduction.

We attempted to obtain the drug master file to evaluate the pre- and post-market experience with these containers. However, those attempts were unsuccessful. It appears, via our review of the literature regarding these devices, that desiccant companies have attempted to design various fail-safes within the desiccant product design, such as changing the “do not eat” label from blue to a bright red to potentially decrease the risk of mistaking the canister for medication,¹¹ but medications come in all colors and, in many cases, similar shapes and sizes. These visual factors, in tandem with the canister's rigid and non-malleable design in comparison to traditional desiccant packets, increases the risk of obstruction and subsequent complications that may increase morbidity in older, at-risk populations.

CONCLUSION

Cylindrical desiccant canisters pose an increased risk of esophageal obstruction in patients with high risk of esophageal obstruction, such as a pre-existing esophageal stricture. The transition from paper/cloth desiccant packaging to a non-malleable cylindrical canister may improve production efficiency and cut costs but has unintentionally increased the risk profile of silica gel, which was previously considered an innocuous substance.

The authors attest that their institution requires neither Institutional Review Board approval, nor patient consent for publication of this case report. Documentation on file.

Address for Correspondence: Nolan Lassiter, BA, Touro University - California - College of Osteopathic Medicine, 1320 Club Drive, Vallejo, CA 94592. Email: Nolan.lassiter@tu.edu.

Conflicts of Interest: By the CPC-EM article submission agreement, all authors are required to disclose all affiliations, funding sources and financial or management relationships that could be perceived as potential sources of bias. The authors disclosed none.

Copyright: © 2020 Lassiter et al. This is an open access article distributed in accordance with the terms of the Creative Commons Attribution (CC BY 4.0) License. See: <http://creativecommons.org/licenses/by/4.0/>

REFERENCES

1. Illinois Poison Center. My child ate silica gel. 2020. Available at: <https://www.illinoispoisoncenter.org/my-child-ate-silica-gel>. Accessed March 25, 2020.
2. U.S Department of Health and Human Services. Toxicological Profile for Silica (p.8-243). 2019. Available at: <https://www.atsdr.cdc.gov/ToxProfiles/tp211.pdf>. Accessed March 25, 2020.
3. Diab R, Canilho N, Pavel IA, et al. Silica-based systems for oral delivery of drugs, macromolecules and cells. *Adv Colloid Interface Sci.* 2017;249:346-62.
4. Leung CC, Yu ITS, Chen W. Silicosis. *Lancet.* 2012;379(9830):2008-18.
5. Bang KM, Mazurek JM, Wood JM, et al. Silicosis mortality trends and new exposures to respirable crystalline silica - United States, 2001-2010. *MMWR Morb Mortal Wkly Rep.* 2015;64(5):117-20.
6. Lavon O and Bentur Y. Silica gel: non-toxic ingestion with epidemiologic and economic implications. *Isr Med Assoc J.* 2015;17(10):604-6.
7. Clariant. Healthcare Packaging: Protection Against Moisture & Oxygen. 2017. Available at: https://www.cphi-online.com/46/resourcefile/08/97/62/Clariant_Healthcare_Packaging_Brochure.pdf. Accessed March 24, 2020.
8. Bounds B. (2006). Endoscopic Retrieval Devices. *ITGE.* 2006;8(1):16-21.
9. Kragha KO. Complete gastroesophageal obstruction by food bolus. *Applied Radiology.* 2016;45(9):40-4.
10. Barkin JA and Barkin JS. Desiccant-induced esophageal obstruction: an emerging patient safety issue. *ACG Case Rep J.* 2015;2(2):67.
11. Clariant. Clariant: Desiccant Canisters with Red Labels. Healthcare Packaging. 2017. Available at: <https://www.healthcarepackaging.com/markets/pharmaceutical/press-release/13291940/clariant-desiccant-canisters-with-red-labels>. Accessed March 27, 2020.

Case Report and Literature Review: Post-Arthroscopy Pneumothorax with Anterior Decompression

Marc A. Cassone, DO*
Kristin L. Kish, DO*
Jordan R. Nester, MD†
Lisa M. Hoffman, DO*

*Geisinger Medical Center, Department of Emergency Medicine, Danville, Pennsylvania
†Geisinger Medical Center, Department of Orthopedic Surgery, Danville, Pennsylvania

Section Editor: Christopher Sampson, MD

Submission history: Submitted June 8, 2020; Revision received July 28, 2020; Accepted August 6, 2020

Electronically published October 9, 2020

Full text available through open access at http://escholarship.org/uc/uciem_cpem

DOI: 10.5811/cpcem.2020.8.48618

Introduction: Emergency providers should recognize that pneumothorax is a rare but serious complication of shoulder arthroscopy that may require a unique approach to decompression.

Case Report: We present a case of a 60-year-old female who presented to the emergency department with right-sided facial swelling, voice change, and shortness of breath three hours after an elective arthroscopic right rotator-cuff repair and was noted to have a right-sided pneumothorax. We also describe a potential novel approach to chest tube decompression that maintains shoulder adduction in patients with recently repaired rotator cuffs.

Conclusion: Although most cases of post-arthroscopy pneumothoraces are reported in patients who received regional anesthesia or have underlying lung pathology, it can occur in lower-risk patients as was demonstrated in our case. We also suggest considering an alternative anterior approach between the midclavicular and anterior axillary lines for chest decompression in select patients when a traditional approach is less ideal due to the need to maintain shoulder immobilization postoperatively. [Clin Pract Cases Emerg Med. 2020;4(4):580–583.]

Keywords: *Shoulder surgery complication; subcutaneous emphysema; chest tube; thoracostomy.*

INTRODUCTION

Over the past few decades shoulder arthroscopy has become an increasingly common technique to treat shoulder pathology. Proponents cite a decreased complication rate when compared to open procedures.¹ Others report not necessarily a lower complication rate but a different set of complications altogether including neurovascular injuries, infection, venous thromboembolic events, pneumothoraces, and soft tissue and neuropraxic injuries due to positioning.² We present a case of a 60-year-old female who presented to the emergency department (ED) with right-sided facial swelling, voice change, and shortness of breath three hours after an elective arthroscopic, right rotator cuff repair and was noted to have a right-sided pneumothorax. Patients undergoing shoulder repair often require immobilization to ensure proper alignment and healing that may limit anatomic placement of chest

thoracostomy tubes. We suggest a possible variation of the traditional approach that may be considered in these cases.

CASE REPORT

A 60-year-old female presented to the ED with right-sided facial swelling, voice change, and shortness of breath three hours after an elective, arthroscopic, right rotator cuff repair. The outpatient surgery comprised a subacromial decompression, major glenohumeral joint debridement, and rotator cuff repair for right shoulder chronic impingement syndrome, intra-articular biceps tear, and full thickness rotator cuff tear. The surgery was performed in the lateral decubitus position under general anesthesia and without regional nerve block. The anesthesia report was reviewed and showed no major complications or episodes of hypotension or desaturation. The patient reported feeling well postoperatively;

however, three hours later she developed right-sided face and neck swelling (Image 1), voice changes, and dyspnea, and thus presented to the ED for further evaluation.

The patient denied significant past medical history including any history of smoking or underlying lung or connective tissue disease. On arrival, her vitals were heart rate 92 beats per minute, blood pressure 135/80 millimeters mercury, respiratory rate 18 breaths per minute, and pulse oximetry was 96% on room air. Her physical exam was notable for predominately right-sided facial swelling, diminished right-sided lung sounds, and crepitus of the right neck, face, and chest. A chest radiograph showed a right-sided pneumothorax of approximately 70% with mediastinal shift and extensive subcutaneous emphysema (Image 2).

A pigtail catheter-type chest drain was placed in the fifth intercostal space between the right midclavicular and anterior axillary line so as to not abduct or displace the patient's shoulder given her recent rotator cuff repair. Successful expansion of the lung was noted (Image 3).

On the third day of admission, the chest tube was removed and the patient was discharged home without further complications. At her two-week follow-up, her shoulder was healing well and she had no significant sequelae from her pneumothorax.

DISCUSSION

Only a handful of case reports and case series describe an association between arthroscopic shoulder surgery and postoperative pneumothorax³⁻⁸; however, cases may be under-reported. It has been postulated that these may be related to preoperative regional anesthesia (notably the interscalene brachial plexus block),^{5,6,8} intubation and related airway trauma,^{3,9} as well as injury to the parietal pleura from laparoscopy including continuous positive pressure-driven pump infusion in the joint space or intra-articular shaving.^{3,7} Patient positioning, including the beach chair vs lateral decubitus, has also been posited as an increased risk for pneumothorax.⁷ Of the cases reported, the majority had underlying lung disease (chronic obstructive

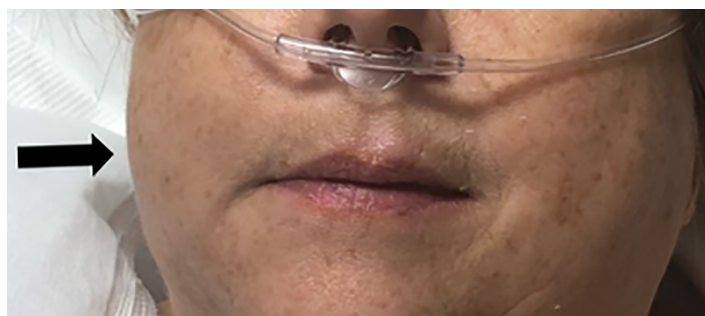

Image 1. Right-sided facial swelling and crepitus noted several hours postoperatively. Patient also reported voice change and dyspnea. Facial swelling denoted by arrow.

CPC-EM Capsule

What do we already know about this clinical entity?

Pneumothoraces have been reported as a possible complication of shoulder arthroscopy.

What makes this presentation of disease reportable?

We present a case of a rare complication of a common procedure and suggest a less common procedural approach to treating pneumothorax.

What is the major learning point?

Pneumothorax is a rare but serious complication of shoulder arthroscopy that may require a unique approach to decompression.

How might this improve emergency medicine practice?

This variation to traditional pneumothorax decompression technique could help avoid re-injury of the rotator-cuff repair site.

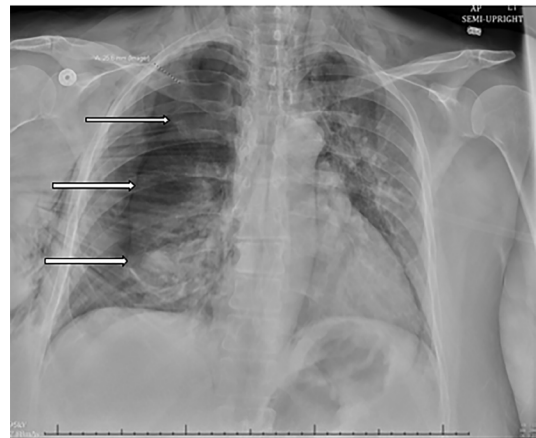


Image 2. A 70% large right-sided pneumothorax (arrows) with left-sided mediastinal shift and extensive subcutaneous emphysema ("gingko leaf sign").

pulmonary disease, asthma, chronic tobacco abuse).^{5,6} For cases not related to regional anesthesia, all those reported occurred within 1-24 hours of surgery.³⁻⁸ Hospital courses were largely unremarkable, and most patients were discharged within two to five days of presentation³⁻⁸ with

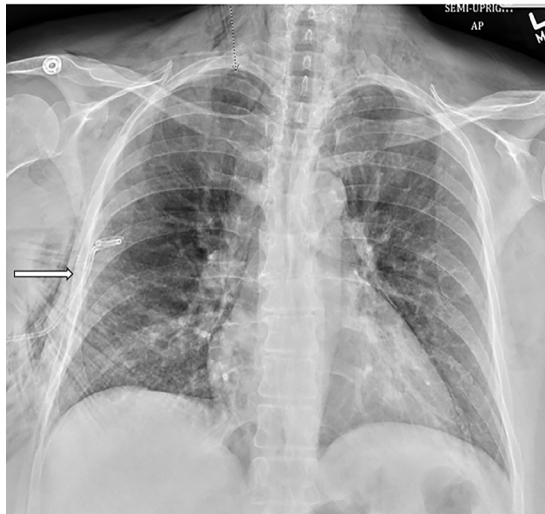

Image 3. Successful lung re-expansion after right-sided pigtail catheter (arrow) was placed using a more anterior approach. Note improved mediastinal shift.

the most common complication reported being chest tube leak.^{4,5} The vast majority of reported cases presented with either face, neck, or chest subcutaneous air on exam or imaging,³⁻⁸ and only one episode of hypotension from tension pneumothorax was reported.³

Emergency providers have traditionally placed tube thoracostomy drains at the fourth or fifth intercostal space at the midaxillary or anterior axillary line¹⁰ to allow for effective decompression and to avoid injury to mediastinal, cervical, and sub-diaphragmatic structures. However, to preserve the shoulder immobilization in the adducted position, the providers in this case placed the pigtail catheter at the fifth intercostal space between the midclavicular and anterior axillary line. No neurovascular injuries or injuries to mediastinal structures were noted during the procedure or in the subsequent days prior to removal. While decompression of the pneumothorax (especially with signs of mediastinal shift) should supersede the need to keep postoperative immobilization, we suggest this as a variation to the approach of the traditional technique to help avoid re-injury of the rotator cuff repair site. Complications of this more anterior approach could include injury to the lateral thoracic artery, long thoracic nerve, and local lymphatics; providers should ensure proper needle insertion technique and note local neurovascular findings before and after decompression. However, even using the traditional approach between the midaxillary or anterior axillary line can lead to local neurovascular injury.¹¹

Limitations to this new approach include left-sided pneumothorax (given proximity to mediastinal structures), obese patients, large area of breast tissue, or use of larger caliber chest tubes. Placing the pigtail catheter at the second intercostal space midclavicular line is a viable alternative in

these cases¹²; however, this technique is not without complications in correct placement,¹³ efficacy,¹⁴ or local vascular injury.¹⁵ Providers should evaluate patients on a case-by-case basis to determine the best approach for decompression. The variation on a traditional approach described in this case offers an alternative option in postarthroscopy patients; however, the authors recommend further studies to confirm safety and efficacy compared to other techniques.

CONCLUSION

Emergency providers should recognize pneumothorax as a rare but serious complication of shoulder arthroscopy. Although most cases reported are in patients who received regional anesthesia or have underlying lung pathology, it can occur in lower-risk patients as was demonstrated in our case. Patients may present with classical findings of pneumothorax including dyspnea, decreased breath sounds, and signs of tension including mediastinal shift. Postarthroscopy pneumothoraces nearly always present with crepitus on exam or subcutaneous air on imaging. The majority of these cases tolerate decompression without issues and patients are discharged within several days without complications. Providers may consider follow-up computed tomography imaging in patients without prior lung disease to assess for underlying lung disease or structural pathology including blebs. We also suggest considering an alternative anterior approach between the midclavicular and anterior axillary lines for chest decompression in select patients when a traditional approach is less ideal due to the need to maintain shoulder immobilization postoperatively; however, more research is needed to confirm safety and efficacy.

The Institutional Review Board approval has been documented and filed for publication of this case report. Patient consent has been obtained and filed for the publication of this case report.

Address for Correspondence: Marc A Cassone, DO, cc: Chadd Kraus, DO, Geisinger Medical Center, Department of Emergency Medicine, 100 N Academy Ave, Danville, PA 17822. Email: Cassone.marc@gmail.com.

Conflicts of Interest: By the CPC-EM article submission agreement, all authors are required to disclose all affiliations, funding sources and financial or management relationships that could be perceived as potential sources of bias. The authors disclosed none.

Copyright: © 2020 Cassone et al. This is an open access article distributed in accordance with the terms of the Creative Commons Attribution (CC BY 4.0) License. See: <http://creativecommons.org/licenses/by/4.0/>

REFERENCES

1. Weber SC, Abrams JS, Nottage WM. Complications associated with arthroscopic shoulder surgery. *Arthroscopy*. 2002;18(2):88-95.
2. Moen T, Rudolph G, Caswell K, et al. Complications of shoulder arthroscopy. *J Am Acad Orthop Surg*. 2014; 22(7):410-9.
3. Bamps S, Renson D, Nijs S, et al. Pneumothorax after shoulder arthroscopy: a rare but life-threatening complication. *J Orthop Case Rep*. 2016;6(4):3-5.
4. Asghar S, Azam M, Gjeka R, et al. Spontaneous pneumothorax with extensive subcutaneous emphysema: a rare complication of shoulder arthroscopy. *Chest*. 2015;148(4):34.
5. Leander-Olsson O, Borglun-Hemph A, Jakobsson J. Pneumothorax following shoulder arthroscopy under combined regional and general anesthesia: a case report. *Int Jour Case Rep Imag*. 2016;24:73-6.
6. Calvisi V, Lupporelli S, Rossetti S. Subcutaneous emphysema and pneumomediastinum following shoulder arthroscopy with brachial plexus block: a case report and review of the literature. *Arch Orthop Trauma Surg*. 2009;129(3):349-52.
7. Lee HC, Dewan N, Crosby L. Subcutaneous emphysema, pneumomediastinum, and potentially life-threatening tension pneumothorax: pulmonary complications from arthroscopic shoulder decompression. *Chest*. 1992;101(5):1265-7.
8. Tandon S, Taxak S, Gupta KB, et al. Pneumomediastinum: a rare complication of brachial plexus block. *Indian J Chest Dis Allied Sci*. 1998;40(3):217-9.
9. Marty-Ané CH, Picard E, Jonquet O, et al. Membranous tracheal rupture after endotracheal intubation. *Ann Thorac Surg*. 1995;60(5):1367-71.
10. Margolis AM and Kirsch KD. (2019). Tube thoracostomy. In JR Hedges, JR Roberts (Eds.), *Roberts and Hedges' Clinical Procedures in Emergency Medicine and Acute Care* (p. 196-220). Philadelphia, PA: Elsevier.
11. Wraight WM, Tweedie DJ, Parkin IG. Neurovascular anatomy and variation in the fourth, fifth, and sixth intercostal spaces in the mid-axillary line: a cadaveric study in respect of chest drain insertion. *Clin Anat*. 2005;18(5):346-9.
12. Gammie JS, Banks MC, Fuhrman CR, et al. The pigtail catheter for pleural drainage: a less invasive alternative to tube thoracostomy. *JSLs*. 1999;3(1):57-61.
13. Ferrie EP, Collum N, McGovern S. The right place in the right space? Awareness of site for needle thoracocentesis. *Emerg Med J*. 2005;22(11):788-9.
14. Inaba K, Ives C, McClure K, et al. Radiologic evaluation of alternative sites for needle decompression for tension pneumothorax. *Arch Surg*. 2012;147(9):813-8.
15. Rawlins R, Brown KM, Carr CS, et al. Life threatening haemorrhage after anterior needle aspiration of pneumothoraces. A role of lateral needle aspiration in emergency decompression of spontaneous pneumothorax. *Emerg Med J*. 2003;20(4):383-4.

One Notable Complication of Nasopharyngeal Airway: A Case Report

Blake Briggs, MD*
Chase Countryman, MD†
Henderson D. McGinnis, MD†

*University of South Alabama, Department of Emergency Medicine, Mobile, Alabama
†Wake Forest School of Medicine, Department of Emergency Medicine, Winston-Salem, North Carolina

Section Editor: Joel Moll, MD

Submission history: Submitted June 18, 2020; Revision received July 27, 2020; Accepted August 6, 2020

Electronically published October 20, 2020

Full text available through open access at http://escholarship.org/uc/uciem_cpchem

DOI: 10.5811/cpchem.2020.8.48811

Introduction: The nasopharyngeal airway (NPA) is used by emergency providers and first responders to assist with oxygenation in obtunded, critically ill patients. There are few recorded NPA complications.

Case Report: We describe a unique case in which a patient went multiple days with recurrent symptoms of upper airway obstruction secondary to retained NPA.

Discussion: Nasopharyngeal airways may be uniquely prone to being displaced and retained due to their use in emergent situations, their small size, and time of insertion in the field prior to emergency department (ED) contact where handoff is not often standardized.

Conclusion: The use of large-flanged NPAs might reduce incidences of displacement into the nasal cavity. This case highlights the need for improved handoff communication between emergency medical services and ED staff, especially to account for all inserted devices to prevent foreign body retention. [Clin Pract Cases Emerg Med. 2020;4(4):584–586.]

Key words: *Nasopharyngeal airway; nasal foreign body; EMS, emergency department communication; retained foreign bodies.*

INTRODUCTION

Emergency providers and first responders often use airway adjuncts to assist with oxygenation in obtunded, critically ill patients. These adjuncts also assist ventilation and improve possible airway obstruction. The nasopharyngeal airway (NPA), or “nasal trumpet,” is one such device. Made of soft plastic or rubber, it is inserted into the naris to assist in maintaining oxygenation in the upper airway. It can be kept in place while endotracheal intubation is being performed to increase passive apneic oxygenation. The NPA is soft with a beveled tip to reduce trauma during insertion. The flared end on the opposite end is designed to prevent displacement of the NPA deeper into the nasopharynx where there would be difficulty in retrieving it.¹ The size, design, and malleability of NPAs greatly vary, depending on the manufacturer. In particular, there is great difference in the flared end, with some having a large flange while others small. When inserting, the beveled tip of the NPA should lie no lower than the uvula.¹

There are few recorded NPA complications. Perhaps the most clinically observed complication is stimulation of the gag reflex, along with epistaxis secondary to mucosal injury. A literature search revealed two reports of intracranial NPA placement in patients with basilar skull fractures, much like cases detailing nasogastric tube malposition.² Additionally, we found a report of a middle turbinate fracture secondary to NPA placement resulting in severe epistaxis.³ In the case report presented here, we describe the retention of an NPA as a nasal foreign body (FB) causing acute upper airway obstruction. After an extensive search on PubMed, we found only one similar case report on this topic; however, this issue has not been discussed in the emergency medicine literature. In that earlier case, a retained NPA in the anterior nasopharynx for nearly 20 months was found to be causing dysphagia and odynophagia.⁴ Importantly, our case is unique in that the patient went multiple days with recurrent upper airway symptoms, including dyspnea, choking, and desaturation events on the monitor.

Considering that emergency providers and emergency medical services (EMS) frequently use these devices, we review this potentially serious complication and raise awareness for safer applications of NPAs.

CASE REPORT

A 79-year-old male with a past medical history of type 2 diabetes, chronic bronchitis, coronary artery disease, and hypertension, presented with county EMS in acute respiratory failure. Per report at the scene, the patient was found unconscious and received 1 milligram of Narcan and atropine for bradycardia. On arrival the patient was receiving assisted ventilation via bag-valve-mask (BVM). He was subsequently intubated. Intubation was without difficulty and was performed by direct laryngoscopy on the first attempt by the emergency physician. The patient was admitted to the medical ICU.

Three days later the patient was extubated after improvement in his clinical condition. Following extubation, he continued to experience brief episodes of oxygen desaturations to the low 80s and endorsed the sensation of “something stuck in my throat.” He had a persistent cough, dyspnea at rest, and a feeling that he could not swallow. After speech therapy was consulted for evaluation, a FB was discovered during their nasal fiberoptic evaluation (Images 1-2). The FB was immediately superior to the larynx, and strongly suspected to be a cause of the patient’s symptoms. Otolaryngology (ENT) was consulted, and the FB was removed at bedside using Magill forceps without complication. After close examination, the FB was found to be an NPA. When reviewing medical records, it was found that the emergency physician and nurses had made no note of the NPA. It was concluded the NPA was likely placed by EMS in the field and had subsequently been displaced deep into the nasal cavity in transport and when ventilating via BVM. The patient continued the remainder of his hospital course without issue and was discharged one week later.




Image 1. Nasal fiberoptic view of a retained nasopharyngeal airway (arrow) just distal to the right naris.

CPC-EM Capsule

What do we already know about this clinical entity?

Nasopharyngeal airways (NPA), when retained as a foreign body, can cause lasting clinical detriment including recurrent discomfort and dyspnea.

What makes this presentation of disease reportable?

While considered safe they can be easily forgotten. A retained NPA caused lasting discomfort and likely increased the patient’s length of stay.

What is the major learning point?

An NPA, like any inserted foreign body, should be clearly listed during hand off.

How might this improve emergency medicine practice?

Clearer communication between first responders and emergency providers regarding all airway adjuncts could reduce complications with these tools.

He was not discharged with any new medications, and follow-up with ENT was arranged; however, there is no medical chart evidence that the patient followed up with ENT.

DISCUSSION

This case highlights several safety issues that NPAs present to care teams, particularly EMS and emergency providers. The *Journal of the American Medical Association of Otolaryngology* published a report of a similar occurrence in 2019, which discussed a retained NPA that was placed by EMS in the field and ultimately remained in the patient for 20 months before surgical extraction. During the 20-month interim, the patient had dysphagia and odynophagia but continued to eat. He did not report symptoms of acute upper airway obstruction, such as dyspnea, cough, or stridor.⁴ In contrast, the patient in our case went multiple days with recurrent upper airway symptoms, including dyspnea, choking, and oxygen desaturation events on the monitor to the low 80s. Additionally, he could not tolerate swallowing well and did not pass his bedside- nursing swallowing evaluation; hence speech therapy was consulted. The NPA was found incidentally during the swallowing trial.

The flange size on a NPA may predispose it to displacement. In our case, the NPA that was removed had a small flange. This finding, along with the added difficulty of managing a critically ill

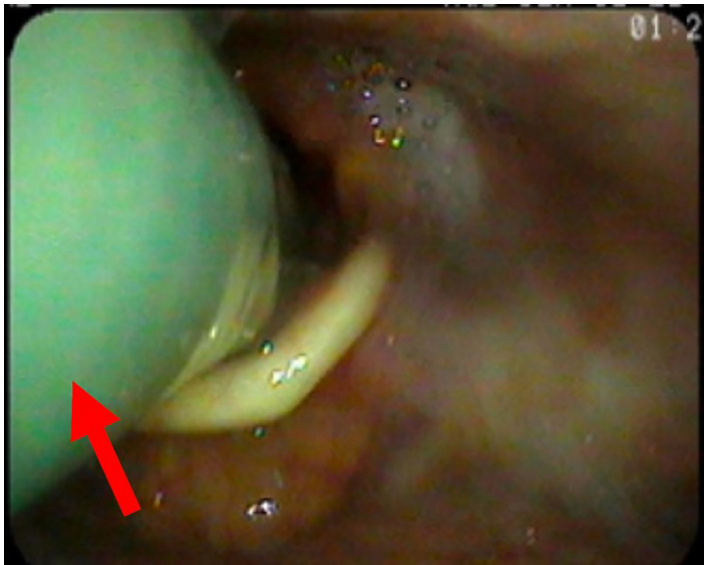


Image 2. Nasal fiberoptic view of a retained nasopharyngeal airway (arrow) just superior to the larynx and posterior to the epiglottis.

patient in the field and mask seal during BVM ventilation, contributed to the NPA being dislodged and going unnoticed during intubation. One method to reduce NPA complications is immediate removal once a definitive airway is secured.

Additionally, the NPA might have been the incorrect size for the patient. In general, the longer the NPA, the larger the diameter of the tube. For example, 8.0-9.0 centimeters (cm) is reserved for large adults, while 7.0-8.0 cm is standard adult size, and 6.0-7.0 cm is for smaller adults.¹ Correct size can be estimated by placing the NPA next to the patient's face with the flared end in line with the naris and the beveled tip toward the ear lobe. The goal is for the NPA to just reach the ear lobe.

This case also highlights the importance of closed-loop communication between healthcare teams. In the operating room, a rigid set of safety protocols exist to prevent iatrogenic-retained FBs. Our PubMed literature search revealed no such standardized processes in EDs, particularly during handoff from EMS to ED staff. Clear communication between the ED, EMS, and intensive care unit personnel about the types of airway adjuncts and assist devices in place are critical in reducing the likelihood of a retained FB. Iatrogenic FBs are a significant source of morbidity and cost to the patient. A study in the *Journal of the American College of Surgeons* found that retained FBs from a variety of situations are associated with higher cost of service and are more likely to occur in geriatric and obese patients.⁵

Nasopharyngeal airways are widely considered safe airway management tools that can be quickly deployed. These airway tools are portable and cost effective, and are actively used prior to establishing a definitive airway. Despite their widespread use, NPAs are not without complications, and there is always a potential risk for displacement and retention as a FB. To prevent this, clear communication that begins in the field with EMS, followed by proper handoff in the ED is essential. We also advise

early removal of an NPA post-intubation, as well as the use of large-flanged NPAs to reduce chances of displacement into the nasal cavity.

CONCLUSION

Nasopharyngeal airways are frequently used as a first-line airway adjunct in critically ill patients. They offer the unique benefit of easy placement and rapid portability from their size. However, NPAs may be uniquely prone to being displaced and retained due to their use in emergent situations, their small size, and time of insertion in the field prior to ED contact where handoff is not often standardized. Special consideration should be paid during patient handoffs as NPAs can prove quite difficult to identify at later stages in patient care. We advise that a more detailed documentation occur in the ED when a patient arrives with multiple devices in place, whether it be nasogastric or orogastric tubes, NPAs, oropharyngeal airways, intravenous access, or drains. The use of large-flanged NPAs might reduce incidences of displacement into the nasal cavity.

Patient consent has been obtained and filed for the publication of this case report.

Address for Correspondence: Blake Briggs, MD, University of South Alabama, Department of Emergency Medicine, 307 N University Blvd, Mobile, AL 36688. Email: brigbc271@gmail.com.

Conflicts of Interest: By the *CPC-EM* article submission agreement, all authors are required to disclose all affiliations, funding sources and financial or management relationships that could be perceived as potential sources of bias. The authors disclosed none.

Copyright: © 2020 Briggs et al. This is an open access article distributed in accordance with the terms of the Creative Commons Attribution ([CC BY 4.0](http://creativecommons.org/licenses/by/4.0/)) License. See: <http://creativecommons.org/licenses/by/4.0/>

REFERENCES

1. Roberts K, Whalley H, Bleetman A. The nasopharyngeal airway: dispelling myths and establishing the facts. *Emerg Med J.* 2005;22(6):394-6.
2. Ellis DY, Lambert C, Shirley P. Intracranial placement of nasopharyngeal airways: Is it all that rare? *Emerg Med J.* 2006;23(8):661.
3. Zwank M. Middle turbinectomy as a complication of nasopharyngeal airway placement. *Am J Emerg Med.* 2009;27(4):513.e3-513004.
4. Kim BJ, Shoffel-Havakuk H, Johns MM. Retained nasal trumpet for 20 months: an unusual foreign body. *JAMA Otolaryngol Head Neck Surg.* 2019;145(1):93-4.
5. Al-Qurayshi ZH, Hauch AT, Slakey DP, et al. Retained foreign bodies: risk and outcomes at the national level. *J Am Coll Surg.* 2015;220(4):749-59.

Case Report of a Left-sided Superior Vena Cava Causing Unique Positioning of Central Line

Michael Mancera, MD*
Nicholas Genthe, BS†
Nicholas Lepa, MD*

*University of Wisconsin, BerbeeWalsh Department of Emergency Medicine,
Madison, Wisconsin

†University of Wisconsin School of Medicine and Public Health, Madison, Wisconsin

Section Editor: Shadi Lahham, MD

Submission history: Submitted May 26, 2020; Revision received August 11, 2020; Accepted August 10, 2020

Electronically published October 9, 2020

Full text available through open access at http://escholarship.org/uc/uciem_cpchem

DOI: 10.5811/cpchem.2020.8.48372

Introduction: Persistent left-sided superior vena cava is a rare congenital venous malformation. While often clinically asymptomatic, these variations in normal anatomy may give rise to complications with central venous catheter placement.

Case Report: We present a case of a 71-year-old male who presented to the emergency department with sepsis of unknown etiology. A right-sided central venous catheter was placed, and due to a persistent left-sided superior vena cava the post-procedure chest radiograph showed a uniquely positioned catheter tip within the left atrium.

Conclusion: A persistent left-sided superior vena cava may lead to uniquely positioned catheter tip placement on post-procedural imaging. This case demonstrates the need to consider variants in normal venous anatomy, such as persistent left-sided superior vena cava, to aid with correct interpretation of post-procedure imaging findings. [Clin Pract Cases Emerg Med. 2020;4(4):587–590.]

Keywords: *Left sided superior vena cava; congenital venous malformation; malpositioned central venous catheter.*

INTRODUCTION

A persistent, left-sided superior vena cava (SVC) is a congenital venous anomaly in the chest that results when the left anterior cardinal vein is not obliterated during normal fetal development. The incidence of a left-sided SVC is 0.3-0.5% in the general population, and increases to 4.5% in individuals with congenital heart defects.¹ Of patients with a left-sided SVC, 90% will have an accompanying right-sided SVC, termed SVC duplication.² A majority of patients with a left-sided SVC are asymptomatic, although a subset of patients may present with cyanosis, secondary to right-to-left shunting, as well as rhythm abnormalities and conduction disturbances.³ The vast majority of left-sided SVC cases are found incidentally on cross-sectional imaging of the chest.⁴ Our case highlights the challenges of performing central venous catheterization on patients with persistent left-sided SVC and emphasizes significant imaging findings for these patients.

CASE REPORT

Our patient was a 71-year-old male with a past medical history of coronary artery disease, diabetes, hypertension, hyperlipidemia, benign prostatic hyperplasia, and obesity who presented to the emergency department (ED) with headaches and confusion. He was a poor historian secondary to altered mental status; therefore, a limited history was obtained. His wife noted that he had been acting confused over the prior 24 hours. The patient also endorsed some neck stiffness, which resolved upon presentation to the ED. No history of trauma was reported.

His vitals upon presentation to the ED included an oral temperature of 36.1° Celsius, blood pressure of 62/40 millimeters mercury, heart rate of 107 beats per minute, respiratory rate of 18 breaths per minute, and oxygen saturation of 98% on room air. Initial laboratory values for this patient included an elevated white blood cell count to 14.3 K/units per liter (uL) (reference [ref] range 3.8-10. /uL), and a lactate of 5.4

millimoles (mmol) /L (ref <2.0mmol/L). The patient was suspected to have septic shock from an infection of unknown etiology. Due to continued hypotension despite intravenous fluid resuscitation, central venous access was obtained by the emergency physicians for vasopressor administration. A central venous catheter (CVC) was placed within the right internal jugular (IJ) vein under ultrasound guidance. The patient tolerated this procedure without complication, and a chest radiograph was obtained following the procedure to confirm proper line placement (Image 1). At this time, the catheter was noted to be abnormally positioned, as it crossed midline from right-to-left, terminating in the left atrium.

Upon further chart review, including prior imaging, the patient was found to have an existing persistent left-sided SVC draining into the left atrium, based on a prior computed tomography of the chest (Image 2). There was no evidence of a right-sided superior vena cava on the prior advanced imaging. The patient was ultimately diagnosed with ascending cholangitis, which was successfully managed with biliary drainage. He did have several other complications throughout his hospital course secondary to his other medical comorbidities, all of which were unrelated to his SVC.

DISCUSSION

Left-sided SVC is the most common congenital venous anomaly in the chest and is known to have an increased prevalence in patients with congenital cardiac abnormalities. The embryologic origin of persistent left-sided SVC stems from failure of obliteration of the left anterior cardinal vein during normal fetal development.⁵ This results in significant variability in anatomy with a majority of left-sided SVC patients draining

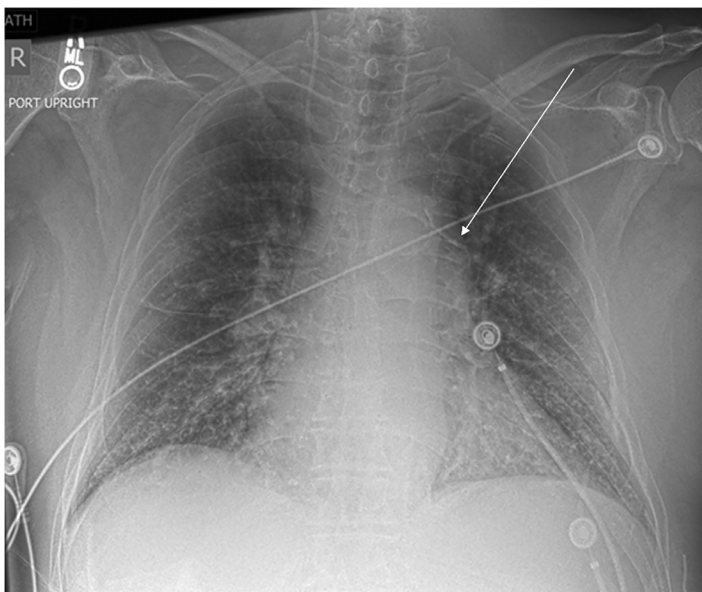


Image 1. Chest radiograph obtained post right-sided internal jugular vein catheter placement, which shows catheter crossing midline right to left terminating within the left atrium (arrow).

CPC-EM Capsule

What do we already know about this clinical entity?

A persistent left-sided superior vena cava is a rare congenital venous malformation that may complicate central venous catheter placement.

What makes this presentation of disease reportable?

This case shows imaging of a malpositioned, right-sided central venous catheter tip secondary to a persistent left-sided superior vena cava with no right-sided superior vena cava.

What is the major learning point?

Consider variants in venous anatomy to aid in the correct interpretation of post-procedure imaging after central line placement.

How might this improve emergency medicine practice?

Early identification of variations in venous anatomy may prevent work-up for additional causes of a malpositioned catheter tip on imaging.

into the coronary sinus, and a minority draining into the left atrium or elsewhere. While an overwhelming majority (>90%) of these patients are asymptomatic, these anatomical variations become clinically relevant in several scenarios. Around 10% of patients with a persistent left-sided SVC will have drainage into the left atrium, leading to a right to left shunt. This shunting allows for the mixing of deoxygenated blood from the venous circuit with oxygenated blood from the left atrium resulting in cyanosis, as well as an increased embolic risk.⁶

Patients with persistent left-sided SVC are also at an increased risk for anomalies of the cardiac conduction system as well as congenital heart defects. This leads to increased incidence of supraventricular tachycardia, atrial fibrillation, atrial flutter, Wolff-Parkinson-White syndrome, and atrioventricular conduction blocks, as well as atrial septal defects, ventricular septal defects, and conotruncal defects.^{7,8} It is for this reason that when these patients are identified it is recommended that they undergo thorough cardiac workup, including electrophysiological studies, echocardiogram, and annual clinical follow-up.

It is important for emergency physicians to understand these variants of normal venous anatomy as they are often diagnosed incidentally on cardiac imaging, including echocardiography. As emergency physicians frequently use point-of-care ultrasound, it

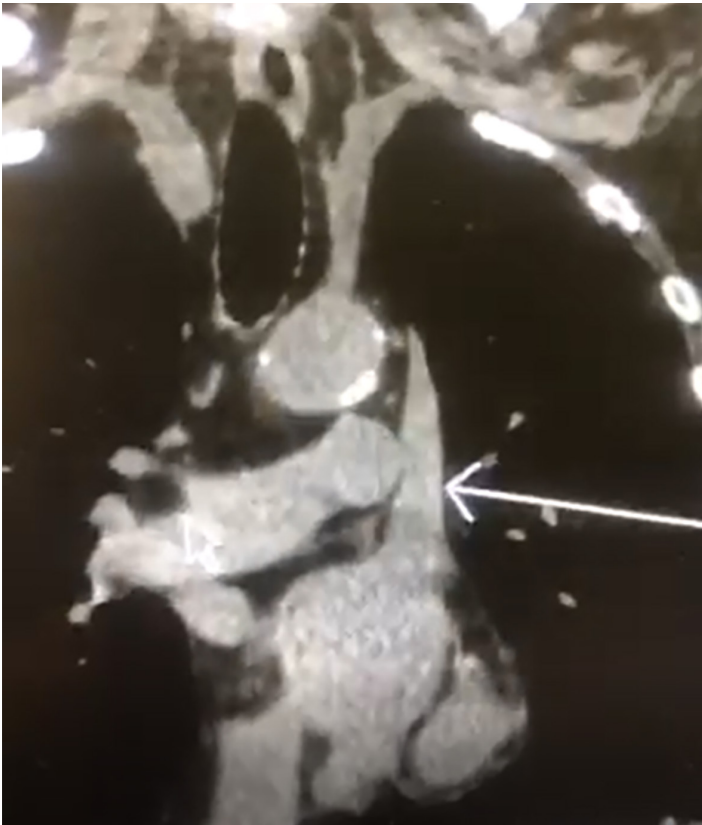


Image 2. Computed tomography of the chest obtained at prior hospitalization demonstrates the presence of a persistent left-sided superior vena cava (arrow), as well as the complete absence of an accompanying right-sided superior vena cava.

is increasingly likely that they may encounter a case of persistent left-sided SVC on transthoracic echocardiogram. Characteristic findings on point-of-care echocardiogram include a dilated coronary sinus without evidence of elevated, right-sided filling pressures. When this diagnosis is suspected it should be confirmed with a saline contrast echocardiography microbubble study or additional vascular imaging studies.⁹ The main ramification of a diagnosis of persistent left-sided SVC is the increased potential for congenital heart defects and dysrhythmias as noted above. When identified this should prompt the evaluation for additional cardiac malformations. The presence of associated cardiac abnormalities is ultimately the prognostic indicator that drives mortality in these patients.¹⁰ The most appropriate setting for further workup is determined by the patient's clinical status; however, most cases are asymptomatic and may be followed on an outpatient basis with cardiology.

A knowledge of anatomical variations within the venous system such as persistent left-sided SVC is critically important for clinicians who perform emergent procedures such as central venous line placement. Proper placement of a CVC requires that the tip of the catheter be placed in as large a central vein as possible and parallel with the long axis of the vein to avoid abutting the catheter against the vein or heart wall.¹¹ It is

estimated that around 5% of CVC placements result in a malpositioned catheter.¹² The presence of a persistent left-sided SVC is an important risk factor for improper positioning of CVCs.¹³ In these cases, catheter placement into the coronary sinus is an understood complication of left-sided CVC placement, resulting in a CVC with an abnormal, left paramediastinal intrathoracic course noted on radiograph.¹³ It is also noted that many of these patients with CVC placement go unnoticed if a right-sided attempt is made. There are no known publications documenting radiographic imaging findings suggestive of an incorrectly positioned right-sided CVC crossing the midline of the chest as a result of a persistent left-sided SVC.

In this case the patient presented with sepsis from an unknown source and needed emergent central line placement for vasopressor administration to maintain adequate perfusion pressures. It was unknown to the clinical team at the time that this patient not only had a persistent left-sided SVC, which drained into the left atrium, but also had the complete absence of a right-sided SVC. This combination is exceedingly rare and explains the post-procedure imaging findings of a right-sided IJ vein CVC crossing the patient's midline. Given that this patient had the complete absence of a right-sided SVC, the catheter tip was tracking through the left brachiocephalic vein. At this point the left brachiocephalic vein merges with a persistent left-sided SVC draining directly into the left atrium. This is where the catheter tip eventually terminated.

Notably, most patients with a persistent left-sided SVC have an associated right-sided SVC that drains into the right atrium. In those cases, right-sided IJ vein placement would not be affected as the right-sided venous circulation is appropriately developed. However, in this case, given the anatomy of the persistent left-sided SVC without an associated right-sided SVC, the catheter crossed the midline and terminated in the SVC as shown in the chest radiograph. It is also important to note that had a left-sided IJ been attempted, the catheter tip would have continued into the left atrium instead of crossing into the right atrium as expected given the complete absence of a right-sided SVC draining into the right atrium.

Based on the post-procedure imaging findings shown, it would be reasonable to conclude that the abnormal positioning could represent arterial line placement, with the CVC entering the aorta and then crossing the midline of the chest. This complication would represent a vascular emergency. However, our case highlights the importance of considering other etiologies for the central line crossing the midline, such as persistent left-sided SVC.

CONCLUSION

This case illustrates an unexpected central venous catheter position on chest radiograph after successful placement of a right-sided internal jugular venous catheter, due to the congenital malformation of a persistent left-sided superior vena cava. This could easily be mistaken for a vascular complication such as arterial line placement. Persistent left-sided SVC is a

clinically important anatomical variant of the central venous system. Emergency physicians should be aware of this variant when placing central venous catheters as it may result in a CVC catheter tip appearing malpositioned on post-procedure imaging. A greater understanding of anatomic variants can aid with correct interpretation of emergent imaging findings. It is, therefore, important for emergency physicians to consider these variants of normal anatomy prior to placing a CVC.

The authors attest that their institution requires neither Institutional Review Board approval, nor patient consent for publication of this case report. Documentation on file.

Address for Correspondence: Michael Mancera, MD, University of Wisconsin School of Medicine and Public Health, Berbee Walsh Department of Emergency Medicine, 800 University Dr. Suite 310, Madison, WI 53705. Email: mmancera@medicine.wisc.edu.

Conflicts of Interest: By the CPC-EM article submission agreement, all authors are required to disclose all affiliations, funding sources and financial or management relationships that could be perceived as potential sources of bias. The authors disclosed none.

Copyright: © 2020 Mancera et al. This is an open access article distributed in accordance with the terms of the Creative Commons Attribution (CC BY 4.0) License. See: <http://creativecommons.org/licenses/by/4.0/>

REFERENCES

1. Tyrak KW, Holda J, Holda MK, et al. Persistent left superior vena cava. *Cardiovasc J Afr*. 2017;28(3):e1-4.
2. Ruano CA, Marinho-da-Silva A, Donato P. Congenital thoracic venous anomalies in adults: morphologic MR imaging. *Curr Probl Diagn Radiol*. 2015;44(4):337-45.
3. Goyal SK, Punnam SR, Verma G, et al. Persistent left superior vena cava: a case report and review of literature. *Cardiovasc Ultrasound*. 2008;6:50.
4. Kellman GM, Alpern MB, Sandler MA, et al. Computed tomography of vena caval anomalies with embryologic correlation. *Radiographics*. 1988;8(3):533-56.
5. Huang SK. Persistent left superior vena cava in a man with ventricular fibrillation. *Chest*. 1986;89(1):155-7.
6. Morgan LG, Gardner J, Calkins J. The incidental finding of a persistent left superior vena cava: implications for primary care providers-case and review. *Case Rep Med*. 2015;2015:198754.
7. Duymus M, Yesilkaya Y, Orman G, et al. Persistent left superior vena cava draining to the left atrium: a case report and review of the literature. *Pol J Radiol*. 2012;77(4):65-6.
8. Mark JB, Slaughter TF, Gerald Reves J. (2009). Cardiovascular monitoring. In: Miller RD. (Ed.), *Anesthesia (p. 1144-51)*. Stonelake, PA: Churchill Livingstone.
9. Kim H, Kim JH, Lee H. Persistent left superior vena cava: diagnosed by bedside echocardiography in a liver transplant patient: a case report. *Korean J Anesthesiol*. 2014;67(6):429-32.
10. Galindo A, Gutiérrez-Larraya F, Escribano D, et al. Clinical significance of persistent left superior vena cava diagnosed in fetal life. *Ultrasound Obstet Gynecol*. 2007;30(2):152-61.
11. Pikwer A, Bååth L, Davidson B, et al. The incidence and risk of central venous catheter malpositioning: a prospective cohort study in 1619 patients. *Anaesth Intensive Care*. 2008;36(1):30-7.
12. Gibson F and Bodenham A. Misplaced central venous catheters: applied anatomy and practical management. *Br J Anaesth*. 2013;110(3):333-46.
13. Wang L, Liu ZS, Wang CA. Malposition of central venous catheter: presentation and management. *Chin Med J (Engl)*. 2016;129(2):227-34.

Pharmacologically-induced Recreational Priapism: Case Report and Review

Grace Kunas, MD*
Janet A. Smereck, MD†
Diana Ladkany, MD†
Jonathan E. Davis, MD†

*Abrazo Health, Department of Emergency Medicine, Goodyear, Arizona
†Georgetown University Medical Center, Department of Emergency Medicine, Washington, District of Columbia

Section Editor: Steven Walsh, MD

Submission history: Submitted April 16, 2020; Revision received August 12, 2020; Accepted August 14, 2020

Electronically published October 9, 2020

Full text available through open access at http://escholarship.org/uc/uciem_cpem

DOI: 10.5811/cpem.2020.8.47763

Introduction: Priapism, a time-sensitive urologic emergency, is associated with hematologic disorders, malignancies, trauma, pharmaceuticals, and recreational drugs.

Case Report: A 51-year-old male presented with 36 hours of priapism after recreational use of nonprescribed pharmaceuticals including an oral phosphodiesterase inhibitor and intracorporally injected erectile medications, together with unspecified quantities of cocaine and alcohol. Venous blood gas confirmed ischemic priapism. Detumescence was achieved with intracavernosal phenylephrine injection, aspiration, and irrigation.

Conclusion: This case highlights the risk that recreational use of vasoactive medications by patients who seek to prolong sexual activity may lead to delayed presentation for ischemic priapism. [Clin Pract Cases Emerg Med. 2020;4(4):591–594.]

Keywords: *ischemic priapism; phosphodiesterase inhibitor; intracorporal injection.*

INTRODUCTION

Numerous factors may lead to priapism, defined as penile erection in the absence of active sexual stimulation that persists for a minimum of four hours due to persistent engorgement of the corpora cavernosa and disruption of normal detumescence mechanisms.¹ Priapism is a time-sensitive urologic emergency that is relatively rare in the general population; priapism disproportionately affects patients with hematologic and neurologic disorders, notably sickle cell disease and spinal cord injury, and is associated with a number of pharmaceuticals and recreational drugs.^{2,3} Although the mean duration is just over two hours per episode, delayed presentation can be associated with use of medications intended to stimulate potency or manage erectile dysfunction.¹ There are two main subtypes of priapism: ischemic (low inflow), and non-ischemic (high inflow). Ischemic priapism, the most frequent subtype, requires emergent intervention to avoid future complications

including tissue necrosis, fibrosis and scarring, and subsequent erectile dysfunction.^{1,2}

CASE REPORT

A 51-year-old male presented to the emergency department (ED) with a chief complaint of persistent erection that had been present for approximately 36 hours after he ingested 20 milligrams (mg) of tadalafil followed by penile self-injection with approximately one milliliter (mL) of Trimix, a compound containing alprostadil, papaverine, and phenolamine. He had no history of erectile dysfunction. Neither medication had been prescribed to him, and his intention was to achieve a sustained penile erection to facilitate prolonged sexual activity with a group of people. There was concomitant use of an unspecified quantity of alcohol as well as intranasal cocaine. The patient reported mild discomfort and some difficulty passing urine due to his prolonged erection, but reported he was still able to void. He denied hematuria, dysuria, or penile discharge. There was no past history

of malignancy or hematologic disorders. His medical issues included stable human immunodeficiency virus (HIV) disease and reported compliance with antiretroviral medication (emtricitabine-tenofovir); there was no history of hypertension.

On examination the patient did not appear to be in distress; his demeanor was consistent with mild intoxication, but he was fully alert and oriented to person, place, time, and situation. His initial vital signs were notable for hypertension, with a blood pressure of 161/104 millimeters of mercury (mm Hg), heart rate of 88 beats per minute, and an afebrile temperature of 36.1 degrees Celsius. His penis was erect and engorged; glans and spongiosum were soft without tenderness to palpation. The examiner was unable to bend the shaft due to rigidity. The testes and vas were nontender.

Initial laboratory evaluation included normal hemogram and renal function; urinalysis showed three white blood cells and six red blood cells per high-powered field. Urologic consultation was requested and ice packs were applied to the penile shaft for several minutes without response. Aspiration of the corpora was performed. Penile venous blood gas (VBG) was remarkable for pH of 7.00 (reference [ref] range 7.31-7.41), partial pressure of carbon dioxide of 88.4 mm Hg (ref range 40-52 mm Hg), calculated venous oxygen saturation of 8.0 % (ref range 75%), and lactic acid level of 14.4 millimoles per liter (mmol/L) (ref range 0.5-2.2 mmol/L), consistent with ischemic priapism. After local anesthetic, corporal injection of phenylephrine 500 µg/mL, diluted in 10 mL of normal saline, followed by aspiration and irrigation with an additional 10 cubic centimeters (cc) of sterile saline, resulted in gradual detumescence. A compression dressing was then applied to the penile shaft. The patient reported no discomfort after the procedure; blood pressure on discharge was normalized to 124/81 mm Hg. The patient was given instructions to remove the pressure dressing in 24 hours and abstain from sexual intercourse for a minimum of seven days.

On follow-up in urology clinic 11 days after his presentation to the ED, the patient reported ability to achieve normal erections; he was noted to have minimal ecchymosis at the base of the penile shaft. He was advised to refrain from using erectogenic medications in the future.

DISCUSSION

Penile erections are a result of vasodilation in the corpora cavernosa, mediated by inhibition of the cyclic guanosine monophosphate (cGMP) hydrolyzing enzyme phosphodiesterase-5 (PDE5). With ischemic priapism, venous outflow is reduced and venous congestion leads to diminished or loss of arterial inflow.¹ Tadalafil is one of several available PDE5 inhibitors. Trimix, a compound intended for intracorporal injection (ICI), consists of alprostadil, phentolamine, and papaverine. The three pharmaceuticals act in different ways to stimulate penile vasodilation. Alprostadil acts directly to stimulate the production of cyclic adenosine monophosphate (cAMP), which like cGMP leads to penile tumescence from smooth muscle relaxation. Phentolamine is

CPC-EM Capsule

What do we already know about this clinical entity?

Ischemic priapism may result from pharmaceuticals including phosphodiesterase inhibitors, injected vasodilators, psychotropics, and alpha-receptor antagonists.

What makes this presentation of disease reportable?

A 36-hour episode of ischemic priapism after combined use of oral and cavernosally injected erectile agents was treated emergently without long-term complications.

What is the major learning point?

Use of erectile medications can result in delayed presentation for ischemic priapism, best managed with sympathomimetic agents injected into the corpora cavernosa.

How might this improve emergency medicine practice?

This report adds to the literature on priapism causes, management and outcomes, highlighting the adverse consequences of recreational use of erectile medications.

an antagonist of alpha adrenergic receptors, resulting in further vascular dilation, while papaverine inhibits several subclasses of PDEs, causing cGMP and cAMP accumulation.⁴

While the above described medications are intended to facilitate erections for a safe duration in persons with erectile dysfunction, this case describes a patient with normal erectile function who recreationally misused a combination of pharmaceuticals resulting in a prolonged, unsafe erection. A retrospective study of 169 priapism encounters highlighted growing recreational use of ICIs within a metropolitan community, finding nearly 50% of cases to be due to ICIs.⁵ Numerous cases of priapism with various medication classes, in addition to ICIs and PDE inhibitors, have been documented. Psychotropic medications implicated in recreational misuse include the following: serotonin specific reuptake inhibitors, most notably trazodone; amphetamines; pregabalin; and typical and atypical antipsychotics (due to alpha-blocking characteristics).⁶⁻⁹ Tamsulosin, due to alpha blocking effects, as well as alpha-receptor antagonist antihypertensives have been associated with ischemic priapism.¹⁰ Priapism associated with cocaine use has long been observed.¹¹ Some herbal supplements marketed for

sexual enhancement have been reported in cases of prolonged priapism. *Tribulus terrestris* has been associated with protracted episodes of priapism (between 48-72 hours), as well as the herbal product yohimbine, ranging between 20-72 hours in case reports.^{12,13} Pharmaceutical agents reported in association with priapism are summarized in the following table.

Regardless of etiology, ischemic or low-flow priapism is a urologic emergency requiring prompt intervention. Diagnosis should be accomplished through history and physical exam, followed by corporal VBG. Venous blood in ischemic priapism is characterized by an acidotic pH (below 7.1).² Hematologic studies can be obtained and duplex ultrasonography can be done to assess arterial blood flow but is not required.² Once ischemic priapism is suspected, management should begin promptly to prevent compartment syndrome and future fibrosis, which then may contribute to permanent impotence. Urologic input is appropriate if feasible. Initial conservative measures may include application of ice packs to the genital area and asking the patient to perform vigorous physical exercise of the lower limbs.¹⁴ Aspiration of blood from the corpora cavernosa is used both for blood gas analysis and to remove blood to relieve cavernosal compartment pressure, which then should be followed by saline irrigation.

If detumescence does not occur, the next step is ICI of an alpha-adrenergic sympathomimetic; this is generally preceded by local anesthetic or nerve block.² The preferred sympathomimetic agent is phenylephrine hydrochloride 10 mg/mL; 0.1-0.5 mL (1-5 mg) is diluted in 10 cc normal saline to give a concentration of 100-500 µg/mL, injected at a rate of 1 mL over three to five minutes until detumescence is achieved. Diluted epinephrine 1:10,000 solution may be used if phenylephrine is unavailable.^{2,15} Sonographic guidance may be used to facilitate cavernosal needle placement but is not a requirement. Oral pseudoephedrine as well

as subcutaneous terbutaline are other options, but are less effective and not recommended for priapism of duration greater than four hours. If these measures fail, a surgical procedure to implant shunts may need to be performed.²

By contrast, non-ischemic priapism, which is rarer and usually a result of trauma or congenital arterial malformation, occurs from unregulated arterial inflow to the corpora cavernosa, creating an arteriolar-sinusoidal fistula. Due to constant high inflow of arterial blood, the corpora cavernosa is not at risk for ischemia and the condition is, therefore, non-ischemic priapism. Non-ischemic priapism is generally painless; treatment is routinely conservative, as most cases resolve spontaneously.²

CONCLUSION

Numerous pharmaceutical agents have been associated with priapism; in addition to medications used to treat erectile dysfunction, several psychotropic medications have been implicated. Recreational use of vasoactive pharmaceuticals with the intention of prolonging sexual activity can lead to delayed presentation for ischemic priapism. In particular, patients who misuse intracorporally injected medications present four hours later on average than those with priapism from other etiologies, more frequently have comorbid HIV disease, and more commonly co-ingest recreational drugs and alcohol, which can exacerbate priapism and likely contribute to delayed presentation.³ A patient presented with an episode of ischemic priapism of approximately 36 hours in duration after use of diverted erectogenic pharmaceuticals, likely exacerbated by concomitant use of cocaine. The patient underwent active intervention in the ED to achieve detumescence, with no apparent permanent sequelae. This case adds to the growing literature on pharmacologically induced priapism. Emergency clinicians should be aware of the potential for misuse of medications prescribed for erectile dysfunction and the need for active management to achieve a favorable outcome.

Table. Pharmaceutical agents associated with priapism.

Category	Agent(s)
Erectile dysfunction medications	ICI agents, PDE inhibitors
Antidepressants/SSRIs	Paroxetine, citalopram, trazodone
Antipsychotics	Atypical and typical (haloperidol, chlorpromazine, quetiapine, clozapine, olanzapine, risperidone)
Amphetamines	Methylphenidate, dexamethylphenidate, lis-dexamphetamine
Anti-epileptic/pain management	Pregabalin
Alpha-adrenergic blockers	Antihypertensives (terazosin), tamsulosin
Herbal products	<i>Tribulus terrestris</i> , yohimbine
Recreational drugs	Cocaine, ethanol

ICI, intracorporal injection; PDE, phosphodiesterase; SSRI, selective serotonin reuptake inhibitor.

The authors attest that their institution requires neither Institutional Review Board approval, nor patient consent for publication of this case report. Documentation on file.

Address for Correspondence: Grace Kunas, MD, Abrazo Health, Department of Emergency Medicine, 13677 W McDowell Rd, Goodyear, AZ 85395. Email: gck11@georgetown.edu.

Conflicts of Interest: By the CPC-EM article submission agreement, all authors are required to disclose all affiliations, funding sources and financial or management relationships that could be perceived as potential sources of bias. The authors disclosed none.

Copyright: © 2020 Kunas et al. This is an open access article distributed in accordance with the terms of the Creative Commons Attribution (CC BY 4.0) License. See: <http://creativecommons.org/licenses/by/4.0/>

REFERENCES

1. Cuartas J, Sandoval-Salinas C, Martínez J, et al. Treatment of priapism secondary to drugs for erectile dysfunction. *Adv Urol.* 2019;2019:6214921.
2. Vilke GM, Harrigan RA, Ufberg JW, et al. Emergency evaluation and treatment of priapism. *J Emerg Med.* 2004;26(3):325-9.
3. Scherzer ND, Reddy AG, Le TV, et al. Unintended consequences: a review of pharmacologically induced priapism. *Sex Med Rev.* 2019;7(2):283-92.
4. Nehra A. Oral and non-oral combination therapy for erectile dysfunction. *Rev Urol.* 2007; 9(3):99-105.
5. Zhao H, Berdahl C, Bresee C, et al. Priapism from recreational intracavernosal injections in a high-risk metropolitan community. *J Sex Med.* 2019;16(10):1650-4.
6. Saghafi O, Kao A, Druck J. Recurrent priapism from therapeutic quetiapine. *West J Emerg Med.* 2014;15(1):114-6.
7. Bhat IA, Shannon KD, Ara A, et al. Ninety-six hours ordeal of priapism induced by paroxetine: a case report and literature review. *Int J Psychiatry Med.* 2015;50(3):326-34.
8. Compton MT and Miller AH. Priapism associated with conventional and atypical antipsychotic medications: a review. *J Clin Psychiatry.* 2001;62(5):362-6.
9. Karancı Y. Priapism associated with pregabalin. *Am J Emerg Med.* 2020;38(4):852.e1-852.e2.
10. Marconi M, Pavez P, San Francisco I, et al. Priapism induced by use of tamsulosin: a case report and review of the literature. *Arch Ital Urol Androl.* 2019;91(3).
11. Altman AL, Seftel AD, Brown SL, et al. Cocaine associated priapism. *J Urol.* 1999;161(6):1817-8.
12. Campanelli M, De Thomas R, Tenaglia RL. Priapism caused by 'Tribulus terrestris.' *Int J Impot Res.* 2016;28(1):39-40.
13. Myers A and Barrueto F Jr. Refractory priapism associated with ingestion of yohimbe extract. *J Med Toxicol.* 2009;5(4):223-5.
14. Gravel J, LeBlanc C, Varner C. Management of priapism with a trial of exercise in the emergency department. *CJEM.* 2019; 21(1):150-3.
15. Roberts J, Price C, Mazzeo T. Intracavernous epinephrine: a minimally invasive treatment for priapism in the emergency department. *J Emerg Med.* 2009;36(3):285-9.

“Botched”: A Case Report of Silicone Embolism Syndrome After Penile and Scrotal Injection

Anantha Singarajah, MS*
Albert Wang, DO†
Julie Sayegh, MD‡
Gary M. Vilke, MD§
Faith C. Quenzer, DO§

*Lincoln Memorial University – DeBusk College of Osteopathic Medicine, Harrogate, Tennessee
†Desert Regional Medical Center, Department of Emergency Medicine, Palm Springs, California
‡Los Alamitos Medical Center, Department of Emergency Medicine, Los Alamitos, California
§University of California, San Diego, Department of Emergency Medicine, San Diego, California

Section Editor: Rick A. McPheeters, DO

Submission history: Submitted June 22, 2020; Revision received August 21, 2020; Accepted September 8, 2020

Electronically published October 20, 2020

Full text available through open access at http://escholarship.org/uc/uciem_cpchem

DOI: 10.5811/cpcem.2020.9.48838

Introduction: Silicone has been commonly used for both major and minor plastic and reconstructive surgery for decades. Due to the high costs associated with minor cosmetic procedures and plastic surgery, the unauthorized use of silicone injections by laypersons has become increasingly common. Improper or illegal subcutaneous injectable silicone has caused significant pulmonary complications and neurological complications, which can range from mild chest pain, hypoxia, and respiratory failure to coma and altered mental status.

Case Report: We present a patient who had a rare complication of respiratory failure secondary to silicone embolism syndrome (SES). SES is a rare, potentially deadly complication and has been associated with subcutaneous silicone injections. The diagnosis of SES can be challenging and requires a thorough patient history indicating recent cosmetic procedures.

Conclusion: This case describes the first case of SES of a male patient who presented to a community emergency department complaining of dyspnea after an episode of self-administered injectable silicone into his penis and scrotum and who developed SES-induced respiratory failure. [Clin Pract Cases Emerg Med. 2020;4(4):595–598.]

Keywords: *Silicone embolism syndrome; illicit silicone injections; injected liquid silicone; acute respiratory failure; acute respiratory distress syndrome.*

INTRODUCTION

Silicone liquid is a mostly inert, liquid polymer that is commonly used for plastic and reconstructive surgery due to its resistance to heat and aging, and low immune response. Subcutaneous injections of silicone are frequently administered mainly in the breast and buttock area for cosmetic augmentations.¹⁻² However, there are reports of injected liquid silicone that resulted in the migration of the silicone, resulting in serious respiratory complications such as silicone embolism syndrome (SES). Symptoms of SES may

include dyspnea, fever, cough, hemoptysis, chest pain, hypoxia, alveolar hemorrhage, and altered level of consciousness.³ Patients presenting with these clinical features have often been diagnosed with pulmonary embolism, acute respiratory distress syndrome (ARDS), alveolar hemorrhage, and pneumonitis based on radiographic imaging. To our knowledge this is the first case of a male patient who self-injected silicone directly into his penis and scrotum who presented to the emergency department (ED) with acute dyspnea and respiratory failure due to SES.

CASE REPORT

A 59-year-old, otherwise healthy male presented to the ED with a complaint of acute onset, non-exertional shortness of breath that began six hours prior to arrival. The patient reported that he had injected approximately 80 milliliters (mL) of liquid silicone into his penis and scrotum for purposes of penile and scrotal enlargement approximately one hour prior to the onset of his symptoms. He noted that he rapidly began to experience fatigue and shortness of breath, as well as lightheadedness, cough, and exertional dyspnea. He denied any other symptoms. The patient also reported that he had been self-injecting 80-100 milliliters (mL) of silicone with lidocaine into his genitals regularly since June 2008.

The patient explained that he was part of a group of “brothers” who engaged in the same subcutaneous silicone injection practices. He stated that in the same group there were others who had been previously diagnosed with silicone pulmonary embolism and some of whom had died. Thus, when he started developing symptoms, he contacted his “group mentor” who encouraged him to come to the ED for further evaluation. He denied injecting silicone intravascularly and reported that he had aspirated the needle prior to the injection to make sure it was not in a blood vessel. The patient denied any penile pain or urinary hesitancy or dysuria. He also admitted to injection of 100 mL of silicone into his nipple areas several years prior but denied any recent injection. He denied smoking or illicit drug use, allergies, or any significant family history. His surgical history was only pertinent for a lumbar fourth and fifth discectomy. He uses 50 milligrams (mg)/mL testosterone intramuscular injections every two weeks and emtricitabine/tenofovir as needed.

On physical exam, his initial vital signs showed a temperature of 36.9 degrees Celsius, heart rate of 102 beats per minute, respiratory rate of 22 breaths per minute, blood pressure of 125/73 millimeters of mercury (mm Hg), and an oxygen saturation (SpO₂) of 82% on room air. The patient appeared to be anxious and in mild respiratory distress. He was diaphoretic, with increased work of breathing with shallow, labored breaths. His lung sounds were notable for diffuse coarse rales and rhonchi throughout the upper and lower lobes bilaterally. His genitourinary exam revealed a significantly enlarged scrotum, approximately 20 centimeters (cm) in diameter, and circumferentially enlarged penile shaft to approximately 6 cm in diameter. The area was firm, without fluctuance, tenderness, erythema or warmth. The penile head appeared normal in size.

The patient’s pertinent laboratory data revealed white blood cell count of 14.1 x 10⁹/ liter (L) (normal 4.0-10.0 x 10⁹/L), hemoglobin of 14.3 grams (g)/dL (normal 13.0-7.0 g/dL), and platelets of 215 x 10⁹/L (normal 150-400 x 10⁹/L). The basic metabolic panel was unremarkable. Arterial blood gas revealed a pH of 7.46 (normal 7.35-7.45), partial pressure of carbon dioxide of 33 mm Hg (normal 35-45 mm Hg), partial pressure of oxygen of 71 mm Hg (normal 75-100

mm Hg), bicarbonate of 23.5 millimoles (mmol)/L (normal 18-22 mmol/L), and a base excess of 0.4 milliequivalents (mEq)/L (normal [-3] - [+3] mEq/L). Prothrombin time, international normalized ratio, and partial thromboplastin time were 12.2, 1.1, and 25.3 seconds, respectively. The urine drug screen was negative for drugs of abuse. The patient’s electrocardiogram revealed a normal sinus rhythm without ischemic changes.

The patient was placed on supplemental oxygen via nasal cannula, and his SpO₂ improved from 82% on presentation to 100%. A chest radiograph was performed that revealed bilateral alveolar infiltrates (Image 1). Point-of-care cardiac ultrasound was performed, which revealed an enlarged right ventricle with minimal mid-chamber collapsibility, indicating right ventricular heart strain. A computed tomography with angiogram (CTA) of the chest was obtained and demonstrated moderate, scattered, diffuse pulmonary ground-glass and interstitial lung markings consistent with alveolar edema vs bronchopneumonia or ARDS (Images 2 and 3). The CTA chest was negative for pulmonary embolism. There was also mild subcutaneous stranding and edema of the anterior chest wall.

CPC-EM Capsule

What do we already know about this clinical entity?

Silicone embolism syndrome (SES) is a rare but potentially lethal complication that can occur following cosmetic silicone injections.

What makes this presentation of disease reportable?

This is the first reported case of SES in a male patient who injected silicone into his penis and scrotum and ultimately succumbed to respiratory failure.

What is the major learning point?

SES should be considered in the differential diagnosis in a patient presenting with dyspnea and hypoxia after cosmetic injections of silicone.

How might this improve emergency medicine practice?

An awareness and understanding of SES following silicone injections may potentially improve morbidity and mortality with early detection.

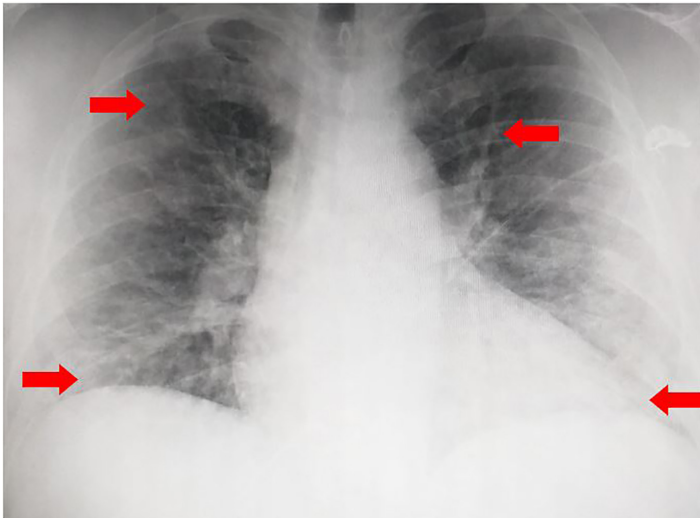


Image 1. Initial chest radiograph demonstrating mild pulmonary vascular congestion with mild, hazy bilateral airspace disease, likely secondary to alveolar edema or aspiration (arrows).

The patient was admitted to the inpatient telemetry unit due to concern for possible silicone pneumonitis and was started on intravenous methylprednisolone 60 mg every six hours to treat pulmonary inflammation. A scrotal ultrasound (Image 3) was non-diagnostic due to the heavy acoustic shadowing created by the silicone within the scrotum. Urology was consulted regarding the patient's scrotal swelling and determined that there was no underlying penile or scrotal infection from the silicone injections. The patient was instructed to halt all silicone penile and scrotal injections. Two

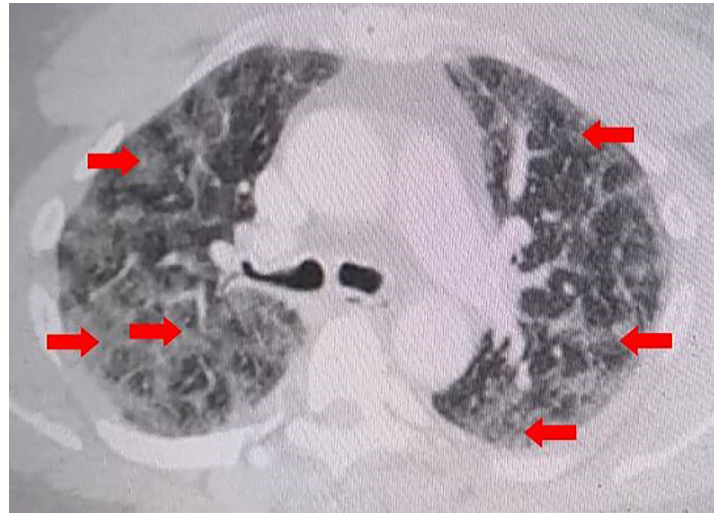

Image 3. Computed tomography angiography of the chest with intravenous contrast in the transverse view demonstrates moderate, scattered, diffuse pulmonary ground-glass and interstitial lung markings without pulmonary embolism as indicated by the red arrows. There is also mild subcutaneous stranding and edema of the anterior chest wall.

days into his admission, he became increasingly dyspneic and hypoxic. His oxygen requirements were increased, and he was subsequently intubated and transferred to the intensive care unit. He was diagnosed with ARDS secondary to SES. He continued to be ventilator dependent, had percutaneous tracheostomy and gastrostomy tube placement, and was subsequently transferred to a long-term care facility.

DISCUSSION

The first report of SES was found in a breast augmentation surgery in 1978 as described by Celli and colleagues.⁴ Since then, cases of complications due to illicit cosmetic silicone injection administration has continued to grow due to increased demand and lack of affordability of medically administered injections.^{2,5-7} In the United States, silicone injections are frequently administered most commonly in the breast and buttock area in women and transgender individuals.^{2,8} It is estimated that there is a 1-2% incidence rate of silicone-injection complications.⁹ These complications typically present within 48 hours after injection but can occur months later.^{5,10}

The most common reported presenting symptoms of SES are the following: hypoxia (92%); dyspnea (88%); fever (70%); alveolar hemorrhage (64%); and cough (52%).^{2,5} Additionally, neurological manifestations of SES such as altered levels of consciousness and coma have been reported and are poor prognostic indicators.^{5-6,11} The exact pathophysiology linking injectable silicone and respiratory symptoms is still fairly unclear. It is generally considered that SES is due to the injected silicone either going directly into the bloodstream or migrating into the bloodstream, leading to

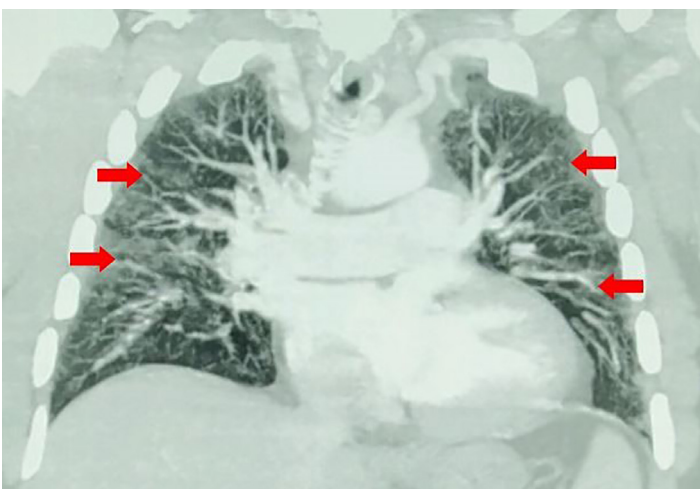


Image 2. Computed tomography angiography of the chest with intravenous contrast in the coronal view demonstrates no pulmonary embolism. However, there are moderate, scattered, diffuse pulmonary ground-glass and interstitial lung markings. The red arrows indicate mild subcutaneous stranding and edema of the pleura.

an embolic event.¹²⁻¹⁴ There is also evidence demonstrating that silicone administration may cause a widespread inflammatory reaction, possibly secondary to the formation of antibodies to silicone.^{10,15} Additionally, injection of large volumes of silicone directly into the body tissues, as occurred in our patient, can result in local tissue damage.^{5,14}

The diagnosis of SES can often be missed in the ED due to a wide differential diagnosis seen on plain films and an incomplete patient history.² The presence of hypoxia and dyspnea often prompts CTA of the chest to rule out pulmonary embolism; thus, SES is most often diagnosed with this modality. Often, SES on CTA chest demonstrates peripherally distributed, ground-glass opacities associated with interlobular septal thickening, similar to what can be observed in some eosinophilic lung diseases and fat embolism syndrome.^{2,5,10} The clinical findings linked in patients with SES are similar to those found in patients with fat embolisms and alveolar hemorrhage.^{2,6,8,15} Thus, anticoagulants are not indicated for SES as they may worsen alveolar hemorrhage and contribute to a decline in respiratory function.¹⁵

Treatment is largely supportive starting with the use of supplemental oxygen, while mechanical ventilation is reserved for severe hypoxia secondary to SES.^{6,10} There is some research to support the early use of corticosteroids to decrease the severity of SES.^{8,10}

CONCLUSION

Widespread use of cosmetic silicone injections can be a cause of silicone embolism syndrome. Most commonly these injections are found in the breast and buttock areas. Due to increased demand and lack of affordability of augmentation procedures, there are reports of increased illicit silicone injections with severe complications. Ours is the first reported case in which a patient injected silicone into his penis and scrotum resulting in acute respiratory failure secondary to SES. The diagnosis of SES should be considered especially in a patient who has a history of recent silicone injection and is exhibiting acute respiratory or neurological symptoms.

The authors attest that their institution requires neither Institutional Review Board approval, nor patient consent for publication of this case report. Documentation on file.

REFERENCES

1. Ashley FL, Braley S, Rees TD, et al. The present status of silicone fluid in soft tissue augmentation. *Plast Reconstr Surg.* 1967;39(4):411-20.
2. Lyapichev K, Chinea FM, Poveda J, et al. Pulmonary empty spaces: silicone embolism—a decade of increased incidence and its histological diagnosis. *Case Rep Pathol.* 2016;2016:3741291.

Address for Correspondence: Faith Quenzer, DO, UC San Diego Health, Department of Emergency Medicine, 200 W. Arbor Drive MC 8676, San Diego, CA 92103. Email: fquenzer@health.ucsd.edu.

Conflicts of Interest: By the CPC-EM article submission agreement, all authors are required to disclose all affiliations, funding sources and financial or management relationships that could be perceived as potential sources of bias. The authors disclosed none.

Copyright: © 2020 Singarajah et al. This is an open access article distributed in accordance with the terms of the Creative Commons Attribution (CC BY 4.0) License. See: <http://creativecommons.org/licenses/by/4.0/>

3. Bartsich S and Wu JK. Silicone emboli syndrome: a sequela of clandestine liquid silicone injections. A case report and review of the literature. *J Plastic, Reconstruct Aesthetic Surg.* 2010;63(1): e1-3.
4. Celli B, Textor S, Kovnat DM. Adult respiratory distress syndrome following mammary augmentation. *Am J Med Sci.* 1978;275(1):81-5.
5. Mendonca D, Leitao, DS, Friend R, et al. An unusual case of pulmonary embolism. *Respir Care.* 2012;57(8):1345-7.
6. Schmid A, Krieger B, Tzur A, et al. Silicone embolism syndrome: a case report, review of the literature, and comparison with fat embolism syndrome. *Chest.* 2005;127(6):2276-81.
7. Adegunsoye AO, Matchett S, Valentino DJ. A 20-year-old woman with rapidly progressive dyspnea and diffuse pulmonary infiltrates. *Respir Med Case Rep.* 2012;5(1):34–6.
8. Rees TD, Platt J, Ballantyne DL Jr. An investigation of cutaneous response to dimethylpolysiloxane (silicone liquid) in animals and humans—a preliminary report. *Plast Reconstr Surg.* 1965;35:131-9.
9. Restrepo CS, Artundauaga M, Carrillo JA, et al. Silicone pulmonary embolism: report of 10 cases and review of literature. *J Comput Assist Tomogr* 2009;33(2):233-7.
10. Chastre J, Basset F, Viau F, et al. Acute pneumonitis after subcutaneous injections of silicone in transsexual men. *N Engl J Med.* 1983;308(13):764-7.
11. Parikh R, Karim K, Parikh N, et al. Acute pneumonitis and alveolar hemorrhage after subcutaneous injection of liquid silicone. *Ann Clin Lab Sci.* 2008;38(4):380–5.
12. Trujillo T, Arias L, Jaramillo LF, et al. Silicone embolism syndrome: a case series. *Am J Respir Crit Care Med.* 2017;195:A5564.
13. Essenmacher AC and Astani SA. Respiratory disease following illicit injection of silicone: a case report. *Case Rep Med.* 2013;2013:743842.
14. Price EA, Schueler H, Perper JA. Massive systemic silicone embolism: a case report and review of literature. *Am J Forensic Med Pathol.* 2006;27(2):97-102.
15. Goldblum RM, Pelley RP, O'Donnell AA, et al. Antibodies to silicone elastomers and reactions to ventriculoperitoneal shunts [published correction appears in *Lancet* 1992 Sep 26;340(8822):800]. *Lancet.* 1992;340(8818):510-3.

An Unusual Case of Tetanus Masquerading as an Acute Abdomen: A Case Report

Rahul Kumar Thakur, MBBS*
Rajshree Singh, MBBS†
Sabin Nepal, MD‡
Prasanna Ghimire, MD‡

*B.P. Koirala Institute of Health Sciences, Department of Emergency Medicine, Dharan, Nepal

†Nepalese Army Institute of Health Sciences College of Medicine, Department of Emergency Medicine, Kathmandu, Nepal

‡Nepalgunj Medical College and Teaching Hospital, Department of Radiology, Bheri, Nepal

Section Editor: Steven Walsh, MD

Submission history: Submitted July 14, 2020; Revision received August 19, 2020; Accepted August 21, 2020

Electronically published October 19, 2020

Full text available through open access at http://escholarship.org/uc/uciem_cpccem

DOI: 10.5811/cpcem.2020.8.49073

Introduction: Tetanus is an acute onset neurological disease that is often lethal. It has a high disease burden in low and middle-income countries. Tetanus is caused by a toxin made by spores of the bacterium *Clostridium tetani*, which are found in soil, dust, and animal feces. The toxin impairs the motor neurons leading to muscle stiffness. However, with the development of a toxoid vaccine, the incidence has sharply declined and is now categorized as a vaccine-preventable disease. The treatment of tetanus is primarily supportive and focuses on managing the complications until the effects of toxins resolve.

Case Report: We report the case of a 67-year-old farmer who previously sustained a laceration injury approximately 45 days prior to presenting to the emergency department with abdominal pain and rigidity. After a comprehensive evaluation to rule out other items in the differential diagnoses, he was diagnosed with tetanus based on clinical symptoms and ultimately required mechanical ventilation. The patient was then managed in the intensive care unit and later made an uneventful recovery.

Conclusion: This case illustrates an uncommon presentation of tetanus and the latency of the infectious process. Often when patients present with atypical symptoms, it poses a diagnostic dilemma to the clinicians. Thus, it is very important to carefully elicit a history of contaminated injury. This case also highlights the importance of prophylactic vaccine in low and middle-income countries, which can reduce disease-related mortality and morbidity. [Clin Pract Cases Emerg Med. 2020;4(4):599–602.]

Keywords: *Tetanus; acute abdomen; abdominal muscle spasm; toxoid; vaccine.*

INTRODUCTION

Tetanus is an acute onset neurological disease caused by the bacterium *Clostridium tetani* and is often lethal. Causing an estimated 213,000-293,000 deaths worldwide annually, tetanus is a global health burden that disproportionately impacts developing countries.¹ In 2016, the United States mortality rate was as low as 11% compared to 20% in developing countries.² Although maternal and neonatal tetanus

in low and middle-income countries (LMIC) is on the verge of elimination, there were significant cases of adult tetanus reported in the same year.³

Tetanus usually occurs in a wound contaminated with soil, manure, or rusted metal.⁴ In up to 50% of cases, the injury may be minor and is not considered significant enough to pursue medical treatment; and in 15-25% of patients, there is no evidence of a recent wound at all.⁴ The incubation

period averages 7-10 days, with a range of 1-60 days.⁴ The initial signs are trismus and risus sardonicus. As the disease progresses, patients may exhibit stiffness of the neck, difficulty in swallowing, opisthotonos, and rigidity of the pectoral, abdominal, and extremity muscle groups.² Most patients achieve a complete but slow recovery with good functional outcomes; however, elderly patients are particularly at risk of functional impairment.⁵

CASE REPORT

A 67-year-old farmer presented to the emergency department (ED) with severe abdominal pain, which had started as a mild, colicky pain in the left lower quadrant. Over a seven-day period, the pain intensified becoming more diffuse and associated with intermittent subjective fevers that prompted the patient to seek medical attention. He denied nausea, vomiting, gastrointestinal bleeding, constipation, and obstipation. He had no significant chronic medical or surgical history. The physical examination was significant for a rigid, diffusely tender abdomen, a normal digital rectal examination, and normal bowel sounds. The patient was afebrile and in distress with a normal oxygen saturation. His vital signs included a blood pressure of 140/90 millimeters of mercury, heart rate of 84 beats per minute, and a normal respiratory rate. Laboratory analysis showed normal complete blood counts, serum electrolytes and urinalysis, serum amylase and lipase. Electrocardiogram and chest radiograph were normal. Ultrasound of the abdomen was ordered. The patient was admitted with a provisional diagnosis of acute peritonitis.

Abdominal ultrasound was normal without evidence of intraperitoneal fluid collection or omental thickening. Subsequently, computed tomography (CT) of the abdomen and pelvis with intravenous (IV) contrast was performed after the patient's symptoms failed to improve. The CT was significant for bilateral nephrolithiasis but without findings suggestive of peritonitis including ascites and mesenteric/omental fat- stranding or thickening.⁶ The patient was started on conservative treatment with IV fluids, analgesic, and broad-spectrum antimicrobial agents.

Over the next 24 hours, the patient developed opisthotonos confirming the clinical diagnosis of tetanus. Further directed history obtained from the patient's wife revealed that he had sustained a contaminated laceration injury to his head approximately 45 days prior to his presentation to the ED. The wound was managed at a local medical store without any post-exposure, prophylaxis tetanus vaccine. Careful examination of the patient's scalp revealed a healing wound. Shortly thereafter, he developed laryngeal spasm requiring mechanical ventilation and was transferred to the intensive care unit. His treatment included human tetanus immunoglobulins, broad-spectrum antibiotics, muscle relaxants comprising diazepam and baclofen, IV hydration, and parenteral nutrition. The patient

CPC-EM Capsule

What do we already know about this clinical entity?

Tetanus is caused by spores of Clostridium tetani, causing impairment of motor neurons, particularly affecting people in low to middle-income countries (LMIC).

What makes this presentation of disease reportable?

We describe a rare case of tetanus presenting as an acute abdomen that could have led to misdiagnosis if pertinent history had been overlooked.

What is the major learning point?

In LMIC, patients presenting as acute abdomen and with a history of contaminated wounds should prompt the clinician to consider tetanus as a differential.

How might this improve emergency medicine practice?

This case reinforces the importance of prophylactic tetanus toxoid vaccine, especially in the elderly.

was successfully weaned off the ventilator after a two-week course. He was then transferred to a general ward and discharged from hospital one week later. He did not suffer any major sequelae after being discharged.

DISCUSSION

As demonstrated in this case, tetanus presenting as acute abdominal pain presents many challenges because it is uncommon, misleading, and non-specific to tetanus. Generalized rigidity with trismus is the most commonly reported symptom at onset in approximately 75% of cases.⁷ While uncommon, tetanus presenting as an acute abdomen in the ED has been reported by various authors over the last century.⁷⁻¹⁰

A patient presenting with an acute abdomen is frequently encountered in the ED and typical non-intraperitoneal differential diagnoses include muscle strain, rectus sheath hematoma, and herpes zoster. This case provides evidence that tetanus should also be included in the differential diagnosis of acute abdomen originating from the abdominal wall in patients from LMIC. Our patient's epidemiological profile fits into this description with a relatively high likelihood of acquiring a tetanus infection. Risk factors

include male gender, >65 years of age, farmer profession, late presentation without signs of wound infection, and lack of post-exposure, prophylaxis tetanus toxoid vaccine.¹¹

Abdominal rigidity has also been demonstrated as a first sign suggestive of tetanus in older children and adults.² The board-like abdominal rigidity is attributed to the spasm of abdominal muscles.¹² Abdominal rigidity can also be a symptom of localized tetanus when the abdominal wall is involved as the site of injury. In an emergency setting, it is challenging to discern abdominal pain from rigidity (which is specific to neuromuscular diseases such as tetanus) and pain from intraperitoneal processes. After imaging rules out serious causes of acute abdomen such as perforated viscus, acute intestinal obstruction, aortic dissection, and mesenteric ischemia, a further history of traumatic injuries, wounds, or infection should be considered in a patient presenting with abdominal rigidity. Furthermore, it is difficult to distinguish abdominal rigidity from abdominal guarding (involuntary tightening secondary to pain), which can be overcome by having the patient purposely relax the muscles.¹³

Most cases of tetanus occur in unvaccinated individuals and adults.² Studies show that patients over the age of 60 with inadequate immunity have antibodies below the 49-66% necessary protective level.⁴ In addition to providing post-exposure, tetanus toxoid vaccination in the emergency care setting to patients with open wounds and no vaccination in the prior 10 years, we recommend a booster dose every 10 years. The full course of vaccination regimen provides immunity to tetanus for 10 years in 95% cases.¹⁴ The immunization programs of many developing nations do not yet have a catch-up or booster immunization program targeted to the elderly. Providers practicing in such settings should not miss the opportunity to vaccinate people aged 65 years or older with combined tetanus, diphtheria and acellular pertussis vaccine (Tdap) in a non-emergency setting.¹⁵ We recommend booster immunization with Tdap because it is immunogenic in population 65 years or older, and has a good safety profile.

CONCLUSION

Tetanus is a vaccine-preventable disease that is still prevalent in many low and middle-income countries, although it is rare in high-income countries. The differential diagnosis in non-immunized older children and adults with abdominal rigidity should include generalized tetanus. Awareness and high index of suspicion in developing countries are crucial for early diagnosis and prompt initiation of appropriate treatment to avoid unnecessary intervention and procedures.

Patient consent has been obtained and filed for the publication of this case report.

Address for Correspondence: Sabin Nepal, MD, Nepalgunj Medical College and Teaching Hospital, Department of Radiology, Kohalpur Banke, Nepal. Email: sabinnepal03@gmail.com.

Conflicts of Interest: By the CPC-EM article submission agreement, all authors are required to disclose all affiliations, funding sources and financial or management relationships that could be perceived as potential sources of bias. The authors disclosed none.

Copyright: © 2020 Thakur et al. This is an open access article distributed in accordance with the terms of the Creative Commons Attribution (CC BY 4.0) License. See: <http://creativecommons.org/licenses/by/4.0/>

REFERENCES

1. European Centre for Disease Prevention and Control. Disease factsheet about tetanus. Available at: <https://www.ecdc.europa.eu/en/tetanus/facts>. Accessed June 25, 2020.
2. (2015). Tetanus. In: Hamborsky J, Kroger A, Wolfe C (Eds.), *Epidemiology and Prevention of Vaccine-Preventable Diseases: the Pink Book: Course Textbook*. Washington DC: Centers for Disease Control and Prevention.
3. Government of Nepal. Ministry of Health and Population. Department of Health Service. Annual Report 2017/2018. Available at: <https://dohs.gov.np/wp-content/uploads/2019/07/DoHS-Annual-Report-FY-2074-75-date-22-Ashad-2076-for-web-1.pdf>. Accessed August 7, 2020.
4. Cook TM, Protheroe RT, Handel JM. Tetanus: a review of the literature. *Br J Anaesth*. 2001;87(3):477-87.
5. Trung TN, Duoc NVT, Nhat LTH, et al. Functional outcome and muscle wasting in adults with tetanus. *Trans R Soc Trop Med Hyg*. 2019;113(11):706-13.
6. Filippone A, Cianci R, Delli Pizzi A, et al. CT findings in acute peritonitis: a pattern-based approach. *Diagn Interv Radiol*. 2015;21(6):435-40.
7. Chan ST and Kang CH. A case of tetanus mimicking acute abdomen. *Singapore Med J*. 1994;35(6):641-2.
8. Laha N. A case of tetanus simulating acute abdomen. *Ind Med Gaz*. 1942;77(11):677-8.
9. Cattaneo I and Vercillo L. Addome acuto medico da tetano [A case of acute abdomen caused by tetanus]. *Prog Med (Napoli)*. 1956;12(1):21-5.
10. Tihista JA, Guergué JM, Osés I, et al. Tétanos en una unidad de cuidados intensivos que simula un abdomen agudo [Tetanus at an intensive care unit simulating acute abdomen]. *Med Clin (Barc)*. 2000;114(5):197-8.
11. Sako FB, Sylla AO, Diallo MOS, et al. Tetanus: epidemiology and factors associated with death in the Department of Tropical and Infectious Diseases of Donka National Hospital, Guinea. *Med Sante Trop*. 2019;29(3):333-6.
12. Garcia-Palmieri MR and Ramirez R. Generalized tetanus: analysis of

- 202 cases. *Ann Intern Med.* 1957;47(4):721-30.
13. Ferguson CM. (1990). Inspection, auscultation, palpation, and percussion of the abdomen. In: Walker HK, Hall WD, Hurst JW, eds, *Clinical Methods: The History, Physical, and Laboratory Examinations 3rd ed.* Boston: Butterworths.
 14. Hammarlund E, Thomas A, Poore EA, et al. Durability of vaccine-induced immunity against tetanus and diphtheria toxins: a cross-sectional analysis [published correction appears in *Clin Infect Dis.* 2016;63(1):150]. *Clin Infect Dis.* 2016;62(9):1111-8.
 15. Havers FP, Moro PL, Hunter P, et al. Use of Tetanus toxoid, reduced diphtheria toxoid, and acellular pertussis vaccines: updated recommendations of the Advisory Committee on Immunization Practices - United States, 2019. *MMWR Morb Mortal Wkly Rep.* 2020;69(3):77-83.

A Case Report of B-cell Lymphoblastic Leukemia/Lymphoma Presenting as Isolated Torticollis in a 2-year-old Female

Marina Boushra, MD

East Carolina University School of Medicine, Department of Emergency Medicine, Greenville, North Carolina
Vidant Medical Center, Department of Emergency Medicine, Greenville, North Carolina
Vidant Beaufort Hospital, Department of Emergency Medicine, Washington, North Carolina

Section Editor: Anna McFarlin, MD

Submission history: Submitted June 2, 2020; Revision received August 2, 2020; Accepted August 21, 2020

Electronically published October 19, 2020

Full text available through open access at http://escholarship.org/uc/uciem_cpem

DOI: 10.5811/cpem.2020.8.48524

Introduction: Malignancy is a rare cause of acquired torticollis in children, and spinal cord involvement from hematolymphoid malignancies is similarly unusual. Neurologic abnormalities may not be present on initial evaluation, and delayed diagnosis and treatment is associated with increased risk of permanent paralysis.

Case Report: The author describes a case of isolated torticollis in a 2-year-old evaluated multiple times in the emergency department (ED) and outpatient settings. For her first three presentations, the patient had no associated neurologic abnormalities. She was discharged with return precautions and a presumptive diagnosis of viral infection/lymphadenitis. She later developed weakness of her left arm and was diagnosed with a B-cell lymphoblastic leukemia/lymphoma causing spinal cord compression.

Conclusion: This case highlights the importance of continued comprehensive and meticulous physical examination in patients with repeat ED visits, as well as the value of detailed discharge instructions in mitigating diagnostic delays in these patients. [Clin Pract Cases Emerg Med. 2020;4(4):603–606.]

Keywords: *atraumatic torticollis; malignancy.*

INTRODUCTION

Evaluation of pediatric neck complaints in the emergency department (ED) is challenging, as the differential is broad and a complete history is often difficult to obtain in pre-verbal patients. History and physical examination are sufficient for diagnosis in most patients. However, when additional evaluation would be helpful, it is often hindered by concerns over radiation exposure in pediatric patients, limited availability of magnetic resonance imaging (MRI) capabilities, and the need for sedation to obtain high-quality images in some pediatric patients.^{1,2}

Acquired torticollis is a common complaint in pediatric patients and is caused by trauma or infection in the vast majority of cases.³ Malignancy is a rare cause of torticollis in children, and hematolymphoid malignancies can rarely present with spinal cord involvement.^{4,5} Early in the clinical

course, these patients may not have associated neurologic or laboratory abnormalities.^{6,7} Here the author presents a case of a patient with painless atraumatic torticollis without associated neurologic abnormalities evaluated in the ED who was later diagnosed with B-cell lymphoblastic leukemia/lymphoma with cervical cord compression.

CASE REPORT

A previously healthy 2-year-old female presented to the ED with her mother for neck pain and limited neck rotation that had started that day. At the time of her first evaluation, she had normal vital signs, normal movement of her neck, no lymphadenopathy, a normal neurologic examination, and rhinorrhea. The mother expressed concern that her symptoms were occurring secondary to an impact to her neck when she struck a table the prior day. Both traumatic and viral causes of

torticollis were considered in this patient. Due to the presence of rhinorrhea and the lack of neurologic or traumatic findings, the patient was diagnosed with a presumptive viral infection and discharged with instructions for supportive care and routine follow-up.

The patient re-presented to the ED with her father two days later with complaint of inability to rotate her head to the right. She was receiving acetaminophen at home without improvement in her symptoms. Her behavior and appetite were unchanged from her baseline. In the ED, her vital signs were again normal and her exam was notable for head deviation to the left with increased tone of the left sternocleidomastoid and multiple enlarged, non-tender, matted lymph nodes in the left anterior cervical chain. A review of systems was notably negative for any recent fevers, changes in appetite or weight, rashes, or bruising. Her neurologic examination was normal and the remainder of her examination, including auscultation over the carotids and a pharyngeal examination, was unremarkable. She showed some improvement with ibuprofen and diazepam and was discharged with a presumptive diagnosis of viral vs traumatic torticollis.

The patient then presented to her primary care provider four days later with persistent inability to rotate her neck. Her exam was unchanged at that time and she was discharged with a diagnosis of viral lymphadenitis and instructions for continued supportive care and a follow-up appointment four days later. At her follow-up appointment her symptoms persisted, and because her oral intake had decreased she was referred for admission. Her admission labs, including a complete blood count with differential, were normal. A computed tomography (CT) of the soft tissue of the neck with contrast was obtained and initially read as unremarkable. She remained hospitalized for four days for pain control and physical therapy without improvement in the range of motion of her neck. On the fourth day of her hospitalization, she developed weakness in her left arm and increasing lethargy. This prompted re-examination of her initial CT, where a possible spinal cord tumor was noted (Image, panel A). Follow-up MRI showed an extramedullary tumor extending from the level of the second cervical vertebra (C2) to the seventh cervical vertebra (C7) with associated cord edema (Image, panel B).

Given her declining neurologic status, she was given dexamethasone for the cord edema. A cervical mass biopsy and bone marrow biopsy done 72 hours later were both inconclusive. Repeat MRI showed complete resolution of the mass with the steroids. Based on this response to steroids, a presumptive diagnosis of leukemia/lymphoma was made and the patient was discharged on dexamethasone. Four days later, she presented to the pediatric ED again, this time with left facial droop and weakness of the upper and lower extremities on the left side. Examination was notable for swelling of the right wrist and left leg. A lytic lesion was noted on radiograph

CPC-EM Capsule

What do we already know about this clinical entity?

The vast majority of acquired pediatric torticollis presentations occur secondary to trauma or viral infection.

What makes this presentation of disease reportable?

This is a case of painless, atraumatic torticollis without neurological abnormalities ultimately diagnosed as B-cell lymphoma with cervical cord compression.

What is the major learning point?

Torticollis may precede the presence of neurological symptoms in pediatric cervical spine malignancies.

How might this improve emergency medicine practice?

This case illustrates the importance of repeat neurologic examinations with repeated presentations and detailed return precautions in pediatric torticollis.

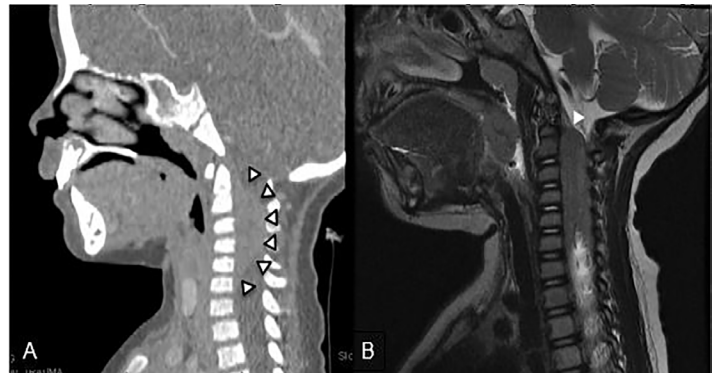


Image. (A) Computed tomography with contrast of neck soft tissue, initially read as containing no pathology. Note the subtle hyperlucent lesion extending from the level of the second cervical vertebra (C2) to the seventh cervical vertebra (C7) (black-edged white arrows), corresponding to the hypodense region on the magnetic resonance imaging (MRI) (B). MRI with contrast of the cervical spine showing a heterogeneously enhancing mass extending from C2 to C7 with edema and cord flattening (white arrow).

of the right ulna. An iliac biopsy was again non-diagnostic. On the second day of her hospitalization, she also developed subcutaneous scalp nodules. Biopsies and flow cytometry

of the nodules were consistent with B-cell lymphoblastic leukemia/lymphoma. The patient was started on chemotherapy and is currently doing well, with strength in her extremities improving with physical therapy.

DISCUSSION

The differential of acquired torticollis is broad and includes a variety of benign and eminently life-threatening conditions. The vast majority of cases are caused by self-limiting infections and trauma. Conditions such as retropharyngeal abscesses and atlantoaxial rotary subluxation are uncommon but important considerations that need urgent management. Central nervous system malignancies account for only an estimated 2% of pediatric cases of acquired torticollis.³ However, one retrospective review of pediatric patients under 13 years of age with tumors of the posterior fossa or cervical spine noted acquired, atraumatic torticollis as the presenting symptom in 22% of the cases.⁶ In the subgroup including only cervical spine malignancies, like the reported patient, 10% presented with isolated torticollis.⁶ In all cases in this study, torticollis preceded the onset of neurologic symptoms, and an average of 9.5 weeks passed before neurologic manifestations developed and led to a diagnosis of malignancy.⁶ The mechanism of torticollis in cervical cord tumors is poorly understood but is theorized to be secondary to compression of the spinal accessory nerve (cranial nerve XI) by the mass.⁴

Neurologic examination is a critical part of the evaluation of any patient with neck complaints. Any abnormality in neurologic examination is a “red flag symptom” that should prompt additional evaluation, typically with imaging of the neck. However, studies have shown that torticollis can precede the onset of neurologic findings by days or weeks in malignancies of the cervical spine and posterior fossa. Concern for the radiation exposure associated with CT imaging of the spine in children precludes routine imaging of these patients.^{1,2} MRI is costly, not typically feasible in the ED setting, and may require sedation in young children.⁸⁻¹⁰

While clinical decision tools such as the Pediatric Emergency Care Applied Research Network criteria and the Pediatric Appendicitis Score have aided in decreasing unnecessary imaging in certain pediatric conditions, there are no guidelines or risk-stratification tools to aid emergency physicians in determining the need for additional evaluation in patients presenting with atraumatic torticollis without neurologic deficits.¹⁰ Given the rarity of this diagnosis, the paucity of physical examination findings early in the course, and the risks of unnecessary imaging in pediatric patients, some diagnostic delay may, unfortunately, be inevitable. However, such cases serve as a reminder of the importance of considering malignancy in patients presenting with atraumatic torticollis, repeating thorough neurologic examinations with repeated ED presentations, and providing detailed return instructions to parents.

CONCLUSION

Acquired torticollis is a common pediatric ED presentation that is usually caused by infection or trauma. Neurologic examination is an essential component of the evaluation of any patient presenting with neck complaints. However, up to 10% of patients with cervical cord malignancy can present with sudden-onset, acquired torticollis without evidence of neurological abnormalities. It is understandably difficult to risk-stratify these patients for imaging given the rarity of this diagnosis and the paucity of physical examination findings. This case of a hematolymphoid malignancy with central neurologic involvement highlights the importance of continued comprehensive and meticulous physical examination in patients with repeat ED visits, as well as the value of detailed discharge instructions. While an uncommon cause and presentation, malignancy of the central nervous system should be considered as a cause of sudden-onset torticollis in pediatric patients and additional evaluation, including MRI, should be considered in patients with sudden onset of symptoms or those with a protracted course.

The author attests that her institution requires neither Institutional Review Board approval, nor patient consent for publication of this case report. Documentation on file.

Address for Correspondence: Marina Boushra, MD, East Carolina University School of Medicine, Department of Emergency Medicine, 2100 Stantonsburg Rd, Greenville, NC 27834. Email: mnb9143@gmail.com.

Conflicts of Interest: By the *CPC-EM* article submission agreement, all authors are required to disclose all affiliations, funding sources and financial or management relationships that could be perceived as potential sources of bias. The author disclosed none.

Copyright: © 2020 Boushra. This is an open access article distributed in accordance with the terms of the Creative Commons Attribution ([CC BY 4.0](http://creativecommons.org/licenses/by/4.0/)) License. See: <http://creativecommons.org/licenses/by/4.0/>

REFERENCES

1. Frush DJ, Commander CW, Hartman TS, et al. Utilization of computed tomography imaging in the pediatric emergency department. *Pediatr Radiol.* 2020;50(4):470-5.
2. Matthews JD, Forsythe AV, Brady Z, et al. Cancer risk in 680000 people exposed to computer tomography scans in childhood or adolescence: data linkage study of 11 million Australians. *BMJ.* 2013;346:f2360.
3. Per H, Canpolat M, Tümtürk A, et al. Different etiologies of acquired

- torticollis in childhood. *Childs Nerv Syst.* 2014;30(3):431-40.
4. Pandey S, Gokden M, Kazemi NJ, et al. Hematolymphoid malignancies presenting with spinal epidural mass and spinal cord compression: a case series with rare entities. *Ann Clin Lab Sci.* 2019;49(6):818-28.
 5. Tumturk A, Kaya Ozcora G, Kacar Bayram A, et al. Torticollis in children: an alert symptom not to be turned away. *Childs Nerv Syst.* 2015;31(9):1461-70.
 6. Fařara-Leř A, Kwiatkowski S, Maryńczak L, et al. Torticollis as a first sign of posterior fossa and cervical spinal cord tumors in children. *Childs Nerv Syst.* 2014;30(3):425-30.
 7. Kumandař S, Per H, Gümüş H, et al. Torticollis secondary to posterior fossa and cervical spinal cord tumors: report of five cases and literature review. *Neurosurg Rev.* 2006;29(4):333-8.
 8. Wachtel RE, Dexter F, Dow AJ. Growth rates in pediatric diagnostic imaging and sedation. *Anesth Analg.* 2009;108(5):1616-21.
 9. McGuirt D. Alternatives to sedation and general anesthesia in pediatric magnetic resonance imaging: a literature review. *Radiol Technol.* 2016;88(1):18-26.
 10. Ohana O, Soffer S, Zimlichman E, et al. Overuse of CT and MRI in paediatric emergency departments. *Br J Radiol.* 2018;91(1085):20170434.

Case Report: Spontaneous Rupture of Inferior Epigastric Artery Masquerading as Inguinal Hernia

Kathryn Sulkowski, MD
Christian Young, MD

University of Nevada, Department of Emergency Medicine, Las Vegas, Nevada

Section Editor: Manish Amin, DO

Submission history: Submitted June 9, 2020; Revision received August 23, 2020; Accepted September 4, 2020

Electronically published October 19, 2020

Full text available through open access at http://escholarship.org/uc/uciem_cpchem

DOI: 10.5811/cpcem.2020.9.48629

Introduction: Spontaneous rupture of an inferior epigastric artery aneurysm is rare with very few cases reported in the medical literature. Although surgical options are available, this case was managed conservatively with outpatient management.

Case Report: A 29-year-old male presented with right groin pain and swelling that was initially felt to be consistent with an incarcerated inguinal hernia. Further evaluation revealed spontaneous rupture of an inferior epigastric artery aneurysm. The patient was treated conservatively and was ultimately discharged home from the emergency department.

Conclusion: Due to the similar clinical presentations, it was important to consider a broad differential to ultimately arrive at the correct diagnosis. In some reported cases of spontaneous epigastric artery aneurysm, surgical intervention was required for control of the bleeding. In our patient, however, conservative management was employed, and the patient was able to be safely discharged with close outpatient follow-up. [Clin Pract Cases Emerg Med. 2020;4(4):607–609.]

Keywords: *inferior epigastric artery rupture.*

INTRODUCTION

Spontaneous rupture of an inferior epigastric artery aneurysm is very rare with very few cases reported in the medical literature.^{1,2,4,5} Presentations are typically varied and with symptoms that are commonly mistaken for a more common diagnosis, making the definitive diagnosis difficult to come to unless there is a clear provocation, such as obvious trauma.¹ In this report we describe the case of an inferior epigastric artery aneurysm rupture presenting as right inguinal pain occurring shortly after sexual intercourse. The symptoms were initially felt to be due to an incarcerated inguinal hernia. Although surgical options are available, this case was managed conservatively with outpatient management.

CASE REPORT

A 29-year-old male presented to the emergency department (ED) with progressive right groin pain and swelling for the prior 24 hours. The patient stated that while he was incarcerated, he

was informed by medical staff that he had an inguinal hernia. The patient was released from prison to a sober living facility the day prior to presentation to the ED. He reported a history of sexual intercourse shortly before symptom onset. Since that time, he had noted increased swelling and tenderness to the area. He presented to the ED due to the increasing severity of the pain. He had a normal bowel movement one day prior to presentation and endorsed passing gas the day of presentation. He denied nausea, vomiting, diarrhea, fever, chest pain, or shortness of breath. He had no dysuria, hematuria, or flank pain. He denied any associated penile discharge, testicular pain, or skin rashes or lesions.

The patient had no past medical history and reported no daily medications. He was newly sexually active with one female partner one time prior to presentation and had been abstinent in prison. He denied a history of sexually transmitted infections. He smoked cigarettes and drank alcohol occasionally but denied any illegal drug use.

Physical exam revealed a thin male resting comfortably on the stretcher. Vital signs were only notable for mild resting tachycardia with a pulse of 102 beats per minute; blood pressure 125/73 millimeters mercury; oral temperature 37.1°C; and oxygen saturation 100% on room air. The head, eyes, ears, nose, and throat, cardiac, and respiratory exams were all unremarkable. The abdomen was soft, nontender, nondistended, with normoactive bowel sounds and no organomegaly. There was no costovertebral angle tenderness.

Genitourinary exam demonstrated a large mass in the right groin region with no overlying skin changes. The bulge was mildly tender to palpation, with no fluctuance noted. Gentle pressure applied to the area did not result in reduction of the bulge. The testicular exam demonstrated normal testicular lie with no abnormal swelling, tenderness, discoloration, or rash. The cremasteric reflex was present bilaterally. The penis was nontender, uncircumcised, and had no lesions or rashes.

Initial diagnostic evaluation demonstrated a white blood cell count of 10,740 cells per/liter (L) (reference [ref] range: 4,500 to 11,000 cells/L); hemoglobin of 15.3 grams per deciliter (g/dL) (ref range: 13.5-17.5 g/dL), and platelets of 233,000 cells/L (ref range: 150,000-450,000 cells/L). The comprehensive metabolic panel was only remarkable for an alanine aminotransferase of 61 international units (IU)/L (ref range: 29-33 IU/L); all electrolytes were within normal limits. A urinalysis demonstrated no cells or bacteria. Lactic acid was normal at 1.10 millimoles (mmol)/L (ref range: 0.5-2.2 mmol/L). The patient was administered 4 milligrams of morphine for pain, which improved his discomfort.

A computed tomography (CT) of the abdomen and pelvis was obtained out of concern for an incarcerated inguinal hernia. It revealed a heterogeneous mass-like process noted within the right inguinal region estimated at approximately 6.2 x 7.1 x 7.7 centimeters (cm) in size (Image). There was stranding of the adjacent fat of the groin with findings suggestive of large hematoma or heterogeneous, soft-tissue mass. There were also prominent lymph nodes and stranding of the fat seen within the right groin with largest lymph node

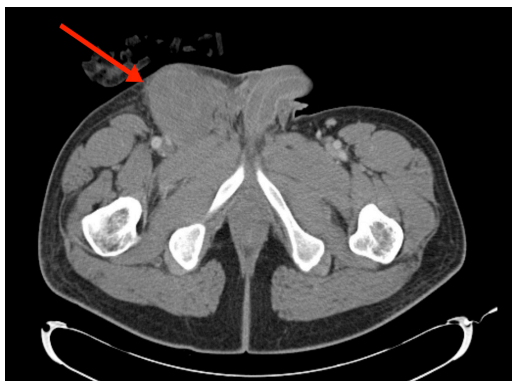


Image. Computed tomography demonstrating a large heterogeneous, mass-like process within the right groin, which may be related to an unusually large hematoma.

CPC-EM Capsule

What do we already know about this clinical entity?

Almost no cases in the literature since the early 1900s have reported conservative management for spontaneous epigastric artery aneurysm.

What makes this presentation of disease reportable?

Though surgical management for bleeding is more common, outpatient management is an option in certain cases and saves the patient a potentially unnecessary surgery.

What is the major learning point?

In patients who present with sudden onset of groin pain and swelling, it is important to consider this diagnosis and the need for surgical versus conservative management.

How might this improve emergency medicine practice?

Physicians should keep a broad differential for groin pain and swelling while introducing a rare entity that may initially be thought to be an incarcerated hernia.

estimated up to 1.8 x 0.7 cm in size. The mass was noted to extend to the musculature of the right groin but did not appear to be related to a hernia. Due to the unusual finding on the CT and the patient's continued pain, general surgery service was consulted. After a bedside evaluation, it was determined that these findings were consistent with a spontaneous rupture of an inferior epigastric artery aneurysm. Per the general surgery team there was no need for admission or surgery. The patient was then discharged with instructions to use warm compresses to help the mass decrease in size over time and to use acetaminophen for pain control. At the time of discharge the patient was no longer tachycardic, was afebrile, and had a normal blood pressure. He did not present to our hospital or outpatient clinics again since his evaluation in the ED.

DISCUSSION

The rupture of inferior epigastric vessels is not a common occurrence. An exploration of both emergency medicine and surgical literature did not demonstrate a consistent explanation or description of this condition.^{1,2,4,5} The differential diagnosis for this presentation is diverse, and the outcomes/management vary based on which diagnosis is selected. While it is an

uncommon presentation that can be easily confused with other diagnoses, early diagnosis will result in a decrease in unnecessary laboratory procedures and possibly even surgical intervention.¹ Spontaneous rupture of an epigastric artery aneurysm typically presents with sudden onset of severe pain to the left or right of midline, typically at the level of the umbilicus but it could also be lower, even in the groin.¹ Although typically abrupt in onset, several cases have been reported that involved insidious onset over five to seven days.¹

The first case of inferior epigastric artery rupture was reported in 1857 by Richardson.² After this there were a few case reports in the literature in the early 1900s. Recently there have been a few more case reports detailing catastrophic cases of rupture in the setting of aortic dissection.³ Typically these cases are treated with surgery, traditionally open repair, and more recently with endovascular technology. Depending on the location in the artery where the aneurysm and rupture occur dictates the need for surgery as those at the distal branches tend to cause less catastrophic bleeding, which typically tamponades off in the tissues.¹

As there is a long list of diagnoses for groin or abdominal pain with a visible bulge or mass, many conditions can be confused for the rupture of the inferior epigastric artery aneurysm. Some examples are incarcerated or strangulated inguinal hernia, tumors of the abdominal musculature, ovarian cysts, appendicitis, abscess of the abdominal wall, mesenteric thrombosis, muscle rupture and, in a few reported cases, intestinal obstruction.^{1,4} Various physical exam clues can help to delineate this diagnosis from others on the list. One characteristic is that the mass does not change its position and always appears fixed in the abdominal wall. This mass will remain present regardless of the patient's positioning and cannot be moved from side to side or reduced with pressure on the area. This sign was first described by Fothergill.⁵ Some cases describe extreme pain and, in rare cases, frank shock. However, most cases described discuss slight elevations in temperature, pulse, and white blood cell count.⁵

With regard to treatment options, there are two schools of thought. The majority of surgeons appear to advocate for surgical intervention to find and ligate the bleeding as the safest and surest therapy.⁵ However, there is a smaller minority that advocates for a more conservative non-operative approach. This includes warm compresses, pain control, and abdominal compressive devices.¹ The conservative approach does run the risk of continued and worsening bleeding, abscess formation, or calcification with chronic pain.¹ Conservative management in a select patient population, however, can prevent unnecessary surgical intervention. In our patient, with stable vital signs, pain that was adequately controlled, with no signs of continued bleeding (the mass had not increased in size in the nearly eight hours he was in the ED), and a patient who understood the reasons to return to the

ED, discharge with symptomatic treatment proved the less-invasive option.

CONCLUSION

We report the case of a 29-year-old male with a ruptured inferior epigastric artery aneurysm. He presented to the ED with a painful right groin bulge, which is a typical presentation of this entity. CT demonstrated a mass concerning for a hematoma but no signs of hernia. Spontaneous rupture of an inferior epigastric artery aneurysm is a rare entity that can masquerade as multiple other diagnoses. In patients who present to the ED with sudden onset of new groin pain and swelling, it is important to consider this diagnosis and consider early consultation with a surgical team, especially in the case of questionably stable patients who will likely need to go to the operating room for stabilization. In stable patients, however, conservative management can be appropriate.

The authors attest that their institution requires neither Institutional Review Board approval, nor patient consent for publication of this case report. Documentation on file.

Address for Correspondence: Kathryn Sulkowski, MD, University of Nevada, Department of Emergency Medicine, 901 Rancho Lane, Ste 135, Las Vegas, NV 89106. Email: Kathryn.Sulkowski@unlv.edu.

Conflicts of Interest: By the CPC-EM article submission agreement, all authors are required to disclose all affiliations, funding sources and financial or management relationships that could be perceived as potential sources of bias. The authors disclosed none.

Copyright: © 2020 Sulkowski et al. This is an open access article distributed in accordance with the terms of the Creative Commons Attribution (CC BY 4.0) License. See: <http://creativecommons.org/licenses/by/4.0/>

REFERENCES

1. Payne RL. Spontaneous rupture of the superior and inferior epigastric arteries within the rectus abdominis sheath. *Ann Surg.* 1938;108(4):757-68.
2. Herrman C. Rupture of the deep epigastric vessels. *Am J Surg.* 1946;71:553-5.
3. Gou M, Feng X, Lu Q, et al. Endovascular covered stent for inferior epigastric artery rupture after EVAR for Stanford B aortic dissection. *Euro J Vasc Endovasc Surg.* 2009;37(1):119-.
4. Kinder CH. A case of spontaneous rupture of the inferior epigastric artery simulating acute intestinal obstruction. *Br J Surg.* 1952;40(159):88-9.
5. Murray SD and Burger RE. Rupture of the inferior epigastric vessels. *Ann Surg.* 1954;139(1):90-4.

Gastric Diverticulum Presenting as Hematemesis: A Case Report Detailing an Uncommon Presentation of an Already Rare Entity

Maddi Massa, DO
Karla Newbold, MD

Spectrum Health Lakeland, Department of Emergency, Saint Joseph, Michigan

Section Editor: Rick A. McPheeters, DO

Submission history: Submitted June 5, 2020; Revision received August 24, 2020; Accepted September 4, 2020

Electronically published October 26, 2020

Full text available through open access at http://escholarship.org/uc/uciem_cpem

DOI: 10.5811/cpcem.2020.9.48603

Introduction: Gastric diverticula (GD) are uncommon. Most are asymptomatic and diagnosed incidentally. Symptoms range from reflux and epigastric discomfort to life-threatening bleeding and perforation. We describe a case of symptomatic GD presenting as hematemesis requiring surgical treatment.

Case Report: A 57-year-old female presented to the emergency department (ED) with one day of epigastric pain and hematemesis. Hemoglobin was found to be stable, but blood urea nitrogen was elevated. Imaging revealed a fundal GD. Esophagogastroduodenoscopy did not show other etiology of hematemesis. The patient underwent partial gastric resection for GD removal and did well without further symptoms on follow-up.

Conclusion: Although rare, GD needs to be included on a differential diagnosis when evaluating gastrointestinal symptoms in the ED. Patients may present with an array of complaints but can potentially develop serious complications. Providers should be familiar with the diagnostic options and treatment regimens available to better care for patients presenting with GD. [Clin Pract Cases Emerg Med. 2020;4(4):610–612.]

Keywords: *Gastric diverticulum; hematemesis.*

INTRODUCTION

Gastric diverticula (GD) are extremely rare.¹ Prevalence ranges from 0.04% on imaging studies and 0.01-0.11% on esophagogastroduodenoscopy (EGD).² Most diverticula are diagnosed incidentally, as the majority are asymptomatic.² Symptomatic patients can experience a wide range of ailments from mild discomfort and reflux to perforation and life-threatening bleeding.³ Management depends on symptoms and diverticular size.³ Although most patients with GD are diagnosed on an outpatient basis, or other subsequent workup, this case report demonstrates an emergency department (ED) diagnosis of a bleeding GD requiring surgical treatment.

CASE REPORT

A 57-year-old female presented to the ED with upper abdominal pain and hematemesis for two to three hours.

She had been experiencing malaise and fatigue during the preceding night. Past medical history included schizoaffective disorder, diabetes, gastroesophageal reflux disease (not currently on medical management), and chronic pain. She lived at an adult foster-care facility. Due to her underlying psychiatric issues, history was very limited. She reported associated nausea with vomiting three times. These episodes involved bright red blood about the size of her palm. She reported normal bowel movements. She did smoke cigarettes but denied any alcohol or illicit drug use.

Vital signs revealed slight tachycardia with heart rate at 105 beats per minute. Other vital signs were within normal limits with blood pressure of 101/65 millimeters of mercury, temperature of 97.9 degrees Fahrenheit, and respirations of 20 breaths per minute with 94% oxygenation. On physical examination, she was in mild distress from pain. The patient

exhibited tenderness to palpation of the epigastrium, as well as the right and left upper quadrants, without rebound or guarding. Laboratory analysis revealed results significant for a hemoglobin of 14.1 grams per deciliter (g/dL) (reference range 12-16 g/dL), a blood urea nitrogen of 24 milligrams (mg)/dL (reference range 6-20 mg/dL), normal prothrombin time, normal partial thromboplastin time, and normal platelets. An upright chest radiograph did not reveal free air under the diaphragm or other signs of perforation. The patient was initially treated with normal saline bolus, anti-emetics, pantoprazole, and fentanyl.

Due to limited history, a computed tomography (CT) of the abdomen and pelvis was also ordered. CT of the abdomen and pelvis revealed a 3.1-centimeter (cm) posterior-inferior fundal gastric diverticulum. (Image 1). General surgery consult recommended pantoprazole infusion and planned for EGD later that day. The patient required additional pain management. She underwent EGD the next day and was found to have a wide-mouthed gastric diverticulum at the posterior fundus without active signs of bleeding. (Image 2). No other abnormalities on EGD were noted. The procedure had to be aborted slightly early due to hypoxia that resolved with simple maneuvers.

She did not have any further pain, nausea, or hematemesis during the remainder of her hospitalization. She was discharged the next day on proton pump inhibitor (PPI) therapy with plans for further partial gastrectomy and diverticulectomy. She returned one week later and underwent a laparoscopic resection of the gastric diverticulum and lysis of adhesions. She had an unremarkable postoperative course. Upon follow-up 11 days later, she had no further issues and has not returned with recurrent symptoms. She was continued on PPI therapy. Pathology of the diverticulum revealed normal gastric mucosa without malignancy.

CPC-EM Capsule

What do we already know about this clinical entity?

Gastric diverticuli (GD) are rare and usually diagnosed incidentally or outpatient. Most are asymptomatic but severe complications can occur.

What makes this presentation of disease reportable?

This case was diagnosed from the emergency department (ED) with excellent computed tomography images. This author was unable to find any GD reports in ED literature.

What is the major learning point?

Emergency physicians need to keep this entity on their differential as perforation, significant bleeding, malignancy, and infectious sequelae can all result from GD.

How might this improve emergency medicine practice?

Increased awareness of GD, and management options, should improve patient centered care with both severe and mild cases of GD.

DISCUSSION

Gastric diverticula are extremely uncommon, being the least common type of intestinal diverticula.¹ They tend to affect

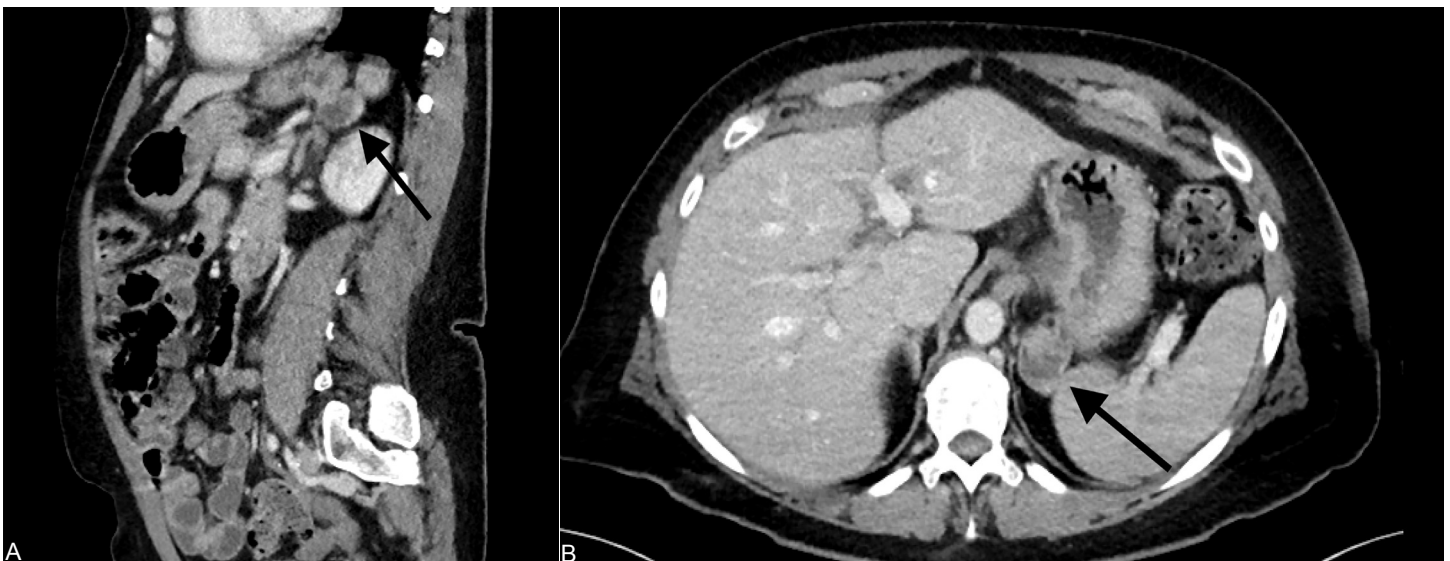


Image 1. Sagittal (A) and axial (B) images illustrating a 3.1-centimeter posterior-inferior fundal gastric diverticulum on computed tomography using intravenous contrast.

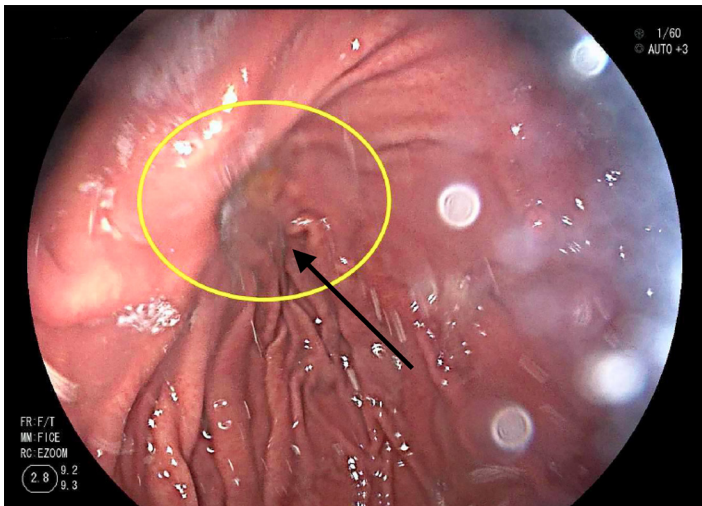


Image 2. Esophagogastroduodenoscopy showing the mouth of a posterior-inferior fundal gastric diverticulum.

males and females equally.¹ Normal diverticular size is usually between 1-5 cm, but sizes up to 11 cm have been described.^{1,3} Classification can be subdivided into true (congenital) and false (acquired) diverticula; with true diverticula involving all layers of the gastric wall.³ False diverticula can be further classified into pulsion and traction diverticula, which result from increased intraluminal pressures or perigastric adhesions.³ True diverticula are more common (70-75% of GD) and arise from the posterior fundus, whereas false diverticula are usually found at the antrum of the stomach.^{1,3}

The favored means of diagnosis is with EGD or upper gastrointestinal (GI) contrast radiographic study. While CT can be used for diagnosis it is not as reliable as the aforementioned methods due to the risk of misdiagnosis; however, oral contrast included in CT protocol may help increase sensitivity.²

Management of gastric diverticula is based on symptoms. Most asymptomatic patients do not require any treatment.² Patients who experience reflux, epigastric pain, and halitosis can be trialed on a PPI. This may not be effective, however, as it does not address the underlying pathophysiology of the GD; food and gastric juices can still be retained in the diverticulum, causing distention, pain, and subsequent reflux.³ It is thought that diverticula with larger mouths are less symptomatic due to decreased chance of content retention.^{1,3} Some portion of patients with diverticula have other GI pathology. GD may simply worsen symptoms or conversely may not affect them at

all.¹ Surgical management is preferred when diverticula are large, symptomatic, cause bleeding, perforation, or are associated with abscess and malignancy.² Laparoscopic resection, possibly with intraoperative EGD, is preferred over laparotomy.¹

CONCLUSION

Due to the potentially life-threatening complications with which gastric diverticulum can present, emergency physicians should keep this entity on their differential diagnosis.^{1,3} Providers need to be alert to the possibility of GD causing symptoms ranging from minor reflux and pain to refractory gastroesophageal reflux disease, hematemesis, perforation, or malignancy. Patients may present for the first time with upper GI hemorrhage or perforation needing emergent surgery.^{1,3} Providers should be familiar with the diagnostic options and treatment regimens available to better care for patients presenting with known or unknown gastric diverticulum.

The authors attest that their institution requires neither Institutional Review Board approval, nor patient consent for publication of this case report. Documentation on file.

Address for Correspondence: Maddi A. Massa, DO, Spectrum Health Lakeland, Department of Emergency Medicine, 1234 Napier Avenue, Saint Joseph, MI 49085. Email: maddi.massa@spectrumhealth.org.

Conflicts of Interest: By the CPC-EM article submission agreement, all authors are required to disclose all affiliations, funding sources and financial or management relationships that could be perceived as potential sources of bias. The authors disclosed none.

Copyright: © 2020 Massa et al. This is an open access article distributed in accordance with the terms of the Creative Commons Attribution (CC BY 4.0) License. See: <http://creativecommons.org/licenses/by/4.0/>

REFERENCES

1. Shah J, Patel K, Sunkara T, et al. Gastric diverticulum: a comprehensive review. *Inflamm Intest Dis*. 2019;3(4):161-6.
2. Rashid F, Aber A, Iftikhar SY. A review on gastric diverticulum. *World J Emerg Surg*. 2012;7(1):1.
3. Marano L, Reda G, Porfida R, et al. Large symptomatic gastric diverticula: two case reports and a brief review of literature. *World J Gastroenterol*. 2013;19(36):6114-7.

Dysphagia Alone as a Unique Presentation of Wound Botulism in the Emergency Department: A Case Report

Ryan H. Wyatt, MD
Eytan Shtull-Leber, MD
Thomas E. Kelly, MD

Valleywise Health Medical Center, Department of Emergency Medicine, Phoenix, Arizona

Section Editor: Austin Smith, MD

Submission history: Submitted June 10, 2020; Revision received August 27, 2020; Accepted September 7, 2020

Electronically published October 20, 2020

Full text available through open access at http://escholarship.org/uc/uciem_cpccem

DOI: 10.5811/cpcem.2020.9.48664

Introduction: Wound botulism is a rare and potentially fatal infectious disease, often seen in patients who abuse injection drugs. It classically presents with dysfunction of bilateral cranial nerves followed by proximal and distal motor weakness, which can progress to respiratory failure.

Case Report: We report a case of a 31-year-old female who presented to the emergency department for the fifth time with an eight-day history of isolated dysphagia without any other neurologic symptoms. She reported a history of injection drug abuse via “skin popping,” was admitted to the hospital, and ultimately diagnosed with wound botulism.

Conclusion: This case exemplifies the diagnostic pitfalls of rare diseases such as wound botulism and provides insight regarding the diagnosis and treatment of this entity. This case also highlights the unique medical and social challenges emergency physicians face while trying to reliably evaluate patients who abuse controlled substances. [Clin Pract Cases Emerg Med. 2020;4(4):613–616.]

Keywords: *Wound; botulism; dysphagia.*

INTRODUCTION

According to the Centers for Disease Control and Prevention (CDC), in 2017 there were 182 laboratory-confirmed cases of botulism reported in the United States, 19 (10%) of which were secondary to wound botulism. Of those 19 patients, none died.¹ Wound botulism is usually seen in persons who use injection drugs, most commonly using a technique known as “skin popping” (under the skin vs in a vein), or “muscling.”¹ While wound botulism is a rare entity overall, it does carry a significant morbidity and mortality risk, even if treated.² Wound botulism from injecting drugs is a well-defined entity in the medical literature.^{3,4} It is especially common among patients who abuse black tar heroin.⁴

Usually, patients infected with a toxin-producing strain of *Clostridium botulinum* experience cranial nerve dysfunction, commonly affecting more than five cranial nerves.⁵ Symptoms then progress to proximal muscle weakness followed by distal muscle weakness, with respiratory impairment that may require mechanical ventilation. If left untreated, respiratory

muscle weakness can lead to respiratory failure and death. We present a case of a patient with isolated dysphagia as a primary symptom, with an initially non-progressive course that later progressed to cranial nerve dysfunction.

CASE REPORT

A 31-year-old female presented to the emergency department (ED) with an eight-day history of dysphagia, initially to solids then progressing to liquids. The patient denied any other neurologic or gastrointestinal symptoms. The patient had been seen in the ED multiple times for the same complaint, including two visits to other EDs and two prior visits to our ED. During the encounters at the other EDs, she had reportedly had a negative magnetic resonance imaging (MRI) of the brain. On the patient’s initial evaluation in our ED, she denied progressive symptoms and had a neurologic exam that did not reveal any bulbar weakness, ptosis, or gross motor weakness. The patient was noted to have chronic-appearing open wounds to her bilateral upper extremities

consistent with a self-reported history of skin-popping/muscling; however, none of the wounds appeared to be acutely infected. After a discussion with radiology, it was felt a swallow study would not be clinically beneficial given her mild symptoms. As she was able to tolerate oral liquids without difficulty, she was discharged home and two days later followed up with neurology.

At the neurology follow-up appointment, the patient felt as though her symptoms were progressing. On physical exam the neurologist noted bilateral ptosis and was concerned for progressive bulbar weakness given the evolution of symptoms. She was sent back to the ED for further evaluation and possible MRI but subsequently left without being seen. She returned to the ED later that night and was evaluated again. During that encounter, the patient was found to have ptosis, which could be overcome with effort, while the remainder of her neurologic exam was determined to be normal and non-focal. Laboratory studies in the ED demonstrated a leukocytosis of 13.6×10^3 /microliters (uL) (reference [ref] range $4.0 - 11.0 \times 10^3$ /uL), mild metabolic acidosis (bicarbonate of 16.0 millimoles (mmol)/ liter (L) (ref range $23 - 30$ mmol/L), and elevated C-reactive protein of 116.5 milligrams (mg)/L (ref range < 10 mg/L). The remainder of her initial labs were normal. Contrast swallow study was obtained, which demonstrated aspiration of contrast material into the trachea that could be visualized in both mainstem bronchi (Image 1).

The patient was admitted to the hospital and the following day was transferred to the intensive care unit (ICU) for progressive respiratory weakness. She was subsequently intubated for airway protection as she had a negative inspiratory force (NIF) of less than -20 centimeters of water. While in the ICU, the patient underwent further study

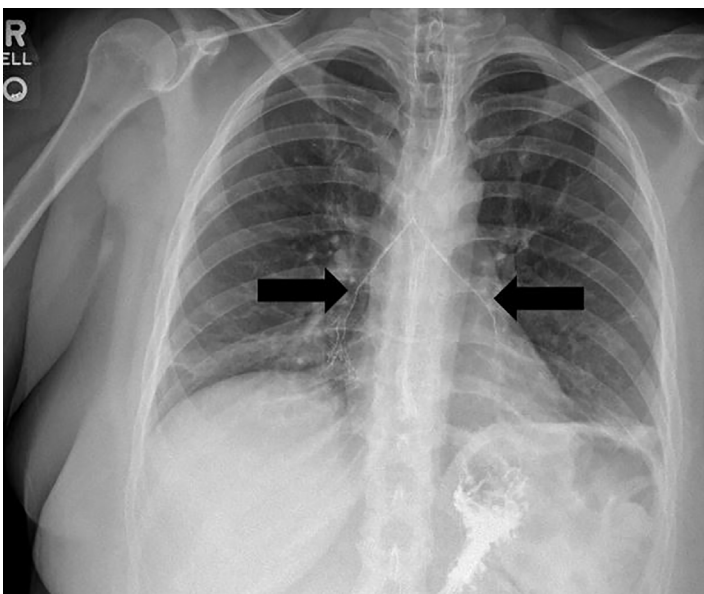


Image 1. Aspirated contrast material during swallow study of patient diagnosed with wound botulism.

CPC-EM Capsule

What do we already know about this clinical entity?

Wound botulism is a rare, potentially fatal disease process that can present a diagnostic dilemma in the emergency department.

What makes this presentation of disease reportable?

This presentation was unique in that the patient presented with isolated dysphagia without other cranial nerve dysfunction.

What is the major learning point?

Wound botulism can have a varied presentation, is easy to miss, and should be considered in cases of isolated dysphagia especially among patients who inject heroin.

How might this improve emergency medicine practice?

This rare presentation will alert emergency practitioners to expand their own differentials and consider this potentially fatal entity.

including lumbar puncture and additional imaging. She had normal cerebrospinal fluid examination, negative blood cultures, and normal computed tomography of the head, neck, and chest. She also had normal MRIs of the brain and cervical, thoracic, and lumbar spine. On the second day of hospitalization, differential diagnosis was broadened, and serum, stool, and wound culture samples were sent to the CDC for botulinum testing. The wound tissue sample ultimately tested positive for a toxin producing strain of *C. botulinum*.

The day that wound cultures were obtained the patient was started on empiric botulism anti-toxin and underwent surgical debridement and wound excision for source control (Images 2, 3). Simultaneously she was started on broad spectrum antibiotics. She exhibited mild clinical improvement but did require tracheostomy due to prolonged intubation and respiratory weakness. The patient remained in the hospital for approximately two weeks. Prior to discharge, she was determined to have such profound residual generalized motor weakness that she required transfer for rehabilitation and subsequent long-term care.

DISCUSSION

Wound botulism can have a wide variety of presentations and is frequently misdiagnosed on the first healthcare

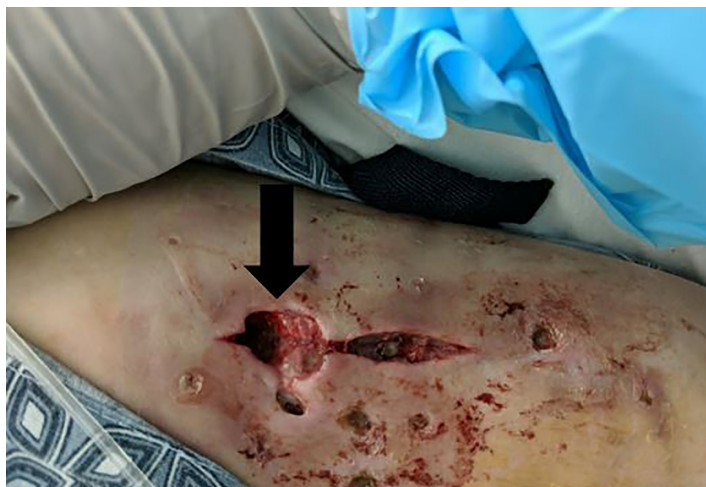

Image 2. Deep left upper extremity wound from “skin popping.” Photo taken after debridement for wound botulism. Mild surrounding erythema noted.

encounter.⁶ If left undiagnosed, it can cause profound respiratory weakness leading to respiratory failure and the need for prolonged mechanical ventilation.⁷ While most cases present in clusters, this appeared to be an isolated case.⁴ It was particularly challenging as the patient’s primary symptom was isolated dysphagia, which was initially described as non-progressive and without other cranial nerve dysfunction. This could have been due to low levels of toxin production from a low-grade infection, as there were only minimal signs of cellulitis surrounding the wounds. She required multiple ED visits, hospital admission, and a prolonged ICU stay before a diagnosis could be established.

Patients suffering from substance abuse, drug intoxication or psychiatric illness are often seen in the ED. Emergency physicians evaluating these patients may be inclined to

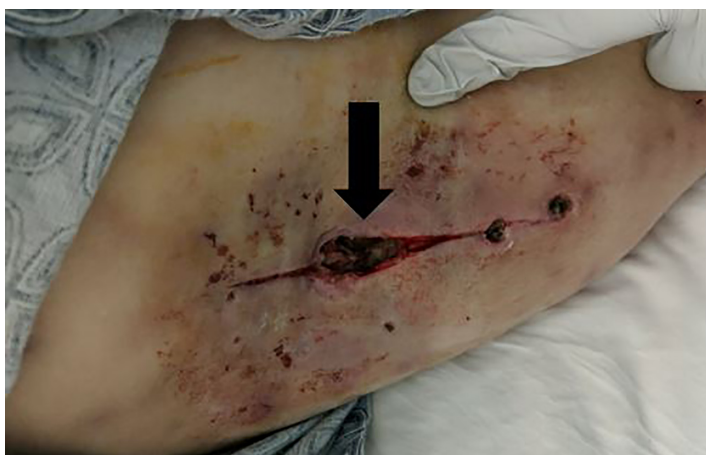

Image 3. Deep right upper extremity wound from “skin popping.” Photo taken after debridement for wound botulism. Mild surrounding erythema noted.

attribute subjective or subtle symptoms to the patient’s personality, drug intoxication, or underlying psychiatric illness. As a result, these patients have a propensity for leaving against medical advice and are at high risk of not being evaluated comprehensively. This can lead to multiple ED visits as it becomes easier for emergency physicians to overvalue previous non-diagnostic workups, thus continuing momentum toward a lack of an emergent diagnosis. Moreover, wound botulism is also because of its rarity.⁸ The combination of these biases can result in missed diagnoses of critical illnesses. Emergency physicians should be aware of these biases and keep them in consideration especially during high-risk patient encounters.

This case highlights some of the core tenets of wound botulism treatment, including botulinum anti-toxin and surgical source control. Whereas food botulism often responds to anti-toxin alone without surgical intervention, treatment of wound botulism with anti-toxin alone may not be successful.⁷ This is noteworthy, as case series demonstrate that time to anti-toxin and time to surgical debridement shortens hospital stays significantly.³ To obtain botulism anti-toxin or submit samples for testing, providers should contact their local state health departments, as well as the CDC at 770-488-7100.⁹

CONCLUSION

Botulism, specifically wound botulism, presents a diagnostic challenge in the ED, especially when compounded with underlying social factors and possible cognitive biases. Providers should be aware that wound botulism can present with isolated cranial nerve dysfunction, may not initially be described as progressive, and that “typical” presentations are the exception, rather than the rule.

The authors attest that their institution requires neither Institutional Review Board approval, nor patient consent for publication of this case report. Documentation on file.

Address for Correspondence: Ryan H. Wyatt, MD, Valleywise Health Medical Center, Department of Emergency Medicine, 2601 E. Roosevelt St., Phoenix, AZ 85008. Email: Wyattrh@vcu.edu.

Conflicts of Interest: By the CPC-EM article submission agreement, all authors are required to disclose all affiliations, funding sources and financial or management relationships that could be perceived as potential sources of bias. The authors disclosed none.

Copyright: © 2020 Wyatt et al. This is an open access article distributed in accordance with the terms of the Creative Commons Attribution (CC BY 4.0) License. See: <http://creativecommons.org/licenses/by/4.0/>

REFERENCES

1. Centers for Disease Control and Prevention (CDC). Botulism Annual Summary, 2017. 2019. Available at: <https://www.cdc.gov/botulism/surv/2017/index.html>. Accessed March 21, 2020.
2. Jackson KA, Mahon BE, Copeland J, et al. Botulism mortality in the USA, 1975-2009. *Botulinum J*. 2015;3(1):6-17.
3. Martin SJ, Penrice G, Amar C, et al. Wound botulism, its neurological manifestations, treatment and outcomes: a case series from the Glasgow outbreak, 2015. *Scott Med J*. 2017;62(4):136-41.
4. Peak CM, Rosen H, Kamali A, et al. Wound botulism outbreak among persons who use black tar heroin — San Diego County, California, 2017–2018. *Morb Mortal Wkly Rep*. 2019;67(5152):1415-8.
5. Chatham-Stephens K, Fleck-Derderian S, Johnson SD, et al. Clinical features of foodborne and wound botulism: a systematic review of the literature, 1932-2015. *Clin Infect Dis*. 2017;66(suppl_1):S11-6.
6. Sobel J. Botulism. *Clin Infect Dis*. 2005;41(8):1167-73.
7. Andrus P and Guthrie M. (2016). Acute peripheral neurologic disorders. In: Tintinalli J, Stapczynski S, Ma J, et al. (Eds.), *Tintinalli's Emergency Medicine: A Comprehensive Study Guide, 8e (1178-1185)*. New York, NY: McGraw Hill Education.
8. Croskerry P. Achieving quality in clinical decision making: cognitive strategies and detection of bias. *Acad Emerg Med*. 2002;9(11):1184-204.
9. Centers for Disease Control and Prevention (CDC). Botulism. 2019. Available at: <https://www.cdc.gov/botulism>. Accessed May 5, 2020.

A Case Report of Neonatal Supraventricular Tachycardia Resolved with Single-Syringe Adenosine

Marc McDowell, PharmD
Tasneem Ahmed, MD
Bill Schroeder, DO
Shannon Staley, MD

Advocate Children's Hospital, Department of Emergency Medicine, Oak Lawn, Illinois

Section Editor: Rick A. McPheeters, DO

Submission history: Submitted June 19, 2020; Revision received August 31, 2020; Accepted September 8, 2020

Electronically published October 20, 2020

Full text available through open access at http://escholarship.org/uc/uciem_cpem

DOI: 10.5811/cpcem.2020.9.48829

Introduction: Supraventricular tachycardia (SVT) is a condition requiring emergency care in neonates.

Case Report: We describe a successfully treated case of neonatal SVT in a four-week-old neonate using the novel adenosine administration method. This technique is potentially easier to facilitate and does not require equipment such as a stopcock. Adenosine 0.2 milligrams per kilogram was drawn up into a syringe containing 0.9% sodium chloride to a total volume of 3 milliliters. Once administered, the patient had near-immediate return to normal sinus rhythm without sequelae.

Conclusion: This case demonstrates that the single-syringe method appears potentially safe and effective in neonates. [Clin Pract Cases Emerg Med. 2020;4(4):617–619.]

Keywords: *Supraventricular tachycardia; adenosine; SVT; neonatal.*

INTRODUCTION

Supraventricular tachycardia (SVT) is a tachydysrhythmia not uncommonly seen in the emergency department (ED). This acute disease state accounts for approximately 50,000 ED visits annually.^{1,2} A recent population-based study from a national, birth cohort database in Taiwan of children born between 2000 and 2008 with complete postnatal medical data estimated the cumulative incidence of SVT in patients aged less than one month as 0.06 per 1000 patient-years overall and 0.05 per 1000 patient-years in those without major congenital heart disease.³ Supraventricular tachycardia is a comprehensive term for a number of rhythms that range from benign sinus tachycardia to Wolff-Parkinson-White syndrome.⁴

Adenosine, a naturally occurring purine nucleoside, is formed from the breakdown of adenosine triphosphate. It acts through a cascade of secondary messengers that initially block atrioventricular nodal conduction via the A1 receptors in the cardiac tissue. These in turn act on Gi proteins, which decrease cyclic adenosine monophosphate. This leads to stimulation of potassium channels and inhibition of L-type calcium channels, causing

hyperpolarization of cardiac myocytes, thus returning the heart to a normal sinus rhythm (NSR).⁵

Given adenosine's unique pharmacokinetic profile of near-immediate onset and a half-life of 5-10 seconds, cardioversion can be performed rapidly with limited adverse effects. Due to its rapid metabolism, a flush of saline is also administered to ensure adequate delivery to the myocardium. The American Heart Association Pediatric Advanced Life Support guidelines recommend adenosine after a trial of vagal maneuvers.⁶ Adenosine is commonly administered as a 0.1 milligrams (mg) per kilogram (kg) (maximum 6 mg) rapid intravenous (IV) bolus over one to two seconds followed by a rapid 5-10 milliliter (mL) saline flush. If the first dose does not result in termination of SVT to NSR within one to two minutes, a repeat dose of 0.2 mg/kg (maximum 12 mg) can be given and the dose may be repeated one additional time if required (for a total of three doses).⁷

To facilitate administering drug and saline flush a three-way stopcock is commonly used; however, this method has physical logistics issues. For example, locating a three-way stopcock may cause a delay in therapy and certain emergency medical

transport services may not stock such a device.⁸ An alternative method of combining the drug and the flush in a single-syringe may offer higher rates of conversion, lower need for repeat dosing, eliminate the need for a stopcock or additional staff, and limit peripheral IV extravasations. Combining medication and flush has been popularized by Free Open Access Medical Education (FOAM) in recent years. In 2019 McDowell et al conducted a prospective, observational cohort study demonstrating the dilute, single-syringe method as non-inferior to the conventional two-syringe method in adults.⁹

CASE REPORT

A full-term, four-week-old male with past medical history of supraventricular tachycardia presented to the ED with a heart rate of 299 beats per minute. An electrocardiogram (ECG) demonstrated a rapid, narrow-complex tachyarrhythmia determined to be SVT (Image 1).

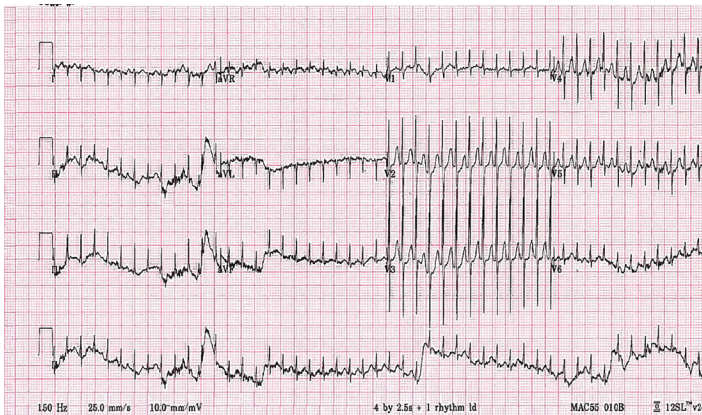


Image 1. Narrow complex tachydysrhythmia in four-week-old patient.

The patient was well perfused with a blood pressure of 62/54 millimeters of mercury (mm Hg). However, oxygen saturation was poor at 82% on 3 liters per minute via nasal cannula and a respiratory rate of 32 breaths per minute. Due to the immediacy of the illness, pharmacologic cardioversion was selected over non-invasive vagal maneuvers. Obtaining supplies to initiate a mammalian diving reflex or facilitating a modified valsalva maneuver were deemed to require too much time. A dose of 0.2 mg/kg of adenosine was prepared by the pharmacist and mixed in a single syringe with 0.9% sodium chloride to a total of 3 mL. The adenosine was administered as a rapid IV push via 24-gauge antecubital IV (Image 2).

The arrhythmia terminated and the patient returned to sinus rhythm with a heart rate of 166 beats per minute (Image 3). Of note, shortened PR intervals with slurred upstrokes resembling delta waves were observed in leads V2-V5. This is reminiscent of Wolff-Parkinson-White syndrome. Pediatric cardiology noted this to be definite evidence of a pre-excitation rhythm.

CPC-EM Capsule

What do we already know about this clinical entity?

Supraventricular tachycardia is a life-threatening tachydysrhythmia. Adenosine is an effective treatment, but administration can be cumbersome.

What makes this presentation of disease reportable?

We report a novel method of adenosine administration, not previously reported in the neonatal population.

What is the major learning point?

Single-syringe diluted adenosine was safely and effectively administered in a 4-week-old neonatal patient in the emergency department.

How might this improve emergency medicine practice?

Providers may consider the transition from traditional administration to single-syringe, diluted method if clinically appropriate.

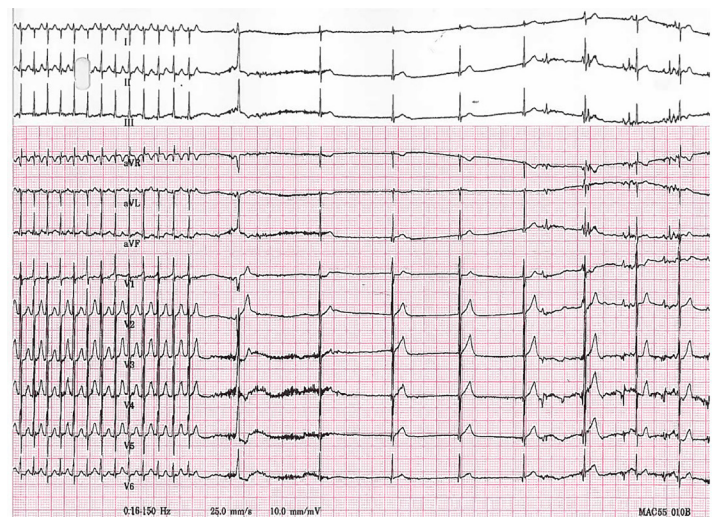


Image 2. Electrocardiogram during administration of 0.2 milligrams per kilogram of adenosine via single-syringe method.

Blood pressure and oxygen saturation both returned to normal limits, 86/73 mm Hg and 99%, respectively. Neither the nurse, pharmacist, nor physician had any difficulty with their tasks and noted the ease of the single-syringe method over the traditional two-syringe method. Point-of-care

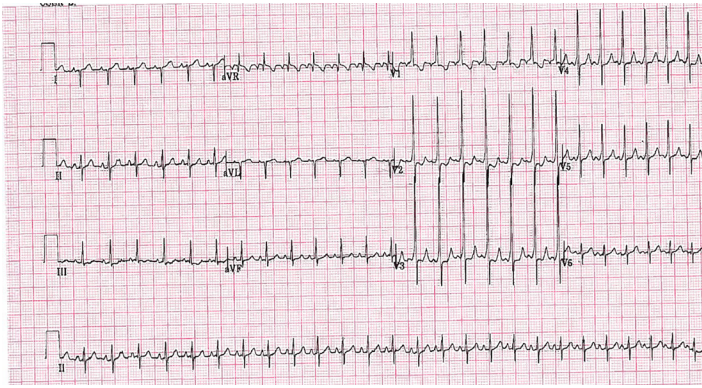


Image 3. Return to sustained normal sinus rhythm with short PR interval and apparent delta waves indicating Wolff-Parkinson-White syndrome.

echocardiogram obtained immediately following conversion to sinus rhythm showed subjectively normal function. The patient was transferred to the pediatric cardiac intensive care unit and maintained normal sinus rhythm for the remainder of his admission.

DISCUSSION

We describe a case of neonatal SVT presenting in respiratory distress with return to NSR with the diluted single-syringe method of adenosine. Adenosine is an effective, guideline-recommended treatment that can chemically convert SVT. The diluted single-syringe method of adenosine is effective in the treatment of adult SVT. Neonatal SVT was safely and effectively treated in this patient. If materials, time, or personnel are limited, the single-syringe method can be considered.

CONCLUSION

Single-syringe adenosine is relatively easier to compound with available materials readily found in an ED. Utilization of diluted adenosine appears potentially safe and effective when administered in the neonatal population for the treatment of supraventricular tachycardia.

Patient consent has been obtained and filed for the publication of this case report.

REFERENCES

1. Lau EW. Intraatrial supraventricular tachycardias: mechanisms, diagnosis, and management. *Pacing Clin Electrophysiol*.

Address for Correspondence: Marc McDowell, PharmD, BCPS, Advocate Children's Hospital, Department of Pharmacy, 4440 West 95th Street, Oak Lawn, IL 60453. Email: marc.mcdowell@advocatehealth.com.

Conflicts of Interest: By the CPC-EM article submission agreement, all authors are required to disclose all affiliations, funding sources and financial or management relationships that could be perceived as potential sources of bias. The authors disclosed none.

Copyright: © 2020 McDowell et al. This is an open access article distributed in accordance with the terms of the Creative Commons Attribution (CC BY 4.0) License. See: <http://creativecommons.org/licenses/by/4.0/>

- 2008;31(4):490-8.
2. Page RL, Joglar JA, Caldwell MA, et al. 2015 ACC/AHA/HRS Guideline for the Management of Adult Patients with Supraventricular Tachycardia: Executive Summary: A Report of the American College of Cardiology/American Heart Association Task Force on Clinical Practice Guidelines and the Heart Rhythm Society [published correction appears in *Circulation*. 2016;134(11):e232-3]. *Circulation*. 2016;133(14):e471-505.
3. Wu MH, Chen HC, Kao FY, et al. Postnatal cumulative incidence of supraventricular tachycardia in a general pediatric population: a national birth cohort database study. *Heart Rhythm*. 2016;13(10):2070-5.
4. Link MS. Clinical practice. Evaluation and initial treatment of supraventricular tachycardia. *N Engl J Med*. 2012;367(15):1438-48.
5. U.S. Food and Drug Administration (FDA). Adenocard injection solution, adenosine injection solution. 2005. Available at: https://www.accessdata.fda.gov/drugsatfda_docs/label/2011/019937s026lbl.pdf. Accessed April 11, 2020.
6. Berg MD, Schexnayder SM, Chameides L, et al. Part 13: Pediatric Basic Life Support: 2010 American Heart Association Guidelines for Cardiopulmonary Resuscitation and Emergency Cardiovascular Care. *Circulation*. 2010;122(18 Suppl 3):S862-75.
7. Gausche M, Persse DE, Sugarman T, et al. Adenosine for the prehospital treatment of paroxysmal supraventricular tachycardia. *Ann Emerg Med* 1994;24(2):183-9.
8. Weberding NT, Saladino RA, Minnigh MB, et al. Adenosine administration with a stopcock technique delivers lower-than-intended drug doses. *Ann Emerg Med*. 2018;71(2):220-4.
9. McDowell M, Mokszycki R, Greenberg A, et al. Single-syringe administration of diluted adenosine. *Acad Emerg Med*. 2020;27(1):61-3.

Case Report: Delayed Presentation of Bowel Obstruction Caused by Blunt Abdominal Trauma

Nicholas H. George, MD
Charles A. Baldi, MD
James M. Tonascia, MD
Siamak Moayed, MD

University of Maryland School of Medicine, Department of Emergency Medicine,
Baltimore, Maryland

Section Editor: Scott Goldstein, MD

Submission history: Submitted July 12, 2020; Revision received August 27, 2020; Accepted September 9, 2020

Electronically published October 20, 2020

Full text available through open access at http://escholarship.org/uc/uciem_cpccem

DOI: 10.5811/cpccem.2020.9.47034

Introduction: Bowel obstruction is a rare but well reported complication of blunt abdominal trauma (BAT). Obstruction is most often seen acutely caused by bowel wall hematomas and chronically as a result of post-traumatic strictures. Here, we present a novel case of BAT causing a subacute obstructing bowel wall hematoma.

Case Report: A healthy, 32-year-old male presented to our emergency department with three days of nausea and vomiting. Chart review revealed he had been seen two weeks prior after a high-speed motor vehicle collision. During that initial visit, the patient had a benign abdominal exam and was discharged without imaging. On this return visit, the patient was found to have a large, obstructing colonic hematoma.

Conclusion: Because emergency physicians care for patients in both the acute and subacute phases of trauma, clinicians should recognize the more subtle sequelae of BAT. [Clin Pract Cases Emerg Med. 2020;4(4):620–622.]

Keywords: *Bowel obstruction; blunt trauma; delayed presentation.*

INTRODUCTION

Bowel obstruction is a common diagnosis made in the emergency department (ED). Classic causes include strictures, hernias, and malignancy. Rarely, clinicians may see a wide range of less common precipitants, from foreign objects to enteroliths.¹ Abdominal trauma is one appreciated cause of bowel obstruction. In the acute setting, blunt trauma can lead to rapidly expanding bowel wall hematomas.² Such injury complexes are often rapidly identified on imaging, and managed with emergency surgery. In the delayed setting, blunt trauma can cause adhesions that might secondarily lead to bowel obstruction.³ Here we present a novel case of a subacute traumatic bowel wall hematoma causing intestinal obstruction. To our knowledge, delayed intestinal obstruction caused by traumatic bowel wall hematoma has not been reported previously.

CASE REPORT

A 32-year-old male presented to the ED after experiencing three days of nausea and vomiting. Additionally, he reported

anorexia with constipation for three days, and obstipation for one day. He had no relevant past medical history, was taking no medications, and had no allergies. Review of the electronic health record revealed the patient had been evaluated two weeks prior following a motor vehicle collision (MVC). He had been the restrained driver in a two-car collision with associated airbag deployment and heavy front-end damage. He was seen approximately 30 minutes after the MVC at a community hospital without a trauma center designation. At the time, he was hemodynamically stable and did not have any abdominal pain or bruising. He was evaluated by an attending physician and, after a primary and secondary trauma survey, was discharged without any indication for imaging or further evaluation.

For the current ED visit, his presenting vital signs were as follows: temperature 97.8 degrees Fahrenheit; heart rate 89 beats per minute; blood pressure 126/73 millimeters of mercury (mm Hg); respiratory rate 20 breaths per minute; and oxygen saturation 98% on room air. Physical examination revealed a soft but diffusely tender abdomen with voluntary

guarding in all quadrants. There was no rebound, rigidity, or palpable mass. Further, no external signs of trauma were appreciated. The remainder of his examination was unremarkable, including bowel sounds, which were present and normoactive. On history-taking he denied new trauma aside from the known MVC, and had been taking acetaminophen since the accident for pain control.

Notable laboratory values were as follows: hemoglobin 13.2 grams (g) per deciliter (dL) (reference [ref] range: 13.5-16.5 g/dL), hematocrit 40.4 % (40.0-49.0% ref range), anion gap 9 milliequivalents (mEq) per liter (L) (ref range: 5-17 mEq/L), aspartate aminotransferase 21 international units (IU) per L (ref range: 8-40 IU/L), and alanine aminotransferase 14 IU/L (ref range: 15-45 IU/L). While awaiting computed tomography (CT), a point-of-care abdominal ultrasound examination was completed. There was no free fluid visualized in the hepatorenal, splenorenal, or pelvic windows. Further, there was no mass visualized within the abdominal cavity. Subsequently, a CT of the abdomen with intravenous (IV) contrast revealed a large intraluminal fluid collection occluding the lumen of the ascending colon, with resulting bowel obstruction. (Image).

We inserted a nasogastric tube – with return of non-bilious stomach contents – for gastric decompression and administered IV fluids. He was admitted to the surgical service for observation and was taken to the operating room two days later for bowel resection. He was discharged on postoperative day six. His course was complicated by a minor surgical site infection, which was managed with point-of-care drainage. No antibiotics were required. At his five-week follow-up appointment, he reported normal bowel movements and eating habits, and was cleared to resume full activity.

DISCUSSION

Causes of post-traumatic bowel obstruction include hematoma formation, bowel wall edema, and late-presenting strictures.^{1,2,3} Complications from hematomas or bowel wall edema typically present within hours to days. These injuries – such as bucket-handle mesenteric injuries, ruptured viscera,

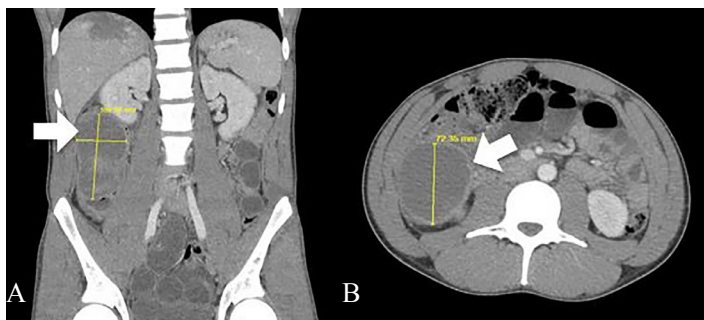


Image. Computed tomography with contrast, showing a large (10.1x5.9x7.2 centimeters), heterogeneous intraluminal collection of fluid in the ascending colon (arrows). A. Coronal view. B. Axial view.

CPC-EM Capsule

What do we already know about this clinical entity?

Post-traumatic bowel obstructions are known to occur within hours after trauma due to hematoma formation. Late-presenting obstructions are often due to strictures.

What makes this presentation of disease reportable?

A late-presenting, sub-acute bowel wall hematoma causing a post-traumatic obstruction has not been previously described in the literature.

What is the major learning point?

Intra-abdominal injury in the form of bowel obstruction from blunt abdominal trauma may only become apparent weeks after the incident.

How might this improve emergency medicine practice?

Patients presenting with abdominal complaints in the post-trauma setting should be evaluated for intra-abdominal pathology despite a previously negative exam.

and mesenteric lacerations – are often detectable with CT at the time of presentation.⁴ Such cases are often described in the duodenum and are mostly self-limited.⁵ Strictures, on the other hand, commonly present in a more delayed fashion between one month and two years after BAT. One case report detailed a patient with traumatic adhesions causing small bowel obstruction more than 20 years after the incident.⁶ Our case does not follow this paradigm and is unique in both location and timing. Our patient's obstructing hematoma was in the ascending colon as opposed to the duodenum, and he became symptomatic two weeks after the initial injury.

Cross-sectional imaging is crucial to the diagnosis and treatment of these injuries. The best imaging modality to diagnose bowel obstruction is CT with IV and oral contrast. Unfortunately, the patient in this case was unable to tolerate oral contrast due to unremitting nausea and vomiting. While the dual-contrast approach would have allowed us to better visualize smaller, more nuanced causes of bowel obstruction, we found an IV-contrast only approach was sufficient for this case.⁷

Within this context, it is notable that CT with IV contrast is preferable to ultrasound (US). In this case, point-of-care US was attempted but was not diagnostic. Ultrasound has been

described as an alternative imaging technique for diagnosing intestinal obstruction, appendicitis, and other bowel diseases.⁸ However, as our case illustrates, US is unlikely to identify the etiology and location of a post-traumatic obstruction. The role of US in delayed presentation after blunt abdominal trauma may be limited to simply identifying the presence of a bowel obstruction or abdominal free fluid.

As the management of these conditions is nuanced and complex, it is imperative they are diagnosed in a timely manner. Yet subacute and rare presentations, like this one, risk going unnoticed. Based on our patient's initial presentation to the ED, directly after his trauma, clinical guidelines did not point toward the need for additional workup.⁸ If abdominal CT imaging had been used at that visit, right after his injury, it is unclear whether any pathology would have been identified. In this way, emergency physicians should be aware that a patient with recent trauma and a negative CT (or no indication for imaging at all) might return to the ED with a related, clinically significant condition.

Initial management of patients with intraluminal hematoma includes bowel rest, insertion of a nasogastric tube for intestinal decompression, and observation. Definitive management is more intricate. Hematomas can be resorbed, some rapidly and spontaneously, but others have taken months.⁹ If a mechanical obstruction is identified, patients should be admitted to a surgical service for management and potential operative intervention, as was done in this case.

CONCLUSION

As this case demonstrates, emergency physicians should consider complications from recent trauma even in the absence of indications for imaging on initial presentation. A patient who presents with symptoms of bowel obstruction after sustaining remote blunt trauma should undergo a CT of the abdomen. As EDs often care for patients both in the immediate aftermath of traumatic injury and later in their lives, emergency physicians must recognize the more subtle, subacute effects of trauma, in this case, blunt abdominal trauma.

The authors attest that their institution requires neither Institutional Review Board approval, nor patient consent for publication of this case report. Documentation on file.

Address for Correspondence: Siamak Moayed, MD, University of Maryland School of Medicine, Department of Emergency Medicine, 110 South Poca St., Suite 200, Baltimore, MD 20201. Email: Mak.moayed@som.umaryland.edu.

Conflicts of Interest: By the CPC-EM article submission agreement, all authors are required to disclose all affiliations, funding sources and financial or management relationships that could be perceived as potential sources of bias. The authors disclosed none.

Copyright: © 2020 George et al. This is an open access article distributed in accordance with the terms of the Creative Commons Attribution (CC BY 4.0) License. See: <http://creativecommons.org/licenses/by/4.0/>

REFERENCES

1. Shatnawi NJ and Bani-Hani KE. Unusual causes of mechanical small bowel obstruction. *Saudi Med J.* 2005;26(10):1546–50.
2. Zirak-Schmidt S and El-Hussuna A. Mechanical small bowel obstruction following a blunt abdominal trauma: a case report. *Ann Med Surg (Lond).* 2015;4(4):338-40.
3. Gray J and Garstin I. Intestinal obstruction following blunt abdominal trauma. *Ulster Med J.* 2002;71(2):139-41.
4. Hou MM and Tsou YK. Gastrointestinal: acute colonic intramural hematoma after blunt abdominal trauma. *J Gastroenterol Hepatol.* 2009;24(3):494.
5. Hazer B, Tanoglu A, Pesluk O, et al. Post-traumatic intramural duodenal hematoma due to blunt abdominal trauma: case report. *Gulhane Med J.* 2015;57(4):436-8.
6. Edwards MK, Kuppler CS, Croft CA, et al. Adhesive closed-loop small bowel obstruction. *Clin Pract Cases Emerg Med.* 2018;2(1):31-4.
7. Sudakoff GS, Rosen MP, Rybicki FJ, et al. ACR Appropriateness Criteria: Blunt Abdominal Trauma. Available at: <https://acsearch.acr.org/docs/69409/Narrative/>. American College of Radiology. Accessed August 27, 2020.
8. Roccarina D, Garcovich M, Ainora ME, et al. Diagnosis of bowel diseases: the role of imaging and ultrasonography. *World J Gastroenterol.* 2013;19(14):2144-53.
9. Jones EL, Stovall RT, Jones TS, et al. Intra-abdominal injury following blunt trauma becomes clinically apparent within 9 hours. *J Trauma Acute Care Surg.* 2014;76(4):1020-3.

Case Report of Traumatic Uterine Rupture in a Multigravida Woman with Emergency Department Cesarean Section

Krista Shaw Wiese, MD
Stacey Ernest, MD
W. Seth Dukes, MD

Loma Linda University, Department of Emergency Medicine, Loma Linda, California

Section Editor: Scott Goldstein, MD

Submission history: Submitted May 26, 2020; Revision received August 20, 2020; Accepted August 21, 2020

Electronically published October 9, 2020

Full text available through open access at http://escholarship.org/uc/uciem_cpccem

DOI: 10.5811/cpcem.2020.8.48388

Introduction: Uterine ruptures in blunt trauma are an extremely rare complication. Furthermore, while perimortem cesarean sections in cardiac arrest patients are a well-established practice in emergency medicine, cesarean sections in the emergency department are rarely performed on non-arresting patients.

Case Report: A multigravida woman at approximately 24 weeks gestation presented as a transfer from an outside hospital after a motor vehicle collision. Upon arriving to our facility, she underwent an emergency cesarean section in the trauma bay and was found to have a uterine rupture with the fetus free floating in the right upper quadrant of the abdomen.

Conclusion: Uterine rupture is a rare but important complication of blunt abdominal trauma in pregnant patients. Resuscitative cesarean sections may be necessary for favorable outcomes. A well prepared and diversified team was essential to maternal survival. [Clin Pract Cases Emerg Med. 2020;4(4):623–625.]

Keywords: *traumatic uterine rupture; emergency cesarean section; trauma in pregnancy.*

INTRODUCTION

There are guidelines in emergency medicine regarding timelines for perimortem cesarean delivery (PMCD) in the case of maternal cardiac arrest. The American Heart Association recommends that PMCD should be initiated after four minutes of failure of resuscitative efforts with a goal of delivery within five minutes (the four- to five-minute rule) of initiation of resuscitative efforts in the case of a pregnant patient with estimated fetal gestation greater than 24 weeks.¹ Current case reports describe PMCD in the setting of a patient who has already undergone cardiac arrest. Less commonly described is a patient who has not undergone cardiac arrest but receives a cesarean section in the emergency department (ED) as a resuscitative measure. A well prepared and diversified team is essential to make this decision upon patient presentation. Herein, we present a multiparous woman who was involved in a motor vehicle collision, initially presented

to an outside hospital, and was ultimately transferred to our facility. She underwent an emergent cesarean section in our trauma bay and was found to have a uterine rupture with the fetus free floating in the right upper quadrant of the abdomen.

CASE REPORT

A 30-year-old female gravida 3, para 2 with an intrauterine pregnancy at approximately 24 weeks was transferred from an outside hospital and was activated as a trauma prior to arrival to our facility. The patient was the restrained driver of her vehicle, which had been traveling approximately 70 miles per hour. She was involved in a multivehicle accident, which occurred two hours prior to her presentation to our facility. The patient was not initially transported by emergency medical services but instead went by private auto to the outside facility. On presentation to that hospital the patient was noted to have abrasions with

underlying ecchymoses across the gravid lower abdomen and the left side of the chest and neck consistent in patterning with where her seatbelt would have been positioned. She also complained of abdominal pain.

Vitals were taken and she was hypotensive with maternal blood pressures 90s/40s millimeters mercury (mm Hg), and tachycardic with heart rate in the 120+ beats per minute (bpm) range. Fetal heart tones were in the 80s bpm. Point-of-care ultrasound was positive for free fluid in the abdomen. Resuscitative efforts were started. As a Level I trauma center, our institution has an agreement with the non-trauma designated hospitals in our area. If they receive a trauma patient, they inform our trauma center that they will be transferring the patient and we automatically accept the patient to expedite the transfer process for what we call a continuation of trauma. For this particular patient a continuation of trauma was initiated. Prior to presentation to our facility, the ED, obstetrics, acute care surgery (ACS), and neonatal intensive care unit (NICU) teams gathered in the trauma bay as one cohesive unit to formulate several contingency plans based on the patient's presentation (see table).

Table. Varying plans for differing patient presentations agreed upon by team leaders prior to patient presentation.

Situation	Plan
1 Mother and fetus are stable.	Acute care surgery will proceed with standard primary trauma survey.
2 Mother unstable but not in cardiac arrest and fetus unstable.	Obstetrics will perform cesarean section in the emergency department.
3 Mother in cardiac arrest and fetus unstable.	Emergency department senior resident will perform perimortem cesarean section.

Upon initial presentation her vitals were blood pressure 127/97 mm Hg, heart rate 145 bpm, respiratory rate 28 breaths per minute, and she was saturating 100% on room air. Her Glasgow Coma Scale was 14 (eye = 3; verbal = 5; motor = six). She was noted to have abrasions and ecchymoses across her gravid lower abdomen, left chest and neck, which were consistent in patterning with an overlying seatbelt. Vaginal bleeding was also noted. The obstetrics team performed a point-of-care ultrasound with fetal heart rates in the 50s bpm, and the decision was made to proceed with emergent cesarean delivery. The ED senior resident intubated the patient and managed medications. Emergent cesarean section was performed via a low transverse incision by the obstetrics team.

Manual evaluation of the lower uterine segment revealed a large defect, and no fetus was palpable in the uterus. Further evaluation of the abdomen revealed the fetus was free

CPC-EM Capsule

What do we already know about this clinical entity?
There are clear guidelines in emergency medicine regarding timelines for perimortem cesarean delivery in the case of maternal cardiac arrest.

What makes this presentation of disease reportable?
Our case report highlights the usefulness of performing a cesarean section as a resuscitative effort on a non-arresting, pregnant trauma patient.

What is the major learning point?
A pregnant trauma patient with a uterine rupture may require a cesarean section in the emergency department before she goes into cardiac arrest.

How might this improve emergency medicine practice?
Awareness of a rare complication of uterine rupture will alert providers to consider cesarean section as a resuscitative measure in the trauma bay.

floating in the right upper quadrant. The fetus was delivered and handed off to waiting NICU staff. A large, lower uterine segment defect was noted extending in the midline to the cervix. The hysterotomy was closed with adequate hemostasis, and the decision was made to proceed to the operating room for further evaluation. Upon initial assessment of the fetus, there was no pulse. The fetus was intubated and chest compressions were begun. Standard Neonatal Advanced Life Support protocol was initiated. Patient remained in asystole and time of death was called after 22 minutes of resuscitation.

The mother was transferred to the operating room, and the ACS team performed an exploratory laparotomy through the Pfannenstiel incision made in the trauma bay. Minor bleeding near the right uterine artery was found and controlled. No liver, spleen, stomach, small or large bowel injuries were appreciated. Patient received four units of packed red blood cells, three units of fresh frozen plasma, and one unit of platelets between the ED and operating room. Postoperatively, the patient underwent computed tomography (CT) of the head, cervical/lumbar/thoracic spine, chest, and abdomen, and CT angiography of the neck. No further injuries were discovered. The patient was extubated on postoperative day (POD) zero and was downgraded from the surgical intensive care unit on POD one.

On POD two she had persistent unexplained tachycardia. CT pulmonary angiography was obtained, which showed

subsegmental pulmonary embolism. She was treated with a heparin drip and transitioned to enoxaparin and then rivaroxaban. She was discharged on POD six. She was readmitted three weeks after discharge for acute anemia in the setting of anticoagulation. The patient was transfused three units of red blood cells and discharged again two days later. At her eight-week postpartum visit she was doing well with no major issues.

DISCUSSION

This case presented two unique features in the traumatic resuscitation of a pregnant patient, including blunt trauma causing uterine rupture, and an ED cesarean section in a non-arresting patient as a resuscitation effort. Post-trauma uterine rupture is an extremely rare complication (0.6% of all trauma-related maternal injuries). They are seen more frequently in women who have a previously scarred uterus or with direct abdominal impact in the latter half of the pregnancy.² Maternal mortality does occur, but fetal mortality is almost universal.³ Suspected uterine rupture with maternal and/or fetal compromise should prompt urgent resuscitative laparotomy.⁴ Our patient followed a similar pattern with a gestational age of approximately 24 weeks, history of previous uterine scarring, seatbelt sign overlying the lower uterine segment causing direct abdominal impact and ultimately fetal death. Surgical intervention consisting of exploratory laparotomy is often required.

Our patient represents a unique case in which surgical intervention was initiated within the ED. The case further demonstrates surgical intervention initiated on a non-arresting, pregnant patient. In cases of maternal cardiac arrest, a well defined practice pattern of performing a perimortem cesarean section has been in place since 1986. This protocol includes cesarean section four minutes after maternal pulse ceases in women with an estimated fetal age greater than 24 weeks or fundal height two or more fingerbreadths above the umbilicus.⁵ Cesarean sections in the ED are much less frequently performed in non-arresting patients. Per our literature review, we could not find any other documented cases of patients undergoing a cesarean section in the ED in a mother who had not already gone into cardiac arrest.

CONCLUSION

Uterine rupture is an extremely rare complication of maternal trauma but should be a consideration when approaching a pregnant trauma patient, especially if there is evidence of direct blunt trauma and concerning vital signs. Even if these patients are not in cardiac arrest, they may

require an emergent cesarean section in the ED. Furthermore, teamwork between a multidisciplinary trauma team can be essential in achieving good outcomes. We firmly believe that in this case, the maternal outcome was favorable because of the rapid decision-making and team effort of four distinct specialties prior to patient arrival and during the resuscitation. Although advanced planning is not always possible in the ED, whenever feasible it is essential to agree upon a number of contingency plans especially when multiple teams are involved in a complex trauma patient such as this one.

The authors attest that their institution requires neither Institutional Review Board approval, nor patient consent for publication of this case report. Documentation on file.

Address for Correspondence: Krista Shaw Wiese, MD, Loma Linda University, Department of Emergency Medicine, 11234 Anderson St, Loma Linda, CA 92354. Email: kwiese@llu.edu.

Conflicts of Interest: By the CPC-EM article submission agreement, all authors are required to disclose all affiliations, funding sources and financial or management relationships that could be perceived as potential sources of bias. The authors disclosed none.

Copyright: © 2020 Wiese et al. This is an open access article distributed in accordance with the terms of the Creative Commons Attribution (CC BY 4.0) License. See: <http://creativecommons.org/licenses/by/4.0/>

REFERENCES

1. Jeejeebhoy FM, Zelop CM, Lipman S, et al. Cardiac arrest in pregnancy. *Circulation*. 2015;132:1747-73.
2. Williams JK, McClain L, Rosemurgy AS, et al. Evaluation of blunt abdominal trauma in the third trimester of pregnancy: maternal and fetal considerations. *Obstet Gynecol*. 1990;75(1):33-7.
3. Kvarnstrand L, Milsom I, Lekander T, et al. Maternal fatalities, fetal and neonatal deaths related to motor vehicle crashes during pregnancy: a national population-based study. *Acta Obstet Gynecol Scand*. 2008;87(9):946-52.
4. Jain V, Chari R, Maslovits S, et al. Guidelines for the management of a pregnant trauma patient. *J Obstet Gynaecol Can*. 2015;37(6):553-74.
5. John PR, Shiozawa A, Katz VL. Perimortem cesarean delivery: its role in maternal mortality. *Semin Perinatol*. 2012;36:68-72.

A Case of Bilateral Hearing Loss

Boris Ryabtsev, MD
Matthew Slane, DO

Kendall Regional Medical Center, Department of Emergency Medicine, Miami, Florida

Section Editor: Christopher Sampson, MD

Submission history: Submitted July 2, 2020; Revision received August 30, 2020; Accepted September 9, 2020

Electronically published October 20, 2020

Full text available through open access at http://escholarship.org/uc/uciem_cpцем

DOI: 10.5811/cpцем.2020.9.48949

Case Presentation: A 53-year-old male presented to the emergency department with acute onset of bilateral hearing loss as well as vertigo and severe vomiting. The Head Impulse–Nystagmus–Test of Skew exam was indicative of a central neurologic process. Computed tomography angiogram of the head and neck revealed near-total bilateral vertebral artery occlusions in the second and third segments. The patient was admitted for further evaluation; subsequent magnetic resonance imaging revealed multiple areas of infarction in the cerebellar hemispheres, medulla, and occipital lobes.

Discussion: This case describes a unique presentation of a posterior stroke. Common symptoms include vertigo, loss of balance, and vomiting. However, bilateral hearing loss as a prominent symptom is uncommon. Imaging revealed a rare finding of bilateral vertebral artery occlusion. [Clin Pract Cases Emerg Med. 2020;4(4):626–627.]

Keywords: *Bilateral hearing loss; posterior stroke; vertebral artery occlusion.*

CASE PRESENTATION

A 53-year-old male presented to the emergency department by ambulance complaining of acute onset of severe vertigo, vomiting, and bilateral hearing loss. Symptoms began six hours prior, and progressively worsened. The patient was unable to walk due to severe ataxia. He denied any significant past medical or surgical history but reported smoking and a family history of stroke. No recent trauma or injury was identified. During evaluation, patient was vomiting and extremely hard of hearing. He was hypertensive at 147/78 millimeters of mercury, all other vital signs were within normal limits. The Head Impulse–Nystagmus–Test of Skew (HINTs) exam was positive for bidirectional horizontal nystagmus and test of skew bilaterally. The patient demonstrated abnormal finger-to-nose and heel-to-shin testing bilaterally. Non-contrast computed tomography (CT) of the brain showed no acute intracranial hemorrhage; however, CT angiograms of the head and neck demonstrated abnormalities that confirmed the diagnosis.

DISCUSSION

Computed tomography angiograms demonstrated near-total bilateral vertebral artery occlusions in the second and third segments (Images 1-3) without dissection.

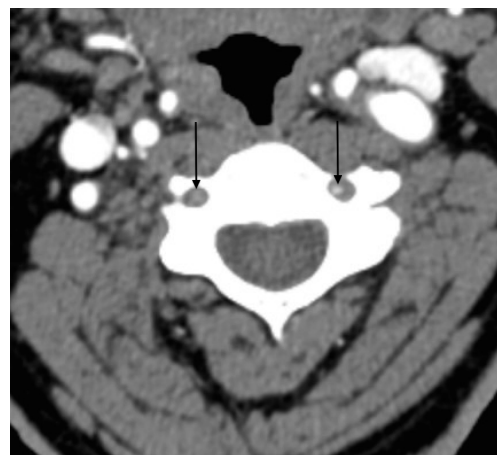


Image 1. Axial computed tomography image showing decreased vertebral artery flow bilaterally at the level of the third cervical vertebra.

Subsequent magnetic resonance imaging revealed multiple acute infarctions of bilateral cerebellar hemispheres, right aspect of medulla, and bilateral occipital lobes. The patient was started on aspirin and clopidogrel per neurology. Cardiology evaluation did not reveal a cardioembolic source. The patient was

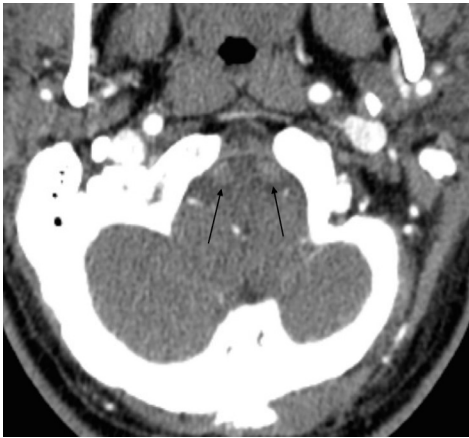


Image 2. Axial computed tomography image showing decreased vertebral artery flow bilaterally at the level of the cerebellum.

additionally diagnosed with hypertension and diabetes, which were likely involved in the disease process.

Posterior circulation strokes make up 10-20% of all ischemic events in the brain.¹ Common presentations include vertigo, loss of balance, vision loss, slurred speech, nausea, and vomiting. Hearing loss may occur due to decreased blood flow through the internal auditory artery, a branch of the anterior inferior cerebellar artery, which supplies the cochlea. However, bilateral hearing loss as a prominent symptom is rare. Studies show the incidence of bilateral hearing loss in vertebrobasilar disease to be less than 2%.²⁻⁴ The HINTs exam was crucial to differentiate central vs peripheral etiology of the patient's vertigo.⁵

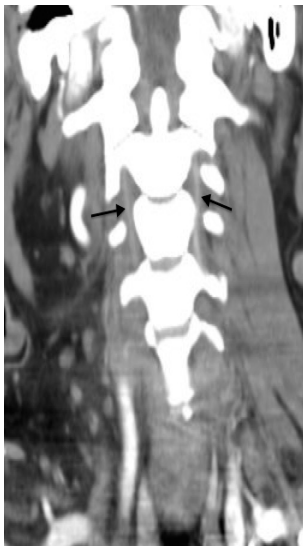


Image 3. Coronal computed tomography image showing decreased vertebral artery flow bilaterally.

The authors attest that their institution requires neither Institutional Review Board approval, nor patient consent for publication of this case report. Documentation on file.

CPC-EM Capsule

What do we already know about this clinical entity?

Posterior strokes make up a considerable number of all ischemic events in the brain. Common symptoms include vertigo, vision loss, slurred speech and nausea.

What is the major impact of the image(s)?

The images show near-total bilateral vertebral artery occlusions, an extremely rare presentation of a posterior stroke.

How might this improve emergency medicine practice?

This case of a patient presenting with bilateral hearing loss may help the physician identify a posterior stroke based on a patient's hearing changes.

Address for Correspondence: Boris Ryabtsev, MD, Kendall Regional Medical Center, Department of Emergency Medicine, 11750 SW 40th St., Miami, FL 33175. Email: bryabt09@gmail.com.

Conflicts of Interest: By the CPC-EM article submission agreement, all authors are required to disclose all affiliations, funding sources and financial or management relationships that could be perceived as potential sources of bias. The authors disclosed none.

Copyright: © 2020 Ryabtsev et al. This is an open access article distributed in accordance with the terms of the Creative Commons Attribution (CC BY 4.0) License. See: <http://creativecommons.org/licenses/by/4.0/>

REFERENCES

1. Savitz SI and Caplan LR. Vertebrobasilar disease. *N Engl J Med.* 2005;352(25):2618-26.
2. Huang MH, Huang CC, Ryu SJ, et al. Sudden bilateral hearing impairment in vertebrobasilar occlusive disease. *Stroke.* 1993;24(1):132-7.
3. Sauvaget E, Kici S, Petelle B, et al. Vertebrobasilar occlusive disorders presenting as sudden sensorineural hearing loss. *Laryngoscope.* 2004;114(2):327-32.
4. Lee H and Baloh RW. Sudden deafness in vertebrobasilar ischemia: clinical features, vascular topographical patterns and long-term outcome. *J Neurol Sci.* 2005;228(1):99-104.
5. Kattah JC, Talkad AV, Wang DZ, et al. HINTS to diagnose stroke in the acute vestibular syndrome: three-step bedside oculomotor examination more sensitive than early MRI diffusion-weighted imaging. *Stroke.* 2009;40(11):3504-10.

Point-of-care Ultrasound in the Evaluation of Mitral Valve Regurgitation and Mitral Annular Calcification

Benjamin Schoenberg, MD*
Marwan Alkhattabi, MBBS†
Shadi Lahham, MD, MS†

*University of California, Riverside, Riverside Community Hospital, Department of Emergency Medicine, Riverside, California

†University of California, Irvine, Department of Emergency Medicine, Orange, California

Section Editor: Rick A. McPheeters, DO

Submission history: Submitted May 10, 2020; Revision received August 5, 2020; Accepted July 24, 2020

Electronically published September 17, 2020

Full text available through open access at http://escholarship.org/uc/uciem_cpem

DOI: 10.5811/cpcem.2020.7.48117

Case Presentation: A 77-year-old female presented to the emergency department (ED) with chest pain. Cardiac point-of-care ultrasound (POCUS) was performed and demonstrated a hyperechoic structure on the posterior leaflet of the mitral valve. Admission to cardiology and echocardiogram revealed moderately decreased mobility of the posterior leaflet, mitral annular calcification, and severe mitral regurgitation.

Discussion: These findings highlight the role of POCUS in identifying mitral valve pathology in the ED, ultimately leading to appropriate disposition and management. Mitral annular calcification can lead to significant manifestations including mitral stenosis or regurgitation, and advanced cases have been associated with an increased risk of infective endocarditis, thrombosis, and arrhythmia. [Clin Pract Cases Emerg Med. 2020;4(4):628–629.]

Keywords: *Mitral valve calcification; mitral valve regurgitation; cardiac ultrasound; point-of-care ultrasound.*

CASE PRESENTATION

A 77-year-old female with a history of atrial fibrillation on apixaban, non-ST-elevation myocardial infarction (NSTEMI), congestive heart failure with preserved ejection fraction, and hypertension presented to the emergency department (ED) with chest pain. The patient described non-exertional, sudden-onset and severe left-sided chest pain radiating to her left shoulder. Review of systems was positive for shortness of breath, nausea, and diaphoresis. Vital signs were notable for an elevated heart rate and respiratory rate. Physical exam revealed jugular venous distension, irregular rate and rhythm, and 2+ lower extremity edema. Electrocardiogram revealed atrial fibrillation, and labs were significant for an elevated high-sensitivity troponin.

Point-of-care ultrasound (POCUS) in parasternal long view of the heart revealed left atrial enlargement, left ventricular hypertrophy, mitral valve regurgitation, and a hyperechoic structure on the posterior leaflet of the mitral

valve representing moderate mitral annular calcification (MAC) with posterior shadowing (Image and Video). The patient was admitted to cardiology for atrial fibrillation with NSTEMI and further management.

DISCUSSION

These findings highlight the role of POCUS in identifying mitral valve pathology in the ED, ultimately leading to appropriate disposition and management. Mitral regurgitation (MR) is the leading cause of valvular heart disease in the United States with a prevalence of 10% in adults older than 75 years.¹ Severe MR can present with a holosystolic heart murmur, dyspnea on exertion, lightheadedness, cough, palpitations, pulmonary congestion, and edema.¹

MAC is a progressive, degenerative process that is a result of calcification of the fibrous mitral annulus.² MAC can lead to significant manifestations including mitral stenosis or regurgitation (such as in this patient); and advanced cases

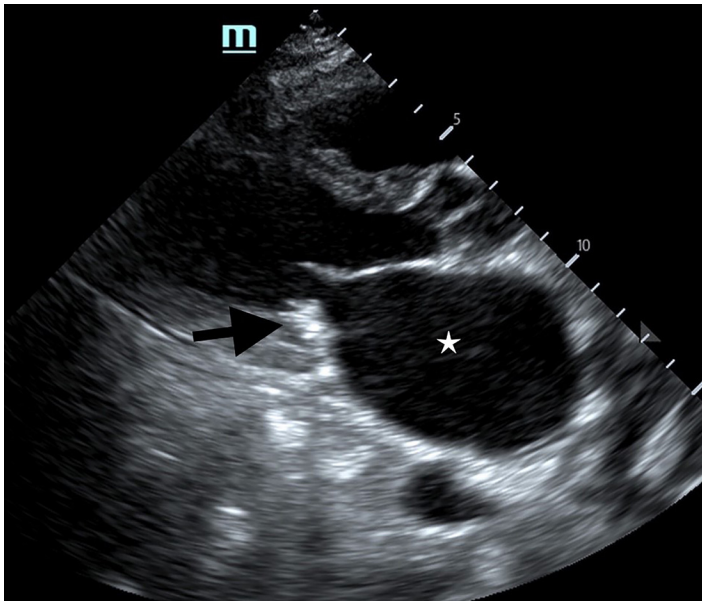


Image. Point-of-care ultrasound in parasternal long view of the heart revealing a hyperechoic structure on the posterior leaflet of the mitral valve representing calcification (black arrow) and left atrial enlargement (white star).

have been associated with an increased risk of infective endocarditis, thrombosis, and arrhythmia.³ Risk factors for MAC include advanced age, diabetes mellitus, hyperlipidemia, chest radiation, chronic kidney disease, and hypertension.⁴

LIMITATIONS

A color Doppler image or video to evaluate MR was not saved in the electronic health record.

Video. Cardiac point-of-care ultrasound revealing a hyperechoic structure on the posterior leaflet of the mitral valve representing calcification (black arrow) and left atrial enlargement (yellow star).

The authors attest that their institution requires neither Institutional Review Board approval, nor patient consent for publication of this case report. Documentation on file.

REFERENCES

1. Apostolidou E, Maslow AD, Poppas A. Primary mitral valve regurgitation: update and review. *Glob Cardiol Sci Pract.* 2017;2017(1):e201703.

2. Abramowitz Y, Jilaihawi H, Chakravarty T, et al. Mitral annulus calcification. *J Am Coll Cardiol.* 2015;66(17):1934-41.
3. Butany J, Vaideeswar P, Dixit V, et al. Massive annular calcification: a stone in the heart. *Can J Cardiol.* 2019;25(1):e18.
4. Freeman RV. Management and prognosis of mitral annular calcification. 2018. Available at: <https://www.uptodate.com/contents/management-and-prognosis-of-mitral-annular-calcification>. Accessed February 22, 2020.

CPC-EM Capsule

What do we already know about this clinical entity?

Mitral regurgitation is the leading cause of valvular heart disease in the United States.

What is the major impact of the image(s)?

Mitral annular calcification can present as either an incidental finding on ultrasound or as a significant contributor in patients with mitral regurgitation.

How might this improve emergency medicine practice?

Point-of-care ultrasound is an important tool to evaluate patients presenting with chest pain and possible valvular pathology in the emergency department.

Address for Correspondence: Shadi Lahham, MD, MS, University of California, Irvine, Department of Emergency Medicine, 333 The City Boulevard West Suite 640, Orange, CA 92868. Email: Shadi1@uci.edu.

Conflicts of Interest: By the CPC-EM article submission agreement, all authors are required to disclose all affiliations, funding sources and financial or management relationships that could be perceived as potential sources of bias. The authors disclosed none.

Copyright: © 2020 Schoenberg et al. This is an open access article distributed in accordance with the terms of the Creative Commons Attribution (CC BY 4.0) License. See: <http://creativecommons.org/licenses/by/4.0/>

A 61-year-old Female with Right Upper Abdominal Pain

Drew A. Long, MD
Brit Long, MD

Brooke Army Medical Center, Department of Emergency Medicine, Fort Sam Houston, Texas

Section Editor: Rick A. McPheeters, DO

Submission history: Submitted June 1, 2020; Revision received July 15, 2020; Accepted July 24, 2020

Electronically published September 17, 2020

Full text available through open access at http://escholarship.org/uc/uciem_cpem

DOI: 10.5811/cpcem.2020.7.48514

Case Presentation: A 61-year-old female presented to the emergency department with right upper quadrant abdominal pain following a cholecystectomy 18 days prior. Computed tomography (CT) of her abdomen demonstrated a large abscess in her post-hepatic fossa. She was admitted to the general surgery service and received an image-guided percutaneous drain placement with interventional radiology with immediate return of purulent material. She was discharged home after a three-day hospital course with outpatient antibiotics and follow-up.

Discussion: Patients may have multiple complications following cholecystectomy, including infection, bleeding, biliary injury, bowel injury, or dropped stone. The emergency clinician must consider cholecystectomy complications including gallbladder fossa abscess in patients presenting with abdominal pain in the days to weeks following cholecystectomy, especially if they present with signs of sepsis. Critical actions include obtaining CT and/or ultrasonography, initiating broad spectrum antibiotics, and obtaining definitive source control by either surgery or interventional radiology. [Clin Pract Cases Emerg Med. 2020;4(4):630–631.]

Keywords: *cholecystitis; cholecystectomy.*

CASE PRESENTATION

A 61-year-old female presented to the emergency department with right upper quadrant (RUQ) abdominal pain for the prior several days. She had a laparoscopic cholecystectomy 18 days prior to presentation for operative management of cholecystitis. Initial vital signs were notable for a heart rate of 110 beats per minute. Abdominal examination demonstrated moderate RUQ abdominal tenderness to palpation. Laboratory evaluation revealed a white blood cell count of 11.3 per microliter (μL) (normal range 4.5-11 μL), total bilirubin 0.5 milligram per deciliter (mg/dL) (normal <1.2 mg/dL), aspartate aminotransferase of 30 international units per liter (IU/L) (normal 5-40 IU/L), alanine aminotransferase of 45 IU/L (normal 7-56 IU/L), and alkaline phosphatase of 247 IU/L (normal 20-140 IU/L). Computed tomography (CT) with intravenous (IV) contrast of her abdomen and pelvis demonstrated a 7.3 x 5.7 x 7.7 centimeter rim-enhancing fluid collection with air-fluid level in the gallbladder fossa (Images 1 and 2).

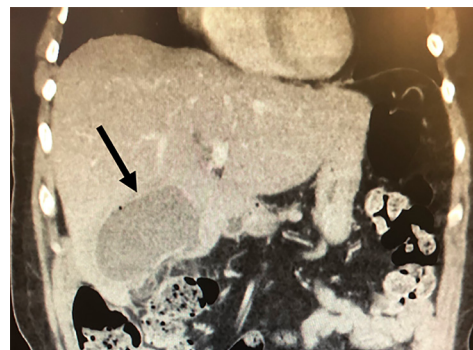


Image 1. Sagittal view of computed tomography of abdomen/pelvis with intravenous contrast demonstrating a 7.3 x 5.7 x 7.7 centimeter rim-enhancing fluid collection in the gallbladder fossa, denoted by black arrow.

DISCUSSION

The patient presentation and imaging were concerning for gallbladder fossa abscess, and she received 4.5 grams of piperacillin/tazobactam IV in addition to 2 L of IV crystalloid and

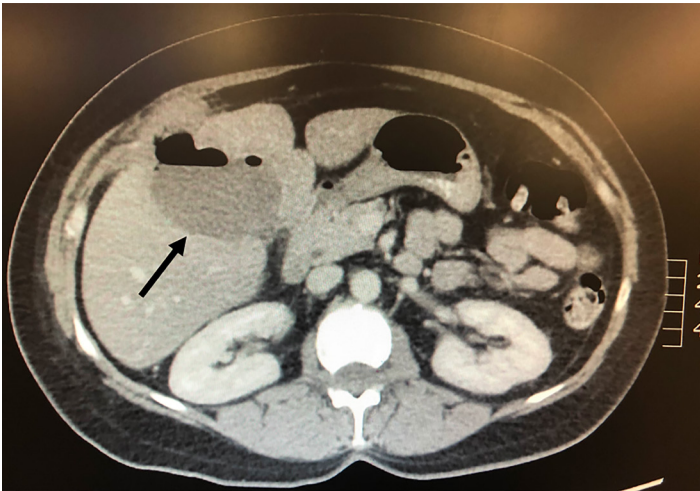


Image 2. Transverse view of computed tomography of abdomen/pelvis with intravenous contrast demonstrating a 7.3 x 5.7 x 7.7 centimeter rim-enhancing fluid collection with air-fluid level in the gallbladder fossa, denoted by black arrow.

was admitted to the surgical service. Interventional radiology placed an image-guided drain, with 100 milliliters of purulent material expressed upon placement. The patient was discharged home on hospital day three with the drain in place on antibiotics with follow-up.

Cholecystectomies are commonly performed in the United States, most commonly laparoscopically. Potential complications include bile duct injury, biliary stricture, bowel injury, bleeding, infection, and dropped gallstones.^{1,2} Complications, particularly infection, are more common in patients with underlying immunosuppression such as diabetes.³ In patients presenting with abdominal pain after cholecystectomy, these complications should be considered and imaging with either CT or ultrasonography obtained. If a patient has signs of sepsis (eg, tachycardia, fever) days to weeks following cholecystectomy, surgical site infection or abscess formation must be considered and appropriate antibiotic treatment with resuscitation provided. Definitive management of a gallbladder fossa abscess is source control with operative drainage or drain placement.⁴

The authors attest that their institution requires neither Institutional Review Board approval, nor patient consent for publication of this case report. Documentation on file.

REFERENCES

1. Duca S, Bălă O, Al-Hajjar N, et al. Laparoscopic cholecystectomy: incidents and complications. a retrospective analysis of 9542 consecutive laparoscopic operations. *HPB (Oxford)*. 2003;5(3):152-8.
2. Deziel DJ, Milikan KW, Economou SG, et al. Complications of laparoscopic cholecystectomy: a national survey of 4292 hospitals and an analysis of 77604 cases. *Am J Surg*. 1993;165(1):9-14.
3. Karamanos E, Sivrikoz E, Beale E, et al. Effect of diabetes on outcomes in patients undergoing emergent cholecystectomy for acute cholecystitis. *World J Surg*. 2013;37(10):2257-64.
4. Shamiyeh A and Wayand W. Laparoscopic cholecystectomy early and late complications and their treatment. *Langenbecks Arch Surg*. 2004;389(3):164-71.

CPC-EM Capsule

What do we already know about this clinical entity?

Patients may have multiple complications following cholecystectomy, including biliary and bowel injuries, bleeding, dropped gallstones, and infection.

What is the major impact of the image(s)?

This image depicts a gallbladder fossa abscess, an uncommon complication following cholecystectomy.

How might this improve emergency medicine practice?

Gallbladder fossa abscess should be suspected in patients presenting with abdominal pain or signs of sepsis in the days to weeks following cholecystectomy.

Address for Correspondence: Drew A. Long, MD, Brooke Army Medical Center, Department of Emergency Medicine, 3551 Roger Brooke Dr., Fort Sam Houston, TX 78234. Email: drew.a.long.mil@mail.mil.

Conflicts of Interest: By the CPC-EM article submission agreement, all authors are required to disclose all affiliations, funding sources and financial or management relationships that could be perceived as potential sources of bias. The authors disclosed none. This manuscript does not reflect the views or opinions of the U.S. government, Department of Defense or its components, U.S. Army, U.S. Air Force, or SAUSHEC EM Residency Program.

Copyright: © 2020 Long et al. This is an open access article distributed in accordance with the terms of the Creative Commons Attribution (CC BY 4.0) License. See: <http://creativecommons.org/licenses/by/4.0/>

Colocutaneous Fistula after Percutaneous Endoscopic Gastrostomy (PEG) Tube Insertion

Matthew Warner, MD
Muhammad Durrani, DO, MS

Inspira Medical Center, Department of Emergency Medicine, Vineland, New Jersey

Section Editor: Rick A. McPheeters, DO

Submission history: Submitted May 20, 2020; Revision received July 8, 2020; Accepted July 24, 2020

Electronically published October 5, 2020

Full text available through open access at http://escholarship.org/uc/uciem_cpem

DOI: 10.5811/cpem.2020.7.48335

Case Presentation: A 48-year-old-female presented to the emergency department with dislodgement of her percutaneous endoscopic gastrostomy (PEG) tube, necessitating bedside replacement. Replacement was done without difficulty and gastrografen radiography was obtained to confirm positioning. Radiography revealed contrast filling the colon at the splenic flexure and proximal descending colon suggestive of colocutaneous fistula formation.

Discussion: The patient required hospitalization with surgical consultation, initiation of parenteral nutrition, and conservative management of the fistula with surgical replacement of the PEG tube. Although rare, it is paramount for the emergency physician to be aware of this complication when undertaking bedside replacement of PEG tubes. [Clin Pract Cases Emerg Med. 2020;4(4):632–633.]

Keywords: *Colocutaneous fistula; percutaneous endoscopic gastrostomy; parenteral nutrition.*

CASE PRESENTATION

A 48-year-old female with past medical history of failure to thrive requiring percutaneous endoscopic gastrostomy (PEG) tube placement presented to the emergency department (ED) with PEG tube dislodgement. Her PEG tube was initially placed in 2009, with surgical replacements in 2012 and 2018. Examination revealed a soft, nontender, non-distended abdomen with an open gastrostomy tract. ED course included placement of a new gastrostomy tube into the existing tract and confirmatory gastrografen radiography (Image).

DISCUSSION

The confirmatory radiography revealed contrast filling the colon at the splenic flexure and proximal descending colon suggestive of colocutaneous fistula formation, without peritoneal extravasation. This required hospitalization with surgical consultation for removal of the misplaced PEG tube, initiation of parenteral nutrition, intravenous antibiotics, and surgical reinsertion of the PEG tube after conservative management of the colocutaneous fistula. Colocutaneous fistulas are a rare complication of PEG tube insertion with incidence rates of 0.5-3%.¹ Fistula formation is mediated by PEG tube penetration of interposed colon between the stomach

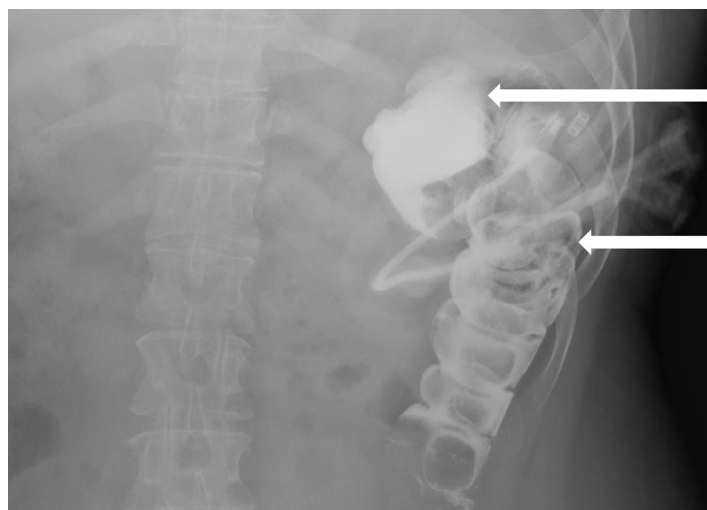


Image. Gastrografen radiography showing percutaneous endoscopic gastrostomy tube in the colon with contrast filling colon at the splenic flexure (top arrow) and proximal descending colon (bottom arrow) suggestive of colocutaneous fistula formation.

and abdominal wall during the initial insertion.¹⁻⁵ Fistula formation occurs at the time of initial insertion but symptoms

manifest after reinsertion of the PEG tube fails to completely pass the tube through the interposed colon to enter the stomach.^{2,3} Risk factors include adhesions from previous laparotomy, postural and spinal abnormalities, and high-riding transverse colon.¹ Symptoms include sudden onset diarrhea after PEG tube feeds, visualization of undigested feeding formula, and feculent vomiting with retrograde passage of material from the colon.¹ Upper endoscopy with water-soluble contrast is the diagnostic modality of choice.¹⁻⁵ Treatment ranges from conservative management aimed at decreasing fistula output and allowing for spontaneous closure after infection control, nutritional optimization and establishing wound care to surgical repair. Since emergency physicians change a large number of PEG tubes, recognition and awareness of this rare complication is important to clinical practice.

The authors attest that their institution requires neither Institutional Review Board approval, nor patient consent for publication of this case report. Documentation on file.

Address for Correspondence: Matthew Warner, MD, Inspira Medical Center, 1505 W Sherman Ave, Vineland, NJ 08360. Email: matthew.warner@ihn.org.

Conflicts of Interest: By the *CPC-EM* article submission agreement, all authors are required to disclose all affiliations, funding sources and financial or management relationships that could be perceived as potential sources of bias. The authors disclosed none.

Copyright: © 2020 Warner et al. This is an open access article distributed in accordance with the terms of the Creative Commons Attribution ([CC BY 4.0](http://creativecommons.org/licenses/by/4.0/)) License. See: <http://creativecommons.org/licenses/by/4.0/>

REFERENCES

1. Lee J, Kim J, Kim HI, et al. Gastrocolocutaneous fistula: an unusual case of gastrostomy tube malfunction with diarrhea. *Clin Endosc*. 2018;51(2):196-200.
2. Yamazaki T, Sakai Y, Hatakeyama K, et al. Colocutaneous fistula after percutaneous endoscopic gastrostomy in a remnant stomach. *Surg Endosc*. 1999;13(3):280-2.
3. Chime C, Ravi M, Daniel M, et al. Gastrocolic fistula: a rare presentation of colon cancer. *Case Rep Gastrointest Med*. 2018;2018:6958925-3.
4. Friedmann R, Feldman H, Sonnenblick M. Misplacement of percutaneously inserted gastrostomy tube into the colon: report of 6 cases and review of the literature. *JPEN J Parenter Enteral Nutr*. 2007;31(6):469-76.
5. Hucl T and Spicak J. Complications of percutaneous endoscopic gastrostomy. *Best Pract Res Clin Gastroenterol*. 2016;30(5):769-81.

CPC-EM Capsule

What do we already know about this clinical entity?

Colocutaneous fistulas are a rare complication of percutaneous endoscopic gastrostomy (PEG) tube insertion mediated by PEG tube penetration of interposed colon between the stomach and abdominal wall.

What is the major impact of the image(s)?

Contrast filling the splenic flexure and proximal descending colon suggests colocutaneous fistula formation, requiring prompt recognition and surgical consultation.

How might this improve emergency medicine practice?

Emergency physicians change a large number of PEG tubes; therefore, recognition and awareness of this rare complication is important to clinical practice.

Extensive Upper Airway Hematoma Secondary to Supratherapeutic Warfarin Anticoagulation

Taofiq Olusegun Oyedokun, MD*
Kevin Manuel Durr, MD†

*University of Saskatchewan, Department of Emergency Medicine, Saskatoon, Saskatchewan, Canada

†University of Ottawa, Department of Emergency Medicine, Ottawa, Ontario, Canada

Section Editor: Rick A. McPheeters, DO

Submission history: Submitted June 14, 2020; Revision received July 16, 2020; Accepted July 24, 2020

Electronically published October 19, 2020

Full text available through open access at http://escholarship.org/uc/uciem_cpem

DOI: 10.5811/cpcem.2020.7.48695

Case Presentation: A 63-year-old female presented to the emergency department complaining of cough, neck swelling, dysphagia, and dysphonia for two days, with a past medical history of atrial fibrillation managed with warfarin. Investigations revealed a supratherapeutic international normalised ratio (greater than 10). Imaging and endoscopic examination showed an extensive retropharyngeal hematoma with significant mass effect on the airway.

Discussion: A rare but potentially fatal complication of warfarin anticoagulation is upper airway hematoma, with violent coughing described as an inciting cause. Signs of airway compromise necessitate specialist consultation and definitive airway management, while mild cases without airway concerns can be managed conservatively with medical anticoagulation reversal. [Clin Pract Cases Emerg Med. 2020;4(4):634–635.]

Keywords: *anticoagulation; swelling; airway; hematoma.*

CASE PRESENTATION

A 63-year-old female presented to the emergency department with a two-day history of cough, neck swelling, dysphagia, and dysphonia. She was taking warfarin for atrial fibrillation. Vital signs were normal, and she was not in respiratory distress. Further examination revealed hoarseness and multiple ecchymoses over the anterior aspect of her neck (Image 1), as well as a sublingual haematoma (Image 2).

Immediate anesthesiology and otorhinolaryngology consultations were requested. Non-contrast computed tomography and endoscopic examination revealed a hematoma extending from the retropharyngeal space of the suprahyoid neck, down into the infrahyoid neck to the level of the thyroid cartilage, causing significant mass effect on the airway and right vocal cord (Image 3).

The patient's international normalised ratio (INR) was supratherapeutic, measuring greater than 10. She was managed conservatively, with 10 mg of vitamin K, 3000 units of prothrombin complex concentrate (PCC), as well as 10 milligrams of dexamethasone, and observed in the intensive care unit (ICU). She was transferred to the

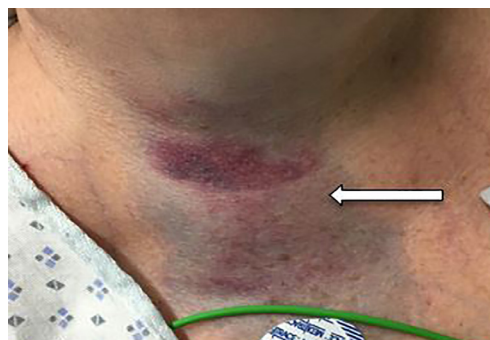

Image 1. General inspection revealing ecchymosis over the anterior aspect of the patient's neck (arrow).

surgical observation unit the following day, and discharged home six days later.

DISCUSSION

Upper airway hematomas are a potentially fatal albeit rare complication of warfarin anticoagulation, with violent coughing described as an inciting cause.¹ Dysphagia, sore throat, neck

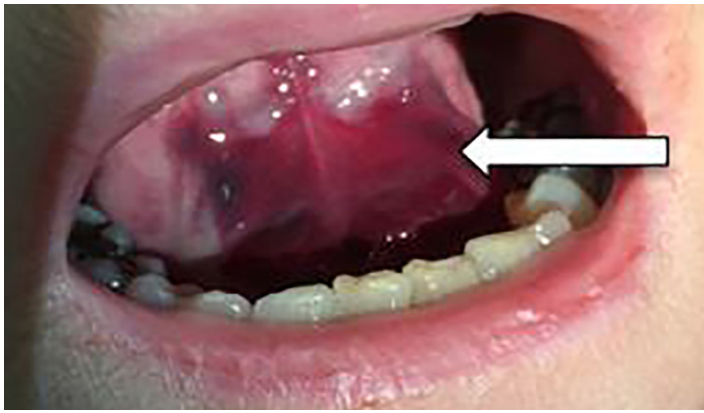

Image 2. Airway assessment revealing a sublingual hematoma (arrow).

swelling, ecchymosis, and hoarseness are common presenting symptoms.¹ Optimal management remains debated. Signs of airway compromise necessitate timely consultation of anesthesiology and otorhinolaryngology and may require definitive airway management, while mild cases without airway concerns can successfully be managed with medical therapy.^{1,2} A combination of vitamin K and fresh frozen plasma (FFP) or PCC, with observation in the ICU is recommended.^{1,3} In the context of warfarin-induced coagulopathy, PCC is associated with faster reversal, as well as fewer red cell transfusions and adverse events, relative to FFP.⁴ The recommended PCC dose is four units per kilogram (U/kg) with an INR greater than 1.5 and 50 U/kg with an INR greater than six.¹

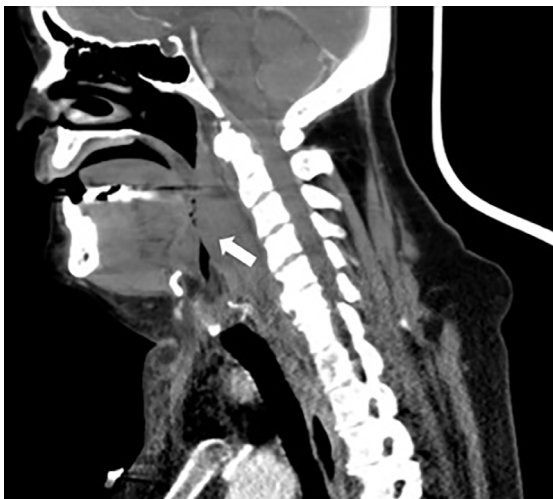

Image 3. Sagittal view of a non-contrast computed tomography of the neck demonstrating an extensive retropharyngeal hematoma causing mass effect on the airway (arrow).

Patient consent has been obtained and filed for the publication of this case report.

CPC-EM Capsule

What do we already know about this clinical entity?

Upper airway hematoma is a rare but potentially fatal complication of warfarin therapy.

Signs of airway compromise necessitate prompt airway management.

What is the major impact of the image(s)?

Initial clinical appearance of unexplained ecchymoses in anticoagulated patients should increase the suspicion of a hematoma in the airway.

How might this improve emergency medicine practice?

Rapid reversal of anticoagulation with vitamin K and prothrombin complex concentrate may prevent the need for airway intervention.

Address for Correspondence: Taofiq Olusegun Oyedokun, MD, Royal University Hospital, Department of Emergency Medicine, Room 2646, 103 Hospital Drive, Saskatoon, SK, S7N 0W8. Email: too698@mail.usask.ca.

Conflicts of Interest: By the CPC-EM article submission agreement, all authors are required to disclose all affiliations, funding sources and financial or management relationships that could be perceived as potential sources of bias. The authors disclosed none.

Copyright: © 2020 Oyedokun et al. This is an open access article distributed in accordance with the terms of the Creative Commons Attribution (CC BY 4.0) License. See: <http://creativecommons.org/licenses/by/4.0/>

REFERENCES

1. Karmacharya P, Pathak R, Ghimire S, et al. Upper airway hematoma secondary to warfarin therapy: a systematic review of reported cases. *N Am J Med Sci.* 2015;7(11):494-502.
2. Akoğlu E, Seyfeli E, Akoğlu S, et al. Retropharyngeal hematoma as a complication of anticoagulation therapy. *Ear Nose Throat J.* 2008;87(3):156-9.
3. Bloom D, Haegen T, Keefe M. Anticoagulation and spontaneous retropharyngeal hematoma. *J Emerg Med.* 2003;24(4):389-94.
4. Hickey M, Gatiem M, Taljaard M, et al. Outcomes of urgent warfarin reversal with frozen plasma versus prothrombin complex concentrate in the emergency department. *Circulation.* 2013;128(4):360-4.

Female with Vaginal Bleeding

Mark Quilon, MD*
Alec Glucksman, DO*
Gregory Emmanuel, MD†
Josh Greenstein, MD*
Barry Hahn, MD*

*Staten Island University Hospital, Department of Emergency Medicine, Staten Island, New York
†Massachusetts General Hospital, Department of Radiology, Boston, Massachusetts

Section Editor: Shadi Lahham, MD

Submission history: Submitted June 9, 2020; Revision received August 17, 2020; Accepted August 21, 2020

Electronically published October 20, 2020

Full text available through open access at http://escholarship.org/uc/uciem_cpem

DOI: 10.5811/cpsem.2020.8.48627

Case Presentation: A 24-year-old pregnant female presented to the emergency department with lower abdominal cramping and vaginal bleeding. A point-of-care ultrasound demonstrated a calcified yolk sac.

Discussion: When identified, calcification of the yolk sac in the first trimester is a sign of fetal demise. It is important for an emergency physician to be aware of the various signs and findings on point-of-care ultrasound and be familiar with the management of these pathologies. [Clin Pract Cases Emerg Med. 2020;4(4):636–637.]

Keywords: *ultrasound; pregnancy.*

CASE PRESENTATION

A 24-year-old female presented to the emergency department (ED) with three days of lower abdominal cramping and vaginal spotting. Physical examination demonstrated suprapubic tenderness, scant blood in the vaginal vault, and closed cervix. The urine pregnancy test was positive. An ED point-of-care, pelvic ultrasound identified a fetal pole with an adjacent echogenic yolk sac (Images 1 and 2, video). Fetal cardiac activity was not appreciated.

DISCUSSION

Calcification of the yolk sac is likely due to dystrophic calcification, in which dead tissue undergoing necrosis accumulates calcium.¹ Calcification of the yolk sac in the first trimester is a sign of fetal demise.² Ultrasound will show increased echogenicity within the gestational sac. The normal ring-like appearance of the yolk sac will instead resemble a hyperechoic, dense, irregular structure, along with posterior acoustic shadowing and possibly comet-tail artifact.^{3,4}

Calcified yolk sacs are usually indicative of a loss of fetal cardiac activity before 12 weeks of gestation. Greater than 80% of miscarriages occur in the first trimester, and

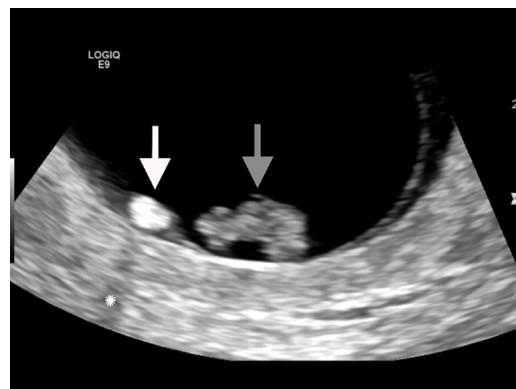


Image 1. Close-up view of transvaginal sonogram demonstrating a fetal pole (gray arrow) with an adjacent echogenic yolk sac (white arrow), along with posterior acoustic shadowing (asterisk).

calcification of the yolk sac may be seen at that time. However, the prevalence is currently unknown. Risk factors are the same as those that are commonly associated with miscarriage, including previous miscarriage, fetal

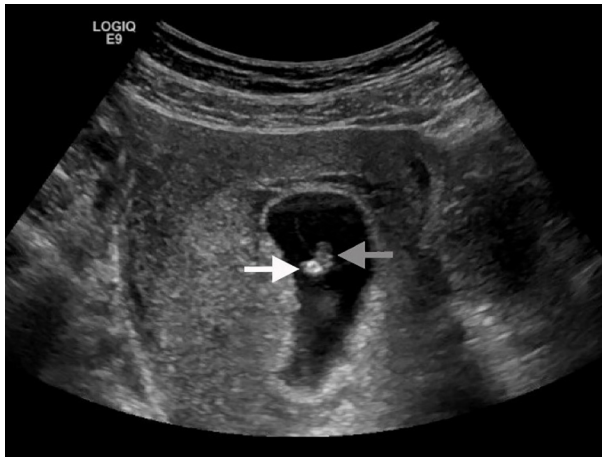

Image 2. Transvaginal sonogram demonstrating a fetal pole (gray arrow) with an adjacent echogenic yolk sac (white arrow).

chromosomal abnormalities, advanced maternal age, and diabetes. Signs and symptoms include abdominal pain or cramps and vaginal bleeding. Physical findings include abdominal tenderness and blood in the vaginal vault with an open or closed cervix. Treatment is expectant management and symptomatic therapy. Outpatient obstetrical follow-up with ultrasonography at 7-14 days to assess the pregnancy for viability is generally appropriate. A calcified yolk sac does not confer any higher risk of future miscarriage or infertility, similar to other first-trimester spontaneous abortions.⁵

Video. Transvaginal sonogram demonstrating a fetal pole (solid arrowhead) with an adjacent echogenic yolk sac (hollow arrow).

The authors attest that their institution requires neither Institutional Review Board approval, nor patient consent for publication of this case report. Documentation on file.

REFERENCES

- Harris RD, Vincent LM, Askin FB. Yolk sac calcification: a sonographic finding associated with intrauterine embryonic demise in the first trimester. *Radiology*. 1988;166(1):109-10.
- Rodgers SK, Chang C, DeBardleben JT, et al. Normal and abnormal US findings in early first-trimester pregnancy: review of the Society of Radiologists in Ultrasound 2012 Consensus Panel recommendations. *RadioGraphics*. 2015;35(7):1661-71.
- Lyons EA and Levi CS. (2005). The first trimester. In: Rumack CM, Wilson SR, Charboneau JW (Eds.), *Diagnostic Ultrasound* (p. 1070-1100). St Louis, MO: CV Mosby Co.
- Tan S, Pektaş MK, Arslan H. Sonographic evaluation of the yolk sac. *J Ultrasound Med*. 2012;31(1):87-95.
- Hoffman BL, Schorge JO, Halvorson LM, et al. (2020). First-trimester abortion. In: Hamid CA, Corton MM, Schaffer JI (Eds.), *Williams Gynecology*. 4th ed. New York, NY: McGraw-Hill.

CPC-EM Capsule

What do we already know about this clinical entity?

A calcified yolk sac is a sonographic sign associated with fetal demise and inevitable abortion.

What is the major impact of the image(s)?

This image can help physicians distinguish fetal demise from other signs of early pregnancy.

How might this improve emergency medicine practice?

Identification of a calcified yolk sac can help manage patient expectations and allow the emergency medicine clinician to counsel the patient, and arrange appropriate follow up.

Address for Correspondence: Josh Greenstein, MD, Staten Island University Hospital, Department of Emergency Medicine, 475 Seaview Avenue, Staten Island, NY 10305. Email: jgreenstein1@northwell.edu.

Conflicts of Interest: By the CPC-EM article submission agreement, all authors are required to disclose all affiliations, funding sources and financial or management relationships that could be perceived as potential sources of bias. The authors disclosed none.

Copyright: © 2020 Quilon et al. This is an open access article distributed in accordance with the terms of the Creative Commons Attribution (CC BY 4.0) License. See: <http://creativecommons.org/licenses/by/4.0/>

Clinicopathological Conference: 54-year-old with Facial Swelling for One Month

Justin Edwin Pile, DO, MSc*

Adam Dawson, DO†

Lynn Maxa, DO*

*Swedish Hospital, Part of NorthShore University HealthSystem, Department of Emergency Medicine, Chicago, Illinois

†Kingman Regional Medical Center, Department of Emergency Medicine, Kingman, Arizona

Section Editor: John Ashurst, DO, MSc

Submission history: Submitted May 27, 2020; Revision received September 13, 2020; Accepted September 17, 2020

Electronically published October 9, 2020

Full text available through open access at http://escholarship.org/uc/uciem_cpccm

DOI: 10.5811/cpcem.2020.9.48439

A 54-year-old female with facial swelling for one month who had repeatedly been treated for allergic reaction during multiple emergency department (ED) visits, presented to the ED for the same complaint of facial swelling. Maintaining a broad differential diagnosis was of critical importance to appropriately evaluating the patient and arriving at the correct conclusion for the etiology of the patient's symptoms. Upon establishing the correct diagnosis, a multidisciplinary approach was used to intervene to provide early treatment without delay. [Clin Pract Cases Emerg Med. 2020;4(4):638–641.]

CASE PRESENTATION (Resident Presentation)

A 54-year-old female with no past medical history presented to the emergency department (ED) of an urban community hospital with persistent facial swelling for more than one month despite five previous ED visits to diagnose and treat her condition. More than a month earlier, she had received a one-week course of clindamycin for a dental abscess, which she took just prior to the onset of facial swelling, redness, and itching. It was thought that these symptoms were due to an allergic reaction to the clindamycin. She was seen in an ED and was given diphenhydramine and prednisone with subjective improvement of the symptoms (follow-up visit one). Since that first ED visit for signs of an allergic reaction, she had four additional visits to different EDs with the same symptoms and was prescribed hydroxyzine during the second visit (follow-up visit two), loratadine during the third visit (follow-up visit three), and additional courses of prednisone in the last two of the five visits (follow-up visits four and five).

After the fifth follow-up visit for symptoms of a presumed allergic reaction, she presented for the same facial swelling this time to our ED. Her facial swelling was worse at night but did not fully resolve during the day. She denied any additional exacerbating or alleviating factors. Of note, the patient denied having a primary care physician or any physician who knew her medical history. At the previous ED visits, she stated that

she thought labs had been drawn but was not certain and could not recall the specific dates she had visited each ED. She denied having had any imaging completed during the prior ED visits.

A review of systems was positive for facial swelling and negative for tongue swelling, oropharyngeal swelling, sore throat, dysphagia, chest discomfort, dyspnea, rash, pruritis, abdominal pain, nausea, vomiting, change in bowel or bladder habits, weight gain or loss, loss of appetite, and extremity swelling. She denied any other medical complaints. She denied any medical or surgical history, tobacco, alcohol, or illicit drug use, and stated that she lived with her husband.

Vital signs were as follows: temperature 98.1 degrees Fahrenheit; blood pressure 111/66 millimeters mercury; heart rate 82 beats per minute, respiratory rate 20 breaths per minute; and oxygen saturation 96% on room air. Physical examination revealed an obese, White female sitting awake and alert in no acute distress with significant diffuse swelling of her face, which was most prominent in the periorbital region without ecchymoses, erythema, or urticaria. Her conjunctivae were without erythema. Her pupils were equal, round, and reactive to light, and the extraocular motions were intact and painless. There were no other abnormal respiratory, cardiovascular, abdominal, or neurologic findings on examination. A complete blood count, basic metabolic panel, and chest radiograph (CXR) were ordered during the initial workup of the patient. Based on CXR findings (Image 1), a

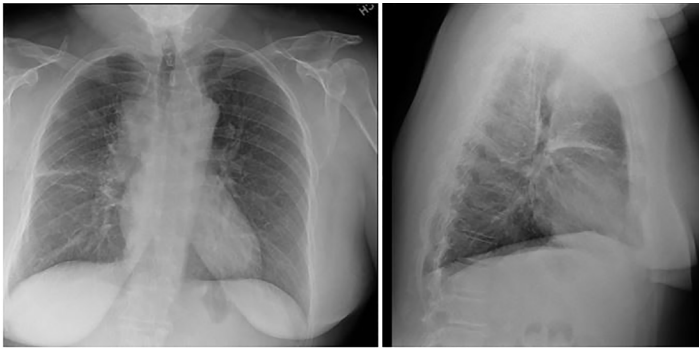


Image 1. Posterior-anterior and lateral chest radiograph of a 54-year-old female with facial swelling.

computed tomography (CT) of the chest was obtained (Image 2). The patient had an uneventful stay in the ED.

CASE DISCUSSION (Attending Discussion)

The underlying cause of facial swelling can be difficult to determine. In the case of this 54-year-old female, she had undergone at least six evaluations prior to this particular presentation. The true first visit was a case of a dental abscess, and this started a pathway of continuing unsuccessful treatment for an allergic reaction to the antibiotic. The physician should consider a variety of possible etiologies for this swelling given the protracted course and unsuccessful treatments.

An allergic reaction is arguably the most likely noninfectious cause of the patient's facial swelling in the absence of additional clues. Antihistamines and steroids were used and were likely appropriate. Perhaps these treatments did even help somewhat with the true underlying cause of the swelling. If the antibiotic

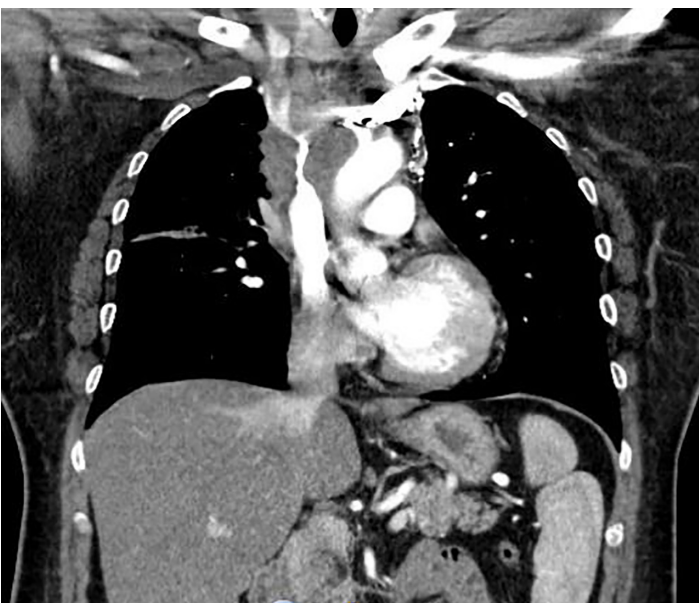


Image 2. Computed tomography of the chest with intravenous contrast of a 54-year-old female with facial swelling.

was indeed the cause of the allergic reaction, then multiple rounds of treatment should not have been required without additional exposures to the allergen. This was the working diagnosis, which was presumptive and incorrect.

Was a dental infection entirely ruled out? Such infections can come in a variety of forms not the least of which would be an abscess. Ludwig's angina is a progressive and dangerous bacterial infection that occurs in the submandibular space; the origin is dental. The physical exam showed no oral/mucosal swelling, redness or tenderness, and the face had a similar exam. The subjective responsiveness to the treatment of an allergy would also imply that infection is unlikely. In fact, quite possibly steroids would have worsened such an infection. Now that we have decided that we no longer think that this could be allergic or infectious, what else is there?

Individuals with autoimmune disorders who are being treated with steroids can have steroid-related facial swelling. Cushing's syndrome can lead to increased weight gain including in the face. There are a variety of potential causes, but iatrogenic steroid use is a common one. Regardless, the fact remains that in this case the patient presumably had initial improvement with steroids, and the initial steroid use was insufficient to propagate such a syndrome.

Angioedema is yet another consideration for our patient's symptoms. Given her age, if she had the hereditary variety of angioedema caused by a C1 esterase inhibitor deficiency, there likely would be a personal or family history of a previous event. Angioedema can also occur due to excessive bradykinin in some patients on angiotensin-converting enzyme inhibitors. In either scenario, the use of antihistamines and steroids is controversial and without formal consensus of indication.

A complete blood count and basic metabolic panel were ordered and noted for hypokalemia, mild leukocytosis, and normocytic anemia as seen in the Table, but were not otherwise suggestive of any paraneoplastic syndromes such as syndrome of inappropriate anti-diuretic hormone.

The truly pivotal clue provided is that the patient's symptoms are in fact worse at night and better during the day. The reason that this makes sense is because there is an issue with the vasculature. The fact that it is worse at night has nothing to do with circadian rhythm and you should suspect superior vena cava (SVC) syndrome. If you see or diagnose this condition once it will forever be in your differential and the primary diagnosis in patients with that description. This syndrome is essentially the sequelae of the backed-up flow to the right heart through the SVC. It can of course lead to much more severe symptoms but does not have to. The treatment definitively would be to correct the underlying cause.

In evaluation, the plain film CXR shows mediastinal widening with a probable mass. The follow-up computed tomography (CT) of the chest indeed demonstrated a circumferential mass around the SVC with narrowing of the vessel. Specifically, there is a mediastinal mass measuring 8.4 x 6.1 x 5.3 centimeters (cm) with significant compression

of the SVC as well as a 3-cm mass at base of neck right side compressing the jugular vein. In addition, there was attenuation of the upper/middle lobe segmental pulmonary arteries and bronchi with post-obstructive, right upper lobe pneumonitis, two pulmonary nodules representing metastatic disease in right upper lobe, and a mass in right lobe of liver compatible with metastatic disease.

Superior vena cava syndrome could most certainly have caused the timing of symptoms the patient experienced. When she was lying down sleeping at night, there was insufficient flow through the SVC into the right atrium. The resulting appearance would be edema of the face. When upright during the day, gravity assists in the flow through the narrow vessel to increase the return to the right heart. If the problem were more directly gravity dependent, such as in congestive heart failure, it would be more likely to see the edema in the lower extremities and the swelling would subside when the person is lying down.

Given that a more common cause of this syndrome is due to malignancy, the steroids that were provided in the patient's care quite possibly were therapeutic in decreasing inflammation, increasing the luminal diameter, and allowing better flow to the heart. The underlying causes of this are usually slow-growing, and it can be easy to miss this diagnosis until the final realization despite multiple attempts.

CLINICAL DIAGNOSIS

Superior vena cava syndrome due to a mediastinal mass.

CASE OUTCOME

The management of this patient relied on finding a diagnosis that explained her persistent facial swelling despite treatment with steroids and antihistamines. The previous diagnosis of allergic reaction at prior ED visits was not the correct diagnosis for her clinical condition. Two diagnoses that seemed plausible were SVC syndrome and malignancy, both of which could contribute to the patient's facial swelling. A CXR (Image 1) indicated a possible mass that warranted chest CT (Image 2), which established the diagnosis of SVC syndrome secondary to a mediastinal mass.

The patient was transferred to another facility with cardiothoracic surgeons and pulmonologists. The patient was eventually diagnosed with small cell lung carcinoma with metastases to the mediastinum, liver, and supraclavicular lymph nodes. Upon follow-up of the patient, palliative surgery was considered for her mediastinal mass and radiation considered for the metastases. The final decision by the patient for treatment is not known.

RESIDENT DISCUSSION

Superior vena cava syndrome is a collection of clinical signs and symptoms resulting from thrombus formation or tumor infiltration of the vessel wall causing either partial or complete obstruction of blood flow through the SVC.¹ When

the SVC is obstructed, there is retrograde flow to the left and right innominate (brachiocephalic) veins, which join to form the SVC.¹ Thus, blood is unable to return to the heart and backs up into the head, neck, upper extremities and torso.¹

This syndrome occurs in approximately 15,000 people in the United States annually.² Originally described as being secondary to infection (tuberculosis or syphilitic aortic aneurysm), now it is now generally considered to result from cancer or thrombotic events.² Most cases of SVC syndrome are associated with advanced malignant diseases that cause invasion of the venous intima or extrinsic mass effect.² Common causes include lung, breast, and mediastinal neoplasms, with adenocarcinoma of the lung the most common cause.² Non-Hodgkin's lymphoma and then metastatic tumors are the second most common etiologies of SVC syndrome, followed by benign or nonmalignant causes, which comprise at least 40% of cases.¹ Pacemaker wires and semipermanent intravascular catheters used for hemodialysis, long-term antibiotics, or chemotherapy are causes of iatrogenic thrombus formation and SVC stenosis.¹

Gradual compression of the SVC leads to edema and retrograde flow. In thrombotic cases, this may result in an abrupt onset of symptoms.³ Signs and symptoms include swelling of the face, head, neck, breast, cough, dyspnea, distended neck veins, orthopnea, and conjunctival suffusion; collateral circulation leads to distension of superficial veins in the chest wall.³ Other less common symptoms of SVC syndrome include stridor, hoarseness, dysphagia, pleural effusion, head plethora, headache, nausea, lightheadedness, syncope, change in vision, altered mental status, upper body edema, cyanosis, papilledema, stupor, and coma.¹ Some rare but serious clinical consequences reported in SVC syndrome include cerebral edema and upper respiratory compromise secondary to edema of larynx and pharynx.¹

A physical exam maneuver associated with SVC syndrome is Pemberton's sign, which is positive when bilateral arm elevation causes facial plethora.⁴ It has been attributed to a "cork effect" resulting from the thyroid obstructing the thoracic inlet, thereby increasing the pressure on the venous system.⁴ Pemberton's maneuver is a clinical test for latent SVC syndrome caused by a substernal mass.⁵ If there is high clinical suspicion, imaging of the upper body and vasculature should be completed including ultrasound of the jugular, subclavian, and innominate veins to assess for thrombus, CXR, CT of the chest, or magnetic resonance imaging to assess for severity of the SVC obstruction. Venography is the gold standard for diagnosing venous obstruction.¹ Multidisciplinary cooperation among radiation and medical oncologists and interventional radiologists is needed to provide an early treatment.⁶ Treatment involves chemotherapy and radiation for underlying cancer to reduce the degree of obstruction. Dilation and stenting as well as bypass of the SVC may be performed. Adjunctive therapies may include diuretics and corticosteroids.¹

FINAL DIAGNOSIS

Superior vena cava syndrome

KEY TEACHING POINTS

- Superior vena cava syndrome is a collection of clinical signs and symptoms resulting from either partial or complete obstruction of blood flow through the SVC.
- SVC syndrome is most commonly due to cancer or thrombotic events.
- Upper body and facial swelling, cough, and shortness of breath are common symptoms.
- The swelling is commonly worse when the patient is lying flat, which is more frequently at night.
- Treatment can involve chemotherapy and radiation; dilatation, stenting, and bypass of the SVC; and diuretics and steroids.

The authors attest that their institution requires neither Institutional Review Board approval, nor patient consent for publication of this case report. Documentation on file.

REFERENCES

1. Seligson MT and Surowiec SM. 2020. Superior vena cava syndrome. StatPearls [Internet]. Available at: <https://www.ncbi.nlm.nih.gov/books/NBK441981/>. Accessed September 11, 2020.

Address for Correspondence: Justin Pile, DO, MSc, Swedish Hospital Part of NorthShore, Department of Emergency Medicine, Attn: Medical Education, 5145 North California Ave., Chicago, IL 60625. Email: jpiled@schosp.org.

Conflicts of Interest: By the CPC-EM article submission agreement, all authors are required to disclose all affiliations, funding sources and financial or management relationships that could be perceived as potential sources of bias. The authors disclosed none.

Copyright: © 2020 Pile et al. This is an open access article distributed in accordance with the terms of the Creative Commons Attribution (CC BY 4.0) License. See: <http://creativecommons.org/licenses/by/4.0/>

2. Cohen R, Mena D, Carbajal-Mendozan R, et al. Superior vena cava syndrome: a medical emergency? *Int J Angiol.* 2008;17(1):43-6.
3. Hinton J, Cerra-Franco A, Shiue K, et al. Superior vena cava syndrome in a patient with locally advanced lung cancer with good response to definitive chemoradiation: a case report. *J Med Case Rep.* 2018;12(1):301.
4. De Filippis EA, Sabet A, Sun MR, et al. Pemberton's sign: explained nearly 70 years later. *J Clin Endocrinol Metab.* 2014;99(6):1949-54.
5. Anders H and Keller C. Pemberton's maneuver – a clinical test for latent superior vena cava syndrome caused by a substernal mass. *Eur J Med Res.* 1997;2(11):488-90.
6. Kohútek F, Litvín I, Tamášová M, et al. [Syndrome of vena cava obstruction in oncology]. *Klin Onkol.* 2013;26(6):434-7.

Morel-Lavallée Lesion Following a Low-speed Injury: A Case Report

Daniel Porter, DO
Jeff Conley, MD
John Ashurst, DO, MSc

Kingman Regional Medical Center, Department of Emergency Medicine, Kingman, Arizona

Section Editor: Rick A. McPheeters, DO

Submission history: Submitted May 20, 2020; Revision received June 1, 2020; Accepted July 3, 2020

Electronically published September 9, 2020

Full text available through open access at http://escholarship.org/uc/uciem_cpsem

DOI: 10.5811/cpcem.2020.7.48358

Introduction: Soft tissue injuries are a common presenting complaint seen in the emergency department following trauma. However, internal degloving injuries are not commonly seen by the emergency provider.

Case Report: A 57-year-old male presented with right lower extremity pain, bruising, and swelling after a low-speed bicycle accident five days prior. Physical examination revealed an edematous and ecchymotic right lower extremity extending from the mid-thigh distally. Computed tomography of the thigh demonstrated a hyperdense foci within the fluid collection suggesting internal hemorrhage and internal de-gloving suggestive of a Morel-Lavallée lesion.

Discussion: The Morel-Lavallée lesion is a post-traumatic soft tissue injury that occurs as a result of shearing forces that create a potential space for the collection of blood, lymph, and fat. First described in 1853 by French physician Maurice Morel-Lavallée, this internal degloving injury can serve as a nidus of infection if not treated appropriately. Magnetic resonance imaging has become the diagnostic modality of choice due to its high resolution of soft tissue injuries. Treatment has been focused on either conservative management or surgical debridement after consultation with a surgeon.

Conclusion: The emergency physician should consider Morel-Lavallée lesions in patients with a traumatic hematoma formation to avoid complications that come from delayed diagnosis. [Clin Pract Cases Emerg Med. 2020;4(4):642–643.]

Keywords: *Morel-Lavallee; trauma; internal degloving.*

INTRODUCTION

Trauma is a common presenting complaint to the emergency department (ED) and is the leading cause of morbidity, hospitalizations, and death in Americans 1-45 years old.¹ Morel-Lavallée lesions are post-traumatic injuries following blunt trauma to soft tissues and often can either go undiagnosed or present weeks after the initial injury.² Typically seen after a high-speed injury, the traumatic shearing mechanism creates a potential space for fluid accumulation by separating the subcutaneous tissue from the underlying deeper fascial layers causing an internal degloving injury.² This newly

created space allows for the collection of blood, lymph, and occasionally necrotic fat.² There could be a delay in diagnosis as these lesions often occur in patients with multisystem trauma, which increases the likelihood of infection, tissue necrosis, and pseudocapsule formation.^{3,4} We present a case of a Morel-Lavallée lesion following a low-speed bicycle accident that was treated with conservative management.

CASE REPORT

A 57-year-old male presented to the ED with right lower extremity pain, bruising, and swelling after striking his leg

on the sidewalk following a low-speed bicycle accident five days prior. He noted no other injuries from the accident but his leg had increased in size over the preceding several days and began to develop wounds. He stated no past medical history and took no medications on a daily basis.

Physical examination revealed an edematous and ecchymotic right lower extremity extending from the mid-thigh distally (Image 1). There were areas of hemorrhagic bullae along the medial thigh and there was a 1+ dorsalis pedis pulse in the extremity. The remainder of the trauma examination was within normal limits.

Ultrasonography revealed a 20 centimeters (cm) x 4 cm x 14 cm hypoechoic fluid collection in the right medial thigh (Image 2). Computed tomography of the thigh demonstrated a hyperdense foci within the fluid collection suggesting internal

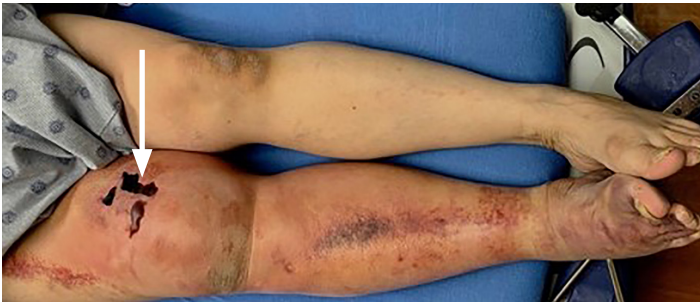

Image 1. Large area of ecchymosis of the right lower extremity with hemorrhagic bullae formation (arrow).

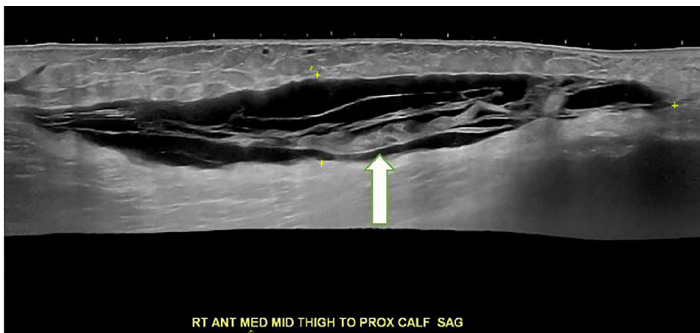


Image 2. Ultrasound of the right lower extremity depicting the formation of a hypoechoic area between muscle and fascia (arrow).

hemorrhage and internal degloving injury suggestive of a Morel-Lavallée lesion (Image 3).

The patient underwent bedside needle drainage of the fluid collection by general surgery, which yielded over 500 milliliters of sanguineous fluid. He was discharged with a compression dressing and general surgery follow-up. The patient unfortunately did not follow up with general surgery as an outpatient and was seen in the ED several weeks later with a deep soft tissue infection of the thigh requiring surgical debridement.

CPC-EM Capsule

What do we already know about this clinical entity?

A Morel-Lavallée lesion is a post-traumatic soft tissue injury that creates a potential space for the collection of blood, lymph, and fat.

What makes this presentation of disease reportable?

While typically presenting after a high-speed injury, we present this case that occurred following a low-speed bicycle accident.

What is the major learning point?

Emergency department management should include consultation with a surgeon to determine best treatment strategies.

How might this improve emergency medicine practice?

Providers should be vigilant in their examination of all injured areas, obtain diagnostics studies, and surgical consultation to prevent long-term complications.

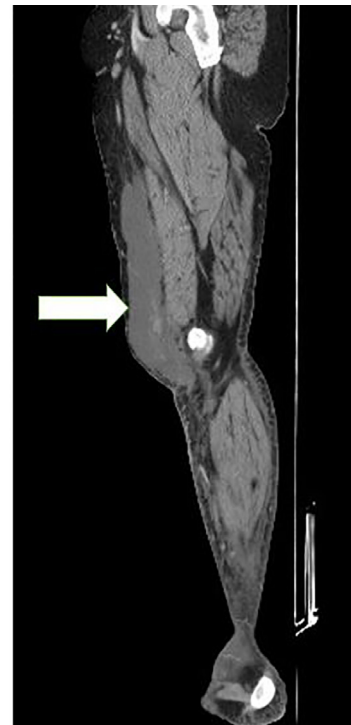


Image 3. Computed tomography of the right lower extremity showing an internal hemorrhage and internal degloving injury of the thigh (arrow).

DISCUSSION

Typically occurring after direct trauma to the pelvis, thigh, or knee, a Morel-Lavallée lesion is caused by a shearing force to an area with strong underlying fascia.⁵ Following disruption of the fascial layer, transaponeurotic capillaries and lymphatic vessels become disrupted and leak haemolymphatic fluids into the newly formed cavity.⁶ Over time, blood is reabsorbed and replaced with serosanguinous fluids, which can cause a sustained inflammatory response and the formation of a cystic mass.⁵

Although the exact epidemiology is unknown, the majority of Morel-Lavallée injuries are seen in those with a body mass index of 25 or more following trauma with a high-energy mechanism.^{5,6} Upon initial ED presentation, a patient may have soft tissue swelling with or without ecchymosis, skin contour asymmetry with hypermobility, or a soft tissue fluctuance with minimal or no tenderness.^{5,6} Given many of these injuries do not become apparent until after the initial injury, patients may also present in a delayed fashion with decreased sensation, necrosis, and color changes over the lesion.^{5,6}

Magnetic resonance imaging is currently the imaging modality of choice due to its high-contrast resolution, multiplanar image acquisition, and enhanced anatomical details as compared to other modalities.² Computed tomography is another diagnostic modality that can be used because of its availability in the trauma setting but does not easily allow for the characterization of soft tissue injuries.² Ultrasonography has also been used in the diagnosis of Morel-Lavallée lesions because of its low cost and the allowance for dynamic imaging.² However, ultrasonography is highly operator dependent and cannot be performed on areas with open wounds.²

Once diagnosed, ED management should include consultation with a surgeon to determine best treatment strategies to prevent long-term sequelae. Currently no validated treatment algorithm exists for Morel-Lavallée lesions and treatment has been based upon surgeon preference, lesion size, and stage of the injury.⁵ Conservative management can include compression dressings or aspiration of fluid, while surgical options include open debridement, limited incision with drainage, and sclerodosis of the injury.⁵ Complications from the injury or procedure can present at any time during the patient's course and can include recurrence of the lesion, infection, necrosis, and contour deformities of the affected area.⁵

CONCLUSION

Morel-Lavallée lesions represent a rare but serious traumatic injury that could lead to devastating long-term morbidity. The emergency provider should be vigilant in his or her examination of all injured areas and obtain diagnostics studies coupled with surgical consultation to prevent long-term complications.

The authors attest that their institution requires neither Institutional Review Board approval, nor patient consent for publication of this case report. Documentation on file.

Address for Correspondence: John Ashurst, DO, MSc, Kingman Regional Medical Center, Department of Emergency Medicine, 3269 Stockton Hill Road, Kingman, AZ 86409. Email: Ashurst.john.32.research@gmail.com.

Conflicts of Interest: By the CPC-EM article submission agreement, all authors are required to disclose all affiliations, funding sources and financial or management relationships that could be perceived as potential sources of bias. The authors disclosed none.

Copyright: © 2020 Porter et al. This is an open access article distributed in accordance with the terms of the Creative Commons Attribution (CC BY 4.0) License. See: <http://creativecommons.org/licenses/by/4.0/>

REFERENCES

1. Moley EJ, Johnson S, Leibner E, et al. Emergency department evaluation and management of blunt chest and lung trauma. *Emerg Med Pract.* 2016;18(6):1-20.
2. Diviti S, Gupta N, Hooda K, et al. Morel-Lavallee lesions: review of pathophysiology, clinical findings, imaging findings and management. *J Clin Diagn Res.* 2017;11(4):TE01-4.
3. Falconi A, Crellin H, Tagawa C. A rare presentation of a Morel-Lavallee lesion of the lower leg successfully treated with ultrasound-guided aspiration. *Clin J Sport Med.* 2018;28(4):e87-8.
4. Nickerson TP, Zielinski MD, Jenkins DH, et al. The Mayo Clinic experience with Morel-Lavallee lesions: establishment of a practice management guideline. *J Trauma Acute Care Surg.* 2014;76(2):493-7.
5. Greenhill D, Haydel C, Rehman S. Management of the Morel-Lavallee lesion. *Orthop Clin N Am.* 2016;47(1):115-25.
6. Singh R, Rymer B, Youssef B, et al. The Morel-Lavallee lesion and its management: a review of the literature. *J of Orthop.* 2018;15(4):917-21.

A Case Report of Pulmonary Sarcoidosis: An Uncommon Cause of Chest Pain

Justina Truong, DO
John Ashurst, DO, MSc

Kingman Regional Medical Center, Department of Emergency Medicine, Kingman, Arizona

Section Editor: Rick A. McPheeters, DO

Submission history: Submitted May 18, 2020; Revision received July 6, 2020; Accepted July 3, 2020

Electronically published September 9, 2020

Full text available through open access at http://escholarship.org/uc/uciem_cpem

DOI: 10.5811/cpem.2020.7.48310

Introduction: Chest pain is one of the most common causes of emergency department visits on an annual basis and carries a high degree of morbidity and mortality if managed inappropriately.

Case Report: A 36-year-old male presented with four months of left-sided chest pain with dyspnea on exertion. Physical examination and laboratory values were within normal limits. Chest radiograph depicted diffuse interstitial nodular opacities throughout the lungs bilaterally with bilateral perihilar consolidations. Computed tomography of the chest demonstrated mid and upper lung nodularity with a perilymphatic distribution involving the central peribronchial vascular regions as well as subpleural and fissural surfaces causing conglomerate in the upper lobes centrally with associated hilar and mediastinal lymphadenopathy. The next day the patient underwent bronchoscopy with endotracheal ultrasound and transbronchial biopsies and pathology revealed non-necrotizing, well-formed granulomas embedded in dense hyaline sclerosis consistent with sarcoidosis.

Discussion: Sarcoidosis is a multi-system granulomatous disease characterized by noncaseating granulomas on pathology. The worldwide epidemiology of sarcoidosis is currently unknown due to many patients being asymptomatic. However, patients may present with a persistent cough, dyspnea, or chest pain. Emergency department management should be aimed at minimizing long-term sequelae of the disease through obtaining labs and imaging after specialist consultation and arranging urgent follow-up.

Conclusion: Although not one of the six high-risk causes of chest pain, sarcoidosis should be included in the differential to minimize the risk of long-term morbidity associated with advanced forms of the disease. [Clin Pract Cases Emerg Med. 2020;4(4):645–648.]

Keywords: *Chest pain; pulmonary sarcoidosis; sarcoidosis.*

INTRODUCTION

Chest pain is the second most common complaint seen by emergency care providers and accounts for 6.4 million visits annually.¹ Emergency clinicians must be able to differentiate the different causes of chest pain in order to minimize both acute and long-term morbidity and mortality. Although not normally a cause of short-term morbidity or mortality, pulmonary sarcoidosis should be considered as an acute cause of chest pain in the correct patient population and should be managed

aggressively to prevent long-term complications from the disease. We present a case of pulmonary sarcoidosis in a 36-year-old male that was managed with urgent consultations and procedures to minimize his risk of long-term complications.

CASE REPORT

A 36-year-old White male presented to the emergency department (ED) with a four-month history of left-sided chest pain with associated shortness of breath on exertion. He described

the pain as a dull ache that occurred at rest and was not worsened by exertion. He also noted a chronic dry cough that he had for the prior several years that was not associated with illness or exercise and a 12-pound weight loss over the previous month. Past medical history was noted for ureterolithiasis several years prior and he took no medications on a daily basis. His last purified protein derivative skin test was several months prior and was negative. He also denied ever smoking or a family history of autoimmune or inheritable disorders.

Upon arrival, his vital signs were all within normal limits and his examination exhibited only scant wheezes and coarse breath sounds in the left upper lobe. Egophony and whispered pectoriloquy were both negative in the concerned area. He also had no discernible skin lesions or clubbing.

Electrocardiogram showed a normal sinus rhythm with 82 beats per minute without any signs of ischemia. Laboratory testing including a complete blood count, complete metabolic profile, and troponin T test were all negative. Chest radiograph (CXR) demonstrated diffuse interstitial nodular opacities throughout the lungs bilaterally with bilateral perihilar consolidations that were worse on the left (Image 1). Computed tomography with intravenous contrast of the chest showed mid and upper lung nodularity with a perilymphatic distribution involving the central peribronchovascular regions as well as subpleural and fissural surfaces causing conglomerate in the upper lobes centrally (Image 2). There was also mild symmetric bilateral hilar and mediastinal lymphadenopathy.

After discussion with pulmonology, the differential included lymphoma, tuberculosis, fungal infections, and

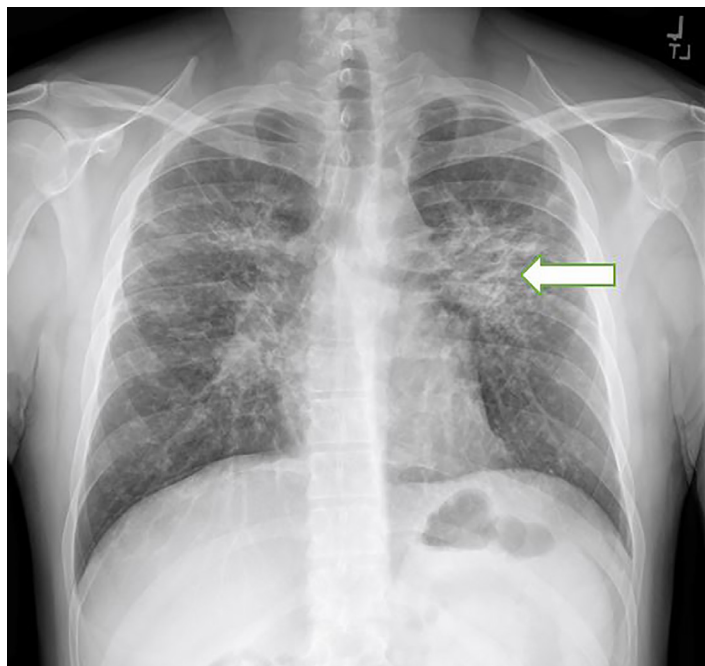


Image 1. Chest radiograph depicting diffuse interstitial nodular opacities throughout the lungs bilaterally with bilateral perihilar consolidations that were worse on the left (arrow).

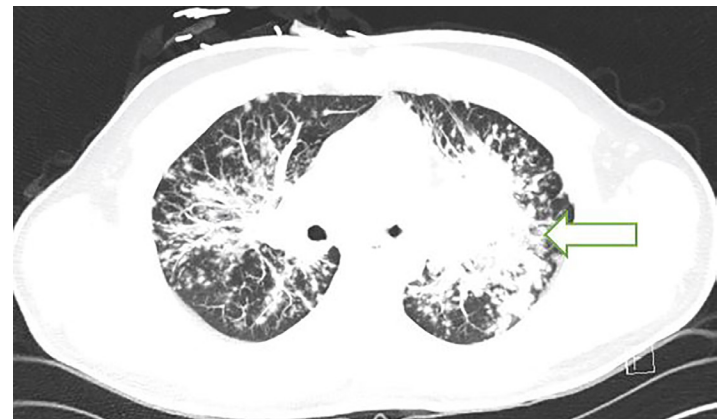


Image 2. Computed tomography of the chest with intravenous contrast depicting mid and upper lung nodularity with a perilymphatic distribution involving the central peribronchovascular regions as well as subpleural and fissural surfaces (arrow).

pulmonary sarcoidosis. The following day, the patient underwent bronchoscopy with endotracheal ultrasound and transbronchial biopsies. Bronchoalveolar lavage was negative for fungal infections, acid-fast bacilli, and malignant cells. Endobronchial biopsies revealed numerous non-necrotizing, well-formed granulomas embedded in dense hyaline sclerosis.

CPC-EM Capsule

What do we already know about this clinical entity?

Sarcoidosis is a multi-system granulomatous disease characterized by noncaseating granulomas that can acutely present with chest pain or dyspnea.

What makes this presentation of disease reportable?

Pulmonary sarcoidosis is an uncommon cause of chest pain seen by the emergency physician.

What is the major learning point?

Emergency department management should be aimed at specialty consultation with agreed upon follow-up to prevent long term sequelae.

How might this improve emergency medicine practice?

Although not one of the six high-risk causes of chest pain, pulmonary sarcoidosis should be in the differential to minimize the risk of long-term morbidity.

The patient was subsequently diagnosed with stage 3 pulmonary sarcoidosis and started on prednisone daily and sulfamethoxazole/trimethoprim three times a week for eight weeks. Following treatment, he had resolution in his symptoms.

DISCUSSION

Sarcoidosis is a multi-system, granulomatous disease without a known etiology. However, it is characterized by a T-helper cell response to CD-4 lymphocytes and activated macrophages that accumulate in the affected organs.² Most studies suggest that the pathogenesis is related to an exaggerated immune response to an environmental factor, microbe, or antigen in a genetically susceptible individual.³

Although the worldwide epidemiology of sarcoidosis is difficult to ascertain due to a large proportion of patients being asymptomatic, it has been estimated that 60 out of 100,000 adults in the United States will be affected by the disease.⁴ More than 80% of these cases will be diagnosed between the ages of 20-50 with a second peak in incidence between 50-65 years of life.^{2,3} Females, nonsmokers, and Blacks are more commonly diagnosed with the disease and 10% of cases will be familial.^{2,4} Mortality has been estimated at between 2-5% secondary to pulmonary complications, while morbidity can be substantial due to poor outcomes in chronic sarcoidosis.⁵

The onset and presentation of sarcoidosis varies widely depending on what organ system may be involved; so maintaining suspicion for this diagnosis is crucial. The lungs are the most commonly affected organ in the disease process, with more than 90% of patients exhibiting pulmonary symptoms.² The liver, spleen, bones, skin, heart, and nervous system may also be involved.^{2,3} Up to one third of patients are asymptomatic at their time of presentation with findings discovered incidentally.⁶

Clinical presentations most commonly include unexplained or persistent cough, dyspnea, or chest pain.^{6,7} Additional symptoms such as fever, erythema nodosum, and hilar lymphadenopathy (known as Löfgren syndrome) may be seen.^{3,4} Extrapulmonary findings such as hypercalcemia, nephrolithiasis, arthritis, and heart failure can be present and should warrant further investigation.⁶ Heerfordt-Waldenström syndrome is another classic syndrome of sarcoidosis that includes uveoparotid fever and facial nerve palsies.^{2,3}

Often, the diagnosis of sarcoidosis is not made until 3-6 months following the initial presentation.⁶ The three criteria for the diagnosis of sarcoidosis include compatible clinical and radiologic findings, histopathologic evidence of noncaseating granulomas, and exclusion of other disease processes.³ Laboratory studies should include a complete blood count, a metabolic panel to include creatinine and liver function testing, calcium levels in blood and urine, Vitamin D assays, and an angiotensin-converting enzyme level.³ Testing for the human immunodeficiency virus as well as tuberculosis should also be performed.³ CXR, computed tomography of the chest, flexible bronchoscopy with biopsies and

bronchioalveolar lavage, and pulmonary function testing should be performed in certain cases.³ CXR can show findings of lung involvement categorized into four stages based on the Scadding scale (Table).²

Table. Scadding scale for staging of pulmonary sarcoidosis.

Stage	Chest radiograph findings
I	Bilateral hilar lymphadenopathy
II	Pulmonary infiltrates and bilateral hilar lymphadenopathy
III	Pulmonary infiltrates
IV	Pulmonary fibrosis

Treatment for sarcoidosis is recommended for those with active disease and who are symptomatic.⁴ Those with stage I and who are asymptomatic need no treatment but do require annual follow-up.³ First-line treatment for those with symptomatic stages II or III is systemic corticosteroids and follow-up every three months.³ Corticosteroids are also recommended for those with serious extrapulmonary disease.³ Treatment with 20-40 milligrams of prednisone per day for four to six weeks and tapering slowly if condition improves is the mainstay of therapy.³ Response to treatment is monitored every three to six months using clinical response, pulmonary function testing, and CXR.^{3,7}

Methotrexate is the most common second-line agent for treatment of pulmonary sarcoidosis. Azathioprine, leflunomide, and the TNF-alpha inhibitor infliximab are reserved for those who cannot tolerate corticosteroids or those with refractory symptoms and disease progression.^{3,4} Those with severe pulmonary disease failing treatment or those progressing to pulmonary fibrosis in stage IV need prompt referral and evaluation for lung transplantation.³ Treatment is also aimed at regular screening for and treatment of complications such as cardiac sarcoidosis and heart disease as well as pulmonary hypertension.

Recurrence and relapse are common in those with pulmonary sarcoidosis.⁴ Those undergoing treatment with corticosteroids and immunosuppressive medications are at risk of the adverse effects such as diabetes mellitus, hypertension, and opportunistic infections such as pulmonary aspergillosis and *Pneumocystis jirovecii*.^{3,6} The most common cause of sarcoidosis-related death in the United States is respiratory failure related to pulmonary fibrosis.^{2,3,7} Pulmonary hypertension is likely to develop in those with severe pulmonary fibrosis and chronic forms of the disease, which is in itself an indicator for increased mortality and for lung transplantation.^{2,6}

CONCLUSION

Although emergency clinicians are trained in diagnosing and treating the deadly causes of chest pain, they must take

one step further when diagnosing a patient with a relatively low-risk disease from an emergency medicine perspective that carries a high degree of long-term morbidity. ED management should be aimed at proper specialty consultation with agreed upon follow-up in the symptomatic patient with consultation to specialties as needed.

The authors attest that their institution requires neither Institutional Review Board approval, nor patient consent for publication of this case report. Documentation on file.

REFERENCES

1. Jung J and Bord S. Emergency department management of non-ST-segment elevation myocardial infarction. *Emerg Med Pract.* 2020;22(1):1-24.
2. Bargagli E and Prasse A. Sarcoidosis: a review for the internist. *Intern Emerg Med.* 2018;13(3):325-31.
3. Soto-Gomez N, Peters JI, Nambiar AM. Diagnosis and management of sarcoidosis. *Am Fam Physician.* 2016;93(10):840-8.
4. Patterson KC and Chen ES. The pathogenesis of pulmonary sarcoidosis and implications for treatment. *Chest.* 2018;153(6):1432-42.
5. Gerke AK. Morbidity and mortality in sarcoidosis. *Curr Opin Pulm Med.* 2014;20(5):472-8.
6. Valeyre D, Bernaudin JF, Jeny F, et al. Pulmonary sarcoidosis. *Clin Chest Med.* 2015;36(4):631-41.
7. Kirkil G, Lower EE, Baughman RP. Predictors of mortality in pulmonary sarcoidosis. *Chest.* 2018;153(1):105-13.

Address for Correspondence: John Ashurst DO, MSc, Kingman Regional Medical Center, Department of Emergency Medicine, 3269 Stockton Hill Road, Kingman, AZ 86409. Email: Ashurst.john.32.research@gmail.com.

Conflicts of Interest: By the CPC-EM article submission agreement, all authors are required to disclose all affiliations, funding sources and financial or management relationships that could be perceived as potential sources of bias. The authors disclosed none.

Copyright: © 2020 Truong et al. This is an open access article distributed in accordance with the terms of the Creative Commons Attribution (CC BY 4.0) License. See: <http://creativecommons.org/licenses/by/4.0/>

Intracranial Air Embolism after Inferior Alveolar Nerve Block: A Case Report

Megan Gillespie, DO*†
Chad Gunsolly, DO*‡

*Jefferson Health - Northeast, Department of Emergency Medicine, Philadelphia, Pennsylvania
†Jefferson Health - Northeast, Department of Family Medicine, Philadelphia, Pennsylvania
‡Jefferson Health - Northeast, Department of Internal Medicine, Philadelphia, Pennsylvania

Section Editor: John Ashurst, DO

Submission history: Submitted May 25, 2020; Revision received July 2, 2020; Accepted July 3, 2020

Electronically published September 13, 2020

Full text available through open access at http://escholarship.org/uc/uciem_cpchem

DOI: 10.5811/cpcem.2020.7.48417

Introduction: The number of nontraumatic dental pain emergency department (ED) visits continues to substantially rise in frequency every year. While there are several methods for treating dental pain, an inferior alveolar nerve block (IANB) is a non-narcotic alternative that provides instantaneous relief of severe pain.

Case Report: A 59-year-old male presented to the ED from a dentist's office for evaluation of a right-sided headache with an associated episode of palpitations and near syncope that developed while receiving an inferior alveolar nerve block. Computed tomography of the patient's head revealed multiple small foci of air in the right temporalis muscle and in the intracranial venous drainage system. Given the patient's history of dental procedure, the intravascular introduction of air and local anesthetic was suspected.

Conclusion: Inferior alveolar nerve block procedures can have complications, including hematoma formation, trismus, facial palsy, needle breakage, and in this case, intravascular injection and cerebral air embolism. To perform a successful IANB, it is critical for providers to be familiar with anatomical landmarks and to consistently perform aspiration to confirm that needle placement is not intravascular. [Clin Pract Cases Emerg Med. 2020;4(4):649–652.]

Keywords: *inferior alveolar nerve block; intracranial air embolism.*

INTRODUCTION

Approximately two million patients present to the emergency department (ED) with dental complaints annually, which accounts for about 2% of total ED visits.¹ The inferior alveolar nerve block (IANB) is the most common injection technique used in dentistry and is a non-narcotic option for pain relief in the ED.² An analysis of 10.1 million dental complaint treatment plans from 2010-2013 from the National Ambulatory Medical Care Survey revealed that only 44% of patients received an analgesic while physically being in the ED.¹ Six percent of dental pain patients received an injection of local anesthetic in the ED, and 35% of dental pain patients received opioid medication.¹ The number of dental nerve blocks performed is expected to

continue to rise as a viable alternative treatment for dental pain during the current opioid epidemic.¹

CASE REPORT

A 59-year-old male with a past medical history of hypertension presented to the ED for evaluation of a right-sided headache with an episode of palpitations and near syncope that developed while receiving an IANB for a tooth extraction at a dentist's office. While his dentist was performing a dental block with lidocaine and epinephrine, he developed acute onset of severe right-sided headache accompanied by palpitations and near syncope with "trouble keeping his eyes open." The dental extraction procedure was aborted and he was brought to the ED. By the time the patient had arrived to the ED, his palpitations and

near syncopal episode had subsided, but his right-sided headache was persistent. The patient denied any other symptoms.

Vital signs at initial presentation included blood pressure of 190/80 millimeters of mercury; heart rate of 73 beats per minute; respiratory rate of 20 breaths per minute; pulse oximetry 96% on room air; and temperature of 98.4° Fahrenheit. Physical exam revealed a middle-aged man in moderate discomfort from pain. His head was normocephalic and atraumatic; no ecchymosis, erythema, or crepitus was noted on his jaw or neck. His pupils were 5 millimeters, equal, round, and reactive to light bilaterally, and without objective ptosis. Cranial nerves II-XII were intact and symmetrical bilaterally. He had 5/5 muscle strength in both the upper and lower extremities bilaterally and 2+ bilateral patella and Achilles deep tendon reflexes. The patient had no ataxia or pronator drift and had a normal finger to nose.

Initial laboratory studies included a basic metabolic panel, complete blood count, coagulation panel, thyroid stimulating hormone level, and troponin. None of these labs demonstrated any significant abnormalities. Twelve-lead electrocardiogram was noted to be normal sinus rhythm with a rate of 63 beats per minute with left axis deviation with high lateral T wave inversion, nonspecific ST changes in anterior leads with no change from previous. A chest radiograph was obtained and was without infiltrates or evidence of cardiomegaly.

Computed tomography (CT) of the head without intravenous (IV) contrast revealed multiple small foci of air predominantly in the expected region of the intracranial venous drainage system (Images 1 and 2). Multiple small foci of air were also noted in the right temporalis muscle. Given the patient's history of dental procedure the possibility of intravascular introduction of air and local anesthetic was raised (Image 1). There was no evidence of hemorrhage or acute territorial infarction or mass.

Given the findings on the CT head, a dedicated CT neck with IV contrast was performed and showed residual punctate foci of gas in the left transverse sinus and posterior right cavernous sinus. Most of the previously seen bilateral cavernous sinus gas noted on CT of the head was not present on CT neck with IV contrast. The CT neck with IV contrast also reported that the patient was noted to have tortuosity of the extracranial internal carotid arteries with a short segment of the retropharyngeal course at the level of the hypopharynx.

The patient was admitted to the intensive care unit for continued neurologic and cardiovascular monitoring after discovering the findings of intracranial venous air embolism and air near the carotid sheath on CT from suspected intravascular injection of local anesthetic. While hospitalized, the patient's headache completely resolved. The patient had a repeat CT of his head and neck 24 hours later with near-total resolution of the previously noted gas in the cavernous sinus region and no acute intracranial infarct or hemorrhage. Neurology evaluated the patient and recommended no additional imaging as repeat CT demonstrated resolution of previously noted venous gas foci, and recommended symptomatic treatment of headache if

CPC-EM Capsule

What do we already know about this clinical entity?

Inferior alveolar nerve block (IANB) is a non-narcotic intervention that provides instantaneous relief of severe dental pain.

What makes this presentation of disease reportable?

Inferior alveolar nerve block in this case was complicated by intravascular injection of lidocaine with epinephrine and subsequent cerebral air embolism.

What is the major learning point?

For successful nerve blocks, be familiar with anatomical landmarks and consistently perform aspiration to confirm needle placement is not intravascular.

How might this improve emergency medicine practice?

This case will inform emergency providers of symptoms and management for intracranial air embolism after IANB.

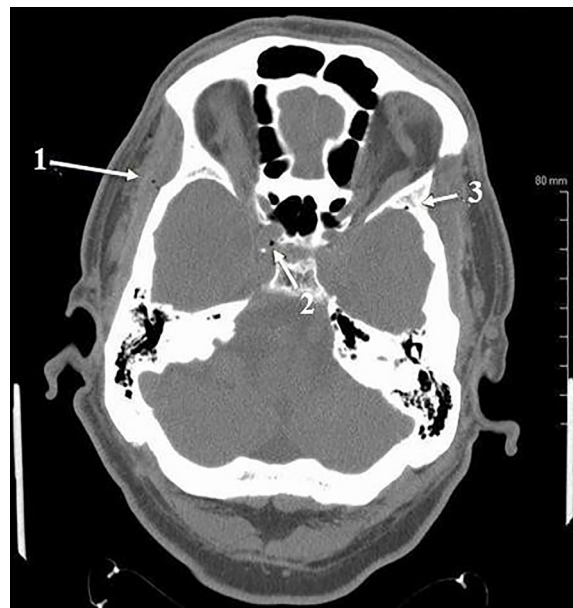


Image 1. Intracranial air noted on patient's computed tomography of the head. Arrow 1 indicates multiple foci of air within the right temporalis muscle. Arrow 2 indicates a focus of gas within the cavernous sinus, part of the intracranial venous drainage system. Arrow 3 indicates focus of gas within the sphenoparietal sinus, also part of the intracranial venous drainage system.

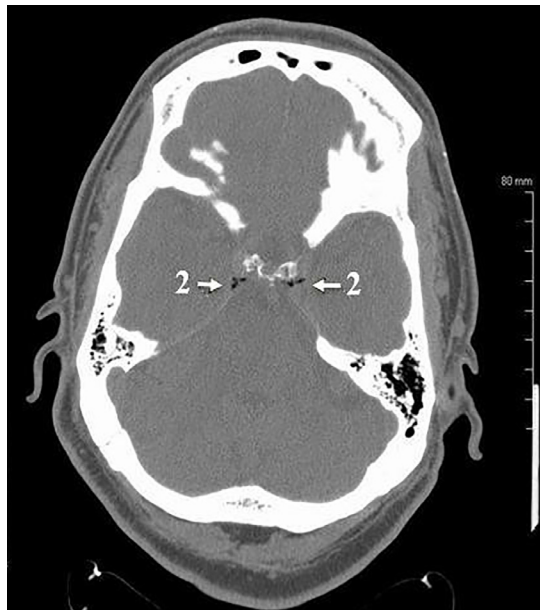


Image 2. Intracranial air noted on patient's computed tomography of the head. The arrows marked with 2 indicate multiple foci of gas within the cavernous sinus, part of the intracranial venous drainage system.

symptoms recurred. The patient was discharged that next day with completely resolved symptoms.

DISCUSSION

Experienced providers perform successful IANBs with familiarity of the anatomical landmarks for both the conventional and modified nerve blocking techniques.² The most important clinical landmarks for IANB needle insertion are the coronoid notch and the pterygomandibular raphe.² The needle is inserted into the highly vascular pterygomandibular triangle until bony resistance is felt, and then the needle is minimally withdrawn 1-2 mm. It is then critical to perform aspiration to confirm placement of needle is not intravascular.² Aspirations positive for blood, indicating intravascular placement, are documented to occur about 15% of the time during IANB procedures, the highest frequency of positive aspirations of all intraoral injections.^{3,4}

The recommended local anesthetic for IANB is 1.8 cubic centimeters of 2% lidocaine with epinephrine +/- bupivacaine for longer duration.⁵ As was the concern for the patient in this case report, one of the potential complications for IANB is the accidental injection of lidocaine with epinephrine into the carotid sheath because of its close anatomical proximity to the pterygomandibular triangle. High-dose or accidental intravascular injection of local anesthetic with vasoconstrictor may result in cardiovascular or central nervous system toxicity with predominant symptoms of hypertension, tachycardia, tachypnea, syncope and/or vertigo, and more infrequent symptoms such as tonic-clonic seizures or diplopia.⁵⁻⁸

Another potential complication of an IANB is intracranial air embolism. Cerebral arterial gas embolism may cause sudden

development of symptoms that range from minor motor weakness and headache to complete disorientation, hemiparesis, convulsions, loss of consciousness, and coma.⁹⁻¹¹ Even small amounts of gas entering the arterial system can occlude functional end arteries.⁹⁻¹¹ Seizures caused by arterial gas emboli typically do not respond to benzodiazepines. Barbiturates can be used instead of benzodiazepines, but ultimately the treatment goal for seizures caused by arterial gas emboli is to reduce the size of the gas emboli. Ways to reduce the size of arterial gas emboli include placing the patient in Trendelenburg or left lateral decubitus position, administering 100% supplemental oxygen, and coordinating initiation of hyperbaric oxygen, which is the first-line treatment of choice.^{10,12,13} Cerebral venous air emboli have a natural tendency to dissolve in flowing blood, but persistent cerebral venous air embolism can result in stasis and venous infarction.^{14,15}

CONCLUSION

Inferior alveolar nerve blocks are a non-narcotic alternative for providing relief to patients who present to the ED with dental pain and are a very common outpatient procedure performed by dentists for anesthesia prior to office procedures. However, IANB procedures can have complications, including hematoma formation, trismus, facial palsy, needle breakage, and in this case, intravascular injection and cerebral air embolism. Frequent review of anatomical landmarks, familiarity with both conventional and modified nerve blocking techniques, and consistent aspiration prior to injection with every IANB procedure will help set the provider up for success in creating analgesia and anesthesia while avoiding complications. Emergency providers should be aware of potential complications from inferior alveolar nerve blocks to allow prompt recognition and proper treatment.

The authors attest that their institution requires neither Institutional Review Board approval, nor patient consent for publication of this case report. Documentation on file.

Address for Correspondence: Megan Gillespie, MD, Jefferson Health - Northeast, Department of Emergency Medicine, Graduate Medical Education Office, % Mary Allegrini, 10800 Knights Road, Philadelphia, PA 19114. Email: megan.gillespie@jefferson.edu.

Conflicts of Interest: By the *CPC-EM* article submission agreement, all authors are required to disclose all affiliations, funding sources and financial or management relationships that could be perceived as potential sources of bias. The authors disclosed none.

Copyright: © 2020 Gillespie et al. This is an open access article distributed in accordance with the terms of the Creative Commons Attribution ([CC BY 4.0](http://creativecommons.org/licenses/by/4.0/)) License. See: <http://creativecommons.org/licenses/by/4.0/>

REFERENCES

1. Singer AJ, Morris M, Wright J, et al. Management of dental pain in the emergency department. *Ann Emerg Med.* 2017;70(4):S83-4.
2. Khalil H. A basic review on the inferior alveolar nerve block techniques. *Anesth Essays Res.* 2014;8(1):3-8.
3. Zenouz AT, Ebrahimi H, Mahdipour M, et al. The incidence of intravascular needle entrance during inferior alveolar nerve block injection. *J Dent Res Dent Clin Dent Prospects.* 2008;2(1):38-41.
4. Reed KL, Malamed SF, Fonner AM. Local anesthesia part 2: technical considerations. *Anesth Prog.* 2012;59(3):127-37.
5. Becker DE and Reed KL. Local anesthetics: review of pharmacological considerations. *Anesth Prog.* 2012;59(2):90-102.
6. Lustig JP and Zusman SP. Immediate complications of local anesthetic administered to 1,007 consecutive patients. *J Am Dent Assoc.* 1999;130(4):496-9.
7. Bader JD, Bonito AJ, Shugars DA. Summary, Evidence Report/ Technology Assessment Number 48: Cardiovascular effects of epinephrine in hypertensive dental patients: summary. *Agency for Healthcare Research and Quality.* Rockville, MD: AHRQ. 2002. Available at: <https://www.ncbi.nlm.nih.gov/books/NBK11858/>. Accessed May 20, 2020.
8. American Academy of Pediatric Dentistry. Use of local anesthesia for pediatric dental patients. *The Reference Manual of Pediatric Dentistry, Best Practices: Use of Local Anesthesia: American Academy of Pediatric Dentistry.* 2015:286-92.
9. Muth CM and Shank ES. Gas embolism. *N Engl J Med.* 2000;342(7):476-82.
10. Tovar EA, Del Campo C, Borsari A, et al. Postoperative management of cerebral air embolism: gas physiology for surgeons. *Ann Thorac Surg.* 1995;60(4):1138-42.
11. Gordy S and Rowell S. Vascular air embolism. *Int J Crit Illn Inj Sci.* 2013;3(1):73-6.
12. Magni G, Imperiale C, Rosa G, et al. Nonfatal cerebral air embolism after dental surgery. *Anesth Analg.* 2008;106(1):249-51.
13. Jensen ME and Lipper MH. CT in iatrogenic cerebral air embolism. *AJNR Am J Neuroradiol.* 1986;7(5):823-7.
14. Schlimp CJ, Bothma PA, Brodbeck AE. Cerebral venous air embolism: what is it and do we know how to deal with it properly? *JAMA Neurol.* 2014;71(2):243.
15. Bothma PA and Schlimp CJ. Retrograde cerebral venous gas embolism: Are we missing too many cases? *Br J Anaesth.* 2014;112(3):401-4.

Miller-Fisher Syndrome: A Case Report and Review of the Literature

Justina Truong, DO
Jeff Conley, MD
John Ashurst, DO, MSc

Kingman Regional Medical Center, Department of Emergency Medicine, Kingman, Arizona

Section Editor: Rick A. McPheeters, DO

Submission history: Submitted May 31, 2020; Accepted July 16, 2020

Electronically published September 9, 2020

Full text available through open access at http://escholarship.org/uc/uciem_cpccem

DOI: 10.5811/cpcem.2020.7.48507

Introduction: Neurological complaints are a common presenting symptom seen by the emergency physician. However, the Miller-Fisher variant of Guillain-Barré syndrome is a rare cause of neurological complaints seen in the emergency department.

Case Report: A 26-year-old male presented with dysphonia and bilateral hand and feet paresthesia after a recent diarrheal illness. Examination revealed the absence of tricep, brachioradialis, patellar and Achilles tendon reflexes bilaterally, and difficulty with phonation. Lumbar puncture revealed the presence of anti-GQ1b antibodies, and the patient was diagnosed with Miller-Fisher variant of Guillain-Barré.

Discussion: Miller-Fisher syndrome is an acute, autoimmune response that typically follows either an upper respiratory or diarrheal illness. Typically associated with dysfunction of cranial nerves three, four, and six, Miller-Fisher syndrome may present with facial paralysis, ophthalmoplegia, areflexia, or ataxia. Lumbar puncture with the presence of anti-GQ1b antibodies is indicative. Treatment could include supportive respiratory care, intravenous immunoglobulin therapy, or plasmapheresis.

Conclusion: Miller-Fisher syndrome is a rare form of Guillain-Barré syndrome that the emergency provider should include in the differential when faced with a patient with cranial nerve dysfunction. [Clin Pract Cases Emerg Med. 2020;4(4):653–655.]

Keywords: *Miller-Fisher syndrome; Guillain-Barré syndrome; neurological emergencies.*

INTRODUCTION

Neurological conditions account for approximately 5% of all emergency department (ED) visits annually and mostly include the diagnoses of headache, dizziness, weakness, and seizures.¹ Rarely, however, does the emergency provider evaluate a patient with either bilateral descending paralysis or ophthalmoplegia. Miller-Fisher syndrome, a variant of Guillain-Barré syndrome, is characterized by the triad of areflexia, ataxia, and ophthalmoplegia and can rapidly progress to respiratory

failure.² We present a case of Miller-Fisher syndrome in a 26-year-old male following a diarrheal illness.

CASE REPORT

A 26-year-old male presented to the ED due to four days of progressive changes in his voice with associated paresthesia in his hands and feet. He stated that when he drank liquids he had difficulty swallowing and had reflux of liquids out of his nasal passage. He did report a recent trip to India followed by several days of diarrhea, which had

resolved several weeks earlier. He also noted difficulty with his vision but denied any weakness, difficulty with ambulation, or recent upper respiratory tract infections. His past medical history was negative, and he took no medications on a daily basis.

Physical examination revealed a healthy appearing male in no acute distress. When attempting to phonate, he had decreased motion of the soft palate and pooling of saliva in the oropharynx. His voice was markedly altered when asked to phonate. Neurologic exam revealed 5/5 muscle strength in the upper and lower extremities but absent triceps, brachioradialis, patellar and Achilles tendon reflexes. Subjective paresthesias were also noted in the hands and feet bilaterally with difficulty discriminating two points.

Complete blood count, basic metabolic profile, and magnesium levels were all normal. Computed tomography of the head was also without abnormality. The patient underwent lumbar puncture and was found to have a glucose of 56 milligrams per deciliter (mg/dL) (reference range 40-70 mg/dL), protein 25 mg/dL (reference range 15-45 mg/dL), and no bacterial growth on culture, but he had a positive anti-GQ1b antibody consistent with Guillain-Barré syndrome. Based upon his symptoms and clinical findings he was diagnosed with the Miller-Fisher variant of Guillain-Barré. He subsequently underwent intravenous (IV) immunoglobulin G (IgG) therapy and had complete resolution of his symptoms after six days of treatment.

DISCUSSION

First described in 1984 by Phillips and Anderson, Miller-Fisher syndrome is a rare variant of Guillain-Barré syndrome and accounts for between 1-5% of all cases in western countries but 15-25% of all cases in Asia.^{2,3} With a mean age of onset of 43.6 years, Miller-Fisher syndrome affects males twice as frequently as females annually.^{2,3} Typically preceded by either an upper respiratory or diarrheal infection, the disease has been associated with the cytomegalovirus, Epstein-Barr virus, and *Campylobacter jejuni*.^{3,4}

Although presentation can vary, the majority of patients will present with a form of distal paresthesia coupled with dysfunction of the cranial nerves.^{3,4} The classic triad of areflexia, ataxia, and ophthalmoplegia is not seen in every patient and is dependent upon the course and duration of illness.^{3,4} Neurologic symptoms typically will not present until 8-10 days following an illness and nadir six days following the initial presentation.⁵ Physical examination may reveal facial paresis, distal hyporeflexia and loss of vibratory and light-touch sensation in the distal extremities.³⁻⁵ Bilateral dilated pupils and pharyngeal involvement may also occur in patients with Miller-Fisher syndrome in the absence of other neurologic symptoms.⁵

Although the clinical features are indicative of the disease, lumbar puncture can further aid the emergency provider. The combination of a normal cell count with increased protein in the cerebral spinal fluid is classic, but normal protein levels do not

CPC-EM Capsule

What do we already know about this clinical entity?

Miller-Fisher syndrome is a variant of Guillain-Barré syndrome that presents with distal paresthesia coupled with dysfunction of the cranial nerves.

What makes this presentation of disease reportable?

Although presenting after a diarrheal illness, the patient did not have the classic triad of areflexia, ataxia, and ophthalmoplegia on examination.

What is the major learning point?

Miller-Fisher syndrome is diagnosed by the presence of immune globulin G autoantibodies to GQ1b in the cerebral spinal fluid and treatment includes intravenous immunoglobulin and plasma exchange therapy.

How might this improve emergency medicine practice?

A high index of suspicion and early respiratory support can prevent long term sequelae from complications associated with Miller-Fisher syndrome.

essentially rule out the disease.³ The presence of IgG autoantibodies to GQ1b in the cerebral spinal fluid is strongly associated with Miller-Fisher syndrome and should be obtained to further aid the clinician to rule in or out the diagnosis.

ED management should be aimed at symptomatic care and respiratory support if needed. IV and oral steroids are no longer recommended in the course therapy and may actually slow recovery. IV immunoglobulin and plasma exchange therapy are now the standard of care for those with Miller-Fisher syndrome. Following treatment, the mortality is less than 5%, but recurrence of the disease can occur between 5-10% of the time.

CONCLUSION

Although rarely seen by the emergency care provider, Miller-Fisher syndrome should be included in the differential diagnosis of patients who present with cranial nerve dysfunction or descending paralysis following a recent illness. When considered, lumbar puncture should be performed in the ED and treatment should be initiated after consultation with neurology to prevent progression of the disease.

The Institutional Review Board approval has been documented and filed for publication of this case report.

Address for Correspondence: John Ashurst DO, MSc, Kingman Regional Medical Center, Department of Emergency Medicine, 3269 Stockton Hill Road, Kingman, AZ 86409. Email: Ashurst.john.32.research@gmail.com.

Conflicts of Interest: By the CPC-EM article submission agreement, all authors are required to disclose all affiliations, funding sources and financial or management relationships that could be perceived as potential sources of bias. The authors disclosed none.

Copyright: © 2020 Truong et al. This is an open access article distributed in accordance with the terms of the Creative Commons Attribution (CC BY 4.0) License. See: <http://creativecommons.org/licenses/by/4.0/>

REFERENCES

1. Pope J and Edlow J. Avoiding misdiagnosis in patients with neurological emergencies. *Emerg Med Int.* 2012;2012(7):949-275.
2. Kozminski MP. Miller Fisher variant of Guillain-Barre syndrome: a report of case. *J Am Osteopath Assoc.* 2008;108(2):51-2.
3. Willison HJ, Jacobs BC, van Doorn PA. Guillain-Barre syndrome. *Lancet.* 2016;388(10045):717-27.
4. Yuki N and Hartung H. Guillain-Barre syndrome. *N Engl J Med.* 2012;366(24):2294-304.
5. Othman B, Raabe J, Kini A, et al. Update: the Miller Fisher variants of Guillain-Barre syndrome. *Curr Opin Ophthalmol.* 2019;30(6):462-6.

Appropriate Evaluation of Psychiatric Patients Highlighted by Creutzfeldt-Jakob Disease: A Case Report

Kathryn Bartlett, DO*
Kathleen E. Kane, MD*†
Bryan G. Kane, MD*†
Kevin R. Weaver, DO*†
Gavin C. Barr, MD*†

*Lehigh Valley Hospital and Health Network, Department of Emergency Medicine, Allentown, Pennsylvania

†University of South Florida Morsani College of Medicine, Department of Emergency Medicine, Tampa, Florida

Section Editor: John Ashurst, DO, MSc

Submission history: Submitted March 24, 2020; Revision received July 21, 2020; Accepted July 21, 2020

Electronically published September 3, 2020

Full text available through open access at http://escholarship.org/uc/uciem_cpem

DOI: 10.5811/cpem.2020.7.47384

Introduction: Determination of medical stability for patients presenting with psychiatric complaints is common for emergency clinicians. A thorough history and physical examination is important.

Case Report: A 53-year-old male presented to the emergency department (ED) with depression, suicidal ideation, and decline in activities of daily living over six months. While his initial neurologic examination was non-focal, subsequent re-evaluations demonstrated significant changes, and he was ultimately diagnosed with Creutzfeldt-Jakob disease.

Conclusion: This case demonstrates how a detailed history of the present illness could have led to a more accurate and timely medical disposition from the ED. [Clin Pract Cases Emerg Med. 2020;4(4):656–659.]

Keywords: *Creutzfeldt-Jakob disease; psychiatric evaluation.*

INTRODUCTION

The incidence of psychiatric concerns as chief complaints to the emergency department (ED) approaches 10%.¹ Psychiatric patients have a higher incidence of morbidity and mortality than the general population; so it is important to use the ED encounter to ensure proper disposition and treatment.² The history and physical examination are essential in the determination of medical stability prior to a psychiatric admission. Many medical conditions, including thyroid disorders, cerebrovascular accident, and dementia can have presentations that either manifest psychiatric symptoms or mimic psychiatric illness. This case of Creutzfeldt-Jakob disease (CJD) highlights several key points missed within the initial history and physical exam that, if identified in the ED, should have led to additional medical evaluation. While ultimately not changing the outcome, earlier identification would have expedited appropriate disposition of the patient. This case also

highlights how an appreciation for several types of cognitive error can improve patient care.

CASE REPORT

A 53-year-old, disheveled male presented to the ED with complaints of anxiety and depression with concomitant suicidal ideation. The patient noted worsening depression over the prior four to six months. His anxiety and depression led him to quit his job of 28 years as a bakery manager due to the inability to concentrate or follow directions. He attributed this to his worsening depression. The patient quit driving six days prior to presentation after an episode of forgetfulness caused him to run off the road. Review of systems revealed intermittent chest pain as well as decreased appetite and a 20-pound unintentional weight loss in the preceding several months, which the patient attributed to overwhelming anxiety. His wife also described multiple episodes in which he would blankly stare at nothing for seconds before returning to baseline.

The patient had a history of depression for many years prior to this presentation. However, the patient had never considered suicide or had difficulty with activities of daily life (ADL) prior to the last four months. His primary care physician documented normal physical examinations on an office visit within the prior month for depression and anxiety. His sertraline dose was increased by his primary care physician without improvement in symptoms.

In the ED, the patient's physical examination was remarkable only for slow, tangential speech with repetitive answers. Initial laboratory testing, including toxicology, was unremarkable. Due to his chest discomfort at initial presentation, two serial troponins were obtained before deeming the patient medically stable. He signed a voluntary commitment for psychiatric treatment and was admitted to the behavioral health unit. On the inpatient psychiatric unit, the patient continued with depression and anxiety. While he no longer felt suicidal, he developed significant paranoia. His inattention worsened and he became increasingly disoriented. His speech, while slow, remained clear. However, despite several trials of antidepressants and antipsychotics, his symptoms persisted.

Due to the progression of his symptoms over several weeks, the patient was reevaluated medically. It was felt that his neurologic status was related to his psychiatric illness. Several days later, he developed brief episodes of an arm drop, as well as frequent staring episodes. At that point, neurologic consultation discovered deterioration when compared to previous neurologic examination. His speech was now solely confabulation. While strength and sensation remained intact, the patient now had mildly increased tone. Magnetic resonance imaging (MRI) of his brain, with and without contrast, a lumbar puncture (LP), and an electroencephalogram (EEG) were obtained.

MRI with diffusion-weighted imaging demonstrated high signal intensity/restricted diffusion in bilateral cerebral cortices and basal ganglia. As depicted in the image, the abnormality was more pronounced in the right hemisphere.

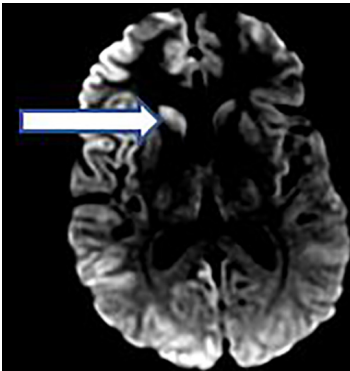


Image. A single, magnetic resonance imaging slice of diffusion-weighted imaging of the patient's brain. The image shows high-intensity signaling in the right basal ganglia, indicated by the arrow. The high-intensity signaling in the right basal ganglia is consistent with Creutzfeldt-Jacob disease.

CPC-EM Capsule

What do we already know about this clinical entity?

While guidelines for evaluation of psychiatric complaints exist, it is imperative to reevaluate patients with persistent progression of symptoms despite treatment.

What makes this presentation of disease reportable?

Nearly a third of patients with Creutzfeldt-Jacob Disease present with psychiatric complaints.

What is the major learning point?

Significant loss of daily life activities, neurologic findings on examination and changes in examinations should prompt a thorough medical work up.

How might this improve emergency medicine practice?

A thoughtful evaluation of patients presenting with psychiatric complaints will provide best practice patient care and ensure appropriate resource utilization.

Such findings can be seen with CJD, encephalitis, toxic/metabolic processes, and ischemic injury.

The EEG demonstrated slowing over the right hemisphere with anterior rhythmic slowing consistent with a diffuse encephalopathy. Cerebrospinal fluid (CSF) evaluation demonstrated large amounts of T-tau protein and was positive for CJD protein 14-3-3. These test results confirmed the diagnosis of CJD. The patient continued to decline cognitively; he was transitioned to hospice care and expired within one month of initial presentation to the ED.

DISCUSSION

The history of present illness (HPI) and physical examination are the most important aspects of assessing medical stability of a psychiatric patient.³ Physicians must avoid anchoring, confirmation bias, and diagnosis momentum when evaluating patients presenting with psychiatric complaints. Anchoring bias is the failure to adjust decision-making process in the light of new information.⁴ Confirmation bias is the tendency to seek out information that supports the initial presumption, rather than to refute the initial thought.⁴ Diagnostic momentum exists when a label is placed on a patient or presentation,

regardless of who places the label or how much information they have in support of that label.⁴ In this case, in addition to the HPI, the final diagnosis of CJD was made with MRI, EEG, and CSF analysis. CJD can be diagnosed as sporadic, familial, or iatrogenic.⁵ Sporadic is the most common type with typical age of onset at 60.⁵ The figure presents additional diagnostic detail regarding diagnostic criteria of CJD.⁶ A variant clinical presentation of CJD is characterized by psychiatric symptoms at an earlier stage

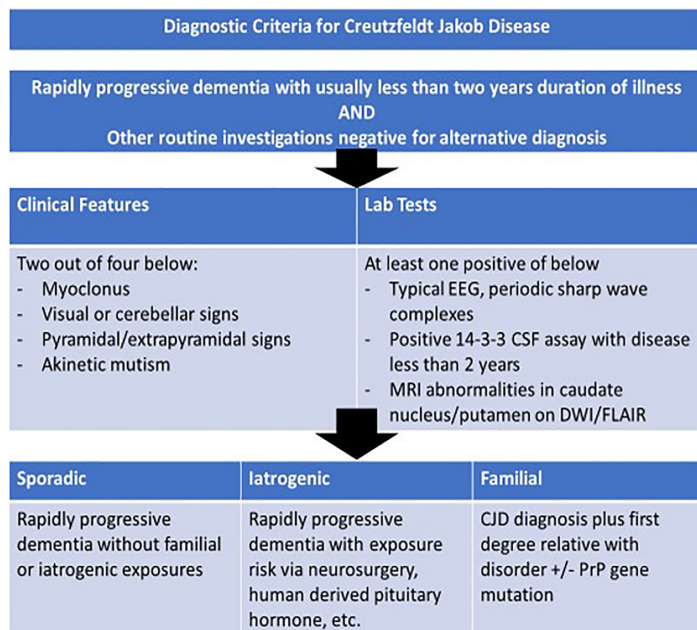


Figure. The diagnostic criteria for Creutzfeldt-Jakob disease.⁹ Amended from Centers for Disease Control and Prevention diagnostic criteria. EEG, electroencephalogram; CSF, cerebrospinal fluid; MRI, magnetic resonance imaging; DWI, diffusion-weighted imaging; FLAIR, fluid attenuated inversion recovery.

with longer clinical deterioration and death at a younger age.⁵ Nearly one third of cases of variant CJD initially present with depression, emotional lability, behavioral changes, loss of appetite, and insomnia.^{7,8}

In the case presented, rapid loss of ADLs and markedly worsening depression should have led to a broader differential diagnosis and expedited the patient’s disposition and care. The differential diagnosis for rapidly progressive dementia includes, but is not limited to, heavy metal toxicity, thyroid disorders, autoimmune disorders, vasculitis, sarcoidosis, viral or bacterial encephalopathies, and vitamin deficiencies, as well as CJD.^{6,10} While CJD will rarely be diagnosed in the ED, it is important to note the progressive decline presented in the HPI and to begin the appropriate medical evaluation.^{6,8}

When evaluating a patient with rapidly progressive dementia, the work-up should include a complete blood count, comprehensive metabolic panel, thyroid function, and computed tomography of the brain. In consultation with neurology, other diagnostic studies may be warranted, including serology for neurosyphilis, paraneoplastic antibodies, or limbic encephalitis.¹¹ In a prospective study of more than 500 patients with psychiatric illnesses, nearly 20% of the patients’ psychiatric illnesses could be attributed to medical ailments.¹²

MRI is more than 90% sensitive in the diagnosis of sporadic CJD.⁷ MRI images from patients with CJD often display patchy and extensive anomalies in more than one cortical region.⁷ Importantly, appropriate personal protective equipment (PPE) should be worn when performing an LP on someone suspected of having CJD. Ideally, disposable items should be used when collecting the CSF fluid; these should be incinerated as to avoid transmission of the prion protein.¹³ WHO guidelines on PPE for procedures provide a valuable resource for clinicians evaluating patients with suspected prion protein disease.¹³

CJD symptoms are caused by an abnormal accumulation and/or metabolism of prion proteins. The mutation in the prion protein results in the production of protease-resistant prion proteins, which cause nerve damage resulting in a variety of clinical presentations of the disease.⁶ For most patients diagnosed with CJD, rapid clinical progression from normal functioning to death occurs in approximately one year.⁶ CJD is ultimately fatal in all cases.⁶

CONCLUSION

As the 2017 American College of Emergency Physicians clinical policy acknowledges, no laboratory or imaging studies are currently available to definitely and rapidly obviate all medical illnesses in psychiatric patients from the ED.² Further supporting this is the 2017 American Association for Emergency Psychiatry comments that a thorough history and physical, including vital signs and a mental status examination, are of paramount importance when determining medical stability for patients with psychiatric illnesses.¹⁴ In the case presented, rapid loss of ADLs with behavioral changes should have increased the clinicians’ suspicion for a medical etiology. Further medical testing was indicated prior to determination of medical stability and admission to the behavioral health unit. This case highlights that recognition of concerning findings within the HPI and physical examination, as well as appreciation for minimization of cognitive bias, are important for identification of medical illnesses associated with psychiatric presentations and are necessary for appropriate disposition and treatment.

The authors attest that their institution requires neither Institutional Review Board approval, nor patient consent for publication of this case report. Documentation on file.

Address for Correspondence: Kathryn Bartlett, DO, Lehigh Valley Hospital and Health Network, Department of Emergency Medicine, 2545 Schoenersville Road, 5th Floor Emergency, Emergency Medicine Suite, Bethlehem, PA 18017. Email: Kathryn.Bartlett@lvh.com.

Conflicts of Interest: By the CPC-EM article submission agreement, all authors are required to disclose all affiliations, funding sources and financial or management relationships that could be perceived as potential sources of bias. The authors disclosed none.

Copyright: © 2020 Bartlett et al. This is an open access article distributed in accordance with the terms of the Creative Commons Attribution (CC BY 4.0) License. See: <http://creativecommons.org/licenses/by/4.0/>

REFERENCES

1. Santillanes G, Axeen S, Lam CN, et al. National trends in mental health-related emergency department visits by children and adults 2009-2015. *Am J Emerg Med.* 2019;S0735-6757(19):30842-3.
2. Felker B, Yazel JJ, Short D. Mortality and medical comorbidity among psychiatric patients: a review. *Psychiatr Serv.* 1996;47(12):1356-63.
3. Nazarian DJ, Broder JS, Thiessen MEW, et al. Clinical policy: critical issues in the diagnosis and management of the adult psychiatric patient in the emergency department. *Ann Emerg Med.* 2017;69(4):480-98.
4. Daniel M, Khandelwal S, Santen SA, et al. Cognitive debiasing strategies for the emergency department. *AEM Educ Train.* 2017;1(1):41-2.
5. National Institute of Neurological Disorders and Stroke website. Creutzfeldt-Jakob Disease fact sheet. 2018. Available at: <https://www.ninds.nih.gov/Disorders/Patient-Caregiver-Education/Fact-Sheets/Creutzfeldt-Jakob-Disease-Fact-Sheet>. Accessed March 23, 2020.
6. Gencer AG, Pelin Z, Kucukali CI, et al. Creutzfeldt-Jakob disease. *Psychogeriatrics.* 2011;11(2):119-24.
7. Cambier DM, Kantarci K, Worrell GA, et al. Lateralized and focal clinical, EEG, and FLAIR MRI abnormalities in Creutzfeldt-Jakob disease. *Clin Neurophysiol.* 2003;114(9):1724-8.
8. Miyake K, Hara T, Oshima E, et al. Creutzfeldt-Jakob disease with Alzheimer pathology, presenting with status epilepticus following repeated partial seizures: a case report and literature review. *BMC Neurol.* 2018;18(1):54.
9. Centers for Disease Control and Prevention (CDC). Diagnostic criteria: Creutzfeldt-Jakob disease, classic (CJD): Prion Disease. 2018. Available at: <https://www.cdc.gov/prions/cjd/index.html>. Accessed December 30, 2019.
10. Mead S and Rudge P. CJD mimics and chameleons. *Pract Neurol.* 2017;17(2):113-21.
11. Rosenbloom MH and Atri A. The evaluation of rapidly progressive dementia. *Neurologist.* 2011;17(2):67-74.
12. Black DW, Warrack G, Winokur G. The Iowa record-linkage study. I. Suicides and accidental deaths among psychiatric patients. *Arch Gen Psychiatry.* 1985;42(2):71-75.
13. Centers for Disease Control and Prevention (CDC). Iatrogenic transmission of CJD: Creutzfeldt-Jakob disease, classic (CJD): Prion disease. 2019. Available at: <https://www.cdc.gov/prions/cjd/infection-control.html>. Accessed December 30, 2019.
14. Wilson MP, Nordstrom K, Anderson EL, et al. American Association for Emergency Psychiatry Task Force on Medical Clearance of Adult Psychiatric Patients. Part II: controversies over medical assessment, and consensus recommendations. *West J Emerg Med.* 2017;18(4):640-6.

Pulmonary Embolism Presenting as an Anterior ST-elevation Myocardial Infarction: A Case Report

Varvara Ladage, DO*

Miciah Jones, DO†‡

Faheem Ahmad, MD†

Cherian Plamoottil, DO*

Ryan Misek, DO‡

Nicole Alexander-Anyaogu, DO, MS§

*Midwestern University Chicago College of Osteopathic Medicine, Department of Emergency Medicine, Downers Grove, Illinois

†Franciscan Health Olympia Fields, Department of Cardiology, Olympia Fields, Illinois

‡Midwestern University Chicago College of Osteopathic Medicine, Department of Clinical Education, Downers Grove, Illinois

§Franciscan Health Olympia Fields, Department of Emergency Medicine, Olympia Fields, Illinois

Section Editor: John Ashurst, DO, MSc

Submission history: Submitted May 30, 2020; Revision received July 17, 2020; Accepted July 21, 2020

Electronically published September 23, 2020

Full text available through open access at http://escholarship.org/uc/uciem_cpem

DOI: 10.5811/cpem.2020.7.48421

Introduction: While the electrocardiogram (ECG) for pulmonary embolism typically shows tachycardia or evidence of right heart strain, it can demonstrate ischemic changes similar to acute coronary syndrome.

Case Report: The patient in this case presented with syncope, chest pain, and an ECG showing an anterior acute myocardial infarction (AMI) without evidence of right heart strain. His cardiac catheterization showed no coronary artery occlusions, but some signs of pulmonary embolism (PE), which was confirmed on computed tomography angiography of the chest.

Conclusion: This case demonstrates that PE should be high on the differential for AMI and describes an uncommonly encountered mimic for classic ST-elevation myocardial infarction ECG changes. Further diagnostics to confirm the diagnosis should be obtained when indicated. [Clin Pract Cases Emerg Med. 2020;4(4):660–663.]

Keywords: *Pulmonary embolism; STEMI; chest pain; syncope.*

INTRODUCTION

Acute myocardial infarction (AMI) and pulmonary embolism (PE) can present in similar ways: chest pain; shortness of breath (SOB); and diaphoresis.^{1,2} One challenge for AMI presenting with an ST-elevation myocardial infarction (STEMI) is the speed at which patients are supposed to be taken to the catheterization lab.³ The current goal for door-to-balloon time is 90 minutes, but studies are looking at potentially shortening these times.⁴ Furthermore, studies that have sought to shorten door-to-balloon time have come with a concomitant increase in negative catheterizations or, non-cardiac, etiologies for the patient's symptoms.⁴

CASE REPORT

A 56-year-old male with history of multiple myeloma status post-bone marrow transplant on suppressive therapy,

hypertension, and peripheral neuropathy presented to the emergency department (ED) after a syncopal episode, where he was found in the bathtub by his family with his eyes rolled back. Upon initial examination, the patient complained of mild chest pain. Upon arrival to the ED, the patient was found to be tachycardic with a pulse of 108 beats per minute, tachypneic with 24 breaths per minute, a blood pressure of 95/68 millimeters mercury, and oxygen saturation of 100% on room air. An electrocardiogram (ECG) demonstrated ST elevations in V1 through V3 with reciprocal changes in the inferior leads (Image 1).

High-sensitivity troponins were obtained and were elevated to 0.20 nanograms (ng) per milliliter (mL) (reference range: normal <0.04 ng/mL). The patient was taken to the cardiac catheterization laboratory where he underwent percutaneous coronary intervention (PCI), which did not

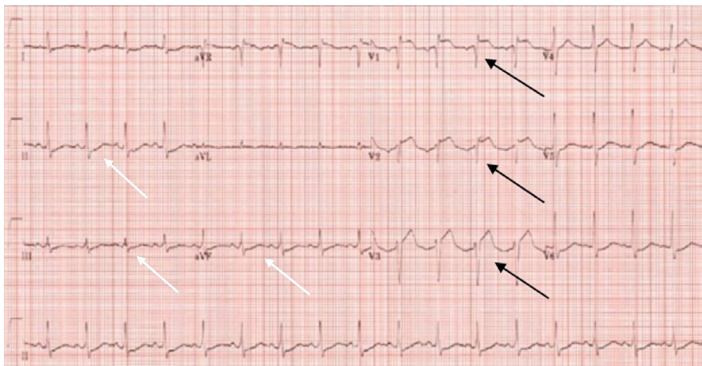


Image 1. Acute anterior myocardial infarction with ST-segment elevations in V1 through V3 (black arrows) and associated reciprocal changes in leads II, III and aVF (white arrows).

reveal severe coronary artery disease (Image 2) but did show hyperdynamic left ventricle with an ejection fraction >70% on ventriculography, tachycardia, and low left ventricular end-diastolic pressure indicating low filling pressures with suspicion for reduced preload. This was concerning for hypovolemia or pulmonary embolus.

Computed tomography angiography (CTA) of the chest was obtained showing submassive PE as well as right ventricular strain with a right ventricle to left ventricle ratio of 1.2 suggestive of cor pulmonale (Image 3).

It was later reported after cardiac catheterization that the patient had had increased bilateral leg swelling and discomfort as well as dyspnea on exertion for several weeks preceding his presentation to the ED, which he attributed to his neuropathy following chemotherapy. The patient was started on a continuous heparin infusion, and repeat ECG demonstrated resolution of anterior ischemic changes. Venous duplex ultrasound of the bilateral lower extremities was obtained on hospital day two and demonstrated a partially occlusive venous thrombus in the left popliteal, peroneal, and posterior tibial veins. The patient underwent catheter-assisted thrombolysis on hospital day three. He was started on apixaban 10 milligrams (mg) twice daily for the first week, followed by 5 mg twice daily, and discharged home in stable condition.

DISCUSSION

Differentiating between myocardial infarction and PE can be difficult based on initial symptoms alone because they can have similar presentations. PE can present with ST-segment elevations, making it important to consider other conditions that can mimic STEMI.⁵ The patient presented with syncope and dyspnea. Due to time pressures secondary to the door-to-balloon time mandate, his initial history was appropriately brief. Based on the ECG showing ST-segment elevations in leads V1-V3 with reciprocal changes, STEMI was diagnosed and he was taken directly for emergency cardiac catheterization. His elevated troponin lent more evidence to

CPC-EM Capsule

What do we already know about this clinical entity? *Pulmonary embolisms (PEs) have a variety of presentations, including acute ST-elevation myocardial infarctions (STEMI), chest pain, shortness of breath, and syncope as documented by several case reports in the literature.*

What makes this presentation of disease reportable? *When PEs present as STEMI there is typically evidence of right heart strain on electrocardiogram (ECG). In this case, no right heart strain was noted on the ECG.*

What is the major learning point? *Have pulmonary embolism on your differential diagnosis even if the ECG shows a STEMI with no evidence of right heart strain.*

How might this improve emergency medicine practice? *The case highlights the importance of having a broad differential for STEMI seen on ECG, including PE, even without any evidence of right heart strain.*

a diagnosis of acute coronary syndrome. When reviewing the ECG in this case, no evidence of right heart strain was present unlike in other cases noted in the literature.⁶⁻⁹

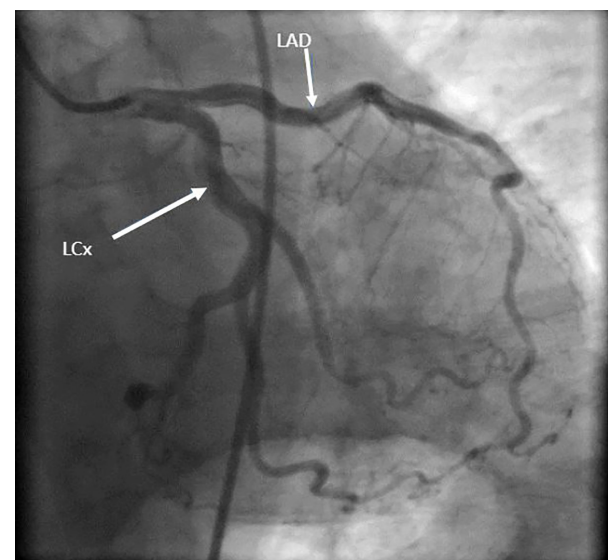


Image 2. Percutaneous coronary intervention with arrows pointing to the left circumflex (LCx) and left anterior descending (LAD) arteries with no stenosis.

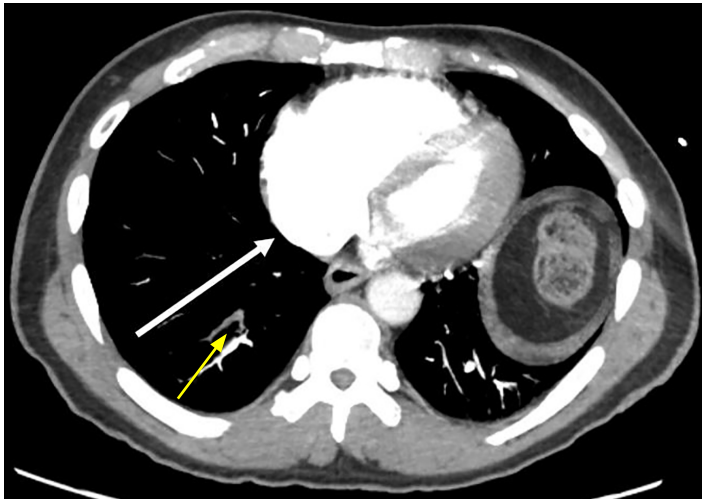


Image 3. Axial image from computed tomography angiogram of the chest demonstrating significantly dilated right ventricle (arrow) and filling defect consistent with pulmonary embolism (yellow arrow) .

History of syncope, unilateral leg swelling or pain, deep venous thrombosis, sudden dyspnea, recent surgery, or hemoptysis all increase the probability of a PE while the absence of dyspnea, and tachypnea reduce the probability of a PE.¹ However, no one symptom alone can point to any specific diagnosis. Further testing, such as an ECG, can help narrow the differential when history alone is inadequate. Typically, PEs present as sinus tachycardia on ECG but they can also have ECG findings suggestive of acute right ventricular (RV) strain, such as deep T-wave inversions in leads V1, V2 and V3, complete or incomplete right bundle branch block, or S1Q3T3.¹⁰ While rare, there have been several documented cases of PE presenting with ST-segment elevation mimicking anterior wall MI.⁶⁻⁹ This is likely due to acute RV strain and poor left ventricular (LV) filling resulting in decreased blood flow to the coronaries.¹¹

Massive PE is defined as a PE with sustained hypotension, need for inotropic support, or persistent bradycardia.¹² Submassive PEs are typically normotensive but have either myocardial ischemia as evidenced by an elevated troponin or B-type natriuretic peptide, or RV dysfunction visualized typically on ultrasound or an RV to LV ratio of greater than 0.9 on imaging.¹² Lastly, uncomplicated PEs have no ventricular dysfunction of myocardial ischemia and are normotensive.¹²

In this case, CTA chest demonstrated RV dysfunction, which was not seen on the ECG. The finding of RV dysfunction in patients who present with anterior AMIs on ECG is demonstrated several times in the literature.⁶⁻⁹ The patient in this case met criteria for a submassive PE due to his normotension, elevated troponin, and visualized RV dysfunction. The RV does not begin to dilate until there is greater than 50-70% occlusion of the pulmonary vasculature.¹² The dilation of the RV distorts the septum and the LV leading to eventual ventricular desynchrony as well as ST-segment elevations on the ECG.¹³

CONCLUSION

Since ST-segment elevations are associated with multiple diagnoses such as AMIs, pericarditis, and early repolarization, it is not only important to keep a differential broad but to obtain a thorough history. Clinical history affects the interpretation of ECGs, leading clinicians to search for specific ECG findings or alerting them to other diagnoses that may not have been in the initial differential.¹⁴ Although emergency physicians have increased time pressure to expedite cardiac catheterization on patients with STEMI on ECG, this pressure can result in increased incorrect activations. While PE presenting as a STEMI is a rare phenomenon, there have been several reported cases.⁶⁻⁹ Obtaining good initial history, despite mandated time limits, can help further guide the differential to differentiate between PE and STEMI.

The Institutional Review Board approval has been documented and filed for publication of this case report.

Address for Correspondence: Varvara Ladage, DO, Midwestern University Chicago College of Osteopathic Medicine, Department of Emergency Medicine, 555 31st St., Downers Grove, IL 60515. Email: vvassiliev39@midwestern.edu.

Conflicts of Interest: By the CPC-EM article submission agreement, all authors are required to disclose all affiliations, funding sources and financial or management relationships that could be perceived as potential sources of bias. The authors disclosed none.

Copyright: © 2020 Ladage et al. This is an open access article distributed in accordance with the terms of the Creative Commons Attribution (CC BY 4.0) License. See: <http://creativecommons.org/licenses/by/4.0/>

REFERENCES

1. West J, Goodacre S, Sampson F. The value of clinical features in the diagnosis of acute pulmonary embolism: systematic review and meta-analysis. *QJM*. 2007;100(12):763-9.
2. Swap CJ and Nagurney JT. Value and limitations of chest pain history in the evaluation of patients with suspected acute coronary syndromes. *JAMA*. 2005;294(20):2623-9.
3. Park J, Choi KH, Lee JM, et al. Prognostic Implications of door-to-balloon time and onset-to-door time on mortality in patients with ST-segment elevation myocardial infarction treated with primary percutaneous coronary intervention. *J Am Heart Assoc*. 2019;8(9):e012188.
4. Fanari Z, Abraham N, Kolm P, et al. Aggressive measures to decrease "door to balloon" time and incidence of unnecessary

- cardiac catheterization: potential risks and role of quality improvement. *Mayo Clin Proc.* 2015;90(12):1614-22.
5. Wang K, Asinger RW, Marriott HJ. ST-segment elevation in conditions other than acute myocardial infarction. *N Engl J Med.* 2003;349(22):2128-35
 6. Dasa O, Ruzieh M, Ammari Z, et al. It's a ST-elevation myocardial infarction (STEMI), or is it? Massive pulmonary embolism presenting as STEMI. *J Emerg Med.* 2018;55(1):717-8.
 7. Goslar T and Podbregar M. Acute ECG ST-segment elevation mimicking myocardial infarction in a patient with pulmonary embolism. *Cardiovasc Ultrasound.* 2010;8(1):8.
 8. Livaditis IG, Paraschos M, Dimopoulos K. Massive pulmonary embolism with ST elevation in leads V1-V3 and successful thrombolysis with tenecteplase. *Heart.* 2004;90(7):754.
 9. Özer N, Yorgun H, Canpolat U, et al. Pulmonary embolism presenting with evolving electrocardiographic abnormalities mimicking anteroseptal myocardial infarction: a case report. *Med Princ Pract.* 2011;20(6):577-80.
 10. Golpe R, Castro-Añón O, Pérez-De-Llano LA, et al. Electrocardiogram score predicts severity of pulmonary embolism in hemodynamically stable patients. *J Hosp Med.* 2011;6(5):285-9.
 11. Chan TC, Vilke GM, Pollack M, et al. Electrocardiographic manifestations: pulmonary embolism. *J Emerg Med.* 2001;21(3):263-70.
 12. Bryce YC, Perez-Johnston R, Bryce EB, et al. Pathophysiology of right ventricular failure in acute pulmonary embolism and chronic thromboembolic pulmonary hypertension: a pictorial essay for the interventional radiologist. *Insights Imaging.* 2019;10(1):10-8.
 13. Grant-Orser A, Ballantyne B, Haddara W. Unique ECG findings in acute pulmonary embolism: STE with reciprocal changes and pathologic Q wave. *Case Rep Crit Care.* 2018;2018:7865894.
 14. Cruz MF, Edwards J, Dinh MM, et al. The effect of clinical history on accuracy of electrocardiograph interpretation among doctors working in emergency departments. *Med J Aust.* 2012;197(3):161-5.

Palmoplantar Pustulosis: A Case Report

Anne Dulski, DO
Vince Varamo, DO

Kent Hospital, Department of Emergency Medicine, Warwick, Rhode Island

Section Editor: John Ashurst, DO, MSc

Submission history: Submitted May 29, 2020; Revision received June 12, 2020; Accepted August 7, 2020

Electronically published September 17, 2020

Full text available through open access at http://escholarship.org/uc/uciem_cpem

DOI: 10.5811/cpem.2020.7.48476

Introduction: Dermatology complaints account for 3.3% of emergency department (ED) visits per year. Most rashes are benign, but there are a select few that emergency physicians must be familiar with as delay in treatment could be life threatening.

Case Report: A well-appearing, 76-year-old male presented to the ED with multiple coalescing pustules to his palms and soles and was transferred to the nearest tertiary care hospital for dermatology consult. He was diagnosed with palmoplantar pustulosis and discharged home with a five-day course of clobetasol propionate 0.05% cream twice daily and outpatient dermatology follow-up.

Conclusion: Palmoplantar pustulosis is an uncommon skin condition characterized by recurrent eruptions of sterile pustules localized to the palms and soles. Emergency physician awareness of this rare diagnosis may help prevent hospital admissions and lead to earlier initiation of treatment with outpatient dermatology follow-up. [Clin Pract Cases Emerg Med. 2020;4(4):664–667.]

Keywords: *Palmoplantar pustulosis; rash; emergency medicine.*

INTRODUCTION

The chief complaint of rash is a common reason patients present to the emergency department (ED). It is estimated that dermatology complaints account for 3.3% of all ED visits per year.¹ Although patients who present to the ED with rashes are usually well appearing and can be treated with outpatient management, there are a select few conditions that emergency physicians must be aware of as proper diagnosis and treatment could prevent further complications and even death. Palmoplantar pustulosis (PPP) is an uncommon, chronic skin condition characterized by recurrent eruptions of sterile pustules localized to the palms and soles.² Because it is an uncommon diagnosis data pertaining to it is limited. It is thought that PPP usually develops in middle-aged adults, 50-69, and occurs more in females.³ Classical findings of PPP include eruptions of sterile pustules on the palms and/or soles with associated scaling, erythema, pruritus, burning, and/or pain.^{4,5} The diagnosis is based primarily on history and physical.

First-line treatment includes topical corticosteroids and smoking cessation; more advanced therapy includes

oral retinoids, photochemotherapy, immunosuppressants and, if there is no improvement, anti-tumor necrosis factor drugs.^{6,7} The patient we describe presented with an acute rash to the palms and soles consistent with this disease with no history of psoriasis or skin disorders. Due to the rarity of this disease and broad differential at presentation, the patient was transferred to a nearby tertiary care center with dermatology referral. The more that is known about PPP, the sooner patients can be diagnosed correctly and started on the appropriate course of treatment.

CASE REPORT

A 76-year-old male, daily smoker, with a history of chronic obstructive lung disease, peptic ulcer disease, prostate cancer status post prostatectomy in 1996, presented to the ED with a new rash to his palms. The rash started four to five days prior and had been progressively worsening without pain or pruritus. He admitted to using a furniture polish without gloves the day prior to the rash starting but had used it in the past without any side effects. He denied any systemic symptoms, recent illnesses,

new or current medications, or sexual activity. On initial presentation, the patient's blood pressure was 119/66 millimeters of mercury, heart rate 76 beats per minutes, temperature 36.7° Celsius and his oxygen saturation was 99% on room air. Physical exam revealed multiple, coalescing pustules on background erythema on the palms and soles (Images 1 and 2) with a few diffusely scattered pustules to his back (Image 3) and abdomen. There was no mucosal involvement.

Workup in the ED included a complete blood count, comprehensive metabolic panel, C-reactive protein, erythrocyte sediment rate, herpes simplex virus, hepatitis panel, gonorrhea, chlamydia, and syphilis testing. Due to all labs being within normal limits, the decision was made to transfer to a nearby tertiary care center for urgent dermatology referral. During his admission, he was evaluated by dermatology and hematology. Lab work showed a 20.6% monocytosis (normal monocyte range 2-8%) but was otherwise unremarkable, and a potassium hydroxide prep was negative for fungal infection. Skin biopsy results showed acute spongiolitic dermatitis with subcorneal pustules composed of neutrophils, consistent with pustular psoriasis. He was diagnosed with PPP and discharged home after five days with clobetasol propionate 0.05% cream twice daily and outpatient dermatology follow-up.

DISCUSSION

Palmoplantar pustulosis is an uncommon skin disorder with a presumed prevalence of less than 1% of the population.² It is characterized by recurrent eruptions of sterile pustules primarily localized to the palms and/or soles.² Some consider PPP to be a subtype of psoriasis, but others suggest it is a separate entity.⁵ It is thought that PPP

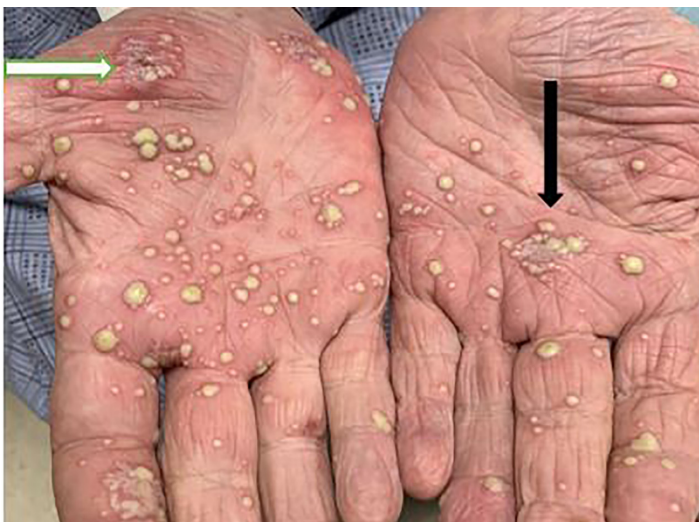

Image 1. Patient's palms with black arrow pointing to coalescing pustules with surrounding erythema and white arrow pointing to pustules with scaling consistent with palmoplantar pustulosis.

CPC-EM Capsule

What do we already know about this clinical entity?

Palmoplantar pustulosis is characterized by sterile pustules to the palms and/or soles; treatment includes clobetasol propionate cream and smoking cessation.

What makes this presentation of disease reportable?

The patient had no history of skin conditions and had an acute eruption of a rash that is not commonly seen in the emergency department.

What is the major learning point?

Palmoplantar pustulosis is a rare but benign skin condition that emergency physicians should be aware of to aid in early diagnosis and initiation of treatment.

How might this improve emergency medicine practice?

Awareness of this rare diagnosis may help prevent hospital admissions and lead to earlier initiation of treatment.

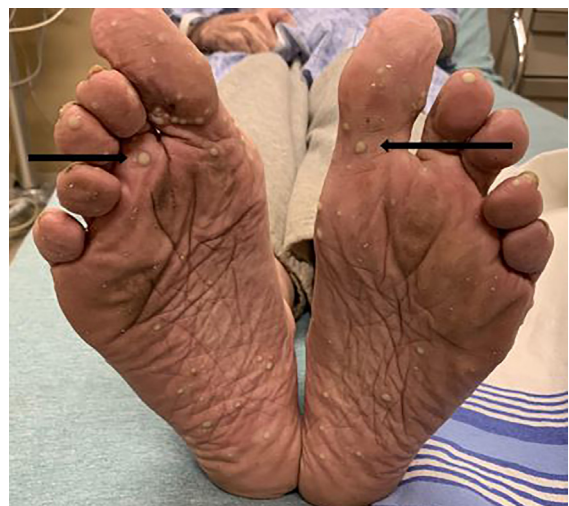

Image 2. Patient's feet with black arrows pointing to pustules on the soles consistent with palmoplantar pustulosis.

usually develops in middle-aged adults, 50-69, and occurs more often in females.³ While the pathogenesis is unknown, studies have suggested an inflammatory process that destroys

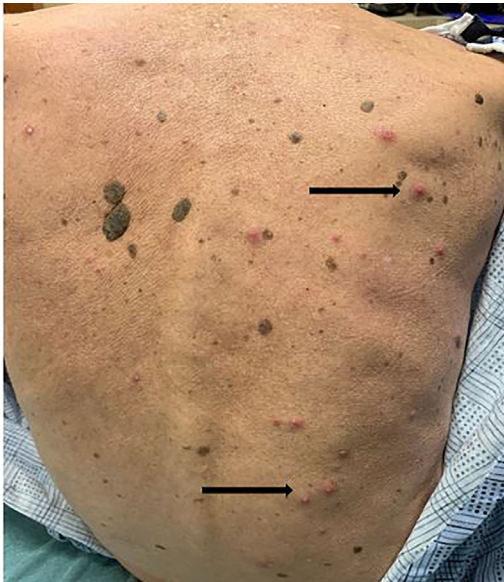


Image 3. Scattered pustules with surrounding erythema on the patient's back as indicated by the black arrows.

the acrosyringium (intraepidermal eccrine sweat ducts) and a possible association with increased interleukin-8, interleukin-17, tumor necrosis factor-alpha, interleukin-22, and interferon-gamma.⁸ Proposed environmental factors that may contribute to the onset of PPP include smoking, stress, infection, genetics, and cessation or initiation of certain medications.^{4,9} The associated symptoms of scaling dry skin can lead to painful cracks and fissures that can make activities of daily living challenging and have a negative impact on a patient's life.¹⁰

Diagnosis is based on history and physical examination because lab work is usually unremarkable. Skin biopsies are often not necessary but may help in supporting the diagnosis if there is uncertainty.^{2,5} The recommended first-line treatment for PPP is high potency clobetasol propionate 0.05% cream twice daily for at least four weeks.^{9,11} In addition to a steroid cream, first-line treatment options include daily living changes. Research has found a strong association between PPP and smoking; and patients who successfully quit have been found to have a decrease in their symptoms and recurrence rate.⁴ In addition to smoking cessation, other behavioral changes include daily skin moisturizing and avoidance of skin irritants. Due to the rarity of this skin condition, there remains incomplete consensus of the best treatment; however, topical steroids have been found to be the most effective and have the least amount of side effects. Other treatment options include oral retinoids and photochemotherapy, but side effects of both limit their use for second-line therapy.^{12,13} Palmoplantar pustulosis is a chronic recurrent skin condition and many patients will need to be on lifelong therapy for symptomatic relief and to decrease recurrence rate.¹⁴

CONCLUSION

Palmoplantar pustulosis is an uncommon skin disorder that is characterized by recurrent eruptions of sterile pustules primarily localized to the palms and/or soles. Emergency physician awareness of this rare diagnosis may help prevent hospital admissions and lead to earlier initiation of treatment with outpatient dermatology follow-up.

The Institutional Review Board approval has been documented and filed for publication of this case report.

Address for Correspondence: Anne Dulski, DO, Kent Hospital, Department of Emergency Medicine, Warwick, Rhode Island, 455 Toll Gate Road, Warwick, RI 02886. Email: adulski@kentri.org.

Conflicts of Interest: By the CPC-EM article submission agreement, all authors are required to disclose all affiliations, funding sources and financial or management relationships that could be perceived as potential sources of bias. The authors disclosed none.

Copyright: © 2020 Dulski et al. This is an open access article distributed in accordance with the terms of the Creative Commons Attribution (CC BY 4.0) License. See: <http://creativecommons.org/licenses/by/4.0/>

REFERENCES

1. Baibergenova A and Shear NH. Skin conditions that bring patients to emergency departments. *Arch Dermatol.* 2011;147(1):118-20.
2. Hellgren L and Mobacken H. Pustulosis palmaris et plantaris. Prevalence, clinical observations and prognosis. *Acta Derm Venereol.* 1971;51(4):284-8.
3. Kubota K, Kamijima Y, Sato T, et al. Epidemiology of psoriasis and palmoplantar pustulosis: a nationwide study using the Japanese national claims database. *BMJ Open.* 2015;5(1):e006450.
4. Brunasso AM, Puntoni M, Aberer W, et al. Clinical and epidemiological comparison of patients affected by palmoplantar plaque psoriasis and palmoplantar pustulosis: a case series study. *Br J Dermatol.* 2013;168(6):1243-51.
5. de Waal AC and van de Kerkhof PC. Pustulosis palmoplantaris is a disease distinct from psoriasis. *J Dermatolog Treat.* 2011;22(2):102-5.
6. Reitamo S, Erkkö P, Remitz A, et al. Cyclosporine in the treatment of palmoplantar pustulosis. A randomized, double-blind, placebo-controlled study. *Arch Dermatol.* 1993;129(10):1273-9.
7. Brunasso AM, Laimer M, Massone C. Paradoxical reactions to targeted biological treatments: a way to treat and trigger? *Acta Derm Venereol.* 2010;90(2):183-5.
8. Murakami M, Hagforsen E, Morhenn V, et al. Patients with palmoplantar pustulosis have increased IL-17 and IL-22 levels both in

- the lesion and serum. *Exp Dermatol*. 2011;20(10):845-7.
9. Becher G, Jamieson L, Leman J. Palmoplantar pustulosis: a retrospective review of comorbid conditions. *J Eur Acad Dermatol Venereol*. 2015;29(9):1854-6.
 10. Trattner H, Bluml S, Steiner I, et al. Quality of life and comorbidities in palmoplantar pustulosis – a cross sectional study on 102 patients. *J Eur Acad Dermatol Venereol*. 2017;31(10):1681-5.
 11. Adışen E, Tekin O, Gülekon A, et al. A retrospective analysis of treatment responses of palmoplantar psoriasis in 114 patients. *J Eur Acad Dermatol Venereol* 2009;23(7):814-9.
 12. Sevrain M, Richard MA, Barnette T, et al. Treatment for palmoplantar pustular psoriasis: systematic literature review, evidence-based recommendations and expert opinion. *J Eur Acad Dermatol Venereol*. 2014;28 Suppl 5:13-6.
 13. Lassus A and Geiger JM. Acitretin and etretinate in the treatment of palmoplantar pustulosis: a double-blind comparative trial. *Br J Dermatol*. 1988;119(6):755-9.
 14. Marsland AM, Chalmers RJ, Hollis S, et al. Interventions for chronic palmoplantar pustulosis. *Cochrane Database Syst Rev*. 2006;(1):CD001433.

Sepsis-induced Autoimmune Hemolytic Anemia: A Case Report

Zach Edwards, BA*
Stephen DeMeo, DO†

*Campbell University School of Osteopathic Medicine, Raleigh, North Carolina
†WakeMed, Department of Neonatology, Raleigh, North Carolina

Section Editor: John Ashurst, DO, MSc

Submission history: Submitted July 12, 2020; Revision received August 16, 2020; Accepted August 22, 2020

Electronically published October 5, 2020

Full text available through open access at http://escholarship.org/uc/uciem_cpem

DOI: 10.5811/cpcem.2020.8.49040

Introduction: Sepsis commonly brings patients to the emergency department (ED). Patient outcomes can vary widely. In some cases, rare complications of sepsis such as autoimmune hemolytic anemia can occur.

Case Report: A 68-year-old female presented with sepsis secondary to infected nephrolithiasis. The patient had signs and symptoms consistent with hemolysis upon arrival to the ED. Her hemolysis progressively worsened over a two-day period leading to a diagnosis of warm autoimmune hemolytic anemia. She responded well to treatment; however, her condition began to worsen due to a new infection caused by perforated colonic diverticula. The patient ultimately expired from complications of her perforated colonic diverticula.

Conclusion: It is crucial that emergency physicians understand the risk factors, symptoms, pathophysiology, and treatment of this rare complication of sepsis so that favorable patient outcomes can be achieved. [Clin Pract Cases Emerg Med. 2020;4(4):668–670.]

Keywords: *Autoimmune hemolytic anemia; sepsis; sepsis-induced autoimmune hemolytic anemia.*

INTRODUCTION

Globally, it is estimated that between 20-30 million people develop sepsis annually and that eight million will die each year.¹ Prompt treatment and identification of the infectious etiology is key in preventing end-organ damage and or death. In rare instances, patients can develop complications from sepsis; one such complication is autoimmune hemolytic anemia. This patient's complicated hospital course offers valuable insight on sepsis-induced autoimmune hemolytic anemia.

CASE REPORT

A 68-year-old female with a past medical history of atrial fibrillation, deep vein thrombosis, pulmonary embolism, nephrolithiasis, diverticulitis, and asthma presented with two days of flank pain, abdominal pain, subjective fever, nausea, vomiting, and diarrhea. On physical exam the patient was noted to have bilateral costovertebral angle tenderness, mild diffuse abdominal pain, scleral icterus, and a negative

Murphy's sign. Her blood pressure was 80/64 millimeters of mercury, heart rate 116 beats per minute, and temperature 97.9 degrees Fahrenheit.

Initial laboratory values demonstrated a leukocyte count of 26,400 microliters (μ L) (reference [ref] range 4000-10,000/ μ L); hemoglobin 9.7 milligrams per deciliter (mg/dL) (ref range 11.4 – 15 mg/dL); total bilirubin 8.5 mg/dL (ref range 0.3 – 1.0 mg/dL); direct bilirubin 1.5 mg/dL (ref range 0.0 – 0.2 mg/dL); lactic acid 6.6 millimoles per liter (mmol/L) (ref range 0.67-1.8 mmol/L); and creatinine 2.37 mg/dL (ref range 0.7-1.3 mg/dL). The patient's urine was positive for nitrites (ref negative result), leukocytes (negative), and blood (negative). A non-contrast abdominal computed tomography demonstrated a left renal pelvic stone and evidence of sigmoid diverticulosis without diverticulitis. Broad-spectrum antibiotics, fluids, and vasopressors were started immediately. The patient was started on intravenous (IV) ceftriaxone, metronidazole, and vancomycin. Five hours after her arrival she was switched to cefepime and vancomycin.

Urology was consulted and opted to emergently place a left renal stent to alleviate the obstruction. On the second day, her hemoglobin decreased to 5.8 grams (g)/dL (ref range 12-16 g/dL) requiring a blood transfusion with two units of packed red blood cells. Prior to transfusion, she was found to have a positive direct Coombs test and spherocytes on the peripheral blood smear. There were no schistocytes on her peripheral blood smear (which can be seen in microangiopathic hemolytic anemia and disseminated intravascular coagulation). She was diagnosed with warm autoimmune hemolytic anemia secondary to sepsis. The patient’s key lab values at the time of diagnosis can be seen in Table. Cephalosporin-induced hemolytic anemia was considered; however, the patient was hemolyzing prior to presenting to the ED, which made sepsis a more likely culprit. The patient was started on IV methylprednisolone 60 mg every six hours. Over the next 24 hours the patient’s signs and symptoms of hemolysis began to improve.

On the eighth day of the patient’s hospital course her autoimmune hemolytic anemia began to worsen due to a new infectious process. Her condition deteriorated rapidly, which lead to septic shock. An abdominal computed tomography was performed and demonstrated pneumoperitoneum, abscess, and viscous perforation. She underwent an exploratory laparotomy, which revealed peritonitis due to several perforated colonic diverticula, and resulted in a hemicolectomy and sigmoidectomy. Shortly after being transferred to the intensive care unit postoperatively, the patient underwent cardiac arrest. The healthcare team was unable to obtain the return of spontaneous circulation and the patient expired.

DISCUSSION

Autoimmune hemolytic anemia is a rare blood cell disorder with an incidence of 1-3 per 100,000 people per year.² This disorder can be broken down into primary (idiopathic) and secondary (due to a known trigger).³

Table. Patient’s laboratory data upon diagnosis of warm autoimmune hemolytic anemia.

Variable	Reference range	Patient’s labs upon diagnosis
Hemoglobin	11.4-15 mg/dL	5.8 mg/dL
Hematocrit	31-42%	17%
Platelet	150 – 450 K/ μ L	204
Total bilirubin	0.3-1.0 mg/dL	33.5 mg/dL
Direct bilirubin	0.0-0.2 mg/dL	20.6 md/dL
Haptoglobin	44-215 mg/dL	<30 mg/dL
Lactate dehydrogenase	140-271 IU/L	657 IU/L

mg, milligram; *dL*, deciliter; μ L, microliter; *K*, thousand; *IU*, international unit; *L*, liter.

CPC-EM Capsule

What do we already know about this clinical entity?

Autoimmune hemolytic anemia is a rare complication of sepsis.

What makes this presentation of disease reportable?

There are few published case reports on sepsis-induced autoimmune hemolytic anemia.

What is the major learning point?

This case highlights the epidemiology, pathophysiology, signs, symptoms, and treatment for autoimmune hemolytic anemia.

How might this improve emergency medicine practice?

Understanding this rare complication of sepsis will help providers diagnose and treat the disease.

Furthermore, there are two distinct types, cold agglutinin-mediated autoimmune hemolytic anemia and warm autoimmune hemolytic anemia.⁴ Warm autoimmune hemolytic anemia occurs far more often than the cold variant.⁵ Between 70-80% of autoimmune hemolytic anemia cases in adults are the warm variant.^{2,6} This blood cell disorder has several etiologies. These include infection, malignancy (chronic leukocytic leukemia), autoimmune disorders (systemic lupus erythematosus), and many medications (most notably cephalosporins).^{2,4,7,8}

Warm autoimmune hemolytic anemia is an example of a type II hypersensitivity reaction. The pathophysiology behind this disorder involves immunoglobulin G antibodies attacking red blood cells, resulting in extravascular hemolysis.⁸ These immunoglobulins react with red blood cells at temperatures near 37°C.³ This causes red blood cells to be coated with antibodies that signal the immune system to destroy the red blood cells.² The host’s red blood cells are destroyed in an antibody-dependent manner that is carried out by cytotoxic CD8+T cells and natural killer cells within the spleen.² Spleen macrophages also play a significant role in the extravascular hemolysis of the host’s red blood cells, primarily through phagocytosis.⁵ The complement system contributes to a lesser degree in warm autoimmune hemolytic anemia vs cold agglutinin disease.^{2,6}

Patients typically present with signs and symptoms of anemia and hemolysis. Symptoms include pallor, jaundice,

splenomegaly, and dark urine.^{3,5,8} These symptoms are not specific and can present in a variety of disorders. However, if the clinical picture aligns with this disorder (eg, recent cephalosporin use, infection, malignancy) and these symptoms present, then warm autoimmune hemolytic anemia should be on the clinician's differential diagnosis. Laboratory findings include reduced hemoglobin, hematocrit, and haptoglobin. Patients will also have elevated lactate dehydrogenase and indirect bilirubin.^{5,6,7} The peripheral blood smear will demonstrate spherocytosis.⁵ The presence of hemolytic anemia, positive direct Coombs test, and spherocytes are required to make a diagnosis of autoimmune hemolytic anemia.^{5,7}

Initial management of patients with this disorder should be to determine whether a blood transfusion is necessary. This decision should be guided by the hemoglobin level, symptoms, and risk factors of the patient. Hemoglobin levels less than 7 mg/dL usually require a blood transfusion. Clinicians should also assess the need for venous thromboembolism prophylaxis, as one study found between 15-33% of patients diagnosed with warm autoimmune hemolytic anemia experienced venous thromboembolism.⁹ The first-line treatment for this disorder is with oral prednisone or intravenous (IV) high-dose steroids such as methylprednisolone.² If the patient does not adequately respond to steroids, then other treatments such as IV immunoglobulin or plasmapheresis may be used. Second-line therapy includes rituximab and splenectomy.^{2,6} Mortality rates for autoimmune hemolytic anemia are low and are usually related to infection secondary to splenectomy.⁷ Although most patients achieve full remission some will have a chronic relapsing course.⁵

CONCLUSION

Nephrolithiasis may induce septic shock, which can result in autoimmune hemolytic anemia. Knowing the symptoms and risk factors for this disorder will allow emergency physicians to add it to their differential when appropriate. To increase favorable patient outcomes, emergency physicians must understand the treatment and pathophysiology of warm autoimmune hemolytic anemia.

The authors attest that their institution requires neither Institutional Review Board approval, nor patient consent for publication of this case report. Documentation on file.

Address for Correspondence: Zach Edwards, BA, Campbell University School of Osteopathic Medicine, PO Box 4280, Buies Creek, NC 27506. Email: z_edwards0529@email.campbell.edu.

Conflicts of Interest: By the CPC-EM article submission agreement, all authors are required to disclose all affiliations, funding sources and financial or management relationships that could be perceived as potential sources of bias. The authors disclosed none.

Copyright: © 2020 Edwards et al. This is an open access article distributed in accordance with the terms of the Creative Commons Attribution (CC BY 4.0) License. See: <http://creativecommons.org/licenses/by/4.0/>

REFERENCES

1. Yu CW, Chang SS, Lai CC, et al. Epidemiology of emergency department sepsis. *Shock*. 2019;51(5):619-24.
2. Kalfa TA. Warm antibody autoimmune hemolytic anemia. *Hematology Am Soc Hematol Educ Program*. 2016;2016(1):690-7.
3. Bass GF, Tuscano ET, Tuscano JM. Diagnosis and classification of autoimmune hemolytic anemia. *Autoimmun Rev*. 2014;13(4-5):560-4.
4. Hill A and Hill QA. Autoimmune hemolytic anemia. *Hematology Am Soc Hematol Educ Program*. 2018;2018(1):382-9.
5. Barcellini W. Immune hemolysis: diagnosis and treatment recommendations. *Semin Hematol*. 2015;52(4):304-12.
6. Barcellini W and Fattizzo B. Clinical applications of hemolytic markers in the differential diagnosis and management of hemolytic anemia. *Dis Markers*. 2015;2015:635670.
7. Brodsky RA. Warm autoimmune hemolytic anemia. *N Engl J Med*. 2019;381(7):647-54.
8. Barcellini W. New insights in the pathogenesis of autoimmune hemolytic anemia. *Transfus Med Hemother*. 2015;42(5):287-93.
9. Audia S, Bach B, Samson M, et al. Venous thromboembolic events during warm autoimmune hemolytic anemia. *PLoS One*. 2018;13(11):e0207218.

A Noteworthy Case Report of Neuroborreliosis in an Unvaccinated Pediatric Patient

Amber R. Walker, DO
Teresita Morales-Yurick, MD

Doctors Hospital, Department of Emergency Medicine, Columbus, Ohio

Section Editor: Shadi Lahham, MD

Submission history: Submitted June 12, 2020; Revision received August 19, 2020; Accepted September 15, 2020

Electronically published October 26, 2020

Full text available through open access at http://escholarship.org/uc/uciem_cpem

DOI: 10.5811/cpem.2020.9.48688

Introduction: Lyme disease typically presents with viral-like symptoms and a pathognomonic rash. With disease progression, symptoms of nervous system involvement usually include facial nerve palsy and meningitis, but other atypical neurologic manifestations have less commonly been documented.

Case Report: A six-year-old male presented with prolonged fevers, rash, headache, and non-specific neurologic symptoms. The diagnosis of neuroborreliosis with meningitis and polyradiculitis was confirmed with laboratory evaluation and lumbar puncture.

Conclusion: Neuroborreliosis is a disseminated form of Lyme disease. While meningitis is a common sign, the presentation of polyradiculitis in children is rare and can lead to misdiagnosis and delay in treatment. [Clin Pract Cases Emerg Med. 2020;4(4):671–674.]

Keywords: *Lyme disease; neuroborreliosis; Lyme meningitis.*

INTRODUCTION

Lyme disease is the most common tick-borne disease in the United States.¹ The disease is easily treatable once recognized; however, in children this diagnosis can be confounded by the similarity of the early symptoms of infection to other childhood illnesses.² We present a case of a six-year-old-male who was evaluated for prolonged fevers associated with multiple other systemic and neurologic symptoms. He was found to have Lyme neuroborreliosis (NB), an early disseminated form of the disease, with specific findings of meningitis and polyradiculitis. As Lyme NB presents with such non-specific symptoms in pediatric patients, cases can easily be missed unless the diagnosis is high on the differential list. The resultant delay in management could lead to longstanding complications. This case serves as an important reminder of the illness presentation, especially for providers in high-risk regions.

CASE REPORT

A six-year-old male with history of minimal vaccinations presented with his parents for evaluation of fatigue, headache, and vomiting that started after two weeks of a rash. Symptoms

initially started three weeks prior with malaise, nausea, and tactile fevers. Upon resolution, a painful, non-pruritic, circular rash started on his right ankle and spread up his legs and back. He went to urgent care (UC), where he was diagnosed with viral hives and discharged home with five days of prednisone. The rash improved initially but returned, although no longer painful, after completion of the steroid burst.

Four days prior to arrival to the emergency department (ED), tactile fevers returned, his fatigue and rash worsened, and he developed a new-onset headache, vomiting (non-bloody, non-bilious), photophobia, diplopia, and myalgias. He went to another UC, was diagnosed with erythema multiforme and discharged on alternating acetaminophen and ibuprofen as well as loratadine. He slept constantly in the three days prior to presentation. The patient's mother was also concerned because his gait was slow, and he appeared unsteady on his feet due to persistent leg pain. Several siblings lived at home with him, but none of them were sick. Mother denied known tick or other animal bites. He denied chest pain, shortness of breath, sore throat, cough, abdominal pain, and diarrhea.

On examination, he was a very tired but nontoxic appearing male with normal vital signs for his age. His rash

consisted of several large, annular, asymmetric, papular, blanchable lesions on his torso, legs, and back (Images 1, 2). There was no neck rigidity. Neurological examination was significant for decreased abduction of both eyes without complete paralysis. No other focal cranial deficits were noted. Neuromuscular exam demonstrated normal strength and sensation of all extremities. Deep tendon reflexes were 2+ throughout. Gait was slow and somewhat unsteady.

A head computed tomography (CT) was obtained and showed no intracranial lesions. Laboratory studies were drawn due to concern for possible infection and did not show significant abnormalities, apart from a slightly elevated erythrocyte sedimentation rate (Table). A lumbar puncture was then performed, which demonstrated a cerebrospinal fluid (CSF) pleocytosis (Table). With the overall benign lab evaluation and head CT combined with the CSF pleocytosis and rash resembling large erythema migrans (EM), there was concern for early disseminated Lyme disease complicated by meningitis. He was thus started on intravenous (IV) ceftriaxone and admitted to the hospital for further infectious disease and neurologic workup. Diagnosis was later confirmed by positive Lyme immunoglobulin M and immunoglobulin G antibodies of the blood and CSF. His hospitalization was complicated by sacral radiculopathy causing urinary retention, cranial nerve six palsy, and increased intracranial pressure with optic nerve swelling requiring administration of acetazolamide. He was discharged home on hospital day five with 16 days of oral doxycycline and had complete recovery on follow-up office visits.

DISCUSSION

Lyme disease is caused by the spirochete *Borrelia burgdorferi* and is the most common tick-borne disease in the United States.¹ The majority of cases occur in the Upper

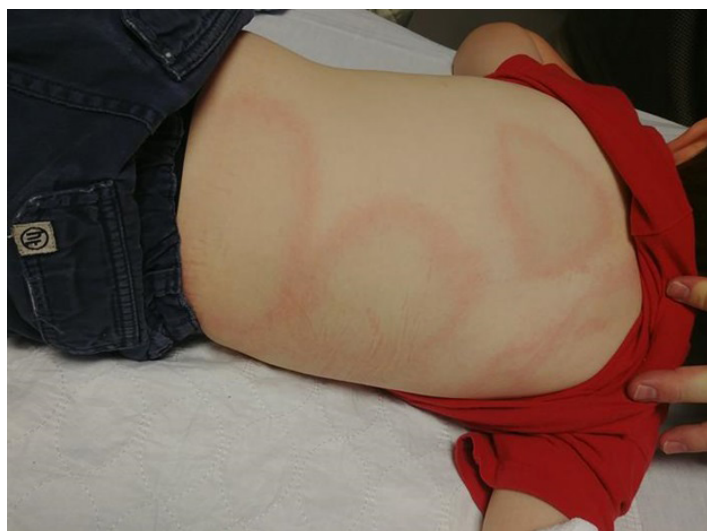

Image 1. A 6-year-old male patient with an acute febrile illness presents with the depicted annular rash to his torso.

CPC-EM Capsule

What do we already know about this clinical entity?

Lyme disease is divided into three stages (early localized, early disseminated, late) and can lead to long standing multisystem complications if left untreated.

What makes this presentation of disease reportable?

This patient presented with atypical neurologic symptoms from hematogenous spread of the disease, which ultimately led to a delay in the diagnosis.

What is the major learning point?

*Evaluation of cerebrospinal fluid for *Borrelia burgdorferi* antibodies should be considered in patients presenting with viral-like illness and unusual neurologic symptoms.*

How might this improve emergency medicine practice?

This case will hopefully prompt consideration of this diagnosis earlier in patients presenting with nonspecific viral and neurologic symptoms.

Midwest, Northeast, and Atlantic regions. Peak incidence of disease presentation is in the late spring and early summer, as people are more active outdoors in the warmer months.¹

Clinically, Lyme disease is divided into three stages: early localized; early disseminated; and late stage. The classic EM rash is the most common sign of early localized stage, occurring in at least 80% of patients usually 7-14 days after the tick bite.¹ If left untreated, hematogenous dissemination can lead to involvement of multiple organ systems. Neuroborreliosis occurs when the spirochetes invade the nervous system, causing meningitis and inflammation of cranial and peripheral nerves.^{3,4} Late manifestations of the disease occur after six months and include Lyme arthritis and acrodermatitis chronic atrophicans.¹

Key features of the history include known tick exposure or bite; however, most patients often do not recall a tick bite. The development of the single EM rash at the site of the tick bite with non-specific viral symptoms (fever, headache, fatigue, myalgias) is characteristic of early disease as well. Children with neuroborreliosis typically present with a facial nerve palsy and/or lymphocytic meningitis, but there has

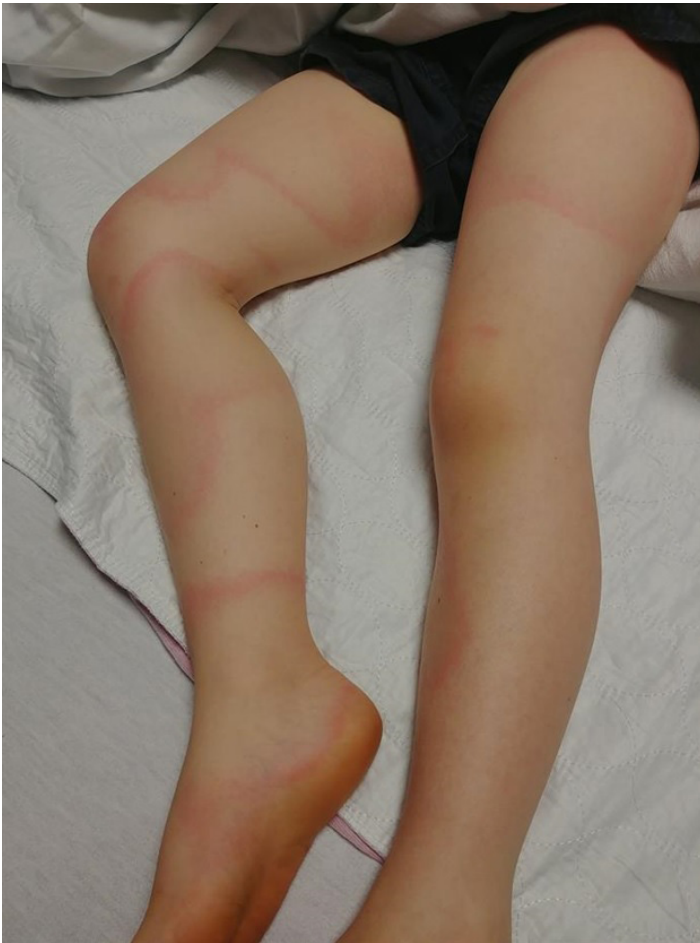

Image 2. Image of the lower extremities demonstrating an annular rash similar to the rash present on the torso.

been documentation of other rare manifestations.⁵⁻⁹ In this case, the patient presented with symptoms of meningitis and ultimately developed involvement of multiple cranial and peripheral nerves.

The diagnosis of Lyme disease is often made clinically based on history of exposure and development of symptoms. If there is additional concern for NB, evaluation for antibodies, histopathologic and microbiologic evidence of *B. burgdorferi* has been recommended by the American Academy of Neurology.¹⁰ This typically includes detection of *Borrelia*-specific antibodies in CSF, which is mandatory for definitive diagnosis of NB.^{3,5} Direct detection of *B. burgdorferi* can be performed as well, but is seldom used due to its low sensitivity, long incubation period, and requirement of special culture media.¹ Additional CSF findings include a lymphocytic pleocytosis, which appears similar to that of aseptic meningitis.⁴

There are multiple treatment options for treatment of pediatric Lyme disease, depending on the severity of infection and the age of the patient. In early uncomplicated Lyme disease, outpatient oral therapy with doxycycline is recommended.^{3,4,11} If the child is younger than eight years of age, amoxicillin is the

Table. Laboratory data of six-year-old child diagnosed with neuroborreliosis.

Variable	Value	Reference Range
Sodium (mmol/L)	134	135-145
Potassium (mmol/L)	4.4	3.7-5.6
Chloride (mmol/L)	98	95-106
Carbon Dioxide (mmol/L)	22	18-27
Glucose (mg/dL)	82	60-115
Urea Nitrogen (mg/dL)	12	5-18
Creatinine (mg/dL)	0.41	0.10-0.60
Calcium (mg/dL)	9.0	8.0-10.5
Magnesium (mg/dL)	2.0	1.5-2.4
Phosphorous (mg/dL)	4.9	4.1-5.9
WBC ($10^6/uL$)	11.3	5.0-14.5
Neutrophils (%)	84.4	36.0-72.0
Lymphocytes (%)	11.3	27.0-57.0
Monocytes (%)	3.9	2.0-8.0
Eosinophils (%)	0.2	1.0-4.0
Basophils (%)	0.2	0.0-1.0
RBC ($10^6/mL$)	4.67	4.0-5.2
Hemoglobin (g/dL)	12.3	11.5-15.5
Hematocrit (%)	35.6	35-45
Platelet count ($10^3/uL$)	293	140-440
Mononucleosis Screen	Negative	Negative
Sedimentation Rate (mm/h)	45	0-13
C-reactive protein (mg/dL)	1.1	< 1.2
Cell count, CSF (cells/uL)	22	None
Color	Clear, Colorless	None
RBC, CSF fluid (/mm ³)	0	None
WBC, CSF fluid (/mm ³)	22	None
PMNc, CSF fluid (%)	28	None
Lymphocytes, CSF fluid (%)	50	None
Monocyte/macrophage, CSF fluid (%)	22	None
Gram stain	No organisms seen	None
Glucose, CSF (mg/dL)	45	40-70
Protein, CSF (mg/dL)	18	15-45

mmol, millimole; *L*, liter; *mg*, milligram; *dL*, deciliter; *WBC*, white blood cell; *uL*, microliter; *%*, percent; *RBC*, red blood cell; *mL*, milliliter; *g*, gram; *uL*, microliter; *mm*, millimeter; *h*, hour; *CSF*, cerebrospinal fluid; *PMNc*, polymorphonuclear cell.

drug of choice.¹¹ Treatment for more severe infection such as NB consists of IV ceftriaxone preferably due to its favorable dosing schedule, but IV cefotaxime and IV penicillin G have been used successfully as well.¹¹

The diagnosis of NB in children can be difficult because the symptoms may be nonspecific, leading to the possibility of a

wide range of diseases and significant delay in diagnosis.^{2,5} Thus it is crucial for emergency physicians to consider evaluation of CSF for pleocytosis and *B. burgdorferi* antibodies in patients who present as in this case with viral-like illness and unusual neurological symptoms.

CONCLUSION

Lyme disease classically presents with multiple, nonspecific symptoms and a characteristic rash. If left untreated, cardiac, neurologic, and rheumatologic complications can occur. Diagnosis of this illness can be difficult in the pediatric population due to symptom similarity to other diseases common throughout childhood. This is compounded when the presentation includes atypical neurologic symptoms. This case represents a unique case of neuroborreliosis presenting with partial bilateral abducens nerve palsy, peripheral nerve involvement, and lymphocytic meningitis. This case emphasizes the importance of considering Lyme disease in pediatric patients who present with rash, viral-like illness, and nonspecific neurologic symptoms.

The authors attest that their institution requires neither Institutional Review Board approval, nor patient consent for publication of this case report. Documentation on file.

REFERENCES

1. Marques AR. Lyme Neuroborreliosis. *Continuum (Minneapolis)*. 2015;21(6):1729-44.
2. Esposito S, Bosis S, Sabatini C, et al. *Borrelia burgdorferi* infection and Lyme disease in children. *Int J Infect Dis*. 2013;17(3):153-8.
3. Skogman BH, Croner S, Nordwall M, et al. Lyme neuroborreliosis in children: a prospective study of clinical features, prognosis, and outcome. *Pediatr Infect Dis J*. 2008;27(12):1089-94.
4. Pachner AR. Early disseminated Lyme disease: Lyme meningitis. *Am J Med*. 1995;98(4A):30S-43S.
5. Baumann M, Birnbacher R, Koch J, et al. Uncommon manifestations of neuroborreliosis in children. *Eur J Paediatr Neuro*. 2010;14(3):274-7.
6. Ewers EC, Dennison DH, Stagliano DR. A unique case of adolescent neuroborreliosis presenting with multiple cranial neuritis and cochlear inflammation on magnetic resonance imaging. *Pediatr Neurol*. 2015;52(1):107-9.
7. Roaldsnes E, Eikeland R, Berild D. Lyme neuroborreliosis in cases of non-specific neurological symptoms. *Tidsskr Nor Laegeforen*. 2017;137(2):101-4.
8. Miller MM, Müllegger RR, Spork KD, et al. Lyme borreliosis of central nervous system (CNS) in children: a diagnostic challenge. *Infection*. 1991;19(4):273-8.
9. Vukelic D, Bozinovic D, Morovic M, et al. Opsoclonus-myoclonus syndrome in a child with neuroborreliosis. *J Infect*. 2000;40(2):189-91.
10. Halperin JJ, Logigian EL, Finkel MF, et al. Practice parameters for the diagnosis of patients with nervous system Lyme borreliosis (Lyme disease). *Neurology*. 1996;46(3):619-27.
11. Wormser GP, Dattwyler RJ, Shapiro ED, et al. The clinical assessment, treatment, and prevention of Lyme disease, human granulocytic anaplasmosis, and babesiosis: clinical practice guidelines by the Infectious Diseases Society of America. *Clin Infect Dis*. 2006;43(9):1089-134.

Address for Correspondence: Amber R. Walker, DO, Doctors Hospital, Department of Emergency Medicine, 5100 West Broad Street, Columbus, Ohio 43228. Email: Amber_Walker@teamhealth.com.

Conflicts of Interest: By the CPC-EM article submission agreement, all authors are required to disclose all affiliations, funding sources and financial or management relationships that could be perceived as potential sources of bias. The authors disclosed none.

Copyright: © 2020 Walker et al. This is an open access article distributed in accordance with the terms of the Creative Commons Attribution (CC BY 4.0) License. See: <http://creativecommons.org/licenses/by/4.0/>

Secondary Syphilis

Sarah Ehlers, DO
Shane Sergent, DO
John Ashurst, DO, MSc

Kingman Regional Medical Center, Department of Emergency Medicine, Kingman, Arizona

Section Editor: Rick A. McPheeters, DO

Submission history: Submitted June 1, 2020; Revision received July 13, 2020; Accepted July 16, 2020

Electronically published October 20, 2020

Full text available through open access at http://escholarship.org/uc/uciem_cpem

DOI: 10.5811/cpem.2020.7.48515

Case Presentation: A 40-year-old male presented to the emergency department (ED) due to a diffuse body rash after a sexual encounter. Examination revealed a maculopapular rash that included the palms and soles of the feet bilaterally. A rapid plasma reagin was positive, and the patient was treated with 2.4 million units of benzathine benzylpenicillin intramuscularly.

Diagnosis: Secondary syphilis can mimic many disease processes but classically presents as a painless macular rash on the palms of the hands and soles of the feet. Diagnosis is based upon clinical examination coupled with serological testing. Emergency department management should include 2.4 million units of benzathine benzylpenicillin intramuscularly and mitigation strategies. [Clin Pract Cases Emerg Med. 2020;4(4):675–676.]

Keywords: *Syphilis; secondary syphilis.*

CASE PRESENTATION

A 40-year-old male presented to the emergency department due to a diffuse body rash that occurred several weeks earlier. He noted that several weeks prior to the rash developing he was involved in a group sexual encounter and did not use barrier protection. Examination revealed a diffuse maculopapular rash that included the palms and soles of the feet bilaterally (Image). A rapid plasma regain (RPR) was positive, and the patient recalled that he had a painless lesion on the shaft of his penis before the rash developed. The patient was treated with 2.4 million units of benzathine benzylpenicillin intramuscularly and admitted to the medical service for infectious disease consultation.

DISCUSSION

Over the last several decades there has been a sharp rise in the number of sexually transmitted illnesses across the United States. Syphilis is a genital ulcerative disease caused by the bacterium *Treponema pallidum* and has seen a 72.7% increase in the number of cases since 2013.¹ Secondary syphilis is the most commonly recognized manifestation of syphilis. The

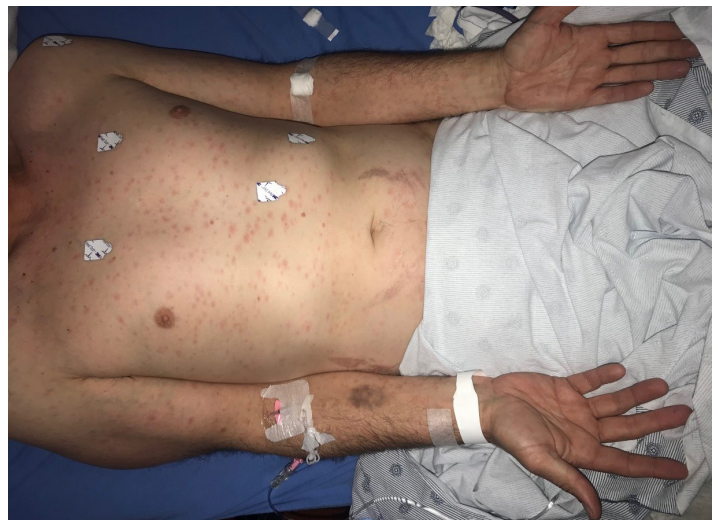

Image. Diffuse maculopapular rash involving the palms bilaterally indicative of secondary syphilis.

classic rash of secondary syphilis consists of painless, macular, reddish or copper-colored lesions on the palms of the hands or

soles of the feet but can be extremely variable.² Lesions can mimic other disease processes including pityriasis rosea, Rocky Mountain spotted fever, contact dermatitis, erythema multiforme, psoriasis, and drug eruptions. Non-cutaneous manifestations can include diffuse lymphadenopathy and hepatosplenomegaly that may mimic mononucleosis or Hodgkin's lymphoma. Serologic testing with RPR and venereal disease research laboratory tests are most commonly used to diagnosis the disease.² Treatment is 2.4 million units of benzathine benzylpenicillin intramuscularly, which may elicit a Jarisch-Herxheimer reaction.² Patients should be urged to abstain from sexual intercourse and discuss diagnostic strategies and treatment with their sexual partners.

The authors attest that their institution requires neither Institutional Review Board approval, nor patient consent for publication of this image in emergency medicine. Documentation on file.

Address for Correspondence: John Ashurst, DO, MSc, Kingman Regional Medical Center, Department of Emergency Medicine, 3269 Stockton Hill Road, Kingman, AZ 86409. Email: Ashurst.john.32.research@gmail.com.

Conflicts of Interest: By the *CPC-EM* article submission agreement, all authors are required to disclose all affiliations, funding sources and financial or management relationships that could be perceived as potential sources of bias. The authors disclosed none.

Copyright: © 2020 Ehlers et al. This is an open access article distributed in accordance with the terms of the Creative Commons Attribution ([CC BY 4.0](http://creativecommons.org/licenses/by/4.0/)) License. See: <http://creativecommons.org/licenses/by/4.0/>

CPC-EM Capsule

What do we already know about this clinical entity?

There has been a sharp rise in the number of sexually transmitted illnesses annually with syphilis accounting for a 72.7% increase since 2013.

What is the major impact of the image(s)?

The classic rash of secondary syphilis are painless, macular, reddish or copper colored lesions on the palms or soles of the feet and is the most commonly recognized form of syphilis.

How might this improve emergency medicine practice?

Early recognition, diagnosis, and management can help prevent the spread of sexually transmitted illnesses.

REFERENCES

- Centers for Disease Control and Prevention. Sexually transmitted disease surveillance. 2017. Available at: <https://www.cdc.gov/std/stats17/default.htm>. Accessed June 1, 2020.
- Hook E. Syphilis. *Lancet*. 2017;389(10078):15-21.

**JOIN
CAL/AAEM!**



CALAAEM

CALIFORNIA CHAPTER DIVISION OF THE
AMERICAN ACADEMY OF EMERGENCY MEDICINE

*Championing
individual physician rights
and workplace fairness*

BENEFITS

- *Western Journal of Emergency Medicine* Subscription
- CAL/AAEM News Service email updates
- Discounted AAEM pre-conference fees
- And more!

CAL/AAEM NEWS SERVICE

- Healthcare industry news
- Public policy
- Government issues
- Legal cases and court decisions

In collaboration with our official journal

WestJEM Integrating Emergency Care
with Population Health




FACEBOOK.COM/CALAAEM



FOLLOW US @CALAAEM

[HTTP://WWW.CALAAEM.ORG](http://www.calaaem.org)



ADVANCED **ED** >

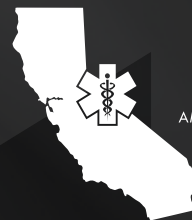SAVE THE DATE

> CALIFORNIA ACEP'S ANNUAL CONFERENCE 2021

Education is targeted to Medical Students and Residents, but all are welcome to attend.

Friday, September 10, 2021

Westin San Diego Gaslamp Quarter



CALIFORNIA ACEP
AMERICAN COLLEGE OF EMERGENCY PHYSICIANS