

# CPC Emergency Medicine

Volume V, Number 1, February 2021

Open Access at [www.cpcem.org](http://www.cpcem.org)

ISSN: 2474-252X

## *Clinical Practice and Cases in Emergency Medicine*

In Collaboration with the *Western Journal of Emergency Medicine*

### Clinicopathological Cases from the University of Maryland

- 1 **40-year-old Female with Sudden Onset Dyspnea**  
*Kebort BM, Hong AJ, Bontempo LJ, ZDW Dezman*

### Case Series

- 6 **Case Series of Patients with Opioid Use Disorder and Suicidal Ideation Treated with Buprenorphine**  
*Spaderna M, Bennett M, Arnold R, Weintraub E*
- 11 **E-cigarettes and Vaping, Product-use Associated Lung Injury: A Case Series of Adolescents**  
*Khan A, Parlette K, Kuntz HM*

### Case Reports

- 17 **Case Report of Thrombosis of the Distal Aorta with Occlusion of Iliac Arteries in COVID-19 Infection**  
*LaFree A, Lenz A, Tomaszewski C, Quenzer F*
- 22 **A Case Report of Cerebral Venous Thrombosis as a Complication of Coronavirus Disease 2019 in a Well-appearing Patient**  
*Logan M, Leonard K, Girzadas Jr D*
- 26 **COVID-19 Presenting as Encephalopathy in the Emergency Department: A Case Report**  
*Goodloe III TB, Walter LA*
- 30 **Where There's Smoke, There's Fire: A Case Report of Turbulent Blood Flow in Lower Extremity Point-of-care Ultrasound in COVID-19**  
*Nelson M, Shi D, Gordon M, Chavda Y, Grimaldi C, Bajaj T*
- 35 **A Case Report on Distinguishing Emphysematous Pyelitis and Pyelonephritis on Point-of-care Ultrasound**  
*Mazumder P, Al-Khouja F, Moeller J, Lahham S*
- 39 **Case Report: Using Point-of-care Ultrasound as a Tool to Identify a Urethral Foreign Body**  
*Frier J, Nicholas E, Klawitter P*

Contents continued on page iii



UC Irvine Health





**ACOEP stands with all emergency  
physicians and providers on the  
front line. We thank you for your  
tireless work and effort.**



[www.acoep.org](http://www.acoep.org)

# Clinical Practice and Cases in Emergency Medicine

Indexed in PubMed and full text in PubMed Central

**Rick A. McPheeters, DO, Editor-in-Chief**

Kern Medical/UCLA- Bakersfield, California

**Mark I. Langdorf, MD, MHPE, Senior Associate Editor**

University of California, Irvine School of Medicine- Irvine, California

**Shahram Lotfipour, MD, MPH, Senior Associate Editor**

University of California, Irvine School of Medicine- Irvine, California

**Shadi Lahham, MD, MS, Associate Editor**

University of California, Irvine School of Medicine- Irvine, California

**Manish Amin, DO, Associate Editor**

Kern Medical/UCLA- Bakersfield, California

**John Ashurst, DO, Decision Editor/ ACOEP Guest Editor**

Kingman Regional Health Network, Arizona

**Anna McFarlin, MD, Decision Editor**

Louisiana State University Health Science Center- New Orleans, Louisiana

**Austin Smith, MD, Decision Editor**

Vanderbilt University Medical Center-Nashville, Tennessee

**Christopher Sampson, MD, Decision Editor**

University of Missouri- Columbia, Missouri

**Joel Moll, MD, Decision Editor**

Virginia Commonwealth University School of Medicine- Richmond, Virginia

**Scott Goldstein, DO, Decision Editor**

Sidney Kimmel College of Medicine- Philadelphia, Pennsylvania

**Steven Walsh, MD, Decision Editor**

Einstein Medical Center Philadelphia-Philadelphia, Pennsylvania

**Melanie Heniff, MD, Decision Editor**

University of Indiana School of Medicine- Indianapolis, Indiana

**Gentry Wilkerson, MD, Decision Editor**

University of Maryland School of Medicine

## Editorial Board

Amin A. Kazzi, MD, MAAEM

The American University of Beirut, Beirut, Lebanon

Anwar Al-Awadhi, MD

Mubarak Al-Kabeer Hospital, Jabriya, Kuwait

Arif A. Cevik, MD

United Arab Emirates University  
College of Medicine and Health Sciences, Al Ain, United Arab Emirates

Abhinandan A. Desai, MD

University of Bombay Grant Medical College, Bombay, India

Bandr Mzahim, MD

King Fahad Medical City, Riyadh, Saudi Arabia

Barry E. Brenner, MD, MPH

Case Western Reserve University

Brent King, MD, MMM

University of Texas, Houston

Daniel J. Dire, MD

University of Texas Health Sciences Center San Antonio

David F.M. Brown, MD

Massachusetts General Hospital/Harvard Medical School

Edward Michelson, MD

Texas Tech University

Edward Panacek, MD, MPH

University of South Alabama

Erik D. Barton, MD, MBA

Icahn School of Medicine, Mount Sinai, New York

Francesco Dellacorte, MD

Azienda Ospedaliera Universitaria "Maggiore della Carità," Novara, Italy

Francis Counselman, MD

Eastern Virginia Medical School

Gayle Galletta, MD

Sorlandet Sykehus HF, Akershus Universitetssykehus, Lorenskog, Norway

Hjalte Björnsson, MD

Icelandic Society of Emergency Medicine

Jacob (Kobi) Peleg, PhD, MPH

Tel-Aviv University, Tel-Aviv, Israel

Jonathan Olshaker, MD

Boston University

Katsuhiko Kanemaru, MD

University of Miyazaki Hospital, Miyazaki, Japan

Khrongwong Musikatavorn, MD

King Chulalongkorn Memorial Hospital, Chulalongkorn University, Bangkok, Thailand

Leslie Zun, MD, MBA

Chicago Medical School

Linda S. Murphy, MLIS

University of California, Irvine School of Medicine Librarian

Nadeem Qureshi, MD

St. Louis University, USA  
Emirates Society of Emergency Medicine, United Arab Emirates

Niels K. Rathlev, MD

Tufts University School of Medicine

Pablo Aguilera Fuenzalida, MD

Pontificia Universidad Católica de Chile, Región Metropolitana, Chile

Peter A. Bell, DO, MBA

Liberty University  
College of Osteopathic Medicine

Peter Sokolove, MD

University of California, San Francisco

Robert M. Rodriguez, MD

University of California, San Francisco

Robert Suter, DO, MHA

UT Southwestern Medical Center

Robert W. Derlet, MD

University of California, Davis

Rosidah Ibrahim, MD

Hospital Serdang, Selangor, Malaysia

Samuel J. Stratton, MD, MPH

Orange County, CA, EMS Agency

Scott Rudkin, MD, MBA

University of California, Irvine

Scott Zeller, MD

University of California, Riverside

Steven Gabaeff, MD

Clinical Forensic Medicine

Steven H. Lim, MD

Changi General Hospital, Simei, Singapore

Terry Mulligan, DO, MPH, FIFEM

ACEP Ambassador to the Netherlands Society of Emergency Physicians

Vijay Gautam, MBBS

University of London, London, England

Wirachin Hoonpongmanont, MD, MSBATS

Stirraj Hospital, Mahidol University, Bangkok, Thailand

## Advisory Board

Amal Khalil, MBA

UC Irvine Health School of Medicine

Elena Lopez-Gusman, JD

California ACEP  
American College of Emergency Physicians

Adam Levy, BS

American College of Osteopathic Emergency Physicians

John B. Christensen, MD

California Chapter Division of AAEM

Lori Winston, MD

California ACEP  
American College of Emergency Physicians  
Kaweah Delta Healthcare District

Mark I. Langdorf, MD, MHPE

UC Irvine Health School of Medicine

Jorge Fernandez, MD

California ACEP  
American College of Emergency Physicians  
University of California, San Diego

Peter A. Bell, DO, MBA

American College of Osteopathic Emergency Physicians  
Liberty University, College of Osteopathic Medicine

Robert Suter, DO, MHA

American College of Osteopathic Emergency Physicians  
UT Southwestern Medical Center

Shahram Lotfipour, MD, MPH

UC Irvine Health School of Medicine

Brian Potts, MD, MBA

California Chapter Division of AAEM  
Alta Bates Summit-Berkeley Campus

## Editorial Staff

Leila Danishgar, BS

Editorial Director

Nicholas Gossett, BS

CPC-EM Associate Editorial Director  
Associate Marketing Director

Maria Nguyen, BS

WestJEM Associate Editorial Director

June Casey, BA

Copy Editor

Alissa Fiorentino, BA

WestJEM Staff Liaison

Cassandra Saucedo, BS

CPC-EM Publishing Director

Ishan Shah, BS

CPC-EM Associate Publishing Director  
Associate Marketing Director

Christine Louis, BS

WestJEM Publishing Director

Isabelle Nepomuceno, BS  
WestJEM Associate Publishing Director  
Associate Marketing Director

Official Journal of the California Chapter of the American College of Emergency Physicians, the American College of Osteopathic Emergency Physicians, and the California Chapter of the American Academy of Emergency Medicine



Available in MEDLINE, PubMed, PubMed Central, Google Scholar, eScholarship, DOAJ, and OASPA.

Editorial and Publishing Office: WestJEM/Department of Emergency Medicine, UC Irvine Health, 333 City Blvd, West, Rt 128-01, Orange, CA 92866, USA

Office: 1-714-456-6389; Email: Editor@westjem.org

# Clinical Practice and Cases in Emergency Medicine

Indexed in PubMed and full text in PubMed Central

This open access publication would not be possible without the generous and continual financial support of our society sponsors, department and chapter subscribers.

## Professional Society Sponsors

AMERICAN COLLEGE OF OSTEOPATHIC EMERGENCY PHYSICIANS  
CALIFORNIA ACEP

CALIFORNIA CHAPTER DIVISION OF  
AMERICAN ACADEMY OF EMERGENCY MEDICINE

## Academic Department of Emergency Medicine Subscribers

Albany Medical College Albany, NY	INTEGRIS Health Oklahoma City, OK	Robert Wood Johnson University Hospital New Brunswick, NJ	University of Florida, Jacksonville Jacksonville, FL
American University of Beirut Beirut, Lebanon	Kaweah Delta Health Care District Visalia, CA	Rush University Medical Center Chicago, IL	University of Illinois at Chicago Chicago, IL
Arrowhead Regional Medical Center Colton, CA	Kennedy University Hospitals Turnersville, NJ	Southern Illinois University Carbondale, IL	University of Illinois College of Medicine Peoria, IL
Augusta University Augusta GA	Kern Medical Bakersfield, CA	St. Luke's University Health Network Bethlehem, PA	University of Iowa Iowa City, IA
Baystate Medical Center Springfield, MA	Lakeland HealthCare St. Joseph, MI	Stanford/Kaiser Emergency Medicine Residency Program Stanford, CA	University of Louisville Louisville, KY
Beaumont Hospital Royal Oak, MI	Lehigh Valley Hospital and Health Network Allentown, PA	Staten Island University Hospital Staten Island, NY	University of Maryland Baltimore, MD
Beth Israel Deaconess Medical Center Boston, MA	Loma Linda University Medical Center Loma Linda, CA	SUNY Upstate Medical University Syracuse, NY	University of Michigan Ann Arbor, MI
Boston Medical Center Boston, MA	Louisiana State University Health Sciences Center New Orleans, LA	Temple University Philadelphia, PA	University of Missouri, Columbia Columbia, MO
Brigham and Women's Hospital Boston, MA	Madigan Army Medical Center Tacoma, WA	Texas Tech University Health Sciences Center El Paso, TX	University of Nebraska Medical Center Omaha, NE
Brown University Providence, RI	Maimonides Medical Center Brooklyn, NY	University of Alabama, Birmingham Birmingham, AL	University of South Alabama Mobile, AL
Carl R. Darnall Army Medical Center Fort Hood, TX	Maricopa Medical Center Phoenix, AZ	University of Arkansas for Medical Sciences Little Rock, AR	University of Southern California/Keck School of Medicine Los Angeles, CA
Conemaugh Memorial Medical Center Johnstown, PA	Massachusetts General Hospital Boston, MA	University of California, Davis Medical Center Sacramento, CA	University of Tennessee, Memphis Memphis, TN
Desert Regional Medical Center Palm Springs, CA	Mayo Clinic College of Medicine Rochester, MN	University of California Irvine Orange, CA	University of Texas, Houston Houston, TX
Doctors Hospital/Ohio Health Columbus, OH	Mt. Sinai Medical Center Miami Beach, FL	University of California, Los Angeles Los Angeles, CA	University of Texas Health San Antonio, TX
Eastern Virginia Medical School Norfolk, VA	North Shore University Hospital Manhasset, NY	University of California, San Diego La Jolla, CA	University of Warwick Library Coventry, United Kingdom
Einstein Healthcare Network Philadelphia, PA	Northwestern Medical Group Chicago, IL	University of California, San Francisco San Francisco, CA	University of Washington Seattle, WA
Emory University Atlanta, GA	Ohio State University Medical Center Columbus, OH	UCSF Fresno Center Fresno, CA	University of Wisconsin Hospitals and Clinics Madison, WI
Genesys Regional Medical Center Grand Blanc, Michigan	Ohio Valley Medical Center Wheeling, WV	University of Chicago, Chicago, IL	Wake Forest University Winston-Salem, NC
Hartford Hospital Hartford, CT	Oregon Health and Science University Portland, OR	University of Colorado, Denver Denver, CO	Wright State University Dayton, OH
Hennepin County Medical Center Minneapolis, MN	Penn State Milton S. Hershey Medical Center Hershey, PA	University of Florida Gainesville, FL	
Henry Ford Hospital Detroit, MI	Presence Resurrection Medical Center Chicago, IL		

## State Chapter Subscribers

ARIZONA CHAPTER DIVISION OF THE  
AMERICAN ACADEMY OF EMERGENCY MEDICINE  
CALIFORNIA CHAPTER DIVISION OF THE  
AMERICAN ACADEMY OF EMERGENCY MEDICINE  
FLORIDA CHAPTER DIVISION OF THE  
AMERICAN ACADEMY OF EMERGENCY MEDICINE

GREAT LAKES CHAPTER DIVISION OF THE  
AMERICAN ACADEMY OF EMERGENCY MEDICINE  
TENNESSEE CHAPTER DIVISION OF THE  
AMERICAN ACADEMY OF EMERGENCY MEDICINE

UNIFORMED SERVICES CHAPTER DIVISION OF THE  
AMERICAN ACADEMY OF EMERGENCY MEDICINE  
VIRGINIA CHAPTER DIVISION OF THE  
AMERICAN ACADEMY OF EMERGENCY MEDICINE

## International Society Partners

EMERGENCY MEDICINE ASSOCIATION OF TURKEY  
LEBANESE ACADEMY OF EMERGENCY MEDICINE  
MEDITERRANEAN ACADEMY OF EMERGENCY MEDICINE

NORWEGIAN SOCIETY FOR EMERGENCY MEDICINE  
SOCIEDAD ARGENTINA DE EMERGENCIAS

SOCIEDAD CHILENO MEDICINA URGENCIA  
THAI ASSOCIATION FOR EMERGENCY MEDICINE

To become a *WestJEM* departmental sponsor, waive article processing fee, receive print and copies for all faculty and electronic for faculty/residents, and free CME and faculty/fellow position advertisement space, please go to <http://westjem.com/subscribe> or contact:

Alissa Fiorentino  
*WestJEM* Staff Liaison  
Phone: 1-800-884-2236  
Email: [sales@westjem.org](mailto:sales@westjem.org)

## JOURNAL FOCUS

*Clinical Practice and Cases in Emergency Medicine* (CPC-EM) is a MEDLINE-indexed internationally recognized journal affiliated with the *Western Journal of Emergency Medicine* (WestJEM). It offers the latest in patient care case reports, images in the field of emergency medicine and state of the art clinicopathological and medicolegal cases. CPC-EM is fully open-access, peer reviewed, well indexed and available anywhere with an internet connection. CPC-EM encourages submissions from junior authors, established faculty, and residents of established and developing emergency medicine programs throughout the world.

## Table of Contents *continued*

- 43 **Peer Pressure = Explosive Consequences: A Case Report of Toxic Ingestion of Cyclonite (C-4) Explosive on a Dare**  
*JD Whitesides, N Turner, S Watts, SA Watkins*
- 47 **Moyamoya as a Cause of Altered Mental Status in the Emergency Department: A Case Report**  
*M West, E Dearing*
- 50 **Human Zinc Phosphide Exposure in Lebanon: A Case Report and Review of the Literature**  
*H Hamade, A Sahin, C Sukhn, C El Tawil, J Rizk, Z Kazzi, T El Zahran*
- 58 **Case Report: Subcutaneous Emphysema and Pneumomediastinum Following Dental Extraction**  
*RM Brzyck*
- 62 **Young Man with Cardiac Arrest Secondary to Undiagnosed Mediastinal Mass: A Case Report**  
*I Mallett, B Watsjold, AK Chipman*
- 66 **Rare Complications of Acute Appendicitis: A Case Report**  
*N Kurtzman, J Adler, A Ketterer, J Lewis*
- 70 **Mediastinitis Secondary to Peripherally Inserted Central Catheter Migration and Perforation after Minor Trauma: A Case Report**  
*O Martinez, J Puller*
- 75 **A Case Report of Ring Avulsion Injury: Under-recognized for Its Unique Implications in Transfer**  
*A Horn, B Freniere, AY Sheng*
- 79 **Recurrent Bell's Palsy During Takeoff on a Commercial Flight: A Case Report**  
*G Galletta*
- 82 **Testicular Torsion in Monorchism Diagnosed with Point-of-care Ultrasound: A Case Report**  
*C Correa, S Onishi, E Abrams*
- 85 **Blunt Chest Trauma Causing a Displaced Sternal Fracture and ST-elevation Myocardial Infarction: A Case Report**  
*K Nasser, J Matsuura, J Diep*
- 89 **Unmasking Long QT Syndrome in the Emergency Department: A Case Report**  
*E Leslie, A Medenbach, E Pittman*
- 93 **Point-of-care Ultrasound for Suspected Pectoralis Major Rupture: A Case Report**  
*N Franks, J Gress, R Joseph*

Policies for peer review, author instructions, conflicts of interest and human and animal subjects protections can be found online at [www.cpcem.org](http://www.cpcem.org).

## Table of Contents *continued*

- 97 **Septic Malleolar Bursitis in a Patient with an Ankle Electronic Monitoring Device: A Case Report**  
*B Besinger, S Ryckman*
- 101 **Hyperhemolysis Syndrome in a Patient with Sickle Cell Disease: A Case Report**  
*JA Kalter, R Gupta, MR Greenberg, AJ Miller, J Allen*
- 105 **Don't Forget the Flu – Determining the Etiology of Infective Myositis in a Child: A Case Report**  
*LM Crowley, RJ Mazzaccaro, AL Dunn, SE Bauch, MR Greenberg*
- 109 **A Case Report of Pediatric Ovarian Torsion: The Importance of Diagnostic Laparoscopy**  
*A Corre, S Dandekar, C Lau, L Ranasinghe*
- 113 **Complication of Hepatitis A Infection: Case Report of Acute Inflammatory Demyelinating Polyneuropathy**  
*D Laursen, J Krug, R Wolford*
- 117 **Case Report: Bilateral Ultrasound-guided Serratus Anterior Plane Blocks for a Chest Wall Burn**  
*T Benesch, D Mantuani, A Nagdev*
- Images in Emergency Medicine**
- 121 **Penile Dorsal Vein Rupture Identified by Emergency Department Ultrasound**  
*SE Scott, R Langenohl, T Crisostomo-Wynne, C Kang*
- 123 **New Onset Nystagmus in a Patient with Multiple Sclerosis**  
*S Daugherty, B King, M Milliron, JN Carlson*
- 125 **A Young Boy with Fever and Grunting**  
*DJ Shapiro, JT Neal*
- 127 **Abdominal Pain in the Elderly Patient: Point-of-care Ultrasound Diagnosis of Small Bowel Obstruction**  
*A Hussein, A Arena, C Yu, A Cirilli, E Kurkowski*
- 129 **A Piercing Diagnosis – Occult Foreign Body as the Cause of Acute Inguinal Pain**  
*C Bays-Muchmore, DT Sims, JA Gross, JS Ilgen*
- 131 **Male with Altered Mental Status**  
*J Kondrat, B Ilyaguyev, J Stern, T Choe, J Greenstein, B Hahn*

*Clinical Practice and Cases in Emergency Medicine* (CPC-EM) is a open-access Medline-indexed internationally recognized journal affiliated with the *Western Journal of Emergency Medicine* (WestJEM). CPC-EM is distributed electronically to 19,000 emergency medicine scholars. This includes our sponsors California ACEP, the American College of Osteopathic Emergency Physicians, California Chapter of AAEM, and over 83 academic department of emergency medicine subscribers and 8 AAEM State Chapters.

# CPCEM Clinical Practice & Cases

## CALL FOR SUBMISSIONS

-Patient Care Case Reports

-Images In Emergency Medicine

Fully open-access, peer reviewed, well indexed: CPC-EM is available anywhere with an internet connection at [CPCEM.org](http://CPCEM.org)

*Clinical Practice and Cases in Emergency Medicine* is an internationally recognized journal affiliated with the MEDLINE-indexed *Western Journal of Emergency Medicine*

CPC-EM encourages submissions from junior authors and countries with developing emergency medicine programs

## IS NO DISABILITY INSURANCE A RISK YOU'RE WILLING TO TAKE?

COVID-19 HAS INCREASED THE RISKS OF PRACTICING EMERGENCY MEDICINE

## LET US PROTECT YOUR LIFESTYLE

- EMERGENCY MEDICINE SPECIFIC POLICIES
- MAJOR DISABILITY & LIFE INSURANCE COMPANIES
- DISCOUNTS AVAILABLE INCLUDING MILITARY & FEDERAL
- NO MEDICAL EXAM REQUIRED
- CURRENT POLICY CHECKUP

 **DI 4 MDS**  
DISABILITY INSURANCE SPECIALISTS  
30+ YEARS OF EXPERIENCE

**CONTACT NOW**

## 40-year-old Female with Sudden Onset Dyspnea

Breanna M. Kebort, MD\*

Aleta J. Hong, MD<sup>†</sup>

Laura J. Bontempo, MD, MEd<sup>‡</sup>

Zachary D.W. Dezman, MD, MS, MS<sup>‡</sup>

\*University of Maryland Medical Center, Department of Emergency Medicine, Baltimore, Maryland

<sup>†</sup>University of Massachusetts Medical School, Department of Emergency Medicine, Worcester, Maryland

<sup>‡</sup>University of Maryland School of Medicine, Department of Emergency Medicine, Baltimore, Maryland

Section Editor: Joel Moll, MD

Submission history: Submitted September 11, 2020; Revision received October 15, 2020; Accepted October 16, 2020

Electronically published December 28, 2020

Full text available through open access at [http://escholarship.org/uc/uciem\\_cpem](http://escholarship.org/uc/uciem_cpem)

DOI: 10.5811/cpem.2020.10.49781

A 40-year-old female presented to the emergency department (ED) after the acute onset of dyspnea. The patient was tachypneic with accessory muscle usage and diffuse wheezing on initial examination. Despite aggressive treatment, the patient deteriorated and was intubated. This case takes the reader through the differential diagnosis and systematic workup of a patient presenting to the ED with dyspnea and arrives at the unexpected cause for this patient's presentation. [Clin Pract Cases Emerg Med. 2021;5(1):1–5.]

**Keywords:** *Dyspnea; adenoid cystic carcinoma; CPC.*

### CASE PRESENTATION (DR. KEBORT)

A 40-year-old female presented to the emergency department (ED) with sudden onset dyspnea. She stated she had been having progressive shortness of breath over two weeks that worsened acutely just prior to her presentation. The patient also reported a cough productive of yellow/brown mucus over the same time course.

The patient had a past medical history of severe persistent asthma for which she was on multiple inhalers including albuterol sulfate, fluticasone/vilanterol, tiotropium bromide, and ipratropium bromide. She also had a history of seasonal allergies for which she was on dexamethasone nasal spray, fluticasone nasal spray, levocetirizine, ranitidine, and montelukast. She had been using these regularly during her illness with no improvement in symptoms. She recently saw her pulmonologist who found that she had elevated peripheral eosinophils in her blood work and started her on her first injection of mepolizumab.

In addition to asthma, the patient had a medical history of gastroesophageal reflux for which she took pantoprazole, hypertension for which she took losartan, and depression for which she took fluoxetine. She had no surgical history. The patient was a former smoker who had quit nine years earlier. She denied any illicit drug use and reported only social alcohol use. She worked as a nurse at the same location for

the prior three years. Her only allergies were to escitalopram and lettuce.

On arrival to the ED, the patient was noted to be in significant respiratory distress with increased work of breathing. She was afebrile (37.5° Celsius) with a heart rate of 135 beats per minute, a respiratory rate of 38 breaths per minute, an oxygen saturation of 100% on room air, and a blood pressure of 160/98 millimeters of mercury. She weighed 88.9 kilograms (kg) and was five feet, five inches in height with a body mass index of 32.6 kg/meter<sup>2</sup>. She was well developed and well nourished. Her head was normocephalic and atraumatic with moist mucous membranes, a clear oropharynx with no uvular edema, tonsillar enlargement or audible stridor. Her neck was supple with no tender lymphadenopathy, and her trachea was midline. She was tachycardic but had a regular rhythm with no murmurs, rubs, or gallops. She was tachypneic and had accessory muscle usage with diffuse wheezing, greatest at the bases. Her abdomen was obese but soft and nontender. She had trace lower extremity edema bilaterally with normal dorsalis pedis pulses. Her lower extremities had no asymmetry or calf tenderness. She had a Glasgow Coma Scale score of 15 with no motor or sensory deficits.

An electrocardiogram was performed, which showed sinus tachycardia with a normal axis, normal intervals, and no

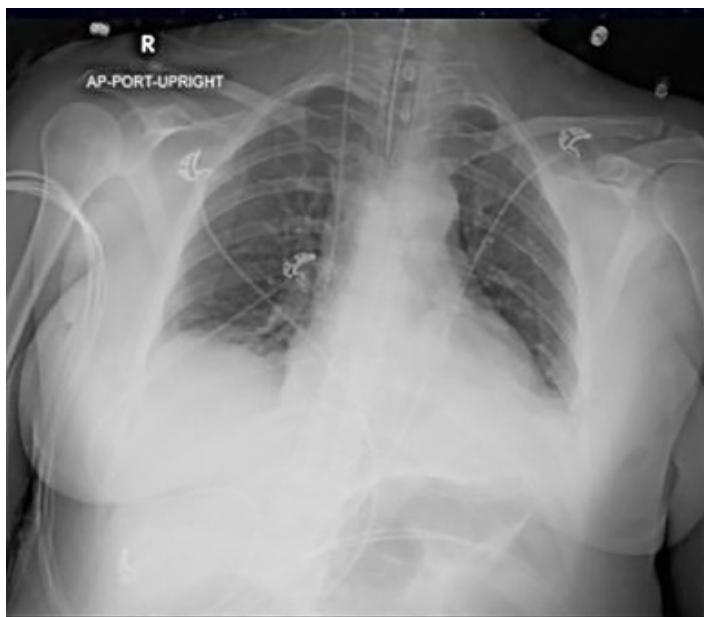
ST-segment or T-wave changes. Her chest radiography (CXR) is shown (Image 1). Her initial laboratory results are shown in Tables 1 and 2.

The patient received inhaled albuterol 0.083% 5 milligrams (mg) and ipratropium 500 micrograms with 2 grams of intravenous magnesium and solumedrol 125 mg in the ED without significant improvement and with increasing fatigue and declining mental status. Approximately one hour after her arrival to the ED, the patient was intubated using ketamine and rocuronium for presumed status asthmaticus without complication. She was started on broad spectrum antibiotics due to concern for possible pneumonia given her failure to improve. She was admitted to the intensive care unit (ICU). A test was then done that revealed the diagnosis.

### CASE DISCUSSION (DR. HONG)

In this case, a 40-year-old obese female with a history of asthma presented to the ED with difficulty breathing and wheezing. As I read through the case, I was struck by how it served as a valuable reminder that we need to keep our differentials broad, even when the presentation may initially seem clear.

Asthma is a common disease, and as emergency physicians we care for patients with wheezing on a near-daily basis and tend to follow a formulaic treatment pathway, generally with positive results. However, deep down we know that there are more causes to wheezing than just asthma and chronic obstructive pulmonary disease (COPD). It is crucial that whenever we care for a patient who is not improving with standard treatments we step back and reassess our plan, including expanding our differential diagnosis. This is



**Image 1.** Chest radiograph of a 40-year-old female with sudden onset dyspnea.

**Table 1.** Complete blood cell count, serum chemistry and coagulation studies of a 40-year-old female with sudden onset dyspnea.

Blood test	Patient value	Normal range
<b>Complete Blood Count</b>		
White Blood Cells	12.2 K/mcL	4.5 - 11.0 K/mcL
Hemoglobin	11.5 g/dL	12.6 - 17.4 g/dL
Hematocrit	40.4%	37.0 - 50.0%
Platelets	338 K/mcL	153 - 367
<b>Differential</b>		
Polymorphonuclear leukocytes	90.4%	42-75%
Lymphocytes	2.0%	20-50%
Monocytes	6.4%	2-10%
Eosinophils	0.1%	1-3%
<b>Serum chemistries</b>		
Sodium	138 mmol/L	136-145 mmol/L
Potassium	3.8 mmol/L	3.5-5.1 mmol/L
Chloride	104 mmol/L	98-107 mmol/L
Bicarbonate	26 mmol/L	21-30 mmol/L
Blood Urea Nitrogen	10 mg/dL	7-20 mg/dL
Creatinine	0.75 mg/dL	0.66-1.25 mg/dL
Glucose	249 mg/dL	70-99 mg/dL
Magnesium	2.2 mg/dL	1.6-2.6 mg/dL
Phosphorus	3.3 mg/dL	2.5-4.5 mg/dL
Total Protein	5.5 g/dL	6.3-8.2 g/dL
Albumin	3.1 g/dL	3.5-5.2 g/dL
Total Bilirubin	0.3 mg/dL	0.3-1.2 mg/dL
Aspartate Aminotransferase	13 u/L	17-59 u/L
Alanine Aminotransferase	24 u/L	21-72 u/L
Alkaline Phosphatase	49 u/L	38-126 u/L
Lactic Acid	0.9 mmol/L	0.5-1 mmol/L
<b>Coagulation Studies</b>		
Prothrombin Time	13.3 s	10.8-13.3 s
Partial Thromboplastin Time	23.3 s	31.4-48.0 s
International Normalized Ratio	1.1	

K, thousand; mcL, microliter; g, grams; dL, deciliter; mmol, millimole; L, liter; mg, milligrams; u, units; s, seconds.

important even when a patient's presentation seems as though it should be straightforward.

After reading the case presentation, my immediate concern for the patient was her severe respiratory distress complicated by respiratory failure requiring intubation. The physical exam was concerning for impending respiratory failure due to fatigue, and the ED team took the appropriate course of action in intubating the patient prior to

**Table 2.** Venous blood gas of 40-year-old female with sudden onset dyspnea.

	Patient value	Normal range
pH	7.30	7.31-7.41
pCO <sub>2</sub>	51 mm Hg	41-51 mm Hg
pO <sub>2</sub>	108 mm Hg	36-42 mm Hg
HCO <sub>3</sub>	29 mmol/L	23-29 mmol/L

pH, potential of hydrogen; mm Hg, millimeters mercury; pCO<sub>2</sub>, partial pressure of carbon dioxide; pO<sub>2</sub>, partial pressure of oxygen; HCO<sub>3</sub>, bicarbonate.

decompensation. As emergency clinicians we must never forget the basics of resuscitation and the need to address our ABCs in emergency medicine.

In this case the patient had a history a severe persistent asthma for which she was on multiple medications including short-acting and long-acting beta-agonists; inhaled corticosteroids; montelukast; and she had recently been started on mepolizumab, an interleukin-5 antagonist immunomodulator used in more severe cases of eosinophilic asthma.<sup>1</sup> Despite her disease severity, a two-week course of symptoms with acute worsening in the setting of medication compliance struck me as unusual. A productive cough combined with minimal response to advanced asthma treatments suggested that her wheezing and respiratory failure was not caused by her asthma alone and that there was another process at play.

At this point I felt I needed to take a step back and reconsider the information I had been presented. Although the patient was noted to be tachypneic on exam with increased work of breathing, her oxygen saturation was 100% on room air and her venous blood gas pH of 7.36 showed no acidosis, both unusual for an asthma exacerbation severe enough to require intubation. Her partial pressure of carbon dioxide (pCO<sub>2</sub>) was elevated, but the lack of acidosis suggested a more chronic process as the cause of her respiratory failure rather than a severe acute asthma exacerbation. As I considered the many causes of wheezing, I eliminated diagnoses based on the information available.

While there are many causes of wheezing, there are some that could be quickly ruled out based on the patient's history and physical exam. The physical exam did not note any goiter, or enlargement or asymmetry of the neck. Tonsillar hypertrophy, vascular rings, and bronchiolitis were all unlikely causes of wheezing in an adult. As the patient had no history of recent surgery or intubations and had no history of chronic upper airway inflammation, I reasoned that tracheal stenosis, tracheomalacia, and mucous plugging were unlikely to be the cause of the patient's wheezing. Vocal cord edema was unlikely as the patient had no stridor or history of voice changes, and, per the ED course she was intubated without any issue.

Given the two-week duration of symptoms and lack of any pertinent history, I removed anaphylaxis from the

differential. I also felt that a foreign body was unlikely to be the cause of the patient's symptoms. While it is possible to have a foreign body present for a prolonged period these are usually small and unlikely to eventually cause acute severe airway compromise. The excellent social history provided by the medical team helped rule out occupational exposures such as bird feces, farming chemicals, or silicosis.

Besides the blood gas, the patient's laboratory studies did not offer insight into the cause of her symptoms. The CXR was overall unremarkable with the exception of the correct placement of the endotracheal tube. While not diagnostic, I would have expected a patient with respiratory failure due to asthma or COPD to have more hyperinflated lungs than seen on this CXR. There was no sign of a focal infiltrate suggestive of an infectious cause such as bacterial pneumonia or aspergillosis. There were no signs of pulmonary edema on imaging. Given the patient's lack of history of heart failure I felt comfortable ruling out cardiac causes as the reason for her wheezing. While not a common cause of wheezing, I considered pulmonary embolism (PE) as the patient was tachypneic, tachycardic, and in respiratory distress. Using the revised Geneva score she would be in the moderate risk group, warranting a D-dimer. However, she was neither hypoxic nor hypotensive, unusual for a PE large enough to cause such a significant degree of respiratory failure. Further workup for a PE was therefore not pursued.

At this point I was left with a handful of diagnoses: tumor; autoimmune causes such as eosinophilic granulomatous polyangiitis (EGPA); and infectious causes primarily from pulmonary parasitic infections. While the patient's history of asthma put her at higher risk for autoimmune diseases like EGPA, she lacked the characteristic extrapulmonary findings such as rash, granulomatous skin lesions, nasal polyps, or recurrent sinusitis.<sup>2,3</sup> Her elevated eosinophil count made pulmonary parasitic infections such as Löffler's syndrome more likely. Löffler's syndrome can present insidiously, but the reticulonodular pulmonary opacities typically associated with the disease were not seen on this patient's CXR. This disease is also rare in the United States, and most of the reported cases are associated with rural living.<sup>4</sup> All in all, I felt that Löffler's syndrome would be unlikely.

It can be challenging to narrow a broad differential diagnosis down to a single diagnosis. However, the patient's smoking history gave me pause as smoking is an independent risk factor for all types of head and neck cancers.<sup>5,6</sup> These cancers often slowly grow in size and can cause both wheezing and severe respiratory distress, depending on their location. After considering a broad differential of potential causes of wheezing, I determined the patient likely had local neck pathology causing an obstruction of the trachea.

If I were the treating physician, I would obtain a computed tomography (CT) of the soft tissue of the neck and chest with intravenous contrast to evaluate for an obstructive mass, most likely in the trachea.

### CASE OUTCOME (DR. KEBORT)

After failing to be weaned off the ventilator despite trials of antibiotics, nebulizers, furosemide, terbutaline, and aminophylline, additional imaging was done. The diagnostic study was a CT of the chest. As read by the radiologist, there was a soft tissue mass involving the carina projecting into the lumen of the distal trachea measuring approximately two cubic centimeters (cm) (Image 2) for which direct visualization was recommended. Rigid bronchoscopy showed a large tracheal tumor, which was extensively debulked (Image 3).

The patient was extubated two days after debulking. Her final pathology showed adenoid cystic carcinoma. She had a positron emission tomography (PET) revealing no metastases. Repeat bronchoscopy performed approximately one month later revealed tumor involvement extending two cm from the main carina into the proximal left mainstem bronchus as well as the proximal opening of the bronchus intermedius and into the distal trachea; no lymph nodes sampled were positive for malignant involvement. The patient was deemed to not be a surgical candidate given the extensive airway involvement. She underwent concurrent chemoradiation with weekly carboplatin and paclitaxel as well as proton radiation therapy. Her follow-up CT imaging showed stable irregularity along the tracheal bifurcation with

post-radiation changes. She gets repeat CT imaging every three months for continued surveillance.

### RESIDENT DISCUSSION

Primary tracheal tumors are exceedingly rare as the majority of tumors found in the trachea are due to invasion from local tissues including lung, esophagus, or thyroid. In total, primary tracheal tumors account for less than 0.1% of all malignant tumors.<sup>7</sup> In adults, more than 80% of these primary tracheal tumors are malignant.<sup>8</sup> Multiple studies show malignant tracheal tumors are more likely to occur in males and usually in the fifth or sixth decades of life.<sup>9</sup>

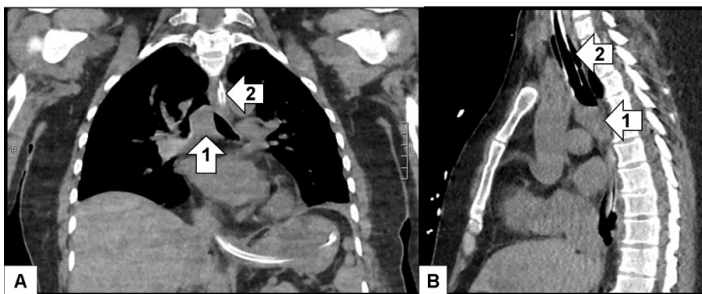The most common types of malignant tracheal tumors include squamous cell carcinoma (SCC), adenoid cystic carcinoma (ACC), and carcinoid tumors. Cigarette smoking is a common risk factor for the development of SCC, known to be a fast-growing malignancy. With SCC, the tumor can grow into the mucosa, which can lead to bleeding within the trachea and hemoptysis. ACC has less of a potential to invade the mucosa with bleeding occurring significantly less often.<sup>7</sup>

Despite differences in histology, these malignant tumors present in a similar way with symptoms of airway obstruction being by far the most common. However, these symptoms do not usually occur until at least 50% of the airway is occluded, which can lead to a significant delay in diagnosis. SCC is typically diagnosed within four to six months of initial symptom onset with the most common presentation of hemoptysis, occurring in about 60% of patients with SCC, given its ability to invade the mucosa.<sup>10</sup> ACC is not diagnosed until an average of 18 months after symptom onset, commonly being misdiagnosed as adult onset asthma due to its overlapping of symptoms of dyspnea on exertion and wheezing.<sup>7,8</sup>

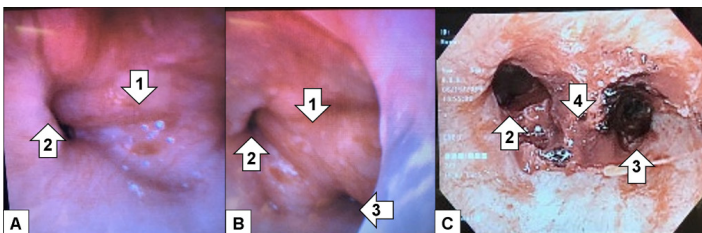
The ED workup, as with any patient with new respiratory symptoms, includes a CXR. In addition to identifying lung pathology, the CXR can evaluate for any significant tracheal narrowing. Sensitivity of a CXR is poor with a sensitivity of only 66% when there is a known tracheal mass and can be as low as 20% without a known diagnosis as tracheal tumors can be easily overlooked.<sup>11</sup> A CT of the chest is usually the next diagnostic step. This can depict the area of obstruction, degree of stenosis, vascular involvement, as well as identify any surrounding lymphadenopathy.<sup>10</sup>

If a tracheal mass is identified on CT imaging, the next diagnostic step is a bronchoscopy for histologic testing and confirmation.<sup>12</sup> After tissue sampling, PET scans are typically performed for staging of the malignancy although there is no widely accepted staging system in place for tracheal tumors.<sup>8</sup>

Initial management in the ED most importantly included management of the patient's airway. A smaller-bore endotracheal tube than is typically used in the ED should be selected to prevent a forceful, traumatic airway or inability to pass the endotracheal tube. Steroids do not play a beneficial role in airway obstruction in the setting of tracheal tumors and



**Image 2.** Coronal (A) and sagittal (B) computed tomography of the chest without contrast of a 40-year-old female with dyspnea showing a mass at the carina (1). (Trachea with endotracheal tube [2] is marked to orient the reader.)



**Image 3.** Bronchoscopy images (A, B) of a 40-year-old female with dyspnea showing the carinal mass (1), and the left (2) and right (3) main bronchi. Post-surgical bronchoscopy (C) shows improved cross-sectional diameter of the left (2) and right (3) main bronchi, as well as the area of the resection (4).

are therefore not recommended. If a patient had previously been misdiagnosed with asthma and was previously being treated with steroids, these should be discontinued prior to any possible resection.<sup>11</sup>

The main treatment for all types of tracheal malignancies includes resection. However, the maximum length of tissue resection in a trachea is five cm, potentially limiting the full ability to resect it depending on the extent of the tumor. Additional contraindications to surgical resection of these malignancies include multiple confirmed positive lymph nodes, involvement of greater than 50% the length of the trachea, mediastinal invasion of unresectable organs, and distant metastases.<sup>7</sup> Approximately 50-70% of patients will have resectable disease at their time of diagnosis.<sup>9</sup> Chemoradiation may be offered in some cases. However, there is a dearth of data regarding its role in treatment of tracheal tumors. At this time, a similar approach is taken to tracheal tumors as those of other tumors with head and neck origin with administration of cisplatin every 21 days along with radiation.<sup>9</sup> For tumors that are unresectable, rigid bronchoscopy may be performed with laser partial resection or placement of stents, however only as a palliative approach.

The strongest prognostic factor for these patients is the degree of resectability. Squamous cell carcinoma has a worse prognosis with a five-year survival of only 13%. Despite ACC being diagnosed usually significantly later than SCC, with its relatively slow growth and more prolonged course, patients with these tumors have an increased five-year survival of 74%.<sup>13</sup>

## FINAL DIAGNOSIS

Tracheal adenoid cystic carcinoma, complicated by respiratory failure.

## KEY TEACHING POINTS

- When a patient with dyspnea is not improving with standard treatments, reevaluate and reconsider your differential diagnosis.
- Symptoms of tracheal obstruction, such as from a tumor, typically do not present until approximately half of the airway is occluded, which can lead to a delay in diagnosis.
- Initial testing for a tracheal mass includes CXR followed by CT. If a mass is found, bronchoscopy should be performed for direct visualization and tissue sampling.

The authors attest that their institution requires neither Institutional Review Board approval, nor patient consent for publication of this case report. Documentation on file.

*Address for Correspondence:* Laura J Bontempo, MD, MEd, University of Maryland, Department of Emergency Medicine, 110 S Paca Street, 6th Floor, Suite 200, Baltimore, MD 21201. Email: [Lbontempo@som.umaryland.edu](mailto:Lbontempo@som.umaryland.edu).

*Conflicts of Interest:* By the CPC-EM article submission agreement, all authors are required to disclose all affiliations, funding sources and financial or management relationships that could be perceived as potential sources of bias. The authors disclosed none.

*Copyright:* © 2021 Kebort et al. This is an open access article distributed in accordance with the terms of the Creative Commons Attribution (CC BY 4.0) License. See: <http://creativecommons.org/licenses/by/4.0/>

## REFERENCES

1. National Heart, Lung, and Blood Institute. National Education and Prevention Program. Expert Panel Report 3: Guidelines for the Diagnosis and Management of Asthma. 2007. Available at: <https://www.ncbi.nlm.nih.gov/books/NBK7232/>. Accessed September 10, 2020.
2. Marques CC, Fernandes EL, Miquelin GM, et al. Cutaneous manifestations of Churg-Strauss syndrome: key to diagnosis. *An Bras Dermatol*. 2017;92(5 Suppl 1):56-8.
3. Gioffredi A, Maritati F, Oliva E, et al. Eosinophilic granulomatosis with polyangiitis: an overview. *Front Immunol*. 2014;5:549.
4. Gipson K, Avery R, Shah H, et al. Löffler syndrome on a Louisiana pig farm. *Respir Med Case Rep*. 2016;19:128-31.
5. Jethwa AR and Khariwala SS. Tobacco-related carcinogenesis in head and neck cancer. *Cancer Metastasis Rev*. 2017;36(3):411-423.
6. Napieralska A, Miszczyk L, Blamek S. Tracheal cancer: treatment results, prognostic factors and incidence of other neoplasms. *Radiol Oncol*. 2016;50(4):409-17.
7. Gupta D, Singh I, Sakthivel P. Adenoid cystic carcinoma of trachea: a diagnostic and therapeutic challenge. *Indian J Otolaryngol Head Neck Surg*. 2016;68(1):94-6.
8. Ahn Y, Chang H, Lim YS, et al. Primary tracheal tumors: review of 37 cases. *J Thorac Oncol*. 2009;4(5):635-8.
9. Manninen MP, Antila PJ, Pukander JS, et al. Occurrence of tracheal carcinoma in Finland. *Acta Otolaryngol*. 1991;111(6):1162-9.
10. Gaissert HA. Tracheal tumors. 2019. Available at: <https://www.pulmonologyadvisor.com/home/decision-support-in-medicine/pulmonary-medicine/tracheal-tumors/>. Accessed January 23, 2020.
11. Manninen MP, Paakkala TA, Pukander JS, et al. Diagnosis of tracheal carcinoma at chest radiography. *Acta Radiol*. 1992;33(6):546-7.
12. Harris C, Cao C, Croce B, et al. Tracheal tumors. *Ann Cardiothorac Surg*. 2018;7(2):317.
13. Urdaneta AI, Yu JB, Wilson LD. Population-based cancer registry analysis of primary tracheal carcinoma. *Am J Clin Oncol*. 2011;34(1):32-7.

# Case Series of Patients with Opioid Use Disorder and Suicidal Ideation Treated with Buprenorphine

Max Spaderna, MD  
Melanie Bennett, PhD  
Rachel Arnold, BA  
Eric Weintraub, MD

University of Maryland School of Medicine, Department of Psychiatry, Baltimore, Maryland

Section Editor: Steven Walsh, MD

Submission history: Submitted August 24, 2020; Revision received October 11, 2020; Accepted October 16, 2020

Electronically published December 12, 2020

Full text available through open access at [http://escholarship.org/uc/uciem\\_cpem](http://escholarship.org/uc/uciem_cpem)

DOI: 10.5811/cpcem.2020.10.49610

**Introduction:** Buprenorphine benefits patients with opioid use disorder (OUD) in the emergency department (ED), but its efficacy for OUD patients with suicidal ideation (SI) in the ED is unknown.

**Case Series:** We present a case series of 14 OUD patients with SI who were given buprenorphine and a referral to outpatient substance use treatment in the ED. All experienced SI resolution, engaged with outpatient services, and remained in outpatient substance use treatment 30 days after ED discharge.

**Conclusion:** Our data provide evidence for the feasibility of starting buprenorphine in OUD patients with SI in the ED, and suggest that buprenorphine may be useful in helping to resolve SI for these patients. Future research with larger samples is needed. [Clin Pract Cases Emerg Med. 2021;5(1):6–10.]

**Keywords:** *Opioid-related disorders; buprenorphine; suicidal ideation; emergency service, hospital.*

---

## INTRODUCTION

The opioid epidemic in the United States has seen an almost sixfold increase in overdose deaths since 1999, a rise that parallels a 30% increase in the suicide rate between 2000-2016.<sup>1,2</sup> While the association between opioid use and suicidal ideation (SI) has been documented, the impact of opioid use on the current escalation in suicides is unclear.<sup>3</sup> It is likely that suicides caused by opioid overdose are underreported and that many opioid overdose deaths classified as “undetermined” by coroners are suicides.<sup>4</sup> Treating individuals with opioid use disorders (OUD) must include attention to suicide risk.

The 99.4% increase in opioid-related visits to emergency departments (ED) between 2005-2014 represents an opportunity for EDs to encourage patients already in a vulnerable period to make behavioral changes.<sup>5,6</sup> This includes offering medication-based treatment with methadone and buprenorphine to OUD patients. Studies show that ED-initiated buprenorphine decreases opioid use and increases engagement in outpatient substance use treatment.<sup>7,8</sup> A limitation of these studies is that OUD patients with SI have

been excluded, despite some evidence that buprenorphine might reduce SI.<sup>9</sup>

We present observational data on 14 OUD patients with SI who presented to the ED for treatment. Our goals were to explore the feasibility of starting buprenorphine in these patients in the ED, and to determine whether ED-initiated buprenorphine treatment would be associated with improvements in SI and engagement in outpatient substance use treatment.

## CASE SERIES

This study was approved by the medical school’s institutional review board. The 14 patients presented to the ED of a tertiary care hospital between July 2012–August 2018. All met criteria for OUD and reported current SI or a suicide attempt at their index ED visit. All were evaluated by a psychiatrist and offered buprenorphine with a referral to an outpatient substance use treatment program.

We retrospectively reviewed health records of patients referred to the outpatient substance use program affiliated with the medical school. Information collected from the records

included the patients' background characteristics, reasons for ED visit, current substance use, mental health symptoms, buprenorphine use during their ED visit, and engagement in outpatient substance use treatment after ED discharge. Variables collected regarding outpatient substance use treatment included referral to the program during the index ED visit (yes/no); number of days between ED referral to the program and the first appointment (defined as the number of days between discharge from the ED and attendance at the first scheduled appointment); attendance at the first scheduled appointment (yes/no); engagement with the program 30 days after the first scheduled appointment (yes/no, defined as having notes documenting services received on and after day 30); number of medical visits during the 30-day period (defined as visits with a physician to discuss medication and side effects); and number of support visits during the 30-day period (defined as visits with a non-physician to discuss issues besides medication and side effects).

Two of the authors conducted the health record reviews. One (RA) completed the initial review using a data-collection form that matched an Excel (Microsoft Corporation, Redmond, WA) spreadsheet where the data were entered. The second (MB) reviewed the data after these were entered into the spreadsheet and did a comparison with the health record for these variables. Any discrepancy was corrected (if simple), or discussed to reach consensus (if more complex).

Baseline characteristics are summarized in Table 1. Patients were 86% male and 86% Caucasian with a mean age of 41.36 years (standard deviation [SD] = 12.18, range 26-60 years). Besides opioids, patients reported current cocaine (n = 10), cannabis (n = 4), and alcohol use (n = 7), along with symptoms of mood (n = 12) and anxiety (n = 6) disorders. Two patients had attempted suicide immediately before presenting to the ED; 12 reported SI as a main reason for their visit.

Buprenorphine use during the ED visit and engagement with outpatient substance use treatment after discharge are summarized in Table 2. The doses of buprenorphine given in the ED ranged from 2-16 milligrams (mg) (mean = 8.00 mg, SD = 3.76). None of the patients required an inpatient hospitalization for SI. All patients received a referral to an outpatient substance use treatment program, attended their first scheduled outpatient substance use treatment visit, and remained engaged with the outpatient substance use treatment program 30 days after their first visit. During the 30 days after their first visit, patients attended between 1-8 medical visits and 7-28 support visits at the outpatient substance use treatment program.

## DISCUSSION

This case series provides evidence for the feasibility and potential benefit of initiating buprenorphine in the ED to OUD patients who present with SI. For all the patients in our observational data, ED-initiated buprenorphine was associated with SI resolution, discharge from the ED, and engagement in

### *CPC-EM Capsule*

What do we already know about this clinical entity?

*Buprenorphine initiation in the emergency department (ED) improves engagement in outpatient substance use treatment for opioid use disorder (OUD) patients.*

What makes this presentation of disease reportable?

*This is the first report of successfully initiating buprenorphine in OUD patients who present to the ED with suicidal ideation (SI).*

What is the major learning point?

*Buprenorphine initiation and a referral to outpatient substance use treatment may help resolve SI and promote outpatient substance use treatment engagement.*

How might this improve emergency medicine practice?

*In the ED, buprenorphine initiation and a referral to outpatient substance use treatment may be successful interventions for OUD patients who present with SI.*

outpatient substance use treatment. Given that SI rates remain high among OUD patients in outpatient methadone treatment, medication-based treatment by itself is unlikely to explain why the patients in our series experienced SI resolution.<sup>10</sup> Although other factors besides buprenorphine initiation might have contributed to SI resolution, our results provide evidence that ED-initiated buprenorphine may be helpful in the treatment of OUD patients who present to the ED with SI.

There could be several explanations for our findings. One explanation might involve buprenorphine's pharmacology as a partial mu-opioid receptor agonist and kappa-opioid receptor (KOR) antagonist. KOR activation is known to worsen depressive states, and buprenorphine's antidepressant effect is thought to result from its KOR antagonism, a property methadone lacks.<sup>11,12</sup> Studies have shown that there might be a role for buprenorphine to decrease SI for individuals with and without OUD, and it has been hypothesized that buprenorphine's anti-suicidal property might result from its KOR antagonism.<sup>9,13</sup> Although pharmacologically compelling, this mechanism of action remains speculative, and no evidence links the KOR to SI. Studies are needed to determine whether KOR activation causes or worsens SI.

**Table 1.** Characteristics of 14 patients with opioid use disorder and suicidal ideation at presentation to the emergency department

	Age	Gender	Race	Reasons for ED visit	Self-reported substance use recorded at ED visit	Positive urinalysis at ED visit	Suicidal ideation description recorded at ED visit	Psychiatric symptoms and diagnoses recorded at ED visit
Patient 1	59	Male	Caucasian	suicidal ideation, chest pain	heroin, cocaine	heroin, cocaine	suicidal ideation with plan	depression, bipolar disorder
Patient 2	26	Male	Caucasian	suicidal ideation, alcohol withdrawal	heroin, alcohol	cocaine, benzodiazepines	suicidal ideation with plan	depression
Patient 3	45	Male	Black	suicidal ideation	heroin, cocaine, alcohol, cannabis	heroin, cocaine	unknown	substance-induced mood disorder, depression
Patient 4	35	Male	Caucasian	suicidal ideation, nausea/vomiting, depression	heroin, cocaine, alcohol, cannabis, inhalants	heroin, cocaine, cannabis	suicidal ideation with plan	depression, sleep disturbance, anxiety
Patient 5	60	Male	Caucasian	suicidal ideation, substance use disorder	heroin, cocaine	cannabis	passive suicidal ideation with no plan	depression
Patient 6	27	Female	Caucasian	suicidal ideation with plan	heroin, cocaine, alcohol, benzodiazepines	alcohol	suicidal ideation with plan	post-traumatic stress disorder, substance-induced mood disorder
Patient 7	33	Male	Caucasian	suicide attempt	heroin, cocaine, cannabis, sedatives	cocaine	suicide attempt	depression, sleep disturbance
Patient 8	37	Male	Caucasian	suicidal ideation, groin rash	heroin, cocaine	heroin, cocaine, morphine, fentanyl	suicidal ideation	attention-deficit disorder, anxiety
Patient 9	40	Male	Caucasian	suicidal ideation	heroin	heroin, cannabis, morphine, fentanyl	suicidal ideation	anxiety, depression
Patient 10	28	Male	Caucasian	suicidal ideation, abdominal pain, mild ear pain	heroin, cocaine	cocaine	suicidal ideation with plan	poor sleep, weight loss, irritability
Patient 11	31	Female	Caucasian	suicidal ideation, substance use disorder	heroin, cocaine, cannabis, alcohol	cannabis	passive suicidal ideation	post-traumatic stress disorder, anxiety, bipolar
Patient 12	50	Male	Caucasian	suicidal ideation	heroin, cocaine, alcohol	unknown	passive suicidal ideation	depression
Patient 13	55	Male	Black	suicide attempt	heroin	heroin	suicide attempt	depression, sleep disturbance, appetite disturbance, anxiety
Patient 14	53	Male	Caucasian	suicidal ideation, depression	heroin, alcohol	heroin, cannabis	suicide attempt	loss of appetite, weight loss, low energy

ED, emergency department.

Another explanation might be that the ED referral to outpatient substance use treatment addressed the non-clinical

issue of access to care for OUD treatment that had led these patients to experience SI.<sup>14</sup> It is notable that all 14 patients

**Table 2.** Buprenorphine initiation and outpatient-treatment engagement for 14 patients with opioid use disorder and suicidal ideation at presentation to the emergency department.

	Patient													
	1	2	3	4	5	6	7	8	9	10	11	12	13	14
Buprenorphine prescribed at ED visit	Yes	Yes	Yes	Yes	Yes	Yes	Yes	Yes	Yes	Yes	Yes	Yes	Yes	Yes
Buprenorphine dose in mg* prescribed at ED visit	8mg	4mg	16mg	12mg	12mg	4mg	8mg	8mg	8mg	8mg	8mg	10mg	2mg	4mg
Required inpatient hospitalization for SI	No	No	No	No	No	No	No	No	No	No	No	No	No	No
Self-harm within 30 days after ED visit	None	None	UK	None	None	None	UK	UK	UK	UK	UK	UK	UK	None
Outpatient referral made at ED visit	Yes	Yes	Yes	Yes	Yes	Yes	Yes	Yes	Yes	Yes	Yes	Yes	Yes	Yes
Days between ED referral and 1 <sup>st</sup> appointment	1	1	UK	5	5	4	UK	UK	UK	UK	4	UK	UK	2
Outpatient referral – 1 <sup>st</sup> appointment attended	Yes	Yes	Yes	Yes	Yes	Yes	Yes	Yes	Yes	Yes	Yes	Yes	Yes	Yes
Outpatient referral – engaged 30 days after 1 <sup>st</sup> appointment	Yes	Yes	Yes	Yes	Yes	Yes	Yes	Yes	Yes	Yes	Yes	Yes	Yes	Yes
Outpatient referral – number of medical visits* attended in 30 days	2	2	2	2	2	8	3	2	2	1	3	UK	2	5
Outpatient referral – number of support visits** attended in 30 days	7	19	10	20	23	11	UK	UK	UK	UK	UK	UK	20	28

\*Medical visits = visits with a physician, discussion focused on medication and side effects.

\*\*Support visits = visits with a nurse or counselor, discussion focused on issues other than medication and side effects.

ED, emergency department; mg, milligram; SI, suicidal ideation; UK, unknown.

attended their first outpatient appointment and remained in treatment for 30 days. Other studies of ED-initiated buprenorphine and referral to treatment have found lower percentages of OUD patients attending their first outpatient appointment.<sup>7</sup> Many patients did not have to wait long to start outpatient treatment: for the seven patients in our case series whose data are available, the range between the ED referral to outpatient treatment and attendance at the first appointment was 1-5 days. Moreover, by treating both the opioid-withdrawal symptoms and SI, ED-initiated buprenorphine might have illustrated the benefits of continuing buprenorphine after ED discharge to these patients. It might be that the combination of a quick referral to outpatient substance use treatment and the experience of ED-initiated buprenorphine was enough to promote treatment engagement.

Several limitations should be noted. This was a small case series of 14 patients who were not compared with a matched control group that did not receive buprenorphine. We did not

examine changes in treatment engagement, opioid use, and SI after 30 days, so we cannot determine how these outcomes might have changed over a longer period of time. We were not able to access data on two variables that might have had an impact on engagement: how patients paid for treatment (eg, insurance, other payment programs, self-pay), or their degree of opioid withdrawal (measured by clinician-rated scores from the Clinical Opiate Withdrawal Scale). It would be useful to know whether any patient experienced self-harm or attempted suicide after the 30 days following their first outpatient substance use visit. Future research should follow patients to examine whether self-harm or suicide attempts occur in the early days of outpatient substance use treatment to evaluate more fully the potential benefit of ED-initiated buprenorphine.

## CONCLUSION

The observational data in our case series provide evidence for the feasibility of starting buprenorphine in OUD patients

with suicide ideation in the ED and referring them to outpatient substance use treatment. More rigorous studies are needed to determine the effectiveness of ED-initiated buprenorphine on a larger and more diverse sample of patients.

The Institutional Review Board approval has been documented and filed for publication of this case report.

---

*Address for Correspondence:* Max Spaderna, MD, University of Maryland School of Medicine, Department of Psychiatry, 701 West Pratt Street, 3<sup>rd</sup> Floor, Baltimore, MD, 21201. Email: mspaderna@som.umaryland.edu.

*Conflicts of Interest:* By the CPC-EM article submission agreement, all authors are required to disclose all affiliations, funding sources and financial or management relationships that could be perceived as potential sources of bias. The authors disclosed none.

*Copyright:* © 2021 Spaderna et al. This is an open access article distributed in accordance with the terms of the Creative Commons Attribution (CC BY 4.0) License. See: <http://creativecommons.org/licenses/by/4.0/>

---

## REFERENCES

- Centers for Disease Control and Prevention. Opioid Data Analysis and Resources. 2019. Available at: <https://www.cdc.gov/drugoverdose/data/analysis.html>. Accessed January 8, 2020.
- Hedegaard H, Curtin SC, Warner M. Suicide rates in the United States continue to increase. *NCHS Data Brief*. 2018;(309):1-8.
- Kuramoto SJ, Chilcoat HD, Ko J, et al. Suicidal ideation and suicide attempt across stages of nonmedical prescription opioid use and presence of prescription opioid disorders among U.S. adults. *J Stud Alcohol Drugs*. 2012;73(2):178-84.
- Rockett IR, Kapusta ND, Coben JH. Beyond suicide: action needed to improve self-injury mortality accounting. *JAMA Psychiatry*. 2014;71(3):231-2.
- Weiss AJ, Elixhauser A, Barrett ML, et al. Opioid-Related Inpatient Stays and Emergency Department Visits by State, 2009–2014: Statistical Brief #219. 2017. Available at: <https://www.ncbi.nlm.nih.gov/books/NBK441648/>. Accessed January 8, 2020.
- Rhodes KV, Gordon JA, Lowe RA. Preventive care in the emergency department, Part I: Clinical preventive services—are they relevant to emergency medicine? Society for Academic Emergency Medicine Public Health and Education Task Force Preventive Services Work Group. *Acad Emerg Med*. 2000;7(9):1036-41.
- D'Onofrio G, O'Connor PG, Pantalon MV, et al. Emergency department-initiated buprenorphine/naloxone treatment for opioid dependence: a randomized clinical trial. *JAMA*. 2015;313(16):1636-44.
- D'Onofrio G, Chawarski MC, O'Connor PG, et al. Emergency department-initiated buprenorphine for opioid dependence with continuation in primary care: outcomes during and after intervention. *J Gen Intern Med*. 2017;32(6):660-6.
- Yovell Y, Bar G, Mashiah M, et al. Ultra-low-dose buprenorphine as a time-limited treatment for severe suicidal ideation: a randomized controlled trial. *Am J Psychiatry*. 2016;173(5):491-8. Erratum in: *Am J Psychiatry*. 2016;173(2):198.
- Xu YM, Zhong BL, Chen WC, et al. Suicidal ideation among Chinese methadone-maintained patients: prevalence and correlates. *Oncotarget*. 2017;8(49):86181-7.
- Carlezon WA Jr and Krystal AD. Kappa-opioid antagonists for psychiatric disorders: from bench to clinical trials. *Depress Anxiety*. 2016;33(10):895-906.
- Kristensen K, Christensen CB, Christrup LL. The mu1, mu2, delta, kappa opioid receptor binding profiles of methadone stereoisomers and morphine. *Life Sci*. 1995;56(2):PL45-50.
- Ahmadi J, Jahromi MS, Ehsaei Z. The effectiveness of different singly administered high doses of buprenorphine in reducing suicidal ideation in acutely depressed people with co-morbid opiate dependence: a randomized, double-blind, clinical trial. *Trials*. 2018;19(1):462.
- Kroll DS, Karno J, Mullen B, et al. Clinical severity alone does not determine disposition decisions for patients in the emergency department with suicide risk. *Psychosomatics*. 2018;59(4):388-93.

# E-cigarettes and Vaping, Product-use Associated Lung Injury: A Case Series of Adolescents

Abdullah Khan, MD  
Karli Parlette, DO  
Heather M. Kuntz, MD

Loma Linda University, Department of Emergency Medicine, Loma Linda, California

Section Editor: Anna McFarlin, MD

Submission history: Submitted June 14, 2020; Revision received October 6, 2020; Accepted October 5, 2020

Electronically published January 16, 2021

Full text available through open access at [http://escholarship.org/uc/uciem\\_cpccem](http://escholarship.org/uc/uciem_cpccem)

DOI: 10.5811/cpcem.2020.10.48707

**Introduction:** Lung injury associated with the use of electronic cigarettes and vaping (EVALI) was first identified in 2019. Since then, clusters of cases have been reported in the literature. Our aim was to describe the clinical presentation of adolescents with EVALI in the emergency department and their clinical outcomes.

**Case Series:** In our case series, we identified seven adolescents diagnosed with EVALI. We describe their signs and symptoms on presentation to the emergency department and their clinical course. The most common symptoms on presentation were cough, shortness of breath, and vomiting. Each of these symptoms was seen in 71% of patients (n = 5), although not always together. Sinus tachycardia was noticed in 100% of patients (n = 7) and tachypnea in 85% (n = 6). While 85% (n = 6) required hospitalization for respiratory support, all patients were later discharged home on room air. After the diagnosis of EVALI, 85% of patients (n = 6) were treated with steroids.

**Conclusion:** EVALI is a new disease with unclear mechanisms that commonly presents with symptoms of cough, shortness of breath, and vomiting. It causes severe respiratory compromise in the adolescent population, requiring hospitalization and respiratory support. [Clin Pract Cases Emerg Med. 2021;5(1):11–16.]

**Keywords:** *Electronic cigarettes, and vaping, product-use associated lung injury; adolescents; emergency department.*

## INTRODUCTION

Electronic cigarettes (e-cigarettes) and vaping products are new devices for inhaling various substances such as nicotine and cannabinoids, with or without flavoring chemicals. “Vaping,” or “Juuling,” is a term used to describe the use of e-cigarettes and vaping products.<sup>1</sup> These devices, also known as e-cigs, vape pens, vapes, mods, pod-mods, tanks and electronic nicotine delivery systems, are available in different shapes and sizes.<sup>1,2</sup>

All e-cigarettes and vaping products are made of three components. The first component is the cartridge that contains e-liquid and the atomizer, a coil that heats and converts e-liquid into aerosols. E-liquids can be broadly categorized into two types: regular e-liquids made of propylene glycol-

containing chemical flavors and vegetable glycerine used to dissolve nicotine or cannabis e-liquids containing tetrahydrocannabinol and cannabidiol. The second component is the sensor that activates the coil, and the third component is the battery.<sup>1,3</sup> The hookah, also known as a water pipe, is an ancient method of smoking nicotine. In this method, the coal heats the tobacco and then the smoke passes through the water reservoir before it is inhaled.<sup>4</sup> Contrary to public perception, hookah use is also associated with oral, lung, and esophageal cancers, similar to smoking cigarettes.<sup>4</sup> In our study, we focused on e-cigarettes, and vaping, product-use associated lung injuries (EVALI).

According to the United States Centers for Disease Control and Prevention (CDC), in 2018 e-cigarettes were used

by 3.05 million high school and 570,000 middle school students.<sup>5</sup> EVALI is a diagnosis of exclusion, with a definition outlined by the CDC for confirmed and probable cases.<sup>6</sup> EVALI was first identified in August 2019 after the Wisconsin Department of Health Services and the Illinois Department of Public Health received multiple reports of a pulmonary disease of unclear etiology, possibly associated with the use of e-cigarettes and related products.<sup>6</sup> Since then, more than 2000 cases of EVALI have been reported, and in 80% tetrahydrocannabinol (THC)-containing products were used.<sup>7,8</sup> Our study aimed to identify the clinical characteristics and hospital course of adolescents diagnosed with EVALI.

## CASE SERIES

### Methods

We performed a retrospective chart review of adolescents (11-18 years old) presenting to our hospital between January–December 2019, with diagnosis of EVALI. Subjects were identified by the *International Classification of Diseases, Tenth Revision* (ICD-10) diagnostic codes outlined by official ICD-10 guidelines.<sup>9</sup> The following codes were used: J68.0 (Bronchitis and pneumonitis due to chemicals, gases, fumes and vapors; includes chemical pneumonitis); J69.19 (Pneumonitis due to inhalation of oils and essences; includes lipoid pneumonia); J80 (Acute respiratory distress syndrome); J82 (Pulmonary eosinophilia, not elsewhere classified); J84.114 (Acute interstitial pneumonitis); J84.89 (Other specified interstitial pulmonary disease); J68.9 (Unspecified respiratory condition due to chemicals, gases, fumes, and vapors); T65.291 (Toxic effect of other nicotine and tobacco, accidental); and T40.7X1 (Poisoning by cannabis or its derivatives, accidental).

We used a standardized data collection sheet. Data were collected by trained personnel who were not blinded to the objectives of study. The data extracted from the medical records were age, gender, weight, and vital signs (temperature, respiratory rate, blood pressure, heart rate) obtained in the ED. We also compiled data on duration of symptoms, history of cough, shortness of breath, chest pain, vomiting, wheezing, rales, use of accessory muscles, and presence of altered mental status. We also included data on respiratory support, duration of hospital stay, use of steroids during treatment, and laboratory tests and imaging obtained in the hospital (complete blood count, respiratory virus panel, respiratory cultures, computed tomography [CT] findings).

We identified cases using the CDC definition of adolescents who had used e-cigarettes or other vaping devices in the 90 days prior to presentation, with bilateral airspace disease on chest imaging (radiograph and/or CT) and a negative infectious workup or the decision by the clinical care team to treat as a case of EVALI.<sup>6</sup> Exclusion criteria were gastrointestinal and central nervous system (CNS) manifestations without interstitial pulmonary involvement, ingestions of cannabinoids, duplicate visits, and if it was unclear whether vaping device was used or

### CPC-EM Capsule

What do we already know about this clinical entity?

*Electronic cigarettes (e-cigarettes), and vaping, product-use associated lung injuries (EVALI) is a growing disease entity, especially in adolescents, with diagnostic criteria outlined by Centers for Disease Control and Prevention (CDC).*

What makes this presentation of disease reportable?

*In our series, we aim to increase awareness by highlighting the clinical presentation of EVALI in the emergency department and its outcome.*

What is the major learning point?

*EVALI often presents with respiratory and gastrointestinal symptoms, leading to acute respiratory failure, requiring hospital admissions.*

How might this improve emergency medicine practice?

*Asking a single question about the use of E-cigarette and vaping products can help diagnose the condition in the context of diagnostic criteria outlined by CDC, differentiating it from other respiratory ailments.*

not. We used descriptive statistics to analyze the data. Median and interquartile range (IQR) were calculated for continuous variables, and proportions were calculated with 95% confidence intervals (CI) for categorical variables. The study was approved by the Loma Linda University Institutional Review Board.

## RESULTS

We identified 16 encounters with the ICD-10 codes for EVALI during the one-year period. Using the exclusion criteria mentioned in the Methods section, we excluded seven patients. Four of these patients presented with CNS manifestations (seizure or altered mental status) and vomiting without pulmonary involvement. In one patient, the history of vaping was unclear. One patient had ingested cannabinoids without vaping. Two encounters were excluded because they were duplicate visits.

Of the seven patients included in the analysis, six (85%) were male. The median age was 16 years (IQR 15-16). The median weight in our series was 70 kilograms (IQR 63-84). The medians for vital signs recorded in the ED were the following: temperature of 100.2° Fahrenheit (IQR 98.6-102.6);

respiratory rate 24 breaths per minute (IQR 18-32); oxygen saturation, 90% (IQR 87-96); heart rate 130 beats per minute (IQR 118-143); systolic blood pressure 128 millimeters of mercury (mm Hg) (IQR 112-139); and diastolic blood pressure 76 mm HG (IQR 64-79). Three (43%; 95% CI, 9-81) patients had documented fever in the ED.

The most common symptoms reported in our study were cough, shortness of breath, and vomiting, each occurring separately in five patients. Three patients presented with chest pain. Two patients presented with altered mental status in the form of unresponsiveness, with one patient requiring intubation. The other unresponsive patient, a 16-year-old male, returned to a normal mentation with bag-valve-mask ventilation and naloxone but required high-flow nasal cannula (HFNC) for shortness of breath. On physical examination, accessory muscle use was the most common finding, reported in four patients. Rales were appreciated in two patients, while no patients were found to have wheezing (Table 1).

In our study, six patients (86%; 95% CI, 42-99) presented with respiratory failure. Four (57%; 95% CI, 22-96) required HFNC. One patient (14%; 95% CI, 0-57) was intubated; one patient (14%; 95% CI, 0-57) required simple nasal cannula oxygen at two liters per minute; and one patient (14%; 95% CI, 0-57) maintained normal oxygen saturations in room air during his ED visit and was discharged home. A brief clinical presentation, summary of findings on imaging, and type of respiratory support needed are summarized in Table 2.

Five patients (71%; 95% CI, 36-99) were admitted to the pediatric intensive care unit, and one patient (14%; 95% CI, 0-57) was admitted to the normal pediatric unit. The median hospital length of stay was six days (IQR 3-7). All patients (100%) were discharged with no comorbidities or deaths reported. Six patients (86%; 95% CI, 42-99) were treated with steroids. The median duration of treatment with steroids during admission and after discharge was nine days (IQR 5-10).

Our patients had a variety of laboratory tests ordered. Most common were complete blood count, respiratory virus panel, respiratory cultures, and urine drug screen. All patients

had a complete blood count, and the median for white cell count was 16 thousand cells per cubic millimeter (reference range 4.80-11.80; IQR 11-21). A respiratory virus panel was collected from five patients and it was negative in all of them (0%; 95% CI, 0-50). Respiratory cultures were collected from two patients and both resulted negative. A urine drug screen was performed for six patients and was positive for cannabinoids in all six (100%; 95% CI, 63-100).

Three patients (43%) followed up at different intervals in the pulmonology clinic (Table 1: Cases 1, 2 and 4). Spirometry showed normal results in all three patients (100%) at that time. Case 1 followed up one week after discharge, at which time spirometry showed evidence of obstructive lung disease, which returned to normal at three-month follow-up visit. No repeat imaging was performed for that patient. Case 2 followed up six weeks after discharge with near-complete resolution of ground-glass appearance on repeat CT and normal spirometry. Case 4 followed up two weeks after discharge with improvement in lung opacities on repeat radiograph and normal spirometry. All three patients had received steroids for 10 days when they were originally diagnosed with EVALI. No follow-up data was available for the remaining four patients.

## DISCUSSION

EVALI was an emerging disease entity in 2019. In our case series, we describe adolescents diagnosed with EVALI and their clinical course in the ED and the hospital. In our study, the most common symptoms of cough, shortness of breath, and vomiting presented with an equal frequency of 71%. In a study by Layden et al, shortness of breath and cough was noticed in 85% of patients and vomiting in 61%; whereas, according to Belgaev et al, 90% of patients in their study presented with gastrointestinal (GI) and respiratory symptoms.<sup>6,10</sup> In a report by the CDC, 85% of the EVALI population had respiratory symptoms and 57% had GI symptoms.<sup>11</sup> The results of our study are similar to previous literature in suggesting that respiratory and GI symptoms are common in patients with EVALI.

According to Balgaev et al, 67% of patients had clinical and radiological improvement with residual findings on radiological and pulmonary function tests at time of follow-up.<sup>10</sup> In our study, the three patients who had documented follow-up visits had normal spirometry without residual deficits. Only two of those patients had repeat imaging, and both showed improvement without residual abnormalities.

E-cigarette liquids and aerosols have been shown to contain a variety of chemical constituents including flavors that can be cytotoxic to human pulmonary fibroblasts and stem cells.<sup>12</sup> Exposure to heavy metals such as chromium, nickel, and lead has also been reported.<sup>13</sup> None of our patients were tested for heavy metal exposure. Most of the delivery systems have nicotine in them, with one cartridge providing the nicotine equivalent to a pack of cigarettes.<sup>12</sup>

**Table 1.** Common presenting signs and symptoms of EVALI: electronic cigarettes, and vaping, product-use associated lung injury.

Signs and symptoms	N (percentage; 95% CI)
Cough	5 (71%; 36-99)
Shortness of breath	5 (71%; 36-99)
Vomiting	5 (71%; 36-99)
Chest pain	3 (43%; 9-81)
Accessory muscle use	4 (57%; 22-96)
Tachycardia	7 (100%; 63-100)
Tachypnea	6 (85%; 42-99)
Rales	2 (29%; 5-85)
Altered mental status	2 (29%; 5-85)

N, total number; CI, confidence interval.

**Table 2.** Characteristics of adolescents with electronic cigarettes, and vaping, product-use associated lung injury.

Cases	Age (yrs)	Gender	Clinical presentation	Imaging (CT)	Respiratory support	Steroid duration (Days)	Antibiotics	Disposition	Length of stay in hospital (Days)
1	17	M	Fever, shortness of breath and cough for 3 days with 5 episodes of non-bloody, non-bilious vomiting	Bilateral, lower lobe predominant ground glass attenuation with subpleural sparing	HFNC 20 lpm FiO <sub>2</sub> 40%	10	Yes	PICU	6
2	16	F	History of epilepsy. Had a self-resolved seizure followed by development of a cough, shortness of breath, chest pain and hemoptysis	Bilateral ground glass opacities with interlobular septal thickening predominantly in the mid and upper lung zones	HFNC 20 lpm FiO <sub>2</sub> 100%	10	Yes	PICU	4
3	16	M	Found unresponsive, locked in his room. Arousable but developed acute respiratory failure and required intubation	Right pneumothorax, dense consolidation of right lung/partial white out, L lung base consolidation, subcutaneous emphysema	Intubated ACPC 26/5 FiO <sub>2</sub> 40%	0	Yes	PICU	10
4	16	M	Non-productive, dry cough for 5 days followed by worsening shortness of breath for 1 day	Extensive bilateral patchy areas of infiltration with some basilar consolidation and small bilateral pleural effusions	Nasal Cannula 2 lpm	10	Yes	Pediatric in-patient unit	7
5	15	M	Vaping marijuana and snorting acetaminophen-oxycodone; was found unresponsive by family. Returned to normal mentation with naloxone, but developed hypoxia, chest pain and shortness of breath	Fluffy centrilobular opacities in central and peripheral lungs, with prominence at posterior lower lobes	HFNC 10 lpm FiO <sub>2</sub> 35%	5	No	PICU	3
6	15	M	Vomiting once per day for 5 days followed by cough and chest pain for 2 days	Reticular opacities, particularly in bi-basilar subpleural space, may represent mild/early fibrosis but chronicity has not been established	Room air	5	Yes	Discharged home	N/A
7	16	M	Abdominal pain and diarrhea for 2 weeks, followed by non-bloody, non-bilious vomiting and shortness of breath for 2 days	Mild granular and patchy parenchymal opacities in both lung bases concerning for bilateral pneumonia	HFNC 20 Lpm FiO <sub>2</sub> 21%	9	Yes	PICU	7

CT, computed tomography; HFNC, high-flow nasal cannula; lpm, liters per minute; PICU, pediatric intensive care unit; ACPC, assist control, pressure-controlled setting; FiO<sub>2</sub>, fraction of inspired oxygen.

In addition to nicotine, e-cigarette devices can be used to deliver THC-based oils.<sup>14</sup> According to Trivers et al, one-third of the adolescents who used e-cigarettes had used cannabinoids in their e-cigarettes.<sup>15</sup> In our patients with EVALI, urinary drug screen was positive for cannabinoids in all patients. One caveat is that we do not know whether our patients used only THC-containing products or a combination of nicotine and THC-containing products.

In our case series, the majority of patients presented with pulmonary disease requiring respiratory support and intensive care unit admission. None of these patients developed acute respiratory distress syndrome (ARDS). We likely did not see this disease process due to our small sample size, as Layden et al reported ARDS development in several of their examined cases.<sup>6</sup> In our series, we did not evaluate the pathologic pulmonary changes in different patients. In other case reports, different pathophysiologic patterns of pulmonary involvement, in the form of diffuse alveolar hemorrhage, exogenous lipoid pneumonia, acute eosinophilic pneumonia, or hypersensitivity pneumonitis have been identified.<sup>16-19</sup>

Although the mechanism of EVALI is not clearly understood, the CDC suggests the use of steroids for treatment.<sup>11</sup> According to a series of patients in Illinois, 51% of those patients had improvement in symptoms after the administration of steroids.<sup>6</sup> In another study, patients showed clinical and radiological improvement following the use of antibiotics and steroids.<sup>10</sup> In our study, six patients received steroids and six patients received antibiotics; three of those patients followed up in clinics with normal spirometry. But this evidence is not sufficient to establish that use of steroids or antibiotics is beneficial in EVALI.

There are several limitations of our study. First, because it was a retrospective chart review we could not establish causation. Second, all data may not have been recorded on all patients (such as smoking THC vs nicotine vs both). We might have missed some if the ICD-10 codes were not correct on the chart. Only three had documented follow-up, so we don't know whether the other four had any comorbidities after their hospitalization. Third, we had a small number of patients. Fourth, this was a single-center study; so results may not be generalizable to other hospitals with different patient demographics.

## CONCLUSION

Our study supports that EVALI can present with respiratory and gastrointestinal symptoms. It can lead to acute respiratory failure requiring respiratory support and hospital admission. Respiratory complaints are a common reason for adolescents to present to the ED, and physicians should consider EVALI when there is a history of recent use of vaping devices. We also suggest counseling adolescents against use of e-cigarette with and without THC-containing products, whenever that history is elicited in the ED.

The Institutional Review Board approval has been documented and filed for publication of this case series.

---

*Address for Correspondence:* Abdullah Khan, MD, Loma Linda University, Department of Emergency Medicine, 11234 Anderson Street, Room A809A, Loma Linda, CA 92354. Email: [abdullahkhan120@gmail.com](mailto:abdullahkhan120@gmail.com).

*Conflicts of Interest:* By the CPC-EM article submission agreement, all authors are required to disclose all affiliations, funding sources and financial or management relationships that could be perceived as potential sources of bias. The authors disclosed none.

*Copyright:* © 2021 Khan et al. This is an open access article distributed in accordance with the terms of the Creative Commons Attribution (CC BY 4.0) License. See: <http://creativecommons.org/licenses/by/4.0/>

---

## REFERENCES

- Centers for Disease Control and Prevention. E-Cigarette, or Vaping, Products Visual Dictionary. 2020. Available at: [https://www.cdc.gov/tobacco/basic\\_information/e-cigarettes/pdfs/ecigarette-or-vaping-products-visual-dictionary-508.pdf](https://www.cdc.gov/tobacco/basic_information/e-cigarettes/pdfs/ecigarette-or-vaping-products-visual-dictionary-508.pdf). Accessed September 22, 2020
- Wagoner KG, Cornacchione J, Wiseman KD, et al. E-cigarettes, hookah pens and vapes: adolescent and young adult perceptions of electronic nicotine delivery systems. *Nicotine Tob Res*. 2016;18(10):2006-12.
- Caponnetto P, Campagna D, Papale G, et al. The emerging phenomenon of electronic cigarettes. *Expert Rev Respir Med*. 2012;6(1):63-74.
- Akl EA, Gaddam S, Gunukula SK, et al. The effects of waterpipe tobacco smoking on health outcomes: a systematic review. *Int J Epidemiol*. 2010;39(3):834-57.
- Gentzke AS, Creamer M, Cullen KA, et al. Vital signs: tobacco product use among middle and high school students - United States, 2011-2018. *MMWR Morb Mortal Wkly Rep*. 2019;68(6):157-64.
- Layden JE, Ghinai I, Pray I, et al. Pulmonary illness related to e-cigarette use in Illinois and Wisconsin - Final Report. *N Engl J Med*. 2020;382(10):903-16.
- Hartnett KP, Kite-Powell A, Patel MT, et al. Syndromic surveillance for e-cigarette, or vaping, product use-associated lung injury. *N Engl J Med*. 2020;382(8):766-72.
- Chatham-Stephens K, Roguski K, Jang Y, et al. Lung Injury Response Epidemiology/Surveillance Task Force; Lung Injury Response Clinical Task Force. Characteristics of Hospitalized and Nonhospitalized Patients in a Nationwide Outbreak of E-cigarette, or Vaping, Product Use-Associated Lung Injury - United States, November 2019. *MMWR Morb Mortal Wkly Rep*. 2019;68(46):1076-80.
- Centers for Disease Control and Prevention. ICD-10-CM Official Coding Guidelines - Supplement Coding encounters related to E-cigarette, or Vaping, Product Use. 2020. Available at: [https://www.cdc.gov/nchs/data/icd/Vapingcodingguidance2019\\_10\\_17\\_2019.pdf](https://www.cdc.gov/nchs/data/icd/Vapingcodingguidance2019_10_17_2019.pdf).

Accessed September 22, 2020.

10. Blagev DP, Harris D, Dunn AC, et al. Clinical presentation, treatment, and short-term outcomes of lung injury associated with e-cigarettes or vaping: a prospective observational cohort study. *Lancet*. 2019;394(10214):2073-83.
11. Siegel DA, Jatlaoui TC, Koumans EH, et al. Lung Injury Response Clinical Working Group; Lung Injury Response Epidemiology/Surveillance Group. Update: Interim Guidance for Health Care Providers Evaluating and Caring for Patients with Suspected E-cigarette, or Vaping, Product Use Associated Lung Injury - United States, October 2019. *MMWR Morb Mortal Wkly Rep*. 2019;68(41):919-27.
12. Strongin RM. E-cigarette chemistry and analytical detection. *Annu Rev Anal Chem (Palo Alto Calif)*. 2019;12(1):23-39.
13. Olmedo P, Goessler W, Tanda S, et al. Metal concentrations in e-cigarette liquid and aerosol samples: the contribution of metallic coils. *Environ Health Perspect*. 2018;126(2):027010.
14. Salzman GA, Alqawasma M, Asad H. Vaping associated lung injury (EVALI): an explosive United States epidemic. *Mo Med*. 2019;116(6):492-6.
15. Trivers KF, Phillips E, Gentzke AS, et al. Prevalence of cannabis use in electronic cigarettes among US youth. *JAMA Pediatr*. 2018;172(11):1097-99.
16. Agustin M, Yamamoto M, Cabrera F, et al. Diffuse alveolar hemorrhage induced by vaping. *Case Rep Pulmonol*. 2018;2018:9724530.
17. McCauley L, Markin C, Hosmer D. An unexpected consequence of electronic cigarette use. *Chest*. 2012;141(4):1110-3.
18. Arter ZL, Wiggins A, Hudspath C, et al. Acute eosinophilic pneumonia following electronic cigarette use. *Respir Med Case Rep*. 2019;27:100825.
19. Sommerfeld CG, Weiner DJ, Nowalk A, et al. Hypersensitivity pneumonitis and acute respiratory distress syndrome from e-cigarette use. *Pediatrics*. 2018;141(6):e20163927.

## Case Report of Thrombosis of the Distal Aorta with Occlusion of Iliac Arteries in COVID-19 Infection

Andrew LaFree, MD  
Alexis Lenz, DO  
Christian Tomaszewski, MD, MBA  
Faith Quenzer, DO

University of California, San Diego, Department of Emergency Medicine, San Diego, California

Section Editor: Steven Walsh, MD

Submission history: Submitted August 22, 2020; Revision received October 17, 2020; Accepted November 5, 2020

Electronically published December 7, 2020

Full text available through open access at [http://escholarship.org/uc/uciem\\_cpccm](http://escholarship.org/uc/uciem_cpccm)

DOI: 10.5811/cpccm.2020.11.49593

**Introduction:** The severe acute respiratory syndrome coronavirus 2 (SARS-CoV-2), which is responsible for the coronavirus disease of 2019 (COVID-19) pandemic, has been associated with a variety of prothrombotic sequelae. The pathogenesis of this hypercoagulability has not yet been fully elucidated, but it is thought to be multifactorial with overactivation of the complement pathways playing a central role. There is emerging evidence that the resulting complications are not confined to the venous circulation, and even in patients without typical respiratory symptoms or traditional risk factors, there is a significant rate of arterial thromboembolic disease in patients with SARS-CoV-2 infection.

**Case Report:** We describe a patient presenting with bilateral leg pain without any respiratory symptoms or fever who ultimately was found to be COVID-19 positive and had thromboembolism of the aorta and bilateral iliac occlusion. This report reviews available evidence on the prevalence of arterial thromboembolism in COVID-19 patients and some proposed mechanisms of the pathophysiology of COVID-19-associated coagulopathy.

**Conclusion:** It is important that the emergency physician maintain a high degree of suspicion for arterial thromboembolic disease in patients who are infected with COVID-19 even in the absence of typical respiratory symptoms. Additionally, COVID-19 should be considered in patients with unexplained thromboembolic disease, as this may increase the detection of COVID-19. [Clin Pract Cases Emerg Med. 2021;5(1):17–21.]

**Keywords:** SARS-CoV-2; COVID-19; arterial thromboembolism; coagulopathy; aortoiliac occlusion.

---

### INTRODUCTION

The severe acute respiratory syndrome coronavirus 2 (SARS-CoV-2) may create numerous complications outside of the respiratory tract. Coagulopathies have also been observed as complications associated with the virus.<sup>1-3</sup> These prothrombotic sequelae are not confined to the venous circulation. Here we present a case of a patient with thrombosis of the distal abdominal aorta and occlusion of bilateral iliac arteries complicated by severe rhabdomyolysis who presented with lower extremity pain and weakness in the

setting of a coronavirus disease 2019 (COVID-19) infection. Although cases of lower extremity arterial thrombosis have been described before,<sup>1-3</sup> our case is unique in that the patient was relatively young, presented without respiratory symptoms, and had bilateral leg involvement necessitating amputations. This case demonstrates the importance of maintaining a high index of suspicion for arterial thrombosis in patients with COVID-19 infection even in the absence of typical respiratory symptoms or other evidence of severe disease. It also important within this context to also consider COVID-19

in unexplained thrombosis.

## CASE REPORT

A 57-year-old male with a history of type 2 diabetes and hypertension presented to the emergency department (ED) with low back pain radiating into his legs worsening over the prior three days. The patient was not able to identify any clear precipitating factors or trauma. He described the pain as moderate in intensity and of a “burning” quality. Prior to being seen in our ED the patient was seen at an outside clinic in Mexico where he was given a “Toradol shot and steroids” and diagnosed with sciatica. The patient denied any other symptoms including fever, cough, shortness of breath, chills, or weakness.

The patient’s vital signs on presentation were normal except for a heart rate of 101 beats per minute. He was noted to have a blood pressure of 119/79 millimeters of mercury (mm Hg), a pulse oxygen saturation of 96%, and a temperature of 98.2°Fahrenheit (F). The patient’s exam was unremarkable except for pain to palpation of bilateral lower extremities. He was not noted to have any weakness or neurological deficit and had normal bilateral dorsalis pedis pulses. The patient had a blood glucose within normal limits. He was given pain medication and steroids and felt improvement of his symptoms. As the pain seemed to improve, his symptoms were attributed to sciatica and he was discharged home.

Two days later the patient returned to the ED reporting worsening pain in his flank and legs and bilateral lower extremity weakness. He reported moderate to severe pain with movement, which had limited his ability to ambulate. The patient complained of some dysuria but continued to deny other symptoms including fever, cough, shortness of breath, chest pain, nausea, vomiting, diarrhea, numbness or inability to urinate. At this presentation, the patient had a heart rate of 66 beats per minute, blood pressure was 120/79 mm Hg, oxygen saturation was 95% on room air, and his temperature was 97.4°F. He reported that his pain on arrival was 10/10. He was found to have full range of motion, normal sensation, and equal dorsalis pedis pulses bilaterally in his lower extremities. He was noted to have pain with movement of his lower extremities, and endorsed tingling. He had normal rectal tone. His lower extremities were noted to be hyporeflexic.

The patient was given pain medication and his laboratory results revealed an elevated white blood cell count of  $23.5 \times 10^9$ /liter (L) (reference range  $4.0\text{-}10.0 \times 10^9$ /L) with normal hemoglobin, hematocrit, and platelets. His comprehensive metabolic panel was normal with the exception of bicarbonate of 22 milliequivalents (mEq)/L (23-30 mEq/L), an elevated blood urea nitrogen of 60 milligrams per deciliter (mg/dL) (7-20 mg/dL), an alanine aminotransferase of 242 units (U)/L (7-56 U/L), and an aspartate aminotransferase of 617 U/L (normal 0-35 U/L). His creatine phosphokinase was markedly elevated at 26,818 U/L (20-600 U/L). His D-dimer was 562

### CPC-EM Capsule

What do we already know about this clinical entity?

*Severe acute respiratory syndrome coronavirus 2 infection often presents as respiratory illness and hypoxia, but has been associated with significant coagulopathy.*

What makes this presentation of disease reportable?

*We present the case of a large aortoiliac occlusion in a coronavirus disease of 2019 (COVID-19) patient with no initial respiratory complaints.*

What is the major learning point?

*Major coagulopathic complications such as stroke, pulmonary embolism, coronary artery embolism, and arterial thrombosis have been observed in COVID-19 patients.*

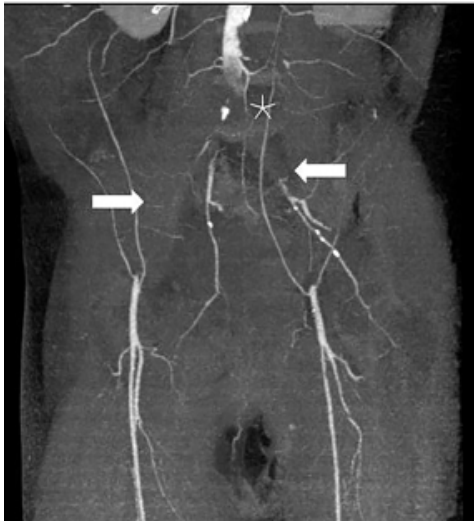
How might this improve emergency medicine practice?

*Providers should consider arterial thrombosis in COVID-19 patients with neurovascular compromise and coagulopathy. Prompt imaging can improve morbidity and mortality.*

nanograms per milliliter (ng/mL) (< 250 ng/mL). His lactate dehydrogenase was 2601 U/L (140-280 U/L). The urinalysis demonstrated 2+ blood and 30 red blood cells. Based on his urinalysis, a computed tomography (CT) abdomen and pelvis was also ordered to evaluate for nephrolithiasis.

The CT of his abdomen did not demonstrate any significant intra-abdominal abnormalities, but he was noted to have diffuse patchy infiltrates in his lower lungs. A chest radiograph demonstrated patchy diffuse bilateral infiltrates. These findings prompted COVID-19 testing, which resulted as positive despite lack of any upper respiratory symptoms. A lumbar spine CT was completed, which was also unremarkable. While in the ED, his pain and weakness worsened and ultimately a magnetic resonance imaging (MRI) of his lumbar spine and a venous duplex of his lower extremities were also obtained and he was admitted for pain control and further workup. The MRI was unremarkable and his lower extremity venous duplex ultrasonography did not demonstrate any acute deep vein thrombosis. Within two hours of his ED stay, an arterial duplex of his lower extremities was performed and demonstrated no blood flow in the right dorsalis pedis artery or left posterior

tibial, anterior tibial, or dorsalis pedis arteries. A computed tomographic angiography (CTA) of the aorta and lower extremities demonstrated diffuse arterial insufficiency with thrombosis of distal abdominal aorta and occlusion of bilateral iliac arteries (Image). He was then placed on a heparin drip. The patient's respiratory status deteriorated over the next few days and he required endotracheal intubation for acute respiratory failure. He was transferred to an outside hospital for possible thrombectomy.



**Image.** Computed tomographic angiography of abdomen and lower extremities with extensive thrombosis of distal abdominal aorta (asterisk) and occlusion of bilateral iliac arteries (arrows).

The thrombectomy was successful; however, the patient's lower extremities were not salvageable and he required bilateral above knee amputations. His hematology workup revealed slight decrease in protein S 39% (reference range 66-143%) with normal protein C, complement, antithrombin 3, homocysteine, and cardiolipin antibodies, and no evidence of disseminated intravascular coagulation (DIC). Ultimately, the patient's respiratory status improved and he was extubated. At the time of writing he remained hospitalized on enoxaparin with discharge planning ongoing.

## DISCUSSION

There is ample documentation of the relatively high rate of thromboembolic complications in critically ill COVID-19 patients. Prior studies of thrombotic events have been estimated to occur in 3.7-45% of COVID-19 cases.<sup>2,5</sup> Prophylaxis and management of thromboembolic complications is an important component of COVID-19 therapy. One retrospective study of 449 admitted severe COVID-19 patients showed that the administration of prophylactic heparin was associated with a marked reduction in mortality (40% vs 64%).<sup>6</sup> However, other observational studies have shown less consistent benefit.<sup>6,7</sup>

As in our case, there are reports that demonstrate an association of lower extremity arterial thromboses such as aortoiliac thromboses and SARS-CoV-2 infection. Vulliamy and colleagues published two cases of patients with COVID-19 pneumonia who also presented with acute thrombotic occlusion of the descending aorta.<sup>3</sup> A recent case series of 16 patients showed a high incidence of aortic and lower extremity arterial thromboses in patients with COVID-19 infection.<sup>1</sup> Prominent features include ischemic leg symptoms, large thrombus burden, and involvement of proximal vessels. Many of these patients required amputation (25%) or had complications that resulted in death (38%). Another cohort of acute lower extremity ischemia in patients diagnosed with COVID-19 pneumonia had an overall mortality rate of 40%.<sup>8</sup> A summary of these case reports and case series is found in the table.

Patients with COVID-19 infection can have pathology consistent with systemic hypercoagulable state, marked by microvascular thrombotic disorders and elevated D-dimer.<sup>9</sup> It can occur despite antithrombotic prophylaxis and be refractory to full anticoagulation.<sup>10</sup> In our case anti-phospholipid antibodies were not elevated, consistent with what has been seen in other series of COVID-19 patients with thrombotic complications.<sup>11</sup> Our patient also did not have evidence of DIC. The modest protein S deficiency manifested by the patient has been hypothesized to contribute to cytokine storm in COVID-19 and could be the result of exuberant dysregulated blood coagulation.<sup>12</sup>

The pathogenesis of hypercoagulability associated with COVID-19 has yet to be fully elucidated, but it is thought to be multifactorial with contributions from excessive inflammation, hypoxia, immobilization and DIC. Additionally, complement pathways may play a role in the pathogenesis of this hypercoagulability. Deposition of complement components has been shown to cause endothelial cell injury and subsequently activate the clotting pathway and lead to fibrin deposition.<sup>13</sup> Multiple studies have documented that in at least a subset of COVID-19 patients, respiratory failure is the result of sustained, complement-mediated thrombotic microvascular injury and activation of catastrophic positive feedback loops with the coagulation system.<sup>9</sup>

Moreover, viral interaction with angiotensin converting enzyme (ACE2) receptors has been postulated to cause an overactivation of complement systems. Research has shown that SARS-CoV-2 enters cells through ACE2 receptors, which leads to downstream effects of increased angiotensin II. Angiotensin II is associated with inflammation and fibrosis and the resulting increases of oxidative stress and complement activation.<sup>13</sup> Patients with severe COVID-19 are observed to have excessive complement activation with elevated lactate dehydrogenase, D-dimer, bilirubin, anemia, and decreased platelets all potentially leading to thrombotic microangiopathy.<sup>10,12,13</sup> Therefore, current research has been targeting complement inhibition for treatment of COVID-19 systemic thrombosis.<sup>7,14</sup>

**Table.** Characteristics of selected case studies demonstrating presence of arterial thromboembolism in coronavirus disease of 2019 positive patients.

Author/Year	Age	Gender	Co-morbidities	Associated pneumonia	Location of arterial thrombus	Thrombectomy	Amputation or surgical intervention	Death
Veyre (2020) <sup>3</sup>	24	M	None	N	Common femoral artery	Y	N	N
Vulliamy (2020) <sup>4</sup>	60	M	None	Y	Infra-renal aorta & bilateral common iliac arteries	Y	N	N
Levolger (2020) <sup>2</sup>	75	M	None	Y	Descending thoracic aorta & superior mesenteric artery	N (catheter directed thrombolysis)	Small bowel resection	N
	50	M	None	Y	Right common iliac artery	Y (received thrombolysis)	N	N
	55	M	None	N	Subclavian artery occlusion	N	N	N
	62	M	Unknown	N	M1 occlusion with subtotal internal carotid stenosis	Y	N	N
Goldman (2020) <sup>1</sup>	Mean Age	Gender	Co-Morbidities	Symptoms	Presence of thrombus	Death or Amputation		
Retrospective propensity score-matched study comparing 16 COVID-19+ patients receiving lower extremity CTA to Control Group	70	7 F 9 M	Variable HTN: 13 DM: 8 HLD: 8 PVD: 8	5 patients presented with only leg symptoms; 11 patients had additional systemic symptoms	All COVID-19+ patients had at least one thrombus between aorta and distal lower extremity arteries	10/16 patients ultimately progressed to death or amputation		

Y, yes; N, no; F, female; M, male; HTN, hypertension; DM, diabetes; HLD, hyperlipidemia; PVD, peripheral vascular disease; CTA, computed tomographic angiography; M1, M1 segment as it originates at the carotid bifurcation and terminates as the middle cerebral artery.

## LIMITATIONS

Literature regarding the association between SARS-CoV-2 and thromboembolism is still rapidly evolving. A recent, large, retrospective study showed that the odds of pulmonary embolism in patients who are diagnosed with COVID-19 vs non-COVID-19 infected patients were not significantly different between the two groups.<sup>15</sup> This may shed some doubt on the association of SARS-CoV-2.

We also could not establish strong causal effect of coagulopathic state with the outcome of the large aortoiliac occlusion in this particular patient. The patient did not initially report a personal or family history of coagulopathies. Additionally, we do not know whether the patient had primary, underlying protein S deficiency, thus making him more susceptible to an increasingly prothrombic state. A hypercoagulable state induced by concomitant COVID-19 infection may have increased the potential for thrombosis,

which could still have made SARS-CoV-2 infection a significant contributing factor. Without known pre-existing risk factors for thromboembolism, the patient still had a devastating thrombotic event. In the presence of abnormal vital signs, neurovascular compromise and coagulopathy, emergency physicians should maintain a high suspicion for thromboembolic events especially if the patient has concomitant COVID-19.

## CONCLUSION

We report a case of a patient with diffuse lower aortic and bilateral iliac arterial thrombosis who tested positively for COVID-19 while lacking any of the common early respiratory complaints. Early recognition of this complication from COVID-19 may have improved outcome, although the literature is unclear on the benefit of anticoagulation. Regardless, emergency physicians should prompt expedient

imaging given presence of leg pain and ischemia in a patient with SARS-CoV-2. Further workup is indicated and early thrombectomy can aid in improved morbidity and mortality.

The authors attest that their institution requires neither Institutional Review Board approval, nor patient consent for publication of this case report. Documentation on file.

---

*Address for Correspondence:* Faith Quenzer, DO, University of California, San Diego, Department of Emergency Medicine, 200 W. Arbor Drive MC-8676, San Diego, CA 92103. Email: fquenzer@health.ucsd.edu.

*Conflicts of Interest:* By the CPC-EM article submission agreement, all authors are required to disclose all affiliations, funding sources and financial or management relationships that could be perceived as potential sources of bias. The authors disclosed none.

*Copyright:* © 2021 LaFree et al. This is an open access article distributed in accordance with the terms of the Creative Commons Attribution (CC BY 4.0) License. See: <http://creativecommons.org/licenses/by/4.0/>

---

## REFERENCES

- Goldman IA, Ye K, Scheinfeld MH. Lower extremity arterial thrombosis associated with COVID-19 is characterized by greater thrombus burden and increased rate of amputation and death. *Radiology*. 2020. In press.
- Levolger S, Bokkers RPH, Wille J, et al. Arterial thrombotic complications in COVID-19 patients. *J Vasc Surg Cases Innov Tech*. 2020;6(3):454-9.
- Vulliamy P, Jacob S, Davenport RA. Acute aorto-iliac and mesenteric arterial thromboses as presenting features of COVID-19. *Br J Haematol*. 2020;189(6):1053-4.
- Lodigiani C, Lapichino G, Carenzo L, et al. Venous and arterial thromboembolic complications in COVID-19 patients admitted to an academic hospital in Milan, Italy. *Thromb Res*. 2020;191:9-14.
- Klok FA, Kruip MJHA, van der Meer NJM, et al. Incidence of thrombotic complications in critically ill ICU patients with COVID-19. *Thromb Res*. 2020;191:145-7.
- Tang N, Bai H, Chen X, et al. Anticoagulant treatment is associated with decreased mortality in severe coronavirus disease 2019 patients with coagulopathy. *J Thromb Haemost*. 2020;18(5):1094-9.
- Paranjpe I, Fuster V, Lala A, et al. Association of treatment dose anticoagulation with in-hospital survival among hospitalized patients with COVID-19. *J Am Coll Cardiol*. 2020;76(1):122-4.
- Bellosta R, Luzzani L, Natalini G, et al. Acute limb ischemia in patients with COVID-19 pneumonia. *J Vasc Surg*. 2020. In press.
- Magro C, Mulvey JJ, Berlin D, et al. Complement associated microvascular injury and thrombosis in the pathogenesis of severe COVID-19 infection: A report of five cases. *Transl Res*. 2020;220:1-13.
- Litjens JF, Leclerc M, Chochois C, et al. High incidence of venous thromboembolic events in anticoagulated severe COVID-19 patients. *J Thromb Haemost*. 2020;18(7):1743-6.
- Galeano-Valle F, Oblitas CM, Ferreiro-Mazón MM, et al. Antiphospholipid antibodies are not elevated in patients with severe COVID-19 pneumonia and venous thromboembolism. *Thromb Res*. 2020;192:113-5.
- Lemke G and Silverman GJ. Blood clots and TAM receptor signalling in COVID-19 pathogenesis. *Nat Rev Immunol*. 2020;20(7):395-6.
- Shagdarsuren E, Wellner M, Braesen JH, et al. Complement activation in angiotensin II-induced organ damage. *Circ Res*. 2005;97(7):716-24.
- Campbell CM and Kahwash R. Will complement inhibition be the new target in treating COVID-19-related systemic thrombosis? *Circulation*. 2020;141(22):1739-41.
- Freund Y, Drogrey M, Miró Ò, et al. IMPROVING EMERGENCY CARE FHU Collaborators. Association Between Pulmonary Embolism and COVID-19 in Emergency Department Patients Undergoing Computed Tomography Pulmonary Angiogram: The PEPCOV International Retrospective Study. *Acad Emerg Med*. 2020. In press.

## A Case Report of Cerebral Venous Thrombosis as a Complication of Coronavirus Disease 2019 in a Well-appearing Patient

Monica Logan, MD  
Kyle Leonard, MD  
Daniel Girzadas Jr, MD

Advocate Christ Medical Center, Department of Emergency Medicine, Oak Lawn, Illinois

Section Editor: Scott Goldstein, MD

Submission history: Submitted August 27, 2020; Revision received October 22, 2020; Accepted November 5, 2020

Electronically published December 7, 2020

Full text available through open access at [http://escholarship.org/uc/uciem\\_cpchem](http://escholarship.org/uc/uciem_cpchem)

DOI: 10.5811/cpcem.2020.11.49633

**Introduction:** While thrombotic complications of severe coronavirus disease 2019 (COVID-19) have been documented, the overall risk in non-critically ill cases of COVID-19 remains unknown.

**Case Report:** We report a case of a previously healthy male patient who presented to the emergency department with headache and extremity paresthesia. The patient was diagnosed with cerebral venous thrombosis (CVT) and found to have a positive COVID-19 test. Inpatient anticoagulation was initiated, and symptoms had largely resolved at discharge.

**Conclusion:** This case demonstrates the importance of considering thrombotic complications, such as CVT, even in well-appearing COVID-19 patients with no other risk factors for thromboembolic disease. [Clin Pract Cases Emerg Med. 2021;5(1):22–25.]

**Keywords:** COVID-19; SARS-CoV-2; cerebral venous thrombosis; stroke; anticoagulation.

---

### INTRODUCTION

Severe acute respiratory syndrome coronavirus 2 (SARS-CoV-2) first emerged in Wuhan, China, in December 2019 as the cause of coronavirus disease 2019 (COVID-19). Since that time, COVID-19 has escalated into a global pandemic as declared by the World Health Organization. Although recognized primarily as a respiratory disease, a growing body of literature has highlighted the association between COVID-19 and significant thromboembolic complications.<sup>1,2</sup> We report a case of a 34-year old male presenting with cerebral venous thrombosis (CVT) in the setting of subacute febrile respiratory illness who was found to be SARS-CoV-2 positive on admission.

Cerebral venous thrombosis is an uncommon cause of stroke affecting approximately 5/1,000,000 people annually, accounting for <1% of all strokes.<sup>3</sup> CVT presents at an earlier age compared to other causes of stroke, typically less than 50 years of age, and affects women more than men at a rate of 3:1, likely due to gender-specific risk factors (pregnancy, postpartum period, oral contraceptive

use).<sup>4</sup> With successful diagnosis and treatment, CVT carries a relatively low overall mortality rate compared with arterial stroke but has a risk of intracranial hemorrhage and a significant incidence of cognitive impairment and difficulty returning to work.<sup>5</sup>

### CASE REPORT

A healthy 34-year-old male employed as a baggage handler at an international airport presented to the emergency department (ED) with a frontal headache, dizziness, left neck pain, as well as paresthesia and subjective weakness in the right upper and lower extremities. One month prior to this presentation, the patient had 10 days of fevers, dry cough, fatigue, diarrhea, anosmia, and ageusia. He had a known SARS-CoV-2 positive contact, but personally had two negative nasopharyngeal tests for SARS-CoV-2. On day 14 after symptom resolution, the patient had a forceful sneeze and sudden onset of a severe, generalized headache. Following the initial onset the headache became intermittent and would resolve with acetaminophen. The patient subsequently

developed blurry vision, imbalance with ambulation, as well as numbness and tingling in his right upper and lower extremities. He decided to come to the ED after dropping objects from his right hand. On review of systems he denied any symptoms of fever, myalgia, nausea, vomiting, abdominal pain, chest pain, shortness of breath, or diarrhea within the prior week. He had no past medical history and denied smoking and drug use.

On physical examination the patient was well appearing with a normal body habitus. His vital signs were as follows: temperature 37.2 degrees Celsius; blood pressure 146/98 millimeters mercury; pulse 80 beats per minute (min); respiratory rate 16 breaths per min; and pulse oximetry 95 percent on room air. The cardiopulmonary examination was unremarkable, and he had normal distal pulses in all extremities. Examination of the ears, nose, and throat was unremarkable. His neurological examination, including full cranial nerve testing, strength, sensation, coordination, and ambulation, was without appreciable deficit. His National Institute of Health Stroke Scale (NIHSS) score was 0.

Laboratory evaluation was significant for a D-dimer quantitative level of 2.31 milligrams per liter (mg/L) fibrinogen-equivalent-units (reference range  $\leq 0.5$  mg/L). The complete blood count, electrolytes, blood glucose, liver enzymes, and kidney function were within normal limits. The initial differential diagnosis included concern for possible carotid or vertebral artery dissection based on headache, left neck pain, and contralateral extremity paresthesia following a forceful sneeze. The patient was sent for a computed tomography angiogram of the head and neck, which revealed absent enhancement and filling defects within the superior sagittal sinus, torcula, left transverse, and left sigmoid sinus, as well as the proximal left internal jugular vein, compatible with cerebral CVT. There was also a partial filling defect within the right transverse venous sinus compatible with partial thrombosis. At this initial ED visit the patient also had a positive rapid SARS-CoV-2 test as part of his routine admission screening. He was treated with intravenous heparin and admitted to the COVID-19 intensive care unit (ICU) with neurology and hematology services on consultation.

During his hospitalization the patient had magnetic resonance imaging, which confirmed presence of dural venous sinus thrombosis along with increased signal in the left posterior frontal and parietal lobes suggestive of a small subarachnoid hemorrhage vs cerebral spinal fluid effusion without acute infarct or midline shift. The hematology consultant ordered hypercoagulability testing that showed a negative factor V Leiden mutation, no activated protein C resistance, undetected Janus kinase-2 mutation, negative peripheral blood flow cytometry for paroxysmal nocturnal hemoglobinuria, negative beta-2 glycoprotein antibodies, and normal protein S activity, with anticardiolipin antibodies still pending. He was positive for circulating lupus anticoagulant although this sample was obtained after initiation of

### *CPC-EM Capsule \*Pending\**

What do we already know about this clinical entity?

*Cerebral venous thrombosis is a rare neurovascular emergency that has been reported in patients with current or recent coronavirus disease 2019 (COVID-19).*

What makes this presentation of disease reportable?

*This is the first case report in the emergency medicine literature of a patient found to have cerebral venous thrombosis in the setting of COVID-19.*

What is the major learning point?

*Cerebral venous thrombosis is a documented complication of COVID-19 and can present in otherwise well-appearing patients with no other risk factors for thrombotic disease.*

How might this improve emergency medicine practice?

*The delay from initial viral illness to onset of thrombotic complication highlights special considerations in evaluating emergency department patients with recent COVID-19 or in those who have already recovered.*

heparin. Lupus anticoagulant testing was to be repeated in a few months out of concern for a possible false-positive result.

At the time of discharge the patient's headache and paresthesia had resolved. He continued to have subjective visual changes as well as a feeling of imbalance. The patient was discharged home on warfarin with close hematology and neurology follow-up.

## **DISCUSSION**

Thrombotic disease has become a well-recognized complication of COVID-19, including deep vein thrombosis, pulmonary embolism, myocardial infarction, and stroke.<sup>1,2,6</sup> The evidence for the increased incidence of thrombotic complications in COVID-19 patients has appropriately focused on the critically ill ICU population, whereas the incidence of thromboembolic complications in non-critically ill COVID-19 patients is considered to be lower.<sup>7,8</sup>

Multiple disease-specific mechanisms have been proposed to explain the increased risk of thrombosis seen in COVID-19. These include severe systemic inflammation leading to hypercoagulability, viral binding to angiotensin converting enzyme-2 receptors on endothelial cells,

endothelial damage, and microvascular thrombosis, as well as patient-specific risk factors such as age, obesity, comorbid conditions, and inherited coagulopathic disease.<sup>1,9,10</sup>

In regard to CVT, there have not been any cases reported in the emergency medicine literature thus far, but there is a prior case series in the neuroradiology literature from a New York medical center describing three patients who developed CVT in the setting of COVID-19. All three patients presented with acute mental status change, had abnormal vital signs and/or abnormal neurologic findings and had multifocal pneumonia on chest imaging. All three of these cases were fatal.<sup>11</sup> In contrast, our case involved a well-appearing patient who had a normal mental status, normal vital signs and a NIHSS score of 0. He had no identifiable risk factors for venous thromboembolism (VTE) by past medical or family history. Additionally, inpatient genetic testing did not identify any definitive inherited hypercoagulable condition.

ED laboratory testing was notable only for an elevated D-dimer level. There is growing evidence that D-dimer levels above 1 mg/L in patients with COVID-19 can help risk stratify patients for increased mortality and thromboembolic complications.<sup>1,12</sup> Thus, emergency physicians may want to consider VTE, including CVT, in their differential diagnosis even in non-critically ill appearing COVID-19 patients who present with concerning symptoms. The additional finding of an elevated D-dimer level may prompt consideration of symptom-related diagnostic imaging even in the absence of other VTE risk factors.

The patient in our case had two prior negative nasopharyngeal SARS-CoV-2 tests prior to his ED visit. The sensitivity of these tests is not well defined. A recent article postulated that if a patient has a pretest probability of infection of 50% and the sensitivity of the SARS-CoV-2 test is 70%, a negative test still leaves the patient with a 23% chance of being infected.<sup>13</sup> Until the testing characteristics of the SARS-CoV-2 test are better defined or improved, emergency physicians will need to continue to consider the possibility of Covid-19 infection and related complications, even when caring for symptomatic patients with a negative SARS-CoV-2 test.

Furthermore, the time lapse between the initial viral illness to the development of a serious thrombotic complication in our patient raises additional concerns. Proposed guidelines from both the American Society of Hematology and the American College of Chest Physicians currently recommend initiation of medical thromboprophylaxis only for hospitalized patients in the absence of contraindication.<sup>1,14,15</sup> Additional expert consensus has also recommended consideration for further short-term thromboprophylaxis for COVID-19 patients who have been discharged from the hospital.<sup>16</sup> As there are no current recommendations for thromboprophylaxis in patients not requiring hospitalization, it may be necessary to consider VTE, including CVT, in non-previously hospitalized patients who present with concerning symptoms weeks to months following their recovery.

## CONCLUSION

Based on prior literature, clinicians anticipate thrombotic complications in critically ill patients infected with SARS-CoV-2.<sup>1,2</sup> A time lapse of 7-14 days or more between initial infection and development of serious thrombotic complications has been reported.<sup>2,8</sup> The risk of thrombotic complications in non-critically ill COVID-19 patients is thought to be lower.<sup>7,8</sup> Our case demonstrates that thrombotic complications such as CVT can occur even in well-appearing, ambulatory COVID-19 patients who present with concerning symptoms.

The authors attest that their institution requires neither Institutional Review Board approval, nor patient consent for publication of this case report. Documentation on file.

---

*Address for Correspondence:* Kyle Leonard, MD, Advocate Christ Medical Center, Department of Emergency Medicine, 4440 W. 95th St., Oak Lawn, IL 60453. Email: Kyle.leonard@aah.org.

*Conflicts of Interest:* By the *CPC-EM* article submission agreement, all authors are required to disclose all affiliations, funding sources and financial or management relationships that could be perceived as potential sources of bias. The authors disclosed none.

*Copyright:* © 2021 Logan et al. This is an open access article distributed in accordance with the terms of the Creative Commons Attribution ([CC BY 4.0](http://creativecommons.org/licenses/by/4.0/)) License. See: <http://creativecommons.org/licenses/by/4.0/>

---

## REFERENCES

1. Kollias A, Kyriakoulis KG, Dimakakos E, et al. Thromboembolic risk and anticoagulant therapy in COVID-19 patients: emerging evidence and call for action. *Br J Haematol.* 2020;189(5):846-7.
2. Klok FA, Kruip MJHA, van der Meer NJM, et al. Confirmation of the high cumulative incidence of thrombotic complications in critically ill ICU patients with COVID-19: an updated analysis. *Thromb Res.* 2020;191:148-50.
3. Mehta A, Danesh J, Kuruvilla D. Cerebral venous thrombosis headache. *Curr Pain Headache Rep.* 2019;23(7):47.
4. Dmytriw AA, Song JSA, Yu E, et al. Cerebral venous thrombosis: state of the art diagnosis and management. *Neuroradiology.* 2018;60(7):669-85.
5. Shakibajahromi B, Borhani-Haghighi A, Ghaedian M, et al. Early, delayed, and expanded intracranial hemorrhage in cerebral venous thrombosis. *Acta Neurol Scand.* 2019;140(6):435-42.
6. Tal S, Spectre G, Kornowski R, et al. Venous thromboembolism complicated with COVID-19: What do we know so far? *Acta Haematol.* 2020;143(5):417-24.
7. Middeldorp S, Coppens M, van Haaps TF, et al. Incidence of venous thromboembolism in hospitalized patients with COVID-19. *J Thromb Haemost.* 2020;18(8):1995-2002.

8. Al-Ani F, Chehade S, Lazo-Langner A. Thrombosis risk associated with COVID-19 infection. A scoping review. *Thromb Res.* 2020;192:152-60.
9. Sardu C, Gambardella J, Morelli MB, et al. Hypertension, thrombosis, kidney failure, and diabetes: Is COVID-19 an endothelial disease? A comprehensive evaluation of clinical and basic evidence. *J Clin Med.* 2020;9(5):1417.
10. Hemasian H and Ansari B. First case of Covid-19 presented with cerebral venous thrombosis: a rare and dreaded case. *Rev Neurol (Paris).* 2020;176(6):521-3.
11. Cavalcanti DD, Raz E, Shapiro M, et al. Cerebral venous thrombosis associated with COVID-19. *AJNR Am J Neuroradiol.* 2020;41(8):1370-6.
12. Artifoni M, Danic G, Gautier G, et al. Systematic assessment of venous thromboembolism in COVID-19 patients receiving thromboprophylaxis: incidence and role of D-dimer as predictive factors. *J Thromb Thrombolysis.* 2020;50(1):211-6.
13. Woloshin S, Patel N, Kesselheim AS. False negative tests for SARS-CoV-2 infection: challenges and implications. *N Engl J Med.* 2020;383(6):e38.
14. Barnes GD, Burnett A, Allen A, et al. Thromboembolism and anticoagulant therapy during the COVID-19 pandemic: interim clinical guidance from the anticoagulation forum. *J Thromb Thrombolysis.* 2020;50(1):72-81.
15. Moores LK, Tritschler T, Brosnahan S, et al. Prevention, diagnosis, and treatment of VTE in patients with coronavirus disease 2019: CHEST Guideline and Expert Panel Report. *Chest.* 2020;158(3):1143-63.
16. Zhai Z, Li C, Chen Y, et al. Prevention and treatment of venous thromboembolism associated with coronavirus disease 2019 infection: a consensus statement before guidelines. *Thromb Haemost.* 2020;120(6):937-48.

# COVID-19 Presenting as Encephalopathy in the Emergency Department: A Case Report

Travis B. Goodloe III, MD  
Lauren A. Walter, MD

University of Alabama Birmingham, Department of Emergency Medicine,  
Birmingham, Alabama

Section Editor: Steven Walsh, MD

Submission history: Submitted September 25, 2020; Revision received December 9, 2020; Accepted December 11, 2020

Electronically published January 26, 2021

Full text available through open access at [http://escholarship.org/uc/uciem\\_cpchem](http://escholarship.org/uc/uciem_cpchem)

DOI: 10.5811/cpchem.2020.12.50036

**Introduction:** The severe acute respiratory syndrome coronavirus-2 (SARS-CoV-2), the etiology of the coronavirus disease 2019 (COVID-19) pandemic, has proven to be an era-defining illness with profound impact on patients and healthcare providers alike. By nearly all measures, daily cases and deaths are growing on a global scale despite conscious infection control efforts. As the medical community strives to better understand the pathogenesis of COVID-19, it has become increasingly appreciated that this “respiratory virus” can present clinically with a wide range of signs and symptoms not necessarily confined to the respiratory system.

**Case Report:** Specifically, the central nervous system has been described as the presenting complaint of COVID-19, including anosmia and headaches and, more rarely, meningitis. This clinical case highlights the presentation of a 52-year-old male who presented to the emergency department with altered mental status and fever, ultimately attributed to COVID-19 infection.

**Conclusion:** This case serves to add to the growing body of evidence surrounding the potentially severe neuropathologic capabilities of the novel SARS-CoV-2 virus. [Clin Pract Cases Emerg Med. 2021;5(1):26–29.]

**Keywords:** COVID-19; encephalopathy; neuropathic; fever; case report.

---

## INTRODUCTION

Severe acute respiratory syndrome coronavirus-2 (SARS-CoV-2), known to cause coronavirus disease 2019 (COVID-19), is primarily considered a viral agent that causes respiratory disease; however, there is increasing evidence regarding the neuropathic capabilities and manifestations of the virus. Neurologic manifestations have been reported to range from mild accounts of headache, ageusia, and anosmia to more severe cases of encephalitis, myelitis, Guillain-Barré syndrome, polyradiculopathy, and even cerebrovascular disease.<sup>1,2</sup> It has been noted that patients with predisposing comorbidities such as hypertension, diabetes, and coronary artery disease are at increased risk for neurological sequelae of COVID-19.<sup>3</sup>

Neurologic involvement is thought to occur through several potential mechanisms. These include central nervous

system access via specific receptors, namely the angiotensin converting enzyme 2 (ACE2) receptor as well as retrograde viral movement along axons, most frequently the olfactory nerve. It has also been suggested that neurological injury may be due to cytokine toxicity-related injury or secondary hypoxia due to cerebral edema and ischemia.<sup>2,3</sup> Of these proposed mechanisms, the neurotoxicity related to cytokine storm has garnered significant attention. It is thought that the hypoxic and metabolic changes that occur due to the presence of cytokines in the brain parenchyma lead to dysregulation of typical metabolic processes.<sup>4,5</sup> This subsequently can present clinically as encephalopathy, which can be defined as diffuse brain dysfunction that manifests as varying degrees of altered consciousness.<sup>4</sup> Our intent in this case report was to further contribute to the growing body of literature describing the neurological presentations and manifestations of COVID-19.

**CASE REPORT**

A 52-year-old male with a past medical history of hypertension, diabetes mellitus type 2, end-stage renal disease (ESRD) on hemodialysis (HD), coronary artery disease status post coronary artery bypass grafting, and past cerebrovascular accident presented to the emergency department (ED) with altered mental status. The patient had been well, per family, including an uncomplicated HD session earlier that day, until the evening of presentation when family noted that he had increasing confusion and agitation, progressive for three to four hours, prompting them to call 911. On arrival to the patient's home, paramedics noted that he was severely agitated, moaning loudly, and "jerking about," particularly the bilateral upper extremities. To facilitate safe transfer to the hospital and due to paramedic concern for possible seizure-like activity, they administered midazolam five milligrams (mg) intramuscularly.

Upon presentation to the ED, the patient was noted to be febrile (38.94°C), tachycardic (115 beats per minute), and hypertensive (blood pressure 224/104 millimeters mercury (mmHg)). He was moaning loudly with no coherent speech and unable to follow specific commands; however, he was responding to painful stimuli and appeared to respond to his name. Additionally, the patient was moving all extremities spontaneously and had no appreciable cranial nerve defects. The remainder of his physical exam revealed clear breath sounds bilaterally, no abdominal distension or perceived tenderness, and warm, dry, intact skin with no signs of breakdown or ulcers. Further evaluation and treatment were initiated, and the patient was started on vancomycin, ceftriaxone, azithromycin, and acyclovir for empiric meningitis coverage. A clevidipine infusion at one mg per hour was also started in the ED.

One hour after arrival and treatment initiation, the patient's blood pressure was 143/90 mm Hg, and the infusion was discontinued. Additionally, chest radiograph did not show any acute abnormality, and computed tomography (CT) of the head without contrast showed chronic changes in the left putamen in the setting of known remote cerebrovascular accident. Laboratory evaluation was significant for an elevated blood urea nitrogen of 60 mg per deciliter (mg/dL) (reference range: 7-20 mg/dL) and creatinine of 8.3 mg/dL (0.8-1.2 mg/dL) in the setting of known ESRD. Otherwise, urinalysis did not show evidence of infection, urinary drug screen was negative, white blood cell count was  $7.05 \times 10^3$ /microliter (mL) ( $4.5-11 \times 10^3$ /mL), and salicylate and acetaminophen levels were within normal limits. However, nasopharyngeal polymerase chain reaction (PCR) swab returned positive for SARS-CoV-2. A lumbar puncture was also performed, which evidenced clear cerebrospinal fluid (CSF), white blood cell count of zero per cubic millimeter ( $\text{mm}^3$ ) ( $0-5/\text{mm}^3$ ), protein of 46 mg/dL (10-60 mg/dL), and mildly elevated glucose of 121

*CPC-EM Capsule*

What do we already know about this clinical entity?

*Coronavirus disease 2019 (COVID-19) has primarily emerged as an upper airway and respiratory disease; however, it manifests in a myriad of clinical presentations.*

What makes this presentation of disease reportable?

*We detail a case of a 52-year-old male who presented with encephalopathy attributed to the virus but without any respiratory symptoms.*

What is the major learning point?

*Continued reporting of novel presentations of this disease entity will hone providers' clinical acumen and ability to recognize COVID-19 in less typical, non-respiratory presentations.*

How might this improve emergency medicine practice?

*Continued research regarding viral pathology and the array of presentations will enable providers to identify and intervene with patients presenting with this deadly virus.*

mg/100 mL (50-80 mg/100 mL). The patient was admitted to the intensive care unit (ICU) for further management.

During ICU admission, the patient remained encephalopathic despite administration of antipyretics in the ED. His blood pressure remained stable with systolic less than 180 mm Hg with lisinopril 20 mg and amlodipine 10 mg daily. Antibiotic coverage was discontinued after approximately 48 hours as no signs of infection were present clinically or by laboratory evidence, and CSF culture returned negative (including varicella, herpes simplex, and cytomegalovirus). Magnetic resonance imaging (MRI) of the brain was performed on the morning of ICU day two, which did not show any acute pathologic changes. Continuous electroencephalogram for 24 hours was begun approximately six hours after initial presentation and showed evidence of mild, diffuse cerebral dysfunction. On ICU day three, the patient's mentation began to improve, and he was noted to be increasingly alert, able to follow basic commands and speak simple phrases. On hospital day four, the patient was downgraded to a floor bed setting where he remained for an additional five days until his mentation was considered "back to baseline" with subsequent hospital discharge.

Repeat SARS-CoV-2 testing during outpatient follow-up 20 days after his initial ED presentation was negative. To date, the patient appears to have fully recovered from this episode of encephalopathy without neurologic sequelae.

## DISCUSSION

Medical literature that has emerged during the pandemic, including some case reports, has provided clinical anecdotes as well as evidence of how COVID-19 may present with neurological signs and symptoms. Although the specific mechanism for neurologic involvement is still being investigated, patients with complex medical histories and comorbidities appear to be at an increased risk for the neurological complications of SARS-CoV-2 infection.<sup>6</sup>

This case presentation of a 52-year-old male with multiple comorbidities who presented with febrile encephalopathy and SARS-CoV-2 positive serology in the absence of any other identifiable infectious or metabolic source provides an additional example of the neuropathologic capabilities of SARS-CoV-2. Although this patient's CSF studies did not show findings consistent with inflammation, including pleocytosis or elevated protein, this is not an uncommon finding in viral encephalitis.<sup>3</sup> Likewise, neurological imaging was unremarkable for acute processes; however, again, normal CT and/or MRI imaging is not uncommon in viral encephalitis, particularly early in the disease process.<sup>3</sup> Posterior reversible encephalopathy syndrome was also considered but thought to be less likely in the absence of neuroradiographic abnormalities.<sup>7</sup>

Of note, the patient did present with significantly elevated blood pressure, which has been reported to be a major complicating factor in many SARS-CoV-2 cases.<sup>8</sup> It is thought that as cerebral blood flow becomes compromised at increasingly elevated blood pressures, encephalopathy can develop due to the subsequent hypoxic effects.<sup>9</sup> The virus' effect on ACE2 receptors in the brain likely also plays a role in this dynamic, especially in patients already taking ACE inhibitors. There is no consensus at this time on the exact mechanisms involved, but viral binding to the ACE2 receptor may lead to an element of renin-angiotensin-aldosterone system disruption that could exacerbate or alter disease presentation in those with pre-existing hypertension.<sup>10</sup>

Additionally, it is important to note that encephalopathy is pathologically different from true encephalitis, which is characterized by inflammation of the brain itself. Reported cases of SARS-CoV-2 presence in CSF as evidenced by pleocytosis and PCR detection, as well as acute changes visualized on neurological imaging, exist in the literature.<sup>11</sup> However, literature review reveals that the predominance of reported encephalopathic presentations of patients infected with SARS-CoV-2 are not found to have

these aforementioned features present.<sup>3</sup> Because neurological manifestations of SARS-CoV-2 are being increasingly recognized, clinical consideration of infection with this virus cannot be excluded in patients who present to the ED with new-onset neurological complaints or symptoms. It has been clearly established that these symptoms alone may be the only initial features of a SARS-CoV-2 positive patient's clinical picture.

Lastly, it is of note that if neurological involvement is ultimately found to be primarily mediated by immune dysfunction and cytokine storm as discussed previously, then this greatly expands the potential for treatment of COVID-19 through utilization of existing drug agents that function to dampen this response. In this way, these treatment modalities may have utility in this unique subset of patients presenting with significant neurological manifestations.

## CONCLUSION

The coronavirus disease 2019 has undoubtedly raised significant questions and prompted a vast mobilization of research due to its novelty and its increasingly recognized variability in clinical presentation. The case presented in this report is evidence of this variability and underscores the importance of considering COVID-19 as a potential cause of a wide range of neurological manifestations. In today's healthcare environment, providers should not overlook COVID-19 as a source of altered mental status, especially in the context of patients presenting to the ED. Without question, further research and evaluation is needed to better understand the neuropathologic capacities of COVID-19 as well as its long-term impacts on those with pre-existing medical comorbidities.

The authors attest that their institution requires neither Institutional Review Board approval, nor patient consent for publication of this case report. Documentation on file.

---

*Address for Correspondence:* Travis B. Goodloe III, MD, University of Alabama, Department of Emergency Medicine, 620 20th Street South, Birmingham, AL 35249. Email: tgoodloe@uabmc.edu.

*Conflicts of Interest:* By the CPC-EM article submission agreement, all authors are required to disclose all affiliations, funding sources and financial or management relationships that could be perceived as potential sources of bias. The authors disclosed none.

*Copyright:* © 2021 Goodloe III et al. This is an open access article distributed in accordance with the terms of the Creative Commons Attribution (CC BY 4.0) License. See: <http://creativecommons.org/licenses/by/4.0/>

---

## REFERENCES

1. Moriguchi T, Harii N, Goto J, et al. A first case of meningitis/encephalitis associated with SARS-Coronavirus-2. *Int J Infect Dis.* 2020;94:55-8.
2. Bridwell R, Long B, Gottlieb M. Neurologic complications of COVID-19. *Am J Emerg Med.* 2020;38(7):1549.e3-7.
3. Ellul MA, Benjamin L, Singh B, et al. Neurological associations of COVID-19. *Lancet Neurol.* 2020;19(9):767-83.
4. Garg RK, Paliwal VK, Gupta A. Encephalopathy in patients with COVID-19: a review. *J Med Virol.* 2020. In press.
5. Benameur K, Agarwal A, Auld SC, et al. Encephalopathy and encephalitis associated with cerebrospinal fluid cytokine alterations and coronavirus disease, Atlanta, Georgia, USA, 2020. *Emerg Infect Dis.* 2020;26(9):2016-21.
6. Koranik IJ and Tyler KL. COVID-19: A global threat to the nervous system. *Ann Neurol.* 2020;88(1):1-11.
7. Fugate JE and Rabinstein AA. Posterior reversible encephalopathy syndrome: clinical and radiological manifestations, pathophysiology, and outstanding questions. *Lancet Neurol.* 2015;14(9):914-25. Erratum in: *Lancet Neurol.* 2015;14(9):874.
8. Berger JR. COVID-19 and the nervous system. *J Neurovirol.* 2020;26(2):143-148.
9. Ahmad I and Rathore FA. Neurological manifestations and complications of COVID-19: a literature review. *J Clin Neurosci.* 2020;77:8-12.
10. Kulkarni S, Jenner BL, Wilkinson I. COVID-19 and hypertension. *J Renin Angiotensin Aldosterone Syst.* 2020;21(2):1470320320927851.
11. Tsivgoulis G, Palaodimou L, Katsanos AH, et al S. Neurological manifestations and implications of COVID-19 pandemic. *Ther Adv Neurol Disord.* 2020;13:1756286420932036.

## Where There's Smoke, There's Fire: A Case Report of Turbulent Blood Flow in Lower Extremity Point-of-care Ultrasound in COVID-19

Mathew Nelson, DO  
Dorothy Shi, MD  
Miles Gordon, MD  
Yash Chavda, DO  
Christina Grimaldi, PA-C  
Tanya Bajaj, DO

North Shore University Hospital, Department of Emergency Medicine, Manhasset, New York

Section Editor: Shadi Lahham, MD

Submission history: Submitted June 18, 2020; Revision received October 8, 2020; Accepted October 10, 2020

Electronically published November 23, 2020

Full text available through open access at [http://escholarship.org/uc/uciem\\_cpem](http://escholarship.org/uc/uciem_cpem)

DOI: 10.5811/cpcem.2020.10.48809

**Introduction:** Coronavirus disease 2019 (COVID-19) may predispose patients to increased risk of venous thromboembolism (VTE) due to various pathophysiological mechanisms, including but not limited to endothelial injury, inflammation, cytokine-mediated microvascular damage, and reactive thrombocytosis. A high risk of vessel thrombosis correlates with disease severity, making early identification and treatment of prime consideration.

Although identification of a deep venous thrombosis (DVT) or pulmonary embolism warrants immediate treatment with anticoagulation, trying to predict which COVID-19 patients may be at increased risk for developing these pathologies is challenging.

**Case Reports:** We present two cases of patients with COVID-19 who had ultrasonographic findings of turbulent blood flow within the deep venous system, without clear evidence of acute proximal DVT, who were subsequently found to have significant VTE.

**Conclusion:** Point-of-care lower extremity ultrasound has become one of the core applications used by emergency physicians. Typically we perform compression ultrasound for DVT evaluation. This novel finding of turbulent blood flow, or “smoke,” within the deep venous system, may serve as a marker of increased risk of clot development and could be an indication to consider early anticoagulation. [Clin Pract Cases Emerg Med. 2021;5(1):30–34.]

**Keywords:** *Point-of-care ultrasound; COVID-19; thromboembolism.*

---

### INTRODUCTION

Coronavirus disease 2019 (COVID-19), the viral illness caused by severe acute respiratory syndrome coronavirus 2 (SARS-CoV-2), has been declared a global pandemic since its initial spread from Wuhan, China. As of June 4, 2020, there have been 6.6 million cases worldwide with more than 389,000 reported deaths.<sup>4</sup> While many people are asymptomatic or have mild symptoms, patients requiring hospitalization have

experienced high mortality rates, often thought to be in part due to undiagnosed venous thromboembolism (VTE). A study of patients hospitalized with COVID-19 showed a cumulative rate of VTE of 21%.<sup>5</sup> Virchow's triad of factors contributing to thrombosis consists of hypercoagulability, hemodynamic stasis, and endothelial injury. Patients suffering from COVID-19 are at particularly high risk for developing VTE due to increased platelet activation, endothelial dysfunction, hemostasis,

hypoxemic vasoconstriction, and activation of hypoxia-inducible factors.<sup>6,7</sup>

Although data is limited at this time, several studies have suggested that despite being on anticoagulation, patients have high rates of VTE; either deep venous thrombosis (DVT) or pulmonary embolism (PE) were found in up to 27% of COVID-19 polymerase chain reaction (PCR) positive patients.<sup>7,8</sup> Patients with COVID-19 also have high rates of other prothrombotic complications such as clotting within the continuous renal replacement therapy (CRRT) or extracorporeal membrane oxygenation (ECMO) circuits.<sup>7</sup> Although patients are suffering from VTE despite being on anticoagulation, a preliminary study from the Mount Sinai health system suggests that systemic anticoagulation may still be associated with improved outcomes.<sup>8</sup>

DVT is a common pathology with an incidence of approximately 100 persons per 100,000 each year in the general population, with higher rates in advancing age.<sup>9</sup> Early recognition and treatment of VTE is important as it is associated with a 28-day case-fatality rate of 11% for a first-time VTE in those over 45 years old.<sup>10</sup> Diagnosis of VTE begins with risk stratification based on history and physical exam findings, followed by imaging modalities including lower extremity ultrasonography or computed tomography angiogram (CTA).

Although there are many ultrasonographic findings suggestive of a thrombus, we report an ultrasonographic finding of slow, turbulent blood flow, or “smoke,” in the deep venous system in two patients presenting with signs and symptoms of COVID-19. In the first case, a patient with “smoke” but an otherwise negative point-of-care ultrasound (POCUS), was found to have a large PE; in the second case the patient was appropriately discharged but returned to the emergency department (ED) days later and ultimately died of a suspected massive PE. Similar findings suggestive of slow venous flow have been reported by Jensen et al<sup>11</sup> in oncology patients. In this paper, the ultrasonographic findings were correlated with a near doubling of the risk of developing a DVT. As there is an increased risk of VTE with COVID-19, the addition of ultrasonographic findings of slow, turbulent flow in the deep veins may suggest that providers may need to start thromboprophylaxis earlier or, at a minimum, ensure increased surveillance and follow-up of these patients.

## CASE REPORTS

### Case 1

A 61-year-old male with no known past medical history, presented with fevers and shortness of breath for three weeks. The patient was seen at another hospital one week prior where he tested positive for COVID-19. On physical exam the patient was ill-appearing, with an increased work of breathing and an oxygen saturation of 77% on room air, which improved to 95% on a 15-liter (L) non-rebreather mask. The rest of his exam was otherwise unremarkable. Laboratory evaluation showed an elevated D-dimer 1556 nanograms per milliliter (ng/mL) [ $\leq$

### CPC-EM Capsule

What do we already know about this clinical entity?

*Little is known about the link between Coronavirus Disease 2019 (COVID-19) and increased turbulent blood flow, or “smoke,” in the deep venous system.*

What makes this presentation of disease reportable?

*This novel finding of increased turbulent blood flow in two COVID-19 patients suggests that the presence of “smoke” may mark an increased risk for clot development.*

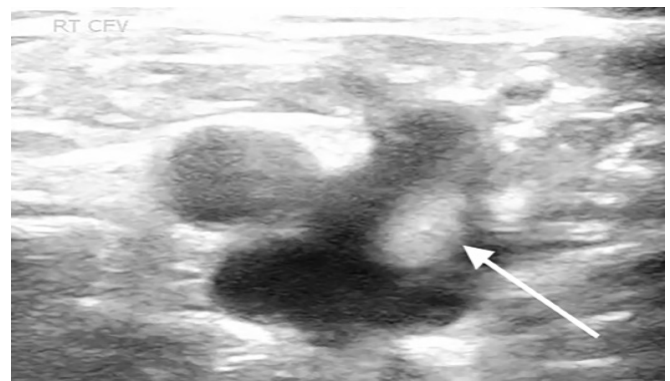
What is the major learning point?

*Turbulent flow may be indicative of ongoing thromboembolic disease and may be used as a predictor for thromboembolic events in COVID-19 patients.*

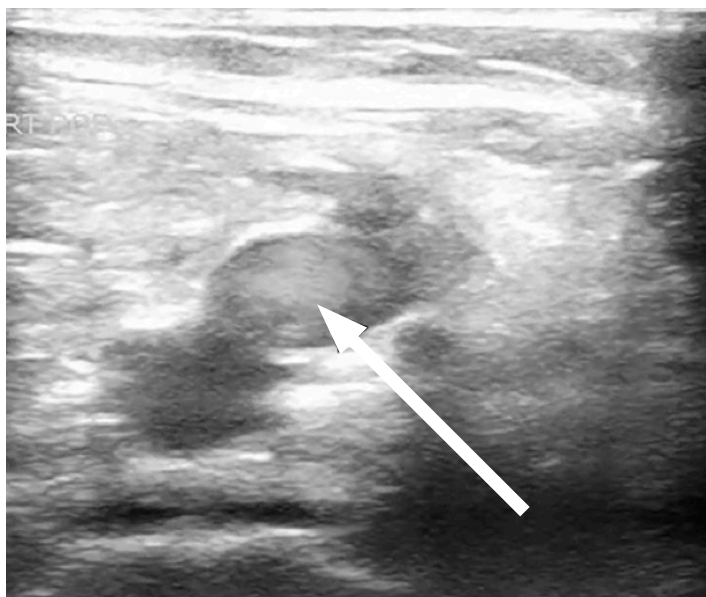
How might this improve emergency medicine practice?

*In patients with COVID-19, bilateral lower extremity duplex demonstrating turbulent flow may lead to earlier detection and treatment of thromboembolic disease.*

229ng/mL D-dimer units], elevated high-sensitivity troponin of 360 ng/L [reference range 0-51 ng/L], and elevated serum pro-brain natriuretic peptide of 2209 picograms (pg)/mL [ref range 0-300 pg/mL]. Chest radiograph demonstrated patchy bilateral opacities. Point-of-care lower extremity duplex compression ultrasound demonstrated adequate compression but multiple areas of turbulent flow within the deep venous system (Image 1 and 2).



**Image 1.** Point-of-care ultrasound of the lower extremity with arrow identifying hyperechoic turbulent flow in the saphenous-common femoral vein junction.



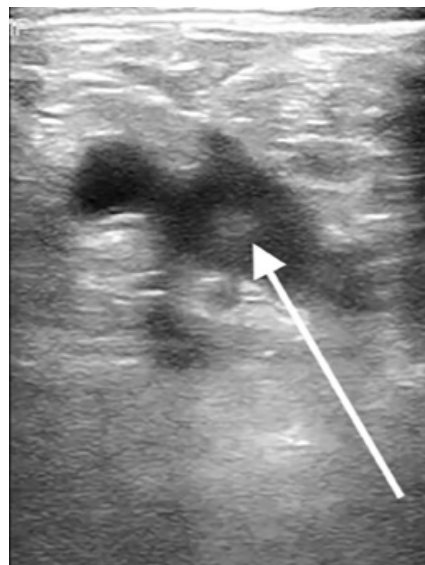
**Image 2.** Point-of-care ultrasound of the lower extremity with arrow identifying hyperechoic turbulent flow in the popliteal vein.

A CTA of the chest showed a PE within the right main pulmonary artery extending into the right upper lobar and segmental pulmonary arteries. The patient was started on therapeutic heparin. He progressively worsened, becoming hypotensive, tachypneic, and acidotic. He was subsequently intubated several days later and ultimately expired.

### Case 2

A 54-year-old male with a history of diabetes, hypertension, hyperlipidemia, hypothyroidism, coronary artery disease, and a DVT, who had not been on anticoagulation at the time due to gastrointestinal bleeding, presented to the ED with fever, chills, body aches, and chest tightness as well as worsening bilateral calf pain. The patient reported feeling ill for the prior 10 days with progressively worsening symptoms of fatigue, fever, myalgias, and diarrhea. The patient was a hospital employee and tested positive for COVID-19 four days prior to the ED visit. Upon arrival to the ED he was found to be hypoxic to 90% on room air, tachypneic with a respiratory rate of 20 breaths per minutes, tachycardic with a heart rate of 102 beats per minute, afebrile with oral temperature of 98.7 degrees Fahrenheit, and blood pressure of 125/75 millimeters mercury. On physical exam the patient was ill-appearing with increased work of breathing, decreased breath sounds bilaterally, and bilateral calf tenderness to palpation. Laboratory evaluation showed an elevated D-dimer of 465 ng/ml (with a normal cutoff value of 229 ng/ml). A point-of-care lower extremity duplex compression ultrasound demonstrated turbulent blood flow in the right lower extremity (Image 3).

A right calf vein thrombosis was noted distal to the trifurcation. (This was an incidental finding as calf vein imaging is not part of the compression ultrasound



**Image 3.** Point-of-care ultrasound of the lower extremity with arrow identifying hyperechoic turbulent flow in the common femoral vein.

protocol.) A CTA was negative for PE but showed bilateral peripheral ground-glass opacities. The patient was placed on supplemental oxygen, started on enoxaparin and admitted to the hospital. He was admitted for four days with improvement and discharged home on anticoagulation. The patient returned to the ED five days later with worsening shortness of breath, hypoxia, and chest pain. A CTA again demonstrated no PE. D-dimer at that time was 31,876 ng/ml. During the second admission, a subsequent comprehensive ultrasound demonstrated a persistent calf vein thrombosis, and the patient's D-dimer continued to downtrend but was significantly higher than on the prior visit. Radiology did not comment on the turbulent flow finding; however, upon retrospective review of these images, the patient continued to have turbulent flow in the deep venous system of the lower extremity. His oxygen requirements continued to escalate along with the deterioration of his hemodynamics. A repeat bedside echocardiogram showed evidence of right heart strain with an enlarged right ventricle, septal bowing, and low tricuspid annular plane systolic excursion. He was given tissue plasminogen activator for a suspected massive PE, without significant improvement and ultimately expired in the intensive care unit.

### DISCUSSION

Venous thromboembolism diagnosis and treatment is a common challenge among emergency providers. Studies have continually attempted to investigate how lab values, such as fibrinogen and D-dimer, may help risk-stratify patients at risk for VTE and predict mortality rates.<sup>12</sup> Traditionally in the ED, D-dimer cutoff levels are used to decide whether further imaging such as

lower extremity ultrasound or CTA chest is warranted. In COVID-19 patients, D-dimer levels seem to be intrinsically elevated, thereby making it a less useful tool to risk-stratify COVID-19 patients. There have been suggestions to modify the D-dimer cutoff levels in order to adapt to COVID-19 pandemic; however, no conclusion has been established to date.<sup>13</sup> To our knowledge, this case report is the first to suggest how an ultrasonographic sign can be used as an adjunct to risk-stratify COVID-19 patients for possible VTE events.

Venous stasis as it relates to VTE has been recognized for years but has been studied in only a few subgroups. Jensen et al<sup>11</sup> described slow venous flow state on ultrasound in oncology patients and how it correlates with higher risk of developing DVTs. We describe this finding in the context of COVID-19 patients. In several COVID-19 patients in our ED, emergency ultrasound fellowship-trained physicians found the ultrasonographic finding of static, turbulent flow, or “smoke,” in the deep venous system without clear evidence of a proximal DVT. In some of these patients we identified this finding in bilateral lower extremities. Typically a DVT is ruled out with a comprehensive duplex ultrasound with Doppler to evaluate for compressibility and normal spectral waveforms<sup>14</sup> POCUS has been used successfully in evaluating the presence of proximal lower extremity thrombosis with compression ultrasound.<sup>15</sup>

We hypothesize that ultrasonographic “smoke” can be an early indicator of venous stasis in COVID-19 patients, which would be associated with increased risk of developing future VTE. Even though evaluation of “smoke” is not a typical component of point-of-care lower extremity ultrasound, we suggest that emergency providers be aware of this finding and its potential prognostic significance for possible development of VTE. In addition, the finding of “smoke” may suggest that closer surveillance of COVID-19 positive patients for VTE may be necessary.

## CONCLUSION

Multiple studies have highlighted the higher risk of thrombotic events in COVID-19 patients and have attempted to correlate laboratory values with venous thromboembolism risk. We propose the addition of the ultrasonographic finding of slow turbulent flow, or “smoke,” as a risk factor for VTE and should prompt the provider to highly consider thromboprophylaxis, or at the very least lower the threshold for further imaging to evaluate for significant VTE.

## ACKNOWLEDGMENTS

I would like to acknowledge the following people for their participation and contributions to this paper: Allison Cohen, MD, Edward Carlin, MD, Ashley Voroba, MD, and Brendon Stankard, PA-C.

The authors attest that their institution requires neither Institutional Review Board approval, nor patient consent for publication of this case report. Documentation on file.

---

*Address for Correspondence:* Matthew Nelson, DO, North Shore University Hospital, Department of Emergency Medicine, 300 community drive, Manhasset, NY 11030. Email: Mnelson9@optonline.net.

*Conflicts of Interest:* By the CPC-EM article submission agreement, all authors are required to disclose all affiliations, funding sources and financial or management relationships that could be perceived as potential sources of bias. The authors disclosed none.

*Copyright:* © 2021 Nelson et al. This is an open access article distributed in accordance with the terms of the Creative Commons Attribution (CC BY 4.0) License. See: <http://creativecommons.org/licenses/by/4.0/>

---

## REFERENCES

1. Bikdeli B, Madhavan MV, Jimenez D, et al. COVID-19 and thrombotic or thromboembolic disease: implications for prevention, antithrombotic therapy, and follow-up: JACC state-of-the-art review. *J Am Coll Cardiol.* 2020;75(23):2950-73.
2. Mei H and Hu Y. [Characteristics, causes, diagnosis and treatment of coagulation dysfunction in patients with COVID-19]. *Zhonghua Xue Ye Xue Za Zhi.* 2020;41(3):185-91.
3. Tang N, Bai H, Chen X, et al. Anticoagulant treatment is associated with decreased mortality in severe coronavirus disease 2019 patients with coagulopathy. *J Thromb Haemost* 2020;18(5):1094-9.
4. Johns Hopkins University Resource Center. COVID-19 Dashboard by the Center for Systems Science and Engineering (CSSE) at Johns Hopkins University (JHU). 2020. Available at: <https://www.coronavirus.jhu.edu/map.html>. Accessed June 4, 2020.
5. Lodigiani C, Iapichino G, Carenzo L, et al. Humanitas COVID-19 Task Force. Venous and arterial thromboembolic complications in COVID-19 patients admitted to an academic hospital in Milan, Italy. *Thromb Res.* 2020;191:9-14.
6. Helms J, Tacquard C, Severac F, et al. High risk of thrombosis in patients with severe SARS-CoV-2 infection: a multicenter prospective cohort study. *Intensive Care Med.* 2020;46(6):1089-98.
7. Menter T, Haslbauer JD, Nienhold R, et al. Postmortem examination of COVID-19 patients reveals diffuse alveolar damage with severe capillary congestion and variegated findings in lungs and other organs suggesting vascular dysfunction. *Histopathology.* 2020;77(2):198–209.
8. Cui S, Chen S, Li X, et al. Prevalence of venous thromboembolism in patients with severe novel coronavirus pneumonia. *J Thromb Haemost.* 2020;18(6):1421-4.
9. White RH. The epidemiology of venous thromboembolism.

- Circulation*. 2003;107(23 Suppl 1):I4-8.
10. Cushman M, Tsai AW, White RH, et al. Deep vein thrombosis and pulmonary embolism in two cohorts: the longitudinal investigation of thromboembolism etiology. *Am J Med*. 2004;117(1):19-25.
  11. Jensen CT, Chahin A, Amin VD, et al. Qualitative slow blood flow in lower extremity deep veins on Doppler sonography: quantitative assessment and preliminary evaluation of correlation with subsequent deep venous thrombosis development in a tertiary care oncology center. *J Ultrasound Med*. 2017;36(9):1867-74.
  12. Kollias A, Kyriakoulis KG, Dimakakos E, et al. Thromboembolic risk and anticoagulant therapy in COVID-19 patients: emerging evidence and call for action. *Br J Haematol*. 2020;189(5):846-7.
  13. Obi AT, Barnes GD, Wakefield TW, et al. Practical diagnosis and treatment of suspected venous thromboembolism during COVID-19 pandemic. *J Vasc Surg Venous Lymphat Disord*. 2020;8(4):526-34.
  14. Needleman L, Cronan JJ, Lilly MP, et al. Ultrasound for lower extremity deep venous thrombosis: multidisciplinary recommendations from the Society of Radiologists in Ultrasound Consensus Conference. *Circulation*. 2018;137(14):1505-15.
  15. Dehbozorgi A, Damghani F, Mousavi-Roknabadi RS, et al. Accuracy of three-point compression ultrasound for the diagnosis of proximal deep-vein thrombosis in emergency department. *J Res Med Sci*. 2019;24:80.

# A Case Report on Distinguishing Emphysematous Pyelitis and Pyelonephritis on Point-of-care Ultrasound

**Proma Mazumder, BS\***  
**Fares Al-Khouja, MS†°**  
**John Moeller, MD‡**  
**Shadi Lahham, MD, MS‡**

\*Touro University Nevada, School of Osteopathic Medicine, Henderson, Nevada  
†University of California, Irvine, School of Medicine, Irvine, California  
‡University of California, Irvine, Department of Emergency Medicine, Orange, California  
°Co-first authors

Section Editor: Melanie Heniff, MD, JD

Submission history: Submitted September 15, 2020; Revision received October 20, 2020; Accepted November 5, 2020

Electronically published December 31, 2020

Full text available through open access at [http://escholarship.org/uc/uciem\\_cpccem](http://escholarship.org/uc/uciem_cpccem)

DOI: 10.5811/cpcem.2020.11.49892

**Introduction:** Point-of-care ultrasound (POCUS) in the emergency department (ED) is being performed with increasing frequency. The objective of this study was to demonstrate how utilization of POCUS can help the emergency physician recognize emphysematous pyelitis (EP) and emphysematous pyelonephritis (EPN).

**Case Report:** A 60-year-old female presented to the ED with normal vital signs and intermittent left-sided flank pain that radiated to her groin. She also had a history of obstructive nephrolithiasis. Within 20 minutes of arrival she became febrile (101.2°Fahrenheit), tachycardic (114 beats per minute), tachypneic (21 breaths per minute), and had a blood pressure of 114/82 millimeters mercury. POCUS was conducted revealing heterogeneous artifact with “dirty shadowing” within the renal pelvis, which was strongly suggestive of air. The emergency physician ordered a computed tomography (CT) to confirm the suspicion for EP and started the patient on broad-spectrum antibiotics. The CT showed a 1.3-centimeter calculus and hydronephrosis with foci of air. The patient received intravenous antibiotics and had an emergent nephrostomy tube placed. Urine cultures tested positive for pan-sensitive *Escherichia Coli*. Urology was consulted and a repeat CT was obtained to show correct drainage and decreased renal pelvis dilation.

**Conclusion:** Distinctly different forms of treatment are used for EP and EPN, despite both having similar pathophysiology. In EP, air can be seen in the renal pelvis on POCUS, as in this case study, which distinguishes it from EPN. In the case of our patient, the use of POCUS was useful to aid in rapid differentiation between EP and EPN. [Clin Pract Cases Emerg Med. 2021;5(1):35–38.]

**Keywords:** *Point-of-care ultrasound; emphysematous pyelitis; emphysematous pyelonephritis.*

## INTRODUCTION

Emphysematous pyelitis (EP) is a rare complication of pyelonephritis that results from gas-forming bacteria localized to the renal pelvis or renal collecting system.<sup>1</sup> Emphysematous pyelitis is a relatively benign condition when compared to emphysematous pyelonephritis (EPN). While EP involves an infection of the renal pelvis by gas-forming bacteria, EPN consists of a necrotizing infection of the renal parenchyma as well. Both EP and EPN are rare complications of acute pyelonephritis. However, EPN can have devastating outcomes

with mortality rates as high as 80% if treated with antibiotics alone.<sup>2</sup> The clinical presentation of both entities is remarkably similar, consisting of fever, chills, flank pain, dysuria, vomiting, and lethargy.<sup>2</sup>

Historically, the only method of differentiation between EP and EPN has been computed tomography (CT) that demonstrates air within the renal parenchyma. It is important to distinguish EPN from EP due to the increased morbidity and mortality associated with EPN, as well as the different treatment course for each condition.<sup>2,3</sup> In this report, we

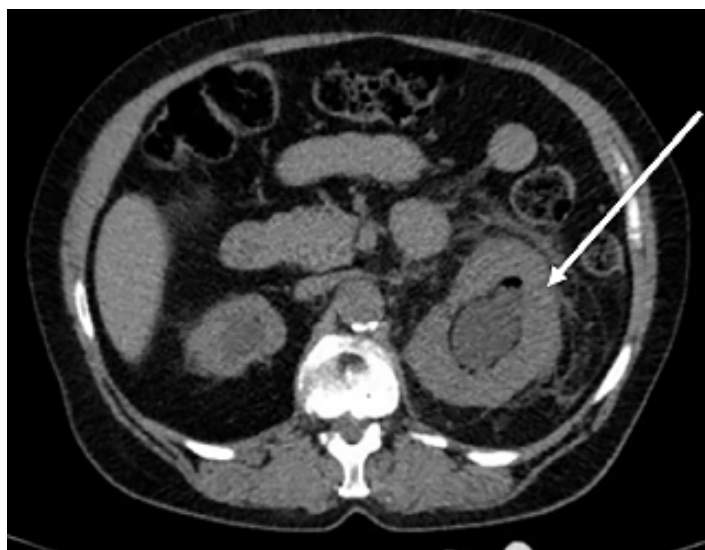demonstrate the utility of point-of-care ultrasound (POCUS) to diagnose EP in a female presenting with symptoms suggestive of pyelonephritis.

### CASE REPORT

A 60-year-old female with an extensive history of obstructive nephrolithiasis presented to our emergency department (ED) with left-sided flank pain. She described her pain as intermittent and sharp in nature, with radiating pain to the groin. Associated complaints included dysuria and gross hematuria. Initial triage vitals were normal; however, within 20 minutes of arrival she became febrile to 101.2° Fahrenheit, tachycardic to 114 beats per minute, tachypneic to 21 breaths per minute, and a blood pressure of 114/82 milligrams mercury. On exam she was in mild distress, with diaphoresis and left costovertebral angle tenderness.

Point-of-care ultrasound performed in the ED showed unilateral moderate hydronephrosis with echogenic debris in the renal pelvis (Video). Specifically, the isolated debris in the renal pelvis was heterogeneous with both hyperechoic and isoechoic artifacts; mobile hyperechoic foci with “dirty shadowing” were highly suggestive of air in the renal pelvis. Blood cultures were obtained, and given suspicion for EP, the emergency physician initiated broad-spectrum antibiotics and consulted urology while waiting for the results of a confirmatory CT.

The CT demonstrated a 1.3-centimeter calculus and hydronephrosis with foci of air, raising suspicion for a hemorrhagic or infectious etiology (Image). The patient was admitted for intravenous antibiotics and emergent nephrostomy tube placement by interventional radiology. Blood cultures were positive for gram-negative rods. Urine cultures revealed pan-sensitive *Escherichia coli*. The patient was evaluated by the



**Image.** Computed tomography of the abdomen and pelvis showing an enlarged left kidney with hydronephrosis as well as air in the renal pelvis (white arrow).

### CPC-EM Capsule

What do we already know about this clinical entity?

*Emphysematous pyelitis (EP) and emphysematous pyelonephritis (EPN) are diagnosed through computed tomography (CT); treatment differs despite similar pathophysiology.*

What makes this presentation of disease reportable?

*The ultrasound video clip demonstrates key findings such as reverberation artifact and “dirty shadowing” to show EP.*

What is the major learning point?

*Ultrasound may be useful to differentiate pathology for EP and EPN.*

How might this improve emergency medicine practice?

*Using ultrasound may expedite diagnosis of EP and EPN to better guide course of therapy before confirming with CT.*

urology service, with repeat CT showing appropriate drainage of infection and decreased renal pelvis dilation.

### DISCUSSION

Emphysematous infections of the renal and genitourinary collecting systems can be life threatening and rapidly progress to sepsis without aggressive intervention.<sup>4</sup> Emphysematous pyelonephritis is characterized by a necrotic infection of the renal parenchyma. Infection with gas-forming microbes will result in the presence of gas in the collecting system and perinephrotic tissue.<sup>5</sup> Acute EPN can result in greater complications than EP due to the increased rate of sepsis. The primary cause of mortality in EPN is complications related to sepsis.<sup>5</sup>

Although both EP and EPN have similar pathophysiology and epidemiological risk factors, the overall prognosis of each pathology and diagnostic criteria are unique. Specifically, EP has a significantly lower mortality rate (18-20%) as compared to the nearly twofold increase in mortality associated with EPN (25-42%).<sup>4,6,7</sup> The clinical presentation of EP can be similar to that of pyelonephritis, with symptoms ranging from fever, chills, hematuria, and vomiting to renal angle tenderness.<sup>1</sup> In contrast, the presentation of EPN is typically more ominous, frequently

presenting with vital sign abnormalities, sepsis, and shock if left untreated.<sup>8</sup>

Computed tomography is considered the best modality for differentiating EPN from EP, as it can consistently differentiate the existence of gas in specific locations within the renal excretory system, including renal parenchyma, renal pelvis, and perinephric spaces.<sup>3</sup> Although there have been a few case reports of the adjunctive roles of ultrasound and kidney, ureter, and bladder radiographs in differentiating EP from EPN, to our knowledge the reported use of POCUS by an emergency physician for rapid identification of EP is unique. Given routine delays in CT imaging in a busy ED, the role of POCUS in helping physicians differentiate between a benign and life-threatening condition has evolved.

POCUS for both EP and EPN demonstrates a reverberation artifact projecting posteriorly from a hyperechoic focus (emphysema). The hyperechoic focus is due to free air bubbles with lateral and axial blooming.<sup>9</sup> The reverberation artifact from the hyperechoic gas bubbles gives a sonographic appearance of “dirty shadowing.” Dirty shadowing is described as superimposed echoes from free gas that give a large radius of curvature of the surface struck by the sound beam.<sup>10</sup> This results in the characteristic dirty shadowing that projects from a hyperechoic focus of free gas with a larger curvature and acoustic noise within the shadow. In contrast, “clean shadowing” is related to solid surface material, such as nephroliths, that creates a clean shadow with no infiltrative artifact.<sup>10</sup> Characteristics of EP on POCUS that distinguish it from EPN include the presence of “dirty shadowing,” which is isolated to the renal pelvis.<sup>11</sup> In comparison, sonographic findings of EPN are similar; however, reverberation artifact is present extending toward the renal parenchyma, not isolated to the renal pelvis as in EP. At times, emphysema into the parenchyma and renal cortex can become so extensive that adequate visualization of the pelvis and uropelvic junction can be challenging.<sup>12</sup>

Current treatment of EP consists of the use of broad-spectrum antibiotics, urology evaluation, and nephrostomy tube placement in cases of obstructive processes.<sup>13</sup> In contrast, EPN requires aggressive interventions. Delays in recognition and/or diagnosis by the provider can result in increased morbidity or mortality. POCUS can help facilitate the prompt diagnosis and treatment of both EP and EPN, resulting in improved patient outcomes.<sup>1,2,14</sup>

## CONCLUSION

Point-of-care ultrasound can be used successfully by emergency physicians to rapidly differentiate between emphysematous renal infections, thus expediting care in critically ill patients. This case report further characterizes the sonographic appearance of emphysematous pyelitis, as well as comparing the subtle differences in ultrasound imaging, presentation, and treatment of EP from the far deadlier emphysematous pyelonephritis.

**Video.** This video clip shows a coronal ultrasound of the left kidney presented in the case report. As seen, there is an obvious hypoechoic dilation of the renal pelvis with blunting of the calyces consistent with moderate hydronephrosis. Also visualized in the clip is a heterogeneous collection of debris. The isoechoic sediment likely represents purulent material in the clinical setting of infection. The hyperechoic foci, with posterior “dirty shadowing,” corresponds to air. The foci of air are isolated to the renal pelvis consistent with the diagnosis of emphysematous pyelitis.

The authors attest that their institution requires neither Institutional Review Board approval, nor patient consent for publication of this case report. Documentation on file.

*Address for Correspondence:* Shadi Lahham, MD, MS, University of California, Irvine, Department of Emergency Medicine, 333 The City Boulevard West Suite 640, Orange, A 92868. Email: slahham@uci.edu.

*Conflicts of Interest:* By the *CPC-EM* article submission agreement, all authors are required to disclose all affiliations, funding sources and financial or management relationships that could be perceived as potential sources of bias. The authors disclosed none.

*Copyright:* © 2021 Mazumder et al. This is an open access article distributed in accordance with the terms of the Creative Commons Attribution ([CC BY 4.0](http://creativecommons.org/licenses/by/4.0/)) License. See: <http://creativecommons.org/licenses/by/4.0/>

## REFERENCES

1. Hiremath R, Mahesh, Padala KP, et al. A rare case of pneumoureter: emphysematous pyelitis versus emphysematous pyelonephritis. *J Clin Diagn Res.* 2015;9(11):TD03-5.
2. Mccafferty G, Shorette A, Singh S, et al. Emphysematous pyelonephritis: bedside ultrasound diagnosis in the emergency department. *Clin Pract Cases Emerg Med.* 2017;1(2):92-4.
3. Craig WD, Wagner BJ, Travis MD. Pyelonephritis: radiologic-pathologic review. *Radiographics.* 2008;28(1):255-77.
4. Kua CH and Abdul Aziz Y. Air in the kidney: between emphysematous pyelitis and pyelonephritis. *Biomed Imaging Interv J.* 2008;4(4):e24.
5. Ubee SS, McGlynn L, Fordham M. Emphysematous pyelonephritis. *BJU Int.* 2011;107(9):1474-8.
6. Stone SC, Mallon WK, Childs JM, et al. Emphysematous pyelonephritis: clues to rapid diagnosis in the emergency department. *J Emerg Med.* 2005;28(3):315-9.
7. Wan YL, Lee TY, Bullard MJ, et al. Acute gas-producing bacterial renal infection: correlation between imaging findings and clinical outcome. *Radiology.* 1996;198(2):433-8.
8. Kalra OP and Raizada A. Approach to a patient with urosepsis. *J Glob Infect Dis.* 2009;1(1):57-63.

9. Wilson SR, Burns PN, Wilkinson LM, et al. Gas at abdominal US: appearance, relevance, and analysis of artifacts. *Radiology*. 1999;210(1):113-23.
10. Rubin JM, Adler RS, Bude RO, et al. Clean and dirty shadowing at US: a reappraisal. *Radiology*. 1991;181(1):231-6.
11. Srinivasan S, Teh HS, Clarke MJ. Clinics in diagnostic imaging (138). Emphysematous pyelitis. *Singapore Med J*. 2012;53(3):214-7.
12. Allen HA 3rd, Walsh JW, Brewer WH, et al. Sonography of emphysematous pyelonephritis. *J Ultrasound Med*. 1984;3(12):533-7.
13. Grayson DE, Abbott RM, Levy AD, et al. Emphysematous infections of the abdomen and pelvis: a pictorial review. *Radiographics*. 2002;22(3):543-61.
14. Chiang CC, Jong YS, Wang WJ. Emphysematous pyelitis. *CMAJ*. 2010;182(7):698.

# Case Report: Using Point-of-care Ultrasound as a Tool to Identify a Urethral Foreign Body

Jacob Frier, MD  
Elizabeth Nicholas, MD  
Paul Klawitter, MD, PhD

SUNY Upstate Medical University, Department of Emergency Medicine, Syracuse,  
New York

Section Editor: Rick A. McPheeters, DO

Submission history: Submitted July 28, 2020; Revision received October 1, 2020; Accepted October 9, 2020

Electronically published January 22, 2021

Full text available through open access at [http://escholarship.org/uc/uciem\\_cpem](http://escholarship.org/uc/uciem_cpem)

DOI: 10.5811/cpem.2020.10.49290

**Introduction:** When patients present to the emergency department with retained urethral foreign objects, imaging is crucial for identifying and further describing the object(s). Imaging is also important to plan the management and to assess the potential complications of foreign object removal. Ultrasonography is sometimes used for this purpose and can often provide more information on the object and its location and characteristics than plain radiographs.

**Case Report:** This case report discusses the identification and characterization of a retained urethral foreign object that was not seen on plain radiography.

**Conclusion:** While ultrasonography has its own limitations, in the cases of retained foreign objects, it can provide preferable imaging and can help guide the management of these patients. [Clin Pract Cases Emerg Med. 2021;5(1):39–42.]

**Keywords:** *Point-of-care ultrasound; genitourinal; foreign body.*

---

## INTRODUCTION

Urethral foreign body (FB) is an uncommon complaint in the emergency department.<sup>2</sup> Typically, these retained urethral FBs are either iatrogenic and retained from a procedure, catheter, or implant, or they are the result of autoerotic stimulation practiced by some individuals.<sup>2-6</sup> Even more rarely is a FB placed intentionally in one's urethra as an attempt at self-harm, and this is usually associated with a history of mental illness.<sup>5-7</sup> Urethral FBs can have many serious complications, including urinary retention (and secondary hydronephrosis and obstructive nephropathy); infection (with the object acting as a nidus until removal); trauma to the urethra and surrounding structures; urethral scarring and subsequent stricture; and sexual dysfunction.<sup>3-6</sup> For these reasons, timely removal of retained urethral FBs is important in preventing serious and permanent complications.

Localizing these FBs is often performed using radiographs, although ultrasound is becoming increasingly used.<sup>1,6,8</sup> In many ways, ultrasound may be a preferable modality for imaging as it provides dynamic views and, if the

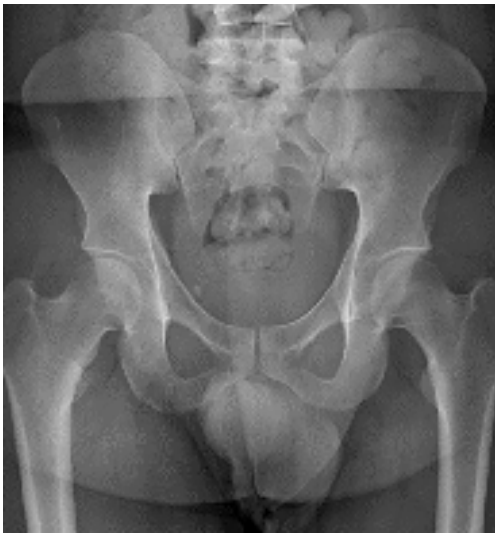location is superficial enough, can provide high definition images of the FB and surrounding structures.<sup>9-11</sup> Imaging plays a vital role in the management of retained urethral FBs by helping to localize the object in relationship to other structures, and to ascertain information on the size, shape, mobility, and susceptibility to various removal techniques. In this case, we discuss a patient with a retained urethral FB that was only seen on ultrasound imaging, and which the ultrasound assisted in determining the best means of foreign object removal.

## CASE REPORT

A 29-year-old male-to-female transgender patient presented to the emergency department complaining of inability to urinate. The patient had a long history of self-injury and genital self-mutilation, including placing foreign bodies in her penile urethra. The patient stated that approximately eight hours prior to arrival, she had intentionally placed a baby carrot inside her urethral meatus and then pushed the carrot entirely into the urethra and

continued to apply pressure to move the FB as proximal as she could. She reported minimal pain during the time of insertion, but since then she had gradually worsening severe suprapubic pressure and penile pressure that radiated to the scrotum. She had not been able to void since inserting the FB. Exam showed slight erythema and irritation of penile meatus, no palpable mass within the penis, non-tender testicles, and a palpable, firm, cylindrical object in the anterior perineal area when palpated through the scrotum. In addition, patient had a tender and distended bladder on suprapubic palpation.

AP and lateral radiographs were obtained of the pelvis, but no obvious foreign object or mass was clearly visualized (Image 1).

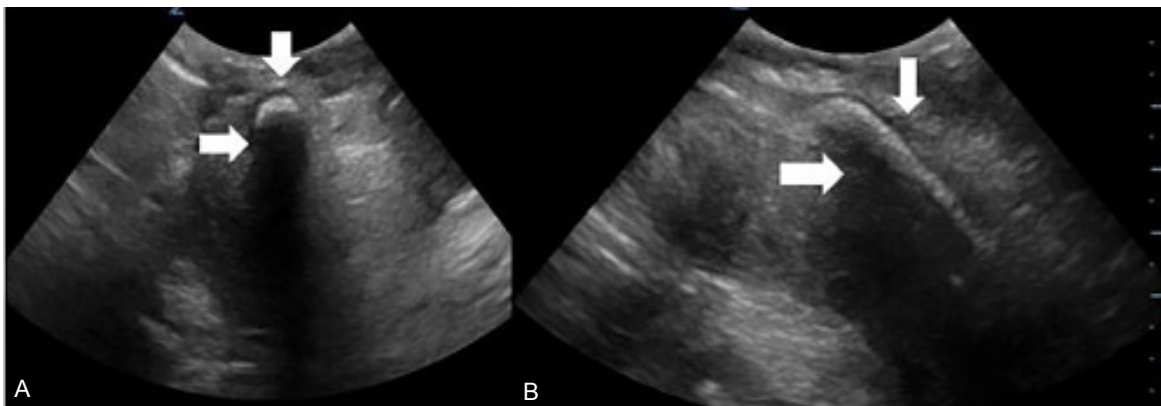


**Image 1.** A plain anteroposterior view of the patient's pelvis, not showing any foreign body.

Point-of-care ultrasound was used for further evaluation. Multiple transverse and longitudinal views were obtained directly through the penis, but again, no foreign objects or

other obvious abnormalities were identified. A trans-scrotal approach was made with the ultrasound probe, focusing on the area with the palpable cylindrical mass. Using this view, a distinct cylindrical mass was identified in both transverse and long axis (Image 2).

Palpation of the mass while obtaining the ultrasound showed that it was mobile and appeared to be within the



**Image 2.** (A) Point-of-care transverse image of the urethra was obtained trans-scrotally. A hyperechoic foreign body (vertical arrow) with shadowing (horizontal arrow) within the penile urethra was identified. (B) Point-of-care ultrasound of the urethra in long axis was obtained trans-scrotally. A hyperechoic foreign body (vertical arrow) with shadowing (horizontal arrow) within the penile urethra was identified.

### *CPC-EM Capsule*

What do we already know about this clinical entity?

*Many foreign bodies (FB) are radiolucent, making traditional radiography unhelpful. Point-of-care ultrasound (POCUS) has become a useful tool in FB identification.*

What makes this presentation of disease reportable?

*This is a unique case of a urethral FB not seen on plain radiograph that was easily visualized with POCUS. Ultrasound was also used to plan FB removal.*

What is the major learning point?

*When urethral foreign body is suspected, POCUS may be a fast and easily accessible tool to aid in diagnosis and removal planning.*

How might this improve emergency medicine practice?

*Using POCUS for radiolucent urethral FBs may save time to both diagnosis and removal when compared to ureteroscopy and/or computed tomography.*

urethra, distal to the prostate. The object was measured (Image 3). The bladder appeared distended, but otherwise no foreign objects were noted in the bladder on ultrasound.

Urology was consulted, and based on ultrasonographic localization, was able to palpate the proximal tip of the mass. The urology resident was then able to hook a fingertip around the proximal tip and push the foreign object distally through the urethra until it was palpable in the penis. External manipulation was continued, and the urology resident was able to “milk” the foreign object entirely out of the urethra. An approximately 5- centimeter baby carrot was removed fully intact, and the patient was able to urinate immediately afterward with significant improvement in pain. The patient had no obvious complications, and was discharged on ciprofloxacin for urinary tract infection prophylaxis.

## DISCUSSION

When retained urethral foreign objects are suspected, imaging is important for diagnosis and prediction of possible complications, as well as for planning the removal of the foreign object and further management. Ultrasound has been shown to be an effective tool in confirming the presence of, locating, and determining the characteristics of a urethral foreign object. In this case, plain radiographs were not able to visualize a retained urethral foreign object, while ultrasound confirmed its presence. POCUS also demonstrated mobility of the object and its shape, which indicated that external manipulation could be a viable means of removal. Because of this, more invasive measures, such as urethroscopy, and any associated potential harms were avoided.

The limitations of POCUS can include missed foreign object depending on the depth, location, composition, and patient tolerance. Likewise, radiographs are often helpful in determining the exact size and shape of the object, and can

highlight metal vs non-metal structures, but ultrasound is limited in this aspect due to various potential forms of artifact, especially with objects that ultrasound waves do not penetrate well. However, despite these limitations, as demonstrated in this case, POCUS can still be a useful and sometimes crucial tool in the management of retained urethral foreign objects.

## CONCLUSION

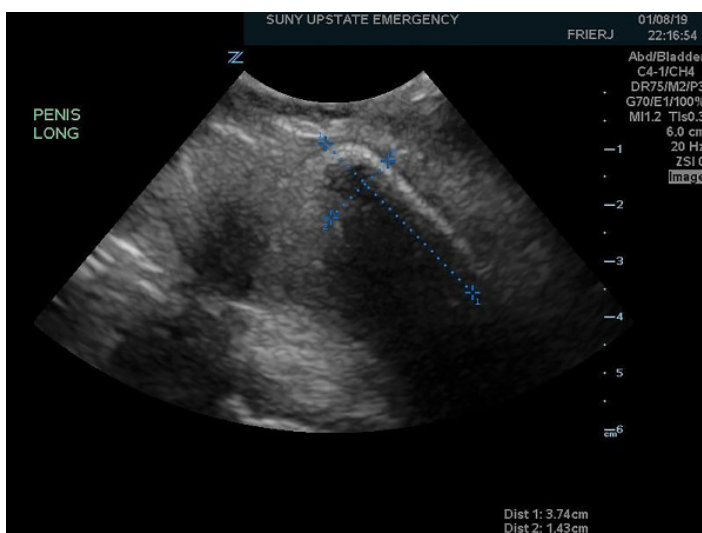
Point-of-care-ultrasound can be a useful tool to evaluate for urethral foreign bodies. It is fast and effective, and location can sometimes be immediately determined. In this case, the foreign body could not be identified with plain radiography. Here we show an example where POCUS proved to be diagnostic in the identification of a urethral foreign body.

The authors attest that their institution requires neither Institutional Review Board approval, nor patient consent for publication of this case report. Documentation on file.

*Address for Correspondence:* Elizabeth Nicholas, MD, SUNY Upstate Medical University, Department of Emergency Medicine, 550 East Genesee Street, Syracuse, New York 13202. Email: balazice@upstate.edu.

*Conflicts of Interest:* By the CPC-EM article submission agreement, all authors are required to disclose all affiliations, funding sources and financial or management relationships that could be perceived as potential sources of bias. The authors disclosed none.

*Copyright:* © 2021 Frier et al. This is an open access article distributed in accordance with the terms of the Creative Commons Attribution (CC BY 4.0) License. See: <http://creativecommons.org/licenses/by/4.0/>



**Image 3.** Urethral foreign body measuring 3.74 x 1.43 centimeters, as measured in long axis on point-of-care ultrasound.

## REFERENCES

1. Avery LL and Scheinfeld MH. Imaging of penile and scrotal emergencies. *Radiographics*. 2013;33(3):721-40.
2. Odoemene CA and Onuh CA. Foreign bodies in the urinary bladder - case series. *J West Afr Coll Surg*. 2017;7(3):124-136.
3. Stamatiou K and Moschouris H. A rubber tube in the bladder as a complication of autoerotic stimulation of the urethra. *Arch Ital Urol Androl*. 2016;88(3):239-40.
4. Unruh BT, Nejad SH, Stern TW, et al. Insertion of foreign bodies (polyembolokoilamania): underpinnings and management strategies. *Prim Care Companion CNS Disord*. 2012;14(1):PCC.11f01192.
5. Rahman NU, Elliott SP, McAninch JW. Self-inflicted male urethral foreign body insertion: endoscopic management and complications. *BJU Int*. 2004;94(7):1051-3.
6. Barzilai M, Cohen I, Stein A. Sonographic detection of a foreign body

- in the urethra and urinary bladder. *Urol Int.* 2000;64(3):178-80.
7. Palmer CJ, Houlihan M, Psutka SP, et al. Urethral foreign bodies: clinical presentation and management. *Urology.* 2016;97:257-60.
  8. Shokoohi H, Kendrick Z, Sikka N, et al. Sonographic localization of a retained urethral foreign body in an elderly patient. *J Clin Ultrasound.* 2018;46(4):296-8.
  9. Bray PW, Mahoney JL, Campbell JP. Sensitivity and specificity of ultrasound in the diagnosis of foreign bodies in the hand. *J Hand Surg Am.* 1995;20(4):661-6.
  10. Schlager D, Sanders AB, Wiggins D, et al. Ultrasound for the detection of foreign bodies. *Ann Emerg Med.* 1991;20(2):189-91.
  11. Graham DD Jr. Ultrasound in the emergency department: detection of wooden foreign bodies in the soft tissues. *J Emerg Med.* 2002;22(1):75-9.

# Peer Pressure = Explosive Consequences: A Case Report of Toxic Ingestion of Cyclonite (C-4) Explosive on a Dare

Joshua D. Whitesides, MD\*

Major Nathaniel Turner, MPAS, PA-C†

Susan Watts, PhD\*

Sarah A. Watkins, DO\*‡

\*Texas Tech University Health Sciences Center El Paso, Department of Emergency Medicine, El Paso, Texas

†William Beaumont Army Medical Center, Department of Emergency Medicine, El Paso, Texas

‡West Texas Poison Control Center, El Paso, Texas

Section Editor: Steven Walsh, MD

Submission history: Submitted July 24, 2020; Revision received October 12, 2020; Accepted October 16, 2020

Electronically published January 12, 2021

Full text available through open access at [http://escholarship.org/uc/uciem\\_cpem](http://escholarship.org/uc/uciem_cpem)

DOI: 10.5811/cpem.2020.10.49241

**Introduction:** We present a case of intentional ingestion of a piece of plastic explosive in a military patient that resulted in tonic-clonic seizure and gastrointestinal illness.

**Case Report:** Although uncommon, such ingestions have been reported in military journals since the Vietnam War. Access to plastic explosives is generally limited to military personnel, and non-military medical providers may not be familiar with treatment of acute intoxication.


**Conclusion:** It is imperative to refresh awareness and provide education to heighten suspicion and broaden differential diagnosis for patients presenting with new onset syncope or seizure, particularly in the military population. [Clin Pract Cases Emerg Med. 2021;5(1):43–46.]

**Keywords:** *Cyclonite; C4; RDX; plastic explosive; seizures; military explosives.*

## INTRODUCTION

Cyclotrimethylenetrinitramine (common names cyclonite, Research Development Explosive [RDX]) is the predominant explosive ingredient in Composition-4 (C-4) plastic explosive used extensively since World War II by the military in the United States (US) and other countries.<sup>1,2</sup> It is a white solid with a putty-like consistency (Image). Previous studies have revealed that soldiers may intentionally ingest C-4 for two reasons: to elicit intoxication with symptoms similar to ethanol ingestion, or to induce illness for secondary gain.<sup>1,3</sup> There are also reports of unintentional occupational exposure in the manufacture of C-4.

Reported symptoms of ingestion include nausea, vomiting, diarrhea, seizures, postictal coma, lethargy, dysrhythmia, and myoclonus. Cardiac abnormalities such as tachycardia and quadrigeminal rhythm have also been reported; however, the exact mechanism has not been elucidated.<sup>4</sup> In addition to ingestion, exposure due to inhalation was reported, on average, four times per month between December 1968–December 1969 when C-4 explosive was used to heat food rations, since it gives off intense heat



**Image.** The plastic explosive compound C-4 is a white solid with a putty-like consistency.

without exploding.<sup>5</sup> It is important to note that both unintentional and intentional exposures to C-4 have a common presentation: new onset seizure in a non-epileptic patient.<sup>6</sup>

**CASE REPORT**

A 20-year-old male, active duty US Army Combat Engineer was brought to the emergency department (ED) via ambulance after ingesting a small piece of C-4, with a volume estimated to be about 1.2 cubic inches, or three-quarter ounce. As a combat engineer, his duties involved detonation of explosives, including C-4, in support of combat operations. During a lull between training iterations at a demolition range, he was dared by a colleague to eat a 4 x 1 centimeter piece of plastic explosive. Immediately following the ingestion, he began to have nausea and a headache. Approximately 30 minutes later, he sustained a witnessed, generalized tonic-clonic seizure lasting two minutes. His unit members contacted their medical support and he was transported to the nearest military ED.

Per emergency medical services, he was alert and oriented to person, place, time, and situation with reassuring vital signs. No antiepileptic medications were administered prior to arrival at the ED. In the ED, the patient reported feeling confused, dizzy, and weak for about 60 minutes following the seizure. He complained of new onset of lower back pain. His initial vital signs were as follows: blood pressure 149/71 millimeters of mercury; heart rate 96 beats per minute; respiration 15 breaths per minute; and his rectal temperature was normal. His physical examination was remarkable for warm skin, hyperreflexia, and non-sustained bilateral lower extremity clonus.

Electrocardiogram (ECG) showed sinus tachycardia without evidence of ischemia, and borderline corrected QT interval prolongation was reported; however, no specific measurement was provided in the patient's record. Radiographs of the chest, thoracic spine, and lumbar spine showed no acute abnormalities, and there was no mention of radiopaque foreign bodies. Computed tomography of the head showed no evidence of acute hemorrhage, edema, or mass effect.

When it became clear the patient had been exposed to C-4, the West Texas Regional Poison Center was consulted. Additional laboratory tests were recommended to assess for signs of organ damage and metabolic aberrations: urinalysis for hematuria; blood gas for methemoglobinemia; comprehensive metabolic panel for elevated anion gap metabolic acidosis, acute kidney or liver injury and hypokalemia; and creatine kinase to assess for rhabdomyolysis. Supportive care was recommended for seizures and nausea. Twenty-four hour observation was recommended as well.

The patient received lorazepam 1 milligram (mg) intravenously (IV), ketorolac 30 mg IV, and 1 liter (L) normal saline bolus. Laboratory results were significant for leukocytosis of  $16.4 \times 10^3$ /microliters (uL) (reference range 4.5 to  $11.0 \times 10^3$ /uL); elevated D-dimer of 2003 nanograms per milliliter (ng/mL) D-dimer units (reference range <250 ng/mL); and elevated lactate at 2.41 millimoles (mmol)/L (reference range 0.5-1 mmol/L).

*CPC-EM Capsule*

What do we already know about this clinical entity?

*Ingestion of the plastic explosive Composition-4 (C-4), whether intentional or unintentional, may result in neurologic, gastrointestinal, renal, and cardiac effects.*

What makes this presentation of disease reportable?

*Ingestion of C-4 is an uncommon practice. Yet it appears cyclically in military medical literature, and non-military medical providers should be made aware.*

What is the major learning point?

*Ingestion of C-4 commonly results in seizures, nausea, and vomiting. Seizures associated with C-4 toxicity respond to standard doses of benzodiazepines.*

How might this improve emergency medicine practice?

*Our goal was to raise awareness that certain patient populations such as young males in the military might ingest plastic explosive and suffer C-4 toxicity.*

He was admitted to the intensive care unit (ICU) for monitoring. On admission, the consulting neurologist recommended doses of valproate 20 mg per kilogram (kg) and levetiracetam 40 mg/kg IV for seizure prophylaxis. In addition, the inpatient team elected to order two 16-ounce doses of polyethylene glycol oral solution and magnesium citrate for gastrointestinal decontamination. There was no report of C-4 found in rectal effluent. He remained on seizure precautions and had resolution of gastrointestinal symptoms, and no further seizure activity or other neurologic symptoms.

Once medically cleared, he was seen by a behavioral health specialist per standard Army protocol. He met face-to-face with a licensed clinical social worker (LCSW) and was evaluated using a battery of seven standardized psychological screening tools routinely used in the US Army Behavioral Healthcare Clinic. There were no concerning results and he was cleared by the LCSW and returned to full duty after his 24-hour observation period.

At follow-up with his primary care provider four days later, he denied any recurrence of symptoms and did not have any further complaints or seizure-like activity.

## DISCUSSION

On our review of the literature, we found that fewer than 10 case reports of human C-4 ingestion have been published in the last 20 years and all published cases involve military personnel.<sup>4,8,9</sup> The cases describe symptoms ranging from acute gastrointestinal illness to severe neurological sequelae. As seen with our patient, the most commonly reported symptom from exposure was new onset of seizures; these have been reported even from occupational exposures where appropriate handling and packaging of materials have been performed.<sup>1</sup> Toxic effects have also been reported in animals. For example, in 2008 a two-year-old male Labrador retriever working in explosive detection ingested C-4 resulting in tonic-clonic seizures.<sup>7</sup>

The practice of purposeful ingestion of C-4 occurs disproportionately in young males. Analysis of case reports from 1969–2019, including both occupational and intentional exposures, found 31 were male, and none were female. Mean age was 26 years old. The average time from ingestion to onset of symptoms was approximately seven hours, with a range of 30 minutes to 16 hours.<sup>4,8,9</sup> Ingestion quantities were inconsistently reported; however, a minimum ingestion of 1.58 grams to a maximum of 180 grams were reported. Of note, seizures were reported in 100% of cases.<sup>1-6,8-9</sup>

Pathophysiologically, seizures after C-4 ingestion are a direct result of central nervous system toxicity. Animal models have shown that cyclonite, the toxic ingredient in C-4, binds *in vivo* to the gamma-aminobutyric acid A (GABA<sub>A</sub>) chloride channel at the picrotoxin binding site with the same or greater affinity than pentylentetrazol, acting as a non-competitive inhibitor of chloride conductance and resulting in seizure activity.<sup>8,10-12</sup> The treatment of status epilepticus from C-4 ingestion is medication with competitive GABA<sub>A</sub> receptor binding, such as benzodiazepines, barbiturates, and propofol. The management of a patient suspected to have ingested C-4 is primarily symptomatic and supportive. An algorithmic approach including first establishing a patent airway followed by prompt ECG to analyze for arrhythmias is imperative. Administration of activated charcoal is then suggested in patients not at risk for aspiration, followed by standard doses of benzodiazepines to prevent and treat seizures.<sup>13</sup> Fluid resuscitation and monitoring of urine output are indicated because acute renal injury is common, and a soldier presenting from a training event is at high risk of volume depletion. After stabilizing the patient, ICU admission for close observation is reasonable.

## CONCLUSION

Exposure to C-4, whether occupational or intentional, is most notable for new onset seizures but can also result in neurologic, renal, and gastrointestinal abnormalities. After standard initial management including airway control to prevent aspiration, the next steps include medications to control seizures, and then assessment for end organ damage. Young adult males who may be susceptible to peer pressure

and ingest C-4 as a rite of passage are a particularly at-risk population. It is imperative that emergency providers consider C-4 ingestion as a possible cause for unexplained first-time seizures in populations with access to the compound.

Patient consent has been obtained and filed for the publication of this case report.

---

*Address for Correspondence:* Joshua D. Whitesides, MD, Texas Tech University Health Sciences Center, Department of Emergency Medicine, 5001 El Paso Dr., El Paso, Texas 79905. Email: [joshua.d.whitesides@ttuhsc.edu](mailto:joshua.d.whitesides@ttuhsc.edu).

*Conflicts of Interest:* By the CPC-EM article submission agreement, all authors are required to disclose all affiliations, funding sources and financial or management relationships that could be perceived as potential sources of bias. The authors disclosed none. The views expressed here are those of the authors and do not reflect the official policy of the Department of the Army, the Department of Defense, or the U.S. Government.

*Copyright:* © 2021 Whitesides et al. This is an open access article distributed in accordance with the terms of the Creative Commons Attribution (CC BY 4.0) License. See: <http://creativecommons.org/licenses/by/4.0/>

---

## REFERENCES

- Harrell-Bruder B and Hutchins KL. Seizures caused by ingestion of Composition C-4. *Ann Emerg Med.* 1995;26(6):746-8.
- Kaplan AS, Berghout CR, Peczenik A. Human Intoxication from RDX. *Arch Environ Health.* 1965;10:877-83.
- Stone WJ, Paletta TL, Heiman EM, et al. Toxic effects following ingestion of C-4 plastic explosive. *Arch Intern Med.* 1969;124(6):726-30.
- Küçükardali Y, Acar HV, Ozkan S, et al. Accidental oral poisoning caused by RDX (cyclonite): a report of 5 cases. *J Intensive Care Med.* 2003;18(1):42-6.
- Ketel WB and Hughes JR. Toxic encephalopathy with seizures secondary to ingestion of Composition C-4. A clinical and electroencephalographic study. *Neurology.* 1972;22(8):871-6.
- Testud F, Glanclaude JM, Descotes J. Acute hexogen poisoning after occupational exposure. *J Toxicol Clin Toxicol.* 1996;34(1):109-11.
- Fishkin RA, Stanley SW, Langston CE. Toxic effects of cyclonite (C-4) plastic explosive ingestion in a dog. *J Vet Emerg Crit Care.* 2008;18(5):537-40.
- Garcia R, Karimian A, Donaldson C, et al. Status epilepticus after C-4 ingestion: using liquid chromatography to quantify toxicity. *Clin Toxicol (Phila).* 2019;57(9):819-21.
- Davies JO, Roberts DM, Hittarage A, et al. Oral C-4 plastic explosive

- in humans - a case series. *Clin Toxicol (Phila)*. 2007;45(5):454-7.
10. Kalueff AV, Gebhardt M, Stewart AM, et al. Towards a comprehensive catalog of zebrafish behavior 1.0 and beyond. *Zebrafish*. 2013;10(1):70-86.
  11. Williams LR, Aroniadou-Anderjaska V, Qashu F, et al. RDX binds to the GABA(A) receptor-convulsant site and blocks GABA(A) receptor-mediated currents in the amygdala: a mechanism for RDX-induced seizures [published correction appears in *Environ Health Perspect*. 2013 May;121(5):A146]. *Environ Health Perspect*. 2011;119(3):357-63.
  12. Jalgama S, Kale VM, Wilbanks MS, et al. Delayed myelosuppression with acute exposure to hexahydro-1,3,5-trinitro-1,3,5-triazine (RDX) and environmental degradation product hexahydro-1-nitroso-3,5-dinitro-1,3,5-triazine (MNX) in rats. *Toxicol Appl Pharmacol*. 2013;266(3):443-51.
  13. Chong S, Long B, Maddry JK, et al. Acute C4 ingestion and toxicity: presentation and management. *Cureus*. 2020;12(3):e7294.

# Moyamoya as a Cause of Altered Mental Status in the Emergency Department: A Case Report

Michael West, DO  
Elizabeth Dearing, MD

The George Washington University Hospital, Department of Emergency Medicine,  
Washington, District of Columbia

Section Editor: Scott Goldstein, MD

Submission history: Submitted August 4, 2020; Revision received October 10, 2020; Accepted October 16, 2020

Electronically published January 22, 2021

Full text available through open access at [http://escholarship.org/uc/uciem\\_cpchem](http://escholarship.org/uc/uciem_cpchem)

DOI: 10.5811/cpcem.2020.10.49415

**Introduction:** This case reviews a patient with moyamoya disease, a rare cause of altered mental status. It highlights the importance of maintaining clinical suspicion for uncommon causes of common presentations.

**Case Report:** A 64-year-old male presented with seizures and persistent altered mental status. Computed tomography demonstrated findings consistent with bilateral ischemia. Cerebral angiography was performed with no thrombus identified but moyamoya disease present.

**Conclusion:** Although rare, moyamoya should be considered as a potential cause of patients presenting with altered mental status. The case presented also highlights the importance of avoiding common diagnostic biases. [Clin Pract Cases Emerg Med. 2021;5(1):47–49.]

**Keywords:** *Seizure; stroke; diagnostic bias.*

---

## INTRODUCTION

Altered mental status is a common presentation to the emergency department (ED), accounting for between 1-10% of all encounters.<sup>1</sup> While some presentations of altered mental status have a clear etiology based on provided history, vital signs or examination, many patients present undifferentiated and, therefore, require a broad evaluation including laboratory testing and neuroimaging. This case reviews a patient presenting with moyamoya disease, a rare cause of altered mental status, and highlights the importance of maintaining clinical suspicion for uncommon causes of common presentations.

## CASE REPORT

A 64-year-old Black male with a reported history of seizure disorder was brought to the ED by emergency medical services (EMS) for altered mental status. Prior to arrival to the ED the patient was found by paramedics with seizure activity, and midazolam 5 milligrams was administered intravenously, causing cessation of the tonic-clonic movements. The patient remained unresponsive during transport and was not intubated prior to arrival. He was altered on arrival to the ED. There was no family present with patient, no family contact information

available, and no prior documentation in the electronic health record; therefore, no additional history was available.

The patient arrived nonverbal with minimal spontaneous movements of all extremities and was not consistently following commands. He was protecting his airway and maintained adequate oxygen saturations. Given these findings on arrival and that the patient was likely in a postictal period without sign of ongoing seizure and improvement in his Glasgow Coma Scale compared to the EMS report, the physicians decided to not intubate the patient on arrival and closely monitor his neurologic status. Initial vitals also revealed that he was afebrile but with an initial blood pressure of 84/52 millimeters of mercury (mmHg). A point-of-care ultrasound was performed to evaluate the hypotension and revealed no sites of bleeding and normal cardiac output. Intravenous fluids were administered and blood pressure quickly normalized. Electrocardiogram was unremarkable. On repeat neurological examinations, the patient continued to exhibit altered mental status, clinically inconsistent with a postictal state.

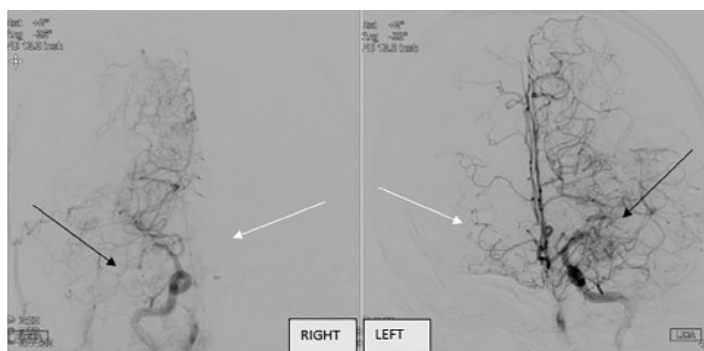
Laboratory workup revealed leukocytosis to  $14.5 \times 10^3$  cells per microliter (mcL) (reference range 4.80-10.80<sup>3</sup> mcL), as well

as a lactate of 9.3 millimoles per liter (mmol/L) (reference value for critical high of  $> 4.0$  mmol/L). Venous blood gas was significant for a pH of 7.25 (reference range 7.32-7.42) with a partial pressure of carbon dioxide of 46.6 mm Hg (reference range 25-40 mm Hg) and bicarbonate level of 20 mmol/L (reference range 24-28 mmol/L). The patient was given vancomycin and piperacillin/tazobactam as empiric antibiotics for potential infectious cause as well as levetiracetam.

A computed tomography (CT) of the brain without contrast showed loss of gray/white matter differentiation on the right side, evidence of right middle cerebral artery (MCA) acute infarction. The on-call neurologist was emergently consulted. The patient was not eligible for tissue plasminogen activator. CT angiography with perfusion imaging was then emergently pursued and showed bilateral MCA infarction at the first segment (M1) with core to penumbra mismatches and no significant core seen on the left. Based on this imaging, the neurology team activated the large cerebral vessel occlusion protocol. The patient was subsequently taken for cerebral angiography, which revealed bilateral internal carotid artery stenosis. Additionally, it found evidence of stenosis of the right and left M1 sections but no thrombus. Extensive perforator collateral circulation was found, consistent with moyamoya disease (Image). No additional intervention was indicated, and the patient was admitted to the intensive care unit. He was eventually discharged to a rehabilitation facility with residual left-sided hemiparesis and dysphagia.

## DISCUSSION

The differential diagnoses and, therefore, the evaluation for a patient presenting with altered mental status is broad. Seizures are one potential cause of altered mental status and a common complaint in the ED, accounting for 1-2% of ED visits annually.<sup>2,3</sup> Although patients may be unresponsive or obtunded immediately following a seizure, they should show gradual improvement in their mental status. If a patient is not



**Image.** Collateralization of the cerebral vessels on cerebral angiography. The collateralization, and therefore cerebral blood flow, on the left is more extensive than the right, consistent with left-sided deficits. Differences in cerebral blood flow can be visualized by comparing black arrows and white arrows.

### CPC-EM Capsule

What do we already know about this clinical entity?

*Moyamoya, a rare disease with progressive stenosis of the internal carotid arteries, is associated with strokes and seizures in children and adults.*

What makes this presentation of disease reportable?

*While moyamoya is classically found in those of Asian descent, we describe a complex presentation of a Black adult male with generalized symptoms of altered mental status.*

What is the major learning point?

*This case highlights the diagnosis of moyamoya disease as a rare cause of altered mental status while emphasizing the need to avoid bias in clinical decision-making.*

How might this improve emergency medicine practice?

*Crucial to safe, accurate diagnosis is continued diagnostic suspicion in atypical presentations and consideration of rare causes of common presentations.*

improving clinically or there are findings inconsistent with seizure, alternative causes must be explored.

Moyamoya, meaning “a puff of smoke” in Japanese, is a rare disease typically affecting the internal carotid arteries in which the lumens of those vessels progressively narrow due to smooth muscle proliferation.<sup>4,5</sup> Over time, collateralization occurs; however, the lack of carotid vessel flow places the patient at higher risk of transient ischemic attacks, arteriovenous malformations, and stroke.<sup>6,8</sup> Classically, this disease has been described in Asia and is often found in childhood. Moyamoya can also present in adulthood as headaches, seizures, altered mental status, transient ischemic attack, and stroke.<sup>7</sup> Presentations in the United States tend to be later in life and are generally associated with a lower stroke recurrence rate and better functional outcomes due to a more robust collateral circulation.<sup>9,10</sup>

In this case, the finding of seizure activity confirmed by paramedics could have potentially led to confirmation bias given the patient’s reported history of epilepsy. Elevation in lactate is common in patients after a seizure; however, the hypotension on arrival in combination with an elevated lactate

could have also led the physician to anchor on infection as the cause. Additionally, the findings on neuroimaging did not correlate directly to the patient's initial neurological exam findings. Finally, the radiologist theorized that heart failure could potentially have been the cause of the inadequate contrast load to the brain and subsequent bi-hemispheric findings; however, this was confounded by point-of-care transthoracic ultrasonography showing sufficient cardiac function.

## CONCLUSION

By maintaining clinical suspicion for alternate diagnoses as well as pursuing continued diagnostic testing and patient reassessment, the rare finding of moyamoya disease, was identified. Moyamoya could be considered in adult patients presenting with acute seizures or strokes in addition to patients with altered mental status.

The authors attest that their institution requires neither Institutional Review Board approval, nor patient consent for publication of this case report. Documentation on file.

## REFERENCES

1. Sanello A, Gausche-Hill M, Mulkerin W, et al. Altered mental status: current evidence-based recommendations for prehospital care. *West J Emerg Med.* 2018;19(3):527-41.
2. Huff JS, Morris DL, Kothari RU, et al. Emergency Medicine Seizure Study Group. Emergency department management of patients with seizures: a multicenter study. *Acad Emerg Med.* 2001;8(6):622-8.
3. ACEP Clinical Policies Committee and Clinical Policies Subcommittee on Seizures. Clinical policy: critical issues in the evaluation and management of adult patients presenting to the emergency department with seizures. *Ann Emerg Med.* 2004;43(5):605-25.
4. NIH National Institute of Neurological Disorders and Stroke. Moyamoya Disease Information Page. 2019. Available at: <https://www.ninds.nih.gov/Disorders/All-Disorders/Moyamoya-Disease-Information-Page>. Accessed April 23, 2020.
5. Scott RM and Smith ER. Moyamoya disease and moyamoya syndrome. *N Engl J Med.* 2009;360(12):1226-37.
6. Ganesan V and Smith ER. Moyamoya: defining current knowledge gaps. *Dev Med Child Neurol.* 2015;57(9):786-7.
7. Smith ER. Moyamoya biomarkers. *J Korean Neurosurg Soc.* 2015;57(6):415-21.
8. Killory BD, Gonzalez LF, Wait SD, et al. Simultaneous unilateral moyamoya disease and ipsilateral dural arteriovenous fistula: case report. *Neurosurgery.* 2008;62(6):E1375-6; discussion E1376.
9. Janda PH, Bellew JG, Veerappan V. Moyamoya disease: case report and literature review. *J Am Osteopath Assoc.* 2009;109(10):547-53.
10. Chiu D, Shedden P, Bratina P, et al. Clinical features of moyamoya disease in the United States. *Stroke.* 1998;29(7):1347-51.

*Address for Correspondence:* Elizabeth Dearing, MD, George Washington University Medical Center, Department of Emergency Medicine, 2120 L St. NW, Suite 450, Washington, DC 20037. Email: edearing@mfa.gwu.edu.

*Conflicts of Interest:* By the CPC-EM article submission agreement, all authors are required to disclose all affiliations, funding sources and financial or management relationships that could be perceived as potential sources of bias. The authors disclosed none.

*Copyright:* © 2021 West et al. This is an open access article distributed in accordance with the terms of the Creative Commons Attribution (CC BY 4.0) License. See: <http://creativecommons.org/licenses/by/4.0/>

# Human Zinc Phosphide Exposure in Lebanon: A Case Report and Review of the Literature

Hani Hamade, MD\*  
Aynur Sahin, MD†  
Carol Sukhn, PhD‡  
Chady El Tawil, MD\*  
Jennifer Rizk, MD\*  
Ziad Kazzi, MD\*§  
Tharwat El Zahran, MD\*

\*American University of Beirut, Department of Emergency Medicine, Beirut, Lebanon  
†Karadeniz Technical University, Trabzon, Turkey  
‡American University of Beirut, Department of Pathology and Laboratory Medicine, Beirut, Lebanon  
§Emory University, Department of Emergency Medicine, Atlanta, Georgia, USA

Section Editors: Rick A. McPheeters, DO

Submission history: Submitted March 25, 2020; Revision received September 28, 2020; Accepted October 5, 2020

Electronically published December 1, 2020

Full text available through open access at [http://escholarship.org/uc/uciem\\_cpccem](http://escholarship.org/uc/uciem_cpccem)

DOI: 10.5811/cpcem.2020.10.47397

**Introduction:** Toxicity from rodenticides such as metal phosphides is common worldwide, particularly in developing countries where consumers have access to unlabeled and uncontrolled insecticides and pesticides.

**Case Report:** We present the first documentation of a metal phosphide exposure in Lebanon. A middle-aged woman presented to the emergency department following the ingestion of an unknown rodenticide. Spectroscopy analysis of the sample brought by the patient was used and helped identify zinc phosphide. The patient developed mild gastrointestinal symptoms and was admitted to the intensive care unit for observation without further complications.

**Review:** We subsequently conducted a literature review to understand the diagnosis, pathophysiology, clinical presentation, and management of metal phosphide toxicity. Multiple searches were conducted on MEDLINE and PubMed, and articles related to the topics under discussion were included in the review. Metal phosphide is associated with significant morbidity and mortality involving all body systems. Patients presenting with metal phosphide intoxication need extensive workup including blood testing, electrocardiogram, and chest radiography. To date there is no antidote for metal phosphide toxicity, and management is mostly supportive. Many treatment modalities have been investigated to improve outcomes in patients presenting with metal phosphide toxicities.

**Conclusion:** Emergency physicians and toxicologists in developing countries need to consider zinc and aluminum phosphides on their differential when dealing with unlabeled rodenticide ingestion. Treatment is mostly supportive with close monitoring for sick patients. Further research is needed to better understand metal phosphide toxicity and to develop better treatment options. [Clin Pract Cases Emerg Med. 2021;5(1):50–57.]

**Keywords:** Zinc phosphide; metal phosphides; Lebanon; rodenticides.

## INTRODUCTION

Rodenticides differ from one another in chemical formulations, mechanism of actions, and toxicity in humans. They contain many heterogeneous agents that are either organic (such as superwarfarins, strychnine, and sodium


monofluoroacetate) or inorganic (such as arsenic salts, phosphorus, barium, and zinc/aluminum phosphide) compound groups.<sup>1</sup> Metal phosphides, such as zinc phosphide (Zn<sub>3</sub>P<sub>2</sub>), are a significant cause of morbidity and mortality in developing countries where the use of these compounds is

very common. Zinc phosphide is cheap, easily available, and a highly potent rodenticide.<sup>2</sup> Mortalities due to accidental, suicidal, and homicidal exposure to zinc phosphide have been reported in Eastern countries such as India, Iran, Sri Lanka, and Thailand.<sup>3-5</sup> Despite being associated with high mortality rates, there are currently no known antidotes for zinc phosphide toxicity, and the treatment is limited to supportive interventions.<sup>6</sup> We report a case of zinc phosphide exposure in Lebanon, as well as a review of the existing literature on zinc phosphide poisoning.

### CASE REPORT

A 38-year-old female, known to have a history of generalized anxiety disorder and depression (on sertraline), presented to the emergency department (ED) with an intentional ingestion of an unknown black powder diluted in 450 milliliters (mL) of water, 30 minutes before arrival (Image). The powder was labeled as “rodenticide” and purchased from a local Lebanese market. The patient waited seven minutes after mixing the solution in a bottle and then drank 400 mL; she reported a garlic-like smell. Her other co-ingestions included three tablets of 0.5 milligrams (mg) alprazolam and two tablets of 500 mg acetaminophen. On arrival, she was alert and oriented, with normal vital signs (heart rate 77 beats per minute, blood pressure 122/81 millimeters of mercury (mm Hg), respiratory rate of 16 breaths per minute, pulse oximetry 98% at room air, and temperature of 37.2°C). Pupils were 4 mm and reactive bilaterally. Neurologic examination was normal with no rigidity or clonus.

The rest of her examination was unremarkable. Electrocardiogram was normal and chest radiography was unremarkable. Urine drug screen was detectable for acetaminophen but undetectable for amphetamines,



**Image.** Residual sample (50 milliliters) of the diluted rodenticide ingested by the patient.

### CPC-EM Capsule

What do we already know about this clinical entity?

*Metal phosphides are a significant cause of morbidity and mortality in developing countries. Toxicity frequently leads to shock and multiorgan failure.*

What makes this presentation of disease reportable?

*To report the first case of zinc phosphide exposure in Lebanon, as well as review the existing literature on zinc phosphide poisoning.*

What is the major learning point?

*Zinc and aluminum phosphides should be included on the differential when approaching an intentional ingestion of unlabeled product that is marketed as a rodenticide. Treatment is supportive with close monitoring for sick patients.*

How might this improve emergency medicine practice?

*Zinc phosphide is a potent rodenticide, and its distribution needs to be better controlled by officials to decrease potential accidental and homicidal toxic exposures.*

barbiturates, benzodiazepines, cannabinoids, opiates, cocaine metabolites, tricyclic antidepressants, methadone, or phencyclidine. Her serum salicylate level was undetectable, and her acetaminophen level four hours post-ingestion was 18.6 mg per liter (L) (toxic level: >150 mg/L four hours post-ingestion). Initial laboratory results are displayed in the Table. Given that the ingestion of the unknown rodenticide was 30 minutes before presentation, activated charcoal with a dose of 1 gram (g)/ kilogram (kg) was administered. The patient vomited once after the charcoal. The remaining 50 ml of the solution that the patient had ingested was sent for qualitative analysis. The sample was shaken and 10 ml was filtered on a 0.2µm filter, acidified, and run on inductively coupled plasma mass spectroscopy (Agilent ICP-MS 7500ce, Agilent Technologies, Inc., Santa Clara, CA) in a semi-quantitative mode for multiple metals. The method used was the EPA 200-7/8 M (US Environmental Protection Agency Method 200.7: Determination of Metals and Trace Elements in Water and Wastes by ICP-MS-atomic emission spectrometry). This test can detect many substances including anticoagulants,

**Table.** Patient's initial test results in the emergency department.

Test	Result	Reference values
White blood cells count	8200	4000 – 11000/mm <sup>3</sup>
Creatinine	0.8	0.5 - 1.0 mg/dL
Blood urea nitrogen	7	8 – 25 mg/dL
Bicarbonate	21	24 – 30 mmol/L
Aspartate transaminase	34	0 – 50 IU/L
Alanine transaminase	20	0 – 50 IU/L
Anion gap	12	
Activated partial thromboplastin time	26.3	27.0 – 39.0 sec
Prothrombin time	11	10.0 – 13.0 sec
International normalized ratio	1.1	0.9 – 1.2

mm<sup>3</sup>, cubic millimeters; *mg*, milligrams; *dL*, deciliter; *mmol*, millimoles; *L*, liter; *IU*, international units; *sec*, second.

thallium, aluminum/zinc phosphide, and other heavy metals (aluminum, vanadium, chromium, manganese, iron, cobalt, nickel, copper, zinc, arsenic, selenium, strontium, silver, cadmium, barium, lead, mercury, and phosphorus).

The test detected zinc (14.7 mg/L, limit for quantification >0.005 mg/L) and phosphorus (14.7 mg/L, limit for quantification >0.005 mg/L). Other metals such as barium (0.026 mg/L), strontium (0.058 mg/L), manganese (0.036 mg/L), lead (0.024 mg/L), and thallium (0.007 mg/L) were detected minimally above the level of quantification (>0.005 mg/L) but not as high as phosphorus and zinc. Testing for whole blood lead and arsenic level were also performed and results were unremarkable. The patient was subsequently admitted to the intensive care unit for 24 hours where she remained hemodynamically stable and only complained of mild abdominal pain and vomited once. Serial coagulation profile was repeated and was within normal limits. The patient was later transferred to the psychiatric ward and discharged with no complications on day three of hospitalization.

## DISCUSSION

The above case highlights the challenges that emergency physicians and toxicologists can encounter in developing countries, where consumers have access to unlabeled and uncontrolled insecticides and pesticides. The differential diagnosis in the case of unlabeled insecticide toxicity is wide and includes toxicity by thallium, zinc and aluminum phosphide, long-acting anticoagulants, lead, or other heavy metals. Analysis of the exposure sample is a key step as it helps in identifying the active ingredient, allowing the medical team to make appropriate medical decisions. In the case under discussion, zinc phosphide did not lead to a significant morbidity or mortality. This may be due to the fact that the zinc phosphide powder was already unpackaged and wrapped in a newsletter at the shop prior to purchase. This form of

storage leaves the substance exposed to air and humidity, resulting in the dissipation of the phosphine gas.<sup>7</sup>

There is a lack of updated evidence in terms of characteristics and management in zinc phosphide toxicity. Our goal was to provide an updated review of the literature in zinc phosphide toxicity, including important information on the pathophysiology, clinical presentation, diagnosis, and treatment. Since the toxic agent in zinc phosphide toxicity is phosphine, studies on phosphine and aluminum phosphide were also reviewed. We used the following search strategy: the National Library of Medicine's MEDLINE database (PubMed) was systematically searched for articles from 1990 to date using the following keywords and strategy: 1) metal phosphide; 2) zinc phosphide; 3) metal phosphide; 4) toxicity or exposure or poisoning; 5) #1 AND #4; 6) #2 AND #4; 7) #3 AND #4; 8) antidote or therapy or treatment; 9) #5 AND #8; 10) #6 AND #8; 11) #7 AND #8; 12) phosphine AND toxicity AND poisoning AND treatment. Every search triggered further review of additional articles. Abstracts of articles were reviewed and selected for inclusion if they discussed metal phosphide toxicity or exposure and treatment. We also conducted an independent hand search of the bibliography of studies to identify relevant articles that were not identified on the initial automated search. No limits on types of articles were set. Articles were excluded by the senior and first author if found to be irrelevant to the scope of this review.

## Exposure

Zinc phosphide is an inorganic chemical compound that is found as dark gray or black powder.<sup>8</sup> Upon ingestion, zinc phosphide is hydrolyzed by gastric acid, generating phosphine gas, which is rapidly absorbed through the gastric mucosa.<sup>9</sup> In its purest form, phosphine is almost odorless, but its commercial grade has a disagreeable, garlic-like or decaying fish odor, due to impurities.<sup>10</sup> The odor threshold for phosphine is 0.14-0.28 mg cubic millimeters (0.1-0.2 parts per million). However, odor is not always a reliable indicator of phosphine levels.<sup>10</sup>

Phosphine gas is absorbed through multiple routes (inhalational, dermal, and oral).<sup>11</sup> It is worth noting that ingestion of the fresh rodenticide in the original packaging is associated with increased toxicity. Once the packaging is removed and the rodenticide exposed to moisturized air, it is rendered less toxic due to the conversion of the phosphide and dissipation of the phosphine gas.<sup>7</sup>

## Pathophysiology

Zinc phosphide is a highly toxic compound, and the ingestion of as little as 4-5 grams can lead to significant toxicity and death.<sup>12</sup> The generated phosphine gas is widely distributed in the body to all organ systems.<sup>13</sup> Phosphine is primarily eliminated through exhalation, but it is also oxidized and eliminated in the urine as phosphites.<sup>14</sup> The pathophysiology of zinc phosphide toxicity is multifaceted, and multiple theories

have been proposed to explain its toxicity. The phosphine gas inhibits the cytochrome C oxidase in the inner mitochondrial membrane, leading to dysregulation of the oxidative phosphorylation pathway.<sup>15</sup> Additionally, nuclear and mitochondrial deoxyribonucleic acid damage through guanine oxidation is observed in the brain and the liver.<sup>16</sup> Additionally, phosphine toxicity increases the production of oxygen reactive species, resulting in lipid peroxidation and tissue destruction, and ultimate organ collapse.<sup>17,18</sup>

### **Clinical Characteristics**

Patients with zinc phosphide intoxication usually have multisystem toxicity. The most common presenting signs and symptoms include nausea, vomiting, dyspnea, retrosternal or epigastric pain, and agitation, although patients may present in cardiovascular shock and hemodynamic instability.<sup>3,19</sup> Zinc phosphide toxicity is associated with a high mortality rate, which can range from 37-100%.<sup>20</sup>

### **Gastrointestinal Toxicity**

In a retrospective study conducted on 455 patients who had ingested zinc phosphide in Thailand, Trakulsrichai et al identified gastrointestinal symptoms as the most common presenting symptoms.<sup>3</sup> However, gastrointestinal symptoms are also prevalent in patients who have been exposed through compound inhalation, as shown by Wilson et al.<sup>19</sup> The common symptoms seen in cases of ingestion include nausea, vomiting, and abdominal pain.<sup>4,19</sup> Phosphine is also associated with garlic-like breath.<sup>11</sup> Additionally, zinc phosphide exposure is associated with hematemesis and corrosive changes in the esophagus and stomach of exposed patients.<sup>20-22</sup> Esophageal strictures are another complication that develops following exposure, with cases of tracheoesophageal fistulas also reported.<sup>23-25</sup>

### **Cardiovascular Toxicity**

Phosphine toxicity leads to a constellation of cardiovascular clinical effects. A collapse of the circulatory system is frequently observed, which typically results in refractory hypotension and shock.<sup>26</sup> Tachycardia is a common finding, although in some cases bradycardia is observed despite the persistent hypotension.<sup>27</sup> In a study of 25 patients with phosphine exposure, Kalra et al reported that phosphine toxicity leads to a specific set of hemodynamic changes, which include profound hypotension, decreased cardiac output, increased systemic venous pressure, normal pulmonary capillary wedge pressure, and inadequate systemic vasoconstriction.<sup>28</sup> Patients with hypotension have been found to have left ventricular enlargement early on following intoxication, as well as hypokinesia of the left ventricle and septum, global hypokinesia, and in some cases akinesia.<sup>29-31</sup>

Additionally, studies investigating histological changes in cardiac tissue following exposure to phosphine confirmed the presence of myocardial edema with fiber separation, fragmentation of fibers, vacuolization of myocytes, as focal

necrosis and neutrophilic and eosinophilic infiltrates in the heart.<sup>32-35</sup> Autopsies of isolated cases have also demonstrated evidence of myocarditis, pericardial effusions, and pericarditis.<sup>19,30,33-35</sup> Dysrhythmias including atrioventricular bundle branch blocks, atrial fibrillation, atrial flutter, and other supraventricular tachycardias has been observed in patients following exposure to phosphine.<sup>36</sup> Additionally, ST-segment changes on the electrocardiogram (ECG) similar to those found in myocardial ischemia have been documented in some patients.<sup>37</sup>

### **Respiratory Toxicity**

Labored breathing and chest tightness are among the most common symptoms in patients exposed to phosphine, particularly in those who inhale it.<sup>6,19</sup> Coughing, cyanosis, and the presence of rales and rhonchi on auscultation are also frequent findings.<sup>21</sup> Pulmonary edema and acute respiratory distress syndrome have also been reported in multiple studies.<sup>38,39</sup>

### **Central Nervous System Toxicity**

Neurological signs and symptoms of phosphine toxicity include headache, dizziness, drowsiness, paresthesia, intention tremors, weakness, fasciculations, and altered mental status.<sup>19</sup> Delayed symptoms may include seizures, delirium, and coma, all of which may be caused by electrolyte abnormalities as well as neuronal damage.<sup>19</sup>

### **Hepatic Toxicity**

Elevation of transaminases and, to a lesser extent, jaundice can be observed in patients with phosphine poisoning.<sup>7,19</sup> Saleki et al studied the histological findings in the livers of 33 deceased patients and noted that sinusoidal congestion (77.4%) and fine vacuolization of hepatocytes (71.1%) were the major findings following exposure.<sup>40</sup> Cases of hepatic failure and hepatic encephalopathy have also been reported.<sup>41,42</sup>

### **Metabolic Findings**

Metal phosphide toxicity is associated with glycemic derangement. Severe and persistent hypoglycemia is a common finding of phosphide poisoning, and it is believed to result from impaired hepatic gluconeogenesis and glycogenolysis.<sup>43</sup> However, hyperglycemia is also observed in rare cases and is associated with poorer outcomes.<sup>44</sup> While the underlying causes of the elevated glucose are not fully understood, timely correction of the glucose level is recommended.<sup>44</sup> Another very common finding is metabolic acidosis, which is often severe and associated with poor prognosis.<sup>12,45</sup> Hypokalemia secondary to vomiting, and hyperkalemia secondary to acidosis and renal failure may also develop.<sup>3,7</sup>

### **DIAGNOSIS**

Laboratory confirmation of phosphine exposure is usually not required if it is a known exposure.<sup>2</sup> Phosphine is not tested for in the blood due to rapid oxidation into phosphites.<sup>46</sup> However, a multitude of tests can confirm phosphide exposure

and are required for forensic investigation. Qualitative color tests can be used to detect phosphine in biological samples. Testing can be done using silver nitrate, mercury chloride, potassium permanganate, or mercury diethylocarbamate, and can be performed on samples of expired air, stomach content, urine, or liver tissue.<sup>2</sup> Testing with silver nitrite paper is the most commonly used technique.<sup>2</sup> Silver nitrate paper turns from blue to black when exposed to phosphine, and can detect phosphine concentrations as low as 0.05 mg/L.<sup>2,12</sup>

When phosphide poisoning is suspected, it is important to obtain laboratory tests that can determine the severity of toxicity as well as the prognosis of the patient. This includes blood testing for complete blood count, electrolytes, glucose, arterial blood gases and pH, hepatic function tests, and kidney function tests.<sup>2</sup> Additionally, chest radiography is required to rule out the presence of pulmonary congestion, and an ECG is needed to detect cardiac involvement.<sup>2</sup> Once phosphide poisoning is suspected, a medical toxicologist should be consulted early on for advice and guidance in management.<sup>2</sup>

## TREATMENT

There is currently no known antidote for zinc phosphide toxicity. Management is generally supportive and needs to be initiated promptly. Patients who are symptomatic at presentation require observation in a monitored setting until they are back to baseline.<sup>2</sup>

### Gastrointestinal Decontamination

Activated charcoal could be considered for patients with oral ingestion of zinc phosphide within one hour if there is no contraindication.<sup>2,7,12</sup> However, the use of activated charcoal or other compounds such as potassium permanganate in gastric lavage for metal phosphide poisoning may be of limited benefit due to the lack of molecular interaction between these compounds and the metal phosphide.<sup>47</sup>

### Blood Pressure Control

Hypotension is a common finding in patients with zinc phosphide intoxication that requires immediate attention. Patients should be initially treated with fluid resuscitation.<sup>2</sup> However, hypotension is often resistant to correction by fluids and requires the use of vasoactive agents such as norepinephrine or phenylephrine.<sup>48</sup> Marashi et al also suggested using hydroxyethyl starch, a colloid that causes intravascular volume expansion in the treatment of hypotension.<sup>26</sup> Hydroxyethyl starch was successfully used in one case reported, although further evidence is needed to determine its impact.<sup>26,49</sup> In refractory hypotension that is resistant to fluids and vasopressors, intra-aortic balloon pumps was used in isolated cases with questionable benefit.<sup>50</sup>

### Electrolytes and Blood pH Corrections

The metabolic acidosis observed following zinc phosphide toxicity is suspected to be the result of oxidative

phosphorylation inhibition and severe tissue hypoperfusion secondary to hypotension and shock.<sup>4,51</sup> Sodium bicarbonate ( $\text{NaHCO}_3$ ) is recommended by multiple sources for acidosis.<sup>2,12</sup> However, Marashi et al and Boyd et al recommended that sodium bicarbonate should be reserved for patients in shock with blood pH lower than 7.0.<sup>49,52</sup> In some cases, hemodialysis and peritoneal dialysis were used to correct severe acidosis and fluid overload.<sup>4</sup>

Conflicting evidence exists as to whether metal phosphide toxicity leads to hypomagnesemia or hypermagnesemia and whether supplementation can lead to better outcomes. Chugh et al conducted a randomized study on patients who had been poisoned by aluminum phosphide, in which a group of patients was given several doses of magnesium while another group acted as controls. The treatment group had a significantly better survival rate compared with the control group.<sup>54</sup> However, the benefits of magnesium supplementation remain unclear.

Potassium disturbances should also be addressed and corrected, as they may predispose or worsen dysrhythmias.<sup>7</sup>

### N-acetylcysteine

A decline of antioxidant levels such as glutathione is documented in patients following metal phosphide poisoning.<sup>55</sup> In a retrospective review of 100 cases of aluminum phosphide poisoning, Bhat and Kenchetty found that the use of N-acetylcysteine (NAC) is associated with lower mortality rate, shorter hospital stay, and lower peak levels of aspartate and alanine transaminases.<sup>56</sup> Tehrani et al conducted a randomized clinical trial aimed at assessing the usefulness of NAC in the treatment of aluminum phosphide toxicity. The authors reported a mortality rate of 36% in patients who received NAC and 60% in patients who did not.<sup>57</sup> These findings suggest that NAC may play a role in the treatment of phosphine toxicity. Additionally, Bhalla et al conducted an interventional study and found no difference in mortality rate between the group treated with NAC and the group that did not receive it.<sup>58</sup> Further studies are therefore needed to confirm the role of NAC in the management.

### Extracorporeal Membrane Oxygenation

Extracorporeal membrane oxygenation (ECMO) is being explored as a treatment modality in the management of patients with aluminum phosphide toxicity. Mohan et al reported a series of seven patients with severe acidosis and refractory shock who were treated with ECMO, where five patients survived and had full recovery of left ventricular function.<sup>59</sup> In another study involving 83 patients, Mohan et al found improved short-term survival in 15 patients who were on ECMO. Therefore, ECMO may play a role in the management of phosphide toxicity although further evidence is needed.<sup>60</sup>

### Hyperinsulinemia-euglycemia

High levels of insulin are believed to promote carbohydrate utilization instead of fats, which allows for better myocardial

functioning.<sup>61</sup> Hassanian-Moghaddam and Zamani evaluated two groups of poisoned patients and treated one group with high-dose insulin euglycemia protocol. Patients in the treatment group had significantly longer hospital stays and better survival compared to patients who received supportive treatment only.<sup>62</sup>

### Blood Transfusion

Rahimi et al used packed red blood cells (PRBC) in rats poisoned with metal phosphide and reported improved acidosis and overall survival.<sup>63</sup> In their study, they infused 1.5 mL of PRBCs into the poisoned rats, one hour after intoxication with aluminum phosphide (4-15 mg/kg). PRBC infusion improved the acidosis, electrolyte disturbances, and plasma troponin levels besides reversing the ECG changes. One proposed mechanism is that increased PRBCs chelate toxic intermediates through phosphine-hemoglobin interaction and modulate acid-base disturbances.<sup>63</sup>

### Other Modalities

In another study, minocycline reversed ECG abnormalities, heart failure signs, and kidney injury in rats intoxicated with metal phosphides. The authors postulate that minocycline's effects are due to its ability to improve mitochondrial function and inhibit apoptosis.<sup>64</sup> Melatonin is another drug that is being explored as a treatment modality following phosphine toxicity. Hsu et al showed that melatonin increases glutathione levels and decreases lipid peroxidation in the brain in vivo and in vitro.<sup>16</sup> Asghari et al conducted a similar study on rats and observed a decrease in the phosphine-induced oxidative damage to the heart in the group receiving melatonin.<sup>65</sup> Additionally, Ahmadi et al studied the use of dihydroxyacetone (DHA) in phosphide poisoning in rats and found that DHA resulted in 100% survival and prevented cardiovascular abnormalities. The authors reported a 100% survival rate with improved ECG abnormalities and more stable hemodynamic status.<sup>66</sup>

Triiodothyronine, vasopressin, and milrinone are also being tested in animal models and show promising signs.<sup>67</sup> Triiodothyronine is associated with decrease in cardiac dysfunction, oxidative stress, and apoptosis. Vasopressin is being shown to have cardioprotective effects and cause increase in adenosine triphosphate production. Milrinone causes a decrease in oxidative stress and apoptosis.<sup>67</sup> Liothyronine and acetyl-L-carnitine have been studied for potential benefit for phosphide toxicity treatment.<sup>67</sup> Based on in vitro studies, theoretically 6-aminonicotinamide showed protective activity in hepatocytes and boric acid may act as a trapping agent to trap phosphine, which can be excreted in urine.<sup>67</sup> Further studies are needed to assess the role of these potential compounds in the management of phosphide toxicity.

### CONCLUSION

Emergency physicians and toxicologists in developing countries often face challenges when caring for patients who

have been exposed to unlabeled and unregulated pesticides commonly found in the marketplace. Zinc and aluminum phosphides should be included on the differential when approaching an intentional ingestion of unlabeled product that is marketed as a rodenticide. This article is a comprehensive review of phosphide toxicity clinical presentation and approach to management. Toxicity affects multiple organ systems and frequently leads to shock and severe metabolic acidosis. Metabolic, cardiovascular, hepatic, and renal complications are common. There remains to be found a recognized antidote for metal phosphide toxicity, and treatment is mostly supportive.

The Institutional Review Board approval has been documented and filed for publication of this case report.

---

*Address for Correspondence:* Tharwat El Zahran, MD, American University of Beirut Medical Center, Department of Emergency Medicine, P.O. Box 11-0236, Riad El Sohl, Beirut, 1107 2020, Beirut-Lebanon. Email: te15@aub.edu.lb.

*Conflicts of Interest:* By the CPC-EM article submission agreement, all authors are required to disclose all affiliations, funding sources and financial or management relationships that could be perceived as potential sources of bias. The authors disclosed none.

*Copyright:* © 2020 Hamade et al. This is an open access article distributed in accordance with the terms of the Creative Commons Attribution (CC BY 4.0) License. See: <http://creativecommons.org/licenses/by/4.0/>

---

### REFERENCES

1. Shadnia S and Soltaninejad K. (2019). Fumigants. In: Nelson LS, Howland MA, Lewin NA, et al (eds). *Goldfrank's Toxicologic Emergencies*, 11e. New York, NY: McGraw-Hill Education.
2. Hashemi-Domeneh B, Zamani N, Hassanian-Moghaddam H, et al. A review of aluminium phosphide poisoning and a flowchart to treat it. *Arh Hig Rada Toksikol.* 2016;67(3):183-93.
3. Trakulsrichai S, Kosanyawat N, Atiksawedparit P, et al. Clinical characteristics of zinc phosphide poisoning in Thailand. *Ther Clin Risk Manag.* 2017;13:335-40.
4. Yogendranathan N, Herath H, Sivasundaram T, et al.. A case report of zinc phosphide poisoning: complicated by acute renal failure and tubulo interstitial nephritis. *BMC Pharmacol Toxicol.* 2017;18(37):37.
5. Nekooghadam S, Haghghatkhah H, Vaezi F, et al. Zinc phosphide poisoning with unusual radiologic findings. *Clin Case Rep.* 2017;5(3):264-7.
6. Proudfoot AT. Aluminium and zinc phosphide poisoning. *Clin Toxicol (Phila).* 2009;47(3):89-100.
7. Moghadamnia AA. An update on toxicology of aluminum phosphide. *Daru.* 2012;20(1):25.

8. PubChem Compound Database. Trizinc diphoside. Available at: <https://pubchem.ncbi.nlm.nih.gov/compound/4643716>. Accessed Jan. 30, 2019.
9. Balali M. International Program on Chemical Safety (IPCS). Phosphine. Available at: <http://www.inchem.org/documents/pims/chemical/pim865.htm>. Accessed May 15, 2019.
10. Assesm L and Takamiya M. *Phosphine Toxicological Overview*. [ebook] Assets Publishing Service, United Kingdom Government 2007 Available at: [https://assets.publishing.service.gov.uk/government/uploads/system/uploads/attachment\\_data/file/338253/HPA\\_Phosphine\\_toxicological\\_overview\\_v1.pdf](https://assets.publishing.service.gov.uk/government/uploads/system/uploads/attachment_data/file/338253/HPA_Phosphine_toxicological_overview_v1.pdf). Accessed September 4, 2020.
11. PubChem Compound Database. Phosphine. Available at: <https://pubchem.ncbi.nlm.nih.gov/compound/24404>. Accessed January 30, 2019.
12. Vij K. Fumigants. In: *Textbook of Forensic Medicine and Toxicology: Principles and Practice. 5th edition (p. 543)*: Amsterdam, Netherlands: Elsevier. 2012.
13. Day CH. Aluminum phosphide. In: Wexler P (ed). *Encyclopedia of Toxicology 2nd ed, (p. 84-6)*. Amsterdam, Netherlands: Elsevier. 2005.
14. Bumbrah GS, Krishan K, Kanchan T, et al. Phosphide poisoning: a review of literature. *Forensic Sci Int*. 2012;214(1-3):1-6.
15. Singh S, Bhalla A, Verma SK, et al. Cytochrome-c oxidase inhibition in 26 aluminum phosphide poisoned patients. *Clin Toxicol (Phila)*. 2006;44(2):155-8.
16. Hsu CH, Chi BC, Casida JE. Melatonin reduces phosphine-induced lipid and DNA oxidation in vitro and in vivo in rat brain. *J Pineal Res*. 2002;32(1):53-8.
17. Sciuto AM, Wong BJ, Martens ME, et al. Phosphine toxicity: a story of disrupted mitochondrial metabolism. *Ann N Y Acad Sci*. 2016;1374(1):41-51.
18. Hsu C, Han B, Liu M, et al. Phosphine-induced oxidative damage in rats: attenuation by melatonin. *Free Radic Biol Med*. 2000;28(4):636-42.
19. Wilson R, Lovejoy FH, Jaeger RJ, et al. Acute phosphine poisoning aboard a grain freighter. Epidemiologic, clinical, and pathological findings. *JAMA*. 1980;244(2):148-50.
20. Anand R, Binukumar BK, Gill KD. Aluminum phosphide poisoning: an unsolved riddle. *J Appl Toxicol*. 2011;31(6):499-505.
21. Chugh SN, Dushyant, Ram S, et al. Incidence & outcome of aluminium phosphide poisoning in a hospital study. *Indian J Med Res*. 1991;94:232-5.
22. Chhina RS, Thukral R, Chawla LS. Aluminum phosphide-induced gastroduodenitis. *Gastrointest Endosc*. 1992;38(5):635-6.
23. Darbari A, Tandon S, Chaudhary S, et al. Esophageal injuries due to aluminum phosphide tablet poisoning in India. *Asian Cardiovasc Thorac Ann*. 2008;16(4):298-300.
24. Kochhar R, Dutta U, Poornachandra KS, et al. Clinical profile and outcome of aluminum phosphide-induced esophageal strictures. *J Med Toxicol*. 2010;6:301-6.
25. Tiwari J, Lahoti B, Dubey K, et al. Tracheo-oesophageal fistula - an unusual complication following celphos poisoning. *Indian J Surg*. 2003;65(5):442-4.
26. Marashi SM, Arefi M, Behnouch B, et al. Could hydroxyethyl starch be a therapeutic option in management of acute aluminum phosphide toxicity? *Med Hypotheses*. 2011;76(4):596-8.
27. Chugh SN, Ram S, Singhal HR, et al. Significance of heart rate response in shock due to aluminium phosphide poisoning. *J Assoc Physicians India*. 1989;37(11):708-9.
28. Kalra GS, Anand IS, Jit I, et al. Aluminium phosphide poisoning: haemodynamic observations. *Indian Heart J*. 1991;43(3):175-8.
29. Gupta MS, Malik A, Sharma VK. Cardiovascular manifestations in aluminium phosphide poisoning with special reference to echocardiographic changes. *J Assoc Physicians India*. 1995;43(11):773-4, 779-80.
30. Akkaoui M, Achour S, Abidi K, et al. Reversible myocardial injury associated with aluminum phosphide poisoning. *Clin Toxicol (Phila)*. 2007;45(6):728-31.
31. El Hangouche AJ, Fennich H, Alaika O, et al. Reversible myocardial injury and intraventricular thrombus associated with aluminium phosphide poisoning. *Case Rep Cardiol*. 2017;2017:6287015.
32. Chugh SN, Jaggal KL, Sharma A, et al. Magnesium levels in acute cardiotoxicity due to aluminium phosphide poisoning. *Indian J Med Res*. 1991;94:437-9.
33. Arora B, Punia RS, Kalra R, et al. Histopathological changes in aluminium phosphide poisoning. *J Indian Med Assoc*. 1995;93(10):380-1.
34. Chugh SN, Chugh K, Ram S, et al. Electrocardiographic abnormalities in aluminium phosphide poisoning with special reference to its incidence, pathogenesis, mortality and histopathology. *J Indian Med Assoc*. 1991;89(2):32-5.
35. Siwach SB, Dua A, Sharma R, et al. Tissue magnesium content and histopathological changes in non-survivors of aluminium phosphide poisoning. *J Assoc Physicians India*. 1995;43(10):676-8.
36. Khosla SN, Nand N, Kumar P. Cardiovascular complications of aluminum phosphide poisoning. *Angiology*. 1988;39(4):355-9.
37. Soltaninejad K, Beyranvand MR, Momenzadeh SA, et al. Electrocardiographic findings and cardiac manifestations in acute aluminum phosphide poisoning. *J Forensic Leg Med*. 2012;19(5):291-3.
38. Dogan E, Guzel A, Ciftci T, et al. Zinc phosphide poisoning. *Case Rep Crit Care*. 2014;2014:589712.
39. Sogut O, Baysal Z, Ozdemir B. Acute pulmonary edema and cardiac failure due to zinc phosphide ingestion. *J Emerg Med*. 2011;40(6):e117-8.
40. Saleki S, Ardalan FA, Javidan-Nejad A. Liver histopathology of fatal phosphine poisoning. *Forensic Sci Int*. 2007;166(2-3):190-3.
41. Bayazit AK, Noyan A, Anarat A. A child with hepatic and renal failure caused by aluminum phosphide. *Nephron*. 2000;86(4):517.
42. Haridas A, Mukker P, Hameed S, et al. Acute on chronic liver failure presentation of zinc phosphide poisoning: a concept elucidating case report. *International Journal of Research in Medical Sciences*. 2016;4(6):2494-6.
43. Frangides CY and Pneumatikos IA. Persistent severe hypoglycemia in acute zinc phosphide poisoning. *Intensive Care Med*. 2002;28(2):223.

44. Mehrpour O, Alfred S, Shadnia S, et al. Hyperglycemia in acute aluminum phosphide poisoning as a potential prognostic factor. *Hum Exp Toxicol*. 2008;27(7):591-5.
45. Louriz M, Dendane T, Abidi K, et al. Prognostic factors of acute aluminum phosphide poisoning. *Indian J Med Sci*. 2009;63(6):227-34.
46. Yadav J, Athawal BK, Dubey BP, et al. Spontaneous ignition in case of celphos poisoning. *Am J Forensic Med Pathol*. 2007;28(4):353-5.
47. Marashi SM, Majidi M, Asadabadi HR, et al. A common misconception in the management of aluminium phosphide poisoning. *Arh Hig Rada Toksikol*. 2013;64(3):475-6.
48. Farahani MV, Soroosh D, Marashi SM. Thoughts on the current management of acute aluminum phosphide toxicity and proposals for therapy: an Evidence-based review. *Indian J Crit Care Med*. 2016;20(12):724-30.
49. Marashi SM and Nasri-Nasrabadi Z. Can sodium bicarbonate really help in treating metabolic acidosis caused by aluminium phosphide poisoning? *Arh Hig Rada Toksikol*. 2015;66(1):83-4.
50. Bagheri-Moghaddam A, Abbaspour H, Tajoddini S, et al. Using intra-aortic balloon pump for management of cardiogenic shock following aluminum phosphide poisoning; report of 3 cases. *Emerg (Tehran)*. 2018;6(1):e3.
51. Chaudhry D and Rai AS. N-acetyl cysteine in aluminum phosphide poisoning: myth or hope. *Indian J Crit Care Med*. 2014;18(10):646-7.
52. Boyd JH and Walley KR. Is there a role for sodium bicarbonate in treating lactic acidosis from shock? *Curr Opin Crit Care*. 2008;14(4):379-83.
53. Hakimoglu S, Dikey I, Sari A, et al. Successful management of aluminium phosphide poisoning resulting in cardiac arrest. *Turk J Anaesthesiol Reanim*. 2015;43(4):288-90.
54. Chugh SN, Kumar P, Aggarwal HK, et al. Efficacy of magnesium sulphate in aluminium phosphide poisoning--comparison of two different dose schedules. *J Assoc Physicians India*. 1994;42(5):373-5.
55. Dua R and Gill KD. Aluminium phosphide exposure: implications on rat brain lipid peroxidation and antioxidant defence system. *Pharmacol Toxicol*. 2001;89(6):315-9.
56. Bhat S and Kenchetty KP. N-acetyl cysteine in the management of rodenticide consumption - life saving? *J Clin Diagn Res*. 2015;9(1):OC10-3.
57. Tehrani H, Halvaie Z, Shadnia S, et al. Protective effects of N-acetylcysteine on aluminum phosphide-induced oxidative stress in acute human poisoning. *Clin Toxicol (Phila)*. 2013;51(1):23-8.
58. Bhalla A, Jyothinath P, Singh S. Antioxidant therapy in patients with severe aluminum phosphide poisoning: a pilot study. *Indian J Crit Care Med*. 2017;21(12):836-40.
59. Mohan B, Gupta V, Ralhan S, et al. Role of Extracorporeal membrane oxygenation in aluminum phosphide poisoning-induced reversible myocardial dysfunction: a novel therapeutic modality. *J Emerg Med*. 2015;49(5):651-6.
60. Mohan B, Singh B, Gupta V, et al. Outcome of patients supported by extracorporeal membrane oxygenation for aluminum phosphide poisoning: an observational study. *Indian Heart J*. 2016;68(3):295-301.
61. Woodward C, Pourmand A, Mazer-Amirshahi M. High dose insulin therapy, an evidence based approach to beta blocker/calcium channel blocker toxicity. *Daru*. 2014;22(1):36.
62. Hassanian-Moghaddam H and Zamani N. Therapeutic role of hyperinsulinemia/euglycemia in aluminum phosphide poisoning. *Medicine (Baltimore)*. 2016;95(31):e4349.
63. Rahimi N, Abdolghaffari AH, Partoazar A, et al. Fresh red blood cells transfusion protects against aluminum phosphide-induced metabolic acidosis and mortality in rats. *PLoS One*. 2018;13(3):e0193991.
64. Haghi-Aminjan H, Baeeri M, Rahimifard M, et al. The role of minocycline in alleviating aluminum phosphide-induced cardiac hemodynamic and renal toxicity. *Environ Toxicol Pharmacol*. 2018;64:26-40.
65. Asghari MH, Moloudizargari M, Baeeri M, et al. On the mechanisms of melatonin in protection of aluminum phosphide cardiotoxicity. *Arch Toxicol*. 2017;91(9):3109-20.
66. Ahmadi J, Joukar S, Anani H, et al. Dihydroxyacetone as a definitive treatment for aluminium phosphide poisoning in rats. *Arh Hig Rada Toksikol*. 2018;69(2):169-77.
67. Karimani A, Mohammadpour AH, Zirak MR, et al. Antidotes for aluminum phosphide poisoning - an update. *Toxicol Rep*. 2018;5:1053-9.

# Case Report: Subcutaneous Emphysema and Pneumomediastinum Following Dental Extraction

Ryan M. Brzycki, DO

Mercy St. Vincent Medical Center, Department of Emergency Medicine, Toledo, Ohio

Section Editor: Scott Goldstein, MD

Submission history: Submitted July 22, 2020; Revision received September 17, 2020; Accepted September 18, 2020

Electronically published January 11, 2021

Full text available through open access at [http://escholarship.org/uc/uciem\\_cpem](http://escholarship.org/uc/uciem_cpem)

DOI: 10.5811/cpcem.2020.9.49208

**Introduction:** Emergency physicians should be cognizant of complications following common procedures (including dental) and be able to readily care for patients with acute dental pain.

**Case Report:** A 22-year-old female presented with dental pain and difficulty swallowing that developed 48 hours after she underwent a dental extraction. The physical exam showed an uncomfortable, afebrile female with dysphonia, inability to tolerate secretions, and crepitus over the neck and anterior chest wall.

**Discussion:** The use of a high-speed dental drill may have caused air to dissect through fascial planes leading to subcutaneous emphysema, or even through deeper planes resulting in pneumomediastinum. It should be noted that subcutaneous emphysema and pneumomediastinum are rare complications of dental procedures.

**Conclusion:** This case highlights an uncommon but potentially life-threatening complication following a routine dental procedure, which emergency clinicians should be attentive to and able to identify and thereby manage. [*Clin Pract Cases Emerg Med.* 2021;5(1):58–61.]

**Keywords:** *Pneumomediastinum; subcutaneous emphysema; dental procedure; dysphagia; dental emergency.*

## INTRODUCTION

Subcutaneous emphysema and pneumomediastinum have a myriad of etiologies ranging from trauma or infection to post-surgical or even spontaneous origin.<sup>1</sup> Although these complications may arise following innocuous dental procedures such as tooth extraction, they are far more rare.<sup>1,2</sup> When subcutaneous emphysema and pneumomediastinum do occur following dental procedures, they are almost always a result of the use of a compressed air drill and involve the mandibular molars.<sup>1</sup> This case highlights the rare complication of subcutaneous emphysema and pneumomediastinum following a tooth extraction with local anesthetic. The mechanisms, clinical presentations, complications, and management are reviewed.

## CASE REPORT

A 22-year-old female presented to the emergency department (ED) with the complaint of left-sided jaw pain,

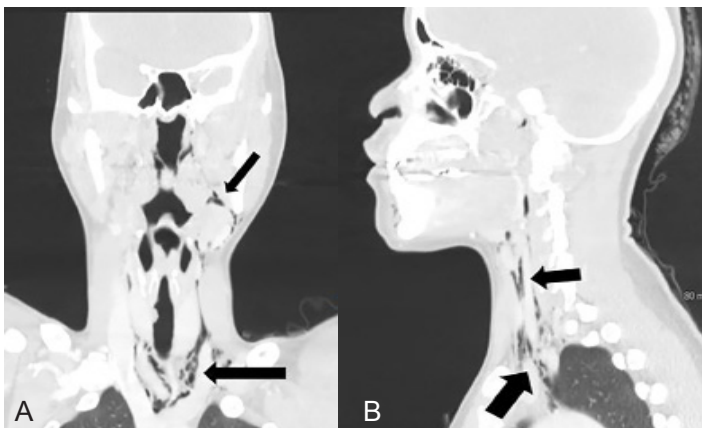
left cheek swelling, dysphagia, and odynophagia that developed 48 hours after a dental extraction. The patient had been seen in the ED earlier that day for left jaw pain but did not endorse odynophagia at that time and was capable of eating and drinking. She denied any fever, headache, vision change, eye pain, nausea, vomiting, dyspnea, or use of straws. Her past medical history did not contain any pre-existing cardiopulmonary disease and she was in good health without any prior surgeries. She denied tobacco or alcohol use. Two days prior to her visit to the ED, she underwent a tooth extraction at her dentist's office where her left mandibular first molar was removed. The patient received bupivacaine with epinephrine injection for local anesthesia. Later review of dental records indicated that a pressurized air turbine dental drill had then been used for resection of the tooth prior to extraction.

Her vital signs in the ED were as follows: blood pressure of 124/68 millimeters of mercury; heart rate 82 beats per

minute; respiratory rate 15 breaths per minute; oxygen saturation of 98% on room air; and oral temperature 36.8° Celsius. Physical examination showed an uncomfortable-appearing female who was expectorating saliva into an emesis basin. She exhibited slight dysphonia but no stridor, and was able to speak in full sentences without difficulty. The patient exhibited tenderness to palpation over the left mandible with mild cheek edema, without erythema. Partial dislodgement of blood clot overlying the left first mandibular molar (tooth number 19) was noted. The trachea was midline and there was no meningismus, although she had increased midline neck pain with resistance to neck extension (secondary to pain). She had palpable crepitus over the neck and anterior chest wall.

Laboratory findings showed a white blood cell count of 6.8 thousand per microliter (K/uL) (reference range 3.5-11.3 k/uL), hemoglobin of 15.2 grams per deciliter (g/dL) (ref range 11.9-15.1 g/dL), platelet count of 300 (K/uL) (ref range 138-453 K/uL), and C-reactive protein 8 milligrams per liter (mg/L) (ref range < 5 mg/L). A computed tomography (CT) soft tissue neck with intravenous (IV) contrast was performed, which demonstrated extensive air accumulation involving the oral, retropharyngeal space, and pneumomediastinum (Image). After consultation with a cardiothoracic surgeon, the decision was made to begin prophylactic antibiotics. She was started on IV maintenance fluids and ampicillin-sulbactam for broad spectrum coverage including oral flora.

The patient was admitted for observation and discharged three days later. An esophagram taken to rule out esophageal damage showed that the esophagus appeared to be without injury and was functioning normally. The patient received a follow-up phone call one week after being discharged and reported complete resolution of symptoms.



**Image.** (A) Computed tomography (CT) with intravenous contrast (coronal) demonstrating extension of the subcutaneous emphysema from left lower molar tooth, along both the anterior and posterior triangles extending up to the retrosternal area and into the mediastinum (arrows). (B) CT with intravenous contrast (sagittal) demonstrating extension of the subcutaneous emphysema from the left lower molar tooth into the retropharyngeal space and mediastinum (arrows).

### *CPC-EM Capsule*

What do we already know about this clinical entity?

*Subcutaneous emphysema and pneumomediastinum following dental procedures is a rare but life threatening complication that may be easily overlooked.*

What makes this presentation of disease reportable?

*Emergency physicians should be aware of the rare but serious complications that may occur following seemingly innocuous dental procedures.*

What is the major learning point?

*The images serve to solidify the severity of the disease process that may occur following local dental extraction.*

How might this improve emergency medicine practice?

*When a patient presents with dental pain, dysphagia, or odynophagia following dental extraction, allergic reaction and subcutaneous emphysema with pneumomediastinal extension should be considered.*

## DISCUSSION

Emergency physicians are more likely to encounter subcutaneous emphysema and pneumomediastinum from non-dental causes. These non-dental causes include traumatic intubation, mechanical ventilation, facial trauma, forceful vomiting leading to esophageal rupture, asthma exacerbation with alveolar rupture, and intense Valsalva maneuver. They can also result following endoscopic procedures such as tracheostomy, head, neck or thoracic surgery, endoscopy, bronchoscopy or, rarely, foreign body or tumor in the bronchopulmonary tree or digestive tract.<sup>1</sup> Subcutaneous emphysema with pneumomediastinal extension are also rare complications following various dental procedures, especially after the use of an air pressurized dental drill used for cutting, extracting, and cooling dental surfaces.<sup>1</sup>

When a pressurized drill is overused or used at an improper angle, it forces pressurized air and unsterile water beneath soft tissue spaces via disruptions in the dentoalveolar membrane.<sup>2-4</sup> Air and water may then dissect along the multiple fascial planes between the mouth and mediastinum, especially near the roots of the three molars that directly communicate with the sublingual and retropharyngeal spaces, risking the spread of contaminants

from the gingival flora into the mediastinum.<sup>2</sup> Mediastinal extension is associated with a myriad of potentially serious complications that increase morbidity and mortality such as infective mediastinitis, tension pneumothorax, pericardial tamponade, airway obstruction, or even air embolism.<sup>2,5-7</sup>

Physicians might attribute immediate dyspnea and swelling after a dental procedure to allergic reaction or angioedema, and delayed symptoms to hematoma or soft tissue infection such as cellulitis, Ludwig's angina or Lemierre's syndrome.<sup>5,8</sup> Patients with isolated subcutaneous emphysema typically present with painless edema of the face and neck; however, the presence of palpable crepitus is pathognomonic and clearly distinguishes from other causes.<sup>4,5,9</sup> Symptom onset is within a few hours following the procedure in over 90% of cases, but seldomly beyond 48 hours.<sup>6,11</sup> Rarely, dysphonia, dyslalia, brassy voice, and hearing loss occur due to free air in the retropharyngeal space compressing the Eustachian tube.<sup>8</sup> Once palpable crepitus is noted, there should be immediate consideration for pneumomediastinum and potentially associated pneumothorax, esophageal rupture, or infection within the fascial planes.<sup>2,10</sup> Patients with pneumomediastinum typically present with dyspnea, chest pain, back pain, dysphagia, odynophagia, or Hamman's sign (a systolic friction rub).<sup>5,7,10,11</sup>

Diagnosis of subcutaneous emphysema and pneumomediastinum is confirmed radiographically. A CT of the chest and neck is the most sensitive test for detecting widespread emphysema and pneumomediastinum.<sup>4,5</sup> If CT is unavailable, use of plain radiographs of the chest and neck will show radiolucent layers of free air.

Subcutaneous emphysema by itself, despite the possibility of leading to local infection, is relatively benign and innocuous, with most cases spontaneously resolving within 2-10 days. These patients can be managed with reassurance, analgesia, and observational telemetry monitoring for cardiac and respiratory efforts. Since infection is rare, antibiotics are not always necessary; nevertheless, they are frequently prescribed. Patients with pneumomediastinum, however, are typically admitted for IV prophylactic, broad-spectrum antibiotics to cover oral aerobes and anaerobes. The possibility of further complications may be decreased by use of sedatives to lower respiratory effort. Additionally, stool softeners, antitussives, and antihistamines to decrease intrathoracic pressure generated from Valsalva, coughing, and nose blowing may be efficacious.

In most cases, the reabsorption of air begins within two to three days, frequently having complete resolution by day 7-10 after onset.<sup>8,9</sup> This process may be hastened with the use of oxygen inhalation through nasal cannula or nonrebreather, which reduces the partial pressure of nitrogen within the blood, ultimately increasing air reabsorption.<sup>10</sup> In the setting of ED presentation following dental work with a high-pressure drill or syringe, further invasive procedures such as

nasoendoscopy, bronchoscopy, esophagoscopy, or barium esophagram are unnecessary.

## CONCLUSION

Cervicofacial and mediastinal emphysema rarely occurs following a common dental procedure such as molar extraction. Most reported cases are localized to the cervicofacial regions; only a few cases have been reported with mediastinal extension. It is imperative that clinicians be able to identify and diagnose complications associated with face or neck swelling following dental procedures as most cases are misdiagnosed and the complications could be fatal.

## ACKNOWLEDGMENTS

The completion of this case report would not have been possible without the assistance from a myriad of people who cannot all be named here but are appreciated and gratefully acknowledged. I would specifically like to express my deepest appreciation to Dr. Plewa, MD, and Dr. Brunn, PhD, for their endless support, mentorship, acumen, and editorial assistance during the preparation of this case report. Above all, I wish to acknowledge my loving parents, brother, grandparents, aunts, and cousins who provided support to me, either financially, physically, or morally. I would not be the man I am today without your sagacious guidance. Thank you.

The author attests that his institution requires neither Institutional Review Board approval, nor patient consent for publication of this case report. Documentation on file.

---

*Address for Correspondence:* Ryan M. Brzycki, DO, Mercy St Vincent Medical Center, Department of Emergency Medicine, 2213 Cherry Street, Toledo, OH 43608. Email: [rmbrzycki@mercy.com](mailto:rmbrzycki@mercy.com).

*Conflicts of Interest:* By the *CPC-EM* article submission agreement, all authors are required to disclose all affiliations, funding sources and financial or management relationships that could be perceived as potential sources of bias. The authors disclosed none.

*Copyright:* © 2020 Brzycki. This is an open access article distributed in accordance with the terms of the Creative Commons Attribution ([CC BY 4.0](https://creativecommons.org/licenses/by/4.0/)) License. See: <http://creativecommons.org/licenses/by/4.0/>

---

## REFERENCES

1. Mitsunaga S, Iwai T, Aoki N, et al. Cervicofacial subcutaneous and mediastinal emphysema caused by air cooling spray of dental laser. *Oral Surg Oral Med Oral Pathol Oral Radiol.* 2013;115(6):13-6.
2. Ali A and Cunliffe D. Surgical emphysema and pneumomediastinum

- complicating dental extraction. *Br Dent J.* 2000;188(11):589-90.
3. Monsour PA, and Savage NW. Cervicofacial emphysema following dental procedures. *Aust Dent J.* 1989;34(5):403-6.
  4. Yang SC, Chiu TH, Lin TJ, et al. Subcutaneous emphysema and pneumomediastinum secondary to dental extraction: a case report and literature review. *Kaohsiung J Med Sci.* 2006;22(12):641-5.
  5. An GK, Zats B, Kunin M. Orbital, mediastinal, and cervicofacial subcutaneous emphysema after endodontic retreatment of a mandibular premolar: a case report. *J Endod.* 2014;40(6):880-3.
  6. Mckenzie WS, and Rosenberg M. Iatrogenic subcutaneous emphysema of dental and surgical origin: a literature review. *J Oral Maxillofac Surg.* 2009;67(6):1265-8.
  7. Mishra L. Iatrogenic subcutaneous emphysema of endodontic origin: case report with literature review. *J Clin Diagn Res.* 2014;8(1):279-81.
  8. Mather A, Stoykewych A, Curran J. Cervicofacial and mediastinal emphysema complicating a dental procedure. *J Can Dent Assoc.* 2006;72(6):565-8.
  9. Jeong CH, Yoon S, Chung SW, et al. Subcutaneous emphysema related to dental procedures. *J Korean Assoc Oral Maxillofac Surg.* 2018;44(5):212-9.
  10. Patel N, Lazow SK, Berger J. Cervicofacial subcutaneous emphysema: case report and review of literature. *J Oral and Maxillofac Surg.* 2010;68(8):1976-82.
  11. Bocchialini G, Ambrosi S, Castellani A. Massive cervicothoracic subcutaneous emphysema and pneumomediastinum developing during a dental hygiene procedure. *Case Rep Dent.* 2017;2017:1-4.

# Young Man with Cardiac Arrest Secondary to Undiagnosed Mediastinal Mass: A Case Report

Ian Mallett, MD  
Bjorn Watsjold, MD, MPH  
Anne K. Chipman, MD, MS

University of Washington, Department of Emergency Medicine, Seattle, Washington

Section Editor: Austin Smith, MD

Submission history: Submitted July 23, 2020; Revision received November 15, 2020; Accepted November 5, 2020

Electronically published January 12, 2021

Full text available through open access at [http://escholarship.org/uc/uciem\\_cpccem](http://escholarship.org/uc/uciem_cpccem)

DOI: 10.5811/cpcem.2020.11.49235

**Introduction:** A 20-year-old man with a reported history of asthma presented to the emergency department in cardiac arrest presumed to be caused by respiratory failure.

**Case Report:** The patient was discovered to have central airway obstruction and concomitant superior vena cava compression caused by a large mediastinal mass—a condition termed mediastinal mass syndrome. While the patient regained spontaneous circulation after endotracheal intubation, he was challenging to ventilate requiring escalating interventions to maintain adequate ventilation.

**Conclusion:** We describe complications of mediastinal mass syndrome and an approach to resuscitation, including ventilator adjustments, patient repositioning, double-lumen endotracheal tubes, specialty consultation, and extracorporeal life support. [Clin Pract Cases Emerg Med. 2021;5(1):62–65.]

**Keywords:** *Mediastinal mass; mediastinal mass syndrome; cardiac arrest; superior vena cava syndrome.*

---

## INTRODUCTION

Masses of the mediastinum are rare. In the Framingham Heart Study, mediastinal masses were present in 0.9% patients<sup>1</sup>; the exact prevalence, however, is difficult to ascertain given that most are asymptomatic until they compress or invade surrounding structures. Compression of the trachea may result in complaints of shortness of breath, orthopnea, cough, or stridor. These symptoms are often exacerbated by upper respiratory tract infections, airway inflammation, or manipulation.<sup>2</sup>

Compression of the vena cava may result in superior vena cava (SVC) syndrome, which is characterized by intermittent swelling of the face and oropharyngeal structures, facial rubor, and/or venous congestion. Compression of pulmonary arteries may mimic massive pulmonary embolism (PE) causing acute right heart failure or circulatory collapse secondary to severely impaired pulmonary venous return, drastically reducing left ventricular preload. Collectively, this constellation of pathologies is known as mediastinal mass syndrome.<sup>2,3,4</sup> Cardiopulmonary arrest has been reported secondary to compression of neck and/or mediastinal structures by large

mediastinal masses causing obstructive shock, and patients can become difficult to ventilate after being given neuromuscular blockade for intubation. Providers must take care to rule out other causes of obstructive shock such as PE, cardiac tamponade, aortic stenosis, and tension pneumothorax.<sup>4-6</sup>

## CASE REPORT

A young man with a reported history of asthma presented to the emergency department (ED) with ongoing cardiopulmonary resuscitation (CPR) after suffering from cardiac arrest on the sidewalk in front of the hospital. Family of the patient reported a two-week history of worsening dyspnea prior to his presentation.

Initial examination revealed an apneic patient with distended veins across his upper chest and neck suggestive of obstructive pathology as a potential etiology of arrest, in addition to the history of respiratory distress. Medical providers inserted one 14-gauge angiocatheter in the bilateral second intercostal spaces for chest decompression, but no rush of air was noted. The cardiac monitor showed an initial rhythm of wide-complex pulseless electrical activity. With CPR ongoing,

the patient was intubated without complication via direct laryngoscopy and manually ventilated with return of spontaneous circulation (ROSC) after approximately six minutes of CPR. No adjuvant medications were given prior to ROSC as the first four minutes of CPR were provided outside of the ED, and intubation with subsequent ROSC was achieved simultaneously with successful peripheral vascular access.

No oropharyngeal or airway abnormalities were noted other than minimal edema of the epiglottis. Endotracheal tube (ETT) placement was verified by auscultation, condensation within the tube, and colorimetric carbon dioxide (CO<sub>2</sub>) device. Initial arterial blood gas (with reference ranges in parentheses) after intubation showed a pH of 6.97 (7.35-7.45); pCO<sub>2</sub> of 104 millimeters mercury (mm Hg) (reference range 35-45 mm Hg); oxygen (pO<sub>2</sub>) of 44 mm Hg (75-100 mm Hg); and bicarbonate (HCO<sub>3</sub>) of 23 milliequivalents per liter (mEq/L) (22-26 mEq/L). After ROSC, his oxygenation was 95%. The patient was given nebulized albuterol and intravenous (IV) magnesium and methylprednisolone for presumed respiratory arrest secondary to severe asthma.

After five minutes, the mechanical ventilator alarmed and then failed to ventilate, with peak inspiratory pressures (PIP) elevated to 90 centimeters of water (cm H<sub>2</sub>O) indicating major airway resistance. The patient's oxygenation decreased to 82%. However, manual bag ventilation was subsequently performed without significant difficulty and with improvement of oxygenation to 95%. Point-of-care ultrasound demonstrated lung sliding bilaterally and showed a heterogeneous mass overlying the heart and obscuring parasternal views. No pericardial effusion was noted. An electrocardiogram demonstrated sinus tachycardia without obvious findings to suggest pericarditis or acute ischemia. A portable chest radiograph was obtained, which showed the ETT in appropriate position and revealed a large, central opacity obscuring the normal airway anatomy and cardiac silhouette (Image 1).

Providers recognized that a large mediastinal mass might be compressing the airway, accounting for the high inspiratory pressures. The ETT was advanced approximately four cm (as far as possible without meeting resistance) attempting to bypass the obstruction; the ventilator was reconnected after manual bag ventilation and ventilated the patient appropriately with the original setting of positive end-expiratory pressure (PEEP) 5 cm H<sub>2</sub>O. Computed tomography (CT) demonstrated a large mass in the anterior mediastinum, with almost complete obliteration of the SVC with significant collateralization, as well as severe stenosis of the airways at the level of the lower one-third of the trachea, carina, and main-stem bronchi (Image 2).

While the patient was undergoing CT the ventilator again failed secondary to increased PIPs, and manual bagging was reinitiated. PEEP was increased to 10 cm H<sub>2</sub>O, and providers raised the patient to a semi-recumbent position, which allowed the ventilator to oxygenate with PIPs in the 40s. Prior to intensive care unit admission, a cooling catheter was placed in

### *CPC-EM Capsule*

What do we already know about this clinical entity?

*Mediastinal masses are rare and can become large enough to cause compression of the trachea or heart. This is called "mediastinal mass syndrome (MMS)."*

What makes this presentation of disease reportable?

*MMS led to cardiac arrest in a young, otherwise healthy patient who was difficult to ventilate secondary to tracheal compression.*

What is the major learning point?

*Simple steps such as patient repositioning and increasing positive end-expiratory pressure may be life saving in cases of MMS.*

How might this improve emergency medicine practice?

*Providers should be aware of MMS, the steps to correct resulting central airway obstruction and also consider extracorporeal membrane oxygenation.*

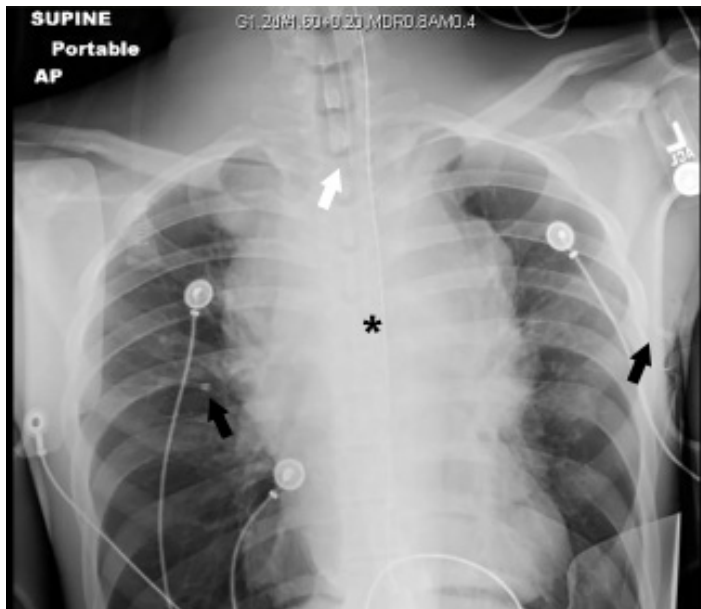
the common femoral vein. Repeat blood gas showed improvement with a pH of 7.33 and downtrending lactate.

The patient regained consciousness after cooling and rewarming but demonstrated diffuse myoclonus affecting the diaphragm, preventing extubation, and ultimately required tracheostomy.

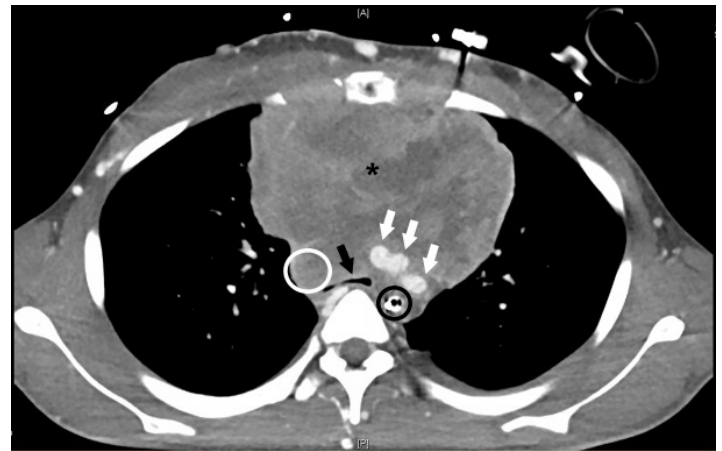Tissue sampling of the mass revealed a large B-cell lymphoma, and chemotherapy was started. He subsequently developed massive hemorrhage from his right common carotid artery and jugular vein due to malignant erosion into these vessels. He suffered a subsequent arrest and was resuscitated in the operating room with ligation of the bleeding vessels but had diffuse brain injury on magnetic resonance imaging (MRI). His family agreed that further treatment was unlikely to lead to meaningful recovery, and he died on hospital day 52 after care was withdrawn.

### **DISCUSSION**

In regard to anterior mediastinal masses, the most common etiologies are taught as the "4 Ts": thymoma, thyroid, teratoma, and "terrible" lymphoma. We describe cardiopulmonary arrest in an otherwise healthy young man due to an undiagnosed mediastinal mass. Although the patient regained spontaneous circulation after his airway was secured



**Image 1.** Supine anteroposterior chest radiograph. Asterisk identifies a centrally located opacity that obscures the normal mediastinal anatomy including the trachea, pulmonary vasculature and aortic contour. Black arrows denote bilateral angiocatheters used for decompression of the chest. White arrow identifies the tip of the endotracheal tube at the level of the clavicles. The lungs appear unremarkable.



**Image 2.** Axial computed tomography with contrast image of the chest. Contrast within the vessels appears white. A heterogeneously enhancing mass is seen occupying the anterior mediastinum (asterisk). There is significant compression of the trachea (black arrow) at the level of the carina, which is smaller in diameter than the adjacent orogastric tube (black circle). White arrows indicate brachiocephalic, left carotid, and left subclavian vessels just superior to their origins from the aortic arch. The superior vena cava (which should be in the vicinity of the white circle) is conspicuously absent.

by endotracheal intubation, he remained difficult to ventilate due to lower airway compression. Mediastinal mass syndrome can lead to arrest due to compression or obstruction of critical structures, including airway obstruction, as in our patient. Circulatory obstruction leading to obstructive shock is possible due to massive PE, pericardial effusion causing tamponade physiology, direct compression of the heart by the mass, and positional SVC syndrome causing sudden decrease in cardiac venous return.<sup>4</sup> Recognizing central obstruction will allow providers to appropriately manage abnormal respiratory and circulatory physiology.

In the case of the decompensating ventilated patient, providers should first assess for complications arising from mechanical ventilation in a stepwise fashion to aid in decision-making. One popular mnemonic for this approach is “**DOPES**”: **D**islodgement/displacement of the ETT or cuff; **O**bsturbation of the airway or ETT; **P**neumothorax; **E**quipment failure (of the ventilator or tubing); and “**S**tacking” (referring to auto-PEEP or “breath-stacking”).<sup>7</sup> In our patient, ventilation was complicated by lower airway obstruction. Normal airway peak inspiratory pressure values are ideally less than 30 cm H<sub>2</sub>O, but 30-40 is considered acceptable. In our patient, PIP was markedly elevated indicating high resistance to airflow through the tracheobronchial tree, ETT or ventilator tubing which caused ventilatory failure, as opposed to elevated PIP *and* plateau pressures, which would have indicated a lung compliance issue. High PIP in the setting of normal plateau pressures indicates

obstruction and several causes of obstructive physiology must be evaluated. These include the following: kinked ventilator tubing; twisted ETT or ETT partially occluded by blood, mucus, etc.; patient biting ETT; bronchospasm/asthma; and trachea or large bronchus *partial* occlusion by mass or mucus plugging.<sup>8</sup>

Our patient required advancement of the ETT past the obstructed segment, PEEP, and repositioning to maintain adequate ventilation. Review of the literature indicates these and several other interventions may alleviate central airway obstruction. Repositioning the patient from supine to a semi-recumbent or upright position may both relieve compression of the central airway and increase venous return to the right heart, increasing preload.<sup>5,9</sup> In addition, increasing PEEP has also been suggested as a means to artificially stent open the large airways and relieve obstruction while awaiting more definitive management.<sup>10</sup> However, providers must be judicious with increasing the PEEP as it may further reduce venous return to the heart (especially in patients with SVC compression) and/or cause compression of the distal airways secondary to increased intrathoracic pressures.

Passage of a double lumen or wire-reinforced ETT, or placement of an endotracheal stent via bronchoscopy, can also be performed to relieve airway obstruction. Surgical or radiologic removal/debulking of the offending mass may be necessary in the subacute phase of care.<sup>2, 11, 12</sup> If providers are still unable to ventilate due to central airway obstruction, they may consider extracorporeal life support (ECLS). While some authors have argued against ECLS as an intervention given the prolonged time necessary to initiate this intervention and unlikely favorable

outcomes due to hypoxic brain injury,<sup>13</sup> other case reports have indicated that patients have survived their initial cardiac arrest to receive other potentially lifesaving interventions.<sup>4,5,11</sup> It is our opinion that providers should consider ECLS in these patients and consult their institution's ECLS specialists if available, according to their institutional protocols.

In addition to airway compression, patients with large mediastinal masses are also at high risk of SVC syndrome. The literature advocates for obtaining vascular access in the lower extremities such as a femoral central line in cases where the SVC may be severely stenosed or occluded.<sup>3,5,14</sup> In such cases, the distribution and effect of IV drugs such as epinephrine or induction agents may be slowed secondary to said occlusion and limit successful resuscitation, thus making access to the inferior vena cava via the lower extremity vasculature a critical component of successful resuscitation.<sup>10</sup> As noted above, raising the patient to a semi-recumbent or upright position may relieve compression of the SVC by shifting the position of the mass relative to the force of gravity. It may also decrease the size of the mass by decreasing venous congestion within the mass itself. However, patients may require endovascular stenting of the SVC if they continue to experience significant symptoms due to compression, and for this reason, providers should consider consultation with cardiothoracic or vascular surgery depending on institutional protocols.<sup>15</sup>

## CONCLUSION

Cardiac arrest from mediastinal mass syndrome is rare and can be difficult to manage. Effective management of airway obstruction and adequate ventilation depend on stenting the airway to relieve obstruction. In the emergent setting, options are limited, and relieving airway obstruction must be accomplished with available tools, namely endotracheal intubation, patient repositioning, and positive end-expiratory pressure. Specialty consultation may be both helpful and necessary, and providers should consider ECLS in the patients who remain unstable. In patients with high suspicion for SVC syndrome providers should also consider obtaining vascular access in the lower extremities as well as potential specialist consultation for endovascular stenting of the SVC.

Patient consent has been obtained and filed for the publication of this case report.

## REFERENCES

1. Araki T, Nishino M, Gao W, et al. Anterior mediastinal masses in the Framingham Heart Study: prevalence and CT image characteristics. *Eur J Radiol Open*. 2015;2:26-31.
2. Theodore PR. Emergent management of malignancy-related acute airway obstruction. *Emerg Med Clin North Am*. 2009;27(2):231-41.

*Address for Correspondence:* Ian Mallett, MD, University of Washington, Department of Emergency Medicine, Box 359702 325 9th Ave., Seattle, WA 98104-2499. Email: ism20@uw.edu.

*Conflicts of Interest:* By the CPC-EM article submission agreement, all authors are required to disclose all affiliations, funding sources and financial or management relationships that could be perceived as potential sources of bias. The authors disclosed none.

*Copyright:* © 2021 Mallett et al. This is an open access article distributed in accordance with the terms of the Creative Commons Attribution (CC BY 4.0) License. See: <http://creativecommons.org/licenses/by/4.0/>

3. Hon KE, Leung A, Chik K, et al. Critical airway obstruction, superior vena cava syndrome, and spontaneous cardiac arrest in a child with acute leukemia. *Ped Emerg Care*. 2005;21(12):844-6.
4. Vanneman MW, Fikry K, Quraishi SA, Schoenfeld W. A young man with a mediastinal mass and sudden cardiac arrest. *Ann Am Thorac Soc*. 2015;12(8):1235-9.
5. Goh MH, Liu XY, Goh YS. Anterior mediastinal masses: an anaesthetic challenge. *Anaesthesia*. 1999;54(7):670-4.
6. Suominen PK, Kanerva JA, Saliba KJ, et al. Unrecognized mediastinal tumor causing sudden tracheal obstruction and out-of-hospital cardiac arrest. *J Emerg Med*. 2010;38(5):E63-6.
7. Weingart S. From zero to hero: the crashing ventilated patient. 2018. Available at: [https://emcrit.org/wp-content/uploads/2013/08/The-crashing-ventilated-patient\\_EMCritconference.pdf](https://emcrit.org/wp-content/uploads/2013/08/The-crashing-ventilated-patient_EMCritconference.pdf). Accessed June 20, 2019.
8. Nickson C. Alarming high airway pressures. 2019. Available at: <https://litfl.com/alarming-high-pressures>. Accessed June 18, 2019.
9. Ahktar MT, Ridley S, Best CJ. Unusual presentation of acute upper airway obstruction caused by an anterior mediastinal mass. *Brit J Anaes*. 1991;67:632-4.
10. Pullerits J and Holzman R. Anaesthesia for patients with mediastinal masses. *Can J Anaesth*. 1989;36(6):681-8.
11. Huang YL, Yang MC, Huang CH, et al. Rescue of cardiopulmonary collapse in anterior mediastinal tumor: case presentation and review of literature. *Pediatr Emerg Care*. 2010;26(4):296-8.
12. Lee J, Rim YC, In J. An anterior mediastinal mass: delayed airway compression and using a double lumen tube for airway patency. *J Thorac Dis*. 2014;6(6):E99-103.
13. Azher I, Buggy D, Carton E. Should ECPR be attempted following refractory cardiac arrest secondary to airway obstruction by a mediastinal mass? *Acta Anaesth Belg*. 2017;68:39-41.
14. Dubey PK, Tripathi N. Anesthetic considerations in a patient with large anterior mediastinal mass. *J Cardiothorac Vasc Anesth*. 2019;33(4):1073-5.
15. Wilson LD, Detterbeck FC, Yahalom J. Clinical practice. Superior vena cava syndrome with malignant causes. *N Engl J Med*. 2007;356(18):1862-9.

# Rare Complications of Acute Appendicitis: A Case Report

Nicholas Kurtzman, MD  
Jamie Adler, MD  
Andrew Ketterer, MD  
Jason Lewis, MD

Beth Israel Deaconess Medical Center, Department of Emergency Medicine,  
Boston, Massachusetts

Section Editor: Melanie Heniff, MD, JD

Submission history: Submitted August 24, 2020; Revision received October 29, 2020; Accepted November 5, 2020

Electronically published January 16, 2021

Full text available through open access at [http://escholarship.org/uc/uciem\\_cpccem](http://escholarship.org/uc/uciem_cpccem)

DOI: 10.5811/cpcem.2020.11.49601

**Introduction:** Appendicitis is a common disease, and as we have improved in early diagnosis and management of this disease process, late stage complications have become extremely rare, but can have indolent presentations.

**Case Report:** A 37-year-old male with no past medical history presented to the emergency department (ED) with vague abdominal pain as well as 12 days of cyclical fever. He had no significant findings on laboratory workup with the exception of a mild aspartate transaminase and alanine transaminase and relative neutrophilia between outpatient, urgent care, and ultimate ED visit. His ED workup included cross-sectional imaging of his abdomen revealing multiple liver abscesses and septic thrombophlebitis secondary to ruptured appendicitis.

**Conclusion:** Liver abscesses and septic thrombophlebitis are an extremely rare complication of appendicitis that has only been documented twice previously. [Clin Pract Cases Emerg Med. 2021;5(1):66–69.]

**Keywords:** *Complicated appendicitis; liver abscess; septic thrombophlebitis.*

## INTRODUCTION

Appendicitis is a common disease with a lifetime incidence of 8.6% of men and 6.4% of women.<sup>1</sup> While the disease process typically presents with nausea, anorexia and right lower quadrant tenderness, if this initial phase is missed a host of complications may result, including perforation, abscess formation, and peritonitis. We present a case of a patient with multiple liver abscesses as well as septic thrombophlebitis secondary to ruptured appendicitis. This case highlights a rare phenomenon that has not been documented since the mid-1900s. The patient responded well to antibiotics, interventional radiology (IR)-guided drainage, and interval appendectomy.

## CASE REPORT

A 37-year-old male presented to the emergency department (ED) complaining of 12 days of fever with vague abdominal pain in an “L” shape from the right upper quadrant to the bilateral lower quadrants for which he had already

presented to his primary care provider (PCP) and urgent care (UC). Additionally, the patient had a headache at the onset of the illness. He worked as a personal trainer and had not been able to function at his job for about one week due to profound fatigue. His fever was cyclical, occurring approximately every 12 hours and ranging from 101-103.4 degrees Fahrenheit. The patient was initially able to control his fevers with acetaminophen and ibuprofen, but by the time of his ED presentation these therapies failed to achieve effect. He also complained of myalgias. The patient had already had a workup from the PCP and the UC, which were unremarkable with the exception of elevated liver function tests.

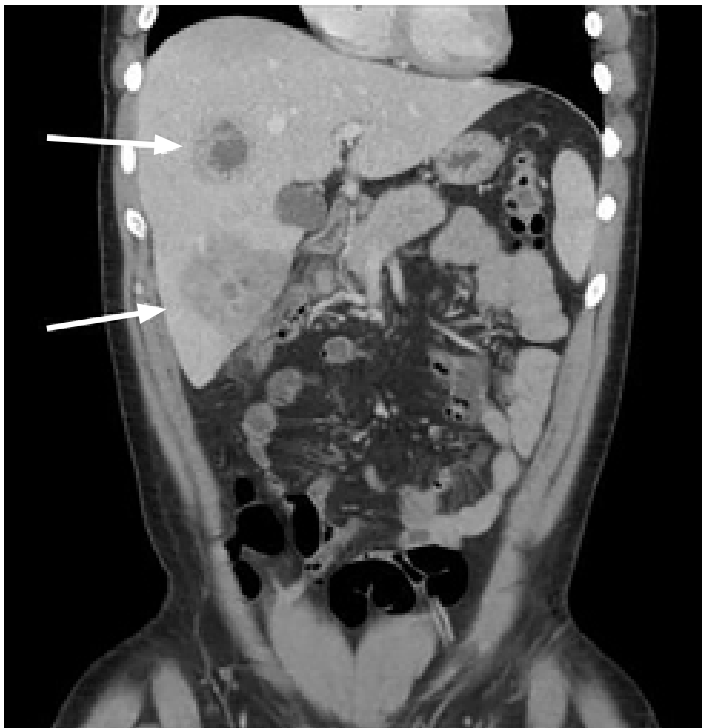At the PCP’s office after three days of fever he had no leukocytosis, no guarding on abdominal exam or abdominal tenderness, and negative testing for Lyme disease, anaplasma, babesia, ehrlichiosis, and influenza. By the time of his UC visit, the patient had been having six days of fevers with a resolution of his initial headache. He had no rash and no guarding on exam, but had diffuse arthralgias. Lab testing

revealed no leukocytosis, and a blood smear for parasites was sent that would eventually result as negative. The patient did have an elevation of his alanine aminotransferase and alkaline phosphatase (ALP).

When he presented to the ED, his initial vital signs showed a blood pressure of 149/80 millimeters mercury, a heart rate of 107 beats per minute, a temperature of 99.2°F, a respiratory rate of 16, and a pulse oximetry reading of 100% on room air. Upon history, the patient had cyclical fevers for the prior 12 days as well as generalized weakness and worsening abdominal discomfort in the right upper quadrant and bilateral lower quadrants. On physical exam, he had intact strength, sensation, and cranial nerve exams, no signs of meningismus, and a non-tender abdomen.

Laboratory values showed a drop in his hemoglobin from 13.3 to 11.0 milligrams per deciliter (mg/dL) (reference range 11.2-15.7 mg/dL), a mild leukocytosis of 12,000 K/uL (4.0-10.0 K/uL) with 84% neutrophils (34-71%) and no bands (0-0.6%), a normal chemistry panel, a lactate of 0.9 millimoles per liter (mmol/L) (0.5-2 mmol/L), an elevated aspartate aminotransferase (AST) of 66 international units per liter (IU/L) (0-40 IU/L), an elevated ALP of 275 IU/L (40-130 IU/L), and a urinalysis showing no evidence of urinary tract infection.

A chest radiograph was negative for signs of pneumonia, after which a computed tomography (CT) of the abdomen and pelvis with intravenous (IV) contrast was obtained, which showed multiple liver abscesses (Image 1), septic



**Image 1.** Coronal computed tomography of the abdomen and pelvis of 37-year-old male with intermittent fever and vague abdominal pain with hepatic abscess (arrows).

### *CPC-EM Capsule*

What do we already know about this clinical entity?

*Appendicitis is common, and frequently identified based on a clear constellation of symptoms and exam findings. It is rare that sequelae of perforated appendicitis are encountered.*

What makes this presentation of disease reportable?

*Appendicitis is not always associated with the classic presentation of right lower quadrant pain, and complications of perforated appendicitis may in fact be the presenting complaint.*

What is the major learning point?

*When patients present with persistent symptoms and no findings by prior workups, it is important to consider atypical presentations of the common pathologies encountered in the emergency department.*

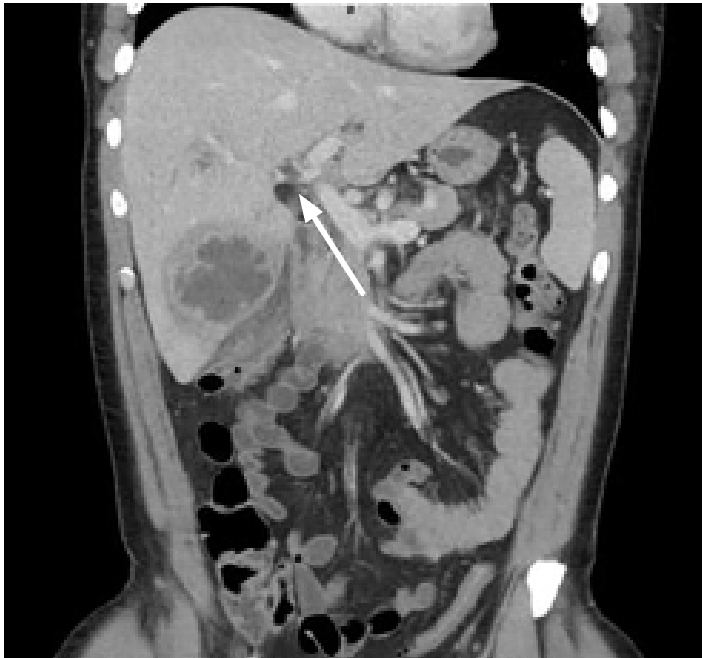
How might this improve emergency medicine practice?

*Highlighting uncommon or atypical presentations is a reminder to be cognizant of anchoring bias.*

thrombophlebitis of the portal system in hepatic segments six and eight (Image 2), and evidence of ruptured appendicitis (Image 3). The patient was initially started on broad spectrum IV antibiotics and within the first 48 hours had IR-guided abscess drainage. Abscess cultures grew out as *Staphylococcus haemolyticus*, which was penicillin sensitive. The patient ultimately underwent an interval appendectomy.

### DISCUSSION

Appendicitis is an extremely common condition affecting 8.6% of males and 6.7% of females, most commonly between ages 10-18 years.<sup>1</sup> More than 250,000 appendectomies are performed per year in the United States.<sup>2</sup> Despite the high prevalence of this condition, the complications suffered by our patient are extremely uncommon. As of the 1950s, cases of septic thrombophlebitis of the portal system occurred in approximately 0.4% of cases of appendicitis.<sup>3</sup> Cases combining liver abscesses and septic thrombophlebitis are even rarer, with only case reports dating back to the 1940s and one other case documented in 2001.<sup>3-5</sup> The 2001 case took six weeks to obtain the definitive diagnosis, which led to further



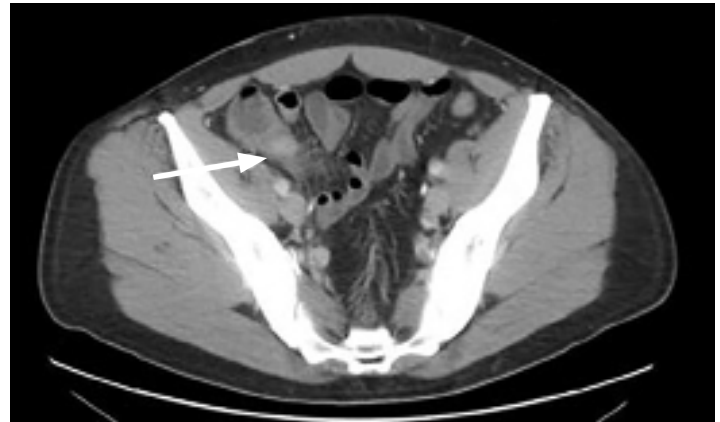
**Image 2.** Coronal computed tomography of the abdomen and pelvis of 37-year-old male with intermittent fever and vague abdominal pain with septic thrombophlebitis (arrow).

complications of ascites, extensive thrombus formation, and spontaneous bacterial peritonitis secondary to *Escherichia coli* and viridans *Streptococci*. Septic phlebitis and hepatic abscesses can have nonspecific clinical findings such as fever, mild peritoneal findings, nausea, vomiting, or abdominal distention, and often come with normal liver function tests and blood cultures.<sup>5</sup> We obtained a CT of the abdomen and pelvis due to the patient's ongoing fever of unknown origin and persistent complaints of abdominal pain and anorexia, despite his benign abdominal exam. The initial expectation was that the patient might have had a malignancy such as lymphoma, given the B symptoms (ie, fevers, night sweats, and weight loss) and lack of a tender abdomen.<sup>6</sup>

While limiting unnecessary CT imaging in younger adults is important,<sup>7</sup> this case shows that CT imaging can have utility in abdominal pain in a non-tender abdomen with persistent fevers and an otherwise unrevealing workup. Even classic right lower quadrant tenderness is only shown to be sensitive between 50-94% of the time.<sup>8-10</sup> If appropriate imaging is not performed, cases of appendicitis can progress to develop complications involving multiple organs as well as septic thrombi. Once the diagnosis of complicated appendicitis is made on cross-sectional imaging, broad spectrum IV antibiotics should be started, and IR and surgery should be consulted for further management and admission.

## CONCLUSION

This case report presents a rare complication of a common disease process that can present in a multitude of



**Image 3.** Transverse computed tomography of the abdomen and pelvis of 37-year-old male with intermittent fever and vague abdominal pain with ruptured appendicitis (arrow).

ways. The patient in question had a broad differential that had been worked up previously as an outpatient with non-specific laboratory findings. His only lab abnormalities were AST and ALP elevation and higher-than-normal percentage of neutrophils. Upon presentation to the ED, his vital signs including tachycardia and persistent fever of unknown origin led the clinical team to believe there was underlying pathology that needed additional workup despite his overall well appearance. While the combination of liver abscesses and septic thrombophlebitis is a rare complication of appendicitis, this case demonstrates how appendicitis can mimic other disease states with non-specific signs and symptoms, and diagnosis can be consequently delayed leading to downstream complications.

The authors attest that their institution requires neither Institutional Review Board approval, nor patient consent for publication of this case report. Documentation on file.

*Address for Correspondence:* Nicholas Kurtzman, MD, Beth Israel Deaconess Medical Center, Department of Emergency Medicine, Rosenberg Building 2, Boston, MA 02215. Email: nkurtzma@bidmc.harvard.edu.

*Conflicts of Interest:* By the *CPC-EM* article submission agreement, all authors are required to disclose all affiliations, funding sources and financial or management relationships that could be perceived as potential sources of bias. The authors disclosed none.

*Copyright:* © 2021 Kurtzman et al. This is an open access article distributed in accordance with the terms of the Creative Commons Attribution ([CC BY 4.0](http://creativecommons.org/licenses/by/4.0/)) License. See: <http://creativecommons.org/licenses/by/4.0/>

## REFERENCES

1. Addiss DG, Shaffer N, Fowler BS, et al. The epidemiology of appendicitis and appendectomy in the United States. *Am J Epidemiol.* 1990;132(5):910-25.
2. Owings MF and Kozak LJ. Ambulatory and inpatient procedures in the United States, 1996. *Vital Health Stat 13.* 1998;(139):1-119.
3. Milliken NT and Stryker HB Jr. Suppurative pylethrombophlebitis and multiple liver abscesses following acute appendicitis; report of a case with recovery. *N Engl J Med.* 1951;244(2):52-4.
4. Soro Y. Pylephlebitis and liver abscesses due to appendicitis. *J Int Coll Surg.* 1948;11(5):464-8.
5. Chang TN, Tang L, Keller K, et al. Pylephlebitis, portal-mesenteric thrombosis, and multiple liver abscesses owing to perforated appendicitis. *J Pediatr Surg.* 2001;36(9):E19.
6. Baris D and Zahm SH. Epidemiology of lymphomas. *Curr Opin Oncol.* 2000;12(5):383-94.
7. Smith-Bindman R, Lipson J, Marcus R, et al. Radiation dose associated with common computed tomography examinations and the associated lifetime attributable risk of cancer. *Arch Intern Med.* 2009;169(22):2078-86.
8. Golledge J, Toms AP, Franklin IJ, et al. Assessment of peritonism in appendicitis. *Ann R Coll Surg Engl.* 1996;78(1):11-4.
9. Andersson RE, Hugander AP, Ghazi SH, et al. Diagnostic value of disease history, clinical presentation, and inflammatory parameters of appendicitis. *World J Surg.* 1999;23(2):133-40.
10. Lane R and Grabham J. A useful sign for the diagnosis of peritoneal irritation in the right iliac fossa. *Ann R Coll Surg Engl.* 1997;79(2):128-9.

# Mediastinitis Secondary to Peripherally Inserted Central Catheter Migration and Perforation after Minor Trauma: A Case Report

Oswaldo Martinez, DO  
Justin Puller, MD

University of Pittsburgh Medical Center, Hamot, Department of Emergency Medicine,  
Erie, Pennsylvania

Section Editor: Christopher Sampson, MD

Submission history: Submitted August 2, 2020; Revision received November 13, 2020; Accepted November 11, 2020

Electronically published January 27, 2021

Full text available through open access at [http://escholarship.org/uc/uciem\\_cpchem](http://escholarship.org/uc/uciem_cpchem)

DOI: 10.5811/cpchem.2020.11.49408

**Introduction:** The use of peripherally inserted central catheters (PICC) has been integral to the advancement of medical care in both in-patient and out-patient arenas.<sup>1</sup> However, our knowledge of PICC line complications remains incomplete, particularly in regard to venous perforation and extraluminal migration. Utilization of displaced catheters harbors lethal complications and is an infrequently reported phenomenon, with traumatic etiologies only referenced as possible mechanisms; however, to date no formal cases have been reported.<sup>5,6</sup>

**Case Report:** We report a case of a fall associated with extraluminal PICC migration and perforation causing mediastinitis and severe sepsis after total parenteral nutrition (TPN) infusion in a 54-year-old woman. Our patient required a right-sided PICC for long-term home TPN due to severe malnutrition following gastric bypass surgery. During a routine home care visit our patient was found tachypneic, hypoxic, and short of breath. Computed topography imaging in the emergency department (ED) identified the injury, likely related to the recent fall. The patient experienced a complicated hospital course after removal of the PICC. Although rare, PICC line migrations and perforations cause serious complications that should be considered by emergency physicians evaluating patients with chronic indwelling vascular access.

**Conclusion:** Given the efficacy and widespread use of PICC lines, we present this case as a rarely reported but life-threatening complication that requires particular attention. Emergency physicians should be aware of such PICC line complications when encountering patients with chronic indwelling vascular access. [Clin Pract Cases Emerg Med. 2021;5(1):70–74.]

**Keywords:** *Peripherally inserted central catheter; catheter migration; catheter perforation; mediastinitis.*

---

## INTRODUCTION

Peripherally inserted central catheters (PICC) have played an integral role to the advancement of medical care in both the in-patient and out-patient arenas.<sup>1</sup> Prolonged therapies that traditionally required hospitalization, such as total parenteral nutrition (TPN), chemotherapy, and extended courses of antibiotics, can now be administered in outpatient facilities or in the home setting via PICC lines, providing convenience to patients and cost savings both to patients and hospitals.

Peripherally inserted central catheters are placed with ultrasound guidance by a dedicated intravascular team or under

fluoroscopy by an interventional radiologist into the large vessels of the upper arm: the cephalic, basilic, or brachial veins. Optimal tip location is considered to be at the lower one-third of the superior vena cava or cavoatrial junction.

Peripherally inserted central catheters lines are generally well tolerated, although complications requiring prompt treatment can arise. Commonly cited frequencies of complications include deep vein thrombosis (30.6%),<sup>2</sup> phlebitis (4-21%),<sup>3</sup> catheter-related infections (3-5.7%),<sup>3</sup> and late tip migration (1.5%).<sup>3</sup> Tip migration, although uncommon, has been reported to occur within the first few days or months

after insertion<sup>3</sup> and is a major risk factor for PICC-related venous thrombosis.<sup>4</sup>

Venous perforation secondary to tip migration is a rare phenomenon that harbors potentially lethal complications. The frequency of PICC line perforations as a result of migration is not known, as few cases have been reported in the literature.<sup>5,7,13,14</sup> Traumatic PICC line migrations and perforations are a particularly unusual entity, and to date there have been no reported cases. This report details a ground-level fall as the likely cause of PICC line migration and perforation, with resulting mediastinitis and severe sepsis.

## CASE REPORT

A 54-year-old woman with a right-sided PICC line placed in November 2015 presented to the emergency department (ED) two months later for evaluation of neck pain and hypoxia. She reported a history of Roux-en-Y gastric bypass in 2007 and revision in 2011 for recurrent marginal ulcers that required long-term TPN through a PICC secondary to severe caloric malnutrition. A visiting home health nurse found the patient short of breath, and hypoxic with oxygen saturations in the 70s percentile on room air. The patient's daughter reported an unwitnessed, ground-level fall three days prior.

Upon initial ED evaluation, patient vital signs were as follows: temperature of 36.4° Celsius, blood pressure of 79/54 millimeters of mercury, heart rate of 136 beats per minute, respiratory rate of 18 breaths per minute, and oxygen saturation of 89% on room air requiring two liters of supplemental oxygen via nasal cannula. Physical examination demonstrated a moderately sized, tender mass to the lower right anterolateral neck, just superior to the clavicle with mild overlying erythema and tenderness along the right trapezius muscle. Radiograph of her chest identified bilateral pleural effusions, with suboptimal location of the PICC line along the proximal right clavicle, several centimeters from the cavoatrial junction (Image 1).

Computed tomography (CT) of the thorax identified a significant amount of gas and fluid collections located in the soft tissues of the right side of the neck with extension into the mediastinum (Image 2).

Bilateral pleural effusions were re-demonstrated from chest radiograph, and the tip of the patient's right PICC line was found to have perforated the right innominate vein, terminating extraluminal in the right upper mediastinum (Image 3). A non-occlusive thrombus was also found at the confluence of the right innominate vein.

Laboratory work returned remarkable for evidence of severe sepsis with a leukopenia of 3.9 white blood cells x 10<sup>9</sup>/liters (L) (normal range: 4.5 – 11 x 10<sup>9</sup>/L) and a lactic acidosis of 4.1 millimoles (mmol)/L (0.5-1 mmol/L) requiring aggressive volume resuscitation and broad-spectrum antibiotics with piperacillin/ tazobactam. Blood cultures were drawn and pending upon admission eventually growing *Staphylococcus Epidermidis* and *Staphylococcus Hominis*.

### CPC-EM Capsule

What do we already know about this clinical entity?

*Out-patient use of peripherally inserted central catheters (PICC) is increasing due to convenience and safety profile but can harbor life-threatening complications.*

What makes this presentation of disease reportable?

*This is the first reported case of venous perforation due to traumatic migration of a PICC line in an out-patient setting causing severe morbidity.*

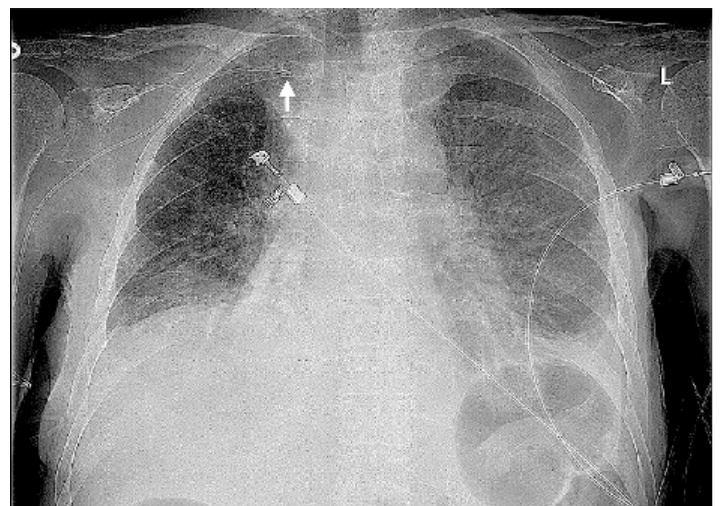
What is the major learning point?

*Emergency physicians should be familiar with both the common and rare highly morbid complications of PICC lines in patients with chronic indwelling vascular access.*

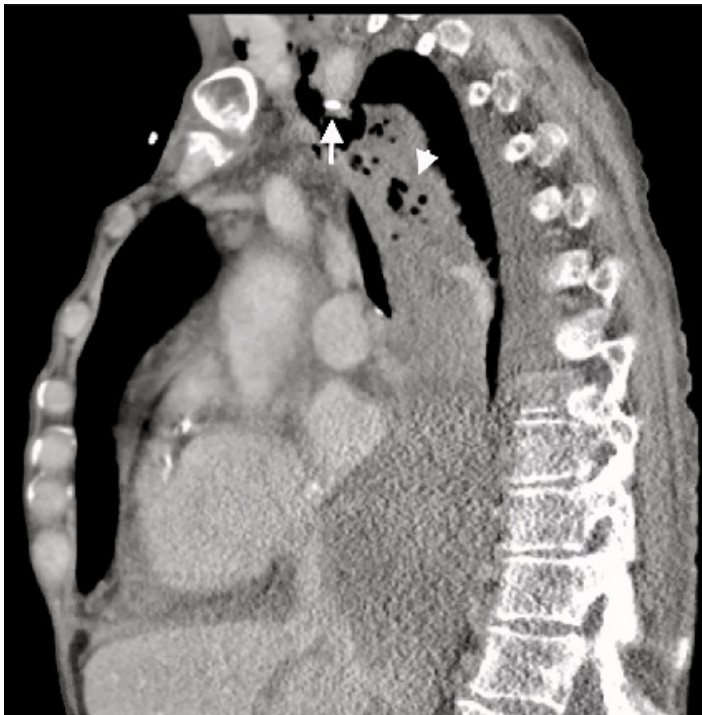How might this improve emergency medicine practice?

*Differentials in patients with PICC lines should broaden to include mechanical and physiologic complications, with lower thresholds for advanced imaging and laboratory evaluation.*

The patient did not require vasopressor medications during her ED course. She was transferred to the medical intensive care



**Image 1.** Radiograph identifying migrated, right-sided peripherally inserted central catheter with tip in proximal right subclavian vein (arrow) with bilateral pleural effusions.



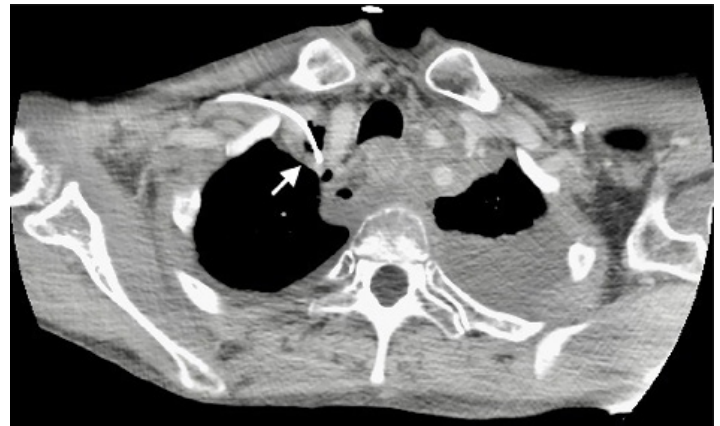
**Image 2.** Sagittal computed tomography of the thorax demonstrating gas and fluid collections in posterior mediastinum (arrowhead) with peripherally inserted central catheter tip (arrow) terminating extraluminally in superior mediastinum.

unit for further management of severe sepsis with bacteremia, mediastinitis, and pleural effusions.

Following admission, cardiovascular-thoracic surgery consult deemed the patient a poor candidate for mediastinal debridement given her profound malnutrition and she was treated medically with an extended course of vancomycin. The PICC line was removed and initial left-sided pleurocentesis was described as a yellow, turbid pleural fluid without odor, similar in appearance to TPN or tube feeds. The mechanism by which TPN extravasation was greater on the left hemithorax than right remains unclear. Our patient required serial pleurocenteses during the course of a complicated 18-day hospitalization, and she was ultimately discharged to a skilled nursing facility with gastrostomy tube placement scheduled 12 days later. At the time of writing this report, the patient continued to experience extreme weight loss and complications from her prior gastric bypasses.

## DISCUSSION

Given the breadth of applications and safety profile, PICC lines are nearly ubiquitous in patients requiring long-term vascular access. Our knowledge of PICC line complications, however, remains incomplete, namely, the frequencies, risk factors, and mortality associated with tip migration and vessel perforation. A search of the literature showed this to be a rarely reported phenomenon,<sup>5,6</sup> and to date there are limited studies detailing the prevalence of migrations or perforations in patients with PICC lines.<sup>7</sup>



**Image 3.** Transverse computed tomography thorax identifying peripherally inserted central catheter line perforation of right innominate vein, located superiorly and extraluminally in right upper mediastinum (arrow) with a large left pleural effusion.

Commonly reported PICC line complications include blood stream infections, occlusion, and thrombosis with tip migration being among the least reported.<sup>8</sup> Catheter migration has been reported on average 43 days after placement<sup>6</sup> with a caudal migration of 2.0 centimeters with abduction and adduction of the arm.<sup>9</sup> Possible mechanisms for tip migration include coughing, vomiting, extreme physical activity, high-pressure infusions, and high-frequency ventilation.<sup>10</sup> One case report proposed altered blood flow from repeated rapid changes in negative intrathoracic pressures and central venous pressures as a mechanism for tip migration in a patient receiving chemotherapy. The patient experienced vigorous coughing and vomiting spells likely resulting in forceful diaphragmatic contraction, alternating blood flow and subsequent tip migration from the superior vena cava to the right internal jugular vein.<sup>11</sup> Other studies mention vessel perforation as a risk with placement of PICCs in the large vessels of the upper arm, asserting such complications are possibly iatrogenic, and caused during initial insertion or erosion after long-term use.

Proposed risk factors of PICC migration and perforation include the PICC line material, orientation, and insertion arm. Fernando et al note softer materials such as silicone or polyurethane likely allow for greater intravascular movement and possible migration but have lower rates of perforations.<sup>14</sup> In contrast, less-compliant polyethylene catheters carry a higher risk of perforation. Malorientation of the migrated PICC line within the vessel is also considered a major risk factor for perforation. PICCs oriented obliquely or perpendicularly following migration are more likely to abut the vessel wall with changes in body positions and over time result in venous perforation.

Some researchers suggest that initial site of insertion may have predilections to vessel-specific migrations. For example,

left-sided PICC line placement is an important risk factor for azygous migration,<sup>12</sup> with an associated 19% complication rate for azygous perforation and resulting mediastinal and pleural effusions of transfused products.<sup>7</sup> Other reported PICC-line vessel migrations include brachiocephalic, subclavian, and internal jugular veins (IJV), but no associations with initial-vessel insertions have been made.

Complications of PICC line migrations with perforations are not only mechanical but also physiologic in nature and carry the potential for high morbidity and mortality. A case report<sup>13</sup> of an 80-year-old female experiencing immediate neck pain after vancomycin infusion through her left-sided PICC line led to a large fluid collection with rightward tracheal deviation, as well as a perforated left IJV. Despite confirmed optimal placement 11 days prior, the PICC line migrated and required removal. She experienced an uncomplicated hospital course thereafter.

Another case describes a fatal cardiac arrest after potassium-enriched solution was infused into the pericardial space via a perforated right-sided PICC, creating a rapidly progressive cardiac tamponade.<sup>8</sup> A pericardial drain was placed, which reversed the patient's hypotension; however, the authors hypothesize the transfused potassium diffused into the pericardium creating a local hyperkalemic state and terminal ventricular fibrillation.<sup>6</sup> This case is particularly important in that it exemplifies a fatal physiologic response to appropriate transfusions in an inappropriate anatomical location. In our case the patient suffered from similar pathology with TPN inadvertently delivered into the mediastinum and pleural space, creating a nidus for bacterial proliferation and severe sepsis.

## CONCLUSION

As illustrated by previous case reports, there are a myriad of proposed mechanisms for and consequences of PICC migration and perforations that harbor lethal potential. Most reported complications were noted to have occurred in-patient, and of iatrogenic causes. Our case report, however, details a unique clinical scenario of a ground-level fall causing a traumatic PICC line migration and perforation of the right innominate vein resulting in mediastinitis. We present this case as a life-threatening PICC line complication that requires particular attention given its high associated mortality, but more importantly the location where the injury occurred. In this case, the patient was reported to have fallen at home with her evaluation initiated in the ED. Thus, emergency physicians need to be aware for the potential of such traumatic PICC line complications to facilitate prompt recognition and treatment when encountering patients with chronic indwelling vascular access.

The authors attest that their institution requires neither Institutional Review Board approval, nor patient consent for publication of this case report. Documentation on file.

*Address for Correspondence:* Justin Puller, MD, University of Pittsburgh Medical Center, Department of Emergency Medicine, 100 State Street, Suite 320, Erie, PA 16507. Email: pullerjp@upmc.edu.

*Conflicts of Interest:* By the CPC-EM article submission agreement, all authors are required to disclose all affiliations, funding sources and financial or management relationships that could be perceived as potential sources of bias. The authors disclosed none.

*Copyright:* © 2021 Martinez et al. This is an open access article distributed in accordance with the terms of the Creative Commons Attribution (CC BY 4.0) License. See: <http://creativecommons.org/licenses/by/4.0/>

## REFERENCES

- Horattas MC, Trupiano J, Hopkins S, et al. Changing concepts in long-term central venous access: catheter selection and cost savings. *Am J Infect Control.* 2001;29(1):32-40.
- Krein SL, Saint S, Trautner BW, et al. Patient-reported complications related to peripherally inserted central catheters: a multicentre prospective cohort study. *BMJ Qual Saf.* 2019;28(7):574-81.
- Amerasekera SS, Jones CM, Patel R, et al. Imaging of the complications of peripherally inserted central venous catheters. *Clin Radiol.* 2009;64(8):832-40.
- Saber W, Moua T, Williams EC, et al. Risk factors for catheter-related thrombosis (CRT) in cancer patients: a patient-level data (IPD) meta-analysis of clinical trials and prospective studies. *J Thromb Haemost.* 2011;9(2):312-9.
- Sposato LA, Yap CH, Powar N, et al. Acute mediastinitis secondary to venous perforation by a peripherally inserted central venous catheter. *J Cardiothorac Vasc Anesth.* 2009;23(5):672-4.
- Orme RM, McSwiney MM, Chamberlain-Webber RF. Fatal cardiac tamponade as a result of a peripherally inserted central venous catheter: a case report and review of the literature. *Br J Anaesth.* 2007;99(3):384-8.
- Bankier AA, Mallek R, Wiesmayr MN, et al. Azygos arch cannulation by central venous catheters: radiographic detection of malposition and subsequent complications. *J Thorac Imaging.* 1997;12(1):64-9.
- Seckold T, Walker S, Dwyer T. A comparison of silicone and polyurethane PICC lines and postinsertion complication rates: a systematic review. *J Vasc Access.* 2015;16(3):167-77.
- Forauer AR and Alonzo M. Change in peripherally inserted central catheter tip position with abduction and adduction of the upper extremity. *J Vasc Interv Radiol.* 2000;11(10):1315-8.
- Beccaria P, Silvetti S, Mucci M, et al. Contributing factors for a late spontaneous peripherally inserted central catheter migration: a case report and review of literature. *J Vasc Access.* 2015;16(3):178-82.
- Wang K, Sun W, Shi X. Upper extremity deep vein thrombosis after migration of peripherally inserted central catheter (PICC): A case

- report. *Medicine (Baltimore)*. 2017;96(51):e9222.
12. Haygood TM, Malhotra K, Ng C. Migration of central lines from the superior vena cava to the azygous vein. *Clin Radiol*. 2012;67(1):49-54.
  13. Oliver JJ, Connor RE, Powell JR, et al. Delayed migration and perforation of the jugular vein by a peripherally inserted central catheter. *Clin Pract Cases Emerg Med*. 2017;1(4):384-6.
  14. Fernando R, Lee YJ, Khan N, et al. Delayed migration of a peripherally inserted central venous catheter to the azygos vein with subsequent perforation. *BJR Case Rep*. 2016;2(2):20150315.

# A Case Report of Ring Avulsion Injury: Under-recognized for Its Unique Implications in Transfer

Amanda Horn, MD\*  
Brian Freniere, MD†  
Alexander Y. Sheng, MD, MHPE\*‡

\*Boston Medical Center, Department of Emergency Medicine, Boston, Massachusetts  
†Lahey Hospital and Medical Center, Department of Plastic Surgery, Burlington, Massachusetts  
‡Boston University School of Medicine, Boston, Massachusetts

Section Editor: Austin Smith, MD

Submission history: Submitted September 17, 2020; Revision received November 11, 2020; Accepted November 19, 2020

Electronically published January 16, 2021

Full text available through open access at [http://escholarship.org/uc/uciem\\_cpccm](http://escholarship.org/uc/uciem_cpccm)

DOI: 10.5811/cpcem.2020.11.49917

**Introduction:** Ring avulsion injuries consist of a characteristic injury pattern resulting from sudden intense force pulling on a finger ring. While ring avulsion injury is a known entity in the hand surgery literature, there is scant description of the injury pattern in emergency medicine, much less its management and transfer implications in the emergency department (ED).

**Case Report:** This is a report of a patient presenting to the ED with ring avulsion injury after a workplace accident, initially transferred to a tertiary care hospital with general hand surgery, who then required a second transfer for consideration of microsurgical revascularization.

**Conclusion:** In addition to fully assessing the degree of injury, including neurovascular and tendon involvement, emergency physicians must recognize cases of severe ring avulsion injuries without complete amputation as potential opportunities for microsurgical revascularization. [Clin Pract Cases Emerg Med. 2021;5(1):75–78.]

**Keywords:** *Ring avulsion injury; traumatic amputation; microsurgery; revascularization; digital replantation.*

---

## INTRODUCTION

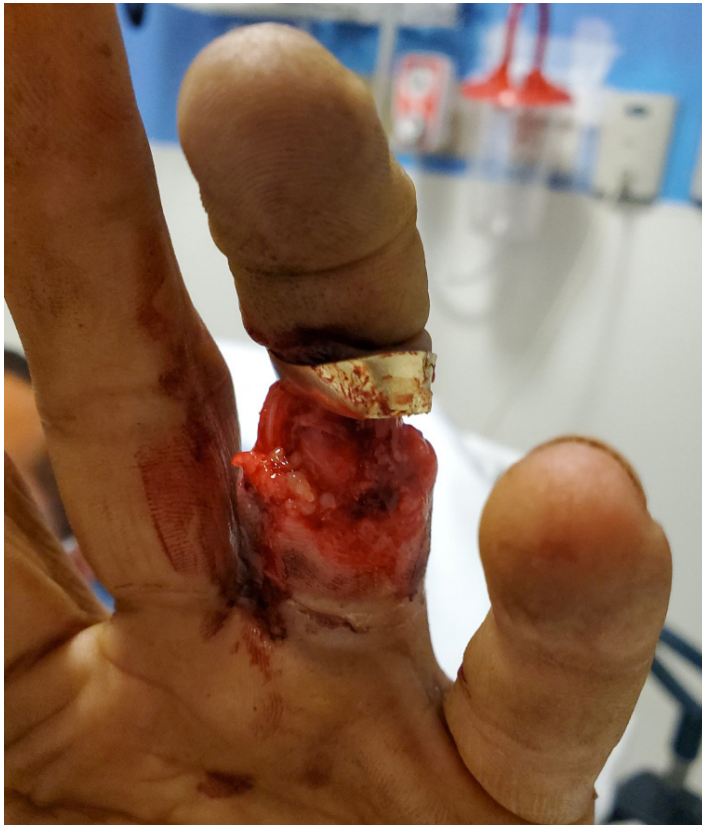Ring avulsion injuries comprise a distinctive injury pattern that results from a sudden intense force on a ring attached to a finger. These injuries range in severity from circumferential tissue laceration to complete digital amputation.<sup>1</sup> While the management of the latter is often clear-cut, treatment and disposition of ring avulsion injuries in the absence of complete amputation is more complex. As there is a paucity of emergency medicine literature with regard to ring avulsion injuries, failure of emergency physicians (EP) to recognize severe ring avulsion injuries as opportunities for microsurgical revascularization can lead to significant long-term morbidity and loss of function.<sup>2</sup> In this case report, we discuss the presentation, early recognition, management, and transfer implications of ring avulsion injuries aimed at optimizing long-term functional outcomes.

## CASE REPORT

A 41-year-old-male, left-hand dominant, heavy machine operator, presented to a local community emergency

department (ED) with an injury to his left ring finger after his wedding band was caught in machinery. He sustained a circumferential degloving injury to his left fourth digit, just distal to the proximal interphalangeal joint (PIP). The patient was given intravenous hydromorphone, cefazolin, and tetanus prior to transfer to a tertiary care hospital for orthopedic evaluation. The case was discussed between the transferring and accepting EPs, and disposition was deemed acceptable to both parties.

Upon arrival to the tertiary care hospital ED, examination revealed a complicated ring avulsion injury with complete tendon and neurovascular disruption with exposed intact bone and distal ischemic tissue attached at the distal interphalangeal joint (DIP) (Images 1 and 2). The wedding band was deformed but still affixed to the distal soft tissue. Radiographs showed no signs of fracture. The EP contacted in-house orthopedic hand surgery. Having recognized the degree of neurovascular compromise and potential need for replantation, the EP concurrently initiated



**Image 1.** Volar view of a severe degloving ring avulsion injury.

contact with hand surgery at another tertiary care hospital with microsurgical revascularization capabilities.

In a phone discussion between the EP and the in-house orthopedic hand surgeon, both parties agreed that further management should be guided by responding microsurgical revascularization specialists at the neighboring institution. After extensive discussion with the outside hand surgeon, as well as shared decision-making with the patient and family, the decision was made to transfer to a tertiary care hospital with microsurgical revascularization capabilities. Removal of the ring at this juncture was deemed unnecessary given the complete degloving of the soft tissues down to bone with complete disruption of neurovascular bundles and the clear ischemic nature of the distal soft tissues.

In the ED of the third hospital, the ring was removed after digital block to facilitate examination, revealing a central slip complete laceration, transection of both radial and ulnar neurovascular bundles, and PIP and DIP joint dislocations. The distal soft tissues were notably dusky. Given the extensive neurovascular, ligamentous, and tendon damage, as well as prolonged ischemia of distal soft tissues, there was a high likelihood of significant dysfunction even after microsurgical revascularization and aggressive rehabilitation. The decision was made with the patient and family to proceed with amputation, instead of revascularization.

### *CPC-EM Capsule*

What do we already know about this clinical entity?

*Ring avulsion injury consists of a characteristic injury pattern resulting from sudden intense force pulling on a finger ring.*

What makes this presentation of disease reportable?

*While ring avulsion injury is a known entity in the hand surgery literature, there is little to no mention of the injury pattern in emergency medicine.*

What is the major learning point?

*Emergency physicians must recognize cases of severe ring avulsion injuries without complete amputation as potential opportunities for microsurgical revascularization.*

How might this improve emergency medicine practice?

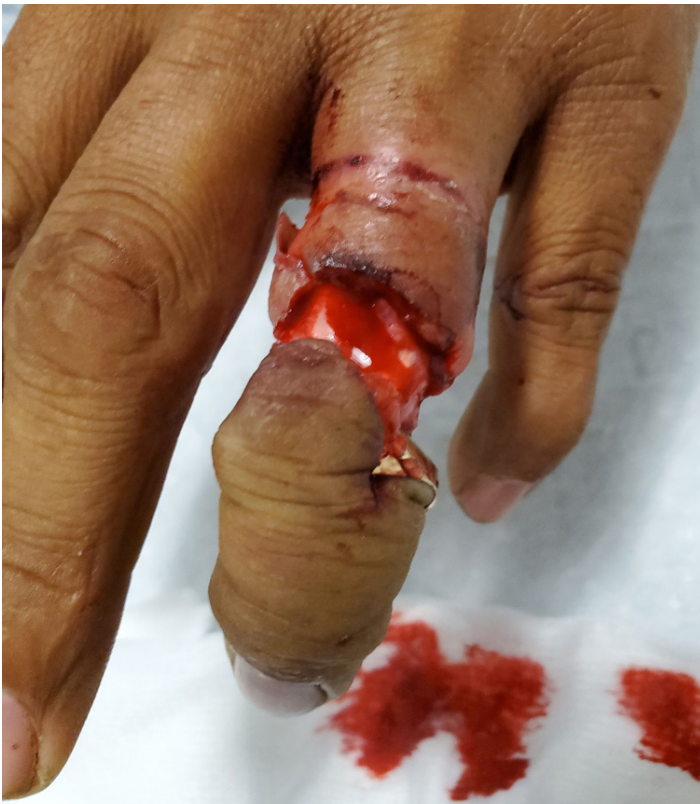*Early recognition and transfer to microsurgical revascularization capable centers can decrease ischemic time of the distal digit and improve functional outcomes.*

## **DISCUSSION**

While uncommon, ring avulsion injuries, when they do occur, will likely present to the ED as the first point of contact. It is crucial that EPs recognize this distinctive injury pattern and its implications for transfer, as failure to do so could result in delayed care and long-term morbidity. Initial management includes hemostasis and analgesia. The EP should ensure that tetanus vaccination is up to date and antibiotics are administered. Plain films can be obtained once the patient has been stabilized but should not delay transfer, if indicated.

A thorough assessment of the extent of damage to the soft tissues, tendons, and neurovascular structures is the critical step. Detailed examination can be facilitated by performing a digital nerve block. Further management is based on the severity and classification of injury. One such classification system based on circulatory status is the Urbaniak classification (Table). Indications to pursue repair is based on the extent of injury and individual patient priorities related to aesthetics and functionality.<sup>3</sup> Lower grading class is associated with better outcomes. Class II or III injuries with questionable perfusion necessitates emergent transfer to a microsurgery-capable hand center.<sup>4</sup>

Amputation was previously the gold standard for class III ring avulsion injuries. However, microvascular surgery has



**Image 2.** Dorsal view of a severe degloving ring avulsion injury.

made revascularization and replantation of higher degree injuries possible, resulting in superior functionality outcomes, measured as long-term sensibility and range of motion, compared to amputation.<sup>5</sup>

Discussion of these injuries should ideally be with a hand surgeon capable of microsurgical revascularization as soon as possible. Depending on injury severity, patient preferences, and local institutional resources, prompt transfer to a tertiary or quaternary care center with microsurgery capabilities must be considered.<sup>6</sup> Severe ring avulsion injuries with intact bone should essentially be considered a traumatic amputation in terms of indications for transfer. When consulting a hand surgeon, it is useful to communicate the level of injury and the circulatory status of the distal digit. This may be facilitated by use of a Doppler probe or pulse oximeter.<sup>7</sup> In addition, the EP should discuss whether ring removal is indicated prior to transfer as less severe injuries may still suffer from distal ischemia due to compression by a deformed ring. Factors influencing the decision to remove the ring include potential damage to surrounding structures during removal, availability of adequate ring cutter at referring institution, and possibility of delay in transfer as a result.

Although other factors are associated with survival rate of digital replantation in cases of traumatic amputations (eg, age, injury mechanism, amputated finger, length of surgery, postoperative complications, and re-intervention requirement),<sup>8,9</sup> preserving the amputated fingers in a specimen bag filled with ice

**Table.** Urbaniak classification for microvascular management of ring avulsion injuries.<sup>3</sup>

Class	Circulation	Management
I	Adequate	Treat bone and soft tissue injury
II	Inadequate	Repair vessels
III	Complete amputation or degloving	Revascularization considered; may limit functionality

and reducing perioperative ischemic time are important elements on which EPs can exert some control. While case reports have described successful digital replantation for traumatic amputation after prolonged periods of warm ischemia,<sup>10</sup> ischemic time greater than 6-12 hours is considered deleterious and expeditious door-to-surgery time of less than 180 minutes is associated with better outcomes.<sup>11</sup> Given that ring avulsion injuries do not result in complete amputations, warm ischemia can quickly ensue. Thus, prompt transfer must be considered.

It remains unclear in this case whether earlier recognition for this characteristic injury pattern and its indications for potential microsurgical revascularization would have affected the eventual outcome. Nevertheless, better awareness of ring avulsion injury and its management could have prevented the additional transfer, thus decreasing the ischemic time of the distal digit.

## CONCLUSION

A thorough evaluation of ring avulsion injuries is critical to identify neurovascular and tendon injuries that require specialized care. Once this distinct injury pattern is recognized, EPs must be aware of the potential need for timely transfer to a microsurgery-capable institution rather than a general hand surgery center to optimize long-term patient outcomes.

Patient consent has been obtained and filed for the publication of this case report.

*Address for Correspondence:* Alexander Y. Sheng MD, MHPE, Boston Medical Center, Department of Emergency Medicine, 800 Harrison Avenue, BCD Building, 1<sup>st</sup> Fl, Boston, MA 02118. Email: shenga@bu.edu.

*Conflicts of Interest:* By the CPC-EM article submission agreement, all authors are required to disclose all affiliations, funding sources and financial or management relationships that could be perceived as potential sources of bias. The authors disclosed none.

*Copyright:* © 2021 Horn et al. This is an open access article distributed in accordance with the terms of the Creative Commons Attribution (CC BY 4.0) License. See: <http://creativecommons.org/licenses/by/4.0/>

## REFERENCES

1. Bamba R, Malhotra G, Bueno RA, et al. Ring avulsion injuries: a systematic review. *Hand*. 2018;13(1):15-22.
2. Davis Sears E and Chung KC. Replantation of finger avulsion injuries: a systematic review of survival and functional outcomes. *J Hand Surg Am*. 2011;36(4):686-94.
3. Urbaniak JR, Evans JP, Bright DS. Microvascular management of ring avulsion injuries. *J Hand Surg Am*. 1981;6(1):25-30.
4. Nissenbaum M. Class IIA ring avulsion injuries: an absolute indication for microvascular repair. *J Hand Surg Am*. 1984;9(6):810-5.
5. Kay S, Wertz J, Wolff TW. Ring avulsion injuries: classification and prognosis. *J Hand Surg Am*. 1989;14(2 PART 1):204-13.
6. Brooks D, Buntic RF, Kind GM, et al. Ring avulsion: injury pattern, treatment, and outcome. *Clin Plast Surg*. 2007;34(2):187-95.
7. Tarabdkar N, Iorio ML, Gundle K, et al. The use of pulse oximetry for objective quantification of vascular injuries in the hand. *Plast Reconstr Surg*. 2015;136(6):1227-33.
8. Yu H, Wei L, Liang B, et al. Nonsurgical factors of digital replantation and survival rate: a metaanalysis. *Indian J Orthop*. 2015;49(3):265-71.
9. Tejedor Navarro A, Vendrell Jordà M, Puente Alonso C. Digital replantation/revascularization: predictive factors to microsurgery success-a single-center study. *Eur J Trauma Emerg Surg*. 2019. In press.
10. Baek SM, Kim SS, Tsai TM, et al. Successful digital replantation after 42 hours of warm ischemia. *J Reconstr Microsurg*. 1992;8(6):455-9.

# Recurrent Bell's Palsy During Takeoff on a Commercial Flight: A Case Report

Gayle Galletta, MD

University of Massachusetts, Department of Emergency Medicine, Worcester, Massachusetts

Section Editor: Austin Smith, MD

Submission history: Submitted October 19, 2020; Revision received December 10, 2020; Accepted December 10, 2020

Electronically published January 16, 2021

Full text available through open access at [http://escholarship.org/uc/uciem\\_cpem](http://escholarship.org/uc/uciem_cpem)

DOI: 10.5811/cpcem.2020.12.50340

**Introduction:** Unilateral facial weakness is a concerning symptom, particularly in a resources poor setting. Distinguishing between peripheral and central causes is critical to the evaluation, treatment, and prognosis.

**Case report:** An unusual case of recurrent, transient Bell's palsy occurring during ascent in a commercial airplane is presented.

**Conclusion:** Emergency physicians should be aware of the possibility of barotrauma to the facial nerve (cranial nerve VII) during flights because accurately diagnosing this condition can prevent costly aircraft diversion, calm the passenger's anxiety, and forgo an expensive medical workup. [Clin Pract Cases Emerg Med. 2021;5(1):79–81.]

**Keywords:** *Case report; recurrent Bell's palsy; transient facial nerve palsy; in-flight emergency; altitude.*

---

## INTRODUCTION

Unilateral facial paralysis may have a central or peripheral etiology. It is important to differentiate between the two because the workup, treatment, and prognosis differ. Transient facial paralysis from peripheral facial nerve paresis (Bell's palsy) is common, accounting for 60-75% of unilateral facial weakness and has an incidence of 20-30 cases per 100,000 annually.<sup>1</sup> It can occur at any age but is most common in the fifth decade. Males and females are equally affected as is the laterality.<sup>2</sup> Most cases of Bell's palsy resolve completely by six months. Bell's palsy has been associated with diabetes, hypertension, pregnancy, Lyme disease, herpes simplex type 1 infection, sarcoidosis, and with the inactivated intranasal influenza vaccine.<sup>3</sup>

Bell's palsy has also been reported to occur from barotrauma, most commonly scuba diving. Less commonly, barotrauma has also been noted to occur with aviation and ascent to high altitude.<sup>4</sup> Bell's palsy during aviation was first described in 1967.<sup>4</sup> Since that time, several case reports have been published, primarily in the otolaryngology literature.<sup>4-11</sup> Recurrent Bell's palsy is rare, occurring in approximately 7% of cases,<sup>12</sup> and has only been reported three times during flights,<sup>4,6</sup> but these cases were not published in the emergency medicine literature.

## CASE REPORT

A 36-year-old Dutch Caucasian male without significant past medical history developed a right facial paralysis shortly after takeoff during a transatlantic flight that departed from the East Coast of the United States. A flight attendant was notified and subsequently called for a doctor onboard. The passenger was standing in the rear of the aircraft with the flight attendant. His physical examination revealed that he was anxious, but otherwise in no acute distress. He was not diaphoretic. His heart rate and respiratory effort were normal. His pupils were equal, round, and reactive to light. He exhibited a right facial droop that involved the forehead. His cranial nerves were otherwise intact. There was no extremity weakness. Cerebellar functions were intact and his gait was normal. His speech was normal. Other than the facial droop and the anxiety that this caused, the patient had no other complaints. He denied having a headache or ear pain.

Interestingly, the passenger stated that he had an identical episode shortly after take-off four days prior. The flight was diverted back to its originating airport due to concern for a stroke. The passenger was taken to a hospital, evaluated for a stroke, and admitted overnight for observation. He stated that his work-up was completely normal, but he did not recall

whether he had been tested for Lyme disease. He was medically cleared to fly home to Europe on the date of this recurrent episode.

Based on the passenger's physical examination that included paralysis of the forehead muscles, and further reassured by his recent negative work-up for an identical episode, it was apparent that his symptoms were due to a peripheral nerve etiology rather than a stroke, and the flight would be able to continue to its destination as scheduled. In-flight medical control was not contacted. Shortly after reaching cruising altitude, the passenger's symptoms resolved.

## DISCUSSION

The anatomy of the facial nerve and the unilateral facial paralysis associated with its disruption was first described by Sir Charles Bell in 1821.<sup>13</sup> The facial nerve has a primarily motor function and originates in the pons. It travels a long, circuitous route and exits the skull through the internal auditory canal. It then traverses the facial canal adjacent to the middle ear. It has been suggested that temporal bone dehiscence in the tympanic segment of the canal at the oval window can predispose patients to barotrauma of the facial nerve.<sup>14</sup>

Central pathology (stroke, tumor, multiple sclerosis) vs peripheral pathology (Lyme, otitis media, viral, idiopathic) of the facial nerve can often be deduced from the physical exam. Somewhat counterintuitively, a peripheral lesion presents with more extensive facial paralysis that involves the entire hemiface. A central lesion will spare the forehead. This can be explained by the fact that the muscles of the upper face are innervated by the corticobulbar tract bilaterally, whereas the muscles of the lower face are innervated only by the contralateral motor cortex. There are always exceptions, however. Bell's palsy can occasionally occur bilaterally, and a brainstem stroke at the facial nerve nucleus could mimic Bell's palsy.<sup>15</sup>

While the etiology is unclear, it is possible that the passenger described above had a predisposing abnormality such as a dehiscence of the temporal bone in the region of the facial canal where the facial nerve courses near the middle ear. Such an abnormality would subject the nerve to temporary ischemia from barotrauma due to the decreased partial pressure of oxygen at decreasing atmospheric pressure during flight ascent.

## CONCLUSION

Diverting a transatlantic flight can cost upwards of 100,000 US dollars. The cost of flight diversion is greatly variable and depends on the size of the aircraft, the cost of dumping fuel, housing and re-booking passengers, and staffing of flight crew. It is important to be aware of the potential for a benign peripheral facial nerve paralysis from barotrauma during flight. Being able to distinguish this from a central stroke (that may benefit from immediate medical treatment) could prevent costly flight diversion and calm passenger

### *CPC-EM Capsule*

What do we already know about this clinical entity?

*The facial nerve can be sensitive to pressure changes such as scuba diving and aviation, resulting in Bell's Palsy.*

What makes this presentation of disease reportable?

*Only three reports of transient, recurrent facial nerve paralysis from aviation barotrauma have been published: none in the emergency medicine literature.*

What is the major learning point?

*Recurrent Bell's palsy is rare, but can occur in individuals susceptible to changes in ambient pressure.*

How might this improve emergency medicine practice?

*Distinguishing a benign facial palsy from a more serious etiology in a low resource setting, such as during a commercial flight, could prevent costly flight diversion and calm passenger anxiety.*

anxiety. It would also be helpful for the passenger to understand that their facial nerve paralysis may recur on future flights and resolve without intervention.

The author attests that their institution requires neither Institutional Review Board approval, nor patient consent for publication of this case report. Documentation on file.

*Address for Correspondence:* Gayle Galletta, MD, University of Massachusetts, Department of Emergency Medicine, 55 Lake Ave North, Worcester, MA 01545. Email: [gayle.galletta@umassmemorial.org](mailto:gayle.galletta@umassmemorial.org).

*Conflicts of Interest:* By the CPC-EM article submission agreement, all authors are required to disclose all affiliations, funding sources and financial or management relationships that could be perceived as potential sources of bias. The authors disclosed none.

*Copyright:* © 2021 Galletta. This is an open access article distributed in accordance with the terms of the Creative Commons Attribution (CC BY 4.0) License. See: <http://creativecommons.org/licenses/by/4.0/>

## REFERENCES

1. Hauser WA, Karnes WE, Annis J, et al. Incidence and prognosis of Bell's palsy in the population of Rochester, Minnesota. *Mayo Clin Proc.* 1971;46(4):258-64.
2. Gilden DH. Clinical practice. Bell's palsy. *N Engl J Med.* 2004;351(13):1323-31.
3. Mutsch M, Zhou W, Rhodes P, et al. Use of the inactivated intranasal influenza vaccine and the risk of Bell's palsy in Switzerland. *N Engl J Med.* 2004;350(9):896-903.
4. Bennett DR and Liske E. Transient facial paralysis during ascent to altitude. *Neurology.* 1967;17(2):194-8.
5. Motamed M, Pau H, Daudia A, et al. Recurrent facial nerve palsy on flying. *J Laryngol Otol.* 2000;114(9):704-5.
6. Ah-See KL, Shakeel M, Maini SK, et al. Facial paralysis during air travel: case series and literature review. *J Laryngol Otol.* 2012;126(10):1063-5.
7. Grossman A, Ulanovski D, Barenboim E, et al. Facial nerve palsy aboard a commercial aircraft. *Aviat Space Environ Med.* 2004;75(12):1075-6.
8. Silverstein H. Facial paralysis associated with air flight. *Am J Otol.* 1986;7(5):394-5.
9. Krywko DM, Clare DT, Orabi M. Facial baroparesis mimicking stroke. *Clin Pract Cases Emerg Med.* 2018;2(2):136-8.
10. White R and Shackleton D. Plane palsy: a case of transient facial weakness during an aircraft flight. *BMJ Case Rep.* 2018;2018:bcr2018224593.
11. Vivekananda U and Omer S. Transient facial weakness whilst on a flight. *J Neurol Sci.* 2017;375:299-300.
12. Pitts DB, Adour KK, Hilsinger RL Jr. Recurrent Bell's palsy: analysis of 140 patients. *Laryngoscope.* 1988;98(5):535-40.
13. Sajadi MM, Sajadi MR, Tabatabaie SM. The history of facial palsy and spasm: Hippocrates to Razi. *Neurology.* 2011;77(2):174-8.
14. Perez B, Campos ME, Rivero J, et al. Incidence of dehiscences in the Fallopian canal. *Int J Pediatr Otorhinolaryngol.* 1997;40(1):51-60.
15. Agarwal R, Manandhar L, Saluja P. Pontine stroke presenting as isolated facial nerve palsy mimicking Bell's palsy: a case report. *J Med Case Rep.* 2011;5:287.

# Testicular Torsion in Monorchism Diagnosed with Point-of-care Ultrasound: A Case Report

Chad Correa, MD  
So Onishi, MD  
Eric Abrams, MD

Kaiser Permanente San Diego, Department of Emergency Medicine, San Diego, California

Section Editor: Melanie Heniff, MD

Submission history: Submitted July 29, 2020; Revision received December 5, 2020; Accepted December 11, 2020

Electronically published January 22, 2021

Full text available through open access at [http://escholarship.org/uc/uciem\\_cpem](http://escholarship.org/uc/uciem_cpem)

DOI: 10.5811/cpcem.2020.12.48944

**Introduction:** Emergency department physicians should incorporate point-of-care-ultrasound (POCUS) in the assessment of patients presenting with acute scrotal pain for rapid identification of the time sensitive urologic emergency, testicular torsion.

**Case Report:** A 20-year-old otherwise healthy male, with a history of monorchism, presented to the emergency department with vague testicular pain. A POCUS was performed, which demonstrated attenuated arterial flow of the patient's single testicle as well as twisting ("whirlpool sign") of the spermatic cord, both highly specific ultrasonographic findings of testicular torsion.

**Conclusion:** These findings expedited definitive management resulting in the salvage of the single ischemic testicle. [Clin Pract Cases Emerg Med. 2021;5(1):82–84.]

**Keywords:** *Testicular torsion; point-of-care ultrasound; testicular ultrasound.*

## INTRODUCTION

Scrotal and testicular complaints comprise at least 0.5% of all emergency department (ED) visits. Of the various etiologies of testicular discomfort, only testicular torsion is seen as a true, time-sensitive urologic emergency.<sup>1</sup> Testicular torsion occurs when a testicle twists around the spermatic cord, resulting in compromised blood flow to the testicle and resultant downstream tissue ischemia.<sup>1</sup> The extent of testicular rotation has also been directly correlated with the time to testicular necrosis and, therefore, the probability of salvage.<sup>2</sup> The incidence of testicular torsion is 3.8 in 100,000 males up to the age of 18. It often occurs during sleep and in the absence of trauma.<sup>3</sup>

The congenital absence of one testes, monorchism, is considered rare.<sup>4</sup> To have monorchism and torsion of the single viable testicle is not only extremely uncommon, but exceedingly more urgent as necrosis would result in long-term sequelae including infertility. With the recent incorporation of point-of-care ultrasound (POCUS) as a core competency in the emergency medicine training curriculum,<sup>5</sup> POCUS has now become a standard tool in the emergency physician's

repertoire. Additionally, since ultrasound is the ideal imaging modality to evaluate the scrotum and its contents,<sup>6</sup> emergency physicians should include POCUS in the workup for the time-sensitive diagnosis of testicular torsion, especially in resource-poor settings.

## CASE REPORT

A 20-year-old male with a past medical history of monorchism presented to the ED with one hour of sudden onset, cramping-like, progressively worsening, 10 out of 10 testicular pain that woke him from sleep. The pain had been present for approximately four hours. He denied any trauma, dysuria, or concerning sexual history. When questioned on the medical history of his single testis, he reported having only one testicle from birth, without understanding the etiology or ever having been evaluated for it.

His vital signs upon presentation demonstrated a heart rate of 79 beats per minute, systolic blood pressure of 145 millimeters mercury, respirations of 18 breaths per minute, oxygen saturation of 99% on room air, and an oral temperature of 97.7° Fahrenheit. Physical exam

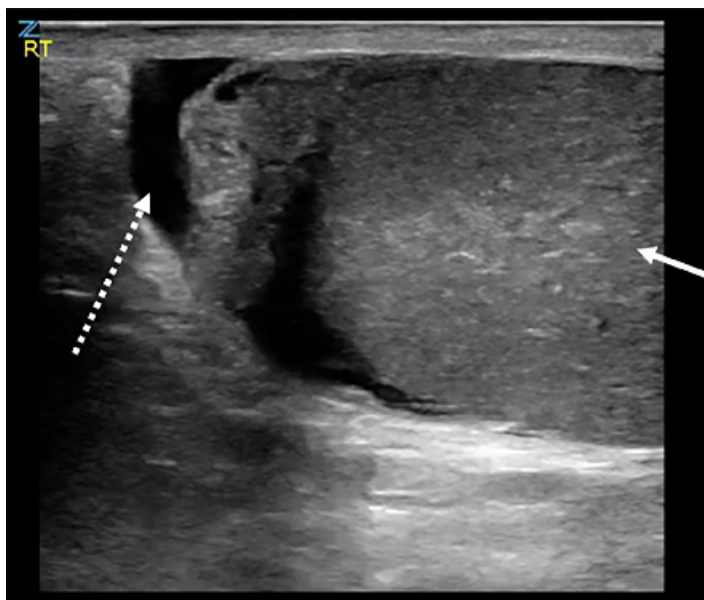
demonstrated a single, firm, edematous testicle with a horizontal lie that was significantly tender to palpation. There was also a tender, firm spermatic cord. There was no surrounding scrotal edema. His abdomen was soft and nontender, and there was no evidence of inguinal hernia. A point-of-care ultrasound was performed, which demonstrated a heterogenous, single right testicle located within a surrounding simple hydrocele (Image 1). The testicle had limited, non-pulsatile flow on spectral Doppler ultrasound (Image 2).

The epididymis appeared unremarkable. The spermatic cord was identified, and when tracked proximally had an abrupt change in its course with a spiral twist in the scrotal sac, referred to as the “whirlpool sign” (Image 3).

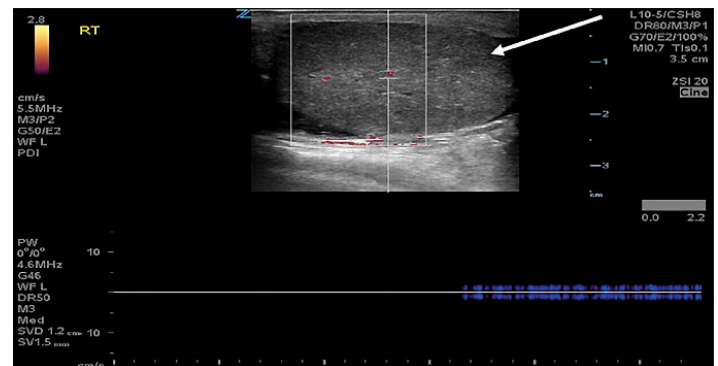
Unfortunately, since the patient had a history of monorchism there was no contralateral testicle for comparison of vascular flow or echotexture. Given the patient’s complaint, exam, and sonographic findings, a diagnosis of testicular torsion was made. Urology was emergently consulted, and the patient was scheduled for immediate surgery. A formal comprehensive ultrasound was performed pending the consultant arrival, which reiterated findings described in the POCUS. The patient was taken to the operating room and had a successful detorsion and orchidopexy, and was ultimately discharged home. Outpatient follow-up evaluation performed by urology five weeks after surgery demonstrated a preserved, single viable testicle.

## DISCUSSION

Ultrasound is the imaging modality of choice for the diagnosis of testicular torsion. A definitive sign, as observed in this case, is twisting of the spermatic cord, also called the “whirlpool sign.”<sup>7</sup> The whirlpool sign is a reliable and direct



**Image 1.** Point-of-care ultrasound demonstrating heterogenous testicle (solid arrow) with simple hydrocele (dashed arrow).



**Image 2.** Point-of-care ultrasound demonstrating heterogenous testicle (arrow) with limited, attenuated arterial flow on spectral Doppler.

### CPC-EM Capsule

What do we already know about this clinical entity?

*Testicular torsion is a time sensitive emergency.*

What makes this presentation of disease reportable?

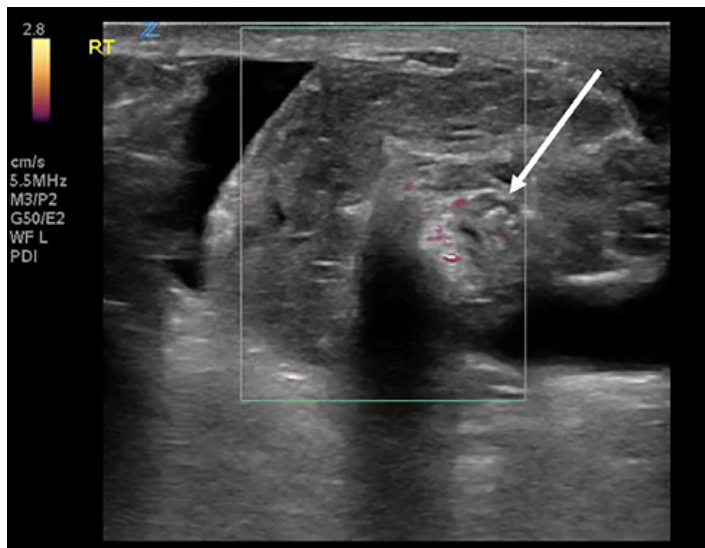
*The use of point-of-care ultrasound to expedite definitive management of torsion in a patient with one viable testicle to preserve fertility.*

What is the major learning point?

*Point-of-care ultrasound can help confirm testicular torsion rapidly at the bedside.*

How might this improve emergency medicine practice?

*Point-of-care ultrasound should be utilized in patients who present with acute testicular pain to facilitate earlier diagnosis, surgical consultation, and definitive management.*



**Image 3.** Point-of-care ultrasound of the spermatic cord demonstrating “whirlpool sign” (arrow) and diminished vascular flow on power Doppler ultrasound.

When performing a scrotal ultrasound, the testicle in question can be compared to the contralateral testicle. Differences in echotexture, testicular size, and vascular flow can aid in the diagnosis of testicular torsion. What makes this case unusual is the patient’s history of monorchism; thus, the ultrasonographic findings could not be compared to a healthy testicle. The appearance of the twisted spermatic cord and absence of testicular flow as visualized by POCUS made the diagnosis of testicular torsion extremely likely even without the ability to compare our findings to a contralateral testicle.

## CONCLUSION

Point-of-care ultrasound helps emergency physicians improve the accuracy of their diagnoses and provides better overall patient care. If a patient presents with testicular or scrotal pain, using POCUS to examine for attenuated or absent vascular flow with the “whirlpool sign” of the spermatic cord may aid in confirming the diagnosis of testicular torsion, thus preventing delay in care and providing consultants with more objective data, especially in resource-poor settings where formal imaging may not be readily available.

The authors attest that their institution requires neither Institutional Review Board approval, nor patient consent for publication of this case report. Documentation on file.

*Address for Correspondence:* Chad Correa, MD, Kaiser Permanente San Diego, Department of Emergency Medicine, 4647 Zion Ave, Ste. 1116, San Diego, CA 92120. Email: chad.correa@kp.org.

*Conflicts of Interest:* By the CPC-EM article submission agreement, all authors are required to disclose all affiliations, funding sources and financial or management relationships that could be perceived as potential sources of bias. The authors disclosed none.

*Copyright:* © 2021 Correa et al. This is an open access article distributed in accordance with the terms of the Creative Commons Attribution (CC BY 4.0) License. See: <http://creativecommons.org/licenses/by/4.0/>

## REFERENCES

- Schick MA and Sternard BT. Testicular torsion. 2020. Available at: <https://www.ncbi.nlm.nih.gov/books/NBK448199/>. Accessed August 2, 2020.
- Howe AS, Vasudevan V, Kongnyuy M, et al. Degree of twisting and duration of symptoms are prognostic factors of testis salvage during episodes of testicular torsion. *Transl Androl Urol.* 2017;6(6):1159-66.
- Davis JE. (2016). Male genital problems. In: Tintinalli J (Ed.), *Tintinalli's Emergency Medicine: A Comprehensive Study Guide, 8th ed (p. 605)*. New York, NY: McGraw-Hill Education.
- Kawaichi GK, Cooper P, O'Donnell HF. Monorchism, a report of two cases. *N Engl J Med.* 1949;240(9):334.
- Mateer J, Plummer D, Heller M, et al. Model curriculum for physician training in emergency ultrasonography. *Ann Emerg Med.* 1994;23(1):95-102.
- Osumah TS, Jimbo M, Granberg CF, et al. Frontiers in pediatric testicular torsion: an integrated review of prevailing trends and management outcomes. *J Pediatr Urol.* 2018;14(5):394-401.
- McDowall J, Adam A, Gerber L, et al. The ultrasonographic “whirlpool sign” in testicular torsion: valuable tool or waste of valuable time? A systematic review and meta-analysis. *Emerg Radiol.* 2018;25(3):281-92.
- Bandarkar AN and Blask AR. Testicular torsion with preserved flow: key sonographic features and value-added approach to diagnosis. *Pediatr Radiol.* 2018;48(5):735-44.
- Hamm B, Beyersdorff D, Asbach P, et al. (2008). The Male Genitals. In: Hein P, Lemke U (Eds.), *Urogenital Imaging (p. 164)*. New York, NY: Thieme Medical Publishers.
- Bhatt S and Dogra VS. Role of US in testicular and scrotal trauma. *Radiographics.* 2008;28(6):1617-29.
- Bomann JS and Moore C. Bedside ultrasound of a painful testicle: before and after manual detorsion by an emergency physician. *Acad Emerg Med.* 2009;16(4):366.

# Blunt Chest Trauma Causing a Displaced Sternal Fracture and ST-elevation Myocardial Infarction: A Case Report

Keaton Nasser, MD\*  
Jaclyn Matsuura, DO†  
Jimmy Diep, MD\*‡

\*University of Nevada Las Vegas, Department of Cardiology, Las Vegas, Nevada

†University of Nevada Las Vegas, Department of Emergency Medicine, Las Vegas, Nevada

‡Nevada Heart and Vascular Center, Department of Cardiology, Las Vegas, Nevada

Section Editor: Rick A. McPheeters, DO

Submission history: Submitted September 14, 2020; Revision received December 5, 2020; Accepted December 11, 2020

Electronically published January 19, 2021

Full text available through open access at [http://escholarship.org/uc/uciem\\_cpem](http://escholarship.org/uc/uciem_cpem)

DOI: 10.5811/cpem.2020.12.49875

**Introduction:** Blunt chest trauma and motor vehicle collisions are common presentations to the emergency department (ED). Chest pain in a trauma patient can usually and reasonably be attributed to chest wall injury, leading to a potential delay in diagnosis and treatment.

**Case Report:** In this case report, we present a 52-year-old male who was brought to the ED with complaints of chest pain and pressure after a motor vehicle collision. He was subsequently found to have both a displaced sternal fracture and simultaneous acute myocardial infarction with 100% occlusion of the mid left anterior descending artery without dissection requiring stent placement.

**Conclusion:** Chest pain after blunt cardiac trauma is a common complaint. While rare, acute myocardial infarction must be considered. Most injuries result as direct trauma to the artery causing either dissection or acute thrombosis resulting in a myocardial infarction as opposed to acute plaque rupture with thrombosis, as seen in this case. [Clin Pract Cases Emerg Med. 2021;5(1):85–88.]

**Keywords:** STEMI; blunt chest trauma; sternal fracture.

## INTRODUCTION

Blunt chest trauma can cause a variety of cardiac injuries. Chest pain in a trauma patient can usually and reasonably be attributed to chest wall injury, leading to a potential delay in diagnosis and treatment. Myocardial infarction from artery dissection, thrombosis from trauma, and plaque rupture need to be considered in the differential. The incidence of coronary artery injury in blunt chest trauma is approximately 2%, with most reported cases being coronary artery dissections.<sup>1</sup> Blunt cardiac injury has been reported as the most overlooked injury in patients who die from trauma; therefore, emergency providers should maintain a high index of suspicion.<sup>2</sup> We report on a patient with a displaced sternal fracture and simultaneous acute myocardial infarction as a result of blunt chest trauma.

## CASE REPORT

A 52-year-old male was brought to the emergency department (ED) via emergency medical services (EMS) with

complaints of chest pain and pressure after a motor vehicle collision. The patient was the restrained driver in a collision while traveling at approximately 45 miles per hour when a car turned in front of him at an intersection. His airbags deployed; he did not lose consciousness and was able to self-extricate from the vehicle. After extrication, he started to experience substernal chest pressure, which was not present prior to the accident. When EMS arrived he was placed in a cervical collar and given aspirin, and an electrocardiogram (ECG) was obtained (Image 1). He was transported to the ED.

On arrival, a repeat ECG was performed, and the emergency physician alerted a cardiac activation given concern for an ST-elevation myocardial infarction (STEMI). He complained of substernal chest pain and pressure that was non-radiating and exacerbated by deep inspiration. Additional review of systems was negative.

On examination in the ED, the patient's temperature was 36.6° Celsius, heart rate 76 beats per minute, respirations 15

breaths per minute, blood pressure 102/60 millimeters mercury, and an oxygen saturation of 97%. He was in no acute distress. He had tenderness to palpation over the sternum with no evidence of contusion or seatbelt sign on chest or abdomen. He had no abnormalities on cardiac, lung, or abdominal exams. He had no bony point tenderness of extremities and had full range of motion of all extremities.

He had no prior medical history but had not had regular medical care in the prior 30 years. He had smoked 1.5 packs per day of cigarettes for many years, consumed alcohol on social occasions, and denied recreational drug use. He had no known drug allergies. He had never had surgery. He denied any family history of coronary artery disease and denied any personal history of hypertension, hyperlipidemia, or coronary artery disease.

Chest radiography demonstrated only mild left lung base atelectasis. Point-of-care echocardiography by the cardiology service was limited by difficult windows and pain on transducer pressure, but demonstrated a relatively preserved ejection fraction, no pericardial effusion, and no obvious wall motion abnormalities. Initial troponin-I was elevated at 0.045 nanograms per milliliter (ng/mL) (reference range 0.02-0.04 ng/mL), and B-type natriuretic peptide was 10 picograms (pg)/mL ( $\leq 99$  pg/mL).

While the diagnosis of cardiac contusion was entertained, the field ECG could not be ignored. With no contraindications to angiography identified, the patient was fully anticoagulated and taken emergently for coronary angiography. Coronary angiogram demonstration 100% occlusion of the mid left

### CPC-EM Capsule

What do we already know about this clinical entity?

*Blunt chest trauma and motor vehicle collisions are common presentations in the emergency department. Chest pain is a common complaint.*

What makes this presentation of disease reportable?

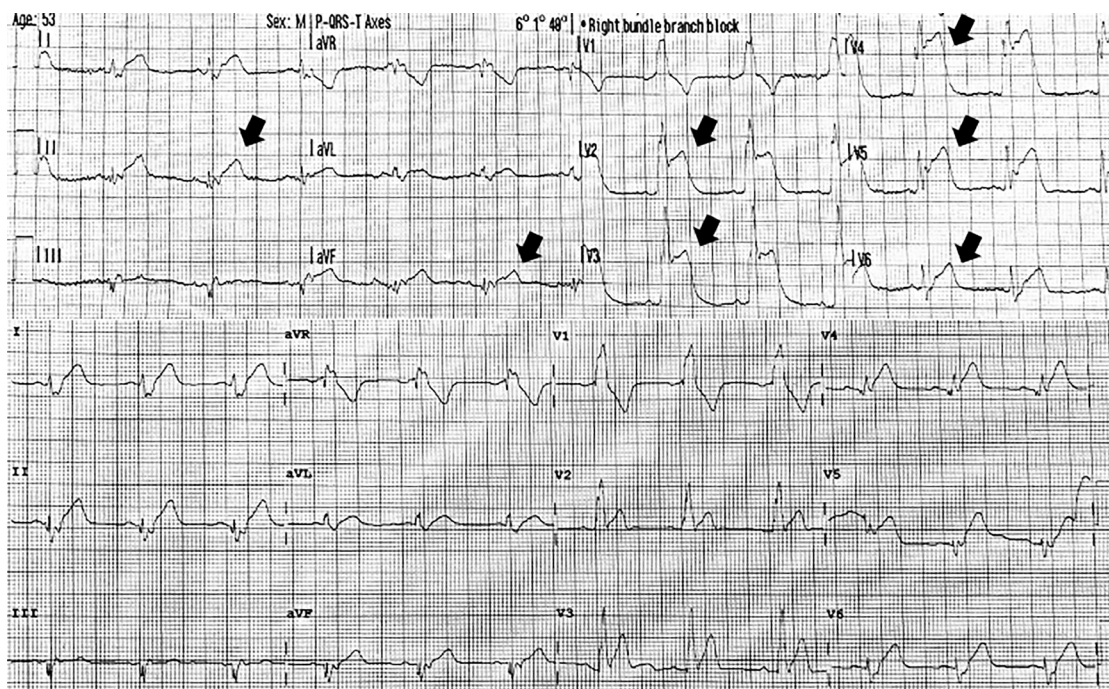
*We report the simultaneous presentation of a displaced sternal fracture and acute myocardial infarction in the setting of blunt chest trauma.*

What is the major learning point?

*Blunt cardiac injury is the most commonly overlooked injury in patients who die from trauma. Acute myocardial infarction and cardiac injury must be considered.*

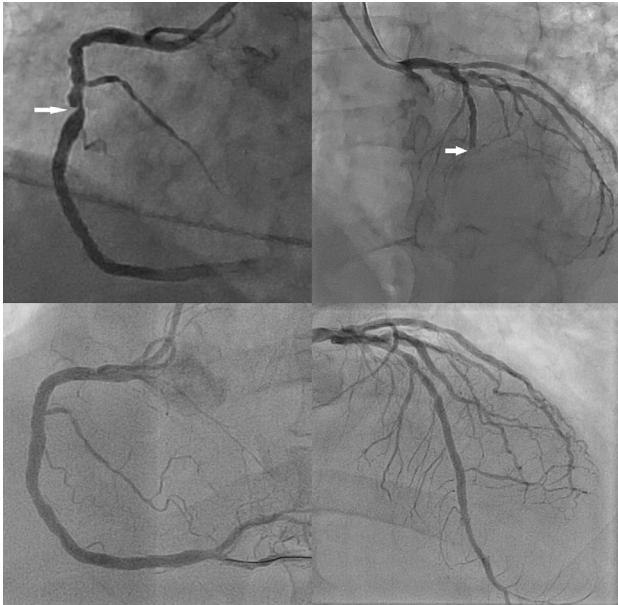
How might this improve emergency medicine practice?

*Suspicion should be high for cardiac injury, even in the setting of reproducible "musculoskeletal" chest pain.*



**Image 1.** Electrocardiograms obtained at the collision scene (top) showing ST elevations (arrows) in leads V2-V6 and leads II and aVF; and on hospital arrival (bottom) showing sinus rhythm with right bundle branch block.

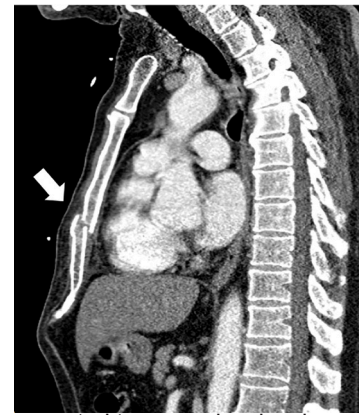anterior descending artery (LAD) without dissection (Image 2). There was also a mid-right coronary artery (RCA) ragged 70-90% lesion. After intervention on the LAD lesion, the patient's pain subsided. The next day, he complained of chest pain on deep inspiration and chest heaviness. He had a staged intervention of the RCA the following day. In the interim, he was discovered to have a sternal fracture by computed tomography (Image 3).



**Image 2.** Coronary angiography showing 100% occlusion of the mid-left anterior descending artery (right) and 70-90% stenosis of the right coronary artery (left) in the upper images, and the subsequent corresponding angiographic results after stenting in the lower images.

## DISCUSSION

The patient's field ECG showed sinus rhythm, a right bundle branch block, and ST-segment elevations in leads V2-V6, consistent with acute anterior injury, and leads II and aVF consistent with acute inferior injury. The ECG obtained in the ED demonstrated sinus rhythm and a right bundle branch block. However, the previous ST-segment elevations were no longer as profound and there were no developing q-waves consistent with the natural progression of ECG changes in ST-elevation myocardial infarctions (STEMI). The degree of variance between these two ECGs could have been simply explained by lead position. The widespread ST changes in multiple territories compounded the diagnosis. Cardiac contusion can have any ECG findings, including ST elevations.<sup>3</sup> The case was further complicated by the patient's significant trauma and reproducible chest pain, which could have been musculoskeletal.



**Image 3.** Chest computed tomography showing a displaced sternal fracture (arrow).

Blunt thoracic trauma can cause a multitude of cardiac injuries. They range from benign and clinically silent cardiac contusion to cardiac wall rupture. Pericardial injuries, valvular injuries, and coronary artery injuries are also possible. Providers should be wary of attributing ECG changes to cardiac contusion alone.

A PubMed search using the terms "STEMI" and "blunt chest trauma" revealed fewer than 30 full cases published in English in the prior 20 years. The cause of STEMI was dissection in 13 patients, acute plaque rupture or thrombosis in 9 patients, cardiac contusion in 1 patient, and an artery to ventricle fistula in 1 patient. Only our case showed ECG changes in more than one territory. Coronary artery occlusions from trauma are a relatively rare phenomenon with three possible mechanisms. Direct impact may cause intimal disruption and dissection. Alternatively, impact can cause acute intra-arterial thrombosis with or without the involvement of acute plaque rupture involvement (ie, thrombosis can occur in normal coronary arteries without other evidence of native atherosclerotic disease). All three types can result in a STEMI.

Treatment can include emergency coronary bypass surgery, percutaneous stenting, aspirational thrombectomy without stenting, or medical management. Invasive angiography is necessary for diagnosis and to determine the treatment course. These injuries can happen in individuals of any age and with any level of intimal plaque.<sup>4-9</sup> Because of its anterior location and its position lying behind the sternum, the left anterior descending artery tends to be the culprit. However, abdominal injuries with an upward force can affect the inferior vessels. There are at least two reports of circumflex artery involvement, but both of those cases also involved the LAD.<sup>10,11</sup> The mechanism for left circumflex artery injury is unclear.

## CONCLUSION

Chest pain after blunt cardiac trauma is a common complaint, and while rare, acute myocardial infarction must be entertained. Blunt cardiac injury has been cited as the most

commonly overlooked injury in patients who die from trauma.<sup>2</sup> Most injuries result as a direct trauma to the artery causing either dissection or acute thrombosis resulting in a myocardial infarction as opposed to acute plaque rupture with thrombosis, as seen in this case. Our patient was fortunate to not have injuries that would preclude invasive angiography and percutaneous intervention. Trauma patients with coexisting injuries may not be candidates for fibrinolytic therapy because of the risk of hemorrhage. Given the emergent need for coronary angiography, emergency providers should maintain a high index of suspicion for STEMI in the setting of blunt chest trauma.

The authors attest that their institution requires neither Institutional Review Board approval, nor patient consent for publication of this case report. Documentation on file.

---

*Address for Correspondence:* Keaton Nasser, MD, University of Nevada Las Vegas, Department of Cardiology, 1701 W Charleston Blvd, #230 Las Vegas, NV 89102. Email: keaton.nasser@unlv.edu.

*Conflicts of Interest:* By the CPC-EM article submission agreement, all authors are required to disclose all affiliations, funding sources and financial or management relationships that could be perceived as potential sources of bias. The authors disclosed none.

*Copyright:* © 2021 Nasser et al. This is an open access article distributed in accordance with the terms of the Creative Commons Attribution (CC BY 4.0) License. See: <http://creativecommons.org/licenses/by/4.0/>

---

## REFERENCES

1. Prêtre R and Chilcott M. Blunt trauma to the heart and great vessels. *N Engl J Med.* 1997;336(9):626-32.
2. Liedtke AJ and DeMuth WE Jr. Nonpenetrating cardiac injuries: a collective review. *Am Heart J.* 1973;86(5):687-97.
3. Sybrandy KC, Cramer MJ, Burgersdijk C. Diagnosing cardiac contusion: old wisdom and new insights. *Heart.* 2003;89(5):485-9.
4. Sinha A, Sibel M, Thomas P, et al. Coronary thrombosis without dissection following blunt trauma. *Case Rep Cardiol.* 2016;2016:8671015. doi:10.1155/2016/8671015
5. Vasudevan AR, Kabinoff GS, Keltz TN, et al. Blunt chest trauma producing acute myocardial infarction in a rugby player. *Lancet.* 2003;362(9381):370. Erratum in: *Lancet.* 2003;362(9389):1082.
6. Shah S, Raj V, Wagle K, et al. Blunt chest wall trauma causing plaque rupture and myocardial infarction. *J Am Coll Cardiol.* 2020;75(11):3435.
7. Joseph S, David S, Timothy H. STEMI due to severe blunt chest trauma. *Trauma Cases Rev.* 2019;5(1):72.
8. Perez O, Nair RM, Kewan T, et al. A rare case of ST-elevation myocardial infarction after blunt chest trauma. *Cureus.* 2020;12(4):e7710.
9. Park WS, Jeong MH, Hong YJ, et al. A case of acute myocardial infarction after blunt chest trauma in a young man. *J Korean Med Sci.* 2003;18(6):889-93.
10. Lai CH, Ma T, Chang TC, et al. A case of blunt chest trauma induced acute myocardial infarction involving two vessels. *Int Heart J.* 2006;47(4):639-43.
11. Kul Ş, Akyol A, Aşker M, et al. A rare cause of myocardial infarction: blunt chest trauma. *East J Med.* 2015;20(4):228-30.

# Unmasking Long QT Syndrome in the Emergency Department: A Case Report

Eric Leslie, MD\*

\*United States Naval Hospital Okinawa, Department of Emergency Medicine, Okinawa, Japan

Andrew Medenbach, DO†

†Naval Medical Center San Diego, Department of Emergency Medicine, San Diego, California

Eric Pittman, MD†

Section Editor: Manish Amin, DO

Submission history: Submitted June 14, 2020; Revision received September 25, 2020; Accepted October 8, 2020

Electronically published December 7, 2020

Full text available through open access at [http://escholarship.org/uc/uciem\\_cpem](http://escholarship.org/uc/uciem_cpem)

DOI: 10.5811/cpcem.2020.10.48716

**Introduction:** Long QT syndrome (LQTS) is an uncommon disorder that can lead to potentially life-threatening dysrhythmias. LQTS can be genetic, acquired, or both.

**Case Report:** A 44-year-old female with well-controlled hypertension and asthma presented with chest tightness. An initial electrocardiogram yielded a normal corrected QT interval of 423 milliseconds (ms) (normal <480 ms in females). Albuterol was administered and induced agitation, tremulousness, and tachycardia. Follow-up electrocardiograms demonstrated extreme prolongation of the corrected QT interval to 633 ms and morphology change of the T wave. Lab values were later notable for hypokalemia and hypomagnesemia, attributable to a recently started thiazide diuretic. The patient was ultimately diagnosed with congenital LQTS after initial unmasking by albuterol in the emergency department.

**Conclusion:** LQTS can be unmasked or exacerbated by electrolyte abnormalities and QT prolonging medications. [Clin Pract Cases Emerg Med. 2021;5(1):89–92.]

**Keywords:** Long QT syndrome; torsades de pointes.

---

## INTRODUCTION

Long QT syndrome (LQTS) is a rare condition in which cardiac myocytes are predisposed to repolarization phase abnormalities, which can lead to life-threatening torsades de pointes.<sup>1</sup> It is one of the leading causes of unexplained sudden cardiac death.<sup>1</sup> Long QT syndrome can be congenital, acquired, or both.

The prevalence of congenital LQTS is estimated at 1 in 2000 births.<sup>2</sup> This does not account for patients with electrocardiographically silent LQTS and those who are genotype positive but phenotype negative.<sup>2</sup> Thus, the true prevalence of the LQTS gene is likely higher. Patients may have electrocardiographically silent LQTS, only to be unmasked by certain QT prolonging medications, electrolyte abnormalities, or sympathetic stimulation.<sup>3</sup> Type I LQTS, one of the most common forms of congenital LQTS, is particularly susceptible to sympathetic stimulation.<sup>3</sup>

Several classes of medications have been demonstrated to lengthen the repolarization phase of cardiac myocytes, thus lengthening the QT interval. Medications classically known to prolong the QT interval include certain antiarrhythmics, calcium antagonists, anti-psychotics, antihistamines, macrolide and fluoroquinolone antibiotics, certain antifungals, and antiretroviral medications (a complete list can be found at [crediblemeds.org](http://crediblemeds.org)).<sup>4-6</sup> In addition, electrolyte abnormalities can similarly affect the repolarization phase. Alterations in serum potassium levels are the most likely to alter the QT interval, however magnesium, calcium and sodium are contributory as well.<sup>4</sup> Sympathetic stimulation has also been implicated, most notably in sudden exposure to cold water, accounting for a large proportion of sudden cardiac death occurring during swimming.<sup>3,7</sup> In fact, during provocative electrophysiology testing, epinephrine boluses are sometimes used to directly

affect the QT interval due to its sympathomimetic effect.<sup>7</sup> Bradycardia, structural heart diseases, female gender, impaired hepatic and renal function, and advanced age are also known risk factors.<sup>8,9</sup>

Due to the above-mentioned risk of sudden death, it is crucially important to recognize LQTS and subsequently follow an appropriate treatment plan. All patients with any significant prolongation of the QT interval, whether transient or persistent, should undergo genetic testing to determine whether they have an underlying channelopathy.<sup>10</sup> If an underlying genetic alteration is identified, family members should be counseled on the need for further testing and evaluation.<sup>10</sup> Treatment for patients with acquired QT prolongation includes withholding medications with known QT prolonging effects and avoiding serum electrolyte perturbations. Treatments for patients with congenital prolonged QT include the above strategies, observation, beta blocker therapy, avoidance of high intensity sports, or implantable cardiac defibrillator (ICD) placement.<sup>11</sup>

### CASE REPORT

A 44-year-old female with a history of well-controlled asthma and hypertension presented to the emergency department (ED) with “chest tightness”, which the patient described as inability to take a full breath with occasional pressure-like sensation across the precordium. The patient denied exertional component, leg swelling, history of coagulopathy, thrombotic risk factors, family history for coronary artery disease, cough, fever, vomiting, or abdominal pain. One week prior to ED presentation, the patient had a routine checkup with her family physician and was started on chlorthalidone for her hypertension. She was prescribed the following home medications: montelukast, fluticasone, chlorthalidone, loratidine, ascorbic acid, ferrous sulfate, and albuterol.

The patient’s initial presenting vital signs were the following: pulse 82 beats per minute; blood pressure of 123/73 millimeters of mercury; respirations 18 per minute; oxygen saturation 100%; temperature 98.2 degrees Fahrenheit. On physical exam, breath sounds were mildly diminished in all lung fields. A subtle end expiratory wheeze was appreciated. There was no accessory muscle use or increased respiratory effort. There was no evidence of stridor or upper airway swelling. Cardiac auscultation demonstrated a regular rate and rhythm with no murmur appreciated. The abdomen was soft, nontender and nondistended. Pulses were equally present and strong in all four extremities. No lower extremity swelling was appreciated. A chest radiograph was within normal limits. An initial electrocardiogram (ECG) (Image A) demonstrated no acute ischemia or dysrhythmia (Bazett QTc 423 milliseconds [ms]).

A troponin was similarly negative after days of symptoms, lowering concern for acute coronary syndrome. A trial of albuterol was instituted as some of her symptoms were considered to be attributable to her otherwise well-controlled asthma. Shortly after receiving the nebulized albuterol treatment,

### CPC-EM Capsule

What do we already know about this clinical entity?

*Long QT Syndrome can predispose patients to Torsades de Pointes. Certain medications are known to further prolong the QT interval.*

What makes this presentation of disease reportable?

*The patient’s underlying Long QT syndrome was effectively unmasked in the emergency department (ED) in the context of albuterol treatment and electrolyte changes from diuretic use.*

What is the major learning point?

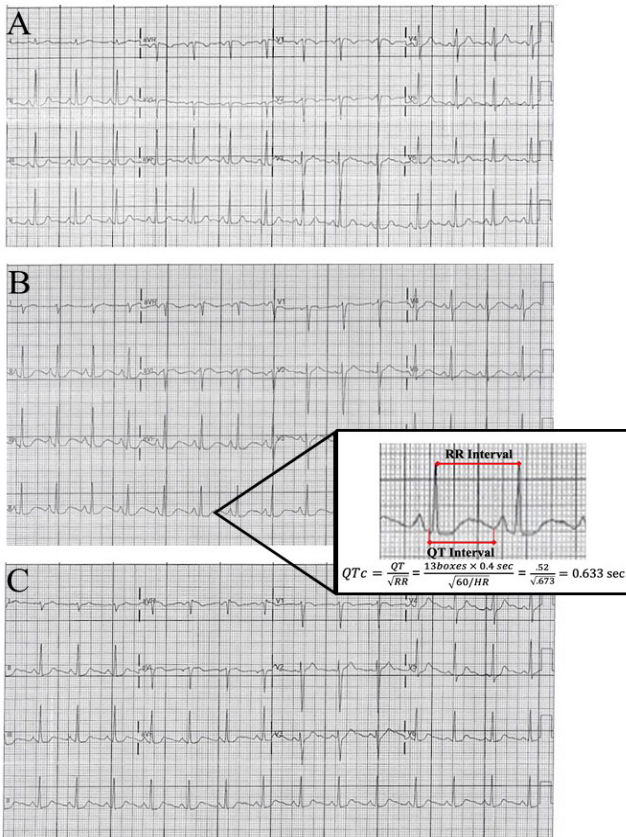
*Be vigilant of the QT prolonging effects of certain medications and electrolyte derangements to further prolong the QT interval. Genetic Long QT Syndrome may only be “unmasked” briefly.*

How might this improve emergency medicine practice?

*Genetic Long QT Syndrome can be identified in the ED and potentially life-saving referrals can be made.*

the patient became tachycardic and very tremulous. A repeat ECG was obtained (Image B) and notable for a significantly prolonged QT interval (Bazett QTc 633 ms) with distinct morphology change of the T wave. Laboratory studies were reviewed and notable for hypokalemia of 3.2 milliequivalents per liter (mEq/L) (reference range 3.4-5.1 mEq/L) and hypomagnesemia of 1.6 milligrams per deciliter (milligrams per deciliter [mg]/dL) (reference range 1.7-2.2 mg/dL). The albuterol treatment was terminated. The patient was immediately treated with 2 grams intravenous (IV) magnesium sulfate, 20 mEq IV potassium chloride, and 40mEq oral potassium chloride. After one hour, the QT interval had shortened (QTc 428 ms) (Image C) but retained the T wave morphology change. The patient was observed in the ED for several more hours, and discharged home with a next day follow-up to have her electrolyte levels reassessed. The patient’s chlorthalidone and albuterol were discontinued.

The patient was referred to an electrophysiologist and ultimately diagnosed with Type 1 LQTS. The patient’s family was referred for genetic counseling. Despite the patient’s asthma being a contraindication, after a risk-and-benefit conversation she was initiated on low-dose beta blocker therapy which was well tolerated. She declined placement of an ICD.



**Image.** Serial electrocardiograms (ECG) demonstrating QT prolongation after albuterol use. ECG A demonstrates the patient’s baseline with no acute dysrhythmia or ischemia and QTc of 423 milliseconds (ms). ECG B demonstrates a QTc interval of 633 ms and T wave morphology change. ECG C demonstrates QTc return to 428ms, with retention of the T wave morphology.

The importance of close monitoring of her electrolytes was stressed, particularly during situations in which electrolyte loss is possible (diarrhea, vomiting, exercise).

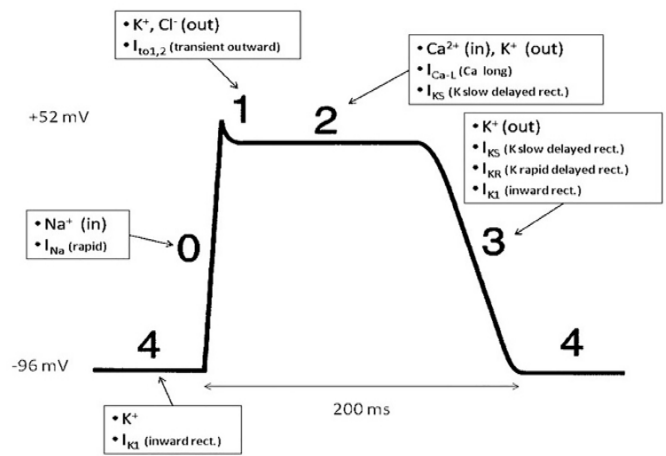
**DISCUSSION**

This case was unique in that it contained elements of both genetic and acquired LQTS. Given her normal ECG at presentation, this represents a case of electrocardiographically silent LQTS. Only after provocation with albuterol did she have demonstrable prolonged QT on ECG. In addition, the electrolyte abnormalities caused by the chlorthalidone lowered the threshold for abnormalities in the repolarization phase. The computer-calculated QTc should always be checked with a manual QTc. This can be done by using Bazett’s equation. This should be repeated with multiple different beats in different leads, preferably lead II and V5. After correction the patient’s QT was calculated to be 633 ms. See Image 1 for our calculation.

Patients with congenital LQTS most commonly have mutations to the Kv11.1 and Kv7.1 potassium channel proteins, responsible for the rapid ( $I_{KR}$ ) and slow ( $I_{KS}$ ) delayed

potassium rectifier currents, respectively.<sup>8</sup> These altered  $I_{KR}$  and  $I_{KS}$  currents can lead to excessive local extracellular potassium levels and ultimately repolarization abnormalities.<sup>12</sup> Should these gradients worsen, the patient is at risk for entering torsades de pointes.

The figure is a schematic demonstrating the action potential of a cardiac myocyte.<sup>13</sup> As described above,  $I_{KR}$  and  $I_{KS}$  are the most commonly affected currents in congenital LQTS. These will directly affect phase three, causing a delay in repolarization. On the ECG, this corresponds to the altered T wave morphology and subsequently the prolonged QT interval.



**Figure.** Cardiac Myocyte Action Potential. Slow delayed rectifier potassium current ( $I_{KS}$ ) and rapid delayed potassium rectifier current ( $I_{KR}$ ) are responsible for efflux of potassium ion during the repolarization phase of the cardiac myocyte (Phase 3). Abnormal serum potassium levels can further affect repolarization in the context of dysfunctional potassium channels.

$K^+$ , potassium;  $Na^+$ , sodium;  $Cl^-$ , chloride;  $Ca^{2+}$ , calcium;  $I_{K1}$ , inward rectifier potassium current;  $I_{Na^+}$ , inward sodium channel;  $I_{to1,2}$ , transient outward potassium current;  $I_{Ca-L}$ , L-type calcium current;  $I_{KS}$ , slow delayed rectifier potassium current;  $I_{KR}$ , rapid delayed potassium rectifier current; *ms*, milliseconds.

\*Adapted and modified from Wikimedia Commons with permission.

In addition, generalized sympathetic stimulation can prolong the QT interval. In fact, in electrophysiology laboratory testing, patients are given epinephrine boluses to elicit sympathetic stimulation to unmask LQTS.<sup>3</sup> The albuterol “challenge” that was administered in the ED certainly could have had a similar sympathomimetic effect. Indeed, a study by Thottathil et al showed beta-2 agonist use by patients with LQTS is a risk factor for cardiac events.<sup>14</sup> Asthmatic patients with LQTS who need beta-2 agonists should have electrolyte levels monitored and repleted as necessary. When not contraindicated, the provider should also consider using a beta blocker as there is decreased risk of cardiac events when beta blockers are used.<sup>14</sup>

## CONCLUSION

In conclusion, this is a cautionary tale in which a patient with an underlying cardiac channelopathy was administered a QT prolonging agent in the context of multiple electrolyte abnormalities induced by a recently started thiazide diuretic. Caution should be exercised in administering patients a medication with known QT prolonging effects. It is not infrequent that several medications with the potential for QT prolongation may be used simultaneously in the ED setting (eg, an agitated elderly patient with chronic obstructive pulmonary disease found to have pneumonia). In patients receiving these medications, consider first obtaining an ECG and/or placing the patient on a cardiac monitor.

Patient consent has been obtained and filed for the publication of this case report.

---

*Address for Correspondence:* Eric Leslie, MD, United States Naval Hospital, Department of Emergency Medicine, PSC 482 BOX 2472, FPO, AP 96362. Email: eric.a.leslie3.mil@mail.mil.

*Conflicts of Interest:* By the CPC-EM article submission agreement, all authors are required to disclose all affiliations, funding sources and financial or management relationships that could be perceived as potential sources of bias. The authors disclosed none. "The views expressed in this case report are those of the authors and do not necessarily reflect the official policy or position of the Department of the Navy, Department of Defense, or the United States Government. We are military service members. This work was prepared as part of our official duties. Title 17 U.S.C. 105 provides that "Copyright protection under this title is not available for any work of the United States Government." Title 17 U.S.C. 101 defines a United States Government work as a work prepared by a military service member or employee of the United States Government as part of that person's official duties."

*Copyright:* © 2021 Leslie et al. This is an open access article distributed in accordance with the terms of the Creative Commons Attribution (CC BY 4.0) License. See: <http://creativecommons.org/licenses/by/4.0/>

---

## REFERENCES

1. Bastiaenen R and Behr ER. Sudden death and ion channel disease: pathophysiology and implications for management. *Heart*. 2011;97(17):1365-72.
2. Schwartz PJ, Stramba-Badiale M, Crotti L, et al. Prevalence of the congenital long-QT syndrome. *Circulation*. 2009;120(18):1761-7.
3. Tanabe Y, Inagaki M, Kurita T, et al. Sympathetic stimulation produces a greater increase in both transmural and spatial dispersion of repolarization in LQT1 than LQT2 forms of congenital long QT syndrome. *J Am Coll Cardiol*. 2001;37(3):911-9.
4. Kao LW and Furbee RB. Drug-induced q-T prolongation. *Med Clin North Am*. 2005;89(6):1125-44, x.
5. Tay KY, Ewald MB, Bourgeois FT. Use of QT-prolonging medications in US emergency departments, 1995-2009. *Pharmacoepidemiol Drug Saf*. 2014;23(1):9-17.
6. Pourmand A, Mazer-Amirshahi M, Chistov S, et al. Emergency department approach to QTc prolongation. *Am J Emerg Med*. 2017;35(12):1928-33.
7. Takenaka K, Ai T, Shimizu W, et al. Exercise stress test amplifies genotype-phenotype correlation in the LQT1 and LQT2 forms of the long-QT syndrome. *Circulation*. 2003;107(6):838-44.
8. Drew BJ, Ackerman MJ, Funk M, et al. American Heart Association Acute Cardiac Care Committee of the Council on Clinical Cardiology; Council on Cardiovascular Nursing; American College of Cardiology Foundation. Prevention of torsades de pointes in hospital settings: a scientific statement from the American Heart Association and the American College of Cardiology Foundation. *J Am Coll Cardiol*. 2010;55(9):934-47.
9. Makkar RR, Fromm BS, Steinman RT, et al. Female gender as a risk factor for torsades de pointes associated with cardiovascular drugs. *JAMA*. 1993;270(21):2590-7.
10. Ackerman MJ, Priori SG, Willems S, et al. HRS/EHRA expert consensus statement on the state of genetic testing for the channelopathies and cardiomyopathies this document was developed as a partnership between the Heart Rhythm Society (HRS) and the European Heart Rhythm Association (EHRA). *Heart Rhythm*. 2011;8(8):1308-39.
11. Garratt CJ, Elliott P, Behr E, et al. Heart Rhythm UK Familial Sudden Cardiac Death Syndromes Statement Development Group. Heart Rhythm UK position statement on clinical indications for implantable cardioverter defibrillators in adult patients with familial sudden cardiac death syndromes. *Europace*. 2010;12(8):1156-75.
12. Splawski I, Shen J, Timothy KW, et al. Spectrum of mutations in long-QT syndrome genes. KVLQT1, HERG, SCN5A, KCNE1, and KCNE2. *Circulation*. 2000;102(10):1178-85.
13. Leslie E. Wikimedia Commons, the free media repository. 2010. Available at: [https://commons.wikimedia.org/wiki/File:Action\\_potential\\_ventr\\_myocyte.gif](https://commons.wikimedia.org/wiki/File:Action_potential_ventr_myocyte.gif). Accessed May 15, 2020.
14. Thottathil P, Acharya J, Moss AJ, et al. Risk of cardiac events in patients with asthma and long-QT syndrome treated with beta(2) agonists. *Am J Cardiol*. 2008;102(7):871-4.

# Point-of-care Ultrasound for Suspected Pectoralis Major Rupture: A Case Report

Nathanael Franks, MBA\*  
Jeremiah Gress, BS\*  
Ryan Joseph, DO†

\*Long School of Medicine, UT Health San Antonio, San Antonio, Texas  
†UT Health San Antonio, Department of Emergency Medicine, San Antonio, Texas

Section Editor: Shadi Lahham, MD

Submission history: Submitted November 7, 2020; Revision received November 24, 2020; Accepted December 6, 2020

Electronically published January 27, 2021

Full text available through open access at [http://escholarship.org/uc/uciem\\_cpem](http://escholarship.org/uc/uciem_cpem)

DOI: 10.5811/cpem.2020.10.50802

**Introduction:** Pectoralis major muscle injuries are relatively uncommon and occur secondary to weightlifting in nearly 50% of cases. Tendon tears occur almost exclusively in males between 20-40 years old and are heavily associated with anabolic androgenic steroid use. While magnetic resonance imaging is often considered the modality of choice, its availability is often limited in the emergency department (ED). In contrast, point-of-care ultrasound (POCUS) is commonly available in the ED and can be used to help confirm the diagnosis and hasten disposition.

**Case Report:** We report a case of a 28-year-old male competitive weightlifter with a history of chronic anabolic steroid use who presented to the ED with acute left shoulder pain after weightlifting. History and physical exam were concerning for pectoralis major rupture, and POCUS confirmed the diagnosis.

**Conclusion:** Prompt evaluation and radiographic confirmation is key in ensuring good patient outcomes in pectoralis major tears. Therefore, proficiency of emergency physicians in musculoskeletal POCUS as an adjunct to estimate the extent of injury is important for expediting disposition and promptly involving orthopedic surgery evaluation. [Clin Pract Cases Emerg Med. 2021;5(1):93–96.]

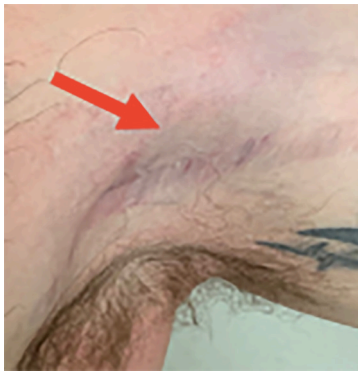**Keywords:** *Point-of-care ultrasound; POCUS; pectoralis major injury; pectoralis major rupture; case report.*

## INTRODUCTION

Injuries of the pectoralis major muscle are relatively uncommon, and roughly 50% have been reported after weightlifting.<sup>1-3</sup> Bench press is a common culprit due to the excessive tension put on an eccentrically contracted muscle.<sup>1-3</sup> Less commonly, injuries occur after direct trauma causing forced abduction and external rotation of the upper extremity.<sup>4</sup> Tendon tears occur almost exclusively in males between 20-40 years old and are heavily associated with anabolic androgenic steroid use.<sup>5,6</sup> Other risk factors for major tendon rupture in general include Black race, young age, male gender, and sports participation.<sup>7</sup> While magnetic resonance imaging (MRI) is often considered the modality of choice for the evaluation of pectoralis major tears due to its ability to differentiate the site, grade, and chronicity, it is

expensive, time-consuming, and often unavailable in the emergency department (ED) setting.<sup>8,9</sup> However, point-of-care ultrasound (POCUS) can be used in the ED due to its low cost and rapid availability to guide evaluation and treatment for patients.<sup>4</sup>

A 28-year-old male competitive weightlifter with a history of chronic anabolic androgenic steroid use presented to the ED with left shoulder pain. The patient reported weightlifting several hours prior, and while performing dumbbell flies with 140 pounds in each arm he felt and heard a sudden “pop” with immediate loss of strength in his left shoulder. The patient endorsed constant pain at the site since the injury, which was exacerbated by arm movement. He denied any numbness or tingling. On physical exam of the left upper extremity, the skin was intact with significant



**Image 1.** Bedside photograph displaying prominent ecchymoses (red arrow) over patient's left axilla.

bruising in the axilla (Image 1). There was asymmetric loss of normal contour of the left pectoralis major, and the left nipple was noted to be lower than the right (Image 2). Tenderness to palpation was reported across the left pectoral region, left axilla, and left anterior deltoid. Additionally, there was decreased strength with arm adduction and increased pain with internal rotation at the shoulder. Given the convincing clinical history and physical exam for pectoralis major rupture, POCUS was used for further evaluation. On sonography there were hypoechoic disruptions of muscular striations, hematoma formation, and pectoralis major muscle retraction noted at the site of injury, helping to confirm the pectoralis major rupture (Images 3 and 4). Radiographs of the left shoulder were performed showing no osseous injury. The orthopedic surgery team was consulted and scheduled the patient for magnetic resonance imaging (MRI) and prompt outpatient follow-up with a shoulder subspecialist.

### CPC-EM Capsule

What do we already know about this clinical entity?

*Pectoralis major tears are relatively uncommon and heavily associated with anabolic steroid use. Magnetic resonance imaging, the gold standard for diagnosis, is time consuming, expensive, and often unavailable for such applications in the emergency department.*

What makes this presentation of disease reportable?

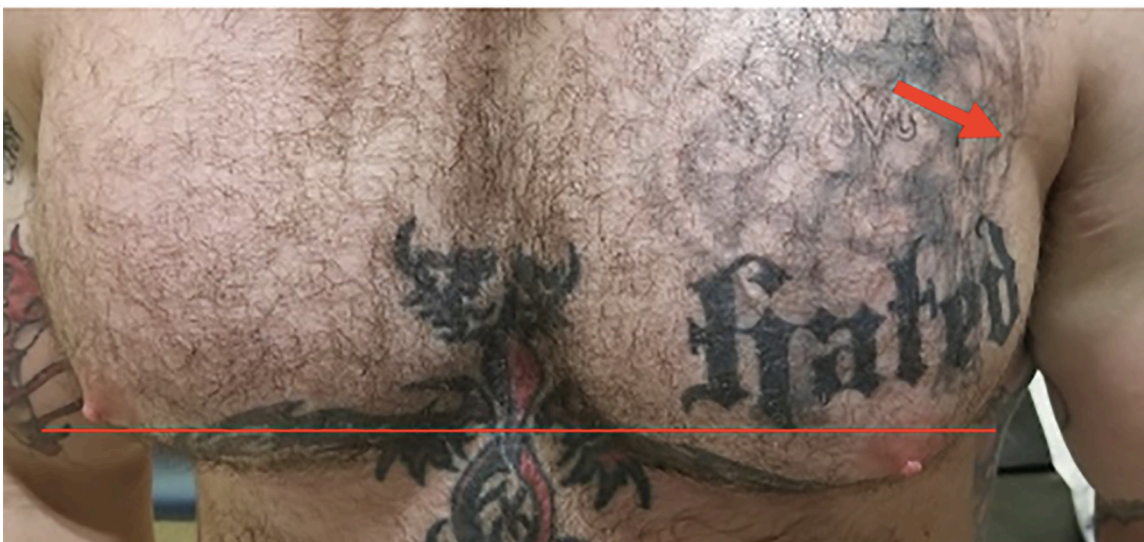
*The confirmation of the diagnosis with point-of-care ultrasound in the emergency department makes this a unique case.*

What is the major learning point?

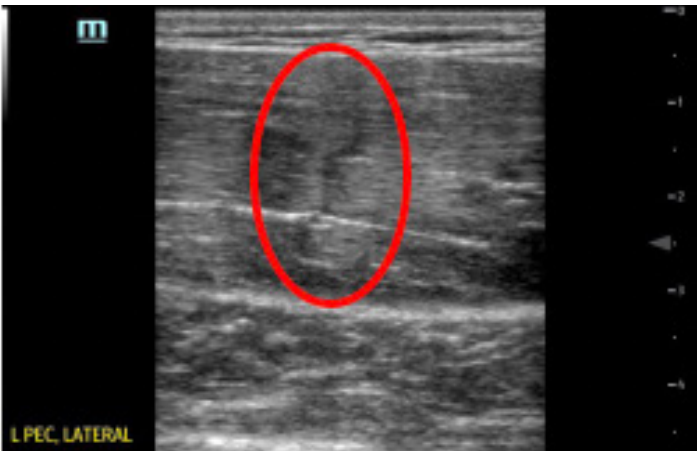*Point-of-care ultrasound can help to quickly confirm the diagnosis of pectoralis major tears and make appropriate consultations for follow-up and further management.*

How might this improve emergency medicine practice?

*By making or confirming the diagnosis of a pectoralis major tear faster, we can get patients appropriate follow-up or specialty consultation more efficiently and avoid other, more expensive imaging modalities.*



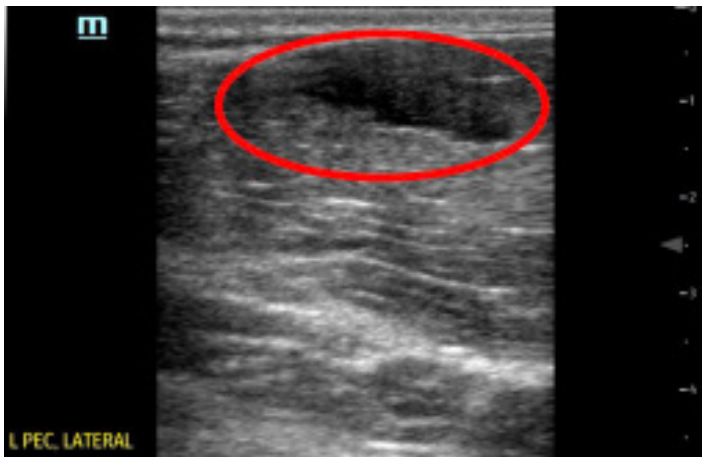**Image 2.** Photograph displaying asymmetry of patient's nipple height (horizontal red line) following injury and subtle indentation (red arrow) over the lateral left pectoralis.



**Image 3.** Point-of-care ultrasound image displaying disruption of the distal pectoralis major muscle bellies with vertical interruption noted (red circle).

## DISCUSSION

The pectoralis major is a complex, fan-shaped muscle comprised of a clavicular head, originating from the medial half of the clavicle, and a sternocostal head, originating from the anterior sternum, costal cartilages of ribs 1-7, and the aponeurosis of the external oblique.<sup>10</sup> The two heads coalesce into a common tendon and insert into the lateral lip of the intertubercular sulcus of the humerus.<sup>10</sup> Rupture occurs most commonly in patients with a history of weightlifting, causing disruption of the distal humeral entheses.<sup>1-3</sup> Pectoralis major rupture in this patient was strongly suggested by the clinical presentation, but the availability of POCUS to confirm our suspicion assisted in expediting the disposition. Young patients with a history of anabolic steroid use should also be evaluated for tendinous disruption due to decreased tensile strength of the tendons secondary to steroid-induced dysplasia of the collagen fibrils.<sup>11</sup>



**Image 4.** Point-of-care ultrasound image displaying hypoechoic hematoma formation (red circle) in the distal portion of pectoralis major muscle bellies.

Musculoskeletal POCUS was performed with a high-frequency 5-10 megahertz linear probe throughout the distribution of the pectoralis muscle groups with special attention given to the distal portion of the pectoralis major muscle. Abduction and external rotation of the left arm were used to provide robust images of the distal pectoralis major under tension. Healthy pectoralis major muscles should appear hyperechoic and fibrillar throughout the clavicular and sternoclavicular heads with a uniform and taut tendon attaching to the bicipital groove of the humerus.<sup>12,13</sup> In this patient, the muscle bellies of the pectoralis major were identified with obvious disruption of a distal muscle belly present. The observation of hypoechoic interruptions of muscular striation proximal to the musculotendinous junction, distal hematoma formation, and retraction of the distal pectoralis major muscle with an intact tendon suggested rupture of the distal pectoralis major muscle without major tendinous disruption.<sup>14,15</sup>

## CONCLUSION

Prompt evaluation, radiographic confirmation, and surgical intervention is key in ensuring positive outcomes in active patients with pectoralis major tears. Therefore, use of POCUS to aid in the diagnosis is pertinent when attempting to expedite disposition and improve patient care. In this case, POCUS evaluation was an effective adjunct in estimating the extent of injury and promptly involving orthopedic surgery to begin surgical planning with MRI.

Patient consent has been obtained and filed for the publication of this case report.

*Address for Correspondence:* Ryan Joseph, DO, UT Health San Antonio, Department of Emergency Medicine, 7703 Floyd Curl Drive MC 7736, San Antonio, TX 78229. Email: Rjosep4@gmail.com.

*Conflicts of Interest:* By the *CPC-EM* article submission agreement, all authors are required to disclose all affiliations, funding sources and financial or management relationships that could be perceived as potential sources of bias. The authors disclosed none.

*Copyright:* © 2021 Franks et al. This is an open access article distributed in accordance with the terms of the Creative Commons Attribution ([CC BY 4.0](http://creativecommons.org/licenses/by/4.0/)) License. See: <http://creativecommons.org/licenses/by/4.0/>

## REFERENCES

1. ElMaraghy AW and Devereaux MW. A systematic review and comprehensive classification of pectoralis major tears. *J Shoulder Elbow Surg.* 2012;21(3):412-22.
2. Durant EJ and De Cicco FL. Pectoralis major tear. 2020. Available

- at: <https://www.ncbi.nlm.nih.gov/books/NBK549875/>. Accessed September 26, 2020.
3. Wolfe SW, Wickiewicz TL, Cavanaugh JT. Ruptures of the pectoralis major muscle. An anatomic and clinical analysis. *Am J Sports Med.* 1992 Sep-Oct;20(5):587-93.
  4. Rehman A and Robinson P. Sonographic evaluation of injuries to the pectoralis muscles. *AJR Am J Roentgenol.* 2005;184(4):1205-11.
  5. Haley CA and Zacchilli MA. Pectoralis major injuries: evaluation and treatment. *Clin Sports Med.* 2014;33(4):739-56.
  6. Kanayama G, DeLuca J, Meehan WP 3rd, et al. Ruptured tendons in anabolic-androgenic steroid users: a cross-sectional cohort study. *Am J Sports Med.* 2015;43(11):2638-44.
  7. White DW, Wenke JC, Mosely DS, et al. Incidence of major tendon ruptures and anterior cruciate ligament tears in US Army soldiers. *Am J Sports Med.* 2007;35(8):1308-14.
  8. Connell DA, Potter HG, Sherman MF, et al. Injuries of the pectoralis major muscle: evaluation with MR imaging. *Radiology.* 1999;210(3):785-91.
  9. Carrino JA, Chandnani VP, Mitchell DB, et al. Pectoralis major muscle and tendon tears: diagnosis and grading using magnetic resonance imaging. *Skeletal Radiol.* 2000;29(6):305-13.
  10. Solari F and Burns B. Anatomy, thorax, pectoralis major major. 2020 Available at: <https://www.ncbi.nlm.nih.gov/books/NBK525991/>. Accessed September 26, 2020.
  11. Laseter JT and Russell JA. Anabolic steroid-induced tendon pathology: a review of the literature. *Med Sci Sports Exerc.* 1991;23(1):1-3.
  12. Merolla G, Paladini P, Artiaco S, et al. Surgical repair of acute and chronic pectoralis major tendon rupture: clinical and ultrasound outcomes at a mean follow-up of 5 years. *Eur J Orthop Surg Traumatol.* 2015;25(1):91-8.
  13. Lee SJ, Jacobson JA, Kim SM, et al. Distal pectoralis major tears: sonographic characterization and potential diagnostic pitfalls. *J Ultrasound Med.* 2013;32(12):2075-81.
  14. Lee YK, Skalski MR, White EA, et al. US and MR Imaging of pectoralis major injuries. *Radiographics.* 2017;37(1):176-89.
  15. Weaver JS, Jacobson JA, Jamadar DA, et al. Sonographic findings of pectoralis major tears with surgical, clinical, and magnetic resonance imaging correlation in 6 patients. *J Ultrasound Med.* 2005;24(1):25-31.

# Septic Malleolar Bursitis in a Patient with an Ankle Electronic Monitoring Device: A Case Report

Bart Besinger, MD  
Sydney Ryckman, BS

Indiana University School of Medicine, Department of Emergency Medicine,  
Indianapolis, Indiana

Section Editor: Joel Moll, MD

Submission history: Submitted October 16, 2020; Revision received December 10, 2020; Accepted December 9, 2020

Electronically published January 16, 2021

Full text available through open access at [http://escholarship.org/uc/uciem\\_cpccem](http://escholarship.org/uc/uciem_cpccem)

DOI: 10.5811/cpcem.2020.12.50299

**Introduction:** Septic malleolar bursitis is a rare cause of ankle pain and swelling. It has been described in certain occupational and recreational activities that involve tight-fitting boots, such as figure skating. Court-ordered electronic monitoring devices are often worn on the ankle. It is not known whether these devices are a risk factor for the development of malleolar bursitis.

**Case Report:** We describe a 41-year-old male under house arrest with an electronic monitoring device on his right ankle who presented to our emergency department with several days of progressive pain and swelling over the medial malleolus. Point-of-care ultrasound revealed a thick-walled cystic structure consistent with medial malleolar bursitis. Bursal aspiration was performed. Fluid culture yielded *Staphylococcus aureus*.

**Discussion:** Emergency physicians regularly see patients with ankle pain and swelling and must consider a comprehensive differential diagnosis. Septic malleolar bursitis is an uncommon but important cause of ankle pain and swelling that requires prompt diagnosis and intervention. Point-of-care ultrasonography may aid in the diagnosis. Additionally, emergency physicians should be aware of potential complications related to electronic monitoring devices. [Clin Pract Cases Emerg Med. 2021;5(1):97–100.]

**Keywords:** *bursitis; ultrasonography; electronic monitoring device; ankle joint; case report.*

---

## INTRODUCTION

Malleolar bursitis is a rare cause of ankle pain and swelling. In many cases, it can be attributed to ill-fitting footwear or repetitive trauma from occupational or recreational activities such as figure skating. It is unknown whether court-ordered ankle electronic monitoring devices contribute to the development of ankle pathology, including malleolar bursitis. We report a case of a 41-year-old male who developed right medial ankle pain and swelling while wearing such a device. His physical examination was concerning for septic medial malleolar bursitis. This was confirmed with point-of-care ultrasonography and aspiration and culture of bursal fluid. We believe this is the first reported case of malleolar bursitis associated with the use of an electronic monitoring device.

## CASE REPORT

A 41-year-old male with no significant past medical history presented to the emergency department (ED) with pain, redness, and swelling of his right ankle's medial aspect for five days. He first noticed his symptoms while mowing grass. He denied any trauma. At the time of symptom onset, he was under home arrest and was wearing an electronic monitoring device on his right ankle. He was concerned that this device might have been contributing to his symptoms and had it moved to his left lower extremity two days before his presentation to the ED. Despite this, his pain, redness, and swelling continued to worsen. Ibuprofen and heating pads improved his pain but did not reduce the swelling. He noted that his pain was aggravated by ambulation, but he maintained

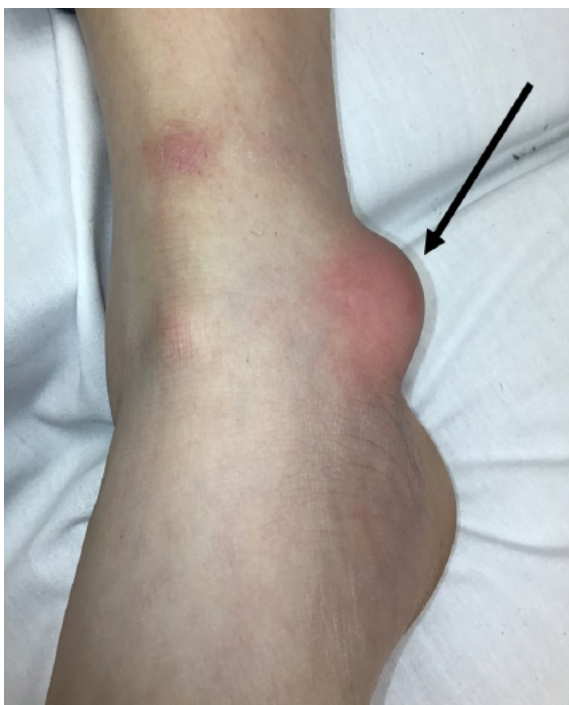the ability to ambulate independently. He denied associated fever or rash. At the time of his presentation to the ED, his pain severity was 7-8 on a 1-10 scale.

On examination, the patient was well appearing. Initial vital signs were as follows: temperature 36.8°C (98.2°F); heart rate 99 beats per minute; respiratory rate 18 breaths per minute; blood pressure 128/82 millimeters mercury; and pulse oximetry 96% on room air. Erythema and swelling were noted overlying the right medial malleolus (Image 1). The area was tender and fluctuant. There was no evidence of trauma to the skin. No crepitus or drainage was present. Distal sensation and pulses were intact, and his ankle had a full range of motion.

Plain radiographs demonstrated marked soft tissue swelling around the ankle joint, most prominent at the medial malleolus. A point-of-care ultrasound was performed, which revealed a 3 centimeter x 1 centimeter thick-walled cystic mass containing fluid of mixed echogenicity, consistent with bursitis (Image 2).

Aspiration of the bursa was performed with an 18-gauge needle, and 3 milliliters of cloudy yellow fluid was removed and sent for culture. No additional studies were obtained. The patient noted decreased pain after the procedure. A presumptive diagnosis of septic medial malleolar bursitis was made, and the patient was discharged with a 10-day course of trimethoprim-sulfamethoxazole. He did not receive antibiotics in the ED.

Gram stain of the aspirated fluid was negative, but culture grew *Staphylococcus aureus*. On telephone follow-up one week later, the patient noted significant symptomatic



**Image 1.** Localized swelling and erythema over the medial malleolus (arrow).

### CPC-EM Capsule

What do we already know about this clinical entity?

*Malleolar bursitis is a well described but uncommon cause of acute ankle pain and swelling, often associated with occupational or recreational activities.*

What makes this presentation of disease reportable?

*Ankle bursitis associated with the use of an electronic monitoring device has not previously been described in the medical literature.*

What is the major learning point?

*Malleolar bursitis may be associated with the use of an electronic monitoring device. Ultrasound may assist in diagnosis.*

How might this improve emergency medicine practice?

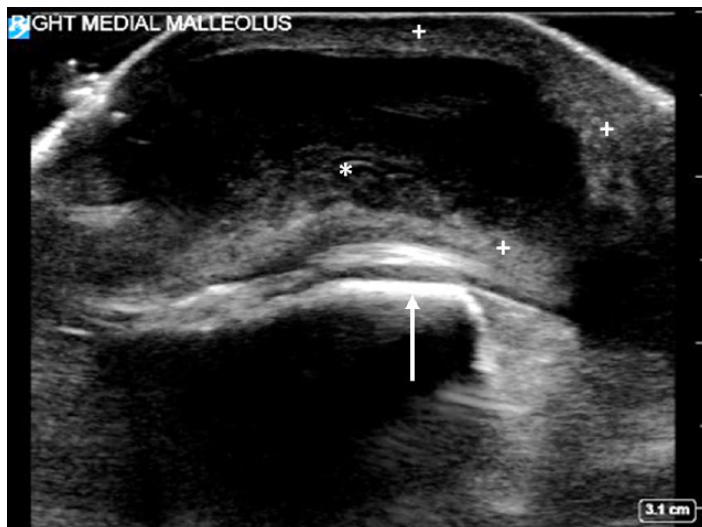
*Clinicians should include malleolar bursitis in the differential diagnosis of ankle pain and swelling in patients wearing an ankle device.*

improvement. Unfortunately, he had not begun taking his antibiotics. He was encouraged to do so. The patient was lost to further follow-up.

### DISCUSSION

Bursae are fluid-containing, extra-articular closed sacs that provide cushioning and relieve friction between skeletal and soft tissue structures, including bone-tendon, bone-skin, and tendon-ligament interfaces. Bursae may be classified as deep or superficial. Deep bursae (eg, subacromial, iliopsoas, and retrocalcaneal) form during embryonic development. Superficial bursae reside in the subcutaneous tissue and tend to develop after birth. Examples include the olecranon and prepatellar bursae. Adventitious superficial bursae are acquired bursae that develop in response to repeated trauma, pressure, or friction.<sup>1,2</sup> They lack a proper synovial lining and are variably present. Two such adventitious bursae may be found in the ankle: the medial and lateral malleolar bursae. They reside in the subcutaneous tissues overlying the bony prominences of the medial and lateral malleoli, allowing the overlying skin to glide more easily.<sup>3-6</sup>

Bursitis is the inflammation of a bursa characterized by bursa wall thickening and excess bursal fluid accumulation, producing localized pain and swelling. It may be septic or



**Image 2.** Ultrasound demonstrating a thick-walled (plus signs) bursa containing complex fluid (asterisk), which overlies the medial malleolus (arrow).

aseptic. Bursitis in some anatomic locations is associated with various occupational and recreational activities, giving rise to numerous descriptive terms such as “carpet layer’s knee” (prepatellar bursitis) and “student’s elbow” (olecranon bursitis).<sup>2</sup>

Aseptic bursitis is commonly caused by repetitive trauma, compression, or shear forces. Still, it may also be caused by crystal deposition or underlying autoimmune disorders such as rheumatoid arthritis or systemic lupus erythematosus.

Septic bursitis occurs when a bursa becomes inoculated with bacteria. This most commonly results from direct penetration of skin flora in the setting of local cutaneous trauma or from the direct spread of an overlying skin infection. Hematogenous spread of infection to bursa has been described but is not common.<sup>1,2</sup> Given the pathogenesis of local inoculation with skin bacteria, it is not surprising that septic bursitis usually occurs in superficial bursae. Patients present with localized pain, swelling, erythema, and warmth. The presence of fever is inconsistent.<sup>2,7</sup>

Clinical features may be unreliable in distinguishing septic from aseptic bursitis; definitive diagnosis is established by culture of bursal aspirate. *S aureus* is the causative agent in approximately 80% of cases.<sup>1,2,7</sup> Streptococci are the second most common cause. Bursa infections with various other bacterial species, including Gram-negative bacilli and anaerobes, have been described but are rare. The treatment of septic bursitis is variable, and there are no well-established guidelines.<sup>1</sup> Treatment typically includes a combination of oral or parenteral antibiotics and needle aspiration or incisional drainage, depending upon disease severity and patient risk factors.

Ultrasound can be useful in establishing the diagnosis of bursitis, as demonstrated by our case. Normal bursae are challenging to visualize with ultrasound and are often invisible.

In bursitis, the bursa appears as a cystic structure with a thickened hyperechoic wall. The fluid within the bursa may be anechoic, or it may demonstrate mixed echogenicity in the setting of a complex or bloody bursal effusion.<sup>8</sup> The use of ED point-of-care ultrasonography for bursitis has been described, but its performance and utility have not been well characterized.<sup>9-11</sup>

There are approximately 150 bursae in the human body, but the vast majority of bursitis cases encountered by the emergency physician occur in only two: the olecranon or prepatellar bursae.<sup>2,4</sup> Bursitis of the malleolar bursae, as described in our case, is relatively uncommon but deserves inclusion in the differential diagnosis of ankle pain and swelling. Like bursitis in other anatomic locations, malleolar bursitis may be septic or aseptic and is often caused by local microtrauma, shear forces, and compression. Lateral malleolar bursitis has been described in patients who sit cross-legged for prolonged periods of time, including children, tailors, and coal miners working in low-seam underground mine environments.<sup>3,6,11,12</sup> An association with ill-fitting shoes has also been reported.<sup>12</sup>

Medial malleolar bursitis has been described in figure skaters and attributed to excessive contact pressure and shear forces that occur between the medial malleolus and snugly fitting skater’s boots while the skater is performing mechanical movements that include jumping, twisting, and changes in direction.<sup>4,13</sup> Aseptic malleolar bursitis often responds well to conservative therapy, including modification of inciting factors such as footwear or activity. Aspiration of the bursa and injection of steroids may be considered.<sup>4</sup> Surgical bursectomy has been employed for recalcitrant cases. Septic malleolar bursitis is treated with drainage and anti-staphylococcal antibiotics in a manner similar to septic bursitis in other anatomic locations. Surgical intervention may be necessary in some cases.<sup>4,5,13</sup>

We report a patient with medial malleolar bursitis who had no apparent occupational or recreational risk factor and no underlying medical conditions. He reported having a court-ordered ankle electronic monitoring device on his ankle prior to developing symptoms. To our knowledge, no case of malleolar bursitis in a patient with an electronic monitoring device has been reported in the medical literature. An exhaustive search of the literature failed to reveal any reports of adverse medical effects of ankle electronic monitoring devices; however, there have been recent reports of lower extremity skin irritation and infection on advocacy websites and in the lay press.<sup>14,15</sup> Although it is impossible to definitively establish causation, it is conceivable that such a device may have produced shear or pressure forces on the medial malleolus and microtrauma to the overlying skin provoking the development of septic medial malleolar bursitis in our patient.

## CONCLUSION

Emergency physicians regularly see patients with ankle pain and swelling and must consider a broad differential

diagnosis. Septic malleolar bursitis is an uncommon but important cause of ankle pain and swelling that requires prompt diagnosis and intervention. Point-of-care ultrasonography may aid in the diagnosis. Additionally, emergency physicians should be aware of potential complications related to electronic monitoring devices.

The authors attest that their institution requires neither Institutional Review Board approval, nor patient consent for publication of this case report. Documentation on file.

*Address for Correspondence:* Bart Besinger, MD, Indiana University School of Medicine, Department of Emergency Medicine, 1701 N. Senate Ave, Room AG012, Indianapolis, IN 46202. Email: brbesing@iu.edu.

*Conflicts of Interest:* By the CPC-EM article submission agreement, all authors are required to disclose all affiliations, funding sources and financial or management relationships that could be perceived as potential sources of bias. The authors disclosed none.

*Copyright:* © 2021 Besinger et al. This is an open access article distributed in accordance with the terms of the Creative Commons Attribution (CC BY 4.0) License. See: <http://creativecommons.org/licenses/by/4.0/>

## REFERENCES

1. Lormeau C, Cormier G, Sigaux J, et al. Management of septic bursitis. *Joint Bone Spine*. 2019;86(5):583-8.
2. Zimmermann B 3rd, Mikolich DJ, Ho G Jr. Septic bursitis. *Semin Arthritis Rheum*. 1995;24(6):391-410.
3. Bermingham WH and Klaber RE. 'Coal miner's ankle' in a child: bilateral malleolar bursitis. *Arch Dis Child*. 2012;97(11):1009.
4. Brown TD, Varney TE, Micheli LJ. Malleolar bursitis in figure skaters. Indications for operative and nonoperative treatment. *Am J Sports Med*. 2000;28(1):109-11.
5. Hashimoto I, Yoshinaga R, Toda M, et al. Intractable malleolar bursitis treated with lateral calcaneal artery adipofascial flap. *Br J Plast Surg*. 2003;56(7):701-3.
6. Hunt TA. Bursitis in miners' ankles: the best ankle and allied conditions in miners' ankles. *Occup Med*. 1955;4(4):122-4.
7. Wasserman AR, Melville LD, Birkhahn RH. Septic bursitis: a case report and primer for the emergency clinician. *J Emerg Med*. 2009;37(3):269-72.
8. Ivanoski S and Nikodinovska VV. Sonographic assessment of the anatomy and common pathologies of clinically important bursae. *J Ultrason*. 2019;19(78):212-21.
9. Costantino TG, Roemer B, Leber EH. Septic arthritis and bursitis: emergency ultrasound can facilitate diagnosis. *J Emerg Med*. 2007;32(3):295-7.
10. Situ-LaCasse E, Grieger RW, Crabbe S, et al. Utility of point-of-care musculoskeletal ultrasound in the evaluation of emergency department musculoskeletal pathology. *World J Emerg Med*. 2018;9(4):262-6.
11. Avci S and Sayli U. Lateral premalleolar bursitis as a result of sitting on the foot. *Foot Ankle Int*. 2001;22(1):64-6.
12. Layfer LF. 'Last' bursitis: a cause of ankle pain. *Arthritis Rheum*. 1980;23(2):261.
13. Parchi P and Addevero F. Surgical treatment for a relapsing malleolar bursitis in a professional figure skating: case report. *Orthop Muscular Syst*. 2016;5(1):1-3.
14. Boczkiewicz R. Lawsuit: tight ankle monitor sent Pueblo man to hospital. The *Pueblo Chieftain*. 2020. Available at: <https://www.chieftain.com/news/20200229/lawsuit-tight-ankle-monitor-sent-pueblo-man-to-hospital>. Accessed October 16, 2020.
15. Kilgore J. Michael Robinson: The wounds of an ankle shackle. 2020. Available at: <https://www.challengingcarceration.org/2020/01/31/michael-robinson-the-wounds-of-an-ankle-shackle/>. Accessed October 16, 2020.

# Hyperhemolysis Syndrome in a Patient with Sickle Cell Disease: A Case Report

Joshua A. Kalter, BS\*  
Ranju Gupta, MD†  
Marna Rayl Greenberg, DO, MPH\*  
Andrew J. Miller, MD\*  
Jamie Allen, DO\*

\*USF Morsani College of Medicine, Lehigh Valley Health Network, Department of Emergency and Hospital Medicine, Allentown, Pennsylvania  
†USF Morsani College of Medicine, Lehigh Valley Health Network, Division of Hematology Oncology, Allentown, Pennsylvania

Section Editor: R. Gentry Wilkerson, MD

Submission history: Submitted October 19, 2020; Revision received December 10, 2020; Accepted December 18, 2020

Electronically published January 26, 2021

Full text available through open access at [http://escholarship.org/uc/uciem\\_cpchem](http://escholarship.org/uc/uciem_cpchem)

DOI: 10.5811/cpchem.2020.12.50349

**Introduction:** Hyperhemolysis syndrome (HHS) is a rare complication of repeat blood transfusions in sickle cell disease (SCD). This can occur acutely or have a delayed presentation and often goes unrecognized in the emergency department (ED) due to its rapid progression and similarity to acute chest syndrome and other common complications of SCD.

**Case Report:** We present a case of a 20-year-old male with SCD who presented to the ED with pain and tenderness in his lower extremities one day after discharge for a crisis. Unbeknownst to the ED team, during his admission he had received a blood transfusion. On presentation he was noted to have hyperkalemia, hyperbilirubinemia, anemia, and uncontrolled pain, and was admitted for sickle cell pain crisis. Over the next 36 hours, his hemoglobin dropped precipitously from 8.9 grams per deciliter (g/dL) to 4.2 g/dL (reference range: 11.5-14.5 g/dL), reticulocyte count from 11.7 % to 3.8% (0.4-2.2%), and platelets from 318,000 per cubic centimeter (K/cm<sup>3</sup>) to 65 K/cm<sup>3</sup> (140-350 K/cm<sup>3</sup>). He also developed a fever, hypoxia, transaminitis, a deteriorating mental status, and severe lactic acidosis. Hematology was consulted and he was treated with methylprednisolone, intravenous immunoglobulin, two units of antigen-matched red blood cells, fresh frozen plasma, and cryoprecipitate. He was transferred to an outside hospital for exchange transfusion and remained hospitalized for 26 days with acute liver failure, bone marrow necrosis, and a fever of unknown origin.

**Conclusion:** Because of the untoward outcomes associated with delay in HHS diagnosis and the need for early initiation of steroids, it is important for emergency providers to screen patients with hemoglobinopathies for recent transfusion at ED presentation. Asking the simple question about when a patient's last transfusion occurred can lead an emergency physician to include HHS in the differential and work-up of patients with sickle cell disease complications. [Clin Pract Cases Emerg Med. 2021;5(1):101–104.]

**Keywords:** *Hyperhemolysis; Sickle Cell Disease; disseminated intravascular coagulation.*

## INTRODUCTION

Sickle cell disease (SCD) is a common genetic hemoglobinopathy that has a wide variety of clinical manifestations due to the propensity of deoxygenated hemoglobin to polymerize.<sup>1,2</sup> Sickle hemoglobin (HbS) is one of the variants in this hemoglobinopathy that can lead to

hemolytic anemia and vaso-occlusion causing ischemic organ damage, pain crises, stroke, infection, and organ failure.<sup>1,2</sup> Acute vaso-occlusive episodes are generally treated with hydration, antibiotics, pain relief, and, when indicated, red blood cell transfusions.<sup>1-4</sup> Multiple transfusions increase the risk of alloimmunization whereby host antibodies recognize

foreign surface antigens on transfused red blood cells and cause hemolysis.<sup>3,4</sup>

Hyperhemolysis syndrome (HHS), is a rare hemolytic transfusion reaction characterized by a lower hemoglobin (Hb) than pre-transfusion, fever and pain, decreased reticulocyte count, hyperbilirubinemia, raised lactate dehydrogenase, and hemoglobinuria generally occurring within two weeks of last transfusion.<sup>3,4</sup> The cause of the precipitous drop in Hb remains a debate. King et al proposed the bystander hemolysis mechanism in 1997 followed in 2004 by Petz and Garratty who described any immune hemolysis of cells that are negative for the antigen against which the relevant antibody is directed.<sup>5,6</sup> The other theory, also first described by Petz et al, suggested a transfusion-induced reticulocytopenia and suppression of erythropoiesis.<sup>7</sup> Complement-mediated lysis and macrophage activation may be a possible mechanism: All these processes are immune-mediated.

The treatment for HHS typically involves immunosuppression with steroids (namely methylprednisolone) as well as intravenous immunoglobulin (IVIG). Hyperhemolysis syndrome is generally divided into an acute and a delayed form based upon its development within seven days vs after seven days of transfusion, respectively. Patients presenting with acute chest syndrome (ACS), aplastic crises, or vaso-occlusive symptoms of SCD may also experience hemoglobinuria, pain, fever, and anemia, making the appropriate diagnosis challenging.<sup>8,9</sup> Rapid diagnosis of HHS is essential as delay in diagnosis can lead to death.<sup>10</sup>

## CASE REPORT

A 20-year-old male with a history of SCD with multiple priapism attacks, ACS, functional asplenia, and sleep apnea presented to the ED with pain and tenderness bilaterally in his lower posterior legs and hips. He had been discharged one day prior from a stay in the hospital for a sickle cell crisis, involving priapism, fever, and generalized pain. Although it was not noted in his intake history, he had received partial exchange transfusion of two units of packed red blood cells (PRBC) four days prior. At the time of arrival, the patient denied any chest pain, shortness of breath, nausea, vomiting, abdominal pain, or genitourinary or gastrointestinal dysfunction including priapism. He reported one episode of a fever at home. Upon examination, there was tenderness to the patient's bilateral thighs and scleral icterus. Labs revealed a Hb of 8.9 grams per deciliter (g/dL) (reference range: 11.5-14.5 g/dL), white blood count (WBC) of 16.7 thousand per centimeter cubed ( $K/cm^3$ ) ( $4.0-10.0 K/cm^3$ ), a reticulocyte count of 11.7 (0.4-2.2%), potassium of 5.4 millimoles per liter (mmol/L) (3.5-5.1 mmol/L), bilirubin of 14.5 milligrams (mg)/dL (0.2-1.0 mg/dL). The patient was admitted for a sickle cell crisis and treated with hydration and analgesics. Of note, historically, the patient's bilirubin had previously been 6.8 mg/dL (0.2-1.0mg/dL).

The next day, he developed fever (102.6° Fahrenheit), tachycardia, hypoxia, and diminishing mental status. Labs

### *CPC-EM Capsule*

What do we already know about this clinical entity?

*Hyperhemolysis syndrome (HHS) is a rare complication of repeat blood transfusions in sickle cell disease (SCD).*

What makes this presentation of disease reportable?

*Lack of information about a prior transfusion in a young male with SCD who presented with declining mental status and fever led to delayed diagnosis of HHS.*

What is the major learning point?

*Given the outcomes associated with delay in diagnosis and the need for early initiation of steroids, patients with hemoglobinopathies must be screened for recent transfusion.*

How might this improve emergency medicine practice?

*Asking a patient when their last transfusion occurred can lead the provider to include HHS in the differential and work-up of patients with SCD complications.*

revealed Hb of 6.0 g/dL (11.5-14.5 g/dL), a decrease in platelets from 318 to 154K/cm<sup>3</sup> (140-350 K/cm<sup>3</sup>), and an increasing WBC count of 17.9K/cm<sup>3</sup> (4.0-10.0 K/cm<sup>3</sup>). Hematology/oncology was consulted, and the patient was transferred to the intensive care unit out of concern for a delayed hemolytic transfusion reaction. Labs drawn later that night showed a hemoglobin level of 4.2 g/dL (11.5-14.5 g/dL), a reticulocyte count of 3.8 (0.4-2.2%), a platelet count of 65 K/cm<sup>3</sup> (140-350 K/cm<sup>3</sup>), and schistocytes on peripheral blood smear. The direct antiglobulin test and antibody screen were negative. A disseminated intravascular coagulation (DIC) panel had been ordered due to worsening condition, which showed fibrinogen of less than 166 mg/dL (180-500mg/dL) and D-dimer greater than 20 micrograms per milliliter (ug/mL) (less than 0.50ug/ml), prothrombin time of 28.9 seconds (s) (12.0-14.6s), international normalized ratio of 2.8, and partial thromboplastin time of 74.8s (21.6-35.6s).

Due to continued rapid deterioration and concern for HHS he was started on methylprednisolone and IVIG. Additionally, he was given two units fresh frozen plasma, 10 units cryoprecipitate (due to possible DIC), and 1 unit of PRBC. He was given IVIG (a dose of 0.5 mg/kg) due to

rising levels of plasma creatinine and concern for renal injury. The patient needed increasing oxygen by nasal cannula. The differential included HHS, thrombotic thrombocytopenic purpura (TTP) and ACS. Urgent plasmapheresis for possible TTP was attempted but was stopped due to equipment failure. The patient was transferred to an outside hospital for exchange transfusion, where he remained hospitalized with multiorgan failure and persistent fever. Extensive autoimmune and infectious disease workup was done and found to be negative. Despite severe anemia he was not transfused due to the diagnosis of HHS, and he eventually improved after 40 days.

## DISCUSSION

Part of the diagnostic challenge of identifying HHS in SCD is that symptoms are largely similar to those of the general vaso-occlusive crises that patients with SCD experience.<sup>3-4,8-9</sup> The common symptoms of hemoglobinuria, fever, pain, jaundice and the complications of ACS and liver damage were seen in our patient, and do not differ greatly from his presenting symptoms for previous hospitalizations and are not uncommon for a patient with an underlying disease of chronic hemolysis.<sup>8,9</sup> While decreased reticulocyte count and nadir hemoglobin – lower than presenting values, hyperbilirubinemia, and lactic acidosis are important diagnostic components of hyperhemolysis syndrome,<sup>3,4</sup> they were not seen until the day after admission and coincided with a dramatic decline in the patient's condition. Additionally, his declining mental status, fever, renal impairment, thrombocytopenia, and microangiopathic hemolytic anemia were initially thought to be from an infectious etiology or TTP.<sup>11</sup> Although uncommon, TTP has been reported in patients with SCD.<sup>12,13</sup>

The key for an emergency physician to successfully make this diagnosis is timing. Per Shah et al, 86.9% of adults and 93.2% of children experience three or less vaso-occlusive crises each year, and moderate-to- severe vaso-occlusive crises often require blood transfusion and hospital admission for several days or longer.<sup>14</sup> Patients with acute or delayed HHS present within 7-14 days of a blood transfusion. Therefore, an emergency physician should have a high index of suspicion for HHS when a sickle cell patient presents with severe anemia within two weeks of a transfusion. While it is a rare event, with hyperhemolysis reportedly complicating only 3% of transfusions given to patients with SCD,<sup>15</sup> asking about recent blood transfusions is paramount when trying to differentiate HHS from ACS and these questions should be included when emergency physicians care for patients with SCD. Even though transfusions may not have been indicated in their prior care, for those who have had a recent transfusion, communicating with the admission team and hemoncologist the possibility of HHS allows potentially for earlier, more definitive care and the case evolves in that direction. Our case highlights the importance of screening for recent transfusions in patients with hemoglobinopathies. The subtle differences

between HHS and vaso-occlusive crisis in SCD were not readily identifiable until the patient's condition had markedly declined.

## CONCLUSION

Earlier identification of recent transfusions allows for the appropriate treatment (steroids) for HHS to be initiated. While HHS is rare, it is important for emergency clinicians to screen for prior transfusions in patients with SCD to consider HHS as a diagnosis in these cases.

The authors attest that their institution requires neither Institutional Review Board approval, nor patient consent for publication of this case report. Documentation on file.

---

*Address for Correspondence:* Marna Rayl Greenberg, DO, MPH, Lehigh Valley Health Network, Department of Emergency and Hospital Medicine, VH-M-5th floor EM Residency S, 2545 Schoenersville Road, Bethlehem, PA 18017. Email: mrgdo@ptd.net.

*Conflicts of Interest:* By the *CPC-EM* article submission agreement, all authors are required to disclose all affiliations, funding sources and financial or management relationships that could be perceived as potential sources of bias. The authors disclosed none.

*Copyright:* © 2021 Kalter et al. This is an open access article distributed in accordance with the terms of the Creative Commons Attribution ([CC BY 4.0](http://creativecommons.org/licenses/by/4.0/)) License. See: <http://creativecommons.org/licenses/by/4.0/>

---

## REFERENCES

1. Piel FB, Steinberg MH, Rees DC. Sickle cell disease. *N Engl J Med*. 2017;376(16):1561-73.
2. Ware RE, de Montalembert M, Tshilolo L, et al. Sickle cell disease. *Lancet*. 2017;390(10091):311-23.
3. Win N. Hyperhemolysis syndrome in sickle cell disease. *Expert Rev Hematol*. 2009;2(2):111-5.
4. Banks M and Shikle J. Hyperhemolysis syndrome in patients with sickle cell disease. *Arch Pathol Lab Med*. 2018;142(11):1425-7.
5. King KE, Shirey RS, Lankiewicz MW, et al. Delayed hemolytic transfusion reactions in sickle cell disease: simultaneous destruction of recipients' red cells. *Transfusion*. 1997;37(4):376-81.
6. Petz LD and Garratty G. (2004). Mechanisms of Immune Hemolysis In: Petz LD, Garratty, G (Eds.), *Bystander Immune Haemolysis Immune Haemolytic Anaemias* (p. 133-65). Philadelphia, PA: Churchill Livingstone.
7. Petz LD, Calhoun L, Shulman IA, et al. The sickle cell hemolytic transfusion reaction syndrome. *Transfusion*. 1997;37(4):382-92.
8. Habibi A, Mekontso-Dessap A, Guillaud C, et al. Delayed hemolytic transfusion reaction in adult sickle-cell disease: presentations,

- outcomes, and treatments of 99 referral center episodes. *Am J Hematol.* 2016;91(10):989-94.
9. Talano JA, Hillery CA, Gottschall JL, et al. Delayed hemolytic transfusion reaction/hyperhemolysis syndrome in children with sickle cell disease. *Pediatrics.* 2003;111(6 Pt 1):e661-5.
  10. Srinivasan A and Gourishankar A. A differential approach to an uncommon case of acute anemia in a child with sickle cell disease. *Glob Pediatr Health.* 2019;6:2333794X19848674.
  11. George JN and Nester CM. Syndromes of thrombotic microangiopathy. *N Engl J Med.* 2014;371(7):654-66.
  12. Kodali S, Ramachandran P, Richard IN, et al. TTP-like syndrome associated with hemoglobin SC disease treated successfully with plasma and red cell exchange. *Leuk Res Rep.* 2019;12:100179.
  13. Lee HE, Marder VJ, Logan LJ, et al. Life-threatening thrombotic thrombocytopenic purpura (TTP) in a patient with sickle cell-hemoglobin C disease. *Ann Hematol.* 2003;82(11):702-4.
  14. Shah N, Bhor M, Xie L, et al. Evaluation of vaso-occlusive crises in United States sickle cell disease patients: a retrospective claims-based study. *J Health Econ Outcomes Res.* 2019;6(3):106-17.
  15. El-Husseini A and Sabry A. Fatal hyperhemolytic delayed transfusion reaction in sickle cell disease: a case report and literature review. *Am J Emerg Med.* 2010;28(9):1062.e5-8.

# Don't Forget the Flu – Determining the Etiology of Infective Myositis in a Child: A Case Report

Lauren M. Crowley, BA\*  
Richard J. Mazzaccaro, MD, PhD†  
Amy Lewis Dunn, DO, MPH‡  
Sarah E. Bauch, MD\*  
Marna Rayl Greenberg, DO, MPH\*

\*University of South Florida Morsani College of Medicine, Lehigh Valley Campus, Lehigh Valley Health Network, Department of Emergency and Hospital Medicine, Allentown, Pennsylvania  
†University of South Florida Morsani College of Medicine, Lehigh Valley Campus, Lehigh Valley Health Network, Department of Pediatrics, Allentown, Pennsylvania  
‡University of South Florida Morsani College of Medicine, Lehigh Valley Campus, Lehigh Valley Health Network, Department of Emergency and Hospital Medicine, Division of Pediatric Emergency Medicine, Allentown, Pennsylvania

Section Editor: Steven Walsh, MD

Submission history: Submitted October 22, 2020; Revision received December 14, 2020; Accepted December 18, 2020

Electronically published January 26, 2021

Full text available through open access at [http://escholarship.org/uc/uciem\\_cpchem](http://escholarship.org/uc/uciem_cpchem)

DOI: 10.5811/cpchem.2020.12.50405

**Introduction:** Infective myositis is an acute, self-limited condition, rarely occurring in children with recent viral infections. The condition is often overlooked by emergency physicians when endeavoring to exclude other diagnoses included in the differential. Diagnosis of the condition can be difficult when based purely on clinical presentation because it shares symptoms with much more concerning neurological illnesses. A few simple laboratory tests are indicated to reach the correct diagnosis.

**Case Report:** The following case report describes a three-year-old female diagnosed with a recent upper respiratory tract infection presenting to the emergency department with complaints of fatigue and inability to walk. She was diagnosed with an influenza-like illness three days prior by her pediatrician, the symptoms of which had mostly resolved by the time of presentation.

**Conclusion:** Muscle weakness and abnormal, uncoordinated gait with an acute upper respiratory tract infection in a child may be cause for concern, prompting unnecessary work-up. Emergency physicians should be aware of the signs and symptoms of influenza-associated infective myositis in children, especially during influenza season. [Clin Pract Cases Emerg Med. 2021;5(1):105–108.]

**Keywords:** *Infective myositis; influenza A; upper respiratory tract infection; pediatrics; case report.*

## INTRODUCTION

Infective myositis is an acute, self-limiting condition that occurs in children with a history of recent viral infection; while there are reports in those with influenza A, it is a significantly more frequent complication in children with influenza B infections.<sup>1,2</sup> This condition affects males more often than females (about 2:1).<sup>2</sup> Characteristic clinical and laboratory features of infective myositis include reluctance or refusal to walk, with intense pain in the lower extremities (most notably swelling and tenderness in the gastrocnemius or soleus muscles) causing abnormal gait, elevated serum creatine kinase (CK)

levels, and positive viral studies.<sup>3</sup> Normal or decreased white blood cell and platelet counts are indicative of an immune response to the recent viral infection,<sup>3</sup> which is most commonly diagnosed as an upper respiratory tract infection.<sup>1</sup>

A complication in diagnosing infective myositis is its onset, which begins in the early convalescent phase of illness, about three days after the onset of fever and respiratory symptoms.<sup>1</sup> Despite its generally good prognosis,<sup>2</sup> myositis is a commonly missed diagnosis. Early consideration and diagnosis of myositis may help prevent an extensive diagnostic work-up and unnecessary, costly laboratory testing or neuroimaging. We

describe a case of a three-year-old female with infective myositis due to influenza A.

### CASE REPORT

A three-year-old female with a past medical history of asthma presented to the emergency department (ED) with fatigue and generalized body aches. The patient complained that her “legs were tired,” and her mother stated that she was unable to walk and could only crawl since waking that morning. She had been diagnosed with an influenza-like illness three days prior by her pediatrician, the symptoms of which had mostly resolved by the time of presentation except for cough and rhinorrhea. She had been afebrile for 36 hours prior to ED presentation.

Vital signs included the following: blood pressure 108/89 millimeters of mercury, temperature 37.6°Celsius, respirations 22 breaths per minute, and oxygen saturation on room air of 99%. Physical examination was remarkable for cervical lymphadenopathy and abnormal coordination and gait. Specifically, the child was alert with mentation appropriate for age, and she had no pupil abnormalities and no slurring of speech. The remainder of her neurological exam (including reflexes) was normal and without focal deficit. The patient had a wide-based, shuffling gait, and while she slightly favored her right leg and hip she had no restricted range of motion of the hips or knees and had no pain in the joints to movement or palpation.

Laboratory serum chemistries were significant for elevated CK levels (319 units per liter (U/L) [normal <201 U/L]) indicating myositis; creatinine 0.34 milligrams per deciliter (mg/dL) (0.39-0.55 mg/dL); alkaline phosphatase 128 U/L (156-369 U/L); and aspartate aminotransferase 65 U/L (26-55 U/L). Trace amounts of protein were found in her urine. Rapid strep A test was negative. Comprehensive respiratory pathogen profile polymerase chain reaction detected influenza A-matrix and influenza A-H3. Complete blood count results showed decreased white blood cell count (3.1 thousand per centimeters cubed [K/cm<sup>3</sup>] [6.0-17.0 K/cm<sup>3</sup>]) consistent with a viral infection. This patient had not been vaccinated for that year’s strain of influenza.

The patient was admitted from the ED for observation overnight and given intravenous fluids, oseltamivir, and ketorolac to treat the flu and pain and inflammation, respectively. Infective myositis of the bilateral lower extremities was determined as the principal problem. By the next morning, she was able to walk without significant pain, showed no signs of ataxia, remained afebrile, and tolerated oral medications. The patient was discharged home 27 hours after initial presentation and instructed to continue ibuprofen every six hours for the next one to two days.

### DISCUSSION

Given that most cases of infective myositis are in males with influenza B, this case of a young female with infective myositis due to influenza A is less common.<sup>2</sup> To avoid

#### CPC-EM Capsule

What do we already know about this clinical entity?

*Infective myositis is an acute, self-limited condition, rarely occurring in children with recent viral infections.*

What makes this presentation of disease reportable?

*The condition is often overlooked by emergency physicians when trying to exclude other diagnoses included in the differential.*

What is the major learning point?

*Emergency physicians should be aware of the signs and symptoms of influenza-associated infective myositis in children, especially during influenza season.*

How might this improve emergency medicine practice?

*Early consideration and diagnosis of myositis may help prevent an extensive diagnostic work-up and unnecessary, costly lab testing or neuroimaging.*

potential neurological damage, physicians quickly assessed her condition for the best outcome. Upon admission, the initial concern was for cerebellar ataxia with flu-like symptoms due to difficulty walking, muscle weakness, and abnormal coordination. In general, it can be difficult to distinguish between pain from muscle inflammation, muscle weakness, and uncoordinated ambulation in young children due to their lack of cooperation and developmental stage.<sup>3</sup> In a child with myositis, the gait can be nonspecific; it sometimes mimics ataxia but can also appear as “toe-walking” due to pain and resistance to flexing and extending at the ankle.<sup>3</sup>

Children with myositis do not need the extensive work-up that children with ataxia sometimes need. Because the patient demonstrated normal reflexes, had no speech abnormalities, headaches, seizures, or altered mental status, and had no history of trauma, toxic ingestion, or a previous ataxic episode, diagnoses such as acute cerebellitis, stroke, peripheral neuropathy, and metabolic disorders were able to be excluded.<sup>4</sup> Imaging and radiology studies were deemed unnecessary in this case, but may be indicated for longer duration of ataxic symptoms or if the patient’s history suggests possibility of intracranial pathology.<sup>5</sup>

The most significant historical detail in this case was the patient's recent upper respiratory tract infection. Viral studies were ordered to determine the underlying cause of infection. Influenza A is known to be associated with infective myositis as well as conditions such as Guillain-Barré syndrome (GBS), rhabdomyolysis, and acute, post-infectious cerebellar ataxia.<sup>1,6,7</sup> Guillain-Barré syndrome is a post-infectious disorder that may cause ataxia. Patients generally experience bilateral, symmetric lower extremity weakness, often with the presence of sensory symptoms, and pain that can present as a refusal to walk in a young, non-verbal child.<sup>6</sup> Absent or decreased deep-tendon reflexes is a principal feature of GBS, and cerebrospinal fluid protein levels are often elevated as determined by lumbar puncture (LP).<sup>6</sup> Since these clinical defining criteria were not present, we ruled out GBS in our case and a LP was not performed. Had we not been as confident in the clinical exam, an LP could have been done to look for cytoalbuminologic dissociation.

Rhabdomyolysis is a rare complication of myositis, possibly leading to renal failure or compartment syndrome. Influenza A and B, parainfluenza, coxsackievirus infection, Epstein-Barr virus, herpes simplex, adenovirus, and cytomegalovirus have been associated with rhabdomyolysis.<sup>8</sup> Influenza A is more common in cases of rhabdomyolysis than influenza B, and more often occurs in young females than young males – the opposite of common characteristics found with infective myositis.<sup>1,2</sup>

Acute post-infectious cerebellar ataxia accounts for about 30-50% of acute ataxia cases in children<sup>7</sup> and is the most common cause of acute ataxia in the post-varicella vaccination era.<sup>9</sup> It should be highly considered in the differential diagnosis of a child with gait abnormalities. Acute post-infectious cerebellar ataxia can qualify as a neurologic emergency due to rapid onset of symptoms in otherwise healthy individuals with normal mental status.<sup>10</sup> In contrast to our patient, clinically the presentation may include slurring of speech, abnormal coordination in balance, or uncoordinated motions of the hands or feet. It is often the result of an autoimmune-mediated inflammatory response, triggered by an infection.<sup>11</sup>

Varicella zoster virus was the most commonly reported etiology prior to widespread vaccination in children;<sup>12</sup> overall varicella incidence decreased by 84.6% from the implementation of one-dose to two-dose recommendation.<sup>13</sup> According to the 2017 National Immunization Survey, an overwhelming majority of children aged 19-35 months received one or more doses of the varicella vaccine (91.0%).<sup>14</sup> Enterovirus, Epstein-Barr virus, hepatitis A, herpes simplex, influenza, measles, mumps, and parvovirus B19 have been associated with acute ataxia following acute infection<sup>4,12</sup>; therefore, one of these viruses is more likely to be related to a child's post-infectious ataxic symptoms than varicella.

With the recent uptick of enterovirus D68 outbreaks in children over the past 10 years,<sup>15</sup> physicians may be specifically aware of enterovirus-associated cases of infective

myositis in addition to influenza. Additionally, a consideration is acute flaccid myelitis, which can also present with normal mentation and isolated limb weakness and gait abnormalities. Yet more often than not, it is influenza A or B that is responsible for myositis and its clinical manifestations of an antalgic gait and muscle weakness/fatigue. Treatment with oseltamivir may be necessary for influenza symptoms, but the symptoms of myositis typically resolve within a few days with hydration and supportive care.

Based on the severity of the pediatric patient's presenting symptoms, emergency physicians should consider a wide array of etiologies with a child presenting with inability or refusal to walk, including infection, trauma, intoxication, accidental ingestion, and hereditary and neurological disorders.<sup>3</sup> Emergency physicians should be aware of the signs and symptoms of infective myositis due to influenza in order to prevent any unnecessary testing and aid in making an accurate clinical judgment.

## CONCLUSION

A case of muscle weakness and abnormal gait in the setting of an acute upper respiratory tract infection in a child may be cause for concern of a serious neurological diagnosis and prompt unnecessary work-up. Performing a thorough neurological exam and the findings of myositis, especially in the right season, can help streamline the appropriate differential and aid in patient care.

The authors attest that their institution requires neither Institutional Review Board approval, nor patient consent for publication of this case report. Documentation on file.

---

*Address for Correspondence:* Marna Rayl Greenberg, DO, MPH, University of South Florida Morsani College of Medicine Lehigh Valley Health Network, Department of Emergency and Hospital Medicine, 2545 Schoenersville Road, Bethlehem, PA 18017. Email: Marna.Greenberg@lvhn.org.

*Conflicts of Interest:* By the CPC-EM article submission agreement, all authors are required to disclose all affiliations, funding sources and financial or management relationships that could be perceived as potential sources of bias. The authors disclosed none.

*Copyright:* © 2021 Crowley et al. This is an open access article distributed in accordance with the terms of the Creative Commons Attribution (CC BY 4.0) License. See: <http://creativecommons.org/licenses/by/4.0/>

---

## REFERENCES

1. Hu JJ, Kao CL, Lee PI, et al. Clinical features of influenza A and B in children and association with myositis. *J Microbiol Immunol Infect.*

- 2004;37(2):95-8.
2. Szenborn L, Toczek-Kubicka K, Zaryczanski J, et al. Benign acute childhood myositis during influenza B outbreak. *Adv Exp Med Biol.* 2018;1039:29-34.
  3. Magee H and Goldman RD. Viral myositis in children. *Can Fam Physician.* 2017;63(5):365-368.
  4. Fogel BL. Childhood cerebellar ataxia. *J Child Neurol.* 2012;27(9):1138-45.
  5. Rudloe T, Prabhu SP, Gorman MP, et al. The yield of neuroimaging in children presenting to the emergency department with acute ataxia in the post-varicella vaccine era. *J Child Neurol.* 2015;30(10):1333-9.
  6. Van Doorn PA, Ruts L, Jacobs BC. Clinical features, pathogenesis, and treatment of Guillain-Barré syndrome. *Lancet Neurol.* 2008;7(10):939-50.
  7. Rossi A, Martinetti C, Morana G, et al. Neuroimaging of infectious and inflammatory diseases of the pediatric cerebellum and brainstem. *Neuroimaging Clin N Am.* 2016;26(3):471-87.
  8. Nauss MD, Schmidt EL, Pancioli AM. Viral myositis leading to rhabdomyolysis: a case report and literature review. *Am J Emerg Med.* 2009;27(3):372.e5-6.
  9. Thakkar K, Maricich SM, Alper G. Acute ataxia in childhood: 11-year experience at a major pediatric neurology referral center. *J Child Neurol.* 2016;31(9):1156-60.
  10. Pedroso JL, Vale TC, Braga-Neto P, et al. Acute cerebellar ataxia: differential diagnosis and clinical approach. *Arq Neuropsiquiatr.* 2019;77(3):184-93.
  11. Naselli A, Pala G, Cresta F, et al. Acute post-infectious cerebellar ataxia due to co-infection of human herpesvirus-6 and adenovirus mimicking myositis. *Ital J Pediatr.* 2014;40:98.
  12. Ryan MM and Engle EC. Acute ataxia in childhood. *J Child Neurol.* 2003;18(5):309-16.
  13. Lopez AS, Zhang J, Marin M. Epidemiology of varicella during the 2-dose varicella vaccination program — United States, 2005–2014. *MMWR Morb Mortal Wkly Rep.* 2016;65(34):902–5.
  14. Hill HA, Elam-Evans LD, Yankey D, et al. Vaccination coverage among children aged 19-35 months - United States, 2016. *MMWR Morb Mortal Wkly Rep.* 2017;66(43):1171-7.
  15. Uprety P, Curtis D, Elkan M, et al. Association of enterovirus D68 with acute flaccid myelitis, Philadelphia, Pennsylvania, USA, 2009-2018. *Emerg Infect Dis.* 2019;25(9):1676-1682.

# A Case Report of Pediatric Ovarian Torsion: The Importance of Diagnostic Laparoscopy

Alana Corre, BA\*  
Shebani Dandekar, MS\*  
Christopher Lau, MD†  
Leonard Ranasinghe, PhD, MD\*

\*California Northstate University College of Medicine, Elk Grove, California  
†Kaiser Permanente, Department of Emergency Medicine, Modesto, California  
°Co-first authors

Section Editor: Melanie Heniff, MD

Submission history: Submitted October 18, 2020; Revision received December 23, 2020; Accepted December 31, 2020

Electronically published January 26, 2021

Full text available through open access at [http://escholarship.org/uc/uciem\\_cpem](http://escholarship.org/uc/uciem_cpem)

DOI: 10.5811/cpem.2020.12.50319

**Introduction:** Pediatric ovarian torsion is a relatively rare occurrence with chances of significant morbidity and possible mortality if not treated emergently.

**Case Report:** In this report, we review a case of pediatric ovarian torsion in a nine-year-old that was difficult to diagnose on initial presentation to the hospital due to various factors, which inevitably led to delayed resolution.

**Conclusion:** We discuss the diagnosis of pediatric ovarian torsion including risk factors, symptoms, imaging modalities, and surgical diagnostics. To improve diagnosis and shorten time to treatment, this case supports the use of laparoscopy for diagnosis of ovarian torsion if indicated by clinical suspicion and supplemental imaging studies. [Clin Pract Cases Emerg Med. 2021;5(1):109–112.]

**Keywords:** *Case report; pediatric; ovarian torsion.*

---

## INTRODUCTION

Pediatric ovarian torsion can be challenging to diagnose. We present a case of ovarian torsion (OT) in a nine-year-old premenarchal female with delayed diagnosis and treatment. We discuss the varied presentations, diagnostics, and imaging modalities used to assess pediatric patients with suspected OT. To improve OT diagnosis and time to treatment, our case supports the use of diagnostic laparoscopy if prompted by clinical suspicion and other studies.

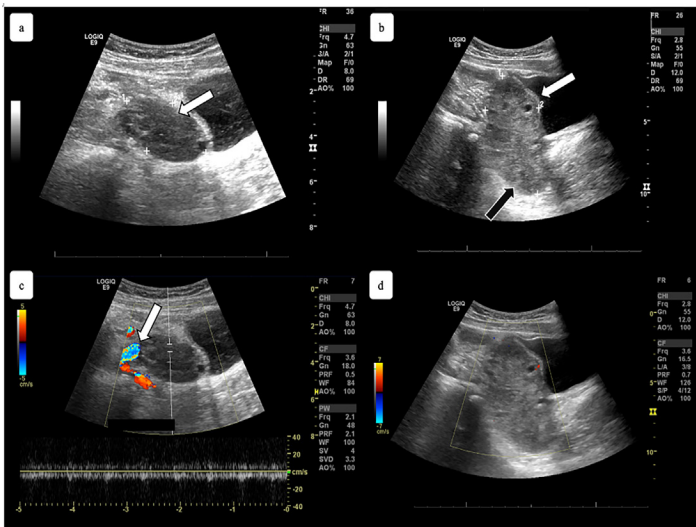
## CASE PRESENTATION

A nine-year-old premenarchal female presented to the emergency department (ED) for intermittent, right lower quadrant abdominal pain that began two days prior. An abdominal and pelvic computed tomography (CT) with intravenous contrast showed a “7 x 7.5 [centimeter (cm)] right ovarian hypoenhancing structure with multiple peripheral and internal follicle-like structures highly suspicious for swollen ovary secondary to ovarian torsion.” A pelvic ultrasound completed after the CT showed right adnexal enlargement and

“no evidence of ovarian torsion”; thus, no further work-up or consultations were pursued and the patient was discharged and instructed to follow up with her primary care physician (PCP) the next day.

At the appointment with her PCP, the patient was still in significant pain and was referred to the ED again, this time at a different hospital. At her second ED visit, the patient was nauseous without vomiting, and reported no fevers or chills. Her physical examination showed minimal diffuse abdominal tenderness worse in the right lower quadrant and moderate McBurney’s point tenderness with guarding. Labs revealed a white blood cell count within reference range, but the differential showed a high neutrophil count. A repeat ultrasound showed an “8.7 [x 1.3 x 6.1] cm heterogenous, mass-like structure containing small cystic foci and lack of blood flow” on her right ovary and a small amount of free fluid (Image).

A gynecologist was consulted and the patient was admitted and sent for an emergent diagnostic laparoscopy, during which OT was identified and corrected. The patient also required an ovarian cystectomy and partial right ovarian



**Image.** a) Sagittal view of the patient's left ovary on transabdominal pelvic ultrasound, measuring 4.4 x 2.4 x 2.0 centimeters (cm), indicating a slightly enlarged but otherwise normal ovary (white arrow); b) sagittal view of the patient's right ovary with measurements of 8.7 x 1.3 x 6.1 cm, demonstrating an abnormally enlarged ovary (white arrow) with a heterogenous mass (black arrow); c) sagittal view of the patient's left ovary with normal color flow Doppler (white arrow); d) sagittal view of the patient's right ovary demonstrating lack of blood flow on color flow Doppler.

oophorectomy. Postoperatively, the patient recovered well and had no known complications or recurrence of disease as documented by her PCP and had not returned to the ED for any similar complaints in the following year. Since a partial oophorectomy was required, the long-term effects remain to be seen as the patient progresses into her childbearing years.

## DISCUSSION

The adnexa of the uterus, which consists of the ovaries, fallopian tubes, and supporting ligaments, can undergo torsion or twisting. In OT specifically, the ovary twists on its axis, causing occlusion of ovarian vessels, which can lead to ischemia and necrosis of the ovary, possibly causing infertility or death. Pediatric OT is rare with an incidence of 4.9 in 100,000 females ages one to 20 years-old.<sup>1</sup> Although rare, pediatric OT is a clinical emergency requiring immediate diagnosis and treatment. However, the difficulty in diagnosing pediatric OT often leads to delayed treatment in youth. The risk factors for OT include the presence of an ovarian mass or lesion, having an enlarged ovary, being of reproductive age, pregnancy, ovulation induction, prior OT, tubal ligation, and polycystic ovarian syndrome. Up to 95% of patients found to have OT had an ovarian mass, making this the primary risk factor.<sup>2</sup>

Ovarian volume can also be measured to assess for risk of OT. Using the equation, length × width × height × 0.523 for measurement of the ellipsoid ovary, premenarchal girls two to 13 years of age have been found to have a mean ovarian volume of 0.7 to 4.2 cm<sup>3</sup>.<sup>3,4</sup> Ovaries with a volume larger than

### CPC-EM Capsule

What do we already know about this clinical entity?

*Pediatric ovarian torsion is rare, difficult to diagnose, and can lead to significant morbidity and possible mortality if not identified and treated emergently.*

What makes this presentation of disease reportable?

*Initial diagnostic imaging was doubted and definitive treatment was delayed, highlighting the challenges in diagnosing this condition.*

What is the major learning point?

*To improve diagnosis and shorten time to treatment, laparoscopy is useful for diagnosis of ovarian torsion if indicated by clinical suspicion and supplemental imaging.*

How might this improve emergency medicine practice?

*Emergency clinicians will be better prepared to diagnose, stabilize, and obtain emergent surgical consultation on pediatric patients presenting with ovarian torsion.*

6.0 to 8.0 cm<sup>3</sup> in premenarchal girls should raise suspicion for torsion.<sup>5</sup> Our patient's 7.0 x 7.5 cm cystic, swollen ovary revealed on her initial CT posed a major risk for OT and should have prompted immediate admission and treatment. The initial follow-up ultrasound detected a smaller 5.4 x 4.9 x 5.0 cm ovary. Although the ultrasound results showed no evidence of torsion, the ultrasound did confirm an enlarged right ovary with a volume of 69 cm<sup>3</sup> placing the patient at increased risk for developing OT. Patients with normal ovaries (ovaries without a mass and not enlarged) are also at risk for developing torsion, particularly individuals in the pediatric population. In patients younger than 15 years-old, 50% of those who present with OT have normal ovaries.<sup>6</sup> In addition to recognizing OT risk factors and the risk of OT in pediatric patients with normal ovaries, other indicators such as clinical symptoms should be assessed.

Pediatric OT can have a multitude of presentations. In a literature review of pediatric OT, most patients presented with peripheral leukocytosis, lower quadrant abdominal pain without radiation, and vomiting.<sup>7</sup> Another study found that vomiting, short duration of abdominal pain (less than six hours), and a high C-reactive protein level have a high

predictive value when diagnosing OT.<sup>8</sup> Clinical presentation of OT in the premenarchal population has been found to be different than the postmenarchal population. In a retrospective study including 41 premenarchal and over 200 postmenarchal patients, those who were premenarchal were more likely to present with restlessness, fever, and a palpable pelvic mass.<sup>9</sup> The most common presentation among both groups was abdominal pain, although diffuse pain was more common in premenarchal while lower abdominal pain was more common in postmenarchal patients.

Even between premenarchal and postmenarchal populations, there are differences in triage and time to surgery for OT cases. For premenarchal patients (median age nine years old), the time from onset of symptoms to admission for OT was 28.5 hours on average, as compared to only seven hours for postmenarchal patients (median age 27 years-old).<sup>9</sup> The time from admission to initiation of the surgical procedure in the operating room was 9.5 hours in the premenarchal group versus 4.6 hours in the postmenarchal group. Theories for these findings postulated in the study include that providers often do not consider OT as a possible diagnosis in the premenarchal population and providers have reservations about operating on premenarchal patients. However, the exact reasons for these differences were unknown due to limitations of the study.

In our case, the patient also presented at her second ED visit with diffuse abdominal tenderness increased in the right lower quadrant and nausea without vomiting. Our patient's CT at the prior hospital was done about 26 hours before she was admitted to the operating room for a diagnostic laparoscopy, which thereby reinforces the difficulty of assessing for OT in premenarchal patients. In addition to symptoms, lab findings can also help to further elucidate the diagnosis and thus reduce time to surgery.

The patient had a normal leukocyte count for her age on initial presentation. However, her neutrophil to lymphocyte ratio (NLR) was high at 5.64 with neutrophils at 79% and lymphocytes at 14%. Many recent studies have found NLR to have diagnostic and prognostic value when assessing patients for OT. One study found that an NLR greater than 2.44 was the best predictor of OT when compared to other complete blood count values, such as red cell distribution width and platelet distribution width.<sup>10</sup> This study also observed that NLR was higher in patients with ovarian necrosis as opposed to those without necrosis. The increased neutrophils and decreased lymphocytes are believed to be the result of ischemia in OT causing a cortisol stress response that leads to neutrophilia and lymphopenia.<sup>10</sup> Based on these studies, our patient's NLR could have been another factor pointing to her diagnosis of OT and the high likelihood of ovarian necrosis present.

Clinical suspicion for OT requires emergent work-up with imaging. Generally, ultrasound is considered the first-line tool for diagnosis. Ultrasound has been shown to be 92% sensitive and 96% specific in detecting adnexal torsion.<sup>11</sup> Ultrasound is useful for diagnosis in that it can indicate size of the ovary,

echogenicity, free pelvic fluid, ovarian lesions, and Doppler flow. A coiled or twisted vascular pedicle seen on ultrasound, called whirlpool sign, is highly specific for torsion.<sup>12</sup> One caveat is that spontaneous ovarian detorsion may occur and can result in intermittent or self-resolving symptoms as well as negative imaging.

In a case study of spontaneous detorsion in a 10-year-old female, the patient had intermittent abdominal pain and a negative ultrasound and so she was subsequently discharged.<sup>13</sup> In our case, the patient may have similarly had a negative ultrasound due to spontaneous ovarian detorsion. Computed tomography can also detect OT and, if it indicates OT, is considered an acceptable diagnostic tool when completed prior to ultrasound. Computed tomography can detect the size of the ovary, twisting of the pedicle, distended pedicle, ovarian lesion, edema, free fluid, and hemorrhagic infarction and necrosis. In our case, the patient had an initial CT that showed a cystic ovary of 7.0 x 7.5 cm with possible OT. However, the patient had a negative follow-up ultrasound with regard to organ perfusion.

Physicians might conduct a confirmatory ultrasound for diagnosis even after finding or suspecting OT on CT; yet CT has been found to be just as sensitive and specific for detecting torsion.<sup>14</sup> One study of 20 cases of OT demonstrated that there was no significant difference in identifying torsion from CT compared to ultrasound images.<sup>14</sup> This indicates that if torsion is found on CT, treatment should be initiated without completion of a confirmatory ultrasound. However, if the CT is negative for OT but OT is clinically suspected, ultrasound should be pursued. Despite the use of CT and ultrasound for diagnosis, a diagnostic laparoscopy is the ultimate standard for diagnosis and confirmation of OT via direct visualization.

According to the American College of Obstetricians and Gynecologists (ACOG) clinical guidelines for adolescents with adnexal torsion, including but not limited to ovarian torsion, "There are no clinical or imaging criteria sufficient to confirm the diagnosis of adnexal torsion. If adnexal torsion is suspected, timely intervention with diagnostic laparoscopy is indicated to preserve ovarian function and future fertility."<sup>15</sup> Additionally, ACOG continues by stating that adnexal torsion is in fact a diagnosis made by surgery, and that if a laparoscopy is negative for torsion in an adolescent or pediatric patient, this is acceptable given preserving ovarian function and fertility outweighs the risks of surgery.

## CONCLUSION

Pediatric ovarian torsion is an emergency that can present in multiple ways and thus can be difficult to diagnose. Clinical suspicion of OT should drive diagnostic laparoscopy. Imaging can be supplemental but should not be used to rule out pediatric OT in the setting of high clinical suspicion. With pediatric patients, there is more at stake given the risk of infertility. The benefit of early diagnostic laparoscopy should outweigh the risk of negative surgical findings.

## ACKNOWLEDGMENTS

We would like to thank the patient and her family for allowing us to present this case. We would also like to thank Dr. Edward J. Durant for his assistance and expertise in curating the ultrasound images presented in this case.

Patient consent has been obtained and filed for the publication of this case report.

---

*Address for Correspondence:* Leonard Ranasinghe, PhD, MD, California Northstate University College of Medicine, 9700 W. Taron Dr., Elk Grove, CA 95757. Email: leonard.ranasinghe@cnsu.edu.

*Conflicts of Interest:* By the CPC-EM article submission agreement, all authors are required to disclose all affiliations, funding sources and financial or management relationships that could be perceived as potential sources of bias. The authors disclosed none.

*Copyright:* © 2021 Corre et al. This is an open access article distributed in accordance with the terms of the Creative Commons Attribution (CC BY 4.0) License. See: <http://creativecommons.org/licenses/by/4.0/>

---

## REFERENCES

- Guthrie BD, Adler MD, Powell EC. Incidence and trends of pediatric ovarian torsion hospitalizations in the United States, 2000-2006. *Pediatrics*. 2010;125(3):532-8.
- White M and Stella J. Ovarian torsion: 10-year perspective. *Emerg Med Australas*. 2005;17(3):231-7.
- Sintim-Damoa A, Majmudar AS, Cohen HL, et al. Pediatric ovarian torsion: spectrum of imaging findings. *Radiographics*. 2017;37(6):1892-1908.
- Siegel MJ. (2011). Female pelvis. In: Siegel MJ (Ed.), *Pediatric Sonography* (p. 509-553). Philadelphia, PA: Lippincott, Williams and Wilkins.
- Cohen HL, Tice HM, Mandel FS. Ovarian volumes measured by US: bigger than we think. *Radiology*. 1990;177(1):189-92.
- Tsafir Z, Azem F, Hasson J, et al. Risk factors, symptoms, and treatment of ovarian torsion in children: the twelve-year experience of one center. *J Minim Invasive Gynecol*. 2012;19(1):29-33.
- Poonai N, Poonai C, Lim R, et al. Pediatric ovarian torsion: case series and review of the literature. *Can J Surg*. 2013;56(2):103-8.
- Bolli P, Schädelin S, Holland-Cunz S, et al. Ovarian torsion in children: development of a predictive score. *Medicine (Baltimore)*. 2017;96(43):e8299.
- Ashwal E, Hirsch L, Krissi H, et al. Characteristics and management of ovarian torsion in premenarchal compared with postmenarchal patients. *Obstet Gynecol*. 2015;126(3):514-20.
- Yilmaz M, Cimilli G, Saritemur M, et al. Diagnostic accuracy of neutrophil/lymphocyte ratio, red cell distribution width and platelet distribution width in ovarian torsion. *J Obstet Gynaecol*. 2016;36(2):218-22.
- Bronstein ME, Pandya S, Snyder CW, et al. A meta-analysis of B-mode ultrasound, Doppler ultrasound, and computed tomography to diagnose pediatric ovarian torsion. *Eur J Pediatr Surg*. 2015;25(1):82-6.
- Vijayaraghavan SB. Sonographic whirlpool sign in ovarian torsion. *J Ultrasound Med*. 2004;23(12):1643-9; quiz 1650-1.
- Skappak C, Thurston JL, Kam AJ. Ovarian torsion in a pediatric patient: the importance of repeat imaging. *Pediatr Emerg Care*. 2019;35(8):e154-5.
- Swenson DW, Lourenco AP, Beaudoin FL, et al. Ovarian torsion: case-control study comparing the sensitivity and specificity of ultrasonography and computed tomography for diagnosis in the emergency department. *Eur J Radiol*. 2014;83(4):733-8.
- American College of Obstetricians and Gynecologists. American College of Obstetrics and Gynecologists' Committee on Adolescent Health Care. Adnexal Torsion in Adolescents. 2019. Available at: <https://www.acog.org/clinical/clinical-guidance/committee-opinion/articles/2019/08/adnexal-torsion-in-adolescents>. Accessed June 22, 2020.

# Complication of Hepatitis A Infection: Case Report of Acute Inflammatory Demyelinating Polyneuropathy

Daniel Laursen, DO  
Jeffrey Krug, MD  
Robert Wolford, MD

University of Illinois College of Medicine – Peoria, Department of Emergency Medicine,  
Peoria, Illinois  
OSF Saint Francis Medical Center, Department of Emergency Medicine, Peoria, Illinois

Section Editor: Rick A. McPheeters, DO

Submission history: Submitted June 19, 2020; Revision received September 26, 2020; Accepted September 19, 2020.

Electronically published November 25, 2020

Full text available through open access at [http://escholarship.org/uc/uciem\\_cpem](http://escholarship.org/uc/uciem_cpem)

DOI: 10.5811/cpcem.2020.9.48827

**Introduction:** Acute inflammatory demyelinating polyneuropathy (AIDP) is characterized by progressive, mild sensory symptoms and progressive areflexic weakness. It typically follows a gastrointestinal or respiratory infection but has rarely been described after acute viral hepatitis.

**Case Report:** This is the case of a 59-year-old male who presented to the emergency department after acutely developing progressive neurologic symptoms following a hospitalization for acute hepatitis A. Cerebrospinal fluid analysis revealed albuminocytologic dissociation, and cervical spine magnetic resonance imaging revealed nerve root enhancement.

**Discussion:** The patient was diagnosed with AIDP, which is the most common subtype of Guillain-Barré syndrome in the United States and Europe. There have been few previously reported cases of AIDP following acute hepatitis A infection. [Clin Pract Cases Emerg Med. 2021;5(1):113–116.]

**Keywords:** *Hepatitis A; acute inflammatory demyelinating polyneuropathy; Guillain-Barré syndrome.*

---

## INTRODUCTION

Approximately 6700 cases of hepatitis due to hepatitis A virus (HAV) occurred in the United States (US) in 2017. Typically, hepatitis due to HAV is self-limiting, resolves spontaneously, requires only supportive care, and has a very low mortality rate. Rarely, there are extrahepatic complications of the disease. We report one such complication.

Acute inflammatory demyelinating polyneuropathy (AIDP), the most common variant of Guillain-Barré syndrome (GBS), is an autoimmune condition classically characterized by loss of reflexes, ascending weakness, cranial nerve involvement, and subtle sensory changes. In the US, 3000–6000 persons are diagnosed annually. Symptoms typically follow an upper respiratory or gastrointestinal infection in the preceding 1–6 weeks.<sup>1</sup> Admission to an intensive care setting is typical, as these patients can develop precipitous ascending weakness, respiratory failure (20% of AIDP patients), and autonomic dysfunction.<sup>1</sup> Early recognition of AIDP and appropriate disposition and treatment are key to improve outcomes and avoid complications. Thus, it is important for

the emergency clinician to develop a broad list of differential diagnoses when patients present with neurologic complaints and physical findings. This is a case of AIDP that followed an acute hepatitis A infection.

## CASE REPORT

A 59-year-old male presented to the emergency department (ED) with a two-day history of weakness, numbness, and tingling bilaterally in the hands, feet, and legs. Five days earlier he had been discharged from the hospital after a three-day admission due to acute HAV hepatitis. Hepatitis A was diagnosed at that time with a serologic acute hepatitis panel that revealed hepatitis A immunoglobulin M antibody. He denied vision changes, difficulty with speech or swallowing, dizziness, difficulty breathing, headaches, or bowel and bladder complaints. Gait was wide-based and mildly ataxic. A non-contrast head computed tomographic (CT) was obtained and was normal.

Lumbar puncture was performed by the neurology service. The cerebrospinal fluid (CSF) protein was found to be

elevated at 68.8 milligrams per deciliter (mg/dL) (reference range 12-60 mg/dL). Two nucleated cells and three red blood cells were found in tube one from the lumbar puncture. Lyme antibody, West Nile virus antibody, Gram stain, and CSF cultures were all found to be negative. Lead levels were below reference range and immunoglobulin A levels within normal limits. The patient was empirically started on intravenous immunoglobulin, (IVIG), for treatment of AIDP. During his hospital admission, he developed objective weakness in bilateral upper and lower extremities, ascending loss of reflexes, and decreased vibratory sense and a positive Babinski sign in the left lower extremity (Tables 1, 2). Due to this observed asymmetry, magnetic resonance imaging (MRI) was performed to evaluate for myelitis. MRI revealed enhancement of the first through seventh cervical spine nerve roots, which may be seen with AIDP (Image), and no evidence of myelitis. Prior to discharge, the patient also developed decreased vibratory sense in his right lower extremity without a positive Babinski sign. He was discharged after receiving five days of IVIG. He never developed respiratory symptoms, and his negative inspiratory force testing remained within normal limits throughout the hospital stay. Four days after discharge, when the patient was seen in the neurology clinic, he required the use of a wheelchair for mobility. However, approximately two weeks later he no longer used the wheelchair, as his strength was returning, and he was working with physical therapy. At follow-up approximately five months post-discharge, the patient's gait had nearly returned to baseline. He did endorse mild continued fingertip paresthesias, but those symptoms were slowly improving.

## DISCUSSION

Acute inflammatory demyelinating polyneuropathy has been associated with a variety of preceding etiologies, including viral and bacterial infections, severe acute respiratory syndrome coronavirus 2 infection,<sup>9</sup> vaccinations, and malignancy.<sup>1</sup> *Campylobacter jejuni*, human immunodeficiency virus, and Epstein-Barr virus are commonly identified illnesses that precipitate AIDP. Hepatitis is rarely reported as a preceding infection. Hepatitis A, similar

**Table 1.** Cranial nerve and sensory examination findings during hospital stay of patient with 2-day history of weakness and bilateral numbness and recent history of acute hepatitis A infection.

	Cranial nerves	Sensory exam
ED presentation	Fully intact	Fully intact
Day 2	Fully intact	Decreased VS left LE
Day 3	Fully intact	Decreased VS left LE
Day 4	Fully intact	Decreased VS b/l LE
Day 5	Fully intact	Decreased VS b/l LE

ED, emergency department; VS, vibratory sensation; LE, lower extremity; b/l, bilateral.

### CPC-EM Capsule

What do we already know about this clinical entity?

*Acute inflammatory demyelinating polyneuropathy (AIDP), an autoimmune disease with weakness and sensory changes, commonly follows a variety of infections.*

What makes this presentation of disease reportable?

*Although associated with respiratory and gastrointestinal infections, AIDP is not commonly reported to follow hepatitis due to hepatitis A virus.*

What is the major learning point?

*The differential diagnosis of patients with a recent history of hepatitis A infection and complaints of weakness and/or sensory changes should include AIDP.*

How might this improve emergency medicine practice?

*Early recognition and management of AIDP is essential to guide appropriate emergency department disposition, avoid complications, and improve patient outcomes.*

to other infections preceding AIDP, is thought to cause a dysregulated immune response against myelin, a result of cross-reactivity and molecular mimicry.<sup>7</sup> There have also been reported cases of hepatitis A preceding other variants of GBS, including acute motor axonal neuropathy, in which the patients suffer from isolated ascending motor symptoms.<sup>3,7,8</sup>

The neurology service was initially skeptical of the AIDP diagnosis, given recent acute hepatitis A infection and few previously reported cases of antecedent hepatitis A infections. Although our patient did not have nerve conduction testing, it is not essential in making the AIDP diagnosis, which can be made based on the clinical course of the illness and laboratory findings. Our patient's clinical presentation and laboratory findings were consistent with AIDP and met level 2 of diagnostic certainty by Brighton criteria.<sup>4</sup> The patient had bilateral limb weakness, along with decreased and absent deep tendon reflexes in the weakened limbs. He also experienced a monophasic pattern of symptoms that – by chart review – nadired within 28 days of onset. There was an absence of better alternative diagnosis to explain the patient's progressive ascending symptoms.

**Table 2.** Strength and deep tendon reflex examination findings during hospital stay.

	UE Strength	LE Strength	UE DTR	LE DTR
ED presentation	Fully intact	Fully intact	Brachioradialis: 1/4 b/l	Patellar: trace b/l Ankle jerk: 0/4 b/l
Day 2	Fully intact	Hip Flexors: 4/5 b/l Quadriceps: 4/5 b/l Hamstrings: 4/5 b/l	Triceps: 1/4 b/l	Patellar: 0/4 b/l Ankle jerk: 0/4 b/l
Day 3	Biceps: 4/5 right Triceps: 4/5 right	Hip Flexors: 4/5 b/l Quadriceps: 4/5 b/l Hamstrings: 4/5 b/l	Biceps: 1/4 b/l Brachioradialis: 1/4 b/l Triceps: 0/4 b/l	Patellar: 0/4 b/l Ankle jerk: 0/4 b/l Upgoing left Babinski Absent right plantar response
Day 4	Biceps: 4/5 right Triceps: 4/5 right Grip: 4/5 b/l	Hip Flexors: 4/5 b/l Quadriceps: 4/5 b/l Hamstrings: 4/5 b/l	Biceps: 1/4 b/l Brachioradialis: 0/4 b/l Triceps: 0/4 b/l	Patellar: 0/4 b/l Ankle jerk: 0/4 b/l Upgoing left Babinski Absent right plantar response
Day 5	Biceps: 4/5 right Triceps: 4/5 right Grip: 4/5 b/l	Hip Flexors: 4/5 b/l Quadriceps: 4/5 b/l Hamstrings: 4/5 b/l	Biceps: 1/4 b/l Brachioradialis: 0/4 b/l Triceps: 0/4 b/l	Patellar: 0/4 b/l Ankle jerk: 0/4 b/l

ED, emergency department; UE, upper extremity; LE, lower extremity; DTR, deep tendon reflex; b/l, bilateral.

The total CSF white blood cell count of less than 50 and elevated CSF protein, known as albuminocytologic dissociation, was also consistent with AIDP. MRI is usually not used in the diagnosis of AIDP, but rather to exclude other diagnoses such as transverse myelitis and acute flaccid

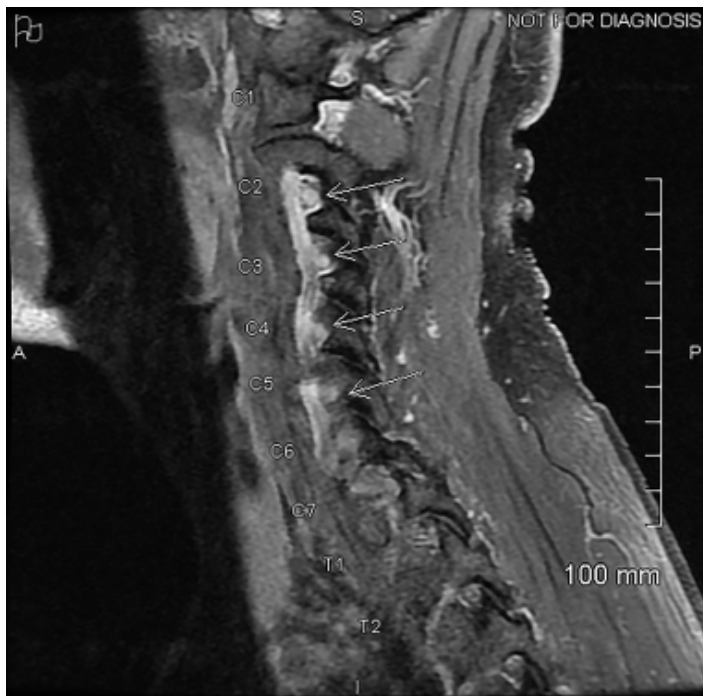myelitis. This patient did have MRI findings of spinal root enhancement, which has been previously reported in GBS.<sup>2</sup> During his hospital course, the patient had paroxysms of tachycardia and hypertension, likely related to the dysautonomia, which is a common clinical feature associated with GBS.<sup>6</sup>

The patient began showing signs of improvement approximately four weeks after the initial onset of symptoms, which is also consistent with the majority of cases of AIDP.<sup>5</sup> Of note, at the time of the patient's initial admission for treatment of acute HAV hepatitis, he had been taking amoxicillin-clavulanate for five days to treat sinusitis. After discussion with the patient, his symptoms did not seem to be consistent with sinusitis. Instead, the generalized malaise, joint pains, chills, and nausea he had complained of and which had led to the antibiotic prescription, were likely related to his HAV infection.

## CONCLUSION

This patient had a convincing diagnosis of acute inflammatory demyelinating polyneuropathy, even in the absence of electrophysiologic testing. Many different antecedent illnesses may lead to AIDP. In this case, it appears viral hepatitis A was the cause. Although there are few reported cases of AIDP following acute viral hepatitis A infection, it is worthy of consideration when evaluating ED patients with neurologic complaints.

The authors attest that their institution requires neither Institutional Review Board approval, nor patient consent for publication of this case report. Documentation on file.



**Image.** Magnetic resonance imaging of the cervical spine with and without contrast revealed enhancement of the cervical spine nerve roots (arrows), which may be seen in acute inflammatory demyelinating polyneuropathy.

*Address for Correspondence:* Robert Wolford, MD, OSF Saint Francis Medical Center, Department of Emergency Medicine, 530 NE Glen Oak Ave, Peoria, IL 61637. Email: Robert.W.Wolford@osfhealthcare.org.

*Conflicts of Interest:* By the CPC-EM article submission agreement, all authors are required to disclose all affiliations, funding sources and financial or management relationships that could be perceived as potential sources of bias. The authors disclosed none.

*Copyright:* © 2021 Laursen et al. This is an open access article distributed in accordance with the terms of the Creative Commons Attribution (CC BY 4.0) License. See: <http://creativecommons.org/licenses/by/4.0/>

## REFERENCES

1. Ramachandran TS. Acute inflammatory demyelinating polyradiculoneuropathy. Background, pathophysiology, epidemiology. 2019. Available at: <https://emedicine.medscape.com/article/1169959-overview>. Accessed April 9, 2020.
2. Alkan O, Yildirim T, Tokmak N, et al. Spinal MRI findings of Guillain-Barré syndrome. *J Radiol Case Rep.* 2009;3(3):25-8
3. Chitambar SD, Fadnis RS, Joshi MS, et al. Case report: hepatitis A preceding Guillain-Barré syndrome. *J of Med Virol.* 2006;78(8):1011-4.
4. Fokke C, Berg BVD, Drenthen J, et al. Diagnosis of Guillain-Barré syndrome and validation of Brighton criteria. *Brain.* 2013;137(1):33-43.
5. National Institutes of Health. Guillain-Barré Syndrome Fact Sheet. National Institute of Neurological Disorders and Stroke. 2020. Available at: <https://www.ninds.nih.gov/Disorders/Patient-Caregiver-Education/Fact-Sheets/Guillain-Barré-Syndrome-Fact-Sheet>. Accessed February 14, 2020.
6. Leonhard SE, Mandarakas MR, Gondim FAA, et al. Diagnosis and management of Guillain-Barré syndrome in ten steps. *Nat Rev Neurol.* 2019 Nov;15(11):671-83.
7. Menon D, Jagtap SA, Nair MD. Guillain-Barré syndrome following acute viral hepatitis A. *J Neurosci in Rural Pract.* 2014;5(2):204-5.
8. Samadi A, Mansour-Ghanaei F, Joukar F, et al. A 30-year-old man with acute motor axonal neuropathy subtype of Guillain-Barré syndrome having hepatitis A virus infection. *Middle East J of Dig Dis.* 2019;11(2):110-5.
9. Sedaghat Z and Karimi N. Guillain-Barré syndrome associated with COVID-19 infection: a case report. *J Clin Neurosci.* 2020;76:233-5.

# Case Report: Bilateral Ultrasound-guided Serratus Anterior Plane Blocks for a Chest Wall Burn

Tara Benesch, MD, MS  
Daniel Mantuani, MD  
Arun Nagdev, MD

Highland General Hospital, Department of Emergency Medicine, Oakland, California

Section Editor: R. Gentry Wilkerson, MD

Submission history: Submitted October 8, 2020; Revision received December 21, 2020; Accepted December 18, 2020

Electronically published January 29, 2021

Full text available through open access at [http://escholarship.org/uc/uciem\\_cpccem](http://escholarship.org/uc/uciem_cpccem)

DOI: 10.5811/cpcem.2020.12.50184

**Introduction:** The serratus anterior plane block (SAPB) has been shown to effectively treat pain following breast surgery, thoracotomies, and rib fractures. We present the first reported case of a bilateral ultrasound-guided SAPB in a multimodal analgesic regimen after an acute large, thoracic, deep partial-thickness burn.

**Case Report:** A 72-year-old male presented in severe pain two days after sustaining a deep partial-thickness burn to his anterior chest wall after his shirt caught on fire while cooking. The area of injury was on bilateral chest walls, and the patient was consented for bilateral SAPBs at the level of the third thoracic ribs (T3). With ultrasound guidance, a mixture of ropivacaine and lidocaine with epinephrine was injected into the fascial plane overlying bilateral serratus muscles at T3. The patient reported complete resolution of pain for approximately 15 hours and required minimal additional intravenous analgesia.

**Conclusion:** The ultrasound-guided SAPB may be an excellent addition to the multimodal analgesic regimen in superficial and partial-thickness burns of the anterior chest wall. [Clin Pract Cases Emerg Med. 2021;5(1):117–120.]

**Keywords:** *ultrasound; serratus anterior plane block; nerve block; burn; pain management.*

## INTRODUCTION

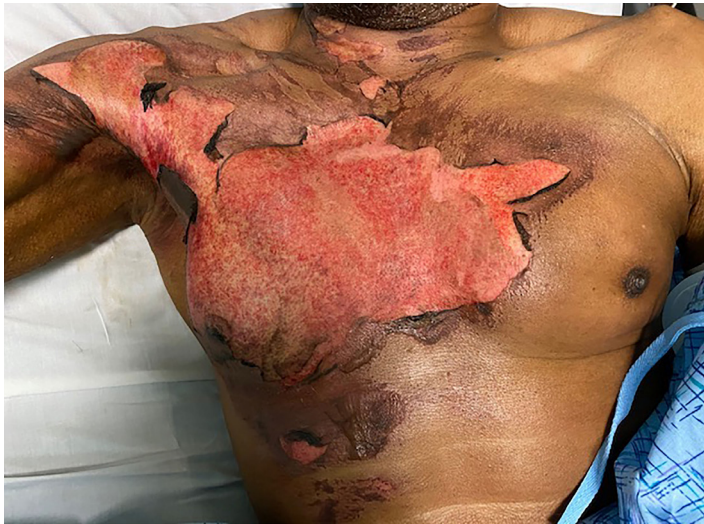Chest wall burns are relatively common, and often do not require specialized treatment at a burn center.<sup>1</sup> In cases of non-circumferential injuries of the chest that do not require surgical intervention, the most common medical management priorities include volume resuscitation and optimal pain management. Mainstays of pain regimens include nonsteroidal anti-inflammatory drugs (NSAIDs), acetaminophen, opioids and ketamine, with ultrasound-guided regional anesthesia uncommonly employed in the non-operative setting.<sup>2</sup>

The ultrasound-guided serratus anterior plane block (SAPB), first described by Blanco et al in 2013, is an effective method of achieving analgesia of the hemithorax from the second thoracic (T2) to ninth thoracic (T9) dermatomes.<sup>3</sup> Approximately 25-30 milliliters (mL) of

anesthetic is injected into the fascial plane either superficial or deep to the serratus anterior (SA) muscle. This targets lateral cutaneous branches of the thoracic intercostal nerves that reside in these fascial planes. SAPBs have been used to reduce pain following breast surgeries, major lung resection, and cardioverter defibrillator insertion.<sup>4-7</sup> More recently, the SAPB is being used in the emergency department (ED) to treat severe pain from rib fractures, herpes zoster, and tube thoracostomy placement.<sup>8,9</sup> This technique can be easily and safely performed at the bedside and offers another option in the multimodal strategy for pain control in a variety of thoracic injuries. We present the first case of bilateral ultrasound-guided SAPBs incorporated into a multimodal acute pain regimen in a case of large thoracic partial-thickness burn in the ED.

## CASE REPORT

A 72-year-old male with diabetic polyneuropathy presented to the ED with a chief complaint of chest pain two days after sustaining a flame burn while cooking. His vital signs were stable and his physical exam revealed a deep partial-thickness burn over the majority of his right pectoralis extending across midline to the left sternal border (Image 1). The patient reported severe thoracic pain (10/10) unrelieved with oral therapy consisting of NSAIDs and acetaminophen at home.



**Image 1.** Partial-thickness burn of the anterior chest wall in the patient prior to receiving bilateral serratus anterior plane blocks for pain.

After obtaining informed consent, bilateral SABPs were performed in the manner described by Blanco et al.<sup>3</sup> The anesthetic dose was calculated based on the patient's weight of 66 kilograms (kg) and recommended maximum dose of 3 milligrams (mg)/kg ropivacaine. This yielded a maximum of 20 milliliters (mL) of 1% ropivacaine (10mg/mL) total for both SABPs, or 10 mL per side. An additional 5 mL of 1% lidocaine with epinephrine was added to each SABP to prolong the effect of the block and reduce the systemic absorption of ropivacaine.<sup>10</sup>

The patient was positioned in the left lateral decubitus position with right arm overhead for the right-sided block. A high-frequency 10-5 megahertz linear transducer was used to locate the third rib in cross section in the mid-axillary line. Superficial to the rib lies the SA, which is deep to the latissimus dorsi (LD) (Figure). The targeted lateral cutaneous branches of the intercostal nerves at thoracic vertebral levels three to nine (T3–T9), are located in the fascial plane separating the SA and LD muscles. Anesthetic spreads in the fascial plane above and below the level of injection to the lateral cutaneous branches of the thoracic intercostal nerves. Although anesthetic will affect dermatomes above and below the site of injection, it is

### CPC-EM Capsule

What do we already know about this clinical entity?

*Serratus anterior plane blocks (SAPB) effectively treat pain following breast surgery, thoracotomies, and rib fractures.*

What makes this presentation of disease reportable?

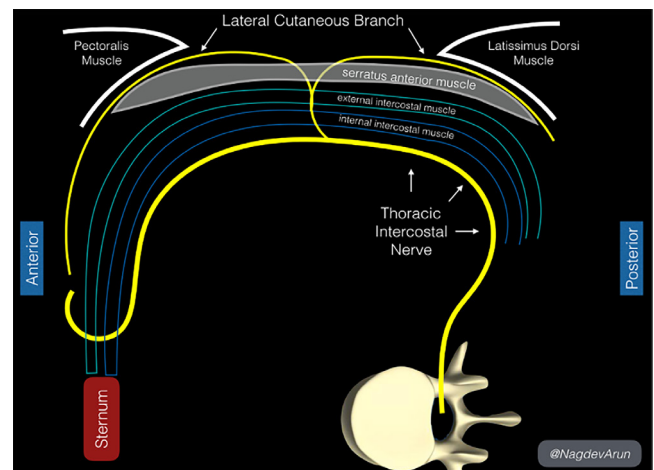
*This is the first description of an ultrasound-guided SAPB performed in the emergency department (ED) for the management of pain from an extensive partial-thickness thoracic burn.*

What is the major learning point?

*Ultrasound-guided SAPBs can provide safe and rapid analgesia for patients with superficial and partial-thickness chest wall burns in the ED.*

How might this improve emergency medicine practice?

*Ultrasound-guided SAPBs can facilitate chest wall burn treatments such as dressing changes and wound debridement while reducing reliance on opioid medications.*

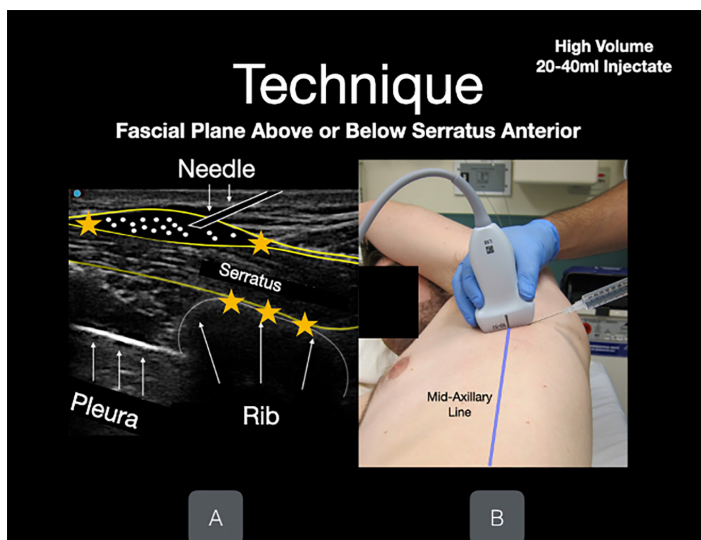


**Figure.** Anatomical landmarks in the serratus anterior plane block. Above the rib lies the serratus anterior (SA), which is deep to the latissimus dorsi (LD). The targeted lateral cutaneous branches of the thoracic intercostal nerves (third to ninth thoracic vertebral level, or T3–T9, arrows), are in the fascial plane separating the SA and LD muscles.

necessary to adjust the injection site based on the dermatome level. We recommend injecting just above the superior level

of injury, targeting the level above the dermatome in case of miscounting the ribs. In this patient, whose burns were located in the T2-T5 dermatomes, we injected at the T2 dermatome above the third rib at the mid-axillary line.

After sterilizing and anesthetizing the skin, an in-plane technique was used to inject the 15-mL mixture of ropivacaine and lidocaine with epinephrine between SA and LD muscles (Image 2) following hydrodissection with 10 mL of normal saline. The same process was repeated on the patient's left side. The injected ropivacaine and lidocaine spreads along the fascial plane above and below the site of injection, a process facilitated by hydrodissection with 10mL of normal saline before and after anesthetic administration. Thus, it is not necessary repeat injections at each thoracic vertebral level to achieve analgesia across the chest wall.



**Image 2.** An in-plane technique is used to inject the mixture of anesthetic (in this case, ropivacaine and lidocaine with epinephrine) between serratus anterior and latissimus dorsi muscles. Hydrodissection with 10 milliliters of normal saline prior to injecting anesthetic can assist with visualization of the fascial plane (white dots). The rib and pleura lie beneath the serratus anterior muscle (white arrows). Photo obtained with consent for demonstration purposes.

Five minutes after the initial injection, the patient reported significant analgesia over his right chest, and 20 minutes after the termination of the procedure he was able to sleep comfortably. The patient reported no discomfort during the injection process and experienced no side effects. A local burn center recommended admission for treatment with silver sulfadiazine and fluid resuscitation; when the patient was interviewed on hospital day two, he reported the SABP took approximately 20-30 minutes to take full effect and lasted for an estimated 15-18 hours. He ultimately required two doses of 2 mg intravenous morphine at approximately 30 hours and 35 hours after his SABP. His only other medications were

acetaminophen 500 mg orally every six hours, ibuprofen 600 mg orally every six hours, and home medications gabapentin and trazodone. The patient was discharged in stable condition on hospital day two.

## DISCUSSION

The SAPB, originally used to control pain following breast surgery, is now becoming increasingly popular among emergency physicians to control pain from thoracic injuries in the ED.<sup>3,8</sup> Although the majority of cases in the literature describe the use of the SAPB to relieve pain from rib fractures, other authors have demonstrated its utility in reducing pain from herpes zoster and tube thoracostomy placement.<sup>8,9</sup> To our knowledge, this is the first description of an ultrasound-guided SAPB used for the management of pain from an extensive partial-thickness thorax burn in the ED.

Burns are a leading cause of accidental injury, many of which will not require management at a burn center. Aggressive pain control is necessary in the treatment of these injuries. A multimodal regimen including opioids and ketamine is often required to achieve adequate analgesia for large burns. However, opioids carry risks and side effects of respiratory depression, nausea/vomiting, constipation, and addiction; and ketamine may cause dizziness, dysphoria, and altered mental status.<sup>11,12</sup> As demonstrated by this case, we believe regional anesthesia is a valuable tool in a multimodal pain control regiment for burn patients in the ED. Peripheral nerve blocks have been effectively used for analgesia in patients undergoing wound debridement and dressing changes at burn centers.<sup>13</sup> A single-injection SAPB can provide approximately 12 hours or more of pain relief to the anterolateral hemithorax without affecting motor function, and may be an ideal option for pain relief prior to dressing changes, wound debridement, or rehabilitation exercises in patients with chest wall burns.

With regard to anesthetic choice, ropivacaine was selected for its long duration of anesthesia and good safety profile. When compared to lidocaine, ropivacaine has a slightly longer mean onset time but provides a much longer mean duration of anesthesia (21.5 hours for ropivacaine compared to 2.4 hours for lidocaine in digital blocks).<sup>14</sup> Although bupivacaine has a similar mean duration of anesthesia as ropivacaine, ropivacaine has fewer motor effects and a better safety profile (including being safe to use in pregnancy).<sup>15-17</sup>

We recognize that the ultrasound-guided SAPB may not be ideal for burns posterior to the mid-axillary line. We have noted minimal success of this planar block in patients with posterior rib fractures and are unclear of the efficacy of this block for these injuries. We also recognize that clinicians performing high-volume SAPB blocks should be aware of maximal anesthetic dosing to prevent administering a toxic dose. The patient's weight should be measured and a dosing calculator should be used to ensure safety.

## CONCLUSION

Ultrasound-guided serratus anterior plane blocks can potentially provide a safe and rapid method of analgesia for patients with superficial and partial-thickness chest wall burns in the ED. They may be easily performed at the bedside with minimal risk of affecting respiration, mental status, or motor function. As such, they may be a valuable addition to a multimodal pain regimen used in the evaluation and treatment of chest wall burns, and may facilitate treatments such as dressing changes and wound debridement while reducing reliance on opioid medications.

The authors attest that their institution requires neither Institutional Review Board approval, nor patient consent for publication of this case report. Documentation on file.

---

*Address for Correspondence:* Tara Benesch, MD, MS, Highland General Hospital, Department of Emergency Medicine, 1411 East 31st Street, Oakland, CA 94602. Email: [tbenesch@alamedahealthsystem.org](mailto:tbenesch@alamedahealthsystem.org).

*Conflicts of Interest:* By the CPC-EM article submission agreement, all authors are required to disclose all affiliations, funding sources and financial or management relationships that could be perceived as potential sources of bias. The authors disclosed none.

*Copyright:* © 2021 Benesch et al. This is an open access article distributed in accordance with the terms of the Creative Commons Attribution (CC BY 4.0) License. See: <http://creativecommons.org/licenses/by/4.0/>

---

## REFERENCES

- Gibran NS. (2002). Burns of the chest wall. In: Karmy-Jones R, Nathens A, Stern EJ (Eds.). *Thoracic Trauma and Critical Care*. Boston, MA: Springer.
- Griggs C, Goverman J, Bittner EA, et al. Sedation and pain management in burn patients. *Clin Plast Surg*. 2017;44(3):535-40.
- Blanco R, Parras T, McDonnell JG, et al. Serratus plane block: a novel ultrasound-guided thoracic wall nerve block. *Anaesthesia*. 2013;68(11):1107-13.
- Hetta DF and Rezk KM. Pectoralis-serratus interfascial plane block vs thoracic paravertebral block for unilateral radical mastectomy with axillary evacuation. *J Clin Anesth*. 2016;34:91-7.
- Ahiskalioglu A, Yayik AM, Demir U, et al. Preemptive analgesic efficacy of the ultrasound-guided bilateral superficial serratus plane block on postoperative pain in breast reduction surgery: a prospective randomized controlled study. *Aesthetic Plast Surg*. 2020;44(1):37-44.
- Ziacchi M, Bisignani G, Palmisano P, et al. Serratus anterior plane block in subcutaneous implantable cardioverter defibrillator implantation: a case-control analysis. *J Cardiovasc Electrophysiol*. 2020;31(1):144-9.
- Viti A, Bertoglio P, Zamperini M, et al. Serratus plane block for video-assisted thoracoscopic surgery major lung resection: a randomized controlled trial. *Interact Cardiovasc Thorac Surg*. 2020;30(3):366-72.
- Lin J, Hoffman T, Badashova K, et al. Serratus anterior plane block in the emergency department: a case series. *Clin Pract Cases Emerg Med*. 2020;4(1):21-5.
- Durant E, Dixon B, Luftig J, et al. Ultrasound-guided serratus plane block for ED rib fracture pain control. *Am J Emerg Med*. 2017;35(1):197.e3-6.
- Karmakar MK, Ho AM, Law BK, et al. Arterial and venous pharmacokinetics of ropivacaine with and without epinephrine after thoracic paravertebral block. *Anesthesiology*. 2005;103(4):704-11.
- Benjamin R, Trescot AM, Datta S, et al. Opioid complications and side effects. *Pain Physician*. 2008;11(2 Suppl):S105-20.
- Rosenbaum SB, Gupta V, Palacios JL. Ketamine. 2020. Available at: <https://www.ncbi.nlm.nih.gov/books/NBK470357>. Accessed October 11, 2020.
- Kovac AL, Mehta N, Salerno S, et al. Peripheral nerve blocks for analgesia in burn unit patients: a retrospective study. *J Burn Care Res*. 2018;39(1):S195-6.
- Keramidas EG and Rodopoulou SG. Ropivacaine versus lidocaine in digital nerve blocks: a prospective study. *Plast Reconstr Surg*. 2007;119(7):2148-52.
- Arthur GR, Feldman HS, Covino BG. Comparative pharmacokinetics of bupivacaine and ropivacaine, a new amide local anesthetic. *Anesth Analg*. 1988;67(11):1053-8.
- Scott DB, Lee A, Fagan D, et al. Acute toxicity of ropivacaine compared with that of bupivacaine. *Anesth Analg*. 1989;69(5):563-9.
- McGlade DP, Kalpokas MV, Mooney PH, et al. A comparison of 0.5% ropivacaine and 0.5% bupivacaine for axillary brachial plexus anaesthesia. *Anaesth Intens Care*. 1998;26(5):515-20.

## Penile Dorsal Vein Rupture Identified by Emergency Department Ultrasound

Sean E. Scott, MD  
Robert Langenohl, DO  
Theodore Crisostomo-Wynne, MD  
Christopher Kang, MD

Madigan Army Medical Center, Department of Emergency Medicine,  
Tacoma, Washington

Section Editor: Rick A. McPheeters, DO

Submission history: Submitted August 27, 2020; Revision received October 6, 2020; Accepted October 9, 2020

Electronically published December 7, 2020

Full text available through open access at [http://escholarship.org/uc/uciem\\_cpem](http://escholarship.org/uc/uciem_cpem)

DOI: 10.5811/cpcem.2020.10.49631

**Case Presentation:** We present the case of a young male with high clinical suspicion of a penile fracture found to have dorsal vein rupture by emergency department point-of-care ultrasound. This false form of penile fracture was subsequently confirmed intraoperatively.

**Discussion:** Penile fracture is a rare clinical entity that may be separated into true vs false penile fracture, with only true fracture requiring surgery. The images submitted here add to the sparse literature evidence that point-of-care ultrasound can be used to differentiate between these two clinical entities. Additionally, this case report highlights an opportunity for further research into and application of point-of-care ultrasound to the evaluation of suspected penile fractures. [Clin Pract Cases Emerg Med. 2021;5(1):121–122.]

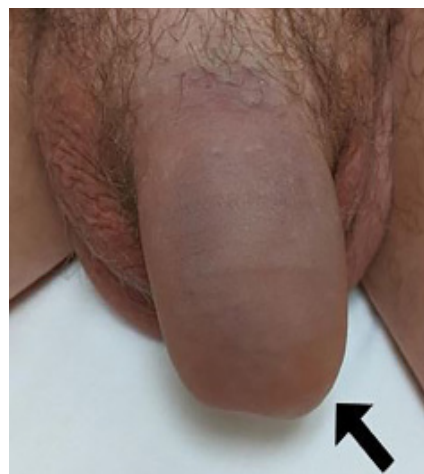
**Keywords:** *Penile fracture; emergency ultrasound.*

### CASE PRESENTATION

A 26-year-old man presented to the emergency department with penile pain and bruising after accidental trauma during intercourse one hour prior to arrival. He reported immediate pain and bruising with detumescence within minutes. Exam was revealing for eggplant deformity of the penis with soft dorsal ecchymosis and mass felt extending into the scrotum (Image 1).

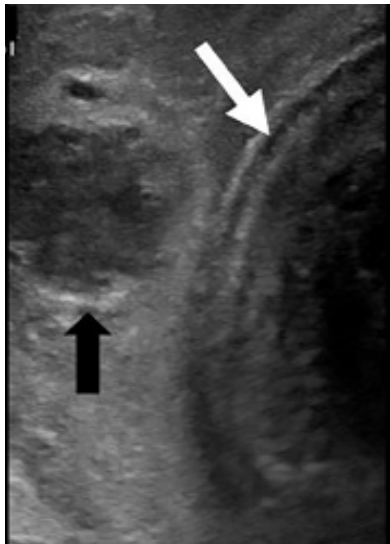
### DISCUSSION

**Dorsal Vein Rupture:** This patient's ultrasound images showed hematoma external to Buck's fascia and intact tunica albuginea, suggestive of dorsal penile vessel injury (Images 2 and 3). This is a type of false penile fracture and requires only conservative treatment.<sup>1</sup> True penile fracture, with disruption of the tunica albuginea, can be exceptionally difficult to distinguish from false penile fracture, has a worse prognosis, and requires emergency surgery.<sup>1</sup> Along with history and physical exam, point-of-care ultrasound can help differentiate these entities.<sup>2</sup> Delay of presentation greater than 24 hours of penile fracture has been linked to an increased rate of postoperative complications; so expeditious diagnosis is important to help reduce the time to

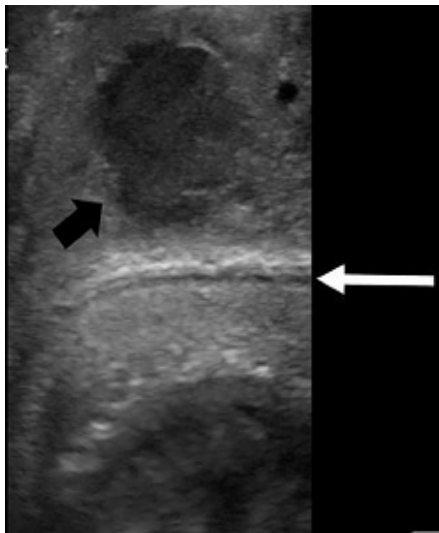


**Image 1.** Patient's penis with eggplant deformity (arrow) at presentation to the emergency department.

intervention.<sup>3</sup> Ultrasound can be an inexpensive, non-invasive, and often readily available means of investigation that may be performed at initial presentation without delay to surgery.<sup>4</sup> False



**Image 2.** Intact tunica albuginea (white arrow) and likely ruptured vein with surrounding hematoma (black arrow).



**Image 3.** Intact tunica albuginea (white arrow) and likely ruptured dorsal vein with surrounding hematoma (black arrow).

penile fracture is exceptionally rare, and is considered exceptionally difficult to distinguish from true penile fracture, often leading to surgery.<sup>5</sup> Further research is necessary to help delineate the role of ultrasound in separating false from true penile fracture.

Surgical exploration confirmed a dorsal vein rupture with subsequent drainage of a large hematoma involving the dorsal vein and dartos layer dorsally. There were no acute complications. On follow-up the patient reported recovery of sexual function without curvature, but with mild residual pain to the incision site at six-week postoperative follow-up.

Patient consent has been obtained and filed for the publication of this case report.

### CPC-EM Capsule

What do we already know about this clinical entity?

*Penile fracture is a rare clinical entity encountered following trauma to the erect penis and is typically managed surgically.*

What is the major impact of the image(s)?

*This image increases awareness of false penile fracture and the utility of ultrasound in evaluation for possible penile fracture.*

How might this improve emergency medicine practice?

*Increased use of point-of-care ultrasound may allow for improved accuracy in differentiating between true and false penile fracture and reduce the need for surgery.*

*Address for Correspondence:* Sean E. Scott, MD, Madigan Army Medical Center, Department of Emergency Medicine, 9040A Jackson Ave., Joint Base Lewis-McChord, WA 98431. Email: sean.e.scott4.mil@mail.mil.

*Conflicts of Interest:* By the CPC-EM article submission agreement, all authors are required to disclose all affiliations, funding sources and financial or management relationships that could be perceived as potential sources of bias. The views expressed here are those of the authors and do not reflect the official policy of the Department of the Army, the Department of Defense, or the U.S. Government. The authors disclosed none.

*Copyright:* © 2021 Scott et al. This is an open access article distributed in accordance with the terms of the Creative Commons Attribution (CC BY 4.0) License. See: <http://creativecommons.org/licenses/by/4.0/>

### REFERENCES

1. Sharma GR. Rupture of the superficial dorsal vein of the penis. *Int J Urol.* 2005;12(12):1071-3.
2. Ash A, Miller J, Preston D. Point-of-care ultrasound used to exclude penile fracture. *Crit Ultrasound J.* 2012;4(1):17.
3. Patil B, Kamath SU, Patwardhan SK, et al. Importance of time in management of fracture penis: a prospective study. *Urol Ann.* 2019;11(4):405-9.
4. Dell'Atti L. The role of ultrasonography in the diagnosis and management of penile trauma. *J Ultrasound.* 2016;19(3):161-6.
5. Feki W, Derouiche A, Belhaj K, et al. False penile fracture: report of 16 cases. *Int J Impot Res.* 2007;19(5):471-3.

# New Onset Nystagmus in a Patient with Multiple Sclerosis

Shane Daugherty, MS\*

Briana King, DO†

Melody Milliron, DO†

Jestin N. Carlson, MD, MS†

\*Lake Erie College of Osteopathic Medicine, Erie, Pennsylvania

†Saint Vincent Hospital, Department of Emergency Medicine, Allegheny Health Network, Erie, Pennsylvania

Section Editor: Shadi Lahham, MD

Submission history: Submitted May 27, 2020; Revision received October 10, 2020; Accepted October 16, 2020

Electronically published December 28, 2020

Full text available through open access at [http://escholarship.org/uc/uciem\\_cpem](http://escholarship.org/uc/uciem_cpem)

DOI: 10.5811/cpem.2020.10.48448

**Case Presentation:** A 50-year-old male with a history of multiple sclerosis with dizziness and nystagmus presented to the emergency department. On physical exam, nystagmus was noted. Computed tomography of the head without contrast was obtained showing a low density in the left frontal lobe. During admission, magnetic resonance imaging (MRI) findings were consistent with Balò's concentric sclerosis.

**Discussion:** Balò's concentric sclerosis is a rare, inflammatory demyelinating disease, often considered to be an infrequent variant of multiple sclerosis with alternating rings of healthy myelin and demyelination leading to pathognomonic findings of concentric lamella on T2 or contrast-enhanced T1 MRI imaging. [Clin Pract Cases Emerg Med. 2021;5(1):123–124.]

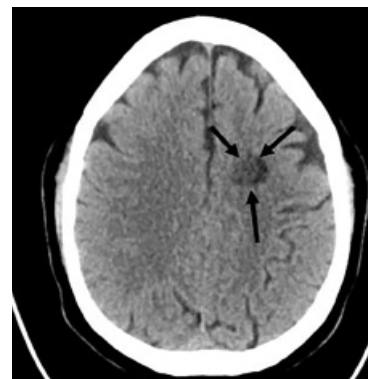
**Keywords:** *Balò's; sclerosis; nystagmus.*

## CASE PRESENTATION

A 50-year-old White male with a history of multiple sclerosis presented to the emergency department with fatigue, lightheadedness, and dizziness, exacerbated with sitting upright and worsening over the prior one to two days. He stated his last flare was approximately two years prior, and presented with aphasia as his primary symptom. On physical exam, the patient had non-fatigable horizontal bidirectional nystagmus with no other abnormalities noted. Non-contrast computed tomography of the head showed an indeterminate 13-millimeter low density in the left frontal lobe (Image 1).

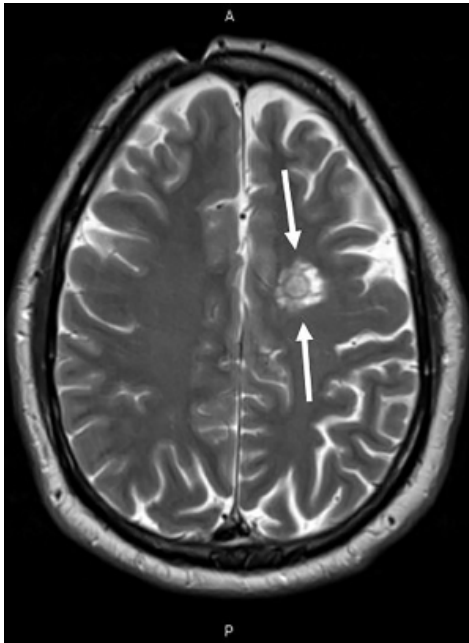
## DISCUSSION

Balò's concentric sclerosis (BCS) is a rare inflammatory demyelinating disease, often considered to be an infrequent variant of multiple sclerosis. Initially termed leuko-encephalitis periaxialis concentrica due to its pathognomonic MRI findings, BCS was originally considered a rapidly progressive encephalopathy that was universally fatal<sup>1,3</sup>; however, it has recently been associated with spontaneous remission.<sup>1</sup> Balò's concentric sclerosis typically affects young adults with a mean age of 37 at diagnosis,<sup>1</sup> and is most commonly noted in Asian and



**Image 1.** Computed tomography of the head without contrast in a 50-year-old male with dizziness. Black arrows identify an indeterminate 13-millimeter low density lesion in the left frontal lobe, further delineated by magnetic resonance imaging (Image 2).

Filipino populations.<sup>3</sup> Lesions are most commonly found in the cerebrum and cerebellum.<sup>2</sup> Alternating rings of healthy myelin and demyelination lead to the unique and pathognomonic MRI findings of a whorled appearance of concentric lamella on T2 or contrast-enhanced T1 imaging (Image 2).<sup>4</sup> The clinical presentation of BCS



**Image 2.** Magnetic resonance image of the head with contrast (T2 image) in a 50-year-old male with dizziness. White arrows identify a heterogeneous lesion in the left frontal centrum semiovale consistent with Balò's concentric sclerosis.

is heterogenous, with symptoms often indicative of a mass-like lesion depending on lesion location. Treatment options range from high-dose intravenous steroids to immunosuppressive agents.<sup>5</sup> Our patient was admitted and treated conservatively with intravenous fluids, meclizine, and promethazine. He was discharged on hospital day two without complications, and was referred for outpatient vestibular rehabilitation evaluation.

The authors attest that their institution requires neither Institutional Review Board approval, nor patient consent for publication of this case report. Documentation on file.

## REFERENCES

1. Karaarslan E, Altintas A, Senol U, et al. Balò's concentric sclerosis: clinical and radiologic features of five cases. *AJNR Am J Neuroradiol.* 2001;22(7):1362-7.
2. Kreft KL, Mellema SJ, Hintzen RQ. Spinal cord involvement in Balò's concentric sclerosis. *J Neurol Sci.* 2009;279(1-2):114-7.
3. Amini Harandi A, Esfandani A, Pakdaman H, et al. Balò's concentric sclerosis: an update and comprehensive literature review. *Rev Neurosci.* 2018;29(8):873-82.
4. Kastrup O, Stude P, Limmroth V. Balò's concentric sclerosis. Evolution of active demyelination demonstrated by serial contrast-enhanced MRI. *J Neurol.* 2002;249(7):811-4.
5. Pietroboni AM, Arighi A, De Riz MA, et al. Balò's concentric sclerosis: still to be considered as a variant of multiple sclerosis? *Neurol Sci.* 2015;36(12):2277-80.

### *CPC-EM Capsule*

What do we already know about this clinical entity?

*Dizziness is a common presenting complaint in the emergency department. Balò's concentric sclerosis (BCS) is unlikely to be included in the differential for dizziness with nystagmus.*

What is the major impact of the image(s)?

*The presented images will broaden the differential diagnosis in patients with intracerebral lesions on computed tomography.*

How might this improve emergency medicine practice?

*Consideration of BCS in the differential could lead to a neurology rather than neurosurgical referral, allowing earlier diagnosis and treatment.*

*Address for Correspondence:* Melody Milliron, DO, Saint Vincent Hospital, Department of Emergency Medicine, 232 West 25<sup>th</sup> St, Erie, PA 16502. Email: melody.milliron@ahn.org.

*Conflicts of Interest:* By the CPC-EM article submission agreement, all authors are required to disclose all affiliations, funding sources and financial or management relationships that could be perceived as potential sources of bias. The authors disclosed none.

*Copyright:* © 2021 Daugherty et al. This is an open access article distributed in accordance with the terms of the Creative Commons Attribution (CC BY 4.0) License. See: <http://creativecommons.org/licenses/by/4.0/>

## A Young Boy with Fever and Grunting

Daniel J. Shapiro, MD  
Jeffrey T. Neal, MD

Boston Children's Hospital, Department of Pediatrics, Boston, Massachusetts  
Boston Children's Hospital, Division of Emergency Medicine, Boston, Massachusetts

Section Editor: Austin Smith, MD

Submission history: Submitted September 10, 2020; Revision received November 6, 2020; Accepted November 5, 2020

Electronically published January 16, 2021

Full text available through open access at [http://escholarship.org/uc/uciem\\_cpem](http://escholarship.org/uc/uciem_cpem)

DOI: 10.5811/cpem.2020.11.49721

**Case Presentation:** A 16-month-old boy presented with a temperature of 99°Fahrenheit (F) (down from 102°F at home after antipyretics), grunting, and tachypnea. On examination, he was tachycardic, tachypneic, and ill-appearing with abdominal distention and diffuse tenderness. A plain film abdominal radiograph showed moderate free air, and emergent laparoscopy revealed perforated Meckel's diverticulitis with peritonitis.

**Discussion:** Although tachypnea and grunting in preverbal or nonverbal patients are often considered to be signs of respiratory illness, these findings may reflect intra-abdominal emergencies. Perforated Meckel's diverticulitis is an important differential consideration in patients with pneumoperitoneum. [Clin Pract Cases Emerg Med. 2021;5(1):125–126.]

**Keywords:** *pneumoperitoneum; grunting; pediatric abdominal emergencies.*

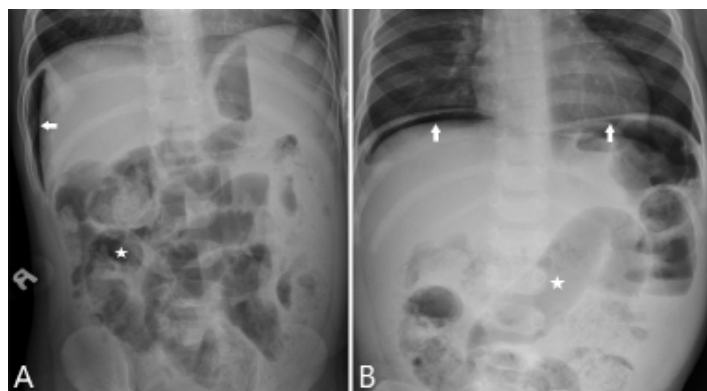### CASE PRESENTATION

A 16-month-old healthy boy presented to the emergency department with a temperature of 99°Fahrenheit (F) (down from 102°F at home after antipyretics), tachypnea, and grunting. Physical examination demonstrated an ill-appearing child with tachycardia and tachypnea, clear lung fields, and a distended, tender abdomen. Plain film abdominal radiography showed mildly prominent, gas-filled loops of small bowel and moderate free air (Image).

The patient received piperacillin-tazobactam and was transferred to the operating room for exploratory laparoscopy, which revealed an acutely inflamed and bleeding Meckel's diverticulum with a well-circumscribed perforation. Uneventful diverticulectomy was performed, and the patient was discharged from the hospital five days later after a full recovery.

### DISCUSSION

Although tachypnea and grunting in a preverbal or nonverbal patient may be signs of respiratory illness, abdominal emergencies may present with similar findings.<sup>1</sup> In such cases, these respiratory phenomena may be physiologic responses to pain or acidemia or may reflect the presence of mechanical thoracoabdominal competition. When an abdominal emergency is suspected in the setting of a respiratory complaint, plain films of the abdomen can provide



**Image.** Plain film abdominal radiographs. Panel A (left lateral decubitus view) and Panel B (upright anteroposterior view) showing free air under the diaphragm (arrows) with dilated loops of bowel (stars).

a rapid assessment for pneumoperitoneum. In this scenario, left lateral decubitus films may be particularly helpful in toxic-appearing young children, in whom obtaining upright radiographs may be logistically challenging.

Meckel's diverticulum occurs in the mid-to-distal ileum as a remnant of the fetal omphalomesenteric duct. Although present in approximately 2% of the general population, it causes symptoms in less than 10% of cases.<sup>2,3</sup> Symptomatic cases, which occur

more commonly in children than in adults, most often present with painless bleeding from heterotopic gastric tissue.<sup>4</sup> However, Meckel's diverticulum may cause small bowel obstruction by (1) acting as a lead point for intussusception; (2) inverting into the bowel lumen; or (3) adhering to adjacent structures to cause a volvulus.<sup>5</sup> Similarly, Meckel's diverticulitis may cause acute abdominal pain that mimics appendicitis and can subsequently perforate to cause peritonitis. Accordingly, Meckel's diverticulum is an important differential consideration in the acute surgical abdomen, particularly in pediatric patients.

The authors attest that their institution requires neither Institutional Review Board approval, nor patient consent for publication of this case report. Documentation on file.

---

*Address for Correspondence:* Daniel Shapiro, MD, Boston Children's Hospital, Department of Emergency Medicine, 300 Longwood Avenue, BCH3066, Boston, MA 02115. Email: daniel.shapiro@childrens.harvard.edu.

*Conflicts of Interest:* By the *CPC-EM* article submission agreement, all authors are required to disclose all affiliations, funding sources and financial or management relationships that could be perceived as potential sources of bias. The authors disclosed none.

*Copyright:* © 2021 Shapiro et al. This is an open access article distributed in accordance with the terms of the Creative Commons Attribution ([CC BY 4.0](http://creativecommons.org/licenses/by/4.0/)) License. See: <http://creativecommons.org/licenses/by/4.0/>

---

## REFERENCES

1. Rothrock SG, Skeoch G, Rush JJ, et al. Clinical features of misdiagnosed appendicitis in children. *Ann Emerg Med.* 1991;20(1):45-50.
2. Cullen JJ, Kelly KA, Moir CR, et al. Surgical management of Meckel's diverticulum. An epidemiologic, population-based study. *Ann Surg.* 1994;220(4):564-8.
3. Sagar J, Kumar V, Shah DK. Meckel's diverticulum: a systematic review [published correction appears in *J R Soc Med.* 2007;100(2):69]. *J R Soc Med.* 2006;99(10):501-5.
4. Huang CC, Lai MW, Hwang FM, et al. Diverse presentations in pediatric Meckel's diverticulum: a review of 100 cases. *Pediatr Neonatol.* 2014;55(5):369-75.
5. St-Vil D, Brandt ML, Panic S, et al. Meckel's diverticulum in children: a 20-year review. *J Pediatr Surg.* 1991;26(11):1289-92.

### *CPC-EM Capsule*

What do we already know about this clinical entity?

*Tachypnea and grunting are often considered signs of respiratory illness, but intra-abdominal emergencies may present with similar findings.*

What is the major impact of the image(s)?

*These images provide an example of an intra-abdominal emergency presenting with primarily respiratory symptoms and signs.*

How might this improve emergency medicine practice?

*These images emphasize the importance of considering alternative causes of respiratory symptoms and signs, particularly in nonverbal or preverbal patients.*

# Abdominal Pain in the Elderly Patient: Point-of-care Ultrasound Diagnosis of Small Bowel Obstruction

Ahmad Hussein, MD  
Alexander Arena, MD  
Connie Yu, MD  
Angela Cirilli, MD  
Ellen Kurkowski, DO

St. John's Riverside Hospital, Department of Emergency Medicine, Yonkers, New York

Section Editor: Rick A. McPheeters, DO

Submission history: Submitted September 25, 2020; Revision received November 12, 2020; Accepted November 23, 2020

Electronically published January 22, 2021

Full text available through open access at [http://escholarship.org/uc/uciem\\_cpem](http://escholarship.org/uc/uciem_cpem)

DOI: 10.5811/cpem.2020.11.50029.

**Case Presentation:** A 67-year-old female presented to the emergency department (ED) complaining of generalized abdominal pain, nausea, and vomiting. Point-of-care ultrasound (POCUS) demonstrated dilated bowel loops measuring up to 4.1 centimeters and localized free fluid, consistent with a small bowel obstruction (SBO). A nasogastric tube was placed without complications. The patient was admitted to the hospital and conservatively managed with an uncomplicated course.

**Discussion:** In elderly patients with abdominal pain, POCUS is an excellent initial imaging modality to assist emergency physicians in rapid and accurate diagnosis of a variety of pathologies to expedite management. Point-of-care ultrasound can be used to rule out and evaluate for conditions encountered in emergency medicine, including acute cholecystitis, renal colic, abdominal aortic aneurysm, and intraperitoneal free fluid. As demonstrated in our case presentation, POCUS had an integral role in the early diagnosis and management of a SBO. [Clin Pract Cases Emerg Med. 2021;5(1):127–128.]

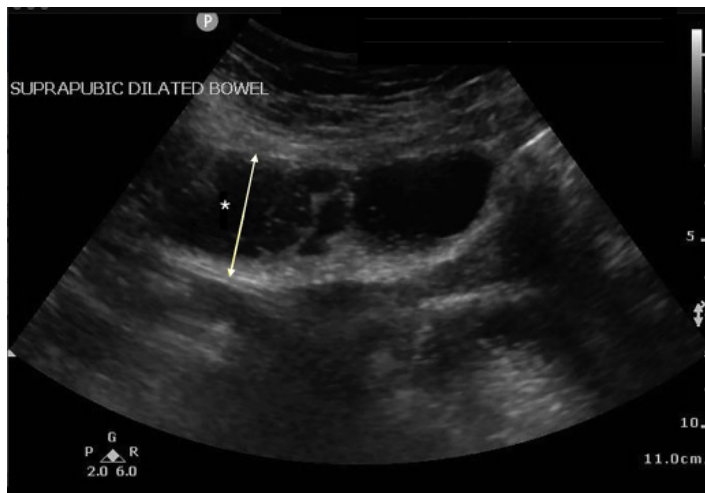
**Keywords:** *Abdominal pain; small bowel obstruction; point-of-care ultrasound.*

## CASE PRESENTATION

A 67-year-old female with a history of hypertension, diabetes, and exploratory laparotomy presented with abdominal pain for one day associated with nausea, nonbloody-nonbilious emesis, and normal bowel movements. Abdominal exam revealed a soft, nondistended abdomen with a laparotomy scar and both periumbilical and right lower quadrant tenderness. Point-of-care ultrasound of the abdomen was performed with no acute abnormalities of the gallbladder or kidneys. The “lawn mower” method, scanning systematically across all abdominal quadrants in a horizontal or vertical fashion, demonstrated dilated, small bowel loops containing air and fluid measuring up to 4.1 centimeters (cm) (Image 1) with localized free fluid (Image 2). Computed tomography (CT) of the abdomen confirmed the diagnosis. Following nasogastric tube placement, the patient was admitted with an uncomplicated hospitalization course.

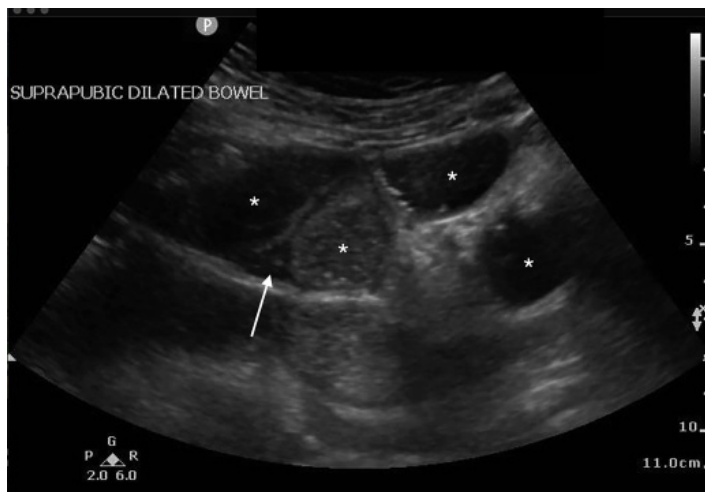
## DISCUSSION

Small bowel obstruction (SBO) is a common emergency department diagnosis estimated to comprise 2% of all patients with abdominal pain, resulting in 300,000 hospitalizations per year with etiologies including adhesions, neoplasms, hernias, and Crohn's disease.<sup>1,2</sup> Expedient diagnosis of SBO can prevent potential complications, including bowel ischemia, necrosis, and perforation.<sup>1,2</sup> Studies suggest that point-of-care ultrasound is highly accurate in diagnosing SBO with sensitivity and specificity of 92% and 94-96%, respectively, compared to CT imaging.<sup>1,3</sup> The most sensitive sonographic findings include dilated bowel loops and abnormal peristalsis.<sup>1,3,4,5</sup> Fluid-filled small bowel loops measuring greater than 2.5 cm is highly indicative of SBO.<sup>4,5</sup> Abnormal peristalsis is manifested by “to-and-fro” or swirling of intraluminal bowel contents.<sup>4,5</sup> More specific sonographic signs include bowel wall edema if plicae circulares project into the bowel lumen (“keyboard sign”); free fluid between



**Image 1.** Point-of-care ultrasound demonstrating long-axis view of dilated, fluid-filled loops of bowel (\*) measuring 4.1 centimeters from outer bowel wall to outer wall, consistent with small bowel obstruction.

adjacent bowel loops; and the identification of a transition point.<sup>4,5</sup> Point-of-care ultrasound is a useful screening tool in the early diagnosis and management of SBO in emergency medicine, where evolving literature has shown reasonable diagnostic accuracy with time and cost-saving implications.



**Image 2.** Point-of-care ultrasound demonstrating short-axis view of dilated loops of bowel (\*) with localized surrounding free fluid (white arrow) consistent with small bowel obstruction.

**Video.** Point-of-care ultrasound demonstrating “to-and-fro” swirling of bowel intraluminal contents signifying abnormal peristalsis consistent with small bowel obstruction.

The authors attest that their institution requires neither Institutional Review Board approval, nor patient consent for publication of this case report. Documentation on file.

### CPC-EM Capsule

What do we already know about this clinical entity?

*Small bowel obstruction (SBO) is a common presenting diagnosis in the Emergency Department (ED) that requires prompt evaluation and intervention.*

What is the major impact of the image(s)?

*Point-of-care ultrasound (POCUS) has emerged as a useful, rapid and noninvasive screening tool in the early diagnosis and management of SBO in the ED*

How might this improve emergency medicine practice?

*Early diagnosis of SBO in the ED allows for improved patient care by initiating the appropriate intervention as well as surgical evaluation.*

*Address for Correspondence:* Ahmad Hussein, MD, St. John's Riverside Hospital, Department of Emergency Medicine. 967 N Broadway, Yonkers, NY 10701. Email: [ahussein359@gmail.com](mailto:ahussein359@gmail.com).

*Conflicts of Interest:* By the CPC-EM article submission agreement, all authors are required to disclose all affiliations, funding sources and financial or management relationships that could be perceived as potential sources of bias. The authors disclosed none.

*Copyright:* © 2021 Hussein et al. This is an open access article distributed in accordance with the terms of the Creative Commons Attribution (CC BY 4.0) License. See: <http://creativecommons.org/licenses/by/4.0/>

### REFERENCES

- Gottlieb M, Peksa GD, Pandurangadu AV, et al. Utilization of ultrasound for the evaluation of small bowel obstruction: a systematic review and meta-analysis. *Am J Emerg Med.* 2018;36(2):234-42.
- Taylor MR and Lalani N. Adult small bowel obstruction. *Acad Emerg Med.* 2013;20(6):528-44.
- Long B, Robertson J, Koefman A. Emergency medicine evaluation and management of small bowel obstruction: evidence-based recommendations. *J Emerg Med.* 2019;56(2):166-76
- Boniface KS, King JB, LeSaux MA, et al. Diagnostic accuracy and time-saving effects of point-of-care ultrasonography in patients with small bowel obstruction: a prospective study. *Ann Emerg Med.* 2020;75(2):246-56.
- Becker BA, Lahham S, Gonzales MA. A prospective, multicenter evaluation of point-of-care ultrasound for small-bowel obstruction in the emergency department. *Acad Emerg Med.* 2019;26(8):921-30.

## A Piercing Diagnosis – Occult Foreign Body as the Cause of Acute Inguinal Pain

**Coral Bays-Muchmore, BS\***  
**Deion T. Sims, BS\***  
**Joel A. Gross, MD, MS†**  
**Jonathan S. Ilgen, MD, MCR‡**

\*University of Washington School of Medicine, Seattle, Washington.  
†University of Washington School of Medicine, Department of Radiology, Seattle, Washington  
‡University of Washington School of Medicine, Department of Emergency Medicine, Seattle, Washington

Section Editor: Scott Goldstein, MD

Submission history: Submitted October 13, 2020; Revision received December 11, 2020; Accepted December 18, 2020

Electronically published January 26, 2021

Full text available through open access at [http://escholarship.org/uc/uciem\\_cpccem](http://escholarship.org/uc/uciem_cpccem)

DOI: 10.5811/cpccem.2020.12.50196

**Case Presentation:** A 35-year-old woman presented to the emergency department with severe right inguinal pain. Her medical history was non-contributory and there was no known trauma or injury to the region. Amid concern for an incarcerated inguinal hernia, a computed tomography was obtained revealing a linear foreign body (FB) lateral to the femoral vessels. The FB was removed without complication at bedside and found to be a beading needle likely occultly lodged three days prior.

**Discussion:** Occult inguinal FBs are rare but can lead to deep venous thrombosis or pulmonary embolism if in or near vessels. By nature of being occult, an absence of ingestion, insertion, or penetrative history should not preclude consideration of a FB etiology. Computed tomography imaging is crucial in determining the urgency of, and approach to, inguinal foreign body removal. [Clin Pract Cases Emerg Med. 2021;5(1):129–130.]

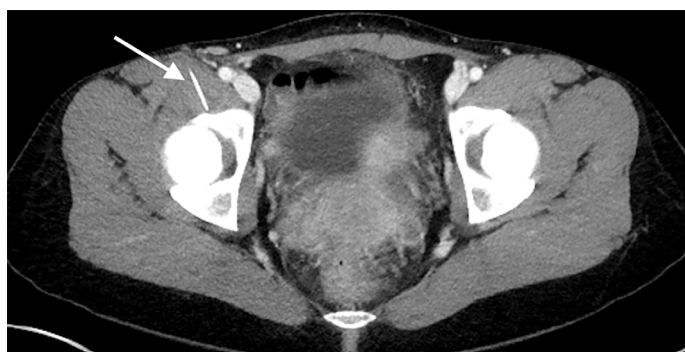
**Keywords:** *Occult foreign body; inguinal pain.*

### CASE PRESENTATION

A 35-year-old woman presented to the emergency department with severe right inguinal pain that began while pushing a grocery cart. Physical examination revealed tenderness and fullness in the right inguinal crease without erythema, warmth, or skin trauma. Amid concern for an incarcerated inguinal hernia, a computed tomography (CT) was obtained (Image 1).

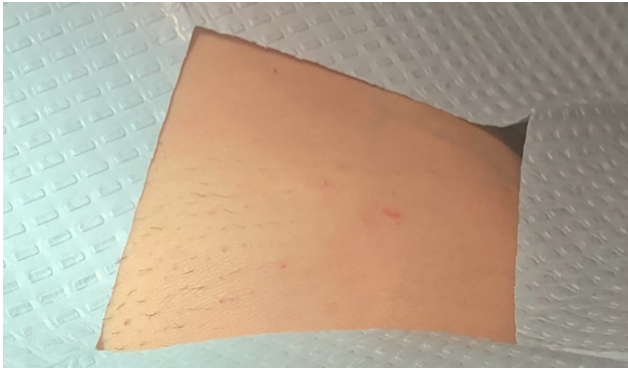
The CT demonstrated a linear 3.8-centimeter (cm) foreign body (FB) extending from the skin into the right iliopsoas muscle (Image 1) without gas or fluid along its length and without vessel involvement. Upon re-interview and re-examination, the patient did not report any preceding history that would explain this finding and there was no visible point of entry on her skin (Image 2).

The CT imaging confirmed this FB to be lateral to the femoral vessels in a location amenable to bedside removal in the ED. The skin was incised, and a 4-cm metallic FB was removed (Image 3).

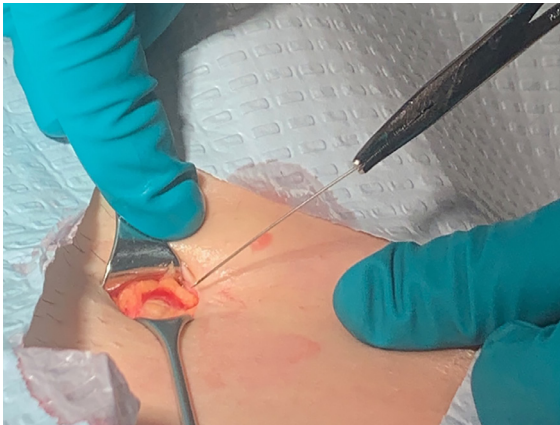

**Image 1.** Computed tomography axial image demonstrating a radiopaque linear foreign body (arrow) passing through the iliopsoas muscle without gas or fluid along its path, resting adjacent to right anterior acetabular wall.

Upon removal, the patient identified the FB as a beading needle and presumed that it had become lodged three days prior when she had fallen asleep adjacent to her beading



**Image 2.** Pre-procedure image of right inguinal region demonstrating no clear puncture site for the foreign body visualized on computed tomography imaging.



**Image 3.** Intra-procedure image demonstrating removal of 4-centimeter beading needle.

materials. Following the FB removal, the incision was closed, and the patient was discharged without complication.

## DISCUSSION

Occult FBs are rare, although needles are common culprits due to their ease of entering tissue with minimal pain and inflammation.<sup>1</sup> Inguinal needle FBs are uncommon but can generally be grouped into those associated with intravenous drug use,<sup>2</sup> acupuncture needle retention,<sup>3</sup> and accidental/inexplicable cases.<sup>4,5</sup> Deep venous thrombosis may be the initial clinical manifestation of occult inguinal FBs in or near vessels.<sup>5</sup> As illustrated by this case and others,<sup>4,5</sup> FBs remain an important consideration even without known history of ingestion, insertion, or penetrative injury. Computed tomography imaging is crucial in determining the urgency of, and approach to, inguinal FB removal.

Patient consent has been obtained and filed for the publication of this image in emergency medicine.

### *CPC-EM Capsule*

What do we already know about this clinical entity?

*Foreign body (FB) injuries are typically apparent from clinical history and have exam findings compatible with tissue injury and inflammation.*

What is the major impact of the image(s)?

*These images demonstrate that a FB can be present without any corresponding history or external exam findings, with the potential for serious downstream sequelae.*

How might this improve emergency medicine practice?

*Although rare, occult FBs must be considered by emergency providers as a source of pain despite an absence of clinical history.*

*Address for Correspondence:* Jonathan Ilgen, MD, MCR, University of Washington School of Medicine, Department of Emergency Medicine, 325 9th Avenue, Box 359702, Seattle, WA 98104-2499. Email: [ilgen@uw.edu](mailto:ilgen@uw.edu).

*Conflicts of Interest:* By the CPC-EM article submission agreement, all authors are required to disclose all affiliations, funding sources and financial or management relationships that could be perceived as potential sources of bias. The authors disclosed none.

*Copyright:* © 2021 Bays-Muchmore et al. This is an open access article distributed in accordance with the terms of the Creative Commons Attribution (CC BY 4.0) License. See: <http://creativecommons.org/licenses/by/4.0/>

## REFERENCES

1. Al-Jasmi F and Al-Khenaizan S. Cutaneous foreign bodies: elusive presentation. Case report and review of the literature. *Int J Dermatol*. 2002;41(5):293-5.
2. Gladman J. Pins and needles in the groin: an incidental finding of retained needle fragments in an intravenous drug user. *BMJ Case Rep*. 2019;12(2):e226220.
3. Hollander JE, Dewitz A, Bowers S. Permanently imbedded subcutaneous acupuncture needles: radiographic appearance. *Ann Emerg Med*. 1991;20(9):1025-6.
4. Lloyd RF and Feeney C. Adolescent hip pain: the needle in the haystack. A case report. *Physiotherapy*. 2011;97(4):354-6.
5. Lebon M, Ancedy Y, Boccara F, et al. Foreign body causing superficial venous thrombosis and subsequent pulmonary embolism: a case report. *Eur Heart J Case Rep*. 2018;2(4):yty125.

## Male with Altered Mental Status

Jason Kondrat, DO\*  
Ben Ilyaguyev, DO\*  
Jonathan Stern, MD†  
Teresa Choe, MD\*  
Josh Greenstein, MD\*  
Barry Hahn, MD\*

\*Staten Island University Hospital, Department of Emergency Medicine, Staten Island, New York  
†Staten Island University Hospital, Department of Radiology, Staten Island, New York

Section Editor: Rick A. McPheeters, DO

Submission history: Submitted November 24, 2020; Revision received December 23, 2020; Accepted December 31, 2020

Electronically published January 26, 2021

Full text available through open access at [http://escholarship.org/uc/uciem\\_cpccem](http://escholarship.org/uc/uciem_cpccem)

DOI: 10.5811/cpcem.2020.12.50960

**Case Presentation:** A 62-year-old male presented to the emergency department with altered mental status and fever. Computed tomography of the head showed enlargement of the left lateral ventricle. Magnetic resonance imaging demonstrated debris and purulence in the ventricle along with edema and transependymal flow of cerebrospinal fluid surrounding both ventricles.

**Discussion:** The patient was diagnosed with ventriculitis. Ventriculitis is an uncommon but serious disease. Early recognition and treatment are essential. [Clin Pract Cases Emerg Med. 2021;5(1):131–133.]

**Keywords:** *confusion; magnetic resonance imaging.*

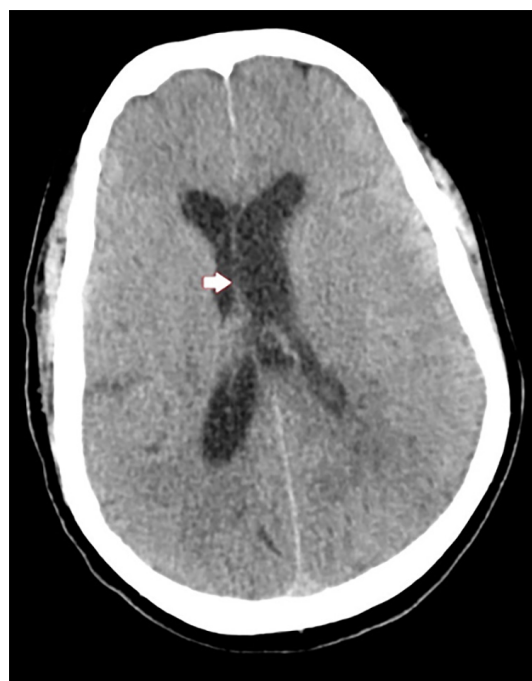### CASE PRESENTATION

A 62-year-old male with no significant past medical history presented to the emergency department with altered mental status for one day. Temperature was 103.3° degrees Fahrenheit, and remaining vital signs were within normal limits. He was alert to person and place only and was not responding appropriately to most questions or commands. Cranial nerves were intact, and upper and lower extremity strength was grossly normal and symmetrical. He resisted flexion of his neck. The patient was empirically started on vancomycin, ampicillin, ceftriaxone, and dexamethasone. Computed tomography (CT) of the head and magnetic resonance imaging (MRI) were performed (Images 1 and 2).

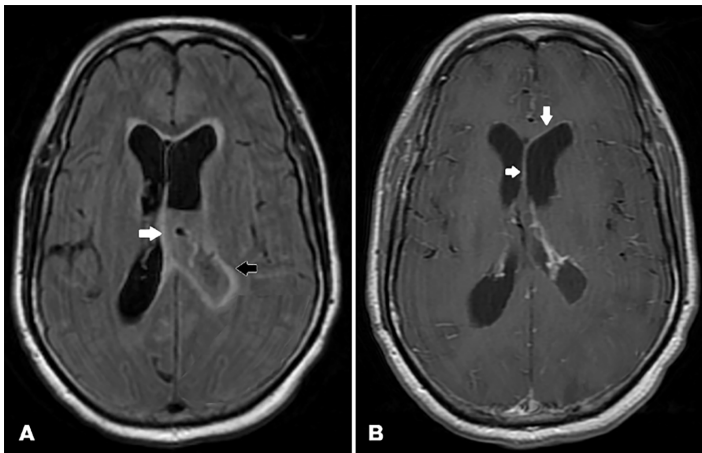
Lumbar puncture obtained cerebrospinal fluid (CSF) with 7628 nucleated cells per microliter (mL) (reference range: 0-5 cells/mL); 83% neutrophils (0-3%); glucose of 4 milligrams per deciliter (mg/dL) (45-75 mg/dL); and protein of 68 mg/dL (15-45 mg/dL).

### DISCUSSION

Ventriculitis is an inflammation of the ependymal lining of the cerebral ventricles, usually secondary to infection



**Image 1.** Axial computed tomography of the head with intravenous contrast showing mild enlargement of the left lateral ventricle (arrow).



**Image 2.** A) Axial magnetic resonance imaging (MRI) (fluid-attenuated inversion recovery sequence) showing mild enlargement of the left lateral ventricle, with debris and purulence in the ventricle (white arrow). Mild edema and transependymal flow of cerebrospinal fluid surrounding both ventricles are present (black arrow). B) Axial MRI without contrast showing enhancement of the left ventricle (white arrows).

or trauma. Ventriculitis has no accepted diagnostic criteria. Meningitis, cerebral abscess with intraventricular rupture, ventricular catheters and shunts, neurosurgical complications, intrathecal chemotherapy, and trauma are potential causes.<sup>1</sup> However, malignancy should also be considered in the differential diagnosis. *Neisseria meningitidis* and skin flora are the common causative agents.<sup>1-3</sup> Gram-positive bacteria are most common in infections involving ventricular implants such as shunts. Gram-negative bacteria are a consideration in postoperative neurosurgical ventriculitis. Ventriculitis secondary to ventricular catheters and shunt infection has an incidence of 10% and varies depending on insertion technique and management. Ventriculitis secondary to meningitis is more commonly seen in infants and immunocompromised individuals.<sup>1</sup>

Symptoms classically include fever and meningismus. Investigations for ventriculitis include CSF sampling and imaging. Cerebrospinal fluid sampling and neuroimaging are vital in making the diagnosis. Cerebral spinal fluid protein greater than 50 mg/dL, glucose less than 25 mg/dL, pleocytosis with greater than 10 cells/mL, and greater than 50% polymorphonuclear neutrophils are suggestive of ventriculitis. Cultures may be negative, despite active infection. The Infectious Diseases Society of America recommends MRI as the modality of choice.<sup>3</sup> Characteristic MRI findings include intraventricular debris and pus, abnormal periventricular and subependymal signal intensity, and enhancement of the ventricular lining. Non-contrast CT most frequently demonstrates dependent, hyperdense layering material, particularly in the occipital horns of the lateral ventricles. Hydrocephalus

### *CPC-EM Capsule*

What do we already know about this clinical entity?

*Ventriculitis is an inflammation of the ependymal lining of the cerebral ventricles, usually secondary to infection or trauma.*

What is the major impact of the image(s)?

*The diagnosis of ventriculitis is both interesting and rare. Early recognition and treatment are essential in treating this serious disease.*

How might this improve emergency medicine practice?

*Maintaining this disease process in the differential diagnosis lessens the potential for significant morbidity and mortality. Early recognition is essential.*

and periventricular low density may also be present. With contrast CT, enhancement of the ependymal lining of the ventricles may be seen.

The mainstay of treatment is intravenous antibiotics and removing any devices for catheter-related infection. Initially, empirical therapy is used based on the patient's age and etiology. For catheter-related ventriculitis, this is generally vancomycin and an anti-pseudomonal beta-lactam. Purulent material due to ventriculitis may result in occlusion of the CSF pathways, causing obstructive or multiloculated hydrocephalus. Mortality rates vary from 10-75%, but quality studies evaluating prognosis are lacking.<sup>4</sup>

Our patient was admitted to the medical ward for sepsis and ventriculitis. Both neurology and infectious disease consults were obtained. On the second day of hospitalization the patient became obtunded and underwent endotracheal intubation for airway protection. He was subsequently upgraded to the intensive care unit. The patient continued to deteriorate despite optimal care and expired on hospital day five.

The authors attest that their institution requires neither Institutional Review Board approval, nor patient consent for publication of this image in emergency medicine. Documentation on file.

---

*Address for Correspondence:* Jason Kondrat DO, Department of Emergency Medicine, Staten Island University Hospital, 475 Seaview Avenue, Staten Island, NY 10305. Email: [jkondrat@northwell.edu](mailto:jkondrat@northwell.edu).

*Conflicts of Interest:* By the *CPC-EM* article submission agreement, all authors are required to disclose all affiliations, funding sources and financial or management relationships that could be perceived as potential sources of bias. The authors disclosed none.

*Copyright:* © 2021 Kondrat et al. This is an open access article distributed in accordance with the terms of the Creative Commons Attribution ([CC BY 4.0](https://creativecommons.org/licenses/by/4.0/)) License. See: <http://creativecommons.org/licenses/by/4.0/>

---

## REFERENCES

1. Harris L and Munakomi S. Ventriculitis. 2020. Available at: <https://www.ncbi.nlm.nih.gov/books/NBK544332/>. Accessed August 27, 2020.
2. Lesourd A, Magne N, Soares A, et al. Primary bacterial ventriculitis in adults, an emergent diagnosis challenge: report of a meningococcal case and review of the literature. *BMC Infect Dis.* 2018;18(1):226.
3. Tunkel AR, Hasbun R, Bhimraj A, et al. 2017 Infectious Diseases Society of America's Clinical Practice Guidelines for Healthcare-Associated Ventriculitis and Meningitis. *Clin Infect Dis.* 2017;64(6):e34-65.
4. Nickson C. Ventriculitis. 2019. Available at: <https://litfl.com/ventriculitis/>. Accessed September 9, 2020.



Journal of Education & Teaching • Emergency Medicine

*A publication of* **CORD**

*Education*

We believe that all learners should benefit from active learning.

We are an online, open access, peer-reviewed journal repository for EM educators in all major topic areas.

*Scholarship*

We believe educators should advance through the scholarship of their educational work. JETem gives you the opportunity to publish & distribute your outstanding, scholarly academic work.

**Submit your content or contact us to become a reviewer!**




[www.jetem.org](http://www.jetem.org)



published by  
Center for Online Research and Scholarship  
University of California

JOIN  
CAL/AAEM!



**CALAAEM**

CALIFORNIA CHAPTER MEMBER OF THE  
AMERICAN COLLEGE OF EMERGENCY PHYSICIANS

*Championing  
individual physician rights  
and workplace fairness*

## **BENEFITS**

- Western Journal of Emergency Medicine Subscription
- CAL/AAEM News Service email updates
- Discounted AAEM pre-conference fees
- And more!!

## **CAL/AAEM NEWS SERVICE**

- Healthcare industry news
- Public policy
- Government issues
- Legal cases and court decisions

In collaboration with our official journal

**WestJEM** Integrating Emergency Care  
with Population Health




[FACEBOOK.COM/CALAAEM](https://www.facebook.com/CALAAEM)



FOLLOW US @CALAAEM

[HTTP://WWW.CALAAEM.ORG](http://www.calaaem.org)



# ADVANCED >

## SAVE THE DATE

### > CALIFORNIA ACEP'S ANNUAL CONFERENCE 2021

Education is targeted to Medical Students and Residents, but all are welcome to attend.

**Friday, September 10, 2021**  
Westin San Diego Gaslamp Quarter



**CALIFORNIA ACEP**  
AMERICAN COLLEGE OF EMERGENCY PHYSICIANS