

## Hill-Sachs Deformity

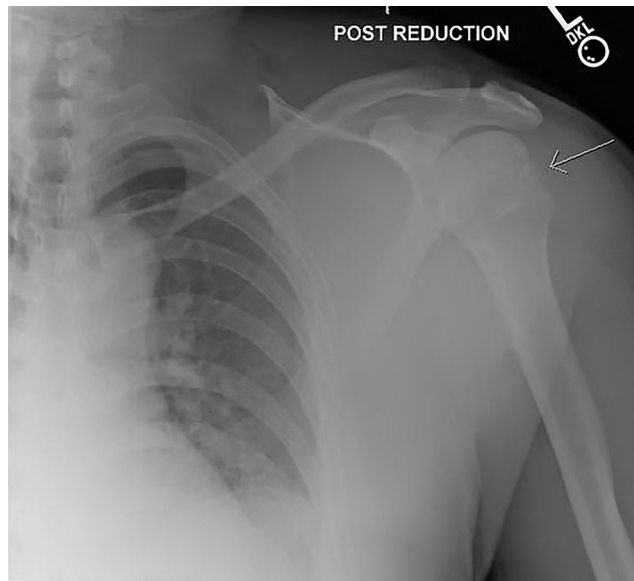
Jessa Baker\* and Shannon Toohey, MD, MAEd\*

\*University of California, Irvine, Department of Emergency Medicine, Orange, CA

Correspondence should be addressed to Shannon Toohey, MD, MAEd at [stoohey@uci.edu](mailto:stoohey@uci.edu)

Submitted: July 29, 2016; Accepted: August 22, 2016; Electronically Published: September 13, 2016; <https://doi.org/10.21980/J8Z59D>

Copyright: © 2016 Baker, et al. This is an open access article distributed in accordance with the terms of the Creative Commons Attribution (CC BY 4.0) License. See: <http://creativecommons.org/licenses/by/4.0/>



**History of present illness:** A 40-year-old male presented to the emergency department with left shoulder pain after falling off his motorcycle, landing on his left side. He denied numbness, tingling, or weakness of the extremity. The patient's vital signs were normal. On exam, his left upper extremity exam was held in adduction and internal rotation. The patient had tenderness to the anterior shoulder, with a defect at the glenohumeral joint. He was unable to flex or abduct the shoulder secondary to pain. The extremity was neurovascularly intact. The patient's shoulder was reduced in the emergency department and a post-reduction shoulder radiograph was obtained.

**Significant findings:** In the post-reduction film, there is a lateral depression in the humeral head (arrow, a Hill-Sachs deformity). A Hill-Sachs deformity is a cortical depression (fracture) in the humeral head that forms as the humeral head hits the glenoid rim during the dislocation.<sup>1,2</sup>

**Discussion:** Shoulder dislocations account for approximately 50% of joint dislocations, with 95%-97% being anterior dislocations.<sup>2-4</sup> A variety of mechanisms may cause an anterior shoulder dislocation, the most common being a blow to the abducted and extended arm. Treatment is reduction of the shoulder, of which there are numerous techniques. A Hill-Sachs deformity occurs in approximately 35%-40% of anterior

dislocations and can be seen on anteroposterior shoulder radiograph when the arm is internally rotated (Hermodsson view).<sup>2,5</sup> The diagnosis of a Hill-Sachs deformity is typically made by anteroposterior radiograph of the shoulder following reduction, and is 45% sensitive in standard view and 76% sensitive in Hermodsson view.<sup>6</sup> Orthopedic referral should be obtained for significant Hill-Sachs deformities, especially if there is an associated Bankart lesion of the glenoid labrum; however, most injuries are non-operative if the defect is less than 20% of the articular surface of the humeral head and if the glenohumeral joint remains stable.<sup>2,7</sup>

**Topics:** Shoulder dislocation, shoulder reduction, Hill-Sachs deformity, orthopedics.

**References:**

1. Blake R, Hoffman J. Emergency department evaluation and treatment of the shoulder and humerus. *Emerg Med Clin North Am.* 1999;17(4):859. doi: 10.1016/j.emc.2014.12.004
2. Sherman SC. Shoulder dislocation and reduction. In: Wolfson AB, ed. *UpToDate*. Waltham, MA: UpToDate Inc. www.uptodate.com. Updated September 19, 2015. Accessed September 6, 2016.
3. Zacchilli MA, Owens BD. Epidemiology of shoulder dislocations presenting to emergency departments in the United States. *J Bone Joint Surg Am.* 2010;92(3):542. doi: 10.2106/JBJS.I.00450
4. Simon RR, Sherman SC, Koenigskecht SJ. *Emergency orthopedics: the extremities.* 5<sup>th</sup> ed. New York, NY: McGraw-Hill; 2006.
5. Riebel GD, McCabe JB. Anterior shoulder dislocation: a review of reduction techniques. *Am J Emerg Med.* 1991;9(2):180.
6. Madler M, Mayr B, Baierl P, Klein C, Habermeyer P, Huber R. Value of conventional x-ray diagnosis and computerized tomography in the detection of Hill-Sachs defects and bony Bankart lesions in recurrent shoulder dislocations. *Rofo.* 1988;148(4):384-9. doi: 10.1055/s-2008-1048216
7. Provencher MT, Frank RM, Leclere LE, et al. The Hill-Sachs lesion: diagnosis, classification, and management. *J Am Acad Orthop Surg.* 2012;20(4):242. doi: 10.5435/JAAOS-20-04-242