

## Trimalleolar Fracture

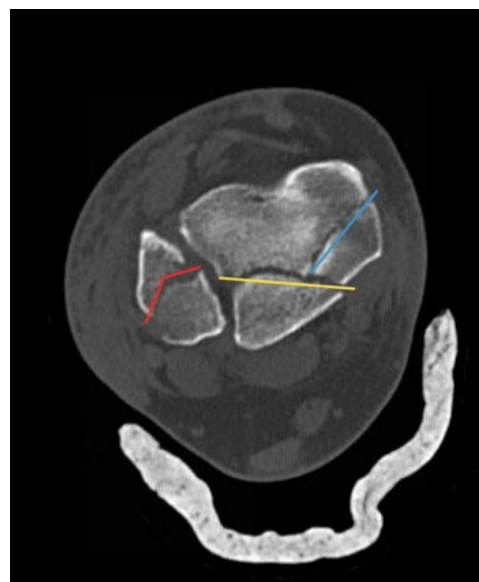
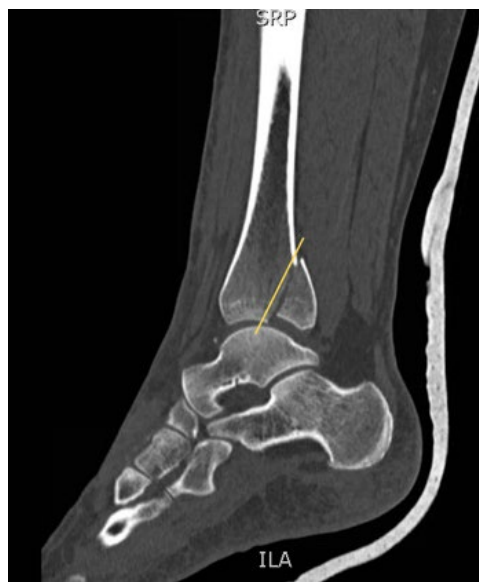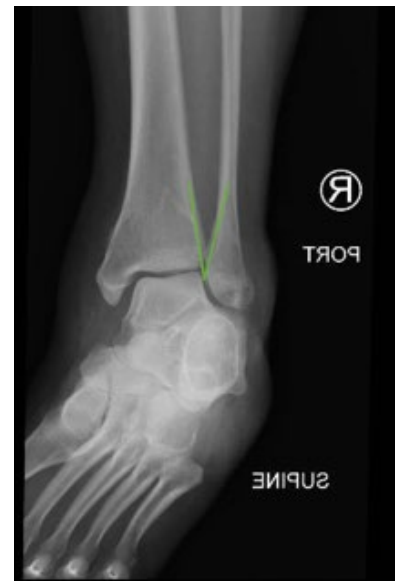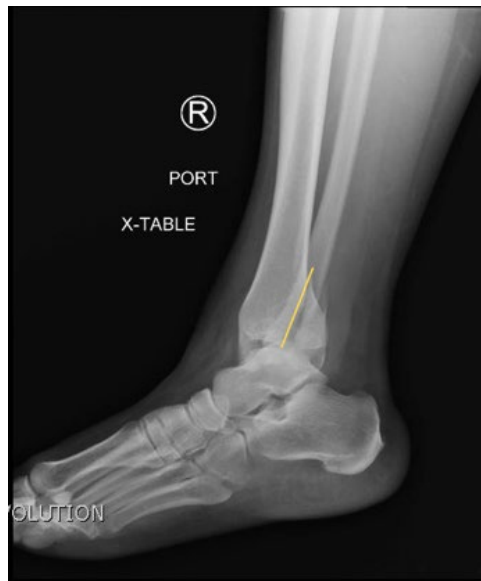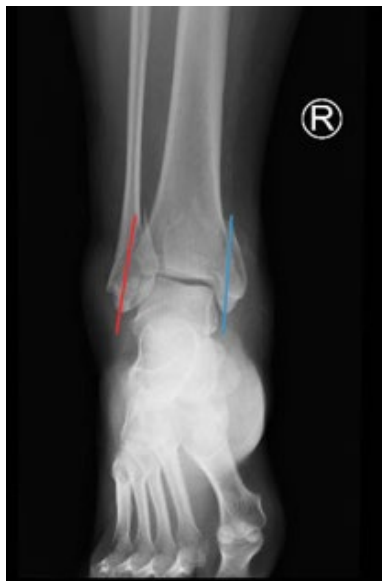Christopher Gilani\* and Shannon Toohey, MD, MAEd\*

\*University of California, Irvine, Department of Emergency Medicine, Orange, CA

Correspondence should be addressed to Shannon Toohey, MD, MAEd at [stoohy@uci.edu](mailto:stoohy@uci.edu)

Submitted: July 20, 2016; Accepted: August 6, 2016; Electronically Published: September 35, 2016; <https://doi.org/10.21980/J8PP46>

Copyright: © 2016 Gilani, et al. This is an open access article distributed in accordance with the terms of the Creative Commons Attribution (CC BY 4.0) License. See: <http://creativecommons.org/licenses/by/4.0/>



**History of present illness:** A 35-year-old female presented to the emergency department (ED) with a chief complaint of right ankle pain after a mechanical fall. She complained of intermittent right foot numbness but otherwise denied any numbness or weakness to the right lower extremity. On examination, the right ankle was diffusely tender to palpation. She had normal motor function, normal distal pulses, and toes were warm and well perfused. Radiograph imaging was obtained.

**Significant findings:** Anteroposterior (AP), lateral, and oblique X-ray views were obtained. The AP view revealed a displaced spiral fracture of the lateral malleolus (red) and a vertical fracture of the medial malleolus (blue). The lateral view revealed a displaced fracture of the posterior malleolus, tibial plafond (yellow), and the oblique view showed widening of the distal tibiofibular syndesmosis (green). Computed tomography scans confirmed trimalleolar fracture, annotated with the same colored lines (red, lateral malleolus; blue, medial malleolus; yellow, posterior malleolus).

**Discussion:** Ankle fractures are a common problem encountered in the ED. The majority of ankle fractures involve the malleolus: 66% are unimalleolar, 25% are bimalleolar, and 7% are trimalleolar.<sup>1-4</sup> In the evaluation of a patient with ankle pain, physicians should ensure that there is no associated neurovascular compromise. Physicians may use the Ottawa ankle rules to determine if radiography is necessary.<sup>3</sup> If a trimalleolar fracture is found, an orthopedic surgeon should be consulted to schedule open reduction and internal fixation (ORIF) surgery.<sup>4</sup>

**Topics:** Ankle fracture, trimalleolar fracture, orthopedics, ortho, musculoskeletal.

#### References:

1. Daly PJ, Fitzgerald RH Jr, Melton LJ, Ilstrup DM. Epidemiology of ankle fractures in Rochester, Minnesota. *Acta Orthop Scand.* 1987;58:539-544.
2. Court-Brown CM, McBirnie J, Wilson G. Adult ankle fractures—an increasing problem? *Acta Orthop Scand.* 1998;69:43-47. doi: 10.3109/17453679809002355
3. Stiell IG, Greenberg GH, McKnight RD, Nair RC, McDowell I, Worthington JR. A study to develop clinical decision rules for the use of radiography in acute ankle injuries. *Ann Emerg Med.* 1992;21:384-390.
4. Koehler SM, Eiff P. Overview of ankle fractures in adults. In: Fields KB, ed. *UpToDate.* Waltham, MA: UpToDate Inc. <https://www.uptodate.com/contents/overview-of-ankle-fractures-in-adults>. Updated December 2015. Accessed September 6, 2016.