

## Ruptured Ectopic Pregnancy

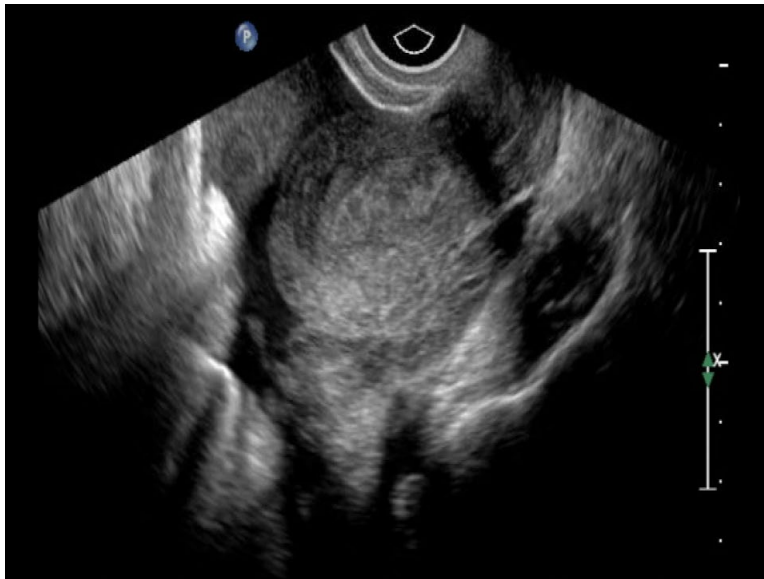
Valentina Park, BS\* and Shannon Toohey, MD, MAEd\*

\*University of California, Irvine, Department of Emergency Medicine, Orange, CA

Correspondence should be addressed to Shannon Toohey, MD, MAEd at [stoohey@uci.edu](mailto:stoohey@uci.edu)

Submitted: June 8, 2016; Accepted: July 26, 2016; Electronically Published: September 13, 2016; <https://doi.org/10.21980/J8SG6T>

Copyright: © 2016 Park, et al. This is an open access article distributed in accordance with the terms of the Creative Commons Attribution (CC BY 4.0) License. See: <http://creativecommons.org/licenses/by/4.0/>



Video Link: <https://youtu.be/biob3h-UFZE>

**History of present illness:** A 21-year-old female presented with sudden onset suprapubic abdominal pain associated with dysuria. The patient also experienced near syncope during bowel movements three times three days ago without falling or losing consciousness. She denied fever, nausea, and vomiting. She stated that she was five weeks pregnant by last menstrual period. She had an ultrasound a few weeks before that, which showed no intrauterine pregnancy, but she had not followed up for additional testing.

**Significant findings:** The patient's serum beta human chorionic gonadotropin (beta-hCG) was 5,637 mIU/mL. The transvaginal ultrasound showed an empty uterus with free fluid posteriorly in the pelvis and Pouch of Douglas (00:00). A 4.5 cm heterogeneous mass was visible in the left adnexa concerning for an ectopic pregnancy (00:10).

**Discussion:** Ectopic pregnancies are a leading cause of maternal morbidity and mortality, as well as decreased fertility.<sup>1,2</sup> Differentiating between an ectopic pregnancy and a normal early pregnancy may be difficult, since ultrasound and quantitative beta-hCG may show inconclusive results.<sup>3,4</sup> Patients who have used fertility treatment may further complicate the picture because they are at risk for heterotopic

pregnancies.<sup>5</sup> Ectopic pregnancies most commonly implant in the fallopian tube, but may alternatively implant in the ovary, cervix, abdomen, or uterine cornua.<sup>4</sup> Ultrasonography may show an empty uterus, adnexal mass, pelvic free fluid, or an extra-uterine gestational sac, yolk sac, and/or embryo.<sup>6</sup> Treatment options for ectopic pregnancy include surgery or methotrexate.<sup>2,4</sup> Some patients may be candidates for close outpatient surveillance if the diagnosis is unclear or in very limited cases for early, non-ruptured ectopic pregnancies.<sup>2,4</sup>

**Topics:** Ultrasound, point-of-care ultrasound, POCUS, ectopic pregnancy, ectopic, ruptured ectopic, obstetrics, OB, OB/gyn.

#### References:

1. Fylstra DL. Tubal pregnancy: a review of current diagnosis and treatment. *Obstet Gynecol Surv.* 1998;53(5):320-328.
2. Farquhar CM. Ectopic pregnancy. *Lancet.* 2005;366(9485):583-591. doi: 10.1016/S0140-6736(05)67103-6
3. Barnhart KT, Simhan H, Kamelle SA. Diagnostic accuracy of ultrasound above and below the beta-hCG discriminatory zone. *Obstet Gynecol.* 1999;94(4):583-587.
4. Medical management of ectopic pregnancy. ACOG Practice Bulletin No. 94. American College of Obstetricians and Gynecologists. *Obstet Gynecol.* 2008;111(6):1479-1485. doi: 10.1097/AOG.0b013e31817d201e
5. Hahn SA, Lavonas EJ, Mace SE, Napoli AM, Fesmire FM. American College of Emergency Physicians Clinical Policies Subcommittee on Early Pregnancy. *Ann Emerg Med.* 2012;60(3):381-390. doi: 10.1016/j.annemergmed.2012.04.021
6. Alkatout I, Honemeyer U, Strauss A, Tinelli A, Malvasi A, Jonat W, et al. Clinical diagnosis and treatment of ectopic pregnancy. *Obstet Gynecol Surv.* 2013;68(8):571-81. doi: 10.1097/OGX.0b013e31829cdeb