

Large Right Pleural Effusion

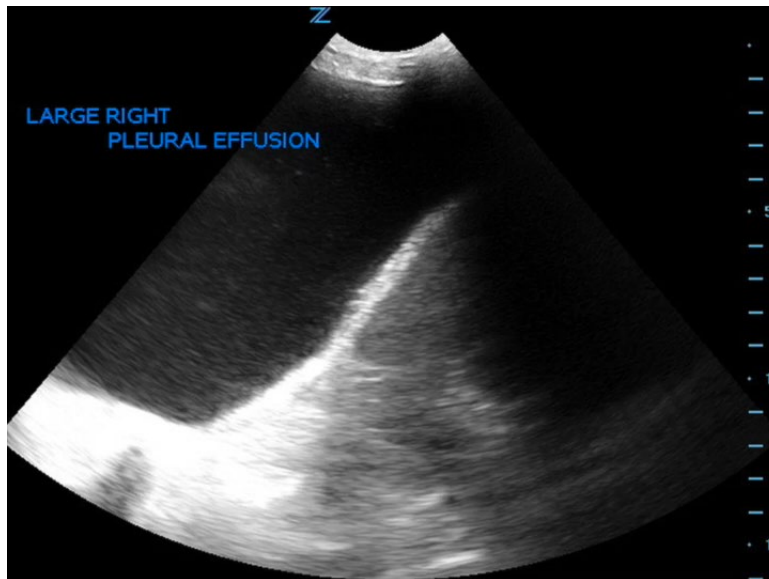
Robert Rowe, MD* and Alisa Wray, MD*

*University of California, Irvine, Department of Emergency Medicine, Orange, CA

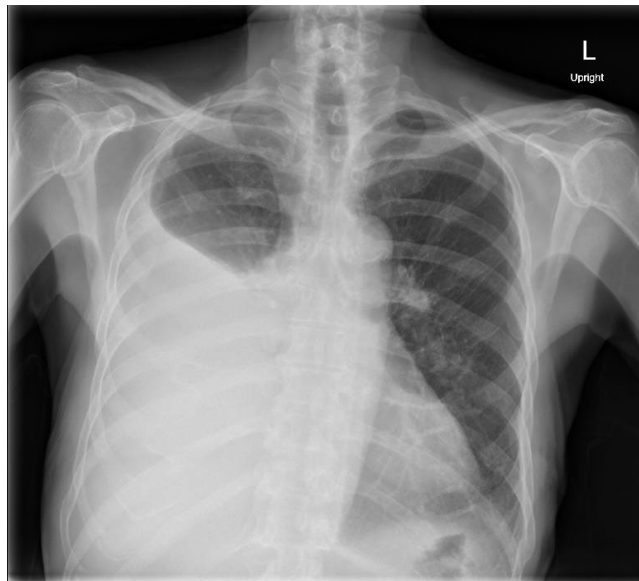
Correspondence should be addressed to Robert Rowe, MD at rower@uci.edu

Submitted: June 23, 2016; Accepted: August 2, 2016; Electronically Published: September 13, 2016; <https://doi.org/10.21980/J8D59F>

Copyright: © 2016 Rowe, et al. This is an open access article distributed in accordance with the terms of the Creative Commons Attribution (CC BY 4.0) License. See: <http://creativecommons.org/licenses/by/4.0/>



Video Link: <https://youtu.be/dCQKYaDgNp0>



History of present illness: An 83-year-old male with a distant history of tuberculosis status post treatment and resection approximately fifty years prior presented with two days of worsening shortness of breath. He denied any chest pain, and reported his shortness of breath was worse with exertion and lying flat.

Significant findings: Chest X-ray and bedside ultrasound revealed a large right pleural effusion, estimated to be greater than two and a half liters in size.

Discussion: The incidence of pleural effusion is estimated to be at least 1.5 million cases annually in the United States.¹ Erect posteroanterior and lateral chest radiography remains the mainstay for diagnosis of a pleural effusion; on upright chest radiography small effusions (>400mL) will blunt the costophrenic angles, and as the size of an effusion grows it will begin to obscure the hemidiaphragm.¹ Large effusions will cause mediastinal shift away from the affected side (seen in effusions >1000mL).¹ Lateral decubitus chest radiography can detect effusions greater than 50mL.¹

Ultrasonography can help differentiate large pulmonary masses from effusions and can be instrumental in guiding thoracentesis.¹ The patient above was comfortable at rest and was admitted for a non-emergent thoracentesis. The pulmonology team removed 2500mL of fluid, and unfortunately the patient subsequently developed re-expansion pulmonary edema and pneumothorax ex-vacuo. It is generally recommended that no more than 1500mL be removed to minimize the risk of re-expansion pulmonary edema.²

Topics: Ultrasound, point-of-care ultrasound, POCUS, pleural effusion, chest X-ray, X-ray, lung, pulmonary, fluid overload.

References:

1. Nicks BA, Manthey DE. Pleural effusion. In: Adams JG, Barton ED, Collings JL, DeBlieux PM, Gisondi MA, Nadel ES, eds. *Emergency Medicine: Clinical Essentials*. 2nd ed. Philadelphia, PA: Elsevier; 2013:431-437.
2. Roberts J, Hedges J. Thoracentesis. In: Adams JG, Barton ED, Collings JL, DeBlieux PM, Gisondi MA, Nadel ES, eds. *Emergency Medicine: Clinical Essentials*. 2nd ed. Philadelphia, PA: Elsevier; 2013:173-189.