

The Halloween Lateral Canthotomy Model

Nur-Ain Nadir, MD, MHPE*, Ifat Sattar, DO* and Ammar Ahmed, MD*

*University of Illinois College of Medicine – Peoria, Department of Emergency Medicine, Peoria, IL

Correspondence should be addressed to Nur-Ain Nadir, MD, MHPE at nurainnadir@yahoo.com

Submitted: March 2, 2017; Accepted: March 9, 2017; Electronically Published: April 15, 2017; <https://doi.org/10.21980/J8GW2N>

Copyright: © 2017 Nadir, et al. This is an open access article distributed in accordance with the terms of the Creative Commons Attribution (CC BY 4.0) License. See: <http://creativecommons.org/licenses/by/4.0/>

ABSTRACT:

Audience: The Halloween lateral canthotomy model is designed to instruct emergency medicine residents PGY 1-4, as well as emergency medicine-bound students.

Introduction: Although uncommon, retrobulbar hemorrhage associated with facial trauma is a potential cause of permanent vision loss due to orbital compartment syndrome.¹ To prevent vision loss, treatment with lateral canthotomy is time-sensitive and to perform this procedure in an emergent setting requires properly trained practitioners.¹

Objectives: The purpose of the model is to teach residents and students how to perform lateral canthotomy and to achieve competency in their skills. By the end of this instructional session learners should be able to: 1) Discuss the indications, contraindications and complications associated with the procedure, and 2) be able to perform cantholysis via lateral canthotomy on simulated models.

Methods: Lateral canthotomy is an important skill to be proficient in for any emergency medicine physician, as it is an uncommon, sight-saving procedure. It is indicated in scenarios of facial trauma that cause a retrobulbar hemorrhage. Patients are at risk for permanent vision loss due to acute orbital compartment syndrome if the procedure is not done expeditiously.¹ A less likely cause of retrobulbar hemorrhage is spontaneous hemorrhage due to a bleeding disorder or anticoagulant use.² The features of retrobulbar hemorrhage include acute loss of visual acuity, relative afferent pupillary defect, proptosis with resistance to retropulsion, increased intraocular pressure, and limited extra ocular movement.³ While the diagnosis is clinical, it can be confirmed by computed tomography (CT) and measurement of intraocular pressure.² When the diagnosis is established, lateral canthotomy and cantholysis should be performed emergently. Cantholysis is contraindicated when a globe rupture is suspected or with an orbital blowout fracture. Potential complications of this procedure include iatrogenic injury to the globe or lateral rectus muscle, damage to the elevator aponeurosis resulting in ptosis, injury to the lacrimal gland and lacrimal artery, bleeding and infection.³ This task trainer uses affordable materials to let learners practice this rare, vision saving procedure.

Topics: Visual acuity, eye trauma, retrobulbar hemorrhage, relative afferent pupillary defect.



USER GUIDE

Learner Audience:

Emergency medicine-bound medical students, interns, junior residents, and senior residents, as well as ophthalmology residents

Time Required for Implementation:

Preparation:

- Each model takes about 10 minutes to assemble.

Didactics:

- Each procedure takes 1 minute. Each learner has the ability to practice on cantholysing the inferior and superior crus of the lateral canthal ligament.

Learners per instructor:

- 2 learners per model – one for each eye and about 6-8 learners per small group session.

Topics:

Visual acuity, eye trauma, retrobulbar hemorrhage, RAPD.

Objectives:

By the end of this instructional session learners should be able to:

1. Discuss the indications, contraindications and complications associated with the procedure.
2. Be able to perform cantholysis via lateral canthotomy on simulated models.

Linked objectives and methods:

Learners are expected to come to this session prepared with pre-reading on the procedure.

Faculty solicit indications, contraindications and complications of this procedure from learners (objective 1) and then proceed to explain and demonstrate the performance of the procedure.

Faculty then directly observe learners performing the procedure (objective 2) and provide real time feedback.

Recommended pre-reading for instructor:

- Ballard SR, Enzenauer RW, O'Donnell T, O'Donnell T, Fleming JC, Risk G, et al. Emergency lateral canthotomy and cantholysis: a simple procedure to preserve vision from sight threatening orbital hemorrhage. *J Spec Oper Med.* 2009;9(3):26-32.
- Knoop KJ, Dennis WR. Ophthalmologic procedures. In: Roberts JR, ed. *Roberts and Hedges' Clinical Procedures in Emergency Medicine.* 6th edition. Philadelphia, PA: Elsevier; 2014:1293-1295.
- Sarwark J. The lateral canthotomy. EM Curious. [http://www.emcurious.com/blog-1/2014/9/25/the-](http://www.emcurious.com/blog-1/2014/9/25/the-lateral-canthotomy)

lateral-canthotomy. Published September 25, 2014. Accessed March 1, 2017.

- Nickson C. Bashed, blind and bulging. Life in the Fastlane. www.lifeinthefastlane.com/ophthalmology-befuddler-033-2. Accessed March 1, 2017.

Learner responsible content (LRC):

- Same as pre-reading for instructor.

Implementation Methods:

- This model is best utilized in small group sessions with faculty to student ratios of 6:1 to 8:1.
- Faculty facilitate each small group session through initial discussion of the indications, contra-indications and complications of lateral canthotomy. They follow this by explaining the procedure and demonstrating its performance on the task trainer. Subsequently they observe learners performing the procedure and provide real time feedback on its performance using a checklist.

List of items required to replicate this innovation:

1. Celebrity or Person (not monster) Halloween masks (available Amazon.com: https://www.amazon.com/gp/product/B003C1APBS/ref=oh_aui_detailpage_o00_s00?ie=UTF8&psc=1)
Tip: To be cost-effective, plan this activity immediately after Halloween because masks on Amazon as well as various party stores go on sale and can be purchased economically, hence the name of the model.
2. Ping-pong Eye Balls (available at Amazon.com: https://www.amazon.com/gp/product/B00EO94V08/ref=oh_aui_search_detailpage?ie=UTF8&psc=1)
3. White Hair Ties 0.3 cm diameter, preferably flat not tubular, available at Claire.com (or any superstore).
4. Styrofoam manikin head (available at Amazon: https://www.amazon.com/Hatop-Styrofoam-Mannequin-Manikin-Glasses/dp/B01N78EQQB/ref=sr_1_20_a_it?ie=UTF8&qid=1488479198&sr=8-20&keywords=white+flat+hair+rubber+band)
5. Scissors
6. Needle and thread to suture
7. Thumbtacks
8. Binder Clips
9. Laceration repair tray (for performing procedure)

Approximate cost of items to create this innovation:

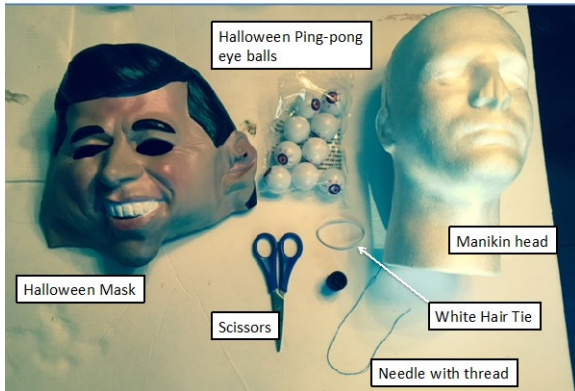
\$7-8* per model (depends on the price of the masks, tip: search around for the cheapest masks available as they tend to fluctuate in price).



USER GUIDE

Detailed methods to construct this innovation:

Supplies

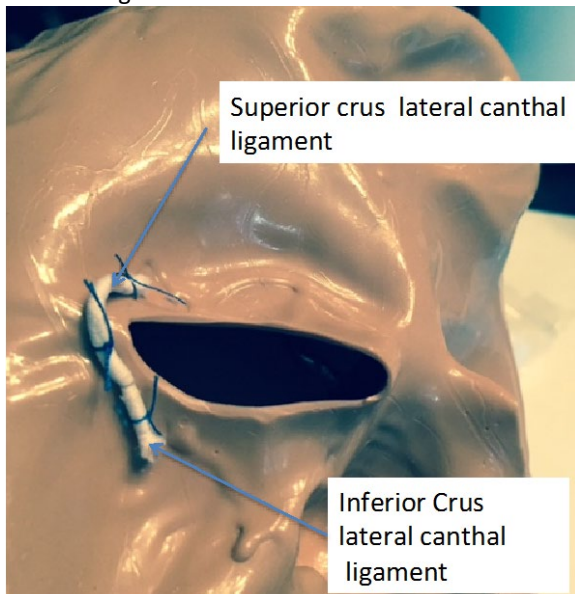


Step 1:

Invert the Halloween mask. Find the lateral corner of the masks eye-holes.

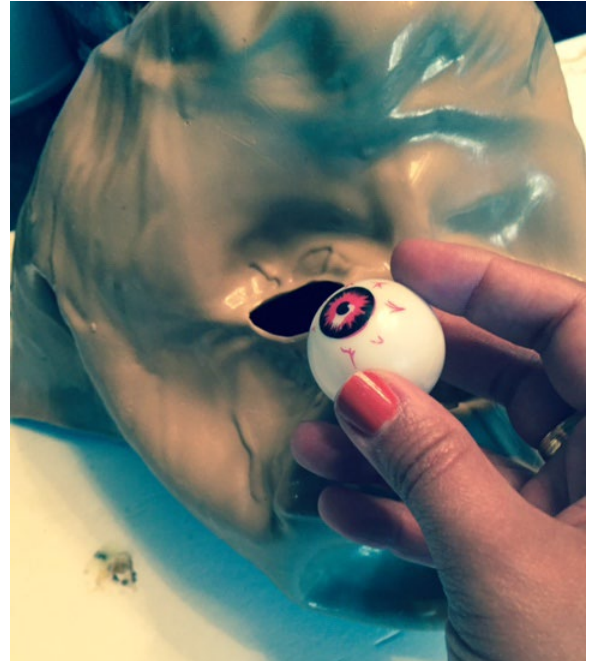Step 2:

Stitch the white hair tie to the lateral corners in the fashion depicted so as to simulate both superior and inferior crus of the lateral canthal ligament.



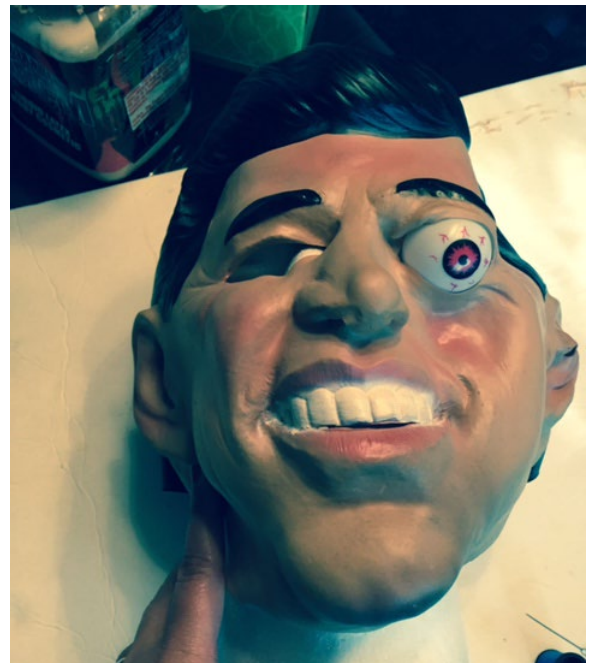
Step 3:

Take the ping-pong ball eye and insert it into the back of the mask. Make sure that this is snug.



Step 4:


Apply the mask to a manikin – we used Styrofoam manikin heads. Ensure that the mask is on firmly. You can use thumbtacks and binder clips to draw it tightly across the manikin face.



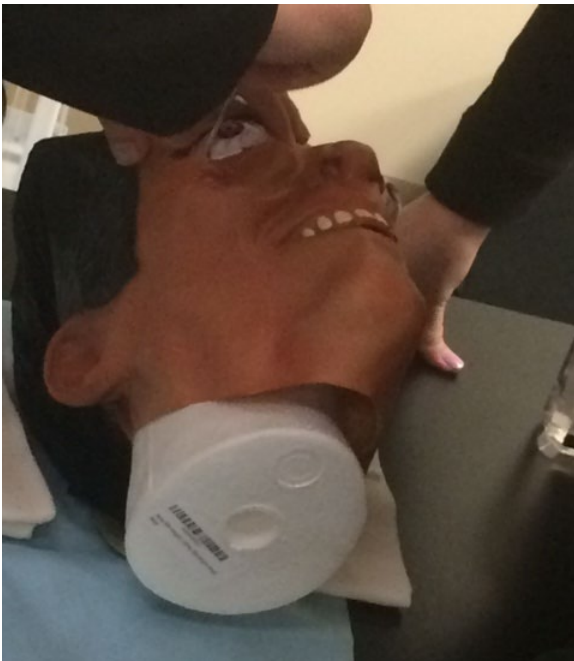


USER GUIDE

Step 5:
Repeat for other eye.



Step 6:
Proceed with procedure using the set up provided. Hold the manikin head to prevent it from rolling while performing the procedure.



This exercise is best implemented in small group sessions with a faculty to learner ratio of 6:1 or 8:1.

Feedback from 36 learners was overwhelmingly positive. 14 of 36 learners completed evaluations and 57% of them reported post-laboratory comfort levels at 4-5/5 on 5-point Likert scale. The rest reported comfort levels at 3/5 on a 5-point Likert scale. With respect to satisfaction with the model itself, 57% of learners rated the lateral canthotomy model at a 4/5 on a 5-point Likert scale. Another 35% of learners reported the model at a 5/5.

Feedback from comments showed some interest in practicing measurement of intraocular pressure during this laboratory. Therefore, this extra component will be added to future laboratories by including tonometry as a separate distinct station within the procedure laboratory.

Tip 1: For optimal performance of procedure, the Styrofoam heads need to be stabilized: therefore, pair 2 learners to one model. Ask learner 1 to hold the model and observe, while learner 2 performs the procedure. Subsequently switch eyes and roles. The procedural skill is reinforced through observation of its performance.

Tip 2: As a variation of this basic model, slip the Halloween Lateral Canthotomy Mask onto a high-fidelity manikin simulator instead of the Styrofoam head to use in a simulation case.

References/suggestions for further reading:

- Ballard SR, Enzenauer RW, O'Donnell T, O'Donnell T, Fleming JC, Risk G, et al. Emergency lateral canthotomy and cantholysis: a simple procedure to preserve vision from sight threatening orbital hemorrhage. *J Spec Oper Med.* 2009;9(3):26-32.
- Nickson C. Bashed, blind and bulging. *Life in the Fastlane.* www.lifeinthefastlane.com/ophthalmology-befuddler-033-2. Accessed March 1, 2017.
- Knoop KJ, Dennis WR. Ophthalmologic procedures. In: Roberts JR, ed. *Roberts and Hedges' Clinical Procedures in Emergency Medicine.* 6th edition. Philadelphia, PA: Elsevier; 2014:1293-1295.
- Sarwark J. The lateral canthotomy. *EM Curious.* <http://www.emcurious.com/blog-1/2014/9/25/the-lateral-canthotomy>. Published September 25, 2014. Accessed March 1, 2017.

Results and tips for successful implementation:

Nadir N, et al. The Halloween Lateral Canthotomy Model. *JETem* 2017. 2(2): 117-20.
<https://doi.org/10.21980/J8GW2N>