

## Development of a Head and Neck Regional Anesthesia Task Trainer for Emergency Medicine Learners

Diane L Gorgas, MD\*, Sarah Greenberger, MD\*, Jillian McGrath, MD\*, David P Way, MEd\* and Chad Donley, MD^

\*The Ohio State University College of Medicine, Department of Emergency Medicine, Columbus, OH

^St. Elizabeth Youngstown Hospital, Department of Emergency Medicine, Youngstown, Ohio

Correspondence should be addressed to Diane L. Gorgas, MD at [diane.gorgas@osumc.edu](mailto:diane.gorgas@osumc.edu)

Submitted: March 2, 2017; Accepted: March 17, 2017; Electronically Published: April 15, 2017; <https://doi.org/10.21980/J8T595>

Copyright: © 2017 Gorgas, et al. This is an open access article distributed in accordance with the terms of the Creative Commons Attribution (CC BY 4.0) License. See: <http://creativecommons.org/licenses/by/4.0/>

### ABSTRACT:

**Audience:** This innovation is designed for medical students through senior residents.

**Introduction:** Regional anesthesia increases the emergency medicine (EM) physician's ability to provide effective pain relief and to complete procedures within the emergency department (ED). Studies consistently demonstrate that emergency physicians undertreat pain when performing basic procedures such as suturing lacerations.<sup>1,2</sup> Regional anesthesia allows for effective pain relief, while avoiding the risks associated with systemic analgesia/anesthesia or the tissue distortion of local anesthesia.<sup>3</sup> Knowledge of the anatomy involved in various nerve blocks is crucial to the development of proper technique and successful performance of this skill. Three dimensional (3-D) model simulation-based mastery of procedural skills has been demonstrated to decrease resident anxiety, improve success rates, and decrease complications during the resident's transition into the clinical setting.<sup>5,6</sup> Similarly, use of a 3-D head and neck model to practice application of facial regional anesthesia is hypothesized to improve provider confidence and competence which will in turn provide an improved patient experience.

**Objectives:** In participating in the educational session associated with this task trainer, the learner will:

- 1) Identify landmarks for the following nerve blocks: Infraorbital, supraorbital (V1), mental, periauricular
- 2) Demonstrate the appropriate technique for anesthetic injection for each of these nerve blocks
- 3) Map the distribution of regional anesthesia expected from each nerve block
- 4) Apply the indications and contraindications for each regional nerve block

**Methods:** This low-fidelity task trainer allows residents and medical students to practice various nerve blocks on the face in order to improve learner confidence and proficiency in performing facial regional anesthesia.

**Topics:** Regional anesthesia, nerve blocks, complex facial laceration repair, infraorbital nerve, periauricular nerve, supraorbital nerve, mental nerve.

# INNOVATIONS





# USER GUIDE

## List of Resources:

Abstract	1
User Guide	2
Learner Materials	9
Indications/Contraindications Examination	9
Regional Facial Anesthesia Examination	11
Instructor Materials	13
Indications/Contraindications Examination	14
Key	14
Regional Facial Anesthesia Examination Key	16

## Learner Audience:

Medical students, interns, junior residents, senior residents

## Time Required for Implementation:

Preparation: 49 hours

- 1 hour preparation
- 24 hours for plaster to set
- 24 hours for gelatin to set

Didactics: 2 hours

- Lecture: 30 minutes
- Hands-on session: 90 minutes

Learners per instructor:

- One faculty member prepared and presented the lecture with an associated PowerPoint presentation
- 3:1 learner-to-task trainer ratio for the hands-on portion of the session provided adequate practice for each learner
- 6:1 learner-to-instructor ratio was found to also work for resident level learners with one instructor covering two groups of learners working on two task trainers simultaneously.
- More instructors would benefit more novice learners (eg medical students)

## Topics:

Regional anesthesia, nerve blocks, complex facial laceration repair, infraorbital nerve, periauricular nerve, supraorbital nerve, mental nerve.

## Objectives:

In participating in the educational session associated with this task trainer, the learner will:

1. Identify landmarks for the following nerve blocks:
  - a. Infraorbital
  - b. Supraorbital (V1)
  - c. Mental
  - d. Periauricular

2. Demonstrate the appropriate technique for anesthetic injection for each of these nerve blocks
3. Map the distribution of regional anesthesia expected from each nerve block
4. Apply the indications and contraindications for each regional nerve block

## Linked objectives and methods:

This format allows achievement of the goals and objectives by introducing the content material in multiple formats (visual and auditory via PowerPoint lecture, read/write pre-assignment reading material, and kinesthetic via hands-on simulation with the task trainer), which optimizes retention for adult learners.

## Recommended pre-reading for instructor:

- Review of anesthetics: Gmyrek R. Local and regional anesthesia. In: Elston DM, ed. Medscape. <http://emedicine.medscape.com/article/1831870-overview#a1>. Updated July 7, 2015. Accessed April 13, 2017.
- Latham JL, Martin SN. Infiltrative anesthesia in office practice. *Am Fam Physician*. 2014;89(12):956-962.
- Infraorbital nerve block: pladmd. 4 infraorbital nerve block UBC CDE. <https://www.youtube.com/watch?v=H382MZF5xvM>. Published Jan 5, 2012. Accessed April 13, 2017.
- Mental nerve block: Latina S. Mental nerve block. <https://www.youtube.com/watch?v=5ALXimfm0EM>. Published December 30, 2013. Accessed April 13, 2017.
- Periauricular nerve block: Hutchens DJ. In: Rahgavendra M, ed. Ear anesthesia. Medscape. <http://emedicine.medscape.com/article/82698-overview#a9> (see anesthesia and multimedia library tabs). Accessed April 13, 2017.
- Amsterdam JT, Kilgore KP. Regional anesthesia of the head and neck. In: *Roberts and Hedges' Clinical Procedures in Emergency Medicine*. 6<sup>th</sup> ed. Philadelphia, PA: Elsevier; 2014:541-553.e1.
- Healy SM, Quinn FB. Local anesthesia techniques in oral and maxillofacial surgery. <http://www.utmb.edu/otoref/grnds/anesth-mouth-0410/anesth-mouth.pdf>. Published October 2004. Accessed April 13, 2017.

## Learner responsible content (LRC):

- Review of anesthetics: Gmyrek R. Local and regional anesthesia. In: Elston DM, ed. Medscape. <http://emedicine.medscape.com/article/1831870-overview#a1>. Updated July 7, 2015. Accessed April 13, 2017.



# USER GUIDE

- Infraorbital nerve block: pladmd. 4 infraorbital nerve block UBC CDE. <https://www.youtube.com/watch?v=H382MZF5xvM>. Published Jan 5, 2012. Accessed April 13, 2017.
- Mental nerve block: Latina S. Mental nerve block. <https://www.youtube.com/watch?v=5ALXimfm0EM>. Published December 30, 2013. Accessed April 13, 2017.
- Periauricular nerve block: Hutchens DJ. In: Rahgavendra M, ed. Ear anesthesia. Medscape. <http://emedicine.medscape.com/article/82698-overview#a9> (see anesthesia and multimedia library tabs). Accessed April 13, 2017.
- Amsterdam JT, Kilgore KP. Regional anesthesia of the head and neck. In: *Roberts and Hedges' Clinical Procedures in Emergency Medicine*. 6<sup>th</sup> ed. Philadelphia, PA: Elsevier; 2014:541-553.e1.

## Goals/Objectives:

In participating in the educational session associated with this task trainer, the learner will:

- 1) Identify the landmarks for the following nerve blocks, and to be able to map out the distribution of regional anesthesia expected from each nerve block.
  - a. Infraorbital
  - b. Supraorbital (V1)
  - c. Mental
  - d. Periauricular.

The learner should be able to trace the course of each nerve on the task trainer. This is observed by the instructor during the session (Note: The instructor and learner can easily attain this objective by reading the pre-session materials). Outlining the course of each nerve is a necessary pre-requisite to being able to successfully administer the associated facial nerve block.

- 2) Demonstrate the appropriate technique for anesthetic injection for each of these nerve blocks.

This list of procedural competency steps is specific, can be measured with a high degree of inter-rater reliability, and is attainable within a 2-hour instructional session. The procedural competency steps are directly transferable to application in the clinical setting. The learner will be able to demonstrate the proper technique for administering each regional nerve block, which includes the following steps:

- a) Communicates the process, benefits, and risks of a nerve block clearly to the patient.
- b) Explains expectations of analgesia, involved areas, duration, and safety.
- c) Chooses the appropriate equipment for performing the nerve block.

- d) Takes a time out period before each procedure to identify the correct patient, the correct procedure, the correct location.
- e) Chooses correct anesthetic and demonstrates proper technique for preparing the medication.
- f) Demonstrates proper aseptic technique for injection.
- g) Positions the patient safely and correctly.
- h) Demonstrates accurate knowledge of surface anatomy and landmarks.
- i) Uses the surface anatomy landmarks to guide the needle correctly.
- j) Aspirates before injection, and performs appropriate test dose.
- k) Performs pertinent pain assessment before and after procedure.

- 3) Review the indications and contraindications for each regional nerve block.

This is measurable through direct questioning of the learner or through post-test assessment. Participants will learn this content material from the pre-session readings and the 2-hour hands-on instruction.

### a) Indications:

- Complex Facial Lacerations
- Lacerations which cross cosmetically sensitive areas (Vermillion border) where local infiltration may distort anatomy
- Expansive lacerations requiring higher volume use of anesthetics

### b) Contraindications:

- Pediatric patients, (i.e. preverbal or children who are too young to be able to cooperate with the procedure), combative patients, demented patients
- Bleeding disorders
- Local anesthetic toxicity risk
- Pre-existing peripheral neuropathies

## Implementation Methods:

Session outline and time allocation:

- 1) Overview of head and neck regional anesthesia pharmacology, indications, contraindications, and expectations for the procedure using PowerPoint presentation (see attached and Figure 4). [20 Minutes]
- 2) Assign learners to small groups. [5 Minutes]
- 3) Review of facial nerve anatomy and bony landmarks. [20 Minutes]
- 4) Kinesthetic practice of regional nerve blocks with instructor feedback. [45 Minutes]
- 5) Competency assessment of behaviors listed in Objective #2. (see Regional Facial Anesthesia Examination) [30 Minutes]



# USER GUIDE

- 6) Post-test assessment on indications and contra-indications [After session]

## List of items required to replicate this innovation:

Supplies listed are to make a single facial regional nerve block model.

- A Styrofoam wig stand head, available at beauty supply stores or online at Amazon:
  - [http://www.amazon.com/dp/B001BAN0FK?tag=googhydr-20&hvadid=85351671651&hvpos=1t2&hvexid=&hvnetw=g&hvrnd=11913436773826322406&hvpon=&hvptwo=&hvqmt=b&hvdev=c&ref=pd\\_sl\\_22g7nj465c\\_b](http://www.amazon.com/dp/B001BAN0FK?tag=googhydr-20&hvadid=85351671651&hvpos=1t2&hvexid=&hvnetw=g&hvrnd=11913436773826322406&hvpon=&hvptwo=&hvqmt=b&hvdev=c&ref=pd_sl_22g7nj465c_b) Accessed 4/1/17.
- A plastic skull model, available from online medical supply sites for example: Anatomy Warehouse.com:
  - <https://www.anatomywarehouse.com/budget-life-size-skull-anatomy-model-a-102491>
- One tub of plaster of Paris (or plaster casting tape, as an alternative) available at hardware stores or online at Amazon:
  - [http://www.amazon.com/3M-Health-Care-82003U-Casting/dp/B00N122OT4?ie=UTF8&keywords=plaster%20cast%20tape&qid=1465483769&ref=sr\\_1\\_1&sr=8-1](http://www.amazon.com/3M-Health-Care-82003U-Casting/dp/B00N122OT4?ie=UTF8&keywords=plaster%20cast%20tape&qid=1465483769&ref=sr_1_1&sr=8-1) Accessed 4/1/17.
- 4 boxes of Knox® gelatin, available at any grocery store.
- 10 cc syringes, 25-gauge 1-inch needles, and saline for practice injections.
- 1 roll of plastic wrap (cling film) such as Saran™ Wrap.
- 3 Chopsticks.

## Approximate cost of items to create this innovation:

Total expenditure for a single task trainer ranged from \$40-\$120, depending on the quality of the plastic skull purchased. For our training program of 50 residents, we purchased supplies for four models, with an initial investment of \$300. The wig form, skull, plaster of Paris cast, needles, and syringes can all be re-used and are therefore a one-time expense.

## Detailed methods to construct this innovation:

- 1) Cover a foam wig stand with plaster of Paris to create a reverse mold, the shape of which will correspond to the soft tissue structures of the face (see Figure 1). Wait 24 hours for the plaster to set, and then remove the plaster mold from the wig stand.
- 2) Line the plaster mold with a thin layer of cling plastic wrap (Saran™ Wrap or a similar product).

- 3) To replicate bony landmarks, suspend the skull face down in the plaster mold, allowing for a small space (4 mm) between the skull and the mold. The skull can be suspended by threading one narrow chopstick or wooden skewer into the skull along the coronal plane between the superior mandibular rami (just anterior to the mandibular fossa) to stabilize the skull in the lateral plane. Two additional chopsticks or skewers are then threaded superior-laterally to inferior and medially along both the right and the left anterior zygomatic arch, protruding caudally and crossing in the submental space. This six point suspension system works to suspend the skull above the mold to allow for a roughly 4 mm gap for the gelatin to fill in, accurately representing soft tissue. (see Figures 2a & 2b)
- 4) Prepare the liquid gelatin according to the package instructions. Then pour the gelatin into the mold between the skull and the plaster of Paris.
- 5) The gelatin will set or harden into a facial mask in roughly 8 hours, after which it can be removed from the mold (see Figure 3). This gelatin facial mask will be re-applied to the skull to create the neuro task-trainer to be used for the hands-on session.



Figure 1. Reverse mold created with Plaster of Paris on a foam wig stand.



## USER GUIDE

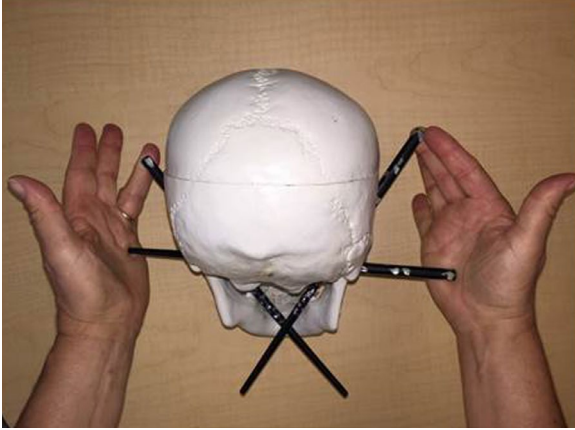


Figure 2a. Preparing the skull with chopsticks.

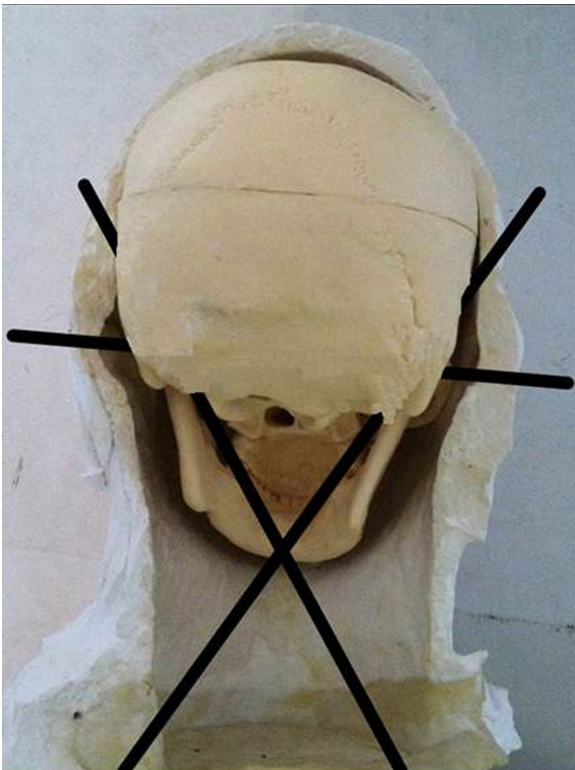


Figure 2b. Suspending the skull with chopsticks in the reverse mold.

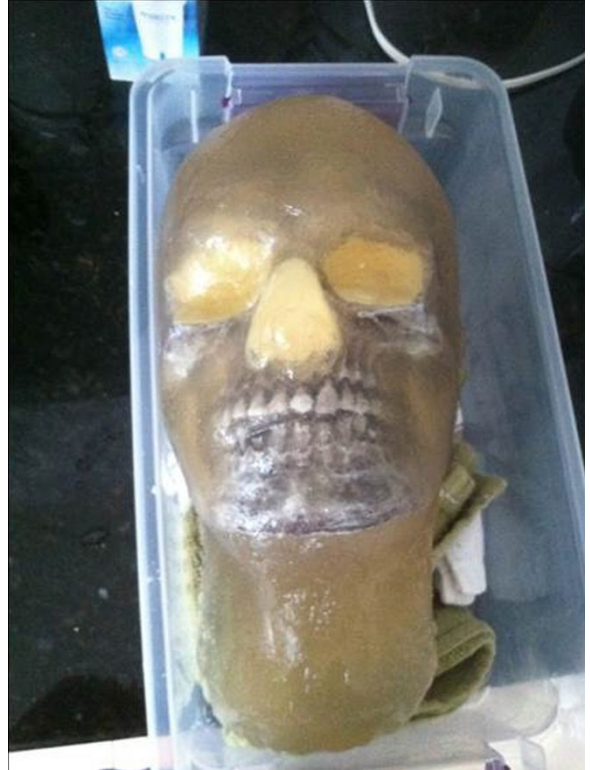

Figure 3. Final product is the gelatin facial mask after it has been removed from the reverse mold and reapplied to the skull.

### Results and tips for successful implementation:

This session was part of a didactic curriculum within a 3-year Emergency Medicine residency program at a large, urban, Level I trauma center. Sessions were also opened to medical students who rotated through the emergency department at the time of instruction. This task trainer was developed in 2012 and has been used annually since then.

A comparison analysis between average instructional assessment of facial regional anesthesia lectures and the simulated curriculum showed an overall increase in learner satisfaction (Likert-type scale of overall quality of material from 4.2 to 4.9 on 1-5 scale) and comfort in performing in the clinical setting improvement (3.2 to 4.7 on 1-5 scale).

The learners were generally more comfortable performing the procedure in the clinical setting following this two-hour session and were evaluated by faculty preceptors during the session as proficient in completing the procedures.

### Planned future modifications:

Based on learner feedback, we are planning to create three different types of task trainers so that the learner can learn and practice in a step-wise fashion from easy to difficult.



# USER GUIDE

- 1) Step 1: Beginning learners will be able to practice with head and neck models in which the targeted nerves are visible. These models will be made the same way as described above, using clear, transparent gelatin but will have colored threads accurately suspended in the gelatin so that learners can visualize the distribution of the nerves in 3 dimensions.
- 2) Step 2: After practice with head and neck models that have visible nerves, learners will progress to the task-trainer models which were described above in the first implementation of the training sessions. In these models, the learner will need to depend on the visible bony landmarks of the skull to identify the proper location for injections.
- 3) Step 3: Finally, advanced learners will be provided with task trainer models which are made with opaque (non-transparent) gelatin. On these models, neither the nerves nor the bony landmarks of the skull will be visible to the learner. This will provide hands-on practice under conditions that more realistically simulate patient skin.

## References/suggestions for further reading:

1. Sinatra R. Causes and consequences of inadequate management of acute pain. *Pain Med.* 2010;11(12):1859-1871. doi: 10.1111/j.1526-4637.2010.00983.x
2. Ali S, Drendel AL, Kircher J, Beno S. Pain management of musculoskeletal injuries in children: current state and future directions. *Pediatr Emerg Care.* 2010; 26(7):518-524. doi: 10.1097/PEC.0b013e3181e5c02b
3. Amsterdam JT, Kilgore KP. Regional anesthesia of the head and neck. In: *Roberts and Hedges' Clinical Procedures in Emergency Medicine.* 6<sup>th</sup> ed. Philadelphia, PA: Elsevier; 2014:541-553.e1.
4. Crystal CS, Blankenship RB. Local anesthetics and peripheral nerve blocks in the emergency department. *Emerg Med Clin North Am.* 2005;23(2):477-502. doi: 10.1016/j.emc.2004.12.012
5. Barsuk JH, McGaghie WC, Cohen ER, O'Leary KJ, Wayne DB. Simulation-based mastery learning reduces complications during central venous catheter insertion in a medical intensive care unit. *Crit Care Med.* 2009;37(10):2697-2701.
6. Conroy SM, Bond WF, Pheasant KS, Ceccacci N. Competence and retention in performance of the lumbar puncture procedure in a task trainer model. *Simul Healthc.* 2010;5(3):133-138. doi: 10.1097/SIH.0b013e3181d040a
7. Gmyrek R. Local and regional anesthesia. In: Elston DM, ed. Medscape. <http://emedicine.medscape.com/article/1831870-overview#a1>. Updated July 7, 2015. Accessed April 13, 2017.
8. Latham JL, Martin SN. Infiltrative anesthesia in office practice. *Am Fam Physician.* 2014;89(12):956-962.
9. pladmd. 4 infraorbital nerve block UBC CDE. <https://www.youtube.com/watch?v=H382MZF5xvM>. Published Jan 5, 2012. Accessed April 13, 2017.
10. Mental nerve block: Latina S. Mental nerve block. <https://www.youtube.com/watch?v=5ALXimfm0EM>. Published December 30, 2013. Accessed April 13, 2017.
11. Hutchens DJ. In: Rahgavendra M, ed. Ear anesthesia. Medscape. <http://emedicine.medscape.com/article/82698-overview#a9>. Accessed April 13, 2017.
12. Healy SM, Quinn FB. Local anesthesia techniques in oral and maxillofacial surgery. <http://www.utmb.edu/otoref/grnds/anesth-mouth-0410/anesth-mouth.pdf>. Published October 2004. Accessed April 13, 2017.

## Images from Regional Facial Anesthesia PowerPoint Presentation

1. Slide 4. Gray H. Figure 784. Sensory distribution of facial nerves. In: Lewis WH, ed. *Anatomy of the Human Body.* 20<sup>th</sup> ed. Philadelphia, PA: Lea and Febiger; 1918.
2. Slide 5. Figure 7-2. Sensory (cutaneous) nerves of the face. Pocket Dentistry Website. <http://pocketdentistry.com/7-the-head-by-regions/>. Accessed April 3, 2017.
3. Slide 6. Facial nerve distribution. Fprmed.com. [http://www.fprmed.com/Pages/Trauma/Lip\\_Laceration.html](http://www.fprmed.com/Pages/Trauma/Lip_Laceration.html). Accessed April 3, 2017.
4. Slide 7. Latham JL, Martin SN. Infiltrative anesthesia in office practice. *Am Fam Physician.* 2014;89(12):956-962.
5. Slide 8. Benko K. Fixing faces painlessly: Facial anesthesia in emergency medicine. *Emerg Med Practice.* 2009;11(12):1-21.
6. Slide 9. Byrne KM, Izzo AJ, Windle ML, et al. Technique and positioning tabs. Medscape 2014. <http://emedicine.medscape.com/article/82641-overview#a7>. Accessed April 4, 2017. [Note: Image used under a Creative Commons Attribution-Non-Commercial 3.0 Unported License].
7. Slide 10. Gray H. Figure 379. Anatomy relevant to the infraorbital nerve block. In: Lewis WH, ed. *Anatomy of the Human Body.* 20<sup>th</sup> ed. Philadelphia, PA: Lea and Febiger. 1918.
8. Slide 11. Lent GS, Schreiber D, and Fansler JL. Transcutaneous approach to the extraoral infraorbital nerve block. Schraga ED, ed. In: *Infraorbital nerve block, technique: technique for extraoral infraorbital nerve block.* Medscape. <http://emedicine.medscape.com/article/83256-overview#a4>. New York, NY: Medscape LLC. Published 2014. Accessed April 4, 2017. [Note: Image reprinted with permission from Gretchen S Lent, MD, Torrance



# USER GUIDE

- Memorial Medical Center, published by Medscape Drugs & Diseases].
9. Slide 12. Byrne KM. Intraoral approach (transmucosal approach) to infraorbital nerve block. In: Raghavendra M, ed. Infraorbital nerve block, technique: intraoral approach. Medscape. <http://emedicine.medscape.com/article/82660-overview#a7>. New York, NY: Medscape LLC. Published 2014. Accessed April 4, 2017. [Note: Image reprinted with permission from Karen M Byrne, MD, Albert Einstein College of Medicine, published by Medscape Drugs & Diseases].
  10. Slide 13. Lin B. Infraorbital nerve block - complex vermilion border laceration. Closing the gap: wound closure for the emergency practitioner. <https://lacerationrepair.com/anatomic-regions/lip-lacerations-part-ii/>. Accessed April 4, 2017. [Note: Image reprinted with permission from Brian Lin, MD, UC San Francisco School of Medicine, published on his training blog: Closing the Gap: Wound Closure for the Emergency Practitioner. 2017].
  11. Slide 14. University Pain Centre Maastricht, Health care providers. Procedure infiltration mental nerve. Anesthesiology/pain management. <http://www.pijn.com/en/health-care-providers/interventional-pain-treatment/face-head-neck/mental-nerve-infiltration/>. Published 2011. Accessed April 4, 2017. [Note: Image used under a Creative Commons Attribution-Non-Commercial 3.0 Unported License].
  12. Slide 15. Gorgas DL. Photo of positioning for the administration of a mental nerve block. The Ohio State University Wexner Medical Center. [Note: Image reprinted with permission from Diane L Gorgas, MD, The Ohio State University Wexner Medical Center. 2017].
  13. Slide 16. McDermott TJ. Mental nerve block: Figure 3. Leawood, KS. American Academy of Family Physicians. 2014. <http://www.aafp.org/afp/2014/0615/p956.html> Accessed April 4, 2017. [Note: Image is copyrighted but use is permitted under a Creative Commons Attribution-Non-Commercial 3.0 Unported License].
  14. Slide 17. Lent GS, Fansler JL, Schreiber D. Complex lip laceration. Image: Lip Laceration involving the lower vermilion border. In: Schraga ED, ed. Medscape. <http://emedicine.medscape.com/article/83256-overview>. New York, NY: Medscape LLC. Published 2016. Accessed April 4, 2017. [Note: Image reprinted with permission from Gretchen S Lent, MD, Torrance Memorial Medical Center, published by Medscape Drugs & Diseases].
  15. Slide 18. Innervation of the auricle diagram. [Note: Image used under a Creative Commons Attribution-Non-Commercial 3.0 Unported License.]
  16. Slide 19. Periauricular block. From Pocket Dentistry - Ch 11: Cosmetic otoplasty and related ear conditions. <http://pocketdentistry.com/11-cosmetic-otoplasty-and-related-ear-conditions/>. Accessed April 4, 2017.
  17. Slide 20. Periauricular block. Bien A, Wagner R, Wilkinson E. Local and regional anaesthesia techniques for otologic (ear) surgery. Figure 13. Fisch postauricular injection technique from: Lancer JM, Fisch U. Local anesthesia for middle ear surgery. *Clin Otolaryngol*. 1988; 13:367-374. [Note: Image used under a Creative Commons Attribution-Non-Commercial 3.0 Unported License.]
  18. Slide 21. Periauricular block. Bachmann D. Photo of ear laceration requiring a periauricular block. The Ohio State University Wexner Medical Center. [Note: Image reprinted with permission from Daniel Bachmann, MD, The Ohio State University Wexner Medical Center. 2017].



## Regional Facial Anesthesia Indications/Contraindications Examination

1. Identify the most significant contraindication for facial regional anesthesia.
  - A) Abscess on the lower neck
  - B) History of steroid use
  - C) Bleeding disorders
  - D) Suspected influenza
2. In which patient is it preferred to use a local anesthetic rather than a regional facial block?
  - A) A laceration which crosses a cosmetically sensitive area
  - B) An expansive laceration
  - C) Complex facial lacerations
  - D) Preverbal pediatric patient
3. Which of the following is an accurate statement in differentiating regional anesthetic from local anesthetic?
  - A) Regional anesthesia has a higher incidence of allergic reactions to the anesthetic agent
  - B) Regional anesthesia will have a slower onset for complete effectiveness
  - C) Regional anesthetics are preferred in uncooperative patients
  - D) Safe doses for lidocaine are higher for regional anesthesia than local
4. Allergic reactions to local anesthetics are extremely rare, but are increased due to additives such as:
  - A) Alcohol
  - B) Distilled water
  - C) Hyaluronidase
  - D) Sodium bicarbonate
5. A patient presents 3 hours post dog bite to the left upper lip. No tissue loss is noted. The laceration extends through the upper lip and involves the Vermillion border. What is the appropriate facial regional block to consider?
  - A) Bilateral mental nerve blocks
  - B) Left infraorbital nerve block
  - C) Left supraorbital and infraorbital nerve blocks
  - D) Trigeminal and supratrochlear nerve blocks



# LEARNER MATERIALS

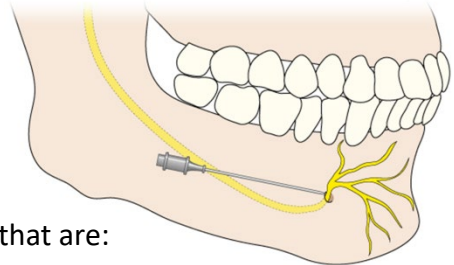
6. The patients who have potential for allergic reactions to local anesthesia include those who:
- A) are allergic to bee stings
  - B) are allergic to penicillin
  - C) have a diagnosis of Lupus (SLE)
  - D) suffer from chronic Lyme Disease
7. All of the following are contraindications to regional anesthesia **EXCEPT**:
- A) uncooperative patients
  - B) bleeding disorders
  - C) local anesthetic toxicity risk
  - D) complex lacerations
  - E) pre-existing peripheral neuropathy



# LEARNER MATERIALS

## Regional Facial Anesthesia Examination

1. The primary benefit of regional nerve blocks for facial procedures is that regional nerve blocks:
  - A) take effect faster
  - B) do not cause tissue distortion (swelling)
  - C) are more accepted by patients
  - D) are easier to administer
  - E) prevent the EM physician from having to call an anesthesiologist
2. A patient had an infraorbital nerve block completed 60 seconds ago and is still feeling sharp sensation in the upper lip. What is the next best step?
  - A) Administer procedural sedation
  - B) Augment with local anesthesia
  - C) Inject an additional 3cc of regional anesthetic
  - D) Wait for 5-10 minutes more
3. The maximum dose of 1% lidocaine without epinephrine is:
  - A) 1 mg/kg
  - B) 2 mg/kg
  - C) 4 mg/kg
  - D) 7 mg/kg
4. The image to the right demonstrates regional anesthesia of the:
  - A) Supraorbital nerve
  - B) Infraorbital nerve
  - C) Mental nerve
  - D) Buccal nerve
5. A field nerve block is preferred over a single nerve block in areas that are:
  - A) severely lacerated
  - B) void of bony landmarks
  - C) affected by the infraorbital nerve
  - D) innervated by multiple cranial nerve branches
6. A woman presents with a large, stellate laceration of the forehead which lies mostly on the right, but crosses the midline and involves both brows. What is the appropriate nerve block(s) if regional anesthesia is to be employed?
  - A) Bilateral Auriculotemporal nerve
  - B) Bilateral Supraorbital nerve
  - C) Greater auricular nerve
  - D) Scalp field block





## LEARNER MATERIALS

7. Match the nerve on the left with its associated field or area on the right. Use the options on the right once, more than once, or not at all.

- |                        |                    |
|------------------------|--------------------|
| ___ Mental nerve       | A) Mandibular area |
| ___ Supraorbital nerve | B) Maxillary area  |
| ___ Infraorbital nerve | C) Ophthalmic area |
| ___ Trigeminal nerve   |                    |

8. While completing a periauricular block, there is swelling noted at the anterior aspect of the ear and the patient complains of increasing anterior ear fullness. Appropriate management for this complication is which of the following?

- A) apply direct pressure
- B) Aspirate over the swelling
- C) Incise over the apex of the swelling
- D) Reassurance

9. A field block (rather than a regional nerve block) is the preferred method for which location?

- A) Infraorbital
- B) Mental
- C) Periauricular
- D) Supraorbital



# INSTRUCTOR MATERIALS

Answer keys to all exercises with explanations, are on the following pages.

Learners: please do not proceed.



# INSTRUCTOR MATERIALS

## Regional Facial Anesthesia Indications/Contraindications Examination Key (Annotated with correct answers and notes)

Instructions: This examination is designed to supplement The Regional Facial Anesthesia Training Session. These items can be used as either a pre- or post-test. The examination items can also be adapted to be delivered through an electronic testing software platform.

1. Identify the most significant contraindication for facial regional anesthesia.
  - A) Abscess on the lower neck
  - B) History of steroid use
  - C)\* Bleeding disorders
  - D) Suspected influenza

Note: This item links to Milestone 11; Level 2: Knows the indications, contraindications, potential complications and appropriate doses of analgesic/sedative medications.

2. In which patient is it preferred to use a local anesthetic rather than a regional facial block?
  - A) A laceration which crosses a cosmetically sensitive area
  - B) An expansive laceration
  - C) Complex facial lacerations
  - D)\* Preverbal pediatric patient

Note: This item links to Milestone 9-Level 4: Performs indicated procedures on any patients with challenging features (e.g., poorly identifiable landmarks, at extremes of age or with co-morbid conditions).

3. Which of the following is an accurate statement in differentiating regional anesthetic from local anesthetic?
  - A) Regional anesthesia has a higher incidence of allergic reactions to the anesthetic agent
  - B)\* Regional anesthesia will have a slower onset for complete effectiveness
  - C) Regional anesthetics are preferred in uncooperative patients
  - D) Safe doses for lidocaine are higher for regional anesthesia than local

Note: This item links to Milestone 11, Level 3: Performs patient assessment and discusses with the patient the most appropriate analgesic/sedative medication and administers the most appropriate dose and route.

4. Allergic reactions to local anesthetics are extremely rare, but are increased due to additives such as:
  - A) Alcohol
  - B) Distilled water
  - C)\* Hyaluronidase
  - D) Sodium bicarbonate



# INSTRUCTOR MATERIALS

Note: Links to Milestone 5 level 3: Considers array of drug therapy for treatment. Selects appropriate agent based on mechanism of action, intended effect, and anticipates potential adverse side effects.

5. A patient presents 3 hours post dog bite to the left upper lip. No tissue loss is noted. The laceration extends through the upper lip and involves the Vermillion border. What is the appropriate facial regional block to consider?

- A) Bilateral mental nerve blocks
- B)\* Left infraorbital nerve block
- C) Left supraorbital and infraorbital nerve blocks
- D) Trigeminal and supratrochlear nerve blocks

Note: Links to Milestone 9 level 4: Performs indicated procedures on any patients with challenging features (e.g., poorly identifiable landmarks, at extremes of age or with co-morbid conditions).

6. The patients who have potential for allergic reactions to local anesthesia include those who:

- A)\* are allergic to bee stings
- B) are allergic to penicillin
- C) have a diagnosis of Lupus (SLE)
- D) suffer from chronic Lyme Disease

Note: Hyaluronidase (a potential additive in local anesthetics) should not be administered to patients with a known bee venom allergy.

7. All of the following are contraindications to regional anesthesia **EXCEPT**:

- A) uncooperative patients
- B) bleeding disorders
- C) local anesthetic toxicity risk
- D)\* complex lacerations
- E) pre-existing peripheral neuropathy

Note: Links to Milestone 9 level 4: Performs the indicated procedure, takes steps to avoid potential complications, and recognizes the outcome and/or complications resulting from the procedure.



# INSTRUCTOR MATERIALS

## Regional Facial Anesthesia Examination Key (Annotated with correct answer and notes)

Instructions: This examination is designed to supplement The Regional Facial Anesthesia Training Session. These items can be used as either a pre- or post-test. The examination items can also be adapted to be delivered through an electronic testing software platform.

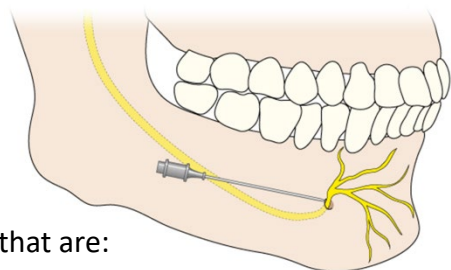
1. The primary benefit of regional nerve blocks for facial procedures is that regional nerve blocks:
  - A) take effect faster
  - B)\* do not cause tissue distortion (swelling)
  - C) are more accepted by patients
  - D) are easier to administer
  - E) prevent the EM physician from having to call an anesthesiologist
2. A patient had an infraorbital nerve block completed 60 seconds ago and is still feeling sharp sensation in the upper lip. What is the next best step?
  - A) Administer procedural sedation
  - B) Augment with local anesthesia
  - C) Inject an additional 3cc of regional anesthetic
  - D)\* Wait for 5-10 minutes more

Note: The 2-5 minute duration of onset for many local anesthetics may even be doubled or tripled. Links to Milestone 9, level 3: Determines a backup strategy if initial attempts to perform a procedure are unsuccessful.

3. The maximum dose of 1% lidocaine without epinephrine is:
  - A) 1 mg/kg
  - B) 2 mg/kg
  - C) 4 mg/kg
  - D)\* 7 mg/kg

Note: The maximum dose is 7mg/kg (up to 500mg).

4. The image to the right demonstrates regional anesthesia of the:
  - A) Supraorbital nerve
  - B) Infraorbital nerve
  - C)\* Mental nerve
  - D) Buccal nerve



5. A field nerve block is preferred over a single nerve block in areas that are:
  - A) severely lacerated



## INSTRUCTOR MATERIALS

- B) void of bony landmarks
- C) affected by the infraorbital nerve
- D)\* innervated by multiple cranial nerve branches

6. A woman presents with a large, stellate laceration of the forehead which lies mostly on the right, but crosses the midline and involves both brows. What is the appropriate nerve block(s) if regional anesthesia is to be employed?
- A) Bilateral Auriculotemporal nerve
  - B)\* Bilateral Supraorbital nerve
  - C) Greater auricular nerve
  - D) Scalp field block

Note: Links to Milestone 9 level 4: Performs indicated procedures on any patients with challenging features (e.g., poorly identifiable landmarks, at extremes of age or with co-morbid conditions).

7. Match the nerve on the left with its associated field or area on the right. Use the options on the right once, more than once, or not at all.

<u>  A  </u> Mental nerve	A) Mandibular area
<u>  C  </u> Supraorbital nerve	B) Maxillary area
<u>  B  </u> Infraorbital nerve	C) Ophthalmic area
<u>  A  </u> Trigeminal nerve	

8. While completing a periauricular block, there is swelling noted at the anterior aspect of the ear and the patient complains of increasing anterior ear fullness. Appropriate management for this complication is which of the following?
- A)\*apply direct pressure
  - B) Aspirate over the swelling
  - C) Incise over the apex of the swelling
  - D) Reassurance

Note: From Milestone 9, Level 4: Performs the indicated procedure, takes steps to avoid potential complications, and recognizes the outcome and/or complications resulting from the procedure.

9. A field block (rather than a regional nerve block) is the preferred method for which location?
- A) Infraorbital
  - B) Mental
  - C)\*Periauricular
  - D) Supraorbital

Note: Links to Milestone 11, Level 2: Knows the anatomic landmarks, indications, contraindications, potential complications and appropriate doses of local anesthetics used for regional anesthesia.