

Ruptured Abdominal Aortic Aneurysm

Jessica Andrusaitis, BS, MS* and Jonathan Peña, MD*

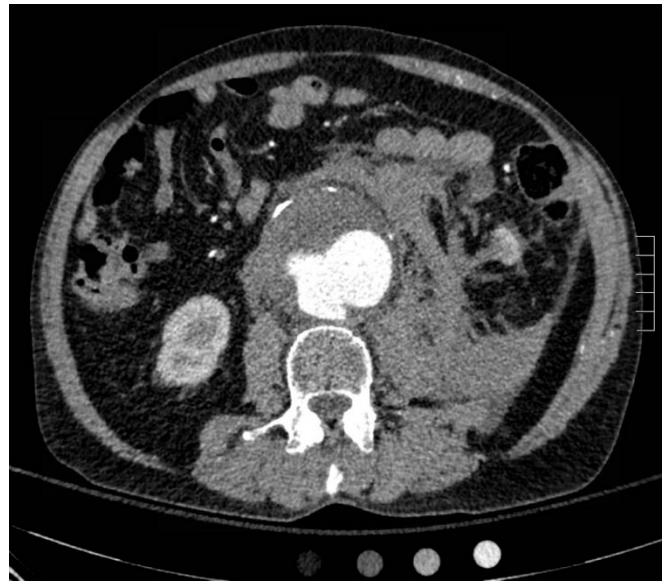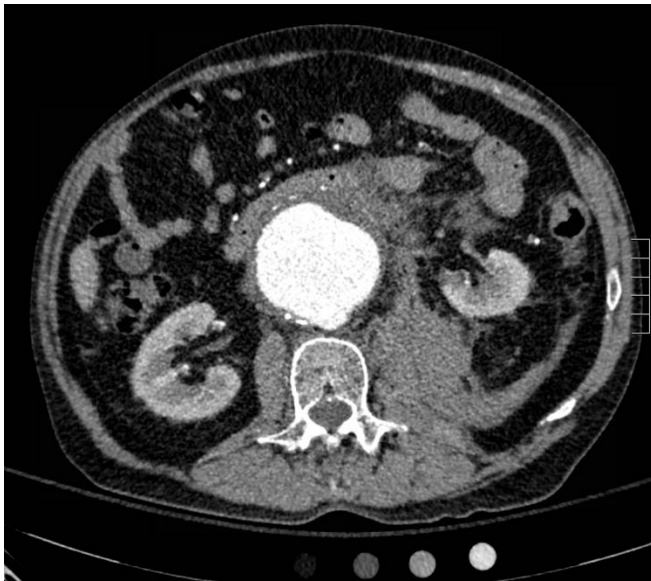
*University of California, Irvine, Department of Emergency Medicine, Orange, CA

Correspondence should be addressed to Jessica Andrusaitis, BS, MS at jandrusa@uci.edu

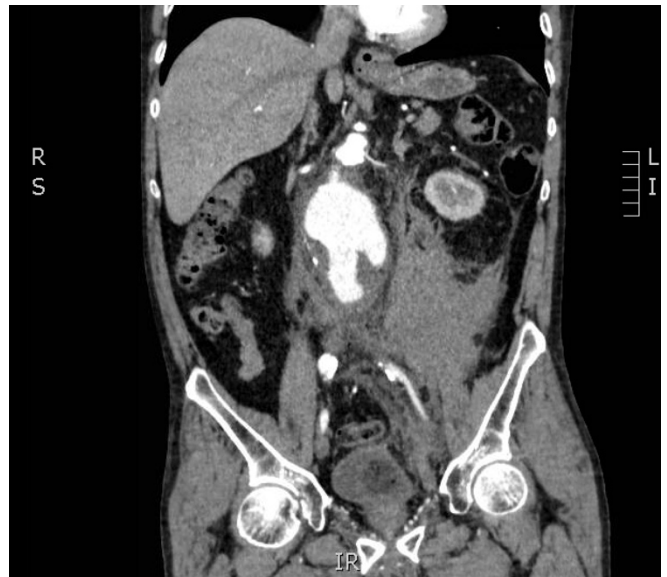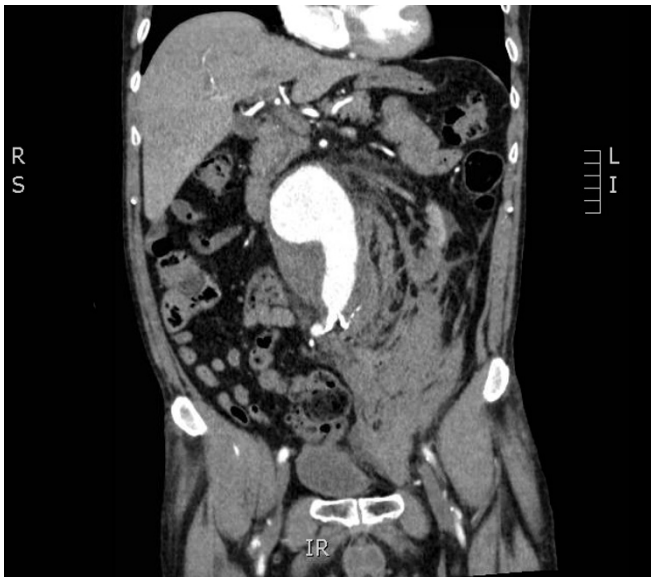Submitted: May 4, 2017; Accepted: June 28, 2017; Electronically Published: July 14, 2017; <https://doi.org/10.21980/J8FP6S>

Copyright: © 2017 Andrusaitis et al. This is an open access article distributed in accordance with the terms of the Creative Commons Attribution (CC BY 4.0) License.

See: <http://creativecommons.org/licenses/by/4.0/>



Video Link: <https://youtu.be/e2AjFETNH4U>



Video Link: https://youtu.be/E0rYPJIXr_g

History of present illness: A 69-year-old male with poorly controlled hypertension presented with 1 hour of severe low back pain that radiated to his abdomen. The patient was tachycardic and had an initial blood pressure of 70/40. He had a rigid and severely tender abdomen. The patient's history of hypertension, abnormal vital signs, severity and location of his pain were suspicious for a ruptured abdominal aortic aneurysm (AAA). Therefore, a computed tomography angiogram (CTA) was ordered.

Significant findings: The CTA demonstrated a ruptured 7.4 cm infrarenal abdominal aortic aneurysm with a large left retroperitoneal hematoma.

Discussion: True abdominal aortic aneurysm is defined as at least a 3cm dilatation of all three layers of the arterial wall of the abdominal aorta.¹ An estimated 15,000 people die per year in the US of this condition.² Risk factors for AAA include males older than 65, tobacco use, and hypertension.^{1,3,4} There are also congenital, mechanical, traumatic, inflammatory, and infectious causes of AAA.³ Rupture is often the first manifestation of the disease. The classic triad of abdominal pain, pulsatile mass, and hypotension is seen in only 50% of ruptured AAAs.⁵ Pain (abdominal, groin, or back) is the most common symptom. The most common misdiagnoses of ruptured AAAs are renal colic, diverticulitis, and gastrointestinal hemorrhage.⁶

Bedside ultrasonography is the fastest way to detect this condition and is nearly 100% sensitive.¹ One study showed that bedside ultrasounds performed by emergency physicians had a sensitivity of .94 [95% CI = .86-1.0] and specificity of 1 [95% CI = .98-1.0] for detecting AAAs.⁷ Computed tomography angiography has excellent sensitivity (approximately 100%) and yields the added benefit of facilitating surgical planning and management.¹

Without surgical treatment, a ruptured AAA is almost uniformly fatal, and 50% of those who undergo surgery do not survive.¹ Early resuscitation and coordination with vascular surgery should be pursued without delay. The concept of permissive hypotension (target systolic blood pressure 90 mmHg) in patients with a ruptured AAA is controversial. Until there are randomized controlled trials supporting patient-centered benefits, such as improved mortality, clinicians should refrain from permissive hypotension.⁸

Topics: Abdominal aortic aneurysm, AAA, CT, ultrasound, low back pain, vascular surgery, critical care.

References:

1. Bessen HA. Abdominal Aortic Aneurysm. In: Marx JA, Hockberger RS, Walls RM, Adams J, Rosen P, eds. *Rosen's Emergency Medicine: Concepts and Clinical Practice*. 7th ed. Philadelphia, PA: Elsevier/Saunders; 2010:1093-1102.
2. National Center for Health Statistics. *Vital statistics of the United States 1985. Vol. II, mortality, part A*. Washington, DC: US Dept of Health and Human Services; 1988. DHHS publication (PHS) 88-1101.
3. Johnston KW, Rutherford RB, Tilson MD, Shah DM, Hollier L, Stanley JC. Suggested standards for reporting on arterial aneurysms. *J Vasc Surg*. 1991;13(3):452-458. doi: 10.1067/mva.1991.26737
4. Blanchard JF, Armenian HK, Friesen PP. Risk factors for abdominal aortic aneurysm: results of a case-control study. *Am J Epidemiol*. 2000;151(6):575-583.
5. Dark SG, Eadie DD. Abdominal aortic aneurysmectomy: a review of 60 consecutive cases contrasting elective and emergency surgery. *J Cardiovasc Surg*. 1973;14:484-491.

6. Marston WA, Ahlquist R, Johnson G, et al. Misdiagnosis of ruptured abdominal aortic aneurysms. *J Vasc Surg.* 1992;16:17-22. doi: 10.1016/S0196-0644(05)80086-1
7. Costantino TG, Bruno EC, Handly N, Dean AJ. Accuracy of emergency medicine ultrasound in the evaluation of abdominal aortic aneurysm. *J Emerg Med.* 2005;29(4):455-460. doi: 10.1016/j.jemermed.2005.02.016
8. Moreno DH, Cacione DG, Baptista-Silva JC. Controlled hypotension versus normotensive resuscitation strategy for people with ruptured abdominal aortic aneurysm. *Cochrane Database Syst Rev.* 2016;(5):CD011664. doi: 10.1002/14651858.CD011664.pub2