

# CURRICULUM

## Novel Emergency Medicine Curriculum Utilizing Self-Directed Learning and the Flipped Classroom Method: Head, Eyes, Ears, Nose and Throat Emergencies Small Group Module

Andrew King, MD\*, Paul Crawford\*, Christopher San Miguel, MD\*, Michael Barrie, MD\*, Sandra Spencer, MD^, Alyssa Tyransky\* and Nicholas Kman, MD\*

\*The Ohio State University Wexner Medical Center, Department of Emergency Medicine, Columbus, OH

^Nationwide Children's Hospital, Department of Emergency Medicine, Columbus, OH

Correspondence should be addressed to Andrew King, MD, FACEP at [andrewking3@osumc.edu](mailto:andrewking3@osumc.edu), Twitter: @akingermd

Submitted: August 15, 2017; Accepted: September 13, 2017; Electronically Published: October 15, 2017; <https://doi.org/10.21980/J8PW5N>

Copyright: © 2017 King et al. This is an open access article distributed in accordance with the terms of the Creative Commons Attribution (CC BY 4.0) License. See: <http://creativecommons.org/licenses/by/4.0/>

### ABSTRACT:

**Audience:** This curriculum created and implemented at The Ohio State University Wexner Medical Center was designed to educate our emergency medicine (EM) residents, post-graduate year (PGY)-1 to PGY-3, as well as medical students and attending physicians.

**Introduction:** Head, eyes, ears, nose and throat (HEENT) complaints are very commonly seen in the emergency department (ED). Numbers vary as to exact prevalence, but sources show that there are about 2 million annual ED visits in the United States for non-traumatic dental problems, representing 1.5% of all ED visits.<sup>1</sup> Other sources show that symptoms referable to the throat encompass 2,496,000 visits or 1.9% of total visits.<sup>2</sup> Notably, about 8% of the written exam in emergency medicine covers the topic of head and neck complaints, making it the second most tested topic behind cardiovascular.<sup>3</sup> Residents must be proficient in the differential diagnosis and management of the wide variety of HEENT emergencies. The flipped classroom curricular model emphasizes self-directed learning activities completed by learners, followed by small group discussions pertaining to the topic reviewed. The active learning fostered by this curriculum increases faculty and learner engagement and interaction time typically absent in traditional lecture-based formats.<sup>4-6</sup> Studies have revealed that the application of knowledge through case studies, personal interaction with content experts, and integrated questions are effective learning strategies for emergency medicine residents.<sup>6-8</sup>

The Ohio State University EM Residency didactic curriculum recently transitioned to a “flipped classroom” approach.<sup>9-13</sup> We created this innovative curriculum aimed to improve our residency education program and to share educational resources with other EM residency programs. Our curriculum utilizes an 18-month curricular cycle to cover the defined emergency medicine content. The flipped classroom curriculum

# CURRICULUM

maximizes didactic time and resident engagement, fosters intellectual curiosity and active learning, and meets the needs of today's learners.<sup>6,9,14</sup>

**Objectives:** We aim to teach the presentation and management of HEENT emergencies through the creation of a flipped classroom design. This unique, innovative curriculum utilizes resources chosen by education faculty and resident learners, study questions, real-life experiences, and small group discussions in place of traditional lectures. In doing so, a goal of the curriculum is to encourage self-directed learning, improve understanding and knowledge retention, and improve the educational experience of our residents.

**Methods:** The educational strategies used in this curriculum include: small group modules authored by education faculty and content experts based on the core emergency medicine content. This program also includes resident-submitted questions that were developed during review of the content. The Socratic Method, used during small group sessions, encourages active participation; small groups also focus on the synthesis and application of knowledge through the discussion of real life experiences. The use of free open access medical education (FOAM) resources allows learners to work at their own pace and maximize autonomy.

**Topics:** Emergency medicine, flipped classroom, medical education, HEENT emergencies, pedagogy, teaching.



# USER GUIDE

## List of Resources:

Abstract	1
User Guide	3
Didactics and Hands-On Curriculum Chart	8
Appendix A: Ear Emergencies	13
Appendix B: Painless Eye Emergencies	18
Appendix C: Painful Eye Emergencies	22
Appendix D: Head and Neck Infections	27
Appendix E: Pediatric Airway Foreign Bodies and Upper Airway Emergencies	33
Appendix F: Nasal Complaints	38
Appendix G: Dental Emergencies	42

## Learner Audience:

Medical students, interns, junior residents, senior residents, faculty

## Length of Curriculum:

The entire didactic curriculum was developed to utilize an 18-month curricular cycle; therefore, resident learners experience each curricular topic twice in the course of their residency training. The HEENT emergencies module consists of seven 45-60-minute small group sessions.

## Topics:

Emergency medicine, flipped classroom, medical education, HEENT emergencies, pedagogy, teaching.

## Objectives:

Each chapter within our curriculum has individual objectives; however, educational objectives for the curriculum and more specifically, the HEENT Emergencies Module include:

1. Resident learners will learn the core content of emergency medicine in an 18-month curriculum utilizing self-directed learning and small group discussions based on the flipped classroom model.
2. After completing the HEENT Emergencies Module, resident learners will exhibit mastery within this content area and will critically discuss the pathophysiology, diagnosis, and treatment of various pediatric and adult HEENT emergencies including:
  - a. Ear Emergencies
  - b. Ophthalmologic Complaints focusing on the Painless Eye Complaint
  - c. Ophthalmologic Complaints focusing on the Painful Eye Complaint

- d. Head and Neck Infections
- e. Pediatric Airway Foreign Bodies and Upper Airway Emergencies
- f. Nasal Complaints
- g. Dental Emergencies

## Brief introduction:

The flipped classroom learning approach is becoming more commonly recognized as a preferred curricular model for mature learners, specifically those in medical education. This particular model is a natural fit for the hands-on, experiential emergency medicine learner.<sup>7</sup> The active learning fostered by this curriculum increases faculty and learner engagement and interaction time, which is typically absent in traditional lecture-based formats.<sup>8,14</sup> Education literature shows that resident learners prefer learning activities that involve small group discussion, are case/skill-based, and emphasize the application of newly obtained knowledge.<sup>3,4</sup> This educational model also provides a clear channel for the incorporation of evidence-based medicine and increases opportunities for educator-learner conversations. A successful flipped classroom curriculum fosters learner accountability and provides robust opportunities for formal assessment in various emergency medicine milestones.<sup>7,11,14</sup> For these reasons, we developed a flipped classroom curriculum at The Ohio State University. This HEENT emergencies curriculum is one of several topics in our overall didactic curriculum.

## Problem identification, general and targeted needs assessment:

Traditional lecture-based didactics may not be the most effective or preferred method for emergency medicine resident education.<sup>9</sup> Previously, we used a traditional lecture format in our residency curriculum despite overwhelming evidence for a more hands-on, “flipped classroom” approach.<sup>11,12</sup> From the perspective of resident learners, the chance to remain fully engaged through the asking of questions developed from personal experiences, and also by learning from the experiences of others provides a manner of learning that makes a topic more difficult to forget.<sup>8</sup>

As current literature reveals, both educators and learners benefit from an interactive and collaborative classroom, leading to the creation and implementation of this proposed curricular model at our emergency medicine residency program.<sup>13</sup> This weekly small group curriculum has now replaced three hours of traditional lecture-based didactics. Since implementation, residents and educators are engaging in new, valuable flipped classroom learning communities at The Ohio State University. Through the curriculum, we continually seek to foster self-directed learning and increased collaboration between resident



# USER GUIDE

learners and education faculty members. This ensures that resident time will be maximized and learning will be more efficient and effective, thereby providing a potential positive impact on patient care and physician wellness. Currently, minimal flipped classroom curricular materials dedicated to the core content of emergency medicine exist.

## Goals of the curriculum:

This curricular innovation was developed and implemented to promote self-directed/active learning and an environment of intellectual curiosity and learner accountability. This flipped classroom curriculum is specifically designed to cover the core content of emergency medicine, and this module promotes the mastery of HEENT emergencies. Secondary goals include the increased interaction between educators and learners, and the evaluation of resident small group teaching skills.

## Objectives of the curriculum:

Each chapter within our curriculum has individual objectives; however, educational objectives for the curriculum and more specifically, the HEENT Emergencies Module include:

1. Resident learners will learn the core content of emergency medicine in an 18-month curriculum utilizing self-directed learning and small group discussions based on the flipped classroom model.
2. After completing the HEENT Emergencies Module, resident learners will exhibit mastery within this content area and will critically discuss the pathophysiology, diagnosis, and treatment of various pediatric and adult HEENT emergencies including:
  - a. Ear Emergencies
  - b. Ophthalmologic Complaints focusing on the Painless Eye Complaint
  - c. Ophthalmologic Complaints focusing on the Painful Eye Complaint
  - d. Head and Neck Infections
  - e. Pediatric Airway Foreign Bodies and Upper Airway Emergencies
  - f. Nasal Complaints
  - g. Dental Emergencies

## Educational Strategies: (See curriculum chart)

Please refer to the curriculum chart of linked objectives and educational strategies.

## Evaluation and Feedback:

This innovative curriculum was literature based and specifically designed to maximize active learning using the flipped classroom learning model. We overcame initial challenges and skepticism from both educators and learners to execute a successful, novel curricular model. Both resident learners and faculty educators provided an overwhelming amount of positive

feedback. Additionally, a survey was administered to each resident prior to initiation of the curricular innovation, and repeated at the conclusion of the first 18-month cycle. Learners and educators were enthusiastic about the conference structure and expressed a preference for it rather than the previous, lecture-based didactics. Resident learner attendance at weekly emergency medicine didactics increased, presumably as a result of our curricular innovation and the associated increase in faculty engagement, active discussions, and learner-perceived value of the sessions. The curriculum is critically evaluated and updated by education faculty members in order to ensure educational material remains current and consistent with the emergency medicine core content.

## References/suggestions for further reading:

1. Sun BC, Chi DL, Schwarz E, Milgrom P, Yagapen A, Malveau Set al. Emergency department Visits for nontraumatic dental problems: a mixed-methods study. *Am J Public Health*. 2015;105(5):947-955. doi: 10.2105/AJPH.2014.302398
2. Rui P, Kang K, Albert M. National hospital ambulatory medical care survey: 2013 emergency department summary tables. [http://www.cdc.gov/nchs/data/ahcd/nhamcs\\_emergency/2013\\_ed\\_web\\_tables.pdf](http://www.cdc.gov/nchs/data/ahcd/nhamcs_emergency/2013_ed_web_tables.pdf). Accessed October 13, 2017.
3. Dietrich A, Green T, Martinez J. *Dr. Carol Rivers' Preparing for the Written Board Exam in Emergency Medicine*. 8<sup>th</sup> ed. Columbus, OH: Ohio ACEP; 2017.
4. Galway LP, Corbett KK, Takaro TK, Tairyan K, Frank E. A novel integration of online and flipped classroom instructional models in public health higher education. *BMC Med Educ*. 2014;29(14):181. doi: 10.1186/1472-6920-14-181
5. Mortensen CJ, Nicholson AM. The flipped classroom stimulated greater learning and is a modern 21st century approach to teaching today's undergraduates. *J Anim Sci*. 2015;93(7):3722-31. doi: 10.2527/jas.2015-9087
6. Tan E, Brainard A, Larkin G. Acceptability of the flipped classroom approach for in-house teaching in emergency medicine. *Emerg Med Australas*. 2015;27(5):453-459. doi: 10.1111/1742-6723.12454
7. Rose E, Claudius I, Tabatabai R, Kearl L, Behar S, Jhun P. The flipped classroom in emergency medicine using online videos with interpolated questions. *J Emerg Med*. 2016;51(3):284-291. doi: 10.1016/j.jemermed.2016.05.033
8. Young TP, Bailey CJ, Guptill M, Thorp AW, Thomas TL. The flipped classroom: a modality for mixed asynchronous and synchronous learning in a residency program. *West J Emerg Med*. 2015;15(7):938-944. doi: 10.5811/westjem.2014.10.23515
9. Heitz C, Prusakowski M, Willis G, Franck C. Does the concept of the "flipped classroom" extend to the



# USER GUIDE

emergency medicine clinical clerkship? *West J Emerg Med.* 2015;16(6):851-855. doi: 10.5811/westjem.2015.9.27256

- Liebert CA, Lin DT, Mazer LM, Bereknyei S, Lau JN. Effectiveness of the surgery core clerkship flipped classroom: a prospective cohort trial. *Am J Surg.* 2016;211(2):451-457. doi: 10.1016/j.amjsurg.2015.10.004
- Sockalingam S, James SL, Sinyi R, Carroll A, Laidlaw J, Yanofsky R, et al. A flipped classroom approach to improving the quality of delirium care using an interprofessional train-the-trainer program. *J Contin Educ Health Prof.* 2016;36(1):17-23. doi: 10.1097/CEH.0000000000000025
- Tainter CR, Wong NL, Cudemus-Deseda GA, Bittner EA. The “flipped classroom” model for teaching in the intensive care unit: rationale, practical considerations, and an example of successful implementation. *J Intensive Care Med.* 2017;32(3):187-196. doi: 10.1177/0885066616632156
- Moffett J. Twelve tips for “flipping” the classroom. *Med Teach.* 2014;37(4):331-336. doi: 10.3109/0142159X.2014.943710
- Liebert CA, Mazer L, Bereknyei MS, Lin DT, Lau JN. Student perceptions of a simulation-based flipped classroom for the surgery clerkship: A mixed-methods study. *Surgery.* 2016;160(3):591-8. doi: 10.1016/j.surg.2016.03.034

## Additional Resources:

Educational resources are available within each individual chapter of this HEENT emergencies curricular module; however, a complete list of resources and educational materials are listed below.

### Ear Suggested Readings

- Herbert M. Malignant otitis externa – a review. EM:RAP. <https://www.emrap.org/episode/september2010/malignantotitis>. Published September 2010. Accessed August 10, 2017
- Hoberman A, Paradise JL, Rockette HE, Shaikh N, Wald ER, Kearney DH, et al. Treatment of acute otitis media in children under 2 years of age. *N Engl J Med.* 2011;364(2):105-115. doi: 10.1056/NEJMoa0912254
- Li M. Trick of the trade: insect removal from the ear. Academic Life in Emergency Medicine. <https://www.aliem.com/2014/trick-of-trade-insect-removal-from-the-ear/>. Published October 2, 2014. Accessed August 10, 2017.
- Weingart S, Newman D. Otitis media – needs no therapy! – An investigate report. EM:RAP. <https://www.emrap.org/episode/may2011/otitismedia> Published May 2011. Accessed August 10, 2017.

### Ear Additional References:

- Chow Y. Trick of the trade: ear foreign body removal with modified suction setup. Academic Life in Emergency Medicine. <https://www.aliem.com/2015/trick-of-the-trade-ear-foreign-body-removal-with-modified-suction-setup/>. Published August 25, 2015. Accessed August 10, 2017.
- Chow Y. Trick of the trade: pediatric video laryngoscope for ear foreign bodies. Academic Life in Emergency Medicine. <https://www.aliem.com/2014/trick-trade-pediatric-video-laryngoscope-ear-foreign-bodies/>. Published November 24, 2014. Accessed August 10, 2017.
- Rauch SD. Idiopathic sudden sensorineural hearing loss. *N Engl J Med.* 2008;359(8):833-840. doi: 10.1056/NEJMcp0802129
- Hosmer K. Common disorders of the external, middle, and inner ear. In: Tintinalli JE, Stapczynski J, Ma O, Cline DM, Cydulka RK, Meckler GD, eds. *Tintinalli's Emergency Medicine: A Comprehensive Study Guide.* 8<sup>th</sup> ed. New York, NY: McGraw-Hill; 2011:1579-1585.
- Spiro DM, Tay KY, Arnold DH, Dziura JD, Baker MD, Shapiro ED. Wait-and-see prescription for the treatment of acute otitis media: a randomized controlled trial. *JAMA.* 2006;296(10):1235-1241. doi: 10.1001/jama.296.10.1235

### Painless Eye Suggested Readings

- Helman A. Episode 9: nontraumatic eye emergencies. Emergency Medicine Cases. <http://emergencymedicinecases.com/episode-9-nontraumatic-eye-emergencies/>. Published November 22, 2010. Accessed August 10, 2017.
- Mahmood AR, Narang AT. Diagnosis and management of the acute red eye. *Emerg Med Clin North Am.* 2008;26(1):35-55,vi. doi: 10.1016/j.emc.2007.10.002

### Painless Eye Additional References

- Bhatia K, Sharma R. Eye emergencies. In: Adams JG, Barton ED, Collings JL, DeBlieux PM, Gisondi MA, Nadel ES, eds. *Emergency Medicine: Clinical Essentials.* 2<sup>nd</sup> ed. Philadelphia, PA: Elsevier; 2013:209-225.
- Hunder GG, Bloch DA, Michel BA, Stevens MB, Arend WP, Calabrese LH, et al. The American College of Rheumatology 1990 criteria for the classification of giant cell arteritis. *Arthritis Rheum.* 1990;33(8):1122-1128.
- Lin M. Tricks of the trade: diagnosing retinal detachment with ultrasound. Academic Life in Emergency Medicine.



# USER GUIDE

<https://www.aliem.com/2009/12/tricks-of-trade-diagnosing-retinal/>. Accessed October 12, 2017.

- Sharma R, Brunette DD. Ophthalmology. In: Walls RM, Hockberger RS, Gausche-Hill M, Bakes KM, et al. eds. *Rosen's Emergency Medicine: Concepts and Clinical Practice*. 8<sup>th</sup> ed. Philadelphia, PA: Elsevier; 2014:909-931.

## Painful Eye Suggested Readings

- Eye emergencies, "answers." EM Lyceum. <https://emlyceum.com/2014/07/01/eye-emergencies-answers/>. Published July 1, 2014. Accessed August 10, 2017.
- Helman A. Episode 9: nontraumatic eye emergencies. *Emergency Medicine Cases*. <http://emergencymedicinescases.com/episode-9-nontraumatic-eye-emergencies/>. Published November 22, 2010. Accessed August 10, 2017.
- Jhun P, Swaminathan A. Annals of Emergency Medicine – A really bad poke in the eye. EM:RAP. <https://www.emrap.org/episode/june2015/annalsof>. Published June 2015. Accessed August 10, 2017.
- Mahmood AR, Narang AT. Diagnosis and management of the acute red eye. *Emerg Med Clin North Am*. 2008;26(1):35-55,vi. doi: 10.1016/j.emc.2007.10.002
- Nickson C. Half an 8 ball. *Life in the Fast Lane*. <https://lifeinthefastlane.com/ophthalmology-befuddler-030/>. Published August 30, 2010. Accessed August 10, 2017.
- Nickson C. The red eye challenge. *Life in the Fast Lane*. <https://lifeinthefastlane.com/the-red-eye-challenge/>. Published August 2, 2010. Accessed August 10, 2017.

## Painful Eye Additional References

- Bhatia K, Sharma R. Eye emergencies. In: Adams JG, Barton ED, Collings JL, DeBlieux PM, Gisoni MA, Nadel ES, eds. *Emergency Medicine: Clinical Essentials*. 2<sup>nd</sup> ed. Philadelphia, PA: Elsevier; 2013:209-225.
- Guluma K, Lee J. Ophthalmology. In: Walls RM, Hockberger RS, Gausche-Hill M, Bakes KM. *Rosen's Emergency Medicine: Concepts and Clinical Practice*. 9<sup>th</sup> ed. Philadelphia, PA: Elsevier; 2018:790-819.
- Osborne B, Balcer LJ. Optic neuritis: pathophysiology, clinical features, and diagnosis. In: Wilterdink JL, ed. *UpToDate*. Waltham, MA: UpToDate Inc. <https://www.uptodate.com/contents/optic-neuritis-pathophysiology-clinical-features-and-diagnosis>. Updated March 24, 2015. Accessed July 27, 2017.
- Rosenbaum JT. Uveitis: etiology, clinical manifestations, and diagnosis. In: Romain PL, ed. *UpToDate*. Waltham, MA: UpToDate Inc. <https://www.uptodate.com/contents/uveitis-etiology->

*clinical-manifestations-and-diagnosis*. Updated February 24, 2017. Accessed July 27, 2017.

## Upper Airway Suggested Readings

- Caretta-Weyer H, Hess J. Pediatric approach to croup. CDEM Curriculum. <http://cdemcurriculum.com/pediatric-approach-to-croup/>. Accessed August 10, 2017.
- Claudius I. Pediatric pearls: pediatric airway. EM:RAP. <https://www.emrap.org/episode/december2012/pediatricpearls>. Published December 2012. Accessed August 10, 2017.
- Cox JM. Pediatric Upper respiratory infection. CDEM Curriculum. <https://cdemcurriculum.com/pediatric-upper-respiratory-infection/>. Accessed August 10, 2017.
- Hsiao J, Pacheco-Fowler V. Videos in clinical medicine. Cricothyroidotomy. *N Engl J Med*. 2008;358(22):e25. doi: 10.1056/NEJMVcm0706755

## Upper Airway Additional References

- Adil E, Adil A, Shah R. Epiglottitis. *Clin Pediatr Emerg Med*. 2015;16(3):149-153. doi: 10.1016/j.cpem.2015.07.005
- Bernius M, Perlin D. Pediatric ear, nose, and throat emergencies. *Pediatr Clin North Am*. 2006;53(2):195-214. doi: 10.1016/j.pcl.2005.10.002
- Cetinkaya EA, Arslan İB, Cukurova İ. Nasal foreign bodies in children: types, locations, complications and removal. *Int J Pediatr Otorhinolaryngol*. 2015;79(11):1881-1885. doi: 10.1016/j.ijporl.2015.08.036
- Ruiz, FE. Airway foreign bodies in children. In: Hoppin AG, ed. *UpToDate*. Waltham, MA: UpToDate Inc. <https://www.uptodate.com/contents/airway-foreign-bodies-in-children>. Updated May 31, 2017. Accessed September 18, 2017.
- Salih AM, Alfaki M, Alam-Elhuda DM. Airway foreign bodies: a critical review for a common pediatric emergency. *World J Emerg Med*. 2016;7(1):5-12. doi: 10.5847/wjem.j.1920-8642.2016.01.001
- Viaznikova T. Adult epiglottitis: not just a hot potato. *CanadiEM*. <https://canadiem.org/adult-epiglottitis-just-hot-potato/>. Published July 21, 2014. Accessed August 10, 2017.
- Woods CR. Epiglottitis (supraglottitis): clinical features and diagnosis. In: Wiley JF II, ed. *UpToDate*. Waltham, MA: UpToDate Inc. <https://www.uptodate.com/contents/epiglottitis-supraglottitis-clinical-features-and-diagnosis>. Updated May 3, 2017. Accessed August 10, 2017.



# USER GUIDE

## Head and Neck Infections Suggested Readings

1. Guthrie K. My throat hurts! Life in the Fastlane. <https://lifeinthefastlane.com/ent-equivocation-002/>. Published March 24, 2011. Accessed August 10, 2017.
2. Lin M. Paucis Verbis card: strep pharyngitis. Academic Life in Emergency Medicine. <https://www.aliem.com/2010/paucis-verbis-card-strep-pharyngitis/>. Published July 30, 2010. Accessed August 10, 2017.
3. Nickson C. Mucormycosis. Life in the Fastlane. <https://lifeinthefastlane.com/ccc/mucormycosis/>. Revised July 29, 2015. Accessed August 10, 2017.
4. Reed K. What really helps a sore throat. EM:RAP. <https://www.emrap.org/episode/december2009/what-reallyhelps>. Published December 2009. Accessed August 10, 2017.

## Head and Neck Infections Additional References

1. Hayward G, Perera R, Del Mar C, Glasziou P. Corticosteroids for pain relief in sore throat: systematic review and meta-analysis. *BMJ*. 2009;339:b2976. doi: 10.1136/bmj.b2976
2. Ingalsbe G. Highlights of the American Academy of Otolaryngology adult sinusitis guidelines. ACEP Now. <http://www.acepnow.com/em-summary-american-academy-otolaryngology-adult-sinusitis-guideline/>. Published June 8, 2016. Accessed September 19, 2017.
3. Mclsaac WJ, Kellner JD, Aufricht P, Vanjaka A, Low DE. Empirical validation of guidelines for the management of pharyngitis in children and adults. *JAMA*. 2004;291(31):1587-1595. doi: 10.1001/jama.291.13.1587

## Nasal Suggested Readings

1. Gallegos M. Epistaxis management in the emergency department: a helpful mnemonic. Academic Life in Emergency Medicine. <https://www.aliem.com/2017/02/epistaxis-management-emergency-department-mnemonic/>. Published February 15, 2017. Accessed August 10, 2017.
2. Grock A. AIR Series: HEENT module 2014. Academic Life in Emergency Medicine. <https://www.aliem.com/2014/09/air-series-heent-module-2014/>. Published September 1, 2014. Accessed August 10, 2017.
3. Helbert M, Swadron S. C3 epistaxis: intro and anatomy. EM:RAP. <https://www.emrap.org/episode/c3epistaxis/introand-anatomy>. Published May 2017. Accessed August 10, 2017.

4. Mason J. Epistaxis management. EM:RAP. [https://www.emrap.org/episode/epistaxis/epistaxis\\_](https://www.emrap.org/episode/epistaxis/epistaxis_). Published May 2017. Accessed August 10, 2017.
5. Schlosser RJ. Clinical practice. Epistaxis. *N Engl J Med*. 2009;360(8):784-789. doi: 10.1056/NEJMc0807078

## Nasal Additional References

1. Barnes ML, Spielmann PM, White PS. Epistaxis: a contemporary evidence based approach. *Otolaryngol Clin North Am*. 2012;45(5):1005-1017. doi: 10.1016/j.otc.2012.06.018
2. Béquignon E, Teissier N, Gauthier A, Brugel L, De Kermadec H, Coste A, et al. Emergency department care of childhood epistaxis. *Emerg Med J*. 2017;34(8):543-548. doi: 10.1136/emermed-2015-205528
3. Gilman C. Focus on: treatment of epistaxis. American College of Emergency Physicians. <https://www.acep.org/Clinical---Practice-Management/Focus-On--Treatment-of-Epistaxis/>. Published June 2009. Accessed August 10, 2017
4. Kasperk ZA, Pollock GF. Epistaxis: An overview. *Emerg Med Clin North Am*. 2013;31(2):443-454. doi: 10.1016/j.emc.2013.01.008
5. Mathiasen RA, Cruz RM. Prospective, randomized, controlled clinical trial of a novel matrix hemostatic sealant in patients with acute anterior epistaxis. *Laryngoscope*. 2005;115(5):899-902. doi: 10.1097/01.mlg.0000160528.50017.3c

## Dental Suggested Readings

1. Beaudreau RW. Oral and dental emergencies. In: Tintinalli JE, Stapczynski J, Ma O, Cline DM, Cydulka RK, Meckler GD, eds. *Tintinalli's Emergency Medicine: A Comprehensive Study Guide*. 8<sup>th</sup> ed. New York, NY: McGraw-Hill; 2011:1598-1613.
2. Kman N, Kumar VP. Acute necrotizing ulcerative Gingivitis (ANUG). *JETem*. 2017;2(2):V1-2. doi: 10.21980/J8S88H
3. Kman NE. Dental emergencies. In: Sherman SC, Weber JM, Schindlbeck MA, Rahul GP, eds. *Clinical Emergency Medicine*. 1<sup>st</sup> ed. New York, NY: McGraw-Hill; 2014:327-332.

## Dental Additional References

1. Atout R, Todescan S. Managing patients with necrotizing ulcerative gingivitis. *J Can Dent Assoc*. 2013;79:d46.
2. Douglass AB, Douglass JM. Common dental emergencies. *Am Fam Physician*. 2003;67(3):511-517.
3. Folayan MO. The epidemiology, etiology, and pathophysiology of acute necrotizing ulcerative



## USER GUIDE

gingivitis associated with malnutrition. *J Contemp Dent Pract.* 2004;5(3):28-41.

4. Hu J, Kent P, Lennon JM, Logan LK. Acute necrotizing ulcerative gingivitis in an immunocompromised young adult. *BMJ Case Rep.* 2015;pii:bcr2015211092. doi: 10.1136/bcr-2015-211092
5. Nguyen, DH. Martin, JT. Common dental infections in the primary care setting. *Am Fam Physician.* 2008;77(6):797-802.



# DIDACTICS AND HANDS-ON CURRICULUM

Topic	Recommended Educational Strategy	Educational Content	Objectives	Learners	Timing, Resources Needed (Space, Instructors, Equipment, Citations of JETem pubs or other literature)	Recommended Assessment, Milestones Addressed
Ear Emergencies	<p>- “Flipped” Classroom Discussion of Pre-reading Material, Case Discussions, and Discussion Questions</p> <p>-Encourage Participants to Share Clinical Experiences to Enhance Discussion</p> <p>-15 Minutes for Brief Topic Review and 30-45 Minutes for Case and Content Discussion</p>	-Pathophysiology, diagnosis, and management of ear infections, ear trauma and foreign bodies, and hearing loss.	<p>-Review the pathophysiology, diagnosis and treatment of otitis media.</p> <p>-Recognize and differentiate treatment modalities for ear trauma and ear foreign bodies.</p> <p>-Examine the pathophysiology, diagnosis and therapies for hearing loss.</p>	PGY-1 PGY-2 PGY-3 Medical Students Faculty	<p>Equipment: Projector and Screen Preferable (instructor can pull up web images during session). Tables and Space Promoting Small Group Discussion.</p> <p>Instructors: 2 Education Faculty Members or Content Experts. Predetermined Senior Resident Discussion Leader</p> <p>Timing: Small Group Discussions Involving No More than 15 Learners and Lasting 45-60 Minutes</p>	<p>Milestone: MK</p> <p>Assessment: --- Learner Preparation and Participation -Senior Resident Teaching Skills</p> <p>Evaluation: Post-test created using a purchased question bank</p>
Painless Eye Emergencies	<p>- “Flipped” Classroom Discussion of Pre-reading Material, Case Discussions, and Discussion Questions</p> <p>-Encourage Participants to Share Clinical Experiences to Enhance Discussion</p> <p>-15 Minutes for Brief Topic Review and 30-45 Minutes for Case and Content Discussion</p>	-Pathophysiology, diagnosis and therapies of painless eye emergencies.	<p>-List differential diagnosis for painless eye complaints.</p> <p>-Describe management of painless eye complaints.</p> <p>-Discuss reasons for emergent ophthalmology consult in patients presenting with painless vision disturbances.</p>	PGY-1 PGY-2 PGY-3 Medical Students Faculty	<p>Equipment: Projector and Screen Preferable. Tables and Space Promoting Small Group Discussion.</p> <p>Instructors: 2 Education Faculty Members or Content Experts. Predetermined Senior Resident Discussion Leader</p> <p>Timing: Small Group Discussions Involving No More than 15 Learners and Lasting 45-60 Minutes</p>	<p>Milestone: MK</p> <p>Assessment: --- Learner Preparation and Participation -Senior Resident Teaching Skills</p> <p>Evaluation: Post-test created using a purchased question bank</p>



# DIDACTICS AND HANDS-ON CURRICULUM

Topic	Recommended Educational Strategy	Educational Content	Objectives	Learners	Timing, Resources Needed (Space, Instructors, Equipment, Citations of JETem pubs or other literature)	Recommended Assessment, Milestones Addressed
Painful Eye Emergencies	<p>- “Flipped” Classroom Discussion of Pre-reading Material, Case Discussions, and Discussion Questions</p> <p>-Encourage Participants to Share Clinical Experiences to Enhance Discussion</p> <p>-15 Minutes for Brief Topic Review and 30-45 Minutes for Case and Content Discussion</p>	-Pathophysiology, diagnosis, and management of non-traumatic painful eye complaints.	<p>-Discuss evaluation of emergent eye complaints.</p> <p>-List differential diagnosis for painful eye complaints.</p> <p>-Discuss management of painful eye disorders.</p>	PGY-1 PGY-2 PGY-3 Medical Students Faculty	<p>Equipment: Projector and Screen Preferable. Tables and Space Promoting Small Group Discussion.</p> <p>Instructors: 2 Education Faculty Members or Content Experts. Predetermined Senior Resident Discussion Leader</p> <p>Timing: Small Group Discussions Involving No More than 15 Learners and Lasting 45-60 Minutes</p>	<p>Milestone: MK</p> <p>Assessment: --- Learner Preparation and Participation -Senior Resident Teaching Skills</p> <p>Evaluation: Post-test created using a purchased question bank</p>
Head and Neck Infections	<p>- “Flipped” Classroom Discussion of Pre-reading Material, Case Discussions, and Discussion Questions</p> <p>-Encourage Participants to Share Clinical Experiences to Enhance Discussion</p> <p>-15 Minutes for Brief Topic Review and 30-45 Minutes for Case and Content Discussion</p>	-Pathophysiology, diagnosis, and management of head and neck complaints.	<p>-Review the pathophysiology, diagnosis and treatment of pharyngitis.</p> <p>-Recognize and differentiate treatment modalities for sinusitis.</p> <p>-Examine the can’t miss diagnoses and complications in the patient presenting to the ED with sore throat.</p>	PGY-1 PGY-2 PGY-3 Medical Students Faculty	<p>Equipment: Projector and Screen Preferable. Tables and Space Promoting Small Group Discussion.</p> <p>Instructors: 2 Education Faculty Members or Content Experts. Predetermined Senior Resident Discussion Leader</p> <p>Timing: Small Group Discussions Involving No More than 15 Learners and Lasting 45-60 Minutes</p>	<p>Milestone: MK</p> <p>Assessment: --- Learner Preparation and Participation -Senior Resident Teaching Skills</p> <p>Evaluation: Post-test created using a purchased question bank</p>



# DIDACTICS AND HANDS-ON CURRICULUM

Topic	Recommended Educational Strategy	Educational Content	Objectives	Learners	Timing, Resources Needed (Space, Instructors, Equipment, Citations of JETem pubs or other literature)	Recommended Assessment, Milestones Addressed
Pediatric Airway Foreign Bodies and Upper Airway Emergencies	<p>- “Flipped” Classroom Discussion of Pre-reading Material, Case Discussions, and Discussion Questions</p> <p>-Encourage Participants to Share Clinical Experiences to Enhance Discussion</p> <p>-15 Minutes for Brief Topic Review and 30-45 Minutes for Case and Content Discussion</p>	-Pathophysiology, diagnosis, and management of pediatric airway foreign bodies and upper airway emergencies.	<p>-Review acute airway obstruction etiologies, diagnosis and treatment in pediatric patients, including airway management.</p> <p>-Discuss differential diagnosis and treatment of airway foreign bodies in the pediatric patient.</p> <p>-Review and recite etiologies of HEENT emergencies in pediatric patients.</p>	PGY-1 PGY-2 PGY-3 Medical Students Faculty	<p>Equipment: Projector and Screen Preferable. Tables and Space Promoting Small Group Discussion.</p> <p>Instructors: 2 Education Faculty Members or Content Experts. Predetermined Senior Resident Discussion Leader</p> <p>Timing: Small Group Discussions Involving No More than 15 Learners and Lasting 45-60 Minutes</p>	<p>Milestone: MK</p> <p>Assessment: --- Learner Preparation and Participation -Senior Resident Teaching Skills</p> <p>Evaluation: Post-test created using a purchased question bank</p>
Nasal Emergencies	<p>- “Flipped” Classroom Discussion of Pre-reading Material, Case Discussions, and Discussion Questions</p> <p>-Encourage Participants to Share Clinical Experiences to Enhance Discussion</p> <p>-15 Minutes for Brief Topic Review and 30-45 Minutes for Case and Content Discussion</p>	-Pathophysiology, differential diagnosis, diagnostic modalities, and treatment of nasal emergencies including trauma.	<p>-Discuss common causes of epistaxis.</p> <p>-Describe first line interventions for management of epistaxis.</p> <p>-Describe an approach to management of complicated epistaxis.</p> <p>-Discuss evaluation and management of nasal trauma.</p>	PGY-1 PGY-2 PGY-3 Medical Students Faculty	<p>Equipment: Projector and Screen Preferable. Tables and Space Promoting Small Group Discussion.</p> <p>Instructors: 2 Education Faculty Members or Content Experts. Predetermined Senior Resident Discussion Leader</p> <p>Timing: Small Group Discussions Involving No More than 15 Learners and Lasting 45-60 Minutes</p>	<p>Milestone: MK</p> <p>Assessment: --- Learner Preparation and Participation -Senior Resident Teaching Skills</p> <p>Evaluation: Post-test created using a purchased question bank</p>



# DIDACTICS AND HANDS-ON CURRICULUM

Topic	Recommended Educational Strategy	Educational Content	Objectives	Learners	Timing, Resources Needed (Space, Instructors, Equipment, Citations of JETem pubs or other literature)	Recommended Assessment, Milestones Addressed
Dental Emergencies	<p>- “Flipped” Classroom Discussion of Pre-reading Material, Case Discussions, and Discussion Questions</p> <p>-Encourage Participants to Share Clinical Experiences to Enhance Discussion</p> <p>-15 Minutes for Brief Topic Review and 30-45 Minutes for Case and Content Discussion</p>	-Pathophysiology, differential diagnosis, diagnostic modalities, and treatment of dental complaints.	<p>-Describe traumatic dental injuries encountered in the ED, including fracture classification, temporary repair, and when to call OMFS/ Dental.</p> <p>-Describe conventions for teeth numbering.</p> <p>-Describe the most common types of dental infections and appropriate ED management.</p> <p>-Describe techniques for dental blocks and anesthesia for dental pain.</p>	PGY-1 PGY-2 PGY-3 Medical Students Faculty	<p>Equipment: Projector and Screen Preferable. Tables and Space Promoting Small Group Discussion.</p> <p>Instructors: 2 Education Faculty Members or Content Experts. Predetermined Senior Resident Discussion Leader</p> <p>Timing: Small Group Discussions Involving No More than 15 Learners and Lasting 45-60 Minutes</p>	<p>Milestone: MK</p> <p>Assessment: --- Learner Preparation and Participation -Senior Resident Teaching Skills</p> <p>Evaluation: Post-test created using a purchased question bank</p>



## Appendix A: Ear Emergencies

### Objectives

1. Review the pathophysiology, diagnosis and treatment of otitis media.
2. Recognize and differentiate treatment modalities for ear trauma and ear foreign bodies.
3. Examine the pathophysiology, diagnosis and therapies for hearing loss.

### Case Studies

**Case 1:** An 18-month-old male patient presents with his parents to the emergency department with fussiness and tugging at his ear. He is not very active in the room but not toxic appearing either. His Left tympanic membrane (TM) is red, but not bulging and does not appear to have pus behind the ear. His parents demand antibiotics (the one that tastes like bubble gum). Vital Signs: Temperature 99.7 degrees Fahrenheit, Heart Rate 136 beats/minute, Blood Pressure 96/54 mmHg, Respiratory Rate 32 per minute, Oxygen Saturation 97%.

### Question Prompts:

1. What are the most common pathogens in otitis media (OM)?
  - a. The most common pathogens in OM are *S. pneumoniae* (40%-50%), *H. influenzae* (20%-30%), *Moraxella catarrhalis* (10%-15%), and *Staphylococcus*, Group A *streptococcus*, and viruses (respiratory syncytial virus). Of note, a subset of *S. pneumoniae* are drug resistant (DRSP). Risk factors for drug resistance include recent antibiotic use, age less than two years, and day care exposure.
2. What do you need to order for this patient? Are any labs/imaging indicated?
  - a. OM is a clinical diagnosis and in most cases labs and imaging are not indicated. Look for pain, fever (may not be related), cough or upper respiratory infection (URI) symptoms, (ear-pulling is not specific and gastrointestinal symptoms are not specific), and/or hearing loss. In Infants, the most sensitive sign of OM is immobility of the TM to insufflation of the ear with the pneumatic otoscope. They also can have nonspecific symptoms such as irritability, crying, vomiting, diarrhea. Older, especially elderly patients, may present with vertigo or tinnitus
3. Do you prescribe antibiotics?
  - a. This is a source of great variability between providers. Treatment with antibiotics is better than no treatment but not by much (95% versus 80%) and 7 patients need to be treated before 1 patient benefits. In non-toxic, immunocompetent patients, who have not recently been on antibiotics, some providers advocate a wait and see approach, in which the patient is given a prescription for an antibiotic but instructed only to fill it, if the patient is not improved in 48 hours.



## DIDACTICS AND HANDS-ON CURRICULUM

- b. If antibiotics are prescribed, a ten-day course of amoxicillin is still considered first line therapy. 90 mg/kg/day is preferred secondary to a high incidence of DRSP. If the patient has persistent pain, fever, bulging and/or redness of the tympanic membrane after 3 days of treatment, they are considered to have failed the initial treatment and their antibiotic regimen should be changed. Second line treatment options include amoxicillin-clavulanic acid, cefuroxime, IM ceftriaxone (once or every day for three days), clindamycin. Trimethoprim/sulfamethoxazole and macrolides can also be considered for those who have greater problems with DRSP. If the patient has had antibiotics within the past 30 days for acute otitis media, treatment should start with a second line agent. If the patient has drainage from the external auditory canal, they should also receive antibiotic otic drops. In severe cases with toxicity, persistent high fevers, or complications, myringotomy can be considered to treat OM.
- c. Regardless of antibiotic prescription, all patients should receive prescriptions oral pain medications such as ibuprofen and acetaminophen. Consider otic analgesics as well.

**Case 2:** On an overnight shift, a 36-year-old male presents holding his ear and shouting. You are concerned he might be psychotic so you grab the haloperidol. Once you calm him down, he tells you he has a scratching in his ear. You look in to see a cockroach moving against the TM. Vital Signs: Temperature 98.7 degrees Fahrenheit, Heart Rate 106 beats/minute, Blood Pressure 140/86 mmHg, Respiratory Rate 18 per minute, Oxygen Saturation 100%.

### Question Prompts:

1. What are the next best steps for treatment of this patient?
  - a. Common causes of otic foreign bodies (FB) include insects, childhood curiosity, and loss of cleaning materials such as cotton swabs. Clinically these patients present with pain, decreased hearing, and/or discharge from the ear. Treatment includes identifying the FB and ruling out TM perforation. The FB should be removed using a probe, suction, forceps (alligator, Hartman), irrigation, or cyanoacrylate glue. Vegetable matter should not be irrigated as this can cause them to swell. Uncooperative patients may require general anesthesia or conscious sedation. Insects may be stupefied with 2% lidocaine, mineral oil, or ether-soaked cotton prior to attempted removal. Complications from removal of the FB include TM perforation, canal trauma, and ossicular damage. The canal and TM should always be examined for damage after the successful removal of a FB. If the epithelium is damaged, the patient should be prescribed an otic drop antibiotic.
2. After removal, you notice that the patient has a very small TM perforation. What do you need to do?
  - a. Common causes of TM perforation include: iatrogenic causes, a penetrating object, otitis media, blunt trauma (explosion), barotrauma, and lightning. These patients clinically present with pain, hearing loss, bleeding, and lack of movement of the TM on exam. Most TM perforations will heal spontaneously within 3 months. All patients should be given analgesia, ENT referral, and instructed to keep the ear dry. If the ear is contaminated,



# DIDACTICS AND HANDS-ON CURRICULUM

antibiotic otic drops should be prescribed. Chronic hearing loss, persistent facial nerve palsy, and a cerebrospinal fluid fistula are all potential long-term complications of middle ear trauma.

**Case 3:** A 61-year-old male presents to the Emergency Department with hearing loss. He was talking on his cell phone when he suddenly realized he couldn't hear well out of his left ear. Vital Signs: Temperature 98.3 degrees Fahrenheit, Heart Rate 75 beats/minute, Blood Pressure 156/96 mmHg, Respiratory Rate 14 per minute, Oxygen Saturation 98%.

## Question Prompts:

1. What are the possible etiologies of this hearing loss?
  - a. Sudden hearing loss is typically unilateral. The differential is often conceptualized based on whether the hearing loss is a conductive loss or sensorineural loss as well as the anatomical location of the lesion or abnormality.
    - External ear
      1. Lesions in this location cause a conductive loss. The most common etiology is cerumen impaction, but FB and otitis externa should also be considered in the differential.
    - Middle ear
      1. Lesions in this location also cause a conductive hearing loss. The differential includes a perforated TM, tympanosclerosis, otosclerosis, and OM.
    - Inner ear
      1. Lesions in this location typically cause a sensorineural hearing loss. Ménière's disease usually presents with unilateral hearing loss, vertigo, and tinnitus. Labyrinthitis should also be considered. Syphilis can cause a bilateral sensorineural hearing loss, but is usually congenital.
    - Other causes that should be considered in this patient's case include idiopathic causes (viral or vascular), viral neuritis of the cochlear branch of the 8th nerve, and acoustic neuroma (though it typically has accompanying tinnitus and vertigo). Other causes of bilateral hearing loss include noise exposure and medication side effects to aminoglycosides, non-steroidal anti-inflammatory medications, and furosemide.
2. How would you treat this patient?
  - a. Treatment and complications are cause-specific, though the current standard treatment for sudden sensorineural hearing loss is a tapered course of oral corticosteroids (prednisone or methylprednisolone). Some otolaryngologists recommend local corticosteroid therapy for sudden sensorineural hearing loss, administered either by intra-tympanic injections or as eardrops by means of a ventilating tube or a wick running from a ventilating tube to the round window membrane in the medial wall of the middle ear.
3. Describe Physical Exam methods to help make the diagnosis.



# DIDACTICS AND HANDS-ON CURRICULUM

- a. All these patients should undergo a full neurological exam and exam of the ears with an otoscope. Weber and Rinne tests can be used to help determine if the hearing loss is conductive or sensorineural.
  - Rinne Test
    1. A tuning fork is struck and placed on the mastoid.
    2. When the patient indicates they can no longer hear, the tuning fork is placed a few centimeters from the external auditory canal.
    3. In a normal test result, the patient will again hear the tuning fork when it is moved.
    4. If the patient fails to hear the tuning fork when it is moved, this is indicative of a conductive hearing loss.
    5. In sensorineural hearing loss, the patient may more quickly lose the ability to hear the tuning fork in the affected side compared to the unaffected side, but the property of losing bone conduction prior to air conduction should be preserved.
  - Weber Test
    1. A tuning fork is struck and placed in the center forehead or the top of the cranium.
    2. In normal hearing, the patient will hear the tuning fork equally between the two ears.
    3. If the patient hears the tuning fork louder in the affected ear, this indicates a conductive hearing loss.
    4. If the patient hears the tuning fork louder in the unaffected ear, this indicates a sensorineural hearing loss.

## Suggested Readings

Herbert M. Malignant otitis externa – a review. EM: RAP.

<https://www.emrap.org/episode/september2010/malignantotitis>. Published September 2010. Accessed August 10, 2017

Hoberman A, Paradise JL, Rockette HE, Shaikh N, Wald ER, Kearney DH, et al. Treatment of acute otitis media in children under 2 years of age. *N Engl J Med*. 2011;364(2):105-115. doi: 10.1056/NEJMoa0912254

Li M. Trick of the trade: insect removal from the ear. *Academic Life in Emergency Medicine*.

<https://www.aliem.com/2014/trick-of-trade-insect-removal-from-the-ear/>. Published October 2, 2014. Accessed August 10, 2017.

Weingart S, Newman D. Otitis media – needs no therapy! – An investigate report. EM:RAP.

<https://www.emrap.org/episode/may2011/otitismedia> Published May 2011. Accessed August 10, 2017.

King, et al. Novel Emergency Medicine Curriculum Utilizing Self-Directed Learning and the Flipped Classroom Method: Head, Eyes, Ears, Nose and Throat Emergencies Small Group Module. *JETem* 2017. 2(4):C1-46. <https://doi.org/10.21980/J8PW5N>





# DIDACTICS AND HANDS-ON CURRICULUM

## Additional References:

Chow Y. Trick of the trade: ear foreign body removal with modified suction setup. *Academic Life in Emergency Medicine*. <https://www.aliem.com/2015/trick-of-the-trade-ear-foreign-body-removal-with-modified-suction-setup/>. Published August 25, 2015. Accessed August 10, 2017.

Chow Y. Trick of the trade: pediatric video laryngoscope for ear foreign bodies. *Academic Life in Emergency Medicine*. <https://www.aliem.com/2014/trick-trade-pediatric-video-laryngoscope-ear-foreign-bodies/>. Published November 24, 2014. Accessed August 10, 2017.

Rauch SD. Idiopathic sudden sensorineural hearing loss. *N Engl J Med*. 2008;359(8):833-840. doi: 10.1056/NEJMcp0802129

Hosmer K. Common disorders of the external, middle, and inner ear. In: Tintinalli JE, Stapczynski J, Ma O, Cline DM, Cydulka RK, Meckler GD, eds. *Tintinalli's Emergency Medicine: A Comprehensive Study Guide*. 8<sup>th</sup> ed. New York, NY: McGraw-Hill; 2011:1579-1585.

Spiro DM, Tay KY, Arnold DH, Dziura JD, Baker MD, Shapiro ED. Wait-and-see prescription for the treatment of acute otitis media: a randomized controlled trial. *JAMA*. 2006;296(10):1235-1241. doi: 10.1001/jama.296.10.1235



## Appendix B: Painless Eye Emergencies

### Objectives

1. List the differential diagnosis for painless eye complaints.
2. Describe the management of painless eye complaints.
3. Discuss reasons for emergent ophthalmology consult in patients presenting with painless vision disturbances.

### Case Studies

**Case 1:** A 52-year-old woman presents with a complaint of sudden onset of floaters and flashes of lights in her right eye followed by loss of vision in that eye while she was eating breakfast. She has a history of nearsightedness and hypertension but has never experienced anything like this before. She denies any recent eye pain or trauma. She states that it seemed like a filmy cover came down over her right eye. Vital Signs: Temperature 98.3 degrees Fahrenheit, Heart Rate 81 beats/minute, Blood Pressure 150/90 mmHg, Respiratory Rate 14 per minute, Oxygen Saturation 98%.

### Question Prompts:

1. List a differential diagnosis for painless vision loss. What about for a painless red eye?
  - a. Loss of vision: Central retinal artery occlusion (CRAO), central retinal vein occlusion (CRVO), retinal detachment, vitreous hemorrhage, macular degeneration, cerebrovascular accident (CVA), neuro-ophthalmologic disease, methanol ingestion, temporal arteritis, and conversion disorder. Vision loss that occurs over a matter of seconds is usually due to a vascular cause.
  - b. Painless Red eye: Kawasaki's syndrome, conjunctivitis (though can have minor irritation), subconjunctival hemorrhage
2. Which of these conditions require emergent ophthalmologic consultation?
  - a. Anything with acute vision loss requires emergent ophthalmologic consultation: CRAO, CRVO, temporal arteritis, retinal detachment.
3. What are the pathophysiology, presentation and management for retinal detachment?
  - a. Retinal detachment is a relatively common condition that affects one in 300 people. The retina is composed of two layers, an inner neuronal layer and an outer pigment epithelial layer (the choroid). Retinal detachment refers to separation of the two layers. It is more common in people 45 years and older and people with myopia. Prior eye surgery and eye trauma are also risk factors. Commonly, patients complain of flashes of light, floaters, or fine dots or cobwebs in their visual fields. The loss of vision is usually sudden in onset and starts peripherally, with propagation to the central visual field. Visual loss is generally



# DIDACTICS AND HANDS-ON CURRICULUM

described as filmy, cloudy, or curtain-like in appearance. Though unlike with vitreous detachment, patients with retinal detachment will have frank visual field deficits. The diagnosis can be made either by direct fundusoscopic exam or by point of care ultrasound. The sooner treatment is initiated, the greater chance of visual preservation and recovery; therefore, emergency ophthalmology consultation is indicated. This applies to detachments that have not yet detached the macula, “mac-on.” In cases where the detachment has already detached the macula, “mac-off,” intervention is less urgent as the prognosis for recovery of central visual acuity is already very poor. Surgery, laser photocoagulation, cryotherapy and intraocular gas are options for therapy.

**Case 2:** A 65-year-old man presents with a complaint of sudden vision loss in his left eye. His medical problems include diabetes mellitus, hypertension and hyperlipidemia but he is non-compliant with his medications which include metformin, hydrochlorothiazide, and atorvastatin. He denies any eye pain, trauma or headaches. On exam, he has a relative afferent pupillary defect (RAPD) of the left eye. Fundusoscopic exam reveals a pale retina with a prominent red fovea. Vital Signs: Temperature 99.1 degrees Fahrenheit, Heart Rate 89 beats/minute, Blood Pressure 178/96 mmHg, Respiratory Rate 14 per minute, Oxygen Saturation 96%.

## Question Prompts:

1. Why is the diagnosis of a CRAO time sensitive? What can you do to manage vision loss from CRAO?
  - a. The pathophysiology is similar to an ischemic CVA; however, instead of a clot limiting blood supply to brain tissue, it is limiting blood supply to the retina. The retina is somewhat resistant to ischemia, so vision can be regained if the obstruction is relieved within 2 hours of onset. Unfortunately, there are no reliable therapies to relieve the obstruction. Classically ocular massage has been taught wherein moderate pressure is applied for 5 seconds and then released for 5 seconds. Anterior chamber paracentesis has been used, guided by the principle that a lower intra-ocular pressure would allow the clot to be propelled distally. Acetazolamide has been used based on this same principle. Other treatment options include inhaled carbogen (mixture of 95% oxygen and 5% carbon dioxide) or breathing into a paper bag to dilate the vasculature, intra-arterial thrombolysis, and hyperbaric oxygen.
2. How does the exam differ versus CRVO?
  - a. The characteristic differences are in the fundusoscopic exam. CRAO has a pale retina with prominent red fovea often described as a “cherry-red spot,” whereas CRVO has a “shock and thunder” appearance from multiple hemorrhages of the retina. Generally, CRVO is more chronic. Ophthalmology will use agents like Anti-VEGF drugs or intravitreal injections but there is nothing to do in the emergency department unless there is a comorbid acute medical issue.
3. What is an RAPD? In what conditions do you see it?
  - a. RAPD stands for relative afferent pupillary defect, and indicates an impairment of the nerve to sense light. Optic nerve lesion or severe retinal disease resulting in vision loss/ lack of sensing



# DIDACTICS AND HANDS-ON CURRICULUM

light cause this exam finding. On exam, you will see neither pupil constrict when a light is shown into the affected pupil, but both pupils will constrict when a light is shown into the unaffected pupil.

**Case 3:** A 62-year-old female presents with sudden loss of vision in her right eye that started three hours earlier. She states she has been having headaches on the right side of her head for several weeks now and has noticed that she has been having some stiffness in her shoulders and hips, but attributes that to “just getting older.” She denies any extremity weakness, or any trauma to the eye. On exam there is tenderness to palpation over the right temple. Vital Signs: Temperature 98.1 degrees Fahrenheit, Heart Rate 64 beats/minute, Blood Pressure 148/86 mmHg, Respiratory Rate 18 per minute, Oxygen Saturation 97%.

## Question Prompts:

1. Discuss the diagnosis of temporal arteritis. How does the patient present? What disease is it associated with? What is the management? Does a lab test rule it out?
  - a. Temporal arteritis is a vasculitis of autoimmune etiology affecting the arterial branches of the internal carotid artery (ophthalmic and temporal arteries) that is often preceded by features of polymyalgia rheumatica (PMR). Symptoms can vary but jaw claudication and diplopia are the most predictive. Other possible symptoms include: temporal area pain and subacute peripheral vision loss, low grade fever, constitutional symptoms lasting weeks to months (anorexia, fatigue, myalgias, night sweats, weight loss), ataxia, and decreased hearing. On physical exam, beading, prominence, or tenderness of the temporal artery is the most predictive, but temporal scalp tenderness, hyperesthesia and hypersensitivity, and vestibular or hearing impairment may also be seen. Elderly patients may present with vague complaints overall, so this diagnosis should be in the differential for those patients who present as “weak and dizzy.” The American College of Rheumatology offers the following diagnostic criteria: age over 50, new headache, abnormality of the temporal artery (tenderness or decreased pulsation), erythrocyte sedimentation rate (ESR) >50 mm/hour, and abnormal temporal artery biopsy. The presence of three out of five positive criteria results in a sensitivity of 93% for the diagnosis, and a specificity of 91% and is considered diagnostic. ESR is not sensitive enough to rule out this diagnosis in isolation. Steroids are the mainstay of treatment, with oral formulation recommended if there are no ocular symptoms and intravenous formulation if there are ocular symptoms. Do not delay treatment even if biopsy cannot be performed for a few days because earlier treatment has been shown to lead to better improvement (60% if treated within 24hrs of symptoms vs. only 5% if treated after 24hrs).



# DIDACTICS AND HANDS-ON CURRICULUM

## Suggested Readings:

Helman A. Episode 9: nontraumatic eye emergencies. *Emergency Medicine Cases*. <http://emergencymedicinecases.com/episode-9-nontraumatic-eye-emergencies/>. Published November 22, 2010. Accessed August 10, 2017.

Mahmood AR, Narang AT. Diagnosis and management of the acute red eye. *Emerg Med Clin North Am*. 2008;26(1):35-55,vi. doi: 10.1016/j.emc.2007.10.002

## Additional References:

Bhatia K, Sharma R. Eye emergencies. In: Adams JG, Barton ED, Collings JL, DeBlieux PM, Gisondi MA, Nadel ES, eds. *Emergency Medicine: Clinical Essentials*. 2<sup>nd</sup> ed. Philadelphia, PA: Elsevier; 2013:209-225.

Hunder GG, Bloch DA, Michel BA, Stevens MB, Arend WP, Calabrese LH, et al. The American College of Rheumatology 1990 criteria for the classification of giant cell arteritis. *Arthritis Rheum*. 1990;33(8):1122-1128.

Lin M. Tricks of the trade: diagnosing retinal detachment with ultrasound. *Academic Life in Emergency Medicine*. <https://www.aliem.com/2009/12/tricks-of-trade-diagnosing-retinal/>. Accessed October 12, 2017.

Sharma R, Brunette DD. Ophthalmology. In: Walls RM, Hockberger RS, Gausche-Hill M, Bakes KM, et al. eds. *Rosen's Emergency Medicine: Concepts and Clinical Practice*. 8<sup>th</sup> ed. Philadelphia, PA: Elsevier; 2014:909-931.



## Appendix C: Painful Eye Emergencies

### Objectives

1. Discuss evaluation of emergent eye complaints.
2. List differential diagnosis for painful eye complaints.
3. Discuss management of painful eye disorders.

### Case Studies

**Case 1:** A 63-year-old female patient with a past medical history of diabetes presents with complaints of a headache and severe pain and blurry vision in her left eye after going to a movie theater earlier in the evening. She is wearing glasses because she is farsighted, but denies wearing contact lenses. She also denies any foreign body sensation. She also denies any trauma to the eye or any previous episodes like this one. On exam her left pupil is 4-5 mm, minimally reactive to light and has some limbic injection, and intraocular pressure (IOP) is 50 mm Hg. The right eye is normal on exam. Vital Signs: Temperature 97.3 degrees Fahrenheit, Heart Rate 89 beats/minute, Blood Pressure 154/98 mmHg, Respiratory Rate 16 per minute, Oxygen Saturation 96%.

### Question Prompts:

1. How do you diagnose acute angle closure glaucoma and what are the risk factors?
  - a. Acute angle closure glaucoma is characterized by at least two of the following symptoms: acute onset ocular pain with nausea, vomiting, intermittent blurring of vision with halos seen around lights (due to corneal edema), photophobia, and visual loss. As well as at least three of the following physical exam signs: intraocular pressure (IOP) >21 mmHg (often 40-80 mmHg), conjunctival injection, corneal epithelial edema causing haziness, fixed and mid-dilated pupil, and shallow anterior chamber (on *oblique flashlight test* with shadow medial to pupil caused by the bulging anterior chamber when the light is flashed from the patient's temporal side). Caution should be taken with elderly, demented, and psychiatric patients as this can be a difficult diagnosis to make when the patient is unable to provide a reliable history. Patients may also present complaining of a headache or abdominal pain and vomiting, rather than providing a classic history. Risk factors include elderly patients who are far-sighted (hyperopic), recent ophthalmologic surgery, and certain medications such as anticholinergics, antimuscarinics, antidepressants, antipsychotics, antihistamines, and sympathomimetics.
2. What is the emergency department management of acute angle closure glaucoma?
  - a. A topical beta-blocker (e.g. 1 drop of timolol 0.25-0.5%) is used to decrease aqueous humor production if there is no contraindication present, such as chronic obstructive pulmonary disease (COPD), asthma, or bradycardia.



# DIDACTICS AND HANDS-ON CURRICULUM

- b. A topical cholinergic (1-2 drops of Pilocarpine every 15min for two doses) is used to cause miosis, decrease the angle of the anterior chamber at the trabecular meshwork level, and increase drainage.
  - c. Acetazolamide 500mg intravenous (IV) or orally is used to decrease aqueous humor production. Mannitol 1.25-2g/kg IV of 20% solution can be added to exert an osmotic diuresis if there is no response to the above agents.
  - d. These patients require reassessment of their IOP every 15 minutes while treatment is initiated.
3. If you are at an outside hospital, what are causes of eye pain that require transfer to a hospital with ophthalmology?
- a. This is debatable but in general those conditions which require emergent ophthalmologic evaluation are those with acute angle closure glaucoma, optic neuritis (could be admitted and transferred potentially), hypopyon, and endophthalmitis.
4. How can the patient's description of eye pain help guide your evaluation?
- a. Characterization of a patient's eye pain helps determine the location of the pathology.
    1. Up-front, scratchy, "sand-in-the-eye" pain relates to anterior structures such as the lids, conjunctivae, cornea, and foreign bodies.
    2. A deep, boring, 'behind-the-eye' toothache pressure-type pain relates to posterior structures.
    3. Photophobia relates to uveal tract pathology such as iris, ciliary body and choroid.

**Case 2:** A 36-year-old woman with a history of recently diagnosed Crohn's disease presents with worsening right eye pain and redness over the last day. She denies ever having problems with her eyes in the past and doesn't wear any corrective lenses. She endorses pain with movement of her right eye, as well as pain with exposure to bright light. On exam, she has mild conjunctival injection, but prominent erythema in the limbic region. Her slit lamp exam is notable for cells in her anterior chamber that scintillate in the light like "snowflakes in a car's headlights." Vital Signs: Temperature 98.6 degrees Fahrenheit, Heart Rate 65 beats/minute, Blood Pressure 114/78 mmHg, Respiratory Rate 14 per minute, Oxygen Saturation 99%.

## Question Prompts:

1. What are the signs and symptoms of anterior uveitis also known as iritis? Why is this an important diagnosis to make?
  - a. The most predominant symptom is a deep, aching pain radiating to periorbital or temporal area that is worse with eye movements and accommodation, and exposure to light (photophobia). Typical exam findings include ciliary flush (erythema that is worse closer to the iris, and not in the periphery as in conjunctivitis), pain relief with cycloplegics but not with topical anesthetics, and consensual photophobia (light in the unaffected eye causes pain in the affected eye by virtue of causing bilateral myosis, which causes pain). Slit lamp exam generally reveals keratic precipitates or hypopyon, and cells and flare in the anterior chamber.



# DIDACTICS AND HANDS-ON CURRICULUM

- b. This is an important diagnosis to make in order to prevent long-term vision loss due to scarring, malfunction in the shape of the iris, and the increased likelihood of retinal detachment. Interestingly 50% of cases of iritis have an underlying infectious or autoimmune disease such as herpes, tuberculosis, syphilis, toxoplasmosis, inflammatory bowel disease, ankylosing spondylitis, reactive arthritis, psoriatic arthritis, Behçet's disease, rheumatoid arthritis, systemic lupus erythematosus, sarcoidosis, and scleroderma. If patients are not known to have any of these pathologies, the iritis may be a presenting symptom and they require further work up in the non-emergent setting.
2. Discuss the acute management of iritis.
  - a. These patients require cycloplegic drops to prevent miosis. These drops provide pain control and break up the synechiae which form around the iris as a consequence of the inflammation. Options include: homatropine (1 drop three times a day of 2%-5% solution) which lasts a few days and is probably best, Cyclopentolate (1 drop three times a day of 0.5%-2% solution), which lasts 1 day, and Tropicamide, which lasts only 2-3hrs, and is therefore most useful in making the diagnosis.
  - b. Topical steroids should only be used in conjunction with ophthalmologist consultation due to the concern for worsening of underlying infection or development of corneal ulcer, both of which may lead to loss of vision.
  - c. These patients require ophthalmological follow-up within 24 hours if they are not seen by an ophthalmologist while in the Emergency Department. They also require follow up with a primary care physician who can investigate for underlying infectious or auto-immune diseases as discussed above.
3. What should be the steps taken to examine the painful eye in the emergency department?
  - a. *Systematic eye exam* for every patient with an eye complaint: 6 parts - visual acuity (the '6th vital sign'), visual fields by confrontation, size and reactivity of pupil, extraocular movements (for cranial nerve palsies), anterior segment (slit-lamp exam) and posterior segment (fundoscopy). If concerned, pressures should be checked as well.

**Case 3:** A 28-year-old otherwise healthy female presents with a complaint of worsening vision in her left eye over the last 12 hours, associated with worsening eye pain. She denies any trauma to the eye, or any foreign body sensation. On exam it is noted that she has a relative afferent pupillary defect (RAPD) in the left eye and a visual acuity of 20/100 in the left eye, compared to 20/20 in the right. She also notes that she seems to have decreased ability to differentiate colors in her left eye. Fundoscopic exam reveals a normal retina and a normal optic disc. She also notes that her older sister had something similar happen and went on to develop multiple sclerosis. Vital Signs: Temperature 99.3 degrees Fahrenheit, Heart Rate 81 beats/minute, Blood Pressure 118/74 mmHg, Respiratory Rate 16 per minute, Oxygen Saturation 98%.

## Question Prompts:

1. Discuss the pathophysiology, diagnosis, and acute management of optic neuritis.
  - a. Optic neuritis is inflammation of the optic nerve due to demyelination. There are multiple underlying causes, but Multiple Sclerosis is the most common identifiable cause. Other



# DIDACTICS AND HANDS-ON CURRICULUM

- causes include ischemic optic neuritis from a blood clot, diabetes, liver dysfunction, and renal dysfunction. The classic triad of symptoms includes unilateral loss of vision, eye pain (especially with eye movement) and dyschromatopsia (washed out colors, as if looking through frosted glass). On exam, these patients generally have markedly decreased visual acuity (often to light perception only) with a RAPD but an otherwise normal eye and fundoscopic exam. The Optic Neuritis Treatment Trial showed that intravenous (IV) methylprednisolone 250mg four times per day for three days followed by an oral prednisone taper over 1 week restores vision more quickly, and delays the development of multiple sclerosis by 2 years.
2. What is the differential diagnosis for the painful eye in the emergency department?
    - a. Corneal abrasion, corneal ulcer/bacterial keratitis, acute glaucoma, optic neuritis, uveitis/iritis, herpes simplex keratitis, corneal foreign body, hyphema, hypopyon, chemical/thermal burn, and endophthalmitis are all considerations.
  3. Which of these diagnoses are vision threatening?
    - a. Corneal ulcer (with time), optic neuritis, hyphema, hypopyon, acute glaucoma, endophthalmitis, viral keratitis, and chemical/thermal burn can all be vision threatening.

## Suggested Readings:

Eye emergencies, “answers.” EM Lyceum. <https://emlyceum.com/2014/07/01/eye-emergencies-answers/> Published July 1, 2014. Accessed August 10, 2017.

Helman A. Episode 9: nontraumatic eye emergencies. *Emergency Medicine Cases*. <http://emergencymedicinercases.com/episode-9-nontraumatic-eye-emergencies/> Published November 22, 2010. Accessed August 10, 2017.

Jhun P, Swaminathan A. *Annals of Emergency Medicine* – A really bad poke in the eye. EM:RAP. <https://www.emrap.org/episode/june2015/annalsof>. Published June 2015. Accessed August 10, 2017.

Mahmood AR, Narang AT. Diagnosis and management of the acute red eye. *Emerg Med Clin North Am*. 2008;26(1):35-55.vi. doi: 10.1016/j.emc.2007.10.002

Nickson C. Half an 8 ball. *Life in the Fast Lane*. <https://lifeinthefastlane.com/ophthalmology-befuddler-030/>. Published August 30, 2010. Accessed August 10, 2017.

Nickson C. The red eye challenge. *Life in the Fast Lane*. <https://lifeinthefastlane.com/the-red-eye-challenge/>. Published August 2, 2010. Accessed August 10, 2017.



# DIDACTICS AND HANDS-ON CURRICULUM

## Additional References:

Bhatia K, Sharma R. Eye emergencies. In: Adams JG, Barton ED, Collings JL, DeBlieux PM, Gisondi MA, Nadel ES, eds. *Emergency Medicine: Clinical Essentials*. 2<sup>nd</sup> ed. Philadelphia, PA: Elsevier; 2013:209-225.

Guluma K, Lee J. Ophthalmology. In: Walls RM, Hockberger RS, Gausche-Hill M, Bakes KM. *Rosen's Emergency Medicine: Concepts and Clinical Practice*. 9<sup>th</sup> ed. Philadelphia, PA: Elsevier; 2018:790-819.

Osborne B, Balcer LJ. Optic neuritis: pathophysiology, clinical features, and diagnosis. In: Wilterdink JL, ed. *UpToDate*. Waltham, MA: UpToDate Inc. <https://www.uptodate.com/contents/optic-neuritis-pathophysiology-clinical-features-and-diagnosis>. Updated March 24, 2015. Accessed July 27, 2017.

Rosenbaum JT. Uveitis: etiology, clinical manifestations, and diagnosis. In: Romain PL, ed. *UpToDate*. Waltham, MA: UpToDate Inc. <https://www.uptodate.com/contents/uveitis-etiology-clinical-manifestations-and-diagnosis>. Updated February 24, 2017. Accessed July 27, 2017.



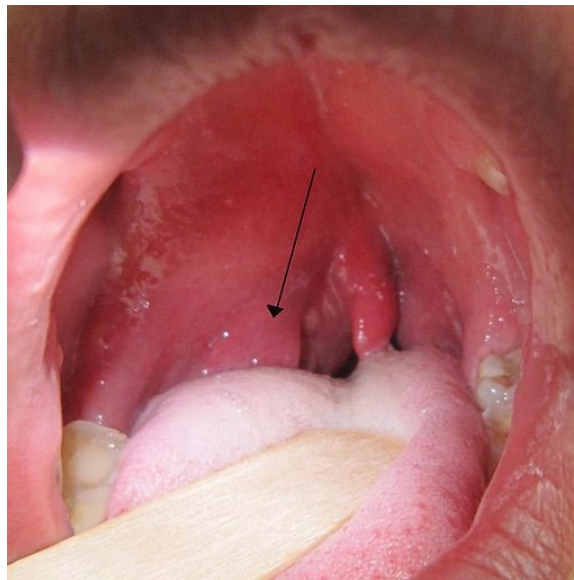
## Appendix D: Head and Neck Infections

### Objectives

1. Review the pathophysiology, diagnosis and treatment of pharyngitis.
2. Recognize and differentiate treatment modalities for sinusitis.
3. Examine the “can’t miss” diagnoses and complications in the patient presenting to the emergency department (ED) with sore throat.

### Case Studies

**Case 1:** A 19-year-old female presents to the ED with severe sore throat. She says that she can’t eat or drink because of the pain. Her mother, who is accompanying her, says that she is having trouble understanding her muffled voice. On exam, she has mild trismus with uvular deviation. Vital Signs: Temperature 101.3 degrees Fahrenheit, Heart Rate 108 beats/minute, Blood Pressure 128/66 mmHg, Respiratory Rate 20 per minute, Oxygen Saturation 97%



[CC BY-SA 3.0 (<http://creativecommons.org/licenses/by-sa/3.0>)], via Wikimedia Commons

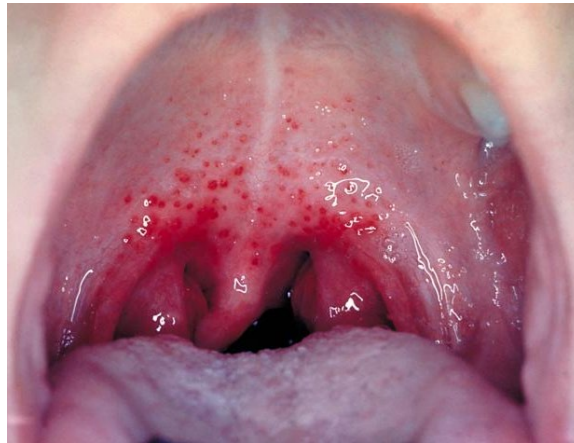### Question Prompts:

1. What is the differential diagnosis of sore throat and what are the key characteristics of each pathology?
  - a. Pharyngitis



## DIDACTICS AND HANDS-ON CURRICULUM

- i. Pharyngitis refers to an inflammation or infection of the mucous membranes of the oropharynx. Symptoms generally include dysphagia, sore throat, fever, and cervical adenopathy. The most common causes are viruses, and the vast majority of cases are self-limiting. Historically Group A beta-hemolytic *Streptococcus* (GABHS) has been an important cause of pharyngitis and subsequent development of rheumatic fever and post-streptococcal glomerulonephritis. Antibiotics decrease symptoms by a matter of hours compared to supportive treatment, decrease the incidence of suppurative complications, and decrease transmission, but most significantly they are prescribed to prevent the development of rheumatic fever.
- ii. The Centor Criteria were developed to guide clinicians in their decisions to perform strep testing or empirically treat patients with antibiotics. Patients are given a point each for the absence of cough, tonsillar exudates, history of fever, and tender anterior cervical adenopathy. The criteria were then modified to add an additional point for age under 15 and subtract a point for age over 44. Classically teaching advocated no testing or antibiotics for scores of one and below. Testing was recommended to guide treatment for scores of two and three. Empiric treatment for antibiotics was recommended for score of four or five. With highly sensitive rapid strep tests, the American Academy of Pediatrics and the Infectious Disease Society of America now recommend that only those with positive rapid tests or cultures should be treated with antibiotics. With such low rates of rheumatic fevers in developed countries, some clinicians advocate only supportive care even for patients with suspected bacterial pharyngitis.



Note the inflammation of the oropharynx and petechiae on the soft palate caused by Strep Throat. Image from <https://phil.cdc.gov/phil/details.asp>.  
Public Domain.

### b. Infectious Mononucleosis

- i. Mono is caused by the Epstein-Barr virus (human herpes virus 4). It typically affects patients between the ages of 10 and 25. Symptoms generally include sore throat, fever, malaise, and fatigue. The exam often reveals exudative pharyngitis



# DIDACTICS AND HANDS-ON CURRICULUM

and tender cervical lymphadenopathy, classically posterior. The patient should also be examined for splenic enlargement. A Monospot/Monoscreen test can confirm the diagnosis; however, it is not reliably positive until 1-2 weeks into the illness. Treatment is largely supportive, though steroids can help hasten the resolution of symptoms. Because these patients are at risk for splenic rupture, they should be advised to avoid contact sports for at least a month. They should also be advised that if they develop sudden left shoulder pain, that this can be a sign of splenic rupture (Kehr's sign).

## c. Epiglottitis

- i. Classically this was a pediatric diagnosis caused by *H. Influenzae*; however, due to successful vaccination that is now rare and more adults are presenting with milder manifestations. Generally, infection causes swelling of the epiglottis most commonly from *H. Influenzae* type B, *S pneumoniae*, and *B. Catarrhalis*. Similar presentations can be seen by other causes of epiglottic inflammation such as toxic fumes, super-heated steam, gasoline ingestion, and angioedema. Patients typically present with 1-2 days of worsening dysphagia, odynophagia and dyspnea, especially when supine, minimal lymphadenopathy, and it rarely causes the patient be hoarse. Non-toxic patients without respiratory distress may undergo indirect laryngoscopy for diagnosis. Other diagnostic options include lateral neck films and computed tomography (CT) scan. However, in toxic patients, this remains a clinical diagnosis. These patients require selective intubation, preferably in the controlled environment of the OR with specialists prepared to perform a cricothyroidotomy if needed. Even if the decision is made not to intubate, they require intensive care unit (ICU) level observation. Antibiotics should be given as soon as possible. Reasonable treatment options include ceftriaxone, ampicillin/sulbactam, ampicillin, and chloramphenicol. Steroid administration is controversial. Potential complications include upper airway obstruction, croup (covered in the pediatric section) and Ludwig's angina (covered in the dental section).

## d. Retropharyngeal Abscess

- i. Most commonly this infection presents in children 6 months to 3 years of age. It is generally caused by mixed flora following nasopharyngitis, otitis media or penetrating trauma or after procedures such as an esophagogastroduodenoscopy (EGD). Presents with fever, neck pain/stiffness/torticollis (particularly limited in lateral rotation), dysphagia, trismus, refusal to eat, muffled voice, and/or stridor. Of note, there is typically minimal pharyngeal edema, though you can see swelling of the posterior wall of the pharynx and cervical lymph nodes.
- ii. This diagnosis cannot be made with certainty on clinical exam alone. The diagnosis can be made on soft tissue neck radiograph. With the neck held in extension, a retropharyngeal space at C2, twice the diameter of the vertebral body, is diagnostic. CT, however, is 100% sensitive and considered the gold standard. These patients should be treated with antibiotics (penicillinase-resistant penicillin



# DIDACTICS AND HANDS-ON CURRICULUM

plus flagyl, clindamycin, cefoxitin or ampicillin/sulbactam) and should undergo surgical evaluation for possible drainage. These patients require admission for monitoring. Potential complications include airway compromise from mass effect, rupture with aspiration and spread of infection causing mediastinitis, pneumonia, or sepsis.

e. Peritonsillar Abscess (PTA)

- i. PTAs are usually seen in adolescents and young adults. It is the most common abscess of the head and neck. A PTA forms when there is a collection of purulent material between the tonsillar capsule and the superior constrictor and palatopharyngeal muscles. Most commonly it is a complication of acute streptococcal tonsillitis, but can also be caused by *S. aureus* and Group A *strep*. Patients typically present with severe sore throat for 2 or more days that localizes to one side, fever, drooling, ear pain, hot potato voice, and/or trismus. Physical exam shows a tender peritonsillar mass that displaces the soft palate and uvula medially. This diagnosis can be made clinically with medial displacement of the palate/uvula and a palpable fluctuant mass. Treatment involves drainage via either needle aspiration or incision and drainage, along with a course of penicillin or clindamycin. The patient should be told to follow-up in 24 hours to ensure there is no re-accumulation. Potential complications include extension beyond the peritonsillar space with septic thrombophlebitis (Lemierre's Syndrome or post-anginal sepsis), intracranial extension, carotid hemorrhage, mediastinitis, and airway compromise.

- f. Other considerations in the differential diagnosis include tonsillitis, cancer, and croup.

2. What are the red flag or "can't miss" diagnoses?

- a. Epiglottitis, retropharyngeal abscess, peritonsillar abscess, cancer/mass, Lemierre's Syndrome or post-anginal sepsis, and mediastinitis are considered the "can't miss" diagnoses.

3. Discuss the diagnosis and treatment of this patient.

- a. This patient likely has a PTA based on the uvular deviation and should undergo incision and drainage along with antibiotic treatment as previously discussed.

**Case 2:** A 33-year-old male presents to the Fast Track area of the ED with runny nose, fever and facial congestion. He says he is in a hurry and just "needs a prescription for some antibiotics." Vital Signs: Temperature 99.7 degrees Fahrenheit, Heart Rate 94 beats/minute, Blood Pressure 132/76 mmHg, Respiratory Rate 15 per minute, Oxygen Saturation 99%

### Question Prompts:

1. What is the differential diagnosis for the patient presenting with rhinorrhea, fever and congestion?
  - a. Viral Upper Respiratory Infection (URI), Seasonal Allergies, Sinusitis (viral, bacterial or fungal), foreign body, and malignancy should all be considered in the differential.



## DIDACTICS AND HANDS-ON CURRICULUM

2. What is the pathophysiology of infectious sinusitis and what are the indications for antibiotic treatment?
  - a. The common denominator in infectious sinusitis is partial or complete obstruction of sinus drainage. This is usually precipitated by an acute viral URI. The clinical presentation includes unilateral or bilateral purulent rhinorrhea, unilateral pain or pus in nose, fever and tooth pain (sensitive but not specific), and pain that is worsened if the head is supine or dependent. The pain should be localized to the affected sinus with frontal sinusitis presenting with forehead pain, maxillary sinusitis with pain below the eyes, near the zygomatic arch, or in the teeth, and ethmoid sinusitis with pain medial to the orbit. A distinction should be made between acute rhinosinusitis and acute bacterial rhinosinusitis. The vast majority of acute rhinosinusitis cases are caused by viruses and are self-limiting. Acute rhinosinusitis is more common with symptoms for seven or more days, sinus pain or tenderness in the face or teeth, and purulent nasal secretions. The most common causative agents other than viruses are *S. Pneumoniae* (30-60%), *H. Influenzae* (20%), *Moraxella catarrhalis* (20%), and fungal (phycomycosis or mucor). Of note, chronic sinusitis is primarily caused by anaerobes. The diagnosis can generally be made clinically, but if obtained a CT is more sensitive than plain films and would be expected to show opacification, air fluid levels, and mucosal thickening > 6 mm.
  - b. Antibiotics should be reserved for patients with moderate sinusitis who do not respond to symptomatic treatment such as Decongestants, Afrin® (limited to 2-3 days) and steroid nasal sprays. Antibiotics should be given if there is no improvement for at least 10 days beyond the onset of symptoms or there is worsening symptoms after initial improvement. Acceptable antibiotic regimens include: ampicillin or amoxicillin – 90 mg/kg/day for 10 days, amoxicillin/clavulanic acid, cefuroxime, doxycycline and fluoroquinolones. Macrolides and sulfa are less effective. The most common complication of an acute infection is chronic sinusitis. Patients are also at risk for bony, central nervous system, ocular, or vascular spread. Potts Puffy Tumor is a rare complication manifested by osteomyelitis of the frontal bone that presents with doughy forehead edema. Intracranial complications include meningitis, cavernous sinus thrombosis, empyema, or abscess. Spread from the ethmoid sinus can cause periorbital cellulitis. Mastoiditis and sphenoid sinusitis are more rare manifestations of sinusitis.

### Suggested Readings:

Guthrie K. My throat hurts! Life in the Fastlane. <https://lifeinthefastlane.com/ent-equivocation-002/>. Published March 24, 2011. Accessed August 10, 2017.

Lin M. Paucis Verbis card: strep pharyngitis. Academic Life in Emergency Medicine. <https://www.aliem.com/2010/paucis-verbis-card-strep-pharyngitis/>. Published July 30, 2010. Accessed August 10, 2017.



# DIDACTICS AND HANDS-ON CURRICULUM

Nickson C. Mucormycosis. Life in the Fastlane. <https://lifeinthefastlane.com/ccc/mucormycosis/>. Revised July 29, 2015. Accessed August 10, 2017.

Reed K. What really helps a sore throat. EM:RAP.

<https://www.emrap.org/episode/december2009/whatreallyhelps>. Published December 2009. Accessed August 10, 2017.

## **Additional References:**

Hayward G, Perera R, Del Mar C, Glasziou P. Corticosteroids for pain relief in sore throat: systematic review and meta-analysis. *BMJ*. 2009;339:b2976. doi: 10.1136/bmj.b2976

Ingalsbe G. Highlights of the American Academy of Otolaryngology adult sinusitis guidelines. ACEP Now. <http://www.acepnow.com/em-summary-american-academy-otolaryngology-adult-sinusitis-guideline/>. Published June 8, 2016. Accessed September 19, 2017.

Mclsaac WJ, Kellner JD, Aufricht P, Vanjaka A, Low DE. Empirical validation of guidelines for the management of pharyngitis in children and adults. *JAMA*. 2004;291(31):1587-1595. doi: 10.1001/jama.291.13.1587



## Appendix E: Pediatric Airway Foreign Bodies and Upper Airway Emergencies

### Objectives

1. Review acute airway obstruction etiologies, diagnosis and treatment in pediatric patients, including airway management.
2. Discuss differential diagnosis and treatment of airway foreign bodies in the pediatric patient.
3. Review and recite etiologies of HEENT emergencies in pediatric patients.

### Case Studies

**Case 1:** A 3-year-old male arrives via emergency medical services (EMS) with concern for respiratory distress. His mother and father state he has had a productive cough and fever for the past several days. Tonight, he refuses to lay down to go to sleep and seems to prefer to lean forward. Mom states that she has not vaccinated the child because she is afraid of the autism risk. He is maintaining his saturations, but looks very focused on sitting up despite being exhausted. You get a neck x-ray that is read by your adult radiologist as having a “thumb print sign.” Vital Signs: Temperature 101 degrees Fahrenheit, Heart Rate 136 beats/minute, Blood Pressure 100/60 mmHg, Respiratory Rate 30 per minute, Oxygen Saturation 96%.

### Question Prompts:

1. What is your most immediate concern for this child? What infection would you consider and why? What is the classic clinical presentation for this pathology?
  - a. The most immediate concern is loss of the airway secondary to edema. The most concerning infection is epiglottitis, most frequently caused by *Haemophilus influenzae*. However, since the introduction of the *H. influenzae* vaccine, *Streptococcus Pneumoniae* and Group A *Streptococcus* have been implicated as well.
  - b. A child with epiglottitis typically has a toxic appearance. Classically, he or she will present with the inability to tolerate secretions and drooling or spitting up secretions. The child may have inspiratory stridor and a muffled voice quality. Retractions may also be noted. Patients classically assume the “tripod” position: leaning forward with their arms extended to support them, or “sniffing” position: neck forward, head upward, and their mouth open in order to maintain their airway. Altered mental status, mottled skin, and cyanosis are signs that airway obstruction and circulatory collapse are imminent.
2. What procedure needs to be done for this child prior to transport? By whom, and under what circumstances, should this procedure be done? What special considerations need to be addressed considering this patient’s size and age?



# DIDACTICS AND HANDS-ON CURRICULUM

- a. Securing the airway should be done immediately upon recognition of the disease. If the patient tolerates it, he should be immediately placed on supplemental oxygen while a definitive airway is prepared. Anesthesia or otolaryngology should be consulted for the intubation; the most experienced person available should do the intubation. The team should be prepared to perform a surgical airway should the intubation fail. Tracheostomy is the preferred surgical airway as the cricoid cartilage is just millimeters high at this age. The preferred site for intubation is in the operating room (OR). Parents are encouraged to accompany the child to the OR to help keep the child calm
  - b. From the OR, the patient should be admitted to the ICU with mechanical ventilation until there is a cuff leak around the endotracheal tube. Cultures should be taken from the epiglottis as well as peripheral blood cultures. Empiric antibiotic therapy is generally a third-generation cephalosporin.
3. How would your management change if the child had been vaccinated? What other processes would be on your differential?
    - a. Other pathogens could be considered to be the cause of epiglottitis, see above. Other potential causes of his presentation could include bacterial tracheitis, foreign body, peritonsillar or retropharyngeal abscess, diphtheria or uvulitis.

**Case 2:** A 6-year-old previously healthy African American girl presents to the emergency department with unilateral foul-smelling rhinorrhea and swelling of the left orbit over the last several days. Her mother says that she noticed the child is missing a hair bead and the daughter will not tell her where it went. The child is noted to have foul smelling, purulent drainage coming from the left nostril. Vital Signs: Temperature 99.3 degrees Fahrenheit, Heart Rate 98 beats/minute, Blood Pressure 110/76 mmHg, Respiratory Rate 16 per minute, Oxygen Saturation 99%.

## Question Prompts:

1. What is the next step in the treatment of this child?
  - a. Visualization of the foreign body (FB) with attempted removal in the emergency department is the next step. Alligator forceps, curette, oto-rhino foreign body remover (Katz extractor), irrigation, or positive pressure air flow through the mouth while occluding the unaffected nostril via bag valve mask, or mouth to mouth from a parent (“mother’s kiss”) are possibilities. A smooth round FB that occludes an entire orifice is not likely to be removed with curette or forceps and may benefit from suction or “mother’s kiss.” Removal of nasal or otic FBs should be attempted in ED only if there is a reasonable expectation for success because repeated, failed attempts result in swelling, trauma, and possibly repositioning the object into a less favorable location. The child needs to be restrained adequately or sedated to optimize the chance for success. Foreign bodies that are unable to be removed should be referred to otolaryngology clinic. Antibiotics are generally prescribed if the object is not able to be removed.
2. How else do these patients present to the emergency department?



# DIDACTICS AND HANDS-ON CURRICULUM

- a. The presentation can be quite variable. Possible presentations include an asymptomatic history of foreign body self-insertion, recurrent epistaxis, foul odor, or pain in ear or nose, or impairment in hearing or olfaction. Findings vary with duration of FB impaction, size of FB, and characteristics of FB. In general, the number of symptoms increases with the size of the FB and the amount of time it has been inserted. Common FBs include toys, food, paper, beads, and insects.
3. How would your management change if this patient had inserted a button battery?
  - a. Children can easily insert small button batteries from electronic devices (eg, calculators, handheld video games, or watches) into their nostrils. Button batteries may release chemicals and voltage that may lead to alkaline chemical burns, necrosis, or septal–tympanic perforation within minutes to hours of insertion. Therefore, batteries should be removed as soon as possible, and these patients are not candidates for outpatient follow up if the FB is unable to be removed by the emergency physician. Rather, these patients require emergent evaluation by otolaryngology.

**Case 3:** A 2-year-old Caucasian male was found down on the ground. He was blue in face and the father says he swallowed a super ball. His father tried to pull it out with a pair of pliers; however, now the child is bleeding. Vital Signs: Temperature 98.3 degrees Fahrenheit, Heart Rate 160 beats/minute, Blood Pressure 70/40 mmHg, Respiratory Rate 0 per minute, Oxygen Saturation 75%

## Question Prompts:

1. What do you do? What do you need to know?
  - a. What was activity prior to obstruction? Was there a preceding illness? Is there any past medical history? What was the time course? What is the child's vaccination status (tetanus)? This helps to understand if this is an obstruction of normal anatomy or whether there are anatomical complications worsening the obstruction. It also helps you get a sense of what else could be causing the symptoms if the history of FB or choking is presumed rather than witnessed.
  - b. Pediatric airway FB
    - i. If patient is audibly coughing or otherwise moving air, they should be left to clear the obstruction on their own, but with equipment and personnel ready to intervene if the obstruction becomes complete.
    - ii. If there is complete obstruction with no movement of air or a loss of respiratory effort, the child requires emergent intervention.
      1. Avoid blind mouth sweeps as this can push FB deeper into the airway.
      2. If the patient is younger than 1-year-old give five back blows followed by five chest thrusts.
      3. If patient is older than 1-year-old give five abdominal thrusts (Heimlich maneuver).
      4. After each round of combined back blows and chest thrusts or five abdominal thrusts, assess for clearance of the FB.



# DIDACTICS AND HANDS-ON CURRICULUM

5. If after one minute, there is no evidence of clearance, perform a direct laryngoscopy and attempt to remove any FB under direct visualization.
6. If you are unable to remove the FB, you must then consider the location of the FB. If the FB is below the vocal cords the patient can be intubated with the intent of pushing the FB into one of the main bronchi, allowing for oxygenation and ventilation via the other main bronchus.
7. If the FB is located above the vocal cords, a cricothyrotomy should be performed. Patients under 12 years of age should undergo a needle cricothyrotomy, while those over 12 should undergo a surgical cricothyrotomy.

## Suggested Readings:

Caretta-Weyer H, Hess J. Pediatric approach to croup. CDEM Curriculum. <http://cdemcurriculum.com/pediatric-approach-to-croup/>. Accessed August 10, 2017.

Claudius I. Pediatric pearls: pediatric airway. EM:RAP. <https://www.emrap.org/episode/december2012/pediatricpearls>. Published December 2012. Accessed August 10, 2017.

Cox JM. Pediatric Upper respiratory infection. CDEM Curriculum. <https://cdemcurriculum.com/pediatric-upper-respiratory-infection/>. Accessed August 10, 2017.

Hsiao J, Pacheco-Fowler V. Videos in clinical medicine. Cricothyroidotomy. *N Engl J Med*. 2008;358(22):e25. doi: 10.1056/NEJMvcm0706755

## Additional References:

Adil E, Adil A, Shah R. Epiglottitis. *Clin Pediatr Emerg Med*. 2015;16(3):149-153. doi: 10.1016/j.cpem.2015.07.005

Bernius M, Perlin D. Pediatric ear, nose, and throat emergencies. *Pediatr Clin North Am*. 2006;53(2):195-214. doi: 10.1016/j.pcl.2005.10.002

Cetinkaya EA, Arslan İB, Cukurova İ. Nasal foreign bodies in children: types, locations, complications and removal. *Int J Pediatr Otorhinolaryngol*. 2015;79(11):1881-1885. doi: 10.1016/j.ijporl.2015.08.036

Ruiz, FE. Airway foreign bodies in children. In: Hoppin AG, ed. *UpToDate*. Waltham, MA: UpToDate Inc. <https://www.uptodate.com/contents/airway-foreign-bodies-in-children>. Updated May 31, 2017. Accessed September 18, 2017.

Salih AM, Alfaki M, Alam-Elhuda DM. Airway foreign bodies: a critical review for a common pediatric emergency. *World J Emerg Med*. 2016;7(1):5-12. doi: 10.5847/wjem.j.1920-8642.2016.01.001

King, et al. Novel Emergency Medicine Curriculum Utilizing Self-Directed Learning and the Flipped Classroom Method: Head, Eyes, Ears, Nose and Throat Emergencies Small Group Module. *JETem* 2017. 2(4):C1-46. <https://doi.org/10.21980/J8PW5N>





# DIDACTICS AND HANDS-ON CURRICULUM

Viaznikova T. Adult epiglottitis: not just a hot potato. CanadiEM. <https://canadiem.org/adult-epiglottitis-just-hot-potato/>. Published July 21, 2014. Accessed August 10, 2017.

Woods CR. Epiglottitis (supraglottitis): clinical features and diagnosis. In: Wiley JF II, ed. *UpToDate*. Waltham, MA: UpToDate Inc. <https://www.uptodate.com/contents/epiglottitis-supraglottitis-clinical-features-and-diagnosis>. Updated May 3, 2017. Accessed August 10, 2017.

King, et al. Novel Emergency Medicine Curriculum Utilizing Self-Directed Learning and the Flipped Classroom Method: Head, Eyes, Ears, Nose and Throat Emergencies Small Group Module. JETem 2017. 2(4):C1-46. <https://doi.org/10.21980/J8PW5N>





## Appendix F: Nasal Complaints

### Objectives

1. Discuss common causes of epistaxis.
2. Describe first line interventions for management of epistaxis.
3. Describe an approach to management of complicated epistaxis.
4. Discuss evaluation and management of nasal trauma.

### Case Studies

**Case 1:** A 59-year-old male presents to the emergency department with right-sided epistaxis that has continued for 3 hours. He estimates he has lost about 1/2 cup of blood. He has a history of hypertension and coronary artery disease. His medications include metoprolol and a daily baby aspirin. Vital Signs: Temperature 98.5 degrees Fahrenheit, Heart Rate 74 beats/minute, Blood Pressure 156/84 mmHg, Respiratory Rate 16 per minute, Oxygen Saturation 97%.

### Question Prompts:

1. What is the pathophysiology of epistaxis?
  - a. The two major categories of epistaxis are anterior and posterior bleeds. Anterior bleeds are typically the result of trauma to Kiesselbach's plexus, located on the anterior and inferior septum. This accounts for 90% of all nosebleeds. Specific etiologies include digital trauma (epistaxis digitorum), iatrogenic coagulopathy, pathological coagulopathy, environmental low humidity, and cocaine use. Posterior bleeds are commonly the result of a rupture of the sphenopalatine artery. This may be related to hypertension, atherosclerosis, coagulopathy, or neoplasm. You should suspect a posterior bleed if you are unable to identify a source, the patient is bleeding from both nares, or there is bleeding down the posterior oropharynx despite pressure or packing.
2. What is your treatment algorithm for epistaxis?
  - a. Conduct a primary survey and assess the airway.
  - b. Assemble all necessary equipment and get good lighting.
  - c. Suction clots or have patient blow nose.
  - d. Start an intravenous line (IV) and get labs if the patient has a coagulopathy or you are concerned about the platelet count or significant blood loss.
  - e. Consider the use of a topical vasoconstrictor/anesthetic on a pledget (cocaine or neosynephrine) or oxymetazoline nasal spray.
  - f. For anterior nosebleeds
    - Pinch the nose at the bilateral ala for 10 minutes



# DIDACTICS AND HANDS-ON CURRICULUM

- If you are able to identify bleeding site, consider cautery (contraindicated with a history of coagulopathy) and/or silver nitrate (use care not to perforate the septum).
  - If the patient has continued bleeding after three attempts at above, consider nasal packing with a re-check in 24 hours. In a study comparing FloSeal™ - vs. nasal packing, FloSeal™ was found to be more effective at stopping nosebleeds (re-bleeding rate at 1 week, 14%, vs. 40% for the other therapies overall). Patients also reported greater satisfaction and less discomfort with FloSeal™ than with the other forms of packing. Other packing options include balloon products such as Rapid Rhino™ or a nasal tampon such as Merocel™. Antibiotics should be prescribed for all anterior packing if it will remain longer than 24 hours. You can also consider coating packing material with antibiotic ointment prior to placing.
  - Patients who receive packing should have urgent Otolaryngology (ENT) follow up.
- g. For posterior nosebleeds
- Attempt posterior packing.
  - Rosen's recommends analgesia and admission for any patient with posterior packing, as they have an increased risk of rebleeding as well as bradydysrthmias. If a posterior balloon device is placed and the patient has good follow up, some clinicians may consider outpatient management.
  - All posterior nasal packs should be placed on antibiotics.
3. What are the potential complications of epistaxis and the above treatments?
- a. The most common complication is a re-bleed. Other considerations include anemia, airway compromise, sinusitis, toxic shock syndrome, hypoventilation, hypoxia, and necrosis of the nasal tissue.

**Case 2:** A 16-year-old female is hit in the face with a football while her brothers are playing catch. She presents to the ED with a swollen nose and minimal epistaxis. She is demanding to see Plastic Surgery for a nose job. Vital Signs: Temperature 98.3 degrees Fahrenheit, Heart Rate 84 beats/minute, Blood Pressure 114/74 mmHg, Respiratory Rate 14 per minute, Oxygen Saturation 98%.

## Question Prompts:

1. How would you approach the assessment of this patient's injury?
  - a. As with all emergency department assessments, this patient's assessment should begin with an evaluation of the airway, breathing and circulation (ABCs). It is also important to assess for more dangerous traumatic injuries. In this case the history and physical exam should focus on determining whether the patient requires advanced intra-cranial and cervical imaging. The goals of assessing a nasal bone fracture include making the diagnosis, controlling the bleeding, and assessing for complications of the fracture. The diagnosis is a clinical one, but X-rays can be confirmatory. The clinical presentation includes crepitus, edema, tenderness, hypermobility, and deformity. Possible complications of nasal bone fractures include septal hematoma, ethmoid and cribriform plate injury with cerebrospinal fluid (CSF) leak, canthal injury, and other fractures.



# DIDACTICS AND HANDS-ON CURRICULUM

2. How would you treat this patient's nasal fracture?
  - a. Immediate reduction is only recommended with gross deformity and mild edema. Otherwise treatment is supportive care with non-steroidal anti-inflammatory agents, ice, and ENT referral for evaluation when the swelling subsides, typically in 5-7 days.
3. Why is it important to identify a septal hematoma and how would you treat it in the ED?
  - a. A septal hematoma has the potential to impede blood flow to the cartilage of the nasal septum by virtue of the pressure it places on the tissue. Potential complications of untreated hematomas include abscess formation, necrosis of the cartilage leading to a saddle-back deformity, and perforation of the septum. If a large purple grape-like swelling over the septum is seen, it should be treated in the ED with incision and drainage. Consider placing a penrose drain or applying a pressure pack if bleeding re-accumulates. These patients should be given an anti-staphylococcal antibiotic and be referred to ENT.

## Suggested Readings:

Gallegos M. Epistaxis management in the emergency department: a helpful mnemonic. *Academic Life in Emergency Medicine*. <https://www.aliem.com/2017/02/epistaxis-management-emergency-department-mnemonic/>. Published February 15, 2017. Accessed August 10, 2017.

Grock A. AIR Series: HEENT module 2014. *Academic Life in Emergency Medicine*. <https://www.aliem.com/2014/09/air-series-heent-module-2014/>. Published September 1, 2014. Accessed August 10, 2017.

Helbert M, Swadron S. C3 epistaxis: intro and anatomy. *EM:RAP*. <https://www.emrap.org/episode/c3epistaxis/introandanatomy>. Published May 2017. Accessed August 10, 2017.

Mason J. Epistaxis management. *EM:RAP*. <https://www.emrap.org/episode/epistaxis/epistaxis>. Published May 2017. Accessed August 10, 2017.

Schlosser RJ. Clinical practice. Epistaxis. *N Engl J Med*. 2009;360(8):784-789. doi: 10.1056/NEJMcp0807078

## Additional References:

Barnes ML, Spielmann PM, White PS. Epistaxis: a contemporary evidence based approach. *Otolaryngol Clin North Am*. 2012;45(5):1005-1017. doi: 10.1016/j.otc.2012.06.018

Béquignon E, Teissier N, Gauthier A, Brugel L, De Kermadec H, Coste A, et al. Emergency department care of childhood epistaxis. *Emerg Med J*. 2017;34(8):543-548. doi: 10.1136/emered-2015-205528

Gilman C. Focus on: treatment of epistaxis. American College of Emergency Physicians. <https://www.acep.org/Clinical-Practice-Management/Focus-On--Treatment-of-Epistaxis/>. Published June 2009. Accessed August 10, 2017

King, et al. Novel Emergency Medicine Curriculum Utilizing Self-Directed Learning and the Flipped Classroom Method: Head, Eyes, Ears, Nose and Throat Emergencies Small Group Module. *JETem* 2017. 2(4):C1-46. <https://doi.org/10.21980/J8PW5N>





# DIDACTICS AND HANDS-ON CURRICULUM

Kasperek ZA, Pollock GF. Epistaxis: An overview. *Emerg Med Clin North Am.* 2013;31(2):443-454. doi: 10.1016/j.emc.2013.01.008

Mathiasen RA, Cruz RM. Prospective, randomized, controlled clinical trial of a novel matrix hemostatic sealant in patients with acute anterior epistaxis. *Laryngoscope.* 2005;115(5):899-902. doi: 10.1097/01.mlg.0000160528.50017.3c

King, et al. Novel Emergency Medicine Curriculum Utilizing Self-Directed Learning and the Flipped Classroom Method: Head, Eyes, Ears, Nose and Throat Emergencies Small Group Module. *JETem* 2017. 2(4):C1-46. <https://doi.org/10.21980/J8PW5N>





## Appendix G: Dental Emergencies

### Objectives

1. Describe traumatic dental injuries encountered in the emergency department (ED), including fracture classification, temporary repair, and when to call oral and maxillofacial surgery (OMFS)/ Dental.
2. Describe conventions for teeth numbering.
3. Describe the most common types of dental infections and appropriate ED management.

### Case Studies

**Case 1:** A 59-year-old female presented to an emergency dental clinic with dental pain and minor left buccal and mandibular swelling. She was found to have fractured tooth 18. She was given clindamycin and told to return in several days for extraction. Overnight, she was febrile to 102° F and the swelling worsened to include her tongue. She presents to your Emergency Department the next day. On exam, you note swelling and induration of the bilateral submandibular spaces and difficulty speaking. Vital Signs: Temperature 101.3 degrees Fahrenheit, Heart Rate 114 beats/minute, Blood Pressure 110/76 mmHg, Respiratory Rate 16 per minute, Oxygen Saturation 97%

### Question Prompts:

1. What is the pathophysiology behind this patient's condition?
  - a. Ludwig's angina is a rapidly spreading cellulitis of the floor of the mouth. It is typically a complication of a mixed flora infection of the 2nd and 3rd mandibular molars, though it can result after any trauma to the floor of the mouth. It most commonly affects young adults. The clinical presentation includes pain, drooling, difficulty talking or swallowing (33% of cases result in airway obstruction), dysphonia with brawny edema of the floor of the mouth, protrusion of a swollen, tender tongue, and bilateral submandibular swelling.
2. What are the next steps in the management of this patient?
  - a. The primary concern is maintenance of the patient's airway. Maintain the patient in a seated position and place airway equipment at the bedside. Similar to epiglottitis in children, these patients can have very difficult airways and if at all possible should be intubated in the controlled setting of the operating room (OR) with specialists available to perform an emergent cricothyroidotomy. The patient should be given parenteral antibiotics, such as penicillin plus metronidazole, cefoxitin, ampicillin-sulbactam, or clindamycin. Otolaryngology (ENT) should be consulted immediately and arrangements made for transfer to the OR for surgical decompression and possible airway intervention. The diagnosis is a clinical one, though stable patients may undergo computed tomography (CT) scan to fully characterize the anatomy and aid in operative planning. These patients



# DIDACTICS AND HANDS-ON CURRICULUM

typically require intensive care unit (ICU) level care. Other than airway obstruction, the major complication from Ludwig's angina is a descending necrotizing mediastinitis.

**Case 2:** A 42-year-old human immunodeficiency virus (HIV) positive female presents to the emergency department with a 5-week history of swollen, painful gums. She has had difficulty eating and chewing, along with aches and general malaise. The patient is an everyday smoker and is not taking any medications. Physical examination reveals inflamed gingiva, ulceration, and soft tissue necrosis along with mandibular lymphadenopathy. Vital Signs: Temperature 98.9 degrees Fahrenheit, Heart Rate 94 beats/minute, Blood Pressure 140/76 mmHg, Respiratory Rate 14 per minute, Oxygen Saturation 97%

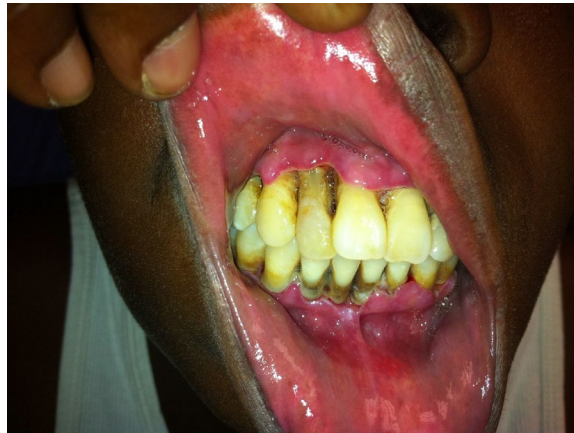

Image from <http://jetem.org/anug/>.

## Question Prompts:

1. What is the most likely diagnosis?
  - a. This patient likely has acute necrotizing ulcerative gingivitis (ANUG). This infection is typically caused by overgrowth of normally present bacteria such as fusobacteria and spirochetes. HIV infection, previous ANUG, poor oral hygiene and stress are all predisposing risk factors. Symptoms typically include pain, metallic taste, foul breath, gray pseudomembrane, fever, malaise, and regional lymphadenopathy.
2. What treatment would you prescribe for this patient?
  - a. Treatment generally includes chlorhexidine oral rinses, oral antibiotics (most commonly metronidazole), analgesics, and referral to a dentist for definitive care. Of note the patient should be told that this is not a communicable infection.

**Case 3:** A 25-year-old male presents with acute onset of pain to his lower right teeth. He denies any injury. He is unsure exactly which tooth is hurting. The pain is worse with chewing. He denies fevers. He had a dentist as a child, but hasn't been in years. He is a smoker and infrequently brushes his teeth. On exam, you see a dental caries on tooth 32 but no surrounding swelling or exposed pulp. Vital Signs: Temperature 97.9 degrees Fahrenheit, Heart Rate 75 beats/minute, Blood Pressure 120/82 mmHg, Respiratory Rate 15 per minute, Oxygen Saturation 98%



# DIDACTICS AND HANDS-ON CURRICULUM

## Question Prompts:

1. How would you manage this patient?
  - a. Dental caries is a common dental reason for presentation to the emergency department. Poor hygiene allows normal oral flora to invade and damage the enamel of the tooth. Typically, they cause dull continuous pain worse with any stimulus. Tenderness to percussion or changes in temperature may indicate a pulpitis. The ED management includes an assessment for abscess, analgesia with oral medications, topical lidocaine, dental, or regional nerve blocks, and referral to a dentist for definitive management.
2. How would your management change if there was accompanying facial swelling?
  - a. Facial swelling generally indicates the presence of a periapical abscess. This general occurs after there is full necrosis of the pulp of the affected tooth. This patient requires antibiotics (typically penicillin, amoxicillin, or clindamycin) and urgent referral to a dentist for tooth extraction vs root canal. Untreated abscesses can cause Ludwig's angina, spread to adjacent tissues such as the buccal space, sinuses, bone, and even intracranial invasion through the cavernous sinus. If a pus collection is visible along the gum line, incision and drainage can be attempted in the emergency department. This may definitively treat a periodontal abscess caused by trapped food.
3. What would the likely diagnosis be if the patient was post-operative day 3 from a wisdom tooth extraction and exam revealed a hole at the extraction site?
  - a. This patient likely has an alveolar osteitis, commonly called "dry socket," caused by premature loss of the healing clot with resultant localized inflammation. This typically occurs 3-4 days after the extraction. Although painful, this generally isn't dangerous. The patient should be given analgesics, the sockets should be gently irrigated, and packed with iodoform gauze dampened with eugenol. The patient should follow up with their surgeon within 24 hours of having the packing placed.
4. How would you manage this patient if he had not yet undergone extraction of his 3rd molar and your exam revealed a flap of tissue over a partially erupted 3rd molar?
  - a. This patient likely has pericoronitis or inflammation of the gingival flap over an erupting tooth. These patient's typically respond well to pain control and a prescribed ongoing treatment of warm saline irrigation. Consider peridex rinses. Fever is an indication for antibiotics, but otherwise, they should not require oral antibiotics. If there is a clear abscess, incision and drainage can be attempted in the ED.

**Case 4:** An 7-year-old patient presents to the emergency department after running into the kitchen counter at home. The patient denies loss of consciousness, vomiting, weakness, or numbness. His only complaint is that one of his front teeth has been knocked out. The bleeding is controlled. His parents put his tooth in milk and brought it with them to the ED. Vital Signs: Temperature 98.9 degrees Fahrenheit, Heart Rate 105 beats/minute, Blood Pressure 110/74 mmHg, Respiratory Rate 15 per minute, Oxygen Saturation 98%



# DIDACTICS AND HANDS-ON CURRICULUM

## Question Prompts:

1. How would you manage this patient?
  - a. If a primary tooth is avulsed it should never be replanted as this can ankylose and block eruption of the permanent tooth. If, however, this is a permanent tooth, it should be replanted as soon as possible. The chances of successful replantation decrease 1% for every minute the tooth is out of the socket. Hank's balanced saline solution, saline, and milk are the preferred transport media in that order. Alternatively, if the child is old enough that he or she won't swallow it, it can be transported intra-orally tucked in the cheek. Once re-implanted, the patient should be placed on a soft diet, tetanus updated as needed, and placed on antibiotics (doxycycline if over 12 years of age, penicillin or amoxicillin if younger). Consider splinting or other stabilization if the tooth remains significantly loose. Regardless of whether the tooth is replanted, these patients require urgent referral to a dentist to monitor healing.
2. What if the patient had chipped his tooth rather than completely knocking it out of his mouth?
  - a. The Ellis classification is used to describe fractures of the teeth and they dictate the proper treatment. Of note the Ellis classification system is not frequently used by dentists or OMFS. It is therefore best to describe the fracture, mainly describing which structures are involved when discussed with these consultants.
    - i. Class I is a fracture of the enamel and is treated by smoothing the edge of the tooth.
    - ii. Class II is a fracture of the enamel and dentin and is treated by placing a calcium hydroxide covering.
    - iii. Class III is a fracture of the enamel, dentin, and pulp and is treated by a pulpotomy (or pulpectomy) via an immediate dental referral.
3. What if the patient was complaining only of a loose tooth?
  - a. The key to management of subluxed or loose teeth is whether the patient's bite is at its baseline. If their bite feels normal, they can be given pain control, placed on a soft diet and instructed to follow up with a dentist. If the bite does not feel normal, the tooth should be gently manipulated into its original position before the patient is discharged.
4. What if on exam, several upper teeth are felt to move together as a single unit?
  - a. This patient likely has an alveolar fracture. They should undergo imaging to fully characterize the fracture and ensure they do not have a LeFort I fracture causing a floating palate. These fractures need to be stabilized for six weeks.
5. What if the patient complains of the tooth being pushed up into his gum?
  - a. If this is a permanent tooth, the patient will require urgent surgical reduction as it will not re-erupt on its own. For primary teeth, imaging is required to see if the apex impacts the follicle of the permanent tooth. If this is the case, then surgical extraction is recommended. Otherwise however, the primary tooth should erupt without intervention. Complete impaction of the tooth can be mistaken for an avulsed tooth, so consider imaging in cases where the missing tooth was never found to ensure it has not been impacted.
6. When communicating with a dental consultant what adjectives and labeling system would you use to describe any physical exam findings?
  - a. Labial or buccal = outside



# DIDACTICS AND HANDS-ON CURRICULUM

- b. Oral, palatal, or lingual = faces the tongue
- c. Occlusal surface = biting area
- d. Apical = toward tooth
- e. Coronal = toward crown
- f. Numbering Primary teeth
  - i. Top, right to left = A - J
  - ii. Bottom, left to right = K - T
- g. Numbering Permanent teeth
  - i. Top, right to left = 1-16
  - ii. Bottom, left to right = 17-32

## Suggested Readings:

Beaudreau RW. Oral and dental emergencies. In: Tintinalli JE, Stapczynski J, Ma O, Cline DM, Cydulka RK, Meckler GD, eds. *Tintinalli's Emergency Medicine: A Comprehensive Study Guide*. 8<sup>th</sup> ed. New York, NY: McGraw-Hill; 2011:1598-1613.

Kman N, Kumar VP. Acute necrotizing ulcerative Gingivitis (ANUG). *JETem*. 2017;2(2):V1-2. doi: 10.21980/J8S88H

Kman NE. Dental emergencies. In: Sherman SC, Weber JM, Schindlbeck MA, Rahul GP, eds. *Clinical Emergency Medicine*. 1<sup>st</sup> ed. New York, NY: McGraw-Hill; 2014:327-332.

## Additional References:

Atout R, Todescan S. Managing patients with necrotizing ulcerative gingivitis. *J Can Dent Assoc*. 2013;79:d46.

Douglass AB, Douglass JM. Common dental emergencies. *Am Fam Physician*. 2003;67(3):511-517.

Folayan MO. The epidemiology, etiology, and pathophysiology of acute necrotizing ulcerative gingivitis associated with malnutrition. *J Contemp Dent Pract*. 2004;5(3):28-41.

Hu J, Kent P, Lennon JM, Logan LK. Acute necrotizing ulcerative gingivitis in an immunocompromised young adult. *BMJ Case Rep*. 2015;pii:bcr2015211092. doi: 10.1136/bcr-2015-211092

Nguyen, DH. Martin, JT. Common dental infections in the primary care setting. *Am Fam Physician*. 2008;77(6):797-802.