

Management of Wolff-Parkinson-White Tachyarrhythmia Presenting as Syncope with Seizure-like Activity

Samuel Kaplan, BS* and Lindsey Spiegelman, MD*

*University of California, Irvine, Department of Emergency Medicine, Orange, CA

Correspondence should be addressed to Samuel Kaplan at kaplansr@uci.edu

Submitted: August 15, 2017; Accepted: September 13, 2017; Electronically Published: October 15, 2017; <https://doi.org/10.21980/J8534P>

Copyright: © 2017 Kaplan, et al. This is an open access article distributed in accordance with the terms of the Creative Commons Attribution (CC BY 4.0) License. See: <http://creativecommons.org/licenses/by/4.0/>

ABSTRACT:

Audience: Emergency medicine residents and medical students.

Introduction: An estimated 3% of the United States population suffers from recurrent convulsive episodes that are most often attributed to primary epileptic seizures.¹ However, recent studies have estimated about 20%-30% of such episodes are associated with occult cardiac etiology,² which carry one-year mortality rates of up to 30%.³ Cardiogenic cerebral hypoxia has been associated with a wide variety of neurologic disturbances, including dizzy spells, headache, syncope, focal motor deficit, generalized tonic-clonic seizure, confusion, dementia, and psychosis.⁴ Convulsive activity has tentatively been ascribed to the ensuing activation of the medullary reticular formation.^{5,6} This scenario is based on a patient that presented to University of California Irvine Medical Center Emergency Department in April 2017 who, following witnessed seizure-like episodes, was diagnosed with underlying Wolff-Parkinson-White (WPW) disorder.

WPW is a congenital condition involving aberrantly conductive cardiac tissue between the atria and the ventricles that provides a pathway for a reentrant tachycardia circuit and ventricular pre-excitation.⁷ Diagnosis is primarily based on the presence of a short PR interval and delta waves on electrocardiography.⁸ While definitive treatment is catheter-based radiofrequency ablation of the accessory pathway, the hallmark of acute management is vagal maneuvers and antiarrhythmic drugs in the symptomatic but hemodynamically stable patient, and synchronized cardioversion in the unstable patient.⁹ WPW is thought to affect between 0.1% and 0.3% of the population, and while the usual clinical course is benign, sudden cardiac death occurs in about 3%-4% of such patients.^{7,10} One survey found 19% of patients with WPW had a history of syncopal episodes;¹¹ however, precise prevalence surveys of WPW-associated seizure-like episodes are lacking in the current literature. This case illustrates the possibility of cardiogenic etiology underlying any convulsive or syncopal event, and thus the importance of its prompt detection and treatment.

SIMULATION

Objectives: At the end of this simulation session the learner will: 1) Recognize clinical history suggestive of cardiogenic syncope, 2) recognize clinical evidence of Wolff-Parkinson-White syndrome, 3) promptly and appropriately treat unstable WPW tachyarrhythmia.

Method: Moderate-fidelity simulation.

Topics: Seizure, arrhythmia, Wolff-Parkinson-White (WPW), simulation, cardiac electrophysiology, adult resuscitation.



USER GUIDE

List of Resources:

Abstract	38
User Guide	40
Instructor Materials	21
Operator Materials	28
Debriefing and Evaluation Pearls	30
Simulation Assessment	33

Learner Audience:

Medical students, interns, junior residents, senior residents, mid-level providers

Time Required for Implementation:

Instructor Preparation: 15-30 minutes
Time for case: 15-20 minutes
Time for debriefing: 15-30 minutes

Recommended Number of Learners per Instructor:

2-5

Topics:

Seizure, arrhythmia, Wolff-Parkinson-White (WPW), simulation, cardiac electrophysiology, adult resuscitation.

Objectives:

By the end of this simulation session, the learner will be able to:

1. Recognize clinical history suggestive of cardiogenic syncope
2. Recognize clinical evidence of Wolff-Parkinson-White (WPW) syndrome
3. Promptly and appropriately treat unstable WPW tachyarrhythmia

Linked objectives and methods:

WPW syndrome is an uncommon but dangerous etiology of syncope and must be treated promptly, especially when the patient is hemodynamically unstable. Through this simulation, learners will practice evaluating and managing an acutely ill patient with history suggestive of seizure-like episode but with an underlying cardiac arrhythmia, namely WPW. If appropriate diagnosis and treatment are delayed learners will experience a decompensating patient at risk of cardiac arrest and death.

More specifically, by running through the simulation learners should recognize historical and physical exam findings suggestive of cardiogenic syncope (objective 1), and recognize Wolff-Parkinson-White syndrome on electrocardiogram (ECG) (objective 2). When they patient goes into an unstable tachyarrhythmia they must appropriately treat it or the patient will decompensate (objective 3). The debriefing session

is allows the instructor to review any cognitive, diagnostic or management errors, problems with communication, or points of confusion.

Recommended pre-reading for instructor:

- Di Biase L, Walsh E. Epidemiology, clinical manifestations, and diagnosis of the Wolff-Parkinson-White syndrome. In: Downey BC, ed. *UpToDate*. Waltham, MA: UpToDate Inc. <https://www.uptodate.com/contents/wolff-parkinson-white-syndrome-anatomy-epidemiology-clinical-manifestations-and-diagnosis>. Updated November 2016. Accessed October 1, 2017.
- Di Biase L, Walsh E. Treatment of symptomatic arrhythmias associated with the Wolff-Parkinson-White syndrome. In: Downey BC, ed. *UpToDate*. Waltham, MA: UpToDate Inc. <https://www.uptodate.com/contents/treatment-of-symptomatic-arrhythmias-associated-with-the-wolff-parkinson-white-syndrome>. Updated September 2016. Accessed October 1, 2017.
- Page RL, Joglar JA, Caldwell MA, Calkins H, Conti JB, Deal BJ, et al. 2015 ACC/AHA/HRS guideline for the management of adult patients with supraventricular tachycardia: a report of the American College of Cardiology/American Heart Association Task Force on clinical practice guidelines and the Heart Rhythm Society. *J Am Coll Cardiol*. 2016;67(13):e27-e115. doi: 10.1016/j.jacc.2015.08.856
- Neumar RW, Shuster M, Callaway CW, Gent LM, Atkins DL, Bhanji F, et al. Part 1: executive summary: 2015 American Heart Association guidelines update for cardiopulmonary resuscitation and emergency cardiovascular care. *Circulation*. 2015;132(18 Suppl 2):S315-S167. doi: 10.1161/CIR.0000000000000252

Results and tips for successful implementation:

- This can be completed on a high- or moderate-fidelity simulation or could be incorporated as a mock oral board case. The patient, accompanied by his girlfriend, should initially present with altered mental status following seizure-like activity, which leaves a wide differential. This simulation case was partially based on an actual patient case.
- Instructors can provide more information suggestive of cardiac syncope or less depending on the level of the learner.
- This case was piloted with 14 emergency medicine residents and medical students. The more advanced learners kept their differential broad and considered a cardiogenic cause while many more junior learners anchored on the seizure and did not diagnose



USER GUIDE

cardiogenic syncope until the tachyarrhythmia occurred. Overall, the case was well received and learners noted they appreciated the reminder that cardiogenic syncope must be on the differential for patients with a chief complaint of seizure.

syndrome: results of a prospective long-term electrophysiological follow-up study. *Circulation*. 2012;125(5):661-668. doi: 10.1161/CIRCULATIONAHA.111.065722

11. Goudevenos JA, Katsouras CS, Graekas G. Ventricular pre-excitation in the general population: a study on the mode of presentation and clinical course. *Heart*. 2000;83(1):29-34. doi: 10.1136/heart.83.1.29

References/suggestions for further reading:

1. Hauser WA, Kurland LT. The epidemiology of epilepsy in Rochester, Minnesota, 1935 through 1967. *Epilepsia*. 1975;16(1):1-66.
2. Kanjwal K, Karabin B, Kanjwal Y, Grubb BP. Differentiation of convulsive syncope from epilepsy with an implantable loop recorder. *Int J Med Sci*. 2009;6(6):296-300.
3. Kapoor WN, Karpf M, Wieand S, Peterson JR, Levey GS. A prospective evaluation and follow-up of patients with syncope. *N Engl J Med*. 1983;309(4):197-204. doi: 10.1056/NEJM198307283090401
4. Schott GD, McLeod AA, Jewitt DE. Cardiac arrhythmias that masquerade as epilepsy. *Br Med J*. 1977;1(6074):1454-1457.
5. Lempert T, Bauer M, Schmidt D. Syncope: a videometric analysis of 56 episodes of transient cerebral hypoxia. *Ann Neurol*. 1994;36(2):233-237. doi: 10.1002/ana.410360217
6. Dell P, Hugelin A, Bonvallet M. Effects of hypoxia on the reticular and cortical diffuse systems. In: Gastaut H, Meyer JS, eds. *Cerebral Anoxia and the Electroencephalogram*. Springfield, IL: Charles C Thomas; 1961:46-58.
7. Cohen MI, Triedman JK, Cannon BC, Davis AM, Drago F, Janousek J, et al. PACES/HRS expert consensus statement on the management of the asymptomatic young patient with a Wolff-Parkinson-White (WPW, ventricular preexcitation) electrocardiographic pattern: developed in partnership between the Pediatric and Congenital Electrophysiology Society (PACES) and the Heart Rhythm Society (HRS). Endorsed by the governing bodies of PACES, HRS, the American College of Cardiology Foundation (ACCF), the American Heart Association (AHA), the American Academy of Pediatrics (AAP), and the Canadian Heart Rhythm Society (CHRS). *Heart Rhythm*. 2012;9(6):1006-1024. doi: 10.1016/j.hrthm.2012.03.050
8. Levis JT. ECG Diagnosis: Wolff-Parkinson-White syndrome. *Perm J*. 2010;14(2):53.
9. Page RL, Joglar JA, Caldwell MA, Calkins H, Conti JB, Deal BJ, et al. 2015 ACC/AHA/HRS guideline for the management of adult patients with supraventricular tachycardia: a report of the American College of Cardiology/American Heart Association Task Force on clinical practice guidelines and the Heart Rhythm Society. *J Am Coll Cardiol*. 2016;67(13):e27-e115. doi: 10.1016/j.jacc.2015.08.856
10. Pappone C, Vicedomini G, Manguso F, Baldi M, Pappone A, Petretta A, et al. Risk of malignant arrhythmias in initially symptomatic patients with Wolff-Parkinson-White



INSTRUCTOR MATERIALS

Case Title: Management of Wolff-Parkinson-White Tachyarrhythmia Presenting as Syncope with Seizure-like Activity

Case Description & Diagnosis (short synopsis): This scenario takes place at a tertiary care teaching hospital in the emergency department at midnight. The patient is a 27-year-old male brought in by his girlfriend via private auto from a bar following reported two episodes of seizure-like activity: chest pain followed by becoming unresponsive, and exhibiting irregular tonic-clonic jerks of his arms for two minutes. On arrival, he is somnolent, disoriented, and has a tachycardic but regular heart rhythm and no external signs of trauma. Initial work-up is notable for electrocardiogram (ECG) (#1) with WPW pattern with rate in low 100s. In the course of history-taking, exam, and work-up, participants should identify that the WPW is potentially related to his presentation. Neurology and/or cardiology consults should be called but will be delayed and unavailable during case.

Within a few minutes of arrival, the patient experiences another episode of the symptoms described by the girlfriend, reproducing an episode of chest pain followed by loss of consciousness and upper extremity tonic-clonic jerks. He is found to be in monomorphic wide-complex tachycardia on the monitor. After one minute of jerking the patient is unresponsive, has a weak and thready pulse, and is hypotensive. If benzodiazepines or anti-epileptic medications are given it does not change his clinical status. Synchronized cardioversion at 100J or greater will immediately terminate the arrhythmia while antiarrhythmics including procainamide, amiodarone, sotalol, ibutilide, or dofetilide will not take effect in time. Patient should be admitted to intensive care unit (ICU) once stable. If arrhythmia is not treated within one minute, patient enters pulseless ventricular fibrillation. At this point, participants need to perform two rounds of advanced cardiac life support (ACLS) with defibrillation to revive patient; otherwise death follows.

Equipment or Props Needed:

- High- or moderate-fidelity simulator
- Infusion pumps
- Normal Saline
- Prop medication vials and syringes
- Cardioverter
- Intubation/airway tray
- Blood pressure cuff
- Cardiac monitor



INSTRUCTOR MATERIALS

Two-lead ECG
Pulse oximeter

Confederates needed:

This simulation needs a confederate to play the girlfriend who provides the history and a nurse to assist with the management of the patient.

Stimulus Inventory:

- #1 Complete blood count (CBC)
- #2 Comprehensive metabolic panel (CMP)
- #3 Lactate
- #4 Cardiac enzymes
- #5 Urine Drug Screen
- #6 Lactate
- #7 Alcohol Level
- #8 Thyroid panel
- #9 Electrocardiogram (ECG) x 3
- #10 Computed tomography (CT) head
- #11 Chest X-ray (CXR)

Background and brief information: This scenario takes place at a tertiary care teaching hospital in the emergency department at midnight. The patient is a 27-year-old male, brought in by his girlfriend via private auto from a bar, following reported seizure-like activity. He is somnolent but arousable, so his girlfriend provides most of the history. She reports that at 11:30pm after a long night of drinking, the patient suddenly grabbed his chest, became unresponsive, and started to exhibit irregular tonic-clonic jerks of his arms for two minutes. He “came to” for a few minutes, then experienced another similar episode in the car on the way to the hospital.

Initial presentation: On arrival, patient is somnolent but arousable, reporting only a mild generalized headache without chest pain, perseverating on “what happened?” and “what’s going on?” Vital signs show mild hypertension, mild tachycardia. Exam shows somnolent, disoriented patient with tachycardic but regular heart rhythm without murmurs, and no external signs of trauma.



INSTRUCTOR MATERIALS

How the scenario unfolds: Initial work-up shows normal CBC, CMP, cardiac enzymes, urine toxicology screen, CXR, and head CT if ordered. Additional tests should include serum alcohol level 105, lactate 1.4, and ECG (#1) with WPW pattern with rate in low 100s. Bedside echocardiogram can be ordered but will be delayed and unavailable during the case. In the course of history taking, exam, and work-up, participants should identify this arrhythmia as potentially related to his presentation. Neurology and/or cardiology consults should be called but will be delayed and unavailable during case.

Within a few minutes of arrival, the patient experiences another episode of the symptoms described by the girlfriend, reproducing the symptoms that brought him in: chest pain followed by loss of consciousness and upper extremity tonic-clonic jerks. On exam, he is now hypotensive, more tachycardic, hypoxic, and dyspneic with audible rales, although spontaneous labored respirations and weak palpable pulses remain. Telemetry and ECG (#2) show increased tachycardia and regular, monomorphic, widened QRS complexes. After one minute of jerking the patient will become unresponsive. If benzodiazepines or anti-epileptic medications are given it does not change his clinical status. Vagal maneuvers cannot be performed due to obtundation, and AV nodal-blocking agents such as adenosine, beta-blockers, and calcium channel blockers will slow rate slightly but will fail to abort arrhythmia. Synchronized cardioversion at 100J or greater will immediately terminate the arrhythmia while antiarrhythmics including procainamide, amiodarone, sotalol, ibutilide, or dofetilide are not appropriate in an unstable patient. Follow-up ECG (#4) will confirm rhythm conversion. If arrhythmia is not treated within one minute, patient enters pulseless ventricular fibrillation (ECG #3). At this point, participants need to perform two rounds of ACLS with defibrillation to revive patient; otherwise death follows. If stabilized, patient should be admitted to ICU.

Critical Actions:

On initial presentation:

1. Check airway, breathing, and circulation (ABCs)
2. Pursue appropriate initial history and physical exam using girlfriend as primary historian
3. Order Head CT and ECG
4. Recognize WPW pattern on ECG
5. Call for cardiology consult

When patient has recurrence of syncope:

6. Repeat ABCs
7. Verbalize recognition of wide-complex tachycardia on telemetry or ECG



INSTRUCTOR MATERIALS

8. Perform synchronized cardioversion
9. Admit to ICU once stable

If patient enters pulseless V-fib:

10. Repeat ABCs
11. Perform 2 rounds of proper ACLS with defibrillation
12. Admit to ICU once stable



INSTRUCTOR MATERIALS

Case title: Management of Wolff-Parkinson-White Tachyarrhythmia Presenting as Syncope with Seizure-like Activity

Chief Complaint: This scenario takes place at a tertiary care teaching hospital in the emergency department at midnight. The patient is a 27-year-old male brought in by his girlfriend via private auto from a bar following reported seizure-like activity.

Vitals: Heart Rate (HR) 109 Blood Pressure (BP) 152/86 Respiratory Rate (RR) 16
Temperature (T) 99.0 Oxygen Saturation (O₂Sat) 99% on room air

General Appearance: Patient is somnolent but arousable on gurney, reporting only a mild headache without chest pain, perseverating on “what happened?” and “what’s going on?”

Primary Survey:

- **Airway:** patent, protected
- **Breathing:** spontaneous, unlabored
- **Circulation:** mild tachycardia with 2+ pulses throughout

History:

- **History of present illness:** Patient is somnolent but arousable, so his girlfriend provides most of the history. She reports that at 11:30pm after a long night of drinking, the patient suddenly grabbed his chest, became unresponsive, and started to exhibit irregular tonic-clonic jerks of his arms for two minutes. He “came to” for a few minutes, then experienced another similar episode in the car on the way to the hospital. On arrival, patient is somnolent but arousable, reporting only a mild headache without chest pain, perseverating on “what happened?” and “what’s going on?” Review of systems is otherwise negative presently.
- **Past medical history:** “hole in his heart” that was never treated; no known seizures
- **Past surgical history:** none
- **Patients medications:** none
- **Allergies:** No known drug allergies
- **Social history:** lives with girlfriend locally; sometimes binge-drinks beer (including six beers tonight at the bar), but denies tobacco or other drug-use
- **Immunizations:** up to date
- **Family history:** brother with a stroke at age 25



INSTRUCTOR MATERIALS

Secondary Survey/Physical Examination:

- **General appearance:** somnolent but arousable on gurney, no signs of trauma
- **Head, ears, eyes, nose and throat (HEENT):** no signs of trauma
- **Neck:** no jugular venous distention (JVD), 2+ pulses
- **Heart:** tachycardic but regular rhythm, normal S1-S2, no murmurs, rubs, or gallops
- **Lungs:** no respiratory distress; clear to auscultation bilaterally
- **Abdominal/GI:** within normal limits
- **Extremities:** within normal limits
- **Back:** within normal limits
- **Neuro:** somnolent but arousable, moves all extremities on command, otherwise within normal limits
- **Skin:** no rashes, jaundice, or external signs of trauma
- **Lymph:** within normal limits
- **Psych:** anxious but otherwise appropriate to circumstances



INSTRUCTOR MATERIALS

Results:

Complete blood count (CBC)

White blood count (WBC)	7.6 x1000/mm ³ (H)
Hemoglobin (Hgb)	13.3g/dL
Hematocrit (HCT)	40.4%
Platelet (Plt)	226 x1000/mm ³

Complete metabolic panel (CMP)

Sodium	142 mEq/L
Chloride	108 mEq/L
Potassium	3.6 mEq/L
Bicarbonate (HCO ₃)	24 mEq/L (L)
Blood Urea Nitrogen (BUN)	11 mg/dL (H)
Creatine (Cr)	0.6 mg/dL (H)
Glucose	102 mg/dL
Calcium	8.8 mg/dL
Total bilirubin	0.2 mg/dL
Albumin	4.2 g/dL
Alkaline Phosphate	100 U/L
Total Protein	7.9 g/dL
Aspartate Aminotransferase (AST)	17 u/L
Alanine Aminotransferase (ALT)	16 u/L
Magnesium	2.3 mg/dL
Phosphorus	1.6 mg/dL

Lactate 1.4 mEq/L

Cardiac Enzymes

Troponin-I	<0.03 ng/mL
Creatine kinase MB (CKMB)	<0.3 ng/mL

Thyroid Panel

Thyroid stimulating hormone (TSH)	2.5 mIU/L
Free T4	0.9 ng/dL
Free T3	0.3 ng/dL
Alcohol Level	105 mg/dL



INSTRUCTOR MATERIALS

Urine Toxicology Screen

Opiates	negative
Cocaine	negative
Marijuana	negative
PCP	negative
Amphetamines	negative
Benzodiazepines	negative
Barbiturates	negative
Methadone	negative
Propoxyphene	negative
MDMA	negative

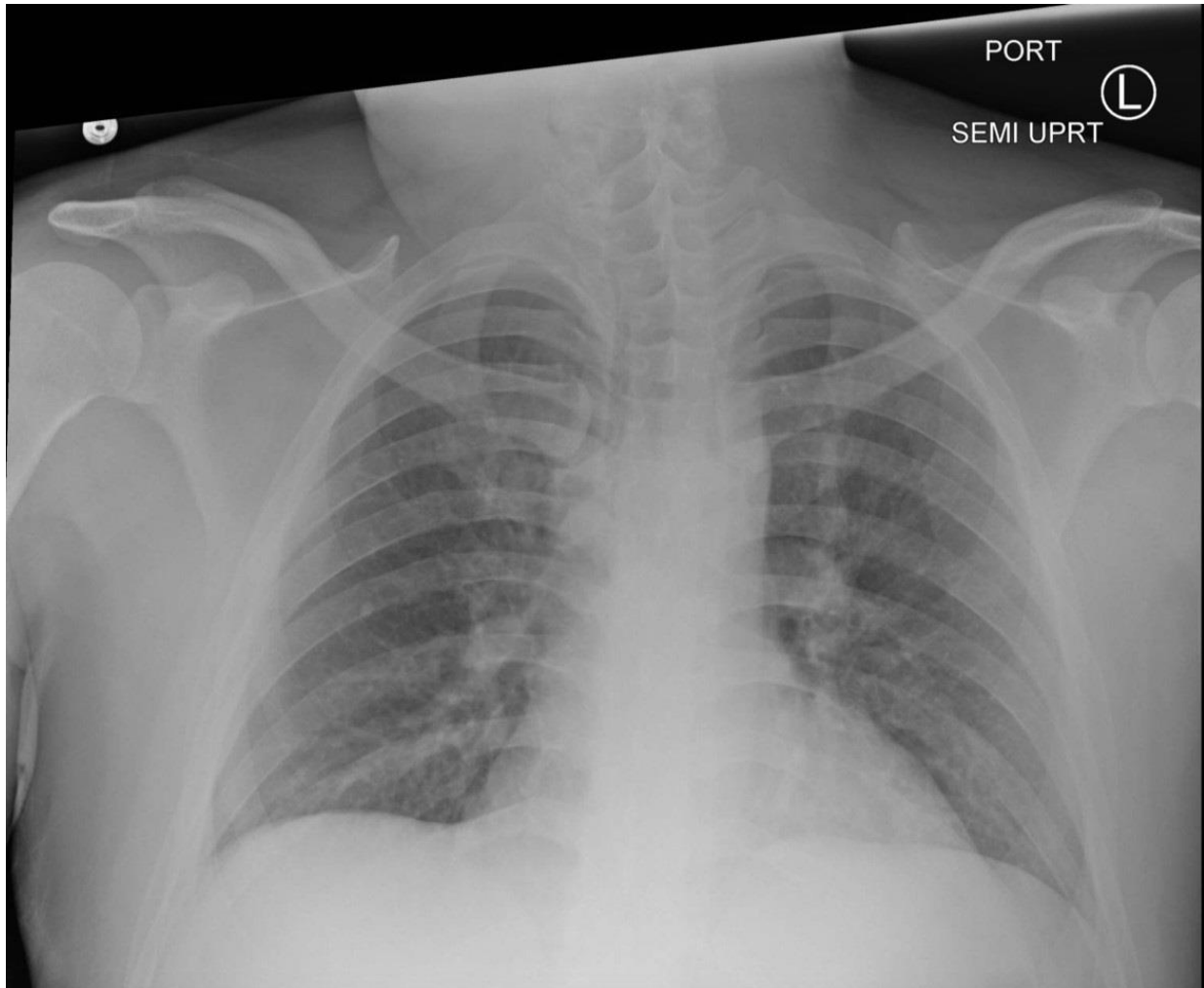
Urinalysis

Color	yellow
Clarity	clear
Spec gravity	1.012
pH	5
Protein	negative
Glucose	negative
Ketones	negative
Bilirubin	negative
Hemoglobin	negative
Leukocyte esterase	negative
Nitrite	negative
Urobilinogen	<2 mg/dL
Red blood cells (RBC)	<1/HPF
White blood cells (WBC)	1/HPF
Bacteria	none
Squamous epithelial	<1/HPF
Mucous	few/LPF



INSTRUCTOR MATERIALS

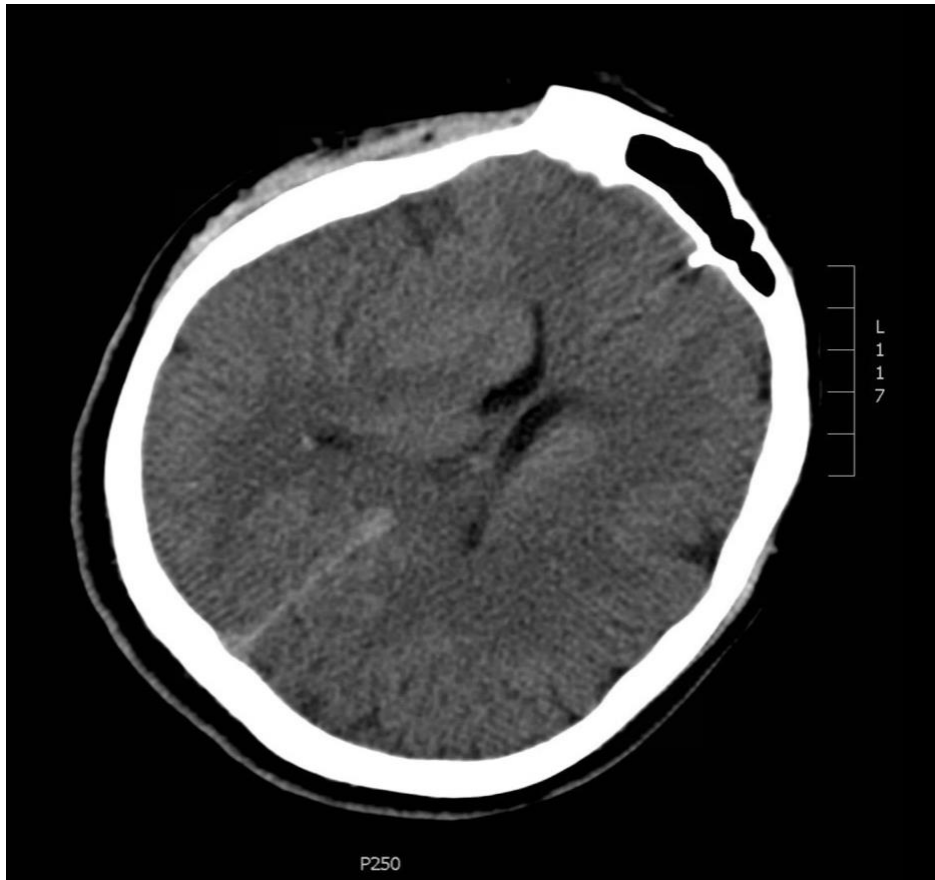Chest X-ray: Normal (author's own image)





INSTRUCTOR MATERIALS

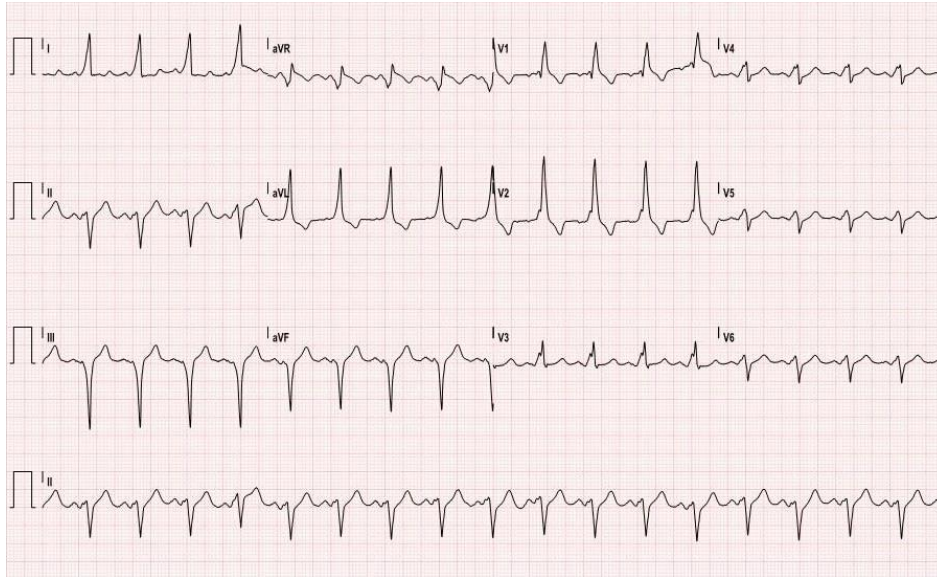
Head CT: Normal (author's own image)





INSTRUCTOR MATERIALS

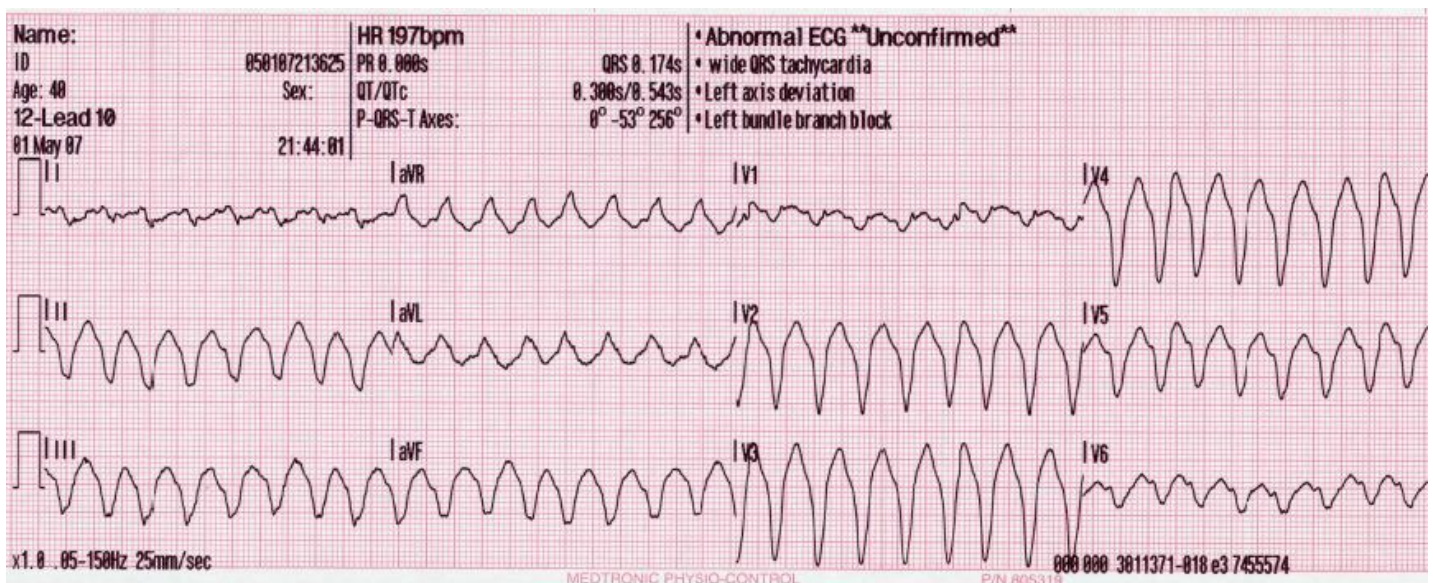
ECG #1: sinus tachycardia with WPW pattern
(author's own image)



ECG #2: wide-complex tachycardia

Larson, G. Lead generated ventricular tachycardia. In: Wikimedia Commons [free media repository].

https://upload.wikimedia.org/wikipedia/commons/4/45/12_lead_generated_ventricular_tachycardia.JPG. The Wikimedia Foundation; 2014.



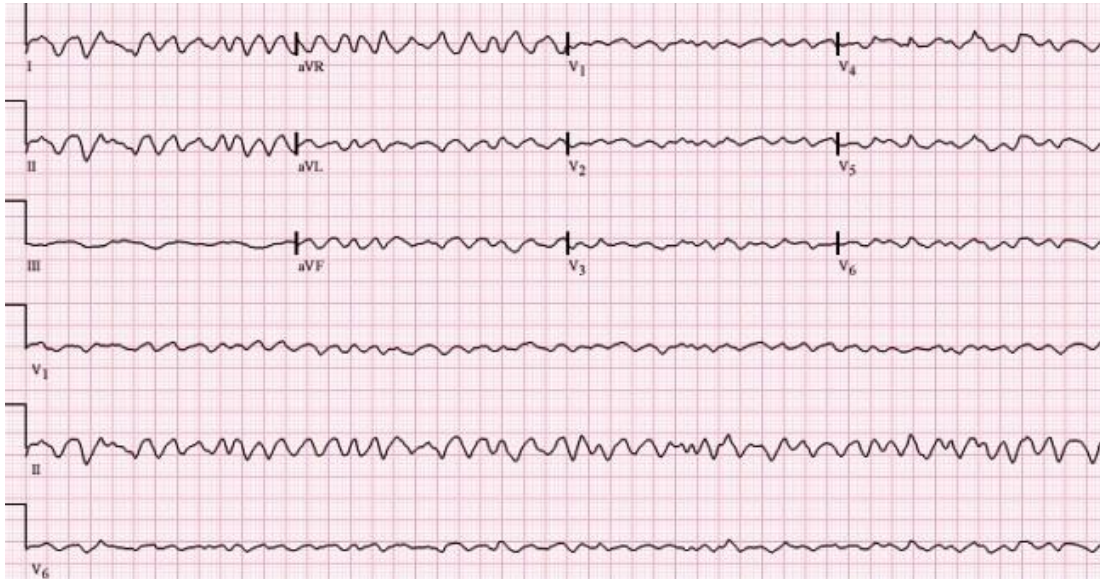


INSTRUCTOR MATERIALS

ECG #3: ventricular fibrillation

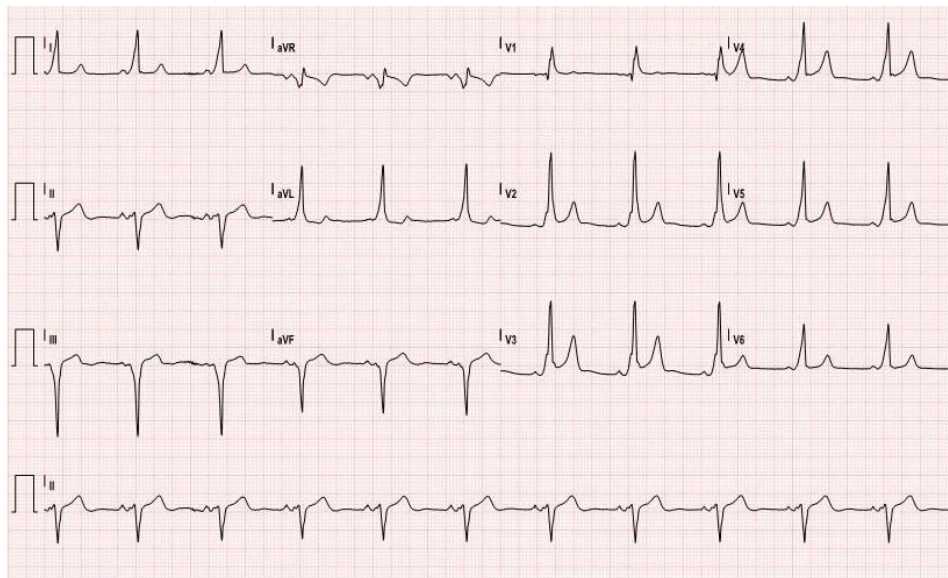
Ventricular Fibrillation. In: Roediger JE, Altman DB. ECG Guru [public domain].

<https://ecgguru.com/ecg/ventricular-fibrillation>. ECG Guru, Inc. October 2011.



ECG #4: normal sinus rhythm with WPW pattern

(author's own image)





OPERATOR MATERIALS

SIMULATION EVENTS TABLE:

Minute (state)	Participant action/ trigger	Patient status (simulator response) & operator prompts	Monitor display (vital signs)
0:00 (Baseline)	Girlfriend brings patient into the room	Patient is somnolent but arousable, reporting only a mild generalized headache without chest pain, perseverating on “what happened?” and “what’s going on?” Exam shows somnolent, disoriented patient with tachycardic but regular heart rhythm, no signs of trauma.	T: 99 HR: 109 BP: 152/86 RR: 16 O2: 99% Telemetry: delta waves, narrow complex QRS
0:00-3:00	<ul style="list-style-type: none"> Obtain focused history from girlfriend Assess airway, breathing, circulation Perform focused physical exam Order work-up: labs, UA, EEG, CTH, ECG 	Patient still somnolent but arousable, intermittently responds to verbal prompting.	T: 99 HR: 109 BP: 152/86 RR: 16 O2: 99% Telemetry: delta waves, narrow complex QRS
4:00-5:00	<ul style="list-style-type: none"> Return of labs, UA, EEG, CTH, ECG #1 Consult cardiology and/or neurology (both delayed) Consider vagal maneuvers or rate-limiting agents 	<ul style="list-style-type: none"> Patient still somnolent but arousable, intermittently responds to verbal prompting. No complaints presently. If vagal maneuvers or AV nodal rate-limiting agents are used, rate slows modestly. 	T: 99 HR: 109 BP: 152/86 RR: 16 O2: 99% Telemetry: delta waves, narrow complex QRS OR T: 99 HR: 82 BP: 142/76 RR: 16 O2: 99% RA



OPERATOR MATERIALS

Minute (state)	Participant action/ trigger	Patient status (simulator response) & operator prompts	Monitor display (vital signs)
			Telemetry: delta waves, narrow complex QRS
5:00-7:00	<ul style="list-style-type: none"> • <i>Timed trigger (5:00)</i> • Benzodiazepines or antiepileptic meds given • If antiarrhythmics or cardioversion used • If no antiarrhythmics or cardioversion used after 2 mins (7:00) 	<ul style="list-style-type: none"> • Pt develops chest pain followed by LOC loss of consciousness (LOC) and upper extremity tonic-clonic activity. Pulses intact. Now more tachycardic and tachypneic with audible rales. ECG #2 cannot be performed during tonic-clonic episode. • If benzodiazepines or antiepileptic meds given, seizure-like activity stops, but vitals and exam are otherwise unchanged. ECG #2 if ordered (after 1 min delay). EEG #2 if ordered (after 1 min delay). • If synchronized cardioversion (at 100J or more) is performed or antiarrhythmics (procainamide, amiodarone, sotalol, ibutilide, or dofetilide) are given, vitals and exam quickly normalize (right). ECG #4 if ordered (after 1-minute delay). Case ends if pt is successfully converted and admission to ICU is ordered. • If no antiarrhythmics or cardioversion, pt enters pulseless V-fib rate 250s, obtunded (ECG #3). 2 rounds of ACLS with defibrillation must be performed to revive patient. VS then normalize (right). ECG #4 if ordered (after 1-minute delay). Case ends if pt is successfully revived and admission to ICU is ordered, or ACLS unsuccessful. 	<p>T: 99 HR: 189 BP: 92/58 RR: 22 O2: 92% Telemetry: wide complex QRS</p> <p>OR</p> <p>T: 99 HR: 65 BP: 126/88 RR: 16 O2: 98% Telemetry: delta waves, narrow complex QRS</p> <p>(CASE ENDS)</p>



OPERATOR MATERIALS

Diagnosis:

Syncope with tonic-clonic jerks, secondary to WPW

Disposition:

ICU admission with cardiology consultation



DEBRIEFING AND EVALUATION PEARLS

Wolff-Parkinson-White

Epidemiology

- An estimated 3% of the US population suffers from recurrent convulsive episodes; 20%-30% of such episodes are of cardiac etiology (e.g. ischemia, valvular disease, arrhythmia). One-year mortality rates in such patients are up to 30%.^{1,2,3}
- Wolff-Parkinson-White disorder is thought to affect between 0.1% and 0.3% of the population with sudden cardiac death occurring in about 3%-4% of such patients.^{7,10}
- 19% of WPW patients surveyed had history of syncope, but unknown prevalence of seizure-like episodes in this population.¹¹

Pathophysiology

- Pathophysiologic basis of cardiogenic encephalopathy is thought to be a transient interruption of cerebral oxygen perfusion. Seizure threshold is lowered in the setting of cerebral hypoxia, and convulsive activity is thought to be the result of disinhibition of the medullary reticular formation.^{5,6}
- WPW is a congenital condition involving aberrantly conductive cardiac tissue between the atria and the ventricles that provides a pathway for an atrioventricular reentrant tachycardia circuit and ventricular pre-excitation.⁷
- WPW-associated tachyarrhythmias often lead to rapid ventricular rates with insufficient diastolic phase and thus stroke volume. Additionally, periods of asystole have been observed at the point of arrhythmia termination due to sinus nodal depression.¹²
- In orthodromic AV reentrant tachycardia (AVRT), the action potential primarily travels first through the AV node then back to the atria via the accessory pathway.¹³
- In antidromic AVRT, the action potential bypasses the AV node by conducting through the accessory pathway to the ventricles (“pre-excitation”) then back up the AV node.¹³

Clinical presentation

- Arrhythmia in general has been associated with a wide variety of neurologic disturbances, including dizzy spells, headache, syncope, focal motor deficit, seizure, confusion, dementia, and psychosis.⁴
- WPW disorder may appear during childhood but often not until middle age.⁷
- In young children, WPW may present with irritability, poor feedings, decreased mental status, febrile illness, and evidence of heart failure. Verbal children may also report chest pain, dyspnea, or palpitations.⁷



DEBRIEFING AND EVALUATION PEARLS

- Symptomatic adults most commonly present with chest pain, irregular or rapid palpitations, neurologic disturbances, but may also manifest cardiopulmonary collapse or cardiac arrest.⁷
- Tachyarrhythmias associated with WPW syndrome include supraventricular tachycardia (SVT), atrial fibrillation, or atrial flutter, with or without rapid ventricular response. In a series of 212 patients with WPW-associated tachyarrhythmias, SVT alone occurred in 64%, a-fib alone occurred in 20%, and both occurred in 16% of patients.⁷ Antidromic SVT is less prevalent than orthodromic SVT but carries a higher risk of ventricular tachycardia or fibrillation.¹³

Diagnosis¹³

- WPW syndrome is typically diagnosed using 12-lead ECG
- Classic WPW syndrome ECG morphology includes:
 - shortened PR interval (<120 ms)
 - slurred or slowed rise in QRS complex (“delta wave”)
 - widened QRS complex (>120 ms)
 - secondary repolarization abnormalities such as T-wave inversion
 - secondary tachyarrhythmia such as AVRT, atrial fibrillation, atrial flutter with or without rapid ventricular response
- Differentiation between orthodromic and antidromic AVRT may be difficult in the acute setting. In general, wide QRS complexes tend to be associated more closely with antidromic conduction due to a greater degree of ventricular pre-excitation via the accessory pathway.
- Echocardiography is used to evaluate for ventricular dysfunction, cardiomyopathies, or congenital abnormalities such as Ebstein anomaly or L-transposition of great vessels.
- More advanced electrophysiologic studies may eventually be needed to localize and characterize accessory pathways, evaluate specific mechanism of arrhythmia, and determine best treatment approach.

Management^{9,14,15}

- Emergent management of ABCs (airway, breathing, circulation) with cardiac monitoring and ACLS equipment available.
- If patient is pulseless, proceed directly into ACLS protocol.
- If pulses are present but tachycardia is hemodynamically unstable (e.g. patient is symptomatic, hypotensive, or with other signs of acute heart failure), immediately perform synchronized cardioversion.



DEBRIEFING AND EVALUATION PEARLS

- If patient is stable with narrow-complex tachycardia, treatment options include:
 - vagal maneuvers (e.g. ice pack on face, Valsalva maneuver, unilateral carotid massage)
 - adenosine, calcium channel blockers, or beta blockers
 - Class IA antiarrhythmic (eg, procainamide)
 - synchronized cardioversion
- If patient is stable with regular, monomorphic wide-complex tachycardia, treatment options include:
 - Class I or III antiarrhythmics (eg, procainamide, amiodarone, sotalol, ibutilide, or dofetilide)
 - synchronized cardioversion
- If patient is stable with evidence of pre-excited atrial fibrillation or flutter, treatment follows that of stable, regular, wide-complex tachycardia. Note that agents that act primarily on the AV node such as adenosine, calcium channel blockers, and beta blockers are contraindicated as they may cause increased aberrant ventricular conduction and further decompensation.
- Look for any reversible precipitating factors such as ischemia, electrolyte imbalance, thyroid disease, toxins, or anemia.
- Involve cardiology consultant early.
- Eventually, definitive treatment in most cases is catheter-based radiofrequency ablation of the accessory pathway after more advanced electrophysiologic studies are performed. Rarely, antiarrhythmic medications are used in the long-term setting.

References:

1. Hauser WA, Kurland LT. The epidemiology of epilepsy in Rochester, Minnesota, 1935 through 1967. *Epilepsia*. 1975;16(1):1-66
2. Kanjwal K, Karabin B, Kanjwal Y, Grubb BP. Differentiation of convulsive syncope from epilepsy with an implantable loop recorder. *Int J Med Sci*. 2009;6(6):296-300.
3. Kapoor WN, Karpf M, Wieand S, Peterson JR, Levey GS. A prospective evaluation and follow-up of patients with syncope. *N Engl J Med*. 1983; 309:197.
4. Schott GD, McLeod AA, Jewitt DE. Cardiac arrhythmias that masquerade as epilepsy. *BMJ*. 1977; 1:1454-7
5. Lempert T, Bauer M, Schmidt D. Syncope: a videometric analysis of 56 episodes of transient cerebral hypoxia. *Ann Neurol*. 1994;36:233-7.



DEBRIEFING AND EVALUATION PEARLS

6. Dell P, Hugelin A, Bonvallet M. Effects of hypoxia on the reticular and cortical diffuse systems. In: Gastaut H, Meyer JS, eds. *Cerebral Anoxia and the Electroencephalogram*. Springfield, IL: Charles C Thomas; 1961:46-58.
7. Cohen MI, Triedman JK, Cannon BC, et al. PACES/HRS expert consensus statement on the management of the asymptomatic young patient with a Wolff-Parkinson-White (WPW, ventricular preexcitation) electrocardiographic pattern. *Heart Rhythm*. 2012;(6):1006–1024. doi: 10.1016/j.hrthm.2012.03.050
8. Levis JT. ECG Diagnosis: Wolff-Parkinson-White Syndrome. *Perm J*. 2010; 14(2):53.
9. Page RL, Joglar JA, Caldwell MA, et al. 2015 ACC/AHA/HRS Guideline for the Management of Adult Patients With Supraventricular Tachycardia: A Report of the American College of Cardiology/American Heart Association Task Force on Clinical Practice Guidelines and the Heart Rhythm Society. *Circulation*. 2016;133: e506. doi: 10.1161/CIR.0000000000000311
10. Pappone C, Vicedomini G, Manguso F, et al. Risk of malignant arrhythmias in initially symptomatic patients with Wolff-Parkinson-White syndrome: results of a prospective long-term electrophysiological follow-up study. *Circulation*. 2012;125(5):661-8. doi: 10.1161/CIRCULATIONAHA.111.065722
11. Goudevenos JA, Katsouras CS, Graekas G. Ventricular pre-excitation in the general population: a study on the mode of presentation and clinical course. *Heart*. 2000;83(1):29–34. doi: 10.1136/heart.83.1.29



SIMULATION ASSESSMENT

Management of Wolff-Parkinson-White Tachyarrhythmia Presenting as Syncope with Seizure-like Activity

Learner: _____

Assessment Timeline

This timeline is to help observers assess their learners. It allows observer to make notes on when learners performed various tasks, which can help guide debriefing discussion.

Critical Actions

On initial presentation:

1. Check ABCs
2. Pursue appropriate initial history and physical exam
3. Order Head CT and ECG
4. Recognize WPW pattern on ECG
5. Call for cardiology consult

When patient has recurrence of seizure-like episode:

6. Repeat ABCs
7. Verbalize recognition of wide-complex tachycardia
8. Perform cardioversion
9. Admit to ICU once stable

If no antiarrhythmic/cardioversion, and patient enters pulseless V-fib:

10. Repeat ABCs
11. Perform 2 rounds of proper ACLS with defibrillation
12. Admit to ICU once stable

0:00



SIMULATION ASSESSMENT

Management of Wolff-Parkinson-White Tachyarrhythmia Presenting as Syncope with Seizure-like Activity

Learner: _____

Critical Actions:

On initial presentation:

- Check ABCs
- Pursue appropriate initial history and physical exam
- Order Head CT and ECG
- Recognize WPW pattern on ECG
- Call for cardiology consult

When patient has recurrence of seizure-like episode:

- Repeat ABCs
- Verbalize recognition of wide-complex tachycardia
- Perform cardioversion
- Admit to ICU once stable

If no cardioversion, and patient enters pulseless V-fib:

- Repeat ABCs
- Perform 2 rounds of proper ACLS with defibrillation
- Admit to ICU once stable

Summative and formative comments:



SIMULATION ASSESSMENT

Management of Wolff-Parkinson-White Tachyarrhythmia Presenting as Syncope with Seizure-like Activity

Learner: _____

Milestones assessment:

	Milestone	Did not achieve level 1	Level 1	Level 2	Level 3
1	Emergency Stabilization (PC1)	<input type="checkbox"/> Did not achieve Level 1	<input type="checkbox"/> Recognizes abnormal vital signs	<input type="checkbox"/> Recognizes an unstable patient, requiring intervention Performs primary assessment Discerns data to formulate a diagnostic impression/plan	<input type="checkbox"/> Manages and prioritizes critical actions in a critically ill patient Reassesses after implementing a stabilizing intervention
2	Performance of focused history and physical (PC2)	<input type="checkbox"/> Did not achieve Level 1	<input type="checkbox"/> Performs a reliable, comprehensive history and physical exam	<input type="checkbox"/> Performs and communicates a focused history and physical exam based on chief complaint and urgent issues	<input type="checkbox"/> Prioritizes essential components of history and physical exam given dynamic circumstances
3	Diagnostic studies (PC3)	<input type="checkbox"/> Did not achieve Level 1	<input type="checkbox"/> Determines the necessity of diagnostic studies	<input type="checkbox"/> Orders appropriate diagnostic studies. Performs appropriate bedside diagnostic studies/procedures	<input type="checkbox"/> Prioritizes essential testing Interprets results of diagnostic studies Reviews risks, benefits, contraindications, and alternatives to a diagnostic study or procedure
4	Diagnosis (PC4)	<input type="checkbox"/> Did not achieve Level 1	<input type="checkbox"/> Considers a list of potential diagnoses	<input type="checkbox"/> Considers an appropriate list of potential diagnosis May or may not make correct diagnosis	<input type="checkbox"/> Makes the appropriate diagnosis Considers other potential diagnoses, avoiding premature closure



SIMULATION ASSESSMENT

Management of Wolff-Parkinson-White Tachyarrhythmia Presenting as Syncope with Seizure-like Activity

Learner: _____

	Milestone	Did not achieve level 1	Level 1	Level 2	Level 3
5	Pharmacotherapy (PC5)	<input type="checkbox"/> Did not achieve Level 1	<input type="checkbox"/> Asks patient for drug allergies	<input type="checkbox"/> Selects an medication for therapeutic intervention, consider potential adverse effects	<input type="checkbox"/> Selects the most appropriate medication and understands mechanism of action, effect, and potential side effects Considers and recognizes drug-drug interactions
6	Observation and reassessment (PC6)	<input type="checkbox"/> Did not achieve Level 1	<input type="checkbox"/> Reevaluates patient at least one time during case	<input type="checkbox"/> Reevaluates patient after most therapeutic interventions	<input type="checkbox"/> Consistently evaluates the effectiveness of therapies at appropriate intervals
7	Disposition (PC7)	<input type="checkbox"/> Did not achieve Level 1	<input type="checkbox"/> Appropriately selects whether to admit or discharge the patient	<input type="checkbox"/> Appropriately selects whether to admit or discharge Involves the expertise of some of the appropriate specialists	<input type="checkbox"/> Educates the patient appropriately about their disposition Assigns patient to an appropriate level of care (ICU/Tele/Floor) Involves expertise of all appropriate specialists



SIMULATION ASSESSMENT

Management of Wolff-Parkinson-White Tachyarrhythmia Presenting as Syncope with Seizure-like Activity

Learner: _____

	Milestone	Did not achieve level 1	Level 1	Level 2	Level 3
9	General Approach to Procedures (PC9)	<input type="checkbox"/> Did not achieve Level 1	<input type="checkbox"/> Identifies pertinent anatomy and physiology for a procedure Uses appropriate Universal Precautions	<input type="checkbox"/> Obtains informed consent Knows indications, contraindications, anatomic landmarks, equipment, anesthetic and procedural technique, and potential complications for common ED procedures	<input type="checkbox"/> Determines a back-up strategy if initial attempts are unsuccessful Correctly interprets results of diagnostic procedure
20	Professional Values (PROF1)	<input type="checkbox"/> Did not achieve Level 1	<input type="checkbox"/> Demonstrates caring, honest behavior	<input type="checkbox"/> Exhibits compassion, respect, sensitivity and responsiveness	<input type="checkbox"/> Develops alternative care plans when patients' personal beliefs and decisions preclude standard care
22	Patient centered communication (ICS1)	<input type="checkbox"/> Did not achieve level 1	<input type="checkbox"/> Establishes rapport and demonstrates empathy to patient (and family) Listens effectively	<input type="checkbox"/> Elicits patient's reason for seeking health care	<input type="checkbox"/> Manages patient expectations in a manner that minimizes potential for stress, conflict, and misunderstanding. Effectively communicates with vulnerable populations, (at risk patients and families)
23	Team management (ICS2)	<input type="checkbox"/> Did not achieve level 1	<input type="checkbox"/> Recognizes other members of the patient care team during case (nurse, techs)	<input type="checkbox"/> Communicates pertinent information to other healthcare colleagues	<input type="checkbox"/> Communicates a clear, succinct, and appropriate handoff with specialists and other colleagues Communicates effectively with ancillary staff