

## Bedside Ultrasound for the Diagnosis of Peritonsillar Abscess

Harshal Bhakta, BS,\* Maili Alvarado, MD<sup>^</sup> and Daryn Towle, MD\*

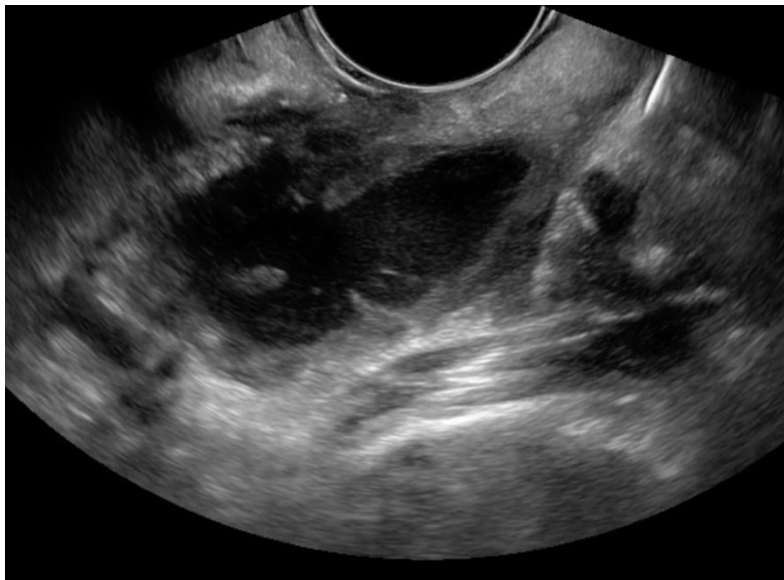
\*University of California, Irvine, Department of Emergency Medicine, Orange, CA

<sup>^</sup>University of Arizona, University Medical Center Tucson, Department of Emergency Medicine, Tucson, AZ

Correspondence should be addressed to Harshal Bhakta at [hbbhakta@uci.edu](mailto:hbbhakta@uci.edu)

Submitted: May 31, 2017; Accepted: September 19, 2017; Electronically Published: October 15, 2017; <https://doi.org/10.21980/J8N33N>

Copyright: © 2017 Towle, et al. This is an open access article distributed in accordance with the terms of the Creative Commons Attribution (CC BY 4.0) License. See: <http://creativecommons.org/licenses/by/4.0/>



Video Link: <https://youtu.be/l22j4q5Wu9c>

<https://youtu.be/eiysZrAE5es>

**History of present illness:** A 34-year-old male presented to the emergency department with fever, sore throat, and difficulty swallowing. On exam, the patient had trismus, a deviated uvula, and swelling of his left peritonsillar space. An intraoral point of care ultrasound (POCUS) was performed, which revealed a fluid collection in the patient's left peritonsillar space. The patient was diagnosed with a peritonsillar abscess (PTA) and needle aspiration was performed under direct ultrasound guidance. The patient tolerated the procedure well and was sent home with a course of antibiotics.

**Significant findings:** The first video is an intraoral ultrasound using the high frequency endocavitary probe demonstrating an anechoic fluid collection adjacent to the patient's enlarged left tonsil. The second video shows real-time ultrasound-guided successful drainage of the PTA.

**Discussion:** Peritonsillar abscesses are the most common deep space infection of the head and neck<sup>1</sup>, most commonly affecting children and young adults.<sup>2</sup> The ability of physicians to accurately differentiate PTA from peritonsillar cellulitis (PTC) by physical exam alone is limited. Traditionally, PTA has been treated using landmark-based needle aspiration.<sup>3</sup> If unsuccessful, computed tomography (CT) imaging and otolaryngology (ENT) consultation is usually required.<sup>3</sup> Although diagnosis of PTA using intraoral ultrasound has a sensitivity and specificity of between 89%-95% and 79%-100% respectively, it is still underutilized in comparison to these traditional methods.<sup>4</sup> Studies have shown the use of ultrasound for diagnosis and treatment of PTA leads to significantly better outcomes and higher success rates of drainage (when compared to landmark-based needle aspiration), less need for CT imaging, and less need for ENT consultation.<sup>3</sup> Utilizing intraoral point-of-care ultrasound is an efficient, safe, and cost-effective way of diagnosing and treating PTA.

**Topics:** Peritonsillar abscess, intraoral ultrasound, head and neck, point of care ultrasound, otolaryngology, ENT.

#### References:

1. Galioto NJ. Peritonsillar abscess. *Am Fam Physician*. 2017;95(8):501-506.
2. Schraff S, McGinn JD, Derkay CS. Peritonsillar abscess in children: a 10-year review of diagnosis and management. *Int J Pediatr Otorhinolaryngol*. 2001;57(3):213-218. doi: 10.1016/S0165-5876(00)00447-X
3. Costantino TG, Satz WA, Dehnkamp W, Goett H. Randomized trial comparing intraoral ultrasound to landmark-based needle aspiration in patients with suspected peritonsillar abscess. *Acad Emerg Med*. 2012;19(6):626-631. doi: 10.1111/j.1553-2712.2012.01380.x
4. Powell J and Wilson JA. An evidence-based review of peritonsillar abscess. *Clin Otolaryngol*. 2012;37(2):136-145. doi: 10.1111/j.1749-4486.2012.02452.x