

Pneumomediastinum After Cervical Stab Wound

Chad Correa, BS* and Emily Ma, MD[^]

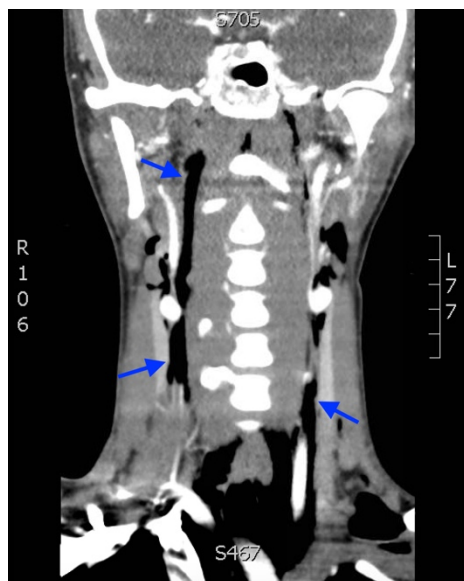
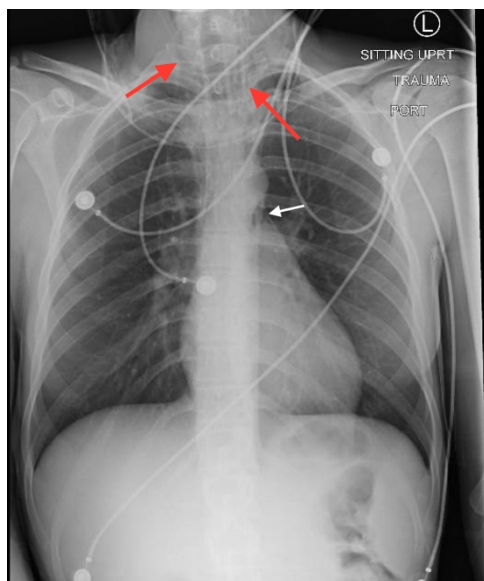
*University of California, Riverside, School of Medicine, Riverside, CA

[^]University of California, Irvine, Department of Emergency Medicine, Orange, CA

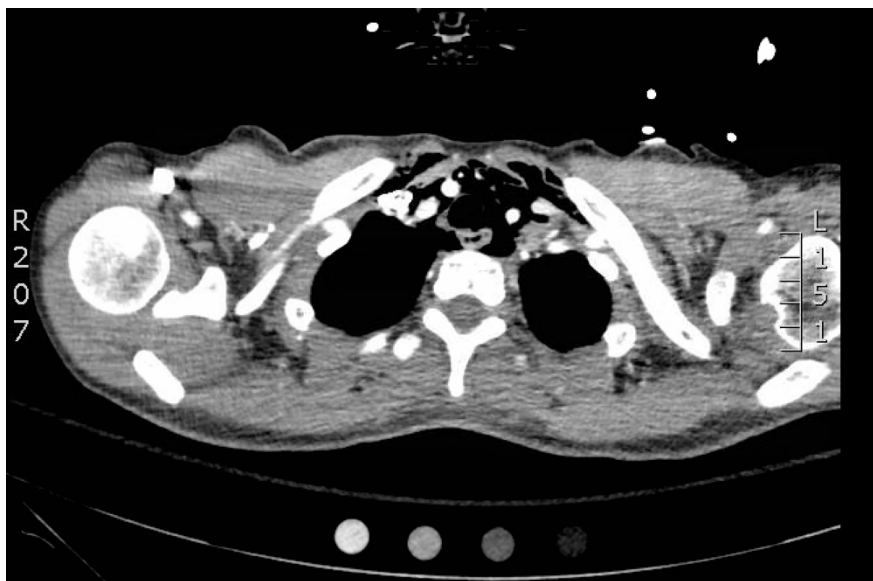
Correspondence should be addressed to Chad Correa, BS at chad.correa@medsch.ucr.edu

Submitted: October 1, 2017; Accepted: November 20, 2017; Electronically Published: January 15, 2018; <https://doi.org/10.21980/J87P79>

Copyright: © 2018 Correa, et al. This is an open access article distributed in accordance with the terms of the Creative Commons Attribution (CC BY 4.0) License. See: <http://creativecommons.org/licenses/by/4.0/>



Video Link: <https://youtu.be/c8IYed1fnoE>



Video Link: https://youtu.be/q_cFK1atwIE

History of present illness: A 21-year old female presented to the emergency department with a stab wound to the left neck. She reported that her boyfriend had fallen off a ladder and subsequently struck her in the back of the neck with the scissors he had been working with. She was alert and in minimal distress, speaking in full sentences, and lungs were clear to auscultation bilaterally. Examination of the neck showed a 0.5cm linear wound at the base of the proximal left clavicle (Zone 1). Cranial nerves were grossly intact, and the patient was moving all extremities spontaneously.

Significant findings: Anteroposterior (AP) chest X-ray showed subcutaneous emphysema of the neck, surrounding the trachea (red arrows), right side greater than left, and a streak of gas adjacent to the aortic arch (white arrow). Computed tomography angiogram (CTA) of the neck showed air outside of the trachea, positive for pneumomediastinum (blue arrows).

Discussion: Penetrating neck injuries account for 5-10% of trauma patients, with a mortality of 3%-10%.¹ These can result in injuries of vital vasculature, the trachea, esophagus, or the spinal cord.² In these patients, Hamman's sign may be auscultated, which can be heard as a crackling, bubbling, or popping that varies with the phases of the cardiac cycle.³ A pneumomediastinum is characterized by extraluminal gas in the mediastinum, which may represent a tracheobronchial or esophageal laceration.^{4,5} This diagnosis is imperative to make in order to avoid serious complications such as mediastinal sepsis.^{2,3,6} Although studies have shown that a CTA of the neck has a specificity of 100% and sensitivity of 90% in identifying vascular lesions of the neck, it has low diagnostic sensitivity for injuries of the respiratory and digestive system.² Therefore, patients with confirmed pneumomediastinum after penetrating cervical injury should undergo further testing such as a bronchoscopy and contrast study to evaluate for perforation of the respiratory and digestive tract.^{4,6}

Topics: Pneumomediastinum, penetrating neck trauma, subcutaneous emphysema.

References:

1. Demetriades D, Skalkides J, Sofianos C, Melissas J, Franklin J. Carotid artery injuries: experience with 124 cases. *J Trauma*. 1989;29(1):91-4. doi: 10.1055/s-0034-1372521
2. Nasr A, Tamara De Oliveria J, Mazepa MM, Cavalcanti de Albuquerque CL, Martini GS, Nazario M, et al. Evaluation of the use of tomography in penetrating neck trauma. *Rev Col Bras Cir*. 2015;42(4):215-219. doi: 10.1590/0100-69912015004004
3. Enguidanos L, Pfleiderer A, Smith W, Ramkumar S. Pneumomediastinum secondary to an apparently trivial stab wound to the neck: the value of the Hamman's sign and thorough radiologic investigation. *Emerg Med J*. 2005;22(3):230-231.
4. Bejvan SM, Godwin JD. Pneumomediastinum: old signs and new signs. *AJR AM J Roentgenol*. 1996;166(5):1041-1048. doi: 10.2214/ajr.166.5.8615238
5. Sørreide JA, Viste A. Esophageal perforation: diagnostic work-up and clinical decision-making in the first 24 hours. *Scand J Trauma, Resusc and Emerg Med*. 2011;19:66. doi: 10.1186/1757-7241-19-66
6. Levy RD, Degiannis E, Hatzitheophilou C, Maberti P, Kantarovsky A, John KD, et al. Management of penetrating injuries of the cervical trachea. *Ann R Coll Surg Engl*. 1997; 79(3):195-7.