

SIMULATION

Chest Pain with Acute Coronary Syndrome

Alisa Wray, MD*

*University of California, Irvine, Department of Emergency Medicine, Orange, CA

Correspondence should be addressed to Alisa Wray, MD at awray@uci.edu

Submitted: October 21, 2017; Accepted: March 21, 2018; Electronically Published: April 15, 2018; <https://doi.org/10.21980/J8K04C>

Copyright: © 2018 Wray. This is an open access article distributed in accordance with the terms of the Creative Commons Attribution (CC BY 4.0) License. See: <http://creativecommons.org/licenses/by/4.0/>

ABSTRACT:

Audience: This simulation was created for medical students and interns to teach the basics of working up and treatment for a patient with acute coronary syndrome.

Introduction: Chest pain is a common presenting chief complaint. It is important for physicians to be able to quickly assess patients with chest pain, develop a differential diagnosis, assess and treat patients for seriously life-threatening causes of chest pain. Although acute coronary syndrome and acute myocardial infarctions are less common causes of chest pain it is important for physicians to rapidly recognize an ST segment elevation myocardial infarction (STEMI) and treat accordingly.

Objectives: At the end of this case learners should be able to prepare a differential for patients with chest pain, provide appropriate medications for a patient with chest pain, recognize an ST segment elevation MI, and appropriately disposition a patient with acute myocardial infarction (AMI).

Method: This simulation can be taught using a low, medium or high-fidelity simulation model or can also be taught using a standardized patient or as an oral boards case.

Topics: Chest pain, acute coronary syndrome, acute coronary syndrome (ACS), STEMI.



USER GUIDE

List of Resources:

Abstract	38
User Guide	39
Instructor Materials	41
Operator Materials	48
Debriefing and Evaluation Pearls	50
Simulation Assessment	52

Learner Audience:

Medical students and interns

Time Required for Implementation:

Instructor Preparation: 20-30 minutes

Time for case: 10-15 minutes

Time for debriefing: 10-30 minutes

Recommended Number of Learners per Instructor:

2-5

Topics:

Chest pain, acute coronary syndrome, acute coronary syndrome (ACS), STEMI.

Objectives:

By the end of this simulation session, the learner will be able to:

1. Recognition of acute coronary syndrome.
2. Prepare an appropriate differential diagnosis of a patient with chest pain
3. Demonstrate appropriate medical management for a patient with chest pain
4. Demonstrate appropriate reading of an electrocardiogram (ECG) with a STEMI
5. Demonstrate appropriate disposition of a patient with acute coronary syndrome

Linked objectives and methods:

Chest pain is a common complaint in the emergency department; it is estimated that approximately 6 million people present to the ED for chest pain, an estimated 6% of all ED visits.¹ The differential diagnosis of chest pain is vast, and it is important for learners to focus on the worst first causes such as acute coronary syndrome (ACS), aortic dissection, and pulmonary embolism.¹ Approximately 4%-7.5% of all patients that present to the emergency department (ED) with complaints of chest pain will be diagnosed with an acute myocardial infarction (AMI).¹ This simulation will allow learners to evaluate and treat in a safe environment a patient who presents to the ED with complaints of chest pain. The case is written for medical student and intern level learners who do not have much experience with ACS or AMI. The case allows the

learner to work through the history, physical, and treatment, and if the learner is not treating it appropriately the simulation can be adjusted to help them make the diagnosis or to have the patient decompensate if an AMI is not diagnosed.

Recommended pre-reading for instructor:

- It is recommended that the instructor read any book chapter on acute coronary syndrome, and /or the most recent set of American Heart Association Advanced Cardiac Life Support Guidelines.

Learner responsible content:

- After the case we strongly recommend the instructor discuss with learners the differential diagnosis of patients with chest pain as well as the management of ACS.

Results and tips for successful implementation:

This case can use a high, medium or low fidelity simulation mannequin or a standardized patient. Alternatively, this case can also be used as an oral boards case. The main objective of the case is to expose the learner to a patient with ACS in a safe environment. This case allows the learner to work through the differential diagnosis for a patient with chest pain, assess the possibility of ACS, order appropriate labs, imaging, and ECG, as well as treat the patient for a STEMI. If the learner is having difficulty recognizing that the patient has ACS, the nurse can help by prompting the learner in appropriate management.

This case was initially piloted with over 100 fourth-year medical students; some adjustments were made in the case to simplify it and allow for easier diagnosis and focus on the treatment of ACS. The students had very positive responses to the case and felt that the case was an important learning opportunity prior to the start of their intern year.

References/suggestions for further reading:

1. Strehlow M, Tabas J. Chest pain. In: James Adam, ed. *Emergency Medicine: Clinical Essentials*. 2nd ed. Philadelphia, PA: Elsevier; 2013:1666-1668.
2. American Heart Association. ACLS Guidelines. <https://eccguidelines.heart.org/index.php/circulation/cpr-ecc-guidelines-2/>. Accessed April 4, 2018.
3. American Heart Association. Highlights of the 2017 American Heart Association focused updates on adult and pediatric basic life support and cardiopulmonary resuscitation quality. https://eccguidelines.heart.org/wp-content/uploads/2017/11/2017-Focused-Updates_Highlights.pdf. Published November 7, 2017. Accessed April 4, 2018.
4. Backus BE, Six AJ, Kelder JC, Bosschaert MA, Mast EG,



USER GUIDE

Mosterd A, et al. A prospective validation of the HEART score for chest pain patients at the emergency department. *Int J Cardiol.* 2013;168(3):2153-8. doi: 10.1016/j.ijcard.2013.01.255

5. The HEART score: a new ED chest pain risk stratification score. REBEL EM. <http://rebelem.com/heart-score-new-ed-chest-pain-risk-stratification-score/>. Published January 10, 2014. Accessed April 4, 2018.



INSTRUCTOR MATERIALS

Case Title: Chest Pain with Acute Coronary Syndrome

Case Description & Diagnosis (short synopsis): The patient is a 53-year-old male who presents to the emergency department with complaints of chest pain. The patient reports a history of myocardial infarction and stent placement 3 years prior. On physical exam the patient is diaphoretic, holding his chest and complaining of pain and difficulty breathing. ECG will be consistent with a STEMI; the learner should activate cardiac catheterization laboratory (cath lab) and discuss the case with cardiology who will request the patient be started on heparin. The patient will then be taken to cath lab for definitive management.

Equipment or Props Needed:

High, moderate or low fidelity mannequin
Infusion pumps
Normal saline
Prop medications
Cardiac monitor
Intravenous (IV) catheter and lines
Pulse oximeter
Blood pressure cuff
Crash Cart with defibrillator

Confederates needed:

If a simulation mannequin is not available a standardized patient or faculty member could be used as the patient
Nurse to assist with the management of the patient
Cardiologist (via phone)

Stimulus Inventory:

- #1 Chest X-ray (CXR)
- #2 Electrocardiogram (ECG)
- #3 Complete blood count (CBC)
- #4 Comprehensive metabolic panel (CMP)
- #5 Troponin
- #6 Brain Natriuretic Peptide
- #7 D-Dimer



INSTRUCTOR MATERIALS

Background and brief information: The scenario takes place in an ED at a tertiary care teaching hospital. The patient is a 53-year-old male who presents with complaints of chest pain.

Initial presentation: The patient presents from home, by himself with no family present.

How the scenario unfolds: On ED arrival the patient will be awake and complaining of chest pain. Learners should quickly assess the patient's airway, breathing and circulation while requesting the patient be placed on the monitor, on oxygen, and have an IV placed and blood work drawn. Initial vitals will be unremarkable. Participants should obtain a history and physical and consider the possible causes of chest pain in the patient. On physical exam the patient will be diaphoretic, clutching his chest, taking shallow respirations and complaining of pain. The patient's pain should be treated with aspirin and nitroglycerin. Learner can consider additional options for pain control such as morphine. An ECG and chest X-ray should be ordered. Chest X-ray will be normal, ECG will be significant for a STEMI. Learners should activate cath lab and give sign out to the cardiologist who will recommend starting heparin and transporting patient to the cath lab.

Should learners fail to order an ECG, give nitroglycerin and aspirin, recognize the patient has a STEMI and activate the cath lab, the patient will continue to complain about worsening chest pain, and ultimately degrade to ventricular fibrillation code. Despite appropriate Advanced Cardiac Life Support (ACLS) the patient will not regain pulses.

Critical Actions:

1. Assess airway, breathing, circulation.
2. Establish intravenous access.
3. Place the patient on a cardiac monitor and pulse oximeter.
4. Take a complete history and perform a complete physical exam.
5. Order an ECG, chest X-ray and cardiac enzymes.
6. Give the patient aspirin and nitroglycerin.
7. Interpret the ECG as a STEMI.
8. Activate catheterization lab (cath lab)
9. Initiate heparin drip.



INSTRUCTOR MATERIALS

Case Title: Chest Pain with Acute Coronary Syndrome

Chief Complaint: Chest Pain

Vitals: Heart Rate (HR) 99 Blood Pressure (BP) 158/90 Respiratory Rate (RR) 18
Temperature (T) 37.5°C Oxygen Saturation (O₂Sat) 99% on room air

General Appearance: middle aged man, clutching his chest

Primary Survey:

- **Airway:** patent
- **Breathing:** clear bilaterally with shallow respirations
- **Circulation:** 2+ pulses femoral pulses

History:

- **History of present illness:** The patient is a 53-year-old male who presents with complaints of chest pain. He states that the pain woke him from sleep this morning, is located in the center of his chest, and is pressure-like in nature. He endorses mild shortness of breath when he tries to take a deep breath and states that he feels very sweaty.

If asked: The patient will report that he has been getting chest pain more frequently, and notices that he gets chest pain and shortness of breath when walking short distances. He will state that he has a history of an MI with stents placed 3 years ago.

- **Past medical history:** hypertension (HTN), hyperlipidemia (HLP), previous myocardial infarction (MI) with stents placed 3 years ago
- **Past surgical history:** appendectomy
- **Patients medications:** “something for my blood pressure and cholesterol”
- **Allergies:** No known drug allergies
- **Social history:** + smoking, denies alcohol or drugs. Lives alone at home.
- **Immunizations:** up to date
- **Family history:** father who died suddenly at age 65, mother with HTN and diabetes mellitus (DM)

Secondary Survey/Physical Examination:

- **General appearance:** mild distress, diaphoretic, holding one hand to his chest



INSTRUCTOR MATERIALS

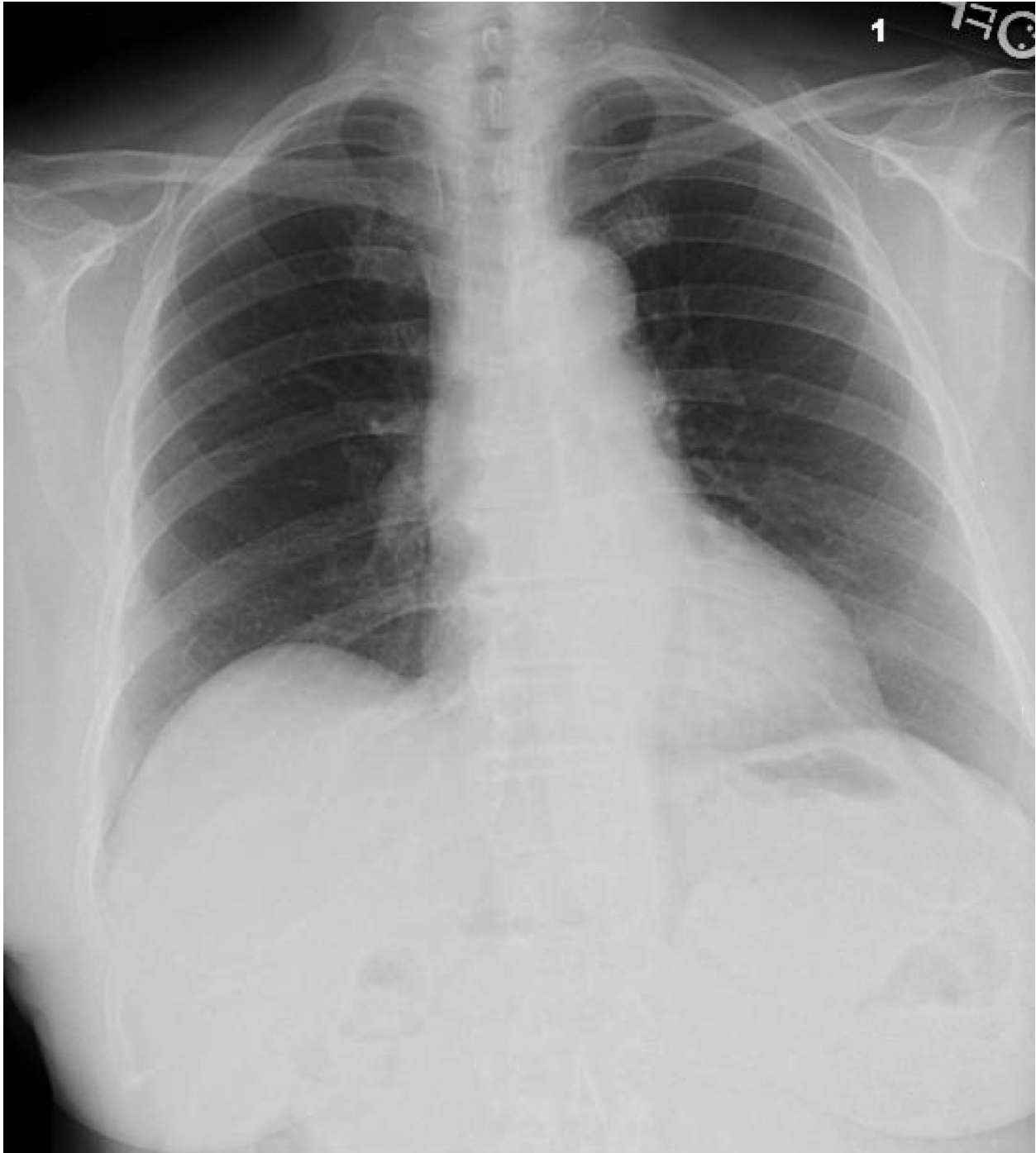- **Head, ears, eyes, nose and throat (HEENT):** within normal limits
- **Neck:** within normal limits
- **Heart:** regular rhythm, no murmurs
- **Lungs:** clear to auscultation, shallow respirations, no rhonchi, no wheezes, no crackles
- **Abdominal/GI:** within normal limits
- **Genitourinary:** within normal limits
- **Rectal:** within normal limits
- **Extremities:** delayed capillary refill, otherwise within normal limits
- **Back:** within normal limits
- **Neuro:** Awake, GCS 15, moving all extremities, sensation intact
- **Skin:** within normal limits
- **Lymph:** within normal limits
- **Psych:** within normal limits



INSTRUCTOR MATERIALS

Results:

Chest X-ray: Normal (author's own image)



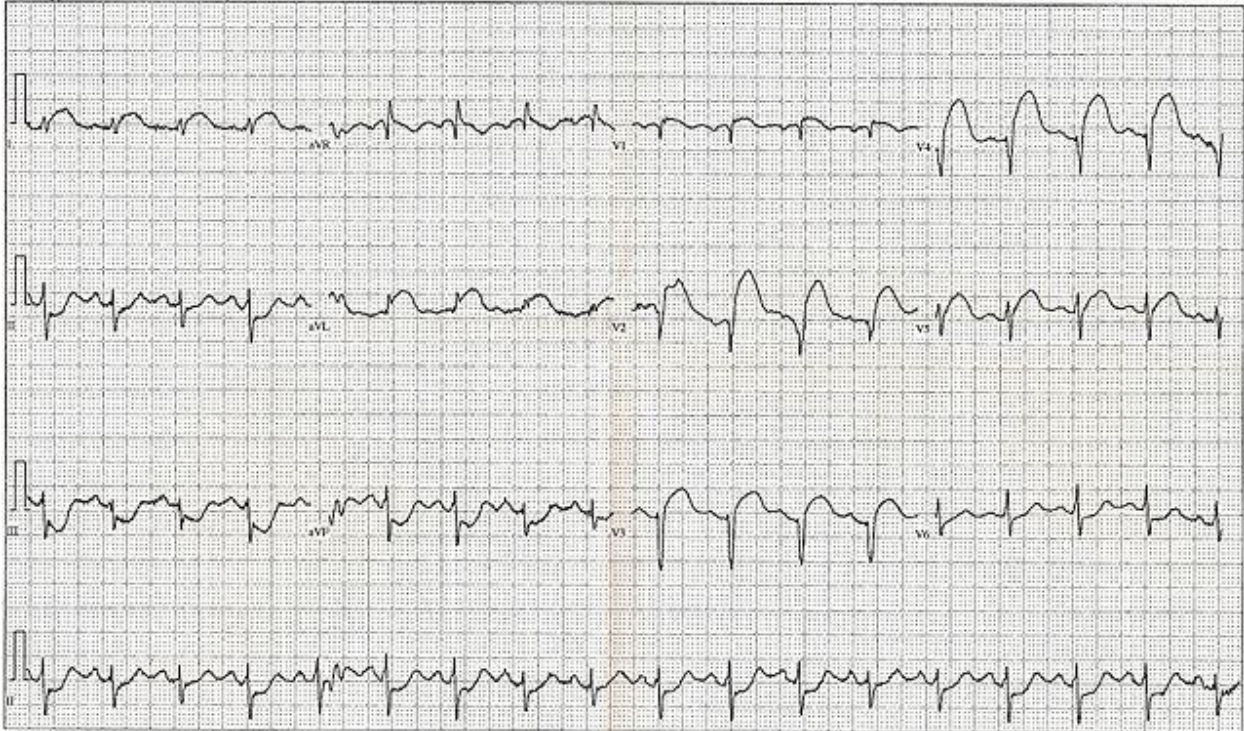


INSTRUCTOR MATERIALS

Electrocardiogram (EKG) 12 Lead EKG ST Elevation tracing only.

In: Wikimedia Commons [free media repository].

https://commons.wikimedia.org/wiki/File:12_Lead_EKG_ST_Elevation_tracing_only.jpg. May 20, 2008. Public Domain.



Complete blood count (CBC)

White blood count (WBC)	6.5 x1000/mm ³ (H)
Hemoglobin (Hgb)	14.4 g/dL
Hematocrit (HCT)	42%
Platelet (Plt)	172 x1000/mm ³

Complete metabolic panel (CMP)

Sodium	138 mEq/L
Chloride	104 mEq/L
Potassium	4.4 mEq/L
Bicarbonate (HCO ₃)	26 mEq/L (L)
Blood Urea Nitrogen (BUN)	19 mg/dL (H)
Creatine (Cr)	0.9 mg/dL (H)
Glucose	127 mg/dL
Aspartate Aminotransferase (AST)	17 u/L



INSTRUCTOR MATERIALS

Alanine Aminotransferase (ALT)	16 u/L
<i>Troponin</i>	
Troponin-I	5.2 ng/mL
<i>Brain Natriuretic Peptide</i>	
BNP	77 pg/mL
<i>D-Dimer</i>	
D-Dimer	440 ng/mL



OPERATOR MATERIALS

SIMULATION EVENTS TABLE:

Minute (state)	Participant action/ trigger	Patient status (simulator response) & operator prompts	Monitor display (vital signs)
0:00 (Baseline)	Obtain history, examine patient, evaluate symptoms	Patient reports symptoms of chest pain, "pressure-like," and it doesn't radiate. The pain started 15 minutes ago and woke up the patient from sleep.	T: 37.5 HR: 99 BP: 155/90 RR: 18 O2: 99% RA
2:00-3:00	Place patient on cardiac monitor, pulse oximeter and oxygen	Monitor shows ST elevation. Patient continues to complain of chest pain	T: 37.5 HR: 99 BP: 155/90 RR: 18 O2: 100% on 2L NC
3:00-5:00	Send off labs: CBC, CMP, CXR, ECG, troponin Place 2 large bore IV lines Give fluid bolus Aspirin, Nitroglycerin ordered and given	ECG and X-ray techs obtain studies. Blood is drawn but nursing reports they will not have results for 10 minutes. Patient continues to complain of chest pain.	If managed appropriately: T: 37.5 HR: 85 BP: 125/70 RR: 18 O2: 100% on 2L NC If no medications given: T: 37.5 HR: 102 BP: 165/95 RR: 20 O2: 99% RA
5:00-7:00	ECG and Chest X-ray are available If not completed previously: give aspirin and nitroglycerin ordered and given	If patient was given medication he will begin to feel improved and start to ask "What is going on? Am I going to die?" If patient is not given medications he will report feeling dizzy and worsening chest pain.	If managed appropriately: T: 37.5 HR: 85 BP: 125/70 RR: 18 O2 100% on 2L NC



OPERATOR MATERIALS

Minute (state)	Participant action/ trigger	Patient status (simulator response) & operator prompts	Monitor display (vital signs)
			Worsening vitals if not managing correctly
7:00-9:00	Learner recognizes STEMI and activates cath lab Labs return If not completed previously: give aspirin and nitroglycerin	If patient given appropriate medications and cath lab activated, patient will report feeling improved but scared about possible cardiac catheterization. Cardiology will request the learner start heparin and clopidogrel and will report that they will be down shortly. If patient is not given appropriate medications, he will become unresponsive and degrade into ventricular fibrillation and arrest.	If managed appropriately: T: 37.5 HR: 85 BP: 125/70 RR: 18 O2 100% on 2L NC Worsening vitals if not managing correctly
(Case Completion)	Heparin drip is started and the patient leaves for cath lab or Learners should recheck vitals and check for a pulse	If all treatment is appropriate the patient will be taken to cath lab. If patient arrested then the learner should begin CPR and defibrillate the patient; despite appropriate ACLS the patient will not regain pulses and time of death will be called.	If managed appropriately: T: 37.5 HR: 85 BP: 125/70 RR: 18 O2 100% on 2L NC Worsening vitals if not managing correctly

Diagnosis:
STEMI/ACS

Disposition:
Patient taken for cardiac catheterization and admitted to the CCU



DEBRIEFING AND EVALUATION PEARLS

Acute Coronary Syndrome

ECG is essential in the work-up of patients who may have cardiac cause of chest pain. It should be done early to rule out STEMI.

It is important to consider a full differential of chest pain in patients with multiple risk factors for ACS. Just ruling out ACS is not sufficient, you must consider:

- Dissection – chest pain radiating to back, with transient or persistent neuro deficits, may have widened mediastinum on CXR
- Pulmonary embolism – risks of blood clot, pleuritic pain
- Pneumonia – cough, fevers, infiltrate on CXR
- ACS including STEMI, NSTEMI, angina and unstable angina

What factors make a patient higher risk for chest pain?

- Risk factors: Age >60, family history, hypertension, diabetes, hyperlipidemia, tobacco smoker, personal history of previous MI
- Characterization of the pain – pressure, radiation to either shoulder or jaw or left arm
- Not all patients present with classic ACS symptoms. ACS equivalents can include nausea, epigastric discomfort, shortness of breath, and generalized weakness.
- HEART Score³:
 - Risk Assessment and Management Tool to help predict the risk of combined endpoint of myocardial infarction (MI), percutaneous coronary intervention (PCI), coronary artery bypass graft (CABG) or death within 6 weeks after presentation.
 - History: HEART Score was developed in an ED setting in ALL patients with chest pain and not just ACS patients.

HEART Score		
• History	<ul style="list-style-type: none"> • Highly Suspicious • Moderately Suspicious • Slightly or Non-Suspicious 	<ul style="list-style-type: none"> • 2 points • 1 point • 0 points
• ECG	<ul style="list-style-type: none"> • Significant ST Depression • Nonspecific Repolarization • Normal 	<ul style="list-style-type: none"> • 2 points • 1 point • 0 points
• Age	<ul style="list-style-type: none"> • >65 • 45-65 • <45 	<ul style="list-style-type: none"> • 2 points • 1 point • 0 points



DEBRIEFING AND EVALUATION PEARLS

<ul style="list-style-type: none"> Risk Factors 	<ul style="list-style-type: none"> >3 Risk Factors or History of CAD 1-2 Risk Factors No Risk Factors 	<ul style="list-style-type: none"> 2 points 1 point 0 points
<ul style="list-style-type: none"> Troponin 	<ul style="list-style-type: none"> >3 x Normal 1-<3 x Normal Normal 	<ul style="list-style-type: none"> 2 points 1 point 0 points
<ul style="list-style-type: none"> Risk Factors: DM, smoker, HTN, HLD, Family Hx of CAD, Obesity 		
<ul style="list-style-type: none"> Score 0-3: 2.5% MACE (major adverse cardiac event) over next 6 weeks → Discharge Home Score 4-6: 20.3% MACE over next 6 weeks → Admit for clinical observation Score 7-10: 72.7% MACE over next 6 weeks → Early Intervention 		

Treatment:

- Aspirin 162-324 mg chewable should be given in all patients who are being worked up for ACS because of the huge mortality benefit of giving Aspirin in patients with ACS (NNT of 42).
- Sublingual nitroglycerin should be given unless concern for right-sided MI or the patient is taking phosphodiesterase inhibitors.
- Reperfusion therapy, either through cardiac catheterization or thrombolysis, reduces morbidity and mortality; if a STEMI is suspected, then cardiac catheterization for percutaneous coronary intervention or fibrinolytics should be given

Wrap Up: *We recommend reviewing the American Heart Association ACLS guidelines as well as any chapter on chest pain.*



SIMULATION ASSESSMENT

Chest Pain with Acute Coronary Syndrome

Learner: _____

Assessment Timeline

This timeline is to help observers assess their learners. It allows observer to make notes on when learners performed various tasks, which can help guide debriefing discussion.

Critical Actions

1. Assess airway, breathing, circulation.
2. Establish intravenous access.
3. Place the patient on a cardiac monitor and pulse oximeter.
4. Take a complete history and perform a complete physical exam.
5. Order an ECG, CXR and cardiac enzymes.
6. Give the patient aspirin and nitroglycerin.
7. Interpret the ECG as a STEMI.
8. Activate Cath Lab.
9. Initiate heparin drip.

0:00



SIMULATION ASSESSMENT

Chest Pain with Acute Coronary Syndrome

Learner: _____

Critical Actions:

On initial presentation:

- Assess airway, breathing, circulation.
- Establish intravenous access.
- Place the patient on a cardiac monitor and pulse oximeter.
- Take a complete history and perform a complete physical exam.
- Order an ECG, CXR and cardiac enzymes.
- Give the patient aspirin and nitroglycerin.
- Interpret the ECG as a STEMI.
- Activate Cath Lab.
- Initiate heparin drip.

Summative and formative comments:

Standardized assessment form for simulation cases. JETem © Developed by: Megan Osborn, MD, MHPE; Shannon Toohey, MD; Alisa Wray, MD

Wray A. Chest Pain with Acute Coronary Syndrome. JETem 2018. 3(2):S81-99.

<https://doi.org/10.21980/J8K04C>





SIMULATION ASSESSMENT

Chest Pain with Acute Coronary Syndrome

Learner: _____

Milestones assessment:

	Milestone	Did not achieve level 1	Level 1	Level 2	Level 3
1	Emergency Stabilization (PC1)	<input type="checkbox"/> Did not achieve Level 1	<input type="checkbox"/> Recognizes abnormal vital signs	<input type="checkbox"/> Recognizes an unstable patient, requiring intervention Performs primary assessment Discerns data to formulate a diagnostic impression/plan	<input type="checkbox"/> Manages and prioritizes critical actions in a critically ill patient Reassesses after implementing a stabilizing intervention
2	Performance of focused history and physical (PC2)	<input type="checkbox"/> Did not achieve Level 1	<input type="checkbox"/> Performs a reliable, comprehensive history and physical exam	<input type="checkbox"/> Performs and communicates a focused history and physical exam based on chief complaint and urgent issues	<input type="checkbox"/> Prioritizes essential components of history and physical exam given dynamic circumstances
3	Diagnostic studies (PC3)	<input type="checkbox"/> Did not achieve Level 1	<input type="checkbox"/> Determines the necessity of diagnostic studies	<input type="checkbox"/> Orders appropriate diagnostic studies. Performs appropriate bedside diagnostic studies/procedures	<input type="checkbox"/> Prioritizes essential testing Interprets results of diagnostic studies Reviews risks, benefits, contraindications, and alternatives to a diagnostic study or procedure
4	Diagnosis (PC4)	<input type="checkbox"/> Did not achieve Level 1	<input type="checkbox"/> Considers a list of potential diagnoses	<input type="checkbox"/> Considers an appropriate list of potential diagnosis May or may not make correct diagnosis	<input type="checkbox"/> Makes the appropriate diagnosis Considers other potential diagnoses, avoiding premature closure



SIMULATION ASSESSMENT

Chest Pain with Acute Coronary Syndrome

Learner: _____

	Milestone	Did not achieve level 1	Level 1	Level 2	Level 3
5	Pharmacotherapy (PC5)	<input type="checkbox"/> Did not achieve Level 1	<input type="checkbox"/> Asks patient for drug allergies	<input type="checkbox"/> Selects an medication for therapeutic intervention, consider potential adverse effects	<input type="checkbox"/> Selects the most appropriate medication and understands mechanism of action, effect, and potential side effects Considers and recognizes drug-drug interactions
6	Observation and reassessment (PC6)	<input type="checkbox"/> Did not achieve Level 1	<input type="checkbox"/> Reevaluates patient at least one time during case	<input type="checkbox"/> Reevaluates patient after most therapeutic interventions	<input type="checkbox"/> Consistently evaluates the effectiveness of therapies at appropriate intervals
7	Disposition (PC7)	<input type="checkbox"/> Did not achieve Level 1	<input type="checkbox"/> Appropriately selects whether to admit or discharge the patient	<input type="checkbox"/> Appropriately selects whether to admit or discharge Involves the expertise of some of the appropriate specialists	<input type="checkbox"/> Educates the patient appropriately about their disposition Assigns patient to an appropriate level of care (ICU/Tele/Floor) Involves expertise of all appropriate specialists
9	General Approach to Procedures (PC9)	<input type="checkbox"/> Did not achieve Level 1	<input type="checkbox"/> Identifies pertinent anatomy and physiology for a procedure Uses appropriate Universal Precautions	<input type="checkbox"/> Obtains informed consent Knows indications, contraindications, anatomic landmarks, equipment, anesthetic and procedural technique, and potential complications for common ED procedures	<input type="checkbox"/> Determines a back-up strategy if initial attempts are unsuccessful Correctly interprets results of diagnostic procedure

Standardized assessment form for simulation cases. JETem © Developed by: Megan Osborn, MD, MHPE; Shannon Toohey, MD; Alisa Wray, MD
 Wray A. Chest Pain with Acute Coronary Syndrome. JETem 2018. 3(2):S81-99.
<https://doi.org/10.21980/J8K04C>





SIMULATION ASSESSMENT

Chest Pain with Acute Coronary Syndrome

Learner: _____

	Milestone	Did not achieve level 1	Level 1	Level 2	Level 3
20	Professional Values (PROF1)	<input type="checkbox"/> Did not achieve Level 1	<input type="checkbox"/> Demonstrates caring, honest behavior	<input type="checkbox"/> Exhibits compassion, respect, sensitivity and responsiveness	<input type="checkbox"/> Develops alternative care plans when patients' personal beliefs and decisions preclude standard care
22	Patient centered communication (ICS1)	<input type="checkbox"/> Did not achieve level 1	<input type="checkbox"/> Establishes rapport and demonstrates empathy to patient (and family) Listens effectively	<input type="checkbox"/> Elicits patient's reason for seeking health care	<input type="checkbox"/> Manages patient expectations in a manner that minimizes potential for stress, conflict, and misunderstanding. Effectively communicates with vulnerable populations, (at risk patients and families)
23	Team management (ICS2)	<input type="checkbox"/> Did not achieve level 1	<input type="checkbox"/> Recognizes other members of the patient care team during case (nurse, techs)	<input type="checkbox"/> Communicates pertinent information to other healthcare colleagues	<input type="checkbox"/> Communicates a clear, succinct, and appropriate handoff with specialists and other colleagues Communicates effectively with ancillary staff