

A Low Cost Escharotomy Simulation Model for Residency Education

Christopher Sampson, MD^{*}, Catherine D Parker, MD^{*}, Edward Burns, MD[^], Marty Runyan, BSN, RN[†], Dena Higbee, EdS[†] and Timothy Koboldt, MD^{*}

^{*}University of Missouri-Columbia, Department of Emergency Medicine, Columbia, Missouri

[^]St George Hospital, Department of Emergency Medicine, Sydney, Australia

[†]University of Missouri School of Medicine. Columbia, Missouri

Correspondence should be addressed to Christopher Sampson, MD at sampsoncs@health.missouri.edu

Submitted: April 26, 2018; Accepted: May 29, 2018; Electronically Published: July 15, 2018; <https://doi.org/10.21980/J8D34V>

Copyright: © 2018 Sampson, et al. This is an open access article distributed in accordance with the terms of the Creative Commons Attribution (CC BY 4.0) License.

See: <http://creativecommons.org/licenses/by/4.0/>

ABSTRACT:

Audience: This escharotomy model is designed to instruct emergency medicine residents, medical students, and community physicians.

Introduction: Burns account for over 40,000 hospitalizations and 3,400 deaths in the United States each year.¹ Circumferential burns commonly lead to constrictive eschar formation, which may cause underlying tissue ischemia and necrosis.² Escharotomies are a life or limb saving procedure, and therefore proper technique is essential to the training of emergency medicine residents. However, they are an infrequently encountered procedure and consequently are often performed with inadequate tissue decompression as well as incidental damage to the surrounding nerves and vessels.³ Simulation has been demonstrated to be an effective tool in successfully improving resident procedural skills.⁴

Objectives: By the end of this educational session, the learner will be able to: 1) Understand the indications for an escharotomy. 2) List equipment needed to perform an escharotomy. 3) Demonstrate how to perform an escharotomy. 4) Perform an escharotomy and experience the sensation of cutting through simulated burned tissue. 5) Understand post-escharotomy management and referral to specialist.

Methods: Attempts have been made previously to build low cost models for teaching escharotomy. We designed a cost-effective model that could be modified to fit any high or low fidelity simulator. A yoga mat is applied to a mannequin torso and extremities to simulate underlying muscle and is then covered with cloth tape and rubber bands. The final stage of building the model includes charring it to simulate the burned tissue. During the simulation session, learners are then able to realistically feel the sensation of incising through the eschar in order to release the compressive effects of the burned tissue. Underlying intravenous tubing provides realistic bleeding from the incised lower tissues.

Topics: Escharotomy, burn, eschar, emergency procedure.



USER GUIDE

List of Resources:

Abstract	41
User Guide	42
Escharotomy Incision Lines	47
Escharotomy Indications	48

Learner Audience:

Medical students, interns, junior residents, senior residents, attending physicians

Time Required for Implementation:

Each model can be built by most instructors in approximately 60-120 minutes.

In the setting of a high-fidelity simulation case, learners can spend up to 30 minutes using this innovation.

In a dedicated procedure lab, times would likely be 15 minutes for a teaching session followed by performing the procedure.

Recommended Number of Learners per Instructor:

A good ratio would be 1 instructor for every 4-5 learners.

Approximate cost of items to create this innovation:

Total cost of materials was under \$60, and the materials can be used to make multiple models.

Topics:

Escharotomy, burn, eschar, emergency procedure.

Objectives:

By the end of this educational session, the learner will be able to:

1. Understand the indications for an escharotomy.
2. List equipment needed to perform an escharotomy.
3. Demonstrate how to perform an escharotomy.
4. Perform an escharotomy and experience the sensation of cutting through simulated burned tissue.
5. Understand post-escharotomy management and referral to specialist.

Linked objectives and methods:

Escharotomies are a life and limb saving procedure; however, they are infrequently encountered in emergency medicine. Therefore, it is important that emergency medicine residents are appropriately trained in the procedure. Previous studies have shown that simulation is an effective tool for teaching escharotomies. This task trainer allows residents to perform escharotomies in a safe learning environment; it ensures that

they are comfortable with the tools needed to perform the procedure and that the learners experience the sensation of cutting through simulated burned tissue and consider the underlying anatomy to avoid injury to nerves and vessels. During this innovation, the learner demonstrates knowledge of escharotomy and the indications of when to perform the procedure (objective 1). The learner then performs the escharotomy on the model using proper equipment and technique (objectives 2, 3 and 4). Success of the learner in performing the escharotomy will attest to acquired knowledge of the procedure. If used as part of a burn simulation case, knowledge of post-escharotomy management would be reviewed (objective 5).

Recommended pre-reading for instructor:

- Mazzeo AS, Burn care procedures. In: Roberts J, Custalow CB, Thomsen TW, eds. *Robert's and Hedges' Clinical Procedures in Emergency Medicine and Acute Care*. 7th ed. Philadelphia, PA: Elsevier; 2019:774-805.

Learner responsible content (LRC):

- Nickson C. Releasing the Roman breastplate. Life in the Fastlane. <https://lifeinthefastlane.com/trauma-tribulation-005/>. Updated May 24, 2016. Accessed June 1, 2018.
- Noonan M, Baker P. The procedures course podcast-escharotomy. <https://player.fm/series/the-procedures-course-podcast/escharotomy>. Published February 25, 2017. Accessed May 30, 2018.

Associated content:

Escharotomy videos that can be used during teaching session:

- <https://youtu.be/y9yaVT83eGg>
- <https://youtu.be/bHkKFZIOYWY>

Implementation Methods:

This innovation could be combined with a high-fidelity mannequin simulation session or used by itself in a procedure lab or procedural station. If used as part of a high-fidelity mannequin session, the escharotomy could be included with a severe full-thickness burn patient scenario. If included as part of a procedure lab, the model could be used to specifically teach escharotomy and have the learners demonstrate the procedure.

This model could be used for multiple levels of learners. Other possibilities for its use include:

- Assessing learner knowledge of correct escharotomy lines by having them draw their proposed escharotomy lines on the mannequin with a marker pen (e.g., Sharpie). For reference of these lines, see handout 1.



USER GUIDE

- Learners can practice the procedure by incising through the eschar (cloth tape) and rubber band until they reach the healthy tissue underlying represented by the red yoga mat (see video). The incision should spring open once the eschar is divided.
- Practicing running their fingers along the length of the wounds to detect and individually divide any constrictor bands.
- Practicing dressing the wounds (e.g. with cling film) post escharotomy.

List of items required to replicate this innovation:

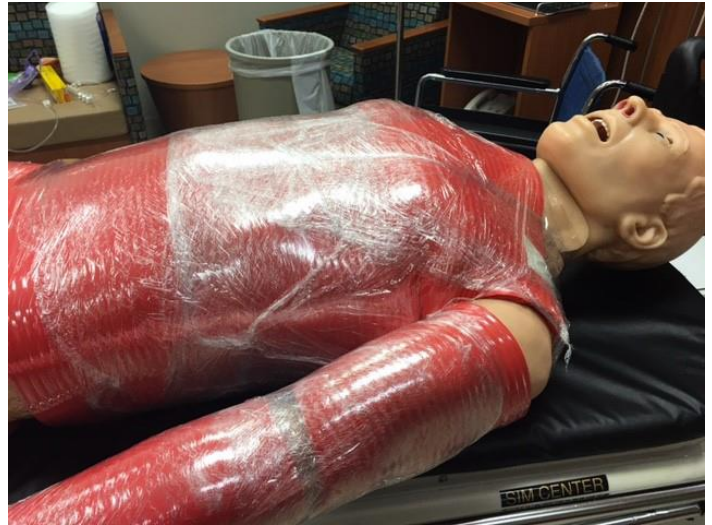1. Two thick foam yoga mats in red or pink color (ordered online, www.amazon.com, for \$16 each)
2. One roll of plastic wrap or cling film (minimum of 100 feet)
3. One roll of packing foam, ¼" thickness and 6" wide (purchased online in 40-foot rolls for \$24)
4. Elastic rubber bands
5. Intravenous tubing
6. Steri-strips to secure tubing
7. 4-5 rolls of medical white cloth tape
8. Butane torch or make-up charcoal
9. Mannequin
10. Punch biopsy tool, 2mm
11. Yellow string
12. Fake blood, available on Amazon.com or from a Halloween store or red food coloring to make red water
13. A large bore stopcock manifold

Detailed methods to construct this innovation:

1. Cut red foam yoga mat into sections and wrap circumferentially around the mannequin's torso and extremities. Tape mat on posterior aspect.



2. Wrap saran wrap and packing foam around the red "muscle" tissue and secure with rubber bands. The red/pink layer represents the viable tissue beneath the eschar which is the end point of the escharotomy procedure.



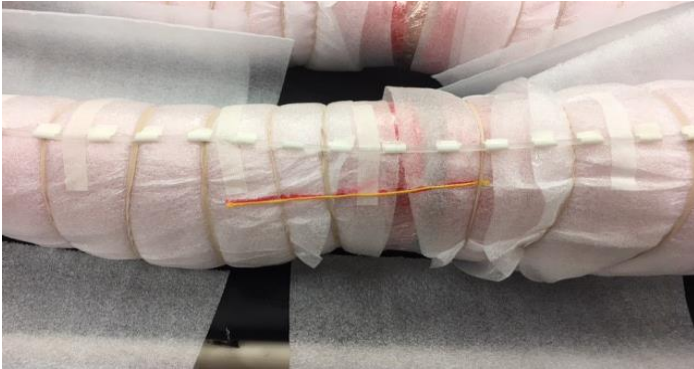3. Wrap white packing foam over the saran wrap. The white packing foam will represent the escharred tissue and will be incised by the learners.



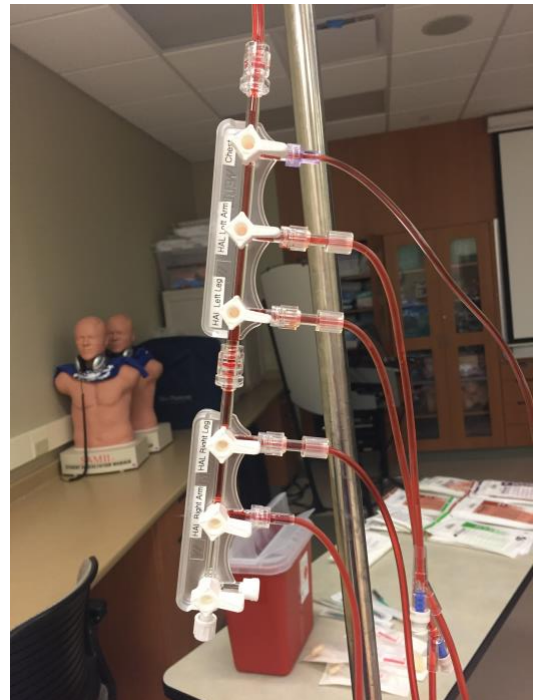


USER GUIDE

4. To simulate bleeding, intravenous (IV) tubing will be used. Punch holes along the tubing in 1-inch increments. We used a 2mm Biopsy Punch to create the holes. Wrap the punch holes with porous cloth tape, lay the tubing along the top of the limbs, and tape in place with Steri-Strips (this is similar to a garden soaker hose and will simulate blood vessels). Glue the yellow string in the appropriate places to represent nerves along the upper and lower extremities.



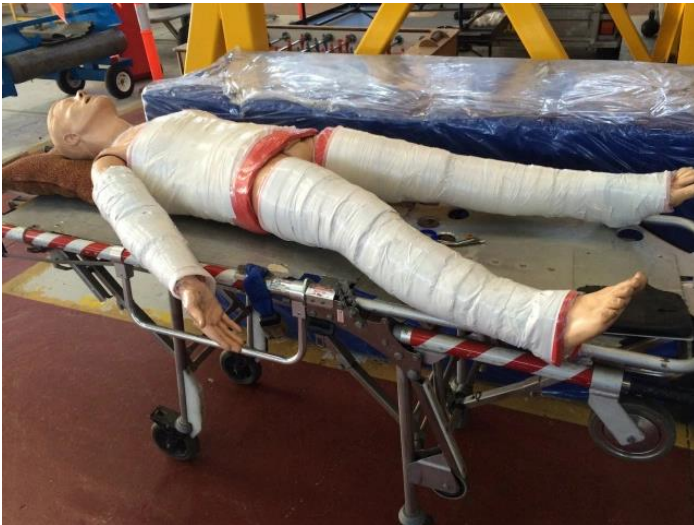5. Attach the IV tubing to a large bore stopcock manifold and label with the locations of the tubing. (i.e., left leg, right arm, chest, etc.) We used 2 three-gang large bore stopcock manifolds connected together and attached directly to the hanging blood bag (Figure 3). For the chest, a circular loop was made, and the end was pulled through the foam packing and red yoga mat in the center of the chest, running the end out past his neck and jaw to the stopcock manifold. This allows for the tubing to remain intact when the escharotomy chest cuts are made. We hung the blood bag from an IV pole and elevated it, allowing gravity to do the work (a pressure bag could be used, if needed). To allow “bleeding,” the instructor will turn the stopcock levers on for the limb the learner is working on. Prime all five tubes prior to start of event by filling the tubes with blood (takes 1-2 minutes at most).



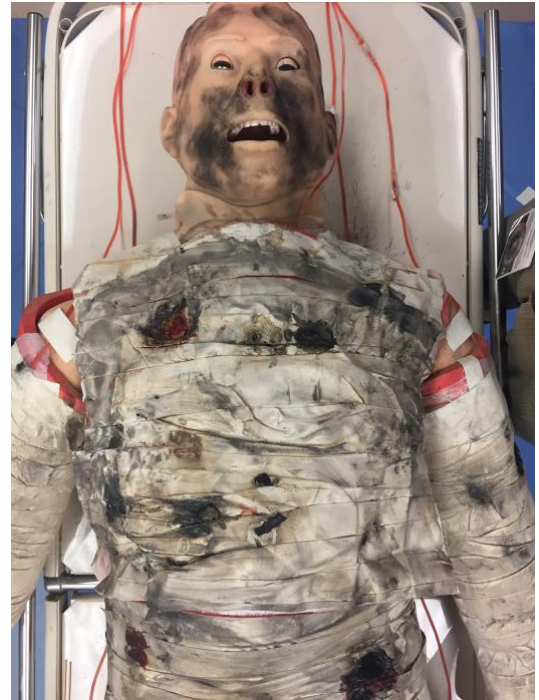
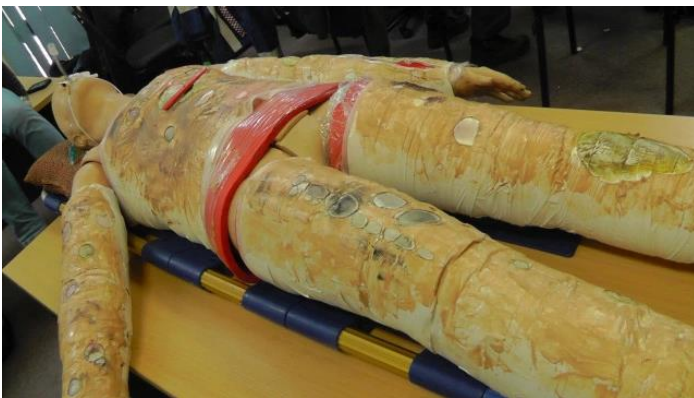
USER GUIDE

- 6. Wrap cloth tape (white, tan, brown) tightly to simulate eschar (restrictive skin). This is an important part of the procedure. The tighter this layer can be applied, the better it will simulate the eschar. The springy foam layers are now compressed by the restrictive tape and will spring apart when incised. Your model is now ready for use. However, step 7 can be performed for more authenticity.



- 7. We used a butane torch to burn the cloth tape and rub ashes and charcoal all over the “skin.” This will produce an unpleasant burned smell as well. Be careful not to burn through your blood tubing. Make-up charcoal can be used as a substitute to simulate charring. The mannequin can now be used for simulation or practical skills teaching.



Results and tips for successful implementation:

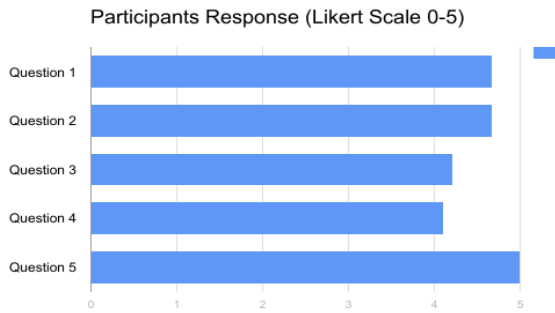
The task trainer was piloted with a total of 21 learners (3 faculty, 14 residents, 2 medical students and 2 physician’s assistant fellows). We asked the participants to answer five questions on a Likert scale at the end of the escharotomy simulation. The Likert scale was defined as 1 strongly disagree, 2 slightly disagree, 3 neutral, 4 slightly agree, and 5 strongly agree. The questions asked were:

Question	Mean	Median
1. This model helped familiarize me with the escharotomy procedure.	4.67	5
2. I am better prepared to perform this procedure.	4.67	5
3. Knowledge from this session will help me in my ED rotations.	4.22	4
4. This model was a good replication of human anatomy.	4.1	4
5. This session enhanced learning better than traditional lectures or reading on escharotomy.	5	5

The response to the survey was overwhelmingly positive with all questions having a mean response from respondents consistent with “slightly agree” or “strongly agree.”



USER GUIDE



This model can be created more quickly with just steps 1, 2, 3, and 6 above. It will not provide the bleeding but will still give learners experience with the “springy” feel of constrictive tissue opening with the escharotomy. However, completing all steps including step 7 will increase realism for learners.

References/suggestions for further reading:

1. Sadideen H, Goutos I, Kneebone R. Burns education: the emerging role of simulation for training healthcare professionals. *Burns*. 2017;43(1):34-40. doi: 10.1016/j.burns.2016.07.012
2. Orgill DP, Piccolo N. Escharotomy and decompressive therapies in burns. *J Burn Care Res*. 2009;30(5):759-768. doi: 10.1097/BCR.0b013e3181b47cd3
3. Ur R, Holmes JH 4th, Johnson JE, Molnar JA, Carter JE. Development of a burn escharotomy assessment tool: a pilot study. *J Burn Care Res*. 2016;37(2): e140-e144. doi: 10.1097/BRC.0000000000000322
4. Pywell MJ, Evgeniou E, Highway K, Pitt E, Estela CM. High fidelity, low cost moulage as a valid simulation tool to improve burns education. *Burns*. 2016;42(4):844-852. doi: 10.1016/j.burns.2015.12.013



INSTRUCTOR MATERIALS

Escharotomy Incision Lines

Lines indicated where to perform the escharotomy incisions and major anatomical structures to avoid

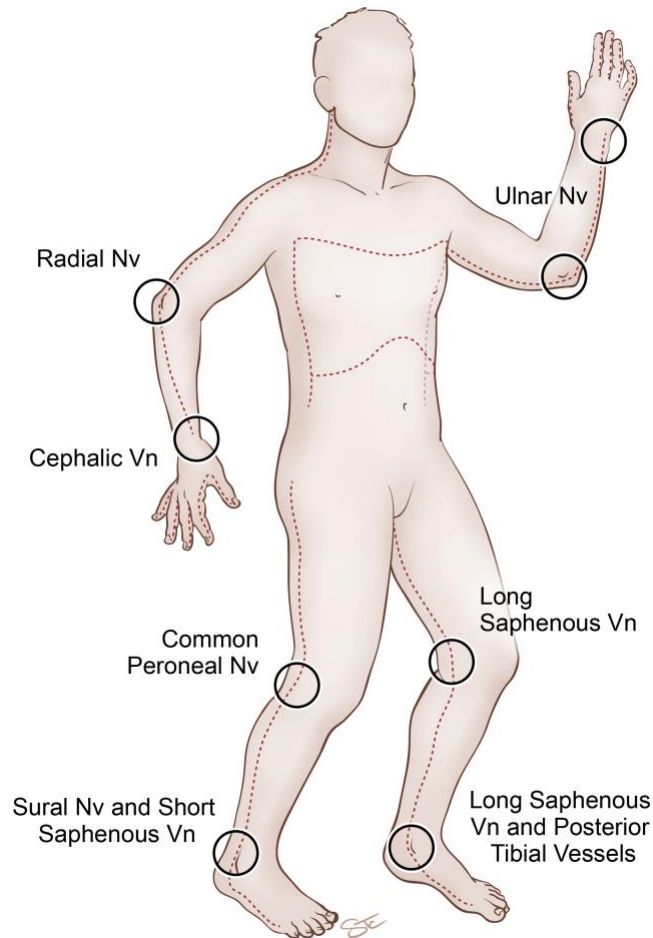


Image source: Stacy Turpin Cheavens, MS, CMI. Escharotomy incisions. University of Missouri Illustrator. Columbia, MO. CC-BY 4.0.



INSTRUCTOR MATERIALS

Escharotomy Indications

Indications for Escharotomy	Burns Effects	Exam Findings
Circumferential Burns of the Chest	Increases chest wall rigidity and impairs ventilation	If intubated, increased peak airway pressures; dyspnea in the awake patient
Circumferential Burns of the Neck	Compromises airway	Increasing difficulty breathing
Circumferential Burns of the Extremities	Leads to development of compartment syndrome	Evidence of decreased circulation in limb; loss of pulses