

Tubo-Ovarian Abscess

Patrick G Meloy, MD*, Amit Bhambri, MD[^] and Megan C Henn, MD*

*Emory University School of Medicine, Department of Emergency Medicine, Atlanta, GA

[^]Swedish Covenant Hospital, Department of Emergency Medicine, Chicago, IL

Correspondence should be addressed to Patrick G Meloy, MD at patrickmeloy@emory.edu

Submitted: May 15, 2018; Accepted: August 29, 2018; Electronically Published: October 15, 2018; <https://doi.org/10.21980/J8Q9Z7>

Copyright: © 2018 Meloy et al. This is an open access article distributed in accordance with the terms of the Creative Commons Attribution (CC BY 4.0) License. See: <http://creativecommons.org/licenses/by/4.0/>

ABSTRACT:

Audience: Emergency medicine residents and medical students on emergency medicine rotations.

Introduction: Tubo-ovarian abscess (TOA) is a relatively common complication of pelvic inflammatory disease (PID). Recent studies have indicated approximately 4.4% of women of reproductive age will develop PID, and of those, 2.3% will go on to develop a TOA.^{1,2} TOA is a gynecologic emergency that requires admission to the hospital, intravenous (IV) antibiotics, and 70% of these patients will require surgical management of the infection.² The etiology is typically polymicrobial, and broad-spectrum antibiotic coverage is recommended. Patients will often present with only pelvic pain; therefore, careful attention to their examination, lab results, and serial evaluations may help elicit the diagnosis. Ultrasound is the diagnostic method of choice for these patients, though computed tomography (CT) imaging and magnetic resonance imaging (MRI) have good sensitivity and specificity, with MRI approaching 89% sensitivity and 95% specificity. Patients who are diagnosed and treated expeditiously often have good resolution of their abscess. Despite this, they have increased likelihood of ectopic pregnancy, infertility, and chronic pelvic pain.

Objectives: At the end of this oral boards session, examinees will: 1) Demonstrate ability to obtain a complete medical history including a detailed sexual history. 2) Demonstrate ability to perform a detailed abdominal and pelvic examination in a female patient presenting with right lower quadrant abdominal pain. 3) Investigate the broad differential diagnoses which include acute appendicitis, colitis, ectopic pregnancy, ovarian torsion, pyelonephritis, ruptured ovarian cyst, pelvic inflammatory disease and acute tubo-ovarian abscess. 4) List the appropriate laboratory and imaging studies to differentiate TOA from other diagnoses (complete blood count [CBC]; complete metabolic panel [CMP]; pregnancy test; CT scan and/or pelvic ultrasonography). 5) Identify a septic patient and manage appropriately: obtain sepsis markers such as lactic acid, provide early treatment for sepsis including obtaining blood cultures, administer adequate IV hydration and appropriate antibiotics. 6) Provide appropriate disposition to the hospital after consulting with gynecology

ORALboards

Method: Oral boards case.

Topics: Tubo-ovarian abscess, pelvic pain, abdominal pain, pelvic infections, gynecologic emergencies, sexually transmitted infections.



USER GUIDE

List of Resources:

Abstract	1
User Guide	3
For Examiner Only	5
Oral Boards Assessment	10
Stimulus	13
Debriefing and Evaluation Pearls	26

Learner Audience:

Medical Students, Interns, Junior Residents, Senior Residents

Time Required for Implementation:

Case: 15 minutes if used as a single case, approximately 10 minutes if part of a triple case

Debriefing: 5-10 minutes

Learners per instructor:

Recommend 1 learner per instructor if using as an oral boards case, may have other learners present to observe.

Topics:

Tubo-ovarian abscess, pelvic pain, abdominal pain, pelvic infections, gynecologic emergencies, sexually transmitted infections.

Objectives:

At the end of this oral boards session, examinees will:

1. Demonstrate ability to obtain a complete medical history including a detailed sexual history.
2. Demonstrate ability to perform a detailed abdominal and pelvic examination in a female patient presenting with right lower quadrant abdominal pain.
3. Investigate the broad differential diagnoses which include acute appendicitis, colitis, ectopic pregnancy, ovarian torsion, pyelonephritis, ruptured ovarian cyst, pelvic inflammatory disease and acute tubo-ovarian abscess.
4. List the appropriate laboratory and imaging studies to differentiate TOA from other diagnoses (complete blood count [CBC]; complete metabolic panel [CMP]; pregnancy test; CT scan and/or pelvic ultrasonography).
5. Identify a septic patient and manage appropriately: obtain sepsis markers such as lactic acid, provide early treatment for sepsis including obtaining blood cultures, administer adequate IV hydration and appropriate antibiotics.
6. Provide appropriate disposition to the hospital after consulting with gynecology.

Linked objectives, methods and results:

The learner in this case must be able to synthesize available historical and physical examination (Objectives 1 and 2) data in order to develop a broad list of differential diagnoses for a female presenting with pelvic pain (Objective 3). Though PID and TOA are often a continuum, the final diagnosis may be missed if the learner does not perform a complete exam and obtain ancillary studies (Objective 4). The oral board formatting allows the learner to synthesize real-time data in order to differentiate a TOA from PID or a sexually transmitted infection (STI) or an ectopic pregnancy. The learner must be able to identify the septic patient and provide timely and appropriate treatment and disposition to prevent morbidity (Objectives 5 and 6). Debriefing of the case immediately afterward ensures assimilation of the sources of data in order to obtain the correct diagnosis in future clinical cases.

Recommended pre-reading for instructor:

- Any resource reviewing tubo-ovarian abscesses.

Results and tips for successful implementation:

This case is best used for oral boards assessment and training. It is presented here as a single case, but can also be integrated into a triple-case format. This case has been found to be challenging for junior residents because the final diagnosis is often missed due to lack of recognition of systemic inflammatory response syndrome (SIRS) and sepsis, which leads to lack of imaging. This case has been trialed with over 20 learners, and the challenge was in obtaining the appropriate physical exam findings. Medical students often missed cues to perform gynecologic examinations and interpreted the vital signs incorrectly more often than residents. Junior residents and medical students found this a challenging case due to lack of clinical experience with these patients, but found it beneficial to practice challenging cases in a safe, simulated environment. Providing correct antibiotic coverage was challenging for all learners, as PID is often discharged home, and junior and senior learners were not familiar with the appropriate IV antibiotic regimen.

References/suggestions for further reading:

1. Kreisel K, Torrone E, Bernstein K, Hong J, Gorwitz R. Prevalence of pelvic inflammatory disease in sexually experienced women of reproductive age — United States, 2013–2014. *MMWR Morb Mortal Wkly Rep.* 2017; 66:80–83. doi: 10.15585/mmwr.mm6603a3
2. Kairys N, Roepke C. Abscess, tubo-ovarian. In: StatPearls [Internet]. Treasure Island (FL): StatPearls Publishing. <https://www.ncbi.nlm.nih.gov/books/NBK448125>. Updated October 13, 2017. Accessed August 27, 2018.
3. Gardella C, Eckert L, Lentz G. Genital tract infections: Vulva, vagina, cervix, toxic shock syndrome, endometritis, and salpingitis. In Lobo R, Gershenson D, Lentz G, Valea F, eds.



USER GUIDE

Comprehensive Gynecology. 7th ed. Philadelphia, PA:
Elsevier; 2017:524-565.

4. Pelvic inflammatory disease (PID) - 2015 STD treatment guidelines. Centers for Disease Control and Prevention. <https://www.cdc.gov/std/tg2015/pid.htm>. Updated June 4, 2015. Accessed August 27, 2018.



Oral Case Summary

Diagnosis: Tubo-ovarian abscess

Case Summary: This is a case of a young, female patient, who experiences abdominal pain and vomiting. She has had malodorous vaginal discharge and has adnexal tenderness on examination. She is found to have a tubo-ovarian abscess. She meets sepsis criteria, and requires IV fluid rehydration and pain medication, as well as early initiation of IV antibiotics once the diagnosis is made. She needs gynecologic consultation and admission onto the gynecology service.

Order of Case: This is a case of a moderately ill patient, meeting sepsis criteria, who has developed a tubo-ovarian abscess (TOA). She has concerning features for possible appendicitis, ovarian torsion, and other intra-abdominal processes; a complete history, including sexual history, as well as physical examination that includes a pelvic/bimanual exam should be performed. If the patient does not receive IV fluid resuscitation, pain medication and antipyretics, she will develop worsening tachycardia and hypotension, which will require systemic vasopressors and intensive care unit (ICU) admission. She should ideally undergo ultrasound imaging, which will reveal a TOA, which requires IV antibiotics, fluid resuscitation, and gynecology consultation and admission. If ultrasound is not obtained, the patient will likely undergo CT scan, but the radiologist will simply note an unusual right lower quadrant mass but be unable to further characterize the findings, except that the appendix appears normal. A pelvic ultrasound should be obtained for appropriate clarification of the abscess. Ultimately, the patient should be admitted to the hospital with a gynecology consultation. Sending the patient home would be considered a dangerous action and would result in failure of the case.

Disposition: Admission

Critical Actions:

1. Intravenous (IV) fluid resuscitation and pain control
2. Full history and physical examination, including pelvic examination
3. Pregnancy test
4. Pelvic imaging, preferably ultrasound
5. Broad-spectrum parenteral antibiotics
6. Gynecology consultation and admission



FOR EXAMINER ONLY

Historical Information

Chief Complaint: Abdominal pain

History of present illness: This is a 25-year-old female patient with no significant past medical history who presents with abdominal pain. Her pain is located in the right lower quadrant of her abdomen. She states that it started approximately five days prior to arrival. It was initially dull and crampy but is now a sharp pain that radiates to her back. She has had two episodes of non-bilious, non-bloody vomiting. She has felt “hot-and-cold” at home, but has not taken her temperature.

She denies headache, chest pain, cough, difficulty breathing, and other associated complaints. IF ASKED DIRECTLY, patient has noticed yellow-green vaginal discharge that is malodorous, and started one week ago. She denies any recent antibiotic use. She is sexually active with more than one partner, and intermittently uses condoms as protection.

Last Menstrual Period: 2 weeks ago, G3P0AB3

Past Medical history: Admits to gonorrhea if asked about sexual history

Past Surgical history: None

Patients Medications: None

Allergies: Penicillin, gets a rash if asked about reaction

Social history:

- Smoking: Drinks socially
- Tobacco: Vapes daily
- Drug use: Smokes marijuana socially

Family history: Non-contributory



FOR EXAMINER ONLY

Physical Exam Information

Vitals: HR 113 BP 101/51 RR 22 Temp 38.9°C O₂Sat 99% on room air

General appearance: Awake, alert, in moderate distress from pain

Primary survey:

- **Airway:** Intact, speaking in complete sentences
- **Breathing:** Breath sounds clear bilaterally, no cyanosis
- **Circulation:** Tachycardic, intact peripheral pulses, vitals as above

Physical examination:

- **General appearance:** Awake, alert, answering questions, appears uncomfortable secondary to pain
- **HEENT:**
 - **Head:** Within normal limits
 - **Eyes:** Within normal limits
 - **Ears:** Within normal limits
 - **Nose:** Within normal limits
 - **Throat:** Mucous membranes dry, otherwise unremarkable
- **Neck:** Within normal limits
- **Chest:** Tachypneic, lungs clear bilaterally, no wheezes, crackles or rales
- **Cardiovascular:** Tachycardic, otherwise unremarkable heart tones
- **Abdominal/GI:** Soft, tenderness concentrated in the RLQ, voluntary guarding in the RLQ, normal bowel sounds, negative psoas sign, negative obturator sign
- **Genitourinary:** Normal external genitalia; thick, yellow-green vaginal discharge, cervical os is closed and friable, no blood in the vaginal vault, + cervical motion tenderness, + right adnexal tenderness, negative left adnexal tenderness, no masses palpated bilaterally
- **Rectal:** Normal tone, guaiac negative with brown stool (if requested)
- **Extremities:** Within normal limits
- **Back:** no costovertebral angle tenderness bilaterally
- **Neuro:** Within normal limits
- **Skin:** Within normal limits
- **Lymph:** Tender femoral nodes bilaterally
- **Psych:** Within normal limits



FOR EXAMINER ONLY

Critical Actions and Cueing Guidelines

1. **Critical Action 1: Intravenous fluid resuscitation and pain control. This is a patient who meets SIRS criteria upon initial assessment, and should receive pain medications while completing workup.**
 - a. Cueing Guideline (if applicable):
Examiner may say, “The nurse caring for the patient started an IV in triage, would you like to give anything?”

2. **Critical Action 2: Full history and physical exam, including pelvic and bimanual exam, and pregnancy test, should be obtained. This is important to emphasize in female patients with lower abdominal and pelvic pain. Gynecologic examination is important, especially in a patient with undifferentiated pain, fever, and tachycardia.**
 - a. Cueing Guideline (if applicable):
Examiner may state, “The nurse caring for the patient apologies that there are no gynecologic rooms available, but the patient can be set-up for an exam if you request it.”

3. **Critical Action 3: Pregnancy test should be obtained to rule out ectopic pregnancy. This is important in any female patient with pelvic pain and abnormal vitals.**
 - a. Cueing Guideline (if applicable):
Examiner may state, “The nurse wants to know if you want any other blood or urine tests.”

4. **Critical Action 4: Abdominal/pelvic imaging should be obtained, preferably a pelvic ultrasound due to age and physical exam. This is preferred in childbearing aged females, and will better characterize the lesion in question.**
 - a. Cueing Guideline (if applicable):
If the learner attempts to discharge the patient without imaging, the patient may ask, “How do you know it’s not my appendix? Also, my mom had ovarian cysts; how do I find out if I have that?”

5. **Critical Action 5: Broad-spectrum parenteral antibiotics are indicated in a patient who meets sepsis criteria, with a known pelvic abscess. This is standard of care, and should be considered a dangerous action if not provided.**
 - a. Cueing Guideline (if applicable):



FOR EXAMINER ONLY

There is no applicable cueing guideline; this is a minimum standard of care for this patient.

6. **Critical Action 6: The patient should have a bedside consultation by gynecology and should be admitted onto their service for parenteral antibiotics and possible surgical management.**
 - a. Cueing Guideline (if applicable):
If the learner attempts to admit to a medical service, the examiner may state, “Does this patient have anything surgical on imaging? We don’t have interventional radiology, so it will be hard for us to manage this case.”



ORAL BOARDS ASSESSMENT

Tubo-Ovarian Abscess

Learner: _____

Critical Actions:

- IV fluids resuscitation and pain control
- Full history and physical examination, including pelvic examination
- Pregnancy test
- Pelvic imaging, preferably ultrasound
- Broad-spectrum parenteral antibiotics
- Gynecology consultation and admission

Summative and formative comments:

Milestone assessment:

	Milestone	Did not achieve level 1	Level 1	Level 2	Level 3
1	Emergency Stabilization (PC1)	<input type="checkbox"/> Did not achieve Level 1	<input type="checkbox"/> Recognizes abnormal vital signs	<input type="checkbox"/> Recognizes an unstable patient, requiring intervention Performs primary assessment Discerns data to formulate a diagnostic impression/plan	<input type="checkbox"/> Manages and prioritizes critical actions in a critically ill patient Reassesses after implementing a stabilizing intervention
2	Performance of focused history and physical (PC2)	<input type="checkbox"/> Did not achieve Level 1	<input type="checkbox"/> Performs a reliable, comprehensive history and physical exam	<input type="checkbox"/> Performs and communicates a focused history and physical exam based on chief complaint and urgent issues	<input type="checkbox"/> Prioritizes essential components of history and physical exam given dynamic circumstances



ORAL BOARDS ASSESSMENT

Tubo-Ovarian Abscess

Learner: _____

	Milestone	Did not achieve level 1	Level 1	Level 2	Level 3
3	Diagnostic studies (PC3)	<input type="checkbox"/> Did not achieve Level 1	<input type="checkbox"/> Determines the necessity of diagnostic studies	<input type="checkbox"/> Orders appropriate diagnostic studies Performs appropriate bedside diagnostic studies/procedures	<input type="checkbox"/> Prioritizes essential testing Interprets results of diagnostic studies Considers risks, benefits, contraindications, and alternatives to a diagnostic study or procedure
4	Diagnosis (PC4)	<input type="checkbox"/> Did not achieve Level 1	<input type="checkbox"/> Considers a list of potential diagnoses	<input type="checkbox"/> Considers an appropriate list of potential diagnosis May or may not make correct diagnosis	<input type="checkbox"/> Makes the appropriate diagnosis Considers other potential diagnoses, avoiding premature closure
5	Pharmacotherapy (PC5)	<input type="checkbox"/> Did not achieve Level 1	<input type="checkbox"/> Asks patient for drug allergies	<input type="checkbox"/> Selects an appropriate medication for therapeutic intervention, considering potential adverse effects	<input type="checkbox"/> Selects the most appropriate medication(s) and understands mechanism of action, effect, and potential side effects Considers and recognizes drug-drug interactions
6	Observation and reassessment (PC6)	<input type="checkbox"/> Did not achieve Level 1	<input type="checkbox"/> Reevaluates patient at least one time during the case	<input type="checkbox"/> Reevaluates patient after most therapeutic interventions	<input type="checkbox"/> Consistently evaluates the effectiveness of therapies at appropriate intervals
7	Disposition (PC7)	<input type="checkbox"/> Did not achieve Level 1	<input type="checkbox"/> Appropriately selects whether to admit or discharge the patient	<input type="checkbox"/> Appropriately selects whether to admit or discharge Involves the expertise of some of the appropriate specialists	<input type="checkbox"/> Educates the patient appropriately about their disposition Assigns patient to an appropriate level of care (ICU/Tele/Floor) Involves expertise of all appropriate specialists



ORAL BOARDS ASSESSMENT

Tubo-Ovarian Abscess

Learner: _____

	Milestone	Did not achieve level 1	Level 1	Level 2	Level 3
22	Patient centered communication (ICS1)	<input type="checkbox"/> Did not achieve level 1	<input type="checkbox"/> Establishes rapport and demonstrates empathy to patient (and family) Listens effectively	<input type="checkbox"/> Elicits patient's reason for seeking health care	<input type="checkbox"/> Manages patient expectations in a manner that minimizes potential for stress, conflict, and misunderstanding.
23	Team management (ICS2)	<input type="checkbox"/> Did not achieve level 1	<input type="checkbox"/> Recognizes other members of the patient care team during case (nurse, techs)	<input type="checkbox"/> Communicates pertinent information to other healthcare colleagues	<input type="checkbox"/> Communicates a clear, succinct, and appropriate handoff with specialists and other colleagues Communicates effectively with ancillary staff



Stimulus Inventory

- #1 Patient Information Form
- #2 Arterial blood gas
- #3 Lactic acid
- #4 Complete blood count with differential
- #5 Basic metabolic panel
- #6 Urinalysis
- #7 Pregnancy test
- #8 Chest x-ray
- #9 CT scan image (axial)
- #10 CT scan image (coronal)
- #11 Ultrasound image (pelvic, transabdominal)
- #12 Ultrasound image (abdomen, right lower quadrant)



Stimulus #1

Patient Information

Patient's Name: Gina Martin
Age: 25
Gender: Female
Chief Complaint: Abdominal pain
Person Providing History: Patient

Vital Signs:
Temp: 38.9°C (102°F)
BP: 101/51 mm Hg
P: 113
RR: 22
Pulse Ox: 99% (room-air)



Stimulus #2

Arterial Blood Gas

pH	7.35
pCO₂	41 mmHg
pO₂	88 mmHg
HCO₃	22 mEq/L
O₂ sat	97%



Stimulus #3

Lactic Acid

3.4 mmol/L



Stimulus #4

Complete Blood Count (CBC)

White blood cell count (WBC) 15.9 x1000/mm³

Hemoglobin (Hgb) 12.2 g/dL

Hematocrit (Hct) 44.3%

Platelets 329 x1000/mm³

Differential

Neutrophils 65%

Lymphocytes 22%

Monocytes 3%

Eosinophils 1%

Bands 9%



Stimulus #5

Basic Metabolic Panel (BMP)

Sodium	143 mEq/L
Potassium	3.9 mEq/L
Chloride	109 mEq/L
Carbon Dioxide (CO₂)	23 mEq/L
Blood Urea Nitrogen (BUN)	18 mg/dL
Creatinine (Cr)	1.3 mg/dL
Glucose	128 mg/dL



Stimulus #6

Urinalysis

Appearance	Hazy
Color	Yellow
Glucose	Negative
Ketones	1+
Sp Gravity	1.030
Blood	Negative
pH	7.5
Protein	Negative
Nitrite	Negative
Leukocyte	Negative
WBC	3-5/hpf
Red blood cells (RBC)	1-2/hpf
Squamous Cells	20-30/hpf
Bacteria	1-2/hpf



Stimulus #7

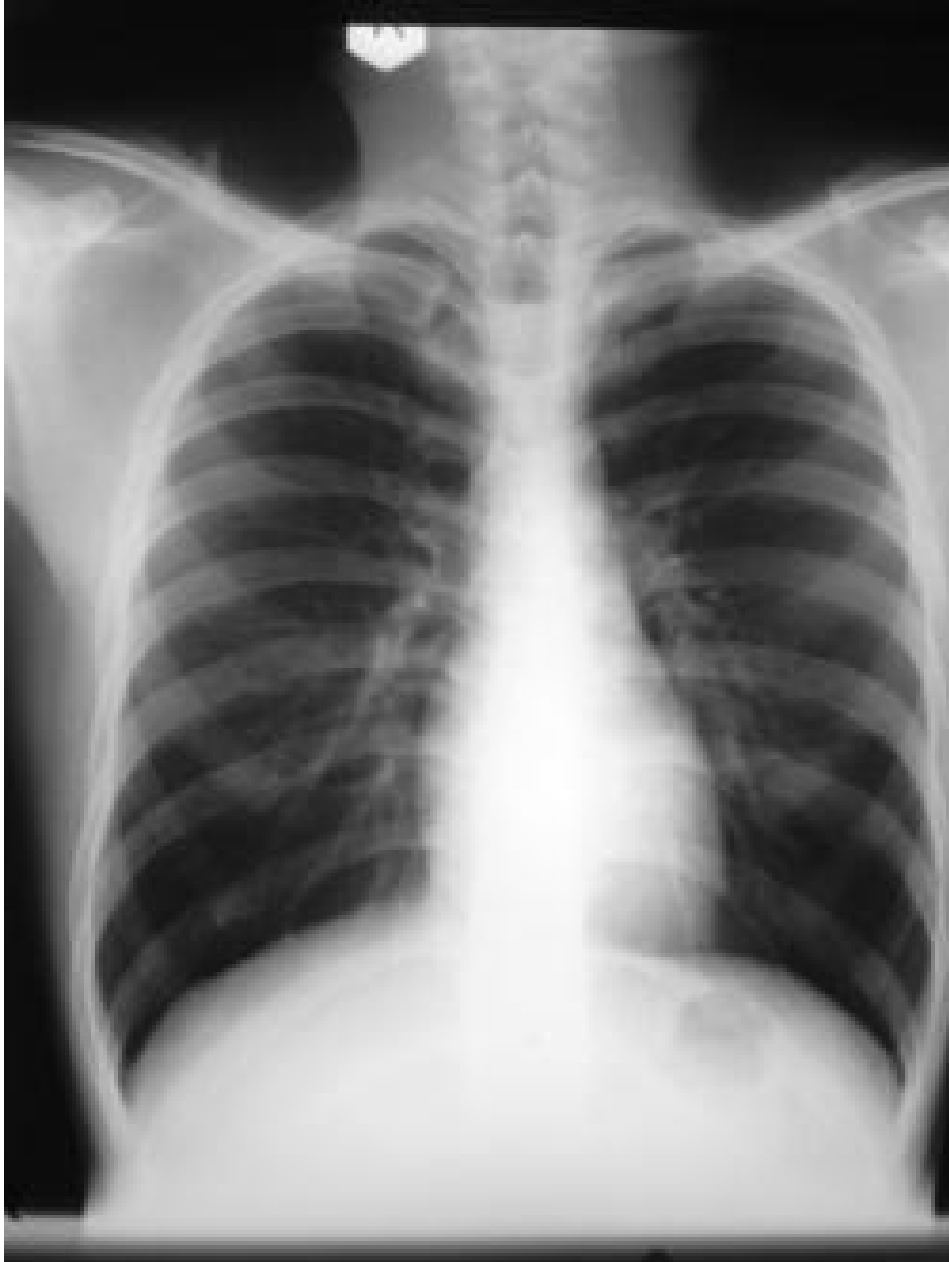Pregnancy test:

Negative



Stimulus #8

Chest X-ray

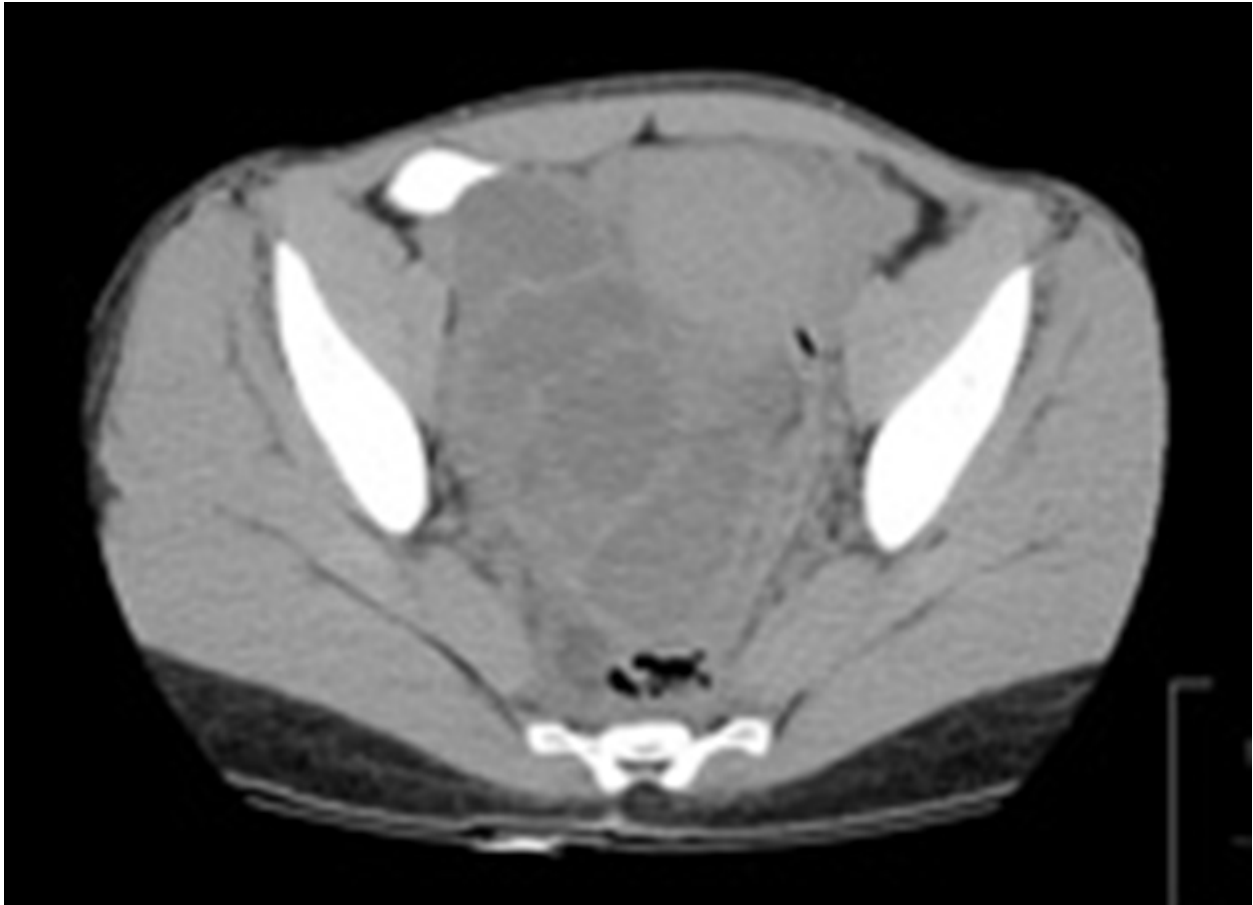


Author's own image



Stimulus #9

Computed Tomography Axial Image

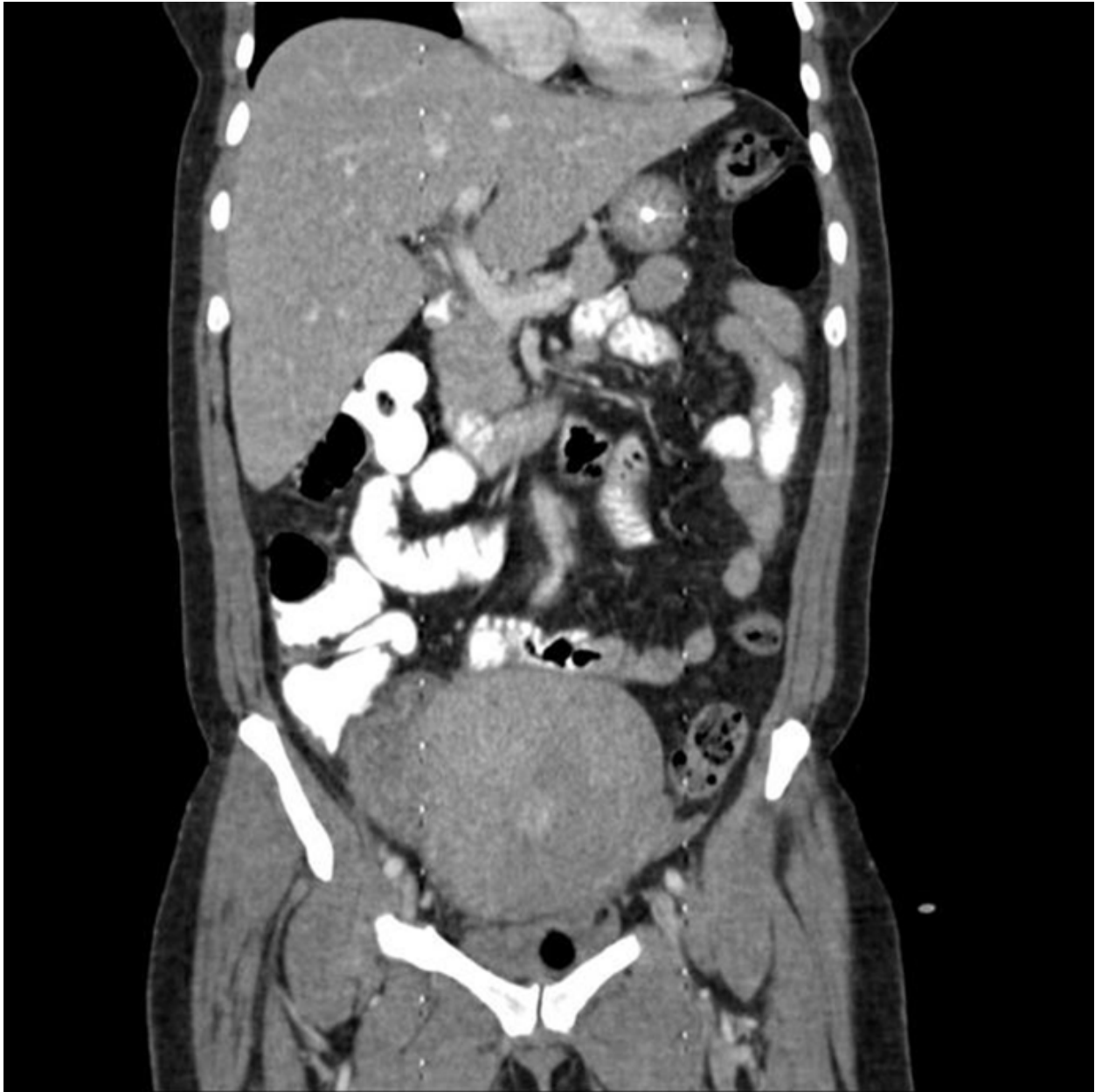

Author's own image



Stimulus #10

Computed Tomography Coronal Image



Author's own image



Stimulus #11

Ultrasound image (pelvic, transabdominal)

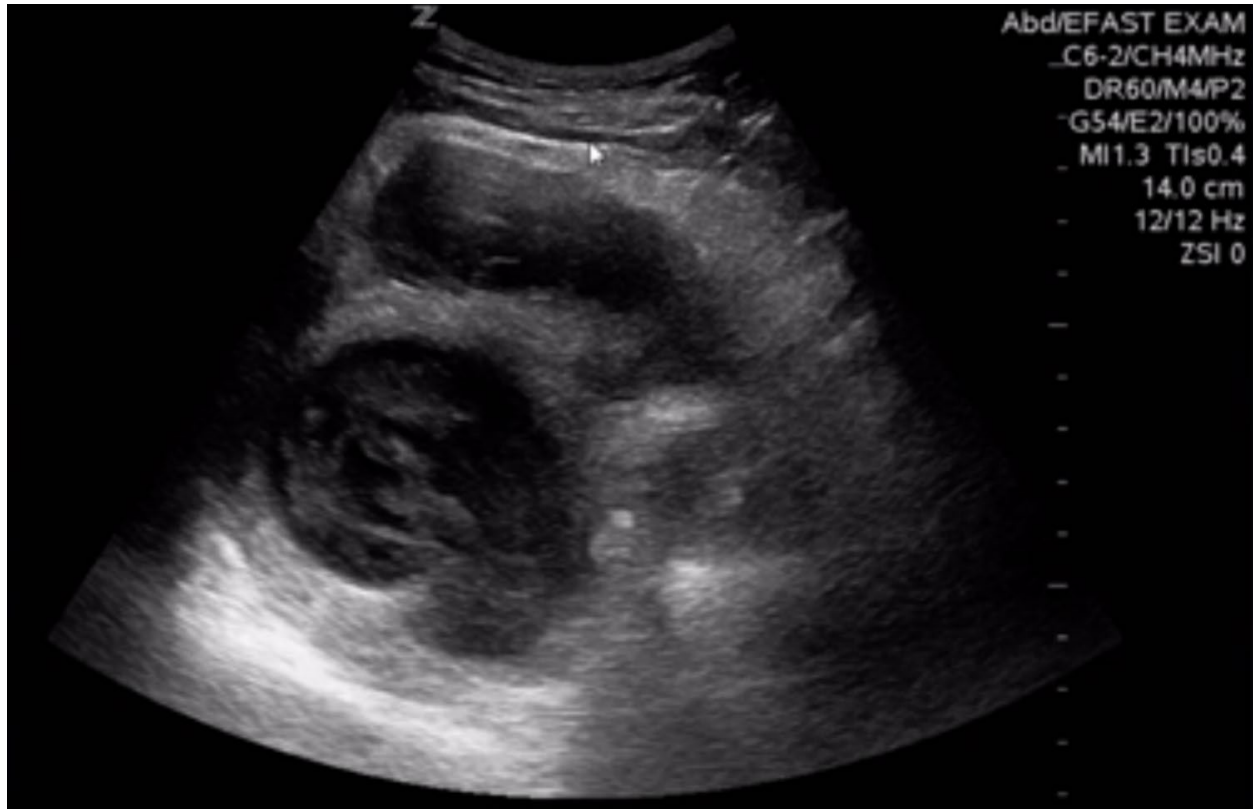


Image courtesy of: Macias M. Ultrasound leadership academy: The basics of pelvic transabdominal ultrasound. In: EM Curious. <http://www.emcurious.com/blog-1/2015/1/8/ultrasound-leadership-academy-the-basics-of-pelvic-transabdominal-ultrasound>. Published January 9, 2015. Accessed August 27, 2018. CC BY 4.0.



Stimulus #12

Ultrasound image (abdomen, right lower quadrant)

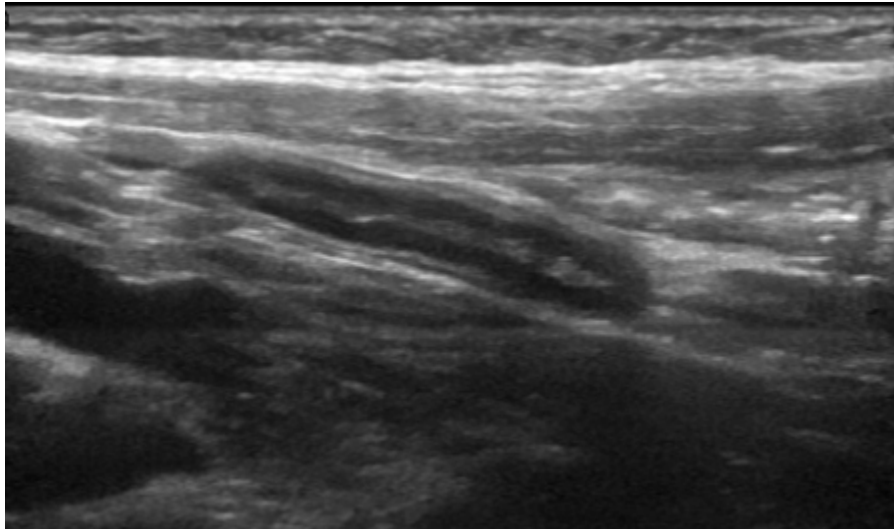


Image courtesy of: Ultrasoundpaedia Pty Limited: Ultrasound of the appendix - normal. <https://www.ultrasoundpaedia.com/normal-appendix/>. Published 2018. Accessed September 4, 2018.



DEBRIEFING AND EVALUATION PEARLS

Tubo-Ovarian Abscess

1. The diagnosis of PID (pelvic inflammatory disease) is imprecise because the clinical presentation varies significantly and depends on the pelvic and bimanual exam. PID treatment is indicated if one or more of the minimum criteria are present: cervical motion tenderness, uterine tenderness, adnexal tenderness.
2. All women with PID should be tested for human immunodeficiency virus (HIV), gonorrhea, chlamydia, and pregnancy.
3. Incidence of adnexal abscess is approximately 2.3% in women with acute PID. Different from other abscesses, a tubo-ovarian abscess is a collection of pus that forms in the anatomic space that is created by adherent adjacent organs, often caused by acute PID. These abscesses are often poly-microbial in nature but dominated by anaerobic organisms.
4. Transvaginal ultrasonography is the diagnostic imaging of choice in childbearing women with concern for pelvic infection and to identify pelvic masses. Ultrasound is low cost and does not expose the patient to ionizing radiation. Though ultrasound cannot determine the cause of the mass, it has a sensitivity of 75% to 82%. Early antibiotic coverage is critical to attempt to reduce the long-term sequelae of the disease. The goal is to resolve symptoms and protect tubal function. Women who are not treated in the first 72 hours are three times as likely to have tubal infertility or ectopic pregnancy.
5. Antibiotics for empiric treatment should be initiated early and have broad coverage, including *N. gonorrhoeae*, *C. trachomatis*, anaerobic rods and cocci, gram-negative aerobic rods, enterococcus, and gram-positive aerobes. Clindamycin, ampicillin, and an aminoglycoside are the standard of care for treatment of tubo-ovarian abscesses. (see CDC guidelines for alternative regimens).
6. Also important in the treatment for PID is the testing and treatment of sexual partners within the last 60 days preceding onset of symptoms and abstinence or barrier method contraception until the completion of treatment for both partners.
7. Hospitalization is indicated in the case of tubo-ovarian abscess for parenteral administration of antibiotics as well as follow-up imaging. Hospitalization is also indicated in the case of pelvic inflammatory disease associated with pregnancy, severe illness including nausea, vomiting, and fever, inability to tolerate oral antibiotics, or no response to oral antibiotics.
8. Consultation with the gynecology team is indicated in all patients with a tubo-ovarian abscess. Transvaginal or transabdominal percutaneous aspiration or drainage of the



DEBRIEFING AND EVALUATION PEARLS

abscess can be done under computed tomography (CT) guidance, or laparoscopic aspiration of the abscess can be performed in addition to medical management.