

Corneal Rust Ring

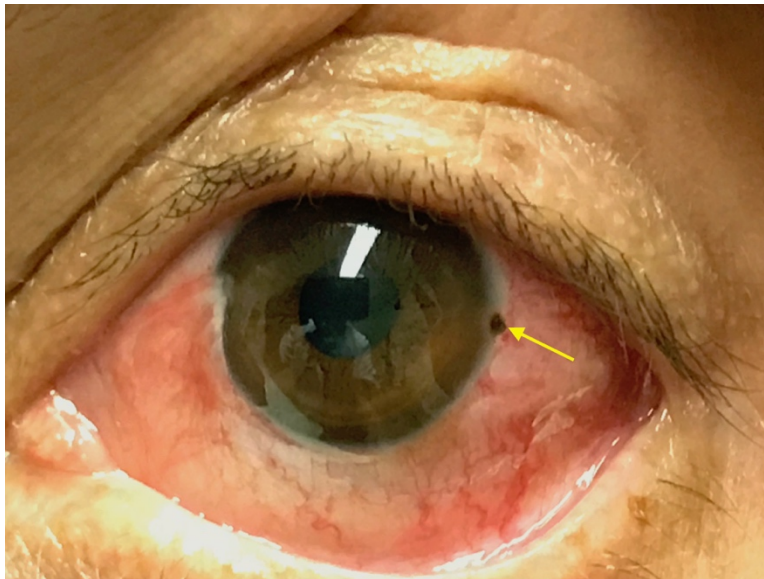
Joseph Zakaria, BS* and Jonathan Peña, MD*

*University of California, Irvine, Department of Emergency Medicine, Orange, CA

Correspondence should be addressed to Jonathan Peña, MD at jdpena@uci.edu

Submitted: April 27, 2018; Accepted: July 25, 2018; Electronically Published: October 15, 2018; <https://doi.org/10.21980/J8X067>

Copyright: © 2018 Peña. This is an open access article distributed in accordance with the terms of the Creative Commons Attribution (CC BY 4.0) License. See: <http://creativecommons.org/licenses/by/4.0/>



History of present illness: A 50-year-old male presented to the emergency department after developing sudden onset, severe, sharp left eye (OS) pain while grinding metal. Although he was wearing protective goggles, he endorsed a foreign body sensation, eye redness, and watery discharge. He denied any contact lens or eyeglasses use. He otherwise felt well and denied fevers, nausea, changes in urination, joint pain, and rash. His visual acuity was 20/20 OS. Initial fluorescein dye test demonstrated a negative Seidel test.

Significant findings: The photograph reveals a limbic metallic foreign body with a surrounding corneal rust ring (arrow) in the three o'clock position of the left cornea.

Discussion: Eye complaints represent roughly three percent of emergency department visits.¹ With eye foreign bodies, one must be cognizant of the possibility of accompanying penetrating ocular trauma which leads to increased ocular morbidity.² If globe rupture is suspected, it is imperative that the physician put an eye shield over the affected eye, refrain from assessing intraocular pressures, and hold off on direct

examination via ultrasound in order to not apply pressure on the tissue until rupture is ruled out.³ Corneal rust rings can arise hours after metallic foreign bodies become lodged in the cornea because of oxidation of iron in the foreign body. Several methods for removing corneal rust rings exist. One procedure typically done by ophthalmologists involves removing the ring at the same time as the foreign body via a rotating burr.⁴ Another option is using a 25 gauge needle to remove the rust ring.⁴ Studies have shown that the dental burr rotated by an electric drill is the safest, most efficient treatment and preferred over manual extraction because it leads to quicker pain relief and allows for complete removal in a single treatment.⁵ An alternative method involves delayed removal of the rust ring. This method is based on the idea that the iron of the corneal rust ring will kill epithelial cells over 24-48 hours allowing deeper rings to rise closer to the surface, thus allowing for easier removal.¹

In this patient, the foreign body was removed in the emergency room by the ophthalmologist, and he was given ofloxacin eyedrops to protect against secondary infection from the corneal abrasion. Three days later he was followed up in the eye clinic and the corneal rust ring was removed using a diamond burr and 30-gauge needle.

Topics: Corneal rust ring, foreign body, ophthalmology.

References:

1. Alteveer J. Eye Pain, redness and visual loss. In: Mahadevan, Swaminatha V, Gus M. Garmel. *An Introduction to Clinical Emergency Medicine*. 2nd ed. Cambridge: Cambridge University Press; 2012:357-373.
2. Ehlers JP, Kunimoto DY, Ittoop S, et al. Metallic intraocular foreign bodies: characteristics, interventions, and prognostic factors for visual outcome and globe survival. *Am J Ophthalmol*. 2008; 146:427-433. doi: 10.1016/j.ajo.2008.05.021
3. Pokhrel PK, Loftus SA. Ocular emergencies. *Am Fam Physician*. 2007;76(6):829-836.
4. Knoop K, Dennis W. Ophthalmologic procedures. In: Roberts JR, Custalow CB, Thomsen TW, Hedges JR, eds. *Roberts and Hedges' Clinical Procedures in Emergency Medicine*. 6th ed. Philadelphia, Pa: Saunders; 2014: 1259-1297.
5. Brown N, Clemett R, Grey R. Corneal rust removal by electric drill. Clinical trial by comparison with manual removal. *Br J Ophthalmol*.1975;59:586-589.