

## Abdominal Pain with Black Tongue

David A Adler, MD\* and Isabel M Algaze Gonzalez, MD^

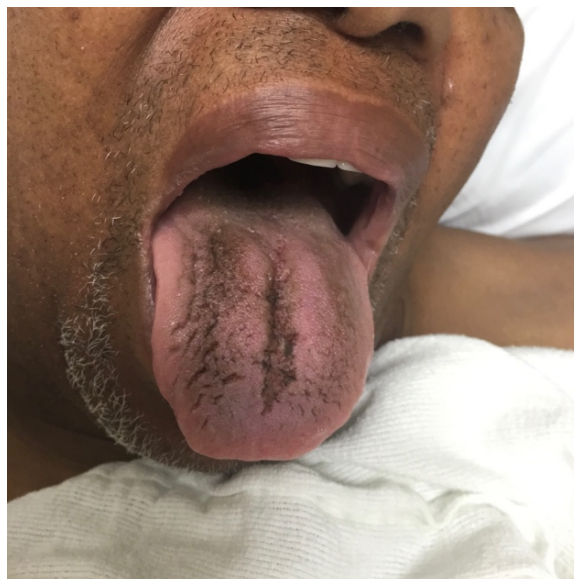
\*University of California, Irvine, Department of Family Medicine, Orange, CA

^University of California, Irvine, Department of Emergency Medicine, Orange, CA

Correspondence should be addressed to Isabel M Algaze Gonzalez, MD at [ialgaze@uci.edu](mailto:ialgaze@uci.edu)

Submitted: July 20, 2018; Accepted: September 9, 2018; Electronically Published: January 15, 2019; <https://doi.org/10.21980/J8XS7J>

Copyright: © 2019 Adler, et al. This is an open access article distributed in accordance with the terms of the Creative Commons Attribution (CC BY 4.0) License. See: <http://creativecommons.org/licenses/by/4.0/>



**History of present illness:** A 59-year-old African American man with a past medical history of non-Hodgkin's lymphoma, status-post chemotherapy, bone marrow transplant, and congestive heart failure, presented with 8/10 abdominal pain which had minimal improvement despite significant use of bismuth subsalicylate (Pepto-Bismol) and other antacids.

**Significant findings:** Patient's tongue had a black discoloration, without elongated filiform papillae. We could not appreciate lymphadenopathy. His abdomen was tender to palpation. WBC of  $2.2 \times 10^3/\text{mm}^3$  and Hg of 11.6 g/dL, platelets of  $126 \times 10^3/\text{mm}^3$  (all stable from baseline). Urinalysis was amber color without blood.

**Discussion:** Black hairy tongue, also known as Lingua Villosa Nigra, is a benign condition. In addition to the black coloration, it also presents with elongated filiform papillae. When the presentation lacks the latter, then it is called "pseudo-black hairy tongue."<sup>1</sup> Patients usually have a history of either heavy smoking, poor oral hygiene, or are immunocompromised.<sup>1,2</sup> There are several medications which may cause this presentation, most commonly bismuth subsalicylate and other antacids.<sup>2,3</sup> Treatment includes discontinuing

the offending medication and good oral hygiene. In rare resistant cases, drug therapy such as topical trichloroacetic acid, topical administration of an antifungal in the case of coinfection with *Candida albicans*, topical triamcinolone acetonide, urea solution, gentian violet, salicylic acid, vitamin B complex, thymol or salicylic acid have been used but without strong evidence of the efficacy.<sup>3,4</sup>

Our patient's physical finding of a tongue with black discoloration may trigger concern for potential bleeding disorder, either locally in the oral mucosa versus gastrointestinal bleed. However, the history, physical exam, and workup did not result in any evidence of bleeding. His history of increased antacid use in the setting of leukopenia suggests the cause. Understanding the differential diagnosis can help facilitate a more basic workup and simple discharge with outpatient management.

**Topics:** Black hairy tongue, lingua villosa nigra, pseudo-black hairy tongue, medication adverse effects.

#### References:

1. Schlager E, St. Claire C, Ashack K, Khachemoune A. Black hairy tongue: predisposing factors, diagnosis, and treatment. *Am J Clin Dermatol*. 2017;18(4):563-569. doi: 10.1007/s40257-017-0268-y
2. Sarti GM, Haddy RI, Schaffer D, Kihm J. Black hairy tongue. *Am Fam Physician*. 1990;41(6):1751-5.
3. Thompson D, Kessler T. Drug-induced black hairy tongue. *Pharmacotherapy*. 2010;30(6):585-593. doi: 10.1592/phco.30.6.585
4. Gurvits G, Tan A. Black hairy tongue syndrome. *World J Gastroenterol*. 2014;20(31):10845-10850. doi: 10.3748/wjg.v20.i31.10845