

Ovarian Teratoma

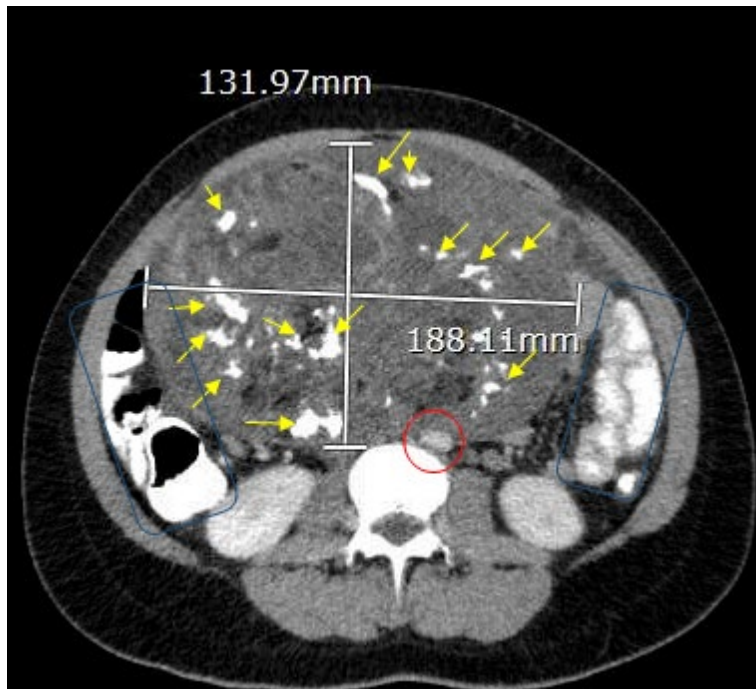
Laura Rubi Cuevas, BS* and Lauren Sylwanowicz, MD*

*University of California, Irvine, Department of Emergency Medicine, Orange, CA

Correspondence should be addressed to Lauren Sylwanowicz, MD at sylwano@uci.edu

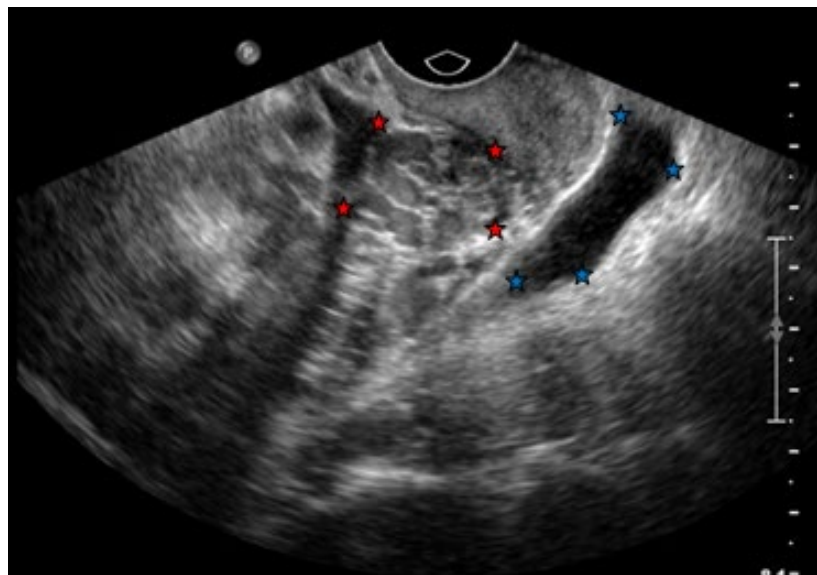
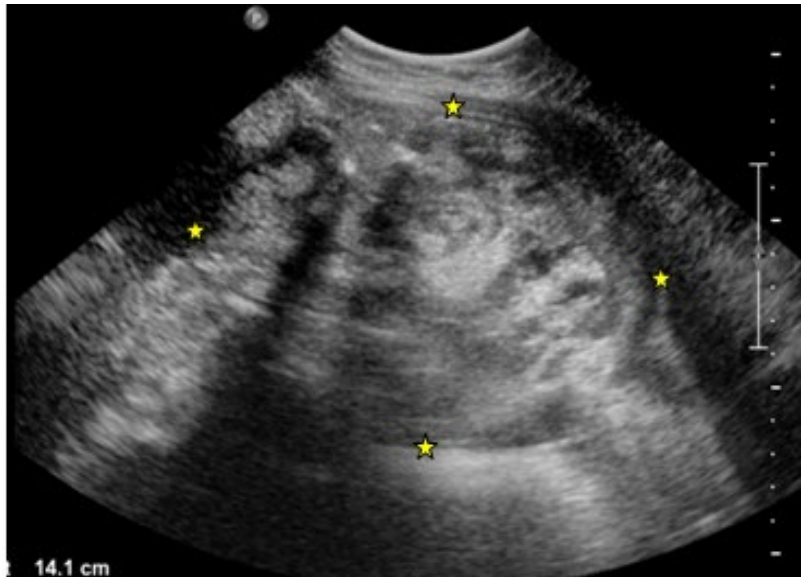
Submitted: July 5, 2018; Accepted: September 10, 2018; Electronically Published: January 15, 2019; <https://doi.org/10.21980/J8934X>

Copyright: © 2019 Cuevas, et al. This is an open access article distributed in accordance with the terms of the Creative Commons Attribution (CC BY 4.0) License. See: <http://creativecommons.org/licenses/by/4.0/>



Axial CT Video Link: <https://youtu.be/52Q6VKN-ilk>

Coronal CT Video Link: https://youtu.be/kITBOVMq_js



History of present illness: A 19-year-old female with no pertinent past medical history presented to the emergency department with sharp, non-radiating, intermittent right lower quadrant abdominal pain that began two months ago. Pain was worse with movement. She denied nausea, vomiting, constipation, fevers, chills, vaginal bleeding or discharge, and dysuria. A distended abdomen was noted on physical exam. She was sent to the emergency department by her primary medical doctor after a mass was found on ultrasound and computed tomography (CT). She noted a history of irregular menses and denied a history of sexually transmitted infections. She denied a family history of ovarian, endometrial, colon or breast cancer.

Significant findings: The CT scan with oral contrast in the emergency department revealed a large heterogeneous abdominopelvic mass measuring 13.2 x 18.8 x 23.1 cm (see white lines), suggestive of an ovarian teratoma from the right ovary. This mass included fat, fluid, calcifications (see yellow arrows), and enhancing soft tissue components. The teratoma resulted in mass effect upon large and small bowel loops (see blue highlighted areas), inferior vena cava (IVC), distal aorta (see red highlighted area) and right common iliac artery. A small volume of ascites was also observed. There was no evidence of bowel obstruction, vascular occlusion or other significant emergent finding. Additionally, transabdominal and transvaginal ultrasound images were obtained. The transabdominal image visualized the abdominopelvic mass (see four yellow stars). The transvaginal image visualized a cross section of the teratoma (see four red stars) in relation to the bladder (see four blue stars).

Discussion: Ovarian teratomas are the most common nonepithelial benign ovarian tumor with about 30% of diagnosed women presenting with abdominal or pelvic pain.¹ Associated symptoms due to mass effect include abdominal pain, constipation and urinary retention.² The use of transvaginal ultrasonography in the emergency department is an excellent tool to identify benign teratomas, with a reported sensitivity of up to 86% and specificity of 99%.¹

The highest incidence of ovarian teratomas occur in women of reproductive age (20-40 years) though they can occur at any age.³ The most common complication associated with ovarian teratomas is ovarian torsion, reported in 3% to 16% of cases.⁴ Torsions are more common with intermediate size tumors compared to small or very rare large ones.⁵ A 34-year study analyzing mature cystic teratomas revealed that the mean size for a teratoma with torsion was 6.5±2.6cm and the mean size for a teratoma that led to rupture was 5.3±3.9cm.⁶ Rarely, ovarian teratomas may present with intestinal obstruction which occurs when a small intestine loop adheres to the tumor. Secondary symptoms include constipation or diarrhea, rectal bleeding or urinary frequency.⁷

Patient was informed to schedule outpatient follow up for preoperative planning with gynecology because she would need surgical management given the size of her teratoma.

Topics: Ovarian teratoma, abdominal or pelvic pain, pelvic mass, torsion, intestinal obstruction.

References:

1. Pascual MA, Graupera B, Pedrero C, Rodriguez I, Ajossa S, Guerriero S, et al. Long-term results for expectant management of ultrasonographically diagnosed benign ovarian teratomas. *Obstet Gynecol.* 2017;130(6):1244-1250. doi: 10.1097/AOG.0000000000002327
2. Horner KB, Marin JR. Diagnosis of cystic teratoma facilitated by point-of-care ultrasonography. *Pediatr Emerg Care.* 2016;32(8):558-560. doi: 10.1097/PEC.0000000000000875
3. Ozgur T, Atik E, Silfeler DB, Toprak S. Mature cystic teratomas in our series with review of the literature and retrospective analysis. *Archives Gynecology Obstetrics.* 2012; 285(4):1099-101. doi: 10.1007/s00404-011-2171-8
4. Fayez I, Khreisat B, Athamneh T, Omoosh R, Dalbes MA. Multiple bilateral ovarian mature cystic teratomas with ovarian torsion: a case report. *Oman Med J.* 2018;33(2):163-166. doi: 10.5001/omj.2018.30

5. Pantoja E, Noy MA, Axtmayer RW, Colon FE, Pelegrina I. Ovarian dermoids and their complications. Comprehensive historical review. *Obstet Gynecol Surv.* 1975;30(1):1-20.
6. Ayhan A, Bukulmez O, Genc C, Karamursel BS, Ayhan A. Mature cystic teratomas of the ovary: case series from one institution over 34 years. *Eur J Obstet Gynecol Reprod Biol.* 2000;88(2):153-127.
7. Yarmohammadi H, Mansoori B, Wong V. Squamous cell carcinoma arising from ovarian mature cystic teratoma and causing bowel obstruction. *J Cancer Res Ther.* 2014;10(3):770-772. doi: 10.4103/0973-1482.136051