

Tick Removal

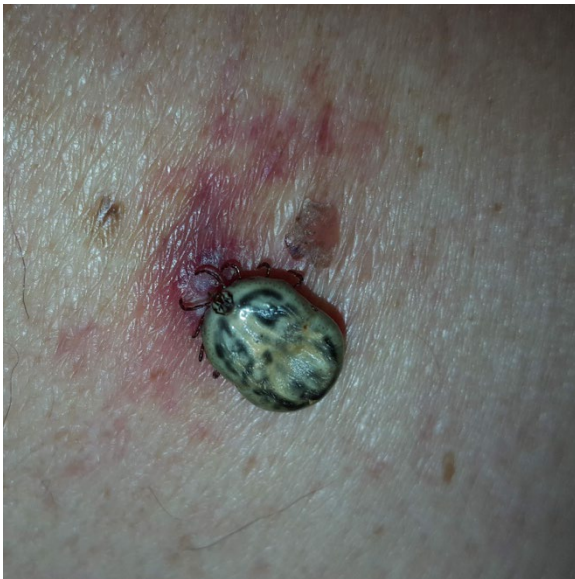
Belinda Lao, MD* and Xiao Chi Zhang, MD*

*Thomas Jefferson University Hospitals, Department of Emergency Medicine, Philadelphia, PA

Correspondence should be addressed to Belinda Lao, MD at Belinda.Lao@jefferson.edu

Submitted: October 1, 2018; Accepted: November 21, 2018; Electronically Published: January 15, 2019; <https://doi.org/10.21980/J8HK9H>

Copyright: © 2019 Lao, et al. This is an open access article distributed in accordance with the terms of the Creative Commons Attribution (CC BY 4.0) License. See: <http://creativecommons.org/licenses/by/4.0/>



Optimal removal of the tick with perpendicular traction of the tick by the mouthparts.
Image source: *Removal of a tick using tweezers*. Wikimedia Commons. Public domain.⁵

History of present illness: A 61-year-old male presented to the emergency department with complaints of fever, chills, nausea, and an “abscess” on his upper back for the past four days. He was employed in construction and frequently worked outdoors. Review of systems was otherwise unremarkable.

Significant findings: On physical exam, an engorged tick was found attached to the patient’s left upper back. The underlying skin was nontender but mildly erythematous, without central clearing. The tick was gently removed with blunt angle forceps and sent for further analysis, which later revealed the specimen to be an American dog tick (*Dermacentor variabilis*).

Discussion: Expedient removal of ticks is critical for reducing the transmission of arthropod-borne disease. Upon attachment, ticks deposit a cement-like material into the wound that facilitate its attachment for the long feeding period. This adhesive property complicates the removal process as forceful retrieval can result in retained tick parts, which can independently stimulate a granulomatous reaction and remain a nidus for further pathogen transmission.^{1,2}

The species of tick can also affect the overall removal difficulty. Ixodes and lone star ticks (*Amblyomma americanum*) attach deeper in the skin, while American dog ticks (*Dermacentor variabilis*) attach superficially but deposit greater amounts of cement.³ Optimal tick removal technique should involve the use of tweezers or blunt angle forceps to grasp the tick by the mouthparts as close to the surface of the skin as possible⁴ [see cartoon image of tick removal].⁵

Once a good grasp has been achieved, the provider should apply a firm, yet gentle steady traction, perpendicular to the surface, until the tick is released. Puncturing or compressing the body of the tick increases the risk of releasing pathogens through the tick saliva or regurgitation into the wound. Common folklore methods such as the use of petroleum jelly, fingernail polish, or 70% isopropyl alcohol to “choke out” the attached tick have not shown to induce spontaneous detachment, likely due to the tick’s low baseline respiratory rate.^{6,7} Local infiltration with lidocaine has also failed to exhibit benefit in rapid removal.⁸ The use of gasoline and flammables to “burn” off the tick has not shown to increase rates of spontaneous detachment. One study of risk factors associated with *Borrelia burgdorferi* antibodies revealed an association between the use of gasoline and risk of positive serology for *B. burgdorferi* (adjusted odds ratio 4.5, 95% CI 1.2-17.6), possibly secondary to the risk of inducing tick saliva regurgitation.⁹ Additionally, the use of flammable materials exposes the patient to risk of thermal injuries and may increase spread of spirochetes if the tick bursts.¹⁰ After tick removal, the area should be thoroughly cleaned of any retained tick parts and appropriate antibiotic coverage using evidence-based guidelines should be provided.^{1,11}

Please refer to http://jetem.org/erythema_migrans/ for Lyme treatment guidelines.

Topics: Tick, tick Removal, Lyme disease, *Borrelia burgdorferi*, infectious disease.

References:

1. Huygelen V, Borra V, De Buck E, Vandekerckhove P. Effective methods for tick removal: a systematic review. *J Evid Based Med*. 2017;10(3):177-188. doi: 10.1111/jebm.12257
2. Kitch BB, Meredith JT. Zoonotic infections. In: Tintinalli JE, Stapczynski J, Ma O, Yearling DM, Meckler GD, Cline DM, eds. *Tintinalli's Emergency Medicine: A Comprehensive Study Guide*. 8th ed. New York, NY: McGraw-Hill; 2015:1085-1093.
3. Stewart RL, Burgdorfer W, Needham GR. Evaluation of three commercial tick removal tools. *Wilderness Environ Med*. 1998;9(3):137-142.
4. Akin BA, Dervis E, Kar S, Ergonul O, Gargili A. Revisiting detachment techniques in human-biting ticks. *J Am Acad Dermatol*. 2016;75(2):393-397. doi: 10.1016/j.jaad.2016.01.032
5. Centers for Disease Control and Prevention. Removal of a tick using tweezers. Wikimedia Commons. <https://commons.wikimedia.org/wiki/File:Tickremoval.png>. Published March 1, 2005. Accessed November 20, 2018. Public domain.
6. Duscher GG, Peschke R, Tichy A. Mechanical tools for the removal of Ixodes ricinus female ticks—differences of instruments and pulling or twisting? *Parasitol Res*. 2012;111(4):1505-1511. doi: 10.1007/s00436-012-2987-6
7. Needham GR. Evaluation of five popular methods for tick removal. *Pediatrics*. 1985;75(6):997-1002.
8. Lee MD, Sonenshine DE, Counselman FL. Evaluation of subcutaneous injection of local anesthetic agents as a method of tick removal. *Am J Emerg Med*. 1995;13(1):14-16. doi: 10.1016/0735-6757(95)90232-5
9. Schwartz BS, Goldstein MD. Lyme disease in outdoor workers: risk factors, preventive measures, and tick removal methods. *Am J Epidemiol*. 1990;131(5):877-885.
10. Due C, Fox W, Medlock JM, Pietzsch M, Logan JG. Tick bite prevention and tick removal. *BMJ*. 2013;347: f7123. doi: 10.1136/bmj.f7123
11. Gammons M, Salam G. Tick removal. *Am Fam Physician*. 2002;66(4):643-645.