

Tricyclic Antidepressant Overdose

Patrick G Meloy, MD^{*}, Amit Bhambri, MD[^] and Megan C Henn, MD^{*}

^{*}Emory University School of Medicine, Department of Emergency Medicine, Atlanta, GA

[^]Swedish Covenant Hospital, Department of Emergency Medicine, Chicago, IL

Correspondence should be addressed to Patrick G Meloy, MD at patrickmeloy@emory.edu

Submitted: December 14, 2018; Accepted: April 5, 2019; Electronically Published: July 15, 2019; <https://doi.org/10.21980/J85W50>

Copyright: © 2019 Meloy, et al. This is an open access article distributed in accordance with the terms of the Creative Commons Attribution (CC BY 4.0) License. See: <http://creativecommons.org/licenses/by/4.0/>

ABSTRACT:

Audience: Emergency medicine residents and medical students on emergency medicine rotations.

Introduction: Though the incidence of tricyclic antidepressant (TCA) overdoses has decreased due to increasing prescriptions of selective-serotonin reuptake inhibitors (SSRI's), tricyclic antidepressants remain in the top 25 causes of poisoning deaths.¹ Patients who attempt suicide with a TCA have a fatality rate of 70% if they do not reach a healthcare facility; however, that rate is lowered to 3% if the patient reaches a facility for treatment.² Women are at higher risk of toxicity than men, particularly in the age range of 20-29.² Emergency medicine physicians should be skilled in the electrocardiogram (ECG) interpretation of acute TCA overdose, and need to be comfortable in the emergent management of patients who are unable, or unwilling, to verbalize the medication they ingested.

This oral boards case tests the learners' approach to a patient with undifferentiated altered mental status, while attempting to focus the learner on intentional overdose as the likely diagnosis. Upon completing this oral board case, learners should be able to recognize the classic pattern of a widened QRS complex, right-axis deviation, and large terminal R-wave (>3mm) in TCA overdose, and treat accordingly with high doses of sodium bicarbonate until the ECG improves. Though a toxicologist's support is an important adjunct, emergency physicians should be confident in managing this case from presentation to appropriate intensive care unit admission.

Objectives: At the end of this oral boards session, learners will be able to: 1) discuss the appropriate laboratory testing and workup for a patient with undifferentiated altered mental status, 2) discuss the importance of obtaining an ECG in a timely manner in order to investigate the broad differential of altered mental status, 3) identify the classic ECG findings of a patient with TCA overdose, 4) review the treatment of TCA overdose, 5) discuss the appropriate disposition of a patient with TCA overdose. **Method:** Oral boards case.

Topics: Tricyclic antidepressants, TCAs, amitriptyline, intentional overdose, toxicological emergency, cardiovascular emergency.



USER GUIDE

List of Resources:

Abstract	1
User Guide	2
For Examiner Only	4
Oral Boards Assessment	11
Stimulus	14
Debriefing and Evaluation Pearls	28

Learner Audience:

Medical students, interns, junior residents, senior residents

Time Required for Implementation:

Case: 15 minutes

Debriefing: 10 minutes

Learners per instructor:

Recommend 1 learners per instructor/case, if using as oral board testing.

Topics:

Tricyclic antidepressants, TCAs, amitriptyline, intentional overdose, toxicological emergency, cardiovascular emergency.

Objectives:

By the end of this oral boards session, learners will be able to:

1. Discuss the appropriate laboratory testing and workup for a patient with undifferentiated altered mental status
2. Discuss the importance of obtaining an ECG in a timely manner in order to investigate the broad differential of altered mental status
3. Identify the classic ECG findings of a patient with TCA overdose
4. Review the treatment of TCA overdose
5. Discuss the appropriate disposition of a patient with TCA overdose

Linked objectives and methods:

TCA overdose is a rare occurrence but an essential diagnosis which can be effectively taught through the oral board or simulation format. The oral board format allows faculty to observe the learner in real time to ensure that critical information is gained in order to ensure the learner can differentiate between causes of altered mental status and use critical information in the case to arrive at a toxidrome as the cause of altered mental status.

In the initial evaluation, the learner should initiate a detailed workup of the broad differentials of a patient with altered

mental status (objective 1). Early in the case, the learner should order and review the ECG, recognizing the classic ECG findings of TCA overdose (objective 2 and 3). The learner should identify the TCA overdose toxidrome and discuss the appropriate urgent management and treatment (objective 4). Lastly, the learner should provide appropriate disposition of the patient to an intensive care unit (objective 5). Debriefing will ensure that the learner can assimilate all of the sources data in a coherent picture to deduce the correct diagnosis and will review any missed points or concepts.

Recommended pre-reading for instructor:

- Levine M, Ruha A. Antidepressants. In: Marx J, Hockberger R, Walls R, Adams J, Rosen P, eds. *Rosen's Emergency Medicine: Concepts and Clinical Practice*. 8th ed. Philadelphia: PA: Elsevier; 2010:1975-1981.
- Body R, Bartram T, Azam F, Mackway-Jones K. Guidelines in emergency medicine network (GEMNet): guideline for the management of tricyclic antidepressant overdose. *Emerg Med J*. 2011;28(4):347-368. doi: 10.1136/emj.2010.091553.

Results and tips for successful implementation:

This case is best used for oral board testing and assessment. It can be part of a single-case or implemented into a triple-case setting. It is challenging for interns and junior residents due to the rarity of the pathophysiology. It is appropriate for the testing of higher-level differential diagnoses in an altered patient, and for rapid-decision-making in an ongoing resuscitation. The case has been trialed on 20 learners as a single-case. Junior and senior learners alike had difficulty with the appropriate diagnosis based on lack of familiarity with the diagnosis. Senior learners tended to understand the pathophysiology and were able to successfully progress to case resolution. Medical students and interns did not have complete understanding, and often the progression led to an assessment of their advanced cardiac life support (ACLS) knowledge. This was also useful, and the examiners were able to redirect most of the cases to a TCA diagnosis. All learners appreciated seeing this case in a simulation-type setting, and the feedback was positive. We recommend using this case in conjunction with a toxicology module to reinforce the broad differential diagnoses associated with altered mental status and potential overdose.

References/suggestions for further reading:

1. Gummin D, Mowry J, Spyker DA, Brooks DE, Fraser MO, Banner W. 2016 Annual report of the American Poison Control Centers' National Poison Data System (NPDS): 34th annual report. *Clin Toxicol (Phila)*. 2017;55(10):1072-1252. doi: 10.1080/15563650.2017.1388087.
2. Tsai V, Silverberg MA. Tricyclic antidepressant toxicity. Medscape.



USER GUIDE

- <https://emedicine.medscape.com/article/819204-overview>.
Published December 12, 2017. Accessed April 23, 2019.
3. Levine M, Ruha A. Antidepressants. In: Marx J, Hockberger R, Walls R, Adams J, Rosen P, eds. *Rosen's Emergency Medicine: Concepts and Clinical Practice*. 8th ed. Philadelphia: PA: Elsevier; 2010:1975-1981.
 4. Bailey B, Buckley N, Amre D. A meta-analysis of prognostic indicators to predict seizures, arrhythmias or death after tricyclic antidepressant overdose. *J Toxicol Clin Toxicol*. 2004;42(6):877-888. doi:10.1081/clt-200035286.
 5. Paris J. Tricyclic antidepressant toxicity. Core EM. <https://coreem.net/core/tricyclic-antidepressant-toxicity/>.
Published 2017. Accessed June 10, 2019.
 6. Simons, D. Tricyclic antidepressant overdose: manifestations and management. Pharmacy Times. <http://www.pharmacytimes.com/contributor/dewilka-simons/2018/02/tricyclic-antidepressant-overdose-manifestations-and-management>. Published February 20, 2018. Accessed June 10, 2019.
 7. Mills KC. Tricyclic antidepressants. In: Tintinalli J, Stapczynski J, Ma O, Yealy D, Meckler G, Cline D, eds. *Tintinalli's Emergency Medicine*. 7th ed. New York, NY: McGraw-Hill; 2011:1025-1033.
 8. Body R, Bartram T, Azam F, Mackway-Jones K. Guidelines in emergency medicine network (GEMNet): guideline for the management of tricyclic antidepressant overdose. *Emerg Med J*. 2011;28(4):347-368.
 9. FOAMcast. Episode 13 – tricyclic antidepressants and sodium channel blockade. <http://foamcast.org/2014/09/03/episode-13-tricyclic-antidepressants-and-sodium-channel-blockade/>. FOAMcast. Published 2014. Accessed June 10, 2019.
 10. Liebelt EL. Cyclic antidepressants. Goldfrank L, Hoffman R, Howland M, et al, eds. *Goldfrank's Toxicologic Emergencies*. 10th ed. New York, NY: McGraw-Hill: 1049-1059.
 11. Misch M, Helman, A. CritCases 1: Massive TCA overdose. Emergency Medicine Cases. <https://emergencymedicinecases.com/critcases-massive-tca-overdose/>. Published 2016. Accessed June 11, 2019.



FOR EXAMINER ONLY

Oral Case Summary

Diagnosis: Tricyclic Antidepressant Overdose

Case Summary: This is a 31-year-old male patient who was found to be altered and incoherent in his parked car. He had been found by coworkers, babbling to himself. He had recently been complaining of “not feeling well” and “not enjoying his job.” He had been married and divorced, all within the last year. His coworkers told emergency medical services (EMS) that he was withdrawn at work, and they knew very little about him. He needs early and aggressive care, which includes an emergent ECG, which clinches the diagnosis of TCA overdose. He requires sodium bicarbonate boluses and drip, and will need toxicology consultation and ICU admission.

Order of Case: This is a case of intentional tricyclic antidepressant overdose. The patient is initially altered and the only history can be obtained from EMS. The patient has undifferentiated altered mental status, and the key is obtaining a challenging history and using the early ECG interpretation to elicit the diagnosis.

If the ECG pattern of TCA overdose is not recognized early, the patient will decompensate, have worsening ECG changes, and require aggressive hemodynamic resuscitation that can only be recovered with sodium bicarbonate therapy. The examiner should provide worsening vital signs, including profound hypotension and tachycardia, and the patient will become unresponsive. Stimulus #9 should be offered to the examinee, spontaneously obtained by the nurse. If TCA-overdose is still unrecognized, the patient should deteriorate into cardiac arrest (the nurse can announce that the patient no longer has a pulse or a blood pressure). The examinee should be required to perform ACLS; however, the patient will not have return of spontaneous circulation until at least two ampules of sodium bicarbonate are given.

If recognized early, the overdose can be treated appropriately; the patient will improve, and can be safely admitted to the hospital. Toxicology should be consulted but will not be able to provide the precise diagnosis or assistance in treatment because this is a bedside diagnosis that should be made by the emergency physician.

Disposition: Admit to medical intensive care unit (MICU).



FOR EXAMINER ONLY

Critical Actions:

1. Transfer patient into the resuscitation room upon arrival.
2. Administer early intravenous fluid (IVF) resuscitation through large bore intravenous (IV) lines.
3. Place patient on the cardiac monitor (*a rhythm strip displaying lead-II is available as stimulus #13, if requested by the examinee*).
4. Order an emergent ECG and recognize ECG findings consistent with TCA toxicity.
5. Order sodium bicarbonate boluses and initiate a sodium bicarbonate drip until the ECG normalizes.
6. Consult poison control/toxicology.
7. Admit the patient to the MICU.



FOR EXAMINER ONLY

Historical Information

Chief Complaint: Confusion

History of present illness: This is a previously healthy 31-year-old male patient who presents with chief complaint of confusion. The patient was found by his coworkers in the parking lot at work and EMS was called. Learner should request that EMS remain to provide further history. If EMS remains, they may relate that per coworkers the patient has been married and divorced, all within the last year. He has been withdrawn and kept to himself at work. He previously attended social events, but lately has not been interested in any social activities. He is otherwise unable to provide any information and babbles incoherently while in the examination room.

Past medical history: Depression (only provided if EMS specifically asked for past medical history)

Past surgical history: Unknown

Patients medications: Unknown

Allergies: Unknown

Social history:

- Smoking: socially
- Tobacco: socially
- Drug use: Unknown, per coworkers

Family history: Unknown



FOR EXAMINER ONLY

Physical Exam Information

Vitals: HR 115 BP 92/54 RR 22 Temp 36.6°C (97.8°F) O₂Sat 98%

General appearance: Disheveled, confused, restless, vomit on shirt

Primary survey:

- **Airway:** Mumbles, no apparent obstructions
- **Breathing:** Clear sounds bilaterally
- **Circulation:** Equal pulses throughout, vitals as shown above

Physical examination:

- **General appearance:** Disheveled, confused, vomit on shirt
- **Head, eyes, ears, nose and throat (HEENT):**
 - **Head:** Within normal limits
 - **Eyes:** Extraocular muscles intact, pupils 4-5mm bilaterally, round and sluggishly reactive to light bilaterally
 - **Ears:** Within normal limits
 - **Nose:** Within normal limits
 - **Throat:** Within normal limits, mucous membranes dry
- **Neck:** Within normal limits
- **Chest:** Lungs clear-to-auscultation bilaterally
- **Cardiovascular:** Tachycardic, no extraneous heart sounds
- **Abdominal/GI: (learner should ask specifics)** Tender diffusely with concentration in the epigastrium; decreased bowel sounds throughout; soft; no rebound, guarding or rigidity
- **Genitourinary:** Within normal limits
- **Rectal:** Should be deferred; if performed, within normal limits with guaiac negative stool
- **Extremities:** Within normal limits
- **Back:** Within normal limits
- **Neuro: (learner should ask specifics)** Extraocular movements intact, pupils equally round and reactive to light but sluggish bilaterally; no facial asymmetry; no obviously slurred speech, but is mumbling; uvula in midline; intact shoulder shrug bilaterally; moves all extremities equally; mumbles answers to questions but is not interpretable; is lethargic but arousable to noxious stimuli; Glasgow coma scale (GCS): eyes open to verbal command, making incomprehensible sounds and obeys commands (11; E=3, V=2, M=6, if asked by learner)
- **Skin:** Flushed, no hives; dry; warm



FOR EXAMINER ONLY

- **Lymph:** Within normal limits
- **Psych:** Confused, unable to understand any answers



FOR EXAMINER ONLY

Critical Actions and Cueing Guidelines

1. **Transfer patient into the resuscitation room upon arrival.**
 - a. Cueing Guideline (if applicable):
Examiner may say, “The nurse caring for the patient would like to know if you want this patient monitored more closely, since the hallway beds do not have cardiac monitors available.”
2. **Administer early intravenous fluid (IVF) resuscitation through large bore intravenous (IV) lines.**
 - a. Cueing Guideline (if applicable):
The examiner may state, “The nurse technician is asking if there are any immediate orders you would like while you obtain further history.”
3. **Place patient on the cardiac monitor (*a rhythm strip displaying lead-II is available as stimulus #13, if requested by the examinee*).**
 - a. Cueing Guideline (if applicable):
The examiner may state: “The nurse technician is asking if there are any immediate orders you would like while you obtain further history.”
4. **Order an emergent ECG and recognize ECG findings consistent with TCA toxicity.**
 - a. Cueing Guideline (if applicable):
Examiner may state, “The patient has a strange rhythm on the cardiac monitor; can you explain to the nurse-trainee what it means?”
5. **Order sodium bicarbonate boluses and initiate a sodium bicarbonate drip until the ECG normalizes.**
 - a. Cueing Guideline (if applicable):
Examiner may state, “RN may state, ‘Can we start treating the patient with anything that we have available in the ACLS cart?’”
6. **Consult poison-control/toxicology.**
 - a. Cueing Guideline (if applicable):
If learner attempts to admit without consultation the hospitalist may state, “What did the toxicologist recommend?”
7. **Admit the patient to the medical ICU.**



FOR EXAMINER ONLY

a. Cueing Guideline (if applicable):

If learner attempts to admit to the “floor,” the hospitalist may state, “Did the toxicologist feel it is appropriate? Is the patient hemodynamically stable?”



ORAL BOARDS ASSESSMENT

Tricyclic Antidepressant Overdose

Learner: _____

Critical Actions:

- Transfer patient into the resuscitation room upon arrival.
- Administer early intravenous fluid (IVF) resuscitation through large bore intravenous (IV) lines.
- Place patient on the cardiac monitor
- Order an emergent ECG and recognize ECG findings consistent with TCA toxicity.
- Order sodium bicarbonate boluses and initiate a sodium bicarbonate drip until the ECG normalizes.
- Consult poison control/toxicology.
- Admit the patient to the medical intensive care unit (MICU).

Summative and formative comments:

Milestone assessment:

	Milestone	Did not achieve level 1	Level 1	Level 2	Level 3
1	Emergency Stabilization (PC1)	<input type="checkbox"/> Did not achieve Level 1	<input type="checkbox"/> Recognizes abnormal vital signs	<input type="checkbox"/> Recognizes an unstable patient, requiring intervention Performs primary assessment Discerns data to formulate a diagnostic impression/plan	<input type="checkbox"/> Manages and prioritizes critical actions in a critically ill patient Reassesses after implementing a stabilizing intervention



ORAL BOARDS ASSESSMENT

Tricyclic Antidepressant Overdose

Learner: _____

	Milestone	Did not achieve level 1	Level 1	Level 2	Level 3
2	Performance of focused history and physical (PC2)	<input type="checkbox"/> Did not achieve Level 1	<input type="checkbox"/> Performs a reliable, comprehensive history and physical exam	<input type="checkbox"/> Performs and communicates a focused history and physical exam based on chief complaint and urgent issues	<input type="checkbox"/> Prioritizes essential components of history and physical exam given dynamic circumstances
3	Diagnostic studies (PC3)	<input type="checkbox"/> Did not achieve Level 1	<input type="checkbox"/> Determines the necessity of diagnostic studies	<input type="checkbox"/> Orders appropriate diagnostic studies Performs appropriate bedside diagnostic studies/procedures	<input type="checkbox"/> Prioritizes essential testing Interprets results of diagnostic studies Considers risks, benefits, contraindications, and alternatives to a diagnostic study or procedure
4	Diagnosis (PC4)	<input type="checkbox"/> Did not achieve Level 1	<input type="checkbox"/> Considers a list of potential diagnoses	<input type="checkbox"/> Considers an appropriate list of potential diagnosis May or may not make correct diagnosis	<input type="checkbox"/> Makes the appropriate diagnosis Considers other potential diagnoses, avoiding premature closure
5	Pharmacotherapy (PC5)	<input type="checkbox"/> Did not achieve Level 1	<input type="checkbox"/> Asks patient for drug allergies	<input type="checkbox"/> Selects an appropriate medication for therapeutic intervention, considering potential adverse effects	<input type="checkbox"/> Selects the most appropriate medication(s) and understands mechanism of action, effect, and potential side effects Considers and recognizes drug-drug interactions
6	Observation and reassessment (PC6)	<input type="checkbox"/> Did not achieve Level 1	<input type="checkbox"/> Reevaluates patient at least one time during the case	<input type="checkbox"/> Reevaluates patient after most therapeutic interventions	<input type="checkbox"/> Consistently evaluates the effectiveness of therapies at appropriate intervals



ORAL BOARDS ASSESSMENT

Tricyclic Antidepressant Overdose

Learner: _____

	Milestone	Did not achieve level 1	Level 1	Level 2	Level 3
7	Disposition (PC7)	<input type="checkbox"/> Did not achieve Level 1	<input type="checkbox"/> Appropriately selects whether to admit or discharge the patient	<input type="checkbox"/> Appropriately selects whether to admit or discharge Involves the expertise of some of the appropriate specialists	<input type="checkbox"/> Educates the patient appropriately about their disposition Assigns patient to an appropriate level of care (ICU/Tele/Floor) Involves expertise of all appropriate specialists
22	Patient centered communication (ICS1)	<input type="checkbox"/> Did not achieve level 1	<input type="checkbox"/> Establishes rapport and demonstrates empathy to patient (and family) Listens effectively	<input type="checkbox"/> Elicits patient's reason for seeking health care	<input type="checkbox"/> Manages patient expectations in a manner that minimizes potential for stress, conflict, and misunderstanding.
23	Team management (ICS2)	<input type="checkbox"/> Did not achieve level 1	<input type="checkbox"/> Recognizes other members of the patient care team during case (nurse, techs)	<input type="checkbox"/> Communicates pertinent information to other healthcare colleagues	<input type="checkbox"/> Communicates a clear, succinct, and appropriate handoff with specialists and other colleagues Communicates effectively with ancillary staff



Stimulus Inventory

- #1 Patient Information Form**
- #2 Arterial blood gas (ABG)**
- #3 Complete blood count (CBC)**
- #4 Basic metabolic panel (BMP)**
- #5 Urinalysis**
- #6 Portable chest radiograph**
- #7 Initial Electrocardiogram (ECG)**
- #8 Improving Electrocardiogram (ECG) with sodiu bicarbonate treatment**
- #9 Worsening Electrocardiogram (ECG) without treatment**
- #10 Serum toxicology**
- #11 Urine drug screen**
- #12 Coagulation panel**
- #13 Rhythm strip (lead II)**



Stimulus #1

Patient Information

Patient's Name: Mark Jones
Age: 31
Gender: Male
Chief Complaint: Altered mental status

Person Providing History: EMS

Vital Signs:

Temp: 36.6 (97.8)
BP: 92/54
P: 115
RR: 22
Pulse Ox: 98% (room-air)



Stimulus #2

Arterial Blood Gas (ABG)

pH	7.29
pCO₂	47 mmHg
pO₂	88 mmHg
HCO₃	22 mmol/L
O₂ sat	98%



Stimulus #3

Complete Blood Count (CBC)

White blood cell count (WBC) 7.9 x1000/mm³

Hemoglobin (Hgb) 14.2 g/dL

Hematocrit (Hct) 42.1%

Platelets 279 x1000/mm³



Stimulus #4

Basic Metabolic Panel (BMP)

Sodium	142 mEq/L
Potassium	3.9 mEq/L
Chloride	101 mEq/L
Carbon Dioxide (CO₂)	19 mEq/L
Blood Urea Nitrogen (BUN)	19 mg/dL
Creatinine (Cr)	1.2 mg/dL
Glucose	121 mg/dL



Stimulus #5

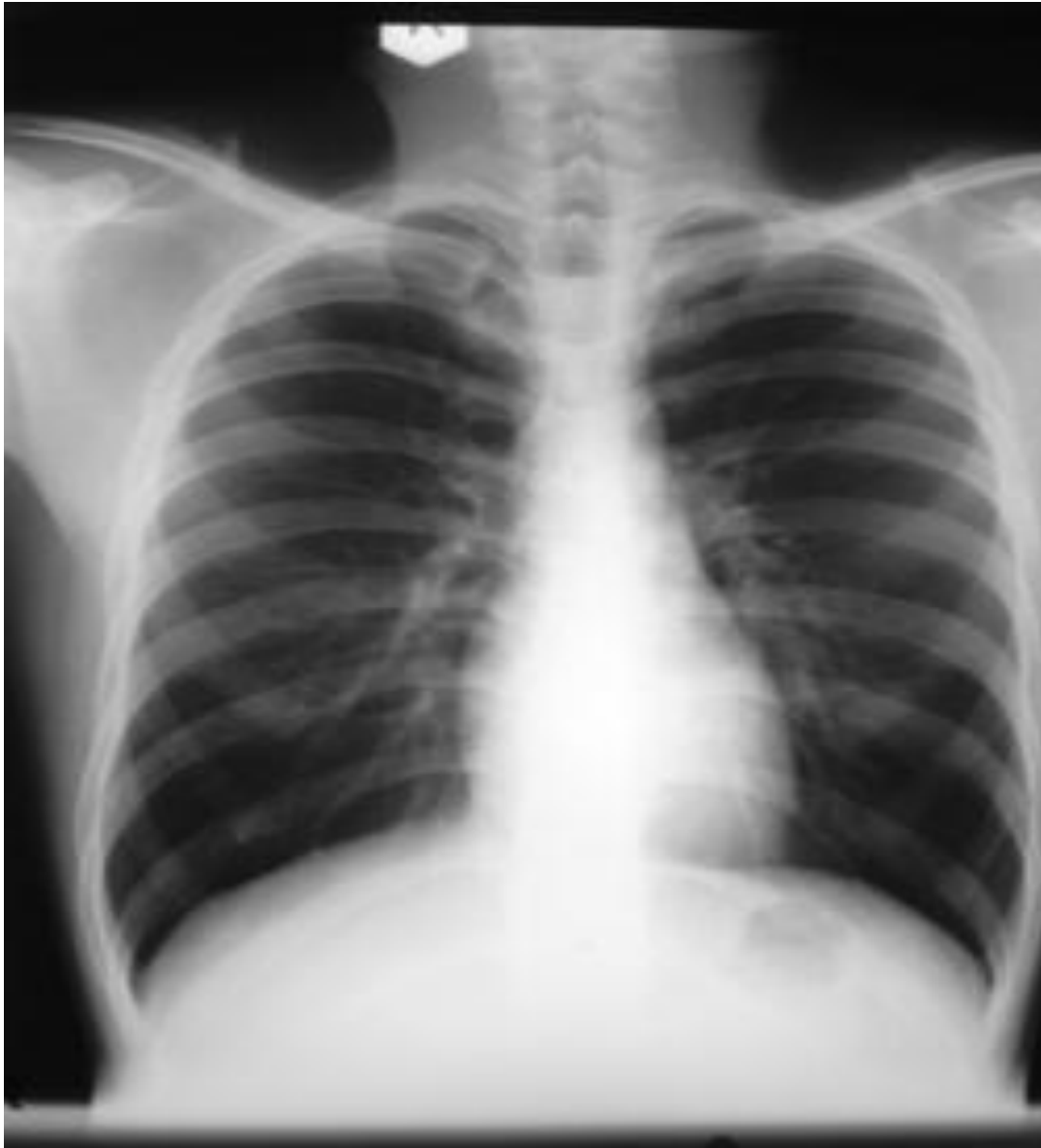Urinalysis

Appearance	Clear
Color	Yellow
Glucose	Negative
Ketones	2+
Sp Gravity	1.030
Blood	Negative
pH	7.0
Protein	Negative
Nitrite	Negative
Leukocyte	Negative
WBC	0-2/high powered field (hpf)
Red blood cells (RBC)	0-2/hpf
Squamous Cells	0/hpf
Bacteria	0/hpf



Stimulus #6

Chest Radiograph

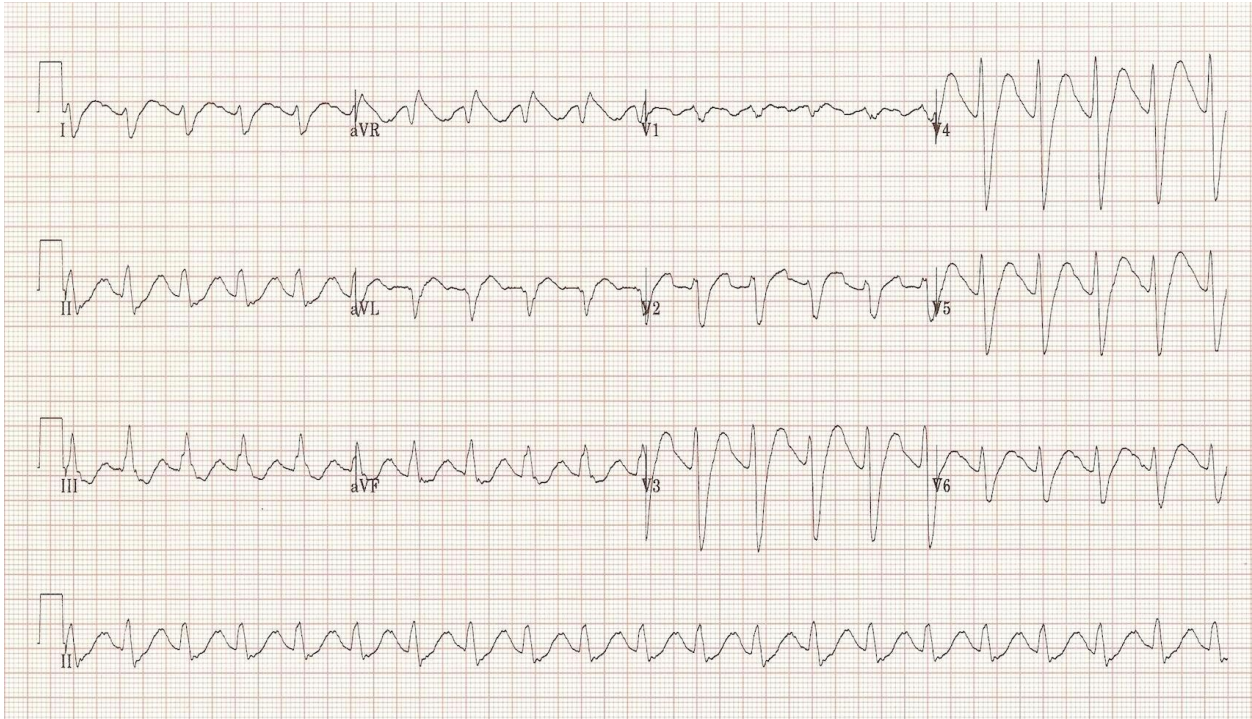

Author's own image



Stimulus #7

Initial Electrocardiogram (ECG)

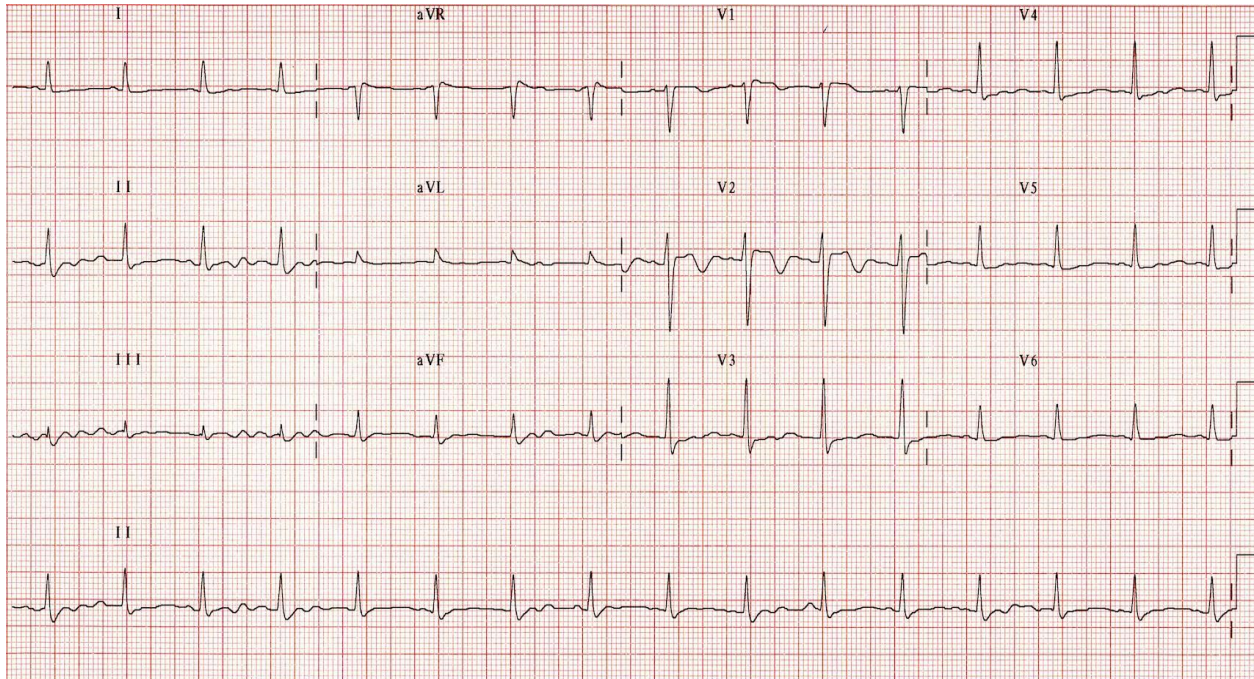


Author's own image



Stimulus #8

Improving Electrocardiogram with Sodium Bicarbonate Treatment

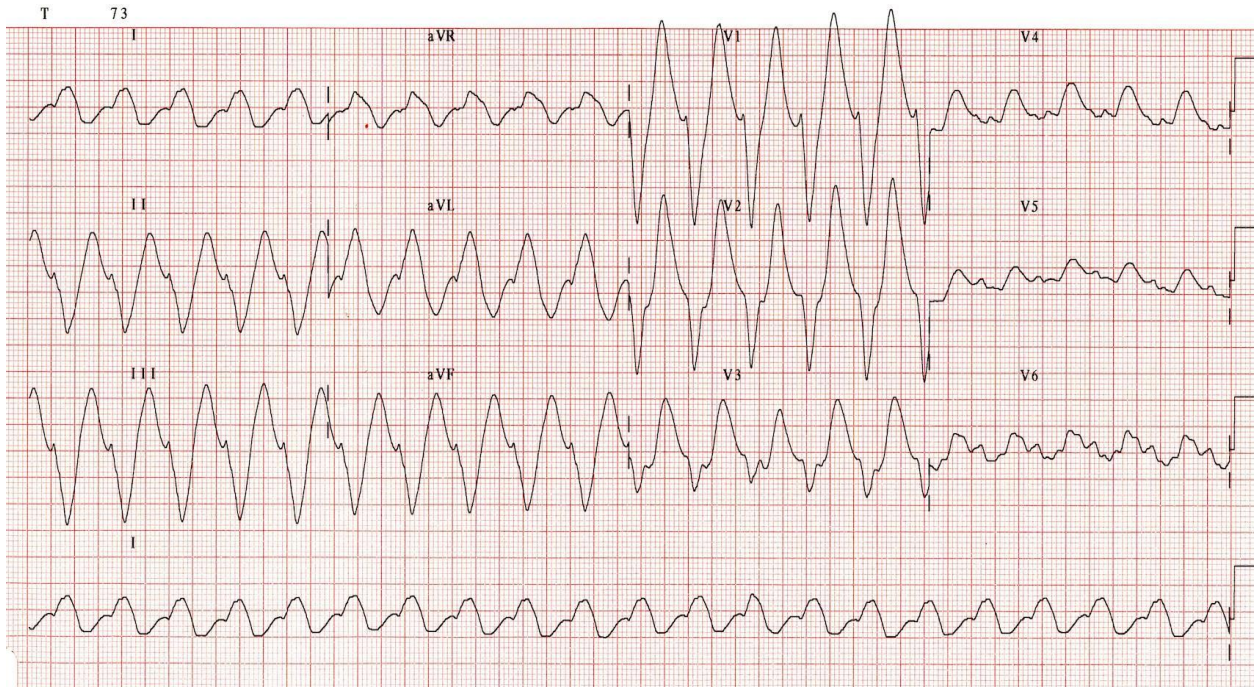


Author's own image



Stimulus #9

Worsening Electrocardiogram without Treatment



Author's own image



Stimulus #10

Serum Toxicology

Acetaminophen: <10 mcg/mL

Salicylates: <15 mg/dL

Ethanol: <10 mg/dL



Stimulus #11

Urine Drug Screen

Amphetamines:	Negative
Barbiturates:	Negative
Benzodiazepines:	Negative
Cocaine:	Negative
Opiates:	Negative
Cannabinoids:	Negative



Stimulus #12

Coagulation Panel

Prothrombin Time (PT)	29.1 seconds
Partial Thromboplastin Time (PTT)	15.1 seconds
International Normalized Time (INR)	1.1



Stimulus #13

Rhythm Strip (lead II)

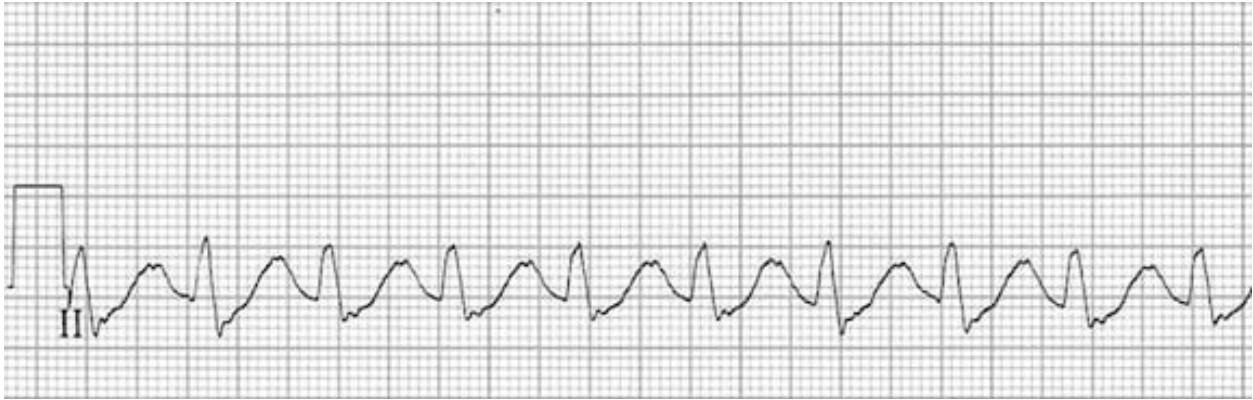

Image source: Burns E. Tricyclic overdose. Life in the Fastlane. <https://litfl.com/tricyclic-overdose-sodium-channel-blocker-toxicity>. CC-BY-NC-SA 4.0



DEBRIEFING AND EVALUATION PEARLS

Tricyclic Antidepressant Overdose

A complete neurological examination and a timely ECG are the most important critical actions when evaluating a possible TCA overdose.

1. Clinical toxicity typically occurs within 2-4 hours of ingestion and can be the result of an overdose of a TCA or of drug interactions that impair the CYP450 system resulting in elevated serum concentrations.^{3,4,5}
2. Early signs (1-2 hours) of toxicity are anticholinergic effects and an altered mental status that varies from confused to comatose and seizures.^{4,6}
3. Later effects (2-6 hours) result from the severe sodium channel blockage and can include myocardial depression resulting in hypotension and bradycardia.^{4,6}
4. A QRS interval greater than 160 msec is likely related to ventricular arrhythmias, and QRS greater than 100 msec can be associated with seizures. Additional ECG findings include a rightward shift of the terminal R wave of the QRS complex in lead aVR. These are indications for initiation of sodium bicarbonate infusion with a goal pH 7.45-7.55.^{1,3,4,6}
5. Hypotensive patients should be fluid resuscitated first and given vasopressors if needed. Initial hypertension should be permitted as hypotension typically follows. After the use of bicarbonate and fluid resuscitation, adjunct therapies including intralipid and extracorporeal membrane oxygenation (ECMO) should be considered.^{1,3,4,6}