

A Low-Cost, Reusable Ultrasound Pericardiocentesis Simulation Model

Jonathan dela Cruz, MD*, Tyler Fulks, MD*, Mark Baker, MD*, Jason Kegg, MD*, Richard Austin, MD*, Jimmy Jain, MD*, Michael Boehler, MS*, Sharon Kim, PhD[^], and Cassie Jaeger, PhD[^]

*Southern Illinois University School of Medicine, Department of Emergency Medicine, Springfield, Ill

*Southern Illinois University School of Medicine, Center for Clinical Research, Springfield, Ill

Correspondence should be addressed to Jonathan dela Cruz, MD at jdelacruz@siumed.edu

Submitted: May 3, 2019; Accepted: August 6, 2019; Electronically Published: October 15, 2019; <https://doi.org/10.21980/J8TD1J>

Copyright: © 2019 dela Cruz, et al. This is an open access article distributed in accordance with the terms of the Creative Commons Attribution (CC BY 4.0) License. See: <http://creativecommons.org/licenses/by/4.0/>

ABSTRACT:

Audience: This low-cost, reusable ultrasound pericardiocentesis simulation model is designed to instruct emergency medicine residents and emergency medicine-bound students.

Introduction: Cardiac tamponade is a time sensitive, life-threatening condition that requires prompt intervention. Cardiac tamponade has an incidence of 2 per 10,000 in the U.S. population.¹ Ultrasound-guided pericardiocentesis is a critical treatment for cardiac tamponade that can be safely performed with high success rates.² With such a rare likelihood of encountering this condition in clinical practice, deliberate practice is vital for practitioners to be proficient in this life-saving procedure when the need does occur. Simulation training improves fund of knowledge, comfort in procedures, and performance within simulated scenarios.³ A key component of simulation training involves utilization of training models that thoughtfully reflect true clinical pictures. The use of clinically realistic models affords residents the opportunity to develop the hand-eye coordination and cognitive sense needed to perform the procedure safely on real patients, all in a no-risk, low-stress setting. Unfortunately, currently available simulation models for training can be expensive and limited in scope.

Educational Objectives: Through the use of this model and skill session, learners will be able to: 1) discuss the indications, contraindications, and complications associated with ultrasound guided pericardiocentesis; 2) demonstrate an ability to obtain subxiphoid and parasternal long views of the heart; 3) demonstrate an ability to identify pericardial fluid in these two views; and 4) demonstrate proper probe and needle placement to successfully perform an ultrasound guided pericardiocentesis in these two views.

Educational Methods: We have developed a reusable, ultrasound-guided pericardiocentesis simulation model that costs approximately \$20.00 in materials and takes 10 minutes to construct. The model utilizes a

INNOVATIONS

fluid-filled balloon inside a press and seal bag that is covered with pork or beef ribs.

Research Methods: To evaluate the model's efficacy and learner experience, we created a 5-point Likert scale survey to determine whether respondents believed the model was realistic enough to improve their comfort with performing an ultrasound-guided pericardiocentesis. The survey assessed prior experience with the simulation model, whether different models had been used, and individual experience including its utility in representing both subxiphoid and parasternal approaches to the procedure.

Results: From a total of 16 completed surveys, one respondent had performed the procedure clinically, and two had used other simulation models. On a 5-point scale, average comfort level to model usage significantly increased 1.38 points from pre- to post-simulation ($P < 0.0001$). On average, respondents rated the model useful in learning the anatomy and ultrasound image acquisition of the procedure and felt better prepared to perform the procedure post-simulation.

Discussion: Our model provided learners the opportunity to practice ultrasound-guided pericardiocentesis with very little cost or effort to create. Users were able to glean feedback in real-time from the images shown on the ultrasound, as well as from the fluid collected in the syringe. The model differed from others by allowing users to practice in two different views with true anatomical landmarks. Survey results indicate the model was effective in improving learner experience since 87.5% of respondents felt more comfortable with performing the procedure post-simulation. Overall, this model proved useful in offering learners a realistic and cost-effective training model for the practice of a rare but important procedure. Emergency medicine residency programs will benefit from the ability to teach and practice ultrasound-guided pericardiocentesis in a controlled environment with immediate opportunities for feedback.

Topics: Ultrasound, pericardiocentesis, model construction, model demonstration, subxiphoid view, parasternal view, simulation model, emergency medicine, cardiac tamponade treatment, cost-effective model.



USER GUIDE

List of Resources:

Abstract	1
User Guide	3

Learner Audience:

Medical Students, Interns, Junior Residents, Senior Residents

Time Required for Implementation:

Preparation: Each model can be assembled in 5-10 minutes.

Didactics: Learners can complete this skill session in 20-30 minutes. They will spend 5-10 minutes discussing the indications, contraindications, and complications associated with ultrasound-guided pericardiocentesis. They will then spend 5-10 minutes showing competence in obtaining subxiphoid and parasternal long views. Their final 10-15 minutes will involve demonstrating an ability to successfully aspirate pericardial fluid in both subxiphoid and parasternal long views.

Recommended Number of Learners per Instructor:

4:1

Topics:

Ultrasound, pericardiocentesis, model construction, model demonstration, subxiphoid view, parasternal view, simulation model, emergency medicine, cardiac tamponade treatment, cost-effective model.

Objectives:

By the end of this instructional session learners, should be able to:

1. Discuss the risks, benefits, indications and contraindications associated with intubation of a vomiting or hemorrhaging patient.
2. Discuss the indications, contraindications, and complications associated with ultrasound-guided pericardiocentesis.
3. Demonstrate an ability to obtain subxiphoid and parasternal long views of the heart.
4. Demonstrate an ability to identify pericardial fluid in these two views.

Linked objectives and methods:

The goal of this innovation is to provide learners with a hands-on opportunity to practice a rare but important procedure with real-time feedback for immediate assessment of both subxiphoid and parasternal long views. Learners are expected to come to this session having completed the pre-reading regarding cardiac ultrasound and pericardiocentesis. Prior to performing the procedure, learners will provide related

indications, contraindications, and complications (Objective 1). Additionally, learners will obtain subxiphoid and parasternal long views of the heart using the model and identify structures including pericardial fluid (Objective 2 & 3). Learners will then perform the procedure with faculty providing real-time feedback on probe and needle positioning/manipulation. The model utilizes a fluid-filled balloon that allows learners to also receive visual feedback of successful or unsuccessful performance of the procedure based on the color of the aspirated fluid (Objective 4).

Recommended pre-reading for instructor:

- Geria R. Ultrasound Guided Procedures in Emergency Medicine Practice - Pericardiocentesis. Sonoguide: Ultrasound Guide for Emergency Medicine. <http://www.acep.org/sonoguide/pericardiocentesis.html>. Accessed May 3, 2019.
- Robert J. Chapter 16: Pericardiocentesis. In: *Roberts and Hedges' Clinical Procedures in Emergency Medicine and Acute Care*. 7th ed. Philadelphia, PA: Elsevier; 2018.

Learner responsible content (LRC):

- Geria R. Ultrasound Guided Procedures in Emergency Medicine Practice - Pericardiocentesis. Sonoguide: Ultrasound Guide for Emergency Medicine. <http://www.acep.org/sonoguide/pericardiocentesis.html>. Accessed May 3, 2019.
- Robert J. Chapter 16: Pericardiocentesis. In: Roberts J, ed. *Roberts and Hedges' Clinical Procedures in Emergency Medicine and Acute Care*. 7th ed. Philadelphia, PA: Elsevier; 2018.

Associated content:

- Construction: <https://youtu.be/OFOMAKcWdp0>
- Demonstration: <https://youtu.be/Bz2EgHtr-8E>
- The link provided is to a site that has instructional videos on how to construct and use the model.

Implementation Methods:

Initial Setup:

This model is best used in a small group session with a learner to faculty ratio of 4:1. At least four models should be prepared to simulate varying anatomy. This is obtained by varying the size and fill of each balloon and zip-locked bag per the provided instructions. This also allows multiple opportunities to perform the procedure especially if a learner "fails" by puncturing the model heart.

Faculty Didactic and Procedure Walk-through:

Learners are assessed on knowledge and comfort of performing an ultrasound-guided pericardiocentesis. Faculty should facilitate discussion on indications, contraindications, and



USER GUIDE

complications of the procedure. Faculty should then demonstrate obtaining subxiphoid and parasternal long views on the model and identify all simulated anatomical structures including the presence of pericardial fluid. Faculty then demonstrate performing an ultrasound-guided pericardiocentesis in both views using the model

Learner Practice, Performance, and Assessment:

Faculty should then observe learners obtaining subxiphoid and parasternal long views and have learners identify simulated anatomical structures and pericardial fluid. Faculty observe the learners performing ultrasound-guided pericardiocentesis on the model and provide real-time feedback on probe and needle position/manipulation. The model will provide visual feedback on successful completion of the procedure (including correct needle depth and positioning) based on the aspirate fluid color.

List of items required to replicate this innovation:

1. 1 spherical party balloon
2. 1 zip-close gallon-size storage bag
3. 1 24 fl oz plastic storage container
4. 1 rubber band
5. 1 roll Glad® Press'n Seal® Wrap, cut to 15 in length
6. 1 3M™ Ioban™ Antimicrobial Incise Drape, cut to 15 in length (optional)
7. 7 drops each red and yellow food dye
8. 6-8 oz ultrasound jelly
9. 1 L regular tap water
10. Pork or beef ribs, cut to 4-6 rib slabs
11. Ultrasound equipment with phased array transducer
12. 18-gauge, 8-cm needle and 12-cc syringe

Approximate cost of items to create this innovation:

\$20

Detailed methods to construct this innovation:

A full assembly instructional video is available at:



<https://youtu.be/OF0MAKcWdp0>

Detailed assembly instructions:

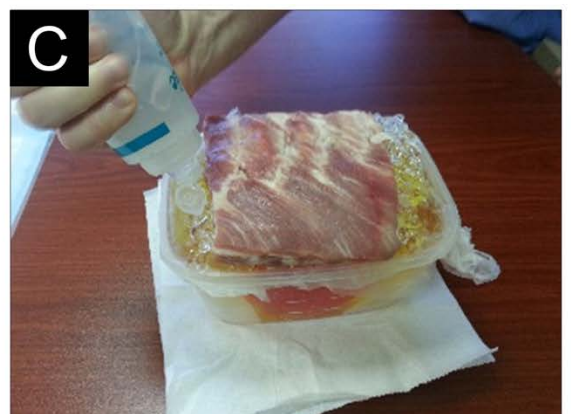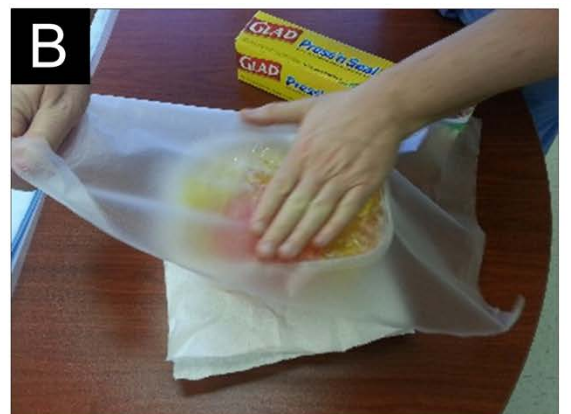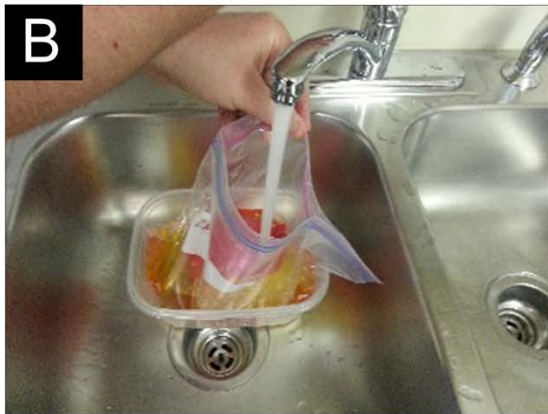1. Add 7 drops red food dye to the deflated balloon (A). Fill balloon with approximately 200-300 mL tap water (or to the approximate size of a child's human fist). Tie-off balloon and set aside (B).



2. Place filled balloon inside gallon-size storage bag (A), and place the storage bag into the plastic container. Add 7 drops of yellow food dye into the storage bag and fill the storage bag with water until the water level is just below the top of the plastic container (B). Carefully, over a sink or trash can, work all excess air out of plastic bag. Slowly compress bag while squeezing air out until only fluid fills the bag. May need to repeat process several times (C).



USER GUIDE

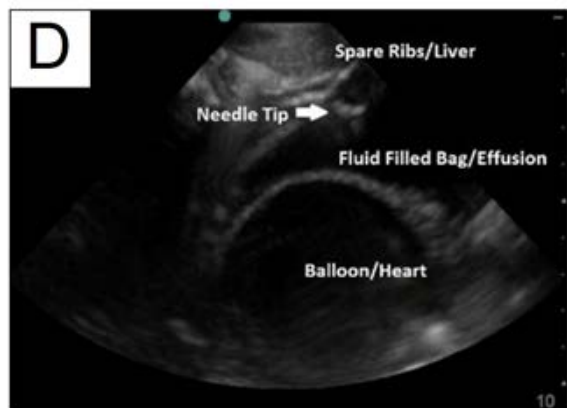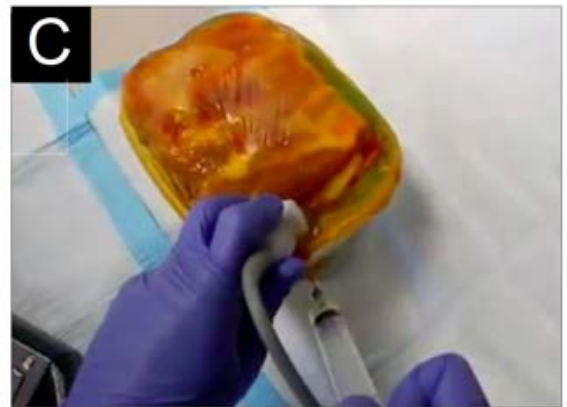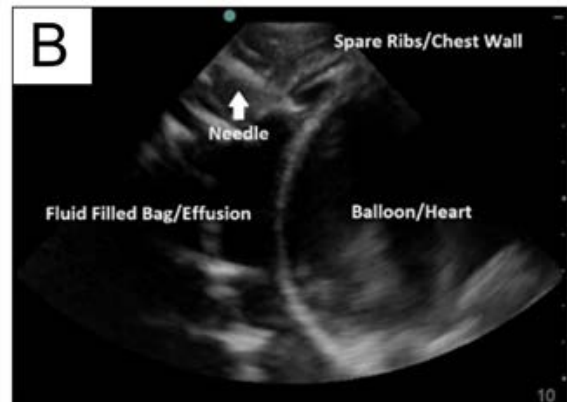


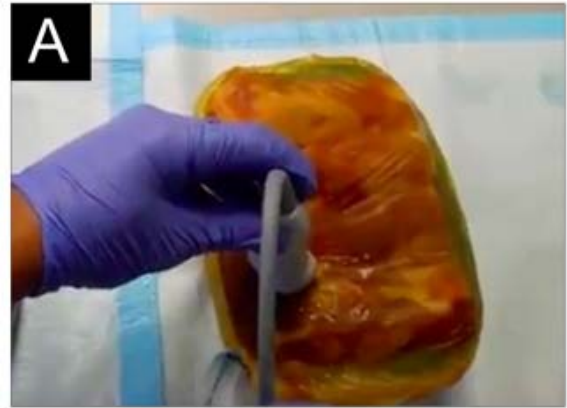3. Liberally coat plastic bag with ultrasound gel so that all space within container is occupied by either bag or gel (A). Any air pockets that remain in the container will alter the ultrasound image and should therefore be avoided. Once the space is filled with gel, seal off top of container with Press'n Seal® Wrap (B). Wearing two pairs of non-latex gloves, cover plastic wrap with a 0.5-1 in (0.03 m) base of ultrasound gel. Place ribs onto gel base. Position ribs at slight angle ($\sim 30^\circ$) to maximize true anatomical simulation (C). Remove top layer of gloves.

4. Cover ribs in additional layer of ultrasound-gel. Add more gel to area surrounding ribs as needed so that all space is occupied by gel and not air.
5. Cover with either Press'n Seal® Wrap or loban™ drape (A). Place rubber band around drape for additional seal. Model is now ready for use (B), or may be refrigerated until needed.



USER GUIDE



- Place probe directly over intercostal space for parasternal long view (A, B). Alternatively, place probe directly beneath ribs for subxiphoid view (C, D). The transducer will display a surrounding layer of fluid (pericardial effusion) separated by a thin wall (myocardium) from a much larger fluid collection resting inside the balloon. The acoustic impedance of the balloon itself is significantly different than that of the fluid surrounding it, allowing for an observed distinction between the two fluid compartments (B, D). During simulation, aspiration should only yield yellow fluid. If a red fluid fills the syringe, the heart has been punctured.

An instructional video is available at:
<https://youtu.be/Bz2EgHtr-8E>



USER GUIDE

Results and tips for successful implementation:

Pericardiocentesis was historically covered as part of our Core EM Procedure curriculum. Following Institutional Review Board approval, this model was utilized as part of a procedure day for our residents during their core conference times. For residency programs, we suggest this approach because it allows a program to cover the greatest number of learners in the shortest amount of time without concerns of the model expiring due to use of pork or beef ribs. We created a survey to determine whether respondents thought the model was realistic enough to improve their comfort with performing an ultrasound-guided pericardiocentesis. The survey was offered during a simulated procedure session as part of our residency conference series. The survey assessed how many attendees had performed the procedure, whether different models had been used, and their individual experience, including its utility in representing the two different ultrasound approaches to the procedure. The survey also provided an opportunity for respondents to provide feedback about the simulation model.

Categorical responses were summarized with frequencies and percentages. Survey responses were scored on a 5-point Likert scale and summarized with measures of central tendency. A paired t-test was used to analyze response change from before to after demonstration of the simulation model. P-values < 0.05 were considered statistically significant.

A total of 16 surveys were completed by 15 self-reported emergency medicine providers and 1 radiologist in various stages of training ranging from medical students to attendings. Only one respondent had performed the procedure clinically. Two respondents had used other simulation models. The overall average comfort level prior to model usage was 1.75 (95% CI=1.32, 2.18) on a linear scale with 1 being "Not at all comfortable" and 5 being "Extremely comfortable." The post-simulation average comfort level was 3.13 (95% CI=2.72, 3.58), exhibiting a significant improvement in comfort performing the procedure by a mean of 1.38 (P<0.0001). Respondents rated the model with a corresponding median score of 4.00 or "Quite useful" in its ability to aid in learning anatomy and ultrasound image acquisition of the procedure. The model was rated the highest in its ability to aid in learning probe and needle position for the procedure with a median score of 4.50.

Overall, respondents rated a median score of 4.00 or "Agree" when asked if after using the model they felt better prepared to perform the procedure. They also rated a median score of 5.00 or "Strongly agree" when asked if after using the model they felt their skills in performing the procedure improved.

When constructing the model, there were a few areas of attention needed to avoid the model pitfalls. The success of the

model requires the successful creation of a pocket of fluid between the simulated chest wall (ribs) and heart (balloon). One thing that we found while constructing the model was that if air was left in the balloon, it would float to the top of the model. This in turn resulted in little to no separation between the simulated chest wall and heart, and a very small or difficult to access simulated pericardial effusion. Solutions to this phenomenon included constructing a smaller heart (filling the balloon with less water), careful expression of all air out of the water-filled balloon, weighing the balloon down with marbles or metal hardware, and securing the balloon down with a tie or adhesive. Additionally, step 3 of construction where air is expressed out of the simulated pericardial sac (gallon-size bag) is technically difficult. Too much air can result in an air pocket forming in the desired ultrasound window resulting in a skewed ultrasound image due to scattering and reverberation artifact. This is best avoided by positioning the gallon-sized bag where the air will rise away from the subxiphoid and parasternal long anatomic landmarks of the model. This may require using padding (such as paper towels) to push the gallon bag towards the "medial" side of the model.

References/suggestions for further reading:

1. Fitch MT, Nicks BA, Pariyadath M, McGinnis HD, Manthey DE. Emergency pericardiocentesis. *N Engl J Med*. 2012;366:e17. doi: 10.1056/NEJMc0907841.
2. Cho BC, Kang SM, Kim DH, et al. Clinical and echocardiographic characteristics of pericardial effusion in patients who underwent echocardiographically guided pericardiocentesis: Yonsei Cardiovascular Center experience, 1993-2003. *Yonsei Med J*. 2004;45(3):462-468. doi: 10.3349/ymj.2004.45.3.462.
3. Okuda Y, Bryson EO, DeMaria S Jr, et al. The utility of simulation in medical education: what is the evidence? *Mt Sinai J Med*. 2009;76(4):330-433. doi: 10.1002/msj.20127.