

## Traumatic Diaphragmatic Rupture—A Case Report

Vincent Hussey, MS\* and Claire Thomas, MD\*

\*University of California, Irvine, Department of Emergency Medicine, Orange, CA

Correspondence should be addressed to Claire Thomas, MD at [clairewt@hs.uci.edu](mailto:clairewt@hs.uci.edu)

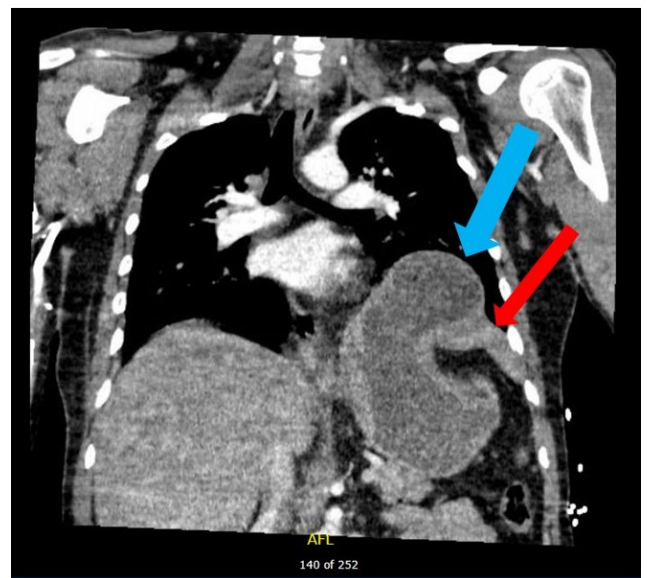
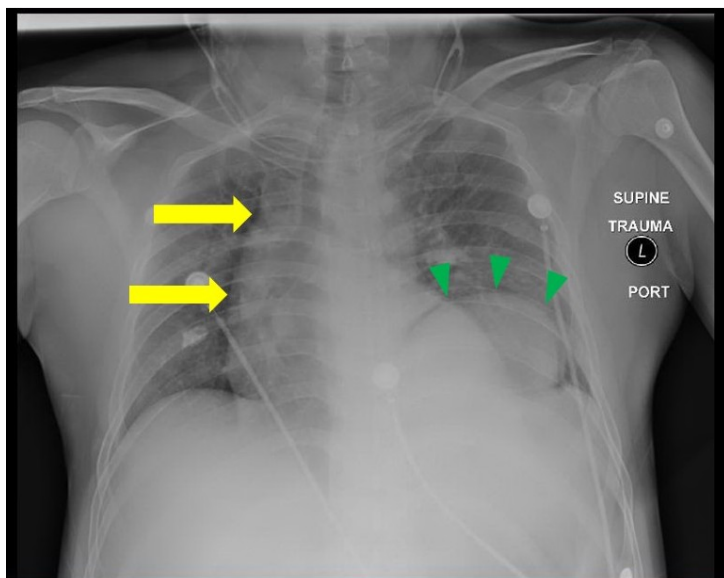
Submitted: April 27, 2019; Accepted: September 11, 2019; Electronically Published: October 15, 2019; <https://doi.org/10.21980/J8G64H>

Copyright: © 2019 Hussey, et al. This is an open access article distributed in accordance with the terms of the Creative Commons Attribution (CC BY 4.0) License. See: <http://creativecommons.org/licenses/by/4.0/>

### ABSTRACT:

Although uncommon, traumatic diaphragmatic rupture (TDR) from blunt force injury is difficult to diagnose and can lead to serious complications if left untreated. Associated symptoms are often non-specific, which can make detection of the injury difficult. Here we present a case report of a patient who suffered a left-sided TDR after blunt trauma. Upon arrival at the emergency department, the patient denied pain but had tenderness to palpation over the epigastrium. A chest X-ray showed an elevated diaphragm on the left with mediastinal shift to the right, and a diagnosis of TDR with stomach herniation was confirmed by computed tomography (CT). The patient was admitted to surgery for reduction and repair and later discharged in good condition. This case report highlights the importance of suspecting TDR in high energy injury mechanisms presenting to the emergency department.

**Topics:** Traumatic diaphragmatic hernia, trauma, blunt trauma.



Video Link: <https://youtu.be/4QI2rWCAG-U>

**Introduction:** Traumatic diaphragmatic rupture can result from penetrating trauma or more rarely from blunt trauma. It is an uncommon diagnosis in trauma activations in the emergency department. An accurate diagnosis is important because untreated diaphragmatic defects can lead to subsequent complications. In this report, we present a case of TDR with associated stomach herniation resulting from blunt trauma.

**Presenting concerns and clinical findings:** A 38-year-old male presented to the emergency department as a trauma activation after an ejection from a motor vehicle. Despite the high energy mechanism of the accident, the patient was not complaining of pain. On exam, the patient's lungs were clear to auscultation bilaterally, and tenderness was noted in the epigastric region. Additionally, the patient had multiple abrasions to his extremities, abdomen, and face. Initial vital signs were heart rate of 93 beats per minute, blood pressure 160/82 mm Hg, respiratory rate 39 breaths per minute and oxygen saturation of 87% on room air.

**Significant findings:** Chest X-ray showed an elevated left hemidiaphragm with superior displacement of a portion of intra-abdominal contents presumed to be the stomach (green arrowheads) with associated rightward mediastinal shift (yellow arrows). The diagnosis was confirmed by CT. Computed tomography imaging of the chest showed a large, left diaphragmatic defect measuring approximately 5.5 cm with herniation of the upper half of the stomach through the defect. The fundus of the stomach (blue arrow) herniated superiorly through the ruptured diaphragm (red arrow).

**Patient course:** The patient was taken to the operating room for exploratory laparotomy. The stomach was reduced back into the abdomen and the diaphragm was repaired. The patient's additional injuries included subdural hematoma, LeFort Fracture I, right frontal skull fracture, and grade two liver laceration. He was discharged in good condition eight days later.

**Discussion:** Traumatic diaphragmatic rupture is a rare traumatic injury which is difficult to diagnose. Symptoms of TDR are non-specific which make the diagnosis challenging.<sup>1</sup> The most commonly associated symptoms of TDR are dyspnea, epigastric pain, chest pain, nausea, and cough. Traumatic diaphragmatic rupture is frequently accompanied by other intra-abdominal and thoracic injuries and is an indicator of severe trauma.<sup>2,3</sup> Some of the most commonly associated injuries include rib fractures, extremity fractures, liver injury, splenic injury and pelvic fractures.<sup>4</sup> Traumatic diaphragmatic rupture can result from penetrating injuries or blunt abdominal trauma, most

notably motor-vehicle collisions. It is thought that the direct blunt blow results in increased intra-abdominal pressure.<sup>2,3</sup> Though early mortality in patients with blunt traumatic diaphragmatic rupture is more often secondary to other injuries, a missed diagnosis of TDR is concerning. Diaphragmatic defects can worsen over time leading to significant morbidity and mortality. Delayed complications include herniation of abdominal organs into the thorax, obstruction, strangulation, and cardiopulmonary dysfunction.<sup>1,5</sup>

Traumatic diaphragmatic rupture has a reported incidence ranging from 0.8%-8% in traumatic injuries in the emergency department.<sup>3</sup> Left-sided TDRs are more common than right-sided TDRs due to the anatomical position of the liver which protects the right side of the diaphragm.<sup>6</sup> Approximately 33% of diagnosed TDRs are due to a blunt mechanism, while 67% are due to a penetrating mechanism.<sup>2</sup> Chest X-ray is often the first modality used to evaluate for diaphragmatic rupture but radiography is insensitive. TDRs are more often found on CT imaging or in exploratory laparotomy. Multidetector CT (MDCT) is the imaging modality of choice for evaluation of TDR, with a sensitivity of 61%-87% and specificity of 72%-100%.<sup>5,7</sup> Despite imaging, an early diagnosis of TDR is often missed or not diagnosed until surgical exploration.<sup>8</sup> Finally, treatment of TDR is surgical reduction and diaphragm repair. This is accomplished most commonly via exploratory laparotomy but also thoracotomy and less invasive approaches.<sup>1,3,4</sup>

## References:

1. Corbellini C, Costa S, Canini T, Villa R, Contessini Avesani E. Diaphragmatic rupture: a single-institution experience and review of the literature. *Turk J Trauma Emerg Surg.* 2017;23(5):421-426. doi: 10.5505/tjtes.2017.78027.
2. Zarour A, El-Menyar A, Al-Thani H, Scalea T, Chiu W. Presentations and outcomes in patients with traumatic diaphragmatic injury. *J Trauma Acute Care Surg.* 2013;74(6):1392-1398. doi: 10.1097/TA.0b013e31828c318e.
3. Ward RE, Flynn TC, Clark WP. Diaphragmatic disruption secondary to blunt abdominal trauma. *J Trauma.* 1981;21(1):35-38. doi: 10.1097/00005373-198101000-00006.
4. Lim KH, Park J. Blunt traumatic diaphragmatic rupture: single-center experience with 38 patients. *Medicine.* 2018;97(41): e12849. doi: 10.1097/md.00000000000012849.
5. Fair KA, Gordon NT, Barbosa RR, Rowell SE, Watters JM, Schreiber MA. Traumatic diaphragmatic injury in the American College of Surgeons National Trauma Data Bank:

- a new examination of a rare diagnosis. *Am J Surg.* 2015;209(5):864-869. doi: 10.1016/j.amjsurg.2014.12.023.
6. Mihos P, Potaris K, Gakidis J, et al. Traumatic rupture of the diaphragm: experience with 65 patients. *Injury.* 2003;34(3):169-172. doi: 10.1016/s0020-1383(02)00369-8.
  7. Leung VA, Patlas MN, Reid S, Coates A, Nicolaou S. Imaging of traumatic diaphragmatic rupture: evaluation of diagnostic accuracy at a level 1 trauma centre. *Can Assoc Radiol J.* 2015;66(4):310-317. doi: 10.1016/j.carj.2015.02.001.
  8. Turhan K, Makay O, Cakan A, et al. Traumatic diaphragmatic rupture: look to see. *European J Cardio-Thoracic Surg.* 2008;33(6):1082-1085. doi:10.1016/j.ejcts.2008.01.029.
  9. Bohay DR, Manoli A. Subtalar joint dislocations. *Foot Ankle Int.* 1995;16(12):803-808. doi:10.1177/107110079501601212.