

SIMULATION

Pulseless Electrical Activity Cardiac Arrest

Erik Sembroski, MD^{*}, Christopher M McDowell, MD[^] and Matthew M Mannion, BA[^]

^{*}University of Missouri—Kansas City School of Medicine, Department of Internal Medicine, Kansas City, MO

[^]Southern Illinois University School of Medicine, Department of Emergency Medicine, Springfield, IL

Correspondence should be addressed to Erik Sembroski, MD at sembroske@gmail.com

Submitted: July 2, 2019; Accepted: October 21, 2019; Electronically Published: January 15, 2020; <https://doi.org/10.21980/J8Z055>

Copyright: © 2020 Sembroski, et al. This is an open access article distributed in accordance with the terms of the Creative Commons Attribution (CC BY 4.0) License.

See: <http://creativecommons.org/licenses/by/4.0/>

ABSTRACT:

Audience: This simulation-based scenario is appropriate for senior level emergency medicine residents.

Introduction: Pulseless electrical activity (PEA) accounts for up to 25% of sudden cardiac arrest;¹ therefore the ability to recognize and care for this condition is an essential skill of emergency medicine physicians. Management of PEA arrest in the emergency department centers on Advanced Cardiac Life Support (ACLS) algorithms and the identification and treatment of potentially reversible causes. Massive pulmonary embolism (PE) is one of several causes of PEA cardiac arrest.² However, diagnosis by CT-angiographic or nuclear imaging may not be obtainable in the hemodynamically unstable patient, requiring physicians to have a high index of suspicion. Systemic thrombolytic therapy is indicated in cardiac arrest due to known or presumed massive pulmonary embolism.^{3,4,5}

Educational Objectives: After competing this simulation-based session, the learner will be able to:

1. Identify PEA arrest
2. Review the ACLS commonly recognized PEA arrest etiologies via the H & T mnemonic
3. Review and discuss the risks and benefits of tissue plasminogen activator (tPA) for massive PE

Educational Methods: This is a high-fidelity simulation that allows learners to evaluate and treat a PEA arrest secondary to massive PE in a safe environment. The learners will demonstrate their ability to recognize a PEA arrest, sort through possible etiologies, and demonstrate treatment of a massive PE with tPA. Debriefing will focus on diagnosis and management of the PEA arrest.

Research Methods: This case was piloted with 12 PGY-2 and PGY-3 residents. Group and individual debriefing occurred post-case.

Results: Post-simulation feedback from the faculty suggested two potential issues. First was fidelity, which we increased by using our ultrasound simulator. Second, the elevated presenting glucose with lactic acidosis could be a poor cue, leading some towards diabetic ketoacidosis (DKA).

SIMULATION

Discussion: Learners felt more confident about running a PEA arrest. The simulation improved resident awareness of the value of point of care ultrasound (POCUS) in cardiac arrest. It also clarified the dosing of tPA in massive PE. Faculty felt simulating the actual US without breaking simulation would be more challenging without our US simulator. Although there was concern about results pointing towards possible DKA, this did not occur in any of the pilot simulations. The presenting glucose was reduced to make this less likely in future simulations.

Topics: Pulseless electrical activity (PEA), syncope, cardiac arrest, Hs and Ts from ACLS PEA instruction, tPA for massive PE, critical care medicine, simulation.



USER GUIDE

List of Resources:

Abstract	1
User Guide	3
Instructor Materials	5
Operator Materials	15
Debriefing and Evaluation Pearls	18
Simulation Assessment	21

Learner Audience:

Senior residents

Time Required for Implementation:

Instructor Preparation: 30-60 minutes

Time for case: 15-30 minutes

Time for debriefing: 15-30 minutes

Recommended Number of Learners per Instructor:

1

Topics:

Pulseless electrical activity (PEA), syncope, cardiac arrest, Hs and Ts from ACLS PEA instruction, tPA for massive PE, critical care medicine, simulation.

Objectives:

By the end of this simulation session, the learner will be able to:

1. Identify PEA arrest
2. Review the ACLS commonly recognized PEA arrest etiologies via the H & T mnemonic
3. Review and discuss the risks and benefits of (tPA) for massive PE

Linked objectives and methods:

By completing this simulation, learners will take a brief history and physical before the patient arrests. After intubation, the patient will arrest and cardiopulmonary resuscitation (CPR) will be initiated. The learner will identify PEA as the rhythm (objective 1) and continue the resuscitation while divulging the possible etiologies via the H&Ts mnemonic (objective 2). Once PE is recognized as a likely cause, the learner will discuss the pros & cons of tPA administration or be prompted to do so. Although learners are familiar with PE, most learners have not all seen cardiac arrest secondary to massive PE. Simulation develops comfort with diagnostic uncertainty and the administration of tPA without confirmatory imaging findings. This case forces them to process the tPA administration risk and benefits in a safe environment (objective 3). Debriefing will ensure that any potential misconceptions or knowledge gaps are addressed.

Recommended pre-reading for instructor:

- DePalo VA, Kharnaf AE. Venous Thromboembolism (VTE) Treatment & Management. In: Medscape. Panchbhavi VK, ed. <https://emedicine.medscape.com/article/1267714-treatment#d10>. Published June 12, 2019. Accessed July 2, 2019.
- Kline JA. Pulmonary embolism and deep vein thrombosis. In: Walls RM, Hockberger RS, Gausche-Hill M, et al. *Rosen's Emergency Medicine: Concepts and Clinical Practice*. 9th ed. Philadelphia, PA: Elsevier; 2018:1051-1066.
- Nickson C. Thrombolysis for submassive pulmonary embolus. Life in the Fast Lane. <https://litfl.com/thrombolysis-for-submassive-pulmonary-embolus/> Updated June 9, 2019. Accessed July 2, 2019.

Results and tips for successful implementation:

This case is best implemented with a team comprised of the learner/upper level resident, pharmacist, nurse, paramedic and family member. We recommend inviting your ED nurses, pharmacists or medics to participate. Faculty or other residents can act as family or embedded participants if staff is not available. The case was initially completed by 12 PGY-2 and PGY-3 residents. Verbal debriefing evaluating the simulation efficacy showed that learners became more comfortable initiating tPA without confirmatory imaging after completing this case. After the initial pilot, laboratory data (eg, venous blood gas, glucose) was amended to prevent exploration of diabetic ketoacidosis as potential etiology. Stimuli were modified to improve the image quality after case feedback.

References/suggestions for further reading:

1. Podrid PJ. Pathophysiology and etiology of sudden cardiac arrest. In: Olshansky B, Manaker S, Downey BC, eds. *UpToDate*. Waltham, MA: UpToDate Inc. <https://www.uptodate.com/contents/pathophysiology-and-etiology-of-sudden-cardiac-arrest>. Updated Apr 18, 2018.
2. Kline JA. Venous Thromboembolism. In: Tintinalli JE, Stapczynski JS, Ma OJ, et al, eds. *Tintinalli's Emergency Medicine: A Comprehensive Study Guide*. 8th ed. New York, NY: McGraw-Hill; 2016:388-398.
3. Kasper W, Konstantinides S, Geibel A, et al. Management strategies and determinants of outcome in acute major pulmonary embolism: results of a multicenter registry. *J Am Coll Cardiol*. 1997;30(5):1165-1171.
4. Sharifi M, Berger J, Beeston P, Bay C, Vajo Z, Javadpoor S. Pulseless electrical activity in pulmonary embolism treated with thrombolysis (from the "PEAPETT" study). *Am J Emerg*



USER GUIDE

Med. 2016;34(10):1963-1967. doi:
10.1016/j.ajem.2016.06.094.

5. Wan S, Quinlan D, Agnelli G, Eikelboom J. Thrombolysis compared with heparin for the initial treatment of pulmonary embolism: a meta-analysis of the randomized controlled trials. *Circulation*. 2004;13(11):38-39. doi: 10.1161/01.CIR.0000137826.09715.9C.
6. DePalo VA, Kharnaf AE. Venous Thromboembolism (VTE) Treatment & Management. In: Medscape. Panchbhavi VK, ed. <https://emedicine.medscape.com/article/1267714-treatment#d10> Published June 12, 2019. Accessed July 2, 2019.
7. Kline JA. Pulmonary embolism and deep vein thrombosis. In: Walls RM, Hockberger RS, Gausche-Hill M, et al. *Rosen's Emergency Medicine: Concepts and Clinical Practice*. 9th ed. Philadelphia, PA: Elsevier; 2018:1051-1065.
8. Nickson C. Thrombolysis for submassive pulmonary embolus. Life in the FastLane. <https://litfl.com/thrombolysis-for-submassive-pulmonary-embolus/>. Published June 9, 2019. Accessed July 2, 2019.
9. Shah SN, Kharnaf AE. Pulseless Electrical Activity. In: Medscape. Dizon JM, ed. <https://emedicine.medscape.com/article/161080-overview>. Published March 27, 2018. Accessed October 30, 2019.
10. Tapson VF, Weinberg AS. Thrombolytic (fibrinolytic) therapy in acute pulmonary embolism and lower extremity deep vein thrombosis. In: Mandel J, Finlay G, eds. *UpToDate*. Waltham, MA: UpToDate Inc. <https://www.uptodate.com/contents/search?search=thrombolytic-fibrinolytic-therapy-in-acute-pulmonary-embolism-and-lower-extremity-deep-vein-thrombosis>. Updated May 3, 2019.
11. Tapson VF, Weinberg AS. Treatment, prognosis, and follow-up of acute pulmonary embolism in adults. In: Mandel J, Hockberger RS, Finlay G, eds. *UpToDate*. Waltham, MA: UpToDate Inc. <https://www.uptodate.com/contents/treatment-prognosis-and-follow-up-of-acute-pulmonary-embolism-in-adults>. Updated Dec 12, 2019.



INSTRUCTOR MATERIALS

Case Title: Pulseless Electrical Activity Cardiac Arrest

Case Description & Diagnosis (short synopsis): Patient is a 40-year-old female brought in by EMS for a suspected syncopal episode after being found unconscious. She was awake and alert at time of EMS arrival but grew increasingly agitated. Paramedics have grown frustrated with her agitation, and her agitation continues upon arrival. She will complain of pain but will not localize and grows progressively distressed. The patient is unable to provide further detailed history, though her family confirms she began birth control in the last few months. She is negative for any other PE risk factors. While in the emergency department she grows increasingly tachypneic, tachycardic, and hypoxic, eventually requiring intubation. Following intubation her blood pressure and pulse are lost and she has a PEA arrest. Participants will need to consider possible etiologies for PEA arrest and implement a treatment strategy. If Hs & Ts are not fully discussed, learners will be verbally prompted by an embedded participant. Participants should establish the diagnosis of massive PE. Ultrasound (US) confirms dilated right ventricle, and participants should discuss the risk and benefits of tPA administration. Embedded participant will prompt the tPA discussion if necessary as well. Participants should then administer tPA, after which they will obtain return of spontaneous circulation (ROSC). Participants may then order computed tomography (CT), which reveals massive PE with bilateral segmental emboli. If participants fail to follow ACLS guidelines, establish the diagnosis of PE, or fail to administer tPA, the patient will proceed to asystole and death.

Equipment or Props Needed:

High fidelity simulator

Infusion pump

IV pole

Cardiac monitor/defibrillator

Crash cart & medications

Intubation equipment

tPA

Confederates needed:

Nurse

Paramedic (control room)

Pharmacist (control room)

Family member (control room)



INSTRUCTOR MATERIALS

Stimulus Inventory:

- #1 Electrocardiogram (ECG)
- #2 Chest Radiograph (CXR)
- #3 Ultrasound/Echocardiogram
- #4 Computed Tomography (CT)
- #5 Basic Metabolic Profile
- #6 Lactic Acid
- #7 Venous Blood Gas

Background and brief information: The scenario occurs in the emergency department at a tertiary care center. The patient is a 40-year-old female brought in by EMS for a suspected syncopal episode. The patient was found unconscious on bathroom floor at work by coworker. She was awake and alert at time of EMS arrival but grew increasingly agitated. Paramedics have grown frustrated with her agitation and refusal to cooperate with their assessment, and this continues on their arrival. She will complain of pain but will not localize and grows progressively distressed in the emergency department. The patient is unable to provide further detailed history, though her family will confirm that she began birth control in the last few months. She is negative for any other PE risk factors. While in the emergency department she grows increasingly tachypneic, tachycardic, and hypoxic, eventually requiring intubation. Following intubation her blood pressure and pulse are lost and she has a PEA arrest. Participants will need to consider possible etiologies for PEA arrest and implement a treatment strategy. If Hs & Ts are not fully discussed, learners will be verbally prompted by an embedded participant.

Initial presentation: Patient is brought in by EMS, who appear frustrated with the patient's lack of cooperation. She is alert, but in severe distress. She is oriented to self but otherwise minimally able to cooperate with history and exam. She is tachypneic and complains of pain and discomfort but cannot localize cause of her distress. She is very agitated, attempting to remove her gown and oxygen mask.

How the scenario unfolds: This patient has a massive PE. Paramedics will be present at the beginning of the case and will give her presenting history in a calm, dismissive tone. The participants should recognize that the patient is sicker than this report suggests and establish IV access, place the patient on the monitor, and apply oxygen. Laboratory and bedside imaging (CXR/US) may be requested at this time, but participants will be told the patient is too unstable for CT. Other than the agitation, tachycardia, and respiratory distress, the exam is



INSTRUCTOR MATERIALS

largely unremarkable. The patient quickly grows increasingly distressed, tachypneic and tachycardic and eventually hypoxic. If the participants do not elect to intubate early, the patient will become progressively hypoxic until this decision is reached (if they attempt to place BiPAP, they will be told that the patient tears it off). Following intubation, the patient has a rapid decline in blood pressure, eventually resulting in loss of pulses and a PEA arrest. The participants should then verbalize Hs and Ts or another approach to determining reversible causes of PEA arrest. The patient will remain in PEA arrest as long as the participants follow ACLS. The participants should identify a massive PE as the most likely cause of the arrest and administer tPA (100 mg IV over two hours). The patient will then have ROSC. Bedside US should be available and if asked for will show right ventricular dilation. Following ROSC and stabilization, if the participants request a CT this will show PE with bilateral segmental emboli. The learners should then discuss with the ICU for admission.

Critical actions:

1. Establish IV access, place the patient on the monitor, and apply oxygen
2. Recognize critically ill patient
3. Intubate
4. Recognize PEA arrest and perform ACLS
5. Discuss reversible causes of PEA
6. Establish diagnosis of PE
7. Administer tPA
8. Admit to ICU



INSTRUCTOR MATERIALS

Case Title: Pulseless Electrical Activity Cardiac Arrest

Chief Complaint: Arrives via EMS. Found in bathroom pale after possible syncope vs. seizure.

Vitals: Heart Rate (HR) 137 Blood Pressure (BP) 110/68 Respiratory Rate (RR) 23
Temperature (T) 36.9°C Oxygen Saturation (O₂Sat) 76% on room air (RA)

General Appearance: 40-year-old female who appears agitated, mottled and dyspneic.

Primary Survey:

- **Airway:** moaning and making incomprehensible noises but not able to state her name when asked
- **Breathing:** rather tachypneic, increased work of breathing
- **Circulation:** pale, cool extremities; no palpable distal pulses

History:

- **History of present illness:** 40-year-old female presents in acute respiratory distress. Per EMS she was found on the bathroom floor by a family member after a loss of consciousness. Initially, they were called for a possible seizure, but on arrival, the patient was agitated and combative. She reports pain and severe trouble breathing but is unable to localize her pain. Her family member arrives and provides history that the patient is on birth control.
- **Past medical history:** Attention deficit disorder
- **Past surgical history:** none
- **Patient's medications:** oral contraceptive pills, amphetamine 20mg
- **Allergies:** No known allergies (NKDA)
- **Social history:** negative for tobacco or recreational drug usage. Occasional alcohol consumption
- **Family history:** unremarkable

Secondary Survey/Physical Examination:

- **General appearance:** patient appears tachypneic and in significant respiratory distress
- **HEENT:**
 - **Head:** normocephalic, atraumatic
 - **Eyes:** Pupils equal and reactive bilaterally
 - **Ears:** Within normal limits (WNL)



INSTRUCTOR MATERIALS

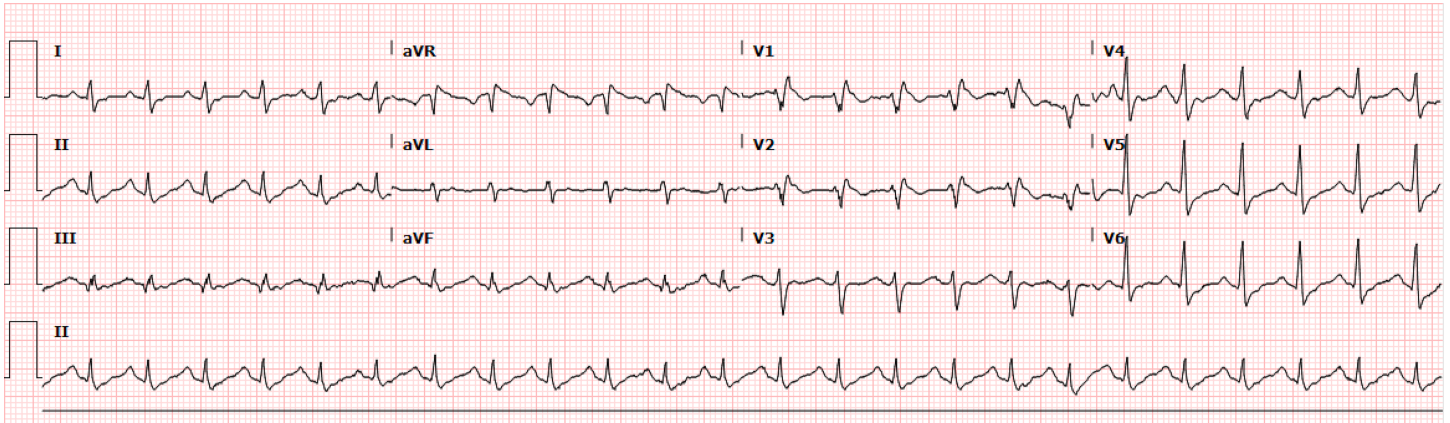
- **Nose:** WNL
- **Throat:** WNL
- **Neck:** WNL
- **Heart:** tachycardic, no murmurs/rubs/gallops
- **Lungs:** diminished but present lung sounds bilaterally; no rales. Severe respiratory distress noted.
- **Abdominal/GI:** soft, mild diffuse tenderness to palpation; no guarding/rebound
- **Genitourinary:** N/A
- **Rectal:** N/A
- **Extremities:** WNL
- **Back:** WNL
- **Neuro:** alert to self only, otherwise uncooperative
- **Skin:** pale/mottled
- **Lymph:** WNL
- **Psych:** agitated, barely conscious



INSTRUCTOR MATERIALS

Results:

Electrocardiogram (ECG)
(author's own image)



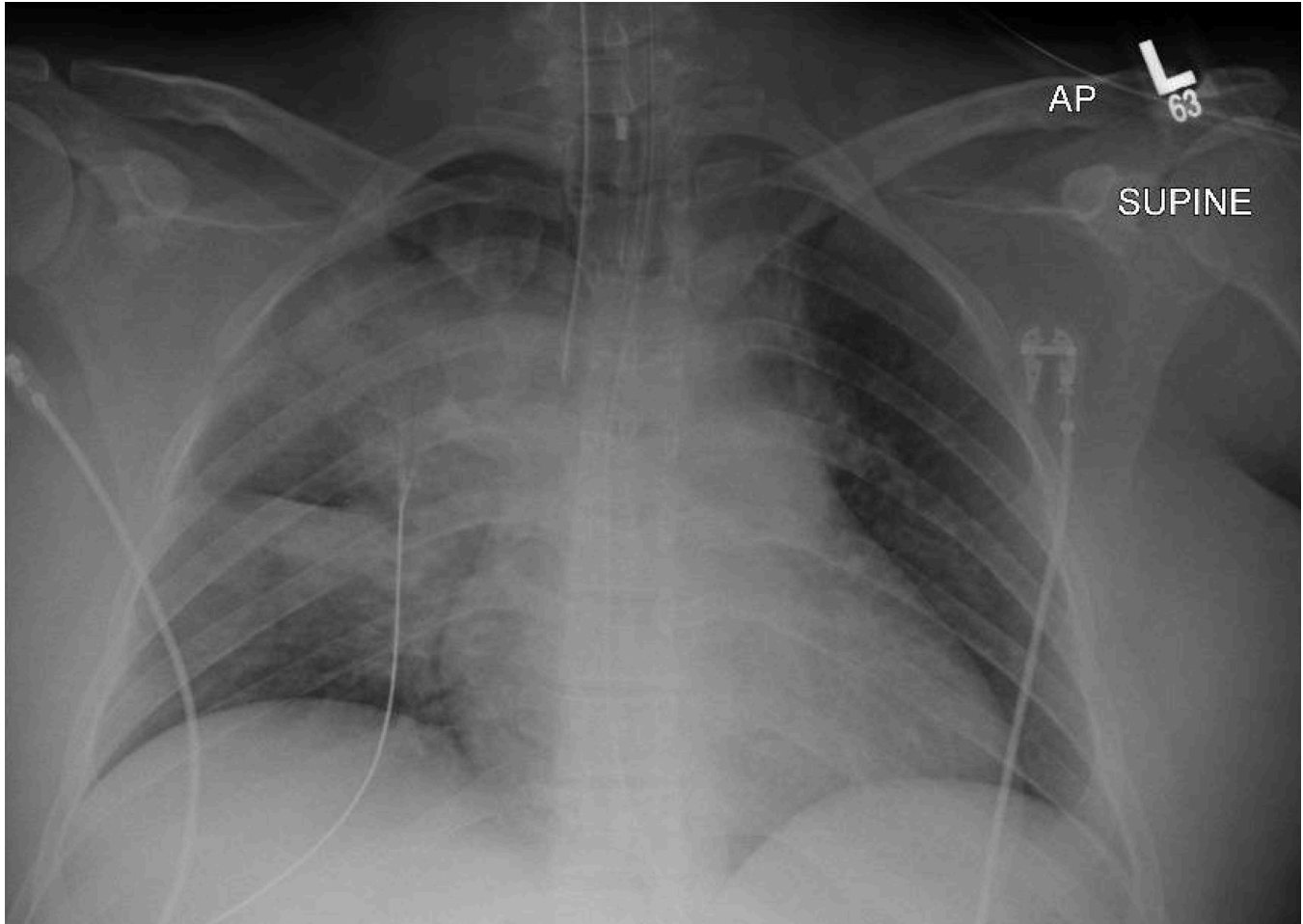


INSTRUCTOR MATERIALS

Chest Radiograph (CXR)

(author's own image)

If chest x-ray is ordered early in the case, learners will be informed it is on the way. CXR can be taken following intubation, arrest, and tPA and is shown below.



EXAMINATION: Single AP view of the chest

HISTORY: Patient admitted to the ER after becoming unresponsive at home in bathroom. Check tube placements.

COMPARISON: None.

FINDINGS: The tip of the endotracheal tube is seen at the level of the carina. Retraction of the endotracheal tube by approximately 3 cm is recommended. The tip of the orogastric tube is seen in the stomach. The cardiomeastinal silhouette is difficult to evaluate due to low lung volumes. There are bilateral patchy opacities in the lungs, right greater than left, which may represent pneumonia, edema, or ARDS. Visualized osseous structures are grossly unremarkable.

IMPRESSION:

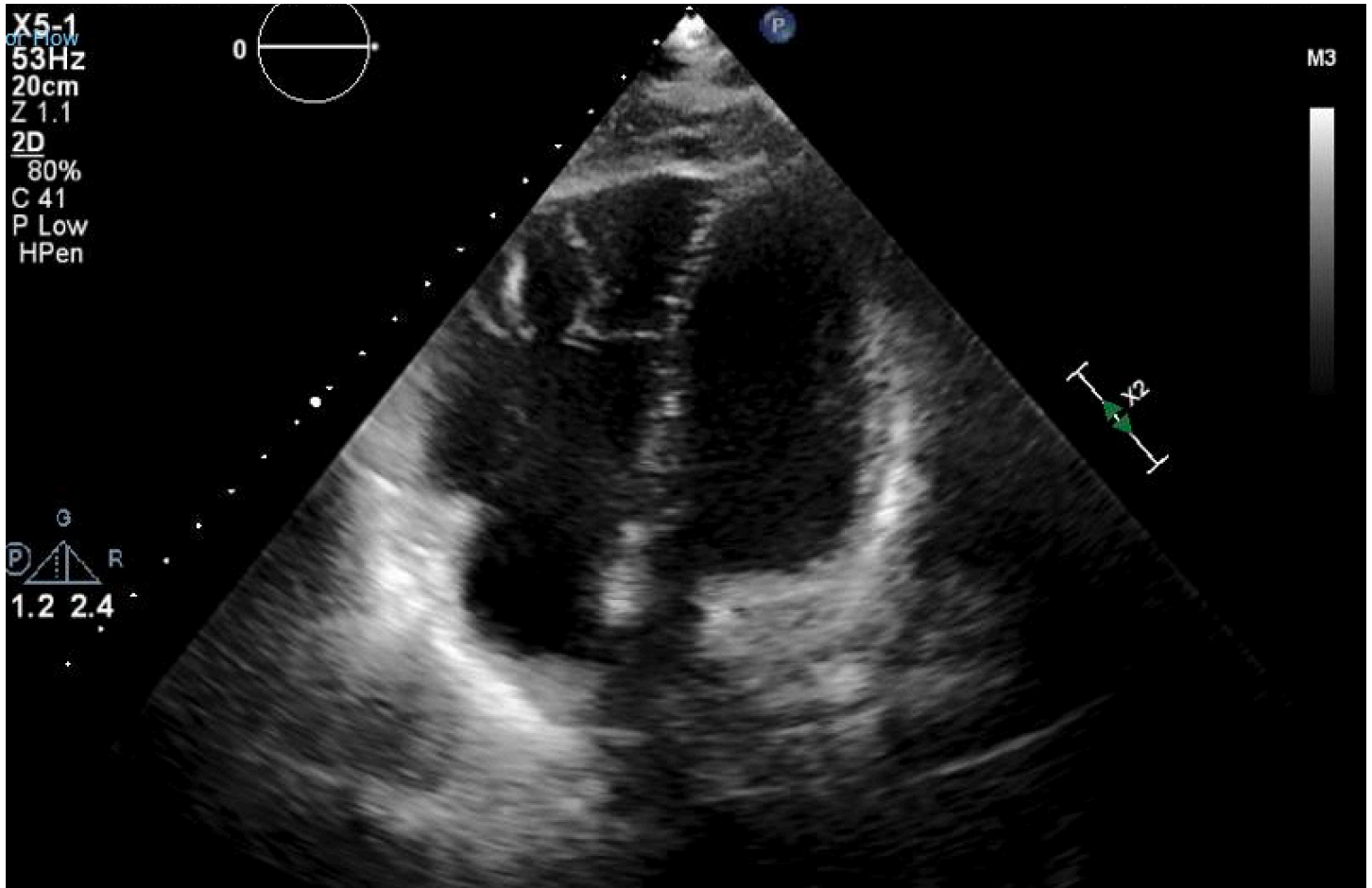
1. The tip of the endotracheal tube is seen at the level of the carina. Retraction of the endotracheal tube by approximately 3 cm is recommended.
2. Bilateral patchy opacities in the lungs, right greater than left, which may represent pneumonia, edema, or ARDS.

Referring provider alerted of Critical result via automated alert system at time of dictation.



INSTRUCTOR MATERIALS

Ultrasound/Echocardiogram
(author's own image)



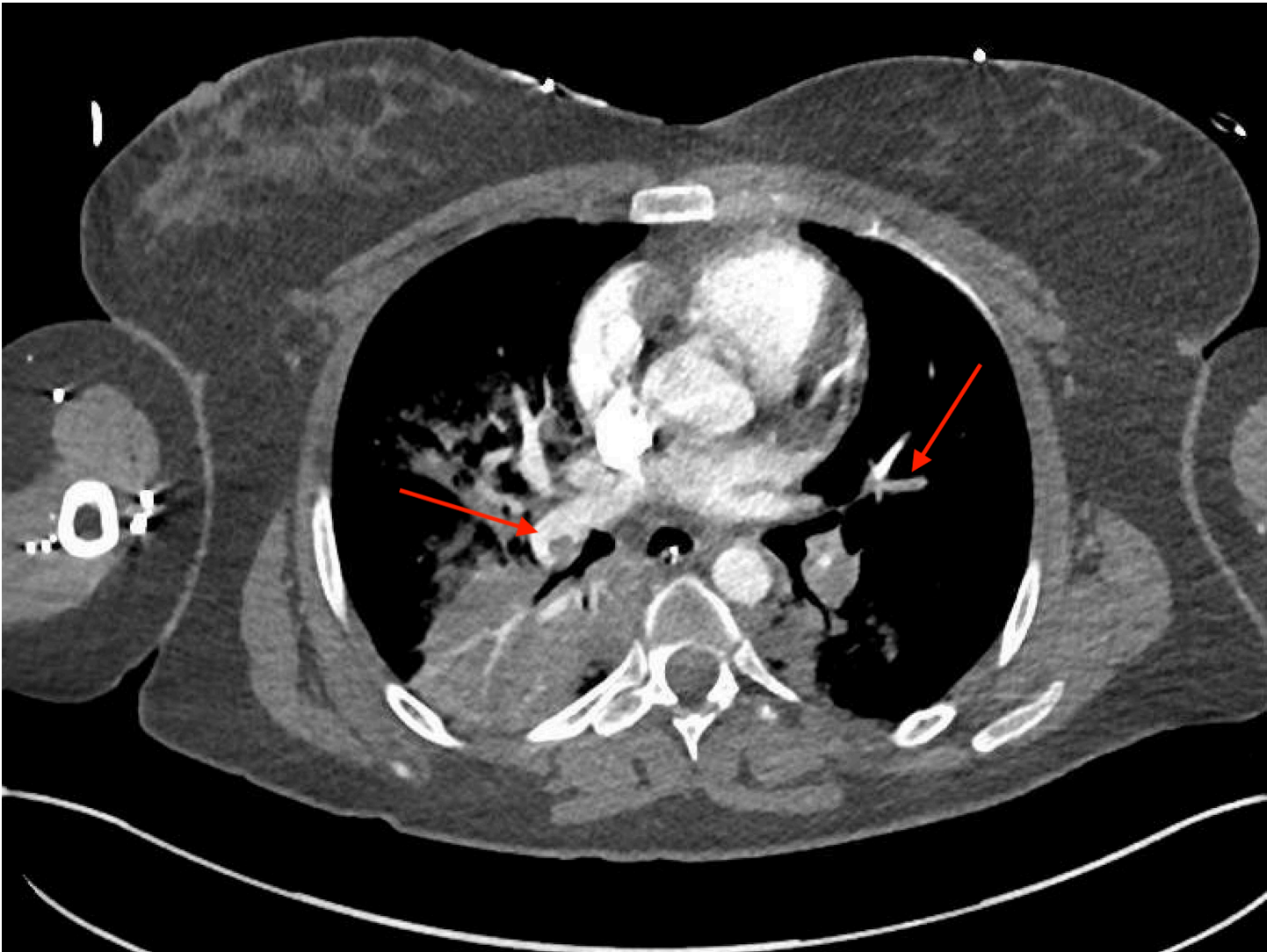


INSTRUCTOR MATERIALS

Computed Tomography (CTA)

(author's own image)

Following arrest, tPA, resuscitation, and ROSC, a CTA may be requested, with image below:



Impression:

1. Extensive pulmonary embolism as described with right ventricular strain
2. Large areas of consolidation in the right lung and to a lesser degree in the left lower lobe indicating pneumonia
3. Periportal edema in the liver and mild ascites
4. Fluid surrounding the pancreas suspicious for acute pancreatitis
5. A 3 cm gastric mass in the distal stomach suspicious for a neoplasm



INSTRUCTOR MATERIALS

Basic metabolic panel (BMP)

Sodium	140 mEq/L
Chloride	101 mEq/L
Potassium	3.6 mEq/L
Bicarbonate (HCO ₃)	18 mEq/L
Blood Urea Nitrogen (BUN)	13 mg/dL
Creatine (Cr)	1.1 mg/dL
Glucose	160 mg/dL
Ionized Calcium	4.4 mg/dL

Lactic Acid 4.1 mEq/L

Venous Blood Gas (VBG)

pH	7.1
PaCO ₂	57 mmHg
PaO ₂	48 mmHg
Bicarbonate (HCO ₃)	16.9 mEq/L
O ₂ saturation, arterial	79%

If further labs are requested, the learners should be informed that lab is running them.



OPERATOR MATERIALS

SIMULATION EVENTS TABLE:

Minute (state)	Participant action/ trigger	Patient status (simulator response) & operator prompts	Monitor display (vital signs)
0:00 (Baseline)	Participants enter the room.	Patient is lying on stretcher, agitated, tachypneic. Paramedics are at bedside to give report. Should be given in a casual/dismissive tone.	Not on monitor
01:00	Assess ABCs Place patient on monitor Establish IV access Place patient on supplemental oxygen Attempt further history from EMS and patient, perform exam	A: Patient is alert, oriented to self, protecting her airway, speaking and moaning in pain. B: Tachypneic, breathing in high 20s. In severe respiratory distress but with clear lung sounds. C: She is tachycardic, pale, mottled, but with adequate initial blood pressure. When placed on supplemental O2 nonrebreather (NRB) patient is adamant it be removed, states "I can't breathe." She is able to say her name, but otherwise does not answer questions. Only states "it hurts" and "I can't breathe." Does not localize pain when asked.	T 36.9°C HR 137 BP 110/68 RR 23 O2 76% room air
03:00 (Initial Resuscitation)	Begin IV fluids Oxygen supplementation Obtain ECG Obtain labs	Tachycardia and blood pressure will stabilize with IVF; however, she will not improve. Patient continues to require increasing amount of supplemental oxygen. ECG provided. Participants will be provided with labs if requested and should be prompted for them when IV is started if they do not request labs. Despite adequate resuscitation the patient's condition continues to decline. Oxygenation worsens despite NRB and patient will not tolerate BiPAP. Tachycardia and hypoxia should continue to progress until decision is made to intubate.	T 36.6°C HR 150 BP 96/50 RR 32 O2 88% NRB



OPERATOR MATERIALS

Minute (state)	Participant action/ trigger	Patient status (simulator response) & operator prompts	Monitor display (vital signs)
	Decision to intubate	Proceed to intubation state.	
05:00 (Delay in treatment)	Despite IV fluids Despite Oxygen supplementation No Decision to Intubate	Tachycardia increases and blood pressure decreases. Hypoxia worsens. Patient arrests—proceed to arrest state.	T 36.6°C HR 162 BP 84/41 RR 35 O2 75% nasal cannula
05:00 Intubation	Prepare for intubation: - Suction - Bag-valve mask - Induction agent - Paralytic Patient should be reevaluated following intubation	Patient paralyzed and sedated. Following intubation, patient’s HR decreases steadily into 70s. BP should be rechecked and is no longer obtainable. Proceed to arrest state.	T 36.6°C HR 162 BP 102/51 RR 12 O2 92% ventilator T 36.6°C HR 74 BP— RR 12 O2 80% ventilator
10:00 PEA Arrest	Begin CPR and progress through ACLS for treatment of PEA Arrest Discussion of Reversible causes (Hs and Ts) Administer tPA	Patient remains in PEA arrest with unchanged condition. Participants may need to be prompted for this discussion while progressing through ACLS. Disparity between patient’s presentation of tachypnea and respiratory acidosis/hypoxia should be discussed. Patient’s family member may be interviewed and will confirm that she is on birth control. Proceed to ROSC.	T 36.6°C HR PEA bagged BP— RR 12 O2 60% ventilator



OPERATOR MATERIALS

Minute (state)	Participant action/ trigger	Patient status (simulator response) & operator prompts	Monitor display (vital signs)
15:00 No tPA Administered	Continue CPR, ACLS Administer tPA	If tPA is not given for presumed PE, patient will progress to asystole and family member will ask for team to “stop everything.” Proceed to ROSC.	
15:00 ROSC	Request for pressor infusion Obtain bedside US and CXR if not done so already Call for CTA Initiate Heparin Infusion	Blood pressure stabilizes, HR increases. Provide CXR and US images as requested. Provide CT images and reports.	T 36.6°C HR 96 BP 112/60 RR 12 O2 90% ventilator
(Case Completion)	Call ICU for admission	ICU accepts the patient.	Case Ends

Diagnosis:

Massive PE; PEA arrest with ROSC

Disposition:

Admission to the medical ICU.



DEBRIEFING AND EVALUATION PEARLS

PEA Arrest

Pearls:

Reversible Causes:

Hs and Ts

- Hypovolemia, hypoxia, hydrogen ions (acidosis), hypokalemia, hyperkalemia, Hypoglycemia, Hypothermia
- Toxins, tamponade (cardiac), tension pneumothorax, thromboembolism (pulmonary or cardiac)

Alternate Approach

Fix with airway

- Hypoxia
- Acidosis (if respiratory)

Fix with a needle

- Tension pneumothorax
- Cardiac tamponade

Fix with an IV

- Hypovolemia – fluid, blood
- Hyperkalemia – calcium, bicarbonate, insulin
- Hypokalemia – potassium/magnesium
- Acidosis (if metabolic) – bicarb
- Hypoglycemia - dextrose
- Massive PE – tPA
- Toxins – antidote

Fix with Dialysis

- Hyperkalemia
- Acidosis
- Toxins

Fix with warming

- Hypothermia

Fix with tPA or heart catheterization

- Acute myocardial infarction

ECG findings of PE

- S1Q3T3 associated with PE (S1Q3 seen on case ECG)
- Most commonly sinus tachycardia



DEBRIEFING AND EVALUATION PEARLS

- Signs of Right heart strain including Right bundle branch block

Ultrasound Findings

- Right ventricular dilation
- Hyperdynamic cardiac function
- McConnell's sign (relative hyperkinesis of apex of right ventricle)

Other debriefing points:

- Discuss the index of suspicion created on entering the room. Report by EMS and their causal air in contrast to patient's appearance. How quickly was safety net established and did initial vitals change participant's perception of the case?
- Discuss the treatment and evaluation of PEA arrest, including progression through analyzing reversible causes and what factors change index of suspicion for each one.
- Discuss the dosing of tPA in massive PE.
- Why did this patient arrest after intubation? (blunting catecholamine response)
- If bedside US was not obtained, discuss how else this patient's likelihood of PE could have been assessed.
- What are this patient's risk factors for PE vs other causes of PEA? What about her presentation suggested PE?

Further reading:

1. DePalo VA, Kharnaf AE. Venous Thromboembolism (VTE) Treatment & Management. In: Medscape. Panchbhavi VK, ed. <https://emedicine.medscape.com/article/1267714-treatment#d10>. Published June 12, 2019. Accessed July 2, 2019.
2. Kline JA. Pulmonary Embolism and Deep Vein Thrombosis. *Rosen's Emergency Medicine: Concepts and Clinical Practice*. 9th ed. Philadelphia, PA: Elsevier, Inc.; 2018. <https://www-clinicalkey.com.siumed.idm.oclc.org/#!/content/book/3-s2.0-B9780323354790000787?indexOverride=GLOBAL>. Accessed October 30, 2019.
3. Nickson C. Thrombolysis for submassive pulmonary embolus. In: Life in the FastLane. <https://litfl.com/thrombolysis-for-submassive-pulmonary-embolus/>. Published June 9, 2019. Accessed July 2, 2019.
4. Shah SN, Kharnaf AE. Pulseless Electrical Activity. In: Medscape. Dizon, JM, ed. <https://emedicine.medscape.com/article/161080-overview>. Published March 27, 2018. Accessed October 30, 2019.
5. Tapon VF, Weinberg AS. Thrombolytic (fibrinolytic) therapy in acute pulmonary embolism and lower extremity deep vein thrombosis. In UpToDate, Mandel J, Finlay G, eds. UpToDate, Waltham, MA, 2019.



DEBRIEFING AND EVALUATION PEARLS

<https://www.uptodate.com/contents/search?search=thrombolytic-fibrinolytic-therapy-in-acute-pulmonary-embolism-and-lower-extremity-deep-vein-thrombosis>. Updated May 3, 2019.

6. Tapson VF, Weinberg AS. Treatment, prognosis, and follow-up of acute pulmonary embolism in adults. In UpToDate, Mandel J, Hockberger RS, Finlay G, eds. UpToDate, Waltham, MA, 2019. <https://www.uptodate.com/contents/treatment-prognosis-and-follow-up-of-acute-pulmonary-embolism-in-adults>. Updated Dec 12, 2019.



SIMULATION ASSESSMENT

PEA Arrest

Learner: _____

Assessment Timeline

This timeline is to help observers assess their learners. It allows observer to make notes on when learners performed various tasks, which can help guide debriefing discussion.

Critical Actions:

1. Establish IV access, place patient on monitor, apply oxygen
2. Recognize critically ill patient
3. Establish definitive airway
4. Recognize PEA arrest and performed ACLS
5. Discuss reversible causes of PEA
6. Establish diagnosis of PE
7. Administer tPA
8. Admit to ICU

0:00



SIMULATION ASSESSMENT

PEA Arrest

Learner: _____

Critical Actions:

- Established IV access, place patient on monitor, apply oxygen
- Recognized critically ill patient and began resuscitation early
- Established definitive airway
- Performed ACLS and recognized PEA arrest
- Discussed reversible causes of PEA
- Establish diagnosis of PE
- Administer tPA
- Patient admitted to ICU

Summative and formative comments:



SIMULATION ASSESSMENT

PEA Arrest

Learner: _____

Milestones assessment:

	Milestone	Did not achieve level 1	Level 1	Level 2	Level 3
1	Emergency Stabilization (PC1)	<input type="checkbox"/> Did not achieve Level 1	<input type="checkbox"/> Recognizes abnormal vital signs	<input type="checkbox"/> Recognizes an unstable patient, requiring intervention Performs primary assessment Discerns data to formulate a diagnostic impression/plan	<input type="checkbox"/> Manages and prioritizes critical actions in a critically ill patient Reassesses after implementing a stabilizing intervention
2	Performance of focused history and physical (PC2)	<input type="checkbox"/> Did not achieve Level 1	<input type="checkbox"/> Performs a reliable, comprehensive history and physical exam	<input type="checkbox"/> Performs and communicates a focused history and physical exam based on chief complaint and urgent issues	<input type="checkbox"/> Prioritizes essential components of history and physical exam given dynamic circumstances
3	Diagnostic studies (PC3)	<input type="checkbox"/> Did not achieve Level 1	<input type="checkbox"/> Determines the necessity of diagnostic studies	<input type="checkbox"/> Orders appropriate diagnostic studies. Performs appropriate bedside diagnostic studies/procedures	<input type="checkbox"/> Prioritizes essential testing Interprets results of diagnostic studies Reviews risks, benefits, contraindications, and alternatives to a diagnostic study or procedure
4	Diagnosis (PC4)	<input type="checkbox"/> Did not achieve Level 1	<input type="checkbox"/> Considers a list of potential diagnoses	<input type="checkbox"/> Considers an appropriate list of potential diagnosis May or may not make correct diagnosis	<input type="checkbox"/> Makes the appropriate diagnosis Considers other potential diagnoses, avoiding premature closure



SIMULATION ASSESSMENT

PEA Arrest

Learner: _____

	Milestone	Did not achieve level 1	Level 1	Level 2	Level 3
5	Pharmacotherapy (PC5)	<input type="checkbox"/> Did not achieve Level 1	<input type="checkbox"/> Asks patient for drug allergies	<input type="checkbox"/> Selects an medication for therapeutic intervention, consider potential adverse effects	<input type="checkbox"/> Selects the most appropriate medication and understands mechanism of action, effect, and potential side effects Considers and recognizes drug-drug interactions
6	Observation and reassessment (PC6)	<input type="checkbox"/> Did not achieve Level 1	<input type="checkbox"/> Reevaluates patient at least one time during case	<input type="checkbox"/> Reevaluates patient after most therapeutic interventions	<input type="checkbox"/> Consistently evaluates the effectiveness of therapies at appropriate intervals
7	Disposition (PC7)	<input type="checkbox"/> Did not achieve Level 1	<input type="checkbox"/> Appropriately selects whether to admit or discharge the patient	<input type="checkbox"/> Appropriately selects whether to admit or discharge Involves the expertise of some of the appropriate specialists	<input type="checkbox"/> Educates the patient appropriately about their disposition Assigns patient to an appropriate level of care (ICU/Tele/Floor) Involves expertise of all appropriate specialists
9	General Approach to Procedures (PC9)	<input type="checkbox"/> Did not achieve Level 1	<input type="checkbox"/> Identifies pertinent anatomy and physiology for a procedure Uses appropriate Universal Precautions	<input type="checkbox"/> Obtains informed consent Knows indications, contraindications, anatomic landmarks, equipment, anesthetic and procedural technique, and potential complications for common ED procedures	<input type="checkbox"/> Determines a back-up strategy if initial attempts are unsuccessful Correctly interprets results of diagnostic procedure



SIMULATION ASSESSMENT

PEA Arrest

Learner: _____

	Milestone	Did not achieve level 1	Level 1	Level 2	Level 3
20	Professional Values (PROF1)	<input type="checkbox"/> Did not achieve Level 1	<input type="checkbox"/> Demonstrates caring, honest behavior	<input type="checkbox"/> Exhibits compassion, respect, sensitivity and responsiveness	<input type="checkbox"/> Develops alternative care plans when patients' personal beliefs and decisions preclude standard care
22	Patient centered communication (ICS1)	<input type="checkbox"/> Did not achieve level 1	<input type="checkbox"/> Establishes rapport and demonstrates empathy to patient (and family) Listens effectively	<input type="checkbox"/> Elicits patient's reason for seeking health care	<input type="checkbox"/> Manages patient expectations in a manner that minimizes potential for stress, conflict, and misunderstanding. Effectively communicates with vulnerable populations, (at risk patients and families)
23	Team management (ICS2)	<input type="checkbox"/> Did not achieve level 1	<input type="checkbox"/> Recognizes other members of the patient care team during case (nurse, techs)	<input type="checkbox"/> Communicates pertinent information to other healthcare colleagues	<input type="checkbox"/> Communicates a clear, succinct, and appropriate handoff with specialists and other colleagues Communicates effectively with ancillary staff