

Acute Flaccid Myelitis

Dane Zappa, MD* and Linda L Herman, MD, FACEP^

*Vituity Healthcare and Medical Staffing Services, St Agnes Medical Center, Department of Emergency Medicine, Fresno, CA

^Sutter Roseville Medical Center, Department of Emergency Medicine, Roseville, CA

Correspondence should be addressed to Linda L Herman, MD, FACEP at hermanll@sutterhealth.org

Submitted: June 2, 2021; Accepted: November 12, 2021; Electronically Published: July 15, 2022; <https://doi.org/10.21980/J8MP9G>

Copyright: © 2022 Zappa, et al. This is an open access article distributed in accordance with the terms of the Creative Commons Attribution (CC BY 4.0) License. See: <http://creativecommons.org/licenses/by/4.0/>

ABSTRACT:

Audience: Emergency medicine residents and medical students on emergency medicine rotation.

Introduction: Although a somewhat rare disease, acute flaccid myelitis (AFM) can cause death, and for those pediatric patients that survive, less than 10% have full recovery.¹ A cluster of cases that resembled polio was first described in California in 2012.² After 120 cases of the disease were confirmed in 2014 in a 5-month period, the Centers for Disease Control and Prevention (CDC) began surveillance of the disease. Since surveillance began, clusters of cases have occurred in a biennial pattern, usually late summer and early fall. There were 218 cases between 2015 to 2017, 238 cases in 2018, 47 cases in 2019, and 32 in 2020.^{3,4,5} AFM has become recognized as a global disease with cases reported across many countries.¹ The CDC has noted that the most common location of the first medical encounter of pediatric patients presenting with AFM is the emergency department in every year that surveillance occurred.⁵ Most of the children that are diagnosed with AFM are admitted to the hospital and of those admitted, 30% require intubation.⁵ Deaths related to AFM are due to respiratory involvement and complications. With appropriate recognition and supportive care, mortality can be avoided.

Educational Objectives: At the end of this oral board session, examinees will: 1) demonstrate the ability to obtain a complete pediatric medical history, 2) demonstrate an appropriate exam on a pediatric patient including a neurological exam, 3) investigate the broad differential diagnoses for neuromuscular weakness in a pediatric patient, 4) order the appropriate evaluation studies including an MRI, 5) interpret the use of a negative inspiratory force in determining the need for intubation and level of care upon admission, and 6) demonstrate effective communication with parents and caregivers.

Educational Methods: Oral board case following a standard American Board of Emergency Medicine-style case in a tertiary care hospital with access to all specialists and resources needed. This case was tested using 5 resident volunteers ranging from PGY 1 – 3 in an ACGME (Accreditation Council for Graduate Medical Education)-accredited emergency medicine program. Also, approximately 3 - 5 observers (other

ORALboards

residents and medical students) were present during the presentation. Learners were immediately able to provide feedback during the debriefing of the case.

Research Methods: Immediate Feedback was solicited from the learners and observers participating in the case both by verbal discussion and completion of a rating for the case following the debriefing. The efficacy of the educational content was assessed by comparing scoring measures across residents based on the training year. Scoring measures of the ACGME core competencies were performed using a scale from 1 – 8, 1- 4 being unacceptable performance and 5 – 8 being acceptable. Efficacy was assumed based on full completion of the case by the residents who acted as practice oral board candidates, and a debriefing session followed to discuss the key components of the case.

Results: Practice candidates were 1 PGY1 level, 2 PGY2 Level and 2 PGY3 level residents. All residents that were practice candidates anchored on the diagnosis of Guillain-Barré Syndrome (GBS) but despite the anchoring were able to manage the patient appropriately and safely. The average score for practice candidates per level was: PGY1: 5.1, PGY2: 5.8, and PGY3: 6.5. The critical action missed by the PGY1 resident was ordering a negative inspiratory force and one PGY2 did not completely order all of the spinal MRI. All learners, both practice candidates and observers rated the case as 4.2 (1 – 5 Likert scale, 5 being excellent).

Discussion: The educational content effectiveness was two-fold. The content was effective for teaching the presentation and appropriate evaluation to diagnose AFM. AFM is significantly like the presentation of poliomyelitis which originally occurred in sporadic cluster outbreaks and then the number of cases in the United States doubled every 4 – 5 years from 1940 – 1952.⁶ AFM is a disease that occurs in a biennial pattern and needs to be recognized and reported appropriately. The case also encouraged the cognizance of other etiologies for acute neuromuscular weakness in a pediatric patient which may require different diagnostic evaluation and medical management. AFM's clinical presentation generally involves asymmetric weakness and may occur in either an ascending or descending pattern with the nadir to maximum weakness attained in a few days. Although there are variants of GBS, the neuromuscular weakness is usually symmetrical and occurs in an ascending pattern with the nadir being reached in 1 – 2 weeks.⁷ AFM requires an MRI with specific abnormalities to meet the case definition while an MRI can be performed when GBS is suspected, but it is not necessary. AFM MRI abnormalities demonstrate brainstem and spinal cord lesions with a predominance of gray matter affected while a GBS MRI demonstrates ventral root abnormalities without any spinal cord or brainstem lesions. Without the MRI results, a patient may be assigned the incorrect diagnosis upon admission. A lumbar puncture and electromyography are required for the diagnosis of GBS. The cerebrospinal fluid (CSF) of GBS demonstrates high protein levels and white blood cell count (WBC) < 10 cells/mm³ while the CSF of AFM demonstrates pleocytosis although usually < 100 cells/mm³.^{1,8} Electromyography will be abnormal in both GBS and AFM, but the test is not necessary for the diagnosis of AFM as it is with GBS. Both intravenous immunoglobulin (IVIG) and plasma exchange

ORALboards

shorten the recovery time of GBS while there is no recommendation for treatment of AFM at this time. IVIG, plasmapheresis, and steroids have been utilized with unclear benefits.^{1,8} Physical therapy and occupational therapy appear to be significantly important in AFM with nerve transfer surgery as a possibility of cure to areas of muscles that have not recovered significant function in AFM.⁹ Reaching the appropriate diagnosis allows the emergency medicine physician to communicate more accurately with worried parents, providing them with correct information on treatment and progression of the disease.

Topics: Pediatric weakness, pediatric neurologic disorders, acute flaccid myelitis, Gullian-Barré Syndrome, neuromuscular weakness.



USER GUIDE

List of Resources:

Abstract	1
User Guide	4
For Examiner Only	6
Oral Boards Assessment	13
Stimulus	16
Debriefing and Evaluation Pearls	28

Learner Audience:

Medical students, interns, junior residents, senior residents

Time Required for Implementation:

Case: 15 minutes if used as a single case, approximately 10 minutes if part of a triple case

Debriefing: 5 minutes (when using the oral boards for practice), 10 minutes (when using oral boards case for teaching)

Learners per instructor:

Recommend one learner per instructor if using as an oral board case, may have other learners present to observe.

Topics:

Pediatric weakness, pediatric neurologic disorders, acute flaccid myelitis, Guillain-Barré Syndrome, neuromuscular weakness.

Objectives:

By the end of this oral boards case, examinees will be able to:

1. Demonstrate the ability to obtain a complete pediatric medical history.
2. Demonstrate an appropriate exam on a pediatric patient including neurological exam.
3. Investigate the broad differential diagnoses for neuromuscular weakness which include AFM, Guillain-Barré syndrome (GBS), spinal cord stroke, demyelinating myelitis, poliomyelitis, other infectious myelitis, acute plexopathy, periodic paralysis, botulism, toxic synovitis.
4. Order the appropriate evaluation studies including an MRI.
5. Interpret the use of a negative inspiratory force in determining the need for intubation and level of care upon admission.
6. Demonstrate effective communication with parents and caregivers.

Linked objectives and methods:

The presented case asks learners to care for a pediatric patient with an acute neurologic disorder. In order to effectively

diagnose and treat the patient, they will need to understand that this patient is sick, solicit a full history from the patient's parent, and transition care to the inpatient side. The oral boards format worked best for this case because any patient that presents with acute weakness and respiratory compromise most commonly creates an anchor (particularly in learners) to Guillain-Barré Syndrome. Utilizing the oral boards format and the associated time limit allows learners to use this anchor while still treating the patient successfully, and then discuss other similar causes of neuromuscular pathology with respiratory decline that should be considered.

Recommended pre-reading for instructor:

- None, review references as needed

Results and tips for successful implementation:

This case was presented at a residency program that practices oral boards with all residents semi-annually. It is best utilized after learners understand the basic format of oral boards, the time constraints, and what resources are available to them. We did not test this case on interns who had no experience with an oral boards case. This case was tested on five learners with approximately 3 – 5 resident or medical student observers in each group. Results were highly similar, with learners treating the patient as a GBS case and managing appropriately. Modifications were made to the case following its testing to make the case more classic for AFM with differentiation from other etiologies such as GBS. Feedback was mixed: most of the learners enjoyed the case and appreciated the learning points regarding acute flaccid myelitis as another item on their updated differential, while some of the learners felt misled to GBS. Our suggestion is that if the learner diagnoses and treats this patient as a GBS patient, at the end of the case make sure to recognize that they did so correctly, even if the diagnosis was incorrect. Emphasize that the purpose of this case is to expand the differential list, and that it was not designed to trick the learner. This is a unique opportunity to expand a real differential diagnosis list while avoiding harm in even a theoretical patient.

References/suggestions for further reading:

1. Murphy OC, Messacar K, Benson L, et al. Acute flaccid myelitis: cause, diagnosis, and management. *Lancet*. 2021 Jan 23;397(10271):334-346.
2. Van Haren K, Ayscue P, Waubant E, et al. Acute flaccid myelitis of unknown etiology in California, 2012-2015. *JAMA*. 2015; 314: 2663-71.
3. Ayers T, Lopez A, Lee A, Kambhampati A, et al. Acute Flaccid Myelitis in the United States: 2015-2017. *Pediatrics*. 2019 Nov;144(5):e20191619.
4. AFM Cases and Outbreaks. Centers for Disease Control & Prevention: Acute Flaccid Myelitis. Published April 1, 2022. Accessed 4/5/2022. At: <https://www.cdc.gov/acute-flaccid->



USER GUIDE

myelitis/cases-in-us.html#:~:text=In%202015%2C%20there%20were%2022%20total%20confirmed%20cases%20in%2017%20states.&text=In%202014%2C%20there%20were%20120,than%2022%20years%20of%20age

5. Kidd S, Yee E, English R, et al. National Surveillance for Acute Flaccid Myelitis – United States, 2018 – 2020. *Morbidity Mortality Weekly Rep.* 2021; 70:1534-1538. DOI: <http://dx.doi.org/10.15585/mmwr.mm7044a2>
6. “Break the back of Polio.” Yale Medical Magazine. Published Autumn 2005. Accessed April 8, 2022. At: <https://medicine.yale.edu/news/yale-medicine-magazine/article/breaking-the-back-of-polio/>
7. Helfferich J, Roodbol J, de Wit MC, Brouwer OF, Jacobs BC; 2016 Enterovirus D68 Acute Flaccid Myelitis Working Group and the Dutch Pediatric GBS Study Group. Acute flaccid myelitis and Guillain-Barré syndrome in children: A comparative study with evaluation of diagnostic criteria. *Eur J Neurol.* 2022 Feb;29(2):593-604. PMID: 34747551. Epub Nov 24, 2021. At: doi:10.1111/ene.15170
8. Gupta N, Andrus P. Acute Peripheral Neurologic Disorders. In: Tintinalli JE, Ma JO, Yealy Dm, et al, eds. *Tintinalli’s Emergency medicine: A Comprehensive Study Guide.* 9th ed. New York, NY: McGraw-Hill 2020: 1160.
9. Vawter-Lee M, Peariso K, Frey M, et al. Acute Flaccid Myelitis: A Multidisciplinary Protocol to Optimize Diagnosis and Evaluation. *J Child Neurol.* 2021 May;36(6):421-431.
10. Case Definitions for AFM. Centers for Disease Control & Prevention. Published September 21, 2021. Accessed April 4, 2022. At: <https://www.cdc.gov/acute-flaccid-myelitis/hcp/casedefinitions.html>
11. Hopkins SE, Desai J, Benson L. Acute Flaccid Myelitis: A Call for Vigilance and an Update on Management. *Pediatr Neurol.* 2021 Jan; 114:26-28.



FOR EXAMINER ONLY

Oral Case Summary

Diagnosis: Acute Flaccid Myelitis

Case Summary: A 6-year-old male without known chronic medical illnesses presents to the ED brought in by mother complaining that he has difficulty walking and less use of the right arm. The symptoms began two days ago and have been progressively worsening. He has never experienced this in the past. He had upper respiratory symptoms with rhinorrhea and a nonproductive cough 5 days ago. At that time, he ate normally, did not have a fever, and there were no GI symptoms. The exam reveals an asymmetric upper and lower extremity weakness, diminished deep tendon reflexes with preserved sensation in the lower extremities, preserved deep tendon reflexes and sensation in the upper extremities. The patient requires an evaluation for the neurological findings which includes laboratory, MRI, and lumbar puncture. The most significant complication is respiratory compromise, so the learner needs to order a negative inspiratory force (NIF) and interpret correctly. The patient does develop respiratory compromise during the stay in the ED, and the learner will have to intubate.

Order of Case: Patient arrives by private vehicle accompanied by the mother. The patient is triaged, and vital signs are performed. The learner then obtains the history from the mother which should include childhood immunization history and past medical illnesses including recent upper respiratory infection symptoms. If the learner does not ask the mother about prior illnesses, the nurse or ED technician should state, “Did the mother mention that he was sick recently?” The physical exam is then performed and includes assessment of upper and lower extremity strength, deep tendon reflexes, sensation, and ambulation. If the learner does not perform a complete exam, the patient should tell the nurse that he has to go to the restroom, and mother states that he is too weak to walk there. After the history and examination, the learner should order appropriate diagnostic testing and also request that the respiratory therapist perform a NIF. A normal NIF of -32 cm H₂O is obtained and the patient is placed on oxygen. The laboratory evaluation should include CBC, BMP, blood culture, thyroid panel, CK, VBG or ABG, CXR, urinalysis, COVID swab, influenza testing. The learner should realize that this is a spinal cord disorder and not order a CT of the brain. If the learner does order a CT, the nurse should ask, “what do you think that the CT will show?” The learner should order an MRI (with and without contrast) of the cervical, thoracic, and lumbar spinal cord. While waiting for the MRI to be performed, the learner should perform a lumbar puncture (LP), explaining risks and benefits to the mother. If the learner does not perform the LP, the nurse should tell the learner, “MRI called and said that they are backed up. Is there anything that you want to do while we are waiting?” Upon returning from MRI, the patient



FOR EXAMINER ONLY

complains of shortness of breath. He now is tachypneic and hypoxic. The learner may ask for a repeat NIF or decide to intubate. The patient is placed on a ventilator. The results of the diagnostic evaluation return and the learner makes the diagnosis, admits to the PICU, and places a neurology consult.

Disposition: Admission to Pediatric Intensive Care Unit (PICU)

Critical Actions:

1. Performs complete physical examination including strength, deep tendon reflexes, and ambulation.
2. Obtains a Negative Inspiratory Force (NIF)
3. Orders cervical, thoracic, and lumbar spinal cord MRI with and without contrast
4. Performs lumbar puncture after explaining risks and benefits to mother
5. Intubates the patient
6. Admits patient to the PICU



FOR EXAMINER ONLY

Historical Information

Chief Complaint: Weakness

History of present illness: 6-year-old male without known chronic medical illnesses, uncomplicated birth, previously ambulatory, presents with difficulty with ambulation. Had an upper respiratory infection 5 – 7 days prior to arrival. No other positive review of systems. Mother first noted two days ago when he was unsteady but now having difficulty standing when getting up. Mother also noted that he has been favoring his right arm and using only his left to eat and pick up objects. He had complained of pain in the right arm before he began to favor the arm, but he told her that the pain was gone.

Past Medical history: No past medical history, immunizations up-to-date

Past Surgical history: None

Patient's Medications: Occasional acetaminophen

Allergies: None

Social history:

- Tobacco: None
- Alcohol: No tobacco use, no exposure to secondhand smoke in the home
- Drug use: None

Family history: Mother and father are both healthy, no siblings



FOR EXAMINER ONLY

Physical Exam Information

Vitals: HR 108 BP 95/62 RR 22 Temp 37°C O₂Sat 94%

Weight: 20.4 kg (45 lbs) **Height:** 45 inches

General appearance: Disheveled, mild-to-moderate distress

Primary survey:

- **Airway:** Intact
- **Breathing:** Breath sounds clear bilaterally
- **Circulation:** No gross signs of hemorrhage or blood loss, peripheral pulses palpable and symmetrical, capillary refill less than 2 seconds

Physical examination:

- **General appearance:** Well-developed, well-nourished male, no acute distress although appears uncomfortable
- **Head, eyes, ears, nose and throat (HEENT):**
 - **Head:** atraumatic, normocephalic (within normal limits)
 - **Eyes:** Pupils equal and reactive (within normal limits)
 - **Ears:** TMs are clear (within normal limits)
 - **Nose:** Within normal limits
 - **Oropharynx/Throat:** Moist mucus membranes, pharynx clear, no cracked lips (within normal limits)
- **Neck:** No lymphadenopathy, no thyromegaly (within normal limits)
- **Chest:** Equal chest rise but shallow, clear breath sounds, diminished in the bases
- **Cardiovascular:** Normal heart sounds, regular, peripheral pulses palpable, and symmetrical, capillary refill less than 2 seconds (within normal limits)
- **Abdominal/GI:** Active bowel sounds, soft, nontender, no hepatomegaly, no masses (within normal limits)
- **Genitourinary:** Within normal limits
- **Rectal:** Within normal limits
- **Extremities:** Scattered small ecchymoses anterior tibial areas (if learner asks, mother states that he received them from falling), no edema, no erythema
- **Back:** Within normal limits
- **Neuro:** Cranial nerves II – XII are intact; diminished strength lower extremities – 3/5, unable to bear weight on lower extremities; unable to ambulate; Right upper extremity



FOR EXAMINER ONLY

(RUE): strength – 4/5; Left upper extremity (LUE): strength – 5/5; Reflexes: RUE and LUE: Brachioradialis and biceps tendon – 2+; Lower extremities – patellar and Achilles tendon – absent; sensation intact to all extremities

- **Skin:** Warm and dry, ecchymoses as described, no rashes
- **Lymph:** Within normal limits
- **Psych:** Alert, oriented, cooperative, appropriate (within normal limits)



FOR EXAMINER ONLY

Critical Actions and Cueing Guidelines

1. **Critical Action 1:** *Performs complete physical examination including strength, deep tendon reflexes and ambulation.*

Patient care

This critical action is met by the learner performing the exam and obtaining the information of asymmetric weakness, preservation of deep tendon reflexes in the upper extremities but not the lower extremities, sensation preservation in all extremities, and difficulty with standing and ambulating.

Cueing Guideline (if applicable): If the learner does not collect that history, the nurse should tell the learner that the patient tried to walk to the bathroom, could not bear weight on either leg for more than 20 seconds, and she had to take him in a wheelchair, and the mother placed him on the toilet.

2. **Critical Action 2:** *Obtain a Negative inspiratory force (NIF).*

Patient care, medical knowledge

This critical action is met by the learner requesting that the respiratory therapist perform a NIF and interpreting it to be normal. Normal NIF is less than -30 cm H₂O. The original NIF is -32 cm H₂O. The learner should recognize that -32 cm H₂O is within the normal range for a NIF but needs to be followed closely with serial measurements. The learner may or may not choose to place the patient on oxygen.

Cueing Guideline (if applicable): If the learner fails to order oxygen or measure an NIF, the mother should mention, "I thought maybe that he was having trouble breathing at home."

3. **Critical Action 3:** *Orders cervical, thoracic, and lumbar spinal cord MRI with and without contrast.*

Patient care, medical knowledge

This critical action is met by the learner recognizing an acute neuromuscular process and requesting an MRI of the cervical and thoracic spinal cord.



FOR EXAMINER ONLY

Cueing Guideline (if applicable): If the learner does not request an MRI, then the nurse should ask the learner if any tests should be ordered. If the learner decides to order a CT scan, the nurse should ask “What do you think the CT will show?”

4. Critical Action 4: *Performs lumbar puncture after explaining risks and benefits to mother.*

Patient care, medical knowledge, interpersonal and communication skills

This critical action is met by the learner consenting the mother for a lumbar puncture, providing adequate analgesia and performing lumbar puncture.

Cueing Guideline (if applicable): If the learner does not perform the LP, the nurse should tell the learner, “MRI called and said that they are backed up. Is there anything that you want to do while we are waiting?”

5. Critical Action 5: *Intubates the patient*

Patient care, medical knowledge

This critical action is met by the learner recognizing that the patient’s respiratory status is deteriorating and intubating the patient.

Cueing Guideline (if applicable): If the learner does not intubate the patient, then the respiratory therapist should ask, “What would you like me to do?” Each strategy that the learner tries such as high-flow oxygen, BiPap, etc. does not result in decreasing the patient’s respiratory distress or improving the pulse oximeter.

6. Critical Action #6: *Admits patient to the PICU.*

Patient care, systems-based practice, interpersonal and communication skills

This critical action is met by the learner giving report to the pediatric intensivist.

Cueing Guideline (if applicable): If the learner does not admit the patient, the nurse should remind the learner that all the results are back and that a disposition needs to occur.



FOR EXAMINER ONLY



ORAL BOARDS ASSESSMENT

Acute Flaccid Myelitis

Learner: _____

Critical Actions:

- Performs complete physical examination including strength, deep tendon reflexes, and ambulation. (patient care)
- Obtains a Negative Inspiratory Force (NIF) (patient care, medical knowledge)
- Orders cervical, thoracic, and lumbar spinal cord MRI with and without contrast (patient care, medical knowledge)
- Performs lumbar puncture after explaining risks and benefits to mother (patient care, medical knowledge, interpersonal and communication skills)
- Intubates the patient (patient care, medical knowledge)
- Admits patient to the PICU (patient care, systems-based practice, interpersonal and communication skills)

Summative and formative comments:

Milestone assessment:

	Milestone	Did not achieve level 1	Level 1	Level 2	Level 3
1	Emergency Stabilization (PC1)	<input type="checkbox"/> Did not achieve Level 1	<input type="checkbox"/> Recognizes abnormal vital signs	<input type="checkbox"/> Recognizes an unstable patient, requiring intervention Performs primary assessment Discerns data to formulate a diagnostic impression/plan	<input type="checkbox"/> Manages and prioritizes critical actions in a critically ill patient Reassesses after implementing a stabilizing intervention



ORAL BOARDS ASSESSMENT

Acute Flaccid Myelitis

Learner: _____

	Milestone	Did not achieve level 1	Level 1	Level 2	Level 3
2	Performance of focused history and physical (PC2)	<input type="checkbox"/> Did not achieve Level 1	<input type="checkbox"/> Performs a reliable, comprehensive history and physical exam	<input type="checkbox"/> Performs and communicates a focused history and physical exam based on chief complaint and urgent issues	<input type="checkbox"/> Prioritizes essential components of history and physical exam given dynamic circumstances
3	Diagnostic studies (PC3)	<input type="checkbox"/> Did not achieve Level 1	<input type="checkbox"/> Determines the necessity of diagnostic studies	<input type="checkbox"/> Orders appropriate diagnostic studies <input type="checkbox"/> Performs appropriate bedside diagnostic studies/procedures	<input type="checkbox"/> Prioritizes essential testing <input type="checkbox"/> Interprets results of diagnostic studies <input type="checkbox"/> Considers risks, benefits, contraindications, and alternatives to a diagnostic study or procedure
4	Diagnosis (PC4)	<input type="checkbox"/> Did not achieve Level 1	<input type="checkbox"/> Considers a list of potential diagnoses	<input type="checkbox"/> Considers an appropriate list of potential diagnosis <input type="checkbox"/> May or may not make correct diagnosis	<input type="checkbox"/> Makes the appropriate diagnosis <input type="checkbox"/> Considers other potential diagnoses, avoiding premature closure
5	Pharmacotherapy (PC5)	<input type="checkbox"/> Did not achieve Level 1	<input type="checkbox"/> Asks patient for drug allergies	<input type="checkbox"/> Selects an appropriate medication for therapeutic intervention, considering potential adverse effects	<input type="checkbox"/> Selects the most appropriate medication(s) and understands mechanism of action, effect, and potential side effects <input type="checkbox"/> Considers and recognizes drug-drug interactions
6	Observation and reassessment (PC6)	<input type="checkbox"/> Did not achieve Level 1	<input type="checkbox"/> Reevaluates patient at least one time during the case	<input type="checkbox"/> Reevaluates patient after most therapeutic interventions	<input type="checkbox"/> Consistently evaluates the effectiveness of therapies at appropriate intervals



ORAL BOARDS ASSESSMENT

Acute Flaccid Myelitis

Learner: _____

	Milestone	Did not achieve level 1	Level 1	Level 2	Level 3
7	Disposition (PC7)	<input type="checkbox"/> Did not achieve Level 1	<input type="checkbox"/> Appropriately selects whether to admit or discharge the patient	<input type="checkbox"/> Appropriately selects whether to admit or discharge Involves the expertise of some of the appropriate specialists	<input type="checkbox"/> Educates the patient appropriately about their disposition Assigns patient to an appropriate level of care (ICU/Tele/Floor) Involves expertise of all appropriate specialists
22	Patient centered communication (ICS1)	<input type="checkbox"/> Did not achieve level 1	<input type="checkbox"/> Establishes rapport and demonstrates empathy to patient (and family) Listens effectively	<input type="checkbox"/> Elicits patient's reason for seeking health care	<input type="checkbox"/> Manages patient expectations in a manner that minimizes potential for stress, conflict, and misunderstanding.
23	Team management (ICS2)	<input type="checkbox"/> Did not achieve level 1	<input type="checkbox"/> Recognizes other members of the patient care team during case (nurse, techs)	<input type="checkbox"/> Communicates pertinent information to other healthcare colleagues	<input type="checkbox"/> Communicates a clear, succinct, and appropriate handoff with specialists and other colleagues Communicates effectively with ancillary staff



Stimulus Inventory

- #1 Patient Information Form
- #2 CBC
- #3 BMP
- #4 Urinalysis
- #5 Venous Blood Gas
- #6 Creatine Kinase
- #7 Thyroid Panel
- #8 COVID and Influenza Testing
- #9 Chest Radiograph
- #10 MRI Cervical, Thoracic, and Lumbar Spine with and without contrast
- #11 CSF Studies



Stimulus #1

Patient Information

Patient's Name: Trevor Riggin

Age: 6 years

Gender: Male

Chief Complaint: Weakness

Person Providing History: Mother

Vital Signs:

Temp: 37°C

BP: 95/62

P: 108

RR: 22

Pulse Ox: 94%

Weight: 20.4 kg (45 lbs) **Height:** 45 inches



Stimulus #2

Complete Blood Count (CBC)

White blood cell count (WBC) 8.0 x1000/mm³

Hemoglobin (Hgb) 12.5 g/dL

Hematocrit (Hct) 37.5%

Platelets 250 x1000/mm³

Segs 64%

Bands 3%

Lymphocytes 0%

Monocytes 31%

Eosinophils 1%



Stimulus #3

Basic Metabolic Panel (BMP)

Sodium	140 mEq/L
Potassium	3.9 mEq/L
Chloride	101 mEq/L
Bicarbonate	35 mEq/L
Blood Urea Nitrogen (BUN)	11 mg/dL
Creatinine (Cr)	0.9 mg/dL
Glucose	95 mg/dL



Stimulus #4

Urinalysis

Color	Yellow
Appearance	Clear
Sp Gravity	1.010
pH	6.0
Glucose	Negative
Protein	Negative
Ketones	Negative
Leukocyte Esterase	Negative
Nitrite	Negative
Blood	Negative

Microscopy

White blood cells (WBC) 0-1/hpf

Red blood cells (RBC) 0-2/hpf

Squamous cells 0/hpf

Bacteria 0/hpf



Stimulus #5

Venous Blood Gas

pH	7.33
pCO₂	52 mmHg
pO₂	30 mmHg
O₂ sat	75%



Stimulus #6

Creatine Kinase (CK)

CK	22 U/L	Reference 22 – 198 U/L
-----------	---------------	-------------------------------



Stimulus #7

Thyroid Panel

TSH	1.52 mU/L	Reference 0.4 – 4.5 mU/L
Total T3	146 ng/dL	Reference 100 – 200 ng/dL
Free T4	.98 ng/dL	Reference 0.9 – 1.8 ng/dL



Stimulus #8

COVID and Influenza Testing

COVID **Not detected**

Influenza A **Not detected**

Influenza B **Not detected**



Stimulus #9

Chest Radiograph (CXR)

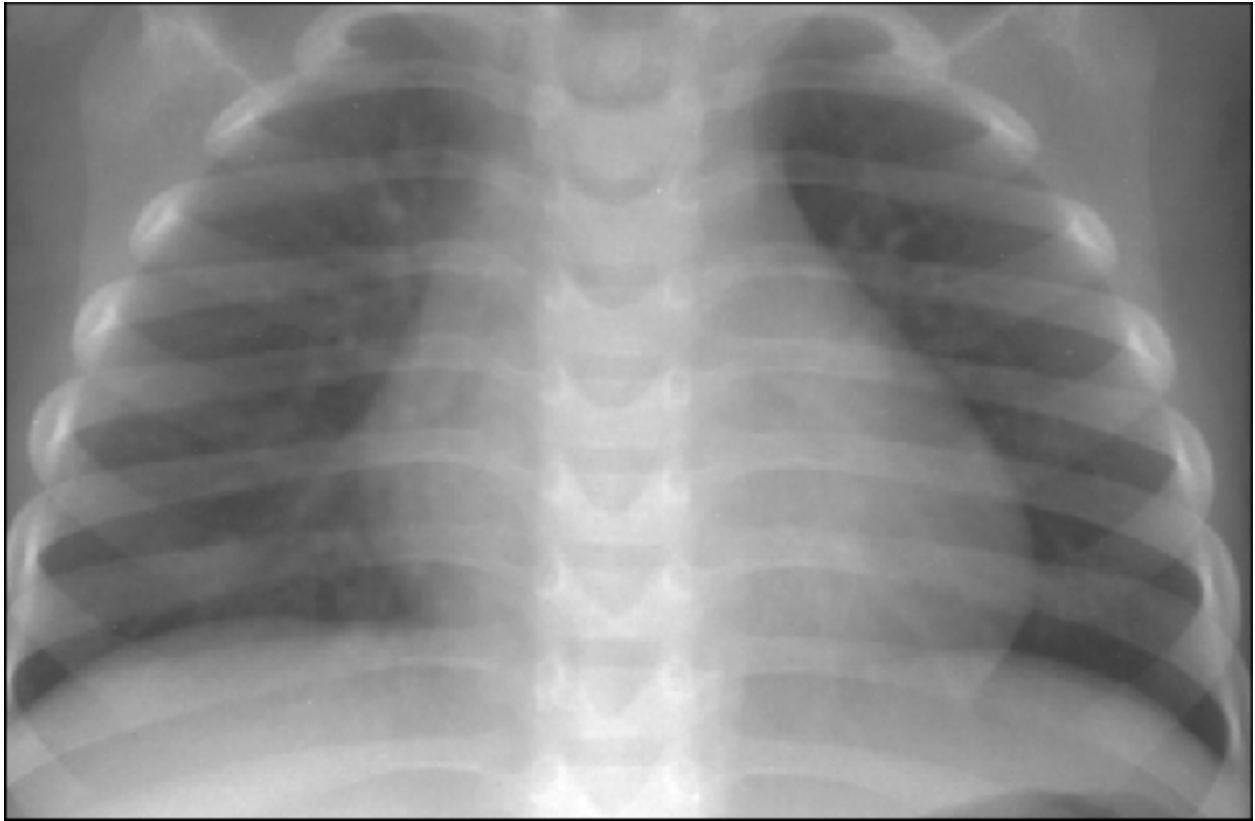


Image Source: Author's own image.



Stimulus #10

MRI Cervical, Thoracic, and Lumbar Spine with + without contrast

Reading: T2-hyperintensity within the anterior spinal cord at the levels of C5 – L4 with selective involvement of the gray matter; Axial T2 weighted image demonstrates prominent anterior horn cell involvement especially on the right in the lower cervical spine and upper thoracic spine. Contrast-enhanced T1 weighted images demonstrate ventral root enhancement in same area.



Stimulus #11

CSF Studies

Opening pressure:	10cm H2O
Color:	Clear
Clarity:	Clear
WBC:	56 cells
RBC:	0 cells
Protein:	41 mg/dL
Glucose:	50 mmol/L
Gram stain:	Negative
Other:	Negative



DEBRIEFING AND EVALUATION PEARLS

Acute Flaccid Myelitis (AFM)

1. Pediatric patients presenting with neuromuscular weakness should have an evaluation of ventilation status including a negative inspiratory force (NIF) measurement.
2. Pediatric patients with a NIF of more than -30 cm H₂O are at risk for respiratory failure and need administration of ventilatory support.
3. AFM weakness can be asymmetrical and have either ascending or descending progression. Paresthesia symptoms are usually absent. GBS demonstrates symmetric weakness in an ascending pattern and symptoms of paresthesia are frequently present.
4. Lumbar puncture should be performed in the setting of neuromusculoskeletal pathology which will demonstrate pleocytosis usually <100 per μ L with lymphocytic predominance which differs from GBS (cell count usually less than 10 per μ L with predominantly mononuclear (lymphocytes and monocytes) cells and spinal cord infarction.^{1,8}
5. MRI abnormality is part of the CDC criteria for the diagnosis of AFM; while MRI can be used to supplement the diagnosis of GBS, it is not part of the criteria necessary to confirm the diagnosis.¹⁰