

# A Dermatologic Condition Mimicking Brown Recluse Spider Bite

Hassan Al-Balushi, Daniel Noguee, Ziad Kazzi, Jonathan de Olano

Emory University School of Medicine, Department of Emergency Medicine, Division of Medical Toxicology, Atlanta, Georgia, United States

Georgia Poison Center, Atlanta, Georgia, United States

## ABSTRACT

*Loxosceles* genus represents a wide number of species including the brown recluse spider. This spider is known worldwide for causing serious injuries resulting from its bite. The diagnosis of brown recluse spider bite is challenging as the injury clinically resembles other conditions and cannot be confirmed unless the spider was observed. We present a case of a 46-year-old male who presented to the emergency department with sudden onset of two painful punctate lesions. We discuss the clinical presentation, investigation and approach; additionally, we briefly highlight the main points with regards to presentation, diagnosis and management of this condition.

**Key words:** arachnids, bite, brown recluse spider, emergency department, venom

## INTRODUCTION

The brown recluse spiders (*Loxosceles*) are well known for causing skin injury and necrosis in humans after bites. Different species of *Loxosceles* genus are identified worldwide including *Loxosceles reclusa* which has a limited range of distribution including the south and central mid-western United States.<sup>1</sup> However, it can be found in other places, most likely transported on personal belongings and materials. Another species (*Loxosceles rufescens*) is found commonly distributed in the Mediterranean region, in Asia and North Africa.<sup>2</sup> Physicians have reported cutaneous injury caused by *Loxosceles reclusa* since the late 1950s.<sup>2</sup> Other conditions that often carry significantly more morbidity and mortality, such as serious bacterial infections, vascular, neoplastic, and environmental etiologies, are misdiagnosed as spider bites.

A study examining 182 patients who presented to the emergency department (ED) with a chief

complaint of spider bite, found that only 3% (7/182) were ultimately confirmed to have the diagnosis of a spider bite, whereas 84% (152/182) had a skin and soft tissue infection, the rest were either bitten by other animals; or given other non-bite diagnoses. The most common cause of the reported skin and soft tissue injuries (SSTIs) was community-acquired methicillin-resistant *Staphylococcus aureus* (MRSA).<sup>3</sup>

## CASE REPORT

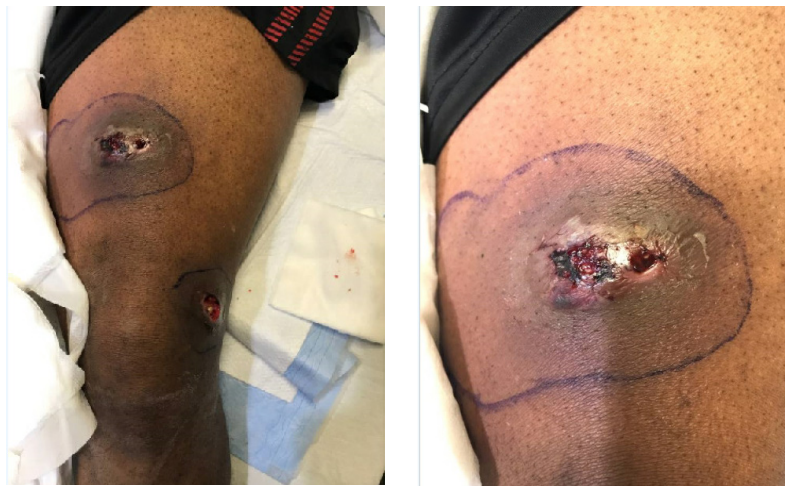A 46-year-old male with no previous medical history, presented to the Emergency Department (ED) with skin lesions concerning for a brown recluse spider bite. He complained of two painful punctate lesions on his left leg associated with redness, swelling, tightness, and blood-tinged purulent drainage. He denied fever or other systemic symptoms. He lives in an old house in an urban area of north-west Georgia, USA. He did not see any spiders at the time surrounding the appearance of the skin lesions, but reported that his initial symptoms were sudden onset of pain that woke him up from sleep and pinpoint puncture wounds that developed into larger lesions over four days. The vital signs at time of ED presentation were temperature, 36.7 degrees Celsius; heart rate 97 bpm; respiratory rate 19 breaths per minute; and blood pressure 134/85 mmHg. His physical exam was notable for two

---

Correspondence to:

Hassan Al-Balushi, MD

Department of Emergency Medicine, Division of Medical Toxicology, Emory University School of Medicine, Atlanta, Georgia, United States  
Georgia Poison Center, Atlanta, Georgia, United States  
alamad808@hotmail.com



**Figure 1** Patient's wounds

tender hyperpigmented ulcerations to the anterior and medial aspect of the left thigh (Figure 1). The rest of his physical examination was unremarkable. Computed tomography imaging of the left thigh and knee were obtained in the ED, and interpreted as “areas of focal cellulitis at the anteromedial aspect of the distal thigh and anterolateral aspect of the

on the need for analgesics and the clinical features, the patient was started on oral opioid analgesia, vancomycin and clindamycin, and admitted for local wound care. The toxicology service was consulted and recommended further workup for other potential loxoscelism-mimics, including dermatology evaluation. Dermatology team felt the wounds were most consistent with MRSA skin and soft tissue infection. The patient stayed in the hospital for 4 days on intravenous antibiotics and discharged with a prescription for clindamycin. Shortly after, the wound culture resulted with clindamycin-resistant MRSA, so the antibiotic was modified to trimethoprim/sulfamethoxazole. The patient was followed up by phone several times after discharge, and reported slow, gradual healing of the wounds over the next few weeks.

**Table 1** - Patient's laboratory tests

Investigation	Result	Units
WBC	9.8	10 <sup>3</sup> /mcl
HGB	12.2	g/dL
PLT	361	10 <sup>3</sup> /mcl
AST	34	U/L
ALT	48	IU/L
INR	1.1	INR
PT	12.7	sec
K <sup>+</sup>	4.9	meq/L
Na	141	meq/L
Cr	1.4	mg/dl
BUN	13	mg/dL

*WBC: white blood cells; HGB: hemoglobin; PLT: platelets; AST: aspartate aminotransferase; ALT: alanine transaminase; INR: international normalized ratio; PT: prothrombin time; Cr: creatinine; BUN: blood urea nitrogen*

knee with possible no-organized fluid or phlegmon within the immediately underlying subcutaneous tissues.” Exudate culture grew clindamycin and methicillin-resistant *Staphylococcus aureus* (MRSA).

The surgical team was consulted by the ED team, and recommended supportive care and local wound care without surgical intervention. Based

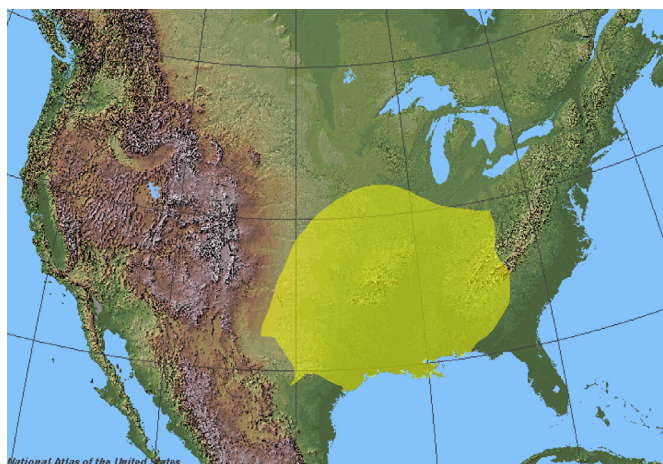
## DISCUSSION

### Clinical Features

The clinical presentation of loxoscelism can be divided into 3 main categories:

The first category is represented by localized urticarial response secondary to the injection of venom. The second category is manifested by the cytotoxic reaction of the bite. It starts with a painless or stinging sensation followed by blistering, bleeding, and ulceration within hours to days. Finally, induration and central necrosis occur, followed by eschar formation and ulceration, which may take days to months to heal via secondary intention. The third category consists

of systemic loxoscelism which may manifest as weakness, edema, nausea, vomiting, fever, chills, arthralgias, petechial eruptions, hemolysis, disseminated intravascular coagulation, hemoglobinuria, rhabdomyolysis, acute kidney injury, and death. However, the incidence of these systemic manifestations is rare.<sup>4</sup>



**Figure 2** Geographic Distribution of brown recluse spiders (Copyright Wikimedia - reproduced under CC BY-SA 3.0 license - available at [https://commons.wikimedia.org/wiki/File:Loxosceles\\_reclusa\\_range.png#/media/File:Loxosceles\\_reclusa\\_range.png](https://commons.wikimedia.org/wiki/File:Loxosceles_reclusa_range.png#/media/File:Loxosceles_reclusa_range.png))

In our case the concern for brown recluse spider bite resulted from the suspicious ulceration and skin changes, appropriate geographic location of the patient, and living in an old house. However several considerations made alternative diagnoses more likely. These included the presentation with multiple lesions with frank pus and swelling that would be unusual from a spider bite, and the time of year of his illness.

### Diagnosis

Witnessing the spider bite or identification by an experienced arachnologist can be the only way for an accurate diagnosis. However this is very rare. Because the spider is usually not found or noticed, and symptoms are delayed, the diagnosis is challenging and can be based on potential exposure, wound appearance, and progression of effects. Laboratory examination can be helpful to exclude alternative diagnoses.

### Management

There is no specific therapy with proven efficacy

for loxoscelism. The wound is typically self-limited and long-term consequences are rare.<sup>3</sup> Analgesics, antipruritics, immobilization, wound care and tetanus prophylaxis are the mainstay of management. Beside its significant side effects, there is insufficient information to recommend the use of dapsone in the management of loxosceles envenomation.<sup>4</sup> Hyperbaric oxygen therapy is another suggested modality but animal studies showed insufficient evidence to support its use.<sup>4</sup>

### CONCLUSION

Brown recluse venom can destroy human tissue causing local and systemic effects. A wide spectrum of serious dermatologic conditions are misdiagnosed for spider bites. Further studies needed to support specific therapeutic modalities for the management of loxosceles envenomation.

**Informed consent:** The patient's consent was taken for publishing of this clinical case and figures.

**Conflicts of Interest:** The author declare no conflicts of interest or sources of funding.

### REFERENCES

1. Anderson PC. Missouri brown recluse spider: a review and update. *Mo Med* 1998; 95:318-22.
2. Platnick NI. The world spider catalog, version 13.5. American Museum of Natural History. 2013. <https://research.amnh.org/iz/spiders/catalog/>
3. Swanson DL, Vetter RS. Bites of brown recluse spiders and suspected necrotic arachnidism. *N Engl J Med*. 2005;352(7):700-707.
4. Suchard JR. "Spider bite" lesions are usually diagnosed as skin and soft-tissue infections. *J Emerg Med*. 2011;41(5):473-481.
5. Repplinger DJ, Hahn IH. Arthropods. In: Nelson LS, Howland MA, Lewin NA, editors. *Goldfrank's toxicologic emergencies*. New York, NY: McGraw-Hill Education; 2019.