

Arterial and Venous Thrombotic Complications in Patients with COVID-19: A Report of Three Cases

Hu AY, MD¹ | Seals K, MD³ | Thomas M, MD³ | Hathout G, MD^{2,3}

Author Affiliation: ¹ Department of Radiological Sciences, David Geffen School of Medicine at UCLA
² Department of Radiology, Greater Los Angeles VA Medical Center
³ Department of Radiology, Olive View-UCLA Medical Center

Corresponding Author: A.Y.H. (ashleyhu@mednet.ucla.edu)

UCLA Radiol Sci Proc. 2022;2(1):7-12

Abstract: Coronavirus Disease 2019 (COVID-19) has had an enormous impact on both the medical community as well as society as a whole. Research on the pathogenesis and the treatment of the disease is rapidly emerging, with new observations and hypotheses appearing daily. One aspect that has been receiving increasing attention is the occurrence of both arterial and venous thrombotic complications in patients with COVID-19. We report three cases of thromboembolic complications in patients affected by COVID-19 and discuss clinical features, pathophysiology, and the proposed approaches to management of vascular complications in these patients. Through our discussion, we also urge physicians to be vigilant for any symptoms or signs suggestive of thrombosis in patients with COVID-19.

Keywords: COVID-19, thrombosis, stroke, pulmonary embolism

Introduction

While the pulmonary manifestations of COVID-19 are well recognized, new signs of the disease in other organs and body systems are constantly being described. Both microvascular and macrovascular complications of COVID-19 have become increasingly evident and recognized as a growing area of concern.^{1,2} This paper will focus on macrovascular arterial and venous complications that have been seen in patients with COVID-19.

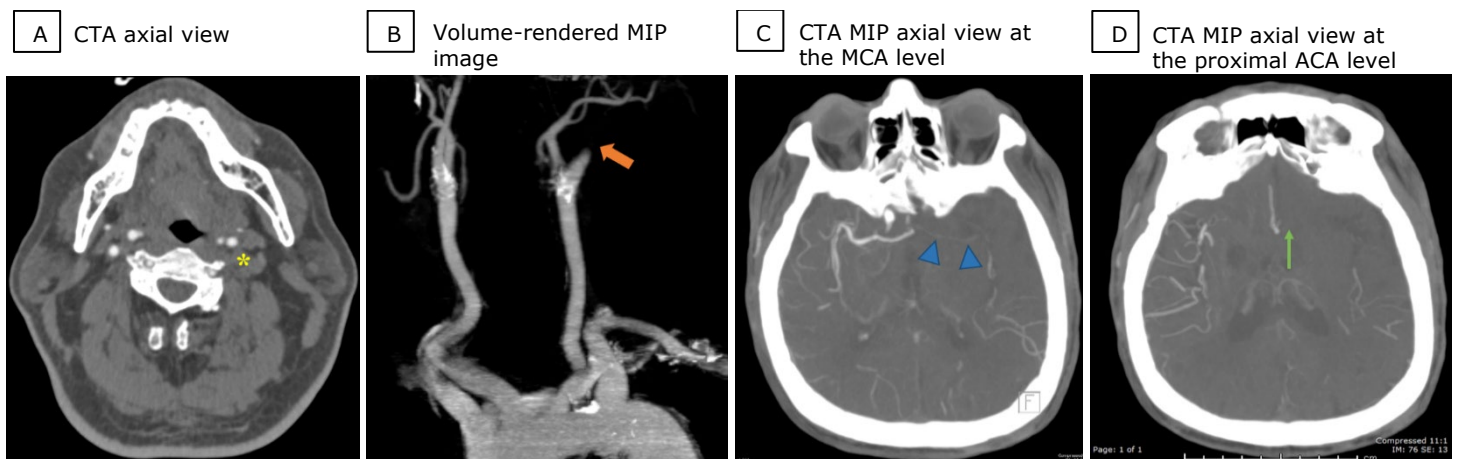
Case 1 Presentation

A 68-year-old man with a history of hypertension, diabetes, coronary artery disease, and stroke initially presented to the hospital for shortness of

Key Points

- Thromboembolic complications among patients affected by COVID-19 increase morbidity and mortality, especially among critically ill patients.
- A proposed mechanism of thromboembolic complications is the binding of SARS-CoV-2 to ACE2 receptors, which leads to endothelial dysfunction and increased susceptibility for thrombosis.
- The development of thromboembolic complications in hospitalized patients despite prophylactic anticoagulation prompted discussion about efficacy and safety of therapeutic versus prophylactic anticoagulation in high-risk patients.

breath and cough. The result of testing the patient for COVID-19 was positive. The patient required supplemental oxygen, but did not need intubation

Figure 1. CT Angiography (CTA) of the Head and the Neck in a 68-year-old Man with COVID-19 (Case 1).

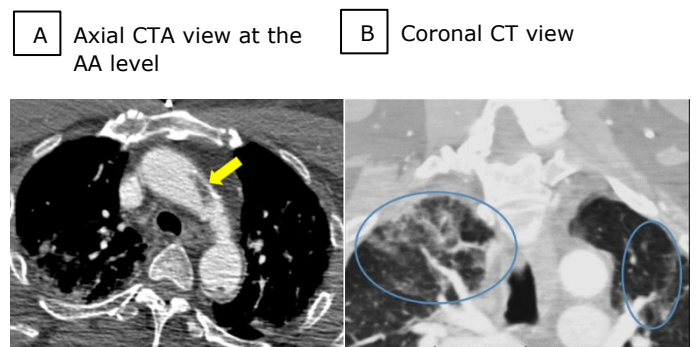
Axial CTA image of the neck (1A) shows absence of opacification in the left internal carotid artery (1A, asterisk). Volume-rendered maximum intensity projection (MIP) image (1B) of the carotid arteries reveals an abrupt cutoff of the left internal carotid artery just distal to the carotid bifurcation (1B, arrow). Axial CTA MIP image (1C) of the head at the level of the middle cerebral artery (MCA) shows absence of contrast within the left middle cerebral artery (1C, arrowheads), with some reconstitution beyond the M2 and M3 segments. Axial CTA MIP image (1D) of the head at the level of the proximal anterior cerebral artery (ACA) shows lack of flow within the left anterior cerebral artery (1D, arrow).

or intensive care. The patient was alert and oriented to person and place. Eight days after hospital admission, the patient had an acute change in mental status, became unresponsive and had a left gaze deviation. Computed tomography angiography (CTA) showed an abrupt cutoff of the left internal carotid artery and lack of opacification of the left middle cerebral artery and the anterior cerebral artery (Figure 1). The images of the partially visualized upper chest showed nonocclusive thrombus within the aortic arch and parenchymal lung abnormalities typical of COVID-19 (Figure 2).

A therapeutic regimen of low-dose aspirin that the patient received at home was continued in the hospital. In addition, the patient was given a daily prophylactic dose of enoxaparin, 40 mg subcutaneously. Laboratory values revealed a plasma D-dimer level of 3.520 $\mu\text{g/mL}$ (reference range < 0.60 $\mu\text{g/mL}$) on the day of stroke. The value was even higher, at 6.760 $\mu\text{g/mL}$, three days prior to stroke.

The patient was last seen to be in his usual mental state approximately 7.5 hours earlier, before he went to sleep. Therefore, the patient was beyond the time window for tissue plasminogen activator (tPA) administration. While the patient was still a candidate for thrombectomy, based on discussion with the patient's family and the patient's multiple

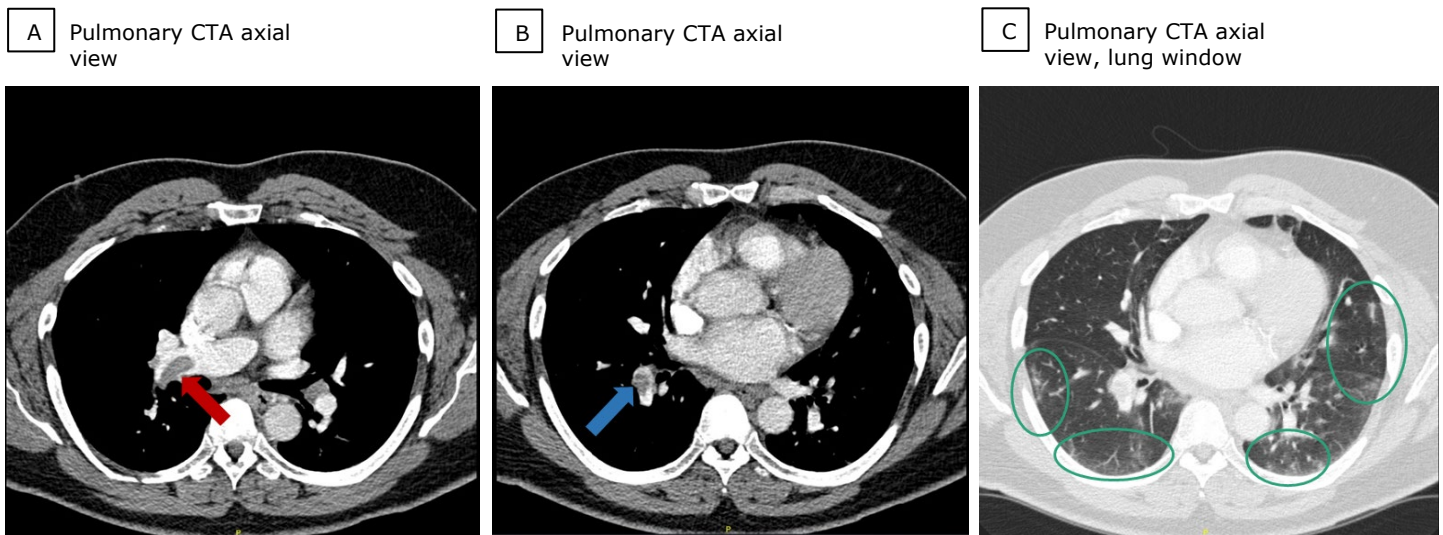
comorbidities, the decision was made not to pursue aggressive treatment, and the patient was transitioned to comfort-focused care.

Figure 2. CT Angiography (CTA) of the Neck and Partially Visualized Upper Thorax in a 68-year-old Man Affected by COVID-19 (Case 1).

Axial CTA image (2A) of the neck at the level of the aortic arch (AA) shows a filling defect within the aortic arch (2A, arrow), compatible with thrombus. Coronal CT of the neck (2B) and partially visualized lung apices reveals peripheral ground-glass opacities (2B, circles) typically seen in patients with COVID-19.

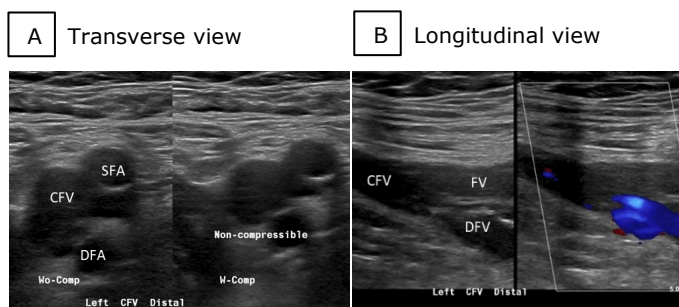
Case 2 Presentation

A 61-year-old man had a medical history of hypertension, hyperlipidemia, internal hemorrhoids, obesity, and pulmonary embolism in 2011, possibly secondary to abrupt cessation of

Figure 3. Pulmonary CT Angiography (CTA) in a 61-year-old Man with COVID-19 (Case 2).

Pulmonary axial CTA (3A and 3B) shows thrombus in the right main pulmonary artery (3A, red arrow), extending into the right interlobar pulmonary artery (3B, blue arrow). In addition, multiple thrombi were seen within the segmental branches (not pictured). Pulmonary axial CTA, lung window (3C) shows patchy, peripheral ground-glass opacities (3C, circles) typical for COVID-19.

usual activities after being diagnosed with gout. In addition, the patient has had chronic cough and dyspnea for the past 1 to 2 years. By the time of presentation, the patient had already discontinued anticoagulation for pulmonary embolism, per physician recommendation. The patient initially presented to his primary care physician with the chief concerns of weakness, acute worsening of cough, and shortness of breath. Given the patient's history of pulmonary embolism, a CTA of the chest was ordered. The examination revealed

Figure 4. Duplex Ultrasound of the Left Lower Extremity in a 61-year-old Man with COVID-19 (Case 2).

Transverse and longitudinal (4A and 4B) views show non-compressibility of the common femoral vein and the femoral vein, compatible with thrombosis. Additionally, thrombosis was observed in the popliteal, the posterior tibial, the peroneal, and the gastrocnemius veins (not pictured). (SFA, superficial femoral artery; DFA, deep femoral artery; CFV, common femoral vein; FV, femoral vein; DFV, deep femoral vein).

multiple pulmonary emboli as well as bilateral peripheral ground-glass opacities typical of COVID-19 (Figure 3).

Based on these findings, the patient was immediately referred to the emergency department. On admission to the hospital, the patient's hemoglobin level was 6.1 g/dL (reference range 13.7-17.5 g/dL) and plasma D-dimer level was 5.407 $\mu\text{g}/\text{mL}$ (reference range $<0.60 \mu\text{g}/\text{mL}$). The result of testing the patient for COVID-19 was positive. The patient was given subcutaneous enoxaparin 100 mg twice a day. Duplex ultrasound of the lower extremities revealed deep vein thrombosis of the left distal common femoral, the femoral, and the popliteal veins, as well as superficial thrombophlebitis of the posterior tibial, the peroneal, and the gastrocnemius veins (Figure 4). The patient was eventually discharged from the hospital in a stable condition and on the same therapeutic dose of anticoagulants.

Case 3 Presentation

A 33-year-old woman presented to the hospital with fever and confusion. The patient has had a complex medical history, including systemic lupus erythematosus, end-stage renal disease treated with peritoneal dialysis, idiopathic intracranial

hypertension with recent ventriculopleural shunt placement, and morbid obesity. On admission, the patient was found to have COVID-19. One of the chief concerns, pleuritic chest pain, prompted examination by CTA of the chest, which showed right interlobar pulmonary embolus (Figure 5). The patient was given heparin drip. On the day of the CT scan, laboratory values were as follows: plasma D-dimer, 1.203 $\mu\text{g/mL}$ (reference range $<0.60 \mu\text{g/mL}$) and fibrinogen, 603 mg/dL (reference range 235-490 mg/dL). Twelve days after the scan, D-dimer level raised to greater than 10 $\mu\text{g/mL}$, with subsequent decrease. The patient's hospital course was complicated by spontaneous bacterial peritonitis and progressive encephalopathy, which required 8 days of intubation for airway protection. At the time of discharge, oxygen saturation was normalized at 93%, and the patient was transferred to warfarin therapy.

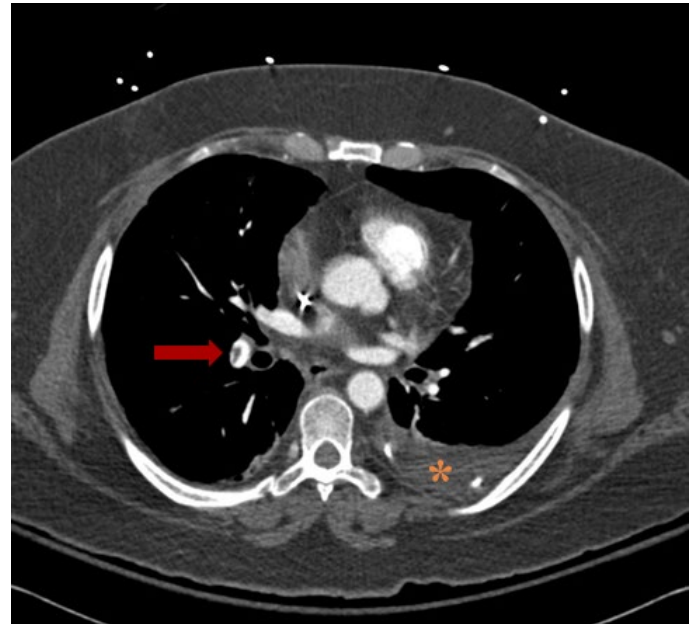
Discussion

With the growing number of COVID-19 cases, various complications of the viral infection have been observed. In this manuscript, we focus on the arterial and venous thromboembolic complications that are seen in patients with COVID-19. Numerous cases of pulmonary embolism, deep vein thrombosis, stroke, and arterial thrombosis causing end-organ infarction in patients affected by COVID-19 have been described in the literature.¹⁻⁴ The cumulative incidence of vascular complications found in one study by Klok et al¹ was as high as 31%. Other retrospective studies^{3,4} showed similar rates of pulmonary embolism, 23% and 25%, respectively. According to many sources,^{1,2,3,5} thromboembolic complications of COVID-19 were often observed in patients in intensive care, which is indicative of the severity of the patients' condition.

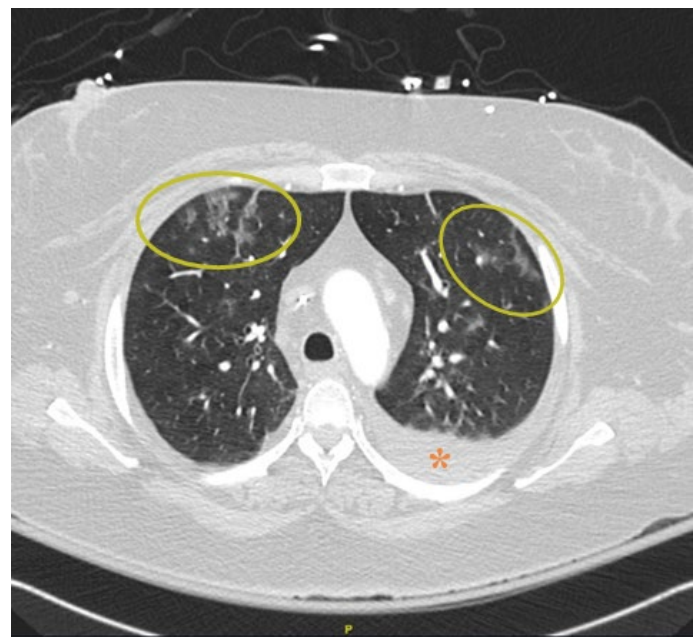
In the cases we presented, all three patients had elevated D-dimer levels, which suggests that the patients were in a prothrombotic state during their illness. As described in the literature,^{5,6} in addition to elevation of D-dimer levels, patients with COVID-19 have elevated levels of other indirect markers for thrombosis, fibrinogen and fibrin

Figure 5. Pulmonary CT Angiography (CTA) in a 33-year-old Woman with COVID-19 (Case 3).

A Pulmonary CTA axial view, soft tissue window



B Pulmonary CTA axial view, lung window



Pulmonary axial CTA image, soft tissue window (5A) shows a filling defect in the right interlobar pulmonary artery (5A, arrow). Pulmonary axial CTA image, lung window (5B) shows patchy peripheral ground-glass opacities (5B, circles), which are typical for COVID-19. The patient had a known ventriculopleural shunt causing a small left pleural effusion (5A and 5B, asterisk).

degradation products. The virus responsible for COVID-19, SARS-CoV-2, is known to target the angiotensin converting enzyme 2 (ACE2) receptor.⁷ This binding of the ACE2 receptors leads to accumulation of angiotensin II, an increase in reactive oxygen species, dysfunction and damage of endothelial cells, and massive release of von Willebrand factor that mediates coagulation.⁷ In addition, immobilization during an acute illness increases risk of thrombosis.

Notably, all three patients described here had relatively complex medical histories. Therefore, it is likely that formation of thrombi in these patients is multifactorial and is not solely caused by the novel coronavirus. Another commonality among our patients is that none of them were critically ill and required intensive care when the thromboembolic events occurred. This suggests that physicians should be extra vigilant for symptoms, such as leg pain, shortness of breath, or neurological deficits that might indicate thrombosis in patients affected by COVID-19. This would include both inpatients and outpatients who may be seeking medical care via telemedicine.

The increased incidence of thromboembolic complications prompted the necessity of thromboprophylaxis in hospitalized patients with COVID-19. However, because of the frequency of thromboembolic complications in hospitalized patients despite prophylactic anticoagulation, debate continues about the efficacy and safety of anticoagulants dose intensity, prophylactic and therapeutic, for the treatment of these patients. In one of the recent clinical trials,⁸ the authors found that therapeutic anticoagulation in these patients with either rivaroxaban or enoxaparin should be avoided because it does not produce better clinical outcomes than prophylactic anticoagulation. Yet, the results of a later trial⁹ suggested that therapeutic doses of low-molecular-weight heparin are more efficient in reducing thromboembolism and death than standard prophylactic doses in general ward patients but not in ICU patients. Ultimately, each patient must be evaluated for the level of risk of a thromboembolic or bleeding event before any increase in the dose of anticoagulants. In outpatients with COVID-19, no arterial or venous complications were registered.¹⁰ It is likely that during the pandemic many individuals have

decreased their levels of activity, which predisposed them to thromboembolism,¹¹ in addition to the proinflammatory and prothrombotic characteristics of COVID-19.

At this time, there is no consensus on the management of thromboembolic complications of COVID-19. However, regardless of the approaches to thromboprophylaxis, physicians should be quick to recognize symptoms that are suggestive of thrombosis, so that the management of these symptoms can be started in a timely fashion.

Author Contributions

Conceptualization, G.H.; Acquisition, analysis, interpretation of data, and writing – original draft preparation, A.Y.H., K.S. and M.T.; Review and editing, G.H. and A.Y.H.; Supervision, G.H. All authors agree to be accountable for all aspects of the work in ensuring that questions related to the accuracy or integrity of any part of the work are appropriately investigated and resolved. All authors had full access to all the data in the study and take responsibility for the integrity of the data and the accuracy of the data analysis.

Disclosures

None to report.

References

1. Klok FA, Kruip MJHA, van der Meer NJM, et al. Incidence of thrombotic complications in critically ill ICU patients with COVID-19. *Thromb Res.* 2020;191:145-147. DOI: [10.1016/j.thromres.2020.04.013](https://doi.org/10.1016/j.thromres.2020.04.013)
2. Llitjos JF, Leclerc M, Chochois C, et al. High incidence of venous thromboembolic events in anticoagulated severe COVID-19 patients. *J Thromb Haemost.* 2020;18(7):1743-1746. DOI: [10.1111/jth.14869](https://doi.org/10.1111/jth.14869)
3. Grillet F, Behr J, Calame P, Aubry S, Delabrousse E. Acute pulmonary embolism associated with COVID-19 pneumonia detected with pulmonary CT angiography. *Radiology.* 2020;296(3):E186-E188. DOI: [10.1148/radiol.2020201544](https://doi.org/10.1148/radiol.2020201544)
4. Riyahi S, Dev H, Behzadi A, et al. Pulmonary embolism in hospitalized patients with COVID-19: a multicenter study. *Radiology.* 2021;301(3):E426-E433. DOI: [10.1148/radiol.2021210777](https://doi.org/10.1148/radiol.2021210777)
5. Tang N, Li D, Wang X, Sun Z. Abnormal coagulation parameters are associated with poor prognosis in patients with novel coronavirus pneumonia. *J Thromb Haemost.* 2020;18(4):844-847. DOI: [10.1111/jth.14768](https://doi.org/10.1111/jth.14768)
6. Terpos E, Ntanasis-Stathopoulos I, Elalamy I, et al. Hematological findings and complications of COVID-19. *Am J Hematol.* 2020;95(7):834-847. DOI: [10.1002/ajh.25829](https://doi.org/10.1002/ajh.25829)

7. Zhang J, Tecson KM, McCullough PA. Role of endothelial cell receptors in the context of SARS-CoV-2 infection (COVID-19). *Proc (Bayl Univ Med Cent)*. 2021;34(2):262-268. Published 2021 Jan 26. DOI: [10.1080/08998280.2021.1874231](https://doi.org/10.1080/08998280.2021.1874231)
8. Lopes PF, de Barros e Silva PGM, Furtado RHM, et al. Therapeutic versus prophylactic anticoagulation for patients admitted to hospital with COVID-19 and elevated D-dimer concentration (ACTION): an open-label, multicentre, randomised, controlled trial. *Lancet*. 2021;397(10291):2253-2263. [10.1016/S0140-6736\(21\)01203-4](https://doi.org/10.1016/S0140-6736(21)01203-4)
9. Spyropoulos AC, Goldin M, Giannis D, et al. Efficacy and safety of therapeutic-dose heparin vs standard prophylactic or intermediate-dose heparins for thromboprophylaxis in high-risk hospitalized patients with COVID-19: the HEP-COVID randomized clinical trial [published correction appears in *JAMA Intern Med*. 2021 Dec 28;:]. *JAMA Intern Med*. 2021;181(12):1612-1620. DOI: [10.1001/jamainternmed.2021.6203](https://doi.org/10.1001/jamainternmed.2021.6203)
10. Piazza G, Campia U, Hurwitz S, et al. Registry of arterial and venous thromboembolic complications in patients with COVID-19. *J Am Coll Cardiol*. 2020;76(18):2060-2072. DOI: [10.1016/j.jacc.2020.08.070](https://doi.org/10.1016/j.jacc.2020.08.070)
11. Kunutsor SK, Mäkikallio TH, Seidu S, et al. Physical activity and risk of venous thromboembolism: systematic review and meta-analysis of prospective cohort studies. *Eur J Epidemiol*. 2020;35(5):431-442. DOI: [10.1007/s10654-019-00579-2](https://doi.org/10.1007/s10654-019-00579-2)