

# Megacystis-Microcolon–Intestinal Hypoperistalsis Syndrome: A Case Report

Kinzel AJ, MD | Chen, J MD

**Author Affiliation:** Department of Radiological Sciences, David Geffen School of Medicine at UCLA

**Corresponding Author:** A.J.K. ([akinzel@mednet.ucla.edu](mailto:akinzel@mednet.ucla.edu))

*UCLA Radiol Sci Proc.* 2022;2(2):13-15

**Abstract:** A 1-day-old girl, late preterm (36 weeks 3 days) infant, was admitted to the neonatal intensive care unit for respiratory distress and megacystis seen on a prenatal ultrasound at 24 weeks of gestation. A babygram (anteroposterior view of the entire body) showed absence of bowel gas, and abdominal ultrasound revealed grade 4 bilateral hydronephrosis. The patient was subsequently diagnosed with megacystis-microcolon–intestinal hypoperistalsis syndrome and was taken to the operating room for appropriate treatment.

**Keywords:** *megacystis-microcolon–intestinal hypoperistalsis syndrome (MMIHS), Berdon syndrome*

## Case Presentation

A 1-day-old girl, late preterm (36 weeks 3 days) infant, was admitted to the neonatal intensive care unit (NICU) for respiratory distress and megacystis seen on a prenatal ultrasound at 24 weeks of gestation. The patient was delivered via cesarean section with initial Apgar scores of 4 and 6 at 1 and 5 minutes, respectively.

On admission in the NICU, it was noted that the infant had central cyanosis and a large amount of bilious secretion following oronasopharyngeal suction. At this point, the patient experienced apnea and was intubated. Clinical examination showed a markedly distended, firm abdomen with absence of bowel sounds. On a babygram, the absence of bowel gas pattern was noted. Abdominal ultrasound showed grade 4 bilateral hydronephrosis. Contrast enema examination recommended by a pediatric surgical consultant revealed microcolon.

Ultimately, the patient was diagnosed with megacystis-microcolon–intestinal hypoperistalsis

## Key Points

- Diagnosis of MMIHS is based on clinical and imaging findings. A rectal biopsy might be performed to exclude Hirschsprung disease, in which case ganglion cells are absent on histologic examination.
- Differential diagnosis for a patient presented with megacystis should include posterior urethral valves, mass, ureterocele, neurogenic bladder, MMIHS, and prune-belly syndrome.
- A paucity of distal bowel gas shown on a radiograph of the abdomen, in addition to megacystis found on ultrasound, strongly suggests a diagnosis of MMIHS.

syndrome (MMIHS) and subsequently underwent a diverting ileostomy, mucous fistula, and gastrostomy tube placement on the second day of life. The results of biopsy of ileum and ascending colon showed the presence of ganglion cells, thereby eliminating the probability that the patient had Hirschsprung disease. The patient had a long-term recovery course in the NICU and was discharged home several months later.

## Discussion

Megacystis-microcolon-intestinal hypoperistalsis syndrome (MMIHS), also known as Berdon syndrome, was first described in 1976 in a case series of 5 newborn girls presenting with small bowel obstruction, microcolon, and enlarged bladder.<sup>1</sup> A genetic mutation in the *ACTG2* gene has been identified as one of the possible causes in 44.1% of cases of MMIHS.<sup>2</sup> In meta-analysis of 450 cases of MMIHS, Nakamura et al<sup>3</sup> found that female-to-male ratio in MMIHS cases is significantly higher in children of consanguineous parents (4.4:1) than in children of non-consanguineous parents (2.3:1).

Wymer et al<sup>4</sup> noticed that megacystis was the most common finding (88% of all cases) on prenatal ultrasound examination of patients with MMIHS, with hydronephrosis presented in 10% of

cases. The same authors recommend that following delivery, in addition to performing a bladder ultrasound, a sacral ultrasound also be performed to exclude spinal dysraphism that could be a cause of neurogenic bladder unrelated to MMIHS.<sup>4</sup>

**Figure 2.** Ultrasound, Longitudinal View, of the Right Kidney of a 1-day-old Girl with Megacystis-Microcolon-Intestinal Hypoperistalsis Syndrome

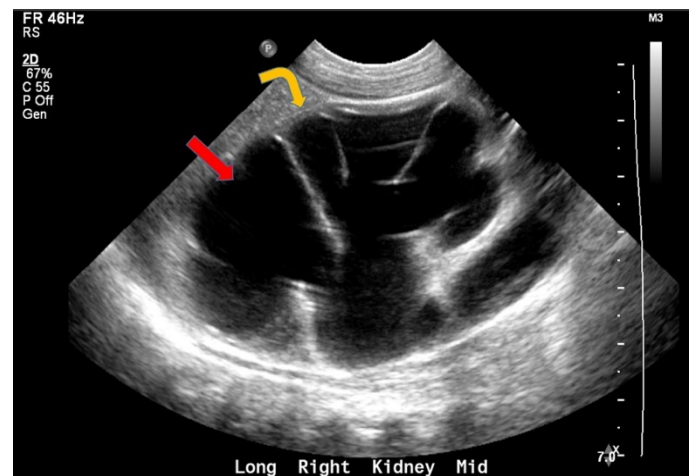


Image shows grade 4 hydronephrosis with large dilated renal calyces (red arrow) and severe thinning of the renal parenchyma (orange curved arrow). The left kidney (not seen on this image) also revealed grade 4 hydronephrosis.

**Figure 3.** Ultrasound, Longitudinal View, of the Abdomen of a 1-day-old Girl with Megacystis-Microcolon-Intestinal Hypoperistalsis Syndrome

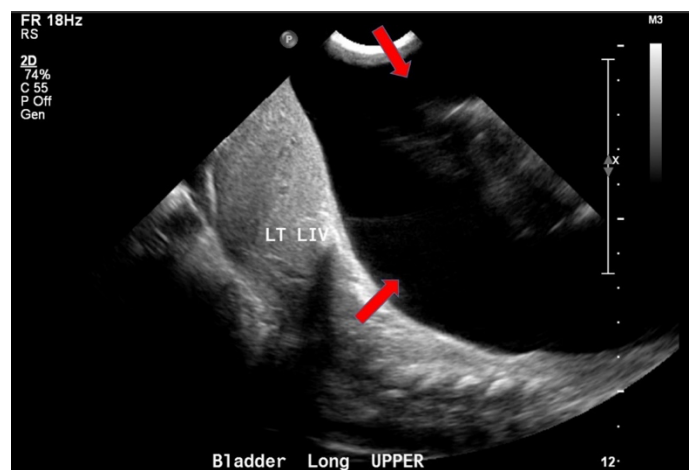


Image shows a markedly enlarged bladder (red arrows) extending up to the liver (LT LIV).

**Figure 1.** Anteroposterior Radiograph of the Chest and the Abdomen of a 1-day-old Girl with Megacystis-Microcolon-Intestinal Hypoperistalsis Syndrome

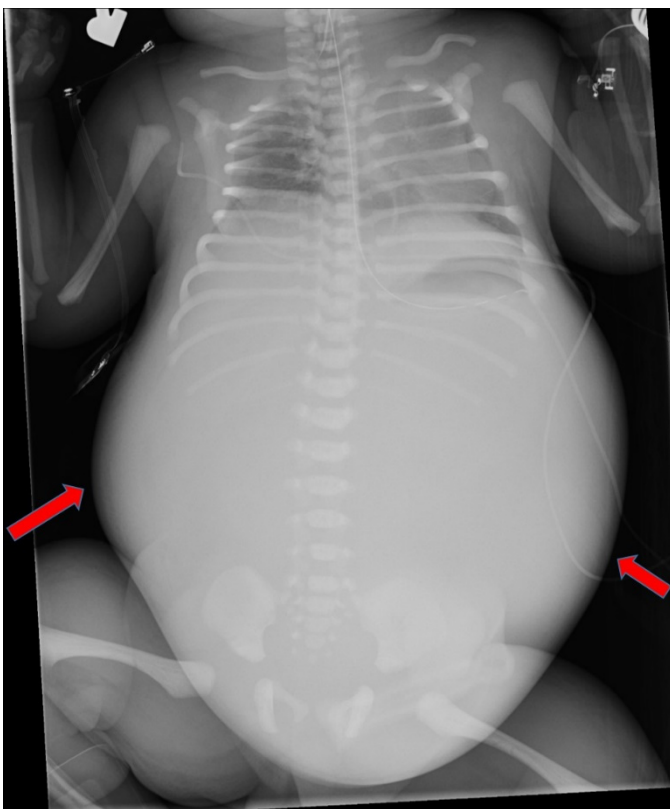


Image shows a distended abdomen with bulging flanks (arrows) and a paucity of bowel gas throughout the abdomen.

**Figure 4.** Anteroposterior Contrast Enema Examination of a 1-day-old Girl with Megacystis-Microcolon-Intestinal Hypoperistalsis Syndrome.

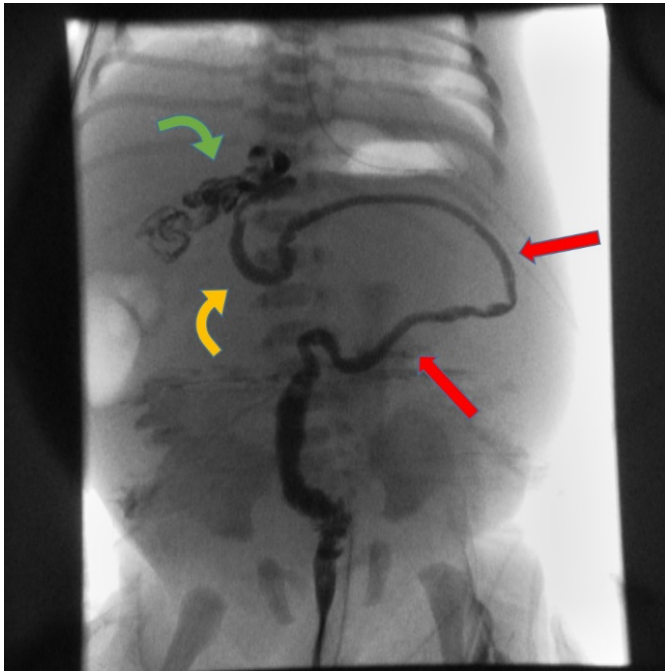


Image reveals an extremely small-caliber colon without haustra (red arrows), mostly located at the midline of the abdomen. The cecum is seen overlying the upper lumbar spine (orange curved arrow) with contrast refluxing into the terminal ileum (green curved arrow).

When MMIHS is undiagnosed at birth, the patients present almost invariably with early abdominal distension as well as with hydronephrosis (46%), bile-stained emesis (34%), and failure to pass meconium (13%).<sup>4</sup>

The diagnostic work-up may include a barium enema and cystogram to examine for the presence of microcolon or enlarged bladder, respectively; features that are both highly characteristic of MMIHS.<sup>4</sup> A rectal biopsy may be performed to distinguish MMIHS from other causes of intestinal pseudo-obstruction, such as Hirschsprung disease, in which case ganglion cells will be present on histologic examination.<sup>5</sup>

Historically, the average life expectancy of patients with MMIHS is less than six months, and the treatment is largely palliative with emphasis on preventing the complications of genitourinary dysfunction and infection.<sup>4</sup> Prophylactic administration of antibiotics and the placement of indwelling suprapubic catheters to continuously drain the bladder are commonly the part of the

treatment considerations.<sup>4</sup> In the rare instances when patients survive beyond infancy, many require total or partial parenteral nutrition.<sup>6</sup> This case report confirms that MMIHS is a rare and often devastating disease, the pathognomonic characteristic of which, enlarged bladder and a microcolon, can be reliably diagnosed on radiologic examination.

### Author Contributions

Conceptualization, J.C. and A.J.K.; Acquisition, analysis, interpretation of data, and writing – original draft preparation, A.J.K.; Review and editing, A.J.K. and J.C.; Supervision, J.C. All authors agree to be accountable for all aspects of the work in ensuring that questions related to the accuracy or integrity of any part of the work are appropriately investigated and resolved. All authors had full access to all the data in the study and take responsibility for the integrity of the data and the accuracy of the data analysis.

### Disclosures

None to report.

### References

1. Berdon WE, Baker DH, Blanc WA, Gay B, Santulli TV, Donovan C. Megacystis-microcolon-intestinal hypoperistalsis syndrome: a new cause of intestinal obstruction in the newborn. Report of radiologic findings in five newborn girls. *AJR Am J Roentgenol.* 1976;126(5): 957–964. DOI: [10.2214/ajr.126.5.957](https://doi.org/10.2214/ajr.126.5.957)
2. Ambartsumyan L. Megacystis-microcolon-intestinal hypoperistalsis syndrome overview. In: Adam MP, Ardinger HH, Pagon RA, et al., eds. *GeneReviews*® [Internet]. Seattle (WA): University of Washington, Seattle; 2019 May 9:1993-2022. Accessed March 16, 2022. <https://www.ncbi.nlm.nih.gov/books/NBK540960/>
3. Nakamura H, O'Donnell AM, Puri P. Consanguinity and its relevance for the incidence of megacystis microcolon intestinal hypoperistalsis syndrome (MMIHS): systematic review. *Pediatr Surg Int.* 2019;35(2):175-180. DOI: [10.1007/s00383-018-4390-6](https://doi.org/10.1007/s00383-018-4390-6)
4. Wymer KM, Anderson BB, Wilens AA, Gundeti MS. Megacystis microcolon intestinal hypoperistalsis syndrome: Case series and updated review of the literature with an emphasis on urologic management. *J Pediatr Surg.* 2016;51(9):1565-1573. DOI: [10.1016/j.jpedsurg.2016.06.011](https://doi.org/10.1016/j.jpedsurg.2016.06.011)
5. Friedmacher F, Puri P. Classification and diagnostic criteria of variants of Hirschsprung's disease. *Pediatr Surg Int.* 2013;29(9):855-872. DOI: [10.1007/s00383-013-3351-3](https://doi.org/10.1007/s00383-013-3351-3)
6. Puri P, Shinkai M. Megacystis microcolon intestinal hypoperistalsis syndrome. *Semin Pediatr Surg.* 2005;14(1):58-63. DOI: [10.1053/j.sempedsurg.2004.10.026](https://doi.org/10.1053/j.sempedsurg.2004.10.026)