

# Extensive Subcutaneous Calcinosis and Hypercalcemia in the Setting of Mineral Oil-Injection-Related Foreign Body Reaction: A Case Report

Chang RO, MD<sup>1</sup> | Khoshchehreh M, MD, MS<sup>2</sup> | Viragh KA, MD<sup>3</sup>

**Author Affiliation:** <sup>1</sup> Department of Radiological Sciences, David Geffen School of Medicine at UCLA  
<sup>2</sup> Department of Pathology, Olive View-UCLA Medical Center  
<sup>3</sup> Department of Radiology, Olive-View UCLA Medical Center

**Corresponding Authors:** K.A.V. ([kviragh@dhs.lacounty.gov](mailto:kviragh@dhs.lacounty.gov)) | R.O.C. ([rochang@mednet.ucla.edu](mailto:rochang@mednet.ucla.edu))

*UCLA Radiol Sci Proc.* 2023;3(4):74-79

**Abstract:** Soft tissue calcifications are a common imaging finding, but in the setting of a cosmetic augmentative injection and hypercalcemia, it may be pathognomonic for lipogranuloma, a delayed granulomatous inflammatory reaction to the injected foreign material. Although diagnosis of lipogranuloma is based on the results of histopathologic examination, the radiologist may play a key role in the clinical evaluation of challenging cases when patients do not report about nonmedical cosmetic procedures. If the treatment of granulomatosis-induced hypercalcemia is not timely, it may result in chronic renal disease and other comorbidities. We report a case of lipogranuloma with extensive subcutaneous calcification and hypercalcemia associated with cosmetic injection.

**Keywords:** *lipogranuloma, foreign body reaction, cosmetic injection, soft tissue calcification, granulomatosis-induced hypercalcemia*

## Case Presentation

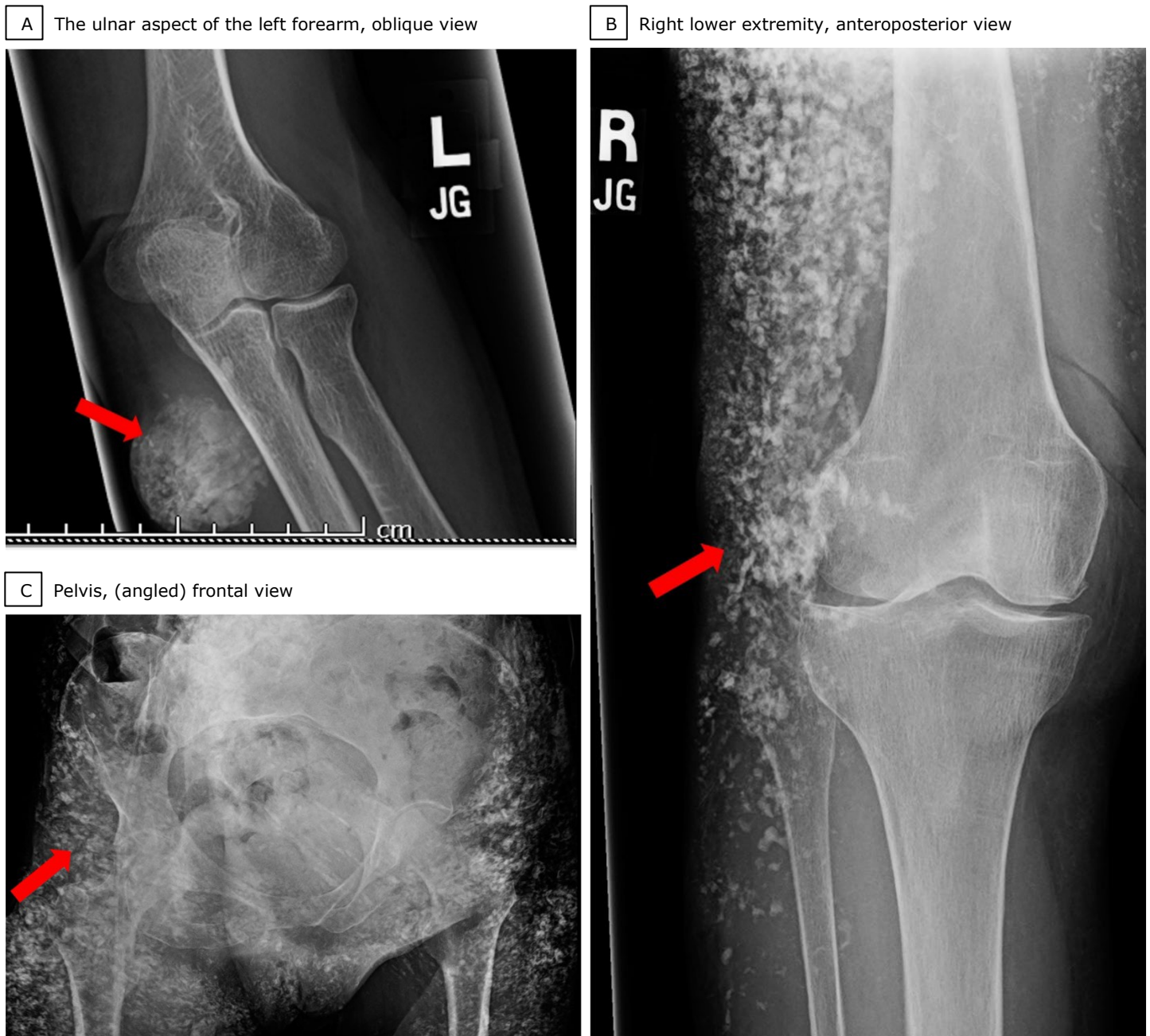
A 56-year-old woman presented with extensive, chronic, and progressive skin induration around her torso and extremities with worsening nonhealing wounds in the gluteal region. The patient reported bilateral injection of mineral oil into the gluteal regions more than 20 years ago in Mexico. Approximately 10 years after the procedure, the patient began experiencing progressive induration of the skin, and during the last 3 years, progressive nonhealing wounds. On physical examination, the lesions were observed covering the patient's abdomen, the back, the perineum, the gluteal regions, the lower extremities, and parts of the left upper extremity. The results of laboratory workup performed at our institution showed that the patient had renal

## Key Points

- Lipogranuloma is a chronic granulomatous inflammatory process that may occur in response to cosmetic augmentative injection.
- The granulomatosis may lead to hypercalcemia through the unregulated active vitamin D production in the granulomatous macrophages, which can result in calcinosis and chronic renal failure.
- The radiologist may help with the timely diagnosis and treatment, when extensive subcutaneous calcinosis is seen on imaging in the setting of hypercalcemia and cosmetic injections.

## Abbreviations

PTH: Parathyroid hormone  
CT: Computed tomography  
MRI: Magnetic resonance imaging

**Figure 1.** Radiographic Imaging of Lipogranuloma in a 56-Year-Old Woman

(A) Calcified soft tissue mass (A, red arrow) is seen over the ulnar aspect of the left forearm. (B, C) Diffuse calcifications are seen over the right lower extremity (B, red arrow) and the pelvis (C, red arrow).

failure with creatinine of 1.8 mg/dL (reference range, 0.74-1.35 mg/dL), hypercalcemia with a calcium level of 13.7 mg/dL (reference range, 8.5-10.3 mg/dL), and hyperphosphatemia with a phosphorus level of 5.4 mg/dL (reference range, 2.5-4.5 mg/dL). These values were found in the setting of a low parathyroid hormone (PTH) level of 5 pg/mL (reference range, 15-65 pg/mL), low

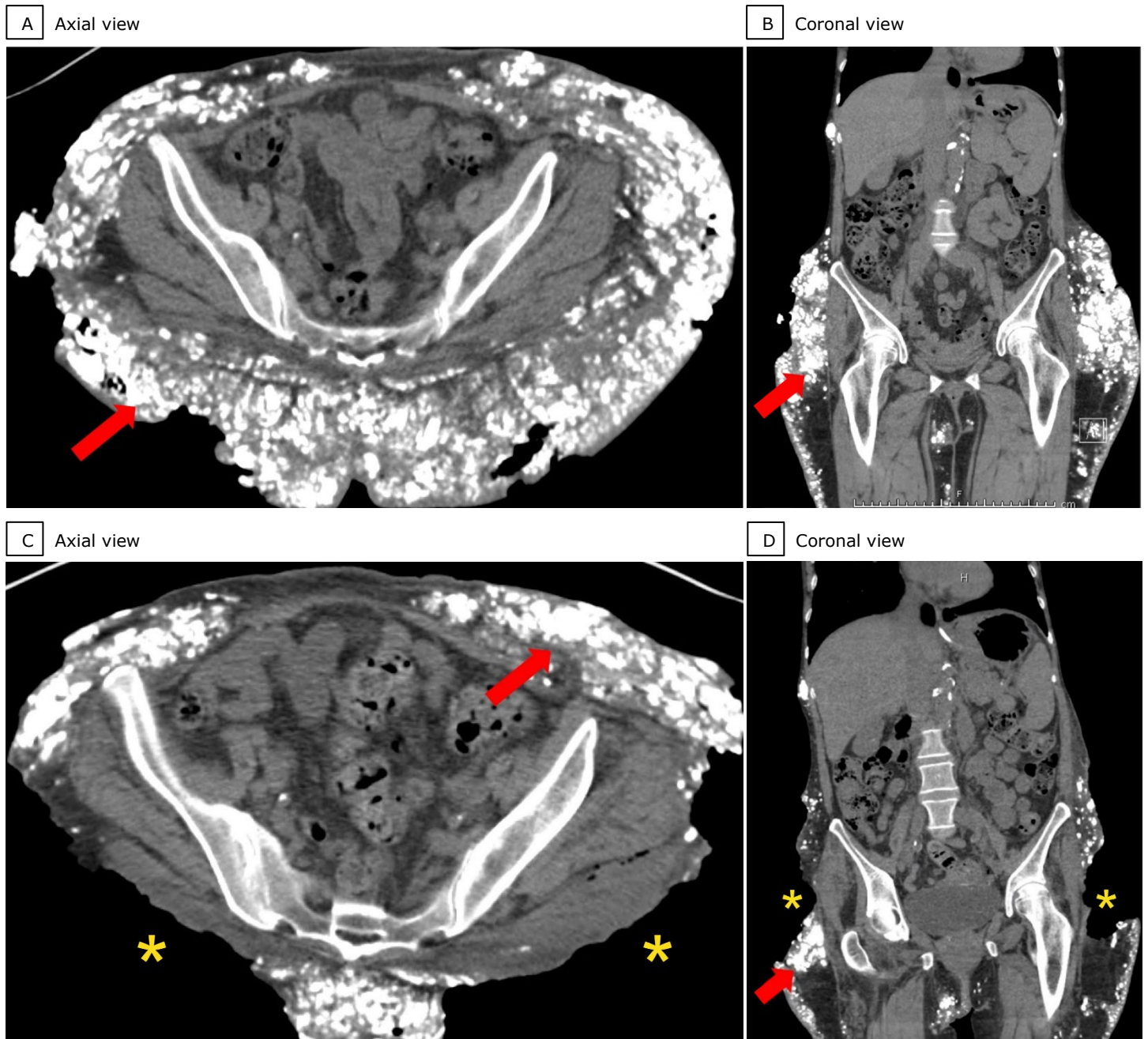
25-Hydroxyvitamin D [25(OH)D] level of 23 ng/mL (reference range, 30-100 ng/mL), but high 1,25-Dihydroxyvitamin D [1,25(OH)<sub>2</sub>D] level of 93 pg/mL (reference range, 18-72 pg/mL; Quest Diagnostics). Otherwise, the patient's extensive laboratory workup was noncontributory to the final diagnosis.

Radiographs of the left elbow (Figure 1A), the right

knee (Figure 1B) and the pelvis (Figure 1C) revealed extensive heterogeneous soft tissue calcifications obscuring other tissues. Computed tomography (CT) of the abdomen, the pelvis, and the lower extremities showed extensive heterogeneous calcification and architectural

distortion of the subcutaneous fat (Figure 2, A-D). There was no muscular or internal organ calcification present, except for bilateral non-obstructing renal calculi, incidental phleboliths, and atherosclerotic calcifications. Although augmentation material was injected only into the

**Figure 2.** Computed Tomography (CT) of the Gluteal Regions of a 56-Year-Old Woman with Lipogranuloma

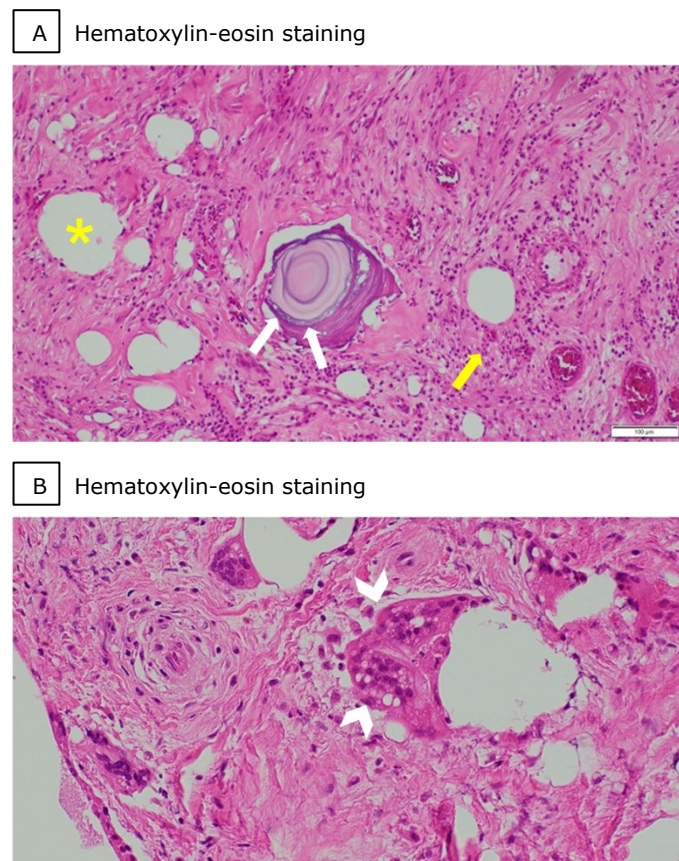


(A, B) CT of the pelvis, axial and coronal views, show bilateral diffuse coarse calcifications and subcutaneous air with skin defects and ulcerations of the gluteal regions (A and B, arrows). (C, D) Post-debridement images show gluteal wounds (C and D, asterisks) cleared of soft tissue calcifications and the abdominal wall with residual soft tissue calcifications (C and D, arrows).

gluteal areas, the soft tissue calcifications extended to adjacent areas, including the lower extremities. Nonspecific soft tissue gas and ulcerations without fluid collections were noted in the gluteal regions. Other imaging was noncontributory to the evaluation of the patient's condition.

Histopathologic analysis of biopsied gluteal subcutaneous tissues revealed fibrosis/sclerosis with lipid-filled vacuoles of variable sizes, dystrophic calcifications, and inflammatory cells infiltrates consistent with lipogranuloma (Figure 3).

**Figure 3.** Histopathologic Examination of a Biopsy Specimen from the Gluteal Subcutaneous Tissue of a 56-Year-Old Woman with Lipogranuloma.



(A) Photomicrograph of the specimen reveals numerous, vacuolated spaces (A, yellow asterisk) of variable sizes, with dystrophic ossification (A, white arrows) and mixed inflammatory cells (A, yellow arrow) (hematoxylin-eosin stain, original magnification x200).

(B) Photomicrograph of the specimen reveals occasional foreign body giant cells/granulomas (B, white arrowheads) (hematoxylin-eosin stain, original magnification x400).

Because of these findings and no evidence of malignant, chronic infectious, ingestive/medication-related, or endocrine conditions, the final diagnosis was cosmetic-injection-related lipogranuloma, secondary subcutaneous calcinosis, and hypercalcemia with subsequent chronic renal failure.

The patient had a prolonged hospital stay with multiple surgical resections, biological skin graft placement, and supportive wound care. Hypercalcemia was managed with intravenous normal saline, calcitonin, cinacalcet, and ketoconazole until normalization of serum calcium level. Steroids were not administered because of the presence of extensive healing wounds. Bisphosphonates were not given because of chronic kidney failure. The patient was eventually discharged to a rehabilitation center for management of remaining chronic wounds.

## Discussion

Lipogranuloma is a chronic granulomatous inflammatory foreign body reaction characterized by the nodular accumulation of inflammatory cells, predominantly histiocytes/macrophages.<sup>1</sup> The pathogenesis of lipogranuloma is incompletely understood, with the role of the allergenic nature of the injected material, its volume, impurities, depth of injection, and the duration of usage still being the subjects of scientific debate.<sup>2</sup> Nonetheless, a foreign body reaction that produces segregation and encapsulation of injected foreign material by macrophages and giant polynucleated cells resulting in tissue fibrosis is a widely accepted view on the general mechanism of lipogranuloma.<sup>3,4</sup> Lipogranuloma development may be latent for years.<sup>5,6</sup> While the granulomatous reaction occurs predominantly in the area of injection, migration of foreign substances within the subcutaneous fat and through lymphohematogenous spread to distant sites has been documented.<sup>7</sup> Injection-related lipogranuloma is often associated with injection site pain and ulceration of the skin.<sup>6</sup> Subcutaneous injections, especially those related to cosmetic enhancement of the penis and the scrotum, have been described since ancient times, and

lipogranuloma formation at different sites has been regularly documented in the scientific literature since the 19th century.<sup>8,9</sup> The lipogranulomas are variably referred to as oil granulomas, paraffinomas, oleomas, siliconomas, and vasinomas, depending on the name of the injected agent. The diagnosis of lipogranuloma is based on tissue biopsy, which shows lipid vacuoles, granulomas, and fibrosclerosis.<sup>5,7</sup> The treatment of lipogranuloma includes anti-inflammatory drugs (tetracyclines, corticosteroids) and surgical excision or other local therapy.<sup>6,8</sup> Because lipogranuloma is usually a chronic condition with extensive soft tissue involvement, complete resection and cure is rarely achieved.<sup>7,8</sup>

Granulomatosis-induced hypercalcemia is well documented in the setting of sarcoidosis or tuberculosis.<sup>10,11</sup> The mechanism of this hypercalcemia is thought to be an unregulated, increased extrarenal production of 1,25(OH)<sub>2</sub>D (the biologically active form of Vitamin D) from 25(OH)D facilitated by high expression of the *CYP27B1* gene in the macrophages within granulomatous tissue.<sup>7,11,12</sup> In this circumstance, chronic overproduction of 1,25(OH)<sub>2</sub>D and chronic hypercalcemia may result in soft tissue calcinosis, chronic hypercalciuria, and chronic renal failure.<sup>5,11</sup> Hypercalcemia secondary to granulomatosis is usually asymptomatic, but can occasionally lead to nephrolithiasis, pathologic fractures, gastrointestinal symptoms, malaise, pancreatitis, cardiac arrhythmias, and/or diabetes insipidus.<sup>7,10,11</sup> Because granulomatosis is often the result of a response to nonallergic and chronic inflammatory processes, there is typically a delay between a subcutaneous introduction of foreign bodies (eg, cosmetic-enhancement injections) and the manifestation of hypercalcemia.<sup>5</sup> Hypercalcemia is diagnosed by measuring the concentration of serum calcium and other electrolytes. In the absence of endocrinopathy (eg, hyperparathyroidism) or malignant tumor (eg, sclerosing liposarcoma or metastatic disease), hypercalcemia in the setting of low PTH and elevated 1,25(OH)<sub>2</sub>D can be indicative of granulomatous inflammation,<sup>11</sup> as it was seen in our patient with lipogranuloma. In general, hypercalcemia is treated urgently with hydration and antiresorptive agents (calcitonin,

bisphosphonates).<sup>11</sup> Hypercalcemia secondary to granulomatous inflammation may be treated with steroids and ketoconazole.<sup>11</sup>

Radiologic imaging is used to assess the complications (eg, abscess, hematoma) of cosmetic injection and exclude other conditions (eg, malignant tumor, infection).<sup>6,13</sup> Radiography or ultrasonography may be used for initial screening and may reveal nonspecific soft tissue calcification, radiopaque foreign bodies, soft tissue gas, or fluid collections.<sup>6,13</sup> Contrast-enhanced CT or magnetic resonance imaging of the involved body parts as well as of the chest, the abdomen, and the pelvis are needed for anatomic localization and systemic evaluation of complications of cosmetic injections.<sup>12</sup> In addition to high sensitivity in the detection of soft tissue calcification and gas, CT has also the capability to show fat-stranding, nodularity, and architectural distortion of the affected body part.<sup>13</sup>

---

## Conclusion

This case of extensive foreign body reaction to injected mineral oil exemplifies two uncommon but serious complications: (1) lipogranuloma formation as well as (2) granulomatosis-induced hypercalcemia with subsequent renal failure, which manifested as extensive subcutaneous calcinosis. In addition, this case report shows the necessity of considering lipogranuloma (foreign body reaction) in a differential diagnosis of subcutaneous calcification, especially when this syndrome is found in patients with hypercalcemia and cosmetic injections in their medical history. Moreover, because patients may not report nonmedical cosmetic injections, and the hypercalcemia is usually asymptomatic, the radiologist may play a key role in suggesting lipogranuloma as a diagnostic possibility when extensive calcinosis is observed.

---

## Author Contributions

Conceptualization, K.A.V.; Acquisition, analysis, and interpretation of data, R.O.C., M.K., and K.A.V.; Writing – original draft preparation, R.O.C.; Review and editing, R.O.C. and K.A.V.; Supervision, K.A.V. All authors agree to be accountable for all aspects of the work in ensuring that

questions related to the accuracy or integrity of any part of the work are appropriately investigated and resolved. All authors had full access to all the data in the study and take responsibility for the integrity of the data and the accuracy of the data analysis.

## Disclosures

None to report.

## References

- Shah KK, Pritt BS, Alexander MP. Histopathologic review of granulomatous inflammation. *J Clin Tuberc Other Mycobact Dis.* 2017;7:1-12. Published 2017 Feb 10. doi: [10.1016/j.jctube.2017.02.001](https://doi.org/10.1016/j.jctube.2017.02.001)
- Lemperle G, Gauthier-Hazan N, Wolters M, Eisemann-Klein M, Zimmermann U, Duffy DM. Foreign body granulomas after all injectable dermal fillers: part 1. Possible causes. *Plast Reconstr Surg.* 2009;123(6):1842-1863. doi: [10.1097/PRS.0b013e31818236d7](https://doi.org/10.1097/PRS.0b013e31818236d7)
- Obed D, Krezdorn N, Harik-Chraim E, Freystaetter C, Radtke C, Vogt PM. Complications after liquid body contouring with site-enhancing oil injections. *Clin Dermatol.* 2022;40(5):556-563. doi: [10.1016/j.clindermatol.2022.03.001](https://doi.org/10.1016/j.clindermatol.2022.03.001)
- Urbach F, Wine SS, Johnson WC, Davies RE. Generalized paraffinoma (sclerosing lipogranuloma). *Arch Dermatol.* 1971;103(3):277-285. doi:10.1001/archderm.1971.04000150047007
- Albitar S, Genin R, Fen-Chong M, et al. Multisystem granulomatous injuries 28 years after paraffin injections. *Nephrol Dial Transplant.* 1997;12(9):1974-1976. doi: [10.1093/ndt/12.9.1974](https://doi.org/10.1093/ndt/12.9.1974)
- Haneke E. Managing complications of fillers: rare and not-so-rare. *J Cutan Aesthet Surg.* 2015;8(4):198-210. doi: [10.4103/0974-2077.172191](https://doi.org/10.4103/0974-2077.172191)
- McRae FL, Duran SF, Villanueva A, Prodanovic E. Sclerosing lipogranulomatosis-induced chronic hypercalcemia and acute pancreatitis. *JAAD Case Rep.* 2019;5(7):587-589. Published 2019 Jun 26. doi: 10.1016/j.jdc.2019.05.003
- Svensøy JN, Travers V, Othter PJS. Complications of penile self-injections: investigation of 680 patients with complications following penile self-injections with mineral oil. *World J Urol.* 2018;36(1):135-143. doi: [10.1007/s00345-017-2110-9](https://doi.org/10.1007/s00345-017-2110-9)
- Downey AP, Osman NI, Mangera A, Inman RD, Reid SV, Chapple CR. Penile Paraffinoma. *Eur Urol Focus.* 2019;5(5):894-898. doi: [10.1016/j.euf.2018.06.013](https://doi.org/10.1016/j.euf.2018.06.013)
- Pando BL, Goldsmith B, Webb AL, Kinger K, Helmlly B. Free silicone-induced granulomatosis and hypercalcemia in a transgender female. *HCA Healthc J Med.* 2022;3(3):161-166. Published 2022 Jun 28. doi: [10.36518/2689-0216.1343](https://doi.org/10.36518/2689-0216.1343)
- Tebben PJ, Singh RJ, Kumar R. Vitamin D-mediated hypercalcemia: mechanisms, diagnosis, and treatment. *Endocr Rev.* 2016;37(5):521-547. doi: [10.1210/er.2016-1070](https://doi.org/10.1210/er.2016-1070)
- Moraitis AG, Hewison M, Collins M, Anaya C, Holick MF. Hypercalcemia associated with mineral oil-induced sclerosing paraffinomas. *Endocr Pract.* 2013;19(2):e50-e56. doi: [10.4158/EP12092.CR](https://doi.org/10.4158/EP12092.CR)
- Abdelmohsen MA. Injectable fillers: imaging features and related complications. *Egypt J Radiol Nucl Med.* 2020;51(129):1-9. Published 2020 Jul 21. doi: [10.1186/s43055-020-00249-4](https://doi.org/10.1186/s43055-020-00249-4)