

Pearl from the Workstation

Spinal Fracture in a 45-year-old Woman with Paraplegia and Diffuse Idiopathic Skeletal Hyperostosis

Roubakha M, MD | Homer R, MD

Author Affiliation: Department of Radiological Sciences, David Geffen School of Medicine at UCLA**Corresponding Author:** MR (MRoubakha@mednet.ucla.edu)*UCLA Radiol Sci Proc. 2022;2(4):36-37*

Diffuse idiopathic skeletal hyperostosis (DISH) is noninflammatory flowing, bridging ossification of the anterior longitudinal ligament in at least four contiguous segments. This type of ossification is nonmarginal¹

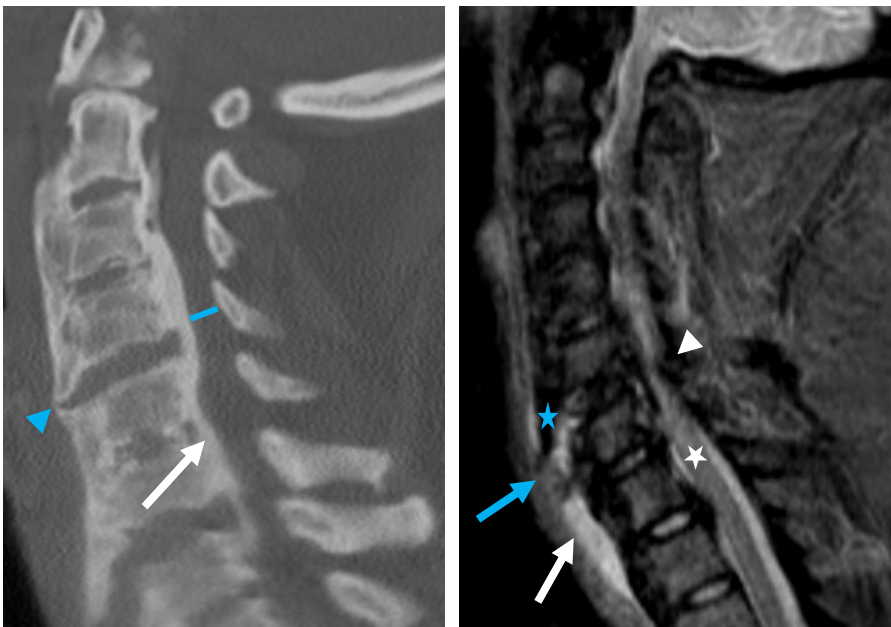
Pearl

It is imperative to scrutinize the spine of individuals with DISH after low-impact trauma, as the rigid spinal column is particularly prone to fractures.

Figure. Multimodality Imaging of Cervical Spine Fracture after Low-impact Collision in a 45-year-old Woman with Type-2 Diabetes, Paraplegia, and Diffuse Idiopathic Skeletal Hyperostosis (DISH).

A Computed tomography (CT), sagittal view

B Inversion recovery magnetic resonance imaging (MRI), sagittal view



(A) CT image of the cervical spine, sagittal view, shows extensive diffuse idiopathic skeletal hyperostosis (DISH): ossification of posterior longitudinal ligament (OPLL) from C2 to C7 (A, white arrow), moderate-to-severe stenosis of the spinal canal (A, blue line), and osteophytes forming ossification along the anterior spine (A, blue arrowhead).

(B) Inversion recovery MRI of the cervical spine, sagittal view, shows DISH and OPLL with bridging osteophyte fracture at C6-C7 (B, blue arrow), fluid between fracture fragments (B, blue star), and prevertebral edema from C6 to T3 (B, white arrow). Severe spinal canal stenosis and cord compression are seen (B, white arrowhead). Spinal cord signal abnormality from C5 to C7 (B, white star) may reflect cord edema or chronic stenosis.

because it protrudes beyond the vertebral bodies. The intervertebral disks are preserved. Diffuse idiopathic skeletal hyperostosis is typically diagnosed in the sixth and the seventh decades of life, is often associated with diabetes and obesity, and affects predominantly men.^{1,2} The DISH related rigidity and altered biomechanics of the spine with osseous fusion of long segments pose an increased risk for spinal fractures even after a minor, low-impact injury. Approximately 40% of DISH-associated fractures include neurologic injury, such as paraplegia and sensory loss, with the cervical spine being most vulnerable.¹

Author Contributions

Conceptualization, M.R. and R.H.; Writing – original draft preparation, M.R.; Review and editing, M.R. and R.H.; Supervision, R.H. All authors agree to be accountable for all aspects of the work in ensuring that questions related to the accuracy or integrity of any part of the work are appropriately investigated and resolved. All authors had full access to all the data in the study and take responsibility for the integrity of the data and the accuracy of the data analysis.

Disclosures

None to report.

References

1. Shah NG, Keraliya A, Nunez DB, et al. Injuries to the rigid spine: what the spine surgeon wants to know. *Radiographics* 2019;39(2):449-466. <https://doi.org/10.1148/rq.2019180125>
2. Kuperus JS, Mohamed Hoesein FAA, de Jong PA, Verlaan JJ. Diffuse idiopathic skeletal hyperostosis: etiology and clinical relevance. *Best Pract Res Clin Rheumatol*. 2020;34(3):101527. DOI: [10.1016/j.berh.2020.101527](https://doi.org/10.1016/j.berh.2020.101527)