

# Massive Idiopathic Nonsurgical Pneumoperitoneum with the Football Sign in a Preterm Infant: A Case Report

Elliott RJ, BA<sup>1</sup> | Ghahremani Koureh S, MD<sup>2</sup>

**Author Affiliation:** <sup>1</sup> David Geffen School of Medicine at UCLA

<sup>2</sup> Department of Radiological Sciences, David Geffen School of Medicine at UCLA

**Corresponding Author:** S.G.K. ([sghahremani@mednet.ucla.edu](mailto:sghahremani@mednet.ucla.edu))

*UCLA Radiol Sci Proc.* 2023;3(3):39-43

**Abstract:** Pneumoperitoneum is the abnormal presence of air in the peritoneal cavity. In cases of massive pneumoperitoneum, abdominal radiographs may reveal "the football sign," which results from air outlining the abdominal cavity and surrounding the falciform ligament. Although most cases of pneumoperitoneum result from visceral perforation, there is increased awareness of other causes, resulting in an entity referred to as nonsurgical pneumoperitoneum (NSP). We report a case of nonsurgical pneumoperitoneum with a football sign on supine radiographs in a preterm 1-month-old infant who had a complex medical history. The patient developed sepsis and underwent an exploratory laparotomy, which ruled out perforation as well as any intra-abdominal cause for the pneumoperitoneum and infection.

**Keywords:** *pediatric radiology, football sign, nonsurgical pneumoperitoneum, idiopathic pneumoperitoneum, spontaneous pneumoperitoneum*

## Case Presentation

During her fifth week of life, an infant girl was transferred to our institution from an outside facility for surgical intervention to relieve thoracic duct obstruction identified on lymphangiography. The patient was born on the 32nd week of gestation (birth weight 2 120 g, height 41.5 cm, head circumference 30.5 cm) via emergency lower-segment transverse cesarean delivery prompted by multiple fetal anomalies and category III fetal heart rate tracings with recurrent late decelerations. Pregnancy had been complicated by polyhydramnios. At the time of delivery, the patient was intubated, and bilateral thoracenteses and paracentesis were performed. The patient had a complex medical history that included trisomy 21, hydrops fetalis (including pleural effusion, pericardial effusion, ascites, and anasarca) with negative infection titers for

## Key Points

- The football sign is seen more commonly on abdominal radiographs of infants than of older children or adults.
- There has been an increased acceptance of nonsurgical causes of pneumoperitoneum known as idiopathic, spontaneous, misleading, isolated, or benign.
- In the absence of clinical signs of perforation, conservative management of nonsurgical pneumoperitoneum in the pediatric population should be considered.

## Abbreviations

CRRT: continuous renal replacement therapy

NSP: nonsurgical pneumoperitoneum

PICC: peripherally inserted central catheter

toxoplasmosis, rubella cytomegalovirus, herpes simplex, and HIV, as well as pneumothorax requiring chest tube placement, right

temporoparietal parenchymal hemorrhage, atrioventricular septal defect, acute kidney injury, and thoracic duct obstruction.

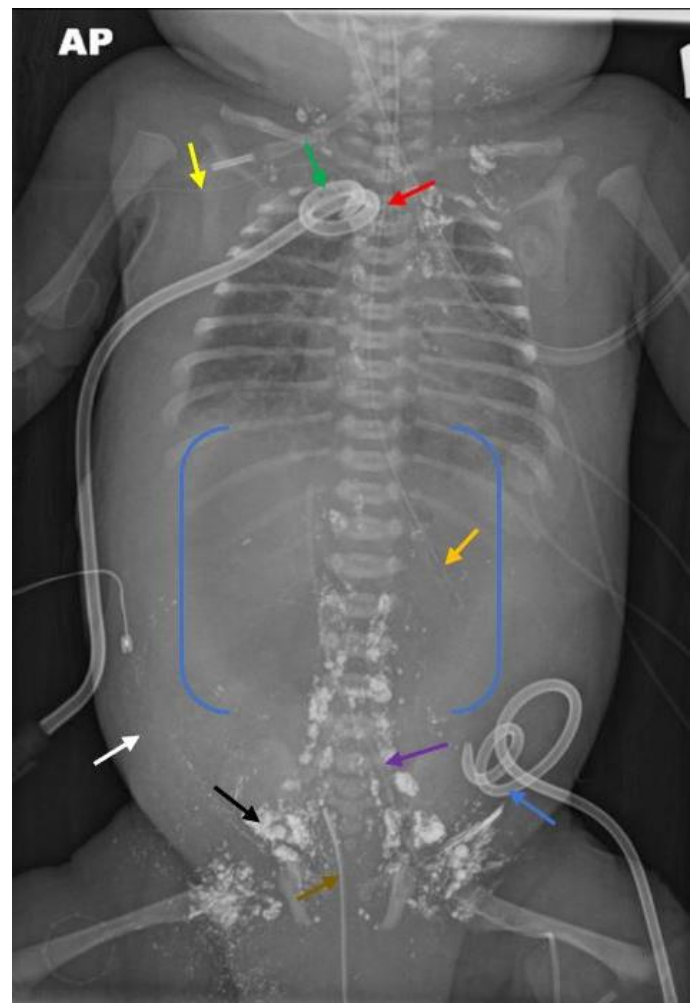
During her fourth week of life, the patient's ascites worsened, compromising her respiratory status and requiring placement of a peritoneal drain. After drain placement, abdominal free air was visualized on supine radiography. The free air was thought to be secondary to air introduced via the stopcock on the peritoneal drain. The pneumoperitoneum resolved completely the following day. The peritoneal drain continued to remove large volumes of ascitic fluid.

During her fifth week of life, the patient was deemed too unstable to undergo surgery for her thoracic duct obstruction. A nephrologist was consulted when the patient developed anuria with laboratory test results indicating renal failure. The patient required inotropic and ventilatory support, and a cardiologist was consulted. On day 1 of hospitalization at our institution, a pneumoperitoneum was noted on supine radiography (Figure 1). By day 3, the pneumoperitoneum had increased in size, and the football sign had become visible (Figure 2). At this point, the peritoneal drain was still in place, but no air was being infused or withdrawn from the drain to explain the pneumoperitoneum.

On day 4, a hemodialysis catheter was placed and continuous renal replacement therapy (CRRT) was initiated in response to persistent anuria. Peritoneal dialysis was not an option given the patient's lymphatic leakage and high ascitic output. Between days 4 and 7, the large pneumoperitoneum persisted and remained relatively stable in size despite replacement of the peritoneal drain on day 4. The patient also developed sepsis, and the care team consulted an infectious disease specialist. The infusion of intravenous broad-spectrum antibiotics was initiated, but blood and peritoneal cultures showed no growth. A pediatric surgeon was consulted, given the presence of peritoneal fluid neutrophilia and concern for a possible intestinal cause of pneumoperitoneum and sepsis. On days 5 and 7, abdominal ultrasound was performed; the examination showed no pathology aside from ascites and persistence of the pneumoperitoneum. There was no evidence of bowel perforation. During this time, a pediatric palliative care

specialist was consulted to facilitate discussions with the patient's family about comfort-focused care.

**Figure 1.** Chest and Abdomen Radiograph of Pneumoperitoneum in a 1-Month-Old Girl on Day 1 of Admission.

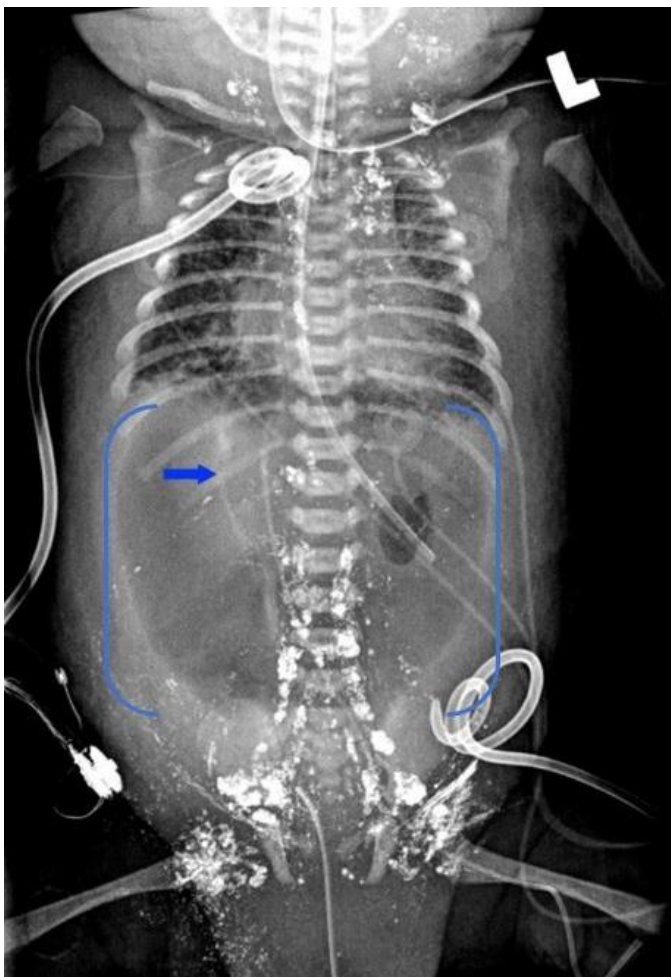


The radiograph shows a significant pneumoperitoneum with lucency of the abdomen and absence of bowel gas (blue brackets). There are diffuse soft tissue edema (white arrow) and residual contrast material from the lymphangiogram (black arrow). The lines and tubes include: endotracheal tube at midthoracic trachea (red arrow), non-weighted enteric tube in the left upper quadrant (orange arrow), right upper extremity peripherally inserted central catheter (PICC, yellow arrow), right pleural pigtail catheter (green arrow), left lower quadrant peritoneal pigtail catheter (blue arrow), left lower extremity PICC (purple arrow), and a urethral catheter (brown arrow).

By day 7, the patient's fluid status had improved on CRRT and she was sufficiently stable to undergo an exploratory laparotomy to rule out a perforated viscus or other surgical cause of the

pneumoperitoneum and to decompress the intra-abdominal air to improve hemodynamic stability. During surgery, a large amount of air was evacuated. Viable bowel was assessed with no succus, fibrinous adhesions, or loculation to suggest necrotizing enterocolitis or a focal intestinal perforation. Two Penrose drains were placed in the abdomen for continued drainage. From day 8 to day 15, there was no significant recurrence of the pneumoperitoneum on daily radiographs (Figure 3). Given continued drainage of large volumes of fluid from the peritoneal drain,

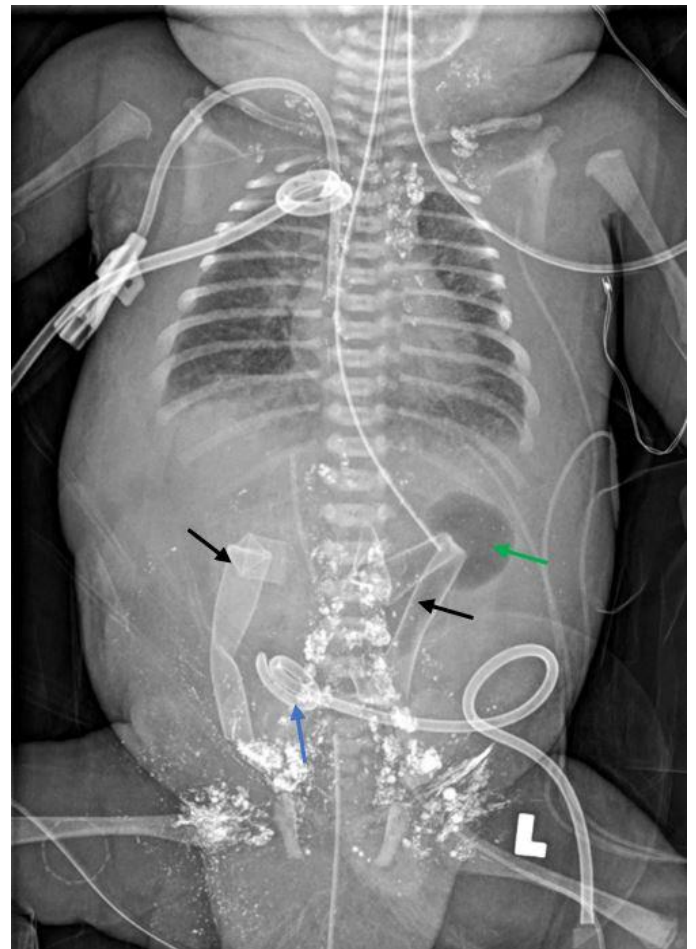
**Figure 2.** Chest and Abdomen Radiograph of Pneumoperitoneum in a 1-Month-Old Girl on Day 3 of Admission.



The radiograph shows a massive pneumoperitoneum with diffuse lucency of the abdomen (blue brackets). The blue arrow highlights the falciform ligament, which represents the longitudinal seam at the center of the football sign. Other radiographic findings remain stable. The lines and tubes are unchanged.

a peritoneal fluid creatinine was obtained to rule out bladder rupture and was normal. During this period, the patient remained critically unstable with hemodynamic intolerance of hemodialysis and required maximal inotropic and ventilatory support as well as frequent transfusions and electrolyte repletion. On day 15, given the poor prognosis and exhaustion of medical treatment options, palliative extubation and withdrawal of life-sustaining measures were performed. The patient died of cardiac and renal failure.

**Figure 3.** Chest and Abdomen Radiograph Without Pneumoperitoneum in a 1-Month-Old Girl on Day 8 of Admission After Exploratory Laparotomy.



The radiograph shows a diffuse paucity of bowel gas, with only the gastric bubble visible (green arrow), and no significant reaccumulation of the previously seen pneumoperitoneum. Other radiographic findings remain stable. The lines and tubes are relatively unchanged aside from the addition of bilateral abdominal Penrose drains (black arrows) and the replacement of the peritoneal pigtail catheter, which is now in the right lower quadrant (blue arrow).

## Discussion

With massive pneumoperitoneum, the football sign may be seen on supine abdominal radiographs.<sup>1</sup> The outline of the football sign results from the sharp interface between air anterior to the viscera and along the parietal peritoneum, while the seam of the football is the longitudinal linear opacity formed by the falciform ligament<sup>1</sup> (Figure 4). The football sign is seen more commonly on radiographs of infants than on radiographs of older children or adults.<sup>1</sup>

Visceral perforation accounts for 85%-95% of pneumoperitoneum cases.<sup>2</sup> It is widely accepted that visceral perforation is a surgical emergency, especially in the presence of suggestive clinical signs.<sup>1-3</sup> Even so, the strength of the association between the surgical finding of visceral perforation and the radiographic finding of pneumoperitoneum varies by anatomic location.<sup>3</sup> One study identified the preoperative radiographic finding of pneumoperitoneum in only 69% of gastroduodenal perforations, 30% of small bowel perforations, and 37% of large bowel perforations.<sup>3</sup>

Cases of pneumoperitoneum not caused by visceral perforation are referred to as nonsurgical, idiopathic, spontaneous, misleading, isolated, or benign pneumoperitoneum. This entity, which accounts for about 5%-15% of pneumoperitoneum cases,<sup>2</sup> will be referred to here as nonsurgical pneumoperitoneum (NSP). The causes of NSP can be categorized as follows: abdominal (most commonly related to postoperative free air, peritoneal dialysis, or endoscopic procedures), thoracic (most commonly related to mechanical ventilation, pneumothorax, or cardiopulmonary resuscitation), gynecological (most commonly related to pelvic manipulation or insufflation), pseudopneumoperitoneum (the misattribution of pneumoperitoneum on imaging), and idiopathic.<sup>2</sup> In the adult population, conservative management is appropriate with NSP in the absence of significant clinical signs of surgical etiologies or hemodynamic collapse.<sup>2,4</sup>

In the pediatric population, pneumoperitoneum was historically thought to be almost always related to visceral perforation.<sup>4</sup> However, cases of pediatric NSP have been increasingly documented, with common causes including peritoneal dialysis,

endoscopic gastrointestinal procedures, pneumatosis cystoides intestinalis, and mechanical ventilation.<sup>2-4,6-8</sup> Pneumatosis cystoides intestinalis can be related to necrotizing enterocolitis, peptic ulcers, intestinal obstruction, pyloric stenosis, and other gastrointestinal pathologies.<sup>6</sup> Khan et al<sup>9</sup> found that the most common cause of pneumoperitoneum in neonates was necrotizing enterocolitis (50.6%), followed by perforated pouch colon and isolated colonic, cecal, gastric, and duodenal perforations. However, in 7.9% of cases, the cause of pneumoperitoneum was unknown.<sup>9</sup> Explanations offered for other idiopathic cases of NSP include peritoneal drains, atelectasis, intra-abdominal sepsis, and microperforations.<sup>10,11</sup> Preterm neonates who receive mechanical ventilation have an especially high rate (1%-3%) of pneumoperitoneum.<sup>2</sup>

**Figure 4.** Football.<sup>5</sup>



The American or Australian football shares its name and its oblong shape with a radiographic finding in images of massive pneumoperitoneum. The abdominal cavity is outlined by gas in the shape of a football, and the median umbilical ligament and falciform ligament are sometimes described as corresponding to a football's seams.

Republished under the Creative Commons Attribution (CC BY-SA 2.0). (<https://creativecommons.org/licenses/by-sa/2.0/>).

In the case presented here, the etiology of NSP remains unknown. It may have resulted from the pneumothorax at presentation, as well as prolonged intubation and ventilatory support. The peritoneal drain was a less likely source of NSP in our patient given persistence of the pneumoperitoneum after the drain was replaced. The patients never received peritoneal dialysis. The exploratory laparotomy revealed no findings that suggested perforation or intra-abdominal

infection. In addition, surgical evacuation of the pneumoperitoneum failed to significantly improve the patient's hemodynamic status, which continued to deteriorate.

Although pneumoperitoneum in the pediatric population was historically believed to be inextricably associated with visceral perforation, the existence of pediatric NSP has been increasingly documented and accepted.<sup>4,6-11</sup> The case presented here provides another example of NSP in a preterm infant. In the absence of clinical signs of perforation, conservative management of pediatric NSP should be considered to decrease the risk of unnecessary instrumentation, morbidity, and mortality.<sup>6-11</sup>

### Author Contributions

Conceptualization, R.J.E. and S.G.K.; Acquisition, analysis, and interpretation of data, R.J.E. and S.G.K.; Writing – original draft preparation, R.J.E.; Review and editing, R.J.E. and S.G.K.; Supervision, S.G.K. All authors agree to be accountable for all aspects of the work in ensuring that questions related to the accuracy or integrity of any part of the work are appropriately investigated and resolved. All authors had full access to all the data in the study and take responsibility for the integrity of the data and the accuracy of the data analysis.

### Disclosures

None to report.

### References

1. Rampton JW. The football sign. *Radiology*. 2004;231(1):81–82. DOI: [10.1148/radiol.2311011290](https://doi.org/10.1148/radiol.2311011290)
2. Mularski RA, Sippel JM, Osborne ML. Pneumoperitoneum: a review of nonsurgical causes. *Crit Care Med*. 2000;28(7):2638-2644. DOI: [10.1097/00003246-200007000-00078](https://doi.org/10.1097/00003246-200007000-00078)
3. Winek TG, Mosely HS, Grout G. Pneumoperitoneum and its association with ruptured abdominal viscus. *Arch Surg*. 1988;123(6):709-712. DOI: [10.1001/archsurg.1988.01400300051008](https://doi.org/10.1001/archsurg.1988.01400300051008)
4. Williams NM, Watkin DF. Spontaneous pneumoperitoneum and other nonsurgical causes of intraperitoneal free gas. *Postgrad Med J*. 1997;73(863):531-537. DOI: [10.1136/pgmj.73.863.531](https://doi.org/10.1136/pgmj.73.863.531)
5. Adams D. Football on American football field. Unsplash. <https://unsplash.com/photos/-nATH0CrkMU>. Published August 23, 2019. Accessed January 31, 2023.
6. Tallant C, Tallant A, Nirgiotis J, Meller J. Spontaneous pneumoperitoneum in pediatric patients: a case series. *Int J Surg Case Rep*. 2016;22:55-58. DOI: [10.1016/j.ijscr.2016.03.017](https://doi.org/10.1016/j.ijscr.2016.03.017)
7. Karaman A, Demirebilek S, Akin M, Gürnlüoğlu K, İrşi C. Does pneumoperitoneum always require laparotomy? report of six cases and review of the literature. *Pediatr Surg Int*. 2005; 21:819-824. DOI: [10.1007/s00383-005-1489-3](https://doi.org/10.1007/s00383-005-1489-3)
8. Duan SX, Sun ZB, Wang GH, et al. Diagnosis and treatment of pediatric benign pneumoperitoneum: a case report series of 9 patients. *Medicine (Baltimore)*. 2017;96(2):e5814. DOI: [10.1097/MD.0000000000005814](https://doi.org/10.1097/MD.0000000000005814)
9. Khan TR, Rawat JD, Ahmed I, et al. Neonatal pneumoperitoneum: a critical appraisal of its causes and subsequent management from a developing country. *Pediatr Surg Int*. 2009; 25: 1093-1097. DOI: [10.1007/s00383-009-2488-6](https://doi.org/10.1007/s00383-009-2488-6)
10. Abdelmohsen SM, Osman MA. Idiopathic neonatal pneumoperitoneum, a case report. *Int J Surg Case Rep*. 2017;31:250-253. DOI: [10.1016/j.ijscr.2017.01.053](https://doi.org/10.1016/j.ijscr.2017.01.053)
11. He TZ, Xu C, Ji Y, Xiao-Yan S, Liu M. Idiopathic neonatal pneumoperitoneum with favorable outcome: a case report and review. *World J Gastroenterol*. 2015;21(20):6417-6421. DOI: [10.3748/wjg.v21.i20.6417](https://doi.org/10.3748/wjg.v21.i20.6417)