

# Imaging Features of Bilateral Breast Metastases from Gastric Adenocarcinoma: A Case Report

Zhao J, MD<sup>1</sup> | Wilsen CB, MD, PhD<sup>1</sup> | Young JJ, MD, MPH<sup>1</sup> | Tsai IS, MD<sup>1</sup>

**Author Affiliation:** <sup>1</sup> Department of Radiological Sciences, University of California, Irvine

**Corresponding Author:** J.Z. ([jasminz2@uci.edu](mailto:jasminz2@uci.edu))

*UCLA Radiol Sci Proc.* 2025;5(4):52-58

**Abstract:** Breast metastasis from gastric adenocarcinoma is exceptionally rare, with only a small number of cases reported in the literature. These metastases often occur in premenopausal women and commonly involve the signet ring cell subtype, usually presenting as unilateral, left breast lesions. We present the case of a 33-year-old Asian woman with signet ring cell gastric adenocarcinoma who developed bilateral breast metastases. This case illustrates the diagnostic challenges associated with this rare metastasis and highlights the essential role of multimodal imaging and biopsy in confirming the diagnosis. Early recognition of the condition is critical given the poor prognosis and lack of standardized treatment.

**Keywords:** *gastric adenocarcinoma, breast metastasis, imaging diagnosis, breast malignancies, signet ring cell*

## Introduction

Although breast cancer is the second leading cause of cancer-related mortality in women worldwide, breast metastases from extramammary primary malignancies are rare, with a clinical incidence of only 0.5-1.3%.<sup>1</sup> Common primary malignancies in cases of breast metastasis include melanoma, lymphoma, lung cancer, and ovarian carcinoma, while gastric adenocarcinoma accounts for fewer than 100 reported cases.<sup>2,3</sup> Of cases involving gastric adenocarcinoma, most cases involve signet ring cell carcinoma, a poorly differentiated subtype representing 10% of gastric cancers and typically affecting younger women of Asian descent.<sup>2</sup> Extramammary metastases tend to involve the upper-outer quadrant of the breast, and gastric cancer metastases to the breast have been reported to more frequently involve the left breast.<sup>2,4,5</sup> Clinically, gastric cancer metastases to the breast can present with a palpable nodule and, less commonly, with inflammatory skin changes.<sup>3</sup>

## Key Points

- Breast metastases from gastric signet ring cell carcinoma are rare and can mimic primary breast malignancy.
- Breast MRI is more sensitive than FDG-PET/CT for detecting early signet ring cell metastases to the breast and may reveal lesions not easily identified on other modalities such as mammography or ultrasound.
- Radiologists play a key role in raising suspicion for metastasis in patients with known extramammary malignancy, prompting biopsy to help guide further oncologic management.

Prior literature has emphasized clinical and histopathological features, with fewer reports detailing radiologic findings and diagnostic pitfalls that can contribute to delayed diagnosis. We describe a rare case of bilateral breast metastases from signet ring cell gastric adenocarcinoma, diagnosed one year after cytoreductive surgery and systemic and intraperitoneal chemotherapy.

## Abbreviations

BI-RADS: Breast Imaging Reporting and Data System

ctDNA: circulating tumor DNA

CT: computed tomography

EGD: esophagogastroduodenoscopy

ER: estrogen receptor

FDG-PET/CT: 18F-fluorodeoxyglucose positron emission tomography computed tomography

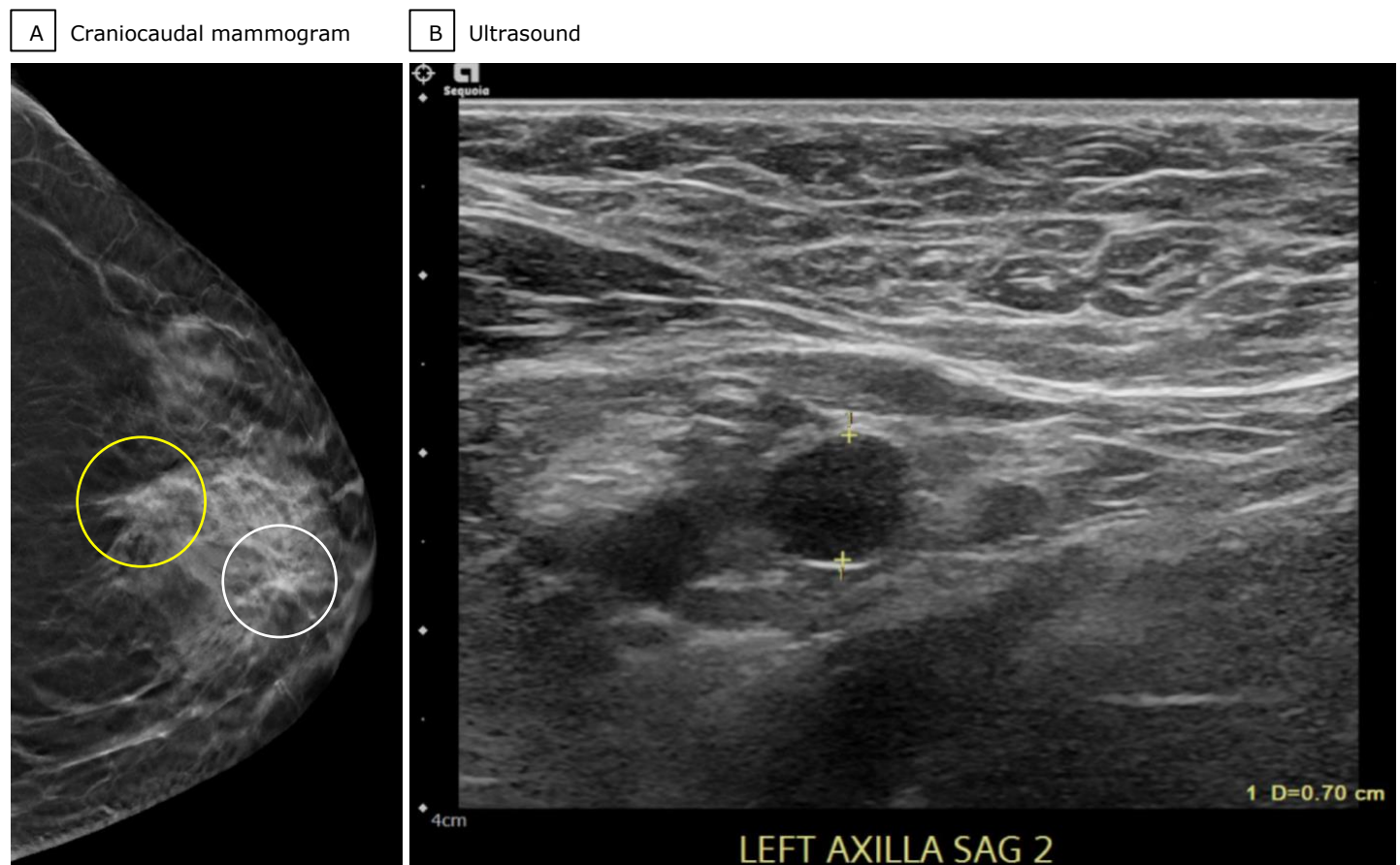
MRI: magnetic resonance imaging

This case highlights subtle imaging clues that may precede overt disease, the role of breast MRI in detecting metastatic breast lesions, and the limitations of 18F-fluorodeoxyglucose positron emission tomography computed tomography (FDG-PET/CT) in evaluating hypometabolic tumors. It also serves as an important reminder to consider metastasis in patients without a history of breast cancer and emphasizes the role of pathologic evidence in distinguishing primary and secondary breast carcinomas. This case report was prepared in accordance with the CARE guidelines for case reporting.<sup>6</sup>

## Case Presentation

A 33-year-old woman with a history of anemia presented to her primary care physician with nausea, a loss of 20 pounds over the previous months, and two weeks of worsening postprandial pain in the left upper quadrant, and nausea. The primary care physician referred her for an outpatient esophagogastroduodenoscopy (EGD), which revealed a circumferential necrotic gastric mass. The patient was sent to an outside emergency department for further imaging. Computed tomography (CT) imaging revealed diffuse thickening of the gastric fundus and body, with surrounding inflammatory changes and prominent perigastric lymphadenopathy, raising concern for gastritis or malignancy. Two months later, repeat EGD with endoscopic ultrasound at our institution confirmed the presence of a gastric mass that extended from just distal to the gastroesophageal junction to the distal body, as well as associated gastric wall thickening,

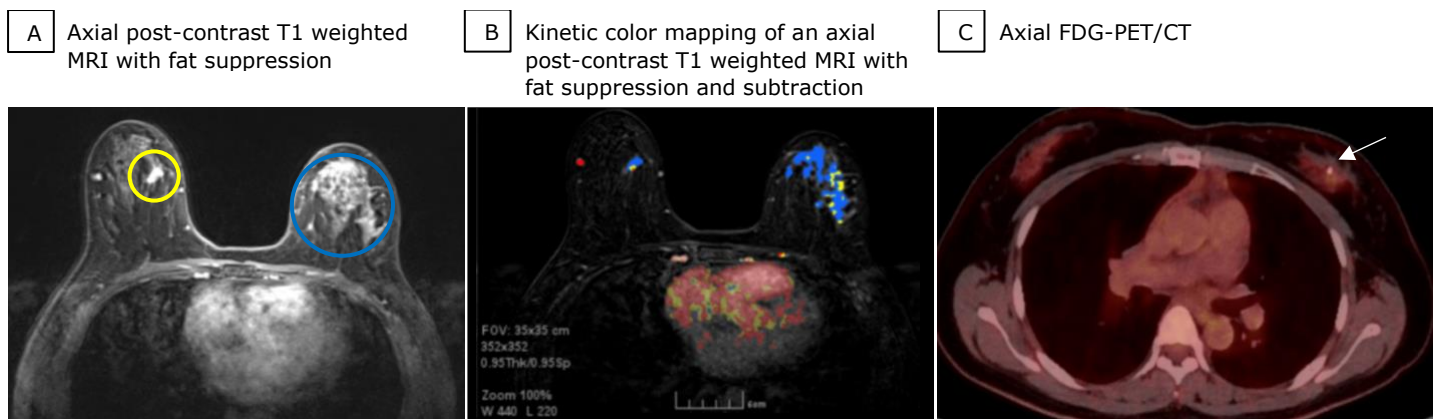
perigastric ascites, and irregular perigastric lymph nodes. Histopathological analysis of the biopsy sample collected at this time showed poorly differentiated gastric adenocarcinoma with signet ring cell features. An FDG-PET/CT scan showed mild uptake in the thickened gastric wall. Low-level activity was also noted in left axillary and bilateral level 2 cervical lymph nodes, which were presumed to be reactive from recent immunization. The patient then underwent staging laparoscopy, which revealed possible peritoneal seeding, prompting initiation of neoadjuvant chemotherapy. A diagnostic laparoscopy was later performed to reassess peritoneal involvement and to initiate concurrent intraperitoneal chemotherapy. Four months after the diagnostic laparoscopy, the patient underwent cytoreductive surgery, including total gastrectomy, D2 lymphadenectomy, distal pancreatectomy, splenectomy, bilateral salpingo-oophorectomy, and hyperthermic intraperitoneal chemotherapy (HIPEC). Postoperatively, she completed chemotherapy and targeted therapy, after which there was no evidence of recurrence on serial CT imaging and undetectable circulating tumor DNA (ctDNA). Approximately one year after surgery, the patient's ctDNA levels began to rise. Repeat EGD with biopsy of the gastroesophageal junction was unremarkable. During a gynecology visit, the patient's left breast was noted to be denser than her right breast, although no palpable mass was identified. Diagnostic mammography revealed two adjacent and similar-appearing areas of architectural distortion in the left breast: one in the upper-outer quadrant at middle depth 5 cm from the nipple and another in the central region at anterior depth 2 cm from the nipple (Figure 1A). A complete left breast ultrasound did not reveal a sonographic correlate for the architectural distortions; however, three axillary lymph nodes had suspicious features, including cortical thickening up to 7 mm (reference range,  $\leq 3$  mm), round morphology, and hilar effacement (Figure 1B). These findings were categorized as suspicious (BI-RADS 4). Stereotactic biopsy of the upper-outer quadrant architectural distortion and ultrasound-guided biopsy of a left axillary node confirmed poorly differentiated metastatic gastric adenocarcinoma with signet ring cell features.

**Figure 1.** Initial Imaging of the Left Breast of a 35-Year-Old Woman 1 Year After Cytoreductive Surgery for Gastric Adenocarcinoma

(A) Craniocaudal mammogram view of the left breast shows two areas of architectural distortion: one in the upper-outer quadrant at middle depth 5 cm from the nipple (yellow circle), which was biopsied under stereotactic guidance, and a second in the central region at anterior depth 2 cm from the nipple (white circle). (B) Left breast ultrasound demonstrates enlarged axillary lymph nodes with round shape and loss of the normal fatty hilum.

Given biopsy-proven distant metastasis after curative-intent surgery, the patient was enrolled in a clinical trial with modified chemotherapy and monoclonal antibody therapy. Subsequent breast magnetic resonance imaging (MRI) demonstrated left level 1 axillary lymphadenopathy and 4.2 cm of heterogeneous non-mass enhancement in the superior left breast at middle depth (Figures 2A and 2B). The non-mass enhancement followed a regional distribution, spanned the two areas of architectural distortion seen on the mammogram (Figure 1A), and corresponded to the previously biopsied metastasis. Additionally, there was a 1.3 cm focal area of heterogeneous non-mass enhancement in the upper-inner quadrant of the right breast, 5 cm deep to the nipple, without associated right axillary lymphadenopathy (Figures 2A and 2B). Although a second-look ultrasound of the left breast was recommended, a

follow-up FDG-PET/CT was obtained, showing no focal activity in either breast (Figure 2C). Four months after the FDG-PET/CT, a limited second-look right breast ultrasound was performed, but there was no sonographic correlation to the MRI finding. Therefore, MRI-guided biopsy or follow-up MRI imaging in six months was recommended. Shortly after the second-look ultrasound, the patient underwent a left mastectomy with axillary lymph node dissection, which showed 11 of 21 nodes to be positive for metastatic disease with extranodal extension. However, persistent elevation of ctDNA levels one month after the left mastectomy raised suspicion for residual disease. Four months after the left mastectomy, the patient reported increased right breast fullness. Diagnostic mammography showed a 1.3 cm area of architectural distortion in the right upper-inner quadrant, 6 cm from the nipple, in the area of the

**Figure 2.** Breast Imaging in a 35-Year-Old Woman with Biopsy-Confirmed Breast Metastases of Gastric Adenocarcinoma

(A) Breast MRI with 1.3 cm focal area of heterogeneous non-mass enhancement in the upper-inner quadrant of the right breast (A, yellow circle) and 4.2 cm regional heterogeneous non-mass enhancement spanning the superior left breast (A, blue circle). (B) Bilateral breast lesions demonstrate predominantly fast initial enhancement with persistent delayed enhancement kinetics. (C) FDG-PET/CT with a metallic clip seen in the left breast from area of prior biopsy without associated uptake (C, arrow). There is no focal abnormal uptake in the breasts to correlate to the known neoplasm or to the abnormal MRI finding seen in the right breast.

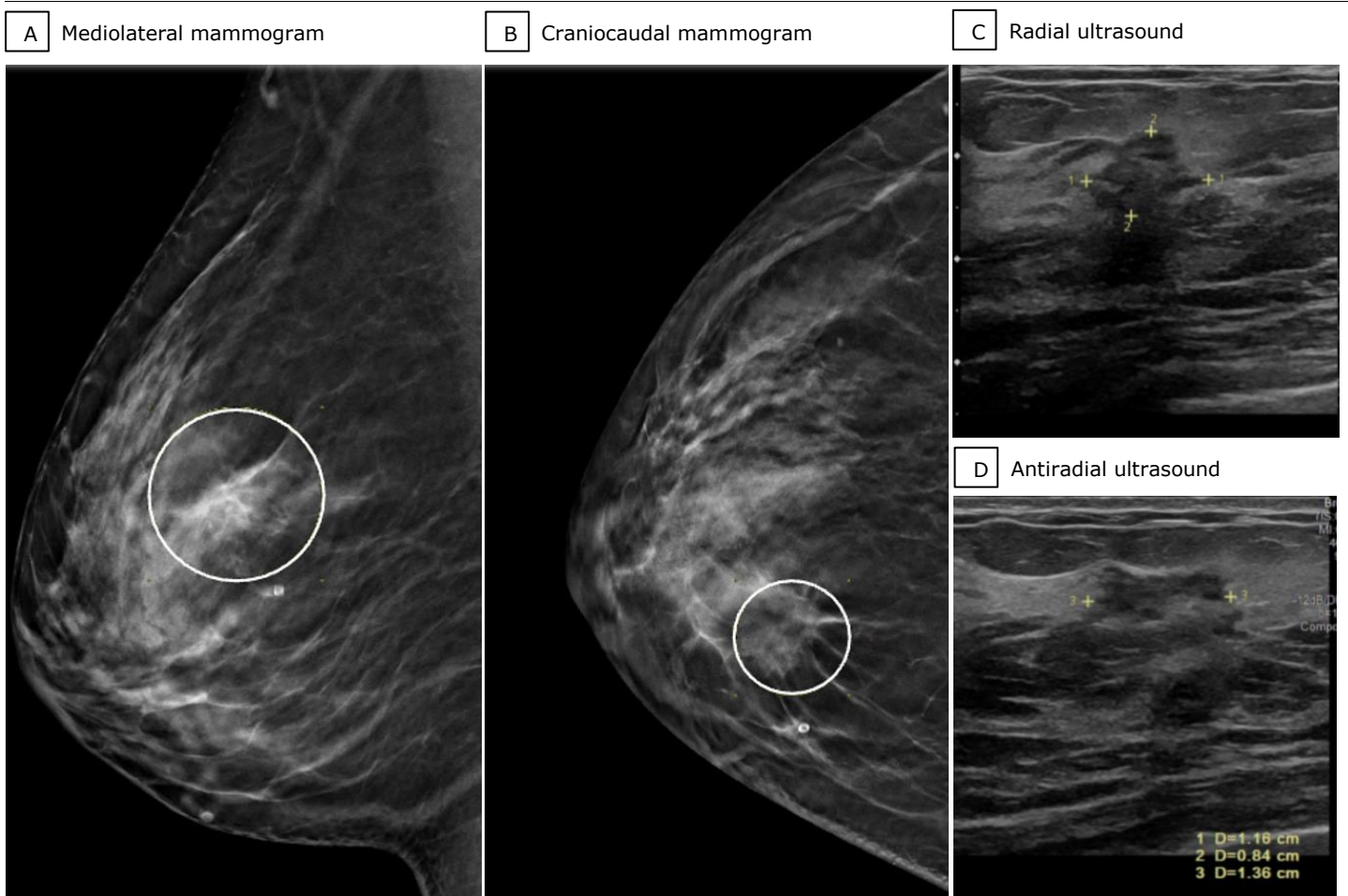
prior MRI finding (Figures 3A and 3B). Ultrasound revealed a 1.4 cm irregular mass with angular margins at the 1-o'clock position 3 cm from the nipple (Figure 3C and 3D), corresponding to the area of architectural distortion on the mammogram. Ultrasound-guided biopsy revealed immunohistochemical staining positive for CK7, CK20, and CDX2, and negative for GATA3, mammaglobin, and estrogen receptor (ER), consistent with gastrointestinal origin. The patient underwent a right mastectomy with clear margins. Follow-up imaging three months after the right mastectomy demonstrated new lymphadenopathy in the left subpectoral and axillary lymph nodes and skin thickening at the left chest wall surgical site. A skin punch biopsy was performed that was positive for metastatic gastric adenocarcinoma. Given the progression of disease, the patient elected to establish care with the palliative team while awaiting other clinical trial opportunities.

## Discussion

Breast metastasis from gastric adenocarcinoma is rare, particularly when no other metastatic sites are present. Of the few reported cases, most have unilateral disease, with over half occurring in the left breast.<sup>2</sup> This left-sided proclivity has been thought to result from retrograde lymphatic spread via the left supraclavicular nodes. Despite these patterns, the exact mechanism of

metastasis to the breast remains unclear. Hormonal influences, such as the action of estrogens through estrogen receptors (ER) like ER- $\beta$ , may promote tumor proliferation in breast tissue despite the absence of a primary breast malignancy. Alternatively, the rich vascular supply of the breast may facilitate hematogenous dissemination of tumor cells.<sup>2,7</sup>

Accurate diagnosis relies on a combination of clinical history, immunohistochemistry, and imaging. Key histopathologic findings include the absence of in situ carcinoma, a lack of breast markers like ER and progesterone receptor (PR), and the expression of gastrointestinal markers like CK20, CEA, and CK7.<sup>4</sup> The imaging presentation of breast metastases is also highly variable. While some cases describe well-circumscribed, oval, and noncalcified masses, others describe indistinct breast masses with associated skin thickening.<sup>5,8</sup> Gastric metastases are more often associated with architectural distortion compared to metastases from other primary tumors,<sup>9</sup> as in this case. MRI proved critical in further delineating disease extent, detecting more extensive regional non-mass enhancement in the left breast and a small lesion in the right upper-inner breast. Notably, this right-sided lesion was not seen on initial mammography or FDG-PET/CT, suggesting greater sensitivity of MRI for dense breasts or subtle metastatic involvement. The absence of FDG uptake aligns with prior

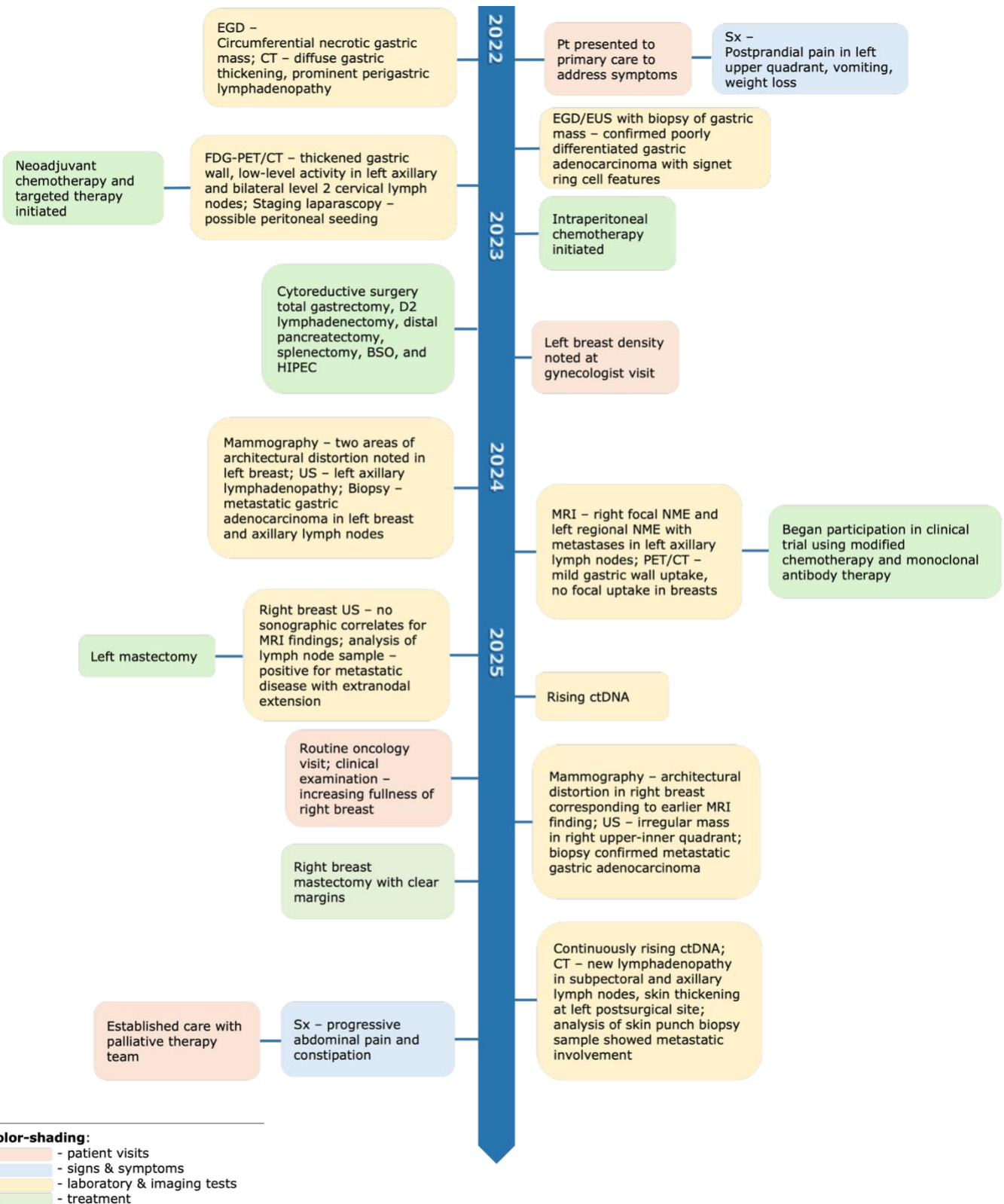
**Figure 3.** Images of the Right Breast of a 35-Year-Old Woman with Confirmed Metastatic Gastric Adenocarcinoma

(A) Mediolateral and (B) craniocaudal mammogram views of the right breast demonstrate an architectural distortion measuring 1.3 cm in the upper-inner quadrant of the right breast 6 cm from the nipple at middle depth (A, B, white circles). (C, D) Radial and antiradial views on right breast ultrasound show a corresponding 1.4 cm irregular mass with indistinct and angular margins in the right breast at the 1-o'clock position 3 cm from the nipple.

reports describing the characteristically low FDG avidity of mucinous tumors like signet ring cell carcinoma. This is attributed to their high mucin content and diminished expression of GLUT-1 receptors, resulting in reduced metabolic activity.<sup>10</sup> These limitations reinforce the importance of correlating FDG-PET/CT findings with other imaging modalities. The lack of FDG uptake also suggests that FDG-PET/CT alone may be insufficient for restaging or recurrence evaluation in this subtype and that MRI, coupled with second-look ultrasound or MRI-guided biopsy, should be performed when metastatic disease is suspected. In this case, expediting MRI-guided biopsy of the right breast focal non-mass enhancement after a negative second-look ultrasound may have contributed to a more timely

diagnosis and surgical planning. Despite therapeutic advances, the prognosis for patients with breast metastases from gastric cancer remains poor. A systematic review reported a median survival of 8.6 months following diagnosis, reflecting the aggressive biology and rapid progression associated with this disease.<sup>3</sup> Currently, there are no standardized treatment guidelines. Management is typically guided by systemic treatment of gastric adenocarcinoma using chemotherapy and anti-cancer agents.<sup>11</sup> Although lumpectomy and wide local resection have been proposed for breast metastases, the role of surgery remains unclear and may be more palliative given limited evidence for improved survival.<sup>2-5</sup>

**Case report timeline.**



Abbreviations: BSO, bilateral salpingo-oophorectomy; CT, computed tomography; EGD, esophagogastroduodenoscopy; FDG-PET, fluorodeoxyglucose-positron emission tomography; HIPEC, hyperthermic intraperitoneal chemotherapy; NME, non-mass enhancement; Pt, patient; US, ultrasound; Sx, symptoms

Breast metastasis from gastric cancer represents a rare but aggressive manifestation of advanced-stage disease. Diagnosis can be delayed due to imaging appearances that are variable and overlap with those of primary breast malignancy. Multimodality imaging and histologic confirmation are essential to diagnose and guide appropriate treatment.

## Conclusion

This case illustrates a rare and diagnostically challenging manifestation of gastric adenocarcinoma. In patients with a known extramammary malignancy, particularly mucinous subtypes such as signet ring cell gastric carcinoma, a combination of mammography, ultrasound, and breast MRI can aid in identifying disease extent. Given variable imaging findings and low FDG avidity of these lesions, maintaining a broad differential and pursuing biopsy of suspicious findings remains critical for timely diagnosis and management.

## Author Contributions

Conceptualization, C.B.W., J.J.Y., I.S.T.; Acquisition, analysis, and interpretation of data, J.Z., C.B.W., J.J.Y., I.S.T.; Writing – original draft preparation, J.Z.; Review and editing, C.B.W., J.J.Y., I.S.T.; Supervision, I.S.T. All listed authors agree to be accountable for all aspects of the work in ensuring that questions related to the accuracy or integrity of any part of the work are appropriately investigated and resolved. All authors had full access to all the data in the study and take responsibility for the integrity of the data and accuracy of the data analysis.

## Disclosures

None to report.

## Acknowledgments

The authors would like to acknowledge the patient on whom the case report is based and Dr. Julio Ibarra for the pathological analysis and expertise.

## References

1. Bohman LG, Bassett LW, Gold RH, Voet R. Breast metastases from extramammary malignancies. *Radiology*. 1982;144(2):309-312. doi:[10.1148/radiology.144.2.7089284](https://doi.org/10.1148/radiology.144.2.7089284)
2. Buerba-Vierregge HH, Fernández-Ferreira R, Soberanis-Piña PD, De la Peña-López IR, Navarro-García LM, Macari-Jorge A. Breast metastasis of gastric signet ring cell carcinoma: A case report and literature review. *Case Rep Oncol*. 2021;14(1):165-172. doi:[10.1159/000510938](https://doi.org/10.1159/000510938)
3. Ma Y, Liu W, Li J, Xu Y, Wang H. Gastric cancer with breast metastasis: Clinical features and prognostic factors. *Oncol Lett*. 2018;16(5):5565-5574. doi:[10.3892/ol.2018.9383](https://doi.org/10.3892/ol.2018.9383)
4. Tian Q, Zeng J, Tao X, Zhang Z, Zhou X, Wang Y. Clinical pathology of metastatic gastric carcinoma to the breast: A report of two cases and a review of literature. *Oncol Lett*. 2016;11(5):3081-3084. doi:[10.3892/ol.2016.4350](https://doi.org/10.3892/ol.2016.4350)
5. Madan AK, Ternovits C, Huber SA, Pei LA, Jaffe BM. Gastrointestinal metastasis to the breast. *Surgery*. 2002;132(5):889-893. doi:[10.1067/msy.2002.126013](https://doi.org/10.1067/msy.2002.126013)
6. Riley DS, Barber MS, Kienle GS, et al. CARE guidelines for case reports: explanation and elaboration document. *J Clin Epidemiol*. 2017;89:218-235. doi:[10.1016/j.jclinepi.2017.04.026](https://doi.org/10.1016/j.jclinepi.2017.04.026)
7. He CL, Chen P, Xia BL, Xiao Q, Cai FL. Breast metastasis of gastric signet-ring cell carcinoma: A case report and literature review. *World J Surg Oncol*. 2015;13:120. doi:[10.1186/s12957-015-0538-1](https://doi.org/10.1186/s12957-015-0538-1)
8. Kwak JY, Kim EK, Oh KK. Radiologic findings of metastatic signet ring cell carcinoma to the breast from stomach. *Yonsei Med J*. 2000;41(5):669-672. doi:[10.3349/ymj.2000.41.5.669](https://doi.org/10.3349/ymj.2000.41.5.669)
9. Abbas J, Wienke A, Spielmann RP, Bach AG, Surov A. Intramammary metastases: comparison of mammographic and ultrasound features. *Eur J Radiol*. 2013;82(9):1423-1430. doi:[10.1016/j.ejrad.2013.04.032](https://doi.org/10.1016/j.ejrad.2013.04.032)
10. Filik M, Kir KM, Aksel B et al. The role of 18F-FDG PET/CT in the primary staging of gastric cancer. *Mol Imaging Radionucl Ther*. 2015;24(1):15-20. doi:[10.4274/mirt.26349](https://doi.org/10.4274/mirt.26349)
11. Ajani JA, D'Amico TA, Bentrem DJ, et al. Gastric Cancer, Version 2.2022, NCCN Clinical Practice Guidelines in Oncology. *J Natl Compr Canc Netw*. 2022;20(2):167-192. doi:[10.6004/jnccn.2022.0008](https://doi.org/10.6004/jnccn.2022.0008)