

## CLINICAL VIGNETTE

# Therapy-related Acute Lymphoblastic Leukemia Associated with MLL Amplification in a Patient with Metastatic Uterine Leiomyosarcoma

Yi-Kong Keung, M.D., FACP; Jensen Hu, B.Sc.; and Eddie Hu, M.D., FACP

### Introduction

Conventional chemotherapy that targets DNA replication and synthesis has been associated with increased risk of leukemia and second malignancy among long-term cancer survivors. Alkylating chemotherapy, DNA topoisomerase II inhibitors, taxanes, etc. have been implicated in secondary leukemia with or without typical cytogenetic abnormalities. The FDA approval of tyrosine kinases inhibitor, imatinib, in the treatment of chronic myeloid leukemia in 2001 has revolutionized the battlefield in the war against cancer. In the past decades, a number of tyrosine kinase inhibitors have been approved for use in various cancer types. Other novel chemotherapy such as trabectedin has also been approved for various types of malignancies. Can these newer agents cause secondary leukemia or cancer as the conventional chemotherapy? We report a case of acute lymphoblastic leukemia (ALL) in a patient with metastatic uterine leiomyosarcoma previously treated remotely with cyclophosphamide, cisplatin, and doxorubicin and more recently with trabectedin and pazopanib, associated with mixed lineage leukemia gene (MLL) amplification.

### Case History

This is a 67-year-old female who initially presented with large uterine leiomyosarcoma, ER/PR both positive, which was resected in 1987. She developed bilateral lung nodules with biopsy proven leiomyosarcoma in May 2002. She received systemic chemotherapy consisting of cyclophosphamide 500 mg/m<sup>2</sup>, doxorubicin 50mg/m<sup>2</sup>, and cisplatin 50mg/m<sup>2</sup> monthly for 3 cycles from July to September 2003 with no significant response. She was surprisingly asymptomatic. Because of the tumor being ER/PR positive, she was placed on high dose megestrol 80mg four times daily. Over the years, the disease progressed slowly, and she developed intractable coughing by September 2009 and recurrent hemoptysis in November 2009. She then received trabectedin under a clinical trial from March to June 2011. Interval CT scan showed no significant improvement in the lung metastases, and she refused further chemotherapy. Soon after, pazopanib was approved by the FDA in treatment of soft tissue sarcoma; the patient was started on pazopanib in May 2012. Her coughing and hemoptysis resolved almost completely though repeat CT scans continued to show multiple pulmonary nodules. She was admitted to local hospital for pneumonia at the end of

December 2013. In January 2014, WBC was 7400/ $\mu$ L, hemoglobin 13.5 g/dL, platelet 130,000/ $\mu$ L with neutrophil 17%, lymphocyte 58%, monocyte 8%, eosinophil 4%, rare blasts, and nucleated RBC 19%. Serum LDH was elevated to 1,166 IU/L. Comprehensive metabolic panel was normal except AST 82 and ALT 73. Bone marrow examination showed hypercellular marrow with 65% blasts. Flow cytometry showed positivity of Tdt, CD10, CD19, CD38, and HLA-DR consistent with precursor B-cell acute lymphoblastic leukemia. Given the poor prognosis of the co-existing metastatic leiomyosarcoma, the patient was reluctant to receive any induction chemotherapy, and she died shortly after.

### Results

Chromosome study of the bone marrow showed 45-46,XX,add(8)(q24.3),add(16)(q22),+21, del(21)(q22),-22,add(22)(q11.2),+mar[cp8]/46,XX[8] (Figure 1). Florescence in-situ hybridization studies showed no evidence of BCR-ABL gene rearrangement, or MLL gene locus 11q23 translocation. However, abnormal hybridization pattern with 3-4 fusion signals of MLL gene (using break-apart probe, Vysis Catalogue #190083) were observed in 30.5% interphase nuclei suggesting MLL gene amplification. Quantitative PCR of the peripheral blood showed both b2a2 and e1a2 transcript being <0.001% and b3a2 0.005%.

### Discussion

Most of the therapy-related acute leukemia are myeloid lineage, but therapy-related acute lymphoblastic leukemia are increasingly recognized.<sup>1,2</sup> Pagano et al<sup>1</sup> reported only 11 (1.2%) out of 901 ALL patients had a history of prior treatment compared to 47 (13%) cases out of 372 acute myeloid leukemia (AML). Although many have initially raised suspicion about the entity of therapy-related ALL, larger studies have supported therapy-related ALL as a distinct entity.<sup>3,4</sup> According to a study of 152 cases of ALL and 876 cases of AML from 2/1989 to 4/2001 in the City of Hope National Medical Center, 4% and 4.9% cases were considered therapy-related with prior chemotherapy and/or radiation treatment for malignancy respectively. MLL gene or 11q23 rearrangement occurred in 16.7% therapy-related AML,

compared to 46% in therapy-related ALL.<sup>5</sup> These cases are usually associated with prior exposure to topoisomerase II inhibitors such as etoposide and doxorubicin.

Amplification of MLL gene has also been recognized though much less frequently in patients with acute leukemia, mostly AML.<sup>6,7</sup> In a United Kingdom Cancer Cytogenetics Group Study, Cuthbert et al<sup>8</sup> reported a series of 12 acute leukemia associated with MLL amplification by FISH, 11 cases were AML, and there is only one case of acute lymphoblastic leukemia. Literature search through MEDLINE by "MLL amplification" and "acute lymphoblastic leukemia" retrieves only a handful of cases that are summarized in Table.

The occurrence of acute lymphoblastic leukemia in this patient may be coincidental. Alternatively, it may be related to the chemotherapy she has received in the past, which include cyclophosphamide, cisplatin, doxorubicin 10 years, trabectedin 33 months, and pazopanib 19 months before. Typical therapy-related AML associated with prior alkylating agents has a latency period of 5-7 years and topoisomerase II inhibitor of 1-3 years. Though not impossible, it is less likely for three cycles of cyclophosphamide, cisplatin, and doxorubicin given 10 years before to cause the ALL in our patient.

Pazopanib is a multi-target tyrosine kinase inhibitor of VEGFR, PDGFR, c-kit, etc.<sup>9</sup> It is approved by FDA for use in previously treated patients with advanced soft tissue sarcoma after it was showed to prolong progression-free survival from 1.6 to 4.6 months in a phase III randomized controlled trial.<sup>10</sup> Pazopanib, being a tyrosine kinase inhibitor and hence an anti-angiogenesis, has no significant direct cytotoxic or DNA-damaging effects to the bone marrow stem cells. It seems improbable for it to be the direct cause of acute leukemia in our patient.

Trabectedin is a fully synthetic compound of a tetrahydroisoquinoline alkaloid. It was approved by European Commission for use in patients with soft tissue sarcoma and recurrent ovarian cancer.<sup>11,12</sup> Trabectedin functions like a guanine-specific alkylating agent that binds and alkylates the GC-rich sequences in the DNA minor groove. It also impairs the DNA repair mechanism and targets tumor inflammation and angiogenesis. Hence, it is a novel multi-target drug that affects both cancer cells and microenvironment.<sup>13</sup>

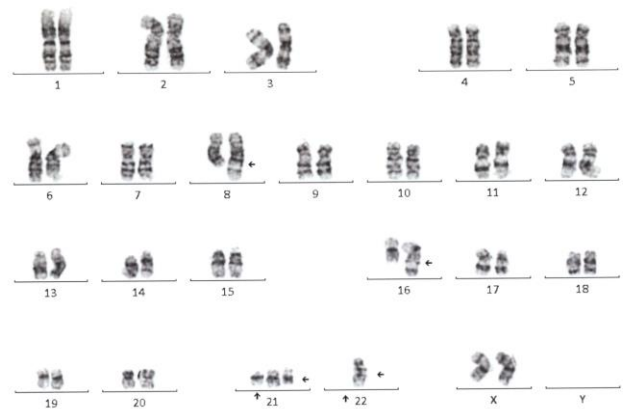
Liu et al<sup>14</sup> reported a case of acute myeloid leukemia 4 months after discontinuation of trabectedin that was administered for 5 months in a 24-year-old female heavily pretreated with various chemotherapy regimens and autologous stem cell transplantation for Ewing's sarcoma. Of note, their patient also has complex chromosomal abnormalities, 46,XX,add(8)(q24.3), der(10)t(10;11)(p12;q23)inv(11)(q13q23)[20]/46,XX[1], and gain of MLL gene signals in 95% interphase nuclei by FISH. It is controversial if the acute myeloid leukemia is due to trabectedin since their patient had been exposed to many prior chemotherapy regimens. However, this case did trigger a response from PharmaMar that six cases of AML were reported among more than 3,000 patients treated in trabectedin clinical trials, 7 weeks to 4 months after discontinuation of

trabectedin; chromosome 5 abnormalities were reported in one case with no karyotypic information available in the remaining patients.<sup>15</sup>

In our patient, the acute lymphoblastic leukemia occurred 30 months after discontinuation of trabectedin given for 3 months. Of interest, our case also demonstrated MLL gene amplification similar to that of Liu et al.<sup>14</sup> In Table 1, two out of the six reported cases of ALL associated with MLL amplification are therapy-related. While it is inconclusive, it is not improbable that our case is related to trabectedin.

**Figures and Tables**

**Figure 1.** Karyotype showing 45-46, XX,add(8)(q24.3),add(16)(q22),+21,del(21)(q22),-22,add(22)(q11.2),+mar [cp8]/46,XX[8].



**Table 1.** Summary of reported cases of acute lymphoblastic leukemia/lymphoma associated with MLL amplification. (Abbreviations: ALL, acute lymphoblastic leukemia; LBL lymphoblastic lymphoma; NA, not reported).

Case	Age	Sex	Presentation
1	7	M	Leukocytosis
2	86	F	Pancytopenia and monoclonal gammopathy IgG
3	12	M	Abdominal mass
4	80	M	Leukocytopenia 2 years after diagnosis of DLBCL treated with R-CHOP x 8,R-ICE x7 and radiation
5	62	M	Cytopenia 5 years after diagnosis of pleiomorphic sarcoma of left hip treated with doxorubicin and ifosfamide followed by radiation
6	4	F	Leukocytosis
Current	67	F	25 years after diagnosis of uterine leiomyosarcoma, 10 years after chemotherapy doxorubicin, cisplatin and cyclophosphamide, 33 months after trabectedin and 19 months after pazopanib

(Table 1 Cont.)

Case	Diagnosis	Cytogenetic Study
1	c-ALL	No metaphase for analysis
2	Pre-B ALL	44,XX,del(5)(q13q31),dic(6;17)(p25;q11),hsr(11)(pter_q23::hsr::q21::hsr::qter),-16,-17[18]/46,XX[2]
3	B-LBL	47,X,-Y,+1,del(1)(q25),-del(1)(q12),dup(11)(q24q23),add(12)(p11.2),+21
4	Pro-B ALL	42,XY,-3,hsr(11)(q23),-14,-16,-20[cp6]/43,idem,+

		mar[cp3]/46,XY[11].ish hsr(11)amp(MLL)
5	Pro-B ALL	44-45,XY,-5,hsr(11)(q23),-15,+mar1 [cp3]/48-50,sl,+6,+8,+20,+22[cp2]/57-59,sdl1,+1,+del(1)(q12),+2,+7,+10,+hsr(11)(q23)a,+12,+13,+21,-mar1,+mar2(cp3)/59,sdl2,+X,-1,-del(1)(q12),+del(1)(q25),+5,+10,+11[cp6]/73-77,sdl2,+Y,+del(1)(q12),+3,+4,+5,+6,+8,+9,+10,+11,-hsr(11),+12,+13,+14,+15,+16,+17,+17,+18,+18,+19,+22,-mar2,+mar3x2[cp7]
6	T-cell ALL	46,XX[20]
Current	Pre-B ALL	45-46,XX,add(8)(q24.3),add(16)(q22),+21,del(21)(q22),-22,add(22)(q11.2),+mar [cp8]/46,XX[8]

(Table 1 Cont.)

Case	Comment	Year/Reference
1	Remission, survival >21 months	2000 <sup>8</sup>
2	Died shortly after diagnosis	2003 <sup>16</sup>
3	Remission, survival >9 months	2012 <sup>17</sup>
4	NA	2012 <sup>18</sup>
5	NA	
6	Remission, survival >25 months	2013 <sup>19</sup>
Current	Died shortly after diagnosis	

## REFERENCES

- Pagano L, Pulsoni A, Tosti ME, Annino L, Mele A, Camera A, Martino B, Guglielmi C, Cerri R, Di Bona E, Invernizzi R, Castagnola C, Bassan R, Mele L, Todeschini G, Leone G, Mandelli F.** Acute lymphoblastic leukaemia occurring as second malignancy: report of the GIMEMA archive of adult acute leukaemia. Gruppo Italiano Malattie Ematologiche Maligne dell'Adulto. *Br J Haematol.* 1999 Sep;106(4):1037-40. PubMed PMID: 10520009.
- Mauritzson N, Albin M, Rylander L, Billström R, Ahlgren T, Mikoczy Z, Björk J, Strömberg U, Nilsson PG, Mitelman F, Hagmar L, Johansson B.** Pooled analysis of clinical and cytogenetic features in treatment-related and de novo adult acute myeloid leukemia and myelodysplastic syndromes based on a consecutive series of 761 patients analyzed 1976-1993 and on 5098 unselected cases reported in the literature 1974-2001. *Leukemia.* 2002 Dec;16(12):2366-78. PubMed PMID: 12454741.
- Abdulwahab A, Sykes J, Kamel-Reid S, Chang H, Brandwein JM.** Therapy-related acute lymphoblastic leukemia is more frequent than previously recognized and has a poor prognosis. *Cancer.* 2012 Aug 15;118(16):3962-7. doi: 10.1002/cncr.26735. Epub 2011 Dec 16. PubMed PMID: 22180297.
- Tang G, Zuo Z, Thomas DA, Lin P, Liu D, Hu Y, Kantarjian HM, Bueso-Ramos C, Medeiros LJ, Wang SA.** Precursor B-acute lymphoblastic leukemia occurring in patients with a history of prior malignancies: is it therapy-related? *Haematologica.* 2012 Jun;97(6):919-25. doi: 10.3324/haematol.2011.057752. Epub 2011 Dec 29. PubMed PMID: 22207681; PubMed Central PMCID: PMC3366660.
- Ishizawa S, Slovak ML, Popplewell L, Bedell V, Wrede JE, Carter NH, Snyder DS, Arber DA.** High

- frequency of pro-B acute lymphoblastic leukemia in adults with secondary leukemia with 11q23 abnormalities. *Leukemia.* 2003 Jun;17(6):1091-5. PubMed PMID: 12764373.
- Dolan M, McGlennen RC, Hirsch B.** MLL amplification in myeloid malignancies: clinical, molecular, and cytogenetic findings. *Cancer Genet Cytogenet.* 2002 Apr 15;134(2):93-101. PubMed PMID: 12034519.
  - Andersen MK, Christiansen DH, Kirchoff M, Pedersen-Bjergaard J.** Duplication or amplification of chromosome band 11q23, including the unrearranged MLL gene, is a recurrent abnormality in therapy-related MDS and AML, and is closely related to mutation of the TP53 gene and to previous therapy with alkylating agents. *Genes Chromosomes Cancer.* 2001 May;31(1):33-41. PubMed PMID: 11284033.
  - Cuthbert G, Thompson K, McCullough S, Watmore A, Dickinson H, Telford N, Mugneret F, Harrison C, Griffiths M, Bown N.** MLL amplification in acute leukaemia: a United Kingdom Cancer Cytogenetics Group (UKCCG) study. *Leukemia.* 2000 Nov;14(11):1885-91. PubMed PMID: 11069023.
  - Sloan B, Scheinfeld NS.** Pazopanib, a VEGF receptor tyrosine kinase inhibitor for cancer therapy. *Curr Opin Investig Drugs.* 2008 Dec;9(12):1324-35. Review. PubMed PMID: 19037839.
  - van der Graaf WT, Blay JY, Chawla SP, Kim DW, Bui-Nguyen B, Casali PG, Schöffski P, Aglietta M, Staddon AP, Beppu Y, Le Cesne A, Gelderblom H, Judson IR, Araki N, Ouali M, Marreaud S, Hodge R, Dewji MR, Coens C, Demetri GD, Fletcher CD, Dei Tos AP, Hohenberger P; EORTC Soft Tissue and Bone Sarcoma Group; PALETTE study group.** Pazopanib for metastatic soft-tissue sarcoma (PALETTE): a randomised, double-blind, placebo-controlled phase 3 trial. *Lancet.* 2012 May 19;379(9829):1879-86. doi: 10.1016/S0140-6736(12)60651-5. Epub 2012 May 16. PubMed PMID: 22595799.
  - Brodowicz T.** Trabectedin in soft tissue sarcomas. *Future Oncol.* 2014 Jun;10(8 Suppl):s1-5. doi: 10.2217/fo.14.117. Review. PubMed PMID: 25048043.
  - Monk BJ, Dalton H, Benjamin I, Tanović A.** Trabectedin as a new chemotherapy option in the treatment of relapsed platinum sensitive ovarian cancer. *Curr Pharm Des.* 2012;18(25):3754-69. Review. PubMed PMID: 22591421.
  - Lopez JP, Gajdos C, Elias A.** Trabectedin: novel insights in the treatment of advanced sarcoma. *Curr Oncol Rep.* 2014 Jun;16(6):387. doi: 10.1007/s11912-014-0387-z. Review. PubMed PMID: 24756367.
  - Liu SV, Zneimer S, Tahbaz A, Douer D.** Therapy-related acute myeloid leukemia following treatment with trabectedin for Ewing's sarcoma. *Acta Haematol.* 2011;126(2):76-8. doi: 10.1159/000324936. Epub 2011 Apr 18. PubMed PMID: 21502754.
  - Cartoafa M, Kahatt C, Soto-Matos A, Roy E, Lardelli P.** Acute myeloid leukemia unlikely related to trabectedin treatment. *Acta Haematol.* 2011;126(4):238-9; author reply 240. doi: 10.1159/000330952. Epub 2011 Sep 24. PubMed PMID: 21952689.

16. **Espinet B, Florensa L, Salido M, Solé F.** MLL intrachromosomal amplification in a pre-B acute lymphoblastic leukemia. *Haematologica.* 2003 Feb;88(2):EIM03. PubMed PMID: 12604431.
17. **Mater DV, Goodman BK, Wang E, Gaca AM, Wechsler DS.** MLL duplication in a pediatric patient with B-cell lymphoblastic lymphoma. *J Pediatr Hematol Oncol.* 2012 Apr;34(3):e120-3. doi: 10.1097/MPH.0b013e3182273b57. PubMed PMID: 22052166.
18. **Racke F, Cole C, Walker A, Jones J, Heerema NA.** Therapy-related pro-B cell acute lymphoblastic leukemia: report of two patients with MLL amplification. *Cancer Genet.* 2012 Dec;205(12):653-6. doi: 10.1016/j.cancergen.2012.11.001. Epub 2012 Dec 11. PubMed PMID: 23238285; PubMed Central PMCID: PMC4032176.
19. **Haltrich I, Csóka M, Kovács G, Török D, Alpár D, Ottoffy G, Fekete G.** Six cases of rare gene amplifications and multiple copy of fusion gene in childhood acute lymphoblastic leukemia. *Pathol Oncol Res.* 2013 Jan;19(1):123-8. doi: 10.1007/s12253-012-9533-9. Epub 2012 Apr 24. PubMed PMID: 22528566.

*Submitted August 3, 2015*