

## CLINICAL VIGNETTE

# A "Benign" Malignancy

Gerard W. Frank, M.D., Ph.D.

### *Case Report*

A 73-year-old man presented with a single episode of hemoptysis, which occurred during an altercation. He denied dyspnea, chest pain or chronic bronchitis. He was a non-smoker, born in Cuba, retired from the media industry where he had been a cameraman. Aside from hypothyroidism, the past history was significant for removal of a spinal schwannoma several years prior. His physical examination was unremarkable. Of relevance was the history three years prior when he presented with a non-productive cough. Workup included a chest CT scan, which showed a lobulated mass in the lower trachea, just above the right mainstem bronchus. (Figs. 1 and 2). There was no significant adenopathy seen. He underwent bronchoscopy and the mass was partially resected by laser. Pathology was read as adenoid cystic carcinoma, low grade (Fig. 3). He received no further treatment and a chest CT scan two years later showed no apparent change in the tracheal lesion. The current chest x-ray was read as unremarkable. He declined further workup.

### *Discussion*

The first recorded tracheal tumor was by Morgagni in 1761. While rare, there are many types, both benign and malignant. They are generally divided by histologic origin into epithelial and mesenchymal tumors<sup>1</sup>. The most common malignant tumor presenting in the trachea is squamous cell carcinoma (SCC), with adenoid cystic carcinoma (ACC) ranking second most common in most series. Other tracheal malignancies include lymphomas and sarcomas. Benign tumors include papillomas, fibromas, schwannomas and lipomas. In one series, SCC, ACC, carcinoid, squamous cell papilloma and mucoepidermoid carcinoma accounted for 86% of 198 tracheal tumors. Adenoid cystic carcinoma (ACC) occurs much more commonly in the salivary glands, and while the trachea is the most common site in the thorax for ACC, it has occasionally been reported peripherally in the lung<sup>2</sup>. There may be a slight female predominance. Consistent with its name,

histology shows gland-like formations often described as "tadpoles" (arrows in Fig. 3). The tubular configuration of the cells explains the original nomenclature of ACC, previously referred to as cylindroma.

Often slow growing, these tumors may remain asymptomatic, or symptoms may be ascribed to other diseases, such as asthma. Plain x-rays are relatively insensitive in detecting tracheal tumors, but it is claimed that high-voltage technique should pick up tumors large enough to be symptomatic. CT scanning is clearly superior but may not indicate mucosal invasion, leading to an underestimation of the longitudinal dimension. Experience with MRI has so far been limited.

Not surprisingly, resection is the preferred management, sometimes requiring removal of a section of the trachea with reanastomosis. There appear to be no series concerning laser treatment, although these tumors may be susceptible to radiation therapy<sup>3</sup>. Since ACC is generally low grade, survival after resection is quite good in spite of the frequency of recurrence and metastatic spread. Survival, however, actually correlates poorly with histology. Survival of 20 years or more is not uncommon<sup>4</sup>, but there is little reported about the natural history of unresected ACC. One series of 62 patients with ACC showed longer survival after complete resection but this was not statistically significant compared with incomplete resection. Moreover, it is not clear if nodal disease impacts survival. In one series resections with positive margins resulted in significantly worse outcomes compared to resections with negative margins<sup>4</sup>. The present patient's history therefore may or may not be typical. Certainly the potential for tracheal occlusion is a major concern. This patient has been spared that complication. His hemoptysis was probably due to his tumor, although it is seen less compared to other symptoms, such as cough, dyspnea or hoarseness<sup>3</sup>.

Recent years have seen a great interest in tyrosine kinase receptors on various tumors, and their susceptibility to treatment with inhibitors (TKI's). Kit protein (CD117) is a type III tyrosine kinase receptor. It was found to be present in thirteen of a series of fourteen patients with ACC<sup>3</sup>. However, nothing has so far been reported regarding treatment of ACC with a TKI.

## REFERENCES

1. **McCarthy MJ, Rosado-de-Christenson ML.** Tumors of the trachea. *J Thorac Imaging.* 1995 Summer;10(3):180-98. Review. PubMed PMID: 7674431.

2. **Kurul IC, Demiroz SM, Celik A, Tuluce K, Aytekin I, Sayan M, Tastepe AI.** Primary pulmonary adenoid cystic carcinoma: report of two cases. *Asian Cardiovasc Thorac Ann.* 2012 Oct;20(5):604-6. doi: 10.1177/0218492312443676. PubMed PMID: 23087312.
3. **Albers E, Lawrie T, Harrell JH, Yi ES.** Tracheobronchial adenoid cystic carcinoma: a clinicopathologic study of 14 cases. *Chest.* 2004 Mar;125(3):1160-5. PubMed PMID: 15006985.
4. **Honings J, Gaissert HA, Weinberg AC, Mark EJ, Wright CD, Wain JC, Mathisen DJ.** Prognostic value of pathologic characteristics and resection margins in tracheal adenoid cystic carcinoma. *Eur J Cardiothorac Surg.* 2010 Jun;37(6):1438-44. doi: 10.1016/j.ejcts.2010.01.005. Epub 2010 Mar 30. PubMed PMID: 20356756.

Submitted on January 30, 2013

Figure 1

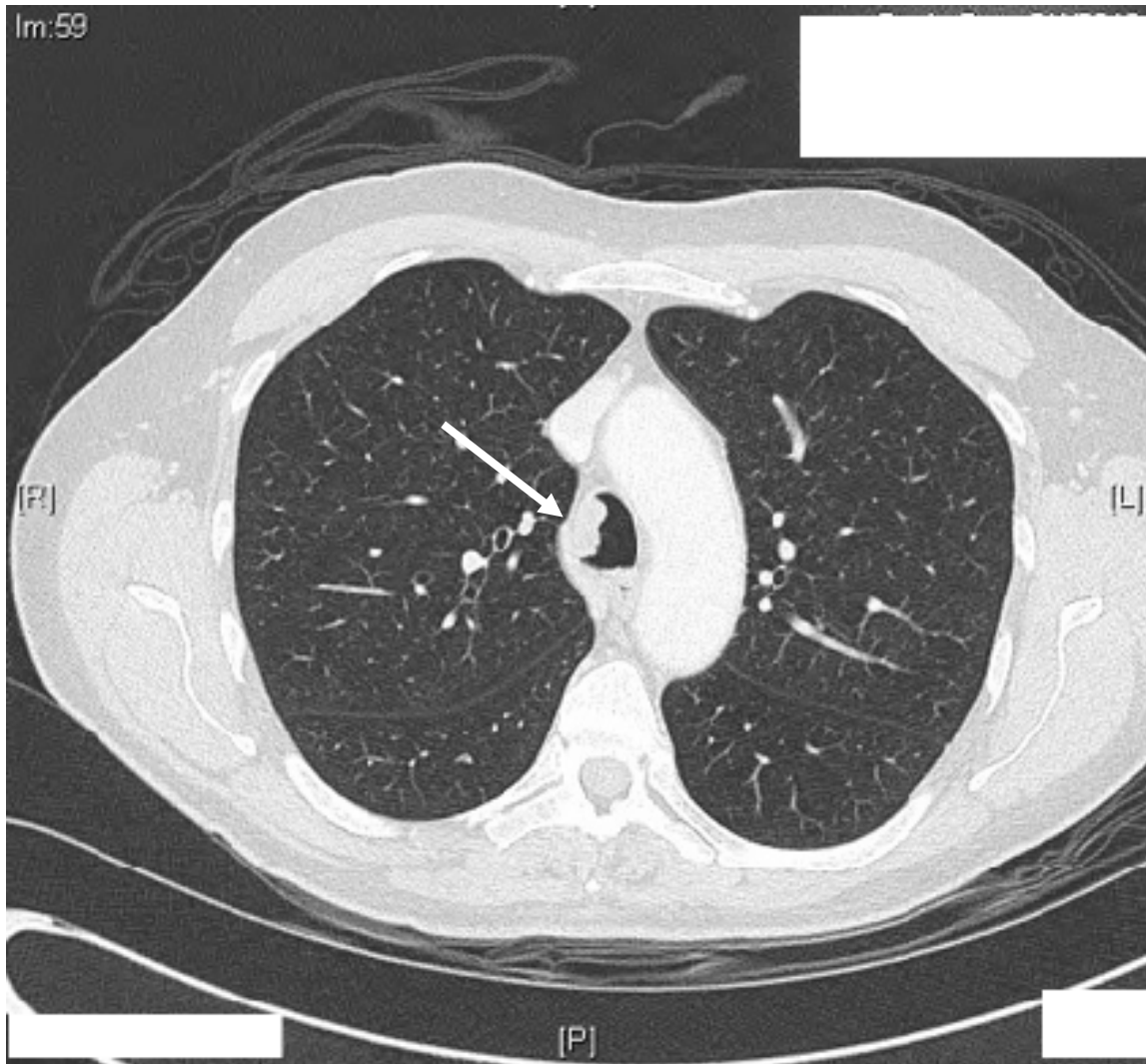
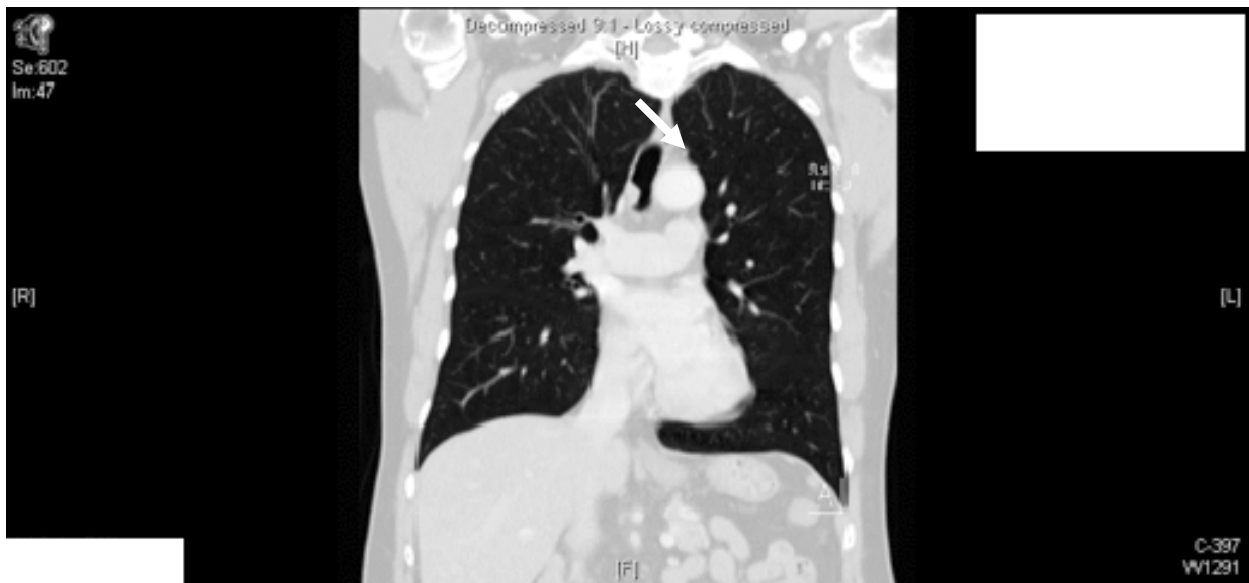

Figure 2



**Figure 3**

