

## CLINICAL VIGNETTE

# Thyrotoxicosis from Metastatic Lung Cancer to the Thyroid Gland: A case report

Archana Sadhu, MD and Dorothy Martinez, MD

### *Introduction*

Thyrotoxicosis from secondary thyroid cancer metastases is extremely rare. However, on autopsy, 1.4% - 24% of metastatic cancers are reported to spread to the thyroid<sup>1-3</sup>. The diagnosis of secondary thyroid metastases may be increasing due to the increased use of imaging for staging of other cancers. Fine needle aspiration cytology can be used to confirm a primary source in these cases. Regardless of the primary source, these metastases in the thyroid are clinically silent and have a poor prognosis<sup>3,4</sup>. In reviewing the literature, there are several cases of thyrotoxicosis from anaplastic thyroid cancer and lymphoma involving the thyroid gland<sup>3,4</sup>. However, only four cases of thyrotoxicosis from extrathyroidal, solid malignancies have been reported<sup>4-7</sup>. The primary malignancies in these cases were lung, pancreas, and breast cancers<sup>4-7</sup>. We report the second case of thyrotoxicosis from metastatic non-small cell lung cancer to the thyroid.

### *Case Report*

A 40-year-old female with a history of recurrent, stage IV non-small cell lung carcinoma (NSCLC) presented with shortness of breath, neck swelling, anterior neck pain, intractable nausea and vomiting. The patient was initially diagnosed with adenocarcinoma of the lung in 1998 and underwent a left lower lung lobectomy, followed by adjuvant chemotherapy. In 2000, she was found to have cervical lymphadenopathy and further workup revealed a left apical mass, multiple superior mediastinal and left hilar nodes. Biopsy of a lymph node in the neck showed recurrent metastatic adenocarcinoma, consistent with the primary malignancy. Over the next two years she had progression of the disease despite further chemotherapy and other investigational drugs. In June 2002, she was

treated with another chemotherapeutic agent, Taxotere, and completed this therapy in late November. In December 2002, she began external beam radiation therapy, which lasted three weeks. During this time, she had noted some shortness of breath, nausea and vomiting. The nausea and vomiting was intractable and the patient required admission in mid January 2003. While in the hospital, she experienced worsening shortness of breath as well as anterior neck pain.

On examination, her heart rate was 110-bpm range. She had a very firm, tender and diffusely enlarged thyroid gland. She also had extensive cervical lymphadenopathy bilaterally. There was no exophthalmos, but a fine tremor of the hands was present. The deep tendon reflexes were normal. On biochemical evaluation, the patient had evidence of mild thyrotoxicosis with an undetectable serum TSH and an elevated free T<sub>4</sub> Index of 15.8. The free T<sub>3</sub> Index and thyroglobulin level were in the normal range. Antithyroglobulin and thyroid peroxidase antibodies were negative. The ESR was elevated at 33mm/hr (Table 1). The day prior to admission, the patient had a CT scan of the neck for repeat staging radiation therapy. The thyroid was diffusely swollen and was causing tracheal narrowing (Fig 1, 2). Ultrasound of the thyroid showed a heterogeneous gland with decreased echogenicity but no fluid collections or nodules. A fine needle aspiration biopsy of the thyroid was performed and the cytologic findings were consistent with metastatic NSCLC. The neoplastic cells were arranged singly and in disorganized aggregates with enlarged, pleomorphic nuclei, prominent nucleoli and moderate amounts of delicate cytoplasm (Fig 3, 4). The patient was treated with intravenous steroids followed by an oral taper to prevent further tracheal compression. Within 10 days,

the TSH increased to 0.09 mIU/mL and the total T<sub>4</sub> and free T<sub>4</sub> index normalized. Two weeks later, she had a total thyroidectomy to protect the airway. The pathology again showed metastatic NSCLC. There was no evidence of inflammation and the follicles were relatively intact among the nests of tumor cells (Fig 5). A mucicarmine stain for mucin was strongly positive in the tumor cells, which is consistent with mucinous adenocarcinoma (Fig 6). The thyroid transcription factor (TTF) immunostain was also positive, but TTF is found both in lung and thyroid tissue (Fig 7). To differentiate between the thyroid tissue and the metastatic tumor, a thyroglobulin immunostain was performed. As expected, it was positive in the thyroid follicles but negative in the adjacent tumor cells (Fig 8). The patient recovered from this surgery but expired a few months later from other pulmonary complications.

### **Discussion**

Like most cases of secondary thyroid cancer, the finding of metastases in the thyroid gland was coincidental. A staging CT of the neck was performed after radiation therapy but she soon developed compressive symptomatology. When this finding was investigated further, she was noted to have clinical and biochemical evidence of hyperthyroidism.

### **Summary of previous cases in the literature**

#### ***Pancreatic Adenocarcinoma***

The first reported case we found in the English literature was from 1977. It described hyperthyroidism from thyroid metastasis of pancreatic adenocarcinoma in a 54-year-old man who rapidly developed a nontender goiter. The thyroxine level of 20 µg/dL (normal 3.5–13), T<sub>3</sub> resin uptake was 38 % (normal 25-35) and free thyroxine index was 23 (normal 3.5-15). The TSH was not reported. A 24-hour thyroid uptake scan with <sup>131</sup>I was 0.6% (normal 7%-33%). A needle biopsy of the thyroid showed invasion and disruption of the thyroid follicles by the neoplastic cells. In this case, it was presumed that the release of thyroglobulin by the disrupted follicles was responsible for the hyperthyroxinemia. Of note, the patient had received high doses of dexamethasone and radiation therapy to the brain and the primary pancreatic lesion prior to the development of the thyroid enlargement and dysfunction. Subsequent thyroid function tests approximately 3 weeks

later showed a spontaneous return of the thyroid function studies to the upper normal range. The patient then received a course of irradiation to the neck, which resulted in a decrease in the size of the thyroid. However, the thyroxine values increased again after the course of thyroid irradiation. Post mortem thyroid histology showed invasion, disruption, and replacement of thyroid follicles by the tumor cells in most of the thyroid<sup>7</sup>.

#### ***Breast Carcinoma***

The next two cases were both reported in 1978 and involve metastases from breast cancer. A 25-year-old woman complained of 4 months of fatigue, shortness of breath, palpitations, anorexia, weight loss and nausea and vomiting. On examination, she was tachycardic and had a diffusely enlarged, non-tender thyroid. The serum thyroxine was elevated at 220 nmol/l (normal 70-160), as was the T<sub>3</sub> at 4.1 nmol/L (normal 1.2-2.8). The TSH was undetectable and the thyroid antibodies were reported as negative. <sup>131</sup>I uptake at 2 and 24 hours was less than 2% without any localized concentration in the neck region. A measurement of PB <sup>131</sup>I at 24 hours was low and plasma inorganic iodine and urinary iodine excretion were within the normal range. A thyroid biopsy was done which suggested a primary thyroid carcinoma. However, on subsequent total thyroidectomy, the pathology showed a moderately differentiated adenocarcinoma that was diffusely infiltrating the thyroid. The follicular architecture was intact and there was not any evidence of thyroiditis. The mechanism in this case was suspected to be related to the release of local “active agents”, possibly prostaglandins, which cause hormone release but not iodine uptake by the follicles<sup>5</sup>.

The second case is of a 51-year-old woman with a history of breast carcinoma treated three years prior who presented with a sensation of choking, swelling of the neck and anterior neck pain. On biochemical evaluation, she had a TSH of 1.3 µU/mL (normal < 10) and a thyroxine level of 11.9µg/dL (normal 4.5-11). The T<sub>3</sub> resin uptake was 32.8% (normal 25-35) and the ESR was high at 60 mm/h. In this case, however, the thyroglobulin and microsomal antibodies were positive at 1:320 and 1:400 respectively (normal <1:100). Again, the <sup>131</sup>I 24 hour uptake was suppressed at 1%. This patient was initially treated with acetylsalicylic acid for a presumptive diagnosis of thyroiditis. When her

course worsened with continued enlargement of the thyroid, prednisone was added to the regimen. A thyroid biopsy was done three weeks later, which was interpreted as papillary carcinoma without any evidence of thyroiditis. Subsequently, a right subtotal thyroid lobectomy was performed which revealed metastatic breast carcinoma with very little normal thyroid tissue present. Again, there was not any evidence of inflammation. The authors of this case concluded that the hyperthyroxinemia was due to "hormone leakage". They also suggested that abnormal circulating iodoproteins, which have been described in cases of both carcinoma and thyroiditis, may cause this leakage phenomenon. In this article, the term carcinomatous pseudothyroiditis was used to describe this process.

### ***Lung Adenocarcinoma***

Excluding the present case, there is only one other report in the literature of severe thyrotoxicosis induced by thyroid metastasis of lung adenocarcinoma. In this case, a 50-year-old woman was diagnosed with stage IV poorly differentiated lung adenocarcinoma and underwent a lung lobectomy. One month after surgery, she developed neck swelling, tachycardia, and a fine finger tremor. Unlike our patient, she did not have any neck tenderness. There were no signs of ophthalmopathy but she did have extensive bilateral cervical and supraclavicular lymphadenopathy. The T<sub>3</sub> level was 51 ng/dL (normal 90-70ng/dL) and the T<sub>4</sub> level was 26.4 µg/dL (normal 5-11.4 µg/dL) with a T<sub>3</sub>/T<sub>4</sub> ratio of 19.4. The free T<sub>3</sub> and free T<sub>4</sub> were also markedly elevated at 21.8 pg/mL (normal 2.5-5 pg/mL) and 8.8 ng/dL (normal 0.95-1.85 ng/dL), respectively. The TSH was suppressed at <0.005 µU/mL (normal 0.5-4.43 µU/mL). The serum thyroglobulin (Tg) was markedly elevated as well at 1,714 ng/mL (normal <35 ng/mL). The thyrotropin receptor antibody (TRAb) was normal and the thyroid peroxidase and antithyroglobulin antibodies were negative. Thyroid uptake scan revealed 4% uptake at 24 hours in the neck, without any uptake elsewhere. Thyroid ultrasound showed an inhomogeneous and hypoechoic internal architecture without obvious tumor or calcification. A fine needle aspiration biopsy disclosed tumor cells infiltrating the thyroid gland, but no fibrosis or lymphocytic infiltration was observed. The tumor cells matched the previously resected lung pathology and were not

thyroglobulin positive on immunostaining. Therefore a diagnosis of metastatic lung adenocarcinoma was confirmed. This patient was treated with beta-blocker therapy only and the thyroid hormone levels normalized over the next few weeks and with progression to hypothyroidism shortly thereafter. The authors report that over the following months, the thyroid gland again increased in size and her condition deteriorated rapidly leading to respiratory failure and death. The authors in this case report concluded that a destructive thyroiditis was responsible for this transient thyrotoxicosis<sup>4</sup>.

In the present case, the mechanism for thyrotoxicosis is unclear, but several interesting comparisons are noteworthy. The first is the variability in the presence of pain with an enlarging goiter. Only one other patient with metastatic breast cancer had anterior neck pain similar to our patient. Although pain is usually associated with a subacute thyroiditis, it may be explained by the rapid enlargement of the thyroid due to the aggressive growth of the tumor cells. All the patients had biochemical evidence of thyrotoxicosis and in those patients in which a T<sub>3</sub>/T<sub>4</sub> ratio could be calculated, it was less than 20. This finding suggests a sudden release of stored thyroid hormone from the gland. However, with this mechanism, we should expect a consistently elevated thyroglobulin level. Although we do not have this data for all the cases, the thyroglobulin level was normal in our patient but markedly elevated in the other patient with metastatic lung carcinoma. The ESR, when available, was elevated consistently in all of the patients. This would suggest a subacute thyroiditis, but none of the patients were reported to have evidence of inflammation on pathology. Only one patient had positive thyroid peroxidase and antithyroglobulin antibodies. All of the patients who had iodine uptake scan showed suppressed uptake at 24 hours, which is consistent with an inflammatory thyroiditis or release of hormone from a destructive thyroiditis rather than increased synthesis of hormone by the gland. The most interesting comparison, though, is in the thyroid pathology. Only our patient and the patient with metastatic breast carcinoma described by Edmonds et al. had pathology available from total thyroidectomy. It was specifically stated in both of these pathology reports that the follicular architecture remained largely intact, which makes destructive thyroiditis unlikely. However,

the patient with pancreatic carcinoma was reported to have disrupted follicles on post mortem thyroid pathology and he was documented to have hyperthyroxinemia a few weeks prior to his death. Nevertheless, none of the cytology or pathology reports had evidence of inflammation or thyroiditis.

Given these variable and sometimes contradictory findings, we are unable to explain the hyperthyroidism in this context by any one mechanism. In our patient, it would have been helpful to have results of an uptake scan and some other immunological markers such as TSI or TRAb antibodies. Unfortunately, the scan was not able to be performed because our patient had received iodinated contrast dye for a CT scan just prior to presentation. It could be argued that our patient may have had iodine induced hyperthyroidism, but she lacked the typical underlying nodular goiter in which this phenomenon generally occurs. The other immunological markers for Grave's disease may have also been useful, but this possibility is unlikely given the low ratio of circulating levels of T3 to T4.

For the interest of discussion, we suggest the possibility that humoral factors released from the tumor cells stimulate the follicles to release thyroid hormone via a TSH independent mechanism. These factors may be acting via both paracrine and endocrine fashion. While this is an interesting theory, we were unable to investigate with any further studies on this patient.

Unlike primary thyroid cancer, the clinical course of secondary thyroid cancer is correlated with a poor survival<sup>2-4</sup>. In all of the cases of secondary thyroid metastases, the patients had a short survival after diagnosis<sup>3,4</sup>. For this reason, the nature of the relationship of these cancers to thyroid function deserves more investigation.

#### **Acknowledgements**

Sunita Bhuta, M.D. and Sharon Hirschowitz, M.D. Department of Pathology UCLA David Geffen School of Medicine.

## REFERENCES

1. **Shimaoaka K, Sokal JE, Pickren JW.** Metastatic neoplasms in the thyroid gland. Pathological and clinical findings. *Cancer*. 1962 May-Jun;15:557-65. PubMed PMID: 13911946.
2. **Silverberg SG, Vidone RA.** Metastatic tumors in the thyroid. *Pacific Med Surg* 1966; 74:175-80.
3. **Lin JD, Weng HF, Ho YS.** Clinical and pathological characteristics of secondary thyroid cancer. *Thyroid*. 1998 Feb;8(2):149-53. PubMed PMID: 9510123.
4. **Miyakawa M, Sato K, Hasegawa M, Nagai A, Sawada T, Tsushima T, Takano K.** Severe thyrotoxicosis induced by thyroid metastasis of lung adenocarcinoma: a case report and review of the literature. *Thyroid*. 2001 Sep;11(9):883-8. Review. PubMed PMID: 11575859.
5. **Edmonds CJ, Thompson BD.** Hyperthyroidism induced by secondary carcinoma in the thyroid. *Clin Endocrinol (Oxf)*. 1978 May;8(5):411-5. PubMed PMID: 647992.
6. **Trokoudes KM, Rosen IB, Strawbridge HT, Bain J.** Carcinomatous pseudothyroiditis: a problem in differential diagnosis. *Can Med Assoc J*. 1978 Oct 21;119(8):896-8. PubMed PMID: 737640; PubMed Central PMCID: PMC1819090.
7. **Eriksson M, Ajmani SK, Mallette LE.** Hyperthyroidism from thyroid metastasis of pancreatic adenocarcinoma. *JAMA*. 1977 Sep 19;238(12):1276-8. PubMed PMID: 578180.

Submitted on January 30, 2013

Table 1: Patient's Laboratory Studies		
Laboratory Test	Patient's Result	Normal Range
TSH	<0.02	0.3-4.7 mIU/mL
Free T4 Index	15.8	4.5-10.5
Total T4	12.6	4.9-11.4 mcg/dL
Free T3 Index	128	78-162
Total T3	102	85-185 ng/dL
Thyroglobulin	9.7	0-40.0 ng/mL
Tg Antibody	<2.0	<2.0 IU/mL
TPO Antibody	<2.0	<2.0 IU/mL
Westergren ESR	33	0-20 mm/hr

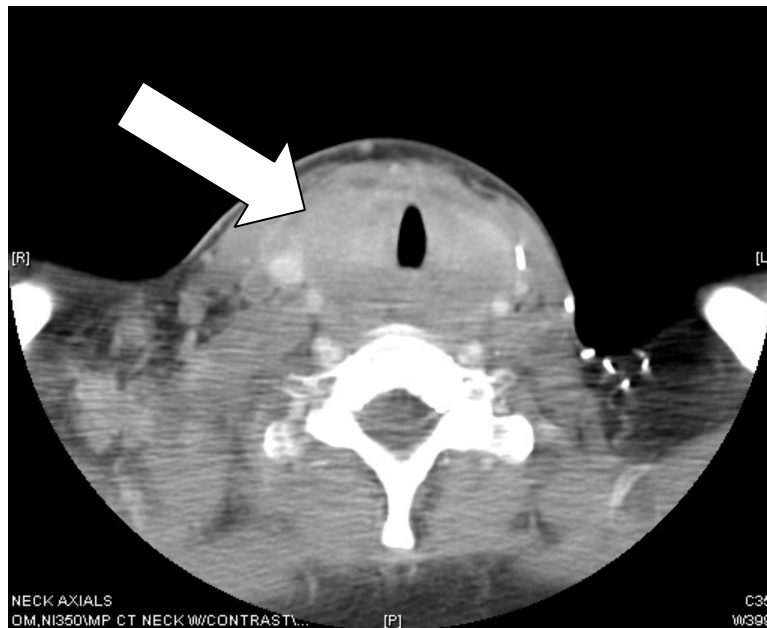

Figure 1. CT Scan of the Neck with contrast  
The arrow points to a diffusely enlarged thyroid gland, which encompasses the trachea.

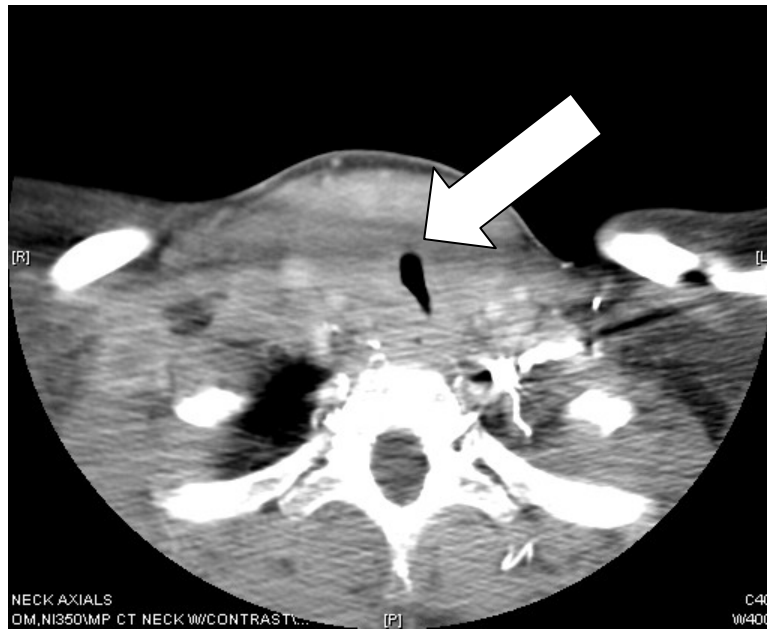
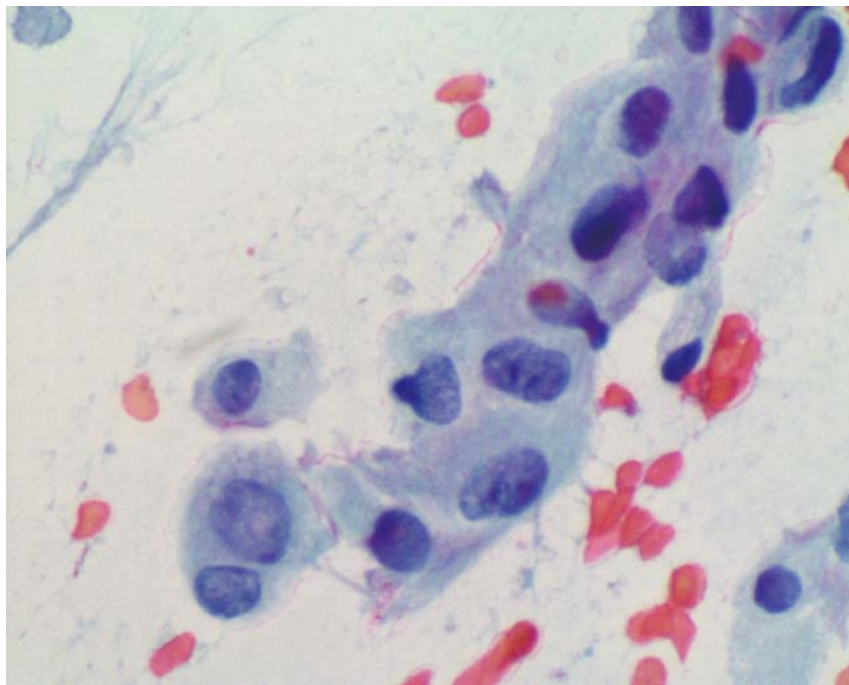


Figure 2. CT scan of the neck with contrast  
The arrow shows the tracheal narrowing and displacement of  
the neck vessels laterally.



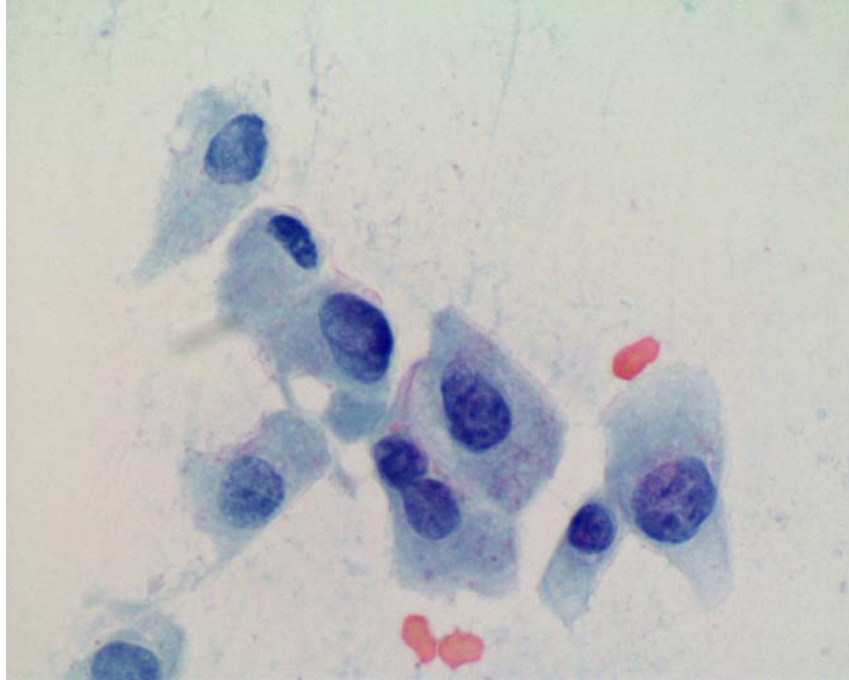


Figure 3 and 4. Fine needle aspiration biopsy of the thyroid. Neoplastic cells arranged singly and in disorganized aggregates are shown with enlarged, pleomorphic nuclei, prominent nucleoli and moderate amounts of delicate cytoplasm. (Papanicolaou stain, X 400).

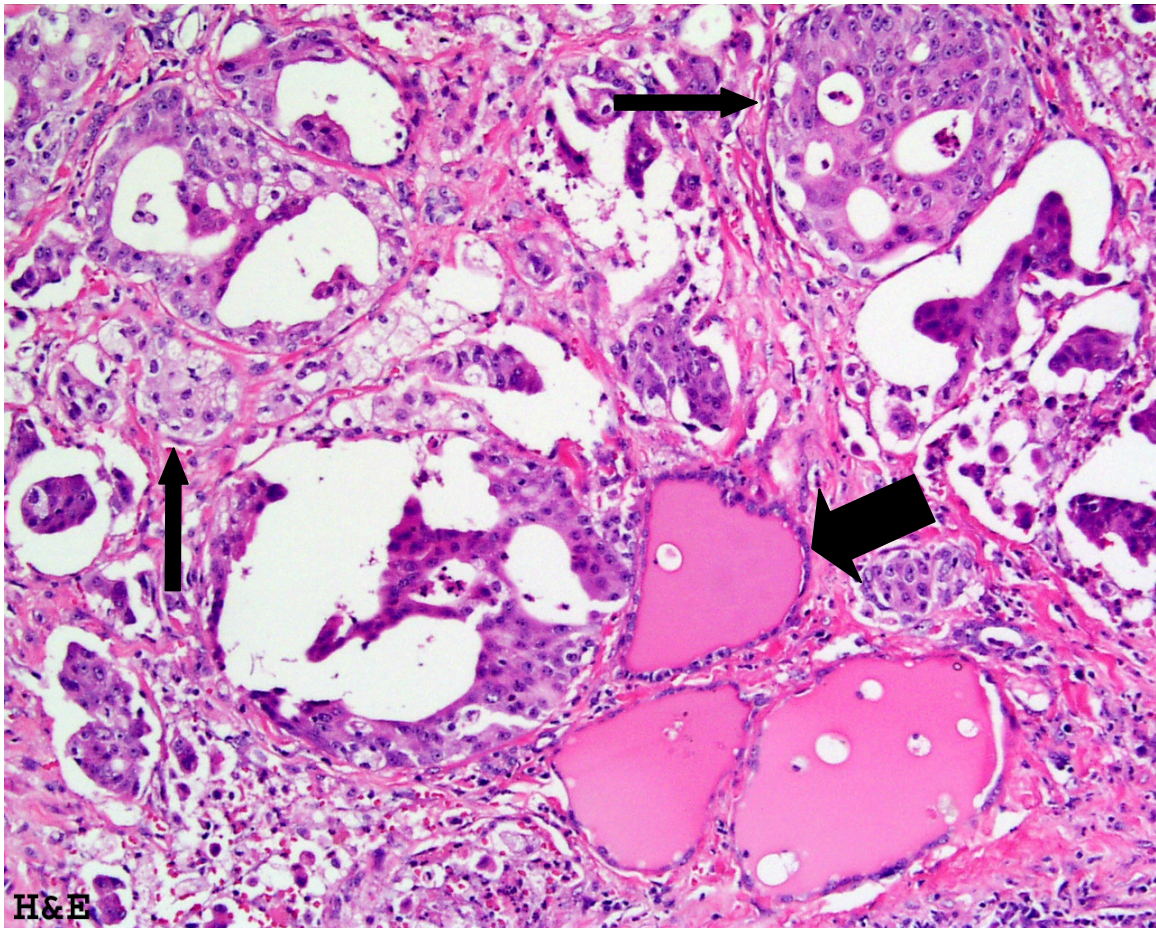


Figure 5. H&E Stain of the thyroid

Thick arrow: Normal appearing and intact thyroid follicles filled with colloid and lined by a single layer of low cuboidal epithelium. Thin arrow: Metastatic tumor cells in solid nests and glandular structures consistent with adenocarcinoma.

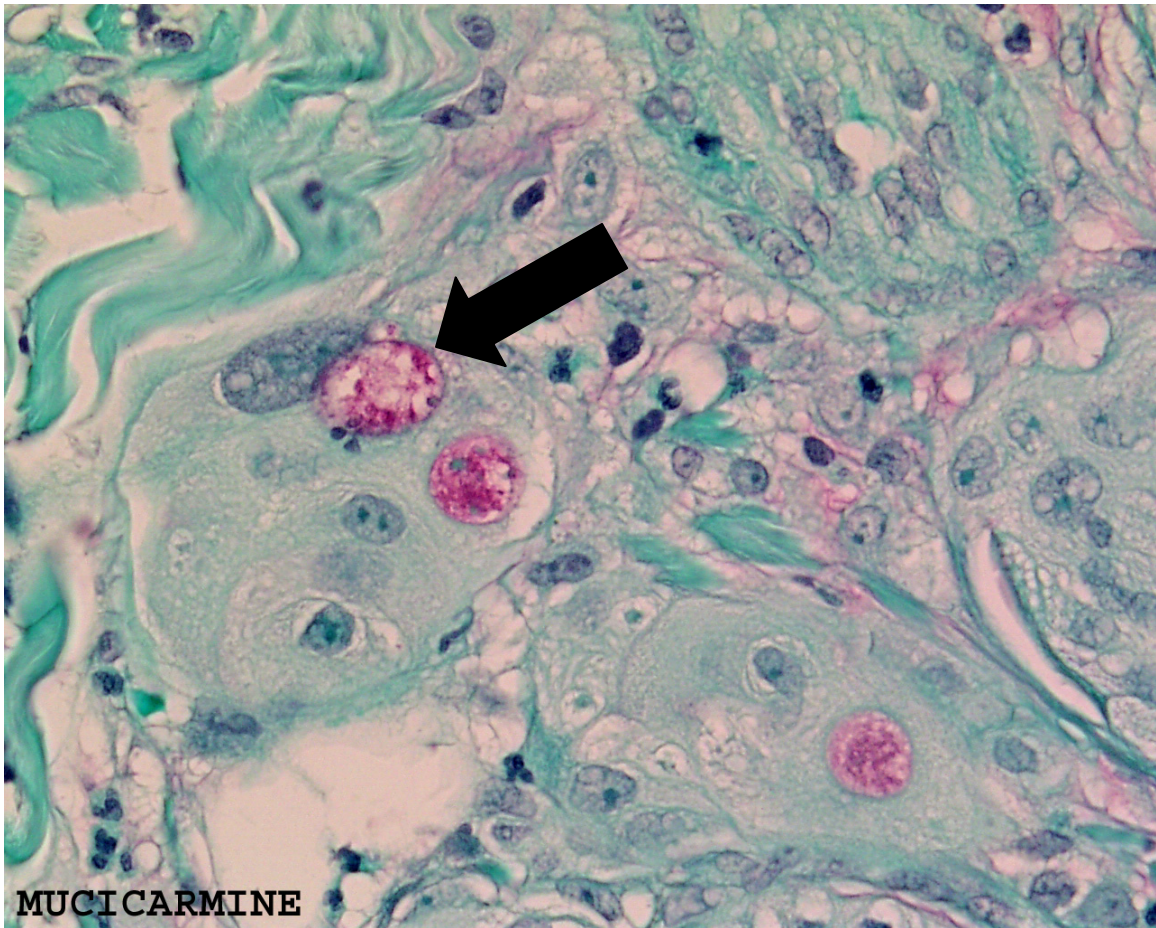


Figure 6. Mucicarmine stain  
An intracytoplasmic stain for mucin is strongly positive (pink), which is consistent with a mucinous adenocarcinoma.

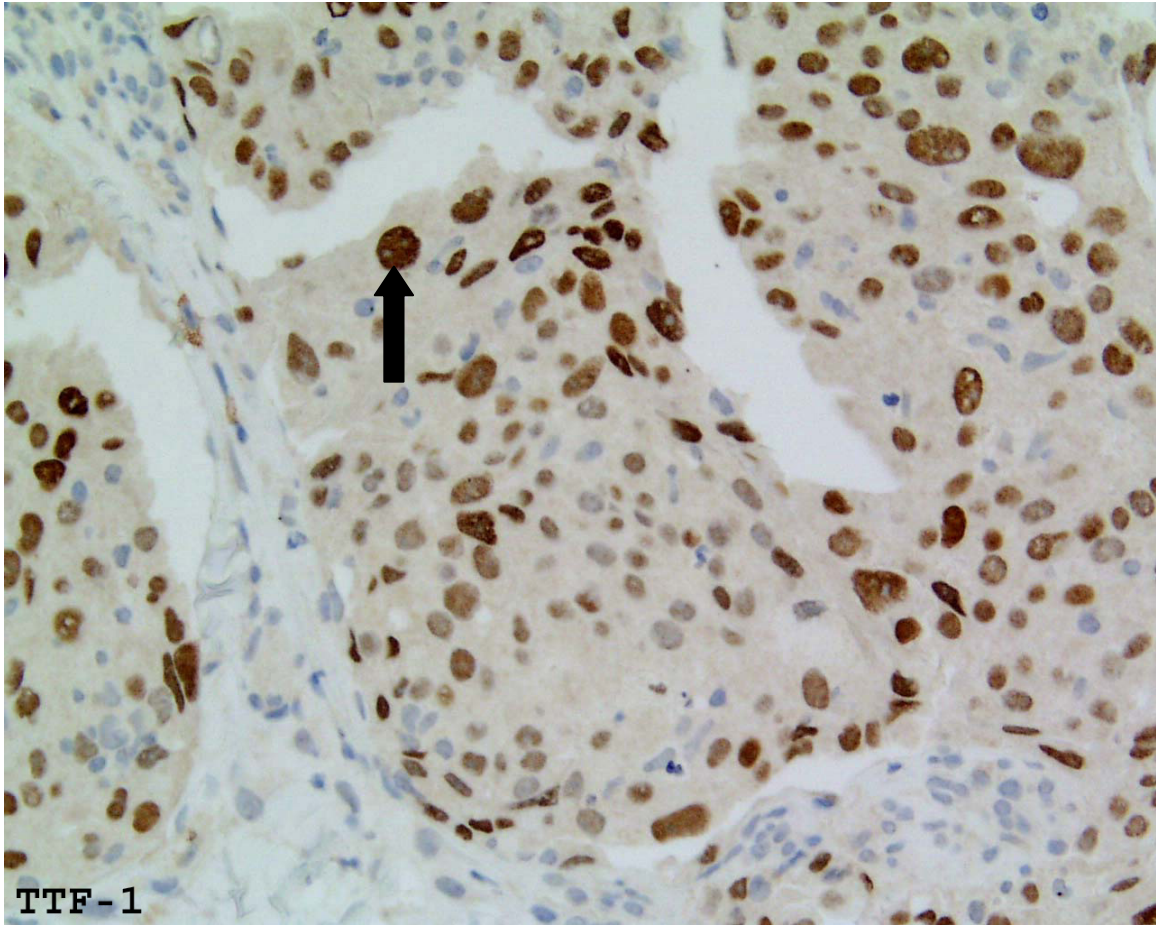


Figure 7. TTF-1 Immunostain  
A nuclear stain for thyroid transcription factor (TTF) is positive (brown) in the tumor cells. However, TTF is found in both lung and thyroid tissue.

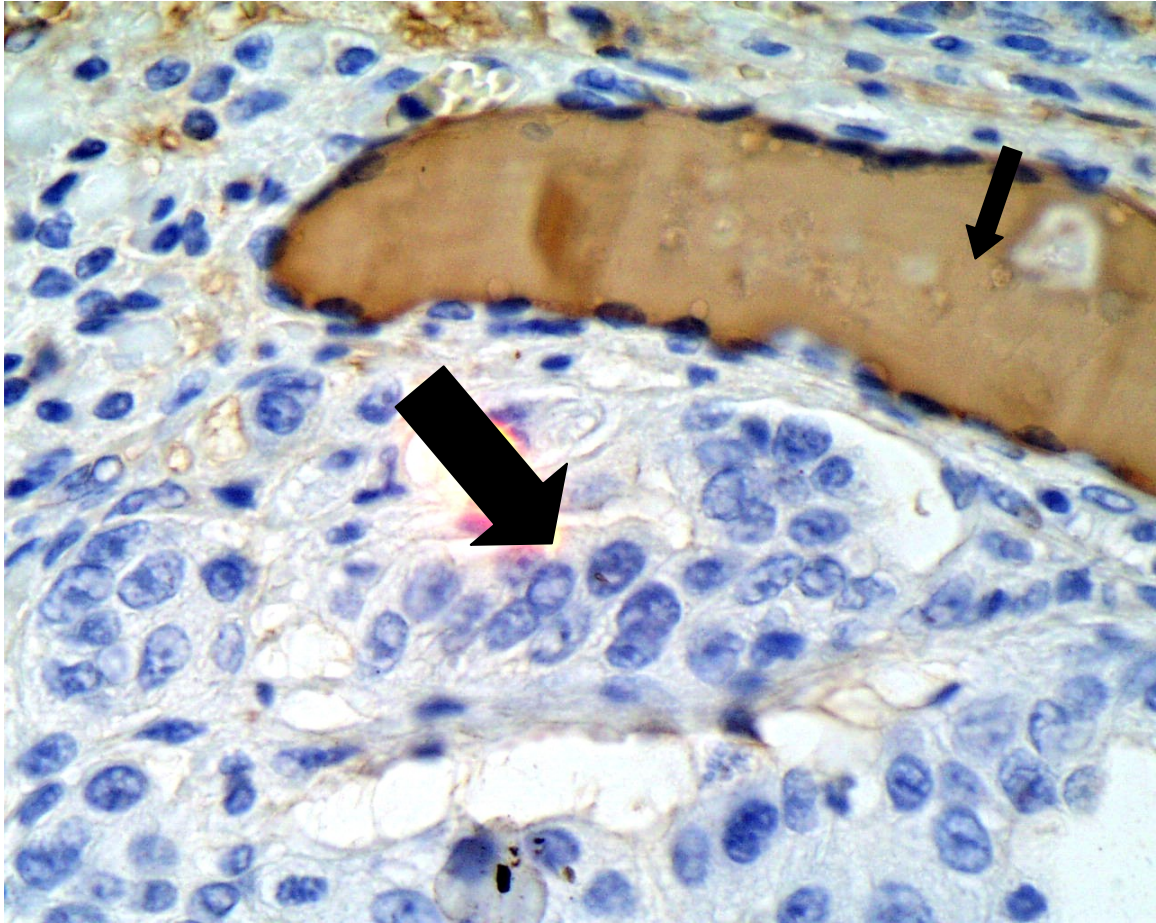


Figure 8. Thyroglobulin Immunostain  
The metastatic carcinoma (thick arrow) fails to stain with thyroglobulin, while the adjacent thyroid follicle (thin arrow) shows strong positive staining in brown.