

CLINICAL VIGNETTE:

Dextrocardia with Situs Inversus: Through the Looking Glass with an ECG

Sanjay Bindra, M.D., Ramin Tabibiazar, M.D., Michael Mazar, M.D., and Ravi Dave, M.D.

A 56-year-old male with history of hypertension, diabetes mellitus type 2 and hypothyroidism presented to the cardiology clinic for evaluation of an abnormal electrocardiogram.

His examination revealed that he was a slightly obese male in no apparent distress. His resting blood pressure was 150/86. His pulse was 92. His jugular venous pressure was elevated to 8cm. There were soft bilateral carotid bruits. His cardiac examination performed on the right anterior thorax revealed an apical impulse in the *right* fifth intercostal space at the mid-clavicular line. There were no palpable thrills. There was presence of a 4th heart sound. There was a grade 2/6 soft systolic ejection murmur. His lungs were cleared to auscultation. His abdominal exam revealed no masses. There were normal pulses felt in the lower extremities. There was no evidence of peripheral edema.

His electrocardiogram revealed: See figure 1 and figure 2, figure legend.

If this EKG pattern (figure 2) is seen with normal electrode position, it suggests reversed placement of left and right arm leads, with normal R wave progression across precordium).

EKG Findings for Dextrocardia

To recognize the EKG changes associated with a dextrocardia, it is important to have a clear understanding of the electrical axis.

- Global negativity in lead I (a negative P-wave, QRS complex and T-wave)
- Positively deflected QRS complex in aVR
- Negative P-wave in lead II
- Reverse R-wave progression in precordial leads
- Right axis deviation.

Right axis deviation is normally due to a pathological cause such as left posterior fascicular block. Extreme right axis deviation, or ERAD, is normally only seen with ventricular rhythms, such as ventricular tachycardia or paced rhythms. ERAD may be a normal finding with a patient who has dextrocardia¹.

On a standard ECG with normal heart placement, lead I will almost always be positive and lead aVR negative with any supraventricular rhythm.

The finding of a positively deflected QRS complex in aVR and a negatively deflected QRS complex in lead I should cause concern. **The most common cause for this finding is reversed electrode placement of arm leads (left and right).**

However, in arm lead reversal, the precordial leads reveal a normal R wave progression (since the heart is on the left side).

In dextrocardia, since the heart is on the right side of the chest, the left ventricular apex is at the right midclavicular line. The left precordial leads reveal reversed R wave progression; the R wave is tallest in V1 and progressively decreases in amplitude in leads V2 to V6 (see figure 1, figure legend below). On performance of a right-sided EKG, normal R wave progression is noted (see figure 2, figure legend below).

If this EKG pattern (figure 2) is seen with normal electrode position, it suggests reversed placement of left and right arm leads, with normal R wave progression across precordium).

CXR: The patient's chest film revealed evidence of dextrocardia and situs inversus (fundus gas bubble on the right and the liver on the left) 2.

Discussion

Dextrocardia situs inversus is a congenital condition characterized by a heart that is horizontally inverse, or mirrored. Mirror-image dextrocardia is the most common form of cardiac malposition encountered and is almost always associated with situs inversus of the abdominal organs. The anatomic right ventricle is anterior to the left ventricle and the aortic arch curves to the right and posteriorly. The anatomic right lung with its three lobes is on the left side. The gastric fundus gas bubble is on the right and the liver on the left. Generally, there is no increased risk of an infracardiac malformation.

Recognizing the presence of dextrocardia will also help avoid unnecessary workup for an abnormal ECG.

Conclusion

While dextrocardia is one of those rare conditions that the average clinician may infrequently encounter, it is important to have an understanding of the EKG pattern and to distinguish it

from the common lead misplacement (left and right arm reversal), where the precordial leads will show normal QRS pattern. Another consideration for treatment is the placement of pacer or defibrillator pads. Effectiveness of defibrillation would be limited if normal placement were utilized. To deliver the most beneficial amount of energy, use anterior/posterior placement just to the right of the patient's sternum. Traditional pad placement can be mirrored as well³.

REFERENCES

1. Jones MB, Glancy DL, Jain N. ECG of the month: Right-axis deviation of the QRS complex with precordial R-wave regression. Situs inversus with mirror image dextrocardia, sinus rhythm, and a long P-R interval. *J La State Med Soc* 161(3):125-128, May-Jun 2009.
2. Maldjian RD, Saric M. Approach to dextrocardia in adults: Review. *American Journal of Roentgenology*. 2007;188:S39-S49.
3. Gorenek B, Kuskus S, Kudaiberdieva G, et al. Electrical cardioversion of atrial fibrillation in a case of dextrocardia. *Can J Cardiol* 20(8):819-821, Jun 2004. Comment in *Can J Cardiol* 21(1):99, Jan 2005; author reply pp. 99-100.

Submitted on June 30, 2011

FIGURE LEGEND:

EKG (normal lead positions):

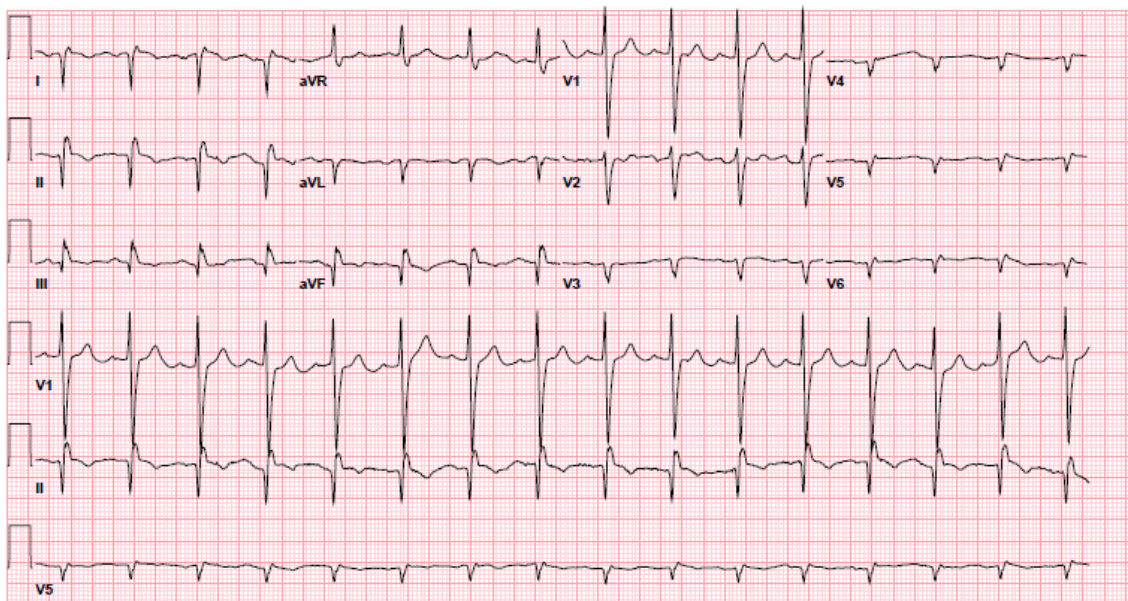


Figure 1. ECG showing marked right-axis deviation of the P wave (negative in aVL and lead I) and of the QRS complex, and low voltage in the precordial leads, V₄ through V₆. Lead aVR is similar to the normal aVL in the normal ECG.

Right-sided EKG:

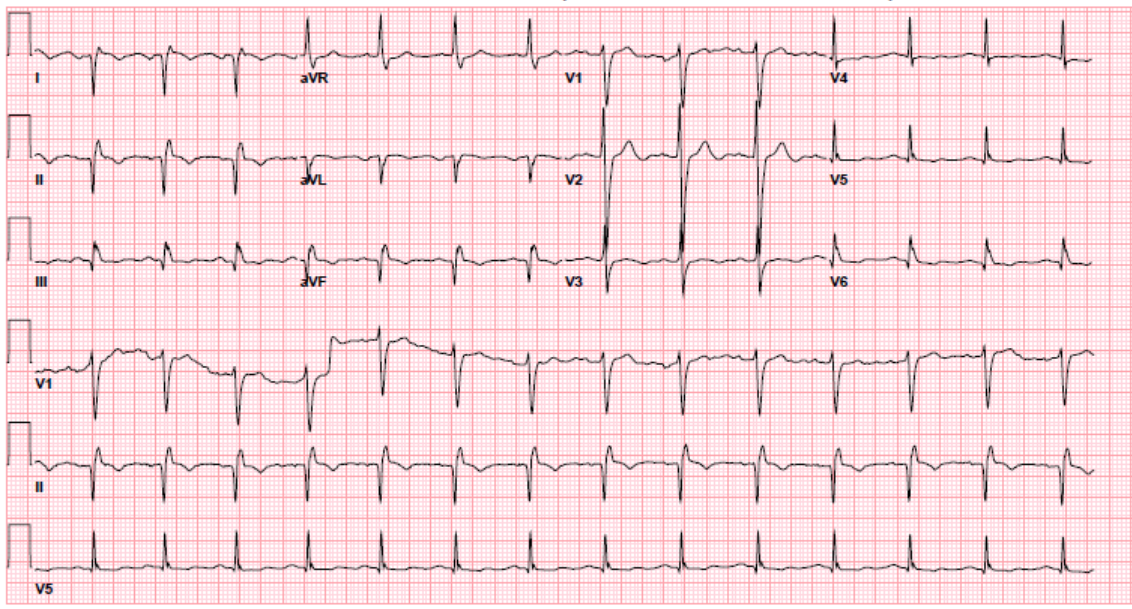


Figure 2. ECG showing marked right-axis deviation of the P wave (negative in aVL and lead I) and of the QRS complex, and normal progression of R waves across the precordium (right sided leads). Lead aVR is similar to the normal aVL in the normal ECG.

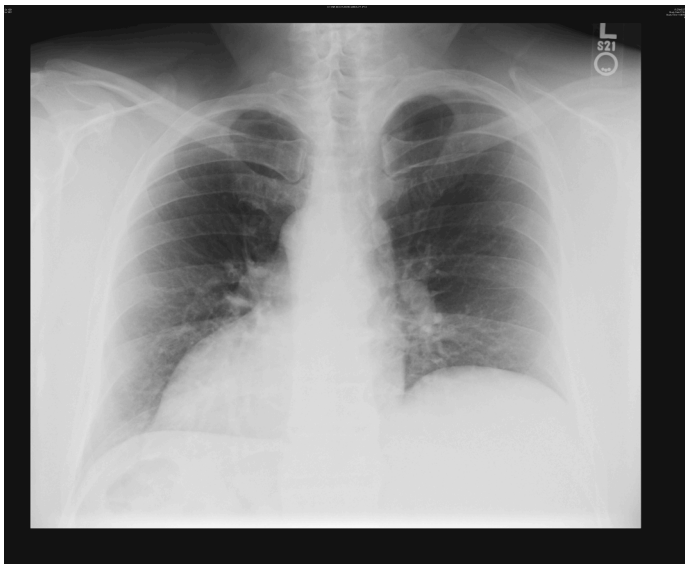


Figure 3. Chest x-ray showing dextrocardia and right-sided gastric air bubble indicating the presence of both dextrocardia and situs inversus (the most common combination).